


D  
0  
0  
0  
2  
3  
0  
7  
4  
6  
0



UNIVERSITY OF SOUTHERN CALIFORNIA LIBRARY FACILITY

*Presented by*

Alfons I. Wray, D. C., F. O. C. O.



COLLEGE OF OSTEOPATHIC PHYSICIANS  
AND SURGEONS • LOS ANGELES, CALIFORNIA













# AN AMERICAN TEXT-BOOK OF DISEASES OF THE EYE, EAR, NOSE, AND THROAT

*De Schweinitz, George Edmund, etc.*

EDITED BY

G. E. DE SCHWEINITZ, A. M., M. D.

Professor of Ophthalmology in the Jefferson Medical College, Philadelphia; Consulting  
Ophthalmologist to the Philadelphia Polyclinic; Ophthalmic Surgeon to  
the Philadelphia Hospital and to the Orthopedic Hospital  
and Infirmary for Nervous Diseases

AND

B. ALEX. RANDALL, M. A., M. D., PH.D.

Clinical Professor of Diseases of the Ear in the University of Pennsylvania; Professor  
of Diseases of the Ear in the Philadelphia Polyclinic; Ophthalmic and  
Aural Surgeon to the Methodist and Children's Hospitals,  
Philadelphia

ILLUSTRATED WITH 766 ENGRAVINGS,  
59 OF THEM IN COLORS

PHILADELPHIA  
W. B. SAUNDERS  
925 WALNUT STREET

1899

WW100  
D416a  
1997

---

Copyright, 1899.  
By W. B. SAUNDERS.

---

---

ELECTROTYPED BY  
WESTCOTT & THOMSON PHILADA.

---

PRESS OF  
W. B. SAUNDERS, PHILADA



## CONTRIBUTORS.

- HENRY A. ALDERTON, M. D.,  
Chief of Aural Clinic, Polhemus Memorial Clinic, Long Island Medical College; Aural Surgeon to the Brooklyn Eye and Ear Hospital. BROOKLYN, N. Y.
- HARRISON ALLEN, M. D.,  
Late Professor of Comparative Anatomy, University of Pennsylvania; late Professor of Diseases of the Nose and Throat, Philadelphia Polyclinic. PHILADELPHIA, PA.
- FRANK ALLPORT, M. D.,  
Professor of Ophthalmology, Chicago Polyclinic; Professor of Ophthalmology and Otology, Northwestern University, Woman's Medical College. CHICAGO, ILL.
- MORRIS J. ASCH, M. D.,  
Surgeon to the Throat Department of the New York Eye and Ear Infirmary; Surgeon to the Throat Department, Manhattan Eye and Ear Hospital. NEW YORK CITY.
- S. C. AYRES, M. D.,  
Professor of Ophthalmology and Otology, Medical College of Ohio, Medical Department of the University of Cincinnati. CINCINNATI, OHIO.
- R. O. BEARD, M. D.,  
Professor of Physiology in the Department of Medicine of the University of Minnesota. MINNEAPOLIS, MINN.
- CLARENCE J. BLAKE, M. D.,  
Professor of Otology, Harvard Medical School; Aural Surgeon to the Massachusetts Charitable Eye and Ear Infirmary. BOSTON, MASS.
- ARTHUR AMES BLISS, A. M., M. D.,  
Laryngologist and Aurist to the German Hospital; late Attending Laryngologist to the Pennsylvania Institution for the Deaf and Dumb. PHILADELPHIA, PA.
- A. P. BRUBAKER, M. D.,  
Adjunct Professor of Physiology and Hygiene, Jefferson Medical College; Professor of Physiology and General Pathology, Pennsylvania College of Dental Surgery. PHILADELPHIA, PA.
- J. H. BRYAN, M. D.,  
Late Passed Assistant Surgeon, U. S. Navy; Surgeon to the Throat and Ear Department, Garfield Memorial Hospital. WASHINGTON, D. C.
- ALBERT H. BUCK, M. D.,  
Clinical Professor of Diseases of the Ear, College of Physicians and Surgeons, Medical Department of Columbia University; Consulting Aural Surgeon, New York Eye and Ear Infirmary. NEW YORK CITY.
- F. BULLER, M. D.,  
Professor of Ophthalmology and Otology, McGill University; Ophthalmic and Aural Surgeon to the Royal Victoria Hospital. MONTREAL, CANADA.
- SWAN M. BURNETT, M. D.,  
Professor of Ophthalmology and Otology, Medical Department, Georgetown University; Director of the Eye and Ear Clinic, Central Dispensary and Emergency Hospital. WASHINGTON, D. C.
- FLEMMING CARROW, M. D.,  
Professor of Ophthalmology and Otology, University of Michigan. ANN ARBOR, MICH.

- W. E. CASSELBERRY, M. D.,  
Professor of Laryngology and Rhinology, Northwestern University Medical School. CHICAGO, ILL.
- COLMAN W. CUTLER, M. D.,  
Attending Ophthalmologist to St. Luke's and R. I. Hospitals; Assistant Surgeon, New York Eye and Ear Infirmary. NEW YORK CITY.
- EDWARD B. DENCH, PH. B., M. D.,  
Professor of Otolaryngology, University and Bellevue Hospital Medical College; Consulting Otolaryngologist to St. Luke's Hospital. NEW YORK CITY.
- WM. S. DENNETT, A. B., M. D.,  
Surgeon to the New York Eye and Ear Infirmary. NEW YORK CITY.
- G. E. DE SCHWEINITZ, A. M., M. D.,  
Professor of Ophthalmology, Jefferson Medical College; Ophthalmic Surgeon to the Philadelphia Hospital; Consulting Ophthalmologist to the Philadelphia Polyclinic. PHILADELPHIA, PA.
- ALEXANDER DUANE, M. D.,  
Assistant Surgeon and Instructor in Physiological Optics, New York Ophthalmic and Aural Institute. NEW YORK CITY.
- JOHN W. FARLOW, M. D.,  
Physician for Diseases of the Nose and Throat, Boston City Hospital; Instructor in Laryngology, Harvard University, Boston. BOSTON, MASS.
- WALTER J. FREEMAN, M. D.,  
Professor of Diseases of the Nose and Throat, Philadelphia Polyclinic; Laryngologist to the Orthopedic and Children's Hospitals. PHILADELPHIA, PA.
- H. GIFFORD, B. S., M. D.,  
Professor of Ophthalmology and Otolaryngology, Omaha Medical College. OMAHA, NEB.
- W. C. GLASGOW, M. D.,  
Professor of the Practice of Medicine, Diseases of the Chest, and Laryngology, Missouri Medical College. ST. LOUIS, MO.
- J. ORNE GREEN, M. D.,  
Clinical Professor of Otolaryngology, Harvard University; Visiting Aural Surgeon, Boston City Hospital. BOSTON, MASS.
- WARD A. HOLDEN, A. M., M. D.,  
Assistant in the Eye Department of the Vanderbilt Clinic, College of Physicians and Surgeons, Columbia University; Pathologist to the New York Ophthalmic and Aural Institute. NEW YORK CITY.
- CHRISTIAN R. HOLMES, M. D.,  
Professor of Otolaryngology, Miami Medical College; Ophthalmic Surgeon, Cincinnati Hospital. CINCINNATI, OHIO.
- WILLIAM E. HOPKINS, M. D.,  
Professor of Ophthalmology, Post-Graduate Medical Department, University of California; Associate Professor of Ophthalmology and Laryngology, University of California. SAN FRANCISCO, CAL.
- F. C. HOTZ, M. D.,  
Professor of Ophthalmology and Otolaryngology, Rush Medical College; Professor of Ophthalmology, Chicago Polyclinic. CHICAGO, ILL.
- LUCIEN HOWE, M. A., M. D., M. R. C. S., ENG.,  
Professor of Ophthalmology, University of Buffalo. BUFFALO, N. Y.
- ALVIN A. HUBBELL, M. D., PH. D.,  
Clinical Professor of Ophthalmology and Otolaryngology, Medical Department, University of Buffalo. BUFFALO, N. Y.
- EDWARD JACKSON, A. M., M. D.,  
Emeritus Professor of Diseases of the Eye, Philadelphia Polyclinic. DENVER, COL.
- J. ELLIS JENNINGS, M. D.,  
Formerly Clinical Assistant, Royal London Ophthalmic Hospital, Moorfields; Lecturer on Ophthalmoscopy and Chief of the Eye Clinic in the Beaumont Hospital Medical College. ST. LOUIS, MO.

- HERMAN KNAPP, M. D.,  
Professor of Ophthalmology, College of Physicians and Surgeons, Columbia University;  
Surgeon to the New York Ophthalmic and Aural Institute. NEW YORK CITY.
- CHARLES W. KOLLOCK, M. D.,  
Lecturer on Diseases of the Eye and Ear in the Charleston Medical School; Ophthalmic  
Surgeon to the Charleston City Hospital. CHARLESTON, S. C.
- G. A. LELAND, A. M., M. D.,  
Aural Surgeon to Out-Patient Department, and Assistant in Throat Department, Boston  
City Hospital; Professor of Laryngology and Otolgy, Dartmouth Medical School. BOSTON, MASS.
- J. A. LIPPINCOTT, A. B., M. D.,  
Ophthalmic and Aural Surgeon, Allegheny General Hospital. PITTSBURG, PA.
- G. HUDSON MAKUEN, M. D.,  
Professor of Defects of Speech, Philadelphia Polyclinic and College for Graduates in  
Medicine; Laryngologist to St. Mary's Hospital and to the Frederick Douglass Memorial  
Hospital. PHILADELPHIA, PA.
- JOHN H. MCCOLLOM, M. D.,  
Instructor in Contagious Diseases, Harvard University; Resident Physician, South  
Department, Boston City Hospital. BOSTON, MASS.
- HORACE G. MILLER, A. M., M. D.,  
Ophthalmic and Aural Surgeon to the Rhode Island Hospital; Consulting Ophthalmic  
and Aural Surgeon to St. Joseph's Hospital. PROVIDENCE, R. I.
- B. L. MILLIKIN, M. D.,  
Professor of Ophthalmology, Medical Department, Western Reserve University; Oph-  
thalmic Surgeon to Lakeside Hospital. CLEVELAND, OHIO.
- ROBERT C. MYLES, M. D.,  
Professor of Otolgy and Adjunct Professor of Rhinology and Laryngology, New York  
Polyclinic; Assistant Surgeon to the Nose, Throat, and Ear Department of the New  
Amsterdam Eye and Ear Hospital. NEW YORK CITY.
- JAMES E. NEWCOMB, M. D.,  
Attending Laryngologist to the Out-Patient Department, Roosevelt Hospital, and to  
the Demilt Dispensary; Instructor in Laryngology, Cornell University Medical College. NEW YORK CITY.
- R. J. PHILLIPS, M. D.,  
Ophthalmic Surgeon to the Presbyterian Hospital, the Presbyterian Orphanage, and  
the Friends' Home for Children. PHILADELPHIA, PA.
- GEORGE A. PIERSOL, M. D.,  
Professor of Anatomy, University of Pennsylvania. PHILADELPHIA, PA.
- W. PEYRE PORCHER, M. D.,  
Lecturer on Diseases of the Throat and Nose, Charleston Medical School; Visiting  
Laryngologist to City Hospital. CHARLESTON, S. C.
- B. ALEX. RANDALL, M. A., M. D.,  
Clinical Professor, Diseases of the Ear, University of Pennsylvania; Professor of  
Diseases of the Ear, Philadelphia Polyclinic. PHILADELPHIA, PA.
- ROBERT L. RANDOLPH, M. D.,  
Associate in Ophthalmology and Otolgy, Johns Hopkins University; Associate Oph-  
thalmic and Aural Surgeon to the Johns Hopkins Hospital. BALTIMORE, MD.
- JOHN O. ROE, M. D.,  
Laryngologist to the Rochester City Hospital. ROCHESTER, N. Y.
- CHAS. E. DE M. SAJOURS, M. D.,  
Fellow of the American, British, and French Laryngological Associations. PHILADELPHIA, PA.
- J. E. SHEPPARD, M. D.,  
Clinical Professor of Diseases of the Ear, Long Island College Hospital; Professor of  
Otolgy, New York Polyclinic Medical School and Hospital. BROOKLYN, N. Y.



- E. L. SHURLY, M. D.,  
 Professor of Laryngology and Clinical Medicine, Detroit College of Medicine; Consulting Physician to St. Luke's Hospital. DETROIT, MICH.
- W. M. SWEET, M. D.,  
 Associate in Ophthalmology, Philadelphia Polyclinic; Instructor in Ophthalmology, Jefferson Medical College. PHILADELPHIA, PA.
- SAMUEL THEOBALD, M. D.,  
 Clinical Professor of Ophthalmology and Otology, Johns Hopkins University; Ophthalmic and Aural Surgeon to the Johns Hopkins Hospital. BALTIMORE, MD.
- ARCHIBALD G. THOMSON, M. D.,  
 Ophthalmic Surgeon to the Children's Hospital; Assistant Ophthalmic Surgeon, Wills Eye Hospital. PHILADELPHIA, PA.
- CLARENCE A. VEASEY, A. M., M. D.,  
 Adjunct Professor of Diseases of the Eye, Philadelphia Polyclinic; Demonstrator of Ophthalmology, Jefferson Medical College. PHILADELPHIA, PA.
- JOHN E. WEEKS, M. D.,  
 Surgeon to the New York Eye and Ear Infirmary, Ophthalmic Department; Clinical Professor of Ophthalmology and Otology, Woman's Medical College of the New York Infirmary. NEW YORK CITY.
- CASEY A. WOOD, C. M., M. D.,  
 Professor of Ophthalmology, Chicago Post-Graduate Medical School; Ophthalmic Surgeon to the Passavant Memorial Hospital. CHICAGO, ILL.
- JONATHAN WRIGHT, M. D.,  
 Clinical Professor of Diseases of the Nose and Throat, Woman's Medical College of the New York Infirmary. BROOKLYN, N. Y.
- H. V. WÜRDEMANN, M. D.,  
 Ophthalmic and Aural Surgeon to the Milwaukee Children's Hospital and to the Milwaukee County Hospital for the Chronic Insane. MILWAUKEE, WIS.

## P R E F A C E.

---

THIS book is offered to students and practitioners of medicine and surgery in general, and to those especially interested in the subjects of which it treats in particular, in the hope that it may take rank with the other volumes of the "American Text-book" series, which have demonstrated their worth and have had their reward in the appreciative reception which has been accorded to them.

In the portion of the work devoted to the Eye, its Embryology, Anatomy, Histology, Physiology, Diseases, and Injuries are discussed in twenty-four sections by twenty-four authors; its Operative Surgery in seven sections by as many authors; while certain practical details in the Examination for Color-blindness among Railroad Employés, etc., receive attention in an Appendix containing five sections.

In the portion of the work devoted to the Ear, its Anatomy, Physiology, Diseases, and Injuries are discussed in thirteen sections by fourteen authors; while Diseases of the Nose and Throat are described in twenty sections by nineteen authors.

Certain novel features, not usually found in text-books, may be noted: Special articles on The Standards of Form and Color-vision Required in Railway Service, The Röntgen Rays in Ophthalmic Surgery, The Practice of Ophthalmic Operations on Animals' Eyes, The Most Important Micro-organisms having Etiological Relationship to Ocular Disorders, etc.

It is unnecessary to discuss the "collaboration-method" thus employed, which has too often demonstrated its value to need either defence or explanation in this place, except to point out its greatest use, and the one to which no doubt it is indebted for its success—namely, that by its means, in the words of Dr. W. H. Howell, "the student gains the point of view of a number of teachers, reaping, in a measure, the same benefit as would be obtained by following courses of instruction under different teachers."

This work is essentially a text-book on the one hand, and, on the other, a volume of reference to which the practitioner may turn and find a series of articles written by men who are authorities on the subjects portrayed by them. Therefore the practical side of the question has been brought into prominence—*i. e.* Functional Testing, Etiology, Symptomatology, Diagnosis, and Treatment, but never to the neglect of Pathology or the important facts comprised in the special chapters on Embryology, Anatomy, Physiology, Physiological

Optics, etc., to which, indeed, special attention is directed. Thus it is hoped that the student will receive not only the point of view of a number of teachers, but a number of points of view of each subject.

A word should be said with reference to the effort to comprise within one volume studies of the Eye, Ear, Nose, and Throat—an effort which may challenge criticism in this day of highly differentiated specialties. Yet it has seemed to the Editors that each of these branches could receive text-book treatment within the space here assigned, while their important correlations could be better brought out by such juxtaposition. Specialism has often been carried much too far in the exclusion of attention to the adjacent fields. The oculist cannot dispense with a fair working knowledge of affections of the nose and its accessory cavities; nor should the aurist have to learn at second hand the important teachings of the ophthalmoscope as to his cases. Indeed, no practitioner, general or special, should be unfamiliar with all the types of disease and the most precise methods of their study, for it must often happen that he cannot avail himself of help from others. He should, like Brougham's educated man, "know a little of everything and all about some one thing." The latter part, as to the specialties here treated, the reader must seek in more voluminous encyclopedic works; but it is hoped that the labors of the eminent teachers here brought shoulder to shoulder will afford a good introduction for the beginner, as before stated, a valuable handy reference-book for the practitioner, and at least quicken some weakening memories in the advanced specialist.

Each author is responsible for the statements and opinions in his article; occasional editorial comment is always suitably marked. For the most part, wherever the same subject receives consideration in different articles, cross references have been supplied, again with the idea of facilitating a study of the point of view. It seems proper to note that there has been complete division of the editorial labor and responsibility, that of the Ophthalmic portion being assumed by Dr. de Schweinitz, and that of the Otological and Laryngological sections by Dr. Randall.

We have to note and deplore the loss to ourselves and to the profession in the death, during the preparation of this work, of Dr. Harrison Allen, robbing us of his finishing touches to his own contribution and the continuance of his friendly counsel as to other portions of the book. Of the greater loss in his many fields of activity we cannot here speak.

In conclusion, the Editors desire to express their hearty thanks to all the contributors for their uniform courtesy and for the presentation of the subjects entrusted to them in a manner which, they feel sure, cannot fail to be satisfactory to students. Also, their thanks are due to Mr. T. F. Dagney and Mr. R. W. Greene for their efficient aid and constant kindness.

1401 LOCUST STREET, }  
1604 WALNUT STREET, } PHILADELPHIA.

February, 1899.



# CONTENTS.

## PART I.—THE EYE.

|                                                                                                                                                 | PAGE |
|-------------------------------------------------------------------------------------------------------------------------------------------------|------|
| EMBRYOLOGY, ANATOMY, AND HISTOLOGY OF THE EYE . . .                                                                                             | 17   |
| By GEORGE A. PIERSON, M. D., Philadelphia, Pa.                                                                                                  |      |
| GENERAL PHYSIOLOGY OF VISION . . . . .                                                                                                          | 88   |
| By ALBERT P. BRUBAKER, M. D., Philadelphia, Pa.                                                                                                 |      |
| GENERAL OPTICAL PRINCIPLES; KATOPTRICS, DIOPTRICS,<br>PHYSIOLOGICAL OPTICS . . . . .                                                            | 102  |
| By WILLIAM S. DENNETT, M. D., and COLMAN WARD CUTLER, M. D., New<br>York City.                                                                  |      |
| EXAMINATION OF THE PATIENT AND EXTERNAL EXAMI-<br>NATION OF THE EYE; FUNCTIONAL TESTING . . . . .                                               | 142  |
| By G. E. DE SCHWEINITZ, A. M., M. D., Philadelphia, Pa.                                                                                         |      |
| THE OPHTHALMOSCOPE AND ITS USE; THE NORMAL EYE-<br>GROUND . . . . .                                                                             | 171  |
| By B. ALEX. RANDALL, A. M., M. D., Philadelphia, Pa.                                                                                            |      |
| METHODS OF DETERMINING THE REFRACTION OF THE<br>EYE: OPHTHALMOMETRY; OPHTHALMOSCOPY, SKI-<br>ASCOPY, OPTOMETRY; THE USE OF MYDRIATICS . . . . . | 196  |
| By EDWARD JACKSON, A. M., M. D., Denver, Col.                                                                                                   |      |
| NORMAL AND ABNORMAL REFRACTION: EMMETROPIA,<br>AMETROPIA, HYPEROPIA, MYOPIA, ASTIGMATISM,<br>PRESBYOPIA . . . . .                               | 212  |
| By EDWARD JACKSON, A. M., M. D., Denver, Col.                                                                                                   |      |
| SPECTACLES AND THEIR ADJUSTMENT . . . . .                                                                                                       | 236  |
| By R. J. PHILLIPS, M. D., Philadelphia, Pa.                                                                                                     |      |
| DISEASES OF THE EYELIDS . . . . .                                                                                                               | 241  |
| By B. L. MILLIKIN, M. D., Cleveland, Ohio.                                                                                                      |      |
| DISEASES OF THE LACHRYMAL APPARATUS . . . . .                                                                                                   | 261  |
| By SAMUEL THEOBALD, M. D., Baltimore, Md.                                                                                                       |      |
| DISEASES OF THE CONJUNCTIVA . . . . .                                                                                                           | 274  |
| By JOHN E. WEEKS, M. D., New York City.                                                                                                         |      |
| DISEASES OF THE CORNEA AND SCLERA . . . . .                                                                                                     | 305  |
| By SWAN M. BURNETT, M. D., Ph. D., Washington, D. C.                                                                                            |      |

|                                                                                                       | PAGE |
|-------------------------------------------------------------------------------------------------------|------|
| DISEASES OF THE IRIS, CILIARY BODY, AND CHOROID;<br>SYMPATHETIC INFLAMMATION AND IRRITATION . . . . . | 331  |
| By ROBERT L. RANDOLPH, M. D., Baltimore, Md.                                                          |      |
| INJURIES OF THE EYE AND ITS APPENDAGES . . . . .                                                      | 358  |
| By ALVIN A. HUBBELL, M. D., Ph. D., Buffalo, N. Y.                                                    |      |
| GLAUCOMA . . . . .                                                                                    | 373  |
| By J. A. LIPPINCOTT, A. B., M. D., Pittsburg, Pa.                                                     |      |
| DISEASES OF THE CRYSTALLINE LENS . . . . .                                                            | 386  |
| By WILLIAM E. HOPKINS, M. D., San Francisco, Cal.                                                     |      |
| DISEASES OF THE VITREOUS . . . . .                                                                    | 398  |
| By FLEMING CARROW, M. D., Ann Arbor, Mich.                                                            |      |
| DISEASES OF THE RETINA . . . . .                                                                      | 405  |
| By LUCIEN HOWE, M. D., Buffalo, N. Y.                                                                 |      |
| DISEASES OF THE OPTIC NERVE . . . . .                                                                 | 432  |
| By HAROLD GIFFORD, M. D., Omaha, Neb.                                                                 |      |
| AMBLYOPIA, AMAUROSIS, AND DISTURBANCES OF VISION<br>WITHOUT OPHTHALMOSCOPIC CHANGE . . . . .          | 457  |
| By CASEY A. WOOD, M. D., Chicago, Ill.                                                                |      |
| AMBLYOPIA OF THE VISUAL FIELD, SCOTOMAS, AND HEMI-<br>ANOPIA . . . . .                                | 470  |
| By H. V. WÜRDEMANNS, M. D., Milwaukee, Wis.                                                           |      |
| INTRAOCULAR GROWTHS . . . . .                                                                         | 489  |
| By WARD A. HOLDEN, A. M., M. D., New York City.                                                       |      |
| MOVEMENTS OF THE EYEBALLS, AND THEIR ANOMALIES . . . . .                                              | 497  |
| By ALEXANDER DUANE, M. D., New York City.                                                             |      |
| INJURIES AND DISEASES OF THE ORBIT . . . . .                                                          | 523  |
| By F. BULLER, M. D., Montreal, Canada.                                                                |      |
| OPERATIONS . . . . .                                                                                  | 539  |
| Preparation of the Region of Operation, the Instruments, and the<br>Dressings; Anesthesia . . . . .   | 539  |
| By G. E. DE SCHWEINITZ, A. M., M. D., Philadelphia, Pa.                                               |      |
| Operations upon the Eyelids . . . . .                                                                 | 541  |
| By F. C. HOTZ, M. D., Chicago, Ill.                                                                   |      |
| Operations upon the Conjunctiva, Cornea, and Sclera; Enucleation<br>and Evisceration . . . . .        | 561  |
| By CHARLES W. KOLLOCK, M. D., Charleston, S. C.                                                       |      |
| Operations upon the Iris and the Crystalline Body . . . . .                                           | 574  |
| By HERMAN KNAPP, M. D., New York City.                                                                |      |
| Operations upon the Eye-muscles . . . . .                                                             | 587  |
| By S. C. AYRES, M. D., Cincinnati, Ohio.                                                              |      |
| Operations upon the Lachrymal Apparatus . . . . .                                                     | 596  |
| By SAMUEL THEOBALD, M. D., Baltimore, Md.                                                             |      |

|                                                                                                                        | PAGE |
|------------------------------------------------------------------------------------------------------------------------|------|
| Operations upon the Orbit . . . . .                                                                                    | 599  |
| By F. BULLER, M. D., Montreal, Canada.                                                                                 |      |
| APPENDIX . . . . .                                                                                                     | 603  |
| The Methods for Detecting Color-blindness, with Special Reference<br>to the Examination of Railroad Employés . . . . . | 603  |
| By J. ELLIS JENNINGS, M. D., St. Louis, Mo.                                                                            |      |
| Standards of Form and Color-vision Required in Railway Service .                                                       | 605  |
| By A. G. THOMSON, M. D., Philadelphia, Pa.                                                                             |      |
| The Röntgen Rays in Ophthalmic Surgery . . . . .                                                                       | 607  |
| By WILLIAM M. SWEET, M. D., Philadelphia, Pa.                                                                          |      |
| The Practice of Ophthalmic Operations on Animals' Eyes . . . . .                                                       | 611  |
| By CLARENCE A. VEASEY, A. M., M. D., Philadelphia, Pa.                                                                 |      |
| The Most Important Micro-organisms having Etiological Relation-<br>ship to Ocular Diseases . . . . .                   | 614a |
| By G. E. DE SCHWEINITZ, A. M., M. D., Philadelphia, Pa.                                                                |      |

---

PART II.—THE EAR.

---

|                                                                                                                            |     |
|----------------------------------------------------------------------------------------------------------------------------|-----|
| THE ANATOMY OF THE EAR, INCLUDING EMBRYOLOGY<br>AND HISTOLOGY . . . . .                                                    | 617 |
| By B. ALEX. RANDALL, M. A., M. D., Philadelphia, Pa.                                                                       |     |
| THE PHYSIOLOGY OF THE EAR. . . . .                                                                                         | 631 |
| By FRANK ALLPORT, M. D., Chicago, Ill., and R. O. BEARD, M. D., Minneap-<br>olis, Minn.                                    |     |
| ETIOLOGY AND PATHOLOGY OF EAR AFFECTIONS. . . . .                                                                          | 617 |
| By C. R. HOLMES, M. D., Cincinnati, Ohio.                                                                                  |     |
| EXAMINATION OF PATIENTS; SYMPTOMATOLOGY AND<br>DIAGNOSIS; INSTRUMENTS NEEDED, AND METHODS<br>OF THEIR EMPLOYMENT . . . . . | 665 |
| By JOHN E. SHEPPARD, M. D., Brooklyn, N. Y.                                                                                |     |
| THE GENERAL THERAPEUTICS OF EAR AFFECTIONS . . . . .                                                                       | 681 |
| By CLARENCE J. BLAKE, M. D., Boston, Mass.                                                                                 |     |
| AFFECTIONS OF THE EXTERNAL EAR . . . . .                                                                                   | 691 |
| By SAMUEL THEOBALD, M. D., Baltimore, Md.                                                                                  |     |
| INJURIES AND DISEASES OF THE DRUMHEAD . . . . .                                                                            | 711 |
| By H. V. WÜRDEMANN, M. D., Milwaukee, Wis.                                                                                 |     |
| ACUTE AFFECTIONS OF THE TYMPANIC CAVITY AND EU-<br>STACHIAN TUBE . . . . .                                                 | 715 |
| By HORACE G. MILLER, A. M., M. D., Providence, R. I.                                                                       |     |

|                                                      | PAGE |
|------------------------------------------------------|------|
| CHRONIC CATARRH OF THE MIDDLE EAR . . . . .          | 726  |
| By EDWARD B. DENCH, Ph. B., M. D., New York City.    |      |
| CHRONIC SUPPURATION OF THE MIDDLE EAR . . . . .      | 739  |
| By ALBERT H. BUCK, M. D., New York City.             |      |
| COMPLICATIONS OF TYMPANIC INFLAMMATION . . . . .     | 749  |
| By HERMAN KNAPP, M. D., New York City.               |      |
| DISEASES OF THE SOUND-PERCEIVING APPARATUS . . . . . | 765  |
| By HENRY A. ALBERTON, M. D., Brooklyn, N. Y.         |      |
| OPERATIONS . . . . .                                 | 782  |
| By J. ORNE GREEN, A. M., M. D., Boston, Mass.        |      |

### PART III.—THE NOSE AND THROAT.

|                                                                                           |     |
|-------------------------------------------------------------------------------------------|-----|
| ANATOMY OF THE UPPER AIR-PASSAGES, INCLUDING HIS-<br>TOLOGY AND EMBRYOLOGY . . . . .      | 807 |
| By HARRISON ALLEN, M. D., LL. D., and ARTHUR A. BLISS, A. M., M. D.,<br>Philadelphia, Pa. |     |
| PHYSIOLOGY OF THE UPPER AIR-PASSAGES . . . . .                                            | 835 |
| By WALTER J. FREEMAN, M. D., Philadelphia, Pa.                                            |     |
| GENERAL ETIOLOGY AND PATHOLOGY OF DISEASES OF<br>THE UPPER RESPIRATORY TRACT . . . . .    | 844 |
| By J. H. BRYAN, M. D., Washington, D. C.                                                  |     |
| METHODS OF EXAMINATION AND DIAGNOSIS IN AFFEC-<br>TIONS OF THE NOSE AND THROAT . . . . .  | 855 |
| By JOHN W. FARLOW, M. D., Boston, Mass.                                                   |     |
| THERAPEUTIS AND PROGNOSIS . . . . .                                                       | 874 |
| By GEO. A. LELAND, A. M., M. D., Boston, Mass.                                            |     |
| ACUTE AFFECTIONS OF THE NOSE . . . . .                                                    | 891 |
| By WILLIAM E. CASSELBERRY, M. D., Chicago, Ill.                                           |     |
| CHRONIC AFFECTIONS OF THE NOSE . . . . .                                                  | 905 |
| By MORRIS J. ASCH, M. D., New York City.                                                  |     |
| DISEASES OF THE TONSILS, PALATE, AND PHARYNX . . . . .                                    | 921 |
| By JAMES EDWARD NEWCOMB, M. D., New York City.                                            |     |
| ATROPHIC RHINITIS . . . . .                                                               | 957 |
| By W. PEYRE PORCHER, M. D., Charleston, S. C.                                             |     |
| DISEASES OF THE ACCESSORY SINUSES OF THE NOSE . . . . .                                   | 966 |
| By ROBERT CUNNINGHAM MYLES, M. D., New York City.                                         |     |
| ACUTE AFFECTIONS OF THE LARYNX AND TRACHEA . . . . .                                      | 985 |
| By WILLIAM E. HOPKINS, M. D., San Francisco, Cal.                                         |     |



|                                                           | PAGE |
|-----------------------------------------------------------|------|
| CHRONIC INFLAMMATORY DISEASES OF THE LARYNX . . . . .     | 998  |
| By C. E. DE M. SAJOUS, M. D., Philadelphia, Pa.           |      |
| DIPHTHERIA OF THE AIR-PASSAGES . . . . .                  | 1010 |
| By J. H. McCOLLOM, M. D., Boston, Mass.                   |      |
| TUBERCULOSIS OF THE AIR-PASSAGES . . . . .                | 1031 |
| By E. L. SHURLY, M. D., Detroit, Mich.                    |      |
| SYPHILIS OF THE AIR-PASSAGES . . . . .                    | 1067 |
| By WILLIAM C. GLASGOW, M. D., St. Louis, Mo.              |      |
| NEOPLASMS OF THE UPPER AIR-PASSAGES . . . . .             | 1075 |
| By JONATHAN WRIGHT, M. D., Brooklyn, N. Y.                |      |
| INJURIES AND DEFORMITIES OF THE NOSE AND THROAT . . . . . | 1116 |
| By JOHN O. ROE, M. D., Rochester, N. Y.                   |      |
| NEUROSES OF THE UPPER AIR-PASSAGES . . . . .              | 1140 |
| By JONATHAN WRIGHT, M. D., Brooklyn, N. Y.                |      |
| THE VOICE—ITS PRODUCTION AND HYGIENE . . . . .            | 1171 |
| By G. HUDSON MAKUEN, M. D., Philadelphia, Pa.             |      |
| OPERATIONS . . . . .                                      | 1180 |
| By JOHN O. ROE, M. D., Rochester, N. Y.                   |      |



THE EYE.



# THE EYE.

## THE EMBRYOLOGY, ANATOMY, AND HISTOLOGY OF THE EYE.

By GEORGE A. PIERSOL, M. D.,  
OF PHILADELPHIA.

### THE DEVELOPMENT OF THE EYE.

THE initial stages in the formation of the visual organ are so intimately related to those of the brain, that a brief sketch of the early development of the nervous system may with advantage precede the more detailed account of the development of the eye.

The first definite trace of the embryo within the embryonal area appears as a pair of slightly converging folds, the *medullary plates*, which partially

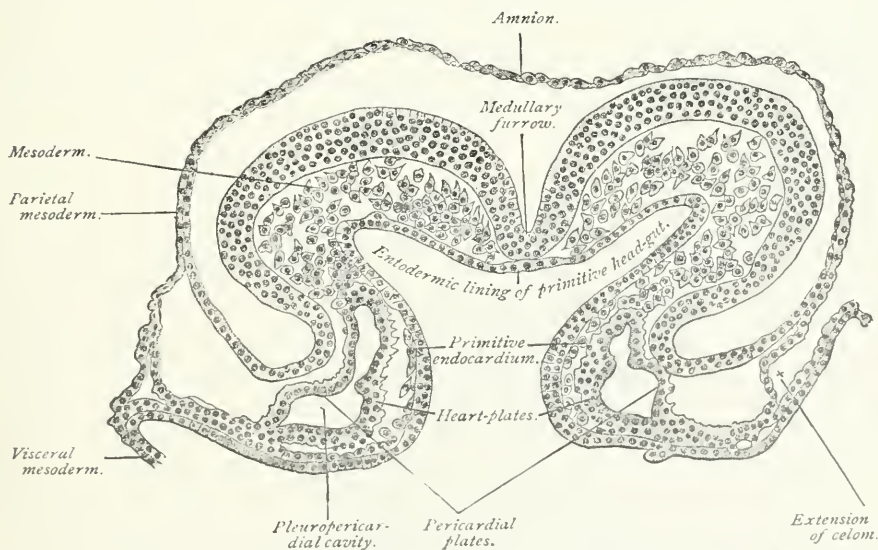


FIG. 1.—Transverse section of a sixteen-and-a-half-day sheep embryo (Bonnet).

enclose the anterior end of the transient primitive streak. Originally widely separated and low, the folds rapidly increase in height, while the included *neural groove* becomes correspondingly deepened (Fig. 1). Very soon the growing medullary plates manifest a tendency to approximate their free edges along the dorsal aspect of the embryo, a disposition which eventually results in their fusion and the conversion of the open neural groove into the closed

neural canal (Figs. 2 and 3). The point at which this fusion earliest occurs does not coincide with the anterior extremity of the canal, but with a point somewhat farther back; from this latter situation closure progresses toward the caudal pole.

The anterior extremities of the medullary folds remain ununited for some

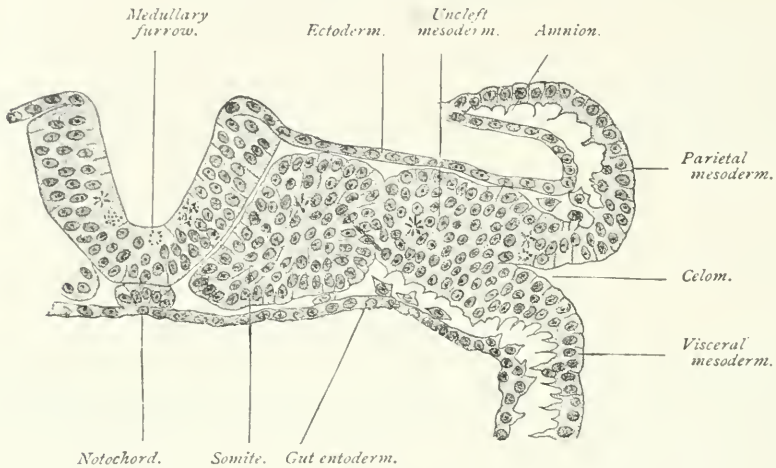


FIG. 2.—Transverse section of a sixteen-and-a-half-day sheep embryo possessing six somites (Bonnet).

time after the more caudally situated parts of the folds have undergone concrescence and closure; the anterior portion of the folds, on the other hand, has meanwhile become locally expanded in such manner that even before the fusion of the folds indications of three distinct dilatations—the *primary brain-*

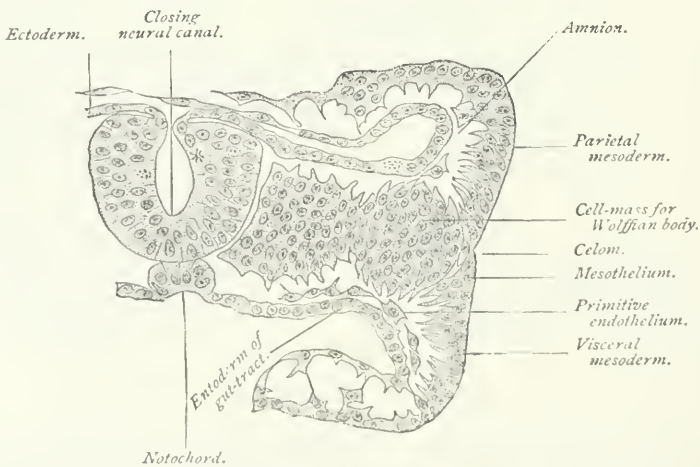


FIG. 3.—Transverse section of a fifteen-and-a-half-day sheep embryo possessing seven somites (Bonnet)

*vesicles*—have become apparent. The foremost of these, the *anterior* brain-sae, occupies the extreme end of the neural canal, and is of large size, the succeeding *middle* and *posterior* vesicles being less expanded, although of greater length.



The primary cerebral vesicles, however, soon undergo further change, since the anterior and the posterior each become subdivided, the cephalic segment of the neural tube being then represented by the five *secondary brain-vesicles*. These latter are designated, from before backward, as the *fore-brain*, or *prosencephalon*; the *inter-brain*, or *thalamencephalon*; the *mid-brain*, or *mesencephalon*; the *hind-brain*, or *rhombencephalon*; and the *after-brain*, or *metencephalon* (Figs. 4

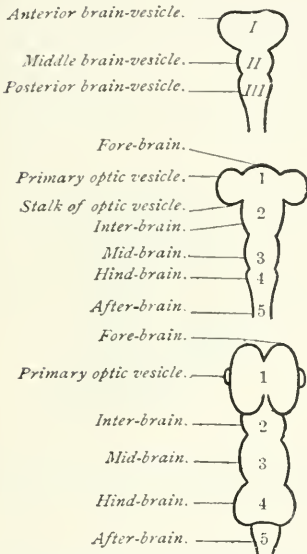


FIG. 4.—Diagrams illustrating the primary and secondary segmentation of the brain-tube (Bonnet).

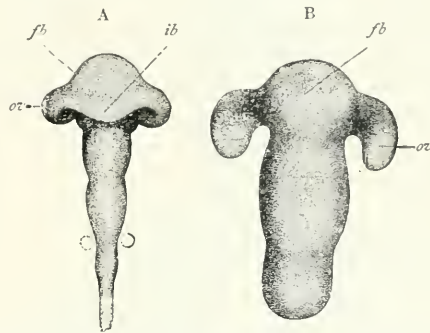


FIG. 5.—A, brain of two-day chick embryo; B, brain of human embryo of three weeks (His); shows the development of the optic vesicles and brain-vesicles; *fb*, fore brain; *ib*, inter-brain; *ov*, optic vesicle.

and 5). The remains of the greatly modified and relatively reduced cavities of these early brain-segments are represented respectively by the lateral ventricles, the third ventricle, the aqueduct of Sylvius, and the fourth ventricle; while from the walls of the secondary brain-vesicles are developed the structures situated around the corresponding part of the ventricular space.

Coincidentally with the development of the primary cerebral vesicles, even before the complete closure of the neural canal, the anterior brain-sac becomes distinguished by the evagination of a conspicuous diverticulum on either side, which extends almost at right angles to the general cerebral axis. These outgrowths from the hinder part of the early anterior cerebral segment are the *primary optic vesicles*, from which the nervous tunic of the eye is largely developed. The optic vesicle at first opens so widely into the brain-sac that there is little differentiation of the ocular rudiment from the general cavity of the brain-segment; soon, however, the communication between the two becomes narrowed and the optic vesicle better defined as an independent organ. The *optic stalk*, which results from this constriction, lies almost trans-versely placed when first formed, but gradually assumes a more oblique axis as its development progresses. The relations of the optic stalks to the brain-segments also somewhat change, since when definitely formed the stalks open into the inter-brain, or thalamencephalon, having seemingly become posteriorly removed during their growth.

In attaining its full expansion the primary optic vesicle has encroached to such an extent on the mesoderm lying between the eye-sac and the surface of the embryo, that in mammals an extremely thin stratum of mesodermic tissue alone separates the optic vesicle from the surface ectoderm: in birds even this is wanting, the mesoderm being entirely displaced and the ectoderm

of the exterior and anterior wall of the optic vesicle coming into apposition (Fig. 6).

Each optic vesicle may be regarded as possessing four walls—a *lateral* or outer wall, including the area in apposition to the surface; a *mesial* or inner wall, marked by the position of the early optic stalk; a *lower* wall, on a level with the floor of the inter-brain; and an *upper* wall.

After meeting the surface layers in its outward expansion, the primary optic vesicle becomes profoundly modified by the invagination of its lateral

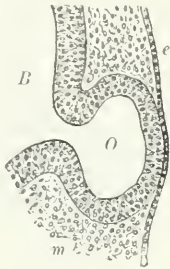


FIG. 6.—Section through head of ten-day rabbit embryo, exhibiting primary optic vesicle (*O*) protruding from fore-brain (*B*), and coming in contact with surface ectoderm (*e*); *m*, surrounding mesoderm (Piersol).

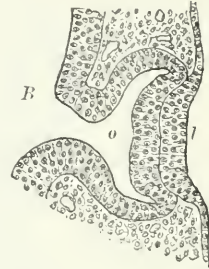


FIG. 7.—Section through developing eye of clevan-day rabbit embryo (Piersol): *B*, fore-brain connected by stalk with optic vesicle (*o*), whose anterior wall is partly invaginated; *l*, thickened and depressed lens area.

or outer wall, in consequence of which pushing in, the cavity of the primary vesicle is gradually reduced, and, finally, obliterated by the application of the invaginated portion of the wall of the vesicle to the mesial segment of the same, which has not suffered displacement. The space which results from the invagination of the outer portion of the primary eye-sac gradually acquires a cupped form, and is known as the *secondary optic vesicle*, or, more appropriately, as the *optic cup* (Figs. 7 and 8).

Coincidentally with the changes in the optic vesicle which result in the production of the optic cup, the ectoderm lying over the optic vesicle exhibits

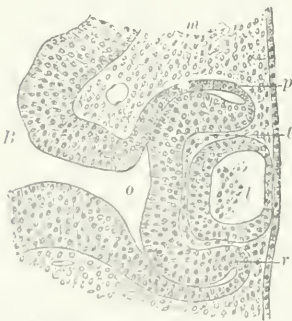


FIG. 8.—Section through developing eye of eleven-and-a-half-day rabbit embryo (Piersol): *B*, fore-brain connected with optic vesicle (*o*), nearly effaced by apposition of invaginated anterior segment (*r*) with posterior wall (*p*); *l*, lens-sac completely closed and separated from ectoderm; *t*, tissue within secondary optic cup derived from surrounding mesoderm.

proliferation of its elements and becomes thickened, and, at the same time, sinks into the subjacent invaginating optic vesicle, thus forming a depression known as the *lens-pit*. The thickened ectoderm lining the bottom and sides of the pit is accurately applied to the receding lateral wall of the optic vesicle, separated in mammals, however, by a thin sheet of mesodermic tissue. The invagination of the early lens-pit increases, and, at the same time, the margins of the depression become approximated and eventually united, so that the lens-pit is converted into the *lens-vesicle*, a structure from which the future crystalline lens is developed in a manner presently to be described. The lens-sac thus formed for a time remains connected with the ectoderm; later, the union between the two is severed, and the primary lens-rudiment lies as an isolated ectodermic vesicle completely surrounded by mesoderm. The mesodermic stratum which separates the lens-sac from the

overlying ectoderm later contributes the connective-tissue stroma of the cornea, while the corresponding ectodermic area becomes the corneal epithelium (Fig. 8).

Returning to the consideration of the changes involving the optic vesicle, we have to follow modifications which result in the formation of the most important parts of the nervous tunic of the eyeball. As already sketched, the lateral wall of the primary optic vesicle becomes invaginated as the lens-sac is developed: while in the early stages the two invaginations progress with uniform rapidity, there comes a time, after the lens-sac has reached completion, when the expansion of the inner wall of the latter no longer keeps pace with the pushing-in of the optic vesicle, in consequence of which disparity a space, the *primitive vitreous chamber*, appears between the lens-vesicle and the retreating wall of the optic vesicle. The completion of the invagination results in the approximation of the lateral folded-in wall toward the mesial wall of the vesicle, until the two layers are in contact and the

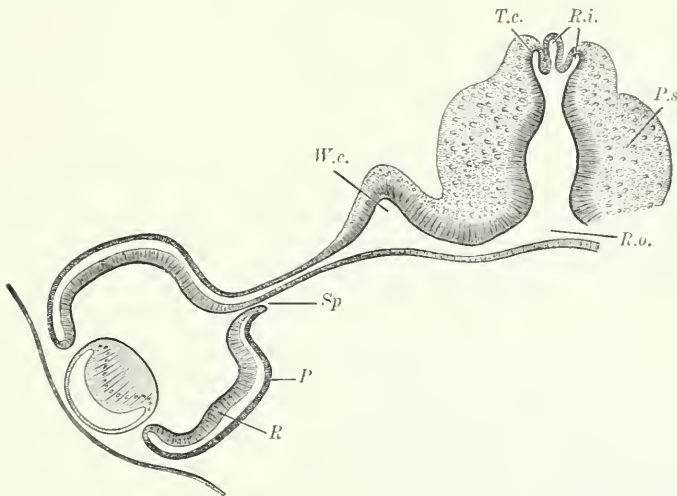


FIG. 9.—Section through the optic vesicle, the optic stalk and adjoining parts of the cerebral vesicle of a five-weeks' human fetus (His): *R, P*, retinal and pigment layers of optic vesicle; *Sp*, cleft for entrance of central artery; *T.c.*, tuber cinereum, with recessus infundibuli (*R.i.*); *W.c.*, basal conus; *R.o.*, recessus opticus. The lower part of the figure corresponds to the nasal side, the upper to the temporal.

included cavity of the primary optic vesicle is obliterated. The secondary vesicle, or the *optic cup*, is now bounded by a double-layered wall.

Almost from the beginning of the process of involution involving the primary optic vesicle the portion of the wall of the sac so affected exhibits a disposition to undergo proliferation and thickening, in consequence of which change the developing optic cup is immediately bounded by a disproportionately thick stratum, which from the resulting structures is appropriately termed the *retinal layer*. In marked contrast to the inner, the outer layer of the optic cup not only fails to increase in thickness, but becomes attenuated in consequence of the general expansion of the growing primitive visual organ, so that by the time the retinal layer comes in contact with the outer layer of the optic cup, the latter has become reduced to a delicate stratum of cells which would be inconspicuous were it not for its characteristic dark tint due to the presence of rapidly augmenting pigment-particles. The pigmented condition of the cells of the outer layer early foreshadows the subsequent fate of this portion of the optic vesicle, which eventually forms the single layer of pigmented



retinal epithelium. From the thickened inner layer are derived the essential nervous elements of the retina, including the rods and cones, the various ganglion-cells and the nerve-fibers proceeding from them, together with the supporting neuroglial tissue.

The invagination described in the preceding paragraphs as affecting the lateral or outer wall of the primary optic vesicle is not limited to that portion of the eye-sac, but involves also the lower wall of the vesicle and its hollow stalk. Reference to the accompanying figure (9, Sp) will show that the lower wall of the double-layered vesicle is not complete, but is pushed in—in frontal sections this inferior groove appearing as a hiatus in the vesicle, the *choroidal cleft*. This latter slit establishes communication between the surrounding mesoderm and the interior of the optic cup, and affords entrance of the mesodermic tissue which constitutes the primary vitreous stroma; it soon becomes greatly narrowed and finally closes.

In consequence of the infolding of its lower wall the optic stalk, at first cylindrical, becomes deeply grooved; the groove, which is occupied by vascular mesodermic tissue, after attaining a certain depth, gradually closes by the approximation and final union of its lips, the imprisoned mesoderm and the included blood-vessels being later represented by the arteria centralis retinae and the associated connective tissue occupying the central area of the optic nerve.

**The Development of the Lens.**—The earliest phases of the formation of the crystalline lens, including the conversion of the lens-pit into the closed lens-sac, have been already described; the subsequent development of the lens is largely the history of the growth and differentiation of the walls of the lenticular vesicle. By the time the lens-sac has become completely isolated from its attachment with the surface ectoderm its walls consist of two or three layers of epithelial cells, externally limited by a delicate membrane, the earliest suggestion of the lens-capsule. Very soon the inner portion of the wall of the lens-sac becomes conspicuous by reason of its greater thickness—a disparity which becomes progressively more marked as development proceeds. The early mammalian lens-vesicle contains a mass of small cells derived from the proliferation of the surface elements of the primitive epidermis. These cells are unimportant, being transient, and later undergoing degeneration and absorption.

The obliteration of the cavity of the lens-sac and the conversion of the organ into a solid mass are effected by the phenomenal growth and elongation of the epithelial elements composing the posterior or internal wall of the sac. These cells rapidly increase in length, becoming converted into the primitive lens-fibers. At first the thickened inner wall projects into the lens-vesicle, the greatly reduced cavity of the sac intervening between it and the anterior wall. With the growth of the fiber-mass this space is gradually reduced, until finally the now greatly thickened and specialized posterior wall comes into contact with the anterior layer and the lens becomes solid.

The thickening and growth which have characterized the changes affecting the posterior or inner wall of the lens-sac are in marked contrast to the progressive attenuation of the anterior or outer wall. The columnar type of the early cells of this region is replaced by the low cuboidal form which characterizes these elements in later stages.

After the primitive lens becomes solid in consequence of the obliteration of the cavity of the lens-vesicle by the growth and modification of the posterior wall, the subsequent increase in the size of the lens takes place by the conversion of the cells of the anterior wall, which are later known as the

epithelium of the anterior capsule, into lens-fibers, and the addition of these as peripheral increments. The transformation of the epithelial cells into fibers takes place at the equatorial zone, where the low columnar elements may be seen elongating and assuming the peculiarities of young fibers. The appositional growth of the lens which thus takes place results in the formation of layers of lens-fibers which cover the surface of the organ and enclose the lens-core. In consequence of their mode of equatorial formation the young fibers extend from the anterior to the posterior surface of the lens, their ends meeting along definite radiating lines which in the embryo and the new-born animal constitute three-rayed figures known as the *lens-stars*. The star of the *anterior* surface always has its superior limb directed vertically, the remaining rays diverging laterally at an angle of  $120^\circ$ . The rays of the *posterior star* are disposed in such manner that they fall between those of the anterior figure, the vertical limit being below and the others extending upward and outward. In the adult lens the figures lose their former simplicity by the appearance of other and secondary rays, the adult lens-stars being indistinct and uncertain in their outlines. The modifications of the stars in the fully-grown lens are largely due to the fact that in the enlarged organ the fibers are no longer capable of spanning the entire distance between the anterior and posterior surfaces, as do the young embryonal fibers.

The *lens-capsule* is early suggested by the appearance of a delicate membrane, which limits the outer surface of the lens-vesicle, and afterward undergoes thickening, becoming apparently homogeneous and of elastic character, which distinguishes this part of the eye. Two opposed views exist regarding the source of the capsule: according to one, the capsule is developed as a secretion from the cells of the lenticular vesicle, while the other regards it—and, the author believes, correctly—as derived from the mesodermic tissue surrounding the primitive lens.

It will be noted from the foregoing description that the entire lens, excluding its capsule, is of ectodermic origin.

The unusual demands made by the young, rapidly-growing and, at the same time, non-vascular lens on surrounding tissues for its nutrition result in the provision of a special, although temporary, structure designed to meet that need. The structure so developed consists of an envelope of vascular mesodermic tissue, the *tunica vasculosa lentis*, which completely surrounds the young lens from the second month to toward the end of gestation, at which latter period it has usually atrophied and disappeared.

The *tunica vasculosa* is closely associated with the vitreous, since its blood-vessels are derived from those of that body. The large vessels over the posterior surface of the lens break up into smaller branches, which, bending around the equator of the lens, ramify within the mesodermic sheet covering the anterior surface, proceeding almost as far as the center of the pupil, where they end in terminal loops. The different parts of the vascular membrane of the lens bear particular names, in consequence of having been first observed at different times. The portion of the membrane opposite the pupil was called the *membrana pupillaris*; the more peripherally situated zone constituted the *membrana capsulo-pupillaris*; while that covering the posterior surface was designated the *membrana capsularis*. It is evident that these are but parts of one and the same vascular sheet which is now appropriately called the *tunica vasculosa lentis*. Usually this structure is best developed at about the seventh month, after which time it undergoes atrophy and absorption, so that at, or even before, birth it has entirely dis-

appeared. Exceptionally, parts of the embryonal structure remain after birth, the anterior portions, when present, constituting the *persistent pupillary membrane*. (See page 331.)

The early infolding of the lower wall of the optic vesicle is closely related to an outgrowth of the surrounding mesoderm, which occupies the invagination, and thus gains entrance into the secondary optic vesicle or optic cup, in which space it rapidly expands until the actively proliferating mesodermic tissue completely fills the space between the primitive lens and the retinal layer of the optic cup. In structure the primary vitreous corresponds to an embryonal form of connective tissue, in which a delicate network of branched connective-tissue elements is conspicuous. At a later stage these cells atrophy, while numerous leukocytes, derived from the ingrowing blood-vessels, invade the vitreous tissue. Coincidentally with the growth of the primitive vitreous an extension of the artery occupying the young optic nerve, which later becomes the *arteria centralis retinae*, takes place, the vessel invading the vitreous passing to the posterior pole of the young lens as the *hyaloid artery*. With the appearance of the latter vessel the vitreous becomes abundantly supplied with capillaries, from which not only the leukocytes already mentioned pass into the proliferating mesoderm, but also the watery constituents which later give to the vitreous tissue its characteristic semi-fluid condition (Fig. 10).

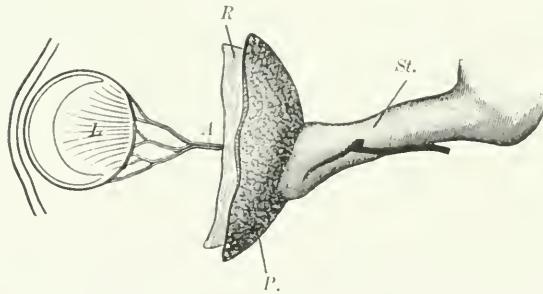


FIG. 10.—Projection from nasal side of the stalk of the optic vesicle and the central artery of the retina (His): *L*, lens; *A*, anterior continuation of the central artery to the vascular tunic of the lens; *R*, *P*, respectively the nervous and pigment lamella of the optic vesicle; *St*, optic stalk, with entrance of central artery.

In addition to providing the vitreous tissue with capillaries for its direct nutrition during the early stages of its active growth, the hyaloid artery ramifies within the mesodermic layer covering the posterior surface of the lens, thus first supplying that portion of the tunica vasculosa lentis known as the *membrana capsularis*. From this portion of the lens envelope, as already mentioned, the blood-vessels extend forward, and finally spread out within the anterior segment over the corresponding surface of the lens, to constitute the vessels of the *membrana pupillaris*.

During the last weeks of fetal life the blood-vessels of the vitreous, together with the tunica lentis, disappear, the only indication of this elaborate intraocular vascular network which persists being the remains of the hyaloid artery within a passage, the *hyaloid canal*, which extends from the optic entrance to the posterior pole of the lens. Sometimes, however, the hyaloid artery undergoes less atrophy, and is then represented by a cord which extends toward the lens, and may be provided with a lumen for a portion of its length; in such cases the persistent hyaloid artery may form a conspicuous object when viewed with the ophthalmoscope. (See page 403.)



**Development of the Retina.**—In the foregoing consideration of the initial changes in the formation of the optic cup the early conspicuous differentiation of the inner and the outer layers composing its walls has been pointed out. By the time the infolded portion of the vesicle has been closely applied to the uninvolved segment, the former, or inner layer, has attained a thickness of many times that of the outer layer: the latter, however, has become conspicuous, notwithstanding its attenuation, by reason of the pigment-granules which early accumulate within its cells. The pigment appears earliest near the anterior margin or lip of the optic cup, gradually extending toward the posterior pole, until the entire outer layer appears uniformly dark. This layer becomes the future *pigmented retinal epithelium* (Fig. 11).

The fate of the greatly thickened inner layer is largely identical with the history of the development of the retina, since it contributes the most important parts of the nervous tunie. The early stages in the development of the retina resemble closely those seen elsewhere in the walls of the young brain-vesicles, active proliferation of the cells lining the neural tube being a conspicuous feature. As in other parts of the young cerebro-spinal tube, the differentiation of the cells constituting the inner layer of the optic cup results in the formation of two varieties of tissues—the nervous elements and the sustentacular tissue.

The differentiation of the nervous constituents results in the formation of two groups of elements—the nerve-cells and their outgrowths, the nerve-fibers, and the retinal neuro-epithelium; the latter eventually becomes specialized as the layer of rods and cones and the outer nuclear layer, these two strata together constituting the layer of *visual cells*, as the sensory epithelium is here appropriately called. The further development of the sustentacular tissue produces the characteristic radial fibers of Müller, which extend throughout the thickness of the retina and afford support and connection to the nervous elements. In addition to the derivatives from the involuted ectoderm, ingrowths of true connective tissue take place from the surrounding mesodermic tissue which accompanies the ramifications of the early *arteria centralis retinae*.

While the developmental changes just described affect the far greater part of the optic cup, the anterior zone, corresponding to the double-layered lips of the cup, differs materially in its growth and fate. Coincidentally with the increase of surface which the general expansion of the developing eye effects, the anterior zone of the optic cup becomes greatly thinned, the inner layer becoming reduced to a single layer of low columnar elements, in marked contrast to the conspicuous thickening which this layer undergoes throughout the posterior segment of the cup.

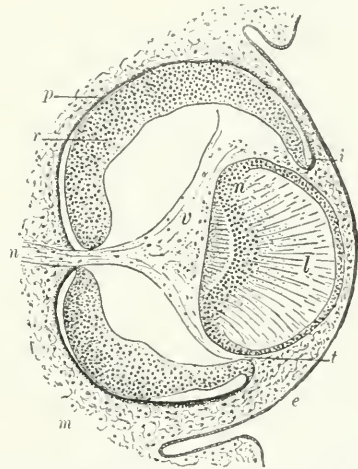


FIG. 11.—Section through developing eye of thirteen-day rabbit embryo (Piersol): *e*, ectoderm; *l*, lens, consisting of anterior nucleated division representing thin front wall of lens-sac, and greatly thickened posterior division completely filling cavity of sac by elongated fibers whose nuclei present crescentic zone (*z*); *p*, posterior pigmented layer; *r*, specialized anterior retinal layer; *z*, point where layers of optic vesicles become continuous; *n*, extreme peripheral section of tissue of primitive optic nerve connected with vascular tunic (*v*), occupying posterior surface of lens; *m*, surrounding mesoderm, which (at *t*) grows between lens and retina.



The extension of the anterior marginal zone of the optic cup is intimately associated with the changes within the surrounding mesoderm, which lead to the development of the structures composing the ciliary region and the iris: the forward growth of the attenuated lips of the cup contributes the double-layered, and later deeply pigmented, epithelial investment covering the inner surface of the ciliary body and the iris as far as the pupil. The *pars ciliaris retina* and the *pars retinae iridica*, which include the deeply pigmented stratum covering these respective regions, are, therefore, representatives of the anterior zone of the ectodermic optic cup. The line of demarcation between the posterior visual and the anterior rudimentary segments of the optic cup is at first not sharply marked, but later, when the conspicuous differences in the growth of the layers in the two regions become established, the anterior limit of the retinal area gradually becomes well defined at the position later indicated by the *ora serrata*.

**Development of the Optic Nerve.**—The early optic stalk, which establishes connection between the primary optic vesicle and the inter-brain, is involved in its ocular end in the invagination which affects the lower wall of the optic vesicle and results in the formation of the *choroidal fissure*. This folding-in—in addition to affording a means of entrance into the interior of the future optic nerve for the vascular mesoderm, from which later are produced the central retinal blood-vessels—is rendered necessary by the new relations of the layers composing the walls of the optic cup: without the corresponding readjustment of the walls of the optic stalk, as effected by the invagination along its lower margin, the walls of the stalk-tube would be continuous with the outer layer of the optic vesicle alone. In consequence of the folding-in of the lower wall of the stalk and the subsequent obliteration of its lumen by the apposition of its walls the layers composing the latter remain continuous with the invaginated portion of the optic cup, as well as with that possessing the original relation; hence the connection is maintained not only with the thickened retinal sheet, but also with the attenuated outer stratum.

The early lumen of the primary optic stalk soon disappears, and is replaced by a solid condition of the young optic nerve. This solidification is effected by two processes, one of which affects the greater central part of the stalk as far as its cerebral attachments, while the other, which includes the end applied to the optic vesicle, is limited to the peripheral and smaller segment of the nerve. The greater part of the hollow stalk is converted into a solid cord by the gradual thickening of its walls, due to active proliferation of the elements, which results in the subsequent apposition and final obliteration of the lumen. The solidification of the ocular portion of the stalk is the result of both invagination and proliferation: the early invagination of the lower wall of the stalk when completed effects the closure of the lumen of the tube by the apposition and final fusion of the walls of the tube; while the proliferation of the margins of the furrow results in the approximation and complete closure of the groove, the growth of the so imprisoned mesoderm, together with the accompanying blood-vessels, producing the connective tissue surrounding the central retinal blood-vessels as they occupy the interior of the optic nerve.

The development of the nerve-fibers is a secondary but coincident process, the newly-formed fibers occupying the walls of the rapidly closing stalk. The older views which regarded the optic fibers as being produced *in loco* along the course of the optic stalk are no longer accepted since the investigations of Müller, Kölliker, His, and others showing that the young fibers grow

into the optic stalk from the nerve-cells located at its extremities. The great majority of fibers of the optic nerve may be regarded as the centrally directed outgrowths of the young neuroblasts situated within the developing retina: the axis-cylinder processes of these elements are guided in their journey to form central relations with the brain-centers by the supporting tissue contributed by the optic stalk. In addition, however, to the centrally growing fibers, there are others which pass in the opposite direction, and represent the peripherally directed axis-cylinder processes of the neuroblasts situated within the brain. Further complexity of structure later arises from the ingrowth of the vascular connective tissue constituting the pial sheath of the optic nerve, the extensions of which tissue form the septa subdividing the nerve into the variously sized bundles which are so conspicuous in transverse sections. The posterior parts of the optic stalks become the optic tracts, while their middle portions unite to form the optic chiasm. The sheaths of the optic nerve are produced by the direct continuation of the mesodermic investment from which the cerebral dura, arachnoid, and pia are derived.

**Development of the Fibrous and Vascular Coats.**—With the exception of the corneal epithelium, the lens, and the nervous tunic with its cerebral attachments, which are derived from the ectoderm, all parts of the eyeball are developed from the mesoderm surrounding the primary optic vesicle. Coincidentally with the changes affecting the optic vesicle, as already noted, the surrounding mesoderm exhibits a differentiation, marked by active cell-proliferation and condensation, which results in the production of a distinct envelope of actively growing embryonal connective tissue. The posterior segment of this mesodermic capsule undergoes further differentiation into an outer, relatively dense tunic, which becomes the sclerotic, and an inner coat, which later is distinguished by a looser texture and greater vascularity.

Very early in the history of the eye the lens-sac is separated from the overlying ectoderm by a thin stratum of mesodermic tissue; later this layer becomes cleft, one part remaining as a thin mesodermic sheet over the outer surface of the young lens, the other adhering to the inner surface of the ectoderm. The strata of mesoderm so formed constitute the pupillary membrane and the substantia propria of the cornea, the intervening cleft being the earliest indication of the future anterior chamber. The forward growth of the thin double-layered lip of the optic cup beyond the equator of the young lens and over its anterior surface is accompanied by a proliferation of the adjacent mesoderm and the extension of the primitive choroidal stratum which accompanies the retinal tissue in its growth forward. This anterior extension of the lip of the optic cup and the associated mesoderm gives rise to the rudiments of the iris and ciliary body, this expansion progressing until almost the entire anterior surface of the lens is covered: the central unoccupied area thus corresponds to a circular aperture within the retino-iridial sheet which remains as the pupil. In the early stages this opening is closed by the vascular pupillary membrane, a temporary structure which disappears before birth.

The active growth of the thin lips of the optic cup results in still greater attenuation of the component strata of epithelial cells until these are represented by the low columnar and cuboidal elements of the pars ciliaris and pars iridica retinae; the pigmentation of these epithelial cells also increases until the anterior portion of both layers is loaded with color-particles and the conspicuous pigment layer covering the posterior surface of the iris is produced. The accompanying mesodermic layer thickens and gives rise to

the stroma and muscular tissue of the iris and ciliary body, and for a time is also continuous with the vascular tunic of the lens.

About the beginning of the third month, in consequence of an unusual active lateral expansion, the epithelial layers are thrown into a series of radial folds which surround the equator of the lens: these plications are the earliest suggestion of the future ciliary processes, and into them shortly afterward delicate processes of mesodermic tissue extend; later these become more robust, and in them the characteristic richly vascular structures of the ciliary processes develop. In contrast to the deep pigmentation involving both epithelial layers of the pars iridica retinae, only the outer stratum of the pars ciliaris contains pigment, the elements of the inner layer remaining uncolored and retaining to a greater extent their original columnar form.

The corneal stroma becomes blended with that of the sclerotic tunic, so that eventually the two become continuous. With the formation of the anterior chamber the mesodermic elements immediately in contact with the lymph-space differentiate into flattened cells which become the posterior endothelium of the cornea and the anterior endothelium of the iris. The formation of the spaces of Fontana and of the trabeculae of the ligamentum pectinatum iridis is closely associated with the differentiation of the anterior extremity of the primitive choroidal tract and the production of the membrane of Descemet; to this tract the name *pars uvealis cornea* has been applied.

**Development of the Vitreous Body.**—This is intimately related with the primary changes of the optic vesicle. As already described, the invagination of the latter sac involves not only the external portion directed toward the surface, but affects likewise its inferior wall, resulting in the production of the choroidal fissure, which leads from the exterior into the cavity of the secondary optic vesicle. The surrounding mesoderm takes advantage of the cleft so established to gain entrance into the interior of the optic cup, which soon becomes filled with an extremely delicate mesodermic tissue occupying the space between the young lens and the retina. The primitive vitreous early becomes vascular by the multiplication and extension of the branches of the hyaloid artery, which is continued from the central retinal vessels as far forward as the inner and posterior surface of the lens, where they spread out to aid in forming the vascular tunica lentis.

The vitreous body, therefore, must be regarded as composed of modified mesoderm, and presents the characteristics of embryonal connective tissue throughout the earlier periods of its growth. Later, the blood-vessels of the vitreous disappear and the structural elements become reduced to atrophic cells of irregular form and distribution: the remains of the hyaloid vessels are sometimes observed even after birth as a delicate cord stretching from the optic-nerve entrance toward the lens. (See page 403.)

The peripheral zone of the young vitreous becomes condensed, and produces the hyaloid membrane which limits the vitreous on all sides except behind the lens, and is continued forward to fade away over the ciliary region.

**Development of the Eyelids.**—This begins quite early as an upper and lower fold of the integumentary layer, which grow over the corneal surface until they meet and fuse. The fusion of the palpebral folds in man takes place early in the third month of fetal life, the union continuing until shortly before birth, when the permanent separation is effected by cleavage through the common epithelial layer formed by the union of the ectoderm along the line of juncture.

During the period of fusion the mesoderm contained within the palpebral folds, bounded externally and internally by coverings of ectoderm, differentiates into thin layers, which give rise to the subcutaneous tissues, the muscular structures, and the subconjunctival or tarsal stratum. The Meibomian and other glands contained within the lid are derived as ingrowths and proliferations of the ectoderm covering the adjacent surface of the immature lid. The tear-gland appears during the third month as a solid ingrowth of the conjunctival ectoderm close to the upper lid; later the epithelial ramifications acquire a lumen. The ocular muscles, together with the various structures contained within the orbit, with the exception of the nerve-fibers, primarily are derivatives of the mesoderm.

The foregoing sketch of the development of the eyeball shows that the derivatives of the outer and middle blastodermic layers may be grouped as follows:

A. From the ectoderm are derived—

Anterior epithelium of the cornea and its conjunctival continuation.

Crystalline lens, including the epithelium of its anterior capsule.

Retina, including the anterior extensions forming the *pars ciliaris* and *pars iridica*.

Sustentacular tissue of the optic nerve.

B. From the mesoderm are derived—

Corneal stroma and endothelium.

Sclerotic coat.

Vascular tunic, including the choroid and the connective-tissue stroma of the ciliary region and iris.

Vitreous body.

Suspensory apparatus of the lens.

Connective-tissue investments of the optic nerve.

Vascular tissues of the retina.

The epithelial tissues of the eyelids and conjunctival sac, including the lid-glands, the lachrymal gland, and the lining of the tear-channels, are derivatives of the ectoderm; the surrounding connective tissues are products of the mesoderm.

### ANATOMY OF THE EYE.

**The Orbits.**—The orbits are horizontally-placed pyramidal fossæ, the anteriorly and somewhat outwardly directed bases of which correspond with the facial plane, their apices being occupied by the inner extremity of the sphenoidal fissure. The angles between the four conventional walls of the space are not sharply marked, but rounded off, so that the surfaces pass gradually one into the other, each orbital cavity approaching often more closely the conical than the pyramidal form. The inner walls, composed of the nasal process of the superior maxilla, the lachrymal, the ethmoid, and the body of the sphenoid, lie generally parallel with each other; the external walls, formed by the orbital surface of the malar bone and great wing of the sphenoid, on the contrary, form almost a right angle between their planes. The roof and floor, composed respectively of the frontal and small wing of the sphenoid and of the malar, the superior maxillary, and the palate bones, gradually converge toward the apex of the generally conical cavity.

The *orbital axes* do not correspond accurately with the horizontal plane, since at their posterior poles they lie from  $15^{\circ}$  to  $20^{\circ}$  above; when prolonged backward, the axes meet in the vicinity of the sella Turcica and include an angle of about  $43^{\circ}$ . The distance between the anterior ends of the orbital



axes is approximately 60 mm. The depth of the orbit varies from 40–45 mm., being usually from 3–5 mm. greater in the male than in the female skull. The capacity of the adult orbit approximates 30 c.cm.

The irregularly quadrilateral base of the orbit, corresponding to the facial apertures, is bounded by the thickened, rounded, and partially overhanging margins contributed by the frontal, malar, and superior maxillary bones. The apex is occupied by the inner and wider extremity of the sphenoidal fissure, the narrower continuation of which extends upward and outward as a conspicuous cleft separating the roof and outer wall of the orbit throughout the posterior half of their line of meeting. The optic foramen lies slightly to the inner and upper side of the apex of the orbit, within the smaller ala of the sphenoid. The angle between the external wall and the floor is occupied throughout its posterior three-fourths by the narrow and elongated sphenomaxillary fissure, which communicates with the sphenomaxillary fossa at its posterior inner end, and with the zygomatic fossa at its anterior outer extremity. The posterior part of the orbital floor is grooved by the beginning of the infraorbital canal; the contour of the anterior margin of the roof is interrupted by the supraorbital notch or foramen; the inner wall below lodges the lachrymal groove, formed by the lachrymal and superior maxillary bones, while higher, in close relation with the internal boundary of the arched roof, is the depression occupied by the pulley of the superior oblique muscle. Behind the external angular process lies the lachrymal fossa for the accommodation of the tear-gland.

**The Eyelids and the Conjunctiva.**—The eyelids are two broad movable folds of integument supplemented and strengthened by muscular bundles and dense fibrous tissue, and lined by a mucous membrane: they are attached to the upper and lower orbital margins, and aid in covering in the structures at the base of the orbit and the projecting anterior segment of the eyeball.

As already noted, the eyelids develop as duplications of integument which gradually approach, and, finally, about the end of the third month, fuse along the approximated edges to form a closed sac surrounding the anterior segment of the eyeball. Before birth the permanent separa-

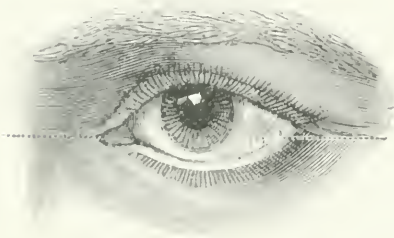

FIG. 12.—Eyelids naturally opened, from a photograph (Merkel). Horizontal plane passes through inner canthus.

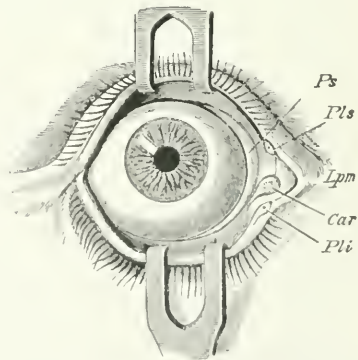


FIG. 13.—Right eye from before, the eyelids separated by hooks (Quain-Merkel): *Fs*, frontal sinus; *Pls*, plica semilunaris; *Pli*, superior and inferior lacrimal puncta; *Car*, lachrymal caruncle; *Lpm*, internal tarsal ligament.

tion of the lids takes place, by which time the skin in relation to the eyeball has lost its original integumentary characteristics, and has assumed those of a mucous membrane—the conjunctiva.

The palpebral fissure, bounded by the arched free margins of the eyelids, resembles an almond in its general form (Fig. 12). Its length, measured

from its extreme angles, is usually between 28 and 30 mm., and its greatest width when open is about 13 mm.

Individual variations from these measurements are very common, shortening and narrowing of the opening being not infrequent to the extent of several millimeters; slight differences in the palpebral clefts of the two eyes exist in many instances.

The symmetry of the palpebral opening is broken by the variation in its two angles, the *outer* or *lateral canthus* being bounded by the converging borders which directly continue the arches of the lids until they meet at an acute angle, while the *inner* or *mesial canthus* is situated at the junction of the slightly arching and almost parallel margins which enclose the diverticulum known as the *lacus lacrymalis*, or *tear-lake*. The latter is formed by the sharp deviation which the free lid-margins undergo about 5 mm. before reaching their mesial juncture, their subsequent direction being almost horizontal until they converge just before uniting (Fig. 12).

The space included between the rounded mesial extremities of the eyelids, or lachrymal lake, is partly occupied by a low, spongy-looking elevation of

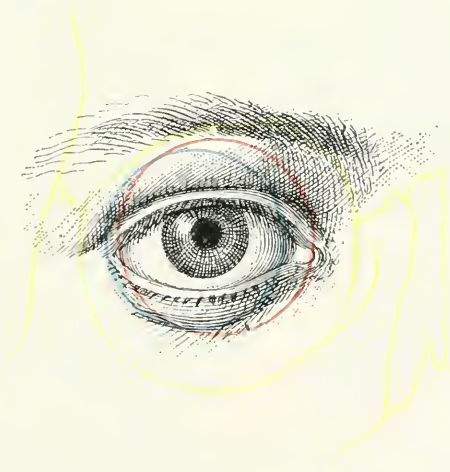

FIG. 11.—Relations of the palpebral opening to the eyeball (blue), conjunctival sac (red), and orbit (yellow) (Merkel).

reddish color, the *caruncula lacrymalis*; the caruncle is an isolated area of skin containing a few large modified sweat-glands, in addition to sebaceous follicles connected with the follicles of the minute hairs which spring from the summit of the elevation. Fat-cells and involuntary muscular tissue are also usually present. The lateral or outer extremity of the lachrymal caruncle sinks into the surrounding conjunctival tissue, which in this position presents a vertically placed crescentic fold, the *plica semilunaris* (Fig. 13). This duplicature represents a rudimentary nictitating membrane, or third eyelid, which in many lower types, as birds or amphibians, attains conspicuous dimensions. Minute cartilaginous plates and a few glandular acini lodged within the base of the semilunar fold are additional rudimentary representatives of the crescentic cartilage and Harder's gland of the lower animals.

The relation of the anterior segment of the eyeball to the palpebral opening varies with the position of the eyeball and the approximation of the lids. When the eyelids are apart and the eye directed horizontally forward toward distant objects, the cornea lies midway between the lateral canthus and the

lacrimal puncta, or slightly external to the middle of the line joining the canthi. The axis of the palpebral cleft does not quite coincide with the horizontal, since the mesial canthus lies a little lower than the external. The cornea is unequally covered by the two lids, the lower lid usually not quite reaching the corneal margin, while the upper lid covers a small variable segment of the periphery above. The extent to which the cornea is covered by the upper lid is an important factor in producing staring or somnolent expressions (Fig. 14).

Closure of the eye is chiefly effected by the upper lid, which from its larger size and general mobility covers about three-fourths of the exposed portion of the eyeball. The excursion made by the upper lid in closing and opening the palpebral orifice measures about 3 mm., the distance traversed by the lower lid being somewhat less. When the eyelids are closed during sleep the eyeball is rotated, so that the cornea lies above and slightly to the median side: closure of the lids while awake, however, is not attended with such change, the position of the cornea being then maintained. The slit-like palpebral fissure of the closed lids lies below the horizontal line drawn through the mesial canthus, the arched margin of the upper lid being directed downward, or just the opposite to its form when the eye is open.

The eyelid in the vicinity of its free border presents three principal strata when examined in section: (1) the skin and subcutaneous tissue; (2) the muscular layer; (3) and the tarsal plate covered with the conjunctiva (Fig. 15).

The integument of the eyelid presents the usual details of delicate skin in other locations, the hair-follicles and surface hairs being, however, extremely small and the subcutaneous tissue devoid of fat. The rounded outer margins of the lids bear conspicuous large hairs, the eyelashes or *cilia*; those of the upper lid are larger and more numerous than those of the lower, the former measuring from 9–12 mm. in length and numbering about 150, while the latter are only half as many and only from 6–8 mm. long. The hair-follicles of the cilia

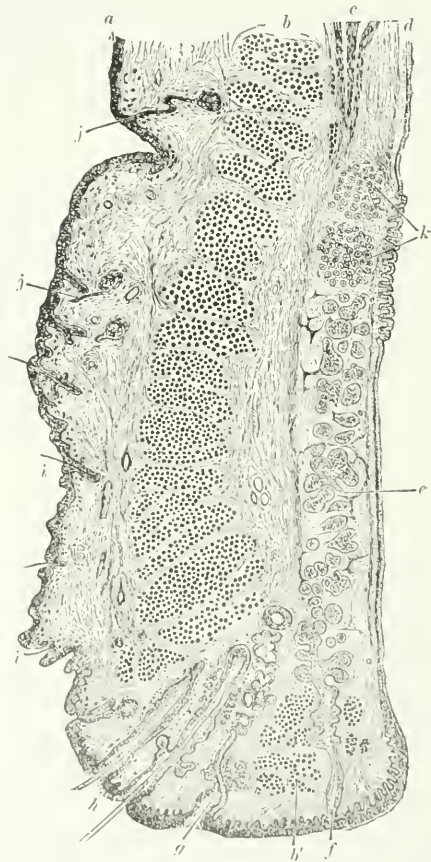


FIG. 15.—Vertical section through the upper eyelid (Waldeyer): *a*, skin; *b*, cut fibers of the orbicularis; *c*, ciliary bundle of orbicularis; *e*, muscle (involuntary) of Müller; *d*, conjunctiva; *e*, tarsal plate in which are imbedded the Meibomian glands (*f*); *g*, sebaceous glands near cilia (*h*); *i*, small hairs of integument; *j*, sweat-glands; *k*, posterior tarsal glands.



are arranged in double or triple rows near the anterior border of the lid. The average life of an eyelash is probably about four months, the older and thicker cilia being constantly replaced by the young and slender hairs.

The muscular layer of the eyelid consists essentially of the palpebral portion of the *orbicularis palpebrarum*, which is arranged as concentric fibers, which occupy the interval between the subcutaneous tissue and the tarsal plate and its associated tendons. The elliptical muscular bundles, when cut in longitudinal section of the eyelid, appear as irregular groups of transversely cut fibers. The innermost of the concentric bundles of the orbicularis lies close to the inner margin of the lid, and constitutes a robust and partly isolated group of fibers known as the ciliary muscle or muscle of Riolan. The fibers composing these bundles surround the structures occupying this part of the border of the lid, including the hair-follicles, sebaceous glands, glands of Moll, and the ducts of the Meibomian glands (Fig. 15).

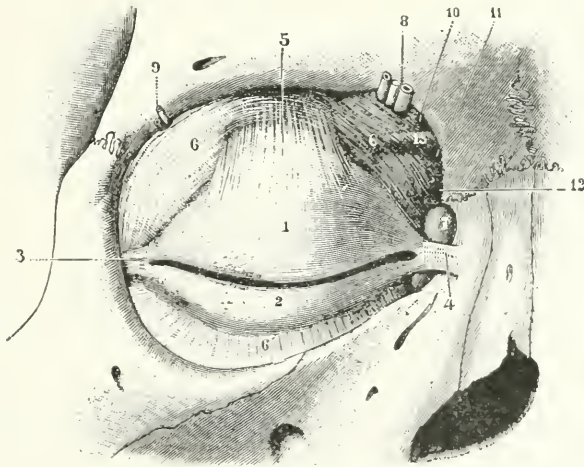


FIG. 16.—Dissection of the tarsal plates and their ligaments (Testut): 1, 2, upper and lower tarsus; 3, 4, external and internal tarsal ligaments; 5, expanded tendon of levator palpebrae; 6, 6', septum orbitale; 7, lachrymal sac; 8, supraorbital vessels and nerve; 9, lachrymal artery and nerve; 10, 11, openings for supra- and infraorbicular nerves; 12, opening for the angular vein; 13, tendon of superior oblique muscle.

The fibrous stratum of the eyelid has as its principal constituent the crescentic plate of firm fibrous tissue known as the *tarsus* or *tarsal cartilage*. This structure, composed entirely of dense connective tissue and without cartilage-cells, exists in both eyelids as a sustaining band, which is important in maintaining the proper form of the lid-margins. The tarsal plates vary in size in the two eyelids, the upper tarsus being broader and more arched than that within the lower lid. The extremities of the tarsi are united to each other and to the orbital walls by firm bands of fibrous tissue, the *mesial* and *lateral palpebral ligaments*. The upper tarsus, corresponding with the greater width of the superior lid, is wider than the lower plate, measuring about 10 mm. at the point of its greatest breadth, or about twice the width of the lower. In length the tarsi are almost equal, and extend along nearly the entire lid-margin, about the middle of which they possess their greatest thickness, diminishing toward either end as well as toward their convex borders.

The tendon of the levator palpebrae, as its lower broadened end expands

into the upper eyelid, becomes closely related to the inward extension of the orbital fascia, which, as the *septum orbitale*, passes from its peripheral attachment at the orbital margin into the eyelids, forming a partition which closes in the periorbital structures and prevents the extrusion of the orbital fat between the eyeball and orbit (Fig. 16).

In the upper lid the *septum orbitale* or palpebral fascia blends with the tendon of the levator palpebræ, the two forming a layer of connective tissue which intervenes between the orbicularis and the conjunctiva above, and is largely inserted into the tarsus below, some bundles passing in front of the tarsal plate. In the lower lid the *septum* joins the tarsus in common with fascial expansion connected with the inferior straight and oblique muscles.

The relations of the upper tarsal plate to the expanded tendon of the levator palpebræ muscle are most intimate. The fibrous tissue of the tendon of this muscle is arranged in three layers—the upper, which expands into bundles which are inserted into the summit of the conjunctival fornix and adjacent part of the orbital portion of the lid, while in the tarsal portion the fibrous bundles interlace with the muscle-fibers of the orbicularis palpebrarum, on the inner surface of which they form an imperfect fibrous sheet.

The middle part of the levator aponeurosis contains bundles of involuntary muscle, the so-called *superior palpebral* muscle of Müller, which are inserted principally into the upper margin of the tarsal plate. The lower stratum of the tendon consists of bundles of fibrous tissue, and is attached at various points to the conjunctiva, and is closely blended with the fascial process connected with the superior rectus muscle. In the lower lid the expansions of the fascial process connected with the inferior rectus replace the levator aponeurosis of the upper lid. Bundles of involuntary muscle occur also in the lower lid, and constitute the *inferior palpebral* muscle, while the fibrous bundles are interwoven with the fasciculi of the orbicularis palpebrarum.

The ocular surface of the tarsal plates, when inspected during life after eversion of the eyelids, presents numerous parallel vertical rows of small yellowish granules: these latter are the acini of the *Meibomian* or *tarsal glands* seen through the conjunctiva. When examined more carefully the tarsal glands are seen to be enlarged and modified sebaceous glands imbedded within, and occupying almost the entire thickness of, the dense connective tissue forming the tarsi; they number between thirty and forty in the upper lid and from twenty to thirty in the lower. Each gland consists of a straight or slightly sinuous vertical duct, from the sides of which open numerous diverticula or alveoli. The Meibomian glands occupying the middle of the tarsi are longer and more vertically disposed than those placed nearer the extremities of the plates, where the glands, in addition to being shorter, not infrequently terminate by sharply bending on themselves. The ducts terminate as minute puncta arranged in a row along the margin of the eyelid near its sharp inner border, and are lined by a direct continuation of the stratified squamous epithelium of the adjacent integument; the acini of the glands are clothed with cuboidal cells which resemble the elements found in other sebaceous glands, containing numerous fat-droplets within their protoplasm.

The free margins of the eyelids present an outer and inner border, which differ in their forms and relations; the outer border is somewhat rounded and beset with the long curved cilia, while the inner is sharply defined by the line of juncture of integument and conjunctiva, along which open the orifices of the Meibomian glands. In addition to the hair-follicles and associated

sebaceous glands lodged within the palpebral margin, a number of enlarged and modified sweat-glands, or *glands of Moll*, lie about midway between the two borders of the lid, and open in close proximity to or into the mouths of the hair-follicles; the glands of Moll in the upper lid extend into the surrounding tissue to a depth equal to the extremities of the hair-follicles in the lower lid—indeed, exceeding the hair-follicles in length. The ends of the hair-follicles, sebaceous glands, and glands of Moll are surrounded by the deepest fibers of the ciliary muscle of Riolan, the greater part of the group of muscular bundles lying between the glands of Moll and the tarsus.

The conjunctiva invests the ocular surface of the eyelids and the anterior segment of the eyeball, and is, therefore, appropriately divided into the *palpebral* and *bulbar* portions. The annular fold which marks the peripheral limit of the conjunctival sac is known as the *fornix conjunctiva*.

The palpebral conjunctiva presents a further subdivision into the *tarsal* and *orbital* areas, based on the differences which characterize these two segments. The conjunctiva covering the tarsus, directly continuous with the integument at the lid-margin, so closely adheres to the firm fibrous tarsal plate that the conjunctival membrane is immovably attached to the fibrous lamella; the Meibomian glands indistinctly show through the conjunctiva as vertically arranged, parallel, yellowish-white lines.

The *orbital conjunctiva*, covering the fascial and tendinous expansions which are blended with the arched border of the tarsi, is attached by the loose subconjunctival connective tissue to the subjacent structures, upon which it freely moves. In contrast to the velvety appearance of the tarsal portion, the orbital conjunctiva is smooth and glistening, although less firmly fixed to the underlying tissues.

The peculiar velvety appearance of the tarsal conjunctiva depends upon the presence of minute interlacing furrows and intervening ridges and papillæ; the latter are especially well developed near the orbital border of the tarsus. The lymphoid characteristics of the subepithelial layer of the tarsal conjunctiva are conspicuous in the situations in which the tarsal papillæ are best developed; hence in the vicinity of the tarsal border the general lymphoidal infiltration is often replaced by local aggregations of cells in the form of lymph-follicles or trachoma-glands. These structures, however, are very variable in their position, number, and size, and may be entirely wanting or found in other parts of the conjunctival sac.

At the mesial canthus the conjunctiva lines the lachrymal lake, and on the caruncle maintains its primary integumentary character. Just external or lateral to the puncta the conjunctiva presents a well-marked vertical crescentic fold, the *plica semilunaris*, which represents a rudimentary nictitating membrane.

The conjunctiva covering the tarsi and the corner is more fixed than elsewhere, being in these situations so inseparably attached to the subjacent structures that it follows the frequent movements of these parts.

The remaining portions of the conjunctiva are separated from the underlying structures by the subconjunctival tissue, which, on account of its loose and elastic nature, allows the conjunctiva to be moved to and fro with readiness. The same loose character of this areolar tissue permits the accumulation, and consequent distortion, of extravasated fluids to an enormous degree.

The epithelium lining the several portions of the conjunctival sac varies; thus, over the tarsal region the cells retain the stratified squamous character of the adjacent palpebral integument; shortly beyond the attached border of the tarsi the cells assume a columnar form, which they retain over the

foreskin on to the bulbar surface, where the cells again become squamous. This latter type includes the elements constituting the anterior epithelium of the cornea. The subepithelial stroma throughout the orbital conjunctiva is especially rich in elastic fibers, which are well represented in the fornix and bulbar conjunctiva almost as far as the corneal margin. In the latter vicinity the tunica propria of the conjunctiva ends by blending with the sclerotic, while the epithelium alone continues uninterruptedly over the corneal surface: the termination of the conjunctival stroma is sometimes indicated by an annular thickening which corresponds to the limbus corneae in position.

Glands have been described within the more concealed portions of the conjunctival sac, those of the fornix very closely resembling the tear-gland in structure. Adipose tissue not infrequently occurs as groups of fat-cells; in advanced age the accumulation becomes conspicuous as a yellowish patch close to the corneal margin.

The *blood-vessels of the eyelids* are derived from several sources (Fig. 17),

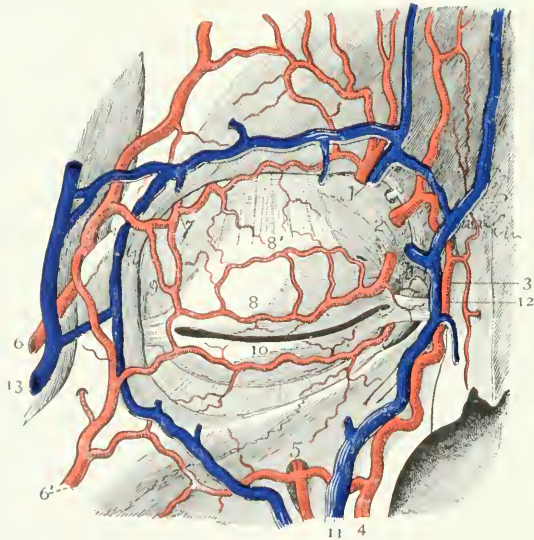


FIG. 17.—Blood-vessels of the eyelids (Testut): 1, supraorbital artery and vein; 2, nasal artery, anastomosing with terminal branch of angular (3) of facial artery (4); 5, infraorbital artery; 6, superficial temporal artery; 7, malar branches of transverse facial; 8, lachrymal; 9, superior palpebral artery, with secondary arch (8'), and anastomoses (9) with temporal and lachrymal; 10, inferior palpebral artery; 11, facial vein; 12, angular vein; 13, superficial temporal vein.

since all the surrounding neighboring arteries contribute branches which more or less directly take part in the supply of the palpebral folds. The principal blood-supply of the eyelids is from the internal and external palpebral arteries; the former are direct branches from the ophthalmic, usually by a common trunk given off just before the ophthalmic artery divides into its frontal and nasal branches, and the latter are derived from the lachrymal. The internal palpebral arteries, commonly somewhat larger than the external, include a superior and inferior, which after piercing the palpebral fascia as the marginal arteries, run along the free margin of the corresponding eyelid, from 2.5–3 mm. removed, and anastomose with the external palpebral vessels to form the upper and lower tarsal arches. The transverse facial and superficial temporal contribute branches which join in the anastomotic circuit at the outer margin of the orbit.



In the upper eyelid, and sometimes less perfectly developed in the lower as well, a secondary tarsal arch is formed by a branch of the superior palpebral, the superior marginal artery, which runs along the convex border of the tarsal plate between the lamellæ of the tendon of the levator palpebræ. Numerous small twigs join the tarsal arches, and establish an elaborate anastomosis in which the infraorbital and facial arteries also take part. Branches of distribution pass forward from the tarsal arches for the supply of the integument and orbicularis, and backward, by means of perforating and encircling twigs, to supply the tarsus and Meibomian glands and the palpebral conjunctiva. The supply of the tarsus is maintained especially by the superior tarsal arch, while the inferior arch is devoted to the nutrition of the margin of the eyelid. Just before the internal palpebral artery reaches the lid numerous twigs are distributed to the lachrymal caruncle, tear-sac, and the tissues surrounding the latter and the canaliculi. The nasolachrymal canal receives its supply from a branch formed by the anastomosis of the infraorbital with the inferior internal palpebral artery.

The *veins of the eyelids* do not accurately follow the course of the arteries, but are arranged in two series, the post-tarsal and pre-tarsal. The former collects the blood from the conjunctival surface and a part of the Meibomian glands, and is tributary to the ophthalmic vein; the latter receives radicles from the integument, muscular structure, and the Meibomian glands, and forms a subcutaneous network which passes into the superficial temporal and facial veins.

The *lymphatics of the eyelids* are disposed as a pre-tarsal and a post-tarsal network, the former of which receives the tissue-juices from the integument and muscle, the latter from the conjunctiva and Meibomian glands. Perforating branches establish communication between the two networks. The submaxillary and parotid lymph-glands receive the larger lymph-vessels from the palpebral networks.

The *sensory nerves of the eyelids* are derived from the ophthalmic and superior maxillary divisions of the trifacial. The upper eyelid is supplied principally by branches from the frontal and supraorbital nerves, which freely join and form a *superior marginal plexus* along the edge of the eyelid. The chief supply of the lower lid is derived from the branches of the infraorbital nerve, which ascend to the border of the lower lid, where they form the *inferior marginal plexus*. These nerves are supplemented by twigs from the supra- and infratrochlear branches, which are distributed to the area around the mesial canthus. An especial lower branch from the infratrochlear nerve supplies the mucous membrane of the lachrymal sac. The terminal branches of the lachrymal nerve become subcutaneous a short distance beyond and above the external canthus, contributing a few twigs to the eyelids, but ending chiefly in the integument to the outer side of the orbit.

The *motor nerves* distributed to the muscular structures of the eyelids include branches from the oculo-motor to the levator palpebræ, and from the facial to the orbicularis palpebrarum; additional sympathetic fibers are distributed to the involuntary muscle of the lids. The ramifications of the motor and sensory nerves freely intermingle, and constitute a network of considerable complexity within the superficial structures of the eyelids.

**The Contents of the Orbit.**—The orbital contents, including the visual apparatus, consisting of the eyeball and its associated nerves, muscles, and glands, and the incidental structures, as branches of the ophthalmic blood-vessels and the trifacial nerve, which pass through the orbit *en route* to more remote parts, are supported by the general fibro-adipose intraorbital tissue.

This periocular cushion of fat occupies the interspaces between the various connective-tissue partitions and bands constituting the fibrous framework, which separates, as well as holds together, the various constituents of the orbital contents. Variations in the amount of the intraorbital fat affect the relations of the eyeball to the orbital opening, a conspicuous example of such change being familiar in the sunken or "hollow-eyed" appearance following illness or conditions favorable to the absorption of adipose tissue.

Since the majority of the structures within the orbit are grouped around the eyeball as parts subservient and accessory to the visual organ, the position of the ocular bulb with relation to the orbit is of importance, inasmuch as this

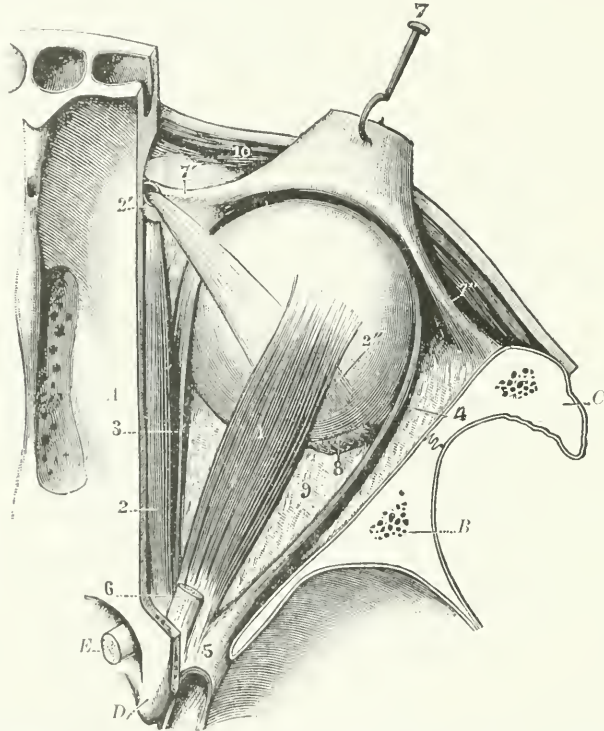


FIG. 18.—Ocular muscles of right side, viewed from above, after removal of roof of orbit (Testut). *A*, frontal bone; *B*, section of great wing of sphenoid; *C*, section of malar bone; *D*, anterior clinoid process; *E*, optic nerve; 1, superior rectus; 2, superior oblique muscle with its pulley (2') and its insertion into the eyeball (2''); 3, internal rectus; 4, external rectus; 5, common origin (ligament of Zinn) of muscles; 6, cut tendon of levator palpebrae; 7, 7', 7'', palpebral expansion of same; 8, insertion of inferior oblique; 9, intraorbital cushion of fat; 10, orbicularis palpebrarum.

primary relation largely determines the secondary arrangement of the associated structures. The eyeball corresponds with the orbit neither in the direction of its axis nor in the position of its center, since the bulbar axis subtends with that of the orbit an angle of from  $42^{\circ}$  to  $45^{\circ}$ , while the eyeball itself lies 1 or 2 mm. nearer the lateral than the mesial wall, and probably also slightly nearer the roof than the floor. Owing to the eccentric position of the eyeball, together with the receding plane and the slight projection of the lower and outer segment of the orbital margin, the position most favorable to reach the bulb is the vicinity of the inferior and external angle. The ball occupies the anterior half of the orbit, its position being such that a line joining the upper and lower margins of the orbit opposite the anterior pole comes in contact with the anterior corneal surface.



**The Ocular Muscles.**—The eyeball is rotated around its three principal axes by the individual or combined action of six muscles—the four straight and the two oblique; an additional seventh muscle, the *levator palpebrae*, is attached to the upper eyelid, which it raises.

Of the six muscles inserted into the eyeball, all except the inferior oblique, which occupies the anterior part of the orbit, take their origin from the apex of the orbit and pass forward to their insertion. The elevator of the eyelid has a similar course, since its origin is closely associated with the straight muscles of the ball (Fig. 18).

The four straight or recti muscles may be considered as having a common tendinous origin from the fibrous ring which is attached to the apex of the orbit. This fibrous oval ring, the *ligament of Zinn*, passes down the inner side of the optic foramen as far as its lower margin, then extends transversely across the inner part of the sphenoidal fissure, to the lower border of which it is attached, again bridges the sphenoidal fissure about the middle, and finally gains the upper margin of the optic foramen. The tendinous origins of the straight muscles from the ligament lie so closely placed that at first they are continuous, and form a somewhat flattened tube which extends between 2 and 3 mm. before separating into the individual tendons of the recti muscles. The tendinous tube is particularly strong above and below, the thickened bands developed within the ring at these points being sometimes described as the *common tendons*. The origins of the levator palpebrae and superior oblique form a second imperfect concentric layer to the inner side of the optic foramen, where they constitute a crescentic zone in close relation to the origin of the superior and internal rectus.

The *superior rectus* arises from the upper border of the optic foramen and beneath the levator palpebrae; the *internal rectus* occupies the mesial or inner and part of the lower margin of the foramen; the *inferior rectus* springs from its lower border; while the *external rectus* possesses two heads. The lower and larger head is attached to the inferior and inner border of the sphenoidal fissure and that part of the tendinous ring which stretches across the fissure; the upper and outer, or accessory, head springs from the outer wall of the sphenoidal fissure, being separated from the main part of the muscle by a narrow interval occupied by a small amount of connective tissue and the third and sixth nerves and the nasal branch of the fifth, together with the ophthalmic veins. The four recti muscles proceed forward toward the eyeball, the posterior half of which they embrace above, below, and at the sides, and are inserted into the sclera by short, thin, and slightly broadened tendons a short distance behind the corneal margin (Fig. 19).

The straight muscles differ considerably, when compared with one another, in their general development, length, breadth, and exact place of insertion. As is to be expected from its unusual work in converging the eyes, the internal rectus leads in its general development, being the broadest and strongest, as well as possessing the longest tendon and most anteriorly situated place of insertion. The superior rectus is the smallest and weakest of the straight muscles, and has its insertion farthest from the cornea, but possesses the broadest line of attachment; the inferior and external recti exceed the others in their length.

Shortly before reaching the eyeball the muscular fibers of the recti terminate in thin membranous and somewhat expanded tendons of insertion, the fibers of which not only blend, but become intimately interwoven, with the tissue of the sclerotic coat. The lines of attachment, the slight convexities of which are directed toward the cornea, vary in their relation to the corneal

margin, that of the internal rectus being nearest, and that of the superior rectus farthest removed. The length of the tendons of insertion of the

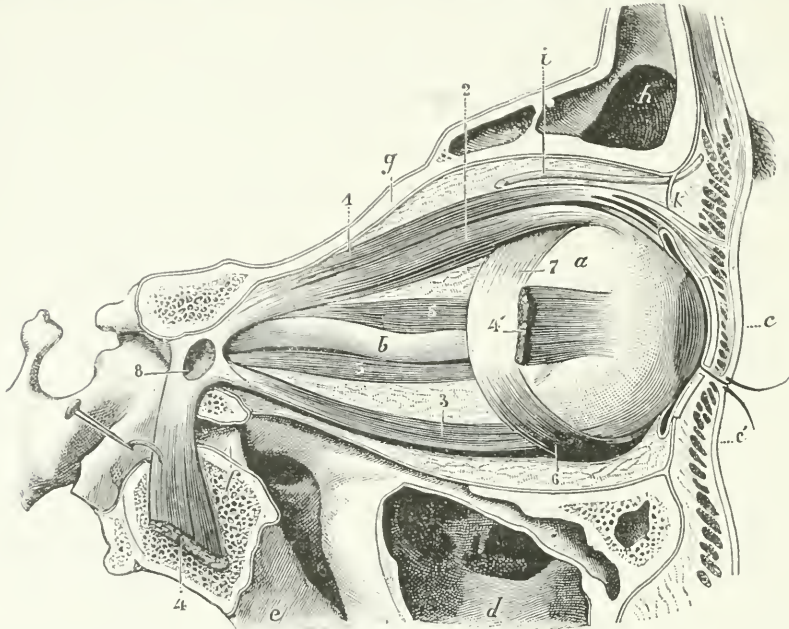


FIG. 19.—Ocular muscles viewed after removal of lateral wall of orbit (Testut); *a*, eyeball; *b*, optic nerve; *c, c'*, eyelids; *d*, maxillary sinus; *e*, pterygoid plate; *f*, foramen rotundum; *g*, roof of orbit; *h*, frontal sinus; *i*, supraorbital nerve; *k*, septum orbitale; 1, levator palpebrae superioris; 2, 3, superior and inferior recti; 4, 4', portions of the cut external rectus; 5, internal rectus; 6, inferior oblique; 7, insertion of superior oblique; 8, annular ligament or tendon of Zinn.

recti and the distance from the cornea, determined by the accurate measurements of Merkel and of Fuchs, are as follows:

|                           | Length of tendon. | Distance of insertion from cornea. |
|---------------------------|-------------------|------------------------------------|
| Internal rectus . . . . . | 8.8 mm.           | 5.5 "                              |
| Inferior rectus . . . . . | 5.5 "             | 6.5 "                              |
| External rectus . . . . . | 3.7 "             | 6.9 "                              |
| Superior rectus . . . . . | 5.8 "             | 7.7 "                              |

The insertion-lines, therefore, progressively recede from the corneal margin from the insertion of the internal rectus to that of the superior, with a cor-

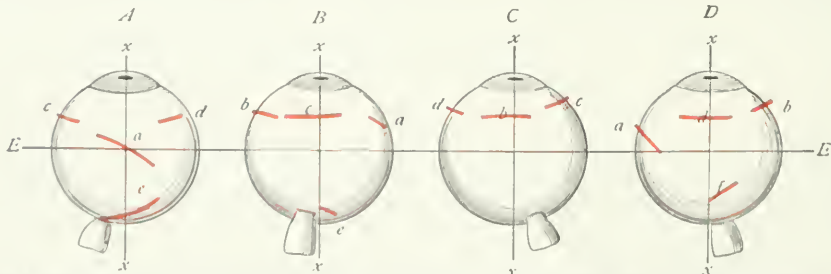


FIG. 20.—Diagram of the positions of the insertions of the ocular muscles (Fuchs-Testut). Right eye. *A*, viewed from above; *B*, from nasal side; *C*, from below; *D*, from temporal side; *x, x*, antero-posterior axis; *E, E*, equator; *a, b, c, d*, superior, inferior, internal, and external rectus; *e, f*, superior and inferior oblique.

responding diminution in the effectiveness of the pull of the several muscles. As suggested by Tillaux, the distance of the insertions from the

cornea may be taken, for practical purposes, respectively as 5, 6, 7, and 8 mm. (Fig. 20).

The *superior oblique*, or *trochlearis*, arises about 2 mm. in front of the inner margin of the optic foramen; it proceeds forward and upward in close relation to the orbital wall, as far as the trochlear fossa, where its rounded tendon traverses the short fibrous tube of the trochlea, and, at the anterior extremity of the canal, changes its direction at an angle of about  $50^\circ$ , the muscle passing backward and outward between the eyeball and the anterior end of the superior rectus, to find its insertion into the sclerotic beneath the latter muscle, about midway between the corneal margin and the optic nerve.

The *inferior oblique*, situated within the anterior part of the orbit, arises from the mesial wall of the orbit, close to its anterior margin, from a slight depression in the orbital plate of the maxilla over the outer wall of the naso-lachrymal duct. Starting in short tendinous fibers, the muscle leaves the orbital wall and sweeps in a gentle curve

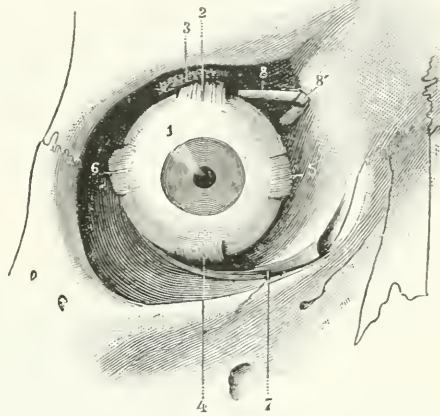


FIG. 21.—The eyeball *in situ* with its muscles after removal of surrounding parts of orbital contents (Testut): 1, eyeball; 2, superior rectus; 3, levator palpebrae; 4, inferior rectus; 5, internal rectus; 6, external rectus; 7, inferior oblique; 8, superior oblique; 8', pulley and reflected tendon of same.

outward, backward, and upward, passing between the inferior rectus and the floor of the orbit, and terminates in a tendon which is inserted into the sclerotic at the posterior and outer part beneath the rectus externus (Fig. 21).

The *levator palpebrae superioris*, as indicated by its name, is related to the upper eyelid, and claims attention in this place only on account of its incidental association with the ocular muscles. In its origin it is closely related to the superior rectus, arising by a pointed tendon above and in front of the optic foramen. The muscle broadens in its course along the roof of the orbit, close to the periosteum for the greater part of its length, and covers the posterior half of the superior rectus; on reaching the anterior part of the orbital cavity, a little behind its superior margin, it descends through the adipose tissue as a membranous expansion which is attached to the root of the upper eyelid. Its insertion is peculiar, and consists of two distinct layers: the upper anterior of these is fibrous and passes in front of the tarsal plate, blending with the fibers of the orbicularis, while the lower posterior layer contains non-striped muscular tissue, and is inserted into the upper border of the tarsus, constituting what is often described as the *superior palpebral muscle of Müller* (Fig. 23).

Closely associated with the actions of the superior and inferior recti are the oblique muscles, by means of which the obliquity of the pull of these straight muscles is neutralized. The action of the *superior oblique*, from the location of the insertion and direction of its fibers, when the eyeball is in the primary position, is to move the cornea downward and outward; that of the *inferior oblique* is to cause the cornea to move upward and outward. The slight outward rotation thus effected takes place, however, in opposite directions, since when caused by the superior oblique the movement of the cornea



is from within outward, while when produced by the inferior oblique the upper half of the vertical diameter is displaced outward, the lower half at the same time being deflected inward. The obliquity of the pull of the oblique muscles is, therefore, well adapted to neutralize the obliquity attending the contraction of the superior and inferior recti, and, in point of fact, simple elevation and depression of the cornea are effected by the combined action of the superior straight and the inferior oblique and the inferior straight and the superior oblique, respectively.

Oblique movements are also the results of the associated efforts of the recti and oblique muscles, as instanced in the common action of the superior and internal recti and the inferior oblique in movements by which the cornea is carried upward and inward; the inferior and external recti and the superior oblique are similarly associated in moving the cornea downward and outward.

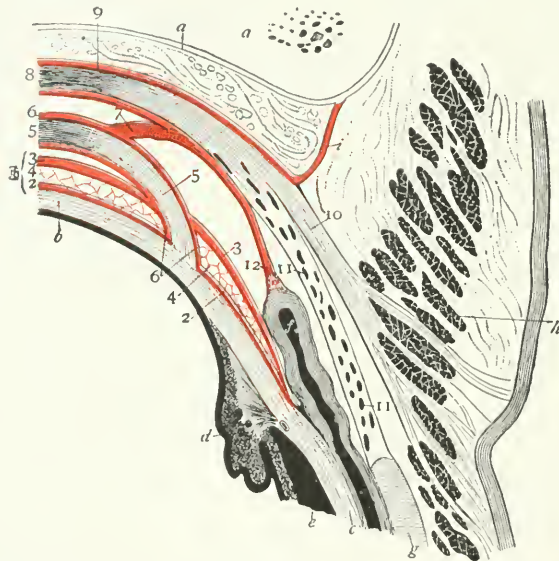


FIG. 22.—Semi-diagrammatic view of the relations of the orbital fascia with the superior muscles (Testut): *a*, frontal bone, with its periosteum (*a'*); *b*, sclerotic; *c*, cornea; *d*, ciliary process; *e*, anterior chamber; *f*, superior fornix of the conjunctiva; *g*, superior tarsus; *h*, orbicularis palpebrarum; *i*, septum orbitale; 1, capsule of Tenon, consisting of its inner (2) and external (3) wall and the enclosed lymph-space (4); 5, 5', 6, respectively the belly, tendon, and sheath of the superior rectus; 7, orbital prolongation; 8, levator palpebrae, with its sheath (9) and its conjunctival (10) and muscular (11) insertions; 12, its prolongation and insertion into the fornix conjunctiva.

In all other oblique movements of the cornea, likewise, the straight muscles are supplemented by the oblique, the desired motion representing the resultant of the forces exerted. Abduction and adduction further influence the action of the superior and inferior recti in consequence of the alterations in the direction of the pull; thus, when the eyeball is strongly abducted the transverse axis coincides with the axis around which elevation and depression occur, in which case the superior and inferior recti exert a simple action without their accustomed tendency toward oblique or rotary movement. (See also page 100.) The actions of ocular muscles are further described on pp. 497, 498.

**The Orbital Fascia.**—The periosteum of the orbit, directly continuous with the intracranial dura through the sphenoidal fissure, forms a funnel-shaped investment, which encloses the orbital contents and becomes blended with the external periosteum around the margins of the orbit. Numerous

septa of fibrous tissue are intimately connected with the inner surface of the periosteum on the one hand, and extend between the various structures lodged within the orbit, to which they afford support and protection on the other; the framework thus formed is largely occupied by the cushion of periocular fat which fills the interspaces between the eyeball, blood-vessels, nerves, and muscles.

In the immediate vicinity of the eyeball the intraorbital fibrous tissue becomes condensed to form a fascial investment which surrounds the greater part of the organ; this fibrous envelope is known as the *tunica vaginalis oculi*, or *capsule of Tenon*. This consists of a tunic of fascia of considerable strength which surrounds the posterior two-thirds of the eyeball, from which it is separated by a narrow lymph-cleft, the *space of Tenon*; the interval between

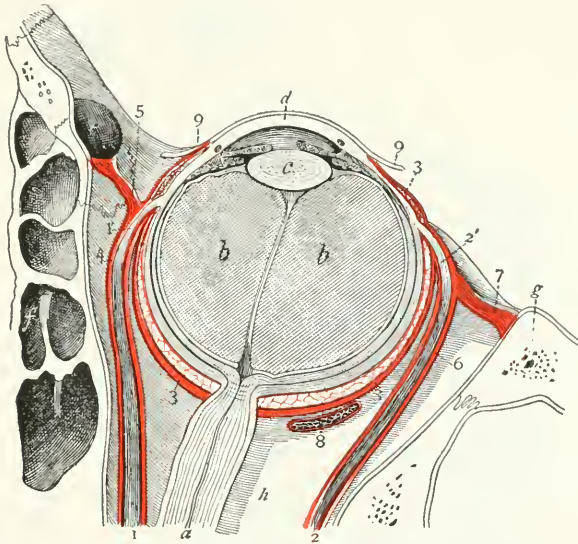


FIG. 23.—Semi-diagrammatic view of the orbital fascia of right side, seen after horizontal section of the eyeball and orbit, the lower half of the eyeball being represented (Testut): *a*, optic nerve; *b*, vitreous body; *c*, lens; *d*, cornea; *e*, section of lacrimal sac; *f*, ethmoid cells; *g*, malar bone; *h*, floor of orbit; 1, 2, internal and external rectus, with their tendons (1', 2'); 3, capsule of Tenon; 4, sheath of internal rectus with its orbital prolongation (5); 6, sheath of external rectus, with its orbital prolongation (7); 8, inferior oblique, with its sheath; 9, conjunctiva.

the eyeball and capsule is bridged by numerous delicate bundles of fibrous tissue which pass from the fibrous tunic to the adjacent sclera, thus subdividing the general cavity into a great number of imperfectly separated, freely intercommunicating spaces. The inner surface of the capsule, as well as the outer surface of the sclera and the trabecula, is clothed with endothelial plates, the entire space of Tenon strongly recalling the intracranial sub-arachnoidean lymph-space, which it closely resembles. The loose attachment of the capsule to the eyeball facilitates the free play of the visual organ in the fossa thus formed within the peribulbar adipose cushion, the eyeball moving in the capsule in a manner somewhat resembling an articulation.

The relations of Tenon's capsule are so complicated by its prolongations and attachments to surrounding structures that special reference to these is desirable. Posteriorly, the capsule extends as far as the point at which the optic nerve pierces the sclerotic coat, where it fuses with the sclera and outer sheath of the nerve as the latter blends with the fibrous tunic of the eyeball; likewise the ciliary arteries and nerves are excluded from the space. Ante-

riorly, the capsule lies beneath the ocular conjunctiva, with which it blends close to the margin of the cornea. If the conjunctiva is divided by a circular incision just posterior to the corneal margin, the capsule of Tenon will be found so closely united with the conjunctiva that reflection of the latter structure will open Tenon's space and expose the capsule at its anterior limit (Fig. 23).

The tendons of the various ocular muscles pierce the capsule of Tenon in order to gain their insertions into the sclera, which may thus be regarded as lying within the space of Tenon, although the tendons are separated from actual contact with the lymph-stream by means of an endothelial covering. The slit-like openings in the capsule made by the passage of the tendons are strengthened by local thickenings of the fibrous tunic, from which tubular

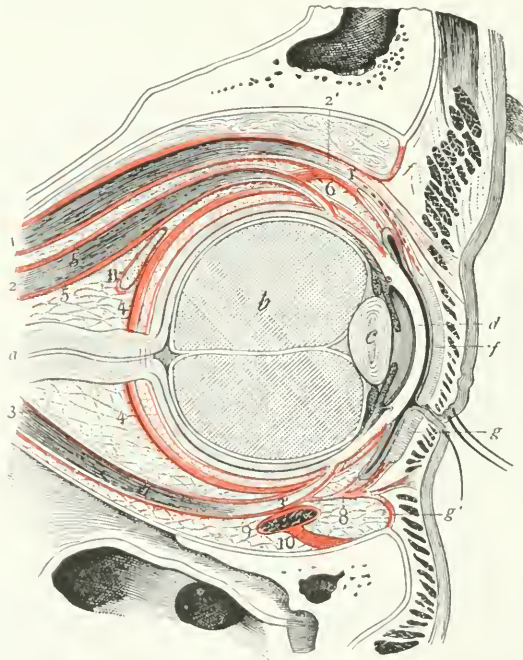


FIG. 21.—Semi diagrammatic view of relations of orbital fasciae as seen after sagittal section of the right eye; the internal half of orbit *in situ* (Testut): *a*, optic nerve; *b*, vitreous body; *c*, crystalline lens; *d*, cornea; *f, g*, upper and lower tarsal plates, with their ligaments (*f', g'*); 1, levator palpebrae, with its tendon; 2, 3, superior and inferior recti, with their tendons (2', 3'); 4, capsule of Tenon; 5, sheath of superior rectus, with its orbital prolongation (6); 7, sheath of inferior rectus, with its orbital prolongation (8); 9, inferior oblique muscle, with its orbital prolongation (10); 11, tendon of superior oblique.

extensions of the capsule are prolonged backward upon the muscles for a variable distance, approximately for half their length. The fascial sheaths thus obtained become gradually more and more attenuated in their course toward the origin of the muscles, until finally they fade away by blending with the perimysium. In the case of the superior oblique the tubular prolongation of the capsule extends only over the reflected tendon of the muscle, and terminates at the trochlea, where it ends by becoming attached to the margin of the pulley. The sheath investing the inferior oblique extends as far as the floor of the orbit, and there fuses with that accompanying the inferior rectus.

The inner or ocular border of the vertical slit-like openings through which the tendons of the straight muscles, particularly of the external and



internal, pass, is especially strengthened by thickenings of the fascia, which are further reflected outwardly along the adjacent sides of the tendon-sheaths, forming additional connections between the muscles and the capsule of Tenon. In view of the fact that the latter structure at certain points is firmly connected with the bony walls of the orbit, these supplementary bands in a measure act as pulleys and effect the important object of preventing undue pressure on the eyeball during muscular contraction.

In addition to the foregoing conjunctival and muscular relations, the capsule of Tenon is connected with the orbital walls by means of fascial bands, the most important of which are the suspensory and check ligaments (Fig. 24). The *suspensory ligament* consists of a band of orbital fascia in the anterior part of the orbit, where it forms a hammock-like band of considerable breadth and density; the suspensory ligament is attached mesially to the lachrymal and externally to the malar bone, while its broader central part blends with the capsule of Tenon below the eyeball, to the support and position of which it materially contributes. A somewhat similar but less well-developed band lies above the eyeball and blends with the sheath of the superior rectus and the levator palpebræ, its extension forward coming into close relations with the upper lid. Other fibrous bands stretch across the orbit above the levator palpebræ from the trochlea to the fronto-zygomatic juncture, and thereby form a fascial arch of importance to the support of the upper division of the lachrymal gland.

The *check ligaments* are robust bands which extend from the fascial sheaths surrounding the external and internal recti muscles laterally as far as the malar and lachrymal bones respectively, where they blend with the extremities of the suspensory ligament already described. Their action in limiting the contraction of the outer and inner straight muscles and in preventing excessive rotation of the eyeball is appropriately suggested by their name of "check ligaments." A somewhat similar, but less complete, arrangement exists in connection with the superior rectus, the contraction of which muscle is still further limited by close association with the levator palpebræ. The fascial extension from the sheaths of the inferior rectus is joined by a process from that of the inferior oblique, the two constituting a fibrous band of considerable strength which is attached to the floor of the orbit on the one hand, and blends with the suspensory ligament of the eyeball on the other.

**The Lachrymal Apparatus.**—The lachrymal apparatus consists of the tear-gland, lodged in the anterior part of the upper and outer orbital wall, and the system of canals by which the tears are conveyed from the inner side of the conjunctival sac to the inferior nasal meatus.

The *lachrymal gland*, resembling in shape and size a small almond, consists of two fairly distinct parts—the superior *orbital* portion and the inferior *palpebral* or *accessory* portion. The former, occupying the fossa lacrimalis, is distinctly larger, and measures about 20 mm. in length, 12 mm. in breadth, and 5 mm. in thickness, just reaching the orbital margin at the point where the roof of the orbit joins the outer wall. The upper convex surface is attached to the periosteum of the depression in which it is lodged. Below the gland is supported by the fascial arch, which extends from the trochlea to the fronto-malar suture.

The lower or *palpebral portion* of the gland, sometimes described as a distinct *glandula lacrimalis inferior*, is somewhat smaller than the upper, from which it is partially separated by the fascial expansion already mentioned. Its lower concave surface rests upon the fornix of the conjunctiva and extends laterally almost to the outer canthus.



In structure the lachrymal gland corresponds to a tubulo-racemose gland of the serous type, its acini being drained by a number of small ducts which in the orbital portion of the gland unite to form from three to six larger canals; these receive as tributaries the ducts from the lower portion of the gland, the canals so formed opening by distinct orifices arranged with considerable regularity in a line in the fornix.

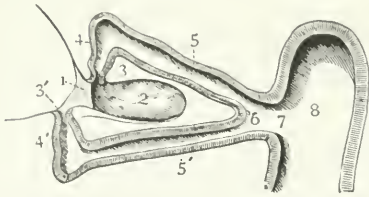


FIG. 25.—Section exposing the lachrymal channels and part of the lachrymal sac (Testut): 1, plica semilunaris; 2, lachrymal caruncle; 3, 3', lachrymal puncta; 4, 4', vertical portions of lachrymal canaliculi; 5, 5', horizontal portions; 6, fused portion; 7, opening into lachrymal sac (8).

In addition to the chief ducts, which open with definite regularity, a variable number of smaller, independent canals terminate in irregular groups about the apertures of the larger ducts.

The *lachrymal passages* (Fig. 25), including segments of very varying lumen and course, begin at the small crater-like *lachrymal puncta* which

surmount the conical *lachrymal papillae*. The latter elevations occupy the sharply defined margins of the lids just where the mesial end of the arched palpebral borders passes over into the approximately horizontal and more nearly parallel boundaries of the lachrymal lake. The upper punctum lies 6 mm. from the mesial canthus, the lower one being slightly farther removed. The apex of each papilla is directed toward the conjunctival surface, over which it glides during the changes of position of the bulbar conjunctiva occasioned by the excursions of the eyeball. The lachrymal puncta are immersed in the collection of tears occupying the inner angle of the conjunctival sac, and continually carry off the secretion of the tear-gland by capillary attraction. When closely examined the upper and lower papillae and puncta are seen to vary slightly, the upper papillae being more slender, higher, and pierced by a punctum about 0.05 mm. less in diameter than that of the lower lid.

In structure the papillae resemble the adjacent tarsal bands, being largely composed of closely-felted bundles of fibrous tissue, meagerly supplied with blood-vessels, well calculated to resist the action of the orbicular muscle.

The *lachrymal canaliculi*, into which the puncta open, have at first a vertical course; very soon, however, they bend sharply, and continue their converging course generally parallel to the margins of the lachrymal lake as far as the inner canthus, where the canaliculi usually unite in a common canal which almost at once terminates by opening into the lateral and slightly posterior wall of the lachrymal sac. In exceptional cases the canaliculi maintain an independent course, and terminate by separate orifices which open into a diverticulum of the lachrymal sac, the *sinus of Maier*. The entire length of each canaliculus measures from 8–10 mm., the upper canaliculus being longer, more curved, and steeper in its descending course than the lower. The lumen of the canal varies at different points: beginning at the narrow orifice of the punctum, which marks the most constricted point and measuring only 0.1 mm. in diameter, the canal soon widens into a spindle-form dilatation, which is followed by a diverticulum occupying the bend of the canaliculus. The horizontal portion of the canal measures a little over 0.5 mm. in diameter.

The walls of the canaliculi consist of a lining of stratified squamous epithelium supported by a delicate tunica propria rich in elastic fibers; outside, the muscular bundles of the lachrymal portion of the orbicularis palpe-

brarum contribute an additional stratum, and by their sling-like fibers constitute a sphincter around the vertical portion of the canaliculi.

The *lachrymal sac*, into which the canaliculi open, may be regarded as the upper dilated orbital segment of the naso-lachrymal duct, the lower part of which, or the duct proper, traverses the bony canal and opens into the inferior nasal meatus. The length of the sac approximates 12 mm., when distended measuring between 6 and 7 mm. in diameter.

The sac is situated at the side of the nose, near the inner canthus, and lies within the deep lachrymal groove between the superior maxillary and the lachrymal bone; its upper part is embraced externally by the mesial tarsal ligament and some of the inner fibers of the orbicularis palpebrarum, while the orbital surface of the sac is covered by the fibers which spring from the lachrymal bone and constitute the *tensor tarsi*, or *Horner's muscle*. The upper blind end of the sac, or fundus, usually reaches to the level of the upper margin of the tarsal ligament, sometimes a little higher. The lower portion of the sac, between the inferior margin of the tarsal ligament and the commencement of the bony canal, differs materially from the upper in being covered in by comparatively thin and weak structures, the anterior wall of this portion of the sac having the attenuated orbicular fascia alone interposed between the integuments. In consequence of this weakness this point is frequently the seat of dilatations, both normal and pathological; the conspicuous bulging often seen in connection with impeded escape of the tears corresponds to the lower part of the sac, which is unprotected by the dense fibromuscular covering which lies in front of its upper half. The wall of the sac, as well as that of the duct, is composed of fibro-elastic tissue, strengthened by fibrous processes derived from the tarsal ligament. Externally the wall of the sac is loosely connected with the periosteum by fibrous tissue, and therefore capable of distention; internally it is lined by mucous membrane directly continuous with that of the nasal duct. The epithelium covering the mucous membrane of the sac, as well as of the duct, is columnar in type and possesses areas in which cilia are present.

The *nasolachrymal duct*, which constitutes the last segment of the tear-passage, lies within the bony canal formed by the apposition of the superior maxillary, lachrymal, and inferior turbinated bones. The length of the nasal duct is very variable, at times being little over 11 or 12 mm., at others measuring twice as much, the difference being largely due to the manner in which the duct terminates in relation to the nasal mucous membrane, since as much as from 6-8 mm. of its length may be included in the oblique passage through the mucous membrane. The diameter of the nasal duct is from 3-4 mm.; it is not uniform, however, since slight constrictions at its beginning from the sac and about the middle of its course are very frequent. The position of the lower end of the nasal duct also varies, but it is usually about 30 mm. behind the posterior margin of the anterior nasal opening, and about 10 mm. from the front of the inferior turbinal. The direction of this canal, as indicated by the position of probes, varies considerably with regard to the degree of inclination of the course of the canal in relation to both the frontal and sagittal planes. In determining on the living subject the inclination of the canal with the sagittal plane, both Arlt and Merkel regard as trustworthy a comparison of the distance between the middle of the tarsal ligaments of the two sides with the distance between the points where the nasal ale join the cheek. When these measurements coincide the nasolachrymal canal descends vertically; when, as usually, a difference is noted, the deviation from the perpendicular will be equal to half the difference. The direction of

the duct with regard to the frontal plane is best determined, according to Merkel, by a line drawn from the inner canthus to the interval between the second premolar and first molar tooth of the upper jaw. The course of the nasolachrymal duct in general may, therefore, be described as deviating slightly backward from the vertical (Fig. 26).

The mucous membrane of the duct is connected by areolar tissue with the periosteum lining the bony canal, the mucosa, however, being separated from the periosteum by a venous plexus. The exact manner in which the duct opens into the inferior nasal meatus varies: it may terminate as a simple round or elliptical orifice or by an inconspicuous slit-like opening leading obliquely into the mucous membrane. The latter arrangement is sometimes described as forming the so-called *valve of Hasner*, but the presence of a distinct occluding fold must be questioned. The valves described in other parts of the nasal duct consist merely of imperfect, irregular, and inconstant folds of the mucosa, the most constant and best-marked of which lies at the

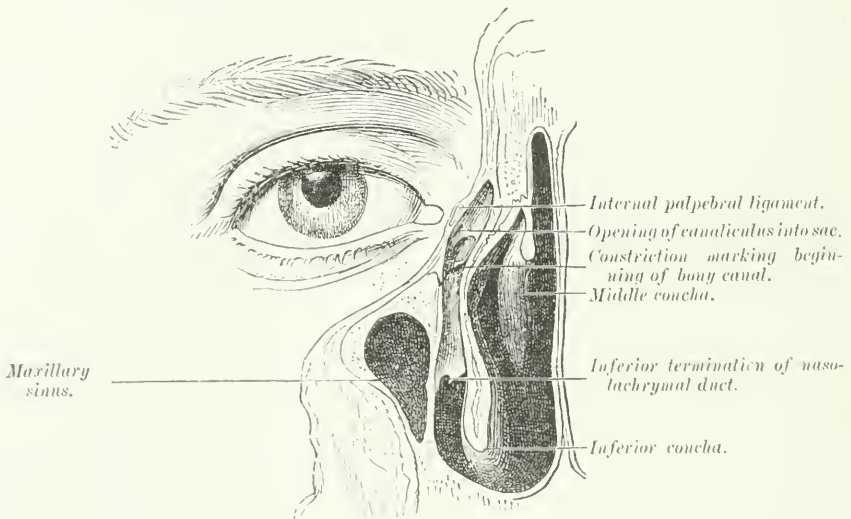


FIG. 26.—Section showing the course and relations of the lachrymal sac and nasolachrymal duct (Merkel).

junction of the lachrymal sac and the duct, which corresponds to the narrowest point of the entire lachrymal canal.

The blood-vessels supplying the lachrymal duct consist of the arterial branches from the nasal and inferior palpebral; the relatively large and numerous veins mostly join the nasal plexus and become indirect tributaries to the ophthalmic and facial.

The nerves distributed to the tear-passages are derived from the infra-trochlear branch of the nasal division of the ophthalmic.

#### MACROSCOPICAL AND MICROSCOPICAL ANATOMY OF THE EYEBALL.

The general form of the eyeball, as represented by the outlines of its outer fibrous coat, is spherical: when critically examined, however, the anterior segment of the globe presents deviation from the typical form, due to flattening within a zone lying in front of the equator, corresponding to the attachment of the recti muscles, and consequent apparent undue prominence of the corneal segment. In sagittal section the eyeball is seemingly made

up of the segments of two spheres—a larger posterior sclerotic segment, embracing approximately four-fifths of the globe, and a smaller anterior corneal segment, which contributes the remaining portion of the bulb. The junction of these segments is marked by an external broad annular groove, the *sulcus scleræ*, which surrounds the corneal periphery.

The eyeball presents further deviations from the globular form in the inequality of its three principal diameters, the anteroposterior diameter being the longest, the vertical the shortest, and the transverse intermediate. The exact determination of these measurements is by no means a matter of

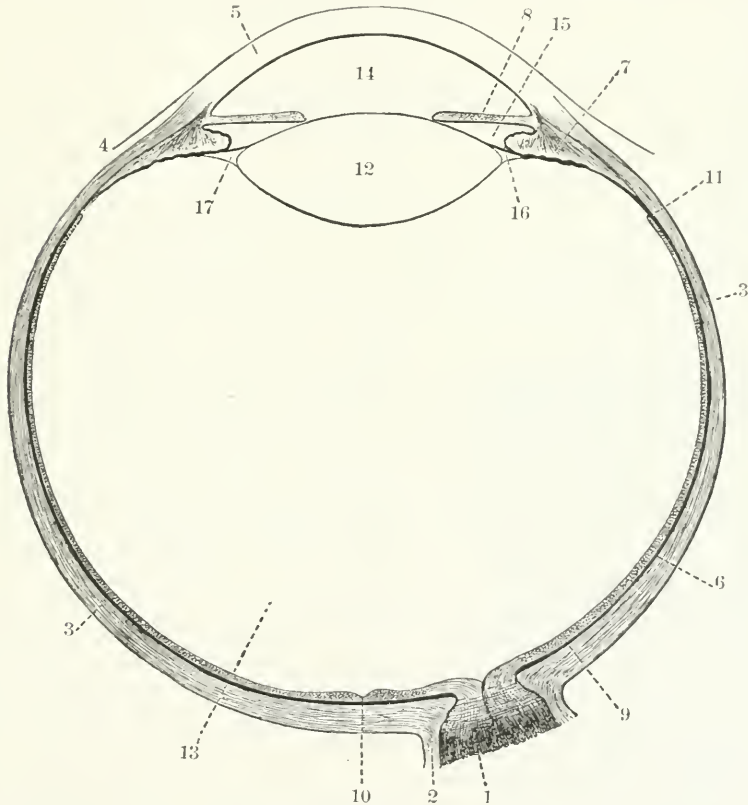


FIG. 27.—Diagram of horizontal section of human eye (Merkel-Rauber): 1, optic nerve; 2, dural sheath; 3, sclera; 4, conjunctiva; 5, cornea; 6, choroid; 7, ciliary body and processes; 8, iris; 9, retina; 10, fovea centralis; 11, ora serrata; 12, lens; 13, vitreous body; 14, anterior chamber; 15, posterior chamber; 16, zone of Zinn; 17, intrazomular cleft.

ease, as is evidenced by the discrepancies in the figures obtained by a number of competent investigators, since variations in the tension, and consequently in the dimensions, of the eyeball are quickly produced by the changes which begin very soon after death. Additional variations are also referable to the deviations in the antero-posterior diameter associated with refractive errors.

The principal diameters of the eyeball in millimeters, based upon the careful and elaborate series of measurements of Sappey, are as follows:

|                                     | Male. | Female. | Average. |
|-------------------------------------|-------|---------|----------|
| Antero-posterior diameter . . . . . | 24.6  | 23.9    | 24.2     |
| Vertical diameter . . . . .         | 23.5  | 23.0    | 23.2     |
| Transverse diameter . . . . .       | 23.9  | 23.4    | 23.6     |



Approximately, these diameters may be considered for practical purposes as antero-posterior, 24 mm.; vertical, 23; transverse, 23.5. The eyeball may therefore be regarded as a sphere slightly flattened from above downward and from side to side. When directed toward distant objects or in a condition of accommodative rest the axes of the eyes are very nearly parallel; the axes of the optic nerves, on the contrary, are divergent, their entrance lying between 2 and 3 mm. to the inner or nasal side of the point at which the axis of the eyeball meets the posterior wall (Fig. 27).

The eyeball consists of three coats or tunics:

1. The *external fibrous tunic*, of which the sclerotic forms the posterior four-fifths and the cornea the anterior fifth, upon which depend the protection of the more delicate parts within and, to a limited degree, the maintenance of the general form of the organ.

2. The *middle vascular tunic*, embracing the parts to which the chief blood-supply of the eyeball is distributed, including the choroid, the ciliary body, and the iris.

3. The *inner nervous tunic*, which contains the specialized neuro-epithelium for the reception of visual stimulus, the nerve-cells, and the nerve-processes, which, as the nerve-fibers, converge to form the optic nerve.

The *refractive media*, the crystalline lens, the aqueous humor, and the vitreous body, are enclosed within these coats, which the media, in turn, materially aid in supporting.

**The Fibrous Tunic.**—The **Cornea.**—The anterior fifth of the eyeball is occupied by the cornea, which structure, although principally composed of closely-felted bundles of dense fibrous tissue, presents a remarkable glass-like transparency, so important in admitting the rays of light to the interior of the ocular bulb. The refractive index of the cornea is about 1.37, or a little above that of water and the aqueous fluid. The transparency of the cornea is preserved only when the close normal apposition of its elements is maintained, any disturbance of the normal arrangement, as by compression, resulting in impaired transparency.

The form of the cornea, when examined from in front, is not quite circular, but elliptical, the greater transverse diameter measuring 11.6 mm., the smaller vertical only 11 mm. The apparent projection of the cornea beyond the sclera depends on a slight flattening of the latter near the equator, rather than on an actual projection of the corneal pole beyond the general sphere of the eyeball.

The curvature of the anterior corneal surface does not accurately correspond to a sphere, since the radius of curvature in the transverse direction (7.8 mm.) is slightly greater than the vertical radius (7.7 mm.); while slight asymmetry of the corneal curvature is probably always present, marked variations are also of frequency and then constitute *astigmatism*.

The form of the inner surface of the cornea, on the contrary, corresponds to a sphere, the radii of curvature being equal in all meridians, and measuring about 6 mm. The discrepancy in the curvatures of the outer and inner corneal surfaces shows that the thickness of the cornea necessarily varies: the cornea is slightly thicker at the periphery, where it measures from 0.9 to 1.1 mm., being from 0.8 to 0.9 mm. thick at the centre.

The corneae of persons advanced in age usually present the *arcus senilis*, which appears as a narrow gray or yellowish-white crescentic border extending beyond the periphery toward the pupil. Not infrequently a complete ring encircles the corneal limbus, formed by the fusion of the upper and lower crescents. The appearance is due to the infiltration of the corneal

stroma by particles which are usually assumed to be of a fatty nature, although this is questioned by Fuchs, who regards the change as due to a limited hyaline degeneration of the corneal fibers. (See also p. 326.)

The cornea differs from ordinary fibrous tissue in not yielding gelatin on boiling, but a modified form of chondrin.

The structure of the cornea, as seen in vertical section, includes five well-marked layers: these are, from without in—

1. The anterior epithelium;
2. The anterior limiting membrane;
3. The substantia propria;
4. The posterior limiting membrane;
5. The posterior endothelium.

The *anterior epithelium* of the cornea is a direct continuation of the ectodermic covering of the adjacent conjunctiva, and represents one of the few parts of the eye derived from the outer embryonic layer. The epithelium is stratified squamous in type, and thinnest over the central part of the cornea, the six to eight layers in this position together measuring about 0.045 mm.; at the periphery the epithelium is almost twice as thick. The deepest cells approach the columnar form, their bases, often somewhat extended, resting upon the anterior limiting membrane, while the outwardly-directed rounded ends are received between the cells of the more superficial strata. The elements composing the middle layers are polyhedral in form, and often present the appearance of prickle-cells. The cells of the superficial strata and free surface are greatly flattened and lie parallel to the free surface (Fig. 28).

The *anterior limiting membrane*, *membrane of Bowman*, or *lamina elastica anterior*, is conspicuous in the human cornea and represents a highly developed basement-membrane. This layer appears as a homogeneous glassy band, about 0.002 mm. in thickness, immediately beneath the epithelium; it is thickest at the center and thinnest at the corneal periphery. The membrane is resolvable into the fibrous fibrillæ upon the application of suitable reagents, thus demonstrating its true nature as a localized condensation of the fibrous corneal stroma, of which it is a specialization.

The *substance proper* constitutes the chief bulk of the cornea, and is composed of the fibrous stroma, which is built up of innumerable interlacing bundles of fibrous tissue. The interlacing fibrous bundles are disposed with some regularity as lamellæ, although the exact number and arrangement of these are variable. The fibrillæ of fibrous tissue, as well as the bundles, are held together by the interfibrillar cement substance, which likewise aids in joining the lamellæ. The fibrous bundles




FIG. 28.—Section of cornea (Piersol): a, anterior epithelium; c, anterior limiting membrane; b, b, fibrous stroma of substantia propria, containing corneal corpuscles (f) lying within the corneal spaces; d, posterior limiting membrane; e, endothelium lining anterior chamber.



cross one another at various angles, and are often united by bands which pass between the adjacent bundles; these *fibrae arcuatae* are especially conspicuous in the anterior lamellae. The peculiarity of the substantia propria in yielding after boiling a modified form of chondrin, instead of the usual gelatin, has already been mentioned.

The *cellular elements*, the *corneal corpuscles*, are flattened, plate-like connective-tissue cells which lie between the lamellae of the fibrous stroma within the intercommunicating lymph-spaces hollowed out within the cement substance. The corneal cells are irregularly branched, and form, by means of their united processes, a protoplasmic network throughout the corneal stroma. The corneal spaces in which the cells lie are larger than the cells, and are therefore only partially filled by the protoplasmic elements, the unoccupied space affording channels for the circulation of the nutrient tissue-juices upon which the investment of the non-vascular cornea depends. Communication between the corneal spaces is established by the canaliculi which pass from one space to the other. The corneal cells usually are applied to one wall of the spaces, and, in principle, resemble the endothelial plates which line other and larger lymphatic cavities. Occasional migratory leucocytes, or *wandering cells*, are also found within the system of corneal juice-channels.

The *posterior limiting membrane*, *membrane of Descemet*, *membrane of Demours*, or *posterior elastic membrane*, appears as a sharply-defined homogeneous band from 0.010 to 0.012 mm. in its thickest peripheral portion, at the inner boundary of the substantia propria. It differs from the anterior limiting membrane in its marked resistance to acids, alkalies, boiling water, and other reagents; it resembles, but is by no means identical with, elastic tissue. It is capable of complete separation from the substantia propria after prolonged maceration in a 10 per cent. solution of sodium chlorid. The layer in question contains no cells, and ordinarily presents no indication of being composed of secondary lamellae, although sometimes after reagents it shows traces of such structure.

The relations of the posterior limiting membrane at the corneal periphery are of interest, since in this position it breaks up into numerous bands which are continued into the trabeculae forming the pectinate ligament of the iris.

The *posterior endothelium* covers the inner surface of the membrane of Descemet and forms part of the lining of the anterior chamber of the eye. This innermost stratum of the cornea is composed of a single layer of polyhedral plates, the outlines of which constitute a mosaic of considerable regularity. The cells closely resemble ordinary endothelial plates, possessing oval, sometimes reniform, nuclei which are usually of greater thickness than the surrounding cell-body. The endothelium and the membrane of Descemet are of importance as constituting almost impassable barriers to the escape of the aqueous humor into the lymph-channels of the cornea.

The *blood-vessels* of the normal fully-developed cornea are limited to an extremely narrow peripheral zone, about 1 mm. in width, the remaining portions of the cornea being entirely devoid of blood-channels. The vascular zone contains the terminal loops of the episcleral branches derived from the anterior ciliary arteries. The venous radicles become tributaries of the anterior ciliary veins.

The *nerves* of the cornea constitute a rich supply arranged in the form of numerous plexuses. The corneal nerves are derived from the ciliary plexus, contributed by the long and short ciliary nerves, and form an annular plexus in the vicinity of the corneal margin. The twigs from the annular plexus pass either directly or indirectly to the corneal tissue, those destined for the

anterior layers first having joined the conjunctival nerves before proceeding to the cornea. The more numerous branches which pass directly to the corneal stroma from the annular plexus enter the substantia propria near the posterior limiting membrane, the far greater number, however, passing to the anterior lamella, only about one-third of the nerves which enter the cornea being distributed to the posterior layers. The nerve-bundles, on penetrating into the corneal stroma, are invested for a short distance, from 0.75–1 mm., by perineural lymph-sheaths, the individual nerve-fibers losing their medullary sheaths at about the same time.

After entering the substantia propria the nerves form the *fundamental plexus* within the corneal stroma, from which numerous lateral branches are given off at various levels; these are composed of non-medullated fibers which soon break up into the component varicose fibrillæ. In addition to the lateral twigs, *perforating branches* ascend through the anterior lamellæ as far as the epithelium, beneath which they form the *subepithelial plexus*. The terminal fibers of this plexus in many instances enter the epithelium to end either in special end-bulbs or between the cells as the *intra-epithelial plexus*. The plexuses within the substantia propria formed by the twigs given off at various levels spread out between the lamellæ of fibrous tissue; the nodal points or places of meeting of the fibers are often marked by angular areas outlined by the interlacing fibers; nuclei, belonging to the delicate nerve-sheaths, are sometimes present. The terminal fibers of the corneal nerves are related to various forms of end-organs, among which are intricate *convolutions*, less-contorted *loops* and *hooks*, and irregular quadrate *plates*.

**The Sclera.**—The sclerotic coat forms the posterior four-fifths of the fibrous tunic of the eyeball, contributing largely to the protection and support of the more delicate structures within, as well as affording the points of attachment of the ocular muscles. Although composed of practically the same histological elements as the cornea, the disposition of these is such that the dead-white opacity is produced which so conspicuously contrasts with the beautifully transparent cornea.

The sclera is thickest over the posterior third of the ball, where the maintenance of a uniform curvature for the support of the retina is of great importance: in the vicinity of the optic nerve the sclerotic coat measures nearly 1 mm. in thickness, gradually becoming thinner toward the anterior boundary, until beneath, or just posterior to, the zone of attachment of the recti muscles the sclera is reduced to about 0.4 mm. Anterior to the tendon-zone the thickness of the fibrous tunic is augmented by the expansion of the muscle insertions until it reaches about 0.6 mm. In individuals possessing thin sclerae and deeply pigmented eyes the sclerotic coat presents a bluish or skimmed-milk tint, due to the deeply-colored tissue beneath the fibrous coat; this bluish appearance is well marked in the eyes of young children.

In its structure the sclera closely resembles the cornea, being composed of interlacing bundles of fibrous tissue disposed with much greater irregularity, however, than those of the cornea. The clefts between the fibrous bundles correspond to the corneal spaces and contain irregularly stellate connective-tissue cells—the *scleral corpuscles*. The scleral spaces are less regularly arranged and possess a less elaborate system of connecting canaliculi. The scleral bundles further differ from those of the cornea in containing numerous elastic fibers and in yielding gelatin on boiling: their general disposition is equatorial and meridional, although the bundles interlace with one another at all angles.

In addition to the usual branched scleral corpuscles, those occupying the

innermost stratum are deeply pigmented, in consequence of which the inner surface of the sclerotic coat presents a dark color and is known as the *lamina fusca*: this layer constitutes the outer wall of the sub-scleral lymph-space, and is attached to the subjacent choroid by numerous trabeculae, which, together with the limiting walls of the space, are covered with endothelial plates. The greater extent of the outer surface of the sclera, from the sheath of the optic nerve to the insertion of the ocular muscles, is also clothed with endothelium, which forms part of the lining of the episcleral space of Tenon.

The *blood-vessels* of the sclera, in addition to the perforating vessels, which include anterior branches from the anterior ciliary vessels, the large equatorially situated *venae vorticosae*, and posterior branches from the posterior ciliary vessels, are represented by the meager twigs within the superficial strata of the fibrous tunic derived from the wide-meshed episcleral network formed by branches derived from the anterior and posterior ciliary arteries. The sclera receives additional branches from the short ciliary arteries in the vicinity of the optic entrance: these small vessels are of interest, since from the *circulus Zinnii*, which they form within the fibrous coat around the optic nerve, minute twigs extend into the dural nerve-sheath and anastomose with the arterioles supplying the sheath derived from the central artery of the retina, thus establishing a communication between the retinal and choroidal circulation.

The veins which drain the scleral coat are tributary to three sets of vessels: those from the anterior tract, emptying into the anterior ciliary veins; those from the equatorial zone, joining the *venae vorticosae*; and those from the posterior part, pouring their blood into the posterior ciliary veins.

The *lymphatics* of the sclera are represented by the system of intercommunicating scleral spaces, those in the vicinity of the sclero-corneal juncture being in close relation with the spaces of Fontana at the angle of the anterior chamber, which they indirectly aid in draining.

The *nerves* distributed to the sclerotic coat consist of a few twigs derived from the ciliary nerves as these pass between the sclera and choroid, which terminate between the fibrous bundles of the superficial layers as tortuous and intricately coursing ultimate fibrillae.

The relations of the scleral tissue to the sheaths surrounding the optic nerve will be considered with the description of the Optic Entrance.

**The Sclero-corneal Juncture.**—The position at which the sclera and corneal segments of the fibrous coat meet is one of the most important regions of the eye, since in the immediate vicinity of this junction lie important channels through which escapes the aqueous humor as well as the fibers giving origin to the ciliary muscle.

The conspicuous line of union between cornea and sclera depends far more upon the physical differences of the two portions of the fibrous coat than upon actual structural variation, since the elements are not only almost identical, but directly continuous. When seen in section the scleral tissue extends along both margins farther forward than does the corneal substance, the effect of this arrangement being to receive the cornea with an apparent annular groove bounded by the *outer* and *inner scleral processes*: of these the inner is shorter and does not reach as far toward the anterior pole as the outer.

The connections of the inner scleral process are of especial importance on account of the relations to the structures marking the meeting of the cornea, the iris, and the ciliary muscle. Just anterior and external to the



inner scleral process a distinct, usually somewhat irregularly elliptical, opening indicates the position of the annular venous sinus, the *canal of Schlemm* (Fig. 29). This channel, also called the *circulus venosus ciliaris*, as seen in meridional sections, elliptical or pyriform in its transverse figure, measures about 0.3 and 0.045 mm. in the longest and shortest diameters respectively. The walls of the canal of Schlemm differ greatly in character, the outer boundary being dense, while the inner is composed of a spongy reticulated layer, apparently the continuation of the inner scleral process. The inner wall is closely united with the posterior limiting membrane of the cornea anteriorly, and internally with the pectinate ligament of the iris and meridional fibers of the ciliary muscle.

The character of Schlemm's canal, whether a venous or lymphatic channel, was long a subject of active controversy: the recent investigations of Leber, however, have brought the formerly opposed views into harmony by showing that the conflicting evidence, based upon carefully conducted observations, was due to conditions of intraocular tension under which the experiments were carried out. It may be regarded as definitely established that the canal of Schlemm is an annular venous sinus which by means of the spaces of Fontana stands in close relation to the anterior chamber on the one hand, and directly communicates with the anterior ciliary veins on the other. Under usual conditions Schlemm's canal contains but little blood—a fact which is explained by Schwalbe upon the supposition that the sinus is an annular reserve diverticulum for the reception and storage of blood when for any reason there is a temporary retardation to the escape of the blood passing through the anterior ciliary veins; the narrowness of the communicating branches between Schlemm's canal and the scleral veins under ordinary conditions favoring the more direct passage of the contents of the scleral veins into the anterior ciliary vessels, rather than its entrance into the canal.

The tissue forming the wall of the anterior chamber at its angle, occupying the space between it and the canal of Schlemm, is peculiar in character, being composed of an aggregation of interlacing trabeculae composing a spongy mass containing interfascicular clefts, the *spaces of Fontana*. These spaces constitute a system of intercommunicating lymph-channels which are imperfectly lined with endothelial plates and freely communicate with the anterior chamber, the aqueous humor filling the spaces.

The spongy tissue containing the spaces of Fontana collectively constitutes an annular prismoidal mass, the apex of which begins at the corneal margin, where the membrane of Descemet splits up into delicate bands: these bands mark the origin of the trabeculae which pass toward the iris and constitute the *ligamentum pectinatum iridis*, a rudimentary structure in man representing the much more conspicuous series of conical processes extending from the iris toward the cornea in ruminants. The imperfect character of the endothelial lining of the spaces of Fontana allows the ready entrance of the lymph contained within the anterior chamber, so that the clefts between the trabeculae are filled with the escaped aqueous humor; the loose nature of the septum forming the inner wall of Schlemm's canal is also favorable to the passage of fluids, in consequence of which arrangement the aqueous humor is continually passing, under normal conditions of intraocular tension, through the spaces of Fontana into the canal of Schlemm, and thence into the communicating venous radicles. This exit for the intraocular lymph is of the utmost importance in maintaining an equilibrium of tension within the eyeball.

**The Vascular Tunic.**—The *middle or choroidal coat* of the eyeball, distinguished by its dark color, and therefore often called the *uveal tract*, is essen-

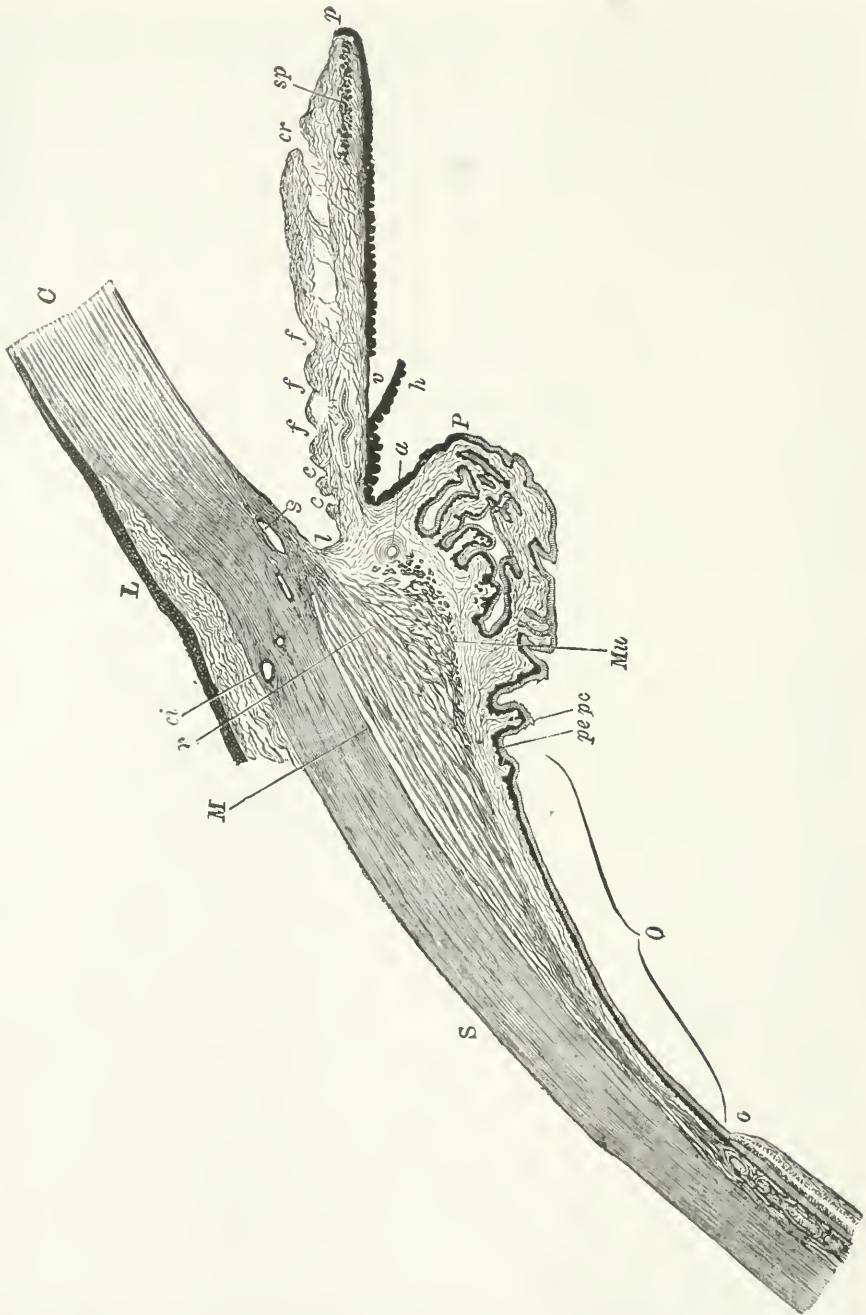


FIG. 29.—Section through ciliary region, including part of cornea and sclera, the iris, ciliary process, and muscle (Fuchs). C, cornea; S, sclera; M, ciliary muscle; r, radiating fibers; Mu, circular fibers of Müller; p, p, pigmented and non-pigmented cells of pars ciliaris retinae; ca, anterior ciliary artery; s, canal of Schlemm; z, origin of ciliary muscle; cr, cr, folds of anterior surface of iris; cr, artificial break in iris; sp, spleneter papillae; p, papillary border of iris; b, pigment partly detached from iris; P, ciliary process; O, ciliary ring; a, ora serrata.

tially a sheet of vascular connective tissue. It includes three distinct portions—the choroid, the ciliary region, and the iris—and extends from the optic nerve



to the pupil. The character of its component structures renders the nutritive coat soft, friable, and extensible, and, owing to the presence of muscular tissue within its ciliary and iridial segments, it is subjected to constant variations in its tension. The blood-vessels of this tunic constitute the chief nutritive apparatus of the eye, since the functionally most active portions of the organ, as the percipient layers of the retina and the ciliary muscle, receive their nutrition from this source.

The choroid constitutes the posterior two-thirds of the vascular tunic, extending from the optic-nerve entrance to the anterior limit of the visual portion of the retina, or ora serrata, lying closely united to the functioning segment of the nervous tunic, to the nutrition of which it ministers. The thickness of the choroid gradually diminishes toward the ora serrata, being about 0.1 mm. near the nerve and 0.06 mm. at the ora serrata. While applied to the inner surface of the sclera the union between the two coats is not firm, since the opposed surfaces, covered with endothelium, are separated by the intervening *suprachoroidal lymph-space*; irregular trabeculae extend across this space, and, in addition to attaching the sclera and choroid imperfectly, subdivide the cleft into numerous secondary compartments. When separated from the fibrous coat the outer surface of the choroid appears rough

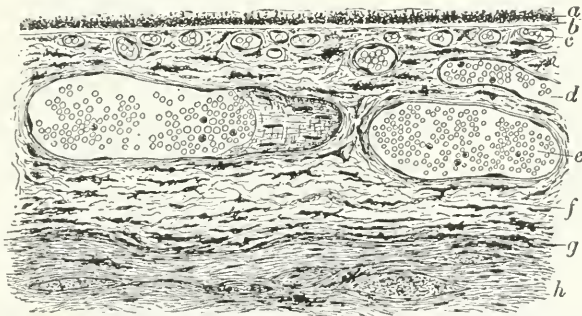


FIG. 30.—Section of human choroid (Piersol): *a*, retinal pigment adhering to vitreous membrane (*b*); *c*, capillary layer, or chorio-capillaris; *d*, *e*, large blood-vessels of stroma layer; *f*, lamina suprachoroidea; *g*, tissue of sclera.

and ragged, owing to the adherent torn trabeculae. The suprachoroidal space is also occupied by the large vascular and nervous trunks which traverse the cleft in their course to other parts of the eyeball; those which pierce the sclera, as the *venae vorticosae*, aid in further uniting the vascular and fibrous tunics. The inner surface of the choroid, on the contrary, is very intimately united with the adjacent pigmented layer of the retina, so that the latter often adheres to the choroid when the middle coat is removed.

The choroid consists of a more or less compact connective-tissue stroma, which supports numerous blood-channels of very varying size; the arrangement of these vessels largely determines the peculiarities of the layers into which the choroid is divided (Fig. 30). These are three:

1. The layer of choroidal stroma containing blood-vessels of large size;
2. The layer of dense capillary networks—the chorio-capillaris;
3. The homogeneous glassy lamina or membrana vitrea.

The loose layer of trabecular bands connecting the outer surface of the choroid and the inner surface of the sclera constitutes the *lamina suprachoroidea*, sometimes described as an additional layer of the choroid. The membrane-like trabeculae consist of interlacing fibro-elastic bundles, upon

the surface of which lie the flattened, irregularly-branched pigmented connective-tissue cells, the deeply-pigmented protoplasm rendering them conspicuous elements.

The *choroidal stroma* consists of a ground-substance of closely interwoven connective-tissue lamellæ, which support the blood-vessels. The structural elements include the usual bundles of white fibrous tissue, numerous elastic fibers, and stellate pigmented cells; the stroma is especially dense in the immediate vicinity of the blood-channels.

The layer containing the large blood-vessels constitutes the larger part of the choroid, the vascular canals appearing as apertures and lighter channels within the darker choroidal stroma. The largest vessels occupy the most superficial or outer stratum of the choroidal stroma, those of medium size the

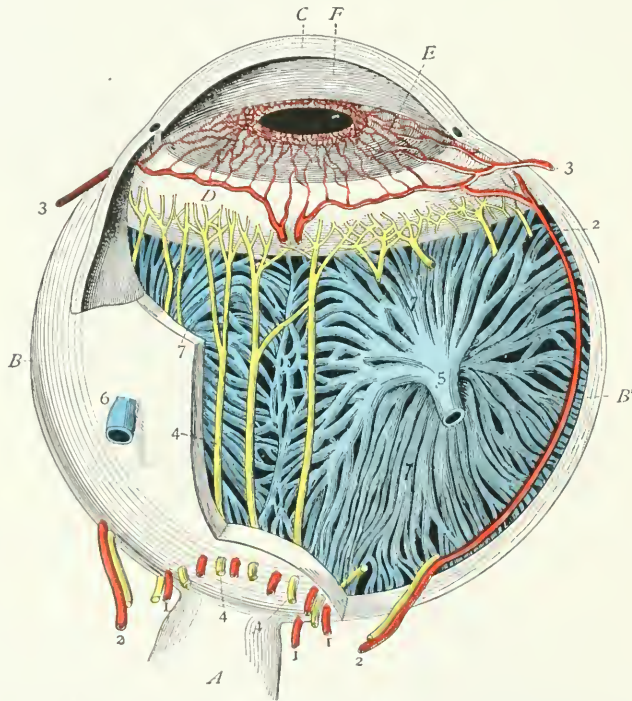


FIG. 31.—Diagrammatic view of principal blood-vessels and nerves of the eyeball (Testut): *A*, optic nerve; *B*, sclera; *B'*, viewed in section; *C*, section of cornea; *D*, ciliary muscle; *E*, iris; *F*, anterior chamber; 1, short posterior ciliary arteries; 2, long posterior ciliary arteries; 3, anterior ciliary arteries; 4, ciliary nerves; 5, one of the large vena vorticiosa; 6, vena vorticiosa after piercing the sclera; 7, vasa vorticiosa of the choroidal tunic.

middle layer, while the innermost layer is devoted to the capillary network, the *chorio-capillaris*.

The most conspicuous of the large superficial blood-channels are the four venous trunks, the *vena vorticiosa*; these pierce the choroid within the equatorial zone at points about equidistant and establish foci toward which the smaller veins within each quadrant converge; these tributaries form peculiar venous whorls within the superficial layers of the choroidal stroma (Fig. 31). The vena vorticiosa traverse the suprachoroidal space, invested by a partial envelope contributed by the lamina suprachoridea, and pierce the sclera, running obliquely backward. Perivascular lymph-sheaths usually invest the venous trunks within the choroid. The arteries within the choroidal stroma

possess longitudinally disposed muscle-bundles in addition to the customary circular fibers.

A narrow *boundary-zone* separates the layer containing the large veins from the capillary stratum: it consists of closely felted fibro-elastic fibers intermingled with sparingly distributed connective-tissue cells devoid of pigment. In many animals, as the horse, cow, or sheep, the boundary-zone contains many bundles of dense connective tissue, which arrangement produces the peculiar metallic reflex sometimes seen in such eyes; this shining layer constitutes the *tapetum fibrosum*, as distinguished from the *tapetum cellulosum* of the carnivora, which structure depends upon the presence of several layers of cells containing minute crystals.

The inner capillary zone of the choroid, the *chorio-capillaris* or *membrane of Ruysch*, occupies the inner portion of the vascular tunic lying next the vitreous membrane, which alone separates the rich vascular layer from the nervous coat, to the nutrition of which it so largely ministers. The capillaries are unusually uniform in size, measuring about 0.009 mm. in diameter; the meshes of the network are very small, even surpassing in closeness those of the lungs, being only 0.01 to 0.02 mm. in the macular region, and about 0.02 to 0.03 mm. toward the ora serrata. The red reflex seen in the eye when viewed with the ophthalmoscope is due to the reddish color of this vascular layer showing through the retina.

The *vitreous membrane*, *lamina basilaris*, *membrane of Bruch*, or *lamina vitrea*, constitutes the inner boundary of the choroid, lying next the nervous tunic, which it separates from the chorio-capillaris. The membrane represents a specialized condensation of the choroidal stroma, and appears as a homogeneous zone which measures only 0.002 mm. in thickness.

The *nerves* of the choroid are derived from branches given off from the long and short ciliary nerves during their course between the vascular and fibrous tunics. The choroidal nerves, which are both medullated and non-medullated, form a wide-meshed plexus within the lamina suprachoroidea containing groups of ganglion-cells. From this plexus numerous slender, non-medullated fibers proceed to the arteries, the muscular tissue of which they especially supply; isolated or very limited groups of ganglion-cells are found along the blood-vessels.

The *lymphatics* of the choroid are probably represented by distinct capillary vessels which communicate with the lymph-spaces between the channels of the chorio-capillaris on the one hand, and the perivascular sheaths tributary to the larger lymph-canals on the other.

The *ciliary body* includes the middle segment of the vascular tunic, extending from the ora serrata behind to the sclero-corneal juncture in front. As seen in meridional sections, this region appears as a triangle, the longer and outer side of which lies next the sclera and sclero-corneal juncture, the short anterior side against the pectinate ligament, and the inner margin in apposition with the irregular, deeply pigmented extension of the retinal tunic.

The ciliary body presents three subdivisions—the ciliary ring, the ciliary processes, and the ciliary muscle.

The *ciliary ring*, or *orbiculus ciliaris*, includes the smooth annular tract lying between the sinuous border of the ora serrata behind and the ciliary processes in front, constituting a band about 4 mm. in width. This zone differs in its structure from the choroid proper, chiefly in the absence of the rich vascular supply, since the capillary layer ceases at the ora serrata, or at the point where the percipient elements of the nervous tunic end for whose



nutrition the chorio-capillaris is especially designed. The larger blood-vessels of the choroid are here represented by the venous trunks which return the blood from the iris and ciliary processes and proceed as tributaries to the venæ vorticosæ. When viewed from the posterior surface the ciliary ring presents numerous delicate radial striations: these are due partly to the blood-vessels and partly to minute plications of the surface, best marked toward the anterior boundary of the ring.

The *ciliary processes* appear on the posterior surface of the ciliary region as an annular series of pyramidal folds, about seventy in number, the conspicuous projecting bases of which encircle the attached border of the iris, while their apices gradually fade away in the orbiculus ciliaris. The delicate radial striations seen on the surface of the latter are so related to the ciliary processes that each projection seemingly begins by the fusion of several striations, and rapidly increases in breadth and height to a point opposite the margin of the crystalline lens, and then abruptly diminishes to the level of the iris. The elevations measure between 2 and 3 mm. in length, 0.12 to 0.15 mm. in breadth, and in their boldest part from 0.8 to 1 mm. in height. The processes consist chiefly of convoluted blood-vessels supported by delicate connective-tissue stroma, and covered by the pigmented extension of the retinal tunic, the *pars ciliaris retinæ*. It is probable that the particular function of the ciliary processes, in addition to affording attachment for the fibers of the suspensory ligament of the lens, is the secretion of the aqueous humor, to which end their peculiar formation and unusual vascularity are especially adapted.

When seen in meridional sections each process is observed to be composed of a number of irregular projections, varying greatly in size and arrangement (Fig. 29); in general, the maximum elevation marks the inner angle next the iris, from which point they gradually diminish toward the orbicular ring, where they fade away. In addition to the connective-tissue stroma containing the rich convolution of blood-vessels, the inner surface of the ciliary processes, as well as that of the orbiculus ciliaris, is covered by a continuation of the vitreous membrane of the choroid, which in this region is somewhat thickened, measuring from 0.003 to 0.004 mm.; this limiting membrane separates the stroma of the ciliary process from the retinal layer represented by the double stratum of epithelial cells which covers the inner surface of the projections.

The *ciliary muscle* is very conspicuous in meridional sections of the eyeball, then appearing as a triangular fold of involuntary muscle and connective tissue which lies between the sclera and the proper tissue of the ciliary processes. In its entirety the ciliary muscle forms a prismoidal annular band which surrounds the angle of the anterior chamber and attached margin of the iris.

The muscular area consists of three sets of bundles of involuntary muscle, intermingled with connective tissue, arranged as *meridional*, *radial*, and *circular* fibers. The meridional bundles are closely grouped and constitute a compact muscular layer next the sclera, to which they are loosely connected by fibers of the lamina suprachoroidea. These muscular bundles take origin from the inner scleral process and tissue, forming the inner wall of Schlemm's canal; posteriorly, the meridional bundles are attached to the choroidal tract, into which they are inserted by delicate tapering processes; from their relation to the vascular tunic the meridional muscular bundles are often called the *tensor choroidea*. The typical meridional fibers lie next the sclera; those more internally situated gradually assume a more radial

disposition, and insensibly blend with those whose course is such that they constitute the radial group (see Fig. 29).

The radial fibers of the ciliary muscle are less closely placed than the meridional, and form a reticulum in which the muscular bundles are separated by a considerable amount of intervening connective tissue. The fan-shaped mass of radial fibers diverges from their point of origin from the membrane of Descemet and inner wall of Schlemm's canal, the innermost fibers passing toward the ciliary processes and the outer to the anterior border of the orbiculus ciliaris.

In addition to the meridional and radial bundles an isolated group of circularly disposed muscular fibers occupies the inner angle of the triangular field formed by the ciliary muscle at the base of the iris; these fibers constitute the *circular or ring muscle of Müller*.

The general form of the ciliary muscle in the emmetropic eye approximates a right-angled triangle, the hypotenuse corresponding to the long scleral margin: in the markedly abnormal refractive conditions of myopia and hypermetropia the circular fibers are respectively atrophic or over-developed, which results in the obtusely-angled myopic muscle and the unusually acute-angled muscle of the hypermetropic eye.

The *blood-vessels* of the ciliary body are derived from the anterior and long ciliary arteries, which form around the root of the iris the anastomotic ring, the *circulus iridis major*. In their course through the ciliary muscle to gain the periphery of the iris these vessels give off twigs which pass directly to the muscle-substance; the arteries supplying the ciliary processes pass backward from the *circulus iridis major*, piercing the inner part of the muscle to reach the anterior extremities of the elevations.

The *veins* returning the blood from the ciliary muscle pass principally into the anterior ciliary trunks: additional venous radicles, however, convey a part of the blood in the opposite direction to join that returned from the ciliary processes by the posteriorly coursing vessels, which finally become tributary to the great equatorial veins.

The *nerves* of the ciliary body include sensory, motor, and sympathetic fibers derived from the anterior branches of the long and short ciliary trunks; these nerves form an annular plexus, the *orbiculus gangliosus*, within the ciliary muscle. Four sets of fibers probably exist within the ciliary body: 1, sensory fibers, largely sub-scleral in distribution; 2, vaso-motor fibers distributed to the walls of the blood-vessels; 3, motor fibers ending within the muscular tissue of the ciliary body; 4, fibers terminating within the inter-fascicular tissue of the ciliary muscle.

The iris constitutes the anterior segment of the vascular tunic, and is visible, on looking through the clear cornea, as the delicate, contractile, variously tinted septum which contains the central aperture or *pupil*. The plane of the iris is not quite vertical, as its pupillary margin rests upon the anterior surface of the lens, which causes slight convexity of its plane. The thickness of the curtain is about 0.04 mm. in the quiescent condition, in a widely dilated state being nearly doubled. The diameter of the iris is about 11 mm., of which the pupil appropriates from 3-6 mm. when at rest (see also p. 147).

The attached or ciliary border of the iris joins the ciliary body behind, and is continuous with the membrane of Descemet through the pectinate ligament in front; its zone of attachment lies about 3 mm. behind the apparent corneal margin as viewed from before. The exact outline of the thin pupillary border is difficult to see, owing to its intense black color due to



the deeply pigmented tissue which forms the immediate boundary of the opening: critically examined, it presents a slightly irregular or dentated contour.

The *color of the iris*, as viewed from the anterior surface, varies greatly, and depends for its production upon two factors—the deeply pigmented cells covering the posterior surface of the iris as well as lining the pupillary opening, and the amount of pigment contained within the iridial stroma. When the pigmented stroma-cells are very few or absent the dark color of the posterior layer shines through the thin stroma, and the iris appears blue; when the stroma is thicker the tint becomes modified to gray. With the presence of additional pigment within the stroma varying deeper shades, as green, hazel, brown, are produced; finally, when the stroma is laden with pigmented cells, the darkest tints of brown appear—the so-called “black eyes” (see also page 147).

The color is not uniform, but is distributed in irregular spots and patches, sometimes of fanciful form, of lighter and darker tints, so that a definite tint is produced only on viewing the iris at a distance sufficient to blend the variously tinged areas. Close examination shows a further disposition of the color in two zones concentric with the pupil—the *pupillary*, from 1–2 mm. wide, which is lighter in dark eyes and darker in light eyes, and an outer or *ciliary*, from 3–4 mm. in width, which is darker in dark eyes and lighter in light eyes. The boundary-zone between the two is often marked by a series of festoon-like ridges, the *circulus minor iridis*.

The *anterior surface* of the iris, when viewed from before, exhibits a distinct sculpturing consisting in numerous radial striate ridges; these are particularly fine and closely approximated within the pupillary zone, where they unite toward the inner margin, leaving deep intervening clefts. The broader ciliary portion is subdivided into three secondary zones concentric with the pupil—an inner *smooth* ring, not plicated during dilatation of the pupil; a middle *furrowed* band; and an outer irregularly pitted *marginal* or *cribriform* zone. The first two are visible in the living eye, the third is covered by the scleral border.

The *posterior surface* of the iris presents numerous radially arranged ridges separated by intervening furrows, which are intersected by concentric lines; within the pupillary zone the concentric markings almost disappear, while the radial are more numerous than elsewhere, resulting in the apparent plication of the inner zone of the iris.

The form of the human pupil is normally circular under all conditions of contraction; in marked contrast are the elliptical or slit-like pupils of many mammals, in some of which, as the horse and ox, the long axis of the contracted pupil is horizontal; in others, as the cat and tiger, vertical.

The structure of the iris, as seen in radial sections, presents two chief layers—the iridial stroma proper and the pigment layer; these include five sub-layers (Fig. 32):

1. Anterior endothelium;
2. Anterior boundary layer;
3. Vascular stroma layer;
4. Posterior limiting layer;
5. Pigment layer.

Reference to the development of the iris shows that the pigment layer is the contribution of the nervous tunic, and morphologically represents the anterior edge of the secondary optic vesicle, derived from the ectoderm, while the remaining parts of the iris are mesodermic in origin.

The *anterior endothelium* forms part of the lining of the anterior cham-

ber, and consists of a single layer of irregular polygonal plates, directly continuous with those covering the posterior surface of the cornea.

The *anterior limiting membrane* does not exist as a distinct layer, being simply the modified and condensed subendothelial stratum of the general stroma into which it blends. The connective-tissue cells are here unusually closely placed, with a corresponding meagerness of the intercellular fibrous tissue; minute interfascicular clefts represent a system of intercommunicating lymph-spaces. Blood-vessels are wanting within this part of the iris.

The *vascular stroma* layer, forming the bulk of the iris, consists of a loose connective tissue supporting the numerous blood-vessels and nerves which occupy this stratum, and enclosing interfascicular lymph-spaces, as well as

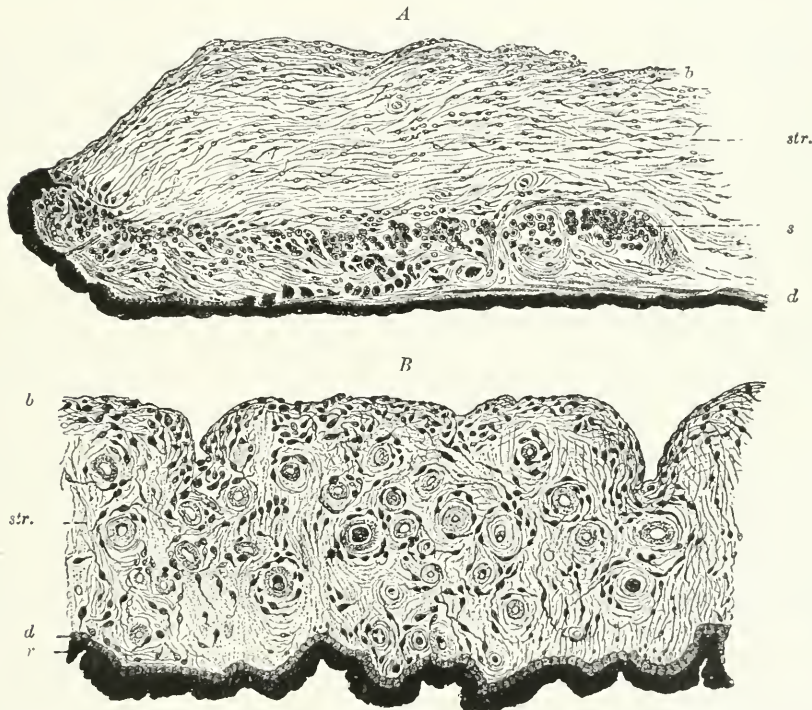


FIG. 32.—Sections of the human iris: *A*, radial section; *B*, section across the radii (Retzius); *b*, anterior condensed zone and endothelium; *str.*, stroma-layer; *s*, bundles of muscular fibers composing the sphincter pupillae; *d*, muscle-cells constituting the dilatator pupillae; *r*, pigment layer of iris belonging to retinal tract.

the groups of involuntary muscle-bundles which constitute the sphincter and dilatator pupillae muscles. The radially disposed blood-vessels and nerve-trunks are invested by local condensations of the iridial stroma, the perivascular sheaths so formed representing the most robust portions of the stroma layer, the intervening areas being occupied by a comparatively loose connective-tissue reticulum.

The variable and often large amount of pigment contained within the stroma layer in dark irides occurs as irregular accumulations of pigment-cells, the anterior layer and the pupillary zone usually containing the greatest number of the colored elements. In very dark irides the distribution of the pigment is very general, all portions of the stroma layer being filled with the colored particles.

The muscular tissue within the iris occurs within the vascular stroma layer, and includes the well-marked circular fibers surrounding the inner margin of the iris and constituting the *sphincter pupillæ*, and the much less evident and often disputed radially disposed fibers which form the *dilatator pupillæ*.

The *sphincter pupillæ* consists of an annular band of involuntary muscle, varying in width between 0.7 and 1.0 mm., according to the condition of contraction, and from 0.07 to 0.10 mm. in thickness. The immediate edge of the pupil is not formed by the muscular tissue, since the pigmented retinal sheet intervenes. The muscle occupies the posterior plane of the stroma layer, behind the blood-vessels; the bundles composing its outer border are loosely disposed, certain fibers often assuming an arched course and fading away in radial offshoots.

While the presence of a sphincter muscle is universally admitted, the existence of a radially disposed *dilatator pupillæ* is by no means undisputed. The demonstration of a distinct layer of radiating fibers is very unsatisfactory, so much so that many competent observers have concluded that such fibers do not exist, and that a true dilatator is absent, although the presence of radially disposed delicate spindle-cells is indisputable. Without entering upon a *résumé* of the various views relating to the nature of these spindle-cells lying in close relation with the posterior limiting lamella, it may be stated that the most recent and trustworthy investigations, both from the morphological and the physiological standpoint, as those by Retzius and by Langley and Anderson, tend to uphold the existence of dilatator fibers—if not as a continuous sheet, at least as groups of radiating fibers which collectively constitute the dilatator pupillæ, the presence of which as a distinct dilatator muscle may be regarded as definitely established.

The *posterior limiting lamella* has likewise been the subject of much discussion, due largely to the uncertain relations of the layer of delicate spindle-cells occupying the iridial stroma in the immediate vicinity of the posterior pigment. The limiting lamella, or basal membrane, appears as a clear layer of great delicacy, its maximum thickness not exceeding 0.002 mm., which closely adheres to the deeply pigmented retinal zone, with which it is often inseparably united. The lamella in question may be regarded as the attenuated anterior continuation of the membrane of Bruch, which extends forward from the choroid over the orbiculus ciliaris and ciliary processes.

The *pigment layer* covering the posterior surface of the iris as far as the anterior margin of the pupil, although a conspicuous anatomical portion of the iris, morphologically represents the anterior segment of the atrophic portion of the nervous tunic—the *pars retinæ iridicæ*. The deeply colored layer, although ordinarily appearing as a uniform stratum of pigment-particles, in reality consists, as seen in suitable preparations, of two distinct layers—an outer, made up of low irregular fusiform elements, and an inner, composed of short polygonal cells; these layers are continuous as the anterior margin of the pupil and represent the double-layered anterior lip of the optic cup. On approaching the ciliary processes the amount of pigment gradually lessens, first in the inner layer, and subsequently likewise in the cells of the outer layer; finally, at the base of the ciliary elevations the outer layer alone contains pigment-particles. The inner cells are covered on their free surfaces by an extremely delicate cuticular membrane, the *limitans iridis*, which is probably the continuation of the cuticle investing the ciliary portion of the retinal sheet.

The *blood-vessels* of the iris include the arterial stems given off from the



anterior border of the *circulus arteriosus iridis major*, situated around the periphery of the iris, from which the radially disposed arterioles proceed through the stroma layer as far as the sphincter zone. At this point they freely join to form a second anastomotic circuit, the *circulus arteriosus iridis minor*, which surrounds the pupillary opening and gives off three sets of twigs—an internal, for the supply of the sphincter muscle, and anterior and posterior groups to the corresponding layers of the iris stroma.

The capillary networks derived from these sources join to form *venous radicles* which take a generally radial course, the veins uniting at acute angles to form the larger venous trunks which accompany those from the ciliary processes along the inner border of the ciliary muscle and terminate by joining the large *venae vorticosae*. The vessels of the iris are provided with perivascular lymph-sheaths within the thickened adventitious coat.

The *lymphatics* of the iris are represented by the interfascicular tissue-spaces which constitute an intercommunicating system of clefts within the stroma, and at the periphery communicate with the spaces within the ciliary body and with the spaces of Fontana.

The *nerves* of the iris are derived from the *orbiculus gangliosis*, which, as already noted, is formed within the accommodative muscle by the branches of the ciliary nerves. The trunks destined for the iris pursue a spiral course toward the periphery, and upon entering the stroma break up into branches which soon become reunited, after undergoing new combinations, to form plexuses within the stroma-layer.

The nerves of the iris possess three varieties of terminal fibers: 1, motor endings within the muscular tissue; 2, sensory endings within the superficial layers of the stroma; 3, vaso-motor endings within the walls of the arteries and capillaries.

The presence of ganglion nerve-cells within the iris is doubtful. At best, they occur as small, sparingly distributed elements, usually of irregular multipolar form, the nervous nature of which is not beyond dispute.

**The Nervous Tunic.**—**The Retina.**—Viewed in the light of the more modern conceptions, the nervous coat can no longer be regarded as of the same limited morphological value as the other tunics of the eyeball, but must be considered as a true nervous center, consisting of a peripherally situated portion of the nervous system, and not merely as a complex apparatus for the perception of light-stimulus.

The entire nervous tunic, as representing the structures derived from the optic vesicle, extends from the optic-nerve entrance to the anterior pupillary margin. The modifications which take place within this extensive tract suffice to differentiate two sharply-defined segments—the *posterior*, embracing the hindermost part of the tunic from the optic entrance to the *ora serrata*, and constituting the functioning *pars optica retinae*; and the *anterior*, which includes the atrophic segment covering the posterior surface of the ciliary body and the iris, and hence appropriately designated as the *pars ciliaris* and *pars iridica retinae*, respectively.

The visual portion of the nervous tunic, or *retina proper*, is closely applied to the choroid, and extends from the optic entrance over the posterior two-thirds of the eyeball, ending abruptly at the ciliary region in a sinuous border, the *ora serrata*, where it passes over into the greatly attenuated anterior non-visual segment of the coat.

The retina during life and in health is perfectly smooth and transparent, its blood-vessels alone being distinguishable: owing to this transparency of its inner division the dark color of the deeply pigmented outer retinal layer



becomes an important factor in absorbing reflected light-rays and thus preventing interference. During life the retina possesses a purplish-red tint, due to the presence of the so-called *visual purple* within certain of its elements. After death the retina soon becomes cloudy, later appearing as a thin gray veil. In thickness the retina decreases from about 0.4 mm. at the posterior pole to little over 0.2 mm. in the vicinity of the ora serrata.

On examining the eye-ground (see also page 184) a conspicuous circular whitish area marks the position of the optic-nerve entrance, lying a little to the nasal or inner side of the posterior pole of the eyeball. The *optic disk*, *optic papilla*, *optic entrance*, or *porus opticus*, is not quite circular, but is elliptical in form, its longest diameter being vertical and measuring about 1.7 mm. as against 1.5 mm. in the horizontal direction. The surface of the optic disk often presents a distinct funnel-like depression, the *physiological excavation*, which results from the mode of development; the excavation is usually eccentrically placed, being somewhat toward the nasal side, where the depression is steepest and occupied by the retinal vessels. Remains of the fetal hyaloid artery may be seen as a filament of connective tissue extending into the vitreous body from the optic disk. The white appearance of the area is due to the scleral connective tissue of the lamina cribrosa and the medullated nerve-fibers shining through the semi-transparent layer of axis-cylinders which occupy the disk.

Critically examined through the ophthalmoscope, the margin of the optic nerve appears as a faint reddish outline; next the nerve the optic disk presents a narrow white annular edge, the *scleral ring*, which is the edge of the aperture in the fibrous tunic; outside of the scleral border a second circle, often quite dark, and not infrequently broken, appears as an irregular pigmented zone, the *choroidal ring*, the presence of which is due to the deeply colored choroid. The optic entrance corresponds with the "blind spot," the explanation of which is found in the absence of the perceptive elements within this area.

The *macula lutea*, or *yellow spot*, is an area of slightly oval form distinguished by its peculiar reddish-brown tint, which is due to the presence of diffused pigment-particles. The macula corresponds closely with the axis of the eyeball, and lies about 4 mm. to the temporal side of the centre of the optic entrance and about 0.75 mm. below the horizontal meridian. The limits of the yellow spot are not sharply defined, since it blends into the surrounding retina, but its form, when accurately studied, is usually almost circular or but slightly elliptical, since the oval form frequently described depends, probably, more upon ophthalmoscopic appearances than upon anatomical arrangement. The greatest diameter of the yellow spot measures a little over 2 mm., and often does not quite correspond with the horizontal meridian.

About the center of the macular area a dark-brown, apparently deeply pigmented spot marks the position of the *fovea centralis*, a depression in which the retina becomes greatly thinned, and thus allows the deeply-tinted subjacent pigment to become exceptionally conspicuous. The fovea corresponds to the point of highest acuity of vision, and anatomically is distinguished by profound modifications in the arrangement of the histological elements of the retina.

The size of the fovea as usually given, between 0.2 and 0.4 mm., is too small, the recent investigations of Dimmer, Golding-Bird, and Schäfer indicating a diameter exceeding 1 mm., and, exceptionally, approximating nearly 2 mm. Owing to the absence of the rods within the fovea, and there-

fore, likewise, of the visual purple, this region possesses an inherently lighter tint than the surrounding retina, sometimes appearing as a faintly tinted spot when examined with the ophthalmoscope. The *foveal reflex* seen with the mirror is due to the direction and slope of the sides of the depression, the variations in these resulting in the differences observed in the ophthalmoscopic image (compare with page 188).

The retina morphologically consists of two distinct layers—an outer and inner lamella, which correspond to the external and the internal layers of the optic vesicle; the outer lamella is represented by the pigment layer, while the inner lamella includes the remaining retinal strata. The inner lamella may be further subdivided into the *neuro-epithelial* and the *cerebral* layers.

Sections of the nervous tunic, when perpendicular to the surface of the membrane, show numerous strata, the outermost of which is distinguished by its dark color, and constitutes the retinal pigment; the succeeding layers differ widely in the amount of protoplasmic elements which they contain, and hence vary in the intensity with which they stain, so that the retina presents lighter and darker strata when seen in usual carmine or hæmatoxylin preparations. The designation of the retinal layers (Fig. 33), as well as their morphological relations from without inward, is as follows:

*Retinal Layers.*

|                                   |   |                                                                                                                                                                                                                           |   |                         |
|-----------------------------------|---|---------------------------------------------------------------------------------------------------------------------------------------------------------------------------------------------------------------------------|---|-------------------------|
| I. Outer layer of optic vesicle,  | { | Pigment layer,                                                                                                                                                                                                            | } | Pigment layer.          |
|                                   | { | Layer of rods and cones,<br>Layer of bodies of visual cells<br>or outer nuclear layer,                                                                                                                                    | } | Neuro-epithelial layer. |
| II. Inner layer of optic vesicle, | { | External plexiform layer or<br>outer reticular layer,<br>Layer of bipolar cells or inner<br>nuclear layer,<br>Internal plexiform layer or<br>inner reticular layer,<br>Layer of ganglion-cells,<br>Layer of nerve-fibers, | } | Cerebral layer.         |

The retina may be regarded as an isolated portion of the central nervous system immediately connected with a highly specialized perceptive sense-apparatus: as other parts of the nervous axis, so the retina is composed of two varieties of elements, the nervous and the sustentacular, the latter being represented by the modified neuroglial reticulum and columns, the fibers of Müller. The nervous elements constitute collectively the *ganglion retinae*, and represent the cortical cells of the brain. In principle, therefore, the retina consists of the percipient elements, closely applied to the pigment layer, the ganglion retinae and the ganglion-cells with their fibers, which establish communication with the brain-centers.

*The Pigment Layer.*—The conspicuous deeply-colored stratum of pigment-cells which forms the most external layer of the retina is the direct representative of the attenuated outer lamella of the optic vesicle. It is composed of hexagonal elements, about 0.015 mm. in diameter, although subject to marked individual variation, smaller cells often surrounding larger ones. Close examination of the pigment-cells in section shows that the colored particles do not invade the entire protoplasm, but that an outer zone, containing the nucleus, is clear, the pigment being confined to the middle and inner segments of the cells. The inner margin of the pigment-cells is irregular, in contrast to the smooth external border and in close relation to the outer ends of the rod and cone segments of the visual cells (Fig. 34).

The pigment-cells are profoundly affected by light stimulus, since under the influence of light the colored particles migrate toward the rods and cones, between which the protoplasm of the pigment-cells extends (Fig. 35). After

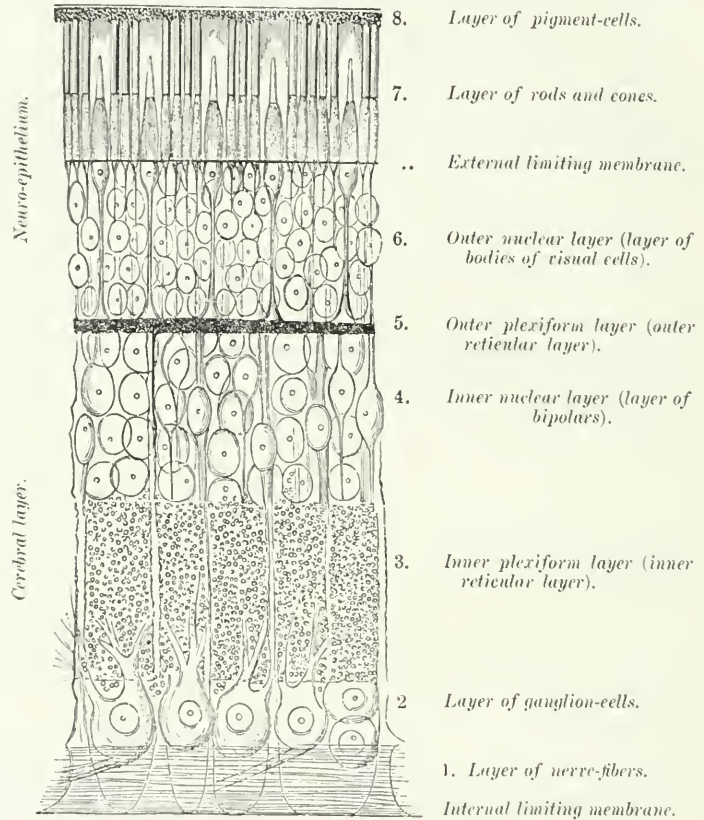


Fig. 33.—Diagrammatic section of the human retina (Max Schultze).

being subjected to darkness, on the contrary, the pigment particles are retracted and collected within the middle or so-called *basal zone* (Fig. 36). The relation between the pigment-cells and the rods and cones explains the variations in the

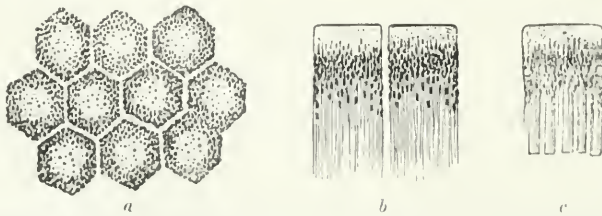


Fig. 34.—Pigmented epithelium from human retina (Max Schultze): a, surface view of cells, showing clear nuclei and intercellular lines; b, cells seen in profile, with protoplasm extended between percipient elements; c, cell still connected with rods.

degree of attachment between the colored and remaining portions of the retina: after exposure to light the intimate relation between the pigment and percipient elements renders the attachment between the two originally distinct lamellae



much stronger than that existing after seclusion in darkness, under which conditions the tendency to the natural separation of the embryologically distinct lamellæ becomes pronounced, the pigment then remaining attached to the choroid when the retina is removed.

*The Layer of Neuro-epithelium.*—Under this heading are included two strata, which are usually described as the layer of rods and cones and the external nuclear layer, the former being the specialized outer parts, and the latter the extended and attenuated nucleated bodies of the visual cells.

The *layer of rods and cones* represents the highly differentiated outer extremities of two forms of light-perceptive elements, the *rod-* and the *conevsual cell*. Under high amplification, as seen in section, *rods* of the human retina appear as elongated cylindrical forms, about 0.060 mm. in length and 0.002 mm. in thickness, each consisting of an *outer* and *inner segment* of about

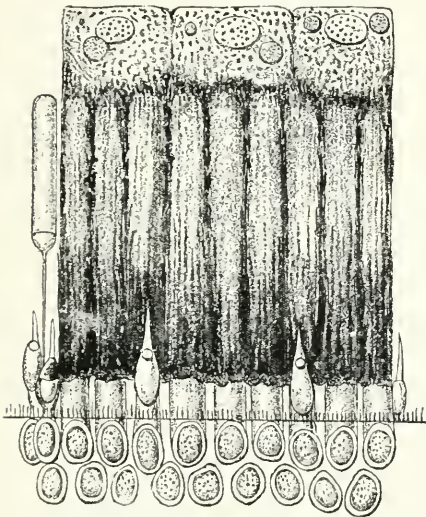


FIG. 35.—Section of frog's retina, showing the action of light upon the pigment-cells and upon the rods and cones (v. Gendren-Stort). The retina had been exposed to light for some time before killing; the pigment-cells have extended their protoplasm between the rods and cones nearly to their bases; the cones have retracted.

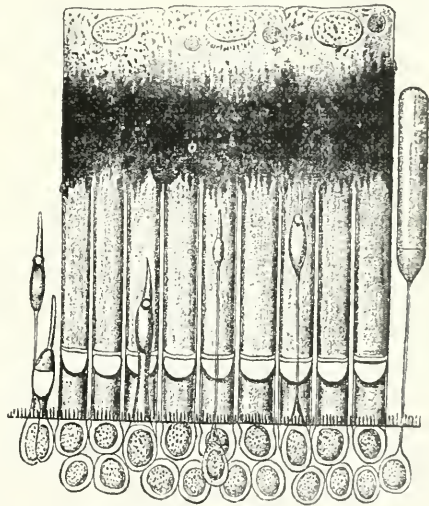


FIG. 36.—Section of frog's retina, showing action of darkness upon the pigment-cells and upon the rods and cones (v. Gendren-Stort). The retina had been kept in the dark for some hours before death, in consequence of which the pigment is retracted toward the nucleated part of the cells and from between the rods. The cones are elongated.

equal length. The *outer* segment possesses a uniform diameter and presents a homogeneous structure, being probably of the nature of a cuticular appendage. The external segments of the rods are of interest as being the chief, if not the sole, possessor of the visual purple or *rhodopsin*, the color being uniformly distributed throughout this part of the rod. The *inner* rod segment, with slightly increased diameter, is of feebly marked, ellipsoidal form, and exhibits more or less clearly a differentiation into an external faintly striated subdivision, the *rod-ellipsoid*, and an internal granular area, the *lenticular body* (Fig. 37).

The *body* of the rod-visual cell lies within the external nuclear zone and consists of the attenuated column of protoplasm, the *rod-fiber*, and the more conspicuous nucleus, the *rod-granule*. The rod-fiber is directly continuous with the inner part of the rod at the outer end, and extends into the external plexiform layer, within which it ends in a minute knob-like expansion in close relation with the terminal arborizations of the bipolar nerve-cells (Fig. 38).



The nuclei of the rod-cells, which usually present transverse dark and light stripes, are of much greater thickness than the rod-fiber, in consequence of which the position of the nucleus in each visual cell is indicated by a marked enlargement consisting of the nucleus surrounded by a thin envelope of protoplasm. The nuclei, or rod-granules, are situated at all layers, and contribute for the larger share of the deeply staining bodies which constitute the chief elements of the outer granule-layer.

The *cone-visual cells* are made up of the same general divisions as the associated rod-elements, including the specialized outer part, the cone, and

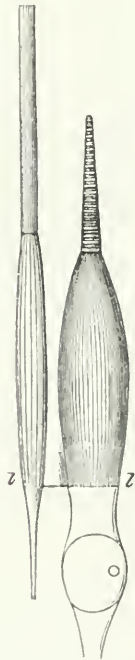


FIG. 37.—A rod and a cone from the human retina (Max Schultze). The line, *z, z*, indicates the position of the external limiting membrane; the portion of the figure unshaded represents parts of the visual cells contained within the outer nuclear layer.

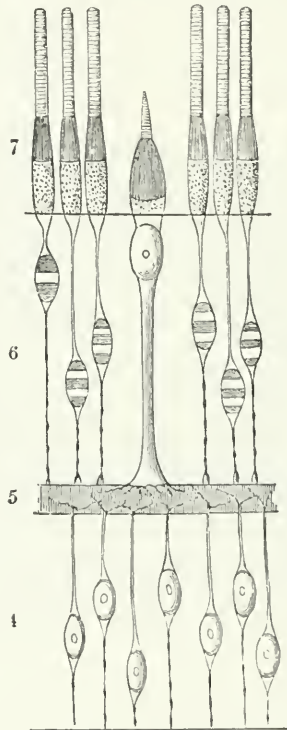


FIG. 38.—Diagram of the neuro-epithelial elements of the retina (Quain-Schwalbe): 4, bipolar nerve-cells, related to the rod- and cone-visual cells in the outer plexiform layer (5); 6, the nucleated bodies of the rod- and cone-visual cells, containing the rod- and cone-granules (nuclei) and the rod- and cone-fibers (these parts of the visual cells constitute the outer nuclear layer); 7, the layer of rods and cones which represents the outer highly specialized ends of the visual cells: each rod and cone is composed of the outer and inner segment.

the cone-cell body within the external nuclear layer. Each *cone* comprises an outer and an inner segment, which differ both in length and in thickness. In contrast to the almost uniform diameter and length of the two parts of the rods, the outer segment of the cones is shorter and thinner than the inner segment, which is conical, or, more accurately regarded, ellipsoidal, and measures about 0.006 mm. where it is broadest. The cones do not extend as far into the pigment layer as the rods, terminating as blunted cones at a point about opposite the middle of the outer segments of the adjacent rods. The cones do not contain the visual purple, but possess a somewhat higher refrac-

tive index than the rods. While the outer cone segment displays a tendency to break up into transverse disks, the inner segment exhibits a faint longitudinal striation.

The *body of the cone-visual cell* contributes to form the external nuclear layer, and consists of the attenuated cell-body, the *cone-fiber*, and broader conspicuous nucleus, the *cone-granule*. The latter, instead of occupying all levels of the nuclear layer, as do the nuclei of the rod-cells, are limited to the zone immediately below the external limiting membrane, being continuous with the bases of the inner cone-segments: additional characteristics of the cone-granules are their large size, lack of cross-stripes, and possession of nucleoli. The cone-fibers terminate within the outer plexiform layer in expanded bases or feet, which stand in close relation with the arborizations formed by the terminal expansions of the cone-bipolars.

The entire number of rods within the human retina has been estimated by Krause at 130,000,000; that of the cones, by Salzer at 3,360,000; the number of rods, therefore in the man is greatly in excess of the cones throughout most parts of the retina—in the fovea, however, the cones are alone present. The numerical proportion between the two varieties of percipient elements varies in different parts of the nervous tunic, as shown by the variation in the pattern seen on inspecting the surface of the retina where the cones appear as larger circles surrounded by areas of smaller rings; the cones are usually separated by an interval occupied by three or four rods. In the vicinity of the macula the cones increase so that only a single row of rods intervene, while in the fovea the cones alone are present (Fig. 39).

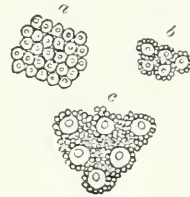


FIG. 39.—Surface view of the rods and cones, showing the relative distribution of these elements (Kölliker): *a*, from macula lutea, where only cones are present; *b*, from near macula, where only a single layer of rods separates the cones; *c*, from midway between macula and ora serrata, where rods preponderate.

#### *The External Plexiform, or Outer Reticular*

*Layer.*—This stratum lies next the layer of visual cells or neuro-epithelium, and is the first of the lamellae which constitute the cerebral division of the retina. The layer appears as a light, faintly staining zone, about 0.01 mm. in breadth, the apparent granular structure of which, as seen under moderate amplification, giving place to an intricate reticulum when examined with higher magnification. The true nature of this reticulum was demonstrated only after the introduction of the more recent improved methods of staining by the Golgi silver and methylene-blue processes: recent investigations have shown that the major part of the plexiform layer consists of the delicate ramifications and intricate interlacings of the processes of the nerve-cells constituting the ganglion retinæ and occupying the inner nuclear zone, held together by the delicate framework of sustentacular tissue.

The exact relations between the central extremities of the cone- and rod-visual cells and the endings of the nerve-cell processes have long been the subject of discussion. The direct connection formerly supposed to exist between the nerve-cells and the visual cells is no longer tenable in the light of our modern conceptions regarding the ultimate endings of nerve-processes, since the best authorities are agreed that each nerve-cell exists as an independent element, whose relation to other cells is one of contiguity and not of anatomical continuity. The nervous elements in close relation with the visual cells are the “rod” and “cone” bipolars, the nucleated bodies of which form the conspicuous “granules” of the inner nuclear layer. The peripherally directed processes of these nerve-cells extend within the external

plexiform layer and terminate in end-arborizations surrounding the inner extremities of the visual cells, which also penetrate into the reticular zone.

Additional nervous elements, the *horizontal, basal, or stellate cells*, are found within the external plexiform layer; they exist in two forms, the *smaller outer* and the *larger inner cells*. The former are flattened stellate elements which lie within the outer part of the plexiform layer, through which their long axis-cylinder processes extend for considerable distances to terminate in arborizations surrounding the ends of the visual cells, thus establishing indirect conduction between the elements lodged within the plexiform stratum. The larger inner horizontal cells occupy the deeper portions of the layer, some possessing descending processes which penetrate centrally as far as the inner plexiform layer, in which they terminate in arborizations.

*The Layer of Bipolar Nerve-cells, or the Inner Nuclear Layer.*—This stratum, as usually seen, closely resembles the outer nuclear layer, being apparently composed of large numbers of deeply staining granules. The layer measures from 0.035 mm. in the vicinity of the optic disk to 0.018 mm. at the ora serrata.

The ganglion-cells of the layer consist of two chief varieties—those especially related to the rod-visual cells, and hence appropriately called *rod-bipolars*; and those associated with the cone-cells, known as the *cone-bipolars*. The particular purpose of the bipolars is to supply the connecting link between the visual cells, around which they terminate on the one hand, and the large ganglion elements giving off the nerve-fibers to the brain, in relation to which their centrally directed processes expand, on the other. Reference to Fig. 40 shows that the arrangement of the processes of the cone-bipolars differs from that of the processes of the rod-bipolars: the latter extend through the entire thickness of the inner plexiform layer to the bodies of the ganglion-cells, which they enclose with their arborizations. The descending processes of the cone-bipolars, on the contrary, are limited to the inner plexiform layer, meeting with the expansions of the ascending dendrites of the large ganglion-cells at various levels, where the interlacing

FIG. 40.—Elements of the mammalian retina after treatment with the Golgi silver method (Cajal): I. Section of the dog's retina: *a*, cone-fiber; *b*, rod-fiber and nucleus; *c, d*, bipolar cells (inner granules) with vertical ramification of outer processes destined to receive the enlarged ends of rod-fibers; *e*, bipolars with flattened ramification for ends of cone-fibers; *f*, giant bipolar with flattened ramification; *g*, cell sending a neuron or nerve-fiber process to the outer molecular layer; *h*, amacrine cell with diffuse arborization in inner molecular layer; *i*, nerve-fibrils passing to outer molecular layer; *j*, centrifugal fibers passing from nerve-fiber layer to inner molecular layer; *m*, nerve-fibril passing into inner molecular layer; *n*, ganglionic cells.

II. Horizontal or basal cells of the outer molecular layer of the dog's retina. *A*, small cell with dense arborization; *B*, large cell, lying in inner nuclear layer, but with its processes branching in the outer molecular; *a*, its horizontal neuron; *C*, medium-sized cell of the same character.

III. Cells from the retina of the ox: *a*, rod-bipolar with vertical arborization; *b, c, d, e*, cone-bipolars with horizontal ramification; *f, g*, bipolars with very extensive horizontal ramification of outer process; *h*, cells lying on the outer surface of the outer molecular layer, and ramifying within it; *i, j, m*, amacrine cells within the substance of the inner molecular layer.

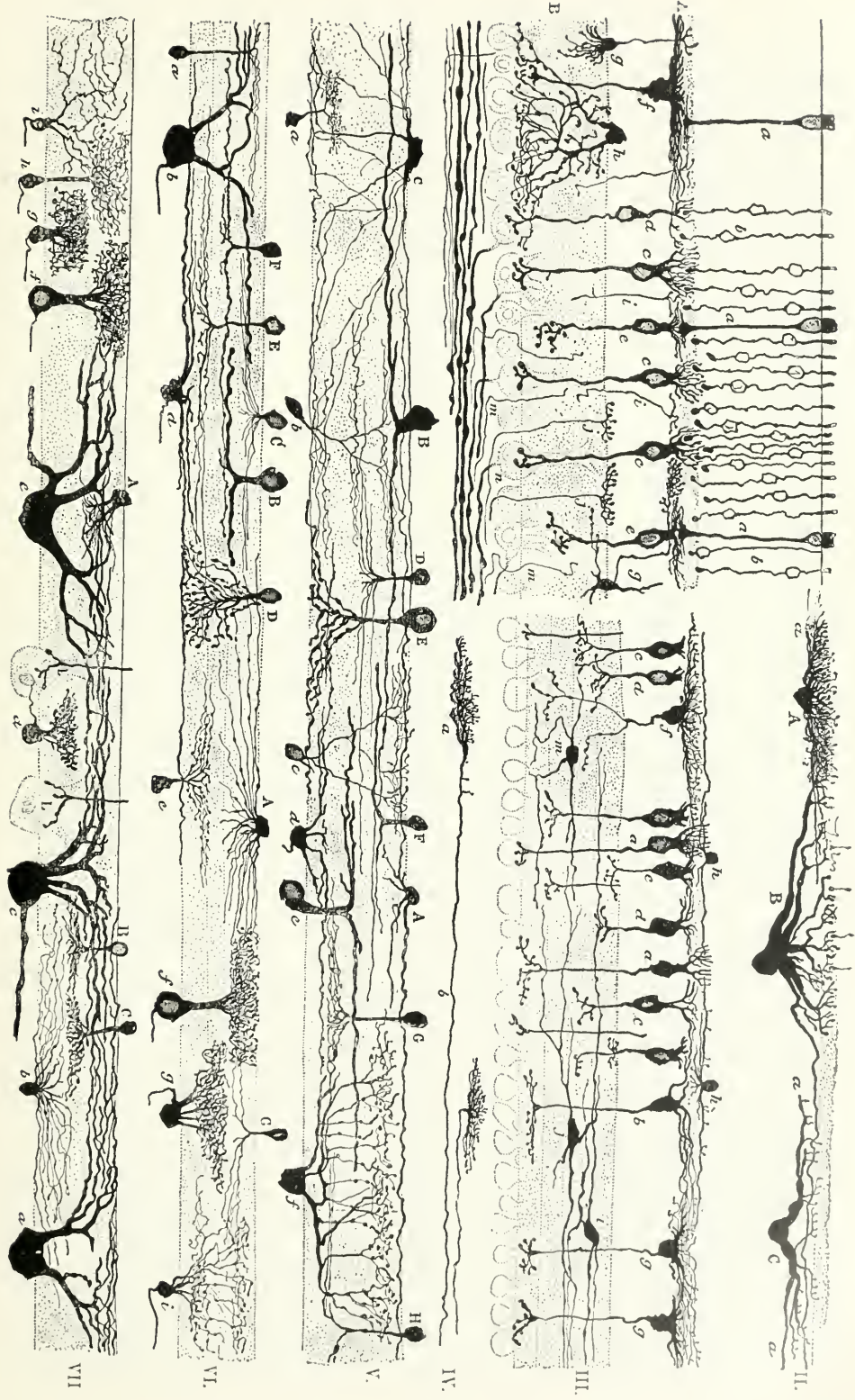
IV. Neurons or axis-cylinder processes belonging to horizontal cells of the outer molecular layer, one of them, *b*, ending in a close ramification at *a*.

V. Nervous elements connected with the inner molecular layer of the ox's retina: *A*, amacrine cell, with long processes ramifying in the outermost stratum; *B*, large amacrine with thick processes ramifying in second stratum; *C*, flattened amacrine with long and fine processes ramifying mainly in the first and fifth strata; *D*, amacrine with radiating tuft of fibrils destined for third stratum; *E*, large amacrine, with processes ramifying in fifth stratum; *F*, small amacrine, branching in second stratum; *G, H*, other amacrines destined for fourth stratum; *a*, small ganglion-cell sending its processes to fourth stratum; *b*, a small ganglion-cell with ramifications in three strata; *c*, a small cell ramifying ultimately in first stratum; *d*, a medium-sized ganglion-cell ramifying in fourth stratum; *e*, giant cell, branching in third stratum; *f*, a bistratified cell ramifying in second and fourth stratum.

VI. Amacrines and ganglion-cells from the dog: *A*, amacrine with radiating tuft; *B*, large amacrine passing to third stratum; *C* and *G*, small amacrines with radiations in second stratum; *F*, small amacrine passing to third stratum; *D*, amacrine with diffuse arborization; *E*, amacrine belonging to fourth stratum; *a, d, e, g*, small ganglion-cells, ramifying in various strata; *c*, a small cell ramifying in first stratum; *b, f*, large ganglion-cells, showing two different characters of arborization; *i*, bistratified cell.

VII. Amacrines and ganglion cells from the dog: *A, B, C*, small amacrines ramifying in middle of molecular layer; *b, d, g, h, i*, small ganglion-cells showing various kinds of arborization; *f*, a larger cell, similar in character to *g*, but with longer branch; *a, c, e*, giant cells with thick branches ramifying in the first, second, and third layers; *L, L*, ends of bipolars branching over ganglion-cells.







arborizations of the two elements form plexuses of considerable extent. The peripheral arborizations of the cone-bipolars expand beneath the broad bases of the cone-visual cells, forming horizontally-extended, terminal plate-like groups of ultimate fibrillae.

In addition to the bipolar cells the inner zone of the inner nuclear layer contains nervous elements which were long ago described by Müller under the name of "spongioblasts," under the impression that the cells in question were concerned in the production of the sustentacular framework of the layer: these elements are now regarded as nervous in character, and, from their peculiarity of seemingly being without axis-cylinder processes, have been named by Cajal *amacrine cells*. The richly branching dendrites of these elements extend into the inner plexiform layer, in which they end either in the expanded brush-like arborizations of the *diffuse amacrines*, or in the horizontally extending arborizations of the *stratiform* type. A few oval nuclei within this stratum belong to the long columnar supporting fibers of Müller, which usually possess irregular uncleated expansions within the zone.

*The Internal Plexiform, or Inner Reticular Layer.*—This has been already largely described incidentally to the consideration of the bipolar cells, since the expansions of the processes of these elements contribute largely to the formation of this layer. The inner plexiform stratum, about 0.04 mm. in width, resembles closely the similar outer zone, being really an intricate reticulum formed by the interlacement of the processes of nerve-cells situated in the adjacent laminae. In addition to the delicate supporting framework of neuroglia, the principal constituents of the layer are the descending processes of the rod- and cone-bipolars and the horizontal cells of the inner nuclear layer, and the ascending dendrites from the subjacent large ganglion-cells, augmented by the processes derived from the amacrine cells. The supporting fibers of Müller are also conspicuous as vertically coursing striae within this stratum.

*The Layer of Ganglion-cells.*—This layer, as indicated by the name, is characterized by the large nervous elements which form its chief constituent. The conspicuous ganglion-cells are disposed as a closely-placed single row throughout the greater part of the retina: toward the macular region, however, they become more numerous, and in the immediate vicinity of the yellow spot are arranged as a double layer, increasing in number within that area until, at the margin of the fovea, they are superimposed to such an extent that they lie from six to eight deep. Toward the ora serrata, on the contrary, they are sparingly distributed, lying isolated and widely separated. The ganglion-cells resemble other typical nervous elements in the possession of richly branched dendrites, which pass into the inner plexiform layer to end in arborizations in relation with the descending processes of the bipolars, and axis-cylinder processes, or neurites, which become the axis-cylinders of the nerve-fibers converging toward the optic entrance, and thence, as optic fibers, brainward. The details of the distribution of the dendrites within the inner plexiform layer have supplied a basis for the division of the ganglion-cells into two groups—those which terminate in *horizontal* ramifications limited to definite strata, and those which terminate in *diffuse* ramifications distributed to the entire layer. Additional distinctions, depending on the size of the cells, as *large*, *medium*, and *small*, are also recognized.

*The Layer of Nerve-fibers.*—This is largely the direct contribution of the preceding stratum, since the nerve-fibers composing this zone are the extended neurites of the ganglion-cells. After arising from the presiding cells the fibers almost at once assume a horizontal course and form larger or smaller bundles, which, after traversing a distance varying with the position of their origin, con-

verge to the optic entrance and contribute to the formation of the visual nerve. The size of the nerve-fibers is generally small, but a limited number of very large fibers also exist: these, it is supposed, are connected with ganglion-cells of exceptional magnitude.

In addition to the centrally coursing fibers the presence of fine peripherally directed, or "centrifugal," nerve-fibers has been established. The central connections of such fibers are at present uncertain; their peripheral terminations lie within the inner plexiform layer, and apparently have no discoverable connection with the cells of the ganglion layer.

The bundles of nerve-fibers, while pursuing a general radial course toward the optic entrance, freely intermingle and form a reticulum. The presence of the macula lutea disturbs the strictly radial course of the bundles on the temporal side of the optic disk, the space separating the latter from the yellow spot being traversed by from twenty-five to thirty delicate fasciculi which possess an almost straight course from the macula to the disk; these fibers collectively constitute the *macular bundle* described by Michel. The bundles adjacent to the macular group suffer deflection from the typical radial course and arch above and below the macular area; beyond the yellow spot the arching bundles possess the typical radial arrangement.

**The Sustentacular Tissue.**—The *sustentacular tissue*, or *neuroglia*, of the retina exists in two forms—as the conspicuous radial fibers of Müller and as the spider-cells (Fig. 41).

The *fibers of Müller* constitute a sustaining framework which supports the nervous elements as well as the neuro-epithelium, coming into intimate relations with all parts of the retina. The Müllerian fibers are modified neuroglia-cells, derived originally from the ectodermal tissue of the wall of the neural tube, which extend through almost the entire thickness of the retina, reaching from the rods and cones, between which they contribute delicate septa, to the inner surface of the nervous tunic, where their expanded bases unite to form a seemingly continuous sheet, the *membrana limitans interna*. The fibers are slender nucleated columns which contribute lateral offshoots at various levels to the several retinal layers, among the elements of which the processes break up into delicate sustaining fibrillæ and reticula. The broadest expansion along the course of the fibers usually occupies the inner nuclear layer, and also contains the oval nucleus. At a level corresponding to the position of the inner ends of the rods and cones the sustentacular fibers come into apposition and form an apparent fenestrated partition, the *membrana limitans externa*, from the outer surface of which minute septa project between the rods and cones,

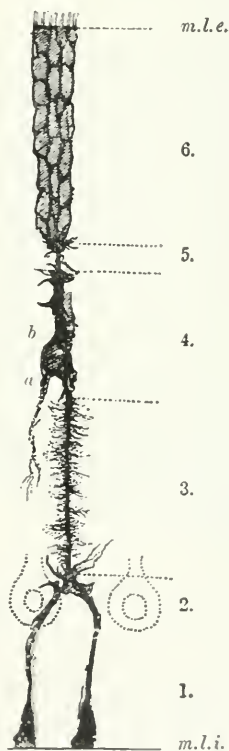


FIG. 41.—A supporting fiber of Müller after staining by Golgi's silver method (Ramon y Cajal). The extensions of a single fiber are shown in relation to the several retinal layers: 1, layer of nerve-fibers; 2, ganglion-cells; 3, inner plexiform layer; 4, inner nuclear layer; 5, outer plexiform layer; 6, outer nuclear layer; *m.l.e.*, *m.l.i.*, respectively, the external and internal limiting membrane; *b*, nucleus of fiber; *a*, process extending into internal limiting layer.

probably acting as an insulation of the individual percipient elements. As already noted, the inner ends of the fibers of Müller are greatly enlarged, the *bases* of the conspicuous pyramidal or conical expansions coming into close contact and producing the appearance, when treated with silver nitrate, of a continuous layer of endothelial plates; the bundles of retinal nerve-fibers pass between the diverging fibers to continue their radial course. Within the fiber layer additional sustentacular elements exist as the *spider-cells*, neuroglial elements whose characteristic appearance is due to the long, delicate processes which extend from the cell-body between the nerve-fibers in various directions.

**The Macula Lutea.**—The structure of the retina undergoes important modifications within two areas—at the macula lutea and the ora serrata (Fig. 42). On approaching the macula the ganglion-cells become so numerous that a single layer no longer suffices for their accommodation, and consequently they lie two deep; within the macular area the number further increases, so that they constitute a stratum which includes from six to eight rows of the nervous elements. On reaching the fovea centralis, however, the greatly thickened ganglion-layer rapidly decreases in thickness toward the center of the depression, becoming scattered and no longer sufficient to constitute a complete stratum, until at the bottom of the pit the ganglion-cells are altogether absent. The fiber-layer consequently suffers a corresponding diminution, and disappears as a distinct stratum at the point where the ganglion-cells end. The bipolar cells continue to the center of the fovea as an irregular row of small elements supported within the finely reticular tissue which represents the fused outer and inner plexiform layers, and fills the space between the visual cells and the inner surface of the retina.

The most prominent stratum within the fovea is that formed by the visual cells, here composed entirely of the cone-cells, which present a depth about three times that of all the more internally placed strata combined. The cones gradually lengthen on approaching the foveal center until, over the middle of the depression, they measure more than double the length of the corresponding elements at the margins of the pit; associated with the increased length, the cones become greatly attenuated, appearing as long, delicate, slender fibers of which the outer segment contributes by far the greater part (Fig. 42).

The external limiting membrane exhibits a slight inward deflection over the area included within the outward curve of the inner membrane: this outer depression, the so-called *fovea externa*, produces, however, but slight dipping inward of the outer surface of the retina, as the increased length of the cones in a measure compensates for the sinking of the limiting membrane. It is probable that the position of the external fovea corresponds to an associated thickening of the choroidal tissue. In recapitulation, therefore, the layers occupying the center of the fovea are the cone visual cells, constituting the layer of cones and the external nuclear layer and the fused outer and inner plexiform strata, with the included bipolar cells. The ganglion-cells and their derivative nerve-fibers are absent in the center of the fovea.

**The Ora Serrata.**—The extreme anterior limit of the visual portion of the retina is distinguished by a sudden diminution in the thickness of the nervous tunic, dependent upon the abrupt termination of the percipient elements, as well as those layers concerned in the transmission of the light stimuli centrally, the layer of retinal pigment alone retaining its identity in the further extension of the nervous coat.

The characteristic series of about forty well-marked dentations observed



in the adult retina are closely associated with the accommodative function, since in early life, before accommodation is fully exercised, the typical serrated border is wanting, the termination of the visual part of the retinal sheet being marked by a comparatively smooth line, the "transition border" of Schön, beset with numerous minute projections which afford attachment to certain of the delicate zonular fibers.

The sudden reduction of the retina depends especially upon the disappearance of the plexiform strata, the layer of rods and cones, however, having previously lost its integrity as a distinct zone. The inner nuclear layer is continued farthest, at the anterior limit of the ora passing into the single layer of columnar elements, which, in conjunction with the pigmented cells, are continued over the ciliary zone and processes as the pars ciliaris retinae.

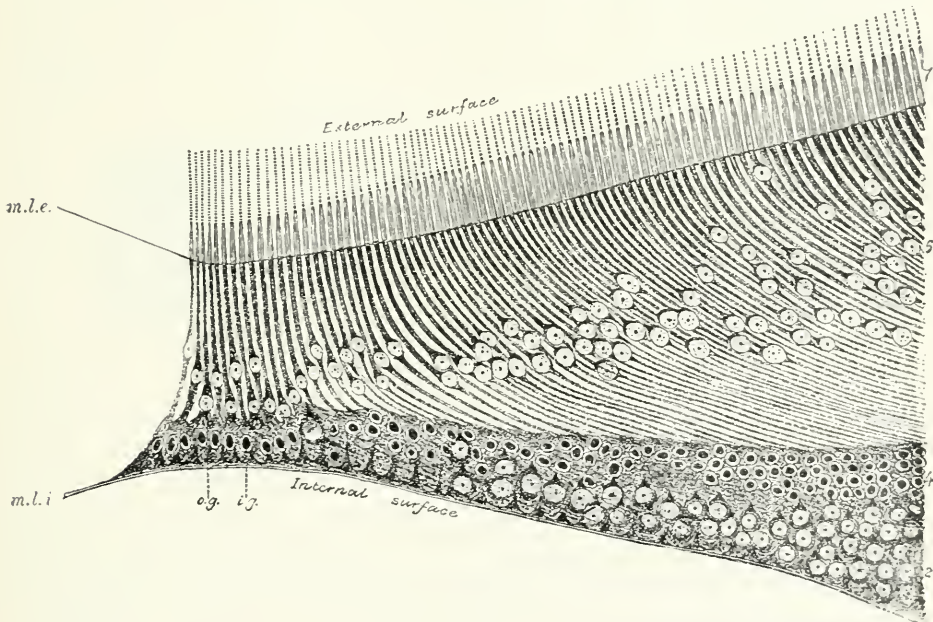


FIG. 42.—Diagrammatic section through the fovea centralis of the human retina (Golding-Bird and Schäfer); 2, ganglion-cell layer; 3, inner nuclear layer; 6, outer nuclear layer, the cone-fibers forming the so-called external fibrous layer of Henle; 7, cones; *m.l.e.*, external limiting membrane; *m.l.i.*, internal limiting membrane; *o.g.*, *i.g.*, outer and inner granules (cone-nuclei and bipolars).

The radial fibers of Müller are especially well developed in the vicinity of the ora serrata, being of large size and numerous. So close is the relation between the sustentacular tissue and the ora that it has been suggested that the supporting fibers are continued beyond the limits of the serrated border and become connected with the zonular fibers.

**The Optic Entrance.**—The point toward which the centrally directed axis-cylinders of the fiber-layer converge to escape from the interior of the eyeball and to form the optic nerve is marked by a light-colored circular area, varying from 1.5 to 1.7 mm. in diameter, the *optic entrance*, *optic disk*, or *optic papilla*. The surface of the yellowish- or bluish-white disk is broken by the central retinal vessels which pierce the area eccentrically, lying usually somewhat nearer the nasal side, and pass over the margins of the disk to gain the surrounding fiber-layer.

On examining a vertical section through the optic entrance (Fig. 43) it



will be seen that the thick bundles of the optic fibers which arch over the margins of the interrupted retinal and choroidal layers to gain the disk produce a slight elevation, the *papilla optici*: in consequence of the rapid arching of the fibers the center of the disk is lower than the margin; hence the production of the so-called *physiological excavation* (see also page 66). The remaining retinal layers terminate abruptly in the vicinity of the nerve-entrance, a narrow maze of reticulated *intermediate tissue* separating them from the arched bundles of nerve-fibers. The ganglion-cells are the first to disappear, while the visual cells continue farthest toward the nerve, the rod- and cone-fibers assuming an oblique position.

The *blood-vessels* of the retina first appear on the optic disk as they emerge from the bundles of nerve-fibers, between and parallel to which they run from the point at which they obliquely enter the optic nerve some 15 to 20 mm. beyond the eyeball. The retinal vessels, of which the *arteria centralis retinae* and the accompanying vein are the chief trunks, form a closed system which only indirectly, in the vicinity of the optic entrance, communicates

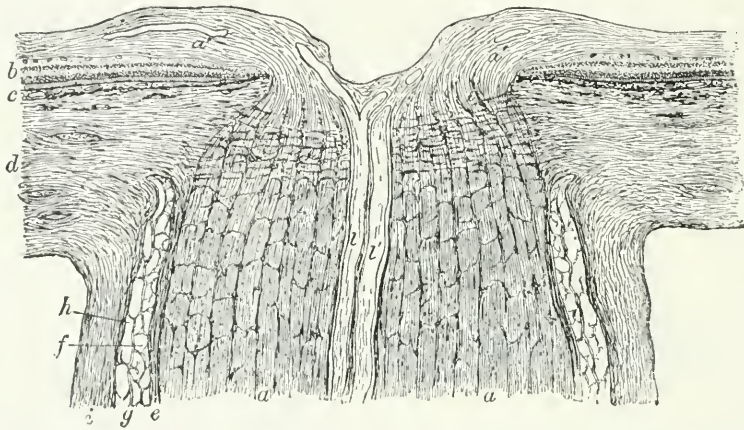


FIG. 43.—Longitudinal section of optic entrance of human eye (Piersol): *a, a*, bundles of optic fibers, which spread out over retina at *a', a'*; *b*, layers of retina; *c*, choroid; *d*, sclera, continued across optic nerve as the lamina cribrosa; *c, g, h*, respectively the pial, arachnoid, and dural sheaths of optic nerve, enclosing subdural and subarachnoid lymph-spaces; *l, l'*, retinal blood-vessels cut longitudinally.

with the vessels distributed to the remaining coats of the eyeball. On attaining the optic disk the central artery divides into two main stems, the *superior* and *inferior pupillary branches*, directed almost vertically upward and downward. These subdivide into smaller branches, the *superior* and *inferior nasal* and *temporal arteries*, which run mesially and laterally; additional twigs pass directly outward as the *superior* and *inferior macular arteries* to supply the important area of the yellow spot. While the greater part of the macular area is richly supplied with blood-vessels, the fovea centralis is without them.

On examining the details of the vascular distribution of the retina it is found that the vessels of larger size are contained within the fiber-layer, dividing into branches which do not anastomose, being "end-arteries." The arterioles break up into rich capillary networks, which are distributed as the *inner* and *outer plexuses*, the former lying at the junction of the fiber- and the ganglion-layer, while the latter is situated within the inner nuclear zone, being especially destined for the nutrition of the functionally active bipolar nerve-cells. As already noted, the nutrition of the percipient elements, the visual cells, is mainly maintained by the dense vascular network of the chorio-capillaris of the middle tunic.

The *lymphatics* of the retina are represented chiefly by the perivascular lymph-channels which enclose all the veins and capillary blood-vessels, and communicate with the subpial lymph-space of the optic nerve. Between the larger nerve-bundles, in the vicinity of the optic papilla, the interfascicular lymph-clefts may be regarded as additional lymphatic channels. The fact that injections from the subpial space pass between the pigment layer and the rods and cones, and again between the inner surface of the retina and the adjacent hyaloid membrane, has been regarded as proof of the existence of lymph-spaces in these situations.

**The Optic Nerve.**—The nerve of sight, about 5 cm. in length, is divisible into three segments—the *intracranial*, the *intraorbital*, and the *intraocular*. The first of these, the intracranial, extends from the optic commissure to the optic foramen, a distance of about 1 cm., and contains the extensions of the fibers which eventually pass to end in terminal arborizations associated with the nerve-cells of the cerebral centers within the pulvinar of the optic thalamus, the external geniculate bodies, and the anterior corpora quadrigemina. The cortical areas connected with sight have been definitely located within the occipital lobe, and probably include the cuneus. The intraorbital portion of the nerve presents a series of slight curves which render the nerve sigmoid rather than straight.

Transverse sections of the optic nerve show it to be composed of a large number, about eight hundred, of distinct bundles of medullated fibers separated from one another by connective-tissue septa, which are derived as offshoots from the pial sheath investing the nerve. The entire number of fibers contained within the optic nerve probably approaches a million, the measurable fibers having been estimated at about half that number by Salzer. In its arrangement and composition the optic nerve resembles a gigantic funiculus, the endoneurium being in the present instance represented by the penetrating pial tissue, while the sheath itself corresponds to the perineurium. The nerve-fibers vary in diameter from a delicacy which defies measurement to a thickness of 0.01 mm. In addition to the connective-tissue fibers forming the coarser trabecula and septa, the sustentacular tissue proper consists of neuroglia in which numerous spider-cells are prominent: these elements are supplemented by the deeply-staining connective-tissue cells belonging to the fibrous septa.

The intraorbital portion of the optic nerve is invested by extensions of the brain-membranes which form the corresponding *dural*, *arachnoidal*, and *pial sheaths*. The general character of these envelopes is similar to that of the meninges, the tough dural sheath lying outside and the pial sheath closely applied to the nerve, with the arachnoidal sheath between. Between the dural and arachnoidal envelopes lies the *subdural* lymph-space; between the arachnoidal and the pial sheaths, the *subarachnoidal* space. On reaching the fibrous tunic of the eyeball all these sheaths, together with the included spaces, terminate by blending with the fibro-elastic stroma of the sclera, the lymph-spaces extending sometimes for a short distance between the fibrous bundles of the outer tunic.

The external limit of the intraocular segment of the optic nerve is distinguished by the position at which the nerve-fibers acquire a medullary sheath on emerging from the sclerotic tissue which they traverse. The scleral bundles separate to allow the passage of the groups of optic fibers, and interlace with one another to form a sieve-like structure, the *lamina cribrosa* (Fig. 43). The bridging fibers are contributed particularly by the inner third of the scleral coat, but are supported by additional bundles

of fibrous tissue derived from the connective-tissue septa of the optic nerve.

**The Crystalline Lens.**—The most important part of the refractive apparatus of the eye consists of a transparent lenticular body, the *crystalline lens*, of circular outline and biconvex section, which supports the pupillary margin of the iris in front and rests within a depression, the *patellar fossa*, on the anterior surface of the vitreous body behind; laterally, the lens is connected with the supporting fibers which collectively form the suspensory ligament, or zone of Zinn. The lens substance consists of a soft, compressible material of such transparency during youth as to possess no color; later, with the advent of senile changes, it assumes a yellowish tint and slight opalescence, which first affects the central portion of the lens and gradually extends toward the periphery. Early in life the lens substance is of the same consistency throughout; gradually, however, the central portion becomes harder, until in advanced age considerable difference in condensation distinguishes the "nucleus" from the cortical layers. The lens being non-vascular, its nutrition is maintained entirely by the intercellular transmission of nutritive fluids: the differentiation of the central and peripheral portions is due to the loss of water of the favorably situated central portion of the lens. The hardening which thus gradually takes place results in loss of elasticity of the lens substance, which change is manifested in the defective accommodation which characterizes the eyes of persons after middle life. Owing to the increased density of the nucleus, the central portion of the lens of advanced years reflects more light, and the pupil consequently lacks the jet black of young eyes and appears slightly dimmed.

The soft lens substance is enclosed within a delicate elastic but strong membrane, the *lens capsule*: the latter is resistant to reagents, such as alcohol and acids, as well as to putrefactive changes. While possessed of considerable strength, it is brittle and readily torn by sharp instruments; when incised its cut edges roll in a characteristic manner, with the outer surface inward. When viewed in section that portion of the enveloping membrane covering the front surface of the lens is seen to be distinctly thicker than the corresponding part behind: these differences have given rise to the designation of these portions of the membrane as the *anterior* and *posterior* capsule, although both are but parts of the same general envelope.

Invested by its capsule, the lens measures from 9–10 mm. in its transverse diameter, being larger in old and large subjects; its average thickness is about 4 mm., but this dimension necessarily varies with the condition of accommodation, being somewhat greater when the eye is fixed on near objects and less when accommodated for distance. The radius of curvature of the surfaces also varies under such changing conditions, that of the anterior surface, however, manifesting greater change under the extremes of accommodation than that of the posterior; thus, while the radii of the anterior surface for distant and near vision are respectively 10 and 6 mm., those of the posterior surface for the same conditions are respectively 6 and 5 mm. These figures establish the fact that the curvature of the anterior surface of the lens is much more affected in accommodation than that of the posterior, which remains almost unchanged. (See also page 135.) The length of a meridian of the lens measures about 12 mm. The average weight of the lens is about 0.22 gm., and the specific gravity 1.121. The anterior pole of the lens lies about 2.3 mm. behind the cornea under passive conditions of accommodation; its posterior pole, about 15.5 mm., in front of the macula lutea. Critical examination has demonstrated a slight outward devi-



ation, of from three to seven degrees, of the antero-posterior lens-axis from that of the eye; an additional, but smaller, vertical deviation has also been noted.

The structure of the crystalline lens can best be appreciated after recalling what has already been stated in connection with its mode of formation. The lens develops by the elongation and modification of the original ectodermic epithelial cells, which become converted into the lens-fibers, those constituting the posterior wall of the primary lens-sac at first composing the entire lens substance. Subsequently additional layers of lens-fibers are produced by the elongation and specialization of the cells constituting the anterior wall of the lens-sac, which later are known as the *epithelium of the anterior capsule*. The region in which the transformation of the epithelial cells into lens-fibers takes place corresponds to the equatorial area, and is known as the *transitional zone*; throughout the entire period of growth this region exhibits the conversion of the columnar epithelial elements of the anterior capsule into the elongated meridionally arranged lens-fibers. The lens substance, therefore, is composed of modified epithelial tissue.

The capsule of the lens is of entirely different origin, since its development is due to mesodermic tissues, and is distinct from that of the lens substance.

The *capsule* of the lens envelops the lens substance on all sides with a delicate, highly elastic membrane, which, in addition to supporting the soft material constituting the bulk of the lens, affords attachment for the fibers of the suspensory ligament. The capsule varies in thickness, being most robust in the central area

of its anterior surface, where it measures from 0.010 to 0.015 mm. in thickness, and thinner at the periphery; its most attenuated part is the central area of its posterior portion, where it measures from 0.005 to 0.007 mm. The capsule does not exhibit any details of structure, and in chemical composition and reactions differs from both fibrous and elastic tissue.

The *epithelium of the lens-capsule* lies beneath the anterior capsule alone, consisting of a single layer of polyhedral flattened cells, about 0.020 mm. in diameter. These elements morphologically represent the anterior wall of the original lens-sac. On approaching the margin of the lens the cells of the anterior capsule become more elongated, until finally, in the transition zone, the epithelial elements become converted into the young lens-fibers. As a result of these changes being confined to a limited area, the nuclear zone, a peculiar spiral figure, is produced by the elongating cells and their nuclei, to which the term *lens-whorl* has been applied.

The *substance* of the lens, constituting its entire bulk, is composed of layers of elongated and modified epithelial cells, the *lens-fibers*, united by an extremely thin layer of cement substance. The individual lens-fibers, as

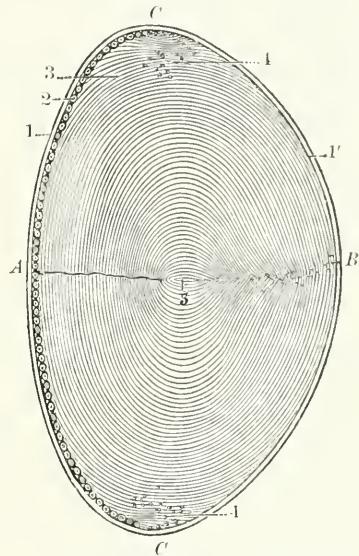


FIG. 44.—Meridional section through human crystalline lens (Babuchin): A, anterior, B, posterior surface; C, C, equatorial region; 1, 1', anterior and posterior capsule; 2, epithelium beneath anterior lens-capsule; 3, lens substance composed of fibers; 4, transition zone where cells of anterior epithelium are converted into lens-fibers; 5, nucleus.



seen after isolation by boiling, maceration in dilute acids, and other methods, are long, ribbon-like fibers which, on transverse view, present a compressed hexagonal outline. The lens-fibers vary in length, those forming the outer layers of the lens being distinctly longer than those found within the nucleus: the former extend about two-thirds of the meridional distance from pole to pole, while the latter correspond to the length of the lens-axis. Additional differences in the breadth and thickness exist between the fibers from the periphery and central layers, the dimensions of the more superficially situated fibers being the greater. The fibers also exhibit variations in consistency, depending upon the relatively greater amount of tissue-juices in the cortical layers.

The lines of apposition of the meridionally arranged lens-fibers, joined by the cement substance, produce definite figures of a stellate form, the so-called *lens-stars*, which are especially well marked in the young or in the cortical portion of the older lens. (See page 23.)

The growth of the lens after its primary development is due entirely to the addition of layers of new lens-fibers derived exclusively from the cells of the anterior epithelium, the transformation being limited to the equatorial zone. There is no evidence of the direct multiplication of the lens-fibers themselves, since these elements represent cells which have become specialized beyond the limits of reproduction.

**The Vitreous Body.**—The extensive space bounded by the crystalline lens and its suspensory ligament in front, and by the retina behind, is filled by the vitreous body or *humor vitreus*. The fresh vitreous body appears as a semi-fluid mass, perfectly transparent, whose general form resembles a flattened sphere, the anterior pole of which is further modified by the presence of the patellar fossa for the reception of the posterior surface of the crystalline lens. The function of the vitreous is to support the nervous tunic, rather than to act as a refractive medium, since its index of refraction (1.336) is almost identical with that of the aqueous humor, and but slightly in excess of that of water.

When the fresh vitreous is thrown upon a filter, by far the greater part of the tissue passes through as a watery fluid, a very slight proportion of the entire structure remaining as morphological constituents: this observation establishes the fact that the vitreous body anatomically consists of two portions, the supporting framework and the fluid tissue. Chemically, the vitreous consists of about 98.5 per cent. water, the remaining small proportion of the whole, composed of solids, includes salts, extractives, and minute quantities of proteids and nucleo-albumin.

The semi-fluid, gelatinous vitreous substance proper is enclosed within a delicate envelope, the *hyaloid membrane*, from which a delicate supporting reticulum extends throughout the mass of the vitreous body. Without considering in detail the conflicting views as to the structure of the vitreous body which from time to time have been advanced, it may be regarded as established that the vitreous substance represents an embryonal form of connective tissue modified by an unusual infiltration of water, so that its original condition as a connective tissue becomes masked.

The true nature of the tissue in question can only be determined by examination of the fetal vitreous before the infiltration of the watery constituents has taken place. The young tissue presents a delicate reticulation of connective-tissue elements, the interlacing fibrillae forming a delicate meshwork containing numerous nucleated areas. With the advance of development the connective-tissue elements of the vitreous tissue become

less and less conspicuous, until the adult tissue contains only suggestions of the stellate cells which at one time were prominent morphological elements. In suitably prepared specimens a delicate supporting framework composed of exceedingly fine fibrillae can be demonstrated in all parts of the vitreous: at the peripheral parts of the vitreous local condensations exist which in places, as within the patellar fossa, suffice to form the external limiting envelope. Membranous septa, concentrically or otherwise disposed, as described by various authors, must be regarded as artificial products if at all present.

The cellular elements of the adult vitreous (Fig. 45) are very meager, and consist in a few sparingly distributed atrophic connective-tissue cells; in addition to these elements, which belong to the vitreous tissue, *migratory leukocytes*, or *wandering cells*, also occur, especially immediately beneath the hyaloid membrane, where they all constitute the *subhyaloid cells*. These cells are derived probably from the blood-vessels in the vicinity of the optic entrance and the ora serrata.

The central portion of the vitreous is penetrated by a channel, the *hyaloid canal*, *canal of Stilling*, *canal of Cloquet*, or *central canal*, which extends

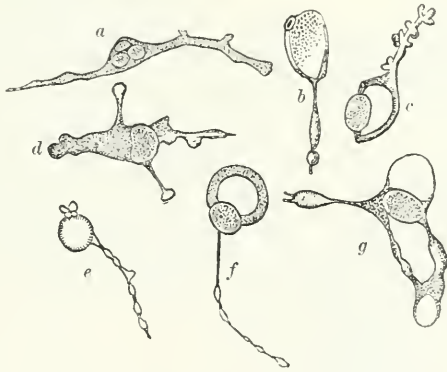


FIG. 45.—Morphological elements found within the vitreous body (Schwalbe): *a, g, d*, cells without vacuoles; *b, c, e, f, g*, vacuolated forms.

from the optic entrance toward the lens as far as the patellar fossa: this canal surrounds the atrophic remains of the fetal hyaloid vessels, which traversed the vitreous and supplied the vascular lens envelope. The channel begins as a slight enlargement, the *arcu Martegiani*, of a diameter equal to that of the optic disk, and ends in the neighborhood of the posterior lens surface in a blind, not infrequently somewhat dilated, extremity.

The *hyaloid membrane* encloses the greater part of the vitreous body as a transparent envelope of great delicacy which closely adheres to the retina. In eyes which have been kept for several days in dilute alcohol the hyaloid membrane can be demonstrated on the vitreous body, since in such specimens it can be separated from the retina without mutilation. The hyaloid membrane is wanting over that part of the vitreous body which surrounds the patellar fossa: within this depression the peripheral condensation of the supporting tissue of the vitreous body alone constitutes the limiting envelope of the soft gelatinous tissue within.

**The Suspensory Apparatus of the Lens.**—The position of the crystalline lens is maintained by means of a series of delicate bands, which pass from the vicinity of the ora serrata over the ciliary processes to be attached

to the periphery of the lens. These fibers collectively constitute the *suspensory ligament*, or *zone of Zinn*, a structure of great importance not only for the support of the lens, but also in effecting the changes in the curvature of the lens surface associated with accommodation (Figs. 46 and 47).

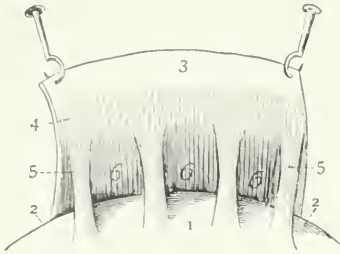


FIG. 46.—Diagrammatic view, from posterior surface, of the insertion of the zone of Zinn into the capsule of the lens (Testut): 1, posterior lens surface; 2, its equator; 3, zonula; 4, 5, the anterior and posterior bands, inserted into the corresponding surfaces of the lens-capsule; 6, the interfascicular spaces, formerly regarded as the canal of Petit.

Viewed from the posterior surface, the suspensory ligament appears as a delicate annular structure, about 6 mm. in width, which blends with the periphery of the lens on the one hand, and with the hyaloid membrane in the vicinity of the ora serrata on the other. When examined under low magnification in meridional sections of the ciliary region the suspensory ligament is seen to be not a continuous membrane, but an interlacing series of delicate fibers which bridge at various angles the space between the lens and the ciliary processes.

The older view, whereby the zone of Zinn was regarded as a direct continuation of the inner leaflet of the hyaloid membrane, formed by means of the cleavage which was supposed to take place in the vicinity of the ora serrata, has been now generally displaced by the newer teachings founded upon the more accurate studies of the developmental relations of the parts in question: according to these observations the hyaloid membrane does not undergo cleavage, but continues closely applied to the ciliary body, over which its attenuated extension stretches as far as the processes before fading away. The suspensory fibers constituting the zone of Zinn originate as independent structures, and genetically are closely related to the primitive vitreous body. Subsequently the zonular fibers become closely attached to the ora serrata as well as the hyaloid membrane, and seemingly take partial origin from these structures (Fig. 47).

The zonular fibers of the adult may be divided into *chief* and *accessory*. The chief zonular fibers, which constitute the principal union between the lens and the surrounding ciliary body, may be subdivided into *orbiculo-capsular* and *cilio-capsular* according to the position of their attachment to the ciliary body, whether to the orbiculus ciliaris or the ciliary processes. When traced to their attachment to the lens the fibers are found to vary in the position of their insertion into the capsule, some being fused in advance, others behind the lens periphery: these variations of attachment affect especially the orbicular group of zonular fibers, and hence their classification into the *orbiculo-antero-capsular* and the *orbiculo-postero-capsular* fibers, which pass from the ciliary ring to the anterior and posterior surfaces of the lens-capsule respectively. The fibers springing from the summits and sides of the ciliary processes join the lens-capsule either on the posterior surface or at the periphery, and are hence designated the *cilio-postero-capsular* or the *cilio-equatorial fibers*.

The accessory fibers are important additions to the strength of the suspensory ligament, since they comprise numerous shorter bands which act as braces and binders to the longer chief trabeculae. The accessory fibers are principally of two kinds—those which pass from the ciliary processes to the long zonular fibres, and those which extend from point to point within the ciliary zone. The first group includes numerous short bands which unite the



orbiculo-capsular fibers with the ciliary processes and ciliary ring; the second comprises especially the bands which have the fixation of the ciliary processes as their especial purpose, and constitute two principal groups—the *orbiculo-ciliary* and the *intraciliary* fibers.

The zone of Zinn, or the suspensory ligament, is evidently not a continuous membrane, but a series of interlacing bands between which numerous apertures and clefts occur. The insertion of the zonular fibers into the lens is so regular and the fibers bound together so intimately that it is possible to inject air between the constituents of the zone, so that the lens is surrounded

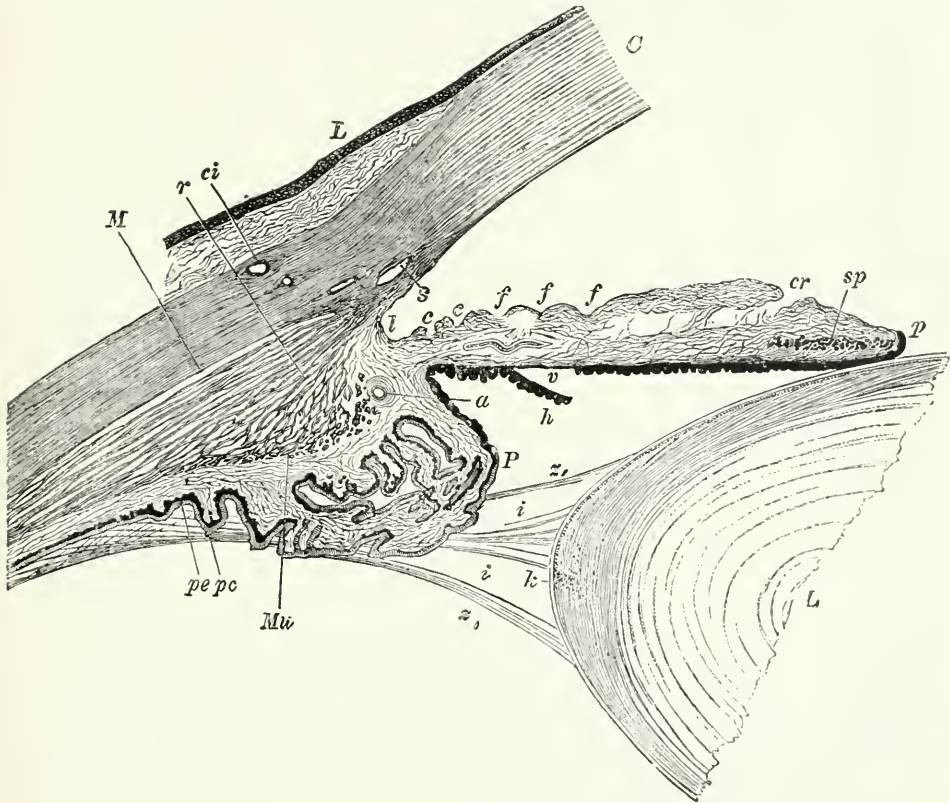


FIG. 47.—Meridional section through ciliary region, including part of the lens (Fuchs): *C*, cornea; *pe, pc*, pigmented and non-pigmented cells of the pars ciliaris retinae; *L*, lens; *M*, ciliary muscle; *r*, its radiating, *Mu*, its circular fibers; *ci*, anterior ciliary artery; *s*, canal of Schlemm; *z*, origin of ciliary muscle; *c, f*, anterior surface of iris; break at *cr*; *sp*, sphincter pupillae; *p*, edge of pupil; *P*, ciliary process; *h*, pigment lining iris, partly separated at *v*; *a*, blood-vessel; *z*, zone of Zinn; *z<sub>1</sub>, z<sub>2</sub>*, fibers of suspensory ligament, enclosing spaces *i, i'*; *k*, lens-capsule.

by an annular series of beaded dilatations. This appearance was long accepted as demonstrating the existence of a delicate channel, the *canal of Petit*, encircling the periphery of the lens. With the more accurate understanding of the composition of the supporting apparatus of the lens the existence of the canal of Petit has become doubtful, and in the former sense of a closed annular channel altogether denied by most authorities. The intercommunicating spaces between the zonular fibers establishes a passageway for fluids from the posterior chamber into the vitreous chamber.

**The Aqueous Humor.**—The aqueous humor, the transparent lymph derived from the blood-vessels surrounding the spaces in which it is con-



tained, fills both the anterior and posterior chamber, as well as the extensions of the latter represented by the intrazonular spaces.

The production of the aqueous humor takes place in the posterior chamber, and is effected chiefly by the blood-vessels of the ciliary processes, and possibly also by those of the vascular ridges which extend to the posterior surface of the iris. The recesses between the ciliary processes have been regarded by some as representing special secreting tissue, the so-called "ciliary glands," but there is little evidence to sustain the view that in the secretion of the aqueous humor the entire ciliary processes do not take part.

The quantity of aqueous humor usually present is about 275 cub. mm., its weight about 0.275 gm., and its specific gravity 1.0053. Its index of refraction is 1.337, but slightly in excess of that of water (1.334), and nearly that of the cornea (1.360): compared with the refracting index of the vitreous (1.336), it is found to be almost identical. The quantity of aqueous humor present is an important factor in determining the intraocular tension, and hence the maintenance of the free escape of the lymph, as provided for in the spaces of Fontana and the canal of Schlemm, is of great importance. In its chemical composition the aqueous humor consists chiefly of water: in addition to the 98.6 parts of this constituent, small quantities of solids, extractives, and proteids are present. The aqueous humor possesses the property of absorbing certain organic substances with which it comes in contact, such as blood and the lens substance; it also possesses solvent properties to an extraordinary degree for many drugs. With the exception of a few migratory leukocytes, the aqueous humor is without morphological elements.

**The Blood-vessels of the Eyeball.**—The terminal arrangement and distribution of the blood-vessels of the various parts of the eye have already been described in connection with the consideration of the various structures: a brief description of the general arrangement of the vessels supplying the visual organ is here added.

All the arteries supplying the eyeball are derived from the ophthalmic artery as two sets of branches, the *retinal* and the *ciliary*. These form two separate systems, which communicate only in the vicinity of the optic entrance by means of minute anastomotic twigs.

The retinal system is based upon the distribution of the *central artery of the retina*, a small branch which arises from the ophthalmic close to the optic foramen, usually in common with the internal ciliary, seldom as an independent trunk. On gaining the interior of the eyeball the central stem divides into the retinal arteries, and during the fetal stages continues forward to the posterior lens surface as the hyaloid artery, a vessel which later disappears.

The ciliary system supplies the remaining parts of the eyeball, and consists of two sets of vessels, the *posterior* and *anterior ciliary arteries*. The posterior arise by two chief trunks, an *inner* and an *outer*, which are given off from the ophthalmic artery while it lies below the optic nerve. These stems each divide into from four to ten branches, which surround the optic nerve, and on reaching the eyeball pierce the sclerotic coat in the vicinity of the point of entrance of the nerve. The posterior ciliary arteries then form two groups—the *short*, which pass at once to the choroidal tract to take part in forming the rich vascular network of the middle tunic; and the *long*, which pass forward, one on each side of the eye, between the sclera and choroid, to the ciliary region, where, after giving direct branches to the ciliary muscle, they join the anterior ciliary arteries to form the vascular plexuses from which the adjacent parts are supplied.

The *anterior ciliary arteries*, usually from six to eight in number, are derived from the muscular and lachrymal branches of the ophthalmic; in the vicinity of the corneal margin they penetrate the scleral coat, and finally join the long posterior ciliary vessels to form the *circulus arteriosus iridis major*. Before passing through the sclerotic these arteries give off anterior and posterior branches which supply the conjunctiva and anterior parts of the fibrous tunic. After piercing the sclera twigs are given off which pass to the ciliary muscle, as well as others which as *recurrent branches*, together with similar branches from the long posterior ciliary arteries, anastomose with the choroidal vessels derived from the short ciliary trunks. An important anastomotic communication is thus established between the blood-vessels supplying the choroid proper and those distributed to the ciliary region.

The branches of the long posterior and the anterior ciliary arteries inosculate within the ciliary region to form in the vicinity of the root of the iris an arterial circuit, the *circulus arteriosus iridis major*, from which vessels are given off to the ciliary processes and the iris, as well as recurrent anastomotic twigs to the choroid.

The *venous trunks* draining the eyeball in general correspond in their arrangement to that of the arteries, the chief groups being the *retinal, posterior, and anterior ciliary veins*. The retinal veins receive the blood from the closed retinal system and follow closely the corresponding arteries. The posterior ciliary veins, or, more familiarly, the *vena vorticosæ*, collect the blood from the iris, the ciliary processes, part of the ciliary muscle, the orbiculus ciliaris, and the choroid, and pierce the sclerotic coat within the equatorial region as four large trunks, which converge at points about equidistant from one another; after penetrating the fibrous tunic they additionally receive the episcleral veins. The anterior ciliary veins drain a much more limited area than that supplied by the corresponding arteries, since within the eyeball they receive only the blood returned from the ciliary muscle, taking up the small radicles communicating with Schlemm's canal: after emerging from the sclerotic coat the anterior ciliary veins receive as tributaries the episcleral and the anterior conjunctival vessels.

**The Lymphatics of the Eyeball.**—The lymph-channels of the eyeball comprise two systems, the *anterior* and the *posterior*.

The *anterior lymph-tract* embraces (1) the chambers occupied by the most important intraocular collection of lymph, the aqueous humor, together with the system of spaces by which this fluid is normally carried off, as represented by the spaces of Fontana and canal of Schlemm; and (2) the elaborate system of juice-channels within the cornea and adjacent part of the sclera. The *posterior lymph-tract* includes two separate systems, that of the choroid and of the retina. The lymphatic fluid of the choroid is collected within the *perichoroidal lymph-space*, between the choroid and the sclera, from which cleft the lymph escapes chiefly into the space of Tenon, or *episcleral lymph-space*, by means of the perivascular lymphatic canals accompanying the *vena vorticosæ*: additional perivascular channels may also exist in connection with the posterior ciliary arteries. The accumulated lymph within the space of Tenon finds its way into the large intracranial lymph-spaces, probably by means of the supravaginal space which surrounds the exterior of the optic nerve. The retinal system of lymphatics is represented by the perivascular lymph-sheaths surrounding the retinal vessels, as well as by the hyaloid canal within the vitreous. These channels communicate with the lymph-clefts within the optic nerve, which are connected with the great intracranial lymph-spaces by means of the subarachnoidal spaces of the optic nerve.

# GENERAL PHYSIOLOGY OF VISION.

BY ALBERT P. BRUBAKER, M. D.,

OF PHILADELPHIA.

**Introduction.**—The visual apparatus in its entirety constitutes a mechanism the excitation of which gives rise (1) to the sensation of light and its different qualities—colors; (2) to the perception of light and color under the form of pictures of external objects; (3) to the production of muscular sensations by which we judge of the size, distance, and direction of objects. The specific physiological stimulus to the terminal apparatus of the optic nerve is the impact of the undulations of a perfectly elastic medium, the ether. The transfer of the energy of the ether-vibrations into that form of energy known as a nerve-impulse takes place in the pigment of the neuro-epithelial layer of the retina. The nerve-impulses so generated are transmitted by the fibers of the optic nerve to the cells of the cerebral cortex, in which some molecular process takes place out of which the mind forms the sensations of light and color. In general, it may be said that, at least for the same color, the intensity of the objective vibrations determines the intensity of the sensations.

The optic nerve, obeying the same general laws of nerve-stimulation, reacts also to the electric current and to mechanical agencies, as shown by flashes of light with varying shades of color.

The formation of images on the percipient elements of the retina, which by their forms and associated colors give rise to the perception of objects, is made possible by the introduction of a complex refracting apparatus consisting of the cornea, aqueous humor, crystalline lens, and vitreous humor. Without these agencies ether-vibrations would only give rise to a sensation of diffused luminosity. The movements of the eyeball occasioned by the contractions of the ocular muscles are attended by muscular sensations, out of which the mind draws its conclusions as to the size, distance, and direction of objects.

**The Eye a Living Camera.**—In its construction, in the arrangement of its various parts, and in their mode of action the eye may be compared to a *camera obscura*. Though the comparison may not be absolutely exact, yet in a general way it is true that there are many striking points of similarity between them—*e. g.* the sclera and choroid may be compared to the walls of the camera; the combined refractive media to the single lens, the action of which results in the focussing of the light-rays; the retina to the sensitive plate receiving the image formed at the focal point; the iris to the diaphragm for the regulation of the amount of light to be admitted, and for the partial exclusion of those marginal rays which give rise to *spherical aberration*; the ciliary muscle to the adjusting screw, by means of which the image is brought to a focus on the sensitive plate, notwithstanding the varying distances of the object from the lens. The presence of the *visual purple* in

the rods of the retina capable of being altered by light makes the comparison still more striking.

**The Retinal Image.**—The existence of an image on the retina can be readily seen in the excised eye of an albino rabbit, the coats of which are quite transparent from the absence of pigment. Its presence in the human eye can be demonstrated with the ophthalmoscope. It is this image, composed of focal points of luminous rays, which is the basis of our sight-perceptions, and which stimulates the rods and cones, and out of which the mind constructs space-relations of external objects. In only two essential respects does the image on the retina differ from the object, aside from the fact that the object has usually three, the image only two, dimensions—viz. in size and relative arrangement of its parts. Whatever the distance, the image is generally smaller than the object: it is also reversed, the upper part of the object becoming the lower part of the image, and the right side of the object the left of the image, and the reverse.

**The Dioptric Apparatus.**—The media by which rays of light entering the eye are refracted and brought to a focus with the production of an image consist of the cornea, aqueous humor, lens, and vitreous body. As the two surfaces of the cornea are practically parallel, and as the index of refraction of the aqueous humor is the same as that of the cornea, they may be regarded as but one medium. The refracting surfaces may therefore be reduced to the anterior surface of the cornea, the anterior surface of the lens, and the posterior surface of the lens.

Rays of light emanating from one point—that is, *homocentric rays*—entering the eye must traverse successively the different refractive media. In their passage from one to the other they undergo at their surfaces changes in direction before they are converged to a focal point. In order to mathematically follow the rays in all their deviations through the media, to determine their focal point, and to construct the image, a knowledge of the form of the refracting surfaces, the refractive index of the different media, and the distance of the surfaces from each other, must be obtained.

The following constants are now accepted: The radii of curvature of that portion of each refracting surface used for distinct vision are for the cornea 7.829 mm., for the anterior and posterior surfaces of the lens 10 and 6 mm., respectively. The indices of refraction of the different media are as follows: cornea and aqueous humor, 1.3365; lens, 1.4371; vitreous body, 1.3365. The distance from the vertex of the cornea to the lens is 3.6 mm.; the thickness of the lens, 3.6 mm.; the distance from the posterior surface of the lens to the retina, 15 mm.

*Homocentric rays* of light entering the eye pass from air with a refractive index of 1.00025 into the cornea with an index of 1.3365. In passing from the rarer into the denser medium they undergo refraction and are rendered somewhat convergent. The extent of this first refraction and convergence is sufficiently great to bring parallel rays, if continued, to a focus about 10 mm. behind the situation of the retina. On entering the lens they are for the same reason again refracted and converged, and if continued would come to a focus about 6.5 mm. behind the retina. On passing into the vitreous body they are again converged to an extent sufficient to focalize them on the retina (Fig. 48).

While it is possible thus to geometrically follow the rays through these media by means of the above-mentioned factors, the procedure is attended with many difficulties. Moreover, as the relations all change when rays enter the eye from objects situated progressively nearer the eye, a separate



calculation is necessitated for each distance for the determination of the size of the image.

A method by which these difficulties are much reduced was suggested by Gauss and developed by Listing. It was demonstrated by Gauss that in every complicated system of refracting media separated by spherical centered surfaces there may be assumed certain *ideal* or *cardinal points*, to which the system may be reduced, and which, if their relative position and properties be known, permit of the determination, either by calculation or geometrical construction, of the path of the refracted ray, and the position and size of the image in the last medium of the object in the first.

Every dioptric system can be replaced, as Gauss showed, by a single system composed of six cardinal points and six planes perpendicular to the

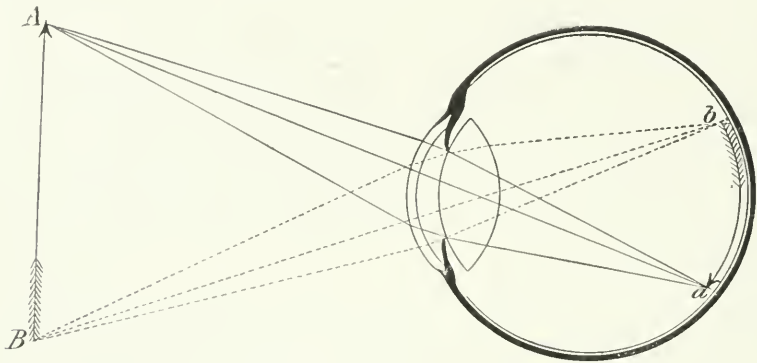


FIG. 48.—Refraction of homocentric rays and the formation of images on the retina.

common axis—*e. g.* two focal points, two principal points, two nodal points, two focal planes, two principal planes, and two nodal planes.

**Properties of the Cardinal Points.**<sup>1</sup>—The *first focal point*,  $F_1$  in Fig. 49, has the property that every ray which before refraction passes through it after refraction is parallel to the axis.

The *second focal point*,  $F_2$ , has the property that every ray which before refraction is parallel to the axis passes after refraction through it.

The *second principal point*,  $H_2$ , is the image of the *first*,  $H_1$ ; that is, rays in the first medium which go through the first principal point pass after the last refraction through the second. Planes at right angles to the axis at these points are *principal planes*. The second principal plane is the image of the first. Every point in the first principal plane has its image after refraction at a corresponding point in the second principal plane at the same distance from the axis and on the same side.

The *second nodal point*,  $N_2$ , is the image of the *first*,  $N_1$ : a ray which in the first medium is directed to the first nodal point passes after refraction through the second nodal point, and the directions of the rays before and after refraction are parallel to each other. In Fig. 49 let  $AB$  represent the axis. The distance of the first focal point,  $F_1$ , from the first principal plane,  $H_1$ , is the *anterior focal distance*. The distance of the posterior focal point,  $F_2$ , from the second principal plane,  $H_2$ , is the *posterior focal distance*. The distance of the first nodal point,  $N_1$ , from the first focal point is equal to the second focal distance. The distance of the second nodal point,  $N_2$ , from the posterior focal point is equal to the anterior focal distance. It is evi-

<sup>1</sup> For additional consideration of this subject see pages 109 and 125.

dent, therefore, that the distance of the corresponding principal and nodal points from each other is equal to the differences between the two focal distances. Also the distance of the two principal points from each other is equal to the distance of the two nodal points from each other. Finally, the

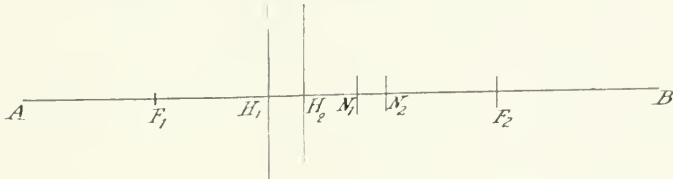


FIG. 49.—Diagram showing the position and relation of the cardinal points.

focal distances are proportional to the refractive indices of the first and last media. Planes passing through the focal points vertically to the axis are known as *focal planes*.

From these properties of the cardinal points the position of an image in

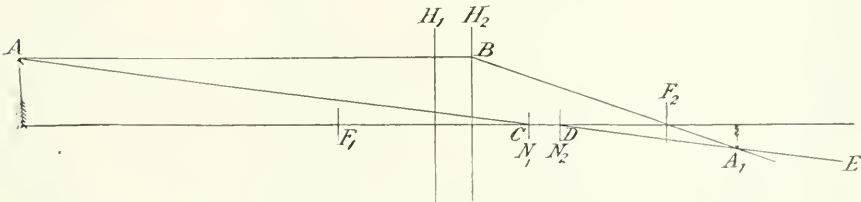


FIG. 50.—Diagram to find the image in last medium of a luminous point in the first.

the last medium of a luminous point in the first may be determined, and the course of a refracted ray in the last medium be constructed if its direction in the first be given according to the following rules:

1. To find the image in the last medium of a luminous point in the first:

Let  $A$  (Fig. 50) be this given point. Draw  $AB$  parallel to the axis until it meets the second principal plane in  $B$ ; then  $BF_2$  will be this ray after refraction. Draw a second ray from  $A$  to the first nodal point; then draw another ray,  $DE$ , from the second nodal point parallel to  $AC$ . This will be the refracted ray in the last medium. Where the two refracted rays,  $BF_2$  and  $DE$ , intersect, the image of  $A$  will be  $A_1$ .\*

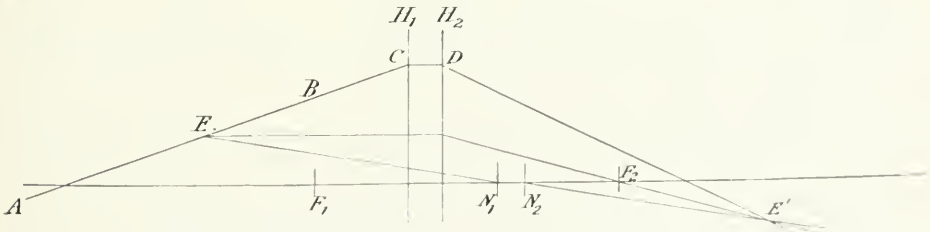


FIG. 51.—Diagram to find the refracted ray in the last medium of a given ray in the first medium.

2. To find the refracted ray in the last medium of a given ray in the first medium. Let  $AB$  (Fig. 51) be the given ray. Continue this ray until it meets the first prin-

\* If the point  $A$  is infinitely far from the eye, all the rays striking the eye will be parallel to each other. The nodal ray must therefore be drawn, and the point where this nodal ray meets the second focal plane will be the image of  $A = A_1$ , where all rays parallel to the nodal ray will meet.

cipal plane in  $C$ . Draw  $CD$  parallel to the axis. Now assume any point, such as  $E$ , in the given ray, and find its image  $E_1$  by the Rule 1. Then  $DE_1$  becomes the course of the refracted ray.

**The Schematic Eye.**—Accepting the system of cardinal points, Listing, Donders, and v. Helmholtz have constructed “schematic” eyes to be substituted for the refracting system of the natural eye.

For this purpose it is necessary to deduce from the various estimates of the indices of refraction of the different media, of the radii of curvatures of the different refractive surfaces, and of the distances separating them an average eye as a basis for calculation. The most recent attempt is that of v. Helmholtz. The data he assumed are as follows: The refractive index of air = 1; of the cornea and aqueous humor, 1.3365; of the lens, 1.4371; of the vitreous humor, 1.3365; the radius of curvature of the cornea, 7.829 mm.; of the anterior surface of the lens, 10 mm.; of the posterior surface, 6 mm.; the distance from the apex of the cornea to the anterior surface of the

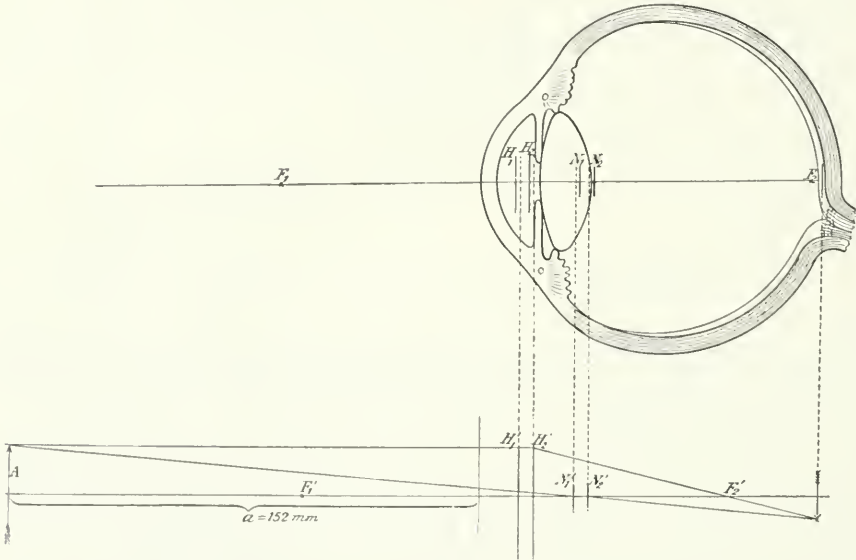


FIG. 52.—Diagram showing the position of the cardinal points in the “schematic eye.” The continuous lines in the upper half of the figure show their position in the passive emmetropic eye. The dotted lines indicate the change in their position in an eye accommodated for the object  $A$  at the distance  $a$  from the cornea, or 152 mm. The lower half of the figure shows the formation of a distinct image on the retina of an eye accommodated for the object  $A$  at the distance  $a$  from the cornea.

lens, 3.6 mm.; thickness of lens, 3.6 mm. From these data v. Helmholtz calculated the position of the cardinal points for the eye as follows (see Fig. 52): The first focal point is situated 13.745 mm. before the anterior surface of the cornea; the posterior focal point is situated 15.619 mm. behind the posterior surface of the lens; the first principal point, 1.753 mm. behind the cornea; the second principal point, 2.106 mm. behind the cornea; the first and second nodal points, 6.968 and 7.321 mm. behind the apex of the cornea, respectively. The anterior focal distance of this schematic eye therefore amounts to 15.498 mm., and the posterior focal distance to 20.713 mm.

When the eye, however, is accommodated for near vision, the relations of the cardinal points are changed as follows, if the point accommodated for lies 152 mm. from the cornea: Anterior focal distance, 13.990 mm.; posterior focal distance, 18.689 mm.; distance from cornea of the first and second

principal points, 1.858 and 2.257 mm. respectively ; distance of the posterior focus, 20.955 mm. from cornea. Given this schematic eye in the accommodated state, the course of the rays and the determination of the position of an image in the last medium of a luminous point in the first can easily be determined by the rules above given.

**The Reduced Eye.**—As suggested by Listing, this schematic eye may be yet further simplified or reduced to a single refracting surface bounded anteriorly by air and posteriorly by aqueous or vitreous humor. Without introducing any noticeable error in the determination of the size of the retinal image, the anterior principal and the anterior nodal points may be disregarded, owing to the minuteness of the distances (0.39 mm.) separating the two systems of points. There is thus obtained one principal point and one nodal point, which latter becomes the center of curvature of the single refracting surface. The dimensions of this “reduced” eye are as follows (see Fig. 53):

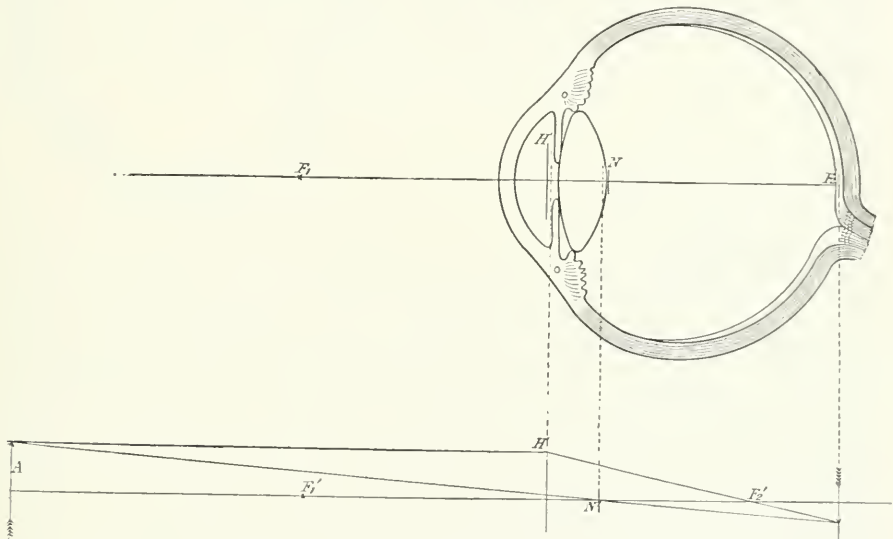


FIG. 53.—Diagram showing the position of the cardinal points in the “reduced eye.” The continuous lines in the upper half of the figure show their position in the passive eye. The dotted lines refer to their change of position when the eye is accommodated for the near object,  $A$ . The lower half of the figure shows the formation of an image in the reduced eye and the relation between the size of the object and the size of the image.

From the anterior surface of the cornea to the principal point, 2.106 mm. ; to the nodal point, 7.321 mm. The anterior focal distance is 15.498 mm. ; the posterior focal distance, 20.713. There is thus substituted for the natural eye a single refracting surface having a radius of curvature of 5.215 mm. The index of refraction of this eye is 1.3365, which is that of the vitreous humor. In such an eye luminous rays emanating from the anterior focal point are parallel to the axis after refraction in the interior of the eye. Also rays parallel to the axis before refraction unite at the posterior focal point. By means of this reduced eye the construction of the refracted ray, the various calculations as to the size of the image, the size of diffusion circles, etc. are much facilitated.

In Fig. 54 let  $AB$  represent an object. From  $A$  homocentric rays fall on the single refracting surface  $H$ . One of the rays, the nodal ray, falling on the surface perpendicularly, passes unrefracted through the single nodal point,  $N$ , to the posterior focal plane. The remaining rays, falling on this surface under varying degrees of incidence, undergo corresponding degrees of refraction, by which they form a converging cone of



rays which unite at a point situated on the nodal ray. These two points are known as *conjugate foci*. The same holds true for homocentric rays emanating from *B* or any other point of the object.

The size of the retinal image, *I*, may now be easily calculated, when the size of the object, *O*, and its distance, *D*, from the refracting surface with radius of curvature, *R*, are known, by the following formula :

$$O : I = D + R : F_2 - R.$$

For, as the triangles  $\triangle NAB$  and  $\triangle Nba$  are equal, we have

$$\triangle B : ab = fN : Ng, \text{ or } ab = \frac{AB \times Ng}{fN}.$$

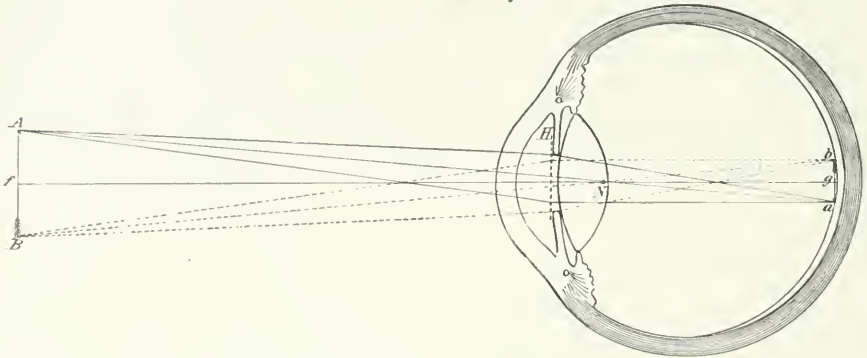


FIG. 51.—Diagram to illustrate formation of images in reduced eye.

**Accommodation.**<sup>1</sup>—In a normal or *emmetropic* eye homocentric parallel rays of light after passing through the optic media are converged and brought to a focus on the retina. Rays, however, which come from a luminous point situated near the eye, and which are therefore divergent and passing through the optic media at the same time, are intercepted by the retina before they are focussed, and give rise to the formation of diffusion-circles and indistinctness of vision. The reverse is also true. When the eye is adjusted for the refraction and focussing of divergent rays, parallel rays will be brought to a focus before reaching the retina, and, again diverging, will form diffusion-circles. It is evident, therefore, that it is impossible to simultaneously focus both parallel and divergent rays, and to see two objects distinctly at the same time which are situated at different distances. The eye must be alternately adjusted first to one object and then to another. The capability which the eye possesses of adjusting itself to vision at different distances is termed *accommodation*.

The following table of Listing shows the size of the diffusion-circles formed of objects situated at different distances when the accommodative power is suspended :

| Distance of luminous point. |    | Distance of the focal point behind the posterior surface of the retina. |     | Diameter of the diffusion-circle. |     |
|-----------------------------|----|-------------------------------------------------------------------------|-----|-----------------------------------|-----|
|                             |    | 0.                                                                      | mm. | 0.                                | mm. |
| ∞                           | m. | 0.005                                                                   | “   | 0.0011                            | “   |
| 25                          | “  | 0.012                                                                   | “   | 0.0027                            | “   |
| 12                          | “  | 0.025                                                                   | “   | 0.0056                            | “   |
| 6                           | “  | 0.050                                                                   | “   | 0.0112                            | “   |
| 3                           | “  | 0.100                                                                   | “   | 0.0222                            | “   |
| 1.500                       | “  | 0.20                                                                    | “   | 0.0443                            | “   |
| 0.750                       | “  | 0.40                                                                    | “   | 0.0825                            | “   |
| 0.375                       | “  | 0.80                                                                    | “   | 0.1616                            | “   |
| 0.188                       | “  | 1.60                                                                    | “   | 0.3122                            | “   |
| 0.091                       | “  | 3.20                                                                    | “   | 0.5768                            | “   |
| 0.088                       | “  | 3.42                                                                    | “   | 0.6484                            | “   |

<sup>1</sup> For additional consideration of this subject consult page 134 and page 155.

The normal eye when adjusted for distant vision is in a passive condition and unattended with fatigue. In the act of adjustment, however, for near vision the eye passes into an active state, the result of a muscular effort, the energy of which is proportional to the nearness of the object toward which the eye is directed. From the above table it is evident that rays of light coming from infinity or from any object even but 6 m. distant are so nearly parallel and the diffusion circles so very small that the indistinctness of the image is scarcely perceived, and hence no perceptible accommodative effort is required. Rays coming from objects situated progressively nearer the eye require for their focalization a constantly increasing effort of accommodation. During accommodation the lens undergoes a change of shape, becoming more convex, especially on its anterior surface. The greater the degrees of divergence of the rays the greater must be the increase in lens convexity, in order that they may be sufficiently converged and focalized on the retinal surface. Changes in the curvatures of the lens, either of increase or decrease, are attended with corresponding changes in the distinctness of the image.

**Mechanism of Accommodation.**—Though it is generally admitted that the increase in the convexity of the lens is caused by the contraction of the ciliary muscle and the subsequent relaxation of the suspensory ligament, the exact manner in which this is brought about is not well understood. When the eye is in repose and adjusted for distant vision the lens is somewhat flattened from the traction of the suspensory ligament. When the eye requires adjustment for near vision the ciliary muscle contracts, the suspensory ligament relaxes, and the lens, in consequence of its inherent elasticity, bulges forward and becomes more convex. Its antero-posterior diameter is thus increased and its refractive power is proportionally greater.

It is generally admitted that during accommodation the meridional fibers of the ciliary muscle draw forward the ciliary processes and relax the ligament. At the same time the outer border of the iris is drawn somewhat backward. In extreme efforts of accommodation it is also believed by some observers that the circular fibers, the so-called "annular muscle," contract and exert a pressure on the periphery of the lens, and thus aid other mechanisms in increasing the convexity. This view appears to be supported by the fact that in hyperopia, where there is a constant effort required for distinct vision even of distant objects, the annular muscle becomes very much hypertrophied, thus serving to reinforce the action of the meridional fibers. In myopia, on the contrary, where the accommodative effort is at a minimum, the entire muscle possesses less than its average size and development (compare with page 135).

**Optical Defects.**<sup>1</sup>—From a purely physical point of view the eye is not a perfect instrument. It is not quite achromatic, is not free from spherical aberration, and is not exactly centered. Moreover, its area of distinct vision is quite limited, and does not correspond with the field of projection, the retina. In first-class optical instruments the lenses are centered—that is, their exact centers are situated on the same axis. In viewing an object through such a system the visual line corresponds with the axis of the lens-system. This is not the case with the lens-system of the eye.

A line passing through the center of the cornea and the center of the eye, the *optic axis*  $OA$  in Fig. 55, does not pass exactly through the center of the lens, and does not fall into the point of most distinct vision, the fovea. This

<sup>1</sup> For a full consideration of the optical defects of the eye, see sections devoted to Optics and Refraction.

has led to the recognition of other lines, the relations of which must be borne in mind in all optical discussions.

1. The *visual axis*, or line of vision  $V'L$ , is the line connecting the point viewed, the nodal point, and the fovea centralis.

2. The *line of fixation*, or *line of regard*  $V'C$ , is the line connecting the point viewed with the *center of rotation*, the latter being situated 6 mm. behind the nodal point of the eye and 9 before the retina. The relations of these lines and certain angles in connection with them are shown in the following figure :

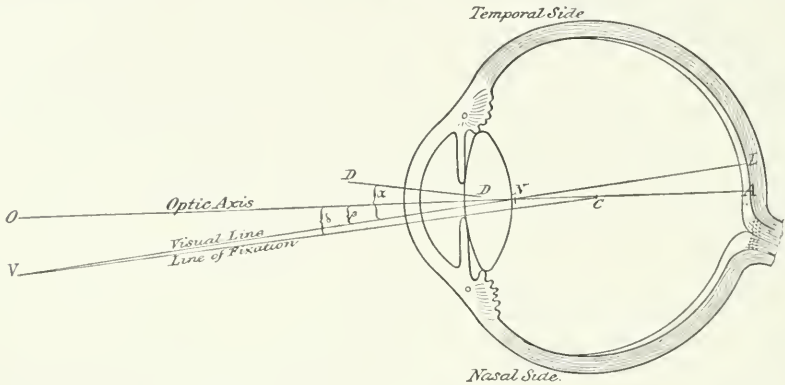


FIG. 55.—Diagram showing the corneal axis  $DD$ , the optic axis  $OA$ , the visual axis  $V'L$ , and the line of fixation  $V'C$ ; also the three angles  $\alpha$ ,  $\beta$ ,  $\gamma$ .

The angle included between the line  $DD$  (the major axis of the corneal ellipse) and the visual line is the *angle alpha*, amounting, on the average, to about  $5^\circ$ . The angle included between the optic axis and the line of regard is known as the *angle gamma*, while the angle between the optic axis and the line of vision is known as the *angle beta* (see also page 129).

**Functions of the Iris.**—The iris, in virtue of the capability it possesses of alternately enlarging and diminishing the size of its central opening, the *pupil*, forms in several respects an important corrective apparatus of the eye. It serves as a diaphragm by which the rays of light which would otherwise pass through the margin of the lens are cut off, so that *spherical aberration* is in a great measure overcome. It also serves, through the contraction of its muscular fibers, to form a fixed point of support for the ciliary muscle during the period of active accommodation. Owing to the fact that the circular fibers of the iris alternately contract and relax with increasing and decreasing intensities of light, it serves to regulate the amount of light entering the eye necessary for distinct vision. In the absence of light the *sphincter pupillæ* relaxes and the pupil enlarges. As the light increases in intensity the muscle contracts and the pupil becomes smaller. The contraction of the sphincter muscle is with a given intensity of light greater when the light falls directly into the fovea. Contraction of this muscle also occurs as an associated movement in the act of convergence of the optic axes in accommodative efforts and in consensus with the other eye.

The movements of the iris by which the size of the pupil is determined from moment to moment are caused by the contractions of the *sphincter pupillæ* and *dilatator pupillæ* muscles. The contraction of the sphincter is entirely reflex and involves for its action the parts necessary to the performance of any reflex act—viz. a sentient surface, the retina; an afferent nerve, the optic; a central center situated in the gray matter of the aqueduct of

Sylvius; and an efferent nerve, the motor oculi. The stimulus requisite for the calling forth of a contraction is the impact of ether-vibrations on the ends of the rods and cones. According to the intensity of the light or ether-vibrations will be the energy of the contraction. The contraction of the *dilatator pupillæ* is determined by the activity of a continuously active nerve-center situated in the medulla oblongata, which transmits its regulative nerve-impulses to the iris through fibers in the sympathetic.

The exact course of these fibers, however, in man is not satisfactorily determined. From their origin they pass successively through the cervical cord, the anterior roots of the first and second dorsal nerves, the upper thoracic ganglion, the cervical sympathetic, the upper cervical ganglion through fibers to the ophthalmic division of the fifth nerve, the nasal nerve, and long ciliary nerve to the iris.

As to the action of the two sets of muscles, they appear to bear an antagonistic relation to each other, for section of the motor oculi is followed by relaxation of the circular fibers and dilatation of the pupil. Stimulation of the sympathetic in the neck is followed by a much larger dilatation of the pupil. The normal physiological stimulus to the dilator center is probably dyspneic blood, though it is excited by muscular activity and stimulation of various sensory nerves.

**Functions of the Retina.**—Of all the layers of the retina, the rods and cones appear to be the most essential to vision. It is only this layer which is capable of receiving the light-stimulus and of transforming it into some specific form of energy, which in turn arouses in the fibers of the optic nerve the characteristic nerve-impulses. The nerve-fibers themselves are insensible to the impact of the ether-vibrations, and require for their excitation some intermediate form of energy. That this is the case was shown by Donders, who reflected a beam of light on the optic nerve at its entrance without the individual experiencing any sensation of light. This region, occupied only by the optic-nerve fibers and devoid of any special retinal elements, is therefore an insensitive or blind spot. The diameter of this spot is about 1.5 mm., and occupies in the field of vision a space of about 6°. It is situated about 3.5 mm. to the nasal side of the visual axis. Its existence can be demonstrated by the familiar experiment of Mariotte—*e. g.* if the right eye be directed to the cross in the following figure (56) and the



FIG. 56.—To demonstrate the blind spot.

left eye closed, and the paper be held at a distance of 10 inches, the circle will entirely disappear. This occurs when the image falls on the optic nerve at its entrance. (See also page 470.) The experiment of Purkinje demonstrates the same fact.

It is well known that the blood-vessels of the retina are situated in its innermost layers a short distance behind the optic-nerve fibers. Owing to this anatomical arrangement, a portion of the light coming through the pupil will be intercepted by the vessels and a shadow projected on the layer of rods and cones. Ordinarily, these shadows are not perceived, for the reason



that the shaded parts are more sensitive and their excitability less readily exhausted, and perhaps because the mind has learned to disregard them. But if light be made to enter the eye obliquely, the position of the shadows will be changed, when at once they become apparent. This can be shown in the following way :

If in a darkened room a lighted candle be held several inches to the side and to the front of the eye, and then moved up and down, there will be perceived, apparently in the field of vision, an arborescent figure corresponding to the retinal blood-vessels. This is due to the falling of the shadows on unusual portions of the layer of rods and cones (see also page 141).

**Excitability of the Retina.**—The retina is not equally excitable in all parts of its extent. The maximum degree of sensibility is found in the macula lutea, and especially in its central portion, the fovea. In this region the layers of the retina almost entirely disappear, the layer of rods and cones only remaining, and in the fovea only the latter are present. That this area is the point of most distinct vision is shown by the observation that when the eye is directed to any given point of light, its image always falls in the fovea. Any pathological change in the fovea is attended by marked indistinctness of vision. The sensibility of the retina gradually but irregularly diminishes from the macula toward the periphery. This diminution in sensibility holds true for monochromatic as well as white light.

As stated above, the nature of the molecular processes which take place in the retinal tissue, and which are caused on one hand by the light-vibrations, and on the other hand develop nerve-impulses, is entirely unknown. The discovery of the *visual purple* in the outer segment of the rods gave promise of some explanation of the process, especially when it was shown to undergo changes when exposed to the action of light. Kühne even succeeded in obtaining an *optogram*, or a fixed image, of an external object in a manner similar to that by which an image is fixed on the sensitive plate of a camera. But as the pigment is wanting in the cones, and especially in the fovea, it cannot be considered essential to distinct vision, although that it plays some important rôle in the visual process is highly probable. The visual purple disappears when the eye is exposed to light, but is restored when light is excluded. It has also been observed that under the influence of light-stimulation the cones become shorter, and in the darkness again become longer (see page 69).

**Color-perception.**—A beam of sunlight passed through a glass prism is decomposed into a series of colors—red, orange, yellow, green, blue, indigo, and violet—the so-called *spectral colors*, so well exemplified in the rainbow. The spectral colors are termed *simple colors*, because they cannot be any further decomposed by a prism. Objectively, the spectral colors consist of very rapid transverse vibrations of the ether, from about 400 millions of millions per second for red to about 760 millions of millions for violet, but subjectively they are sensations caused by the impact of the ether-waves on the percipient layer of the retina.

It is possible to mix or blend these spectral color-sensations in the eye by stimulating the same area of the retina by different spectral colors, either at the same time or in rapid succession. The following table shows the results of such experiments as performed by v. Helmholtz (Dk. = dark ; Wh. = whitish).

|              | Violet.    | Indigo.    | Cyan-blue. | Bluish-green. | Green.     | Greenish-yellow. | Yellow. |
|--------------|------------|------------|------------|---------------|------------|------------------|---------|
| Red          | Purple     | Dk.-rose   | Wh.-rose   | White         | Wh.-yellow | Gold-yellow      | Orange  |
| Orange       | Dk.-rose   | Wh.-rose   | White      | Wh.-yellow    | Yellow     | Yellow           | ..      |
| Yellow       | Wh.-rose   | White      | Wh.-green  | Wh.-yellow    | Gr.-yellow | ..               | ..      |
| Gr.-yellow   | White      | Wh.-green  | Wh.-green  | Green         | ..         | ..               | ..      |
| Green        | White-blue | Water-blue | Bl.-green  | ..            | ..         | ..               | ..      |
| Bluish-green | Water-blue | Water-blue | ..         | ..            | ..         | ..               | ..      |
| Cyan-blue    | Indigo     | ..         | ..         | ..            | ..         | ..               | ..      |

These are the *mixed colors*. But it is to be observed that only two new color-sensations can be produced, white and purple, the remaining mixed colors already finding their equivalent in the spectrum. White and purple, therefore, are color-sensations, which have no objective equivalent in a simple number of ether-vibrations like the spectral colors.

Two spectral colors which by their mixture produce the sensation of white are called *complementary colors*. Such are red and green-blue, golden yellow and blue, green and purple. The mixture of all the spectral colors produces white again. This is the result of adding two or more *color-sensations*. Different results are obtained, however, by adding colored *pigments*. Yellow and blue, for example, produce in the eye white, but on the painter's palette green. For the explanation of such facts reference must be made to larger treatises. The colors of nature are usually mixtures of simple colors, as can be shown by spectroscopic analysis or by a synthesis of spectral colors.

In all color-sensations we must distinguish three primary qualities: (1) hue; (2) purity or tint; (3) brightness or luminosity. The first quality gives the main name to the color—*e. g.* red or blue—this depending on the spectral color or the mixture of two spectral colors with which it can be matched. The second quality, the tint, depends on the admixture of white to the ground color; and the third quality, brightness, depends on the objective intensity of the light and the subjective sensitiveness of the retina. Color-perception thus far refers only to the most sensitive part of the retina. At the more peripheral parts of the retina the colors are seen somewhat differently, as is shown by the following table giving the limits up to which the colors are recognized:<sup>1</sup>

|                      |        |       |      |        |
|----------------------|--------|-------|------|--------|
|                      | White. | Blue. | Red. | Green. |
| Externally . . . . . | 90°    | 80°   | 65°  | 70°    |
| Internally . . . . . | 60°    | 55°   | 50°  | 40°    |
| Superiorly . . . . . | 45°    | 40°   | 35°  | 30°    |
| Inferiorly . . . . . | 70°    | 60°   | 45°  | 35°    |

**Theories of Color-perception.**—The *theory of v. Helmholtz*, originated by Thomas Young (1807), assumes in its latest form the existence in the human retina of three different kinds of end organs, each of which is loaded with its own photo-chemical substance capable of being decomposed by a certain color, and thus exciting the fiber of the optic nerve.

In the first group these end organs are loaded with a red-sensitive substance, which is affected mainly by the red part of the spectrum; the second group has its end organs provided with a green-sensitive substance, which is mainly excited by the green color; while the third group is provided with a blue-sensitive substance, this latter being mainly affected and decomposed by the blue-violet portion of the spectrum. All these three different end organs are present in every part of the most sensitive area of the retina, and are connected by separate nerve-fibers with special parts of the brain, in the cells of which each calls up its separate sensation of red or green or blue.

<sup>1</sup> For further discussion of this subject see page 167.

Out of these three primary color-sensations all other color-sensations arise. If a light mainly excites the red- or green- or blue-sensitive substance of a retinal area, we term it red, green, or blue, respectively. But if two of these photo-chemical substances are stimulated simultaneously, quite different sensations arise. Thus simultaneous stimulation of the red and green substances gives rise to the sensation of yellow, that of red and blue to the sensation of purple, and that of blue and green to the sensation of blue-green. Simultaneous stimulation of all three substances of a certain area produces the sensation of white. According to this theory, complementary colors are all those which together excite all the three substances. *Color-blindness* is explained by this theory, on the assumption that two of the photo-chemical substances have become similar or equal in composition to each other.

The *theory of Hering*, brought forward in 1874, has the underlying assumption that the process of restitution in a nerve-element is capable of exciting a sensation. This theory asserts that there are three visual substances in the retina—a white-black, a red-green, and a yellow-blue visual substance. A destructive process in the white-black substance, such as is induced not only by white light, but also by any other simple or mixed color, produces the sensation of white, while the process of restitution or assimilation in this substance produces the sensation of black. Similarly, red light produces disassimilation or decomposition in the red-green substance, and this, again, the sensation of red. Green light, however, favors the process of restitution or assimilation in the red-green substances, and thus gives rise to the sensation of green. In the same way the sensation of yellow has its cause in the decomposition of the yellow-blue substance induced by yellow light, while the sensation of blue is produced by an assimilative process in the same substance. Simultaneous processes of disassimilation and assimilation in the same visual substance antagonize each other, and consequently produce no color-sensation by means of this substance, but only the sensation of white, by reason of decomposition, by both colors, in the white-black substance. Thus, yellow and blue, impinging on the same retinal area, have no effect on the yellow-blue substance, because they are antagonistic in their action on this substance, but only produce the sensation of white, as both yellow and blue decompose the white-black material. *Color-blindness* is explained by the assumption of the absence of either the red-green or the yellow-blue visual substance in the retina.

**Movements of the Eyeball.**—The almost spherical eyeball lies in a correspondingly shaped cavity of the orbit, like a ball placed in a socket, and is capable of being moved to a considerable extent by the six ocular muscles which are attached to it. The movements of each eye are referred to three fixed lines or axes which have their origin at the point of rotation of the eyeball, this point lying about 1.7 mm. behind the center of the globe. If the eye looks straight forward in the horizontal plane (the head being erect), the line joining the center of rotation with the object looked at is the *visual line* or *visual axis*. Around this antero-posterior axis the eye may be regarded as performing its circular *rotation* or *torsion*. At right angles to this line, and joining the center of rotation of both eyes, is the *horizontal* or *transverse axis* around which the movements of elevation (up to 34°) and depression (down to 57°) take place. At right angles to both of these lines there is the *vertical axis*, around which the movements of adduction (toward the nose up to 45°) and abduction (toward the temple up to 42°) occur. The six muscles may be divided into three pairs, each of which has a common axis around which it tends to move the eyeball. But only the common axis of the internal and

external recti coincides with one of three axes before mentioned—namely, with the vertical axis—thus moving the ball only inwardly or outwardly, respectively. The other two pairs, however, have their own axes of action, and their movements of the ball must be therefore analyzed with regard to all the three axes, each of these four muscles producing rotation, elevation, and depression, and abduction or adduction. The superior and inferior recti muscles, forming one pair, move the eye around a horizontal axis which intersects the median plane of the body in front of the eyes at an angle of 63°, and the superior and inferior oblique muscles forming the third pair rotate the globe around a horizontal axis which cuts the median plane of the body behind the eyes at an angle of 39°. Thus it is that each muscle moves the eye as follows, the movement for practical purposes being referred to the cornea: The rectus externus draws the cornea simply to the temporal side, the rectus internus simply to the nose; the superior rectus displaces the cornea upward, slightly inward, and turns the upper part toward the nose (medial torsion); the inferior rectus moves the cornea downward, slightly inward, and twists the upper part away from the nose (lateral torsion); the superior oblique displaces the cornea downward, slightly outward, and produces medial torsion; while the inferior oblique moves the cornea upward, slightly outward, and produces lateral torsion. These facts show that for certain movements of the eye at least three muscles are necessary (see following table):

|                   |   |                      |  |                    |   |                    |
|-------------------|---|----------------------|--|--------------------|---|--------------------|
| <i>Inward,</i>    | . | Rectus internus.     |  | <i>Inward and</i>  | { | Rectus internus.   |
| <i>Outward,</i>   | . | Rectus externus.     |  | <i>downward,</i>   | { | Rectus inferior.   |
| <i>Upward,</i>    | . | { Rectus superior.   |  |                    | { | Obliquus superior. |
|                   |   | { Obliquus inferior. |  | <i>Outward and</i> | { | Rectus externus.   |
| <i>Downward,</i>  | . | { Rectus inferior.   |  | <i>upward,</i>     | { | Rectus superior.   |
|                   |   | { Obliquus superior. |  |                    | { | Obliquus inferior. |
| <i>Inward and</i> |   | { Rectus internus.   |  | <i>outward and</i> | { | Rectus externus.   |
| <i>upward,</i>    | . | { Rectus superior.   |  | <i>downward,</i>   | { | Rectus inferior.   |
|                   |   | { Obliquus inferior. |  |                    | { | Obliquus superior. |

If both eyes have their line of vision in the horizontal plane parallel with each other and with the median plane of the body, they are said to be in the *primary position*. All other positions are called *secondary*. Both eyes always move simultaneously, which is called the *associated movement of the eyes*. There are three forms of associated movements: (1) movement of both eyes in the same direction; (2) movements of convergence by which the visual lines are converged on a point in the middle line of the body; (3) movements of divergence, by which the eyes are brought back from convergence to parallelism, or even to divergence, as in certain stereoscopic exercises. A combination of (1) and (2) or of (1) and (3) takes place for certain positions of the object looked at.<sup>1</sup>

<sup>1</sup> For further and similar consideration of the physiological action of the ocular muscles see pages 41, 42, 497, and 498.



# GENERAL OPTICAL PRINCIPLES:

## KATOPTRICS, DIOPTRICS, PHYSIOLOGICAL OPTICS.

BY WILLIAM S. DENNETT, M. D., AND COLMAN WARD CUTLER, M. D.,  
OF NEW YORK CITY.

**Light** from its source spreads from center to circumference—not as the arrow flies, but as the wave passes. The continually repeated cycle at the origin is imitated in all its essentials at each surrounding particle, which, being thus made luminous, transmits in turn what it has received to others next removed.

This is not the place to discuss at length the wave theory of light, but let it be remembered that the image on the retina is the result of purely mechanical processes into which the time element necessarily enters. Whatever the nature of the cycle at the origin, it has to do with a mass of matter controlled by elastic forces, hence its period is constant. The conditions at half-cycle periods are such as may be represented by algebraic equals and opposites, compounding into zero if both are impressed on the same body at the same time.

The passage of light through space is the transference of motion from one body to another, or to many others whose reactions bring or tend to bring the first to rest, and which are brought to rest in turn by those on whom they act.

The time element in this process of light propagation is also determined strictly in accordance with mechanical laws, and hence the spherical shell of a wave-surface is deformed or distorted by any change in the density or structure of the medium through which it passes.

At the outset, in a homogeneous medium, the wave-surfaces are spherical, and the light received by any body to which the wave has reached is measured by the area of wave-surface which it intercepts. This means that the body is, as it were, a buffer to the moving masses of which the medium is composed.

If the recipient is at an equal distance from two such sources of light whose phases and cycles are similar, it will of course receive twice the light that it would from one. Now, the whole theory of transmission by waves implies that every separate point of a wave-front is itself, while the wave is passing, nothing other than an instantaneous source of light, and may be treated as such, and that the results traceable to any one luminous element (Fig. 57, *l*) are the same as may be obtained by the summation of results

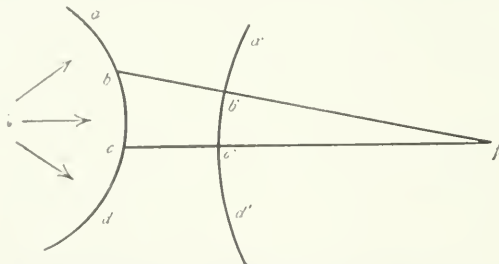


FIG. 57.—To illustrate the fact that when the center of a wave-surface is behind the wave, it is a radiant; when in front of the wave, it is a focus.

due to similar conditions as they exist at some later period in every separate element, *a*, *b*, *c*, *d*, etc., along the whole wave-surface. Thus it happens that any point, *p*, equally distant from the points, *b* and *c*, receives double the amount of light or energy from both these points that it does from either.

A change in the form of the wave-front so that, as at  $a'$ ,  $d'$ , it curves in a circle about the point  $p$  toward which it is advancing, makes that point the recipient of all the energy which was distributed along its arc.

*Image-forming optical instruments* are devices by which each light-wave that comes from one of a configuration of points, *the object*, is made to curve around the corresponding one of another configuration of points, *the image*.

Fig. 58 delineates this process in its simplicity, where a lens is made of such medium as will delay by its density the progress of the wave, and is so shaped that it will give

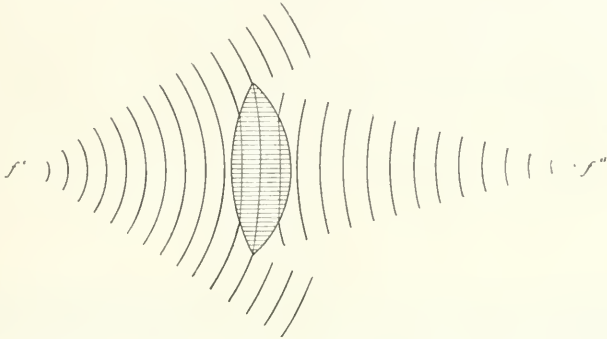


FIG. 58.—Showing the physical relation of a lens to its conjugate foci:  $f'$ , radiant;  $f''$ , focus conjugate to  $f'$ .

to the wave-front a circular section. The ray, as indicative of the direction toward which the wave at any point is moving, is identical with the radius of the curved wave-surface at that point, and the radius of a circle measures its straightness of arc, just as the reciprocal of the radius measures its curvature.

Thus it will be seen that the study of the propagation and distribution of light is very much, at bottom, the study of curves, and, as curves are determined by the properties of their normals or radii, it is possible for *Geometrical Optics* to be cultivated as a degenerate form of *Physical Optics*, dealing principally with the positions of points and the lengths of line-segments.

The accessibility of certain truths when sought by geometrical methods, and the accessibility of the methods themselves as instruments of research, are their all-sufficient but not their only recommendation. In the pages that follow only occasional reference will be made to the physical aspects of the case, but attention is here invited to the fact that not only as a figure of speech, but in the accurate mathematical sense, *rarity* is the reciprocal of *density*, *straightness of curvature*, and *slowness of velocity*. From these hints it will be found that the formulae used in the study of refracting and reflecting surfaces and centered lens-systems give abundant evidence of their physical origin, and a recognition of this relationship will be an easy and legitimate mnemonic device.

Thus in Equation 13, page 108, one may read each term as the value in diopters of a lens or a pencil. One recognizes the  $f$ 's as typical of focal distances, and the  $r$  as a radius, but  $f'$  and  $f''$  are also radii, and their magnitudes measure the flatness of the incident and refracted waves;  $\frac{1}{f}$  is the curvature of a wave-surface, and  $\mu''$  is the coefficient of slowness for wave-travel in the medium thus indexed, while  $\mu'' - \mu'$  is the lag of the wave as it passes from one medium to another; and so on until the whole physical theory is read from the necessary geometrical relations.

**Refraction and Reflection.**—With *Snell's law* for a stepping-stone we now pass to the geometrical consideration of *refraction* and *reflection*. This

law for nearly a hundred years was the expression merely of the results of experience in the observation of refracted light. It is now generalized and applied to both reflection and refraction. Its consistency with the *wave theory of light* may be seen as follows:

When a wave-surface whose section may be represented by  $ab$  (Fig. 59) passes through  $d$ , the surface separating one medium from another in which

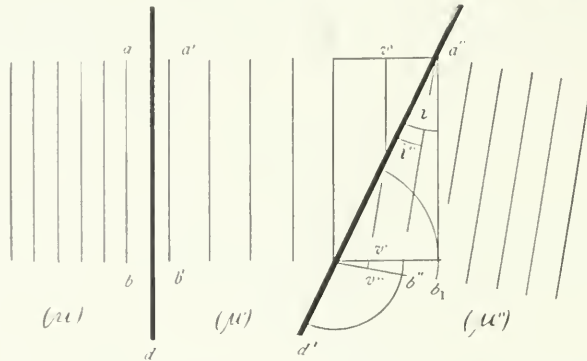


FIG. 59.—Showing that a wave-surface is not changed in its direction by passing through ( $d$ ) an optical surface parallel to it, however the character of the medium may change at that surface, but that when the optical surface ( $d'$ ) is inclined to the wave-surface, the latter must experience a change in its direction dependent on its change of velocity in passing from one medium into the other.

for any reason whatever light makes its way at a different rate of speed, if the wave-surface immediately before its passage is parallel to the surface separating the two media, it will be parallel to it immediately after its passage, because at no time have the circumstances governing its speed differed along the whole line of the wave-front, the change having taken place everywhere at the same instant. The length of section is immaterial so that it be straight. Its straightness as a measurable quantity is the arc divided by the radius, so whatever the curve for a section *as small as you please*, the above statement is practically true, neither end of the wave gains on the other and it continues to advance in a straight line.

If the wave enters a retarding medium whose surface,  $d'$ , is not parallel to its own, instead of making its way as it otherwise would to the position  $a'', b_1$ , the spread of the light-disturbance from particle to particle has covered, say, a smaller area in the new medium than in the old, and the limit of its advance is along the common tangent of the circles whose radii are proportional to the time since they began to form in the new medium. Since the line  $r'$  represents the velocity of propagation in the medium  $\mu'$  and  $r''$  in the medium  $\mu''$ , the desired relations are easily established. Each is perpendicular to its wave front and is consequently a *radius* or *ray*;  $a'', b_1$  shows the place to which the wave would have advanced had the character of the medium not changed at  $d'$ , and  $a'', b''$  shows the place to which it really has advanced during the same interval of time. Each forms the side of a right-angled triangle whose hypotenuse is the separating surface, and whose respective bases are corresponding sections of wave-surface, and form with the surface of separation the angles  $i'$  and  $i''$ . One of these angles is the *angle of incidence*; the other is the *angle of refraction*. Hence the sine of the angle of incidence is to the sine of the angle of refraction as the velocity at incidence is to the velocity after refraction, or, as usually stated,

$$\frac{\sin i'}{\sin i''} = \frac{v'}{v''} \tag{1}$$

In practice it is easy to locate the centers from which the waves come and to which they go, and easy to locate the center of the optical surface; connecting these centers,  $p'$ ,  $p''$ , or  $p'''$  and  $n$  with the point of incidence  $a$  (Fig. 60), gives us the three radii, each of course perpendicular to the surface to which it belongs, and consequently mutually inclined to each other as are those surfaces.

Through the relations of these radii the law was discovered, through them it is most easily proved, and through them it is most frequently stated, angles of incidence, reflection, and refraction being defined as angles made by the incident, reflected, or refracted ray (perpendicular) with the radius of the optical surface.

The ability to transfer the attention from surfaces to rays, and to replace velocities by their reciprocals, is a great geometrical advantage, though it gives a show of artificiality to the whole theory of optical instruments as far as we have occasion to pursue it.

If  $\mu$ , however accented, is taken to represent  $\frac{1}{v}$ , Equation 1 may be written

$$\sin i'\mu' = \sin i''\mu'', \quad (2)$$

and Equation 2 is **Snell's law**.

As here used,  $\mu'$ ,  $\mu''$ , etc. represent the time needed for light to travel unit distance in the medium with which each is connected; they might be called coefficients of slowness or coefficients of sine magnitude; they are, in fact, called *indices of refraction*.

The time needed for light to spread unit distance in ether—or in air, which is very nearly the same—is the standard of measurement, and is assumed to be 1. The actual value in seconds for ether, for air, or for other media is of no special import to us here; we need only the relative magnitudes, which are known or easily obtained, and are represented by  $\mu$  appropriately accented. When  $\mu$  is equal to 1, it is often omitted from a product as a matter of brevity and convenience. In all the formulæ here used it will be written for the sake of symmetry and clearness.

With this much of physical explanation and the law of sines as the rule of the road, we may proceed to speak of *rays* and *foci* as of *pencils* and *points*, hoping that their true significance will not be forgotten, and believing that the little effort that is necessary to identify physical with geometrical relationships will more than pay for itself as a guard against error and as a mnemonic aid.

We shall use the word *refraction* in its most general sense, including refraction and reflection. If exceptions to this usage occur, they will be noted.

The first general problem that presents itself in the study of image-forming optical instruments is this: Given waves of circular section, what will be their curve in either medium after incidence on the spherical surface which separates it from another of different index?

The problem may be solved by the aid of Fig. 60, *A*, in which waves at  $a$   $h$  would converge upon the point  $p'$ , except that the optical surface changes their curvature, giving them a center at  $p''$ . In this particular case  $n$ ,  $h$ ,  $p'$ ,  $\mu'$ ,  $\mu''$  are known, and  $p''$  is sought, but the solution desired should enable us to determine the position of any one of the quantities when the others are given,  $h$  being the point where the optical surface meets the line connecting its center with that of the incident wave.



At  $h$  the incident wave and the optical surface have a common tangent, and there is no change in the direction of the wave or of its radius; consequently, the center of the two waves will be on a line with the center of the optical surface. At any other point of incidence the law of sines applied to the two known radii will indicate the third, and its cross with the axis at  $p''$  will be approximately the center of wave curvature. The solution is as follows:

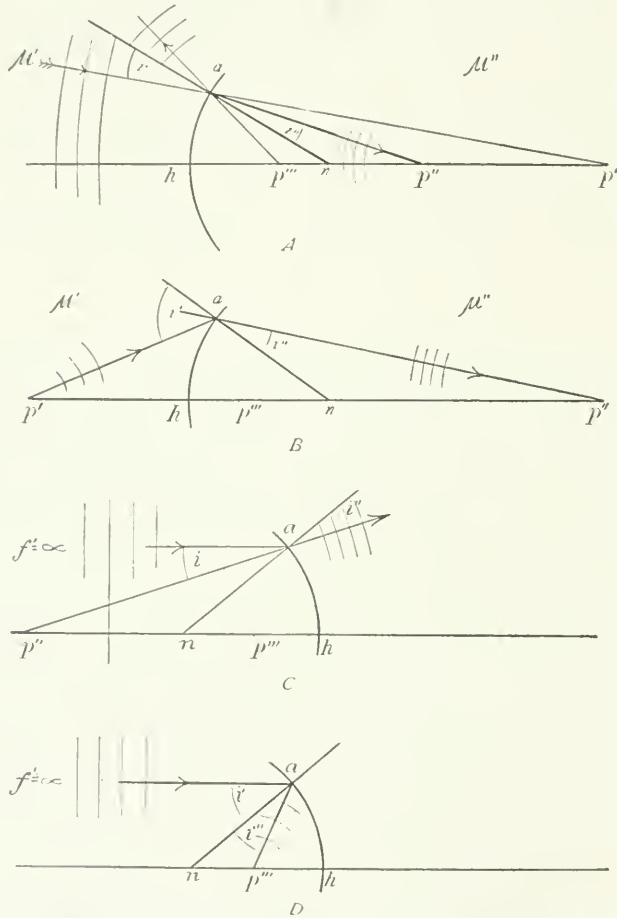


FIG. 60.—Typical cases of refraction and reflection, showing the relative positions as expressed by Snell's law to be the same for rays and normals as for the surfaces to which they belong. At  $h$  the waves are parallel to the optical surface;  $a$  is any point common to optical and wave-surfaces;  $p'$  is the center of the incident wave,  $p''$  of the refracted, and  $p'''$  of the reflected wave. The values of radii, curvatures, and focal distances are ordinarily considered positive when the centers to which they appertain lie to the right of  $h$ ; in (A) they are all positive.

For the convenience of a one-letter notation draw Fig. 61 identical with Fig. 60, but represent the radius of the refracting surface by  $r$ , the distance of any point  $p$  from the center of the refracting surface by  $g$  appropriately accented, the distance of any point  $p$  from  $a$  by  $c$ , also appropriately accented, and distances from  $h$  by  $f$ . Then in Fig. 61 will be seen one triangle whose sides are  $r$ ,  $c'$ , and  $g'$ , and whose vertex measures the angle of incidence, and another triangle whose sides are  $r$ ,  $c''$ , and  $g''$ , and whose vertex is the angle of refraction. The angle between  $r$  and  $g$  may be called  $\delta$ .

From the well-known property of triangles come these two equations :

$$\frac{\sin i'}{\sin \delta} = \frac{g'}{e'} \quad (3)$$

$$\frac{\sin i''}{\sin \delta} = \frac{g''}{e''} \quad (4)$$

Dividing 3 by 4 to eliminate  $\delta$ ,

$$\frac{\sin i'}{\sin i''} = \frac{g' e''}{e' g''} \quad (5)$$

By Snell's law, Eq. 2,

$$\frac{\sin i'}{\sin i''} = \frac{\mu''}{\mu'} \quad (6)$$

Therefore,

$$\frac{\mu''}{\mu'} = \frac{g' e''}{g'' e'} \quad \text{or} \quad \mu'' g'' e' = \mu' g' e'' \quad (7)$$

It should be noticed here that when the point  $a$  (Fig. 61) is placed very near to  $h$  the pole of the optical surface,  $e$  is nearly equal in value to  $f$ , and at the limit, when  $a$  and  $h$  become identical, any  $e$  is exactly equal to the corresponding  $f$ . The value of  $f$  at the instant when  $a$  and  $h$  coincide is the value that gives accurately the curvature of the wave at  $h$ . If the wave is circular in section,  $p''$  determined for one point on its surface is determined for all. When the refracted wave has not a circular section, it is usual in practice either to shut

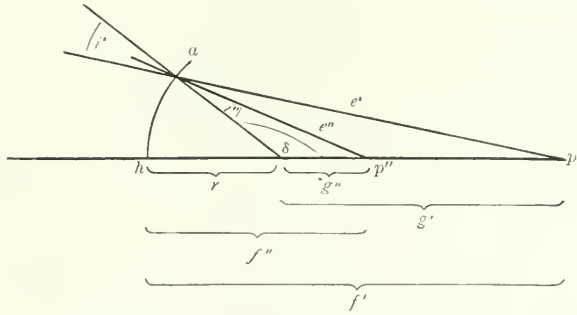


FIG. 61.—A one-letter notation for case (A) Fig. 60.

off that portion of its surface which departs appreciably from a uniform curve, and assumes that all the rays cross at the limiting position of  $p''$ , or to name for the focal point that position of  $p''$  which is nearest to the greatest number of rays at once. Some information may be obtained concerning the curve of the wave by substituting for  $e'$  and  $e''$  in Eq. 8 the value which each possesses by virtue of its being opposite to the angle  $\delta$  in the triangle to which it belongs; thus :

$$e'^2 = g'^2 + r^2 - 2g'r \cos \delta. \quad (8)$$

$$e''^2 = g''^2 + r^2 - 2g''r \cos \delta. \quad (9)$$

Squaring 7 and substituting the value  $e$  from 9,

$$\mu''^2 g''^2 (g'^2 + r^2 - 2g'r \cos \delta) = \mu'^2 g'^2 (g''^2 + r^2 - 2g''r \cos \delta). \quad (10)$$

It is not necessary to ask here the full significance of this formula, but only to remark that when  $g'$  is equal to  $\left(\frac{\mu''}{\mu'}\right)^2 g''$ ,  $\delta$  disappears from the equation, and consequently the refracted wave has a circular section. One such position may be found for  $p'$  on either side of  $r$ . The distance from any position of  $p''$  to the limiting position when  $a h = 0$  is the aberration for the

angle  $\delta$  (longitudinal spherical aberration), and there is no aberration for such values of  $g'$  or  $g''$  as cause  $\delta$  to disappear.

As will be readily appreciated, any irregularity in the curvature of the refracted wave interferes with the point-to-point correspondence of the image to its object. The optical surfaces of most instruments are spherical, and many circumstances conspire to limit our use of these surfaces to that part which is so near the axis as to be practically without aberration, or to have only so much aberration as may be ignored or eliminated by compensatory errors; so in all first approximations  $p''$  in its limiting position is taken as the focus conjugate to  $p'$ ; and since the  $c$ 's and the  $f$ 's are in this position identical, Eq. 7 may be written thus:

$$\frac{\mu'' - g'f''}{\mu' - g'f'} \quad \text{or} \quad \frac{\mu''}{\mu'} = \frac{f''}{f'} \pm \frac{g''}{g'}. \quad (11)$$

Designating these segments by their terminal points, as in Fig. 60, the nature of the relation sought becomes apparent:

$$\frac{\mu''}{\mu'} = \frac{hp'}{p'n} \pm \frac{hp''}{p''n}. \quad (12)$$

In ( $h n p'p''$ ) we have an anharmonic range in which the two foci are conjugate to the center and the pole of the optical surface, and the cross ratio is the ratio of wave velocity in the two media. It is worth while to study into this a little if necessary, for, besides furnishing the easiest possible method of remembering the relations of the foci to their surface, it shows that the relations are reciprocal, and that the two foci, being given a surface of any curve, may be placed, or a curve corresponding to any place may be determined in precisely the same way.

Any combination of lenses and mirrors may be replaced by an equivalent surface: this is of very general utility, and, moreover, in the theory of thin pencils the circle of least confusion is located between the first and second focus of the pencil by the harmonic variety of this relation, the ratio being, as in the case of the mirror, equal to  $-1$ . (See p. 127.)

Again, when  $g$  in Eq. 11 is replaced by its equal ( $f-r$ ), we have the following:

$$\frac{\mu''}{\mu'} = \frac{(f'-r)f''}{f''-rf'}, \quad \text{which, when reduced, as it easily}$$

can be, gives the most important formula in this part of the book:

$$\boxed{\frac{\mu''}{f''} - \frac{\mu'}{f'} = \frac{\mu'' - \mu'}{r}}. \quad (13)$$

In as brief a treatise on geometrical optics as this must be, Eq. 13 may be considered an epitome of all that has gone before and a key to all that follows. It should be committed to memory and associated with Fig. 60, *A*, until each is a "word-sign" for the other. It should never be written in any other form until it has become so familiar to the eye that from any side an error of transcription would be discovered at a glance. It is general in its application for the focal distances of axial pencils for a surface of any circular curvature, plus or minus, between any media of whatever index. It might just as well have been deduced from any of the special cases pictured in Fig. 60, and the preceding applies and may be read equally well in connection with any one of these cases.  $p'''$  is used in this figure to indicate the position which  $p''$  assumes when  $\mu'' = -\mu'$ ; that is, in all cases of reflection. Fig. 60, *A*, was chosen as the type by which all may be classed and remembered, because in it all the curvatures, all the focal distances, and other magnitudes are positive quantities; and if Eq. 13 is remembered as belonging to the case where all the quantities are plus, no confusion need arise

in interpreting apparent anomalies of sign when a numerical equation of this form presents itself.

The discussion of Eq. 13 is much more simple than its derivation. If the optical surface is a plane,  $r$  becomes infinite and the last member vanishes, and consequently  $\frac{\mu''}{f''} = \frac{\mu'}{f'}$  or  $\frac{\mu'}{\mu''} = \frac{f''}{f'}$  which must be construed to mean that the conjugate foci of a plane refracting surface are on the same side of the surface and at distances whose ratio is the same as the indices for the two media. If any value represented by  $f'$ ,  $f''$ , or  $r$  has a minus sign, it of course represents a distance to the left of  $h$ . If  $f'$  or  $f''$  represents an infinite value, the inference is that the wave surface is perfectly flat, that the rays are parallel.

Only in one case can  $\mu'$  and  $\mu''$  be replaced by quantities having different signs. That  $\mu'$  should equal  $-\mu''$  would indicate a position of the wave that physical conditions can only account for by the supposition that it is a reflected wave—that is, turned back into the medium whence it came—and consequently travelling with the same velocity as before. Therefore the numerical value of  $\mu''$  must be the same as  $\mu'$ . And it can be stated in this connection that when the indices differ in sign their numerical values do not differ, and  $\left(\frac{\mu'}{\mu''}\right) = -1$ . This only happens in cases of reflection.

It is not only unnecessary, but it is confusing, to make any distinction between problems of reflection and refraction other than what is indicated by the signs of the refractive indices.

The simplicity and generality of the conditions is such that the laws, the methods, the formulæ, and their interpretations are the same for katoptrics as for dioptrics.

**Katoptrics** is that part of the science of optics that deals with the phenomena of reflection, especially from regular surfaces like mirrors.

**Dioptrics** treats of the phenomena of refraction, and with the definitions we dismiss the distinction, except in such degree as it is shown by the signs of the indices. Eq. 13 is the open sesame to all of Optics that we require. When the quantities that are represented by  $\mu'$  and  $\mu''$  are of unlike sign, they are equal and we are dealing with reflection. All other cases are refractive.

The inverse situation is covered by the rule which tells us to treat all mirrors as optical surfaces between media whose indices are 1 and  $-1$ .

**Cardinal Points**, four in number, may be named in connection with a single optical surface (Fig. 62). They are  $n$ , the center of the surface,  $h$ , the

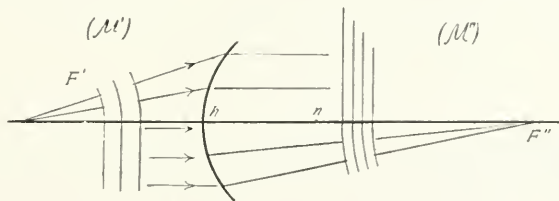


FIG. 62.—Above, the first principal focus is a radiant, and rays become parallel in  $(\mu'')$ . Below, rays parallel in  $(\mu')$  converge in  $(\mu'')$  to the second principal focus.

*principal point,  $F'$ , the first principal focus, and  $F''$ , the second principal focus.*

**The Center.**—Since concentric circles are parallel, the wave whose center of curvature before incidence is  $n$  will have  $n$  for a center after incidence—*i. e.* the ray that passes through  $n$  is unrefracted.

It will be seen hereafter that the relative size of object and image is the ratio of their respective distances from  $n$ ; that they approach  $n$  together; that each is inverted in passing through  $n$ ; and that when they meet at  $n$  the size of one, in terms of the other, is numerically equal to the ratio of the velocities of the light waves by which



the respective images are formed. It will be seen also that the center  $n$  is to the optical surface what the two nodal points  $n'$  and  $n''$  are to the lens or the optical system.

The principal point  $h$  is the point where the optical surface is pierced by the line connecting its center with the radiant.

Object and image approach  $h$  together. At  $h$  they are equal and congruent (see page 112), and to  $h$  of the optical surface correspond the two principal points,  $h'$  and  $h''$ , of the system.

The principal foci,  $F'$  and  $F''$ , are the same for the surface as for the system.

The first principal focus,  $F'$ , is the center of those waves which after incidence become plane. In other words,  $F'$  is the cross of rays that are made parallel by incidence on the optical surface.

The second principal focus is the center of those waves that before incidence on the surface were parallel; or it may be stated thus: Rays previously parallel cross after incidence at the last principal focus.

These foci are found by giving to the variables of Eq. 13 such values as will impose the required conditions.

To find  $F'$ , substitute  $\infty$  for  $f''$  in Eq. 13 and solve for  $f'$ . This is because the center of a plane wave or the focus of a parallel pencil is at infinity. If  $f'' = \infty$ ,  $\frac{1}{f''} = 0$ , and so disappears from the expression, and we have

$$f' = -\frac{\mu' r}{\mu'' - \mu'} = F', \quad (14)$$

the necessary result of the condition imposed.

The second principal focus,  $F''$ , is found in the same way, for when  $f' = \infty$ ,  $\frac{1}{f'} = 0$ , and

$$f'' = \frac{\mu' r}{\mu'' - \mu'} = F''. \quad (15)$$

To apply this, suppose light from air is incident on a convex glass surface whose radius is one-fifth meter (.20 M). Replacing  $\mu'$  by 1, the index for air,  $\mu''$  by 1.54, the index for glass, and  $r$  by .20, Eq. 15 gives

$$F'' = \frac{1.54 \times .20}{1.54 - 1} = \frac{.308}{.54} = .57.$$

If the surface had been concave, as in Fig. 60 (C),  $r$  would have been equal to  $-.20$ , and  $F''$  would have had the same value, with a contrary sign to indicate that it was on the left of  $h$ . If the surface is to be a mirror, the same equations are used, and  $\mu'$  is put equal to  $-\mu''$ ; thus from Eq. 14:

$$F' = -\frac{\mu'' \cdot .20}{\mu'' - (-\mu'')} = \frac{\mu'' \cdot .20}{2 \mu''} = \frac{.20}{2} = .10.$$

For  $F''$  one obtains the same result, showing that the principal focus for either side of a reflecting surface is halfway between the center and the surface.

When  $F'$  and  $F''$ , the principal foci, are known, a very simple formula may be obtained for placing the conjugate of any other given focal point; thus, multiplying Eq. 13 by  $r$  and then dividing each numerator by  $\mu'' - \mu'$ , it becomes

$$\frac{\mu'' r}{f''} - \frac{\mu' r}{f'} = \mu'' - \mu' = 1.$$

Replacing each numerator by the values obtained from Eqs. 14 and 15, we have

$$\frac{F''}{f''} - \frac{F'}{f'} = 1. \quad (16)$$

Free from fractions and subtract  $F'F''$  from each side :

$$F'f' + F'f'' - f'f'' - F'F'' - F'F''$$

$$(F'' - f'')(f' - F') = -F'F''.$$

$(F'' - f'')$  is  $u''$  (Fig. 63) and  $(f' - F')$  is  $u'$ .

Changing the sign convention so that one accented quantity measures distances to the left and two accented quantities are measured toward the right,

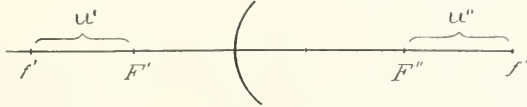

FIG. 63.—Showing the relation of conjugate foci to principal foci. Symmetrical notation about  $F'$  and  $F''$  as origius.

we get a very convenient symmetrical notation for the relation of conjugate foci to principal foci :

$$u' u'' = F' F'' \tag{17}$$

For the relation given in Eq. 16 there is a very simple graphic solution. As the line  $k$  (Fig. 64) is turned on the point  $p$  whose rectangular co-ordinates are  $F'$  and  $F''$ ,

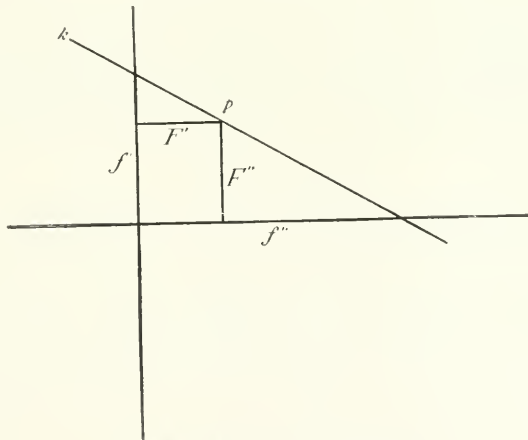


FIG. 64.—Graphic solution for Eq. 16.

the parts cut off from the axes are respectively equal to  $f'$  and  $f''$ , due regard being had to sense.

**Conjugate Images:** Object and image are corresponding configurations of points. By this is meant that to each point in one configuration there corresponds a point in the other configuration whose relation to it and to some optical surface is that by which in the preceding paragraphs  $p'$  has been connected with  $p''$ . The path of the light-wave being reversible, either configuration may in theory play the part of object to the other as image. Their distances from each other and from the cardinal points of the surface are determined by previous considerations. Their relative magnitudes are to be determined.

The magnification of an object by its image is ordinarily of two kinds, *longitudinal* and *transverse*. With the longitudinal, which may be obtained, for example, by comparing (Fig. 65)  $q' s'$  with  $q'' s''$ , we will not here concern ourselves. The following is an easy geometrical determination of the transverse dimensions of object and image: Let the line  $p' q'$  perpendicular



quadrilateral. Its fourth side will cut the axis at  $n$ , the point required. If one of the middle points of the range is sought, as  $h$ , connect the two contiguous elements with any point,  $a$ , as before. Cross the triangle thus formed by any line  $n e$ , put in the two

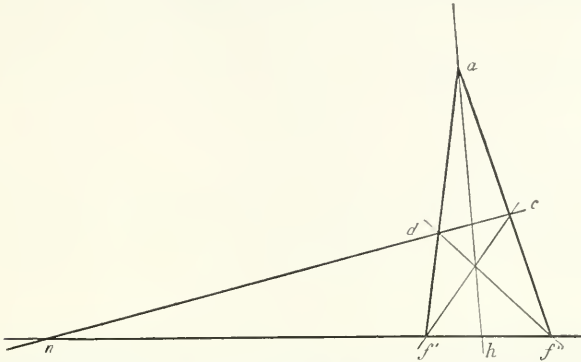


FIG. 66.—Graphic construction by which the following questions are answered: Given the surface of a mirror, what must its curvature be, or where must its center be in order to produce a picture of  $f'$  at  $f''$  or of  $f''$  at  $f'$ ? Given the center, where must the surface be? Given the mirror and the object, where will the image be? or the mirror and the image, where must the object be?

diagonals, and draw through their intersection the line  $a h$ ;  $h$  is the fourth harmonic sought.

An analogous construction serves for surface, lens, or system. Take three points,  $c, d$ , and  $e$  (Fig. 67), equally distant from the line  $a n$ , and so placed that the distances  $c d$

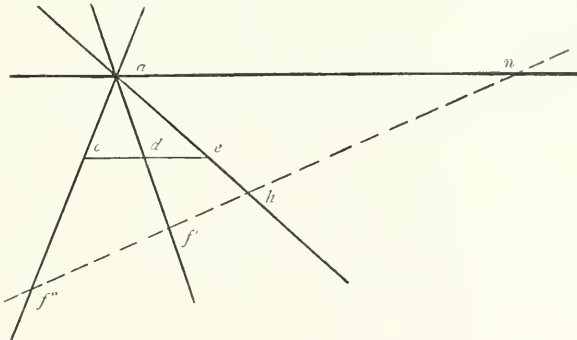


FIG. 67.—Graphic method for locating any one of the four cardinal points of an optical surface when the other three are known. Any axis may be placed across the pencil ( $a c d e n$ ), so that any three points shall fall on any three of the lines. The point sought will be on the other line. It is only necessary in the construction to make  $c d : c e = \mu' : \mu''$ , and  $c e$  parallel to  $a n$ .

and  $c e$  are proportional to the indices of the first and last media. From  $a$  through each of the other points draw a line. The axis of any optical surface may be placed across this pencil of four lines, so that three of the lines cross it at any three cardinal points. The fourth point is determined by the cross of the axis  $a$  and the fourth line. This drawing will answer too for all systems whose first and last media are in this ratio.

Before proceeding to show that other systems of more surfaces than one

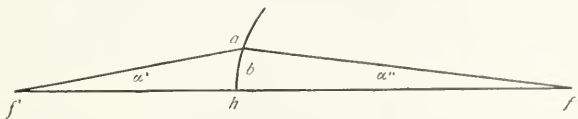


FIG. 68.— $\tan \alpha' : \tan \alpha'' = f' : f''$  (relative to "Helmholtz's formula").

may, if their centers are colinear, be treated much in the same way as single surfaces, it is necessary to prove *Helmholtz's formula* connecting the size



of each image with the inclination to the axis of any ray common to them all. Let  $f'$  or  $f''$  (Fig. 68) be the ray between two images. Assuming the figure to be made up of two right-angle triangles,

$$\frac{ah}{f'} = \tan \alpha \quad \frac{ah}{f''} = \tan \alpha'';$$

therefore,

$$\frac{\tan \alpha'}{\tan \alpha''} = \frac{f''}{f'}. \quad (20)$$

As is evident from Fig. 65,

$$\frac{g'}{g''} = \frac{j'}{j''}. \quad (21)$$

Substituting in Eq. 11 the values obtained from Eqs. 20 and 21, we have the relation sought :

$$\mu' j' \tan \alpha' = \mu'' j'' \tan \alpha''. \quad (22)$$

Here we begin the study of **centered optical systems** by calling attention to the fact that the geometrical relations of object and image are such that distinction is often unnecessary ; that an object and its  $n$  images are frequently spoken of as  $(n + 1)$  images ; and that any image may be considered object or image at convenience.

The *position* and *size* of any image may of course be determined for any number of surfaces by proceeding step by step from the object to the final image through as many refractions and reflections as are necessary to attain it. This laborious method is avoided by the localization of cardinal points, which fulfil the same function for the system as do those previously described for the single surface.

Of focal points for the system this must be said : They are measured not from the first and last surface (Fig. 69), but from two **principal points** the

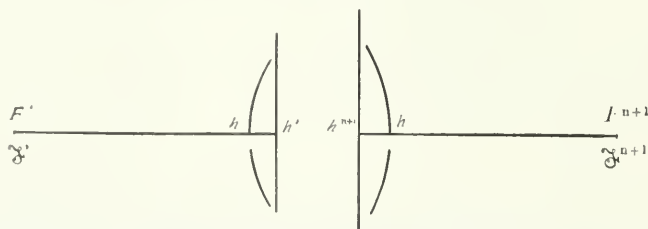


FIG. 69.—Foci of surfaces are measured from the surfaces, as  $F'$ ,  $h$ . Foci of systems are measured from the principal points of the system, as  $F''h'$ .

“*first*” and the “*last*,” whose functions are described below, and whose positions and distances from their respective surfaces are designated by  $h'$  and  $h^{n+1}$ .

The “*second*” principal point, principal focus, principal plane, nodal point, and so on, are properly so named for a single surface, but for a system of surfaces to use the ordinal adjective thus is sometimes misleading. We shall use the term *last* principal point or  $(n + 1)$ th principal point, and so on, giving it the ordinal adjective and the number of primes that corresponds to the medium to which it appertains. This is not so much an innovation as a conscientious adhesion to the spirit and method of the notation and nomenclature in detail. Something is gained if the accents on letters serve to locate the phenomena to which their existence is due. The ability to locate other cardinal points—a set, in fact, for each medium reached by waves that were parallel at incidence on the system—may not be of any special importance, but it is of advantage to have characters systematically named and accented. It enables us to read our records aright and to locate easily the processes to which the characters refer.

The removal of the origin for the estimation of focal distances accounts for the appearance of  $h'$  and  $h''$  in the denominators of Eqs. 23 and 24 (*infra*). The obscurity,

if any, vanishes when it is remembered that  $h$  and  $h'''$  as distances are, by convention, counted plus when measured into the system from the first and last surface respectively.  $F$ 's and  $\Phi$ 's, the surface foci, are measured both right or both left, each from its surface, while the  $\mathfrak{F}$ 's, the foci for the system, are measured both in the same direction as the  $F$ 's and  $\Phi$ 's. This is the reason why in Eq. 23  $F'$  has been replaced by  $(\mathfrak{F}' - h')$ , while in Eq. 24,  $\Phi'''$  has been replaced by  $(\mathfrak{F}''' - h''')$

We may now proceed to the consideration of three media separated by

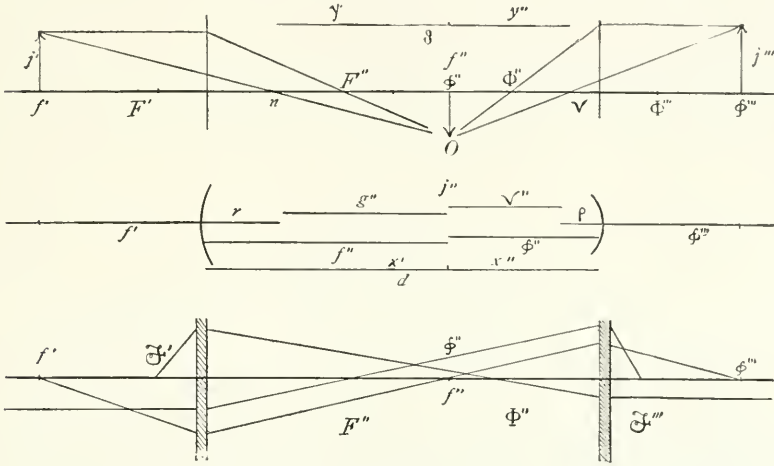


FIG. 70.—Combined systems of optical surfaces.

two surfaces. In this system are three images (Fig. 70),  $j'$ ,  $j''$ , and  $j'''$ , each corresponding to light distribution in the similarly accented medium,  $j''$  serving as image to  $j'$  by the first surface, and as object to the image  $j'''$  by the second surface.

The first principal focus of the system is the focus conjugate by the  $F$  surface (Fig. 71) to the first principal focus of the  $\Phi$  surface. Changing the

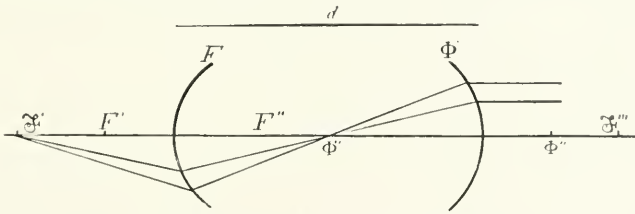


FIG. 71.—“The first principal focus of the system is the focus conjugate by the  $F$  surface to the first principal focus of the  $\phi$  surface.”

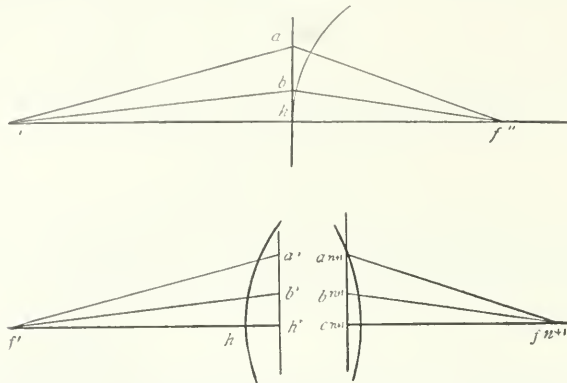
surface of reference, thus from one surface to another, demands, of course, that  $\phi$  be replaced by  $(\phi - d)$ .  $d$ , being the distance between the two surfaces  $(\mathfrak{F}' - h')$ , is obtained from Eq. 13 by the following substitution, and, being the only unknown quantity, its value is immediately forthcoming :

$$\frac{\mu'''}{\phi'' - d} - \frac{\mu''}{\mathfrak{F}' - h'} = \frac{\mu''' - \mu''}{r}. \tag{23}$$

By the same method is obtained

$$\frac{\mu'''}{\mathfrak{F}''' - h'''} - \frac{\mu''}{F'' - d} = \frac{\mu''' - \mu''}{\rho}. \tag{24}$$

**Principal Planes.**—There are definite reasons for replacing the one principal point on the pole of the single surface by the two points,  $h'$  and  $h'''$ , not necessarily on any surface. We may imagine a plane through each cardinal point perpendicular to the axis and designated by the name of the point. On the *principal plane*, which is tangent to and within required limits is coincident with the single surface (Fig. 72), the end points of incident rays



FIGS. 72 and 73.—Principal points and planes as defined for the surface and for the system.

are arranged in a configuration that is identical with the beginning points of refracted or reflected rays; and it will be remembered that conjugate images approach this plane together until their corresponding points are united each to each and the two images become identical. No such single plane can be placed in any system of optical surfaces, but two planes perpendicular to the axis may always be found such that the configuration of end points  $a' b' h'$  (Fig. 73) of incident rays on one surface is congruent with  $a^{n+1}, b^{n+1}$ , and  $c^{n+1}$ , the beginning points of reflected or refracted rays in the last or  $(n + 1)$ th medium, such also that when the first image moves toward one of these planes and disappears in it, the final image moves also toward the second plane and disappears in it. A little consideration will convince the student that if  $J$ , the *middle image* of the three index system (Fig. 74), be so placed that it as

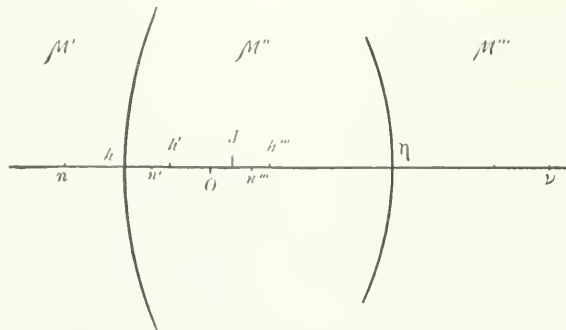


FIG. 74.—The cardinal points of a three-index system: Above,  $h$  and  $n$ , first and last surfaces;  $h'$  and  $h'''$ , first and last principal points;  $J$ , middle image. Below,  $r$  and  $r''$ , first and last centers;  $n'$  and  $n''$ , first and last nodal points;  $O$ , optical center.

an object produces two images (one by each surface) equal in size and cosensual, these two images will lie in planes which answer the above description. We

shall call this middle image  $J$ . From these planes along the axis conjugate foci of the system are measured.

Whatever transformations take place within the system are comparatively unimportant if only we may receive light emergent from one plane apparently unchanged since its entrance at the other. If also these planes are so related that the object approaches one as its image approaches the other, until in size and sense alike each disappears in its plane, then the two principal planes are quite fit to replace the single plane of the single surface, and Fig. 73, which we use here to illustrate the system, becomes exactly what Fig. 72 would become if pulled apart and separated by the distance between  $h'$  and  $h'''$ .

We now proceed to find the position of this middle image, indicating principal foci as usual by capital letters, other focal distances by small letters. Of course the distance of the *middle image* from the  $F'$  surface will be indicated by  $f''$ , its distance from the  $\Phi$  surface by  $\phi''$ .

$$\left. \begin{aligned} \text{From Eq. 18,} & \quad \frac{j'}{j''} = \frac{F''}{F'' - j''} \\ \text{Also,} & \quad \frac{j'''}{j''} = \frac{\Phi''}{\Phi'' - \phi''} \end{aligned} \right\} \quad (25)$$

$$\text{Divide 25 by 26, and} \quad \frac{j'}{j'''} = \frac{F''\Phi'' - F''\phi''}{F''\Phi'' - \Phi''j''}$$

$$\text{By condition,} \quad \frac{j'}{j'''} = 1; \quad \text{therefore} \quad F''\phi'' = \Phi''j'',$$

$$\text{and} \quad \frac{\Phi''}{F''} = \frac{\phi''}{j''} \quad (26)$$

Thus it is seen that the middle image will have in the two surfaces conjugates that are equal and cosensual if it divides the middle medium into parts proportional to the principal foci appertaining thereto. If  $d$  represents the distance between the surfaces and  $J$  the place of the middle image,  $Jh$  will be equal to  $f'' = \frac{d F''}{F'' + \phi''}$ . The conjugate focal distance  $Jh'$  may be found by substituting this value for  $f''$  in Eq. 13.

In like manner Eq. 13 applied to the  $\Phi$  surface will give the value of  $\phi'''$  for  $h'''$  from that of  $\phi'' = \frac{d \Phi''}{F'' + \phi''}$ .

It is hardly necessary to repeat that  $h'$  and  $h'''$  used as magnitudes define the distances of the principal points from their surfaces: they are usually considered positive when in the middle medium. It is not uncommon to give to an optical system a symmetrical notation, so that the direction  $F' F''$   $h' h''$  are considered positive when each is measured from its own principal plane away from the other.

**Optical Center.**—It remains for us to determine what point or points, if any, may be found along the axis of the system having properties like those of the centers of single surfaces. There is, generally speaking, no point through which as through a center light will pass without change of direction. Only in the special case where the centers of the surfaces are coincident can this happen. One may assume, however, that somewhere is a point so situated that light passing through it will be equally and oppositely refracted at the two surfaces. In this case the first and final paths, though not necessarily identical, must be parallel.

The optical center is the name by which this point is known, and to determine its place we make use of Equation 22. By it the linear dimensions of  $O$  are connected with those of its first and last image; thus,

$$\mu' j' \tan \alpha' = \mu'' O \tan \alpha'' = \mu''' j''' \tan \alpha''' \quad (27)$$



We may drop out the middle term of this equation, and as the condition imposed is that  $\alpha'$  is equal to  $\alpha'''$ , the other tangents also disappear, giving

$$\mu'j' = \mu'''j''' \tag{28}$$

the condition to which we must conform in locating the three points. By the usual notation we use  $g$  to measure distances from the first center, and  $\gamma$  those from the second, and remember that—

$$u'F'' = \mu''F', \text{ and } \mu'''\Phi'' = \mu''\Phi''' \tag{29}$$

which may be easily proved.

Referring to Fig. 70, where the distribution along the axis of the cardinal points of the two surfaces is shown in its relation to  $O$  and its two images, we have two expressions for the relative size of each pair :

$$\frac{j'}{O} = \frac{g'}{g''} = \frac{F''}{g'' - F'} \tag{30}$$

$$\frac{j'''}{O} = \frac{\gamma'''}{\gamma''} = \frac{\Phi''}{\gamma'' - \Phi'''} \tag{31}$$

Dropping out the middle terms and multiplying Eq. 30 by  $\mu'$  and Eq. 31 by  $\mu'''$ ,

$$\left. \begin{aligned} \frac{\mu'j'}{O} &= \frac{\mu'F''}{g'' - F'} \\ \frac{\mu'''j'''}{O} &= \frac{\mu'''\Phi''}{\gamma'' - \Phi'''} \end{aligned} \right\} \tag{32}$$

The two right-hand members are equal by Eq. 28. Expressing the equality of the two left-hand members after substituting the numerators from Eq. 29 and dividing by  $\mu''$ ,

$$\frac{F'}{g'' - F'} = \frac{\Phi'''}{\gamma'' - \Phi'''} \tag{33}$$

By composition and alternation,

$$\frac{F'}{\Phi'''} = \frac{g''}{\gamma''} \tag{34}$$

Calling  $\delta$  the distance between  $r$  and  $\rho$ , we find here again, for the optical center as for the middle image, we must divide a distance into parts propor-

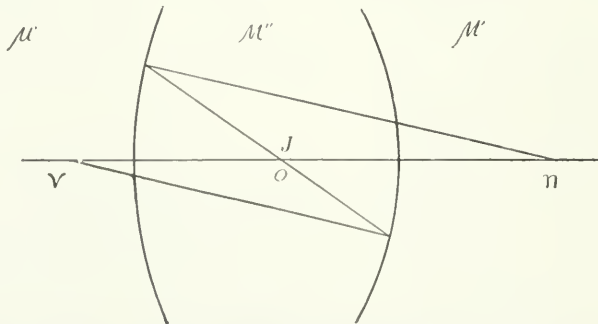


Fig. 75.—The optical center of a lens. The cross of the axis with a line connecting the surface ends of two parallel radii is the optical center.

tional to the principal foci of the two surfaces, but this time we must use the principal foci for rays that are parallel in the middle medium, whereas before we used the principal foci for rays that were parallel outside the middle medium.

In a three-index system the *optical center*, and in the lens, where the first and last media are the same, both *middle image* and optical center can be located geometrically, as in Fig. 75. The surface ends of any two parallel radii are connected by a straight line; its cross with the axis is the optical center of the lens.

The image of the optical center in each surface gives the nodal point corresponding to that surface; it may be found by Eq. 13 as above, remembering that

$$\frac{\delta F'}{F' + \phi'''} = g'', \quad \text{and} \quad \frac{\delta \phi'''}{F' + \phi'''} = \gamma'', \tag{35}$$

and that

$$g'' + r = f'' \quad \text{and} \quad \gamma'' + \rho = \phi''.$$

These two points are called **nodal points**, and transformations of waves and rays incident to the passage of light from one of these points to the other may in many cases be ignored, for we know that what goes into the system as if directed to  $n'$  will come out unchanged in direction as if from  $n'''$ . So here, again, we have, as in the case of the principal points, lost space, and the geometrical constructions which give graphic solutions with single sur-

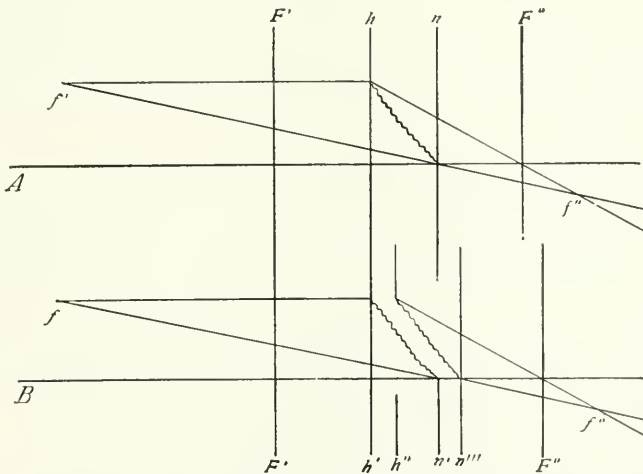


FIG. 76.—Construction for finding the conjugate to any radiant when the cardinal points are known.  $A$  is the axis of an optical surface;  $B$ , the axis of a system of surfaces. Cardinal planes are indicated by the usual letters. Cardinal points are where those planes intersect the axes. To find the conjugate of any radiant  $f'$  in the surface  $A$ , draw two rays, one parallel to the axis, one through the center of the surface. The former after refraction must pass through the principal focus; therefore its path is determined. The direction of the latter is unchanged by refraction. Its cross with the first ray is the focus  $f''$  conjugate to  $f'$ . For a system the method is the same, except that for incident rays the surface and center are replaced by the first principal plane and first nodal point. Refracted rays are drawn from the last principal plane and last nodal point. It will be noticed that the second picture is identical with the first, except that all the lines have parted either at the surface or the center, and the diagram has been lengthened by the break an amount equal to  $n' n'''$ .

faces may be used equally well for systems; but every picture thus formed will be broken in two, some of its lines parting at the principal plane, some at the center. The two halves being separated by translation parallel to the axis, there will result a similar construction, except that the surface  $h$  takes on a finite thickness equal to  $h' h'''$ , and the center  $n$  instead of being a point is stretched out into a line, reaching from  $n'$  to  $n'''$ , and equal in length to  $h' h'''$ .

It is hardly possible in an article as short as this must be to include rigid demonstrations of everything necessary to its usefulness. Little, so far, has been omitted which was necessary to show both geometrical and functional

relations existing between the cardinal points of the optical system and the center, the pole, and the two foci of the single surface.

The student who desires to pursue the matter in the same thorough manner must be referred to Helmholtz for whatever of proof is omitted from the remaining pages.

By a continuation of the methods used above it can be proved that when the principal points are located for any system of two surfaces, and when the principal foci of the system are measured from these points; that when the nodal points are placed, and  $\mathcal{G}'$ ,  $\mathcal{G}''$ ,  $g'$ , and  $g''$  be used as above to indicate distances from them; and when, as in Eq. 17,  $u'$  and  $u''$  are used to measure distances away from the center, with the principal foci as origins,—then not only Eq. 13, but also Eqs. 17 and 18, apply equally well to the system as to the surface, if only allowance be made for the lost space between the principal planes and between nodal points.

This fact is of great practical utility, as it gives no restriction at all in cases where the thickness of the lens is small as compared with its focal length. In most of the cases where spectacles are used the thickness of the glass may be ignored. When we add to this statement the extension which is warranted by fact that not only may surfaces be compounded into systems without change of properties, but these systems still further compounded, the one with the other, it will appear that for every set of surfaces, however many in number, an equivalent set of eight points may be determined as follows: The *optical center*, the *middle image*, the two *principal points*, the two *nodal points*, and the two *foci*.

The following formulæ give the places of the *cardinal points* where three media are concerned. They are applicable to media separated either by surfaces or systems, if only it be remembered to measure  $d$  from the last principal point of the first medium to the first principal point of the last medium, and to measure the distance between nodal points of the component systems in like manner.

In Fig. 74, where  $d$  is  $h\gamma$  and  $\delta$  is  $n\nu$ , we may let  $x'$  and  $x''$  represent the sections of  $d$  by  $J$ , and  $y'$  and  $y''$  the sections of  $\delta$  by  $O$ . (See also Fig. 70.)

The *middle image*  $J$  divides the distance  $d$  into  $x'$  and  $x''$ :

$$\left. \begin{aligned} Jh = x' &= \frac{F''d}{F'' + \Phi''} \\ J\eta = x'' &= \frac{\Phi''d}{F'' + \Phi''} \end{aligned} \right\} \quad (36)$$

The *optical center* divides the distance  $\delta$  into  $y'$  and  $y''$ :

$$\left. \begin{aligned} On = y' &= \frac{F'\delta}{F' + \Phi'} = \frac{u'F'\delta}{\mu'(F' + \Phi')} \\ Ov = y'' &= \frac{\Phi'\delta}{F' + \Phi'} = \frac{\mu'\Phi'\delta}{\mu'(F' + \Phi')} \end{aligned} \right\} \quad (37)$$

From Fig. 75 it is easily proved that  $\delta$  and  $d$  are similarly divided by  $O$ . We may therefore substitute  $d$  for  $\delta$ ,  $h$  for  $n$ , and  $\gamma$  for  $\nu$  in Equations 37, and so obtain the formulæ for the position of the optical center as measured from the two surfaces.

*Principal Points.*— $h'$  and  $h''$  as linear magnitudes are positive when measured from  $h$  and  $\gamma$ , the extremes of  $d$  toward the middle medium:

$$\left. \begin{aligned} h' &= \frac{x'F''}{F'' - x'} = \frac{F''d}{F'' + \Phi'' - d} \\ h'' &= \frac{x''\Phi''}{\Phi'' - x''} = \frac{\Phi''d}{F'' + \Phi'' - d} \end{aligned} \right\} \quad (38)$$

*Principal Foci.*— $\mathfrak{F}'$  and  $\mathfrak{F}'''$  are considered positive when each principal point comes between its focus and the other principal point :

$$\left. \begin{aligned} \mathfrak{F}' &= \frac{F'\Phi''}{F''+\Phi''-d}, \\ \mathfrak{F}''' &= \frac{F''\Phi'''}{F''+\Phi''-d}. \end{aligned} \right\} \quad (39)$$

*Nodal points,*  $n'$  and  $n'''$ , are measured inward from the extremities of  $d$  :

$$\left. \begin{aligned} n' &= h' + \mathfrak{F}''' - \mathfrak{F}' = \frac{F'd + F''\Phi''' - F'\Phi''}{F'' + \Phi'' - d}, \\ n''' &= h''' + \mathfrak{F}' - \mathfrak{F}''' = \frac{\Phi'''d + F'\Phi'' - F''\Phi'''}{F'' + \Phi'' - d}. \end{aligned} \right\} \quad (40)$$

From these last equations, by the substitution of the values of the  $F$ 's and the  $\Phi$ 's, as obtained by Eqs. 14 and 15, are deduced the simplest expressions for the cardinal points of any system. They flow from the above equations without complication or difficulty, and are obtained by the ordinary processes of elimination. Expressed in terms of  $\mu'\mu''\mu'''r$  and  $\rho$ , they reduce to vulgar fractions having

$$\mu''(\mu''' - \mu'')r + \mu'''(\mu'' - \mu')\rho - (\mu''' - \mu'')(\mu'' - \mu')d = N, \quad (41)$$

for a common denominator. This term, being constant for the system, may be calculated once for all, and so is abbreviated to  $N$ , there being no physical significance here intended. It is merely an abbreviation borrowed from Helmholtz.

These are the values :

$$\mathfrak{F}' = \frac{\mu'\mu''r\rho}{N}, \quad \mathfrak{F}''' = \frac{\mu''\mu'''r\rho}{N}, \quad (42)$$

$$h' = \frac{\mu'(\mu'' - \mu''')r d}{N}, \quad h''' = \frac{\mu'''(\mu' - \mu'')\rho d}{N}. \quad (43)$$

$$\left. \begin{aligned} n' &= \frac{\mu''(\mu'' - \mu''')r d + \mu''(\mu''' - \mu')r\rho}{N}, \\ n''' &= \frac{\mu'''(\mu' - \mu'')\rho d + \mu''(\mu' - \mu''')r\rho}{N}. \end{aligned} \right\} \quad (44)$$

$$\left. \begin{aligned} H &= \mathfrak{F}'' - \mathfrak{F}' = \mathfrak{F}'' - \mathfrak{F}''' = d - h' - h''' = \delta - n' - n''' \\ &= \frac{(\mu'' - \mu')(\mu''' - \mu'')(r - \rho - d)}{N}. \end{aligned} \right\} \quad (45)$$

Eqs. 39 to 45 may be used without restriction.

These general formulæ may be much simplified by the imposing of certain conditions which often occur in practice. Thus, if the middle medium is very thin,  $d$  may be considered equal to  $o$ . In that case  $H$  is also equal to  $o$ , and  $h, h', J, h'''$ , and  $\eta$  all coincide ; so the last term in  $N$  disappears, and our system is practically described by the two values of  $\mathfrak{F}'$  and  $\mathfrak{F}'''$ . The first two terms only of their denominators being left, we write in full, as follows :

$$\left. \begin{aligned} \mathfrak{F}' &= \frac{\mu'r\rho}{(\mu''' - \mu'')r + (\mu'' - \mu')\rho}, \\ \mathfrak{F}''' &= \frac{\mu'''r\rho}{(\mu''' - \mu'')r + (\mu'' - \mu')\rho}. \end{aligned} \right\} \quad (46)$$

If both radii are now supposed alike, the middle medium drops out of the account,

$$\mathfrak{F}' = \frac{\mu'r}{\mu''' - \mu''}, \quad \mathfrak{F}''' = \frac{\mu'''r}{\mu''' - \mu''} \quad (47)$$



and we have a single optical surface between the first and third medium—a condition realized in the passage of light through the cornea and aqueous.

A still more important condition that may be imposed on a system of two surfaces is that the first and last media shall have the same index. This gives the lens proper.

**The Lens.**—It would seem the part of wisdom to confine the term “lens” to such combinations, and to use the word “system” for others. In this way a distinction is made which is in keeping with the derivation of the word and with ordinary mechanical constructions, and which is continually in evidence through the simplicity of the resulting formulæ, while a lens that is used as a window between two different media is such only in name, and the name so used is definitive only of a triviality. We shall use the word “lens” only for two-index systems. The crystalline lens of the eye is not excluded from this category, as the aqueous and vitreous are of the same refractive power.

Reducing Eq. 41 to 45 by letting  $\mu''' = \mu'$ , we have the formulæ characteristic of lenses :

$$\mathfrak{F}' = \mathfrak{F}''' = \frac{\mu' \mu'' r \rho}{\mu'' (\mu'' - \mu') (\rho - r) + (\mu'' - \mu')^2 d}. \quad (48)$$

$$\left. \begin{aligned} h' = n' &= \frac{\mu' d r}{(\mu'' - \mu') d + \mu'' (\rho - r)}, \\ h'' = n'' &= -\frac{\mu' d \rho}{(\mu'' - \mu') d + \mu'' (\rho - r)}. \end{aligned} \right\} \quad (49)$$

$$H = d \frac{(\mu'' - \mu') (d + \rho - r)}{(\mu'' - \mu') d + \mu'' (\rho - r)}. \quad (50)$$

Fig. 77, illustrative of the preceding paragraphs, shows the disposition along the axis of the cardinal points of several optical systems. *a* is a single optical surface, and to it corresponds the aphakic eye and the schematic eye of Listing. *b* is the general case of two surfaces separating three media, all of different indices. In this the nodal points and the principal points are not identical. *c* is a true lens as described above, in form resembling the crystalline. In it, as in *defg*, other lenses, principal points, and nodal points coincide, and it may be noted that, assuming  $\mu'' > \mu'$  and *d* less than  $r + \rho$ , positive lenses are thicker in the middle.

Double convex and double concave lenses have their principal points between the curved surfaces. In plano-convex and plano-concave lenses *h'*, *h''*, and *J* all come together on the curved surface. In the meniscus they pass out of the substance of the lens and arrange themselves in the medium farthest from the centers of curvature.

*j* corresponds to the human eye, *k* to the eye with a spectacle lens before it.

The continuity of a series of systems is seen by looking, for example, at system *b*, and noting that the point  $\mathfrak{F}'''$  in the relevant formulæ is such a function of  $\mu'''$  and  $\rho$  that one may be increased as the other is decreased without altering the place of  $\mathfrak{F}'''$ ; so that wherever in a system of three media  $\mathfrak{F}'''$  happens to be placed by making the compensatory changes in  $\rho$  and  $\mu'''$ ,  $\mu'''$  may be brought to be equal to  $\mu''$  without altering the places of the principal foci. In this way, without changing the disposition of the foci, *h''* may be varied until it is equal to *r*, in which case *h'* will be equal to nothing. In other words, the single surface may be treated as a system in which the third index of refraction is equal to the second, and whose second surface has an infinite curvature, and whose center and surface are both coincident with the center of the first surface. Such a substitution of values may always be made in the use of Eqs. 47 to 50, where one of the component systems is a single surface.

**The Diopter.**—Consistent with any scheme that measures the direction of light-propagation as positive, the curvature of the wave is considered positive when its center is in front of it, for its radius must be then positive, and so,

whether mirror, refracting surface, or system, its strength as an optical factor is estimated by the curve of the wave, the convergence of the rays that may be produced by it. The unit which is now universally and almost exclusively used in the estimation of the strength of lenses is the *dioptry*, suggested by Nagel and named by Monoyer. It is to the credit of ophthalmologists that in their optical work inches are being fast forgotten. Lenses are thus described by giving to each the reciprocal of its focal length in meters, and placing before this number the sign + or - to denote whether it has a real or virtual focus for parallel rays. The convenience of this method is its chief recommendation, as combinations of lenses are subject to computation by simple addition in an all but universal standard of measurement, instead of requiring pencil and paper computations in terms that are none too rapidly becoming archaic.

The *focal length* of a lens whose dioptric number is given is of course the reciprocal of that number in meters, or one hundred times that reciprocal in centimeters.

In comparing the two systems it may be said of one that it designates the lenses by their focal lengths in inches, the other gives to a lens its additive value in diopters. To reduce accurately from either system to the other, one divides 39.37 by the number of the lens. A sufficient approximation for all test-case examples is to use 40 as the dividend. Thus a glass of 8-inch focus is equal to 5 diopters. A three-diopter lens has a focal distance of one-third of a meter—that is, 33 c.m.—or, if its old number in inches is desired, divide 40 by 3. It is approximately No. 13; accurately, it is 13.123, unless the method of calculation has proved superior to the method of its original manufacture and measurement, which for ordinary spectacle lenses is quite likely to be the case.

For all thin lenses the distance between the principal planes may be ignored, and the equations that have been used for surfaces may be used without restriction; and in their use they admit of such simplification as comes from putting  $\mathfrak{F}' = \mathfrak{F}''' = \mathfrak{S}' = \mathfrak{S}'''$ . There are but three cardinal points to such a lens. The *middle image*, the *optical center*, the two *nodal points*, and the two *principal points* are all united in a single point halfway between the two principal foci.

The *strength* or *power* of a lens is the convergence that it can produce in parallel rays. It is also the curvature it can give to a plane wave that passes through it; it

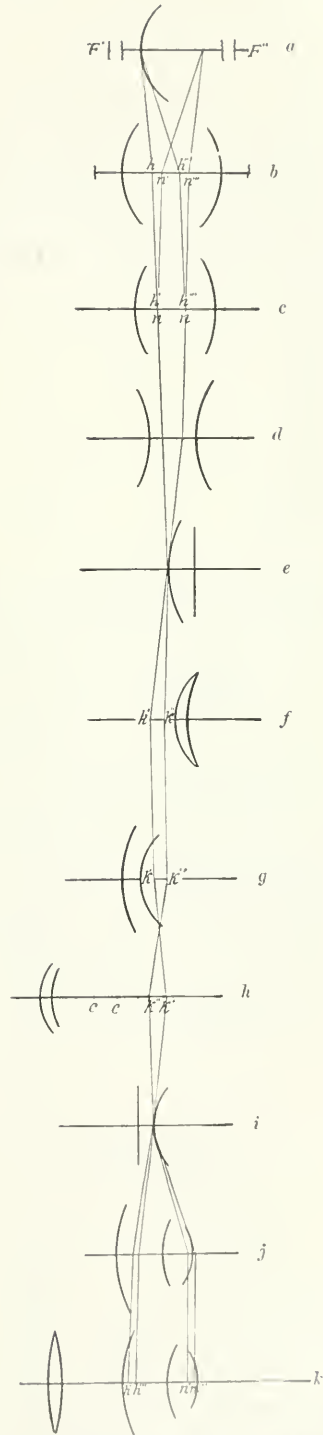


FIG. 77.—Showing the relative positions of the principal points and nodal points for different systems of surfaces.

is also the reciprocal of its focal distance. Either one of these definitions implies the other. Whichever way it is defined,  $\frac{1}{\mathfrak{F}}$  is its measure. This definition must be modified for a single surface or a system other than a lens. The dioptric strength of such a system is consistently considered to be the measure of the curvature in air or vacuum which it will impress on a wave that was flat before reaching it. Some such convention must be adopted, as the convergence produced is greater on the side of the lesser index, though the system is the same (Fig. 78). With this limitation

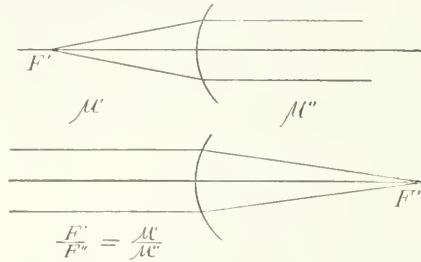


FIG. 78.—For a single surface the convergence produced in parallel rays is greater on the side of the lesser index.

we can evaluate systems as well as lenses in diopters, and the value will be the index of the last medium divided by the length of the principal focus in that medium. With this convention the dioptric value of a system is the same for light travelling in either direction.

It is hardly necessary to define further the word “focus,” or the word “conjugate,” which has been used so often to signify that two points or two configurations of points are associated as object and image through the agency of some surface or system.

**Virtual and Real Images.**—But the distinction of *virtual* and *real* has not been mentioned thus far in relation to foci and images. A focus or image is real when it is a place from which light really emanates or to which it actually attains. It is virtual when the physical conditions that it represents, though having no real existence, are such that they would account for the reactions taking place at some other point if there were no break in the homogeneity of the intervening medium.

Thus we see in Fig. 79 light from any point of  $j'$  falls on the screen  $k'$  as if coming from  $j''$ , though no light-waves or rays enter the medium behind the reflecting surface.

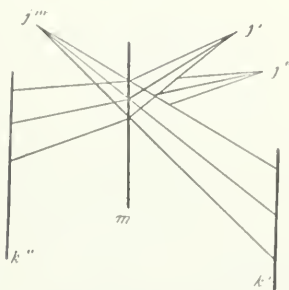


FIG. 79.—Virtual Images of  $j'$ ,  $j''$  by reflections,  $j''$  by refractions.

Again, were the surface a refracting surface, the light would fall on the screen  $k''$  as if coming from  $j''$ , the virtual image of  $j'$ , though none of the waves that are disposed as if coming from  $j''$  are in the medium in which  $j''$  is placed. We may say, consistently with the notation of this article, that

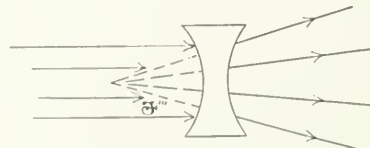


FIG. 80.—Virtual focus of concave lens.

when the image  $j$  finds itself in a medium whose accents are different from its own, the image is virtual. Examples of real images are seen in Figs. 72, 73, and 78. Fig. 80 shows a concave lens with its virtual focus at  $\mathfrak{F}''$ .

We take note here that the general forms of the lenses given in Fig. 77 may be described by the following terms: *Double convex, double concave, plano-convex, plano-concave, concavo-convex, or convexo-concave*; the last variety when thinnest on the edges is called a *meniscus*.

Applying Eqs. 48 to 50 to obtain the characteristic properties of this group, one easily proves that the principal points of the double convex and the double concave variety are between the two surfaces; that in the plano-lenses they are both united on the curved surface; that for the concavo-convex type they pass out of the substance of the lens on the side of the greater curvature.

It will be found also that when radii, surfaces, and indices are so arranged that the strength of the lens is negative—that is, when the lens has a virtual focus  $\mathfrak{F}'''$  falling on the left in the figure and  $\mathfrak{F}'$  on the right—then  $h'$  and  $h'''$  are also transposed, each being found between the other and its own principal focus. With one exception the lenses that are thickest in the middle are of positive focal length, and all positive lenses whose index is greater than that of the surrounding medium are thicker in the middle than at the edges. The one exception of a minus lens that is thinner at the edges occurs when  $r$  is greater than  $\rho$ , when  $d$  is greater than the distance between the centers, and when  $\mu'' (\rho - r)$  is algebraically less than  $(\mu'' - \mu')d$ . Equation 49 will under such conditions give a minus value for  $\mathfrak{F}'''$ .

The *human eye*, as has been said, is a centered system of optical surfaces like that given in Fig. 77 (*j*). We copy here from Czapski's table of dimensions and constants, given for reference in his book on optical instruments, where figures collected from various sources by Helmholtz furnish what might be called a composite reproduction of the type, and where also are tabulated the results of careful measurements and calculations in a single case by Tscherning. Along the vertical line of Fig. 81 are the cardinal points and other points of interest as arranged on the axis of the eye. Between cornea and retina the spaces are correctly given on an enlarged scale of 2.5 to 1. All distances are in meters, so that when applied to use in the above formulæ the strength of a lens or system will be expressed in the diopter, the familiar unit of the test-case.

The cases in which practice suggests or renders useful the application of the above formulæ are not infrequent. We mention only two: One a case of *axial myopia* in which a supposition that the dioptric system of the eye has remained the same, but the retina has been displaced backward an amount which is easily calculated from the strength of the glass needed to give distinct distant vision. Suppose the size of the retinal image is required for the corrected eye. The correcting lens is usually made as thin as possible; hence its optical center and all the cardinal points except the two foci are at its geometrical center.  $F''$  is minus, and, measured along the axis,  $F'$  is plus;  $d$  is the distance of the correcting lens from the cornea added to 0.0017532, the distance of the cornea in front of  $h'$  of the eye. Both foci of the emmetropic eye may be obtained from the table, and thus the figures are all obtainable for getting principal points and nodal points for the complete system through the application of formula 36 to 41.

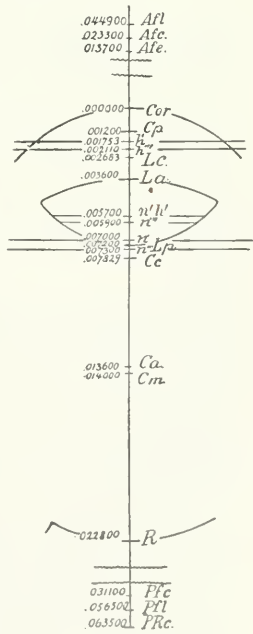


FIG. 81.—The cardinal points of the human eye, measured from the cornea from cornea to retina, enlarged to a scale of 2.5:1.



Another interesting case occurs where the lens has been removed and a strong plus-glass is worn. The nodal points of the glass may be calculated without difficulty, or, if used for reading, a plano-convex, with the flat side in front, will be acceptable to the patient, and its nodal points are on the convex surface.

The surface of the cornea is the principal point of the eye, and its curvature read from the ophthalmometer locates its center, which is the nodal point for the aphakic eye, or this center may be assumed to be like the average and supplied from Fig. 81.

It can be hardly thought necessary to guide the student farther, as he has now all the points of the component systems which are required to give the cardinal points of the equivalent or resultant system, and these being found, the magnification is forthcoming by Eq. 18 or Eq. 20.

**Astigmatic Surfaces and Pencils.**—We pass now to a very brief consideration of astigmatic surfaces and pencils. We have thus far assumed that the optical surfaces were spherical—that is to say, surfaces of revolution about their common axis, and whose principal sections were circular.

It happens that such is not always the case. Imperfections of the cornea or lens give for the surfaces of the eye itself imperfect approaches to sphericity; and even if that were not so, a displacement of any center or radiant focus from the axis of the system produces the same change in the transmitted or reflected pencil that would result from imperfect curvature of the surface.

For the small pencils with which we deal there is only one form of astigmatism. It is that which would be given to a pencil of light by the optical action of a toric surface. A *sphere* is the surface developed by the revolution of a circle about one of its diameters. A *torus* is developed by the revolution of a circle about any line that is in the same plane, but not a diameter. Roughly speaking, when the axial line is a cord the torus is shaped like an apple with a dimple in its blossom end equal to that in its stem end. When the axial line is not a cord, the torus is like an anchor ring. When the line is at an infinite distance from the circle the toric surface is a cylinder.

The *toric lenses* in use are supposed to be such as might be sliced from a toric surface by a plane parallel to its axis of development. Such a lens is centered optically when both its centers, the center of the circle and the center about which in its development the circle revolves, are on the axis of the system.

It will need but little consideration to convince the reader that in two different sections of such a surface the problems relative to the transmission of light will be exactly similar to those which we have just considered as true for any plane whatever of the spherical surface.

A plane section of the toric surface may be taken perpendicular to the circumference of the developing circle, or coincident with that circumference, and in either case it will be a circular section. In one case it will be the section of least, and in the other the section of greatest, curvature, with foci correspondingly shorter and longer than in other sections; and in each case may the optical conditions be described and determined by the same laws and formulate as those previously considered for a spherical surface, which is a surface of circular section.

The section of the toric surface through its two centers, both of which we suppose to be on the axis of our optical system, may take place through a meridian not coincident with the section of greatest or least curvature, and then consecutive rays from any axial point will not be reunited by this surface on the axis, but near it. The result is that an axial pencil directly incident on such a surface has the characteristics that are portrayed by Fig. 82, showing the general form of the pencil from Aubert, and the distribution of

its component rays as in a diagram by Edward Jackson from Norris and Oliver's *System of Diseases of the Eye*.

The point along the axis that can be most satisfactorily utilized as a focal point is at  $F_0$  in the figure. It is the place where the rays are collected into the smallest bundle. It is called "the circle of least confusion," and its place between  $F_1$  and  $F_2$  divides that distance in such ratio that it is a fourth

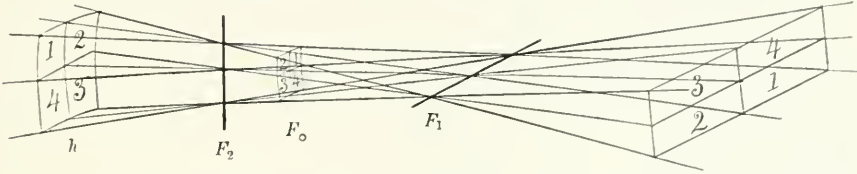


FIG. 82.—showing the distribution of rays and focal lines in an astigmatic pencil ( $h F_0 F_2 F_1 = -1$ ).

harmonic to  $F_1$  and  $F_2$ . Consequently, it is determined by the same formulæ and constructions that are used to locate the conjugate foci in a spherical mirror (see pp. 108 and 113).

**Astigmatism** is usually an anomaly and not a desideratum. It is measured and discussed in terms of the diopter, which have proved equally useful whether applied to pencils or lenses.

The amount of astigmatism is the strength of a lens which under ordinary optical conditions would change the convergence of the meridian of least to that of greatest curvature, or *vice versa*. The correcting lens must be essentially a toric, and one also whose focal anomaly is exactly equal and opposite to that of the pencil to be corrected. For simplicity the cylinder is usually chosen, and, having only one finite focus, it is designated by the dioptric value of the correction required.

In correcting the anomalies of refraction and accommodation it is not in general possible to use a simple lens, either cylinder or sphere. One gives the cylinder necessary to make either of the extreme foci coincident with the other, and then adds whatever of spherical correction is required. The particular combination of cylinder and sphere that is used is more a matter of commercial than of physiological interest.

The astigmatism that has been described as produced by a toric lens is the only kind that has been successfully and systematically corrected. It is for "thin pencils" the only kind that exists, and for pencils as large as may enter the pupil it is the only kind that merits attention, *aberration* being so well known by its own name as to be considered, if at all, under a separate head.

The classification of astigmatism into "*simple*," "*compound*," "*myopic*," "*hyperopic*," and so on may have its clinical advantages, but it seems to the writer to be of very doubtful propriety. We deal only with one kind of astigmatism. It may have its existence in a myopic eye, a paper-weight, or in the glass door of a Gothic house, but a nomenclature that takes cognizance of such facts is confusing to the novice unless he clearly understands that the astigmatism and its method of correction is the same in every case.

For those who find it convenient to classify astigmatism by its associated anomalies it may be stated that when the retina of the eye at rest falls behind the posterior focal line, the condition is what is called "*compound myopic astigmatism*;" when it falls on the posterior focal line, it is called "*simple myopic astigmatism*;" when it falls between the two focal lines, it is called "*mixed astigmatism*."

When the retina passes through the first focal line it is called "*simple hyperopic astigmatism*," and when in front of both focal lines the anomaly is said to be "*compound hyperopic astigmatism*" (see also p. 227). This cumbersome and useless attempt at precision, as it is usually taught, merely serves to conceal the fact that there is a point on the axis between the first and second focal lines through which the retina must pass to obtain the best image compatible with that particular degree of astigmatism.

The construction for finding this point has been given above. The distribution along the axis of the four letters in Fig. 82 is  $hF_2 : hF_1 = -F_0F_2 : F_0F_1$ , or, briefly,  $(hF_0F_2F_1) = -1$ . When the retina of the eye at rest passes through this point ( $F_0$ ), the case should be considered simply as one of astigmatism. If the retina passes behind this point, there is myopia as well; if in front of it, hypermetropia.

The glasses found in most trial cases for the correction of astigmatism are cylinders in pairs, both plus and minus, quarter numbers to 2.50, and half numbers to 6. The spherical lenses are usually in quarter numbers to 2.50, half numbers to 7, whole numbers to 14, and then increasing two diopters at a step to 20 or 22, a pair each of both kinds, plus and minus, the cylinders usually plano-cylinders, the sphericals double convex or double concave.

#### Optic Axis ; Line of Vision ; Line of Fixation ; Line of Sight.—

We have spoken of the eye as a centered system, and such it is in type. Its principal points, its nodal points, its center of motion, as well as the cardinal points of the lens, are usually all on one line or nearly so. This line is called the *optic axis*. It is approximately the axis of symmetry for the whole organ. It is sometimes the case that the macula, the center of the most acute perceptive power, is directly in this line, but oftener it is not. When the optic axis passes through the macula, it is the *line of vision* as well, meaning by the line of vision or the *line of sight* the line on which the object must be placed in order that the visual act should be most advantageously performed. Under these circumstances also the optic axis is the *line of fixation*, for it is the line passing through the center of motion and indicative of the eye's position or aim.

An excentric position of the macula lutea is so common as to be the rule rather than the exception. It is usually toward the outer side of the optic axis. Consequently, the line of vision is no longer coincident with that axis, but crosses it with a slight "fault" at the nodal points, and the line of fixation connecting the center of motion of the eye with the object on which it is trained has now a position which differs from the optic axis almost as much as the line of vision.

The angle  $OMA$  (Fig. 83) is taken as the measure of this lack of symmetry due to the excentricity of the macula. It is called *the angle gamma*,  $\gamma$ . It is reckoned as plus when the optic axis falls outside of the visual axis.

Another peculiarity of construction must be considered in connection with the form and position of the cornea.

It is convenient, and in some measure consistent with existing conditions, to look upon the cornea as ellipsoidal rather than spherical in its contour. Its horizontal section if the curve were completed would occupy a position in the average emmetropic eye something like that pictured in Fig. 84. Here it is seen that the corneal major axis does not coincide either with the visual axis or the optic axis. The lack of symmetry thus pictured is usually measured by the angle which the major axis of the cornea makes with the visual axis. This angle is known as  $\alpha$ , *the angle alpha*, and is reckoned plus when the

visual axis pierces the cornea on its nasal side. In high myopia the angle  $\alpha$  is often negative (see also p. 96).

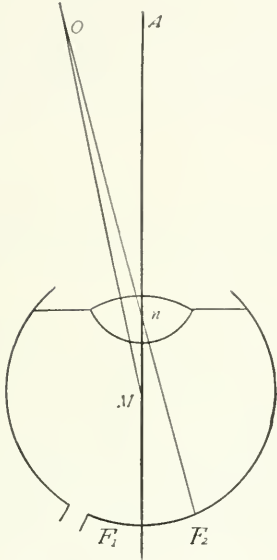


FIG. 83.— $\angle MA =$  The angle gamma.

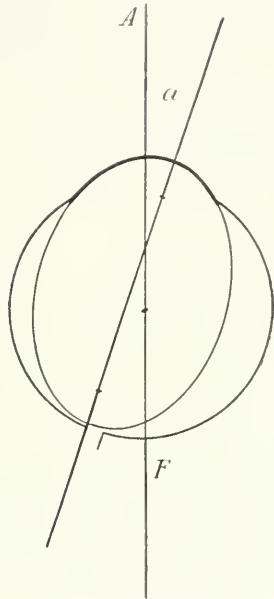


FIG. 84.—The angle alpha.

**Mirrors.**—In the eye itself are no plane surfaces, and no surfaces whose chief function is comparable to that of the mirror; but such surfaces must be considered as being intrinsic parts of many instruments. The mirror-like action of the dioptric surfaces of the eye is made use of in various methods of investigation.

A mirror being only a special case of single optical surface where  $\mu' = -\mu''$ , it may be most satisfactorily discussed in connection with previous studies by making the substitution of  $\mu'$  for  $-\mu''$  in the general formulæ 13 and 18.

Substituting and reducing, we have

$$\frac{1}{f''} + \frac{1}{f'} = \frac{2}{r}. \quad (51)$$

As has been previously mentioned, this formula is suggestive of the harmonic relation for which a construction has already been given (Figs. 66 and 67). Whichever side of the surface is used, the principal focus is halfway between the center and the surface. It is found from Eq. 13 in the usual way.

It is evident from the formula or from the graphic construction that image and object are always on the same side of the principal focus; also that they are always separated by the surface or the center, never by both; also, wherever the object, the image that is on the same side of the principal focus as the reflecting surface is a virtual image.

The relation between the size of object and image is precisely the same as for dioptric surfaces, and may be determined either by Eq. 18 or 21.

We have but one more present application for Eq. 13, and that is for the special case where the surface, either dioptric or katoptric, is plane. In such case  $r = \infty$ , the second member disappears, and

$$\frac{\mu''}{f''} = \frac{\mu'}{f'} \quad (52)$$



which may be construed as saying that the foci conjugate to a plane optical surface vary as their respective indices. Make this a reflecting surface again by putting  $\mu'' = -\mu'$ , and we find that foci conjugate to a plane mirror are of equal length and of opposite sense; thus:

$$\frac{1}{f''} = -\frac{1}{f'} \quad (53)$$

Substituting  $\infty$  for  $F'$  or  $F''$  in Eq. 18, we find that for plane surfaces, whether katoptric or dioptric,

$$\frac{f'}{f''} = \pm 1, \quad (54)$$

showing that in reflection or refraction the image is equal in size to the object. The ambiguity of sign enters the equation on account of the double interpretation which may be given to the expression for infinity.

It must be remembered that the conditions to which these formulæ have been applied, and to which alone they are considered applicable, are such as exist for centered surfaces and pencils of light whose rays make very small angles with each other and with the axis of the system.

**The Prism.**—The *prism* enters a system optically through the decentering of one or more of its surfaces. The prismatic lens in its simplicity differs from the ordinary lens in no other way, and the prismatic element in the lens is measured by the angle between the two lines that contain the cardinal points of the two surfaces. To qualities which the prismatic glass possesses by virtue of its curved surfaces must be added those that are due to the non-coincidence of the two axes, and these are best studied in the case of the plane prism. The action of a prismatic lens as used in ophthalmology is the added action of the simple lens and the plane prism. The plane prism is made up of two plane optical surfaces inclined to each other at an angle less than  $180^\circ$ . The first and third media are usually alike. These conditions cannot be considered analogous to any previously discussed, as on one or both planes the pencil is oblique; neither is it possible to look upon both planes

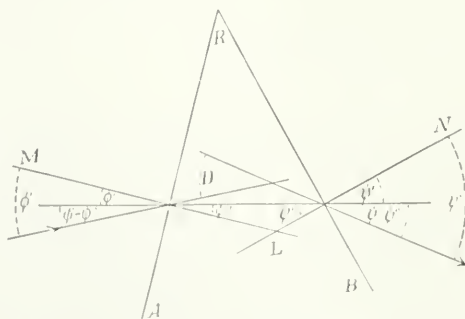


FIG. 85.—Refraction of light in the principal section of a plane prism.

as centered on any finite axis. Consequently, we have to begin again with the law of Snell, and we confine ourselves to refraction in a principal section.

The *apex* or *edge* of the prism is the intersection of the two planes forming its sides or faces. A *principal section* is a section of the prism by a plane perpendicular to the edge. A *base-apex line* is the line of intersection of either side with a *principal section*. From Snell's law we know that a ray of light which before incidence is confined to a *plane of principal section* will pass



The deviation at position of *perpendicular incidence* or *perpendicular exit* is given by

$$D = \sin^{-1}\left(\frac{\mu''}{\mu'} \sin R\right) - R. \tag{66}$$

A simple transposition of 65 gives

$$\frac{\mu''}{\mu'} = \frac{\sin \frac{R+D}{2}}{\frac{R}{2}}, \tag{67}$$

the formula for getting the index of refraction from the deviation and refracting angle.

**Total Reflection.**—There is one special condition that comes to our notice generally in connection with reflection and refraction at plane surfaces. We may take as illustration Fig. 87, and ask guidance of Snell's law

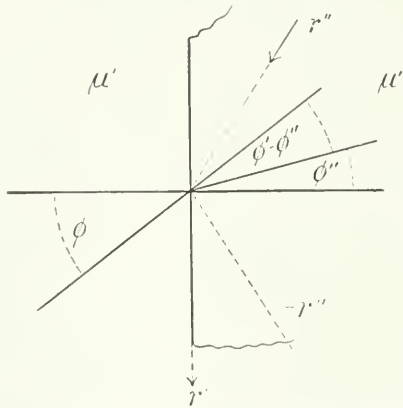


FIG. 87.—Concerning total reflection.

when the wave whose normal  $r''$ , incident from the denser medium ( $\mu'$ ), makes with the limiting surface an angle whose sine, multiplied by  $\frac{\mu''}{\mu'}$ , is greater than 1. The path that Snell's law would seem to indicate for the refracted wave would be an impossible path, for there is no angle whose sine is greater than 1. Under such conditions refraction does not take place.

There is no break in the continuity of the phenomena, for when the angle  $\phi''$  is so great that  $\frac{\mu''}{\mu'} \sin \phi'' = 1$ ; then  $\sin \phi' = 1$ , and the refracted ray,  $r'$ , is parallel to the surface. The wave-front, in other words, is perpendicular to the optical surface, and neither recedes nor approaches it.

A still greater increase of the angle  $\phi''$  would so increase  $\phi'$  that its general direction would be into, instead of out from, ( $\mu'$ ). The angle would have a minus sine, but its numerical value could be nothing other than  $\mu''$ , since the medium is ( $\mu'$ ); and this is the relation characteristic of reflection. Under such conditions all the light that is not destroyed is reflected, and the phenomenon is known as *total reflection*.

The *prism* is of use in ophthalmology chiefly on account of its causing a deviation in the path of light, and thus furnishing an instrument which may be used either as cause of, or compensation for, slight anomalies of the position of the eye itself. The practical application to such purposes is given

elsewhere. In that application it is necessary to take cognizance of its value as used to cause deviation of light, and thus an apparent displacement of any object through it. The relation between the refracting angle and the deviation produced being such, prisms have until recently been described by their refracting angles as Pr.  $1^\circ$ , Pr.  $2^\circ$ , and so on. By Eq. 65 it will be seen that the deviation produced by any prism of ordinary glass,  $D = (1.54 - 1) R$ , is very nearly one-half the refracting angle of the prism; and since one-half a degree is about the smallest increment which ophthalmologists have found useful, the scale is a very convenient one, and in spite of criticisms is still much in use. Its only fault is that the numbers on the glasses do not correspond to the values for which they are used. To remedy this defect it has been proposed to number prisms by the angular deviation in degrees, replacing the degree-mark by a small *d* to avoid confusion, thus Pr.  $1^d$ , Pr.  $2^d$ . This is the *Deviation-angle System* of Jackson. The unit in this system is about double the value of the unit of the *Refracting-angle System*.

To obviate the necessity of making any material change in the size of the working unit, it was proposed to give to each prism the value of its angular deviation in terms of the radian, the only unit of angle that is recognized in works on analysis and mathematical philosophy. One one-hundredth of this, the radian angle, which, in accordance with "C. G. S." (Centimeter-Gramme-Second) nomenclature, is a *centrad*, is so near the unit of the Refracting-angle System as to be practically indistinguishable from it. This is the *Centrad System* of Dennett. The Refracting-angle System and the Centrad System so nearly coincide that for glass of any ordinary index some number between 0 and 35 will be identical for the two systems, and the others of the scale will be so near as to admit of interchange under ordinary circumstances. Centrads are prescribed thus: Pr.  $1^\nabla$ , Pr.  $2^\nabla$ .

The Prism-diopter Scale of Prentice does not differ much from the Centrad Scale, and does not differ appreciably from it in the numbers that are most used. It gives to every prism the value of the tangent of the deviation in hundredths of the radius. Centrads and the prism diopters are compared in Fig. 88.

The same fault may be found with the Prism-diopter Scale as with the Refracting-angle Scale—namely, the number on the glass is a transcendental function of the value for which the glass is used. Within the limits of common use the three scales are alike, and the choice is one of symbol and sentiment only. Prism diopters are described thus: Pr.  $1^\Delta$ , Pr.  $2^\Delta$ , and so on.

To Prentice is due also the suggested change of the  $^\circ$  to  $^d$  for the degree deviation, and to  $\Delta$  for the tangent deviation. The author has extended the symbolism to the centrad system by inverting the triangle for it.

There remains only the *Meter-angle System*, it having been suggested that the "Meter Angle" of Nagel be adopted as a unit for prism nomenclature.

**The Meter Angle.**—The *meter angle* is the angle made by the visual axis and the median plane when the eye is directed to a point in that plane one meter's distance from the center of rotation. The value of this angle depends, of course, on the interocular distance, which must needs be conventionalized if it is used for purposes of prism notation. An interocular distance of .06 makes the meter angle equal to  $3^\nabla$ . Though a little narrow for an adult, it is perhaps as good a distance as any to assume. The advantage

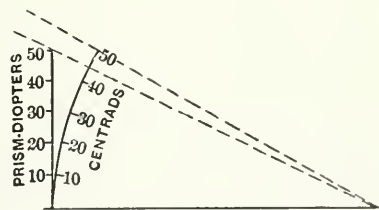


FIG. 88.—Showing the relation of prism-diopter to centrad.



of this unit is supposed to consist in this, that for any point of fixation convergence and accommodation are expressed in the same terms, the inclination of the axis to the median line being the same in meter angles as the accommodation in diopters. The writer is not aware that the meter angle is in actual use as a prism unit. Its relation to convergence may be seen in Fig. 89, and the following notation has been suggested: Pr. 1<sup>m</sup>, Pr. 2<sup>m</sup>.

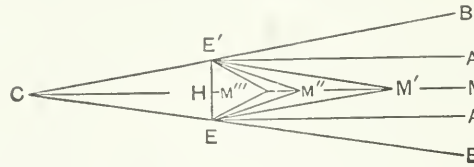


FIG. 89.—The meter angle.

Table I. gives the deviation in degrees corresponding to all the different systems of prism notation :

TABLE I.—Showing the Value in Degrees of Deviation of Prism belonging to the Other Systems.<sup>1</sup>

| Refracting angle.   | Deviation. | Centrad.         | Deviation. | Prism-diopter.  | Deviation. | Meter-angle.                | Deviation.                          |
|---------------------|------------|------------------|------------|-----------------|------------|-----------------------------|-------------------------------------|
| Pr. 1° = 0° 32' 20" |            | 1∇ = 0° 34' 22"  |            | 1Δ = 0° 34' 22+ |            | 1 <sup>m</sup> = 1° 43' 6"  |                                     |
| 2° = 1° 4' 50"      |            | 2∇ = 1° 8' 45"   |            | 2Δ = 1° 9'      |            | 2 <sup>m</sup> = 3° 26' 12" | } For interocular distance of .06.  |
| 3° = 1° 37' 20"     |            | 3∇ = 1° 43' 7"   |            | 3Δ = 1° 43'     |            | 3 <sup>m</sup> = 5° 9' 18"  |                                     |
| 4° = 2° 1' 20"      |            | 4∇ = 2° 17' 30"  |            | 4Δ = 2° 17'     |            | 4 <sup>m</sup> = 6° 52' 24" |                                     |
| 5° = 2° 42' 8"      |            | 5∇ = 2° 51' 53"  |            | 5Δ = 2° 52'     |            | 5 <sup>m</sup> = 8° 30' 5"  |                                     |
| 6° = 3° 14' 50"     |            | 6∇ = 3° 26' 15"  |            | 6Δ = 3° 26'     |            |                             |                                     |
| 7° = 3° 47' 20"     |            | 7∇ = 4° 0' 38"   |            | 7Δ = 4°         |            |                             |                                     |
| 8° = 4° 20' 2"      |            | 8∇ = 4° 33' 10"  |            | 8Δ = 4° 34'     |            |                             |                                     |
| 9° = 4° 51' 40"     |            | 9∇ = 5° 9' 23"   |            | 9Δ = 5° 12'     |            |                             |                                     |
| 10° = 5° 23' 40"    |            | 10∇ = 5° 43' 46" |            | 10Δ = 5° 43'    |            |                             |                                     |
| 11° = 5° 58' 20"    |            | 11∇ = 6° 18' 8"  |            | 11Δ = 6° 17'    |            | 1 <sup>m</sup> = 1° 50'     | } For interocular distance of .064. |
| 12° = 6° 32'        |            | 12∇ = 6° 52' 31" |            | 12Δ = 6° 51'    |            | 2 <sup>m</sup> = 3° 40' 43" |                                     |
| 13° = 7° 4' 50"     |            | 13∇ = 7° 26' 53" |            | 13Δ = 7° 24'    |            | 3 <sup>m</sup> = 5° 30' 41" |                                     |
| 14° = 7° 38'        |            | 14∇ = 8° 1' 16"  |            | 14Δ = 7° 58'    |            | 4 <sup>m</sup> = 7° 21' 23" |                                     |
| 15° = 8° 11' 32"    |            | 15∇ = 8° 35' 39" |            | 15Δ = 8° 32'    |            | 5 <sup>m</sup> = 9° 12' 3"  |                                     |

**Accommodation** is that function of the eye that makes clear vision possible at varying distances.

This adjustment for all distances between the far point, *punctum remotum*, and the near point, *punctum proximum*, is accomplished by the action of the ciliary muscle in changing the form of the lens.

The theory of this process, which has been generally accepted, is that of Helmholtz. The ciliary muscle may be considered as made up of two parts—an outer, formed of longitudinal fibers which arise at the junction of the cornea and sclera, and pass backward to a diffuse attachment in the outer layers of the choroid, called the *tensor choroidæ* or *muscle of Brücke*; and an inner portion, formed of fibers which have an approximately circular course, called *compressor lentis* or *Müller's muscle*. When the ciliary muscle contracts, the choroid and ciliary processes are drawn forward, and by the contraction

<sup>1</sup> This table is taken from Dennett's article on "Prisms" in a *System of Diseases of the Eye*, edited by Norris and Oliver, vol. ii. p. 148.

of circular fibers the circumference of the ciliary processes is narrowed, the zonula or suspensory ligament of the lens relaxed, and the lens, being released from the tension which this has exerted on its capsule, tends to assume a more convex shape. This hypothesis has not been seriously disputed until Tscherning, following in the footsteps of Thomas Young, developed a theory which, as it becomes more generally understood, may in part prove a dangerous rival to that of Helmholtz.

Briefly, Tscherning asserts that the accommodation does not depend on a relaxation of the zonula of Zinn, but on its tension through the agency of the ciliary muscle, whereby the peripheral portion of the lens is flattened and the curve of the anterior surface from an approximately spherical approaches a hyperboloid form. The theories of Helmholtz and Tscherning are illustrated by Fig. 90.

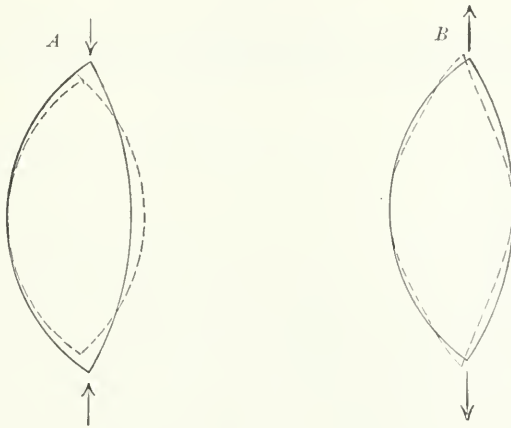


FIG. 90.—A, accommodation according to Helmholtz. The dotted line represents the thicker form assumed by the lens when the traction of the zonula is diminished by the contraction of the ciliary muscle. B, accommodation according to Tscherning. The unbroken lines show the lens at rest. The dotted lines show the change occurring during accommodation, supposed to be due to the traction of the zonula being increased by the contraction of the ciliary muscle. It will be seen that the increased dioptric power of the lens may be obtained either by relaxation of the zonula or by contraction. Tscherning believes that the changes which he has observed in the lens during accommodation prove that the latter theory is correct, while Hess (*Graefe's Arch.*, xlii. 1, s. 288; *Ibid.* xliii. 3, s. 477) opposes it strongly.

As regards the change in the lens itself, Tscherning's view seems abundantly proven by numerous experiments.<sup>1</sup> The action of the ciliary muscle is still undetermined. The older description, as given above, is supported by the diagrams according to Iwanoff,<sup>2</sup> but these results have not been corroborated in recent times, although they appear in some of the best text-books. Tscherning believes that the inner portion of the muscle retracts, having its more fixed attachment posteriorly in the choroid, which is steadied by the tension of the vitreous, this being increased during accommodation by the backward traction of the lens. This retraction of the oblique fibers of Müller's muscle, which is probably not as purely a circular muscle as has heretofore been described, makes traction on the zonula and produces the changes in the lens. The iris as a diaphragm cuts off the peripheral parts of the lens, so that whichever view is taken of the mechanism of accommodation the optical conditions remain practically the same.

By accommodation is meant the muscular effort, the change in the shape of the lens, and the effect produced on vision. The muscular effort is self-evident. The change in the pupillary portion of the lens is seen from the changes which the reflexes called the *images of Purkinje* undergo during accommodation. These images are catoptric—that is, formed by reflection from the cornea, the anterior and the posterior surfaces of the lens. In the

<sup>1</sup> Czsellitzer: "Die Tscherningsche Accommodationstheorie," *Archiv f. Ophth.*, Bd. xlii., iv. Abtheilung.

<sup>2</sup> Graefe and Saemisch: *Handbuch der Augenheilkunde*, Bd. i. p. 276.

pupillary space pictured in Fig. 91 are seen the reflections of two bright squares, one above another: *a* is reflected from the surface of the cornea, *b* from anterior surface of lens, *c* from posterior surface of lens. They are best



FIG. 91.—*A*, reflections during distant vision; *B*, during near vision; *a*, from the cornea; *b*, from the anterior surface of lens; *c*, from posterior surface of lens. It is seen that the reflections from the anterior surface of the lens become smaller, showing that that surface becomes more convex during accommodation. *C*, reflection of a candle flame; *a*, from cornea, sharply defined; *b*, from anterior surface of lens, large and blurred; *c*, from posterior surface of lens, small and inverted.

seen in a dark room when a bright light is thrown on the eye from the side opposite the observer.

During accommodation the reflex of the anterior surface of the lens becomes smaller, which indicates an increase in convexity. In some eyes the image changes its position in a manner to indicate a slight advancement of the surface (Helmholtz), but this is not constant (Tscherning). The posterior surface of the lens becomes slightly more convex, but does not change its position. The pupil contracts during accommodation. According to Tscherning, the portion of the iris between the pupillary border and the periphery retires a little, corresponding to the flattening of the peripheral portion of the lens which he has proven takes place. It has been stated that the tension of the anterior chamber diminishes during accommodation. Foerster (1864) observed that in patients with small keratoceles the protrusion diminished or disappeared during accommodation, to reappear when this was relaxed.

When the accommodation is relaxed the eye is adjusted for a far point. When the greatest accommodative effort compatible with clear vision is made, the adjustment is for the near point.

**Range of Accommodation.**—Accommodation is measured by its effect on the vision, and the effect may be described either in terms of distance traversed between the far and near points, as measured from the eye (*range of accommodation*), or in diopters, expressing the increase of the refractive power of the lens (*amplitude or power of accommodation*). The additional strength which the lens gains may be considered as a separate lens placed in front of the crystalline.

The focal distance of such a lens being *A*, the distance of the far point from the eye *R*, and of the near point *P*, the range of accommodation would be  $A = P - R$ , and, as the refractive power of a lens is the inverse of its focal distance, the refractive power of the lens which we assume to represent accommodation would be

$$\frac{1}{A} = \frac{1}{P} - \frac{1}{R}$$

The application of this to emmetropia is

$$\frac{1}{A} = \frac{1}{P} - \frac{1}{\infty} = \frac{1}{P}$$

the far point being at infinity.

The power of accommodation is measured by the strength of a lens sufficient to give the rays leaving the near point the direction in the vitreous which they would have if without it they came from infinity, or in emmetropia the accommodation is measured by the dioptric value of the near point.

For example, an emmetrope whose near point was at 10 cm. would have 10 diopters of accommodation; thus:

$$\frac{1}{A} = \frac{1}{.10} - \frac{1}{\infty} = \frac{1}{.10} = 10 D.$$

A myope with a far point at 50 cm. (2 diopters of myopia) would have an accommodative ability of 8 diopters; thus:

$$\frac{1}{A} = \frac{1}{.10} - \frac{1}{.50} = 10 D - 2 D = 8 D.$$

In hyperopia only convergent rays are focussed on the retina, and the far point is a virtual focus behind the eye. It has therefore a negative value.

We may best not alter the formula, but remember that a negative sign in its last denominator makes that fraction additive, as seen in the following example, where a person whose hypermetropia is 2 *D*, and whose near point is 10. cm., is shown to have an accommodative power of 12 *D*:

$$\frac{1}{A} = \frac{1}{.10} - \left( \frac{1}{-.50} \right) = \frac{1}{.10} + \frac{1}{.50} = 10 D + 2 D = 12 D.$$

Practically, the accommodation in hyperopia equals the sum of the lens required to bring vision to infinity with that representing the dioptric value of the near distance. It will be seen from what has preceded that the measurement of the far point is equivalent to the determination of the static refraction of the eye. The near point is the nearest point at which very small type can be seen most distinctly, and is usually measured by Jaeger's test type.

**Relative Accommodation.**—Ordinarily, accommodation and convergence are exerted together, the eyes being directed to the point for which vision is adjusted, but a considerable latitude or independence of these functions in their relations to each other is possible. If, for instance, an emmetrope fixes at a point 33 cm. from the eye, the corresponding accommodation would be 3 *D*, but a certain amount of relaxation of accommodation and of additional power is possible with the same convergence. This relative accommodation varies for each point of fixation. The normal relations have been tabulated by Donders.<sup>1</sup>

The practical applications are numerous. A lack of unity between accommodation and convergence is seen in the normal eye at the near point. The function of convergence being stronger than that of accommodation, the absolute near point is attained at a sacrifice of binocular vision, convergence over-acting, and thus reinforcing accommodation. In hyperopia the accommodation required is greater than the convergence, and the same tendency of the two functions to reinforce each other offers a stimulus to the latter which may result in convergent strabismus. In myopia less accommodation is required; accordingly there is less incentive to converge, and insufficiency of convergence or even divergence may occur.

**Presbyopia.**—The power of accommodation diminishes progressively from the earliest youth. As a result, the near point recedes from the eye, until at about the age of forty in emmetropia it reaches the distance of 22 cm., and the strength of accommodation has become about 4.5 *D*. Near

<sup>1</sup> *Accommodation and Refraction of the Eye*, p. 111.



vision then is rendered difficult, and from this time on convex glasses must be used to bring the near point nearer and to compensate for the diminishing power of accommodation. The cause of this change is a physiological sclerosis of the crystalline lens, which renders it less elastic in response to the force of the ciliary muscle. The table (Table II.) and accompanying curve, de-

| Age. | Distance of $P$ in meters. | Distance of $R$ in meters. | Ampli- Presby- tude of opia in A. D. |
|------|----------------------------|----------------------------|--------------------------------------|
| 10   | 0.07                       | $\infty$                   | 14. $D$                              |
| 15   | 0.08                       | $\infty$                   | 12.                                  |
| 20   | 0.10                       | $\infty$                   | 10.                                  |
| 25   | 0.12                       | $\infty$                   | 8.5                                  |
| 30   | 0.14                       | $\infty$                   | 7.                                   |
| 35   | 0.18                       | $\infty$                   | 5.5                                  |
| 40   | 0.22                       | $\infty$                   | 4.5                                  |
| 45   | 0.28                       | $\infty$                   | 3.5                                  |
| 50   | 0.4                        | $\infty$                   | 2.5                                  |
| 55   | 0.66                       | -4. (H. 0.25)              | 1.75                                 |
| 60   | 2.                         | -2. (H. 0.5)               | 1.                                   |
| 65   | -4.                        | -1.33 (H. 0.75)            | 0.5                                  |
| 70   | -1.                        | 0.8 (H. 1.25)              | 0.25                                 |
| 75   | -0.5                       | -0.5 (H. 1.75)             | 0.                                   |
| 80   | -0.4                       | -0.4 (H. 2.5)              | 0.                                   |

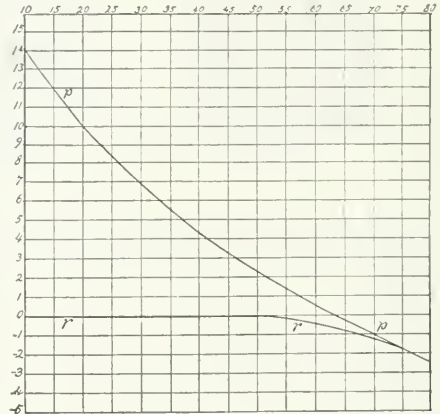


Table II., with the accompanying curve (Fig. 92), shows the relations of age to accommodation and static refraction. The table is taken from Nagel,<sup>1</sup> and is slightly modified. The curve is modified by Landolt from Donders.

vised by Donders, shows the decrease in the amplitude of accommodation as well as the change in the static refraction, beginning at about the age of fifty-five, by which an acquired hyperopia takes place; the curve,  $p p$ , represents the changes in the near point; the curve  $r r$ , the far point.

As has been said, presbyopia begins at the time when near vision becomes difficult. This period varies with the refraction of the eye, for the reason that the strength of the accommodation required to bring the near point to a comfortable distance depends on the position of the far point. Thus in myopia the far point is nearer the eye than in hyperopia, and the same strength of accommodation will continue the range of useful vision for near work at its proper distance later in life; that is to say, presbyopia is postponed in myopia and anticipated in hyperopia as compared with emmetropia.

It will be seen that a myope of 3  $D$  will reach the age of sixty without discomfort, while a hyperope of the same degree would be able to overcome his hyperopia and to bring the near point to the reading distance, at the latest, up to twenty-five years.

It is important to remember that the accommodation cannot be sustained at its maximum. There must always be a reserved power, as in any other continuous work, and that is why the near point is said to be at 22 cm., allowing 0.5  $D$ -1  $D$  reserve above the accommodation required for the average reading distance.

The working distance is decidedly arbitrary, depending on the kind of work done or the habit of the individual as regards the distance the work is held from the eyes and on the visual acuity, for if this is diminished, the work must be brought nearer in order to obtain larger images, and the accommodation must be aided accordingly.

**Visual Acuity.**—Vision is measured by the size of the smallest object which can be recognized at a fixed distance in the most favorable light with the best optical adjustment. The size of the object is expressed by the visual angle formed by lines that pass through its extremities, through the nodal points of the eye, to the inverted image on the retina. The size of the image

<sup>1</sup> Graefe und Saemisch: *Handbuch der Augenheilk.*, Bd. vi. p. 466.

on the retina varies as the distance of the posterior nodal point from the retina, which distance is greatest in myopia and least in hypermetropia. Axial ametropia is referred to, as that is the commonest form.

When the ametropia is corrected by a lens placed at the anterior focus of the eye, the retinal image is the same size as if the eye were emmetropic.

A stronger lens is needed for the correction of myopia the farther the lens is placed from the eye, and a weaker lens suffices for hypermetropia if removed from the eye. Differently stated, this is: a concave lens loses strength and a convex lens gains strength if removed from the eye, which explains the tendency of presbyopes to slide their glasses down the nose as the presbyopia increases. It is obvious that to attain the highest visual acuity for a great distance the eye must be placed in a condition to see to the best advantage; that is to say, the ametropia must be corrected for infinity, consequently the glass that gives the highest visual acuity is the measure of the static refraction.

The distance usually chosen for the examination of vision is 6 m. So great a distance is taken because it is desirable to measure acuity uninfluenced by the effect of accommodation, and rays of light that enter the eye from any point on an object 6 m. away, however wide the pupil, are practically parallel and meet on the retina.

Snellen's type are so devised that each letter subtends an angle of five minutes, each part of a letter and each space being one-fifth of the whole in linear measurement. A visual angle of five minutes has been assumed as representing the average of a great many measurements of the eyes of individuals of all ages, and Snellen acknowledges that a great many young persons have a greater visual acuity.

It has been said above that visual acuity is measured by the ability to recognize an object at a given distance. This means that the parts of which it is composed can be differentiated: each part of one of Snellen's letters subtends an angle of one minute (Fig. 93).

The perception of a single object, however, would not be a reliable test of vision, as its visibility would depend on the intensity of the light by which it was seen, and would be, in some measure, independent of its size and the distance; for instance, a fixed star is visible, although its apparent size is almost infinitely small and its image smaller than one of the perceptive elements of the retina. Two stars, however, cannot be distinguished as separate unless they are about sixty seconds apart; that is, unless the distance between their images on the retina equals at least the breadth of a perceptive element. If the distance were smaller, both images would fall upon the same or upon adjacent elements. In the first case both would produce a single sensation, and in the second case there would be two sensations, but upon adjacent elements, so that it could not be told whether there were two points of light or one which fell upon both elements.

From the fact that the diameter of the cones in the macula corresponds quite closely to the smallest distances between the images of two objects that can be recognized as two,<sup>1</sup> the conclusion has been drawn that the cones are the perceptive elements.<sup>2</sup>

<sup>1</sup> According to Kölliker, the cones in the macula lutea vary from 0.0045 mm. to 0.0054 mm. in diameter, while a visual angle of 60'' covers on the retina a space of 0.00438 mm. and one of 73'' a space of 0.00526 mm.

<sup>2</sup> Helmholtz: *Handbuch der Physiologischen Optik*, Zweite Auflage, p. 256.



Fig. 93.—Two of Snellen's test-type.

Snellen's letters are arranged in lines, over each of which are Roman numerals indicating the distance,  $D$ , at which the letters of that line appear under an angle of five minutes or the distance at which they can be read by an eye of normal vision. The distance at which they can be read by the eye that is being tested is  $d$ . The formula, then, for visual acuity is  $V = \frac{d}{D}$ . As examinations are ordinarily made at a fixed distance of about six meters, " $d$ " is constant, the value of the fractional expression being varied with the value of the " $D$ " which designates the smallest legible letters, thus  $V = \frac{d}{D} = \frac{6}{6}$  is normal vision.  $V = \frac{6}{60}$  indicates that what the patient ought to see at sixty meters he can see at only six meters, an acuity of 0.1. It is best, however, to leave the fraction unreduced, thus recording the exact distance at which the test was made. If vision is inferior to  $\frac{6}{60}$ , the test types may be brought nearer, and the distance recorded at which the largest is read, as  $\frac{3}{60}$ . If this is not enough, the distance may be noted at which the fingers of the outstretched hand can be counted against a dark background, or, still farther, only the movements of the hand may be seen, and finally light perception only, at varying distances, or, simply, the differentiation of light from darkness (L. P.) may be all there is to record.

A better system than that of Snellen is one devised by Monoyer, in which the lines progress in tenths from 1. to 0.1. The regularity of the interval is a decided advantage, and has been utilized by Dennett with the modification that the size of every letter in each line has been so chosen as to ensure its uniform visibility.



FIG. 94.—Test-type for the illiterate.

For the illiterate, characters may be used which can be described without being named, or Burchardt's series of dots may be used. The most common are the E's in different positions (Fig. 94). Guillery proposed to measure the visual acuity simply by the use of a black dot on a white ground. By comparison with the letters of Snellen he found that such a dot seen at an angle of  $50''$  would correspond to the normal visual acuity; at 5 m. it would have a diameter of 1.2 mm. An acuity of one-half would be shown by the ability to see a dot of double the area at the same distance. The dots are placed in various parts of squares and are to be localized by the patient.<sup>1</sup>

**Entoptic Phenomena.**—Objects in the eye in front of the sensitive layer of the retina intercept light that passes through the pupil and throw shadows which under certain conditions can be perceived. Since Listing<sup>2</sup> the examination of objects in our own eyes has been called *cutoptic observation*.

If a clear sky is looked at through a pin-hole in a dark card placed near the anterior focus of the eye—the rays thus reaching the retina parallel—or if a flame at a distance of 5 m. is seen through a strong convex glass held two or three inches from the eye, a bright disk of light will be seen formed by circles of diffusion, upon which various objects are visible: (1) The traces of the lids on the cornea formed by half closing the eyes. These horizontal lines remain an instant after the pressure has ceased, and in some cases show a more lasting effect of constriction, leading to an irritable condition called "tarsal asthenopia."<sup>3</sup> The tears and drops of mucus are seen following the movements of the lids. (2) The lens or some of its parts may become visible if a very small opening is used, the light being homocentric. Physiologically,

<sup>1</sup> Guillery: *Arch. für Augenheilkunde*, xxiii. S. 323.

<sup>2</sup> *Beitrag zur Physiologischen Optik*, Göttingen, 1845.

<sup>3</sup> G. J. Bull: *Trans. Eighth Internat. Ophth. Cong.*, Edinb., 1894.

the radiating star-shaped figure of the lens and numerous small round objects like hyaline globules may be seen. These increase with age until the senile changes, the beginning of cataract, may also become apparent to the possessor in this manner (Donders). (3) In the vitreous there are always floating bodies, cells, and fibers, which as *muscae volitantes* cause alarm to the nervous observer till he is assured of their insignificance. (4) A very interesting application of the entopic method is the observation of the retinal vessels (Purkinje). They may be seen in three ways:

(a) In a darkened room a candle is held at a short distance from the eye which regards the distance. The vessels come into view as dark lines on a yellowish background. They seem to move when the candle is moved.

(b) On looking through a stenopaic opening at the sky, if the opening is kept in motion, the vessels are distinctly seen, even to the smallest around the macula.

(c) If a strong light is focussed on the sclera as far as possible from the cornea, and moved slightly from side to side, the same phenomena occur. The explanation given by Heinrich Müller (1855) is that the shadow of the retinal vessels falls on the sensitive layer of the retina.

In the last experiment Müller measured the movement of a vessel projected on a surface at a known distance, and the movement of the focus on the sclera which produced this excursion, and calculated the distance behind the retinal vessel at which the sensitive layer must lie, his result coinciding very closely with the actual distance between the vessels and the layer of rods and cones.

König and Zumft<sup>1</sup> have recently attempted to apply this principle to the analysis of color vision, and have claimed that different colors are seen at different levels, violet being perceived by the most anterior portion of the sensitive layer, red by the most posterior. Considerable doubt has been raised, however, by Köster<sup>2</sup> as to the accuracy of these statements.

<sup>1</sup> Sitzungsberichte der königlich. preuss. Akademie der Wissenschaft. zu Berlin: Mai, 1894, xxiv.

<sup>2</sup> Graefes Archiv, xli, i, S. 1.



# EXAMINATION OF THE PATIENT AND EXTERNAL EXAMINATION OF THE EYE; FUNCTIONAL TESTING.

BY G. E. DE SCHWEINITZ, A. M., M. D.,

OF PHILADELPHIA.

THE value of case-records is greatly enhanced if a systematic method of examination is pursued with each patient. The following order of examination, based upon the one employed by S. Weir Mitchell in the Infirmary for Nervous Diseases, Philadelphia, is arranged for this purpose:

- Name and residence.
- Age, sex, race, married, single, or widowed.
- Family history: hereditary tendencies; general and ocular health of parents, brothers, sisters, etc.
- Personal history: children, their general and ocular health; miscarriages; menopause; former illnesses; syphilis and gonorrhœa; injuries.
- Occupation: relation of work to present indisposition.
- Habits: brain-use; tobacco; alcohol; narcotics; sexual.
- Date and mode of onset and supposed cause of present trouble; outline of its course.
- Organs of digestion: teeth; tongue; stomach; bowels.
- Organs of respiration: nose; throat; lungs.
- Organs of circulation: heart; pulse; blood.
- Kidneys: examination of urine.
- Abdominal organs: liver; spleen.
- Organs of generation: menses; leucorrhœa; uterine disease.
- Nervous system: intelligence; evidences of hysteria; hallucinations; sleep; vertigo; gait; station; tendon- and muscle-jerks; paralysis; tremor; pain; subjective sensations; convulsions; headaches and their position.
- Eyes: previous attacks of inflammation; injuries; infections; ocular palsy or squint; amblyopia; previous use of glasses; ability to use eyes.
- Direct inspection and examination of eyes: inspection of the skull and orbits (symmetry or asymmetry); lids; ciliary borders; puncta lacrymalia; upper and lower cul-de-sacs; conjunctivæ; caruncles; corneæ (oblique illumination); irides (mobility and color); anterior chambers (depth and character of contents); vision; accommodation; balance of external eye-muscles; mobility of globe; tension; light sense; color sense; fields of vision; field of fixation; ophthalmoscope; ophthalmometer; retinoscope; refraction.

Necessarily the examiner will modify the thoroughness of his investigations according to the character of each case.

**Direct Inspection of the Eye and its Appendages.**—The *lids* should be examined for distended superficial veins, edema, tumors, for example, enlargement of the Meibomian glands, and for anomalies; their edges for inflammation, parasites, misplaced cilia, and small morbid growths; the *puncta* for permeability, deviation or retraction from the globe, pressure at the same time being made over the lachrymal sac in order to express from it, through the puncta, any contained fluid; the *caruncles* and *plicæ* for swelling, foreign bodies, irritation by incurved cilia, and small morbid growths, for instance, polyps or angiomas; the *conjunctival cul-de-sacs* for abnormal

secretion, granulations, foreign bodies, concretions and disturbance of the vascular supply, the examination being carried well up into the upper fornix after thorough eversion of the lid.

In order to *evert the lid* the patient should rotate the eye strongly downward, while the surgeon seizes gently the central eyelashes of the upper lid between the index finger and thumb of his left hand, and draws the lid downward and away from the globe, placing at the same time the point of the thumb of his right hand above the tarsal cartilage of the lid which is to be everted, steadying his remaining fingers upon the patient's brow, and by a quick movement turns the edge of the lid over the point of his thumb, while this is simultaneously depressed. If the patient steadily looks downward during this manœuver there is no difficulty in everting the lid without the aid of the pencil or match-stick so commonly employed as a lever.

When there are no lashes on the upper lid the manipulation is more difficult, but it can be accomplished by pushing the lower lid beneath the margin of the upper in such a manner that it acts as a wedge on which the superior lid is then everted.

The lower lid is everted readily by placing the tip of the fore finger against the edge of the lid and drawing it downward, at the same time pressing the finger backward until the lid is turned over it.

The surgeon should also inspect the skin of the face, examine for scars, and investigate the wrinkles in the forehead and between the brows. The supraorbital ridge, the general character of the orbits, and the position and shape of the globes should next be studied. *Palpation of the orbit* by passing the finger beneath the supraorbital ridge above, along the margin of the malar bone and the superior maxillary below, and to the outer and inner sides, may reveal the presence of accumulations, superficial growths, enlargement of the lachrymal gland, etc. Finally, the action of the orbicularis should be ascertained by causing the patient to close his eyes as if in sleep, and note made of the absence or presence of fibrillary contraction. When the eyes are opened the length, width, and symmetry of the palpebral fissures and the condition of the commissural angles may be studied (see page 31).

**Blood-vessels of the Conjunctiva.**—In health only a few conspicuous blood-vessels are to be observed; in inflammation many more become visible. The conjunctival blood-supply may be conveniently divided, as Mr. Nettleship has done, into three systems:

**System I.**—Posterior conjunctival vessels, whose congestion produces a bright-red, velvety color, moving, on pressure of the eyelids, with the shifting of the conjunctiva, usually associated with muco-purulent secretion and indicating conjunctivitis.

**System II.**—Anterior ciliary vessels composed of perforating and non-perforating arteries and veins. The perforating arteries, which supply the sclerotic, iris, and ciliary bodies are the branches seen in health entering about 5 mm. from the corneal margin, their points of entrance, in dark-complexioned people, often being distinctly tinted.

The non-perforating (episcleral) branches, invisible in the normal eye, produce, when congested, a pink zone surrounding the cornea ("ciliary congestion," "circumcorneal zone"), not moving on pressure of the lids with the shifting of the conjunctiva, unassociated with purulent discharge, and one indication of iritis.

The perforating veins and their non-perforating (episcleral) twigs, when congested, create a zone of dusky hue, often a symptom of glaucoma, or

appear in unequal deep-seated patches of lilac or violaceous color, pointing to cyclitis or scleritis.

**System III.**—Anterior conjunctival vessels and the plexus of capillaries surrounding the cornea, derived from anterior ciliary vessels through whose numerous small branches anastomosis between Systems I. and II. takes place. Their congestion produces a circle of bright-red injection, often partly on the cornea, a sign of inflammation of this membrane, and typified in the early vascular stages of interstitial keratitis.

In addition to these three varieties of congestion numerous departures are noticeable, making it impossible to specify the individual system involved.

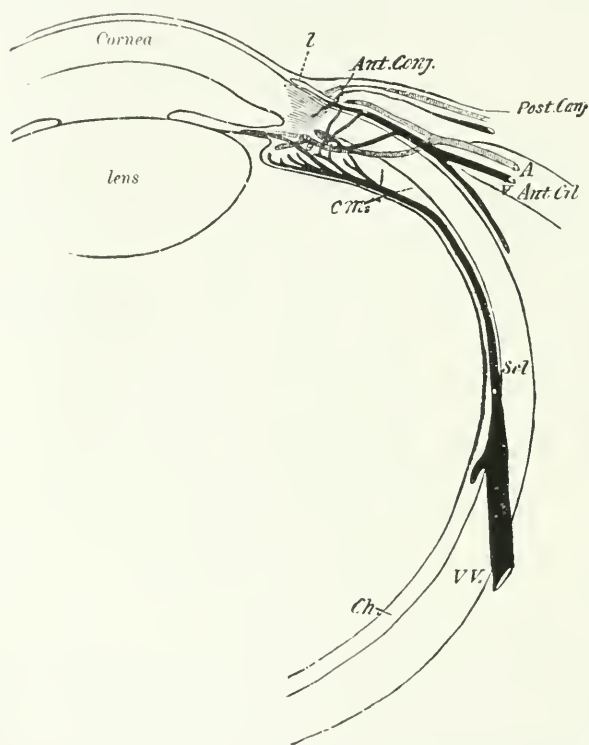


FIG. 95.—Vessels of the front of the eyeball: *cm*, ciliary muscle; *Ch.*, choroid; *Scl.*, sclerotic; *V.V.*, vena vorticiosa; *L.*, marginal loop-plexus of cornea; *Ant.* and *Post. Conj.*, anterior and posterior conjunctival vessels; *Ant. Cyl.*, *A* and *V.*, anterior ciliary arteries and veins (after Nettleship's alteration from Leber).

In these types is found a definite local injection, as the leash of vessels passing to a corneal ulcer; or all systems are commingled in a general inflammation.

**Temperature of the Conjunctival Sac.**—This may be measured with a suitable thermometer having attached to it concavo-convex mercury plates which are placed in the lower conjunctival sulcus, or, more accurately, as in physiological experiments, with thermo-electric couples. Sillex<sup>1</sup> found the temperature of the lower human conjunctival fold to be 35.55° C. (95.99° F.)—*i. e.* about 2° C. lower than that of the rectum,—and in inflamed eyes noted an average increase of 0.98° C. The highest conjunctival temperature is found in acute iritis, but even then does not equal the normal body-temperature.

<sup>1</sup> *Archives of Ophthalmology*, 1893, xxii. p. 451.

**Inspection of the Cornea.**—This will reveal inflammation, ulceration, opacities, the track of former blood-vessels, exudates upon its posterior surface, and foreign bodies. Slight irregularities may be detected by placing the patient before a window, while his eyes are made to follow the uplifted finger held about a foot from his face and moved in various directions; the image of the window-bars reflected from the cornea will be broken as it crosses the spot of inequality. In the same manner abnormalities in the curve of the cornea may be roughly ascertained, because if the curve is normal the reflection does not change, at least in the central portion of the cornea; if the curve is abnormal or the surface of the cornea irregular, there is corresponding distortion in the size or shape of the reflection.

A more accurate method is to employ a *keratoscope*, or *Placido's disk*, as it is called. This instrument consists of a disk shaped like a target, upon

which are drawn concentric black circles, a sight-hole being in the center. The patient is placed with his back to the window, while the surgeon holds the instrument 30 cm. in front of the eye, and, looking through the central aperture, observes the reflections of the circles from the cornea. If these are broken or distorted, the indications of irregularity in the surface are present (Fig. 96). Any irregularity on the surface of the cornea is quickly detected by the method of *keratometry*, especially with the ophthalmometer of Javal and Schiötz (see page




FIG. 96.—Placido's disk or keratoscope.

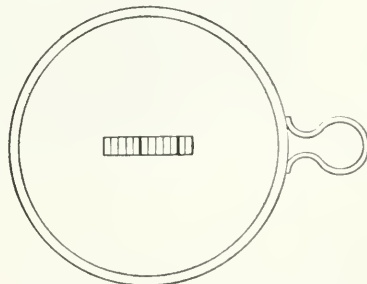


FIG. 97.—Priestley Smith's keratometer.

197), the reflections of the targets being greatly distorted as they cross the point of irregularity.

Abrasions and ulcers, even when minute, may be differentiated by dropping into the eye a concentrated alkaline solution of *fluorescein* (Grübler's fluorescein 2 per cent., carbonate of soda 3.5 per cent.), which colors greenish-yellow that portion of the cornea deprived of its epithelium, while the healthy epithelium, or even that epithelium which is simply roughened and opaque, as in keratitis, remains unaffected. A minute foreign body may thus be located if situated in the centre of an abrasion, because it appears as a black dot surrounded by a green area. So, also, may the progress of a corneal ulcer be studied, the color test differentiating sharply that portion of the ulceration which is still active from that which is covered with new-formed epithelium.

**The Width of the Cornea.**—This may be measured approximately by



holding before it a rule marked in millimeters and noting the number of spaces its width occupies, or, more accurately, by employing Priestley Smith's *keratometer*. This instrument consists of a scale situated between two plano-convex lenses. The surgeon places his eye at the principal focus of the combination, and, holding the scale before the patient's eye, observes that the cornea subtends on the scale exactly its width (Fig. 97). The average horizontal diameter of the normal cornea is 11.6 mm. (Priestley Smith).

**The Sensibility of the Cornea.**—This may be tested by gently touching the surface of this membrane with a wisp of cotton twisted to a fine point. If sensation is intact, the touch will instantly be followed by the reflex action of winking. As a control the opposite eye may be similarly examined. If the cornea is found insensitive, the forehead and face should be examined for areas of anaesthesia either with the point of a moderately blunt pin or with an *esthesiometer*. Thermic as well as tactile sensibility should be investigated.

**Oblique Illumination.**—The surgeon places the patient two feet from the source of illumination and focusses a beam of light with a two-inch or three-inch lens upon the cornea, at the same time observing the surface under

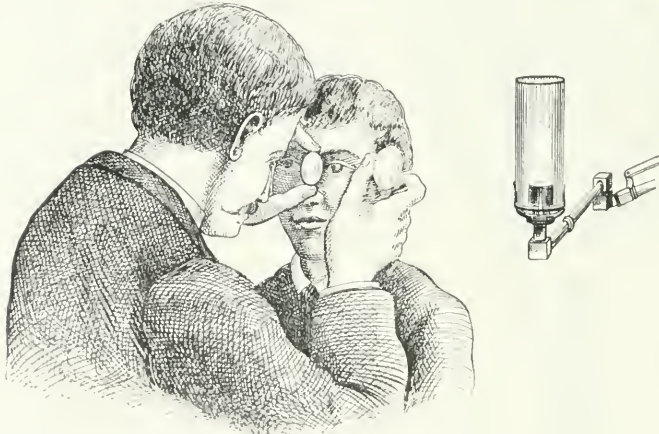


FIG. 98.—Method of oblique illumination.

examination through a lens of the same focal distance, which acts as a magnifier, held between the thumb and fore finger, the disengaged fingers being utilized to elevate the upper lid (Fig. 98). The distance of the lens must be varied slightly to bring the various tissues—the cornea, iris, or crystalline lens—within its focus, the patient being required to look up, down, and to either side while the anterior surfaces and media of the eye are illuminated. To detect a foreign body the light should be directed at an acute angle, but if the pole of the lens is to be examined the light should be thrown perpendicularly into the pupil, the surgeon placing his eye in the same direction without interfering with the light. By this method minute abrasions, foreign bodies, nebulae, and, in short, all corneal changes, may be examined. The character of the aqueous humor, the depth of the anterior chamber, the surface of the iris, synechiae, atrophic fibers, small tumors, and persisting pupillary membrane are readily studied, and, finally, opacities in the anterior capsule and axis of the lens can be investigated, and by focussing deeply even the anterior layers of the vitreous. This routine examination should never be omitted.

Recently Dr. Edward Jackson has designed a *binocular magnifying lens*

for examination of the eye by oblique illumination, which is a material aid. Two lenses are placed side by side, and so joined that the visual line of the right eye pierces the right lens near its optical center, while the visual line of the left eye pierces the left lens near its optical center. This gives each eye an undistorted field all around the point of fixation, and these fields can be combined in full binocular vision.

In place of this lens a *corneal loupe* may be employed. This is a lens, properly mounted, by which the cornea is strongly magnified. A *corneal microscope*, or a specially prepared lens of high power, permits the study of minute changes in this membrane, and is utilized for the examination of traces of former vascularization, and by its help even the circulation of blood in the vessels constituting a pannus may be studied.

**The Color of the Iris.**—Blue and gray are the predominating hues in the irides of the inhabitants of northern countries; brown occurs next in frequency, while the various admixtures produce yellow and green shades. Perfectly black irides are never seen, but dark irides, taking the whole population of the world, are the most frequent in occurrence. With rare exceptions the color of the iris of all new-born children is of a light grayish-blue. The stromal pigment is developed subsequently, and the color of the iris does not become fixed, so to speak, until about the third month.

Slight differences in shade between the two irides are not uncommon. More rarely, even in health, the irides differ in color (chromatic asymmetry), one being brown or greenish, the other blue or gray. Under these conditions one iris usually corresponds in color with the irides of one parent, and the remaining iris with those of the other parent. Instead of uniform pigmentation a single triangular patch or several irregular spots of dark color may appear upon one or both irides (*piebald irides*). When these spots are small they have sometimes been mistaken for foreign bodies. While chromatic asymmetry is perfectly compatible with health, it is stated to be more common in patients with neuropathic tendencies—for example, in chorea and epilepsy. In 25 of 50 cases of chorea of childhood (Sydenham's chorea) examined by the author the irides were equal in color and shade; in the remaining 25 there were slight differences in shade or tone. In only 1 of these 25 was there any true asymmetry of color. In some instances of chromatic asymmetry there is liability to disease, especially to cataract, on the part of the lighter eye. This susceptibility may be present in several members of the same family.

Discoloration from disease causes one iris to be green, while its fellow remains blue. This indicates iritis or cyclitis. It is often an early symptom of inflammation of the iris, and should be looked for in every inflamed eye.

**The Pupil.**—The size of the pupil in health varies with exposure to light and with accommodation and convergence. It is also influenced by age, the color of the iris, and the character of the refraction. Other things being equal, the pupil is generally smaller in old age, in blue eyes, and in eyes with hyperopic refraction, while it is larger in youth, dark eyes, and eyes with myopic refraction. There is no physiological standard on which to base a measurement, but with accommodation at rest the diameter of the pupil varies from 2.44 to 5.82 mm., the average diameter, according to Woinow, being 4.14 mm. Under similar illumination the pupils should be round and of equal size, although a large number of measurements—for instance, those made among healthy military recruits—indicate that slight differences in the width of the pupils are compatible with health.

**Measurement of the Pupil.**—The pupil can be measured approximately by holding before it a rule marked in millimeters and noting the number of spaces its width occupies. The chief objection to this method is, as Edward Jackson points out, that the distance subtended on the rule is less than the diameter of the pupil, in proportion as the distance from the observer's eye is less to the rule than to the pupil. For the purpose of accurate measurement a number of instruments have been devised, known as *pupillometers*. A simple and useful device is one which consists of a scale of circles held close to the observed eye, the scale being slowly rotated until that circle which matches the pupil in size is reached (Fig. 99). Priestley Smith's




Fig. 99.—Simple pupillometer.

keratometer (Fig. 97) can also be employed.

**The Pupil-reactions and Methods of Testing Them.**—A uniform light should be employed and the character of the light should be stated. As Turner insists, the light employed for testing the sensitiveness of the retina or visual center should not be more intense than that to which the eye is usually accustomed. Therefore, except under certain circumstances, examinations made by reflecting light into the eye with a mirror or by passing a flame in front of the eye are not accurate. It is much to be regretted that in recorded examinations such loose statements as "pupils dilated," "pupils contracted," "pupils medium-sized," have been so much used.

**Mobility of the Iris.**—The reflex mobility of the pupil<sup>1</sup> is tested to ascertain the presence of attachments between the iris and the lens (*synchiae*), or immobility from atrophy of the iris, or to examine the sensitiveness to light of the retina or visual center.

(a) The patient, placed before a window in diffuse daylight, with one eye carefully excluded, is directed to look into the distance with the exposed eye, which is then shaded, when, in the absence of abnormalities, a considerable dilatation of the pupil will occur. On removal of the covering hand or card, contraction to the same size as that which existed before the test was applied takes place. This is the *direct reflex action of the pupil*, and is brought about by a muscular contraction of the sphincter of the iris following the stimulation of the optic nerve.

(b) If during this examination the other pupil, which has been shaded by a card or covering hand, is observed, it will be found acting in unison with its fellow. This is the *consensual or indirect reflex action of the pupil*. The iris response to light-stimulus should also be tested with both eyes open and exposed to the same source of illumination. The eyes should then be covered and exposed alternately and the pupil-reactions noted. Under normal conditions the pupils should be equal, not only with both eyes open, but with one eye shaded.

(c) If the patient is required to look into the distance and then quickly direct his eyes at a near object—for example, the point of a pencil held at a distance of about 10 cm.—pupillary contraction occurs under the influence of accommodation and convergence; that is, the sphincter of the iris contracts in association with the ciliary muscle and the internal recti. This is the *associated action of the pupils (convergence-reaction)*. Accommodation in-

<sup>1</sup> It is customary to speak of the action or reaction of the pupil, although really the mobility of the iris is ascertained. For convenience: "mobility of the iris" is synonymous with "pupil-reaction."



creases pupillary contraction, but this does not take place under the influence of accommodation unassociated with convergence. It does occur with convergence without the act of accommodation.

(d) A second reflex action of the iris, the other being its contraction under the stimulus of a beam of light (direct light-reaction, paragraph *a*), consists of a dilatation of the pupil when some cutaneous nerve is stimulated, especially one in the skin of the neck. This is the *skin reflex* (*pain-reaction*), and may be tested by pinching the skin of the neck, or, better, by using a faradic brush.

(e) Finally, the reaction of the iris to the mydriatics and myotics may be tried, especially that produced by cocaine, which in the normal eye should cause nearly full mydriasis and widening of the palpebral fissure from stimulation of the sympathetic. (For the physiology of pupil-phenomena see page 96.)

**Abnormal Pupillary Reactions, or the Pupil in Disease.**<sup>1</sup>—When about to investigate pupil-reactions six possibilities, as William McEwen points out, should suggest themselves to the examiner—namely, (*a*) The action of drugs; (*b*) ocular disease or optical defects; (*c*) spinal or sympathetic lesions; (*d*) localized cerebral lesions in special centers or tracts; (*e*) abeyance of brain-function; (*f*) cerebral irritation. For the convenience of ascertaining in what portion of the path of the pupil-reflex the lesion is situated Magnus<sup>2</sup> has divided it into the following three portions:

1. *The Centripetal Part, including the Optic Nerve, Chiasm, Tracts, and Connecting Fibers to the Cortex.*—If there is interruption of the conducting power of one optic nerve—for example, the right—illumination of the pupillary area on that side fails to elicit either the direct or the indirect reflex action of the pupil. On the other hand, illumination of the left eye causes its own pupil to contract (direct reflex), as well as the pupil of the right or affected eye (indirect reflex).

Lesions affecting the chiasm and the tract are accompanied by hemianopsia (see page 481) and the special pupillary phenomena which belong to this condition, while lesions in the optical pathway between the corpora quadrigemina and the cortex, although accompanied by probable changes in the visual field, are unassociated with pupillary disturbances.

2. *The Part of the Reflex Ring which carries the Light Impulse from the Corpora Quadrigemina to the Oculo-motor Nuclei (Mequet's Fibers).*—If both sides are affected, neither pupil reacts to the impulse of light falling on either eye, but there is normal reaction to accommodation and convergence. (See Argyll-Robertson symptom, below.)

3. *The Centrifugal Portion of the Reflex Ring (the Nucleus of the Sphincter of the Iris, the Third Nerve, and the Termination of the Third Nerve in the Iris).*—If the right nucleus is affected, the direct light-reflex action of the right pupil is abolished, and also its indirect reflex. A beam of light directed into the left eye is followed by pupil-reaction in that eye (direct reflex). Pupil-reaction in that eye also follows light stimulus of the opposite or right eye (indirect reflex), but is somewhat lessened in degree. The pupils react normally to accommodation and convergence, and are unequal, the right being the wider.

If the trunk of the right oculo-motor is affected, there is pupillary immobility under the influence of light directed into the right eye, and also when it is directed into the left eye, as well as loss of accommodation upon the right side. Light falling into the left eye produces on this side a normal reaction which is also manifested if the light is directed into the opposite eye. The pupils are unequal, the right being the larger. Similar conditions arise if the peripheral fibers of the oculo-motor at their termination in the iris are affected upon one side.

We have now to consider a little more in detail:

1. **Dilatation of the Pupil (Mydriasis).**—This occurs in ocular disease—for instance, glaucoma—in cases of non-conductivity of light (optic-nerve atrophy), in orbital disease, and under the influence of mydriatic drugs. It is further seen in fright, emotion, anemia, in depressed nervous tone, neurasthenia, aortic insufficiency, and irri-

<sup>1</sup>The following paragraphs are abstracted from the author's chapter on "Diseases of the Optic, Oculo-motor, Pathetic, and Abducent Nerves," in *A Text-Book of Nervous Diseases by American Authors*, edited by F. X. Dercum, 1895, pp. 794-803.

<sup>2</sup>*Klin. Monatsbl. f. Augenheilk.*, xxvi. p. 255.



tation of the cervical sympathetic. It is noticed in vomiting, forced respiration, and anemia of the brain—for example, syncope—and is said to be present in persons of low mental development.

In disease of the nervous system dilatation of the pupil, when of cerebral origin, indicates extensive lesion; when of spinal origin, irritation of the part (McEwen). Systematic writers have divided dilatation of the pupil into *irritation-mydriasis*, caused by irritation of the pupil-dilating center or fibers, and *paralytic mydriasis*, caused by paralysis of the pupil-contracting center or fibers, or by failure of the stimulus to be conducted from the retina to the center.

The former is apt to be seen in hyperemia and irritation of the cervical portion of the spinal cord, in spinal meningitis, in cases of tumor of the spinal cord, and also, under certain circumstances, in tumor of the cerebral contents, in psychical excitement—for example, acute mania—and in *tabes dorsalis* and progressive paralysis of the insane.

The latter, which is also known as *iridoplegia*, is found in disease at the base of the brain affecting the center of the third nerve, in pressure of the cerebrum when in great amount, as from hemorrhage, tumors, advanced thrombosis of the sinuses, or large abscesses; also in the late stages of meningo-encephalitis. It is said to be present in acute dementia when there is edema of the cortex, and is found in cerebral softening. Hemorrhage into the centrum ovale and cerebral peduncles also produces mydriasis (McEwen).

**2. Contraction of the Pupil (Myosis).**—This appears in congestion of the iris, paralysis of the sympathetic and also of the fifth nerve, in certain fevers, in plethora, venous obstruction, mitral disease, and under the influence of myotics.

If the myosis is of cerebral origin, it indicates an irritative stage of the affection; if of spinal origin, a depression, paralysis, or even destruction of the part (McEwen). Systematic writers divide contraction of the pupil into *irritation-myosis*, caused by irritation of the pupil-contracting center or fibers, and *paralytic myosis*, caused by a paralysis of the pupil-dilating center or fibers, or by a combination of both.

*Irritation-myosis*, as just noted, is found in the inflammatory affections of the brain and its meninges—*e. g.* meningitis, abscess (at first the myosis is on same side as lesion), and beginning sinus-disease. According to the rule previously given, myosis may change to dilatation if the products of disease become excessive; hence the serious prognostic import of mydriasis under these circumstances. Myosis is seen in the early stages of cerebral tumor, in small hemorrhages into the cerebellum, and at the onset of cerebral apoplexy. Berthold, quoted by Swanzy, uses myosis as a diagnostic symptom between apoplexy and embolism. McEwen points out that the convulsions arising from meningo-encephalitis are accompanied by myosis, while those due to epilepsy are usually associated with mydriasis. Apoplexy of, or pressure upon, the pons is associated with myosis.

*Paralytic myosis (spinal myosis)* occurs in lesions of the cord above the dorsal vertebra. It is especially noteworthy in *tabes dorsalis*. At first the pupil reacts to light and convergence, but later exhibits the *Argyll-Robertson phenomenon* (or *reflex iridoplegia*): that is, it responds only slightly or not at all to the light-impulse, but the associated action of the iris—or, in other words, the contraction of the pupil in accommodation and convergence—is preserved. The lesion under these circumstances is probably in the fibers which pass from the proximal end of the optic nerve to the oculomotor nuclei. Turner contends that a single lesion in the fore part of the oculomotor nuclei in the Sylvian gray matter is the cause of both myosis and reflex iridoplegia.

Paralytic myosis is also met with in paralysis of the insane, pseudo-dementia paralytica of syphilitic origin, bulbar palsy when complicated with progressive muscular atrophy or sclerosis of the brain and spinal cord, and, according to Mills, in some forms of multiple neuritis. The iris reacts peculiarly to mydriatics, which dilate this type of pupil only partially, and their effect is for a long time manifest. Cocain, however, readily expands the small pupil of reflex iridoplegia (Heddeus). Myotics contract it *ad maximum*.

*Unilateral reflex iridoplegia*, or that condition when one pupil is unaffected by varying degrees of illumination of both eyes, but reacts to accommodation, the unaffected pupil responding to separate light-stimulus of either eye, may exist with or without mydriasis, and usually is wider than its fellow. It is seen in *tabes dorsalis* and syphilitic cases. It is probably due to lesion in the sphincter nucleus. It should be distinguished from unilateral reflex blindness (see ¶ 1, p. 149).

The reverse of the Argyll-Robertson symptom has been observed, and indicates disease in a special part of the oculomotor nucleus.

**Unequal pupils (anisocoria)** are rarely seen in health, although it is stated by one observer (Iwanow) that among 134 healthy military recruits the right pupil was

larger in 49 and the left in 53, equal width being found in only 12. If there is recent wide dilatation of one pupil and no disease of the eye, the instillation of a mydriatic may be suspected. Unequal pupils occur in eyes with widely dissimilar refraction if one eye is blind, in aneurysm, dental disease, traumatism, and in diseases of the nervous system. If the disease is cerebral, unequal pupils denote unilateral or focal disease. They are not uncommon in tabes, disseminated sclerosis, and paralytic dementia.

**Varying inequality** of the pupils, or a mydriasis now occurring on the one side and now on the other, is, according to Von Graefe, a serious premonitory symptom of insanity.

**Special Pupillary Phenomena.**—The hemiopic pupillary inaction is referred to on page 480. The *cerebral cortex reflex of the pupil* (Haab's reflex) consists of a marked bilateral pupillary contraction which takes place if the patient sits in a darkened room and directs without change of accommodation or convergence his attention to a bright object already present within the compass of the field of vision.

Harold Gifford has described an *orbicularis pupillary reaction*: that is, a contraction of the pupil which takes place when a forcible effort is made to close the lids. The discoverer explains this as the result of an overflow stimulus, attempted closure of the lids exciting in the nucleus of the orbicularis fibers of the facial an activity which is transferred to the pupil-contracting center. The test is of use in determining whether the pupil sphincter is paralyzed.

**Paradoxical Pupil-reactions.**—Dilatation of the pupil under the influence of light-stimulus, and contraction when it has been shaded, have been described in cases of meningitis. A good deal of doubt has been cast upon this type of pupil-reaction.<sup>1</sup>

**Hippus**, which is a normal phenomenon for a few seconds after light-stimulus to the retina and optic nerve, consists of a rhythmical contraction and dilatation of the pupil occurring without alteration of illumination or fixation. It is seen in cerebro-spinal sclerosis, disseminated sclerosis, neurasthenia, hysteria, psychical disturbances, epilepsy, and acute meningitis in its early stages.<sup>2</sup>

**Testing Acuteness of Vision.**—For the purpose of determining acuity of sight test-types are employed, in which the letters are of various sizes and are constructed according to the methods described on page 138.

Inasmuch as many good eyes possess a vision of five-fourths of the standard angle, Dr. James Wallace of Philadelphia and Dr. Culver of Albany have arranged a series of test-types in which, instead of an angle of five minutes, one of four minutes has been substituted as the basis of each letter.

Dr. Randall points out that the order of the letters should be adjusted so as to bring the confusion-letters in the same alternation. It is preferable to have large letters at the top of the card, no particular advantage accruing from the inverted arrangement. The color of the card is of importance, a cream color verging on the India tint giving the best definition through lessening of irradiation (Randall). White letters on a black background are also employed.

When it is desired to test the acuity of sight, the patient is placed 6 meters from the type-card, in a well-lighted room, and each eye is tried separately. If the letters of No. 6 (20 feet, approximately) are read, vision is normal or 1, but if at the same distance no smaller letters than those numbered 18 (60 feet) can be discerned, vision is  $\frac{1}{3}$ . It is usual to express these results accord-

ing to the formula,  $V = \frac{d}{D}$ , in which  $V$  stands for visual acuteness,  $d$  for the distance of the patient from the card, and  $D$  for the distance at which the type should be read, so that in these instances the vision would be recorded  $\frac{6}{6}$  and  $\frac{6}{18}$ , or in feet  $\frac{20}{XX}$ ,  $\frac{20}{LX}$  (see also page 140).

Any other distance may be chosen, provided it does not place the patient

<sup>1</sup> For a full account of this condition see *Gaz. hebdom.*, No. 62, 1896.

<sup>2</sup> The author desires to acknowledge much indebtedness to Swanzy's chapter on "The Motions of the Pupil" in the preparation of the section devoted to the pupil.

closer to the test-card than 3 meters, at which close range the function of accommodation would introduce an element of inaccuracy. Thus, the scale made use of by De Wecker and elaborated by Oliver assumes  $\frac{5}{6}$  ( $\frac{15}{XV}$ , approximately), instead of  $\frac{6}{6}$  as  $\frac{1}{1}$ . In like manner, a 4-meter distance may be utilized, as has been done by Edward Jackson. Rays coming from letters at 6, 5, or 4 m. have so little divergence when they reach the eye that they are usually considered parallel; hence if the patient sees distinctly at this distance, his vision is perfect at the longest range. In point of fact, however, as Frederick K. Smith has insisted, there is an appreciable divergence of rays from the distances mentioned, equivalent respectively to  $\frac{1}{6}$ ,  $\frac{1}{5}$ , and  $\frac{1}{4}$  diopter lens. In the final adjustment of glasses this divergence should be recognized.

For the purpose of a control test, and also for determining the visual acuity of illiterate persons, cards are employed on which a number of black dots and disks of various sizes are placed, which should be counted at different distances. Among the best known of these are Burchardt's "international tests." For the same reason Edward Jackson has designed a visual test which is an incomplete square, the incomplete side being turned successively in different directions (see also page 140). A useful test for children may be constructed by printing on a card small pictures of well-known objects which in size shall approximately conform to the standard angle. Such a series has been published by Dr. Wolffberg of Breslau.

If the patient fails to decipher the largest letter at the distance employed, he should be moved closer to the card. Thus, he may be unable to read the type numbered 60 at 6 m., but may discern this at 4 m.,  $V = \frac{4}{6}$  or  $\frac{1}{1.5}$  of normal. Still further depreciation of visual acuity is recorded by requiring the subject to count the outstretched fingers at various distances ( $\frac{1}{2}$ , 1, or 2 m.),  $V =$  counting fingers at the distance measured. When the ability to distinguish form (qualitative light-perception) no longer exists, the perception of light should be tried by alternately screening and shading the eye, or by illuminating the eye with light reflected from a mirror or focussed through a magnifier.

**Light-sense.**—Having determined the acuity of vision by means of the test-letters, the examiner has ascertained the form-sense, and may proceed to

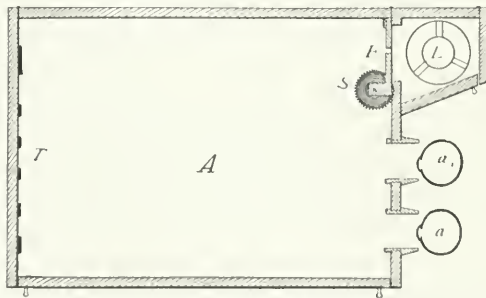


FIG. 100.—Photometer of Förster (Fuchs).

investigate a second subdivision of the sense of sight, the light-sense, which is the power possessed by the retina, or center of vision, of appreciating variations in the intensity of the source of illumination. An instrument called a *photometer* is employed for this purpose, and consists essentially of an apparatus by which the intensity of two sources of light may be compared—as, for



example, in the apparatus of Izard and Chibret. The patient, looking into the instrument, sees two equally bright disks. One disk is now made darker, and the power of the eye to perceive the difference in the illumination of the two disks is ascertained; or one disk is made entirely dark and then gradually illuminated, and the smallest degree of light noted by which the patient can perceive the disk coming from the darkness. The former is called *light-difference* (L. D.), and the latter *light-minimum* (L. M.).

Other instruments have been invented by Förster, Landolt, and R. Wallace Henry.<sup>1</sup> By means of Förster's photometer (Fig. 100) the lowest limit of illumination with which an object is still visible (the *minimum stimulus*) is ascertained. The following description is taken from Fuchs:

"A box, *A*, blackened on the inside, bears on its anterior wall two apertures for the two eyes, *a, a*, which look through these apertures at a plate, *T*, which is fastened upon the posterior wall, and upon which large black stripes upon a white ground are placed as test objects. The illumination is produced by a candle of one-candle power, *L*, the light from which falls through a window, *F*, into the interior of the box. In order to make the illumination perfectly uniform, the window is covered with paper which is made translucent by impregnating it with fat. By a screw, *S*, the size of the window can be altered from complete closure up to an aperture of 5 square cm. The patient is made to look into the apparatus with the window closed, and the plate therefore unilluminated. Then the window is slowly opened until the stripes upon the plate can be recognized. The size of the opening requisite for this purpose gives a measure of the light-sense of the person examined. In conducting this examination the precaution must be adopted of making the patient stay beforehand in the darkness."

Some information in regard to the light-sense may be obtained by testing the acuity of vision on two cards under a different degree of illumination, and by comparing the results with a similar examination of a subject believed to have normal power of appreciating different degrees of illumination. The patient with normal light-sense will be able to recognize the printed letters when the patient with defective light-sense is unable to read them. It is very important in many cases, especially of slight retinal change, to ascertain the acuity of sight under full and under diminished illumination.

**Color-sense.**—A third subdivision of the sense of sight is the color-sense, or the power which the retina has of perceiving color, or that sensation which results from the impression of light waves having a certain refrangibility. This examination is of especial interest in the detection of *color-blindness* (see page 603).

**Measurement of the Vision for Colors.**—Various methods are employed for ascertaining the qualitative and quantitative vision for colors. Direct vision for colors may be studied by placing the patient at a given distance—for example, 5 m.—from a chart or disk of graduated colors. In the scale of De Wecker and Masselon the colored surface, 2 cm. square, should be recognized at 5 m.; that is, the chromatic vision  $V$  ( $C$  or  $C' = 1$ ); if a colored test must be four times this size in order to be recognized,  $C' = \frac{1}{4}$ , etc. (True and Valude). Charles A. Oliver has designed a convenient apparatus for measuring the color-sense in this manner at a given distance, and has found that red requires  $2\frac{2}{3}$  mm. of surface exposure to be properly recognized by the normal eye at 5 m. distance; yellow, a slightly increased area; blue,  $8\frac{3}{4}$  mm.; green,  $10\frac{3}{4}$  mm.; and violet,  $22\frac{3}{4}$  mm.

**Selection Tests.**—Usually one or other of the methods which consist essentially in testing the power to match colors conveniently used in the form of colored yarns is employed. Practically, all of these tests are modifications of Holmgren's wools, a specially commendable method being that devised by

<sup>1</sup> *Ophthalmic Review*, xv., Feb., 1896.



Dr. William Thomson. (For the full consideration of these tests consult page 603.)

**Special Tests.**—In order to obviate the change which occurs in the color of yarns, etc. the color-sense may be investigated by the *spectroscope*, which, however, is not convenient for office-work. The changeable colors, which are colored mixtures like those of wools, may be produced by passing polarized light through a quartz plate and again through a Nicol-prism.

The following account, condensed from Carl Weiland's<sup>1</sup> description of the Javal-ophthalmometer as a *chromatometer*, gives the essential points of instruments constructed for this purpose, and of his own happy modification of the ophthalmometer :

In the *color-measurer* of Rose the light is passed through a Nicol-prism first, and then by a diaphragm through a double refracting prism, from where it enters first a quartz plate cut at right angles to its optic axis, and finally a second Nicol-prism. Two circles of complementary colors are thus produced, which change continually when the upper quartz and Nicol-prism are rotated, but always remain complementary to each other. König's *ophthalmo-leukoscope* is like Rose's instrument, except that the first Nicol-prism is wanting and that quartz plates of different thickness—5, 10, or 15 mm.—are used, according to the degree of color-saturation required.

In Chibret's *chromato-photo-optometer* the quartz plate is cut parallel to its optic axis, and the change in colors is obtained by inclining the plate at different angles to the line of vision. As these instruments are expensive, Weiland has devised a *chromatometer* which he describes as follows :

The color attachment to Javal's keratometer consists "of a straight metal tube, about  $1\frac{1}{2}$  inches in diameter, reaching from the place where the patient's cornea usually is to about the beginning of the barrel of the telescope, and so fastened to the head-rest that its axis coincides with the axis of the instrument. At the front part of this color-tube there is a plane glass plate behind which a Nicol-prism is fastened in a cork. From this prism the polarized light passes by a round diaphragm through a quartz plate, cut at right angles to its axis and about 5 mm. thick.

"The patient, looking with the Javal through this tube, will see two large color-fields partially overlapping each other. These color-fields are of complementary hues, while the place of overlapping shows white; provided, of course, that white light as reflected from a white surface, like a piece of white paper, is employed in this experiment. If now the arc of Javal be rotated, while the color-tube remains in the same position, the colors will change continually, but always remain complementary, returning, however, to their original hues after the arc has been rotated through 90°.

"For the purpose of examination, place the patient's eye at the ocular of the instrument, after you have first looked in yourself and given to the new color-tube such a position that blue and yellow appear, because thus most color-blind persons will recognize two different colors. Now ask the patient whether the two colors are exactly alike or at least shades of the same color. If he answers *No*, turn the barrel of the Javal slowly through 90°, telling the patient to stop you as soon as the two colors are the same. If he has good color-sense he will always see two different colors, but if he is color-blind, he will find that in a certain position of the arc the two colors will appear alike, or at least as much alike as if they were shades of the same color. These colors will usually be green and rose for a green-blind person, while the red-blind person generally selects a more bluish-green and a rose with much more red in it. This suffices to prove that the case is color-blind."

**Pseudo-isochromatic Tests.**—According to Mauthner, certain colors which the normal eye differentiates appear to the color-blind person "falsely of the same color"—*i. e.* pseudo-isochromatic. At one time the color-blind subject will describe as alike a row of colors which are not so; at another time, when the test relates to the recognition of letters or signs on a colored ground, he will not see them, especially when the color of the ground and the letters (figures, signs, etc.) are pseudo-isochromatic and equally clear.

Daac has placed upon a card on which are fastened ten horizontal rows of variously colored wools one row which contains only red wools, one which con-

<sup>1</sup> *Archives of Ophthalmology*, xxiv., 1895, p. 349.

tains only green, and one which contains only purple. In the other seven rows the various colors are placed next to each other. The color-blind person designates rows as of the same color when this is not the case and the reverse. A test of this character, according to Mauthner, is a *positive pseudo-isochromatic* test, because it depends upon the positive expressions of the patient in regard to color similarity.

Of the *negative pseudo-isochromatic* tests—negative because, according to Mauthner, they depend upon the fact that the color-blind person does not read figures or letters which are drawn upon a pseudo-isochromatic ground—the plates of Stilling may be mentioned (see page 604). Pseudo-isochromatic powders have also been prepared by Mauthner for the same purpose.

**Simultaneous contrast tests** based upon experiments with colored shadows are not satisfactory in practical work. Meyer's discovery that if a gray ring or border is placed upon a colored—for example, red—piece of paper, and then covered with tissue-paper, it will appear to the normal eye in the complementary color—that is, green—has been utilized for practical work, particularly in the letters devised by Pflüger. These consist of black or gray letters upon a colored ground. The letters are then covered by tissue-paper and appear in the complementary color.

**Lantern-tests** are sometimes employed, and are of great value in the examination of railroad employes (see page 604).

**Accommodation** is measured in practical work by finding the nearest point at which fine print can be clearly deciphered. The types most frequently adopted are those known as Snellen's 0.5 or Jaeger's 1. Frequently, however, the types in common use are very badly printed and constructed. The letters should be so arranged that they subtend the standard angle of five minutes at a given distance; for example, 25 cm., 50 cm., etc. Ordinarily, these letters are arranged upon suitable cards. Excellent series have been published by Schweigger, by James Wallace, and by Charles A. Oliver.

In order to study the phenomena of accommodation the student should record—(1) The nearest point of perfectly distinct vision attainable with the smallest readable type, or the *punctum proximum* (abbreviated *p. p.*, or simply *p.*). (2) The far point of distinct vision, or the *punctum remotum* (abbreviated *p. r.*, or simply *r.*). (3) The *range, amplitude* of accommodation, or the expression of the amount of accommodative effort of which the eye is capable. This is expressed in the number of that convex lens placed close to the cornea whose focal length equals the distance from the near point to the cornea, and which gives rays a direction as if they had come from the far point; thus, if the near point be at 10 cm., the lens which expresses the amplitude of accommodation is  $+ 10 \text{ D. } \frac{100}{10} = 10$ . A convenient measure is a stick marked

on one side in inches and fractions of an inch, on the other side in millimeters and centimeters; on the edge the amplitude of accommodation is expressed in diopters. (4) The *region* or the *space* in which the range of accommodation is available. (5) *Relative accommodation*, or that independent portion of this function which can be exercised without alteration in a given amount of convergence, and is divided into a *negative* portion, or that portion which is already in use, and a *positive* portion, or that portion which is not in use. If the patient is unable to read the fine test print at any distance, a convex lens should be placed before the eye and the near point and far point recorded with its aid (see also page 134).

**Mobility of the Eyes.**—This is tested by causing the patient to follow with his eyes, the head remaining stationary, the movements of the uplifted

finger, which is directed to the right, to the left, upward, and downward. Both eyes must be observed, and note made of any lagging in their movements or of the failure of either eye to turn into the nasal or temporal canthus. At the same time, the relation of the movements of the upper lid to those of the eyeball is recorded. The attention of the patient must be centered upon the moving finger, and allowance should be made for the imperfect mobility of highly myopic eyes. Any asymmetry of the skull, or difference in the level of the two orbital margins, may be observed, because such conditions are not infrequently associated with ametropic eyes, especially when the two eyes possess great inequality in refractive conditions.

**Investigation of the Balance of the External Eye-muscles.—**

Under normal conditions perfect equilibrium of the external eye-muscles is present, but preponderance, for example, of the power of the external recti, or *vice versá*, produces a tendency to divergence or convergence, which, however, is overcome, with the preservation of binocular single vision, in spite of the disturbed equipoise. This condition was named by Von Graefe *dynamic strabismus*. It is frequently designated *insufficiency of the ocular muscles*. Disturbance of the normal balance (*imbalance*, as it is now called) creates a tendency for the visual lines to depart from parallelism, or the various *phorias* of G. T. Stevens's classification. In order to ascertain the condition of the ocular muscles, in so far as their balance is concerned, we may employ the following tests:

(1) Approach the finger to within a few inches of the eyes, which are steadily fixed upon its tip, and note if a convergence to a distance of 8 cm. ( $3\frac{1}{2}$  in.) is attainable. If one eye deviates outward before this point is reached, weakness of the interni is present, the eye possessing the weaker internus usually being the one which exhibits the deviation. This test is a rough one, and valuable chiefly for ascertaining which of the interni is the weaker.

(2) Require the patient to fix upon a fine object, as a pin-point, held below the horizontal, 20 or 25 cm. from the eye, and, in order to remove the control of binocular vision, cover one eye with a card or the hand, and observe whether the eye under cover deviates inward or outward, and returns to fixation when the cover is removed. If the patient fixes the object accurately, and the manipulations of covering and uncovering first one eye, and then the other, are rapidly performed, trustworthy results will be obtained. In general terms, each millimeter of movement of the deviating eye corresponds to  $2^\circ$  of insufficiency as measured by prisms. In the case of the interni, if the covered eye moves in to fix, with several distinct impulses, each impulse should be multiplied into the foregoing result (Randall).

(3) Produce vertical diplopia with a prism, and test the functions of the lateral muscles at a distance of 6 m.

A small flame is placed against a dark background at 6 m. from the patient and on a level with his eyes. In an accurately adjusted trial frame a prism of  $7^\circ$  is inserted, base down, before one eye—for example, the right. Vertical diplopia is induced, and the upper image belongs to the right eye. If the flames stand one directly over the other, there is no inclination to divergence or convergence. If the upper image stands to the left, there is weakness of the interni; if to the right, of the externi. That prism placed with its base in or out before the left eye, according to circumstances, which brings the two images into a vertical line, measures the degree of the deviation.

Thus the presence or absence of *lateral insufficiency* is determined.

(4) Produce lateral diplopia, and test the functions of the vertical muscles at a distance of 6 m.



The patient is seated as before, and a prism of sufficient strength to induce homonymous diplopia is placed before one eye—for example, the right—*i. e.* with its base toward the nose. If the images are on the same level, no deviating tendency is present. If the right image rises higher than the other, the visual line of the right eye tends to be lower than that of its fellow, and there is *insufficiency of the vertical muscles*. That prism, placed with its base down before the left eye, which restores the images to the horizontal level measures the degree of deviation.

(5) Produce vertical diplopia, and test the functions of the lateral muscles at the ordinary working distance, or 30 cm. For this purpose it is customary to employ the equilibrium test of Von Graefe, in which a card, having upon it a large dot through which a fine line is drawn, is held 25 or 30 cm. from the eyes, diplopia being induced by means of a prism of  $10^\circ$  or  $15^\circ$ , base up or down, before one eye. A more accurate test-object is a small dot and fine line, or a single word printed in fine type, requiring accurate fixation and a sustained effort of accommodation. If, the prism being placed base down before the right eye, the images stand exactly one above the other, equilibrium is evident; if the upper image (image of the right eye) stands to the left of the lower image, there is *crossed lateral deviation*; and that prism, placed before the left eye with its base toward the nose, which restores the image to a vertical line measures the tendency to divergence, *exophoria*, or insufficiency of the internal recti. If the upper image stands to the right of the lower, there is *homonymous lateral deviation*; and the prism placed before the left eye, with its base toward the temple, which restores the images to a vertical line, measures the tendency to convergence, *esophoria*, or insufficiency of the external recti.

(6) Ascertain the power of adduction (prism-convergence), abduction (prism-divergence), and sursumduction (sursumvergence) by finding the strongest prism which the lateral and vertical muscles can overcome.<sup>1</sup>

Beginning with *adduction*, find the strongest prism placed before one eye, with its base toward the temple, through which the flame still remains single. The test should begin with a weak prism, the strength of which is gradually increased until the limit is ascertained. This varies from  $30^\circ$  to  $50^\circ$ . In this test, if diplopia occurs when, for example, the strength of the prism reaches  $20^\circ$ , single vision may not return until the prism has been reduced, for instance, to  $10^\circ$ . The space between the greatest and least power of adduction has been described as the "region of diplopia" (Reeves, Lippincott, Gould).

In like manner *abduction* is tested, the prism now being turned with its base toward the nose;  $6^\circ$  to  $8^\circ$  of prism should be overcome. The ratio between adduction and abduction should be 6 to 1 (Stevens)—*i. e.* if adduction is  $48^\circ$ , abduction should be  $8^\circ$ , but, according to Risley, in carefully corrected or emmetropic eyes the ratio is 3 to 1.

*Sursumduction*, or the power of uniting the image of the candle flame seen through a prism placed with its base downward before one eye with the image of the same object as seen by the other eye, is ascertained by beginning the trial with a weak prism,  $\frac{1}{2}^\circ$  or  $1^\circ$ , and gradually increasing its strength. The limit is usually  $3^\circ$ , but may be as high as  $8^\circ$  or  $10^\circ$ .

If the eyes of the patient under examination are ametropic, the proper

<sup>1</sup>The words "power of adduction," etc. are here used with the significance ordinarily attached to them. For another consideration of this matter the student should read the paragraphs relating to the same subject in Dr. Duane's discussion of "The Anomalies of the Ocular Muscles," p. 503.



correcting lenses should be placed before them, and the examination for the various forms of insufficiency made through this glass. It is, moreover, exceedingly important that the correcting glass should be accurately centered; otherwise, in a lens of considerable thickness, a prismatic effect would be produced which would utterly preclude accurate determination of the muscular conditions, especially of the vertical muscles, where the search for fractions of a degree of deviation is sometimes necessary. If the muscular examinations have been undertaken as part of a routine preliminary investigation of an eye, they should be repeated after the refraction has been accurately determined, and, if anomalous, corrected.

Practically, all of the examinations for muscular errors can be made with a series of prisms and a trial frame, but they are facilitated by the use of certain instruments of precision, especially some form of Herschel or *revolving prism*, the one devised by Rislely being the best (Fig. 101). The latter consists of two prisms, superimposed with their bases in opposite directions, constituting a total value of  $45^\circ$ . They are mounted in a cell which has a delicately milled edge, and fits in the ordinary trial frame. The milled edge permits convenient turning in the frame, so that the base or apex of the prisms can be readily placed in any desired direction. The prisms are caused to rotate in opposite directions by means of a milled screw-head projecting from the front of the cell. With this rotary prism the strength of the abducting, adducting, and supra- and infraducting muscles can be measured. If the rotary prism is placed before the left eye with the zero mark vertical, and the screw turned to the right or left, it will cause the base of the resulting



FIG. 101.—Rislely's rotary prism.

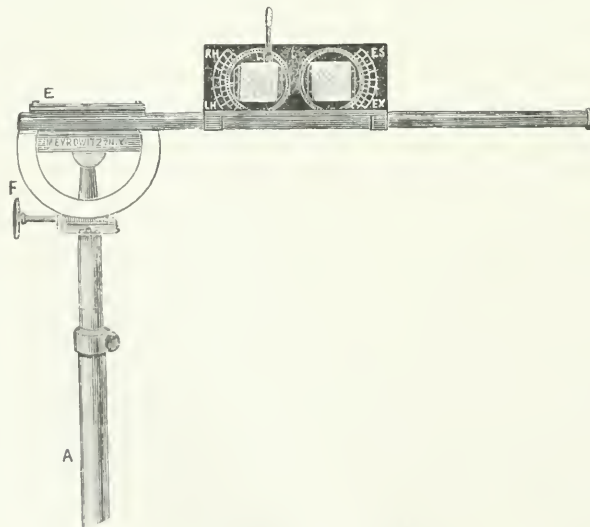


FIG. 102.—Stevens's phorometer.

prism to be either inward or outward, that is, toward the nose or temple, as may be desired; or it may be placed with the zero mark horizontal and the base turned upward or downward. All examinations for muscular defects

may be accurately ascertained with Dr. G. T. Stevens's well-known *phorometer*, which is illustrated in Fig. 102.

One of the simplest tests of the ocular muscles is the *obtuse-angled prism* of Maddox. This is composed of "two weak prisms of  $3^{\circ}$ , united by their bases. On looking through the line thus formed at a distant plane, two false images of it are seen, one higher and one lower than the real image seen by the other eye, the position of which, to the right or the left of the line between the false images, indicates the equilibrium of the eye. A faint band of light, of the same breadth as the two false images, is seen extended between them" (Fig. 103). The answers of the patient may be materially assisted by placing a red glass before one eye and thus tinting the real image. If this stands directly in the center between the two false images, all forms of insufficiency are eliminated; if it stands to the right or to the left, there is insufficiency of the

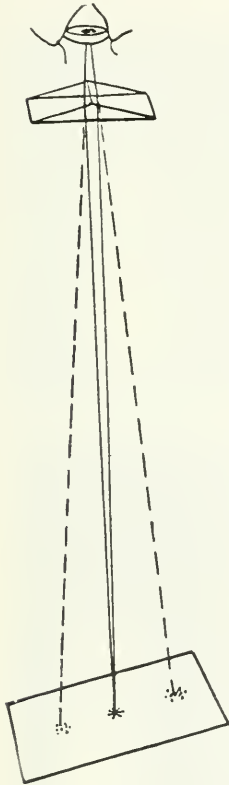


FIG. 103.—Position of the images as seen through the obtuse-angled prism of Maddox (Randall).

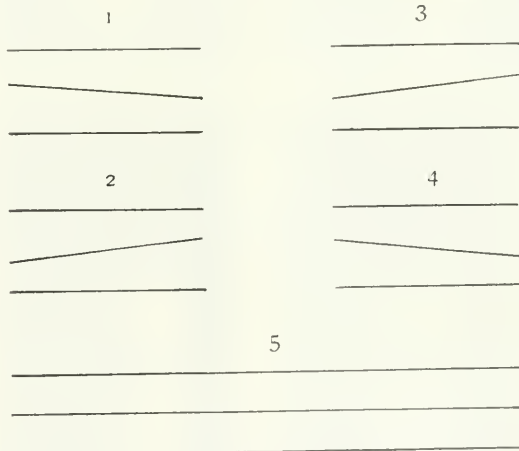


FIG. 104.—Tests for insufficiency of oblique muscles (Savage): 1, insufficiency of left superior oblique; 2, insufficiency of left inferior oblique; 3, insufficiency of right superior oblique; 4, insufficiency of right inferior oblique; 5, equilibrium of oblique muscles.

external or of the internal recti; if it stands above or below the center, or is fused with the upper or the lower image, there is insufficiency of the superior or inferior recti.

*Insufficiency of the oblique muscles* (cyclophoria), according to Savage, may be detected "by placing a Maddox-prism, with its axis vertical, before one eye (the other being covered), which regards a horizontal line on a card 18 in. distant. This line appears to be two, each parallel with the other. The other eye is now uncovered, and a third line is seen between the other two, with which it should be parallel. Want of harmony in the oblique muscles is shown by want of parallelism of the middle with the other two lines, the right end of the middle line pointing toward the bottom and the left end toward the top line, or *vice versa*, depending upon the nature of the individual case"<sup>1</sup> (Fig. 104).

<sup>1</sup> Much doubt has been cast upon the accuracy of this test by F. B. Eaton, who considers the phenomenon a physiologic one. Consult *Journal of the American Medical Association*, Sept., 1894.

The *rod-test*, also designed by Maddox, depends upon the property of transparent cylinders to cause apparent elongation of an object viewed through them, so that a point of light becomes a line of light so dissimilar from the test-light that the images are not united. It may be suitably employed by having mounted in a cell which will fit in the trial frame a transparent glass rod colored red,  $\frac{3}{4}$  in. long, and about the thickness of the ordinary stirring-rod used by chemists, or a series of glass rods placed one above the other (Fig. 105).




FIG. 105.—Maddox-multiple-rod.

The examination for *horizontal deviation* is thus described: "Seat the patient at 6 m. from a small flame, placed against a dark background, and put the rod horizontally before one eye. If the line passes through the flame, there is orthophoria (equipoise) as far as the horizontal movements of the eyes are concerned. Should the line lie to either side of the flame, as in most people it will, there is either latent convergence or latent divergence; the former, if the line is on the same side as the rod (homonymous diplopia); the latter, if to the other side (crossed diplopia)" (Fig. 106).




FIG. 106.—Maddox's rod-test for horizontal deviation; the rod is before the right eye: A, the line passes through the flame—orthophoria; B, the line passes to the right of the flame—latent convergence, or esophoria; C, the line passes to the left of the flame—latent divergence, or exophoria.

In order to test the *vertical deviation*, the rod is placed vertically before the eye: a horizontal line of light appears, and the patient is asked if the line passes directly through the flame or if it appears above or below it. The following rule, quoted from Maddox, will suffice to indicate the "hyperphoric" eye: "If the flame is lowest, there is a tendency to upward deviation of the naked eye; if the line is lowest, of the eye before which the rod is placed"<sup>1</sup> (Fig. 107).

<sup>1</sup> Dr. Swan M. Burnett substitutes for the Maddox-rod a 6 D. cylinder.

The measurement of the extent of the deviation may be made in the ordinary way by finding that prism, placed before the naked eye (preferably with the rotary prism of Risley), which brings the line and flame together.

In order to avoid the awkwardness of the phraseology "insufficiency of the internal recti," etc., and at the same time more accurately to describe the




FIG. 107.—Maddox's rod-test for vertical deviation: the rod is before the right eye: *A*, the line passes through the flame—orthophoria; *B*, the line passes below the flame; the upper image belongs to the left eye—right hyperphoria; *C*, the line passes above the flame; the upper image belongs to the right eye—left hyperphoria.

muscular anomalies, the following terminology has been introduced by Dr. George T. Stevens, and has received a deservedly wide acceptance:

The condition in which all adjustments are made by muscles in a state of physiological equilibrium is called *orthophoria*.

Disturbances of equilibrium are known as *heterophoria*, or insufficiencies of the ocular muscles.

The deviating tendencies of heterophoria may exist in as many directions as there are forces to induce irregular tensions.

The following system of terms is applied to the various tendencies of the visual lines:

I. GENERIC TERMS.—*Orthophoria*: A tending of the visual lines in parallelism.

*Heterophoria*: A tending of these lines in some other way.

II. SPECIFIC TERMS.—Heterophoria may be divided into—

1. *Esophoria*: A tending of the visual lines inward;

2. *Exophoria*: A tending of the lines outward;

3. *Hyperphoria* (right or left): A tending of the right or left visual line in a direction above its fellow.

This term does not imply that the line to which it is referred is too high, but that it is higher than the other, without indicating which may be at fault.

III. COMPOUND TERMS.—Tendencies in oblique directions may be expressed as *hyperesophoria*, a tending upward and inward; or *hyperexophoria*, a tending upward and outward. The designation "right" or "left" must be applied to these terms.

**Power of Convergence.**—In order to determine the maximum of convergence an instrument known as an *ophthalmo-dynamometer* may be employed. The one devised by Landolt consists of a metallic cylinder, blackened on the outside, placed over a candle flame. The cylinder contains a vertical slit 0.3 mm. wide, covered by ground glass. The luminous vertical line thus produced is the object of fixation. Beneath the cylinder is attached a tape measure graduated on one side in centimeters, and on the other in the corresponding number of meter-angles. The fixation object is gradually approached in the median line toward the patient, until that point where double



vision occurs is reached, or the nearest point (*punctum proximum*) of convergence, and the distance in centimeters read from one side of the tape, and the corresponding maximum of convergence in meter-angles on the other.

The minimum of convergence may also be ascertained with the instrument, but when this is *negative* it is determined by finding the strongest abducting prism which will not cause diplopia while the patient is fixing a candle flame at 6 m. If the number of the prism is divided by 7, the quotient will approximately give in meter-angles the amount of deviation of each eye when the prism is placed before one. The amplitude of convergence is equivalent to the difference between the maximum and minimum of convergence.<sup>1</sup>

**The Field of Vision.**—When the visual axis of one eye is directed to a stationary point, not only is the object thus “fixed” visible, but all other objects contained within a given space, which is large or small in proportion to the distance of the fixation point from the eye. This space is the field of vision (conveniently abbreviated V. F.), and the objects within it imprint their images upon the peripheral portions of the retina, or those which are independent of the macula lutea. In contradistinction to visual acuity and refraction, which pertain to the macula in the act of *direct vision*, the function of sight capable of being performed by the rest of the retina is called *indirect vision*.

The limits of the visual field may be roughly ascertained in the following manner: Place the patient with his back to the source of light, and have him fix the eye under examination, the other being covered, upon the center of the face of the observer, or upon the eye of the observer, which is directly opposite his own at a distance of 2 ft. Then let the surgeon move his fingers in various directions midway between himself and the patient on a plane with his own face, until the limits of indirect vision are determined, controlling at the same time the extent and direction of the movements by his own field of vision. Instead of using fingers as the test-object, the author, in common with many surgeons, is accustomed to employ a black rod 18 in. long, which is capped with an ivory ball 12 mm. in diameter. Colored balls may also be employed in the same way, and a fair idea of indirect color vision obtained.

These methods suffice to discover any considerable limitation of the visual field, but should always be supplemented by a more exact procedure.

If it is desired to have a map of the field not larger than 45° in extent, let the patient be placed 25 cm. from a blackboard, which may be conveniently ruled in squares, and fix the eye under observation upon a small white mark. The observer then moves the test-object, a piece of white paper 1 cm. square, affixed to a black handle, from the periphery toward fixation, until the object is seen. If eight peripheral points are marked and afterward joined by a line, a fair map of the field of vision will be obtained,<sup>2</sup> which

<sup>1</sup> Landolt's *Refraction and Accommodation of the Eye*.

<sup>2</sup> The value in degrees of the squares on the blackboard may be ascertained by the following table, provided the eye is placed exactly at 25 cm. from the fixation-point:

|         |     |        |           |             |
|---------|-----|--------|-----------|-------------|
| 2.2 cm. | 5°  | in the | perimeter | semicircle, |
| 4.4 “   | 10° | “      | “         | “           |
| 6.7 “   | 15° | “      | “         | “           |
| 9.1 “   | 20° | “      | “         | “           |
| 11.7 “  | 25° | “      | “         | “           |
| 14.4 “  | 30° | “      | “         | “           |
| 17.5 “  | 35° | “      | “         | “           |
| 21 “    | 40° | “      | “         | “           |
| 25 “    | 45° | “      | “         | “           |
| 30 “    | 50° | “      | “         | “           |
| 36.7 “  | 55° | “      | “         | “           |
| 43.3 “  | 60° | “      | “         | “           |

may be transcribed upon a chart, like the one originally suggested by Joy Jeffries (Fig. 108).

In like manner, a *campimeter* may be employed, the one designed by De Wecker being a useful model. It may be understood by reference to Fig. 109. The patient's eye regards the cross in the center of a black vertical

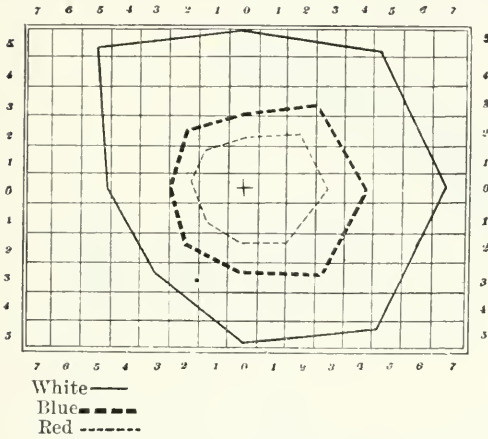


FIG. 108.—Limits of the normal field for white, blue, and red, transcribed upon a blackboard (after Norris).

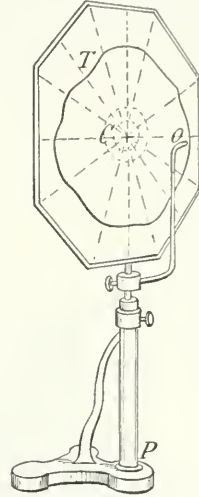


FIG. 109.—Campimeter of De Wecker.

table while the test-object is moved from the periphery toward the center, and the outermost limit of its recognition is marked on the radiating line which it follows. When each line has thus been traversed, the points are joined by a continuous line, and a graphic representation of the visual field results.

The field of vision may also be examined on a flat surface at a greater distance than 25 to 30 cm., after the manner proposed by Bjerrum. The examinations are made at a distance of 2 m. on a large black screen 2 m. in breadth, which can be let down from the ceiling to the floor. At this distance the blind spot (see p. 169), instead of measuring about 2½ cm., as on an ordinary perimeter, measures 20 cm. in diameter, and everything else is in the same proportion. The test-objects used by Bjerrum are small circular disks of ivory fixed on the ends of long dull-black rods. They vary from 10 to 1 mm. in diameter. The examination is begun in the ordinary way at 30 cm. with the 10-mm. disk, and then continued at 2 meters' distance with a 3-mm. disk. In the first case the visual angle approximately is 2°, and in the second 5°. The normal boundaries in the first instance have been given; in the second they are 35° outward, 30° inward, 28° downward, and 25° upward. The method is valuable for finding sector-shaped defects, irregular limitations, and especially scotomata (see p. 169).<sup>1</sup>

Beyond 45° measurements on a flat surface cease to be accurate, because the object is too far away from the eye; rays perpendicular to the visual line

<sup>1</sup> Dr. Joseph E. Willets (*Annals of Ophthalmology and Otology*, 1896, vol. v., No. 3, p. 486) has constructed a prismatic perimeter in which a number of prisms or cones are arranged, which transmit or refract rays of light to that part of the retina corresponding to the degrees in the present perimetrical chart. (For full details the reader is referred to the article.)

coming from a peripheral object would be parallel to the blackboard, and could not arise from it or any object passed across its surface.

The accurate investigation of the functions of the periphery of the retina requires the use of an instrument called a *perimeter*, for which we are chiefly indebted to Aubert and Förster. This instrument consists essentially of an arc (or a semicircle) of wood or metal marked in degrees which rotates around a central pivot, which at the same time is the fixing point of the patient's eye, placed 30 cm. distant—*i. e.* at the center of curvature of the perimeter arc. The test-object, 1 or  $1\frac{1}{2}$  cm. in diameter, affixed upon a carrier, is

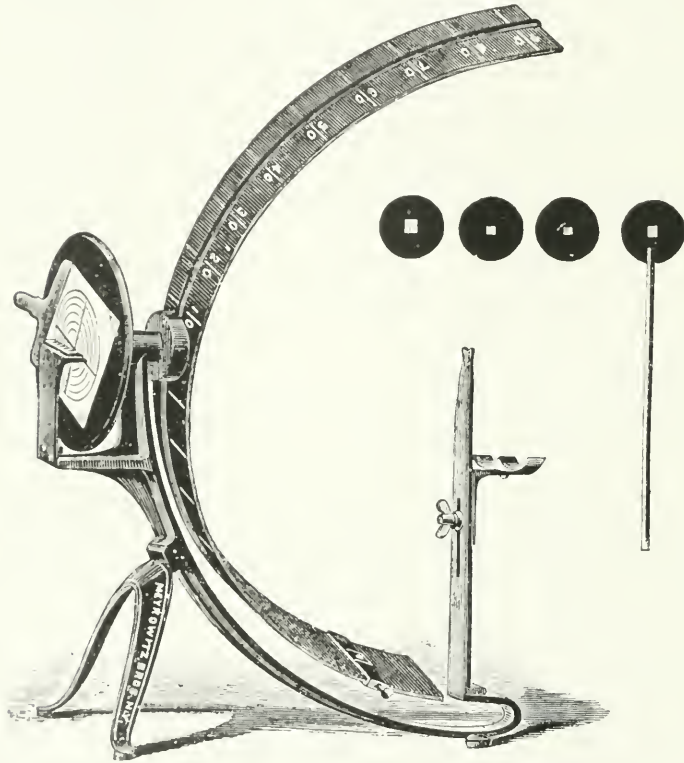


FIG. 110.—Perimeter. The examination may be made with the carrier which moves along the semicircle, or the test-object may be carried along this by means of dark disks attached to a long handle, each disk containing in its center the test-object. The patient's chin is placed in the curved chin-rest; the notched end of the upright bar is brought in contact with the face, directly beneath the eye to be examined, which attentively fixes the center of the semicircle. The other eye should be covered, preferably with a neatly-adjusted bandage. The record-chart is inserted at the back of the instrument, and by means of an ivory vernier the examiner is enabled to mark exactly with a pencil the point on the chart corresponding to the position on the semicircle at which the patient sees the test-object. The various marks are then joined by a continuous line, and a map of the field is obtained.

moved from without inward along the arc, and the point noted in each meridian at intervals of  $30^\circ$ , where it is recognized. Usually the examination is begun with the arc in the horizontal position, which is then moved from this meridian to the next (*e. g.* up and out), and so on until the whole field has been investigated. Generally it is sufficient to examine eight meridians (Fig. 110).

The result is transcribed upon a chart, prepared by having ruled upon it radial lines to correspond to the various positions of the arc, and concentric circles to note the degrees.

The numbering of the meridians on the numerous charts which have been published is far from uniform, as may be seen by examining the accompanying diagrams (Figs. 111, 112, 113). Noyes and Knapp,<sup>1</sup> in order to secure uniform records of the visual field, have advised the designation of the meridians according to the method employed by Helmholtz in his study of the movements of the eye—viz. “to take as the zero point the left end of the horizontal meridian of each eye, and to count from left to right as the hands of a watch viewed by a person under examination move. 0° accordingly marks the temporal end of the horizontal meridian of the left and the nasal end of the same meridian of the right eye; 180° marks the nasal end of the horizontal meridian of the left and the temporal end of the same meridian of the right eye.”<sup>2</sup>

Since the Aubert-Förster instruments appeared the perimeter has undergone numerous modifications and the market is supplied with a host of models. The most practical and time-saving instruments are the so-called

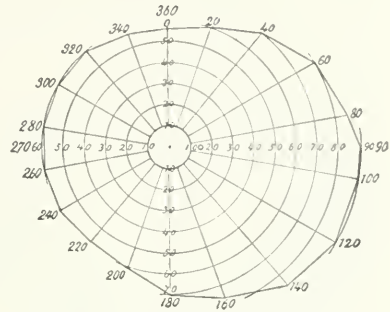


FIG. 111.—Visual-field chart according to Förster.

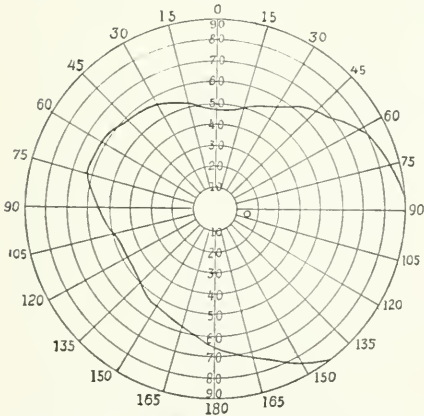


FIG. 112.—Chart for McHardy's registering perimeter.

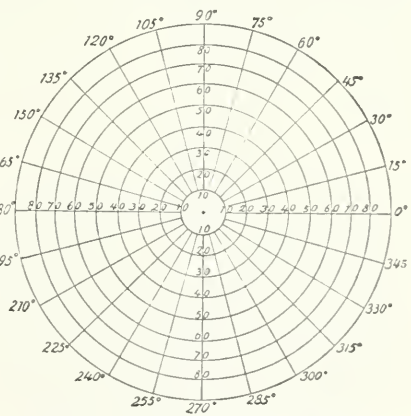


FIG. 113.—Chart for perimeter (Fig. 110).

self-registering perimeters, especially those designed by Stevens, McHardy, and Priestley Smith. A useful model for bedside examinations is the hand perimeter of Schweigger.

The size of the visual field varies considerably within normal limits, being influenced by the character of the light, which should illuminate with equal intensity all portions of the perimeter are in each position; by the size of the test-object, which should be not less than 1 and not greater than 2 cm. in width; by the attention of the patient, whose eye should accurately regard fixation during the measurement; and by the patient's physical and mental condition. Undue prolongation of the examination produces retinal tire and

<sup>1</sup> *Archives of Ophthalmology*, vol. xv. p. 207.

<sup>2</sup> Instead of having the patient fix his eye upon the central pivot, it may be directed upon a porcelain button on a bar placed 15° from the center to the left if the right eye is to be examined, and *vice versa* if the left is under observation. This plan originally suggested by Förster, makes the optic-nerve entrance, and not the macula, the centre of the visual field.



corresponding contraction of the visual field. The extent of the field of vision is also somewhat under the influence of the size of the pupil and the state of refraction, being larger in eyes with widely dilated pupils or with hyperopic refraction, and smaller in eyes with contracted pupils or with myopic refraction. Enlargement of the visual field may be noted during accommodation for the near point and when the patient wears concave glasses<sup>1</sup> (Mauthner).

The average physiological limits of the *form-field*, or, what is practically the same thing, the field when this has been measured with a square of white  $1\frac{1}{2}$  cm. in width, are—outward,  $90^\circ$ ; outward and upward,  $70^\circ$ ; upward,  $50^\circ$ ; upward and inward,  $55^\circ$ ; inward,  $60^\circ$ ; inward and downward,  $55^\circ$ ; downward,  $72^\circ$ ; downward and outward,  $85^\circ$ .

These limits, which form a good working field, are somewhat exceeded by the mean limits resulting from the examination of a number of normal eyes, as recorded by Förster, Landolt, and Baas.<sup>1</sup> The last-named author finds the average result of ten observers as follows: Outward,  $99^\circ$ ; upward,  $65^\circ$ ; inward,  $63^\circ$ ; downward,  $76^\circ$ . Figures indicating a "minimal field," or "smallest physiological field," have been recorded, varying from  $90^\circ$  (Förster) to  $50^\circ$  (Treitel) outward;  $55$ – $21^\circ$  upward;  $60$ – $40^\circ$  inward;  $70$ – $40^\circ$  downward. Certainly, in the judgment of the author, the smaller of these limits cannot be regarded as physiological, and the greater is about equal to the average working field already given.

As we ordinarily measure the visual field, the measurement represents the *relative visual field*, in contradistinction, as Baas points out, to the *absolute visual field*.

The former records the limits for a test-object of definite size; the latter the maximal expansion which it is possible to obtain. The figures then given are the relative visual field (test-object 1–2 cm.), and transcribed upon a chart produce Fig. 114.

Examination of this chart shows that the field of vision is not circular, being greatest outward and below, and most restricted inward and above. This restriction depends partly upon anatomical reasons—*i. e.* the edge of the orbit, the lids, and the nose interfere with vision, and partly upon physiological reasons—*i. e.* the pericipient layers of the retina extend farther forward on the nasal than on the temporal side, or, as Landolt

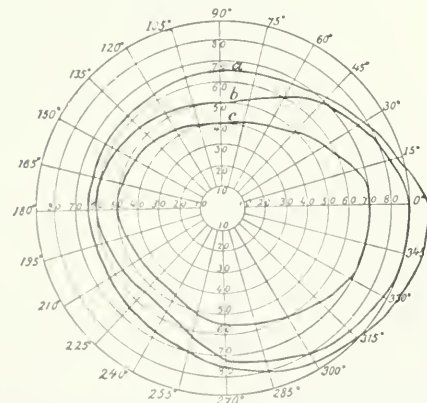


FIG. 114.—Various limits of the form-field: a, Baas's average; b, average working field; c, average least physiological field.

expresses it, the outer part of the retina is less used than the inner, and its functions, therefore, are less developed. Hence, as each portion of the field corresponds to the opposite portion of the retina, the inner part is smaller than the outer. To avoid the influence of the physical obstacles afforded by the cranial bones, the eye should be made to fix an object in each meridian  $30^\circ$

<sup>1</sup> Convex glasses should exercise a contracting influence; indeed, Berlin, quoted by Baas, found a ring-shaped defect in the peripheral visual field if measured through strong convex glasses placed some distance from the eye.

<sup>2</sup> The ten observers are Baas, Birtz, Donders, Drott, Hegg, Landolt, Reich, Schön, Stöber, Treitel. (See Baas: *Das Gesichtsfeld*, Stuttgart, 1896, p. 46.)

in the direction opposite to that under measurement or else suitable rotation of the head should be made.

**Binocular Field of Vision.**—The field of vision for each eye having been defined, it remains to point out that the field of vision which pertains to the two eyes, or that portion in which binocular vision is possible, constitutes only the area where the central and inner parts overlap. This is evident from the diagram. The continuous line *L* bounds the field of vision of the left eye, and the dotted line *R* the visual field of the right eye. The central white area corresponds to the portion common to both eyes, or to that area in which all objects are seen at the same time with both eyes; the shaded areas correspond to the portions in which binocular vision is wanting. In the middle of the white area lies the fixation point, *f*, and on each side of it the blind spots of the right and left eye, *r* and *l* (Fig. 115).

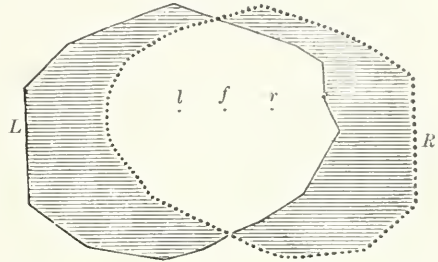


FIG. 115.—Binocular field of vision (Möser).

Having thus determined the *limits* and *continuity* of the visual field, the functions of the peripheral parts of the retina in regard to perception of colors, acuity of vision, and appreciation of light should be investigated.

**Color-field.**—The color-field is examined in the manner described in connection with the general visual field, the squares of white in the instrument being replaced by pieces of colored paper 1 to 2 cm. in diameter. The order in which the colors are recognized from without inward is—(1) blue, (2) yellow, (3) orange, (4) red, (5) green, (6) violet. In practical work blue, red, and green are the colors employed. Non-saturated colors are not correctly recognized when the test-object is first seen. Thus, yellow at first appears white; orange, yellow; red, brown; green, white, gray, or gray-blue; and violet, blue. The investigation of this zone of imperfect color-perception is important in various pathological conditions, especially in the study of the visual fields of hysteria and of disseminated sclerosis.

The physiological extent of the color-fields, like that of the general field, is subject to variations within normal limits, which are represented by the figures in the following columns. In each left-hand column are the figures denoting the extent of an average color-field mapped with 1 cm. square test-object, while in each right-hand column are the averages of the results of ten observers recorded by Baas, the size of the test-object being 20 mm. in diameter :

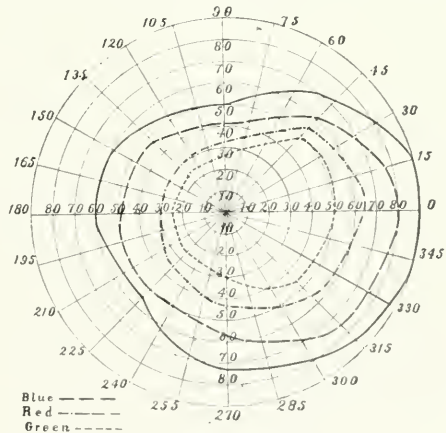


FIG. 116.—Diagram of the field of vision for blue, red, and green: the outer continuous line indicates the limit of the form-field; the broken lines, the limits of the color-fields.

|                                | Blue. | Red.  | Green. |
|--------------------------------|-------|-------|--------|
| Outward . . . . .              | 80-84 | 65-75 | 50-65  |
| Outward and upward . . . . .   | 60    | 45    | 40     |
| Upward . . . . .               | 40-45 | 33-39 | 27-34  |
| Upward and inward . . . . .    | 45    | 30    | 25     |
| Inward . . . . .               | 45-50 | 30-39 | 25-33  |
| Inward and downward . . . . .  | 50    | 35    | 27     |
| Downward . . . . .             | 58-62 | 45-50 | 30-43  |
| Downward and outward . . . . . | 75    | 55    | 45     |

These, when transcribed upon a chart, are represented in Fig. 116.

As may have been inferred, the extent of the color-field is greatly governed by the size of the test-object. According to Gowers,<sup>1</sup> who has recently reopened this subject, with a sufficiently large area of color it will be found that all the color-fields differ in extent very little from the fields for white. Green alone seems to fall short of the edge of the white field by about 5°. The extent of the color-field is further governed by the character of the light, the nature and saturation of the color, the contrast in luminous intensity between the colored test-object and the background. To quote from Ward Holden: Other conditions being the same, the field becomes larger as the saturation, the intensity, or the size of the color is increased; and the field is larger the less the contrast in luminous intensity between test-object and background.

**The Acuity of Vision of the Peripheral Parts of the Retina.**—This diminishes from the macula to the periphery. It may be tested with small squares of black paper, separated from each other by their own width, by noting the point in each meridian where they are recognized as separate objects. The tests of Landolt and Ito are 6, 5, 3, and 2 mm. black quadrants on a white ground. Groenouw employs as a test-object to be passed along the perimeter are black points on a white ground of  $\frac{1}{4}$ ,  $\frac{1}{2}$ , 1, 2, and 4 mm. in diameter. The result obtained is called "visual acuteness for a point."<sup>2</sup> The results have the form of a horizontal oval nearly parallel to the limits of the visual field.

**The Light-sense of the Periphery of the Retina.**—This may be tested conveniently with Ward Holden's tests, which are thus described by the author: One card has a 1-mm. black point on one side, and a 15-mm. quadrant of light gray, having  $\frac{4}{5}$  of the intensity of white, on the other. With a perimeter of 30 cm. radius the black point and gray patch are each seen by a normal eye outward, 45°; upward, 30°; inward, 35°; downward, 35°. The second card has a 3-mm. black point on one side, and a darker gray patch, having  $\frac{3}{5}$  the intensity of white, on the other. Each is seen on the perimeter arc, outward, 70°; upward, 45°; inward, 55°; downward, 55°. Card 2 will reveal slight disturbances of light-sense near the periphery, and card 1 in the intermediate and central zones. Groenouw's and Holden's tests are declared by their authors to be more delicate than color-tests, or at least equally so, while they possess the advantage of being more intelligible to the patient.

According to the experiments of Landolt, the perception of light is the most constant function of the healthy retina, and remains nearly the same throughout its surface, while the color- and form-sense rapidly lessen toward the periphery. Progressive diminution of light-sense, however, from center to periphery will be found if test-objects of varying luminous intensity with

<sup>1</sup> *Trans. Ophth. Soc. U. K.*, vol. xv. p. 12. (For further particulars the reader is referred to this most interesting paper.)

<sup>2</sup> As Baas remarks, the employment of a single point as a test-object affords information not so much of the form-sense as of the light-sense.



the illumination of ordinary daylight are employed. For practical purposes in cases of very defective vision an idea of the retina's sensibility to light may be obtained by passing a candle flame along the arm of the perimeter as a test-object, while a second candle flame is made the point of fixation.<sup>1</sup>

The most frequent departures from those limits of the visual field assumed to be normal are general or concentric contraction; contraction limited especially to one or the other side; peripheral defects in the form of re-entering angles; absence of one segment or quadrant; and absence of the entire right or left half of the field (see page 472).

**Scotomas.**—In addition to these defects, search should be made for dark areas within the limits of the visual field, or *scotomas*. These are distinguished as *positive* when they are perceived by the patient in his visual field, and *negative* when within the confines of a portion of the visual field the image of an external object is not perceived, but the affected area is not discovered until the field is examined. Negative scotomas are further divided into *absolute* and *relative*. Within an absolute scotoma all perception of light is wanting, while within the confines of a relative scotoma the perception of light is merely diminished. The latter are *color scotomas*, usually for red and green. Scotomas are further subdivided, according to their situation and form, into *central*, *paracentral*, *ring*, and *peripheral*.

In every normal eye there is a *physiological scotoma* which may be regarded as the type of an absolute scotoma corresponding to the position of the optic-nerve entrance, which usually may be found  $15^{\circ}$  to the outer side of and  $3^{\circ}$  below the point of fixation, the distance from fixation being greater in hyperopic than in myopic eyes. This is known as *Mariotte's blind spot*. Usually the form of the blind spot is not round, but a vertical oval, its upper and lower end being somewhat drawn out to correspond to the larger retinal vessels. Its size depends upon the distance from the cornea. In Landolt's experiments on his own eye at a distance of 35 cm. from the cornea to the plane of projection the mean height of the blind spot was 52 mm. and its breadth 44 mm. The blind spot is much enlarged under certain conditions; for example, by retained marrow-sheath or by papillitis.

For the detection of scotomata small test-objects, white, gray, or colored,  $\frac{1}{4}$  cm. square, are employed, which are moved in different directions from the point which the eye under observation attentively fixes, and the spot marked where the object begins to disappear or change its color. The arm of the perimeter is usually marked near the center in half degrees for this purpose. All examinations around the center of the field of vision, and hence the examinations for scotomata, are readily made upon a blackboard. Berry urges that the ordinary test for scotomata be supplemented by making an examination of the particular area of the field at a distance of 2 m. or more, so as to obtain a larger projection of the blind portion, and to be able to work with small retinal images without necessitating the use of very small objects.

**Field of Fixation.**—This includes all points which the eye under observation can successively fix, the head being perfectly stationary. Various methods for determining the limits of the field of fixation have been employed; for example, watching the image of a candle flame on the center of the cornea

<sup>1</sup> Readers interested in the acuity of vision of the peripheral parts of the retina and tests for the light-sense of the retinal periphery are referred to the excellent papers on this subject by Groenouw (*Archives of Ophthalmology*, xxii., 1893, p. 502); Ward Holden (*Ibid.*, xxiii., 1894, p. 40); and Karl Baas (*loc. cit.*, pp. 52-57). In the last-named publication the literature of the entire subject is reviewed.



as the eye follows the test-light moved along the perimeter are until the limit of movement is reached. This method, suitable to amblyopic eyes, is not so accurate as one which requires the patient to distinguish letters. The patient is seated before the perimeter, with the semicircle horizontal, precisely as if his visual field was to be examined, and the eye under observation (the head being perfectly rigid) is made to follow a word composed of test-letters representing the minimum acuteness of vision, and the point where vision ceases to be distinct marked in successive meridians.<sup>1</sup> Landolt's measurements of the field of fixation under normal conditions are as follows: Outward, 45-50°; inward, 45°; upward, 35-40°; downward, 60°.

Dr. G. T. Stevens determines the rotations of the eyes with a special instrument called a *tropometer*. According to his measurements, the most favorable rotations are—Outward, 50°; inward, 55°; upward, 33°; downward, 50°. (See also p. 499.)

**Tension.**—This term indicates the intraocular resistance, and is clinically demonstrable by palpating the globe with the finger-tips. The middle and ring fingers are placed upon the brow of the patient, the tips of the index fingers upon the eyeball, and gentle to-and-fro pressure made, the eyes being directed downward. This pressure must be made in such manner as not to push the ball into the orbit; otherwise no information of its true resistance is obtained. The tension of one eye must always be compared with that of its fellow, and in any doubtful case the results may be contrasted with those obtained by examining an eye known to be normal in another patient of similar age.

Normal tension is expressed by the sign *Tn*, and the departures from it by the symbols + 1, + 2, + 3, and - 1, - 2, - 3: the plus signs indicate increased, and the minus signs decreased, resistance. In physiological experiments various kinds of apparatus, constructed upon the principle of the manometer, are employed, and for clinical purposes instruments known as *tonometers* have been devised. In practical work, however, sufficiently accurate data are obtainable by a careful use of the educated finger-tips.

**Protopsis**, or protrusion of the eye, may be caused by orbital diseases, tenotomy, paralysis of the ocular muscles, and Graves's disease; while enlargement of the ball is the result of various conditions residing within the globe—myopia, intraocular tumor, and staphyloma. If the cause is unilateral, the resulting condition is asymmetrical and the two eyes may be compared by observing the relative positions of the apices of the cornea with each other and with the line of the brows.

The eyeball is apparently shrunken (*enophthalmos*) in some cases of ptosis and in wasting of the orbital fat, and is diminished in size in high grades of hyperopia and congenital failures of development. As Nettleship has pointed out, the amount of exposed sclera decides the apparent protrusion or recession of the eyeball.

**Position of the Eyes.**—Instead of presenting parallel visual axes, one eye may be deviated inward, outward, downward, or upward, constituting one of the various types of strabismus, a condition which may or may not be associated with diplopia.

<sup>1</sup> Casey Wood has devised a useful test for this purpose: *Trans. Ophthalmolog. Section A. M. A., Chicago, 1896, 252-259.*

# THE OPHTHALMOSCOPE AND ITS USE; THE NORMAL EYE-GROUND.

BY B. ALEX. RANDALL, A. M., M. D.,

OF PHILADELPHIA.

---

OPHTHALMOSCOPY is the visual exploration of the eye, and is more strictly limited to the study by transmitted light. Its utilization has inaugurated a new era in ophthalmology, from which most of its scientific development dates; but general medicine has been and is greatly concerned in the information thus gained. The ophthalmoscope ought to be in daily use in the hands of every physician, and it will be when the erroneous impression has been removed that its use is difficult to learn. A half-hour's good instruction can give any intelligent person command of its technique and a dozen illustrations of its various revelations; and moderate practice alone, with loyal adhesion to the cardinal rules, will then serve to widen almost *ad maximum* the field of its employment. Compared with medical microscopy, its technique is very simple, although reasonable persistence in the face of difficulties may be less easy when dealing with a patient than in the quiet conditions of laboratory work. The beginner must not expect to succeed at once under adverse conditions which would try or even baffle the expert: the study of a patient in bed is comparatively hard, even with an electric-light ophthalmoscope, and when intractable or otherwise difficult his examination may prove beyond the power of any one; yet it is to such very practical utilization that the physician may at once unreasonably desire to put the new accomplishment. Restricted at first to easy conditions, the art may be practised with few failures and rapidly growing comprehension; the infinite variations which fall within the physiological limits will be gradually learned and cease to be frequent enigmas, and the physician, made duly self-confident by his success, will not too easily accept defeat when difficulties have to be surmounted. Learning that real cause only need disturb him, he will seek the ground of his difficulties in the narrow group of requirements; and when these have all been met can feel assured that he has located, if not overcome, the obstacles, and learned as much, perhaps, as the circumstances would permit to any one.

**The Ophthalmoscope.**—The ophthalmoscope, *augen-spiegel* of the Germans, is a mirror for throwing light into the eye. Elaborate and costly forms have been devised in numberless variety, intended to meet almost every possible requirement in the way which the designer thinks best; but it must not be forgotten that any one can in a moment improvise an instrument better adapted sometimes to the needs of the case before him than any which he could find in the shops, and competent for a considerable group of cases. A bit of looking-glass with a hole scratched in its silvering, two or three

microscope-slides held together in the fingers, or three or four cover-glasses in the end of a split stick—improvisations of the original Helmholtz-mirror—can reveal the commencing changes at the macula of renal disease which might easily escape the user of the most high-priced ophthalmoscope. But this “weak-light” instrument is an over-refinement for the majority of cases: the condensed illumination of a perforated concave mirror is more generally useful, and the brow-mirror of the otologist and laryngologist may revert to its earlier use, when Ruete first employed it for ophthalmoscopy.

Yet an instrument designed for wide diversity of ophthalmoscopic work, and convenient in size and construction, is naturally to be preferred. The original ophthalmoscope of Helmholtz is practically unknown to most modern

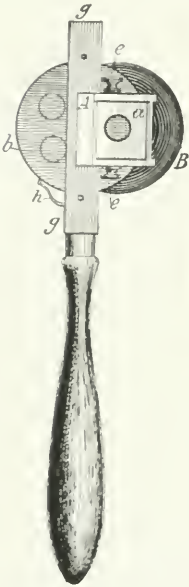

FIG. 117.—Ophthalmoscope of Helmholtz: the concave shade *B* is set at the side of the handle, *a*, with disks of lenses (*b*) centering at its sight-hole. In front of this a triangular case projects, carrying three thin glass plates at an angle of  $56^\circ$  to the line of sight, by means of which the light is reflected into the observed eye.

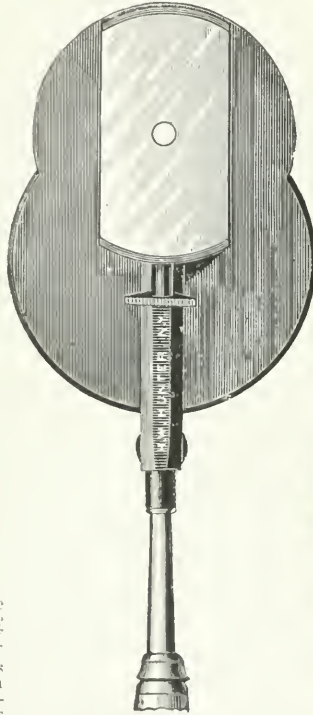
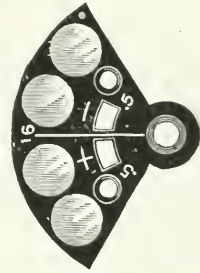


FIG. 118.—Loring's ophthalmoscope, with tilting mirror, complete disk of lenses from  $-1$  to  $-8$  and  $0$  to  $+7$ , and supplemental quadrant containing  $+0.5$  and  $+16$  D. This affords 66 glasses or combinations from  $+23$  to  $-21$  D.



oculists, and its surpassing value in some directions has been eclipsed by less cumbersome rivals (Fig. 117). The convex mirror of Zehender, on which the light is concentrated by a lens, has as completely passed away, and almost every ophthalmoscopist of to-day utilizes, with scant or no recognition, the perforated mirror of Ruete. Behind this is generally placed the revolving disk of lenses added by the optician Rekoss—single, double, or even treble—and upon these fundamental elements have been rung changes more numerous than could be here recorded. Some of the best of these arrangements worthy of being credited to the designer we owe to the lamented Dr. Edward G. Loring. The modifications of his later instrument (Fig. 118) are all questionable gains at the cost of undoubted loss, and are almost as numerous as



the individual users. That of the writer (Fig. 119) aims at unusual completeness of the series of lenses, cylindrical as well as spherical, brought *seriatim* to the sight-hole without removing the instrument from the eye, and boasts a minimum deviation from the dimensions, weight, and balance of the best "Loring." Dr. Edward Jackson's admirable use of slides of lenses (Fig. 120) forms the simplest of "refraction-ophthalmoscopes," most warmly to be commended to the non-expert; while Couper's chain of lenses (Fig. 121) or Morton's modification of it offers a most ingenious solution of the difficulty of bringing a wide series of uncombined glasses close behind the sight-hole of the tilted mirror.

For the practitioner who is willing to make but small outlay the simple Liebreich mirror, with its clip to hold its few lenses, will prove fairly satisfactory.

Optical Principles of the Instrument.—These need concern its user little at first. Rule-of-thumb methods will suffice for the great majority of cases, and the minutiae of the dioptries

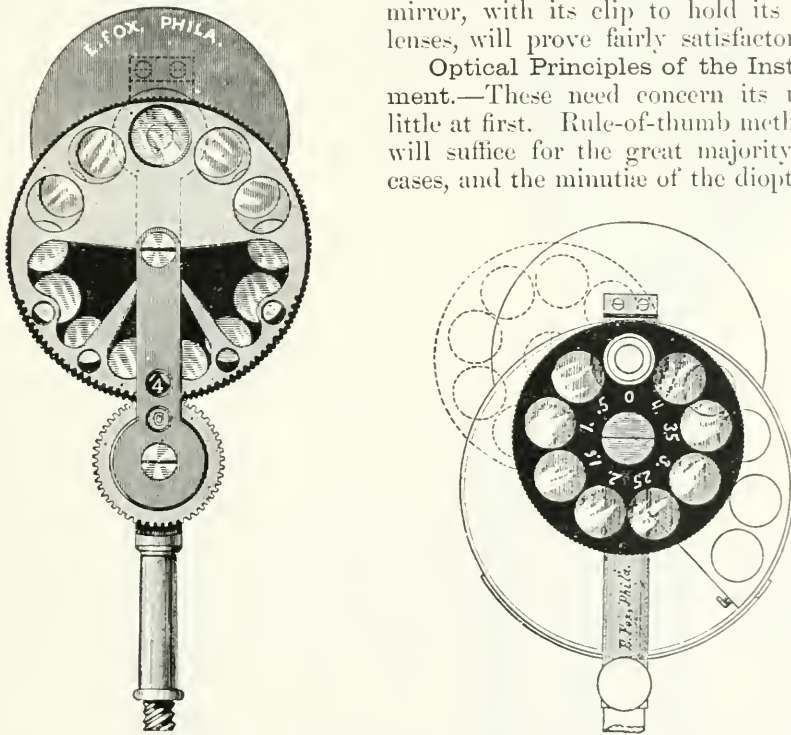


FIG. 119.—Randall's modified Loring ophthalmoscope, in which the "quadrant" is moved by the cog below, so that every glass can be brought to the sight-hole without removing the instrument from the eye. A disk of concave cylinders 0.5 to 4, is eccentrically mounted, so that each can be brought at any desired inclination of its axis into combination with any spherical. It gives 51 spherical lenses or combinations. The mirror can be detached to substitute a weak-light, plane, or more concave mirror, or left off, uncovering the 6 mm. breadth of the lenses when the instrument is used as an optometer. The disk of cylinders can be left off as drawn, or attached to any form of ophthalmoscope.

of the eye, upon which depend such questions as the amplification of the erect image and the height or depth of objects, involve formulas from which most oculists shrink. We will consider only the manifest facts, easily observed and verified, which go to make up the possibilities and limitations of the instrument, and will consider the refraction and accommodation of the eye only so far as they force themselves upon the attention of the ophthalmoscopist.

The eye is a camera obscura, provided with a complex lens-system capable of changing focus and armed with a diaphragm—the iris—which varies the size of its central opening—the pupil—limiting the amount of light which enters and the optical imperfections of the image. This pupil generally



appears black because the light entering it is reflected back, after partial absorption, in exactly the direction from which it came. As the observer's head is not generally a source of light, but an obstacle, cutting off all illumination from that direction, his eye receives none of the returning rays. If the pupil be wide, however, and the retinal surface less than the focal distance behind it, as is common in children and in animals, it is not difficult to obtain a red




FIG. 120.—Jackson's ophthalmoscope, with two superposed slides of lenses coming singly or combined behind the sight-hole of the tilting mirror. It gives 35 lenses or combinations, from +11 to -18 D., with great convenience, and is exceedingly simple and thin.

Like most other ophthalmoscopes, the figures are red, to indicate concave glasses, and white to mark convex, making mistake or confusion as to combinations unlikely.

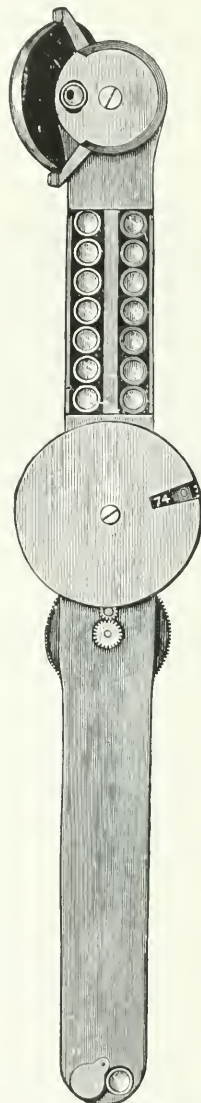


FIG. 121.—Couper's ophthalmoscope, with 71 lenses in endless chain coming singly close behind the excentric tilting mirror, which rotates to the left when the left eye is to be examined. In Morton's modification the lenses are free in the channel, and moved by the sprocket acting below.

reflex from within the eye. Ophthalmoscopy aims to secure uniformly this result, by so reflecting a beam of light that the observer's eye is always in position to receive the returning rays, and not only to obtain a diffused glare from the pupil, but to see numberless details within. For this a number

of optical conditions have to be met, depending not only upon the refraction of the eye in general, but upon that of the observed eye in particular, and involving even the conditions of the observer's eye. To these we first must turn.

By the law of the conjugate foci of lenses, light from within the illuminated eye emerges in parallel rays if the eye be emmetropic, divergent if hyperopic, convergent if it be myopic. To make such rays furnish a clear image of the interior two methods are in vogue, and various optical apparatus is needful for each. The simpler method is known as the "direct," or that of the "upright image," in contrast to the "indirect," which gives an "inverted image."

**Direct Method of Ophthalmoscopy.**—In this method the mirror is placed before the observer's eye, so as to throw light through the pupil of the observed eye, and the two are brought close together (Fig. 122). If the observed eye be emmetropic, parallel rays pass from it into the observer's, and if this be also emmetropic, a clear image is obtained without further aid. If

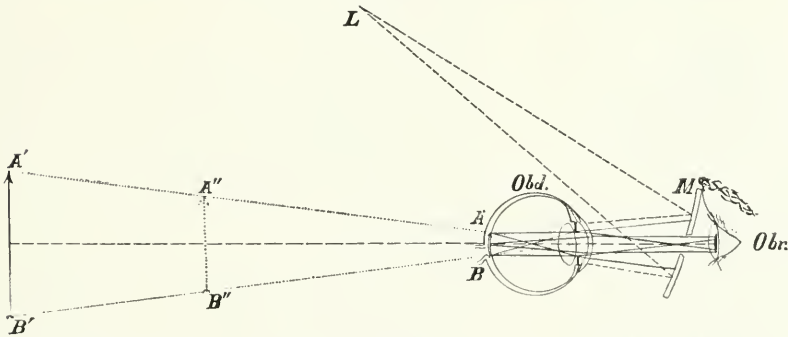


FIG. 122.—Diagram of the direct method with the formation of an upright image: rays from the source of light *L* are received upon the concave mirror *M*, and converged upon the observed eye *Obd.*, within which they cross and illuminate an area of its fundus. From an area *A B* thus lighted, rays pass out of the pupil (parallel if it be emmetropic, as here represented) through the sight-hole of the mirror, and, entering the observer's eye, *Obr.*, are focussed upon his retina. An image is there formed as though the object seen were at a great distance (*c. g.* 25 cm.). By the laws of magnification by a simple lens the image is embraced between the lines passing from the optical center of the magnifying lens (the refracting system of the observed eye), through the extremities of the object, and has the size *A' B'*, *A'' B''*, etc., according to the distance of projection.

the observed eye be hyperopic, myopia or accommodation in the observing eye may neutralize it and permit of seeing clearly; if not exactly thus adjusted, a convex lens must be introduced to render parallel the divergent rays. If, on the contrary, the eye be myopic, the observer must employ a concave glass to bring the convergent rays to parallelism, unless himself hyperopic enough to be focussed for such convergence. Thus it is requisite that there shall be a series of concave and convex lenses at command, which may be skilfully used as required in order to afford clear views in all conditions of refraction.

But this, while inconvenient in some respects, constitutes one of the great advantages of the direct method; for the lens thus required to give a sharp image of the retinal details becomes, under proper conditions, the *measure of the ametropia*. That this should be accurate assumes that the observer must be emmetropic or allow for his error of refraction, and make no accommodative effort that would change it from this basis. The lens thus used must be properly placed before the observed eye. It ought to be about 13 mm. from the cornea, at the anterior focus of the lens-system, and it should be tilted little if

at all, since this has a distorting effect. The ophthalmoscope should be so constructed as to give a considerable series of glasses coming *seriatim* to the sight-hole, which should not be too small nor tunnel-like from thickness of the instrument; and, as the light must be taken from the side of the patient's head, the mirror should incline in the needed direction, leaving the rest of the ophthalmoscope straight.

The field of view open to the direct method is never larger than the pupil, and grows steadily smaller as one draws farther away from the observed eye. So the advantage of a dilated pupil is evident: although an expert can approach so close, locate so well the image presented, and proceeding from it to each other desired part of the eye-ground, can build up from this series of glimpses so satisfactory a mosaic, that he may explore with ease through a 3 mm. pupil when a tyro might find difficulty even were the pupil dilated to 6 or 8 mm. The periphery of the lens and the extremes of the eye-ground cannot be seen through a contracted pupil, however expert the ophthalmoscopist; and a case demanding such study must have a drop or two of a mydriatic, such as 1 per cent. solution of homatropin or 0.5 per cent. of atropin, instilled and given time to act.

When there is inequality of the refraction in the various meridians of the eye, constituting astigmatism, there is a distortion of the image of the eye-ground, and all details are not equally well seen with the same lens. If, as is most common, this be due to excess of curvature of the cornea in its vertical meridian, fine vertical vessels in the retina will be sharply seen with a stronger convex or weaker concave lens than any others, especially the horizontal vessels adjacent; and thus a ready means is afforded of recognizing and measuring astigmatism (see also page 199).

**Indirect Method of Ophthalmoscopy.**—The indirect method has certain decided advantages. The magnification obtained is less and the field proportionately larger; hence a better general view can be thus gained. Then its sharpness is largely independent of the refraction of the eye, unsteady movements are less disturbing, and it can supplement the direct method in many important relations. Differences of level count for less, although quite perceptible, and may reveal their true relief, previously misunderstood.<sup>1</sup> A simpler instrument is competent, since a concave mirror, a double convex lens of 2–3 inches focus (14–20 D.), and one or two lenses to clip behind the sight-hole meet all requirements.

In this method the eye is illuminated from a distance of 25–30 cm., and the emerging rays, unless already strongly convergent, are intercepted with the convex lens held some 5 cm. in front, so that they are brought to a focus near by. Here a real inverted image is formed in the air (Fig. 123), and this, and not the eye-ground itself, is studied by the observer, generally with the help of a convex lens to magnify it. The principle is the same as that of the compound microscope, while the direct method is like the use of a simple lens, the lens-system of the observed eye serving to magnify all the details of its own interior. The myopic observer may often dispense with any magnifier back of his mirror, and if the observed eye be very myopic, it forms the requisite image near enough in front to obviate the need for an object-glass. Here, then, the mere concave mirror may serve all needs, and in circumstances where the satisfactory use of the direct method is very difficult.

In this method much depends upon the clearness of the object-lens held near the observed eye; and one of ample size and of material, like pebble,

<sup>1</sup> The cupping of glaucoma was mistaken for prominence by the earlier observers.

not easily scratched, has distinct advantage. A protecting mounting is often useful. The reflection from the pole of the cornea is less troublesome than when contrasted with the weaker illumination of the direct method; but the reflections from the front and back surfaces of the objective lens compel a little tilting of it to throw them out of the way.

An element of astigmatic distortion is thus introduced which must be allowed for. A round optic disk may be made to appear oval, the longer diameter corresponding with the least inclined diameter of the lens. When the eye is astigmatic a similar distortion of the disk appears, which may be modified by tilting the lens; but irrespective of this, to-and-fro movement of the lens corrects and reverses the apparent lengthening of the nerve-head, which reveals whether it is anatomically or only optically elongated.

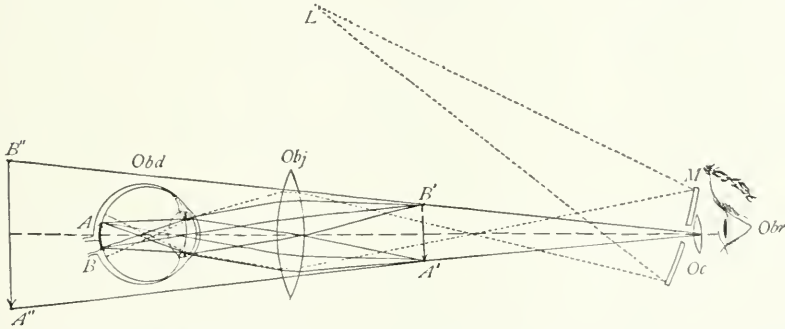


FIG. 123.—Diagram of the indirect method giving an inverted image: rays from the source of light  $L$ , converged toward the observed eye  $Obd$  by the concave mirror  $M$ , are intercepted by the lens  $Obj$ , and after coming to a focus diverge again and light up the fundus. From a part of the illuminated fundus  $A B$  rays pass out of the pupil to be again intercepted by the lens  $O$  and form an inverted real image at its anterior focus  $A' B'$ . This real image is viewed by the observer's eye behind the sight-hole of the mirror with the aid of a magnifying-lens  $Oc$ , and is seen enlarged, as at  $A'' B''$ .

**Size of the Image and Mensuration of Fundus-Details.**—The problems as to the amplifications afforded by the upright and by the inverted image and the mensuration of objects in the fundus are complex and variable. Even in the “reduced eye” many other factors must be determined in order to permit of precise statement of the result. Suffice it here to say that in the emmetropic eye the upright image, when projected to 10 inches, is about sixteen-fold the linear size of the retinal surface seen; and an optic disk 1.5 mm. in diameter will seem 24 mm. broad when projected to 25 cm. An easy test of this is to hold a quarter-dollar or shilling before the one eye while the other views the disk, and find the point where the images seem of equal size: this distance will vary little from 10 inches. In hyperopia the enlargement is less, in myopia more, the myopic eye having virtually an extra magnifying lens in it as contrasted with the emmetropic, and still more the hyperopic. The indirect method affords about one-third as much amplification as the direct, increasing as the object-glass is weakened and the ocular strengthened. Hence myopia gives smaller and hyperopia larger images by this method.

Another interesting point, still more practical, is the mensuration of the axial lengthening or shortening as afforded by prominences or depressions of the eye-ground. Having determined the refraction at the general retinal level, the ability (aside from astigmatic conditions) to see some object with stronger convex or weaker concave lenses marks its protrusion above that level, and the following table shows the amount of elevation calculated for the “reduced emmetropic eye:”



*Lengthening or Shortening of the Eye in Axial Ametropia* (Landolt).

| Myopia. | Increase. | Axial length. | Hyperopia. | Decrease. | Axial length. |
|---------|-----------|---------------|------------|-----------|---------------|
| 0       | 0         | 22.824        | 0          | 0         | 22.824        |
| 0.5     | 0.16      | 22.98         | 0.5        | 0.16      | 22.67         |
| 1       | 0.32      | 23.14         | 1          | 0.31      | 22.51         |
| 2       | 0.66      | 23.48         | 2          | 0.62      | 22.20         |
| 3       | 1.01      | 23.83         | 3          | 0.92      | 21.90         |
| 4       | 1.37      | 24.19         | 4          | 1.21      | 21.61         |
| 5       | 1.74      | 24.56         | 5          | 1.50      | 21.32         |
| 7       | 2.52      | 25.34         | 6          | 1.76      | 21.06         |
| 10      | 3.80      | 26.62         | 7          | 2.03      | 20.79         |
| 15      | 6.28      | 29.10         | 8          | 2.28      | 20.54         |
| 20      | 9.31      | 32.13         | 10         | 2.78      | 20.04         |

On the contrary, the need of stronger concave or weaker convex lenses to bring the object sharply to view demonstrates its depression below the general level, as also shown in the table. The prominence of a swollen optic nerve-head or of a tumor-mass may thus be measured, and comparison will show the variations of its advance or recession. So, too, a glaucomatous or other cupping of the nerve or the staphylomatous bulging in a coloboma may be exactly determined, when at first glance it may have seemed doubtful whether the ill-focussed surface was raised or depressed. The same table holds approximately for general conditions of axial shortening or lengthening, with the proviso that emmetropia (or any other refraction) may exist with different axial lengths if only the power of the refractive media be adjusted to such lengths. The axis of 23.8 mm., which may be assumed for the average adult emmetropic eye, has grown from some 16 mm. in infancy; and while a diopter or so of congenital hyperopia may possibly have been outgrown, the eye may be said to have changed its length and its refraction exactly *pari passu*.<sup>1</sup> As the other diameters of the globe are generally approximately the same as the axis, and the corneal diameter is about one-half as great, a correction can be thus gained, perhaps, when in an eye not showing typically myopic or hyperopic deformity we wish to estimate from the refraction its exact length and the position of objects not on the retinal level within, as may be desired in case of operation for the removal of a foreign body in the vitreous. (See also page 201.)

The mensuration of objects or distances on or near the retinal level can generally best be given in terms of the cardinal objects there presented for comparison—*e. g.* “broad as the retinal vein,” “two disk-diameters out,” etc. The actual size can easily be then estimated with as close approximation as would be possible with the complicated apparatus devised for actual measurement.

**Examination of the Media.**—Previous to the employment of either method of examination of the fundus it is generally advisable to investigate the media lying in front of it both by *focussed incident light* (oblique illumination, see page 146) and by *transmitted light*.

For the latter it suffices to illuminate the eye with the concave mirror from eight or ten inches away, when any opacity in cornea, lens, or vitreous will appear as a dark silhouette against the reddish background. Magnification of this by a convex lens behind the mirror enhances the delicacy of the test, and often brings to view minute details otherwise invisible. Beginning at some 25 cm. away with a + 4 D. lens, the surgeon can study each eye, both looking straight forward and in oblique positions; and then, approaching closer and using stronger lenses, he can focus at will upon the cornea, lens-

<sup>1</sup> Randall: *Trans. Amer. Ophth. Soc.*, v. 1890, p. 657.

layers, anterior or posterior capsule, or the various depths of the vitreous, until at the closest range the strongest available amplification may be utilized. Foreign bodies escaping every other effort at their detection are thus readily seen, and opacities or vascularities of the cornea form striking objects.

The preliminary observation from a distance has a great advantage also in the determination of refractive errors, for little or no eye-ground detail comes sharply to view, except in hyperopia or marked myopia: in the latter, slight movement of the eye or head will show that the image is inverted. Irregularities of refraction also become thus readily manifest, flattened facets left by loss of substance appearing like blisters in a window-pane to distort the details seen through them and give the image as in high hyperopia. The condition known as *conicity of the cornea or lens* may thus appear to give a dark center or surrounding zone, although the tissues be perfectly transparent; and if the observer draw back a meter or more and use a long-focus or plane mirror, every eye will give shadows in the pupil with slight rotations of the mirror, and the method becomes what is known as the *shadow-test* or *retinoscopy*, our most delicate means of estimating the refraction (see page 202). Notable differences of eye-ground level are conspicuous when studied from a distance of 20 or 30 cm., and this constitutes the best way of studying detachments of the retina, vitreous opacities, and intraocular tumors.

Admirable, too, is this method for learning the *position of opacities*, since the movements of the eye are about a fixed center of rotation back of the posterior pole of the lens; and every visible object anterior to this will seem to move in the direction of the gaze, and everything posterior in the opposite direction, the rapidity and extent of the excursion indicating by parallax its distance from that center.

**Auto-ophthalmoscopy.**—A word may also be said as to auto-ophthalmoscopy, although its value is limited. Several methods may be employed, but the simplest is that of Coccius, to hold the plane skiascopy-mirror between the eye and the shaded light, so that the light falls into the pupil through the ample sight-hole, while the emergent rays are caught by the margin of the opening and reflected back to the macula (Fig. 124). Upon the

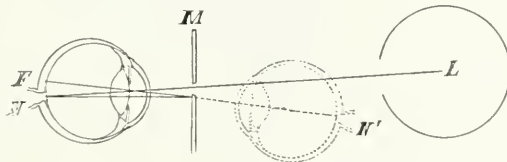


FIG. 124.—To illustrate auto-ophthalmoscopy.

dark background behind the lamp the observer will then project the image of the small illuminated area, and with a little care the disk can be found and studied and the vessels followed out a long way in any direction except close to the macula. The picture is not a mere suggestion, like the Purkinje image, but can be drawn in good detail; and he who is working up eye-ground sketches, and has no other model at hand, can thus often freshen his impressions of form or color at the moment when he most needs them. The inability to see the macular vessels is compensated by the endoscopic methods of bringing them into view (Fig. 134), either by the convex mirror of Ayres or the pin-hole of Mandelstamm.

**Illumination** is, first and last, the most important element of success in all these measures. A steady and ample source of light of fairly uniform

color is therefore essential. Daylight is undoubtedly the truest illumination under which to study conditions where faint gradations of color are at times all-important; yet even within the hours when it is obtainable it varies greatly in any consultation room. Its use may be ignored except as a matter of curiosity or in some leukemic conditions, when it may be noteworthy if the fundus looks as yellow under it as the normal eye does by lamplight.

An Argand gas-burner, so mounted upon a hinged bracket or an adjustable stand that it may be shifted to any desirable position, is almost always obtainable or may be substituted by any good oil lamp. A second chimney, of glass or isinglass, will shut off much radiant heat from the observer, and still more from the patient nearer by; while an opaque chimney of iron or asbestos with a vertically oval opening about 3 to 5 cm. will be found useful in restricting the light to the desired direction, leaving everything else in shadow. With this precaution the ophthalmoscopic room need not be very dark, although strong rays of daylight should be excluded by shutters or shades; and it is very well to have several blackish surfaces conveniently placed to form fixation points for the patient's gaze during examination. The eyes may be thus kept steady, while the dark surface affords nothing to call forth accommodative strain or pupillary contraction. Either of these may prove serious obstacles to some of our measures, and it is worthy of much care to avoid them.

The test and glare are trying even to well eyes, and must be mercifully and judiciously tempered for over-sensitive cases if we would obtain full success and avoid actual injury. Here the use of the plane or weak-light mirror may have decided value, or the reduction of the light by turning it down or narrowing the aperture through which it shines. If gas-fixtures are used, it is very desirable to so arrange them that the light may be near the patient or the observer as desired, and with a range of 4 to 6 m. for skiascopy—a need best met by having a bracket at each end of the room, one being also used for illumination of the test-type. It is inadvisable to have the light too close to the patient, and much heat reflected by the mirror and directly radiated from the flame may be spared him by putting the burner a foot or more back of his head. It is important, too, that the light shall be as nearly as possible behind the head, so as to avoid needless rotation of the mirror; but it must not be cut off by the patient's head when the macula or temporal retina is being studied. It will be found that if it is far enough to the side to illuminate the lid-margins at the outer canthus, it will meet all conditions. Moderate tilting of the mirror will then suffice to throw the light into the eye, and the instrument can be brought so close that it touches the brow and eyelashes of the patient without having the light cut off.

**Position of Surgeon and Patient.**—One of the cardinal errors of the beginner is in not getting close enough: the field of view is thus restricted, the corneal reflex more disturbing, and refractive errors unduly distorting or blurring to the details. In highly ametropic eyes great differences in the required lens depend upon its distance from the anterior focal point of the eye—some 13 mm. from the corneal pole; and in high myopia a satisfactory view can sometimes be obtained only when the observer's brow is actually touching that of the patient. This presupposes the condition, essential in most cases, that the observer use his right eye for the patient's right and hold the ophthalmoscope in his right hand, and *vice versa*.

The convenience, or even the possibility, of doing this depends in part upon the seating of patient and observer, and the face-to-face position usual abroad is not at all the best. It is better that the observer's chair should be



close beside the patient's, with the seats fully overlapping; and then, unless very discrepant in height, each may sit erect and at ease. A child is often of better height standing by the ophthalmoscopist's seat, and, on the other hand, satisfactory studies can be most hastily made when the observer stands by the sitting or standing patient. If the light be on a swinging bracket, it can be instantly swung from one side to the other, while the ophthalmoscopist transfers himself and his seat to that side for the study of that eye. Each will learn the position most satisfactory to himself, and habitually adopt it, but a constrained pose is to be deprecated as imperilling accuracy and thoroughness. Children often tend to nod forward if quiet, or, on the contrary, to wriggle and turn, so as to need some steadying: the free hand may do good service, therefore, in lightly grasping the occiput, while the thumb rests in the concha, controlling any rotation (Figs. 125, 126).

Limited by the pupil into which it is thrown, the beam of light utilized



FIG. 125.—Position of examiner and patient for direct ophthalmoscopy, with seats overlapping and brows almost in contact. The right hand and eye are used in examining the right eye of the patient, and the lamp must be on the same side (De Schweinitz).

in the direct method is that from a portion of the mirror close around the sight-hole, and but little larger than the pupil. This must be quite accurately centered with the pupil, as is sometimes best done by throwing the light from a little distance upon the cheek, when the dark center of the illuminated area marking the sight-hole can be seen, and this then centered in the pupil. At the bedside a light with a lens giving a parallel beam is useful. If a candle only be available, inclination of this gives a broader flame and a less limited area of light on the retina.

Three *principal obstacles* are met in the study of the interior of the eye: *reflections, opacities, and refractive errors.*

**Reflections.**—To the beginner these are very annoying. He hardly ever approaches sufficiently close to the eye, his fundus-illumination is rarely the best, and the brilliant *corneal reflex* seems to occupy most of the pupillary space, and frequently is regarded as the whitish optic disk for which he is instructed first to look. In a narrow pupil this reflection from the cornea (and to an



extent generally unperceived those also from the front and back surfaces of the lens) is ever an obstacle which the expert cannot wholly ignore, and may at times find insurmountable. Generally he can look to the inner side of it or through its margin, and approach so near that its perception is slight. A small sight-hole also reduces its annoyance by increasing the fundus-illumination and cutting off some of the rays reflected from the cornea.

Reflections are present at all the boundaries between the media, but only those upon the retina are apt to be noticed when not specially sought. In childhood, particularly, the whole retina is often covered, especially along the larger vessels, with shimmering, "watered-silk" reflections, which shift with each motion of the mirror, and by the reversed direction of their movement show that they are formed by concave surfaces where the prominence over the vessels passes into the general retinal level. Of the same nature is the more definite *reflex-streak* parallel to the nasal side of the disk, to which

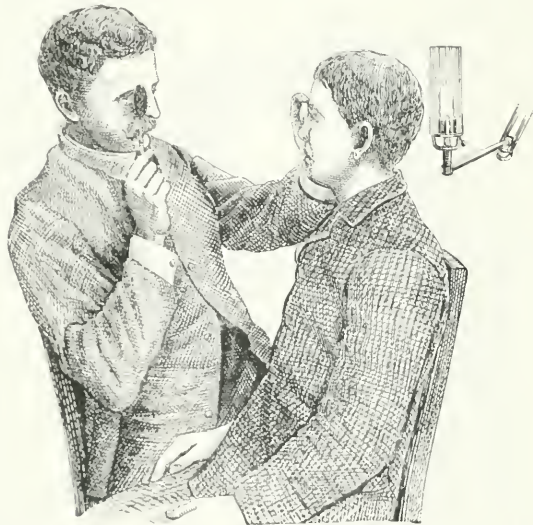

FIG. 126.—Position of examiner and patient for indirect ophthalmoscopy: the seating can be the same as for the direct method, but the examiner sits a foot or more away, holds the object lens at about its focal distance in front of the observed eye, steadying it by resting the other fingers on the face, and can use the same eye and hand, without change of the lamp, to examine either eye of the patient (De Schweinitz).

Weiss has called attention as being prodromal of myopia (see page 187, Fig. 132), and the bright streak (so-called *light-reflex*) always to be seen along the retinal vessels, especially the arteries, has been thus explained.

In the macular region a *halo* can often be seen by the indirect method, generally horizontally oval, and having a diameter two or more times that of the disk. This is less easily seen in the upright image, unless a strongly concave mirror be used; and unless the ring of reflecting mirror just around the sight-hole be centered exactly with the pupil, only a portion of it will be visible. So, too, as to the little reflection from the *fovea centralis*, which is apt to be crescentic or comma-shaped unless the mirror is exactly centered. Then the tiny concavity reflects the entire ring of brightness surrounding the sight-hole, while the center of its floor gives back a central point of light. Like most retinal reflections, these are best seen when the surface is a little beyond the focus, and are more apt to aid than disturb, since they serve to locate the points deserving minute scrutiny, and are lost as the retinal structures are precisely focussed.

**Opacities of the Media.**—These are at times prohibitory of study of what lies beyond them, and unless their presence and character be perceived they may prove very harassing or misleading by suggesting partial obscuration of the fundus details, retinal lesions, or refractive errors. But due employment of focal illumination and the lighting of the fundus from a little distance will rarely fail to reveal the real difficulty and serve to locate it exactly. Against the red field of the illuminated pupil every such opacity will show dark in proportion to its lack of transparency; with a magnifying lens behind the mirror most minute and faint objects may be discerned readily. Not only real opacities, but also irregularities of surface, such as conicity of the cornea or lens, flattened facets, or plications as of the capsule, can be thus revealed, and the resultant impairment of vision correctly interpreted. Most difficult of all are the cases of turbidity of the media, since there are often no formed elements to give definition to the opacity, which merely obscures the view. Where the aqueous humor is at fault the altered appearance of the iris often furnishes the clue; but a discolored lens or a turbid vitreous can at times puzzle the most expert and permit of diagnosis only by exclusion.

**Location of Opacities.**—This is of frequent importance. When far back near the retina the anterior position of opacities can generally be appreciated, if not estimated, by parallax, as compared with the movement of the retinal vessels; but the expert easily measures in the erect image by the interposition of convex lenses how much forward an object lies. Near emmetropia each diopter gives a difference of 0.3 mm.—theoretically increasing to the myopic side, decreasing in hyperopia (*e. g.* + 6 D. = 1.77 mm.; - 6 D. = 2.13 mm., Nagel). Anterior opacities, on the other hand, are generally referred to the pupillary margin, and by their motion relative to it in movements of the eye their distance back or front is determined. The center of corneal curvature, which is near the posterior pole of the lens, may also be used, as pointed out by Jackson: the image of the mirror can always be seen in the line of this point, and any motion in reference to it determined. As previously stated, the rotation-center of the globe is the cardinal point of reference (p. 179).

**Refractive Errors.**—These can markedly complicate the diagnosis if the observer be not well posted. It is often surprising how much can be discerned in an unfocussed eye-ground, not only when hyperopia allows a clear view of details from a distance or to an observer who does not relax his accommodation, but even when considerable myopia or astigmatism precludes sharpness of definition. To the indirect method these cases offer small difficulty: moving the objective lens a little to or from the eye compensates for large axial variations, while a little tilting of it makes or corrects astigmatism as great as is often met. Yet even to the direct method more is revealed than might be expected, and careful focussing is called for to decide whether all the distortion or blur present is really due to the refractive error. Much anatomical anomaly or pathological lesion can be concealed by the imperfection of the view; and minor changes in nerve, choroid, and retina are thus habitually passed over unseen or ignored by ophthalmoscopists of long experience. The habit of sketching the findings in the examinations has here one of its prime functions; and the use of stereotyped forms on which to fill in details is to be condemned, at least for the beginner. Each drawing, however rude and imperfect, should portray with all possible precision the apparent form of the disk, the trend of its vessels, and the conditions of its margins; since the minute observation here called for may prove unexpectedly valuable in these very cases, and begets an exactness of perception essential

and invaluable both in refraction-measurement and in the clinical observation of diseased conditions.

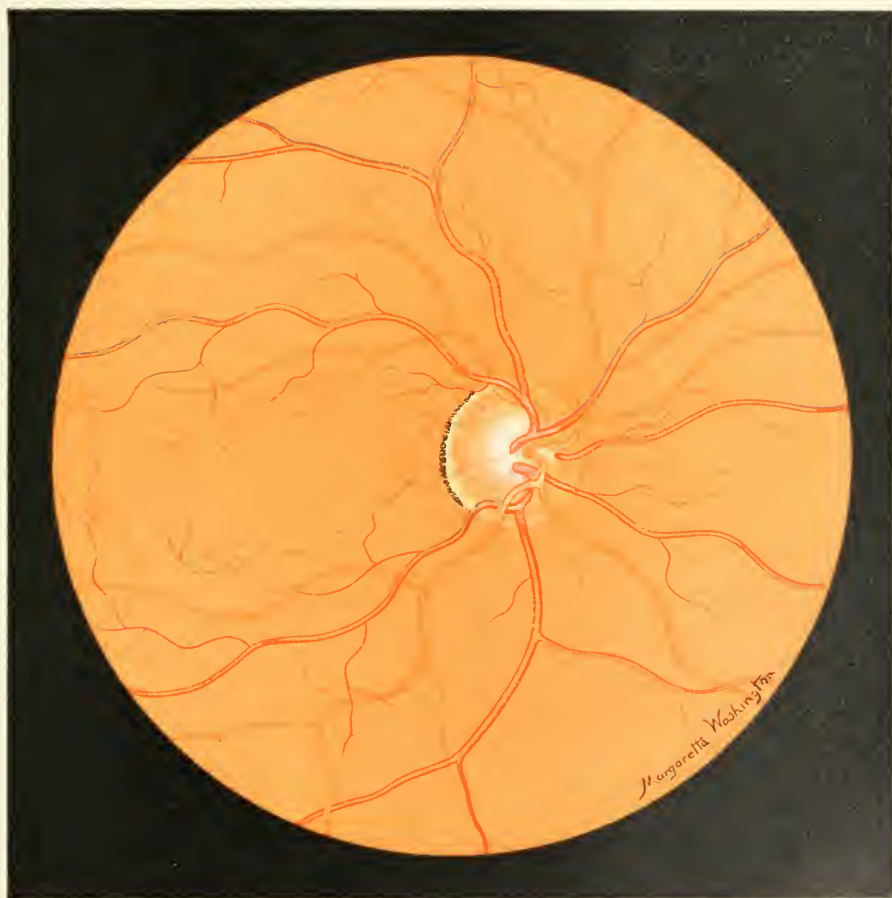
**Differences of Level in the Eye-ground.**—These are always to be expected. The normal disk has a prominence which justifies its name of *papilla*, although its center is often excavated nearly to the level of the *cribriform lamina*. The excentric location of the disk commonly exaggerates the greater protrusion of the nasal side, and its major vessels are decidedly prominent. This prominence may be much increased by edema and inflammatory infiltration, while the lower level of the outer margin and adjacent posterior pole grows deeper with the atrophic changes and stretching of "posterior staphyloma." This phrase, like that of "conns," is often employed as to conditions not strictly fulfilling its primary meaning; but the opposite view, that bulging at this point due to inflammatory softening does not take place, meets daily refutation. These points must always be taken into consideration, not only in relation to the present refraction of the eye, but also as to its past and future.

In the direct examination, then, we measure the direction of the rays of light, which, emerging from the observed eye, form a sharp image on the observer's retina. But this relation is affected by the observer's refraction as well as the patient's. Only upon an emmetropic eye will parallel rays be exactly focussed; and any interposed lens needed to make sharp the image measures the momentary ametropia of the patient  $\pm$  that of the observer. But it is only the refraction at the moment which is measured, and this may be very far from the static refraction which we desire. The ophthalmoscopist must learn what is his true static refraction, and as far as possible relax always to this condition. The author believes every one can learn so to do, although fatigue, headache, or improper conditions will at times preclude utilization of the faculty. If the examiner does not, any fixed allowance for his unrelaxed accommodation is so utterly vague as to be of little value. Those who habitually use mydriatics to the total paralysis of accommodation, and accept in their measurements nothing as "near enough" to right which can possibly be improved upon, learn that total relaxation and total paralysis are identical in almost all cases, and that the "tone" of accommodation of which Donders wrote decreases under scrutiny to the vanishing-point.

**The Normal Fundus.**—The prime feature and landmark of the eye-ground is the *nerve-head*, with its branching central artery and vein. This lies some  $15^\circ$  to the nasal side, and a little higher than the posterior pole of the globe, and appears as a whitish disk from which the vessels ramify in the fundus (Fig. 127). It is surrounded by the red choroid, which usually defines sharply its margin; and the frequent massing of choroid pigment here may give a gray or black edge, which is occasionally half as broad as the disk. The opening through the choroid is normally smaller than that of the sclera, and hides all trace of this; but at times, without recognizable absorption of the choroid or its pigment, a ring of white scleral tissue (*scleral ring*) can be seen, partial or complete, within the *choroidal ring*. (See Plate 1.)

Consisting of the nerve-fibers which enter to the retinal level and then disperse, the disk often presents a slight prominence or *papilla*, in the center of which the diverging tissues form a *porus opticus*. This may be inconspicuous, especially in early life; but is at times both wide and deep, one edge or perhaps all steep or overhanging, while part of it is usually shelving. The most conspicuous feature is the group of branching vessels. Both artery and vein may come to the summit of the papilla before dividing, but commonly both branch in the bottom of the *porus*, while occasionally only the

PLATE I.



The normal fundus.





subdivisions in bewildering number emerge from the nerve-head. Little difficulty should be experienced in distinguishing the broader, darker veins with their crimson tint from the scarlet arteries, which are near the color of the background; but the smaller branches differ less until they cease to be differentiable. On the larger veins and on all the arteries distinguishable as such, a bright streak of reflection ("light-reflex") marks the central convexity and shifts slightly with variations of the light.

The branching is usually dichotomous, giving an upper and a lower artery, which again divides into a temporal and a nasal branch, while the veins

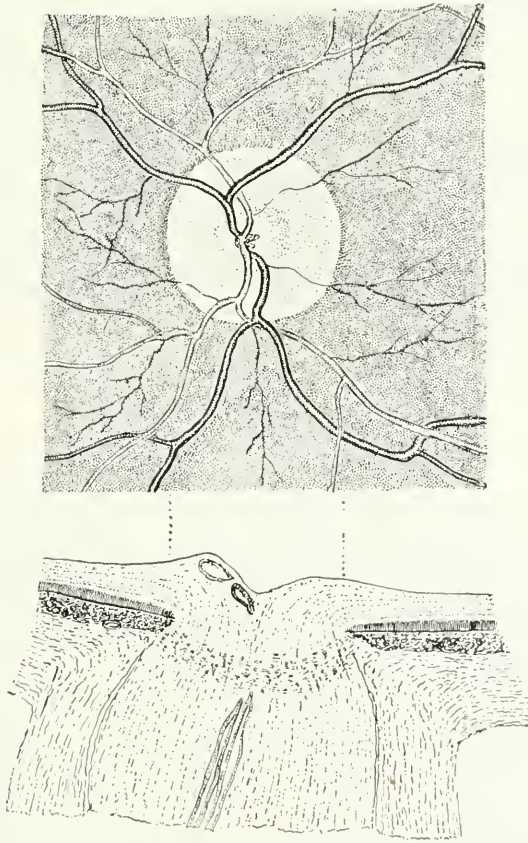
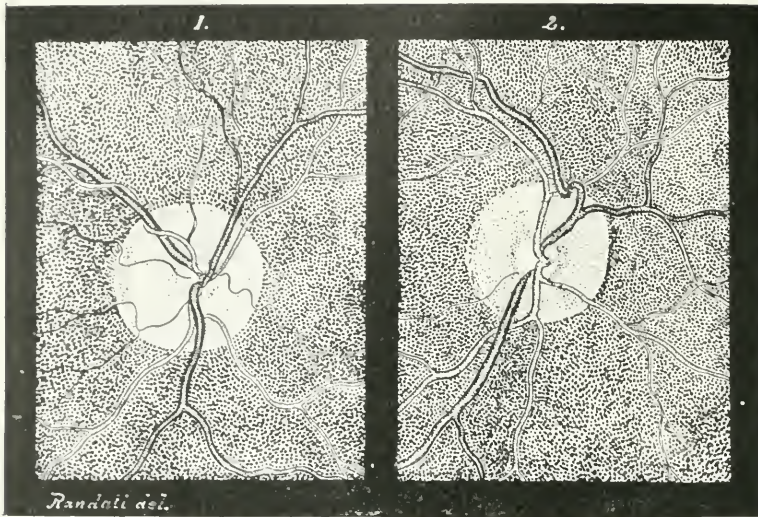


FIG. 127.—Normal optic nerve-head, as seen with the ophthalmoscope and in section under the microscope, each  $\times 15$  diameters. The slight papillary elevation, with its central porus, the central vessels, and the beginning of their ramification in the fiber-layer of the retina, the sharp-cut margin of retinal and choroidal pigmentation outlining the disk and slightly emphasized as a choroid ring, are well shown.

present fair parallelism. Small vessels, not always visibly arising from the central, generally pass outward toward the macula; and at this margin especially, independent *cilio-retinal vessels*, not always of small size, are frequently met. The branches pass from the disk with sinuous curving sweep, as a rule, and with slowly diminishing caliber extend toward the periphery. On the disk, especially as they curve down into the excavation, the veins often present visible pulsation, and in rarer cases of disproportionate pressure the arteries also empty and fill, particularly in glaucoma; crossing and entwining of vein and artery are common (Figs. 128, 129), but it is extremely rare for

vein to cross vein, or artery artery. Anastomosis of the vessels, almost always on the disk, is also of the rarest occurrence (Fig. 130).



Figs. 128 and 129.—Entwined retinal vessels. Twisting of a retinal vein around the accompanying artery on their way to the region supplied is not unusual—generally about the margin of the disk: such a course of an artery, as the superior temporal in (1), is rarer, as is also the recurrent turn of the upper temporal vein to twist around the upper nasal artery in (2).

The rear limit of the nerve-head is the *cribriform lamina*, at which the optic nerve-fibers lose their sheaths and enter the eye as naked axis-cylinders.

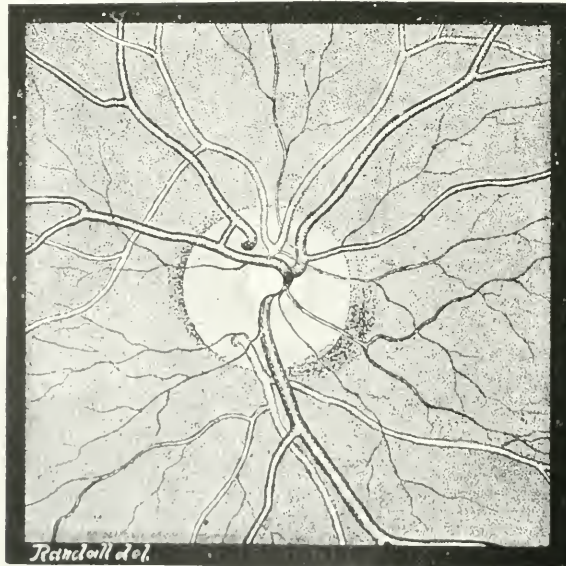

FIG. 130.—Anastomosing veins and aberrant artery.

This varies in depth, but can generally be distinguished, especially at the porus; and a deep excavation generally has as its bottom this mottled sieve-tissue.



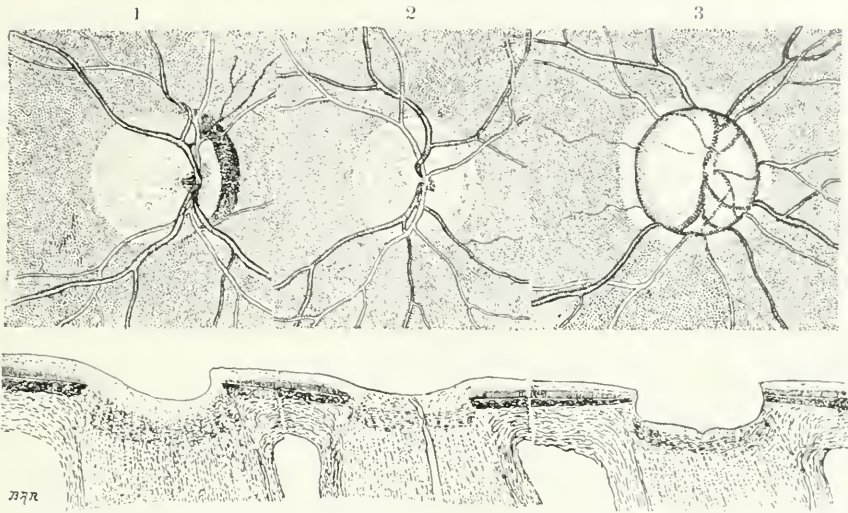
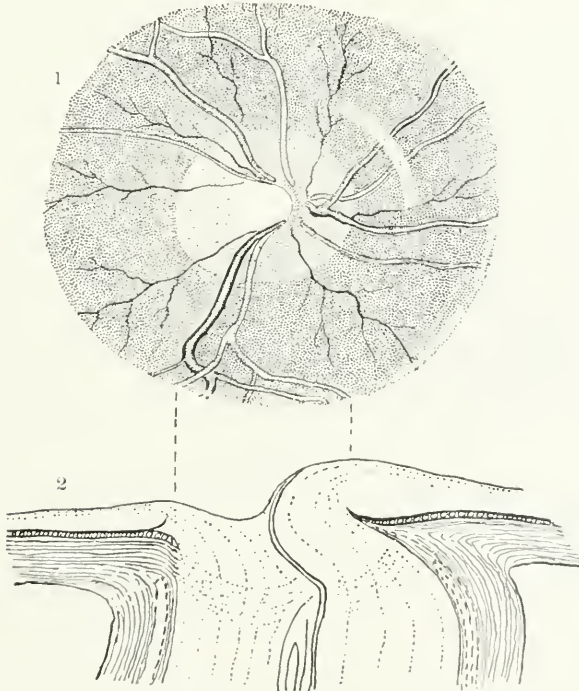


FIG. 131.—Excavations in nerve-head: (1) physiological, (2) atrophic, and (3) glaucomatous excavations.

The *physiological cup* or *excavation* is usually present, and similar on the two sides, and, however deep and sharp-cut, always leaves a marginal ring of the disk undepressed. The vessels can generally be seen to emerge through



*Randall*

FIG. 132.—Curvilinear reflex-streak to the nasal side of distorted disk. The eye-ground appearances are given in (1) with the shimmering yet fairly fixed reflection concentric with the upper nasal nerve-margin of a stretching myopic eye. In (2) (copied from a section of such an eye) (Weiss; *Nettes. Meth.*) is shown the supra-traction of the choroid and the distortion of the nerve-head, projecting high on the nasal side, and furnishing as it passes into the retinal level the concave surface which gives back the reflection.



this tissue, which seldom overhangs the cup at all sides; and while the veins often present pulsation, this is rarely seen in the arteries unless the ocular tension is increased or aortic regurgitation is present (Fig. 131). An examination of the diagrams will make clear the differences between physiological and pathological excavations (see also p. 382).

Often there is a curvilinear reflex a little outside of the nasal nerve-margin, due to the concavity where the prominent disk sinks into the adjacent retinal level (Fig. 132). Weiss, who called attention to this, regards it as prodromal of myopic stretching. In like manner a double-ridged crescentic area to the nasal side was proven by Jaeger to be due to supra-traction of the choroid; and Nagel and Weiss hold it to be a feature in many myopic changes. While none of these things are pathognomonic, they deserve to be seen and weighed.

The **macula** or center of most distinct vision near the posterior pole of the eye is the most important, but generally least conspicuous, region of the retina. The pupil is apt to be at its smallest when this is illuminated, the eye least steady, the corneal reflex most annoying, and the accommodation most variable. Under these conditions some of the older authorities used to be skeptical as to the visibility of the *macula lutea*. "Yellow spot" it is not normally in life, but only a region of deeper coloration, generally maroon in tint, with a little shifting reflex at its center (*foveal reflex*). This, which is an inverted image of the ophthalmoscopic mirror given back from the pit-

like *fovea* as a concave mirror, has the form of the illuminated area of the ophthalmoscope—annular if the sight-hole is exactly centered before the pupil, but generally crescentic or comet-shaped if excentric. A tinier central point from the center of the fovea is sometimes seen.

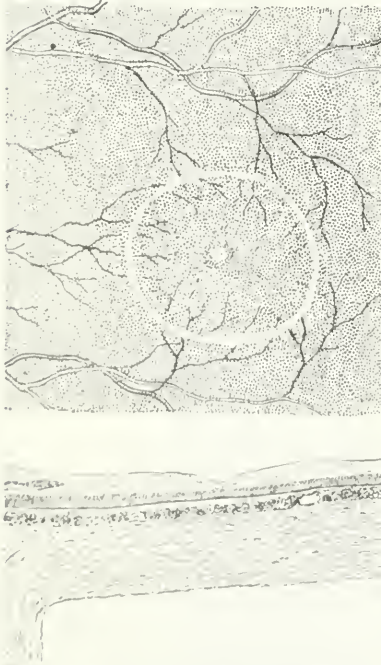


FIG. 133.—Halo around the macula as seen in its entirety and reflex from the fovea.

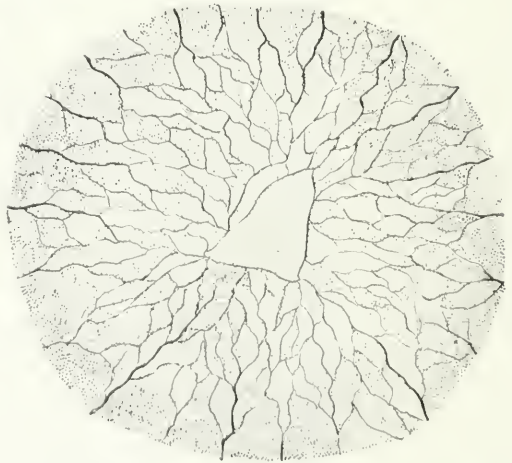


FIG. 134.—Minute vascularization of the macular region as shown by entoscopic study of the writer's right eye illuminated through a moving pin-hole.

Outside of the macula, where the change in retinal thickness begins, a *large ring* or *halo* (*macular reflex*) may be seen, complete only when the mirror is exactly central, generally partial and faint in the upright image. As in the

better definition of the indirect method, it constitutes a horizontally oval ring decidedly larger than the disk, and from 1 to 2 disk-diameters out from its lower border (Fig. 133). Like all retinal reflexes, these phenomena are best seen with a strongly concave mirror, and seem to shift somewhat above the retina, fading as we focus down to the exact level at which they arise—an additional proof that they are real images formed by concave reflecting surfaces. With advancing life all such reflexes are dim or lacking.

The center of the macula is devoid of blood-vessels, as may be best seen by the *entoptic* study (Fig. 134); and the ophthalmoscope, failing to reveal the capillaries which surround it, can best place it by the way in which vessels approach it from all sides without reaching it (with rare exceptions). Its most important blood-supply, like its nerve-fibers, comes from the temporal margin of the disk, and the occasional presence of an independent *cilio-retinal artery* has saved central vision in some cases of embolism of the central artery. More than in thicker parts of the retina, the stipple of the pigment-layer should be recognizable in all this region, and furnishes the most delicate focussing object in measuring the refraction in the optic axis. Senile changes are frequent in this region; albuminuric and other lesions are here most characteristic, and sometimes almost prodromal; and hemorrhagic lesions are not very rare; so its scrupulous study should be the rule (see pp. 416, 420).

The **periphery of the retina** offers no special peculiarities, and is difficult to see only in proportion to the narrowness of the pupil. It is the seat of the earliest changes in retinitis pigmentosa; its underlying choroid may show equatorial myopic stretching or splotches of disseminated choroiditis and other syphilitic affections—lesions that are often most marked up and in; while down and in, where skylight falls unobstructed by the brow, we commonly find any changes due to its irritation.

The **color of the eye-ground** is a composite blending of factors varying in value in every case. In blondes the sheen of the almost invisible retina is backed by the orange-red of the *chorio-capillaris*, veiled by little retinal pigment: back of this are the broader bands of choroidal vessels, through as well as between which light is reflected from the sclera. Only in the albino does this outer coat appear in its full whiteness, while in most eyes little light even reaches it through the pigmented tissues. The amount of pigmentation affects the tone and conceals the deeper layers in varying degree, until in the negro the retinal pigment gives a slaty *tapetum*, almost as reflecting as that in the lower animals. Every gradation of pigmentation can be seen, not only in different eyes, but almost in the same eye, since the periphery is generally less dark, and the choroidal structure may show everywhere except in the macula, where the pigment is richest. These peculiarities, especially at the nerve-margin, are worthy of note, verbal or graphic as well as mental, in a large proportion of cases, since they mark minor but often important changes there in progress. So too as to the *porus opticus*, which is rarely marked in the infantile disk, but soon becomes definite, and at times increases greatly through atrophy or mechanical pressure.

**Physiological Variations and Congenital Anomalies.**—Among the countless deviations from an ideal relation of the eye-ground picture, variation in the vessels is most common. Often the division of the vessels is within the nerve, and only the branches, perplexingly subdivided, appear on the disk. The distribution may be accomplished by most roundabout curves, the whole group of vessels passing inward, or in some other direction, before separating toward the different quadrants of the retina. The main blood-supply of the lower nasal retina may come from the upper nasal vessels (Fig. 130) or any similar irreg-

ularity; and large areas, even in two quadrants, may be supplied by no branch of the central artery, but by a *cilio-retinal vessel* arising at the edge of the disk from the short ciliary vessels or communicating with the choroidal system (Fig.

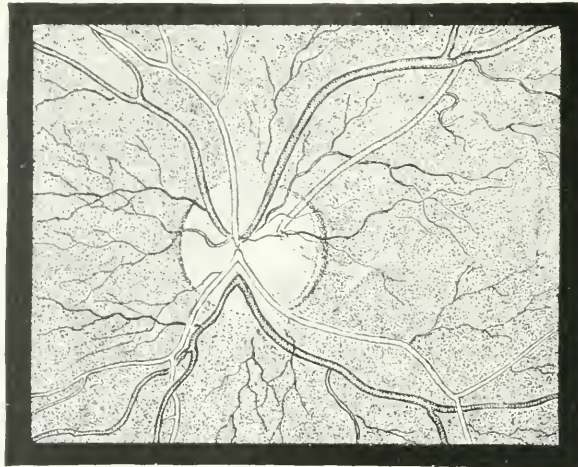

FIG. 135.—Choroïdo-retinal aberrant artery.

135). Tortuosity of vessels may be mere exaggeration of their normal sinuositities; but at times, especially in strained hyperopic eyes, they may have the marked curves, vertical as well as lateral, usual in neuro-retinitis. Single loops may lie across the disk or adjacent retina (Fig. 136) or protrude into the vitreous, or the single strand of the *persistent hyaloid artery*, generally devoid of blood, extends forward, in rare instances reaching or branching upon the posterior capsule of the lens. Small cystic outgrowths, especially to the nasal side, may mark a more atrophic stage of its condition (Figs. 137, 138).

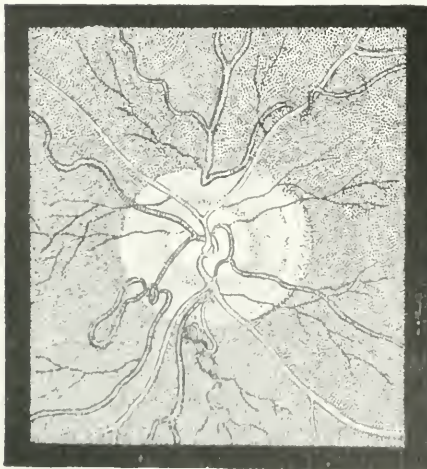


FIG. 136.—Looped and tortuous vessels.

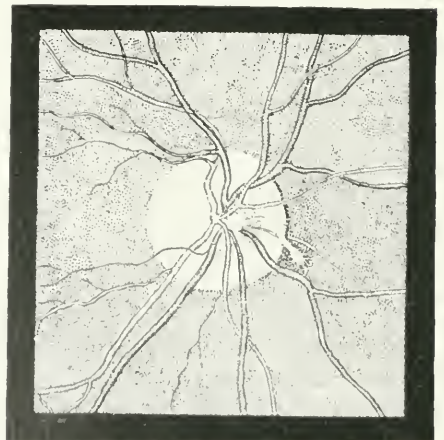


FIG. 137.—Persistent hyaloid artery.

Super-numerary depressions of the disk with emerging vessels are occasionally seen; more often there is a *colobomatous gap*, due to incomplete closure



of the fetal cleft. This, which is normally open but for the sixth or seventh week, may be held open, probably by intra-uterine inflammation, and give rise to most various and extreme malformations. The disk may be alone colobomatous and show a depression, oftenest downward, of dark aspect and apparently

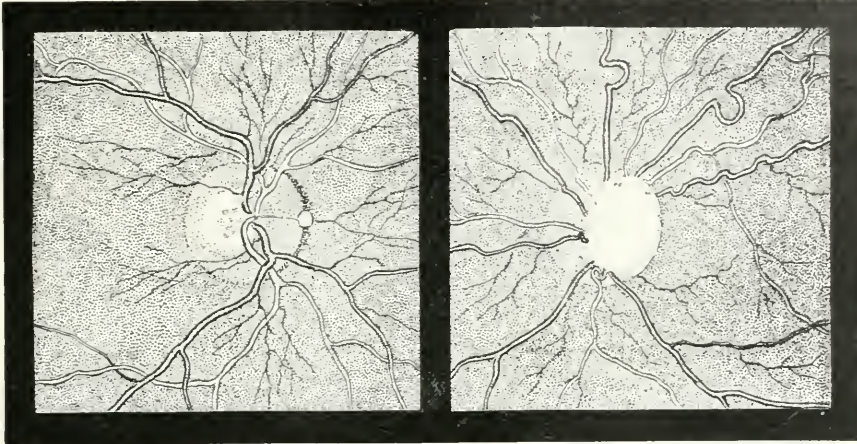


FIG. 138.—Cystic outgrowth on disk.

FIG. 139.—Fibrous outgrowth on disk.

immeasurable depth (Fig. 140), or the white sheath may be plainly seen beneath the gap. Sometimes the sheath alone is involved, and the disk, superficially normal, shows a peculiar greenish coloration near one margin that can be traced into its depths. Oftener the choroid shows a defect, usually downward, at times

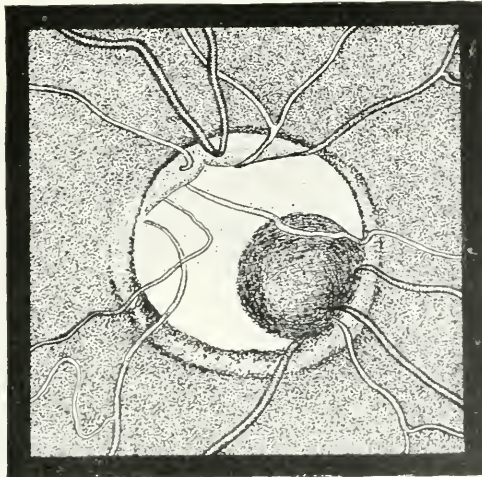


FIG. 140.—Coloboma of nerve and sheath.

involving nerve and sheath, and perhaps extending broadly as far forward as can be seen (Fig. 141), while coloboma of iris or lens, or both, marks the greater extension (in time as well as area). Difficult of explanation are those rarer cases in which the defect is outward, inward, or even upward, where the fetal cleft can hardly be supposed to have had influence. Gap of the retina alone, true persistence of the fetal cleft itself, has hardly ever been



described: some representative of retinal structure is usually present, when perhaps not even a vessel marks choroidal tissue, and the lack or stretching of scleral tissue forms a considerable staphylomatous concavity. Areas of defect at or near the macula (Fig. 142) are probably not related to the fetal cleft, but mark mere atrophy and non-development resulting from fetal inflammation—a process that may leave strands, knobs, or false folds of membrane protruding into the vitreous chamber, and is doubtless responsible for the persistence or perversion of most of that for which the faulty prenatal development is held accountable.

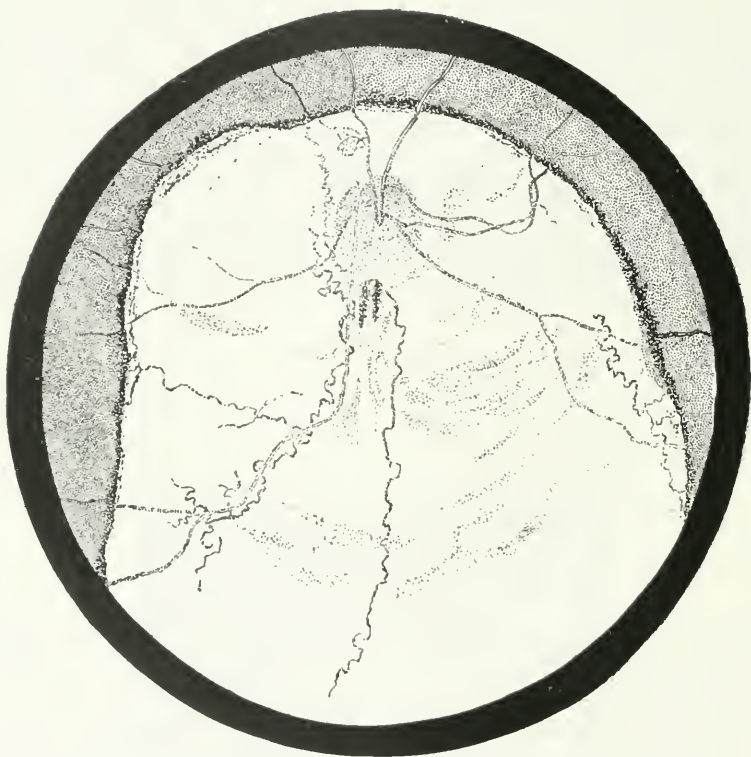

FIG. 141.—Huge coloboma of choroid, involving the nerve-head and extending to iris.

*Conus* was the name early given to the atrophic choroidal changes at the nerve-margin, which sometimes present a form suggestive of a cone. Oftener it is a crescent embracing the outer half of the disk—at times the nasal or other margin—in some cases annular, though generally broadest out. With this is generally associated an ectasia or *staphyloma posticum*, due to coincident atrophy or yielding of the sclera. Noted at first exclusively with myopia, many writers have denied the kinship of the crescents seen in other refractive conditions; and there is little doubt that several groups of conditions ought to be differentiated, just as there are high myopias in the illiterate who do no close work, unrelated to the eye-strain myopia (Fig. 143). Any close and experienced observer has seen at times one of these forms (usually distinct) pass into another, generally with elongation of the visual axis; and he recognizes the relation, although he may feel unable to define or explain it. Whether Hasner's theory of drag by the too short optic nerve

upon its scleral insertion has general or only occasional truth, the crescent most commonly begins at the outer margin as a region of altered color,

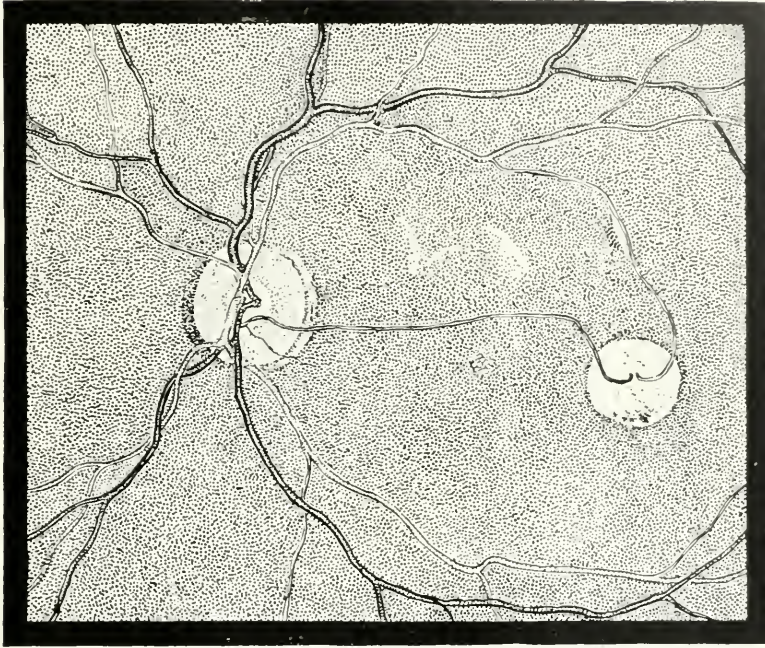

FIG. 142.—Coloboma of macula.

doubtless inflammatory. Pigment is absorbed, to be deposited in most cases at the outer margin of the crescent, and as the atrophy advances the area increases in size, usually by the demarcation of another crescent beyond.

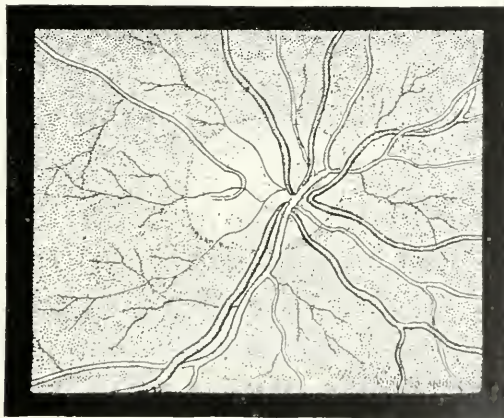

FIG. 143.—Distorted myopic disk with scleral ring, atrophic and semiatrophic conus, aberrant artery, etc.

Three or four crescents at once may be thus shown in one eye in different stages of atrophic change. Rarely the process retrogrades and a crescent of altered color returns to the normal. Actual development of a large myopic



erescens may never have been fully observed, for in most cases it and the advance of the myopic stretching can be stopped by atropine and alterative tonics ; and some of us feel that our full duty has not been done in a case that

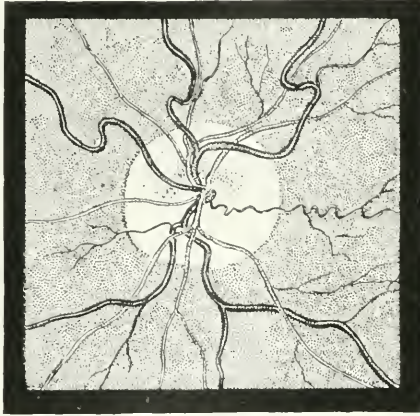


FIG. 144.—Underlying conus below, up to emergence of vessels.

does progress. Yet clinical study has been long and extended, and definite enough to bridge any gaps and show the usual identity of the processes ; and strong anatomical evidence to the contrary could alone disprove it.

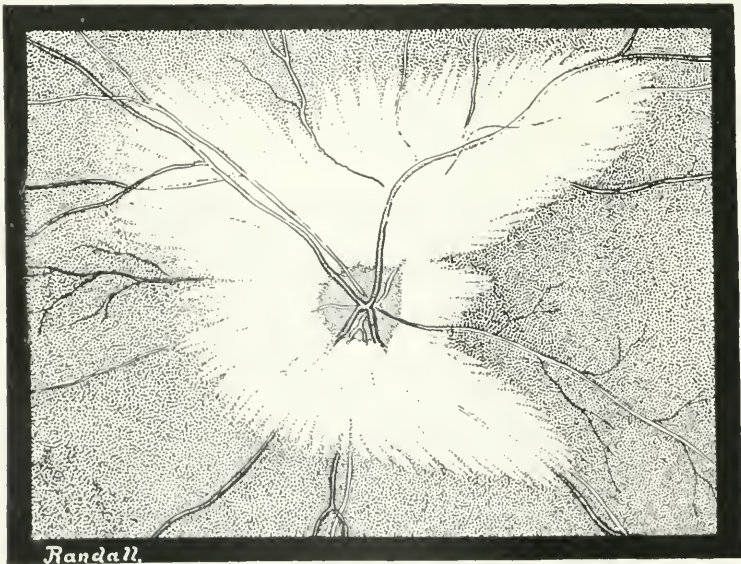


FIG. 145.—Retained marrow-sheath ; huge area surrounding disk.

Probably another matter is presented by the condition called "*congenital conus*," "*conus downward*," or "*underlying conus*." It has the form of a crescent of whitish color, apparently extending *in under* the margin of the nerve, generally below, although also noted in or out or at times even above. It is probably akin to coloboma of the nerve-sheath, although not merging

into this condition, seeming to underlie the upper layers of the nerve-head, and to extend in at times as far as the central vessels. Most like the "scleral ring," normally or morbidly revealed, it yet presents recognizable differences, which seems to mark dissimilarity of nature. Where it is marked, full acuteness of vision can rarely be attained; and the usual presence of notable astigmatism and the frequency of aberrant vessels passing through it point to it as a congenital defect (Fig. 144).

An interesting anomaly, sometimes most striking in appearance, is furnished by *marrow-sheaths on the retinal fibers*. Instead of being lost outside of the *lamina*, these elements are met in patches at or near the disk, of white fringed aspect, partly burying the retinal vessels under their opacity. The

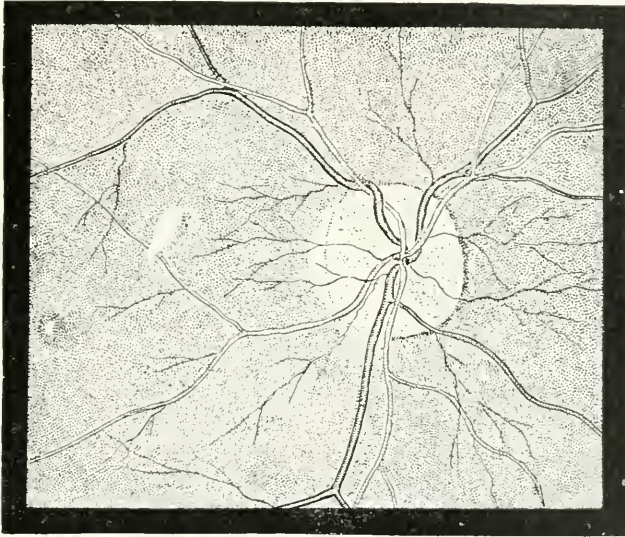


FIG. 146.—Small isolated marrow-sheath patch up and out near macula.

rule in the rabbit and other animals, this is an exception in man, and may constitute a huge broadening of the blind spot (Fig. 145). If extensive, they are apt to extend outward in the line of the major upper and lower temporal vessels, forming a crescentic white patch, within which the macula is seen decentered out. At the nerve they are apt to overlie the margin and to cast a greenish shadow inward; which is, of course, more marked if there be any atrophy of the nerve. They may easily be mistaken for snowy patches of infiltration, such as the "snow-banks" of albuminurie or other retinitis, although generally far more fibrillar in their snowy whiteness; but the differentiation is not easy when they form small isolated patches unconnected with the disk (Fig. 146). Vision, except in the broadened blind spot, may be absolutely unaffected (see also p. 472).



# METHODS OF DETERMINING THE REFRACTION OF THE EYE:

OPHTHALMOMETRY; OPTHALMOSCOPY, SKIASCOPY,  
OPTOMETRY; THE USE OF MYDRIATICS.

BY EDWARD JACKSON, A. M., M. D.,  
OF PHILADELPHIA.

**Ophthalmometry**, more properly called **Keratometry**, is the measurement of the curvature of the cornea and the astigmatism due to the differences in that curvature in different directions. The ophthalmometer consists essentially of a telescope furnished, in connection with its object-lens, with some arrangement for doubling the images formed by it.

In the ophthalmometer of Helmholtz and that of Leroy and Dubois this doubling is effected by covering one-half of the object-lens by a piece of plate glass inclined in one direction, and the other half with a piece inclined in the opposite direction. The separation of the two images produced by this arrangement is the same at whatever distance the object is placed.

In the ophthalmometer of Javal and Schiötz the doubling is effected by a double prism, and the separation of the two images is only constant at a constant distance. To make sure that the images formed by the instrument shall always have this constant distance cross-hairs are placed within the barrel of the telescope. In using the instrument these cross-hairs must be in focus when the images are focussed; that is, the images must be formed at the plane of the cross-hairs. To effect this the eye-piece is so adjusted as to accurately focus the cross-hairs for the observer's eye, and then the images are focussed by moving the telescope to or from the eye under examination until they become distinct with the cross-hairs.

The *curvature of the cornea* is measured by determining how large an object is required to give a reflection from the cornea just equal to the separation of the doubled images. Knowing the size of the object, the size of its reflected image, and the distance of the object from the eye, the radius of curvature of the cornea is ascertained by a simple calculation. With the ophthalmometer of Javal—to which alone, as of most practical value, we shall refer—the distance of the object is always practically the same. It is determined by the distance from which the image of the corneal reflection will be formed at the cross-hairs.

The *size of the corneal reflection* is also constant, being the extent to which the doubling prism separates the two images at the constant distance. This being the case, the size of the object and the curvature (or radius of curvature) of the cornea are inversely proportioned to one another, so that a scale can be calculated upon which a certain size of object will correspond to a

certain radius of curvature of the cornea. Such a scale has been calculated and laid off upon the arm of the ophthalmometer. Along with it is placed a scale of diopters of refracting power, corresponding in an average eye to the different lengths of the radius of corneal curvature.

The instrument is shown in Fig. 147. The most striking part of it is the great metal disk which shades the surgeon from the light, and has on its margin figures to indicate the direction in which the arm is turned. Through the center of this disk projects the telescope, and just below it the arm, placed horizontally, is shown, with the two mires upon it, the fixed mire to the right, the movable mire to the left. On the right of the picture is the head-rest, with adjustable chin-support, and four electric lamps attached to illuminate the mires when good daylight from a space of open sky is not available. The telescope is mounted in a collar which allows it to be freely revolved on its




FIG. 147.—Javal-Schiötz ophthalmometer.


axis, carrying with it the graduated arm and mires, allowing the curvature to be measured in any meridian of the cornea. Unimportant variations as to the disk (which is in some models omitted), form of arm, method of illuminating, etc. are suggested by different writers, but the essential features of the instrument are those above indicated.

**Method of Using the Ophthalmometer.**—To use the ophthalmometer the instrument should be placed where strong light will fall upon the mires. The patient's face, which should be in comparative shadow, is placed in the head-rest, one eye covered with a metal shade and the other directed into the barrel of the telescope. The surgeon, glancing along the telescope, sees that it is turned toward the patient's eye. Then by the large screw passing through one foot of the tripod he adjusts the height of the telescope, and by moving the whole tripod back and forth focusses the corneal images within the instrument. What he sees is the doubled reflection of the disk and mires, one image of each mire (A and B, Fig. 148) being close together. The movable mire is then shifted back or forth along the arm until the edge

of its central image just touches the edge of the central image of the other mire (1, Fig. 149).

It will be noticed that each mire is crossed by a black line parallel to the arm. If the cornea is astigmatic, these lines on the adjoining images of the two mires appear continuous only when the arm is turned in the direction of one of the principal meridians of astigmatism. In other positions they seem relatively displaced. The telescope is now rotated on its axis until the direction of the arm is found in which the lines on the two mires correspond. The mires are then brought so that their images are quite accurately in contact, and the index on the movable mire indicates upon the scale on the arm the radius of curvature of the cornea, and corresponding refraction in one of the principal meridians.

The telescope is next rotated until the arm stands at right angles to its former position. If astigmatism be present, it will be found that in this position the mires either separate or overlap. If they overlap, as in Fig. 149,



FIGS. 148, 149.—Mires or targets of ophthalmometer.

3, the number of steps of overlapping indicates the number of diopters of astigmatism. If in this second position the mires separate, as in 2, Fig. 149, they must again be brought in contact and then rotated back to the former direction, in which they will now overlap and so indicate the amount of astigmatism.

If during the examination the patient looks away from the telescope, so that some portion of the cornea other than the center is presented, the refraction of this other part of the cornea will be indicated, differing, perhaps greatly, from that of the central portion of the cornea. Commonly, the first position in which the mires are brought in contact will be with the arm horizontal. But if it is found that in this position the black lines upon them do not correspond, do not come opposite one another, the instrument must be rotated either way until these become continuous one with the other. The position of the patient during the examination should be made as comfortable as possible by having the height of the instrument or of the patient's chair freely adjustable, and the examination must be completed quickly before the patient has become tired or restless. Ophthalmometry is of special value in cases of aphakia. In other cases the corneal astigmatism which it gives suggests approximately the meridians and amount of the total astigmatism.

**Objective Methods for the Measurement of Refraction.**—Rays of light to be focussed on the retina must enter the eye with a certain degree of divergence or convergence for each degree of ametropia. Rays coming

from any point of the retina and passing out of the eye travel the same paths in the opposite direction, and leave the eye correspondingly convergent or divergent. The refraction of the eye may be determined by ascertaining what divergence or convergence must be given to rays in order that they shall be focussed on the retina. Methods that do this are *subjective* methods for measuring refraction. Or we may take the rays from the retina and ascertain the degree of convergence or divergence which they have on emerging from the eye. Methods of doing this are *objective* methods for the determination of refraction.

**The Ophthalmoscope.**—1. **The Direct Method.**—The retina of the patient being illuminated by the ophthalmoscope, rays proceeding from it enter the eye of the surgeon and are focussed on his retina. If the surgeon is emmetropic parallel rays will be focussed on his retina, and the lens necessary to focus there the rays coming from the patient's retina is the lens necessary to make those rays parallel—*i. e.* the lens which corrects the patient's ametropia.

To determine which lens does this the surgeon watches the finest visible details of the fundus of the patient's eye. When the focussing is imperfect, these details are blurred; when perfect, they are seen clearly. Suppose a case of hyperopia, illustrated in Fig. 150, in which *P* represents the eye of the

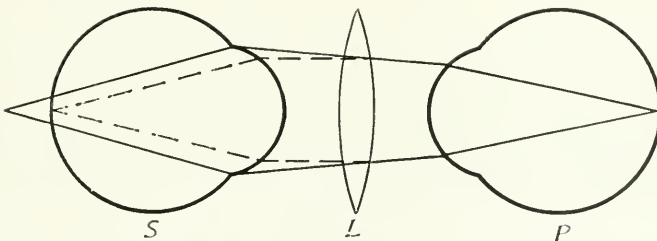


Fig. 150.—Eye of patient and surgeon measuring H.

patient, and *S* the eye of the surgeon. The rays from the patient's retina leave his eye divergent, and are directed to focus back of the surgeon's retina. By trial the convex lens, *L*, is found, which, rendering the rays parallel (see the dotted lines), causes them to be focussed on the surgeon's retina. This lens, *L*, which renders parallel the rays coming out of the patient's eye, is the correcting lens, the lens which would make parallel rays from some distant object convergent enough to focus them upon the patient's retina.

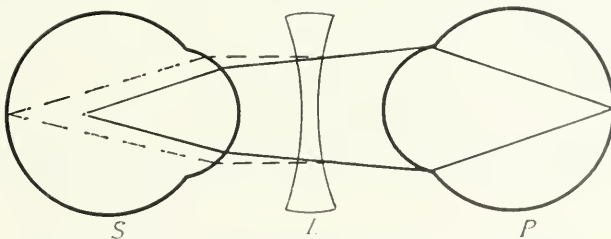


Fig. 151.—Rays in myopia.

In myopia (illustrated in Fig. 151) the rays emerge from the patient's eye convergent. A concave lens, *L*, is required to render them parallel, so that they can be focussed on the surgeon's retina; and this concave lens is the cor-



recting lens which, placed in the same position, would render the parallel rays coming from some distant object sufficiently divergent to be focussed on the patient's retina.

If the patient's eye is emmetropic, the rays emerge from it parallel, and require no lens to secure their perfect focussing upon the surgeon's retina.

What has been said of other forms of ametropia holds for regular astigmatism; only the ametropia differs in different meridians, and its correction in any one meridian affects the distinctness of lines in the fundus running at right angles to that meridian. Thus in an eye where the hyperopia in the horizontal meridian requires a 1 D. convex lens for its correction, and the hyperopia in the vertical meridian requires a 2 D. convex lens for its correction, the 1 D. convex lens renders clear the vessels which run horizontally, and a 2 D. convex lens is required to render clear the vertical vessels; the difference between the two lenses, 1 D., is the amount of astigmatism present.

In the practical use of the ophthalmoscope to measure refraction the chief difficulty is due to the influence of accommodation in the eye of either the patient or the surgeon. In any case the effect of accommodation is the same as the effect of a convex lens, partly correcting hyperopia and diminishing its apparent amount; or adding to myopia, and to that extent increasing its apparent amount. Accommodation in the surgeon's eye is guarded against by practice. Yet always in young eyes, particularly when tired or irritated, there is a chance of some accommodation being present. In the patient's eye accommodation is reduced to the minimum by making the ophthalmoscopic examination in a thoroughly dark room of sufficient size, with the gaze fixed on blank space to encourage the complete relaxation of the ciliary muscle. Using these precautions, the influence of accommodation is still to be guarded against by choosing, as most nearly correct, the strongest convex or the weakest concave lens with which the details of the fundus are clearly visible.

In determining astigmatism one should first seek the strongest convex or weakest concave lens with which the vessels running in any one direction are still clearly seen. This lens will give the hyperopia or myopia present in the meridian at right angles to those vessels. These vessels run in one of the principal meridians of astigmatism, the other being at right angles to this. Having determined the direction of the meridians and the lens required by one of them, the next point is to find what lens renders clear the vessels running at right angles to those seen clearly with the first lens. The difference between the two lenses gives the degree of astigmatism.

Another source of error in measuring refraction with the ophthalmoscope lies in the differences in the refraction of the same eye through different parts of the dioptric media. Thus the refraction at the centre is never the same as the refraction at the margin of the widely-dilated pupil. In some eyes without a mydriatic the pupil dilated in the dark room shows a very different refraction at its margin from that at its center. The refraction at the center of the pupil is commonly what is of importance, and the error which might occur by measuring refraction through the edge of the pupil must be guarded against.

Again, the refraction of the eye varies at different parts of the retina. In a perfectly spherical eye the refraction at the macula is least hyperopic or most myopic. The refraction of the anterior parts of the retina and choroid may be highly hyperopic, even in eyes quite myopic at the macula. Then, too, the depth of the fundus may vary in other ways, as from posterior staphyloma or cupping or swelling of the optic nerve entrance.

It is therefore important to select for the measurement of refraction the details of a certain part of the fundus, generally as near the macula as possible. For astigmatism the examiner should take as test lines the vessels running from the disk to the macula, with their lateral branches. The large vessels as they pass upward and downward from the optic disk are particularly liable to protrude into the vitreous, and thus give an appearance of astigmatism when none is really present. The pigment-layer of the retina and the vessels are usually the parts the refraction of which is measured; but the attention may be fixed upon any other detail seen within the eye. In glaucoma the refraction of the bottom of the cup may be compared with the refraction at the margin of the cup, or in optic neuritis the summit of the swelling may have its refraction compared with that of the retina beyond the swelling. By its refraction the surgeon may seek to locate an opacity in the vitreous. The distances in front of the plane of emmetropia indicated by a certain hyperopia, and the distances behind that plane indicated by an equal myopia, are shown in the following table, calculated for the average eye, having an antero-posterior axis of 22.824 mm. (see also page 178).

| Diopters. | H. Diminution. | M. Increase. | Diopters. | H. Diminution. | M. Increase. |
|-----------|----------------|--------------|-----------|----------------|--------------|
| 1         | 0.31           | 0.32         | 7         | 2.03           | 2.52         |
| 2         | 0.62           | 0.66         | 8         | 2.28           | 2.93         |
| 3         | 0.92           | 1.01         | 9         | 2.53           | 3.35         |
| 4         | 1.21           | 1.37         | 10        | 2.78           | 3.80         |
| 5         | 1.50           | 1.74         | 15        | 3.91           | 6.28         |
| 6         | 1.76           | 2.13         | 20        | 4.90           | 9.31         |

**2. Indirect Method.**—In using the ophthalmoscope by the indirect method rays coming from the retina are focussed by the object lens to form a real inverted image between that lens and the surgeon's eye. When they emerge from the eye parallel, this image is formed at the principal focus of the object lens. When they emerge divergent, as in hyperopia, the image is formed farther from the lens. When they emerge convergent, as in myopia, it is formed close to the lens. By ascertaining the exact distance of the image from the object lens one may determine the refraction of the eye. This has been attempted by placing a screen where the inverted image is most distinct, and measuring its distance from the object lens, but this method is not of practical value.

A modification of this, the *Schmidt-Rimpler method*, instead of the screen has a source of light of peculiar form, enabling the surgeon to judge when it is accurately focussed. To use it the object lens is placed exactly its focal distance from the principal plane of the eye, and by trial the surgeon finds what distance the ophthalmoscopic mirror must be held from the lens to give the most distinct view of the image of the source of light upon the fundus. This is obtained when the focus of the mirror coincides with the focus of the object lens; and a scale attached to the lens gives for each position of this image the amount of hyperopia or myopia to which it corresponds. Fig. 152 represents the course of the rays in this method, the solid lines indicating the rays reflected from the ophthalmoscopic mirror and entering the eye, and the broken lines, the rays coming from the patient's retina to the eye of the surgeon.

By the indirect method the nearer to the eye the object lens is held the smaller is the inverted image in myopia, and the larger it is in hyperopia. The change of size due to the change of distance of the lens in front of the patient's eye varies with the degree of ametropia. Hence the presence and kind of ametropia of high degree can be recognized by varying the dis-

tance of the lens from the eye. In hyperopia the withdrawal of the lens from the eye makes the image smaller, in myopia it makes it larger. In

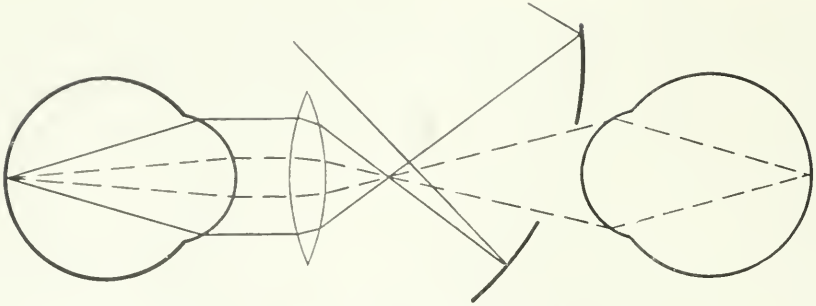


FIG. 152.—Course of rays in Schmidt-Rimpler's method.

astigmatism such withdrawal makes the disk relatively larger in the direction of the meridian of greatest refraction, and relatively smaller in the meridian of least refraction. This change in the form of the disk is an evidence of astigmatism, most noticeable in high mixed astigmatism.

**Skiascopy; Retinoscopy; The Shadow-test.**—The method of determining refraction with the ophthalmoscope by the position of the inverted image is of little practical value, because of the difficulty of ascertaining the exact position of that image and its nearness to the eye. Skiascopy is essentially a method of determining the distance of the inverted image from the patient's eye with great accuracy. Fig. 153 represents an eye in front of which

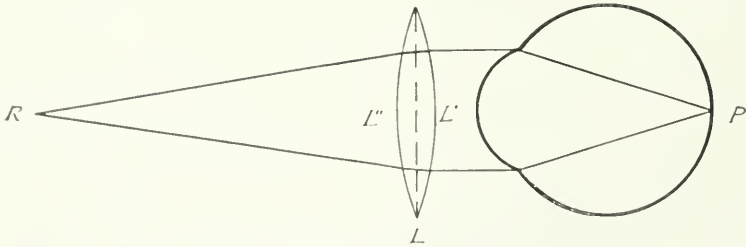


FIG. 153.—Eye with convex lens placed before it.

is placed a convex lens, causing the rays from a point,  $P$ , of the retina to be focussed at  $R$ ; the lens,  $L$ , may be regarded as composed of two lenses,  $L'$  and  $L''$ — $L'$  strong enough to render parallel the rays emerging from the eye, and  $L''$  able to take parallel rays and focus them at  $R$ . By subtracting the strength of  $L''$  from that of  $L$ , it is easy to get  $L'$ , the correcting lens. Suppose  $L$  to have a strength of 5 D., and  $R$  to be 1 m. (the focal distance of a 1 D. lens) from  $L$ .  $L''$  will be 1 D., and  $5 - 1 = 4$  D., the strength of  $L'$  required to correct the hyperopia.

The strength of  $L''$  to be deducted from that of  $L$  is found by determining the distance of  $R$  from the lens. In Fig. 154, representing the patient's eye (myopic) focussing the rays from  $A$  at  $C$  and from  $B$  at  $D$ , it will be noticed that if the surgeon's eye be placed at  $N$ , nearer the patient's eye than  $CD$ , the ray reaching it from  $A$  comes through the upper part of the pupil, so that  $A$  will appear at  $a$  in that direction. But if the surgeon's eye be placed at  $N'$ , beyond  $CD$ , the point  $A$  will appear to be located in the lower part of

the pupil toward  $a'$ , the ray from  $A$  reaching the surgeon's eye from that direction. In the same way, from  $N$ ,  $B$  will appear in the lower part of the pupil, and from  $N'$ , in the upper part of the pupil.

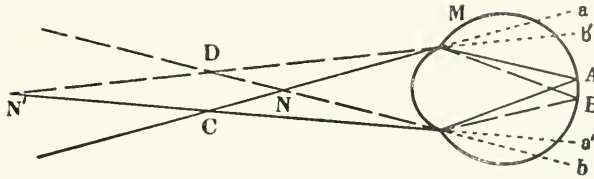


FIG. 154.—Showing how the rays cross, and so change their relative positions at the plane of reversal, D C.

This reversal in the apparent position of any given points of the retina occurs at the distance of  $C$  and  $D$ . Closer to the eye the point really above appears above; the retina is seen in an erect image. Farther from the eye, the point really above appears below, and the point really below appears above; the retina is seen in the inverted image. The change from the erect to the inverted image occurs at the point for which the patient's eye is focussed, either by its own myopic refraction or a lens placed before it; which point is, therefore, called the *point of reversal*.

The position of the point of reversal is determined with practical accuracy by observing the apparent direction of movement of light and shade in the pupil. The light is thrown on the eye with a mirror, usually a special form of the ophthalmoscope mirror, which may be either plane or concave. If plane, it should have a small sight-hole, 2 or  $2\frac{1}{2}$  mm. in diameter, with its margin free from reflections. By turning the mirror slightly in different directions the light reflected from it on the patient's face, and also the portion entering his eye and falling on the retina, are made to move correspondingly. The movement of light and shade as it appears in the pupil is now watched. When the apparent movement is in the same direction as the real movement of the light on the retina, the erect image is being watched, and the surgeon's eye must be inside of the point of reversal, as at  $N$  (Fig. 154). When the apparent movement in the pupil is the opposite of the real movement of light on the retina, an inverted image is being watched and the surgeon's eye is beyond the point of reversal, as at  $N'$ . By studying these opposite movements on the two sides of the point of reversal that point is located.

With a certain movement of the mirror there is always the same movement of the light on the face whether the mirror be plane or concave. Thus, when the mirror is made to face upward the light moves upward across the patient's face. If the mirror is turned down, the light moves down across the patient's face. With the *plane mirror* the light on the retina always moves in the same direction as the light on the face—in the same direction, or *with* the mirror. With the *concave mirror* the light on the retina always moves in the direction opposite to that of the light on the face—always moves *against* the mirror (Fig. 155). The reason for this is that with the plane mirror the light enters the eye as though coming from an image (called the *immediate source* of light) as far behind the mirror as the real or *original source* is in front; but with the concave mirror the *immediate source*—the point from which the light seems to come to the eye—is a small inverted image of the *original source* of light, formed in front of the mirror.

Hence, with the plane mirror, if the light in the pupil appears to move *with* the mirror—with the light on the face—the surgeon knows that the point



of reversal is not between him and the patient. But when, with the same mirror, the apparent movement of light in the pupil is *against* the mirror—in the opposite direction to the movement of light on the face—he knows that the point of reversal is between him and the patient—that he is beyond the point of reversal and looking at the inverted image. On the other hand, when with the concave mirror the light in the pupil appears to move *with* the mirror—with the light on the face—the surgeon knows that this is the opposite of the real movement of light on the patient's retina, and that, therefore, he is watching an inverted image. But if with the concave mirror the light in the pupil appears to move *against* the mirror—against the light on the face—knowing this to be the direction of the real movement of light on

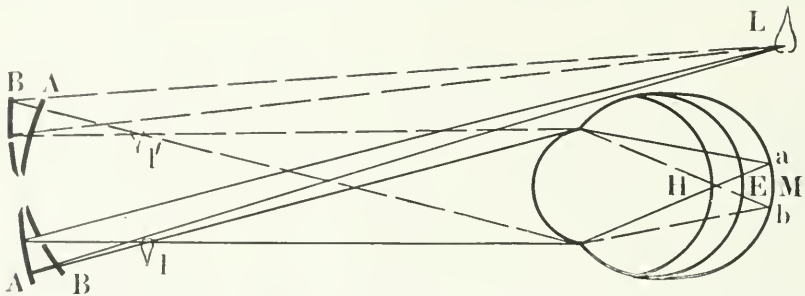


FIG. 155.—Course of rays in skiascopy with concave mirror: A A, one position of mirror giving immediate source of light at *l*, and illuminating retina toward *a*; B B, another position of mirror with immediate source of light at *l'*, and retina illuminated toward *b*.

the retina, he knows he is watching an erect image, the point of reversal being somewhere behind him.

**Rate of Movement, Form, and Brightness of the Light-area.**—Besides the direction of the movement of light and shadow, the brightness and form and rate of movement of the illuminated area in the pupil are of practical importance. At the point of reversal a single point of the retina appears to occupy the whole area of the pupil. As the point of reversal is departed from, more and more of the retina is seen in the pupil. Hence, near to the point of reversal a slight movement of the light-area on the retina will appear to carry the light entirely across the pupil—the light and shadow move in the pupil swiftly. But at a greater distance from the point of reversal they move slower.

The apparent form of the light-area in the pupil is also modified by the nearness of the surgeon to the point of reversal. The actual form of the light-area on the retina is commonly circular. This circle appears greatly magnified when the surgeon is near the point of reversal, and only a small part of its margin can be seen in the pupil at one time, the boundary between light and shade appearing almost a straight line. While far away from the point of reversal, especially if the surgeon be near the pupil, the whole area of retinal illumination may be seen in the pupil as a complete circle. More important still in determining the apparent form of the light-area are regular astigmatism, aberration, and irregular astigmatism, to be presently considered.

The brightness of the light-area in the pupil depends on the concentration of the light thrown into the eye and the extent to which the retina is magnified. The immediate source of light being commonly near the mirror, the light is most concentrated on the retina when the mirror is held near the point of reversal. But just at the point of reversal the magnification of the

retina makes the illumination appear feeble, so that the brightest area of light in the pupil is obtained about 1 or 2 D. from the point of reversal.

**Practical Application of Skiascopy.**—The room should be thoroughly darkened, and the source of light shaded with an opaque chimney having a circular opening opposite the brightest part of the flame.

For the plane mirror the source of light should be so arranged that it can be brought quite close to the mirror and moved with the mirror to or from the patient's eye, and the opening in the shade should be 5 or 10 mm. in diameter.

For the concave mirror the flame is to be back of the patient's head, generally as far from the mirror as possible; and if a shade is used, the opening should be 10 to 20 mm. in diameter.

When not otherwise stated, the following description refers to skiascopy with the plane mirror. It may be applied to the concave mirror by reversing the significance of the direction of movement of the light in the pupil:

1. *Hyperopia.*—Without a lens the light moves across the pupil with the light on the face. The convex lens, *L* (Fig. 153), strong enough to overcome the hyperopia and to give a point of reversal, *R*, is placed before the eye. The surgeon, then varying his distance from the patient's eye, tries the movement of light and shadow alternately from within *R*, where the movement is *with*, and from beyond *R*, where the movement is *against*, the light on the face. The position of the point of reversal is thus determined. Its distance from the patient's eye is then measured or estimated. This is the focal distance of the over-correcting effect of the lens *L*, which over-correcting effect, subtracted from the whole strength of the lens, leaves the strength required to correct the hyperopia.

Suppose a 5 D. convex lens placed before the eye gives movement with the light on the face at 20 in. (51 cm.), and against the light on the face at 30 in. (76 cm.), the point of reversal taken as midway is at about the focal distance of a 1.5 diopter lens; the over-correcting effect of the 5 D. lens equals  $5 - 1.5 = 3.5$  D.—the strength of the lens required to correct the hyperopia.

In making the final determination of the refraction, if the freedom of the eye from astigmatism and aberration allows the movement of light and shadow to be easily watched at a greater distance, a weaker lens, giving a point of reversal farther from the eye, may be used. But if there be much irregular astigmatism or aberration, the determination can be more correctly made with a point of reversal still closer to the eye.

2. *Myopia.*—From the myopic eye the rays emerge already convergent to meet in a point of reversal that can be determined without the use of any lens, except in myopia of very low degree. Commonly, however, it is too close to the eye for accuracy, and a concave lens partly correcting the myopia should be placed before the eye, and the remaining myopia measured and added to the strength of the concave lens for the total myopia.

For example, in a case of myopia of 10 D., a concave 9 D. lens being placed before the eye, the point of reversal is found at 1 m. This corresponds to myopia of 1 D., which, added to 9 D., the strength of the lens, gives 10 D., the total myopia. In the case of very low myopia, as only 0.25 D., a convex 1 D. lens is placed before the eye, and the point of reversal found in this case at 31 in. (78.5 cm.), indicating 1.25 D. of myopia. From this, by subtracting 1 D., the strength of the lens, we get 0.25 D., the myopia originally present.

3. *Emmetropia* is shown when the convex lens placed before the eye gives a point of reversal just at its focal distance.

4. *Regular Astigmatism.*—In regular astigmatism the rays coming from the retina emerge from the cornea with different degrees of divergence or convergence in different meridians. For the two principal meridians there are, therefore, always the two separate points of reversal, their distance apart indicating the amount of astigmatism.

When in such an eye a point of reversal is found, it is soon discovered that it is a point of reversal only for the movement in one direction. The surgeon's eye, placed at this point, sees the retina magnified enormously in the direction of the one meridian, and magnified much less in the other principal meridian. This makes the light-area in the pupil appear elongated in the direction of the first meridian, giving it a *band-like appearance*, shown in Fig. 156.




FIG. 156.—Band-like appearance in shadow test.

To make this band-like appearance most distinct, the immediate source of light should be at the point of reversal for the other meridian. With the plane mirror the surgeon must place his eye at the point of reversal nearest the eye, where he will get movement undistinguishable in one meridian, and *with* the light on the face in the other. The original source of light is then to be pushed away from the mirror, its reflection (the immediate source) retreating correspondingly behind the mirror until it reaches the point of reversal for the other principal meridian. The direction of the band-like appearance is to be carefully noted as the direction of the principal meridian of greatest refraction—the direction for the axis of a convex cylinder that would correct the astigmatism. The direction of the other principal meridian, the direction for the axis of a concave cylinder to correct the astigmatism, will be at right angles to this.

With the concave mirror the surgeon's eye should be placed at the point of reversal that is the farthest from the eye and the original source of light brought closely to the mirror, causing its conjugate image (the immediate source of light) to go farther from the mirror and closer to the patient's eye, until it reaches the nearer point of reversal, and the band-like appearance appears most distinct in the meridian of least refraction. In this position the band cannot be seen to move in the direction of its length, but at right angles it also moves *with* the light on the face.

Having determined the direction of the principal meridians of astigmatism, the hyperopia or myopia in each is to be measured separately, just as hyperopia or myopia would be measured in any other case, with the light as near the plane mirror as possible or as far away as convenient from the concave mirror. The difference of refraction between the two meridians is the amount of astigmatism. When it has been determined, a cylindrical lens correcting it should be placed with the proper spherical lens before the eye, and the test applied to ascertain if the correction is really complete.

*Aberration.*—In most eyes the refraction at the edge of the dilated pupil is more myopic or less hyperopic than at the center. In this form, called *positive aberration*, the point of reversal for the edge of the pupil is nearer the eye than the point of reversal for the center, and from the latter point movement of light *against* the light on the face is to be noticed in the edge of the pupil. This light in the edge is brighter than the light at the center of the pupil, and great care must be taken to avoid error on this account. When the center of the pupil is the more myopic it is called *negative aberration*. The circular distribution of aberration largely determines the shape of



light and shadow in the pupil, making it more circular when otherwise it would be of different shape, as in regular astigmatism.

When aberration is present the point of reversal for the margin of the pupil may be close to the surgeon's eye, while the point of reversal for the center is far from it. In this case the movement of the light in the center of the pupil will be slow, while in the margin it will be swift. The light-area then appears to swing around a fixed center, and assumes an angular shape, shown in Fig. 157. This is the appearance presented in conical cornea where the center of the pupil is more myopic than the margin.

**Irregular Astigmatism.**—The differences of refraction due to the lens-changes preceding cataract, or the irregularities of the cornea following phlyctenular keratitis, break up the light and shadow in the pupil into small irregular areas. The surgeon must find which of these areas is most likely to be of use for eye-work, and measure the refraction in it. To do this it may be necessary, on account of the smallness of the area, to come quite close to the patient's eye. Here a small source of light and a small sight-hole in the mirror are of great importance.



FIG. 157.—Angular appearance in high aberration.

**Subjective Methods of Testing Refraction.**—To determine what lens is required to bring perfectly to a focus the rays entering the eye we may resort to tests based upon a single point of light. Thomson's *ametrometer* consists of two small gas-flames, one fixed and the other movable along a graduated arm, which can be revolved about the first as a center. The distance of the two flames apart when their diffusion-areas appear to just touch each other gives the degree of ametropia in the meridian parallel to the graduated arm. Hotz uses two small holes in a disk placed in front of a window or lamp-flame. To the patient having astigmatism each of the points of light so obtained appears elongated, and by turning the disk so that these elongated images lie in the same line, an index enables the surgeon to read off the direction of the principal meridians of astigmatism.

The simple *optometer* consists essentially of a convex lens which is placed close to the eye, and a graduated arm extending from it on which moves a card bearing test-type. In emmetropia the type can be seen distinctly only as far as the focal distance of the lens. In hyperopia it is read to a greater distance, and in myopia only to a lesser distance, corresponding to the degree of the ametropia.

Either of the above subjective methods may be found of service where others are not available; but they are not commonly used, and by the subjective method of determining refraction is commonly meant the method with trial-lenses and test-letters.

The *trial case* contains a sufficient series of spherical and cylindrical lenses, with trial-frames in which they can be placed before the eye, prisms, solid, pin-hole, and slit disks, and colored glasses. By combining two or more lenses together a very few convex and concave lenses can be made to answer for any case of ametropia, but where many cases are to be tested convenience and economy of time demand a fairly complete set of lenses. This may include pairs of convex and concave lenses, with 0.12 D. intervals to 1.5 D., 0.25 D. intervals to 4 D., and 0.50 D. intervals to 8 D., for both sphericals and cylindricals. Then for the sphericals, 1 D. intervals to 20 D., with, perhaps, 25 D. and 30 D. added. The prisms may run by 1-centrad intervals to 10, with the 12, 15, 20, and 30 centrad prisms in addition.



To use the trial-lenses, test-letters suited to the distance adopted are to be hung in a strong light, either natural or artificial, the latter being preferable because it can be made more uniform. The test-card should always have one or two lines of letters smaller than those intended to be read at the distance adopted. Thus for 6 m. there should be a line of 5-m. letters. Some patients have visual acuteness greater than  $\frac{6}{6}$ .

**Use of the Trial Case.**—The *pin-hole disk* furnishes a ready means of distinguishing between imperfect vision due to ametropia and imperfect vision due to other causes. In the former case the placing the pin-hole opening before the eye lessens the diffusion-areas upon the retina and improves vision; if the imperfection of vision is not due to ametropia, the pin-hole disk rather makes it worse.

The *slit* is used in discovering astigmatism of moderate or high degree and the direction of its principal meridians. In astigmatism the diffusion-areas on the retina are wider in the direction of one principal meridian than in the direction of the other. The slit limits them at right angles to its length, but not in the direction of its length. When, therefore, it is placed before the eye, turned in one direction, it cuts down the diffusion-area in its larger dimension, giving the greatest improvement of vision. At right angles to this it limits the diffusion-area in the other direction, in which it is already most limited, and gives the least improvement of vision. These directions of the principal meridians of the astigmatism being found, the slit may be turned in the direction of one meridian and spherical lenses tried until one is found correcting the ametropia in this meridian, and giving the best vision obtainable through the slit. The same is done for the other meridian, and in this way the correcting lenses, both spherical and cylindrical, may be determined. This test has practical value as an approximate and confirmatory test.

In the *ordinary use of test-lenses* each eye is tested separately, the other being covered by a solid disk or ground glass. When accommodation is absent the aim is to find the lenses which give the best vision. Some idea of the ametropia is given by previous objective tests and the acuteness of vision without a lens. The concave or convex lens expected to correct it approximately is placed before the eye and the vision with it noted. Then weak additional convex or concave lenses are held in the hand in front of this, trying first the one, then the other. If the first lens has been convex, and the additional convex spherical further improves vision, a convex lens correspondingly stronger is substituted. The trial is then repeated, and this is continued until a lens is found which can neither be increased nor diminished in strength without lessening the acuteness of vision.

If the eye is free from astigmatism, this is the lens desired; but to test such freedom from astigmatism cylindrical lenses should be tried. The cylindrical lens is to be held in front of the spherical lens selected, and its axis turned in different directions, as vertical, horizontal, and oblique to the right and to the left. For this purpose the astigmatic lens, convex in one meridian and equally concave in the meridian perpendicular thereto, is preferable to either the convex or concave cylinder. Such astigmatic lenses should be included in the trial case.

Having ascertained that in some one direction the cylindrical lens improves vision, such a lens is to be placed in the trial-frame, either with the spherical lens already there or with one slightly weaker if the cylindrical lens is of the same kind, or a slightly stronger if the cylinder is of the opposite kind. Thus, if the original spherical lens was  $-2$  D., and  $+1$  D. is the

cylinder to be combined with it, the spherical should be changed to  $-1.5$  D. If it is preferred to use a  $-1$  D. cylinder, the spherical lens should be changed to  $+2.5$  D. After this the cylinder is to be slightly turned, first to one side and then to the other, the patient being required to indicate when the turning makes his vision worse. This is repeated until it is pretty certain just what direction of the cylinder-axis gives the best vision. Then weak convex and concave spherical lenses are to be tried in front of the combined spherical and cylindrical lenses, to see if either will still further improve the vision, and these are followed with the astigmatic lens and a new trial of the direction for the axis. This routine is to be repeated until any change in any factor of the combination impairs the acuteness of vision.

The combination thus arrived at is the correcting lens of the eye for the distance at which the test is made. If this distance be 4 or 6 m., 0.25 or 0.17 D. must be subtracted from the convex or added to the concave spherical lens to make it the perfect correction for truly parallel rays from more distant objects. The same process is repeated for the second eye.

*When the power of accommodation is present, the aim must be to find the strongest convex or the weakest concave spherical lens that gives the best vision.* Cylindrical lenses will be tried as above, preferably before attempting the final determination with the spherical lens. The determination of the spherical lens is best effected by testing both eyes at once and beginning with convex lenses that are too strong or concave lenses that are too weak to permit of the best vision. Then, if convex, before removing such glasses the next weaker lenses should be placed before the eyes. In this way whatever relaxation of accommodation has been secured under the first lenses is preserved. If vision is yet not perfect, a still weaker lens is substituted in the same way, and so on until the best vision of which both eyes are capable is obtained.

The eyes are then to be tested separately by covering each of them alternately. If it is found that only one eye has attained to its best vision, the lens before the other eye is to be still further weakened until it, too, has obtained its best vision. The lenses thus chosen will be found to correct the total hyperopia in the majority of even young persons.

In myopia the spherical lenses are to be made successively stronger, and when the best vision is obtained the eyes are to be tested separately by alternate covering.

#### MYDRIATICS.

The drugs atropin, duboisin, hyoscyamin, hyosein, daturin, and scopolamin, alkaloids obtained from members of the Solanaceae, and homatropin, a derivative of atropin, constitute the true mydriatics. Applied to the eye, they produce dilatation of the pupil and paralysis of the accommodation, which after a time, varying with the drug and the amount of it employed, entirely passes away. In some cases the dilatation of the pupil is of use in the determination of refraction, since it renders easier the use of the ophthalmoscope, skiascopy, and the test-lenses. But the chief value of these drugs in this connection lies in their action as cycloplegics. By paralyzing the ciliary muscle they eliminate the influence of accommodation.

In healthy eyes a single drop of one of the following solutions is usually sufficient to accomplish this: atropin, 1 : 100, duboisin, hyoscyamin, or scopolamin, 1 : 250. Of homatropin hydrobromate a single drop of even a saturated solution will not paralyze the accommodation. It must be used by repeated instillations of a 2 to 4 per cent. solution at short intervals. Any of the other drugs will prove effective in weaker solutions if the instillations

are repeated. In practice it is customary to prescribe either atropin, duboisin, or hyoseyamin in solutions of the strength named, to be instilled at the patient's home three times a day for one or more days. The repeated instillations are necessary to guard against their possibly imperfect character.

Homatropin should be instilled by the surgeon or a trained assistant, and the instillations repeated every five or ten minutes until from four to six have been made; and after its use the determination of the refraction should be completed within one or two hours, as it often begins to lose its control of the ciliary muscle soon after that time.

In the choice of the mydriatic homatropin has the advantage of greater brevity of action. The accommodation completely recovers from its effect, usually within forty-eight hours, while after atropin two or three weeks are required before it is quite recovered, and after the use of the other drugs named from one to two weeks must elapse. Scopolamin, 1 : 500, is an efficient mydriatic, used by making two instillations one hour apart. Accommodation will completely return in six days. Even weaker solutions may be efficacious.

In using these drugs certain alarming intoxicating effects must be borne in mind. While in the amount mentioned most people do not experience these, in exceptional cases a single drop of one of the solutions mentioned, except of homatropin, may cause severe symptoms of intoxication. These are—dryness and redness of the throat and skin, with delirium and incoordination of movement, especially inability to walk. The patient is not usually much disturbed, but his friends may be greatly alarmed, although from any such dose these symptoms are quite unattended by danger. On their appearance the use of the drug must be suspended, the patient kept quiet, given water freely, and, if decidedly delirious, small doses of an opiate.

Homatropin is much the least likely to produce such symptoms, and duboisin, hyoseyamin, and scopolamin (which may be but different names for the same drug) are the most likely to produce them. In the eyes of a few persons these mydriatics produce marked conjunctival irritation or inflammation, and the homatropin solutions mentioned always produce a temporary hyperemia of the conjunctival and pericorneal vessels during the period of absorption.

Cocain, a drug of an entirely different class, possessing little or no power to paralyze the ciliary muscle, may be useful to dilate the pupil in persons over fifty years of age whose pupils are small and whose power of accommodation is not sufficient to interfere with tests for refraction. A single instillation of a 2 per cent. solution is followed after thirty minutes or an hour by decided enlargement of the pupil, yet with very little inconvenience and no danger.

All drugs which cause dilatation of the pupil, except cocain, are dangerous in eyes presenting the essential changes of glaucoma, since they may produce a glaucomatous outbreak. But if such a revelation of the presence of glaucoma is promptly met by the proper treatment, it can hardly be regarded as unfortunate for the patient. No eye in which this accident can occur is likely long to escape glaucoma, and without the mydriatic the advent of this disease might be so insidious as to escape detection until irreparable damage had been done.

Whether mydriatics should be used in the great mass of refraction cases is a debated question. That with their use the determination of refraction can be more certainly exact cannot be doubted. The question is as to

whether the increased certainty and accuracy are worth the discomfort and loss of time from ordinary occupations that the mydriatic causes. In deciding this question the desires of the patient and the appreciation of exactness in his work on the part of the surgeon will be the determining factors.

*Table of the Different Mydriatics.*

| Name of drug and salt commonly used. | Relative power in solutions containing the same amount. | Strength of solution commonly used. | Time in which such solutions produce a noticeable effect. | Beginning of maximum effect. | Effect begins to decline. | Recovery complete. |
|--------------------------------------|---------------------------------------------------------|-------------------------------------|-----------------------------------------------------------|------------------------------|---------------------------|--------------------|
| Atropin sulphate . . . .             | 30                                                      | 1:120                               | 12 min.                                                   | 1 hour.                      | 4 days.                   | 15 days.           |
| Daturin sulphate . . . .             | 60                                                      | 1:200                               | 10 "                                                      | 40 min.                      | 3 "                       | 10 "               |
| Hyoscyamin sulphate . . .            | 75                                                      | 1:240                               | 10 "                                                      | 40 "                         | 2 "                       | 8 "                |
| Duboisin sulphate . . . .            | 75                                                      | 1:240                               | 10 "                                                      | 40 "                         | 2 "                       | 8 "                |
| Scopolamin hydrochlorate.            | 75                                                      | 1:1000                              | 15 "                                                      | 1 hour.                      | 12 hours.                 | 6 "                |
| Homatropin hydrobromate.             | 1                                                       | 1:40                                | 15 "                                                      | 1 "                          | 3 "                       | 2 "                |
| Cocain hydrochlorate . .             | { Not com-<br>parable. }                                | 1:125                               | 30 "                                                      | 1 "                          | 2 "                       | 12 hours.          |

With cocain the anesthetic effect passes off before dilatation of the pupil is fairly commenced. The new local anesthetic, eucain, is usually regarded as having no mydriatic effect, but Wagenmann states that, by a strong solution repeatedly applied, some dilatation of the pupil may be produced.

#### GENERAL PLAN OF EXAMINATION.

The acuteness of vision for each eye separately, and the near point of distinct vision, should be first ascertained. If vision be imperfect, the pin-hole disk may be tried to see if such imperfection is due to ametropia or to other causes. Then the eye should be examined with the ophthalmoscope by the direct method. This gives a rough approximation of the refraction, especially as regards hyperopia or myopia. After this skiascopy may be used or a mydriatic employed. Then the corneal astigmatism may be measured with the ophthalmometer.

When the mydriatic has produced its full effect, the refraction is to be carefully measured by skiascopy, and then to be tested by the trial-lenses, commencing with the glass fixed upon by the shadow-test. The value of the results obtained by the subjective method depends largely on the patient not being wearied by prolonged testing.

After the correcting lenses have been thus ascertained, the eye should be allowed to recover from the mydriatic and the trial with lenses repeated. Such a routine, carefully followed by one of fair skill, cannot fail to give accurate and reliable results.



NORMAL AND ABNORMAL REFRACTION :  
EMMETROPIA, AMETROPIA, HYPEROPIA, MYOPIA, ASTIG-  
MATISM, PRESBYOPIA.

BY EDWARD JACKSON, A. M., M. D.,

OF PHILADELPHIA.

DISTINCT vision, by which the existence and position of different objects are recognized, as contrasted with mere perception of light, depends on the assorting or focussing of the light that falls on the retina. Imperfect focussing of this light causes imperfect vision. To avoid this the accommodation may be strongly exerted, contraction of the pupil secured by a bright light, or the space between the lids narrowed. But efforts of this kind to improve vision, if frequently or constantly resorted to, are liable to exhaust the endurance of the nervous system or disturb the nutrition of the eyeball and its appendages.

Errors of refraction lead either to imperfect vision or to eye-strain. They may lead to both, but generally, in so far as the vision is imperfect, there has not been eye-strain, and in so far as there has been eye-strain the imperfection of vision has been partly overcome. If the defect be great, the part of it overcome may cause eye-strain, while beyond this some remains to render the vision still imperfect.

**Normal and Abnormal Refraction: Emmetropia and Ametropia.**—Refraction may be regarded as normal when it gives, under the requirements to which the eyes are subjected, distinct vision without injurious effort. It is, for practical purposes, abnormal when distinct vision is prevented by imperfect focussing of light on the retina or is obtained only by excessive effort—by eye-strain.

In *emmetropia* light from distant objects (parallel rays) is accurately focussed on the retina without accommodative effort. Any departure from this optical condition of the eye constitutes *ametropia*. Emmetropia is the ideal state of refraction. In it not only are rays from distant objects perfectly focussed without effort, but rays from near objects are focussed upon the retina with the minimum exertion of accommodation; not only are distant objects seen distinctly, but the full extent of the accommodation is available for the distinct seeing of near objects. It is true that the myopic eye may be able to see objects still nearer to the eye, but the gain of a very few inches or a fraction of an inch of distinct near vision is more than balanced by the loss of distinct vision for everything beyond a certain very limited distance; and the gain in lessened accommodation required for near objects is more than balanced by loss through the increased need for convergence. Careful examination of large numbers of eyes, particularly among school-children, shows that the actual experience of life fully supports the theoretical advantage of emmetropia.

The same observations show that exact emmetropia is comparatively rare.

The writer among 4000 eyes found the following proportions of ametropia of different kinds, and of emmetropia :

*Frequency of Ametropia.*

|                                          |      |          |      |           |
|------------------------------------------|------|----------|------|-----------|
| Compound hyperopic astigmatism . . . . . | 1610 | eyes, or | 40.2 | per cent. |
| Hyperopia . . . . .                      | 1225 | "        | 30.6 | "         |
| Compound myopic astigmatism . . . . .    | 361  | "        | 9.   | "         |
| Mixed astigmatism . . . . .              | 267  | "        | 6.7  | "         |
| Simple hyperopic astigmatism . . . . .   | 249  | "        | 6.2  | "         |
| Myopia . . . . .                         | 158  | "        | 5.   | "         |
| Simple myopic astigmatism . . . . .      | 79   | "        | 2.   | "         |
| Emmetropia . . . . .                     | 51   | "        | 1.3  | "         |

It may be asked, If emmetropia is the ideal state of refraction, why is it so rarely found? The answer is that the shape of the eye results from processes of growth resisting intraocular pressure, and cannot be a rigid, definite, mathematical form. The ideal form for any part of the body, and the ideal of proportion between different parts, are never found in life. The deviations of the eye are insignificant compared with the deviations of the other organs, but sufficient to cause errors of refraction of practical importance in a very large proportion of eyes. The study above referred to indicates that the largest number of eyes have low hyperopia; 62 per cent. show hyperopia of 1.5 D. or less, including hyperopic astigmatism. The eye has been evolved to meet the requirements of life among the lower animals and savages, for whom myopia, even of low degree, would be a very dangerous defect. Deviation of the eye in that direction caused the extinction of individuals and families. The requirements of modern civilized life, however, rapidly extend in the direction of near eye-work, so that hyperopia becomes a serious defect. Even the emmetropic eye may be unable to meet the requirements of close work; and as the power of accommodation diminishes with age, it loses the power of distinct vision at short distances, requiring optical assistance in all cases (*presbyopia*).

**Eye-strain.**—The *symptoms* arising from excessive efforts to prevent indistinctness of vision may be considered under this head. They are largely the same in different forms of ametropia, and may also arise from excessive eye-work, insufficient light, or other unfavorable conditions, even though the eyes be emmetropic. Eye-strain is caused by excessive use of the accommodation, from too long hours of close work, or by looking at small objects brought too near the eye; or because of deficient vision, or in making good the defect of hyperopic eyes; or by ordinary near work after the accommodation has diminished with age (*presbyopia*). It may also arise from excessive efforts to keep the eyes properly directed, as of convergence where objects have to be brought too close on account of uncorrected myopia, or from the effort of accurately co-ordinating muscular movements, as those of accommodation and convergence. It may come by exhaustion of the visual centers in the effort to appreciate blurred and imperfect retinal images, or it may be due to the use of eyes otherwise normal at a time when the general nutrition is impaired by wasting disease or exhaustion by effort in other directions.

Eye-strain may be manifested by failure of near vision after use of the eyes (*relaxed accommodation*) or by temporary blurring of distant vision (*spasm of accommodation*); by changes in the retina—swelling and opacity, with dilatation of the retinal vessels and exaggerated reflexes; by changes in the optic nerve—redness, haziness, or opacity or swelling of the nerve-head; by changes in the choroid, including increased redness, or alteration of color by edema or atrophy; and, secondary to the changes in the choroid, by opaci-

ties in the vitreous and the crystalline lens, and softening of the sclera with local bulging (*posterior staphyloma*).

The progressive changes in refraction, to be discussed under Myopia, are also symptoms of eye-strain. Acute or chronic conjunctivitis may arise from the same cause. This may amount to a slight exaggeration of the irritation felt when the eyes are tired, or it may develop into a chronic catarrhal conjunctivitis, practically incurable even by removal of the original cause. When the conjunctivitis is severe, corneal disease may be associated with it, and if chronic it is apt to be attended with changes in the lids, marginal blepharitis, styes, etc. Eczema of the lids and neighboring parts has also been ascribed to eye-strain and relieved by wearing glasses.

The symptoms manifested outside of the eye and its appendages are—

*Headache*.—This is often spoken of as reflex, but is better regarded as due to nerve-exhaustion. It is commonly frontal, in some cases extending to the occiput or throughout the whole head. Sometimes it is strictly limited to one side—*hemierania*. It may be directly associated with the use of the eyes, or be apparently constant, or may occur at certain times, apparently not determined by any particular eye-work, and yet in the latter case may be as completely cured by the careful relief of eye-strain as when more evidently connected with eye-work. The headache of eye-strain is not *sui generis*. It has the same characters as headache arising from entirely different causes. In many instances it is partly due to eye-strain and partly to the other causes. If the other causes can be discovered and removed, it may be cured without the wearing of glasses or any reduction in eye-work. More frequently it is cured by the correction of ametropia or faulty habits of using the eyes. Sometimes, when removal of one factor has given temporary relief, but the headache returns, the discovery and removal of the other factor may be necessary to make the relief permanent.

Neuralgic pains in other portions of the body or attacks of migraine may arise from eye-strain. Anorexia, nausea, vomiting, palpitation of the heart, and similar disturbances may be due to eye-strain. Nervousness, which the patient speaks of as an intolerable desire to cry out or do some violent act, inability to keep quiet after prolonged eye-work, peevishness and irritability of temper, are among its manifestations. For the rarer forms of disturbance the therapeutic test by relief from the strain will be necessary to establish the diagnosis. Eye-strain may cause certain motor disturbances, as twitching of the lids, tonic blepharospasm, and in rare cases choreiform movements or epileptiform seizures, or it may be the most substantial cause of hysterical manifestations. With these, as with headache, eye-strain is usually but one of two or more factors.

**Hyperopia.**—*Hyperopia, Hypermetropia, or Far-sightedness, is the error*

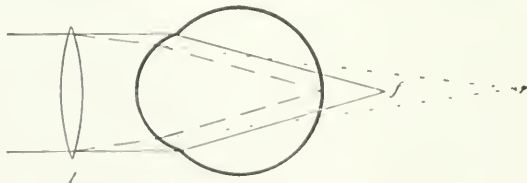


Fig. 158.—The course of rays in a hyperopic eye.

*of refraction which arises when the retina is situated in front of the principal focus of the dioptric surfaces.*

Fig. 158 represents a hyperopic eye able to focus parallel rays at  $f$  behind

the retina and  $l$  the lens which, turning the rays toward  $r$ , the virtual "far point" of the eye, causes them to be focussed on the retina and corrects the hyperopia.

The hyperopic eye is adjusted for convergent rays, and these are not encountered in nature. Without accommodation it sees indistinctly at all distances. By the exertion of accommodation it sees clearly, but only by the exertion of accommodation exceeding (by the amount of its hyperopia) that required of the emmetropic eye; and, having to use some accommodation constantly, it is deprived of the periods of rest which come to the emmetropic eye when fixed on distant objects. The greater amount of accommodation required of it causes the hyperopic eye to suffer earlier from the diminution of accommodation by age, and afterward the further loss of accommodation deprives it of distinct distant vision. We have from hyperopia liability to eye-strain and indistinctness of vision, either of which may become an indication for correction of the defect by convex lenses.

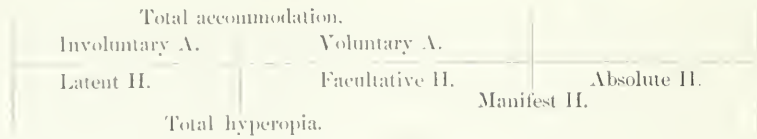
**Causes, Varieties, and Course.**—Hyperopia is due in the majority of cases to antero-posterior shortening of the eyeball, *axial hyperopia*. This is caused not so often by a flattening of the globe as by a diminution in all its diameters. The other causes for it are—flattening of the curvature of the cornea or crystalline lens, *hyperopia of curvature*, and removal of the crystalline lens (accidental or operative), or its congenital absence or dislocation—*aphakial hyperopia*. It is possible to conceive also of hyperopia due to a low index of refraction of the crystalline lens—*index-hyperopia*.

At birth nearly all eyes are hyperopic. It is possible that during the first years of life there is some general tendency for hyperopia to diminish, although this is not proven (see p. 178). On the other hand, from early adult life to old age there is a general tendency for hyperopia to slowly increase, due to the gradual increase in size of the crystalline lens. As Prieſtley Smith has shown, the lens, like other structures of epithelial origin, continues to increase so long as it continues healthy, increasing one-third in bulk between twenty-five and sixty-five years of age. Increase in the size of the lens, supposing it to keep the same shape, causes an equal increase in its focal distance and a corresponding increase of hyperopia. This is independent of the apparent increase due to the failure of accommodation, and continues after all power of accommodation has been lost.

The varieties of hyperopia recognized in practical work are based on the relations of hyperopia to the accommodation. They can be best illustrated by an example: Suppose a case of hyperopia of 10 D. in which the total accommodation is only 8 D. When the full power of accommodation is exerted, there remains 2 D. of uncorrected hyperopia. This, a part of the hyperopia which no effort of the accommodation can correct, is called the *absolute hyperopia*. It often happens where there is considerable hyperopia and good accommodation that the accommodation is not fully relaxed at any time when the eyes are used, even for distant vision. If this part of the accommodation amounts to 2 D., then so much hyperopia is always corrected when the eyes are in use; it is called *latent hyperopia*. Besides the 2 D. of accommodation that cannot be relaxed, there remains 6 D. of accommodation which can be relaxed or exerted, and which, therefore, can be used to correct an equal amount of hyperopia, but which hyperopia can be left uncorrected at will. This part of the hyperopia which can be corrected or not by the accommodation is called *facultative hyperopia*. The absolute hyperopia and the facultative, added together, give the *manifest hyperopia*. The manifest hyperopia, with the latent hyperopia, together constitute the *total hyperopia*.



The relations of these different varieties or parts of the hyperopia may be better understood by the following diagram :



The subject may be still further illustrated by considering what happens when successive convex lenses are placed before an eye with a hyperopia of 10 D., and a total accommodation of 8 D. Without any lens the vision of such an eye is imperfect. A weak convex lens improves it, and the improvement continues as the strength of the lens is increased up to 2 D., which corrects the absolute hyperopia, and, with all the power of accommodation added to it, focusses parallel rays on the retina, giving good distant vision. As the convex lens is made stronger the vision is not further improved, but the best vision is obtained with less exertion of accommodation. Thus, with a 4 D. lens it is necessary to exert only 6 D. of accommodation, and with a 7 D. lens only 3 D. of accommodation. This continues until all the manifest hyperopia is corrected by an 8 D. lens, the vision remaining clear with only 2 D. of accommodation. If, however, a still stronger lens is placed before the eye, the accommodation being able to relax no farther, the 2 D. of accommodation, plus the lens, gives an over-correction, blurring distant vision. The portion of the accommodation which cannot be relaxed has been indicated in the above diagram as *involuntary*, and the part that can be relaxed or exerted at will is *voluntary* accommodation. By the use of a mydriatic the total accommodation, both voluntary and involuntary, is relaxed and the total hyperopia revealed.

Absolute hyperopia only occurs after the power of accommodation for objects at a distance from the eye has fallen below the amount of hyperopia. In early life it is only seen in hyperopia of the highest degree. After middle age, the power of accommodation being lost, it appears in all hyperopic eyes, and when the accommodation is entirely gone all hyperopia is absolute. Latent hyperopia may not be present. Many persons with strong accommodation are able to relax it entirely when looking at distant objects through convex lenses. In other eyes it is constantly present, and in still others is present only part of the time. The inability to relax the accommodation is often spoken of as *spasm of accommodation*. Such spasm is most likely to occur when the eyes are irritated or fatigued. The facultative hyperopia, lying between the latent and the absolute, varies with these, decreasing as either of them increases, and on the whole tending to diminish with age along with the diminishing accommodation. In measuring refraction without a mydriatic the important point is to get as much of the hyperopia manifest as possible, and to do this the two eyes must be tested together, as recommended on page 209.

With reference to these different varieties it is essential always to bear in mind that their relations to each other are not fixed—that there is no constant ratio between the manifest and the latent hyperopia at any particular age or for the individual. The proportions may vary from day to day, or even from minute to minute.

**Symptoms.**—Since hyperopia may be corrected by accommodation, only the highest degrees give rise to symptoms in early childhood. The earliest symptom is *convergent squint*, arising with the effort of accommodation. This

effort being great, the nervous impulse overflows, causing additional muscular contractions in muscles closely associated with that of accommodation, and especially excessive contraction of the internal recti muscles. Convergent squint of this kind is apt to begin before six years of age, and is most commonly associated with hyperopia of high, but not the highest, degree. Squint occurs where the hyperopia can be corrected by great exertion of the accommodation. When this is too difficult imperfect vision is accepted. Such imperfect vision may be noticed by a careful observer in early childhood, but commonly is not detected until the child begins to read. It is then found that to increase the size of the imperfect retinal images the book is held very close to the eyes, as in myopia. This practice in early childhood quite as frequently indicates high hyperopia.

Under the influence of school-work lower grades of the defect begin to cause eye-strain. This often shows itself in local congestion and inflammation of the conjunctiva and lids, conjunctivitis, styes, photophobia, and frequent winking on account of the conjunctival irritation. In later childhood begins the liability to headache; young children rarely complain of ocular headache. During school-life even the lower grades of hyperopia are liable to cause eye-strain, but afterward, most eyes being used to better advantage and not being so severely taxed, the low degrees of defect are less likely to cause trouble, although headaches established during childhood may be continued, and periods of poor health may cause the development of eye-strain.

As the time approaches when even emmetropic eyes suffer from presbyopia, hyperopic eyes manifest the same symptoms earlier, in proportion to the degree of hyperopia. These symptoms are—failure of the vision for near-work, particularly in the latter part of the day or when tired or working by poor light: print has to be held farther from the eyes in order to be read, and conjunctival irritation and inflammation again occur, often in repeated acute attacks that are ascribed to "cold." Still later, as the power of accommodation falls so low that it can no longer correct the hyperopia, indistinctness of vision is developed.

**Treatment.**—While any departure of the refraction of the eye from the emmetropic standard constitutes an error or an anomaly of refraction, it is only when under the conditions of work imposed upon the eye such an error or anomaly causes interference with vision or strain, that the refraction is to be considered abnormal. Treatment, therefore, is not indicated by the mere existence of hyperopia, but by the fact that the hyperopia has caused symptoms, or is likely to cause them, under conditions of work to which the eyes are about to be subjected. Many hyperopic eyes, therefore, do not require the aid of correcting lenses, but when symptoms arise that may with probability be ascribed in part to this error of refraction the correcting lenses should be used.

How they are to be determined has been sufficiently indicated in the preceding section (page 198). The general rule should be to give the full correction—that is, the lens which makes the hyperopic eye similar to the emmetropic eye, enabling it to focus parallel rays on the retina without any exertion of accommodation, and to focus divergent rays with the least effort of accommodation. To this general rule certain objections are offered which must be carefully considered, and certain exceptions which must be recognized.

It is urged that if some eyes continue normal with uncorrected hyperopia, others may continue normal with their hyperopia but partly corrected, and that the rule should be to give the weakest glass that will allow the use of the eyes with comfort. But it is impossible, except by trial, to know that

any incomplete correction will be sufficient in the particular case. The full correction promises the greatest degree or the greatest probability of relief after the eye has once become accustomed to it. The inconvenience of wearing glasses is the same with a partial as with a full correction; therefore, if the patient must wear glasses at all, he ought to have from them the greatest benefit or the greatest certainty of benefit obtainable.

The second objection to giving the full correcting lens is that if a portion of the hyperopia is latent—and it is often incorrectly assumed that this is so in nearly all cases—the wearing of the full correction renders distant vision indistinct. If the latent part of the hyperopia were a fixed amount, this objection would have more practical weight. As it is, one cannot correct the manifest hyperopia of to-day and be sure that the same lens will not over-correct it to-morrow. As long as latent hyperopia is allowed it will vary, and, at certain times, lead to blurring of distant vision unless a very wide margin is left for such variation. On the other hand, it is only necessary to wear constantly the full correcting lenses to render the total hyperopia manifest. Sometimes this is accomplished in a few minutes or a few days; in other cases it may take weeks, but if the glasses are a true correction and are steadily worn, it can always be brought about. This manifestation of total hyperopia is doubted by some ophthalmologists, partly because of the failure of patients to wear their glasses constantly or always to look through them when worn, but chiefly on account of the inaccuracy of supposing that the correcting lens for a limited distance, 15 or 20 feet, is a true correction for greater distances. Such a lens causes a very perceptible blurring at greater distances, very annoying to persons accustomed to distinct vision, and never to be overcome by any amount of persistence in wearing glasses. The person who under a mydriatic sees perfectly at 4 m. with a 1 D. convex lens never will see perfectly at a longer distance with that lens—never will accept such a lens with satisfaction, not because of any “spasm of accommodation,” but because it is not his correcting lens for parallel rays; it is 0.25 D. too strong. (See also page 209.)

A third objection is that even if finally accepted the full correction is harder to become accustomed to than a partial correction. This seems plausible, but experience indicates that it is not the case unless the partial correction is so incomplete as to give a very diminished assistance to the eye. It appears to be easier for an eye to learn to relax its accommodation entirely than to learn the new partial relaxation that a partial correction of the hyperopia renders necessary. Some surgeons claim it is best to arrive at full correction by successively increasing partial corrections. The full correction may at first cause the greater trouble, but this is at its maximum during the first two or three days, and after that it rapidly diminishes; it is certainly less in the aggregate than is entailed by a series of increasingly stronger glasses, which, moreover, cause greater expense.

The wearing of correcting lenses should be constant. This should be the rule in hyperopia, although not so essential as in myopia and astigmatism. Some indications as to the constancy with which glasses should be worn may be drawn from the symptoms. Headache, particularly if continuous or occurring without apparent connection with any particular use of the eyes, is very much more likely to be relieved when the lenses are worn continuously. The same is true of chronic conjunctivitis and marginal blepharitis and of inflammatory changes within the eye. Where there is headache or irritation directly following special use of the eyes, as in reading or sewing, which quickly passes away when such eye-work is suspended, it is likely that

relief will be afforded by using the correcting lenses only during the periods of such work.

It is often necessary to have the glasses worn continually at first, until the headache or chronic inflammation has been entirely cured and the eyes have learned the habit of relaxing accommodative effort when not working. After this it may be quite enough to use the glasses only when the accommodation will be especially taxed. Again, many children have trouble from hyperopia, requiring the use of correcting lenses during school-life, who, when they leave school, can lay aside glasses and continue free from any symptoms of eye-strain.

Exceptions to the prescribing of a full correction are made—first, in young persons with good accommodation and high degrees of hyperopia and with comparatively trifling symptoms, occurring only when the eyes are especially taxed; second, in cases in which it is impossible to persuade the patient to submit to some present inconvenience in the hope of future benefit. Under these circumstances the only thing to do is to give a very incomplete correction at first and increase the strength of the lenses slightly at short intervals. Patients who take this attitude are generally in a position to bear the increased expense, and if it is explained that the first glasses are only for temporary use and are to be changed after short intervals, perhaps changed several times at such intervals, the partial correction may be resorted to. Deficiency of convergence or marked *exophoria* may also be considered as an indication for not completely correcting hyperopia.

In cases of convergent squint the constant wearing of the full correction is always to be tried. Apart from the wearing of correcting lenses, there is no treatment for hyperopia; but the symptoms that arise from it may be relieved by diminished use of the eyes, especially for near work, or by improvement of general health, and by the influences and remedies that bring it about.

**Myopia.**—*Myopia, Brachymetropia, Short-sight, or Near-sightedness, is the error of refraction existing when the retina is situated back of the principal focus of the dioptric surfaces, and rays of light to be focussed upon it must enter the eye divergent from some comparatively near point.*

Fig. 159 represents a myopic eye focussing parallel rays at  $f$  in the vitreous,

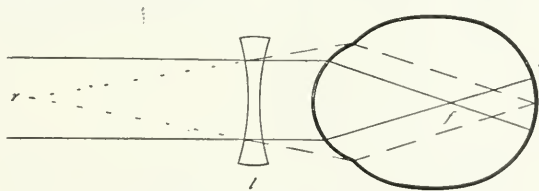


FIG. 159.—The course of rays in a myopic eye.

and requiring the lens  $l$ , which will cause them to diverge from  $r$ , the far point of the eye, in order that they shall be focussed on the retina.

**Causes, Tendency, and Varieties.**—Myopia may occur as the result of a simple congenital tendency to the formation of too long an eyeball or too great curvature of its dioptric surfaces, but the great mass of myopic eyes must be regarded as pathological. They exhibit distinct, and often very grave, lesions of the ocular tissues, to which the myopia may be secondary, but which it tends to aggravate.

The sclera is distended by a normal intraocular pressure of 25 or 30 mm. of mercury. This pressure preserves the form of the eyeball and the proper



relation of the dioptric surfaces to each other and to the retina. The normal sclera resists this pressure without yielding. Acute disease, diathetic impairment of general nutrition, a local inflammatory process starting with congestion of the choroid from eye-strain, or a congenital nutritive deficiency lowers the resisting power of the tissue, leaving it unable to withstand the intraocular pressure. Distention then occurs, commonly near the posterior pole of the eye, causing elongation of the antero-posterior axis of the eyeball.

When such distention is started, anything tending to increase intraocular tension or to diminish the resisting power of the sclera favors it. Different writers attach different degrees of importance to the various possible factors. Some believe a diathetic vice of nutrition essential to the production of myopia; some regard external pressure, dependent largely upon the form of the orbits and the width between them, as most important; some consider inflammatory changes within the eye as the chief cause of distention; some ascribe an important influence to accommodation, and others to excessive convergence. The writer recognizes the possible influence of all these factors, but believes excessive convergence is by far of the greatest practical importance.

It is universally recognized that prolonged near work favors the occurrence and increase of myopia. Such near work causes physiological hyperemia, often exaggerated by poor light or excessive minuteness of the objects looked at; faulty position of the head, leading to venous congestion of the eyes; confinement indoors to a sedentary occupation, which impairs nutrition; strain of accommodation; and excessive convergence which, sooner or later, increasing myopia renders necessary.

When the eye has become myopic its elongation makes convergence abnormally difficult, and the continued use of the eye for near work, because it cannot be used for distinct distant vision, increases the amount of convergence required of it. With weakened sclera, with increased pressure of the extraocular muscles from increased convergence-effort, and the pressure abnormally continuous, the tendency is for distention to increase. Myopia tends to be *progressive*. Probably all cases of myopia are at the start progressive. Some myopias cease to increase when the requirements of excessive near work made temporarily or during school-life are relaxed. Others become stationary from increasing rigidity and resisting power of the sclera which seem to come normally with increasing age. Still other cases continue progressive until convergence becomes too difficult to be sustained, when the more defective eye is permitted to deviate, and *divergent squint*, either intermittent or constant, is established. After this, the muscular pressure of convergence ceasing, the myopia ceases to increase. In a few cases, however, the sclera is so thinned, its resisting power so low, that distention continues until the intraocular changes produce blindness. To these the term *malignant myopia* is properly applied.

Myopia reaches much higher degrees than hyperopia, and the high myopias constitute a larger proportion of the cases; myopia of over 20 D. is as common as hyperopia of 10 D.

In speaking of degrees of myopia we may designate as *low myopia* that of less than 2.5 D., where some accommodation is habitually employed for near work. *Moderate myopia* is from 2.5 D. to 5 D., where near work can be done without accommodation. *High myopia* ranges from 5 to 10 D., in which work is best done at the far point of distinct vision. *Very high myopia* is above 10 D., and is usually accompanied by great alteration in the shape of the eyeball and changes in its coats.

**Symptoms and Complications.**—Myopia renders indistinct all objects situated beyond the far point of the eye. Such indistinctness is not always

noticed if it begins in early childhood or comes on very gradually, although generally it is detected by the patient or his care-takers, especially by inability to see letters on the blackboard at the ordinary distance. The indistinctness is removed by bringing the object closer to the eye, by placing before the eye a solid disk or card with a pinhole opening, or by looking through a concave lens. The changes within the eyeball often prevent full vision even with correcting lenses. The small moving specks or shadows due to points of haze or unequal refraction in the vitreous humor, noted in all eyes under certain optical conditions, are especially noticeable in myopic eyes. Such eyes are also especially liable to vitreous opacities, which give rise to more extensive clouds and shadows upon the retina.

Objectively, the myopic eyeball may appear noticeably enlarged and elongated, especially when turned strongly toward the nose; and the lids over it prominent or widely separated. The pupil is often rather large, and apparently sluggish, because less often contracted in the act of accommodation or convergence. The myope has a vacant or even stupid look, due to inability to see and respond to expression on the faces of others, and shows a distinct inclination toward reading and other pursuits which do not require clear distant vision.

The ophthalmoscope commonly reveals intraocular changes closely associated with the causation and increase of the myopia. The most characteristic

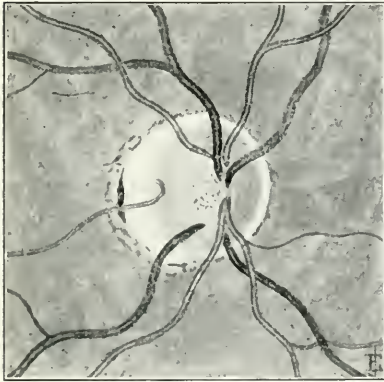


FIG. 160.—The myopic crescent. Figure illustrates also the lamina cribrosa and a cilio-retinal vessel.

of these are alterations in the choroid, as congestion and edema, causing reddening, blurring of details, and lighter patches ("woolly," "fluffy," or "patchy" choroid), and changes in which the pigment in parts of the fundus is reduced, while it may be increased in others ("disturbed" or "moth-eaten" choroid or choroidal atrophy, "slight," "partial," or "complete"). These changes are most frequent at the outer side of the optic disk, usually taking a crescentic form—the *myopic crescent* represented in Fig. 160. An eye may present two or three well-marked successive crescents, the one next the disk characterized by nearly or complete choroidal atrophy, the next showing partial atrophy, and the outer one mere congestion or disturbance of the choroid.

The continued succession of such areas, extending outward and passing on to complete atrophy, gives rise to a triangular area of atrophy extending to the temporal side of the disk, the so-called *comus*. The disturbed area may extend around the disk, forming a ring of atrophy usually broadest to the temporal side (see also pp. 192, 193). Such an area is often the seat of softening of the sclera, with consequent distention and thinning—*posterior staphyloma*. When this occurs at the temporal side of the disk the optic-nerve entrance is tilted, so that it is seen more obliquely. The disk appears a narrow oval. The vessels, drawn upon by the distention, pass more directly outward; the temporal side of the opening in the sclera through which the nerve enters is made prominent as a white crescent, also a "*myopic crescent*." The whole appearance is well characterized as a "*dragged disk*." If these changes occur at the lower, nasal, or upper side, the disk is found "*dragged*" in that direction. In the later

stages of high myopia similar lesions of the choroid are to be found in other parts of the fundus, especially about the macula, where a small lesion may cause great impairment of vision. In the earliest stages, and later if under the influence of eye-strain the myopia is increasing, general hyperemia and disturbance of the choroid may be noticed. Late in the course of high myopia *vitreous opacities, cataract*, especially nuclear and posterior polar, and *detachment of the retina* are liable to occur.

**Course.**—The best statistics of eyes examined at birth show that practically none are then myopic. But high myopia is sometimes encountered in early childhood, and probably sometimes does exist from birth. In the great mass of cases it certainly develops later. In a very few it seems to occur through a healthy development of the eyeball, to go on without choroidal changes or other evidences of disease up to adult life, and then to become stationary. In the great mass of cases *axial myopia* begins in a period of marked ocular congestion accompanying near work; then at times it becomes stationary; at other times, those of especial strain, it rapidly increases. When the myopia is arrested during early life it continues for some years stationary; later, by the slow growth of the lens, referred to under Hyperopia, it may be lessened or finally disappear entirely. In a few cases myopia begins during adult life or old age in connection with degenerative changes in the choroid and sclera, and may be a symptom of *diabetes*. *Curvature myopia* may begin at any time of life after disease causing corneal distention, *conical cornea*, or after injury causing partial dislocation of the lens. *Index-myopia* comes in old age as a precursor of cataract, the so-called *second sight*.

**Treatment.**—The indistinctness of vision is remedied by concave lenses. Permanent avoidance of near work will usually check the progress of myopia, but it is generally necessary to check its progress while near work is continued, and fortunately this also is possible for the great mass of cases by the use of correcting lenses. Two factors in near work that might tend to increase myopia are accommodation and convergence; but accommodation is far more tasked in hyperopia, and hyperopic eyes show no such tendency as the myopic eyes to distention of the eyeball. On the other hand, hyperopia is an obstacle to straining convergence, while myopia favors or compels it. The tendency of myopia to increase does not disappear when by its progress accommodation is reduced to a minimum or becomes unnecessary; but it does often cease when, binocular vision being given up, convergence is no longer required. If excessive convergence causes myopia and keeps it progressive, the first indication for its treatment is its optical correction, that the patient may have distinct vision to induce him to turn his attention toward distant objects, and to free him from the necessity of excessive convergence.

The correcting glasses for myopia should be worn constantly. Wearing them only for distant vision greatly lessens their usefulness. It is most important for a young person to use the correcting lenses constantly, so that in the requirements made on accommodation he shall have a constant check to excessive convergence. The fear that accommodation may prove injurious has frequently led to the use of a partial correction only for near work. This rarely proves permanently satisfactory. Convergence to a near working point without some accommodation is impossible; and this accommodation makes it necessary to bring the object still closer and further tax the convergence.

The fear that normal accommodation is bad for a myopic eye has led to the prescription of lenses strong enough to greatly improve distant vision, yet weaker than the full correction. Such lenses may be very dangerous to the myopic eye. Looking obliquely through them increases their effect and renders dis-



tant vision more distinct. The patient discovers this and avails himself of it. But looking obliquely through a lens gives, besides the increased power of the spherical, the effect of a cylindrical element and aberration, which vary with the direction and amount of obliquity, and which subject the eye to a strain similar to that caused by uncorrected astigmatism—a strain all the harder upon the eye because it is inconstant. Glasses which may be made thus to approximate the full correction for myopia are the most dangerous that can be worn. Yet because their use has often resulted disastrously many surgeons hesitate about giving the stronger lenses of a full correction, although these would be really free from such a danger. If for any reason something less than the full correction is given, it should be carefully considered whether its use is liable to be thus perverted and cause injury.

The general rule is, *in myopia give correcting lenses for constant use.* To this there are certain exceptions. With presbyopia it becomes necessary to give weaker lenses for near work. Again, when binocular vision has been given up, strain of convergence, the chief indication for the use of correcting lenses, is removed, and a full correction may induce a renewed effort of convergence to restore binocular vision. On this account it will generally be better not to give a correcting lens for the worse eye. Persons who have reached middle age or later life without the use of lenses often find it difficult or impossible to become accustomed to them. Improved vision will often not compensate for the discomfort and inconvenience given, so that these cases must be made exceptions. With very high myopia a lens slightly weaker than the full correction gives an image more like that to which the patient has been accustomed, and which is, therefore, preferred. When this is the case, there is no temptation to get an increased effect by looking obliquely through the lens. Some persons object to the diminished retinal images caused by strong concave lenses, and prefer very much weaker lenses. If one weak enough to entail no strain when looking through it obliquely answers the purpose without any risk of excessive convergence, it may be wiser to give it. Occasionally, too, the full correction may be given for distant vision, and something deducted (1 or 2 D.) from the glass for near work, until the habit of accommodating normally for near objects has been formed. Patients should be warned of the dangers of looking obliquely through concave glasses.

Besides using correcting lenses, the myope must learn to keep his near work as far from his eyes as possible. The lenses are chiefly useful by enabling him to have a greater working distance, and no benefit as regards the progress of the myopia or the health of the eye can be expected unless the opportunity to diminish the strain of convergence is utilized. As an aid to a greater working distance, good light and the avoidance of reading very fine print or prolonged looking at other minute objects must be attended to. Care must be taken to avoid protracted near work. It should be interrupted by frequent intervals, during which the convergence may be allowed to relax and the eyes to fix on some distant object. The position of the head is also important, particularly in young persons. Reading while lying down or in a bent posture, causing pressure on the veins of the neck, favors ocular congestion, and should especially be avoided. Use of the eyes during periods of impaired nutrition, as from acute disease, during great physical exhaustion, etc., may also be dangerous. Outdoor life, besides demanding distant rather than near vision, acts by improving general nutrition. When choroidal congestion is marked, the influence of complete rest of the eyes for some days under the influence of a mydriatic may promptly check a process that tends



to soften and rapidly distend the sclera. When increase of myopia does occur the lenses should be promptly changed accordingly.

The *operative treatment of myopia* by removal of the crystalline lens by dissection, followed by extraction if the patient's age makes it necessary, is claimed not only to improve vision by removal of high myopia, making comparatively weak glasses necessary, but also to exert an influence in checking the progress of the myopia, and actually to cause a diminution in the antero-posterior axis of the eyeball. In the judgment of the writer it is not proper to resort to it in any case where the progress of the myopia can be arrested by the wearing of correcting lenses and ordinary hygienic precautions. But where glasses cannot be comfortably worn or with them the myopia continues distinctly progressive, it is proper to extract the crystalline lens. This operation may also be resorted to in cases of high myopia in one eye and in myopia with commencing lens opacity. In such eyes cataract often remains incomplete for many years, and grows no easier of extraction—it may even become more difficult to remove because of the larger nucleus when ripe than when the opacity begins to interfere with vision. The reduction in myopia by extraction of the lens varies in different eyes, usually between 15 and 20 D. Generally, it will not be exactly corrected by the removal of the lens; glasses for both near and distant vision will be required, accommodation being lost with the removal of the lens.

**Astigmatism.**—Its Nature and the Vision of Astigmatic Eyes.—*Astigmatism is always an ametropia of curvature. It is a defect in which rays from a single point do not after refraction tend to meet at a single point.*

In *irregular astigmatism* the curvature is irregular and the refraction differs in the different parts of the pupil.

In *regular astigmatism* the refraction is the same in different parts of the pupil, but differs at the same point in different directions. This depends upon inequality of curvature of the dioptric surfaces in the different directions.

A familiar illustration of the kind of surface causing it is found in the curve of the edge of a watch. The curve in the plane parallel to the face of the watch is weaker than the curve in the plane perpendicular to the face. The inequality of curvature causes the rays to be refracted more strongly in the direction of the stronger curve, and in that plane to come to a focus before they have reached a focus in the plane of the weaker curve. Instead of being focussed to a single point, they are focussed successively to two lines at right angles to each other and separated by a certain interval.

In most cases of regular astigmatism the fault depends chiefly upon inequality of curvature in the cornea, although there is usually also some inequality in curvature in the crystalline lens. It is common to speak as though the astigmatism were due entirely to the corneal curvature, but it should be remembered that this is only exceptionally the case.

In considering the refraction of the astigmatic eye it is only necessary to follow the course of the rays as regards two meridians, called the *principal meridians*—viz. the meridian of greatest curvature or greatest refraction, and the meridian of least curvature or least refraction. In regular astigmatism these are always perpendicular to each other. In some eyes they are not perpendicular, but in such eyes the astigmatism is not regular, or if a part of it be regular, there is present also some irregular astigmatism, which cannot be corrected by any lens. (See page 206.) When the refraction has been corrected in the principal meridians all of the regular astigmatism, all the astigmatism that is corrigible, is corrected for all meridians.

The focussing of light by the astigmatic eye may be illustrated by Fig.

161, in which the circle represents the cornea as seen from the front;  $a a$  represents the principal meridian of greatest refraction, and  $b b$  the principal meridian of least refraction. By the vertical curvature all rays entering the upper half of the cornea are brought down to the level of the central ray when they reach the point  $f$ , and all rays entering the lower half of the cornea are brought up to the central ray at the same point. At  $f$  all the rays have

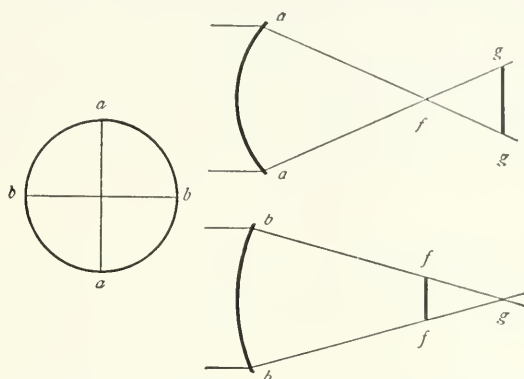


FIG. 161.—Illustrating the refraction of the rays in the principal meridians.

been brought to the level of the central ray, but they have not been focussed to a point, for in the meridian of least refraction,  $b b$ , they have been less turned from their original course, and therefore from side to side are still spread out the distance  $f f$ . Not until they have travelled on to the point  $g$  are those from the right half of the pupil and from the left half of the pupil all collected to the center line of the pupil. By the time they have been thus collected from side to side they have begun to spread downward and upward, so that they occupy vertically the distance  $g g$ . A horizontal line,  $f f$ , into which all the rays are collected, is the focus for the vertical meridian, the *first focal line*; and  $g g$ , a vertical or *second focal line* in which all these rays are afterward collected, is the focus for the horizontal meridian or horizontal curvature of the cornea. The interval between  $f f$  and  $g g$ , depending on the difference of curvature in the directions  $a a$  and  $b b$ , called the *focal interval of Sturm*, shows the amount of astigmatism.

To  $f$  and  $g$  the rays from a single point outside of the eye are collected,

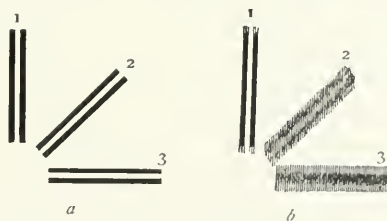


FIG. 162.—Illustrating the appearance of lines running in different directions  $a$ , seen by (a) the normal eye and (b) the astigmatic eye.

forming at each a focal line; at all other distances behind the cornea they spread out, making an area of diffusion which is commonly an ellipse, though at one point between  $f$  and  $g$  it becomes a circle. The focussing of the rays from a point outside of the eye upon a line of the retina gives rise to the peculiar defect of vision produced by astigmatism. This defect is such that

lines running in the direction of the focal line on the retina are seen clearly, except that their ends shade off gradually, but the lines running in other directions appear blurred, as in Fig. 162.

*a* represents lines running in three directions, as seen by an emmetropic eye. *b* represents the impression such lines make on the retina of an astigmatic eye: 1 shows them running in the direction of the focal lines on the retina, so that these overlap each other, giving the impression of a distinct line; 3 shows them running at right angles to the focal lines on the retina, so that they overlap the spaces on either side, giving the greatest blurring; and 2 shows them running obliquely, so that the overlapping causes blurring, but less than that for 3. All lines looked at by the astigmatic eye are seen in one of these ways at any given time. The eye may, by change of accommodation, so vary its refractive power as to bring first one and then another focal line upon the retina, making the lines clear at first in one direction and then in the other.

**Symptoms of Astigmatism.**—Generally lines can be seen clearly only when they run in some one direction, and this direction is that of one of the principal meridians. This necessarily occasions a certain indistinctness of vision, which is peculiar in that, when tested by the test-letters, some of these on account of the direction of their characteristic lines are more blurred than others. The patient may miscall several of the letters of a certain size, and yet recognize others of but half that size. In general, the indistinctness due to astigmatism is not more than half as great as that produced by myopia or hyperopia of equal amount.

It has been stated that the astigmatic eye seeks to overcome indistinctness of vision by unequal contraction of different parts of the ciliary muscle, causing unequal convexity of the crystalline lens in different meridians. It has not been certainly proved that this occurs. But the indistinctness may be partly overcome by rapid changes from one state of accommodation to another, causing first the one focal line and then the other to fall upon the retina in such quick succession that their impressions may aid in a single mental perception. Either use of the accommodation leads to eye-strain with all its possible manifestations—pain, congestion or inflammation of the eye and its appendages, headache, and other manifestations of disturbance of the general nervous system. In childhood the difficulty of the imperfect images hinders the development of the powers of visual perception, and even of the general mental processes. Indistinctness of vision, though present from early life, may somewhat diminish as the patient learns to use his eyes, but increases again when age has caused the impairment or complete loss of accommodation. High astigmatism, especially myopic, with the greatest defect in the vertical meridian, is quite as likely to cause partial closure of the lids, with secondary disturbances of the cornea, as is myopia.

**Varieties.**—*Astigmatism with the rule* is astigmatism with the meridian of greatest refraction vertical or nearly so, as it is in a large majority of cases.

*Astigmatism against the rule* means that the meridian of greatest refraction is horizontal or nearly so. The number of cases of this kind is comparatively small, but they grow more frequent after middle life. The astigmatism that follows cataract extraction, iridectomy, and similar corneal sections is usually of this kind, because such sections are generally made in the upper margin of the cornea, and their influence is to flatten the cornea in the meridian perpendicular to their length. Astigmatism against the rule has also been noted as a forerunner of glaucoma.

*Oblique astigmatism* means that the direction of the principal meridians departs much from the vertical and horizontal, and approaches rather to 45 and 135 degrees. Some writers believe that astigmatism against the rule and oblique astigmatism are most likely to cause inconvenience, or to cause more inconvenience than astigmatism with the rule of equal amount. This may be explained by the fact that only lines parallel to the principal meridians can be perfectly focussed on the retina, and that the greatest number of lines looked at are either vertical or horizontal.

While the amount of astigmatism and the direction of its principal meridians are independent of the position of the retina, the relation of the retina to the focal lines determines the variety under which astigmatism is classified; thus, in Fig. 163, suppose  $c$  represents the cornea, the solid lines represent

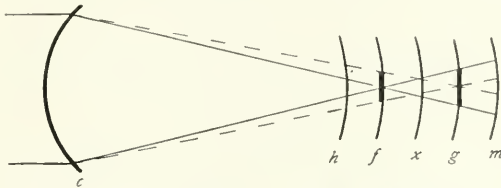


FIG. 163.—Figure illustrating varieties of astigmatism.

rays as refracted in the vertical meridian, and the broken lines the rays as refracted horizontally,  $f$  to be the position of the anterior focal line, and  $g$  the position of the posterior focal line. When the retina passes through  $f$  the defect is called *simple hyperopic astigmatism*—hyperopic because as regards the meridian of least refraction and the focal line  $g$  the eye is hyperopic—simple because it can be corrected by the simple cylindrical lens which corrects the meridian of least refraction.

When the retina is situated at  $h$  the astigmatism is called *compound hyperopic*. The eye is hyperopic for both meridians, for both focal lines, and it can be corrected only by a compound cylindrical or sphero-cylindrical lens.

When the retina passes through  $g$  the defect is *simple myopic astigmatism*, the eye being myopic for the meridian of greatest refraction and the focal line  $f$ , and capable of correction by a simple cylinder correcting the meridian of greatest refraction.

When the retina is at  $m$  the astigmatism is *compound myopic*, the eye being myopic for both focal lines and meridians, and its ametropia is only corrected by a compound cylindrical or sphero-cylindrical lens.

When the retina is situated between  $f$  and  $g$  the eye is hyperopic for  $g$  and the meridian of least refraction, and myopic for  $f$  and the meridian of greatest refraction; the astigmatism is called *mixed*, and requires for the correction of the ametropia a lens convex in one meridian and concave in the other. It is evident that simple increase in the antero-posterior axis of the eyeball by distention will cause the same case of astigmatism to pass from compound hyperopic to simple, then to mixed, afterward to simple, and finally to compound myopic. In case of astigmatism becoming myopic these changes successively occur in the course of the progressive distention of the eyeball (see also pages 127 and 128).

**Correction of Astigmatism.**—This is effected when rays, instead of being focussed to two focal lines, are focussed to a single point. The correction of the ametropia present requires that for parallel rays this point shall fall upon the retina. But the astigmatism may be fully corrected, although a certain



amount of other ametropia (hyperopia or myopia) remains uncorrected. Astigmatism is corrected by any cylindrical lens or combination of lenses that makes up for the difference of refraction in the two principal meridians. Thus a convex cylinder with its curve parallel to the meridian of least refraction, and equal in strength to the difference between the two principal meridians, will correct any case of astigmatism. A concave cylinder with its curve parallel to the meridian of greatest refraction, and strong enough to make the difference between the two meridians, will correct it equally well. Or a convex cylinder correcting a part of the astigmatism may be placed with its curve in the direction of the meridian of least refraction, and a concave cylinder strong enough to correct the remainder of the astigmatism with its curve parallel to the meridian of greatest refraction.

In general, any case of astigmatism may be corrected by one of three combinations of lenses. Take, for instance, a hyperopic astigmatism in which the horizontal meridian is hyperopic 4 D., and the vertical meridian hyperopic 2 D. The astigmatism may be corrected (1) by a convex 2 D. cylindrical lens placed with its curve horizontal (axis vertical), and the additional hyperopia corrected by combining with this a convex 2 D. spherical lens. This astigmatism may be corrected (2) by a concave 2 D. cylindrical lens placed with its curve vertical (axis horizontal). This would have the effect of increasing the hyperopia of the vertical meridian, and to correct the hyperopia a convex 4 D. spherical lens would be required. It would also be possible (3) to correct the astigmatism with a convex 4 D. cylinder with its curve horizontal (axis vertical) and a convex 2 D. cylinder with its curve vertical (axis horizontal). The one cylinder would bring the posterior focal line on the retina without affecting the anterior focal line, and the other cylinder would bring the anterior focal line on the retina without affecting the posterior line. In this way both focal lines, brought to the same distance from the cornea, would become a single point, and the astigmatism would be corrected, and with it also the hyperopia.

For the one case of astigmatism any of the following lenses might be chosen, the correction being optically as good with one as with another :

- (1) + 2 D. sph.  $\odot$  + 2 D. cyl. axis  $90^\circ$  (vertical);
- (2) + 4 D. sph.  $\odot$  - 2 D. cyl. axis  $180^\circ$  (horizontal);
- (3) + 2 D. cyl. axis  $180^\circ$   $\odot$  + 4 D. cyl. axis  $90^\circ$ .

Looking at these, it will be seen that (1) has on the whole the weakest surfaces. It is theoretically possible with it to get the thinnest lens and the one having usually the least aberration. It is also the lens most commonly selected in testing the eye with trial glasses, and the one most frequently prescribed.

It will be observed that (2) has one convex and one concave surface. The spherical surface has to be stronger than that of (1), and therefore causes more aberration; but this is a matter of very little importance. It is of greater importance that by placing the concave surface toward the eye and the convex surface away from it something of a *periscope* effect can be obtained by this second lens allowing the eye to be turned in different directions without causing so much obliquity of the visual axis to the lens surfaces. On this account (2) will prove on the whole the most satisfactory for a large proportion of cases.

With reference to (3), it will be noted that it includes two cylindrical surfaces with their axes exactly perpendicular. Such a lens is very hard to

grind sufficiently accurate for practical purposes, and impossible to grind with theoretic accuracy. Its surfaces, too, are stronger, and therefore cause more aberration. On every account this form of lens, the *crossed cylinder*, is to be avoided. It has rarely been used except for mixed astigmatism, where it gives weaker surfaces than either of the sphero-cylindrical lenses. But this does not compensate for the increased expense and necessary inaccuracy of crossed cylinders, and it is better never to employ them.

The following formulas will illustrate this subject as regards mixed astigmatism :

- (1)  $-1 \text{ D. sph. } \odot -2 \text{ D. cyl. axis } 90^\circ ;$
- (2)  $+1 \text{ D. sph. } \odot -2 \text{ D. cyl. axis } 180^\circ ;$
- (3)  $+1 \text{ D. cyl. axis } 90^\circ \odot -1 \text{ D. cyl. axis } 180^\circ .$

In compound myopic astigmatism the same thing holds, as the following equivalent formulas will indicate :

- (1)  $-2 \text{ D. sph. } \odot -2 \text{ D. cyl. axis } 180^\circ ;$
- (2)  $-4 \text{ D. sph. } \odot +2 \text{ D. cyl. axis } 90^\circ ;$
- (3)  $-4 \text{ D. cyl. axis } 180^\circ \odot -2 \text{ D. cyl. axis } 90^\circ .$

In simple astigmatism the correction for the better meridian is 0 ; and one element of formulas (2) and (3) becomes 0, so that the two become alike. In simple hyperopic astigmatism we would have the following :

- (1) or (3)  $+2 \text{ D. cyl. axis } 90^\circ ;$
- (2)  $+2 \text{ D. sph. } \odot -2 \text{ D. cyl. axis } 180^\circ ;$

from which one may choose the simple cylinder, which is the cheapest lens, or the sphero-cylindrical lens, which gives the better periscope effect.

In simple myopic astigmatism the formulas are thus :

- (1) or (3)  $-2 \text{ D. cyl. axis } 180^\circ ;$
- (2)  $-2 \text{ D. sph. } \odot +2 \text{ D. cyl. axis } 90^\circ .$

**Wearing Glasses for Astigmatism.**—The whole treatment of astigmatism consists in the wearing of glasses. Since astigmatism interferes with distinctness of vision at all distances, and since it entails, when uncorrected, a use of the accommodation entirely different from that of emmetropic, hyperopic, or myopic eyes, it is important that the lenses correcting it should be worn constantly. This is essential in all cases at first. Sometimes a patient, by wearing glasses constantly acquires the habit of using the accommodation normally and can continue to so use it by sacrificing something of distinctness of vision on laying aside his correcting lenses at times when the eyes are not to be especially taxed. Such persons, after the constant use of cylinders for some time, are able to do without using them constantly when the eyes are not employed on work requiring distinct vision. In general, however, a patient having much astigmatism may be warned that he will always require the help of correcting lenses.

Cylindrical lenses, contrary to what is sometimes expected, are often difficult to become accustomed to, especially if they are strong, if the patient is advanced in years, and if the axes of the cylinders before the two eyes must be turned in different directions. Strong cylinders are never satisfactory at

first. With some persons, especially when past middle life, the difficulty of becoming accustomed to them is so great that they are very likely to give up the attempt. This should be carefully considered before ordering glasses. Any cylindrical lens changes somewhat the shape of the retinal images and, therefore, the apparent shape of objects looked at. When the axes are turned in different directions the distortion of the retinal images, corresponding to the directions of the axes, differs in the two eyes, so that it becomes difficult to fuse the two impressions they make and secure binocular vision. These unpleasant effects may be diminished by wearing for a time an incomplete correction of the astigmatism or by bringing the lenses particularly close to the eyes.

**Aberration.**—A spherical lens does not perfectly focus the rays passing through it. In general it acts toward the edge as a stronger lens. This may be illustrated by the following diagram, which shows the course of the parallel rays as refracted by a convex spherical surface (Fig. 164). The rays passing through the center are focussed at  $f$ , the principal focus of the lens, and those passing through the margin are focussed closer to the lens. The unequal distribution of light in the circle of diffusion, its concentration to a

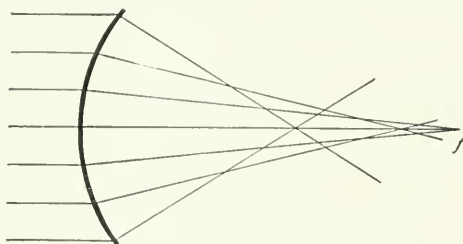


FIG. 164.—Figure illustrating spherical aberration.

ring at the edge and a point at the center of that circle, may be studied with a strong convex lens focussing light upon a card.

In the human eye the periphery of the crystalline lens is more convex than the center, and acts, therefore, as a stronger lens than the center, just as in the ordinary spherical lens. The periphery of the cornea, on the other hand, is always more or less flattened. Within the pupil, in the majority of eyes, the increased convexity of the crystalline lens predominates, so that they present a stronger refraction, higher myopia or lower hyperopia, at the periphery of the pupil than at its center. This condition the writer has called *positive aberration*. When the opposite occurs the refraction is stronger, the myopia higher or the hyperopia lower at the center of the pupil than near its margin, constituting *negative aberration*.

Aberration plays an important part in skiascopy, determining the form and size of the light area in the pupil, causing reversal of the movement of light in the periphery (in positive aberration) to be perceived closer to the eye than the movement of light at the center, where it is of more practical importance.

When aberration is confined chiefly to the extreme periphery of the pupil, where it is shut off by the pupillary contraction in a strong light or during near work, it has no influence on the working power of the eye. When it begins near the center of the pupil, causing the eye to be more hyperopic when the pupil is contracted by a strong light or for close work than when more dilated, it has an important influence in producing eye-strain, and may

be a cause of error in the selection of lenses. An eye with positive aberration will often select with the undilated pupil a convex lens 0.25 D. stronger, or a concave 0.25 D. weaker, than it will accept while the eye is fully under the mydriatic.

Aberration is to be recognized by skiascopy and considered in the choice of lenses. It cannot be exactly corrected by any particular lens, but is sometimes an indication for the wearing of a stronger lens than one which will allow of perfect distant vision, such a lens being found in these cases decidedly more helpful. High negative aberration is sometimes due to increased refractive power in the nucleus of the lens—incipient senile cataract—or to conical cornea.

**Irregular astigmatism** is recognized by skiascopy, causing appearances represented in Fig. 165 *A* and *B*. Traumatism or disease of the cornea, leaving irregularities of its surfaces (Fig. 165, *A*), tissue-changes in the lens preceding cataract (Fig. 165, *B*), and occasionally faulty development of the cornea or lens, cause irregularities of refraction that prevent the perfect focussing of light to a point by the dioptric media. Such defects are not capable of correction by lenses. The eye, however, often presents within the area of the pupil small areas in which the refraction is comparatively uniform, which areas may be corrected by some combination of lenses, and the vision and comfort of the




FIG. 165.—Appearances of irregular astigmatism recognized by skiascopy.

patient thus be greatly improved. The practical thing to do is to study these cases carefully by ophthalmometry and skiascopy, and to correct the most regular portion of the cornea.

In a few cases, where no lens can render much service, it may be worth while to try a *stenopæic spectacle*. This is an opaque disk in front of the eye with a narrow slit or, more commonly, a single pin-hole opening in it. Such an apparatus often gives a noticeable improvement of vision, but it is rarely found very serviceable because it interferes with the visual field.

**Anisometropia.**—Some inequality in the refraction of the two eyes is the rule, and occasionally this is such as to render one eye hyperopic and the other myopic, or one astigmatic, while the other is free from astigmatism. Such a difference constitutes *anisometropia*. The importance of the difference depends entirely on its degree, and not on whether it amounts to a difference in the kind of ametropia.

The general rule when the difference is not great is to give each eye its exact correction. If the difference between the two correcting lenses is very great, they affect the size of the retinal images, so that binocular vision becomes difficult. When one lens is much stronger than the other, looking through the periphery produces a correspondingly different prismatic effect, causing objects to be seen double, or the effort to use the images falling on the two retinas causes strain of the extraocular muscles.



For the above reasons the full correction of anisometropia cannot always be practised. It is generally safe to prescribe the correcting lenses for both eyes when these differ less than 1 D. If they differ not more than 2 D., they will generally be accepted, although this cannot always be assumed. If they differ more than 2 D., the patient will find it very difficult or impossible to use them for satisfactory binocular vision, although a few persons will prefer to have anisometropia of 3 or 4 D. fully corrected. When the difference of refraction cannot be fully met by difference of glasses, the rule is to correct the better eye and to allow the worse eye the full correction of its astigmatism, with a spherical lens equal to that of the better eye or a little stronger. Sometimes, if both eyes have good vision, but cannot work together, one may be corrected for distant vision and the other given a lens that will adapt it for near seeing. Congenital anisometropia often gives little trouble, but anisometropia coming on from change in the refraction, as in progressive myopia, is likely to be very annoying. The similar effect produced by glasses not accurately suited to the eyes is also very annoying. Acquired anisometropia, particularly from 0.5 to 2 D., is especially liable to give rise to squint, and its correction is indicated to preserve or restore binocular vision.

**Presbyopia.**<sup>1</sup>—The failure of accommodation with age leads finally to complete inability to change the optical condition of the eye, so that only rays of a certain convergence or divergence can be focussed upon the retina. In the great majority of eyes, which are hyperopic, this renders necessary the use of convex lenses for near vision. For this purpose the need of lenses is felt—the eye is presbyopic—as soon as the power of accommodation has diminished so that it is unequal to the task of keeping the crystalline lens convex enough to focus rays accurately on the retina when the eye is engaged in ordinary near work. When this occurs either symptoms of strain, such as congestion and pain in the eye, conjunctivitis, or headache, arise, or after the effort has been sustained for some time the ciliary muscles suddenly relax and all near objects become blurred. If the eyes are now rested for a minute, the power of distinct near vision returns, but if the near vision is continued, it again fails, and, persisting in the attempt, such failures become more and more frequent until the effort is given up.

The failure is first for objects at the shortest distance from the eye, as small objects or fine print that needs to be brought close in order to be seen. Objects that may be held farther away, or the same object in a strong light which will render it distinguishable at a greater distance, may still be clearly seen, the patient noticing only that he requires good light and has to hold things farther from the eyes than formerly. Presbyopia is caused first by the increasing rigidity of the crystalline lens, which limits its tendency to become more convex when the tension of the suspensory ligament is removed by contraction of the ciliary muscle. Subsequently the ciliary muscle also becomes weakened or undergoes atrophy, and the power of accommodation is completely lost.

Presbyopia is relieved by supplementing the insufficient focussing power of the crystalline lens by a convex lens of the necessary strength placed before the eye. In choosing such a lens it is to be borne in mind that we have to enable the eye not only to see clearly at the required distance for an instant, but to sustain distinct vision at that distance over periods of continuous use. The maximum contraction of a muscle is always one that cannot be long sustained; hence the lens giving the patient a near point where he wishes to

<sup>1</sup> For additional consideration of this subject see page 137.

work will be insufficient for continuous work. With most persons only two-thirds of the accommodation can be long kept up. A few can sustain three-fourths of it, but others, particularly young persons suffering from weakness of accommodation, can comfortably sustain only one-half of the full amount.

In correcting presbyopia, then, we not only find the near point of distinct vision, but from that near point and the refraction of the eye calculate the total power of accommodation. Then assuming that two-thirds of this accommodative power is available for continuous work, the difference between that available accommodation and the accommodation required for the sort of near work to be done is the strength of lens that should be given to correct the presbyopia. This may be illustrated by examples of different errors of refraction.

Suppose, first, a case of presbyopia in emmetropic eyes. The nearest point of distinct vision being 18 inches (45.5 cm.), corresponding to 2.25 D. of accommodation, two-thirds of this, which may be assumed as available for near work, equals 1.5 D. Now, if the patient wishes to use the eyes for ordinary reading, writing, sewing, etc. at a distance of 13 inches (33 cm.), where 3 D. of focussing power will be required,  $3. - 1.5 \text{ D.} = 1.5 \text{ D.}$  will be the strength of the convex lens that should be given to supplement accommodation—to correct the presbyopia. If the patient has been wearing such a lens or one nearly as strong, and still shows evidence of undue strain of the eyes for near work, it may be that he cannot sustain two-thirds of his total accommodation, but requires the presbyopic correction to be made somewhat stronger, as 1.75 or 2 D. On the other hand, if such a patient has been reading without any lens and without much inconvenience, it may be assumed that he can sustain more than two-thirds of his total accommodation, and therefore a weaker lens, as the 1 or 1.25 D., may be given.

Suppose in another case the patient has hyperopia of 2 D., and a near point of distinct vision of 16 inches (40 cm.), corresponding to 2.5 D. of focussing power, to which is added the 2 D. needed to correct the hyperopia, making 4.5 D. of total accommodation. Two-thirds of this accommodation, or 3 D., would only correct his hyperopia, and leave 1 D. to adapt the eye for near vision at a distance of 1 m. If such a patient is to work at 13 inches (33 cm.), where 3 D. of focussing power is needed, he will require the help of a lens equal to 3 D., — 1 D., or 2 D. The increased use for accommodation will cause the hyperopic eye to suffer earlier from presbyopia if it has not the help of correcting lenses for the hyperopia. It will also be noted that with a certain near point the hyperopic eye requires a stronger supplementary lens, since that near point represents, with a greater amount of accommodation, a greater need for it. The lens required in the above case might be found by correcting the hyperopia with a 2 D. convex lens, when it would be found that the near point was at 9 inches (23 cm.) (4.5 D. of accommodation), and that two-thirds of this accommodation, 3 D., would be sufficient for work at 13 inches (33 cm.). Hence no further correction for presbyopia would be required, the correction of the hyperopia causing the presbyopia to disappear.

By myopia the need for a presbyopic correction is postponed and diminished. Thus, an eye with myopia of 3 D. will be able to work at 13 inches (33 cm.) without any lens and without accommodation, and for that kind of work will never suffer from presbyopia. Take another case, where the myopia is 1 D. and the near point found at 22 inches (57 cm.), corresponding to 1.75 D. of focussing power; subtracting from this 1 D. of myopia leaves 0.75 D. as the

total accommodation. Of this two-thirds, or 0.5 D., being available for near work, is to be added to the 1 D. of myopia, making 1.5 D. of available focussing power, and for work to be done at 13 inches there will be need in addition for a convex lens of 1.5 D. That is, in myopia of 1 D., with only 0.75 D. of accommodation, the same help is required as in emmetropia with accommodation of 2.25 D. With myopia, as with hyperopia, the total accommodation may also be found by first correcting the myopia and then taking the near point.

In astigmatism the accommodation can only be accurately determined by taking the near point after the correction of the astigmatism, and the amount of convex spherical to be added for near work on account of presbyopia will then be determined as though the eye had been originally emmetropic. Sometimes in giving lenses for presbyopia with astigmatism, while the concave cylinder is better for distance, the convex cylinder with its axis turned at right angles is better for near work. Suppose a case of simple myopic astigmatism requires for its correction — 1.5 D., cylinder axis  $180^\circ$ , and with this correction before the eye the near point is 18 inches (46 cm.), the accommodation 2.25 D. The spherical to be added for near work at 13 inches (33 cm.) would be 1.5 D., and a convex 1.5 D. spherical, combined with the concave 1.5 D., cylinder axis  $180^\circ$ , is the optical equivalent of the convex 1.5 D., cylinder axis  $90^\circ$ . For distant vision such an eye may be given — 1.5 D., cylinder axis  $180^\circ$ , and for near vision + 1.5 D., cylinder axis  $90^\circ$ .

**Course.**—Presbyopia usually begins between the ages of forty and fifty. With hyperopia, which may have given no earlier evidence of its presence, it begins younger; with myopia, later or not at all. Even with emmetropic eyes the increasing rigidity of the lens may require the use of convex glasses before the age of forty, and with a few the need of a presbyopic correction is deferred until after the age of fifty.

In all cases after it has begun presbyopia is progressive. The power of accommodation continues to diminish until it is entirely lost, and such diminution causes the necessity for increasing the strength of the supplementary lenses—the presbyopic correction. Generally, the lenses should be changed often enough to have a difference of not more than 0.75 D., or about once every two or three years from forty-five to fifty-five. Most patients require the same correction for presbyopia for both eyes. In a few cases this is not so, the accommodation failing faster in one eye than in the other, and requiring a correspondingly stronger supplementary lens. In such cases the eyes should be repeatedly tested to make sure that there is actually a difference between them, and the tests repeated at short intervals.

**The Mounting of Glasses.**—Lenses are commonly supported before the eyes by spectacle or eye-glass (pince-nez) frames. The former have the advantage of more rigidly fixing the position of the lens before the eye. The latter are more readily removable when the lenses are not required for constant use. The proper adjustment of the frames is a matter of much importance, since the right lens in the wrong position does not have its proper effect, and may be entirely unsatisfactory (see pages 236–240).

**The Period of Adaptation.**—Weak lenses, less than 1 D., may prove satisfactory and comfortable from the start or within a few days after beginning to wear them. Children may become accustomed to even strong lenses in a very few days. Correcting lenses will generally be accepted without complaint when the eye is kept for some time under the influence of a mydriatic. But, apart from these exceptions, lenses are rarely accepted with entire comfort at first.

The period of adaptation during which the first discomfort diminishes and passes away may last from two to six weeks, or even longer; during this period convex lenses are likely to cause blurring of distant vision, concaves render near work noticeably more fatiguing, and cylinders cause distortion of objects and an indefinite discomfort. These unpleasant effects may from the start be more than balanced by the benefits experienced, yet it is prudent in all cases to warn the patient that some weeks must elapse before the glasses can be expected to do their best. With such a warning most people encounter the necessary difficulties without loss of confidence. But if permitted to put on the glasses expecting immediate satisfaction, they become disappointed, lose faith in the prescriber, and are likely to refuse to give them a fair trial. The good of the patient and the reputation of the surgeon both demand that a careful explanation of the period of adaptation should be given when the glasses are prescribed.



## SPECTACLES AND THEIR ADJUSTMENT.

BY R. J. PHILLIPS, M. D.,

OF PHILADELPHIA.

A SPECTACLE-LENS should be so placed that, in use, the line of sight passes through the optical center perpendicular to the plane in which the glass lies. These simple conditions would be extremely easy to satisfy were it not for the fact that the organ of vision must of necessity be extremely active and mobile. The eyeball may, in fact, be rolled in its socket about  $60^\circ$  in every direction from a point immediately in its front, while movements of the head, or even of the entire body, are constantly called in requisition as greater range of vision is required. These facts destroy at once the possibility of so placing a glass that its center may be coincident with, and its plane be perpendicular to, the line of sight under all circumstances. Only a glass fastened to the eye and moving with it could fulfil these conditions.

Though the glass cannot be attached to the eye, it can be and is attached to the head, which, as has been noted, is nearly constantly in motion, seconding the activity of the eyes. The necessity of looking through the center of the glass limits for the wearer the range of the eyes in their sockets, and increases in a corresponding degree the excursions made by the head. This augmented head-motion, which can be noticed in almost all wearers of glasses, arises partly also from the effort to bring the plane of the lenses perpendicular to the line of sight. The only exception to these statements is in the case of a person who is wearing a glass which under-corrects his ametropia, and who looks through it obliquely in order to increase its refractive effect. The more exactly the glass and frame are fitted to the requirements of the case, the less of this auxiliary head-movement will be required; some increase in it must, however, be accepted as one of the concomitants of wearing spectacles. When a person with glasses raises his head continually, markedly elevates or depresses his chin, or forcibly twists his spectacle frame in his fingers, he is instinctively seeking to correct faulty refraction or faulty frame-fitting.

Spectacles are ordered to be worn either constantly, or for near work only, or for distant vision only. It will be readily understood that the circumstances under which near work is usually done admit of the most exact adjustment of the glass. Such work is usually held in the hands or occupies a desk or bench having a fixed position relative to the workman. It is below the level of his eyes and within reach of his hands, and only slight excursions of the eyes are required in its performance. As the line of sight is directed downward, the "near" glass (*n*, Fig. 166) must be placed below the level of the eye; at least its optical center must be so placed. It must face strongly downward in order to bring its plane perpendicular to the line of sight (*b*). It should face slightly inward for the same purpose, since the visual axes converge in near vision. This convergence necessitates, further, that the optical centers of the glasses shall be placed from 4 to 6 mm. nearer together

than are the centers of the pupils, since the visual axes would otherwise pass to their inner sides. If an isosceles triangle is constructed with the interpupillary distance as its base, and the visual axes, directed toward a near object, as its remaining sides, it will be apparent that the farther from the eyes a pair of glasses stand and the nearer to the eyes the work is situated, the less should be the distance between the optical centers of the glasses. The precise distance between optical centers which any given case may require may thus be determined.

In "distant" vision the gaze may be directed toward any point of the horizon or firmament, and yet, practically, the relation of the line of sight to the face, and consequently to glasses attached to the face, does not vary greatly. A distant object would have to change its position considerably in order to move through five degrees of one's field of view. Hence rapid changes in the direction of the line of sight are seldom required. Ample time is afforded for whatever adjustments of the head and trunk may be necessary. Distant vision usually takes place, therefore, with the visual axes directed forward perpendicular to the plane of the face (*a*, Fig. 166). When glasses are ordered for this use alone they should have optical centers separated by the same interval as that between the pupils (since they will not be used during convergence), and should face directly forward, lying in a plane parallel to the general plane of the face (*d*, Fig. 166). The optical centers of the lenses should stand at the same height as the pupils.

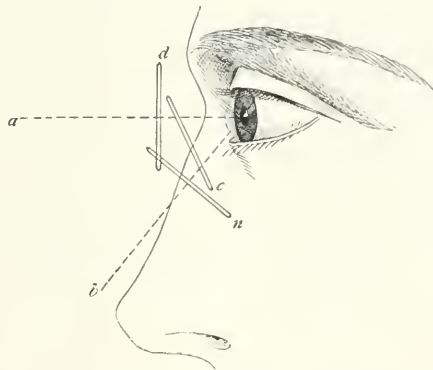


FIG. 166.—Showing position of lenses before eye.

In the greater number of cases the spectacles prescribed are intended for constant use—that is, the wearer will need them as well in viewing distant objects as in work near at hand. It is evident that to place the lenses in the exact position desirable for either of these purposes would render their use awkward for the other. In the height of the optical centers as well as in their distance from each other, and in the facing of the glass, we are therefore forced to place "constant" glasses in a position intermediate between that best for distant vision and that best for near work. This intermediate position is selected, not at all because these glasses are used at an intermediate distance, but because from this position they may be readily shifted, at least approximately, by a motion of the head into either of the other positions. The distance between the optical centers of "near" glasses should be from 4 to 6 mm. less than are the centers of the "distant" glasses intended for the same patient. This dimension is, of course, unaffected by movements of the head. Nevertheless, in order to reduce the unavoidable discrepancy to the minimum, the distance between the centers of the "constant" glasses should be 2 or 3 mm. less than that proper for the "distant" glasses. By a similar concession the "constant" glass is faced moderately downward and its centers placed somewhat lower than those of the "distant" glass, but not so low as those of the "near" glass.

In this connection the occupation of the patient should be considered. A seamstress or bookkeeper, for instance, if wearing a glass constantly should have it adjusted almost like a "near" glass, while persons engaged in outdoor

occupations will require an adjustment much nearer that proper for a "distant" glass.

The greater the strength of the prescribed lens the more necessary is attention to these details, since the effect of slight obliquity of the lens to the visual axis is greater in stronger lenses, as is also the effect of decentration. In bifocal glasses, therefore, in which there is both a stronger and a weaker lens, the former must dominate the position of the spectacles. Convex bifocals in which the "near" element is the stronger should, therefore, approach the "near" spectacles in position, while concave bifocals are placed more nearly like a "distant" glass, as the "distant" element is here the stronger.

A *spectacle frame* is a kind of tripod, its points of support being the top of each ear and the bridge of the nose. It is not possible to make an indifferently selected point on the bridge of the nose serve as the support of spectacles. Nearly always it will be found that there is one particular point at which they tend to rest. In adapting spectacles to any given face, therefore, the problem is to bring the optical centers to the position previously determined that they should occupy with reference to the eyes, while at the same time their support is placed at this best adapted point on the crest of the nose. The spectacle bridge known as the "saddle" bridge is the only one which allows of unlimited variation in the relation of these two points.

In fitting a frame to the face the curved portion of the bridge between *a* and *b*, Fig. 167, should be adapted to the bones of the nose at the point at

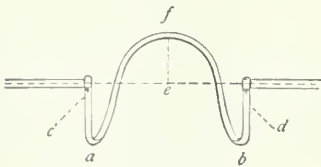


FIG. 167.—Saddle bridge.

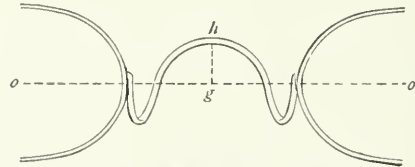


FIG. 168.—Saddle bridge.

which it is supported. Having once received the proper shape, this portion of the bridge should not be altered, as its only function is to furnish a firm, equally pressing support for the "arms" *c* and *d*, by means of which the centers of the glasses may be carried higher or lower on the face or the distance between them varied. These variations are accomplished by alterations in the angles of the wire at *a* and *b*. The length of the arms *c* and *d* governs the distance of the glasses from the eyes.

In prescribing or recording the measurements of a spectacle frame it is sufficient to give the distance between the centers of the glasses, with the height, depth, and width of the bridge. The height is the distance of *h*, Fig. 168 (the top of the bridge) above the line *o o*, joining the centers of the glasses; hence the distance from *h* to *g*. The depth is the distance between the top of the bridge (*f*, Fig. 167) and the point *e* on the plane in which the glasses lie. This distance may be a negative one—that is, *f* may be back of *e*. In the former instance the measurement is recorded as *out*, in the latter instance as *in*. The width of the base of the bridge is the distance between *a* and *b*. The measurements of a spectacle front may, therefore, be recorded in a single line, for example:

60 mm.  $\times$  5 mm. *up*  $\times$  3mm. *out*  $\times$  20 mm. *base*.

The direction in which the front of a spectacle faces depends on the angle which it forms with the side pieces or temples. If these latter are inclined

toward the bottom of the frame, the glasses when in use will face downward. It should be remembered that hook temples are simply hooks. They cannot, with comfort, be made to exert the force of a spring or a clamp upon the skin. They should touch the skin throughout the greatest possible portion of their extent, so as to distribute the weight they carry, and should not be allowed to press unequally owing to inequalities of the surface. Their proper form is a straight line from the hinge of the frame to the top of the ear, where a sharp curve joins that portion which is accurately fitted to the back of the ear, with which it is in contact.

In eye-glasses (pince-nez) the same adaptability to differently proportioned faces is found in the "offset guard," which in spectacles is attained by means of the "saddle bridge." The nose-pieces of these guards should be accurately moulded in every case to the sides of the nose at the point where they obtain the best bearing surface. Fixed points of support for the lenses are thus obtained. The height of the lenses before the eyes will now depend on the point of attachment of the "arm" of the guard to the nose-pieces. In Fig. 169, for

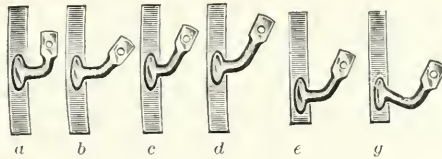


FIG. 169.—Guards of eye-glasses.

example, the guard marked *b* will carry the lenses higher than the one marked *e*. The direction in which the lenses face is controlled by the size of the angle in the arm of the guard. Thus, in the figure, at *a* the arm has a right angle and will render the plane of the lenses nearly vertical; that is, the latter will face directly forward, while at *b* the angle is greater than a right angle, and the glasses will face more downward.

The distance of the glasses from the eyes depends upon the length of this arm of the guard. The longer it is, the farther forward the glasses will be held; *d* and *g*, in the figure, have longer arms than *a* or *b*. Variations in the distance between the centers of the lenses may to a limited extent be procured by an arm which is bent so that its free end does not lie in the same plane as the nose-piece. If greater latitude is required it must be procured by variation in the transverse diameter of the lens used, or by alteration of the length of the "stud" which connects the lens with the guard.

**Methods of Testing Lenses.**—To ensure accuracy and comfort, spectacles, before being worn, should invariably be critically examined as to the strength of the lenses and the fit of the frame.

The most convenient method of determining the strength of lenses is the well-known one of neutralization by means of the test-case lenses of known strength. In practising this manœuvre the lens is held about a foot before the eye and an object several yards away is sighted. On moving the lens slowly across the line of sight the object seen through it appears to move also. In the case of convex lenses this apparent movement is in a direction contrary to the motion imparted to the lens, or, in the language of the refraction room, is "against it." With concave lenses the apparent movement of the object is in the same direction as the movement of the lens, or "with it." If a convex and a concave lens of equal strength are held together, all this apparent movement ceases; they "neutralize" each other. The surgeon is, therefore, able



to quickly discover the strength of an unknown *spherical* lens by trying it with lenses of the opposite sign until that one is found which causes all movement of the object to cease. The strength of this lens is the same as that of the unknown one.

A *cylindrical lens* is recognized by the fact that that portion of a vertical line seen through it assumes an oblique position when the lens is rotated about its optic axis (*a*, Fig. 170). If the rotation of the lens is continued, the motion of the displaced portion of the line is reversed and its continuity is restored, as at *b*. This appearance is, therefore, presented in two positions of the cylindrical lens. In one position the vertical line marks the axis of the cylinder; in the other the line is at a right angle to the axis. To locate the axis an object presenting crossed lines, as at *c*, Fig. 171, is selected; the lens is so held that each line appears unbroken and is first moved horizontally, then vertically. The line across which motion is apparent marks the axis of the cylinder. The cylindrical lens of the opposite sign which neutralizes this

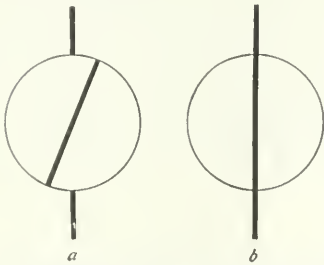


FIG. 170.—Method of testing cylindrical lenses.

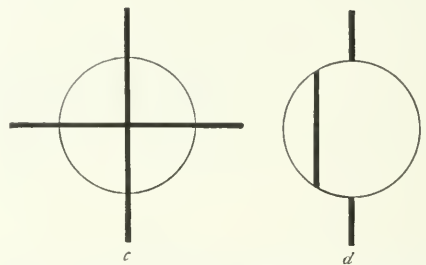


FIG. 171.—Method of testing spherocylindrical and prismatic lenses.

motion discloses the strength of the cylinder under examination. Care must be taken that the axes of the two coincide.

In a *spherocylindrical lens* the cylindrical element is recognized by its causing on rotation an apparent obliquity of a portion of a vertical line, just as did the simple cylinder. On viewing the crossed lines, *c*, however, and moving the lens first horizontally, then vertically, apparent motion of the object is imparted in both directions, but in one it is more rapid than in the other. In neutralizing, the least rapid movement may be first obliterated by means of a spherical lens. This gives the strength of the sphere in the combination. Holding these two together, one proceeds to neutralize the cylindrical element by means of a cylinder of opposite sign, precisely as though no sphere were present.

On rotating a *prismatic lens* about one's line of sight an apparent displacement of a vertical line takes place, as at *d*, Fig. 171. When the line is continuous it marks the base-apex line of the prism. At right angles to this is the meridian of maximum displacement. The prism being held at one meter's distance from the object, each centimeter of apparent displacement of the line shows one centrad of strength in the prism.

The *optical center* of a lens is located by using crossed lines, as at *c*, Fig. 171, except that for this purpose the lens is held within about a foot and the lines should be fine. When each of the lines is continuous their crossing point marks the optical center.

The distance between centers being found correct and a final inspection disclosing no flaws or scratches in the glass, no bends of the frame, or want of symmetry between its two sides, the spectacles are ready for the wearer.

## DISEASES OF THE EYELIDS.

BY B. L. MILLIKIN, M. D.,

OF CLEVELAND, OHIO.

**Congenital Anomalies.**—Partial or complete absence of the eyelids (*ablepharia*) is occasionally met with as a congenital defect. It may occur in one or both eyes.

**Lagophthalmos** is a defect in which the eyelids are wanting and the orbit is divested of any covering for the globe. An abnormal shortness of the lids, which prevents their fully covering the eyeball, has been similarly, and perhaps more correctly, so designated by many authors.

**Cryptophthalmos** is a condition in which the eyeball is completely concealed by the skin, which is stretched over the orbital cavity. Sometimes the eyeball is absent. Under the latter circumstances, however, the name is not an accurate one.

**Cleft-eyelid** (*coloboma palpebræ*) is a congenital defect in which there is a fissure of the lid, usually triangular, with the base toward the ciliary margin. The fissure may exist in either the upper or lower lid, the former being the usual seat. It has also been reported in the upper and lower lids on each side. The cleft involves the entire thickness of the eyelid and is rounded off at its margins. It occurs oftener with cases of hare-lip than with anomalies of the eyeball itself.

**Symblepharon** is a condition of union, either partial or complete, between the eyeball and the lids.

Another unusual congenital anomaly is a union between the margins of the lid-borders (**ankyloblepharon**). This attachment may be thread-like or involve a considerable intermarginal surface. The external angles of the lids may be adherent, producing the defect known as **blepharophimosis**, resulting in a shortening of the palpebral opening.

**Ectropion** is an eversion of the edges of the eyelids, frequently accompanied by enlargement of the eyeball.

**Entropion** is an inversion of the edges of the lids, and is usually associated with the incurving of the lashes—a condition known as **distichiasis**.

**Epicanthus** is an unusual congenital anomaly caused by a fold of skin which stretches across the inner palpebral space connecting the eyebrow with the bridge of the nose, the fold thus covering all the structures located at the inner canthus. It is generally bilateral, and gives rise to, or is associated with, a flattening of the bridge of the nose. Slight degrees of it may exist in children at birth, and with the development of the nasal bones this deformity gradually passes away.

Associated with epicanthus may be **microphthalmos** (sometimes only apparent on account of the diminished palpebral opening), strabismus, drooping of the upper lid, and anomalies of the lachrymal passages.

Epicanthus may be remedied by an operation in which the redundant

skin is removed from the bridge of the nose and the edges of the wound brought together with sutures.

**Congenital ptosis** is a drooping of the upper lid over the eyeball. It may be on one side or bilateral, and never amounts to complete closure of the lids. In this condition there is inability to raise the eyelid except by wrinkling the forehead through the action of the occipito-frontalis muscle. The anomaly is not infrequently associated with other malformations, as epicanthus, paralysis of the eye-muscles, etc. It may be corrected by operative procedures, described on page 557.

**Erythema of the lids** is a form of hyperemia of the skin, usually due to external irritation, such as burns, traumatism, and poisoning, or it may be indicative of some systemic disturbance. It is often well marked in inflammatory conditions of the eye.

Treatment will depend largely upon the cause, the erythema often disappearing with the cure of the primary lesion. Locally, soothing lotions, lead-water or extract of hamamelis, will be all that is required.

**Erysipelas** is rarely, if ever, a primary affection of the lids. It usually develops from a similar lesion of the face. The danger in this disease is that it may involve the deeper tissues of the orbit, affecting the retina or the optic nerve, and thus eventuate in blindness. In severe cases it may produce sloughing of the eyelids, with consequent deformity. The disease is characterized by great swelling, increased tension of the lids, smooth and brawny skin, deep redness, and the formation of vesicles or abscesses.

The treatment, both local and general, must be such as is usually adopted for erysipelas in other portions of the body.

**Abscess of the lid** (*phlegmon*) is characterized by an acute swelling of the eyelid, somewhat localized, indurated in the central portion, accompanied by much redness of the skin, heat, throbbing pain, malaise, and fever. The swelling is frequently very marked, the skin toward the height of the inflammatory stage in the severer cases often presenting a brawny appearance. Abscesses result from external injuries, from disease of the orbital walls, or they may arise from infectious causes or occur during illness—*e. g.* influenza. The tendency for the abscess to “point” is quite characteristic. Abscesses occasionally lead to extensive sloughing of the lid-tissues, and when they are not early opened they may result in lagophthalmos, ectropion, etc.

**Treatment.**—In the early stage ice-packs may sometimes abort the development of the abscess. Should the inflammation continue to increase, recourse should be had to hot packs and poultices to hasten the “pointing.” As soon as there is evidence of pus a free opening should be made into the center of the induration and deep enough to give vent to the pus. In making the incision care should be exercised that the fibers of the orbicularis are not cut across. The abscess-cavity may be washed out with peroxid of hydrogen or bichlorid solution, 1 to 2000, until recovery takes place.

**Furuncles** and **carbuncles** are rare. With them develops a “core” or central slough. Otherwise they present the same symptoms as an abscess and require similar treatment.

**Anthrax pustule** (*malignant pustule*) is a specific, infectious disease, due to inoculation by the poison of anthrax (*bacillus anthracis*), and is generally transferred to man from animals affected with the disease. Usually it occurs in persons working among animals, as hostlers, tanners, farriers, butchers, shepherds, etc. The disease is characterized by marked edema, redness, heat, pain, localized hardness or induration, the last indicating the point of infection. In malignant pustule, as in erysipelas, there may be very exten-

sive sloughing of the eyelid, producing at times a condition of lagophthalmos. After sloughing of the lids the ciliary margins alone may remain intact on account of the rich vascular supply. There is usually marked general depression, with fever. By absorption of the anthrax poison into the deeper tissues orbital cellulitis, or even meningitis, may ensue with fatal results.

**Treatment.**—This must be governed by general surgical principles. As soon as there is any evidence of pus the swelling should be freely opened, with one or more deep incisions, in order to prevent infiltration and possible involvement of the deeper structures of the orbit. The incision, followed by hot poultices or by compresses of absorbent cotton or gauze, wrung out of hot bichlorid-of-mercury solution, 1 to 2000 or 1 to 5000, will be very efficient. The administration of iron and quinin, tonics, stimulants, and good diet is of decided value.

In cases of extensive sloughing of the skin of the lids marked lagophthalmos and ectropion can be prevented by fastening the remaining marginal portion of the lid to its fellow by two or three stitches. The granular surface may then be treated with repeated skin-grafts applied according to the Thiersch-method. If this method cannot be followed, then the proper plastic operative procedures for these deformities must be undertaken, as indicated on page 555.

**Ulcers of the lids** may be due to contusions, burns, and various injuries, as well as to lupus, scrofula, syphilis, and herpes. The symptoms will vary with the cause; likewise the treatment.

**Hordeolum** (*Stye*).—According to the location, hordeolum may be hordeolum externum or hordeolum internum. *Hordeolum externum* is an acute inflammation of one or more of the glands of the hair-follicles. *Hordeolum internum* is an acute inflammation of the Meibomian glands. In other words, hordeolum or stye is a circumscribed inflammatory process, and is due to infection of the sebaceous glands or connective tissues of the lid, usually associated with the staphylococcus pyogenes aureus or albus.

**Symptoms.**—These are rapid edema of the lids, redness and tenderness coming on after a short time—a day or two—often quite severe pain, and sometimes fever and general disturbance. A hard lump or point of induration is felt at the seat of inflammation. Within a few days the color of the tissue over the stye changes from a red to a yellow hue, and the abscess “points.” If allowed to take its course, the abscess-sac ruptures, the pus escapes, and the symptoms rapidly abate.

In hordeolum internum “pointing” of the abscess takes place on the inside of the lid through the palpebral conjunctiva; in hordeolum externum, near the margin of the lid through the skin. The latter variety is much the more common.

Styes usually occur in persons subject to blepharitis, the chronic inflammation of the latter affection affording good soil for acute infectious inflammation of the solitary glands. The infectious character is well indicated by the fact that persons are very liable to successive attacks of styes, which occur, in many cases, at frequent intervals over a period of months. Young persons are generally the subjects of this disease, especially if they are scrofulous, anemic, or poorly nourished.

These two varieties of hordeolum present essentially the same clinical picture. With both there is inflammation of the sebaceous glands, and they are analogous to acne in the skin. The marked swelling of the former, as distinguished from the latter, is due to the anatomical character of the tissues in which the inflammation takes place.



**Treatment.**—In the early stage an attempt may be made to abort the development of a styé by the application of cold or very hot packs, or by touching the mouth of the gland involved with the sharpened point of a stick of nitrate of silver. If unsuccessful in this, “pointing” of the abscess should be encouraged by warm fomentations or properly applied poultices. Early opening of the styé is important. As soon as there is an indication of softening in the center of the induration a free incision should be made into the tumor in order to evacuate the contents and to prevent the extension of the necrotic process. Care should be taken that the incision is made parallel to the fibers of the orbicularis muscle, so that no deformity may remain. Subsidence of the symptoms is rapid after evacuation of the contents of the abscess. Between the attacks treatment should be directed toward improving the general health and alleviating the inflammation of the lid-margins; refractive errors, which may cause styés, should be corrected. Sulphid of calcium has some repute.

**Exanthematous Eruptions of the Lids.**—Ulcer of the lids, due to variola or small-pox, is of not infrequent occurrence. The parts attacked are the hair-follicles and sudorific follicles and glands. The results of severe attacks are pitting, cicatricial contraction of the lids, with ectropion and loss of the eyelashes, which, when permanent, produces the condition called *madarosis*.

**Treatment** is directed toward limiting as much as possible the ulcerative process. Protecting the pustules by dusting with a dry powder, such as starch and zinc oxid, in equal parts, or touching the ulcerated portion with a sharpened stick of nitrate of silver, has been advantageously employed.

**Vaccine Blepharitis** (*Vaccine Ophthalmia*, *Vaccinia of the Eyelids*).—This occasionally occurs from infection from a vaccination ulcer. It usually affects the borders of the lids, and is characterized by the rapid formation of an ulcer of the lid-margin, accompanied by much redness, swelling of the lids and of the preauricular and submaxillary glands, together with general fever, malaise, etc. In the early stage the vesicles appear with pitted center, but later the pustules are quite characteristic. In the last stages of the ulceration they resemble syphilitic ulcers, and must be differentiated from these by the history and progress of the case. Associated with the disease of the lid, marked conjunctivitis occurs, often simulating a diphtheritic membrane.

**Treatment** is directed toward allaying the early inflammatory symptoms, and later touching the ulcers with a 2 or 3 per cent. solution of silver nitrate. Aseptic washes to keep the eye clean should also be used.

**Eczema** appears either on the eyelids alone or is associated with general eczema of the face. It occurs also from the irritative secretions in chronic conjunctivitis, or in children as the result of rubbing the secretions from the eye upon the lids. It is most frequent in serofulous or badly nourished children. Eczema is caused in adults by epiphora, ectropion, etc., the tears running over the cheeks excoriating the surface. In these cases the lesions are usually found on the lower lid.

**Treatment** must be directed primarily to the cause. Locally, zinc ointment or Hebra's diachylon ointment, spread on lint or muslin and applied constantly, is satisfactory. Painting the skin with a 2 to 10 per cent. solution of nitrate of silver has been found to be very serviceable; only the latter in strong solution blackens the skin on exposure to light. Its action, however, in moist or ulcerative eczema, is very effective.

**Herpes zoster ophthalmicus** is the term applied to that variety of

herpes zoster which attacks the skin of the eyelids and other areas supplied by the first division of the trigeminus nerve. The disease is characterized by the formation of vesicles over the terminal portion of the nerve. The attack is preceded by severe neuralgic pain over this area, succeeded by the formation of vesicles over the forehead, the eyelids, the nose, cheek, and the upper lip, the disposition of the vesicles depending upon whether the first or second division of the trigeminus is affected. The third division is rarely affected. The vesicles first contain a clear, limpid fluid, but rapidly become cloudy and purulent, and finally dry into crusts. On removal of the latter, deep ulcers are found. After healing, permanent scars remain, which, by their peculiar grouping, indicate the nature of the attack. Not infrequently the cornea is affected, which greatly complicates the case. These ulcers of the cornea may result in permanent opacities. Iritis and eyelitis are not uncommon, especially if the nasal branch is affected; indeed, there may be a destructive inflammation of the whole eye (ophthalmitis). Palsy of the ocular muscles and atrophy of the optic nerve may follow herpes.

The cause of herpes zoster is obscure, but it is an inflammatory affection of the trigeminus. Persistent neuralgia may remain after an attack of herpes.

**Treatment.**—This is symptomatic. The vesicles should not be opened, but these should be dusted over with a drying powder (rice starch) and the ulcers allowed to heal beneath the crusts. Removal of the latter is productive of much pain. Internally morphin, quinin, and iron, according to indications, must be given. Keratitis and iritis require the usual measures elsewhere described.

**Blepharitis** (*Blepharitis marginalis*, *Blepharitis ciliaris*, *Blepharo-adenitis*, *Blepharitis ulcerosa*, *Psorophthalmia*, *Lippitudo ulcerosa*, *Tinea tarsi*, *Sycosis tarsi*).—On account of the peculiar anatomical structure of the margin of the eyelid this region is subject to a variety of diseases, with somewhat characteristic symptoms, forming a group by themselves. Rich in vascular and glandular structures, the edges of the lids are the seat of marked inflammatory disturbances, the more especially as they are greatly exposed to external irritation. Therefore disorders of the margins of the lids are among the most common of all diseases of the eye. In intensity of inflammation there are all degrees, ranging from a mere red fringe of the lids to a disorganization of their borders.

Two principal varieties of marginal blepharitis have been described, according to the symptoms—(1) squamous or simple blepharitis, and (2) ulcerated blepharitis.

(1) **Simple Blepharitis** (*Blepharitis squamosa*).—In this variety the margins of the lids are bordered with a red fringe, fine bran-like scales appearing at the roots of the cilia and between them, which drop off if the eyes are rubbed. There is also a tendency for the cilia to fall out if disturbed; they grow again perfectly. When the scales are removed the skin beneath is found to be hyperemic, but not moist or ulcerated.

In another variety instead of the scales there is a wax-like secretion which adheres to the lashes, gluing them together, but on its removal there is no evidence of ulceration beneath, the tissues appearing simply red and hyperemic.

(2) **Ulcerated Blepharitis.**—In this variety there are hyperemia, redness, shedding of lashes, and crusts. When the crusts are removed by washing an ulcerative process is evident beneath them. Many yellowish-white points appear, from the center of each of which protrudes a cilium. Upon

pulling out the lash there is often found adhering to the root a small rounded drop of pus. Still deeper is found a small ulcerated base extending into the hair-follicle. The cilia are readily removed on the slightest traction.

As the disease progresses the hair-follicles are successively involved in the ulcerative process, until, not infrequently, the entire series of cilia is destroyed, leaving cicatrices with their attendant and consequent deformity. When the cilium has fallen out a new one takes its place, of a different color, more or less stunted in its growth, and in a malposition the result of cicatricial contraction of the ulcerated hair-follicles. The lashes thus become more and more stunted and misplaced or entirely destroyed.

By the cicatricial contraction the lashes may be turned backward so as to touch the eyeball, giving rise to a condition of *trichiasis*, or the entire line of lashes may be destroyed, leaving the lid bald—*madarosis*. Another result of the ulcerative process may be the gradual eversion of the lower eyelid, due to the cicatricial contraction, which pulls the conjunctiva forward upon the lid-border, the lid itself falling away from the eyeball and permitting the tears to run over, in turn increasing the irritation (*lippitudo*, or “blear-eye”). The final result is an ectropion. Hypertrophy of the body of the lid not infrequently ensues, due to the long-continued inflammation, and produces drooping of the upper lid (*hypertrophic blepharitis*). It may be seen, therefore, that *blepharitis ulcerosa* is a much more serious condition than *blepharitis squamosa*.

The patient suffers little inconvenience as the result of the disease in the milder forms, and consults a physician more on account of the disfigurement than from any great annoyance. In the more pronounced forms the sensitiveness to light, the irritation, the sticking of the lids in the morning, etc. are real discomforts. Patients are unable to use the eyes for close work with comfort, and when the lashes are greatly displaced, with the resulting corneal irritation, they become almost helpless.

**Etiology.**—The causes of *blepharitis* are twofold—viz. local and general. The *local causes* are external irritations due to vitiated air, smoke, injuries, and chronic conjunctivitis, especially if associated with excessive lachrymation, inflammation of the lachrymo-nasal passages, and disease of the rhinopharynx. Abnormal shortness of the lids may excite the affection (Fuchs). Among the *general causes* are the exanthemata, scrofula, anemia, tuberculosis, syphilis, or malnutrition from any cause.

Stubborn varieties may depend upon eczema, eczema seborrhœicum, and seborrhea, and acne of the surrounding facial areas. Staphylococci are found in the pustules, and occasionally the *trichophyton* fungus (*b. trichophytica*). The *demoder folliculorum* has also been seen in the lid-margin. Refractive errors unquestionably play an important rôle in the causation of marginal *blepharitis*, as well as in other irritative and inflammatory lid-diseases; but they have not yet been accorded their due weight as causative factors in these affections. Correction of these errors by proper glasses will alone very often relieve a patient from troublesome *blepharitis*, which other methods seem powerless to effect.

**Pathology.**—In *blepharitis* the inflammatory process involves chiefly the cilia and glands. In squamous *blepharitis* scales are produced on the lid-margins and the cilia fall out. These grow thinner and shorter and less pigmented, and, as the epidermis is cast off, they entirely fail to grow.

In *blepharitis ulcerosa* the epithelium and often the papillæ are destroyed at the seat of ulceration, and if the ulcerative process extends deeply into the



tissues of the hair-follicles, the cilia are permanently destroyed and cicatricial contractions take place.

**Prognosis.**—Blepharitis is essentially a chronic disease. It may last for years and not infrequently for a lifetime. In young persons it may disappear spontaneously as they grow older, while in other cases it persists in spite of all treatment. It is essential that treatment should be vigorous to prevent permanent lesions.

**Treatment.**—The treatment must have reference to both general and local conditions, as well as to the causes. Faulty states of the general health should be corrected by appropriate means. Excessive use of the eyes should be prohibited, refractive errors should be examined, and proper glasses prescribed. Chronic conjunctivitis, so generally present in these cases, should be relieved, and any obstruction to the free discharge of the tears through the proper channel should be removed.

For the milder forms of blepharitis the non-irritating ointments give the most satisfactory results. After carefully removing the scales and crusts with warm water by gently washing them off, an ointment should be well rubbed into the roots of the lashes and along the margin of the lids, usually night and morning. For this purpose a 1 per cent. ointment of white precipitate, as being especially mild, has been much used. The yellow and red oxids of mercury are also favorite prescriptions in the proportion of one-half to two grains to the dram of vaselin or simple cerate. A 5 per cent. solution of chloral hydrate, alternating with a salve of pyrogallol (1 : 8) and a 2 to 3 per cent. sulphur ointment, have been well recommended.

In the severer cases associated with deposits of hard and strongly adherent crusts, which glue the lashes together, the use of a solution of five grains of carbonate of sodium to the ounce of water is most effective in removing them. It is important not to irritate the bases of the ulcers too much by violent means of removing the crusts. A pledget of absorbent cotton, moistened with the above solution, enables the patient or surgeon to remove the crusts effectually and without force. After the margins of the lids and cilia have been cleared of crusts the various ointments can be applied thoroughly to the diseased structures. In case of ulceration touching the ulcers with a five- to twenty-grain solution of nitrate of silver, or with a sharpened point of a silver-nitrate stick, acts most favorably. Where abscesses occur the cilia should be epilated with proper forceps, in order to give the remedies an opportunity of acting upon the diseased structures. No hesitation need be exercised about removing the cilia, for new hairs will replace those removed, even if they are repeatedly pulled out. When the disease has resulted in extensive cicatricial disturbances, as trichiasis, etc., proper operative measures alone are to be recommended. For the condition of madarosis no treatment avails.

**Phthiriasis** (*blepharitis pediculosa*) is an affection resembling blepharitis, and is associated with it. The ciliary margins present a dark appearance, which is due to the presence of the nits of the pediculus pubis. Close examination with a magnifying-glass of the borders of the lid will reveal the bases of the cilia full of the black eggs of the lice, and generally many individual lice clinging to the lashes. Rubbing mercurial ointment into the margins of the lids destroys the lice and their eggs.

**Syphilis of the eyelids** is a somewhat rare affection. However, not only is the primary ulcer met with in this situation, but also secondary and tertiary lesions. Both soft and indurated chancres occur on the skin of the lids. The former is an ulcer with a ragged edge and with a tendency to



spread. It appears without history of injury or other cause. The hard, indurated base of the ulcer in the other case is sufficiently indicative of its nature, and in due time secondary manifestations of the disease are likely to appear.

Not infrequently the lids, along with other portions of the skin, are the seat of secondary eruptions. During the third stage, occasionally, ulcers and gummata appear in the lids, the latter often presenting a striking similarity to chlamydia. These sometimes develop rapidly and undergo extensive ulcerative changes, producing ectropion, lagophthalmos, etc.

**Treatment** must include the proper constitutional remedies, while the extension of the ulcerative process must be combated by the use of the cauterium (nitrate of silver) and proper washes, or with compresses moistened with bichlorid-of-mercury solution.

**Tumors and Hypertrophies.**—Many benign growths occur in the eyelids, important on account of the disfigurement which they produce. Among these are *papillomata*, or *warts*, which grow on the lids and their borders. Occasionally, from irritation, these growths may assume an epitheliomatous type and prove serious. Their early removal, with cauterization of their bases, should be practised.

**Angioma (nevus)** occurs on the lids or their margins as a congenital growth. A nevus appears as a bright-red spot, not elevated, and usually is located near the margin of the lid. Its tendency is to increase in area somewhat rapidly.

The *cavernous* variety is usually elevated, sometimes gives a pulsatile sensation, and consists of greatly enlarged vessels. It disappears under pressure and becomes much enlarged when the patient stoops over. Sometimes there may be a *bruit* present if the orbit as well as the lids is involved or if the dilatation of the vessels is extreme. The conjunctiva may also participate in the diseased process. A *phlebolith* in a varix of the conjunctival veins has been reported by Swan M. Burnett.

Small nevi may be excised or cauterized with nitric acid or with the electro-cauterium by means of the platinum point. *Electrolysis* may likewise be employed with advantage. In the larger varieties the growth may be cauterized at numerous points at a little distance from one another, as the cicatricial contraction of the scars will cut off the vascular supply between. As little scar as possible should be aimed at, and frequent sittings may be advisable.

Rare forms of benign growths are *fibroma*, *adenoma*, *papilloma*, *enchondroma*, *neuroma*, and *lipoma*. The last-named growth may produce a form of ptosis—the so-called *ptosis lipomatosa*. All of these growths should be removed if they produce any disturbing effects, and this is, as a rule, not difficult of accomplishment.

**Cutaneous horns** sometimes attain a considerable size. They arise from the skin of the lids, often near the margin, and sometimes involve a large proportion of the lid-area. The exerescence is slow in its development and attains a horn-like hardness, especially toward its extremity. The growth should be cut off and a plastic operation replace the lost cutaneous tissue.

**Xanthelasma (xanthoma, vitiligoidea)** occurs in the form of rounded spots of various sizes on the surface of the skin of the eyelids. The patches are often situated on the eyelids near the inner angle, vary in size, and show a tendency to increase in numbers. They have a peculiar dark-yellow color, which is their prominent feature. They give rise to no discomfort. They occur mostly in women of advanced years.

The yellow or brownish-yellow patches may lie either on the surface of the skin (*xanthelasma planum*) or rise above it (*xanthelasma tuberosum*). These new growths of tissue are found to contain cells with granules or globules of oil. Brown or yellow molecules of pigment lie singly or in clusters in the cells and walls of the lymphatic vessels. Ablation may be practised on account of the disfigurement they produce.

**Chalazion** (*Meibomian cyst, tarsal tumor, cystic tumor, tarsal cyst*) occurs as a round tumor of variable size, giving the feeling of a shot beneath the finger. The skin over it is freely movable, but the growth has a firm attachment to the tarsus beneath.

**Etiology.**—The cause of chalazion is not well understood. Generally it occurs in persons subject to inflammatory disturbances of the lid-margins, frequently successive glands being attacked, one after another, until most of the Meibomian glands of one or more lids have been involved. Refractive errors seem to be an important element in many bad cases of chalazion, especially of the recurring type.

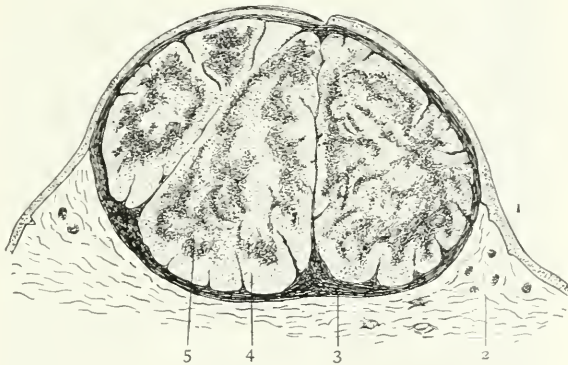


FIG. 172.—Vertical section of chalazion (Meibomian cyst);  $\times 10$ , glycerin: 1, stratified epithelium continued over the surface; 2, connective tissue outside tumor; 3, capsule of fibrous tissue from which septa pass inward, dividing the cyst into lobules; 4, epithelial cells inside capsule; 5, fatty material occupying center of lobules, the outer layers being more opaque (Pollock).

**Pathology.**—Chalazion may be solitary or several chalazia may occur in the lid, and the lower and upper lids of both eyes may be the seat of the growths. They originate in the Meibomian glands, and develop from an obstructive inflammation of the duct of these glands, which prevents the excretion of the sebaceous material. This accumulation aids in the development of an inflammatory action involving the gland and its surrounding tissue. The result is a tumor of considerable size, the contents of which, undergoing a fatty degeneration, become soft, and fill the sac with a gelatinous mass of granulation tissue containing giant-cells or with pus (Fig. 172). The process is very similar to the formation of an atheroma, except that the inflammatory changes are more marked. There is no true cyst-wall. If allowed to take its course, the chalazion develops outward, toward the skin (*external chalazion*), or involves the conjunctiva (*internal chalazion*). It frequently perforates the latter, extensive granulations springing up on the under surface of the lid, often resembling a neoplasm. Usually a catarrhal conjunctivitis, which infects the Meibomian glands, precedes the chalazion.

**Symptoms.**—These vary somewhat in the *acute* and *chronic* varieties. In the former the tumor may develop rapidly, with indications of much inflammation and with some pain and tenderness. It resembles a sty,

except that the tumor is more circumscribed and does not "point." The chronic variety grows slowly and causes no uneasiness to the patient, except the feeling of weight in the lid which it gives (Fig. 173). Should the growth perforate the conjunctiva, there may result some conjunctival and corneal irritation, due to the rubbing of the granulations upon these membranes. An acute chalazion is liable to be confounded with a sty, the diffuse appearance and "pointing" of the latter, however, serving to distinguish it. The chronic variety has been mistaken for small malignant growths and sebaceous cysts. The firm attachment of the chalazion to the tarsus should serve to differentiate it from a cyst. Sarcomata, when small, are difficult to diagnose, and sometimes a microscopic examination becomes necessary to determine the true nature of the growth.




FIG. 173.—Chalazion. (From a patient in the out-patient department of the Western Reserve University, Medical Department.)

**Treatment.**—The only satisfactory treatment for chalazion is surgical. Some relief, perhaps, may be afforded in the acute variety by frequent hot packs, followed by the use of the yellow-oxid-of-mercury ointment. The proper surgical procedure for its removal is described on page 546.

**Sarcoma**, as a primary growth, develops in the connective tissue of the lids, and occurs usually in children. In the early stage of its growth the skin moves freely over the tumor, but this rapidly invades the overlying tissues, which break down and become ulcerated. Sarcoma of the eyelids, of the small spindle-celled variety, may result from traumatism. It sometimes resembles a chalazion, but careful examination is likely to show a deeper coloring, with diffuse swelling. Microscopical examination alone will sometimes determine the true nature of the trouble.

Primary sarcoma of the eyelid may arise from any of the subepithelial



tissues, and may be of the spindle-, large or small round-, or mixed-celled variety. Pigmentation of cells or cells and stroma is sometimes seen (*melanosarcoma*). W. H. Wilmer, who has described a melanotic giant-celled sarcoma, has analyzed 35 cases, and finds that 40 per cent. were spindle-celled, 43 per cent. round-celled, 17 per cent. mixed, and 11 per cent. presented myxomatous elements.

An early excision of the growth alone offers any hope of protection against a fatal outcome of the trouble. Even after thorough removal return of the growth occurs in 40 per cent. of the cases (Wilmer).

**Carcinoma.**—The most usual type of carcinoma of the lid is the epitheliomatous ulcer, commonly called “rodent or Jacob’s ulcer.” The border of the lid is the favorite starting-point for the growth, which occurs in elderly persons. It usually begins as a small pimple covered with a crust, and its

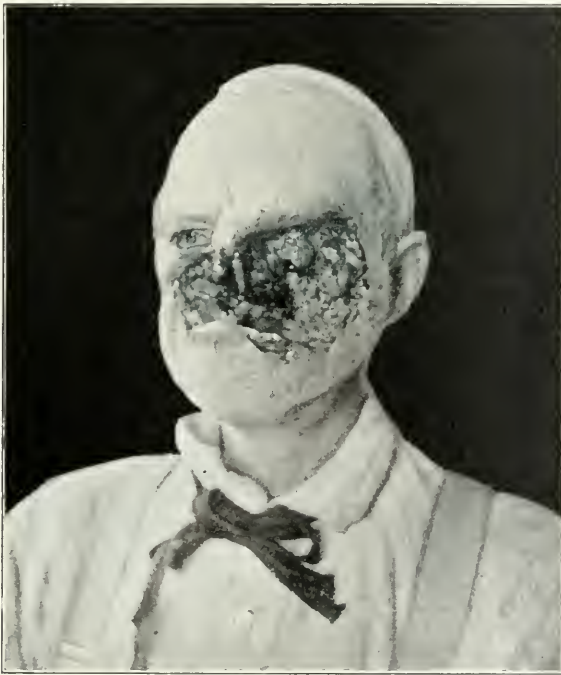

FIG. 174.—Rodent ulcer beginning in the left lower eyelid. (From a patient in Charity Hospital, Cleveland, Ohio, under the care of Dr. Dudley P. Allen.)

growth is often exceedingly slow. As time goes on it gradually develops into a flat ulcer, with indurated, ragged, and elevated edges, attended with only a slight secretion. Eventually it may involve the lids, eyeball, and adjacent structures (Fig. 174). Rodent ulcer may be mistaken for a syphilitic ulcer, but generally the age of the patient, the slow growth of the tumor, and the therapeutic test with iodid of potassium, which rapidly relieves a syphilitic ulcer, suffices to differentiate the epithelial growth from the latter affection. It is distinguished from lupus, because this disease occurs usually in young subjects, because of the greater inflammatory action of lupus, and because other portions of the body are at the same time similarly affected.

**Pathology.**—Ordinary epithelioma of the eyelid presents no differences from epithelioma of the skin elsewhere. From the greatly thickened epidermis irregular outgrowths penetrate into the subepithelial structures. Epithelial



cell-nests may also lie in this layer, together with "epithelial pearls." The surrounding tissue is usually very vascular and infiltrated with round and epithelial cells. The growth may originate from the epidermis or from the epithelial lining of the sebaceous or sweat-glands; rarely from Meibomian glands. At times it appears as a raised ulcer with infiltrated edges. The growth may be very slow, and cicatrization take place in the center as the ulceration progresses at the edges. If the ulcerative process is an elaborate one and extends into the deeper as well as surrounding tissues, a "rodent ulcer" results. The stroma of these epitheliomata is always more or less infiltrated with round-cells and presents the appearance of granulation-tissue.

Rare forms of cancer of the lid-structures having their point of origin in the Meibomian or in Krause's glands may be denominated *glandular carcinomata*, in contradistinction to the ordinary *epitheliomata* and *rodent ulcers*.

**Treatment.**—Radical measures alone give any promise of permanent relief in carcinomata. An early operation for their removal should be performed and the exposed surface covered with suitable skin-flaps. In the later stages palliative measures to aid in limiting the rapidity of the growth may be used. To further this end caustic, chloracetic acid, scraping with a curette, or the actual cautery may be employed. As milder measures aristol, chlorate of potassium, and injections of pyoktanin have been recommended. Not infrequently in the advanced cases it may be necessary to remove the eyeball, together with the orbital and periorbital tissues.

**Lupus Vulgaris.**—Associated with lupus of the face or nose the eyelids may become the seat of this affection. The ulcers are formed by several points of infection coalescing and producing ragged, soft edges, which exude an offensive secretion. The disease frequently inflicts much damage to the lid-tissue, eventuating in marked cicatricial contraction and deformity. The history of the case, together with the fact that the face and nose are involved in the same disease, will serve to distinguish lupus from the *syphilitic ulcer*, for which it is likely to be mistaken.

**Treatment.**—Cauterization by means of caustic paste or the actual cautery gives the best results in the early stage of the disease. The ulcers may also be curetted. When the ulcers are large excision may be practised, with the proper plastic operation for covering the denuded surface of the eyelids.

**Lepra.**—Leprosy of the eyelids is very frequent in countries where the general disease is prevalent. Tubercular growths form in the region of the brows and cilia, producing loss of the lashes and eyebrows. Anesthetic patches of a color slightly different from the surrounding skin, with entropion and ectropion, are frequently developed.

**Elephantiasis Arabum** is characterized by a chronic hypertrophy of the skin and subcutaneous tissue. The lids reach enormous proportions, and from their mere weight prevent the patient from opening the eyes. The upper lids are the ones usually affected. Elephantiasis occurs congenitally or may result from an injury. According as the hypertrophy affects the lymphatics or the blood-vessels the names of *elephantiasis lymphangiectodes* and *elephantiasis telangiectodes* have been assigned. Removal of the excessive growth of tissue sufficient to enable the patient to open the eyes offers the most hope of relief.

**Tarsitis** is usually a chronic inflammation of the tarsus characterized by thickening of this body. *Acute tarsitis*, with sloughing of the tissues, has been described. There is often found associated with conjunctivitis and blepharitis a thickening of the tarsus, especially in scrofulous subjects. *Syphilitic tarsitis* is the most frequent variety of the disease, and in this

affection the thickening of the lids is often very marked, giving rise to much deformity. It usually occurs in the third stage of syphilis, and assumes the gummatous type of the disease; more rarely an *acute* form appears.

The **symptoms** of tarsitis are gradual thickening of the lid, without marked inflammatory disturbance, and the consequent inconvenience to the patient of the bulk of the eyelid, which may droop over the globe. If the lower lid is the seat of the disease, the weight of the lid sometimes pulls it away from the eyeball, producing an ectropion. In severe cases an atrophy of the tarsus may ensue after the subsidence of the inflammation (Fig. 175).

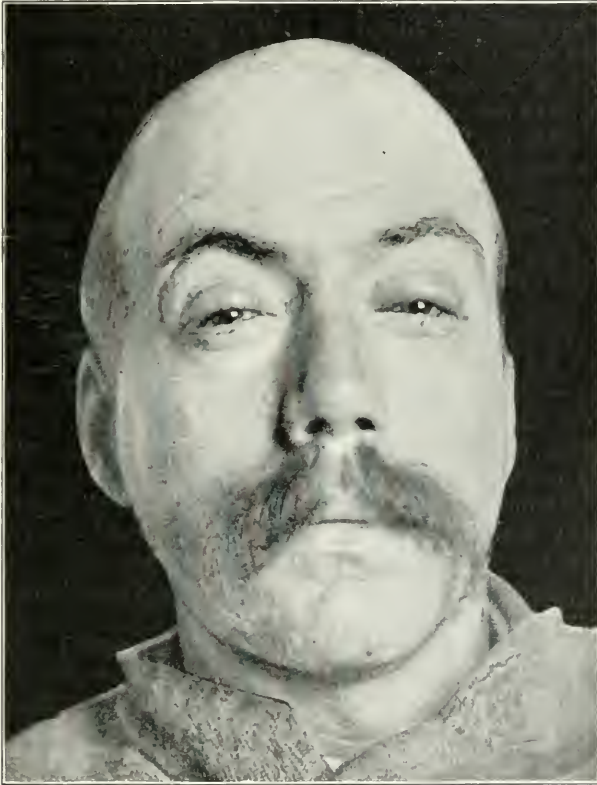


FIG. 175.—Syphilitic tarsitis. (From a patient under the care of Dr. de Schweinitz in the Philadelphia Hospital.)

**Treatment.**—The remedies appropriate to blepharitis should be used locally, and any constitutional disturbance corrected by proper means. In tarsitis syphilitica treatment suitable for the specific disease should be instituted. Recovery is slow, but generally perfect.

**Blepharospasm** is characterized by a cramp-like contraction of some or of all of the fibers of the orbicularis muscle.

A frequent condition in many persons is the contraction of a few fibers of the orbicularis muscle in either the upper or lower lid, which is very annoying. The twitching of the muscle may readily be seen by an observer. This condition is usually indicative of some local irritation of the eyes or the lids, and is of no great import.

A more serious and uncomfortable phase of the difficulty is cramp of the entire muscle, when the eyelids close tightly and violently. There are two

varieties of blepharospasm—the *clonic* and the *tonic* spasms. In the former the spasm is of momentary duration, and consists of a series of forcible uncontrollable “blinkings;” in the latter there is a violent closure of the lids, which remain tightly shut for some minutes or for days or months, and the patient is rendered practically blind by the inability to use the eyes. Blindness has occasionally resulted, manifest when the patient has become able to open the eyes, either with or without grave ophthalmoscopic changes.

Blepharospasm may be either a symptomatic condition or an essential disease. Children especially are prone to have slight more or less frequent “blinking” attacks or nictitation, especially when using their eyes in school-work. They are generally found to have slight conjunctivitis or an asthenopic condition due to refractive error. Not infrequently associated with this is a choreic or spasmodic affection of the facial muscles. Blepharospasm is essentially due to reflex irritation of the fibers of the trigeminus, and hence occurs in follicular conjunctivitis, with foreign bodies in the eye (when the spasms may be tonic), with blepharitis, refractive errors, and muscular insufficiencies. Depending upon the cause, the attacks are monocular or binocular, the latter form prevailing in all severe cases, the attacks being usually more severe on one side. In hysterical subjects the attacks come on without any known cause, the eyes close tightly, the spasm is persistent, and the patient is rendered helpless. In adults as well as in children the facial muscles may twitch as actively as the orbicularis. In elderly people the spasm is often associated with tie or with chronic conjunctivitis.

**Treatment.**—The treatment of blepharospasm depends upon the cause. In case of local irritation removal of the foreign body, relief of conjunctivitis, blepharitis, or other local inflammation, correction of refractive errors, and gymnastic exercise for insufficiency of the eye-muscles are the essential points to be considered. The general health should be looked into, and tonics, especially iron, quinin, and strychnin, should be exhibited, care being taken that the latter does not aggravate the trouble. Antispasmodics, as conium and gelsemium, pushed to their physiological tolerance, may be of benefit.

In many cases medication seems to have no beneficial effect. In some patients pressure on certain points seems to relieve temporarily the difficulty. The patient discovers these and learns to control, in a measure, the orbicularis spasm by pressing upon the point. This point may be situated on the forehead or in some other portion of the head. In such cases galvanism, or, in very bad cases, hypodermic injections of morphin in these regions, may be tried. Complete rest from work, with change of climate, sea-bathing, or mountain-climbing, have sometimes proved efficacious when other means have failed.

**Ptosis** (*blepharoptosis*, *blepharoplegia*) is a term properly applied to a drooping of the eyelid due to paralysis of the levator palpebrarum muscle. In addition to true ptosis there is a more or less marked degree of drooping of the lid due to its increased weight or bulk, which prevents the levator from sufficiently raising the lid to expose the eyeball. This often is the case in tarsitis, hypertrophic blepharitis, granular conjunctivitis, and tumors of various sorts occurring in the substance of the lid. But ptosis proper is due either to paralysis of the oculo-motor nerve or to a fault in the development of the levator muscle itself.

The affection may be a *congenital* or an *acquired* one. In the congenital cases the ptosis may be associated with other congenital malformations of the lids, eye, or orbit. In some cases of unilateral congenital ptosis, usually on



the left side, while the eyelid cannot be raised voluntarily, it is raised when the jaw is moved during eating, or there is contraction of the levator in association with the external pterygoid. Not infrequently ptosis is the result of injury to the muscle-fibers or to the supraorbital branch of the oculo-motor (Fig. 176). Paralysis of the eye-muscles is frequently associated with ptosis, and it may be found in certain cases of hemiplegia or from lesion of the cortical center. In bilateral ptosis the peculiar pose of the head, which is thrown back to enable the patient to look under the drooping lids, is strikingly characteristic.

**Treatment.**—The cause must determine the proper procedure. Medicinal measures must be instituted if the palsies are of syphilitic, rheumatic, or of



FIG. 176.—Traumatic ptosis with cystic tumor of orbit. (Western Reserve University, Medical Department.)

other origin which is amenable to medicinal agents. The surgical treatment is described elsewhere (see page 557).

**Lagophthalmos** manifests itself by an inability of the eyelids to close, the degree of this immobility varying as the cause is a *paralytic* or a *non-paralytic* one. The non-paralytic causes are—shortening of the eyelids, which may be congenital or due to loss of tissue of the lids from burns, ulceration, gangrene, etc.; ectropion; loss of reflex sensibility in the eyeball and protrusion of the globes, so that the lids are unable to cover them, as in exophthalmic goiter, orbital tumors, etc.

The most marked cases are caused by paralysis of the orbicularis muscle, usually associated with facial paralysis. The distressing symptoms of lagophthalmos arise in connection with the cornea, which is exposed to external irritations and suffers the loss of the lubricating and protecting action of the lids. The exposed portions of the cornea and conjunctiva become chronically inflamed, and ulceration and even blindness may be the result.

**Treatment** should have in view, primarily, the protection of the eyeball from external irritation. Patients are likely to suffer most while asleep from inability to close the lids by voluntary action. Hence in bad cases the lids



should be closed with adhesive plaster, a compress and bandage, or by other suitable means. Relief should be directed to the cause of the affection in the paralytic variety, and the operation of tarsorrhaphy (page 547) may be required.

**Symblepharon** is an abnormal adhesion of the eyelid to the eyeball. It may be congenital, but is usually the result of injuries, especially burns from acids, lime, or hot metal (Fig. 177). It occurs always when the conjunctival structure is destroyed in its sulcus and when the palpebral and bulbar conjunctivæ are cauterized in approximate positions. It also results from purulent and granular conjunctivitis, pemphigus, etc. Not infrequently the lid-margins become strongly adherent to the cornea by cicatricial bands or the entire body of the lid may be adherent (Fig. 178).




FIG. 177.—Symblepharon due to burn—hot metal. (From a patient in Western Reserve University, Medical Department.)

**Ankyloblepharon** has the same causes as symblepharon, and likewise may be *congenital* or *acquired*. It consists of a union between the margins of the upper and lower lids, and may be *partial* or *complete*. In the acquired variety burns are the most common cause.

**Blepharophimosi**s is an agglutination of the eyelids at the outer angle of the eye, caused usually by chronic conjunctivitis or ulceration at the commissure. The adhesions cause shortening of the palpebral opening.

**Treatment.**—These conditions, generally due to a similar cause, require like treatment. In case of injury, burns, etc. care should be exercised to keep the lids well separated from each other as well as from the eyeball. In case of extensive burns of both the bulbar and palpebral conjunctivæ no method will prevent the lid and the eyeball from becoming adherent, with the formation of a more or less complete symblepharon. When the deformity has occurred suitable surgical measures should be employed for its correction (see page 548).

**Trichiasis** is a term used to describe that condition of the lids where the eyelashes are turned backward so as to rub against the eyeball. A single cilium or the entire row of lashes may be inverted.

The most frequent cause of trichiasis is trachoma. The entire conjunctival surface being, as a rule, involved in chronic trachoma, the resulting cicatricial contraction affects the entire border of the lid and occasionally develops more or less complete trichiasis. The more localized affection is likely to be due to burns, blepharitis, injuries, operations, etc. The result of the lashes turning in is marked irritation of the cornea, which often results in ulcers; thickening of the epithelial covering, somewhat simulating pannus; constant lachrymation; and, in long-continued cases, permanent impairment of vision.

**Distichiasis** is a term applied to that affection where there are double

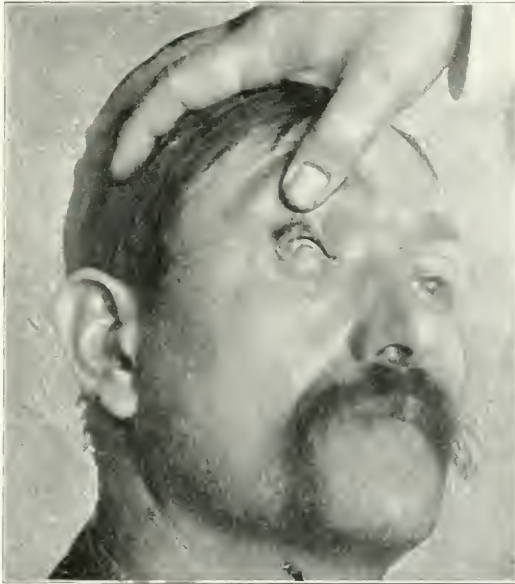

FIG. 178.—Complete symblepharon due to burn. (From a case in Western Reserve University, Medical Department.)

rows of lashes, one row being directed properly, while the other is turned backward against the eyeball. Some authors consider distichiasis simply one step in the development of trichiasis and assign the term to the congenital affection alone. The causes of the two affections are the same.

**Treatment.**—Should a single lash or a small number of lashes turn in, temporary relief is afforded by *epilation* of the cilia which are at fault. The lashes grow again, however, and this operation must be frequently repeated. Patients can often remove the lashes themselves with a pair of cilium forceps. For permanent relief *electrolysis* or some other operative procedure must be employed (see page 545).

**Entropion** is a turning inward against the eyeball of the external lid-margin. Not only the lashes but the skin of the palpebral margin is rolled back against the eye. Two varieties of this affection have been described, the *spasmodic* and the *organic*. The former results from the over-action of the orbicularis muscle due to the reflex irritation of conjunctivitis, keratitis, etc. In elderly people it not infrequently results from operations when the eye has been kept bandaged too long. The organic type results from chronic

trachoma, diphtheritic conjunctivitis, burns, injuries, etc., which lead to cicatricial contraction of the conjunctiva. The effect upon the cornea may be serious on account of the production of ulcers, opacities, etc.

**Treatment.**—Spasmodic entropion is generally relieved by the disappearance of the conjunctivitis, keratitis, or foreign substance which has caused it. Early removal of the bandage is necessary when the entropion occurs after cataract operations. Strips of adhesive plaster applied to the lid-margin by one extremity and by the other to the cheek, or collodion painted over the lid, or strips of gauze fixed with collodion applied in the same manner as the adhesive strips, serve a most useful purpose in case of spasmodic entropion. The *serre-fine* has been used with advantage by fixing a fold of the skin, thus pulling the lid-margin away from the eyeball. The chronic types of entropion require careful surgical treatment. The operations are described on page 548.

**Ectropion** is a rolling outward of the eyelids, so that the conjunctival portion is exposed to view. This eversion may be *partial* or *complete*. It




FIG. 179.—Case of ectropion. (From a patient in the Charity Hospital.)

may also be *spasmodic* or *muscular* and *chronic* or *organic*. In the former case it is due to the over-action of the peripheral fibers of the orbicularis muscle. The lower lid sometimes shows a tendency to droop, particularly in elderly people and in persons affected with facial palsy. The tears thus run over the cheeks and occasion additional irritation.

The causes of organic ectropion are those which produce a cicatricial shortening in the length of the eyelids, as chronic blepharitis, lupus, necrosis of the orbit or malar bone, abscesses, burns, and injuries (Fig. 179). The eye being more or less exposed, the cornea suffers from external irritants.

**Treatment.**—Not infrequently the excessive lachrymation which occurs in ectropion may be cured by slitting up the canaliculus and passing probes through the naso-lachrymal duct. Associated inflammation of the cornea and conjunctiva should receive attention. The severer chronic forms of the affection require operative measures for their relief (see page 551).

**Seborrhea** is characterized by a secretion on the margin of the lids either of an oily fluid or of a sebaceous material, which dries, forming crusts or scales along the cilia. Generally, seborrhea of the face, scalp, or other portions of the body is an accompanying affection. It not infrequently occurs in young persons about the age of puberty. Conjunctivitis and marginal blepharitis are frequent concomitants.

**Treatment** must be directed to the improvement of the general health. Removal of the crusts and the application of mercurial or sulphur ointments, together with measures suited to conjunctivitis and blepharitis, are required.

**Milium.**—Milia are accumulations of sebum in closed sebaceous glands. These growths are about the size of a milletseed, from which they take their name. They present a yellowish-white appearance, and are slightly elevated above the surrounding skin, giving the feeling of a pinhead under the finger. They usually indicate improper care of the skin, and occur in persons with some disturbance of digestion, constipation, etc.

**Treatment.**—Hot applications, frequently repeated, together with suitable remedies for indigestion or constipation, will prove beneficial. After removal of the milium with a knife-point or needle, hot packs and mild ointments, well rubbed in, will afford relief.

**Molluscum contagiosum** (*molluscum sebaceum*) occurs in the lids in the form of small rounded tumors which originate from the sebaceous glands. They attain the size of a pea, have an umbilicated appearance due to the orifice of the gland on the summit of the growth, and have a wax-like color. The material from the growths is contagious. The disease not infrequently occurs among children in asylums and schools in the nature of an epidemic. The contagious nature of the disease is supposed to be due to a parasite, and the affection is allied in character to *contagious epitheliomata*. The parasite is believed by some authors to belong to the class *Coccidia*, and to inhabit the epithelial cells and cause the formation of these small prominent epithelial growths. The coccidia multiply in the cells of the epithelial projections; these are then cast off and accumulate as a mass of epithelial detritus. According to H. Muetze, the molluscum corpuscles are the product of a degeneration of the epithelial cells caused by the contagium, the nature of which is uncertain; but the corpuscles themselves are not parasites.

**Treatment** consists of opening each molluscum and scraping out its contents. Cauterizing the sac with nitrate of silver may also be employed.

**Ephidrosis** (*hyperidrosis*) is a rare affection of the lids characterized by profuse secretion from the sweat-glands. It is associated with excessive sweating of other portions of the face or body, and has been noticed in cases of unilateral facial sweating. Its cause is not understood. It may produce excoriations, especially at the angles of the eyes and in the skin-folds.

**Treatment** must be directed to the excoriations of the skin and to the cause if it can be discovered.

**Chromidrosis** (sometimes called *seborrhea nigricans*<sup>1</sup>) is the formation of various colored secretions on the eyelids, the oily-like fluid giving a bluish or blackish color to the affected skin. It usually occurs on the lower lid. The discoloration can readily be removed by wiping. Some authors believe that it is always an evidence of malingering, as it most frequently occurs in hysterical patients, particularly young women. In rare instances it is genuine. It may be caused by a deposit of dust upon a cutaneous surface affected with seborrhea.

**Treatment** should be directed toward the relief of any general disturbance of the health. The discoloration may be removed with some oily substance; lead-water and glycerin have been recommended.

**Sebaceous cysts** are small rounded bodies of the size of a pea or of a hazelnut which occur in the thicker portions of the skin of the eyelids, especially in the superior or external orbital portion of the lid (Fig. 180). They develop from the sebaceous follicles of the skin, and contain a sebaceous, oily-like material, and frequently fine hairs. They have well-formed

<sup>1</sup> For a full account of this affection see a paper by Dr. J. K. Mitchell in the *Philad. Med. Journ.*, 1898, i. 117-119.



cyst-walls, which enables the surgeon to dissect them out without great difficulty, this being the proper method of treatment.



FIG. 180.—Sebaceous tumor of the eyelid. (From a patient in the Western Reserve University, Medical Department.)

**Dermoid cysts** likewise occur in the same region and should be removed in like manner.

**Cysticercus** has been observed a few times under the skin of the eyelids, having the appearance of a sebaceous cyst, only the contents are fluid. On opening the tumor the remains of the parasite are discovered.

#### THE EYEBROWS.

The eyebrows may be the seat of *eczema* or of *seborrhea*, and are a favorite situation for the development of *sebaceous* and *dermoid* cysts. Occasionally these growths extend some distance into the orbit, where by pressure they may produce a depression in the underlying bone.

# DISEASES OF THE LACHRYMAL APPARATUS.

BY SAMUEL THEOBALD, M. D.,

OF BALTIMORE.

IN treating of diseases of the lachrymal apparatus it is convenient to consider, first, those affections which have to do with the *lachrymal gland* and its *ducts*, and, second, those of the *drainage apparatus*, including the puncta, the canaliculi, the lachrymal sac, and the nasal duct. The lachrymal gland, probably owing to its protected position and its multiple ducts, is, comparatively speaking, rarely the seat of disease, while, on the other hand, disease of the drainage apparatus, doubtless because of its intimate anatomical and pathological relationship to the nasal passages, is of very frequent occurrence.

## DISEASES OF THE LACHRYMAL GLAND.

**Dacryoadenitis**, or inflammation of the lachrymal gland, occurs as an *acute* and as a *chronic* affection. Both varieties are rare, though it seems not improbable that acute inflammation of the gland is sometimes mistaken for cellulitis of the orbit, from which it is not always easy to differentiate it.

**Etiology.**—It occurs more frequently in children than in adults, and oftener in women than in men. It has been known to assume an epidemic character, and Galezowski reports having met with an unusual number of cases during an epidemic of mumps. Other causes to which it has been ascribed are traumatism, "cold," rheumatism, gout, struma, syphilis, septic absorption, and the extension of inflammation from the conjunctiva and cornea. It is usually unilateral, but not infrequently both glands are involved.

**Symptoms.**—*Acute dacryoadenitis* gives rise to severe pain, which may be accompanied by elevation of temperature, cerebral excitement, sleeplessness, and delirium. The lids, especially the upper lid, are greatly swollen, and there is marked chemosis of the conjunctiva. The eyeball may be displaced and its movements restricted and rendered painful through the enlargement of the gland. Palpation of the exquisitely sensitive gland is difficult because of the edema of the lids, and eversion of the lid, to permit of its inspection, is out of the question. The general appearance of the eye is not unlike that which characterizes purulent conjunctivitis (S. C. Ayres). Suppuration may supervene within a few days, the pus making its way through the integument of the lid or into the conjunctival cul-de-sac, or the inflammation may subside without the formation of pus.

In *chronic dacryoadenitis* the characteristic enlargement of the gland may be recognized by palpation, and sometimes by simple inspection. By everting the upper lid the swollen gland may be brought into view as a red, tongue-shaped, nodular mass (Hirschberg). The gland is usually sensitive to pressure, but the pain, swelling of the lids, and conjunctival chemosis are much less pronounced than in the acute variety of the disease. As in the latter, there may be marked displacement of the eyeball, usually downward and inward,

and this may give rise to diplopia. In rare instances non-suppurative dacryoadenitis (*mumps of the lachrymal gland*, Hirschberg) is bilateral.

**Treatment.**—The treatment of acute dacryoadenitis, if the case is seen at the outset of the attack, should consist in leeching, the application to the lid and brow of an ointment of mercury with opium or belladonna (ext. opii vel ext. belladonnæ ʒj; ung. hydrarg. ʒj), and the administration of an energetic mercurial purgative, to be followed by liberal doses of quinin, sodium salicylate, or sodium pyrophosphate (the last-named drug in twenty-grain doses every two hours); or, instead, small and frequently repeated doses of calomel may be administered. Should these measures fail to cut short the attack, warm fomentations, containing opium or belladonna, should be employed, and as soon as the presence of pus can be detected it should be evacuated by an incision either through the integument of the lid or through the conjunctival cul-de-sac as may seem to be indicated.

In chronic inflammation of the gland the local application of mercurial or compound iodine ointment, and the administration of alteratives and tonics, are indicated. Extirpation of the gland (see page 596) may be necessary should it become so enlarged as to endanger the integrity of the eyeball.

**Fistula of the Lachrymal Gland.**—This troublesome variety of lachrymal fistula may be a consequence of dacryoadenitis or may be of traumatic origin. Cases of *congenital fistula* of the lachrymal gland have also been observed.

The fistulous opening is usually at some point in the upper lid, and the constant flow of tears, which prevents its closure, gives rise to much annoyance.

It is not easy to bring about a healing of the fistula, and if this is accomplished, it is at the risk of precipitating a fresh attack of inflammation of the gland. The operative procedure which has proved most effectual is that proposed by Sir William Bowman (see page 596).

**Dacryops**, or *cyst of the lachrymal gland*, is a rare condition due to occlusion of one or more of the efferent ducts of the gland. It has also been met with as a congenital affection.

Upon eversion of the upper lid the cyst may be brought into view as a semi-transparent, elastic swelling, consisting, perhaps, of several nodules. During a spell of crying the cyst may become markedly increased in size.

**Treatment.**—This consists in establishing a permanent opening between the cyst and the conjunctival sac. This may be done by removing a portion of the cyst-wall and preventing the closure of the wound by the repeated introduction of a probe, or, as suggested by von Graefe, a silk thread may be passed through the wall of the cyst, tied in a loop, and left to cut its way out.<sup>1</sup>

**Dacryoliths** (*Lachrymal Calculi*).—Chalky concretions, known as *dacryoliths*, occasionally form in the lachrymal gland. As they are apt to cause mechanical irritation, their early removal (through a conjunctival incision) is indicated.

**Dislocation of the Lachrymal Gland.**—This affection, sometimes described as *hernia* or *prolapse of the gland*, has been met with as a spontaneous condition, and also as a consequence of injury involving the neighboring parts.

Cases of *spontaneous dislocation* of the gland have been reported by Snell, Noyes, Mauthner, and Brière. In Brière's case the luxation of the gland

<sup>1</sup>An interesting paper upon fistula and cysts of the lachrymal gland, by Mr. Hulke, may be found in the *Royal London Ophthalm. Hosp. Reps.*, vol. i. p. 285.

was due to caries of the orbit, and was accompanied by ectropion of the upper lid.

Von Graefe and Rampoldi have reported cases of *traumatic dislocation* of the gland.

If possible the gland should be restored to its normal position, as was done successfully in von Graefe's and in Snell's cases, and a compress bandage should be applied and worn for a time to prevent a redislocation. If this cannot be accomplished, removal of the gland may become necessary (see page 596).

**Hypertrophy of the Lachrymal Gland.**—This condition occurs more frequently in children than in adults, and has been known to be of congenital origin. The enlargement of the gland may become so great as to force the eyeball from the orbit, and destroy the sight through stretching and compression of the optic nerve.

The accompanying illustration (Fig. 181) represents a striking example of a case of this character which occurred in the practice of the late Prof. Christopher Johnston of Baltimore. The hypertrophied gland, which was about the size of a hen's egg and contained numerous *dacryoliths*, was removed through an incision made parallel with the orbital margin. The eye subsequently resumed nearly its normal position, and retained vision equal at least to counting fingers.

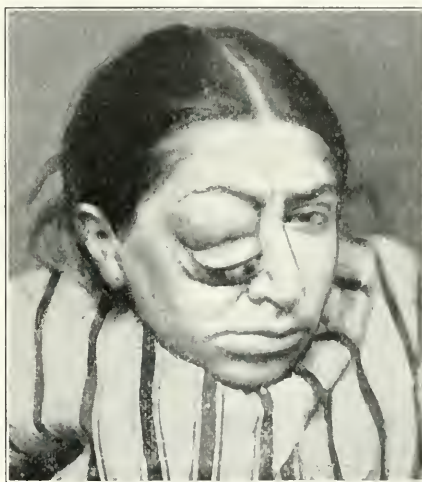

FIG. 181.—Hypertrophy of the lachrymal gland.

If the enlargement of the gland is so great as to endanger the integrity of the eye, it should be removed without unnecessary delay (see page 596); but if it is not so great as to interfere with vision, less radical measures, such as the local application of iodine or mercury and the administration of the iodides, may be tried. The fact that the hypertrophic process may be of syphilitic origin (*syphilis of the lachrymal gland*) should not be lost sight of in considering the treatment to be adopted.

**Atrophy of the Lachrymal Gland.**—This has been observed in xerophthalmia (see page 296). Arlt has described a case of this character in which the gland was reduced to one-third its normal size and its efferent ducts obliterated. In paralysis of the trigeminus the functional activity of the lachrymal gland may be abolished.

**Tumors of the Lachrymal Gland.**—These are rare, and, not infrequently, are traceable to some previously received injury. They are usually of slow growth and occur oftenest in advanced life. As they increase in size they interfere with the movements of the eyeball, giving rise to diplopia. Later they produce exophthalmos, and eventually may not only destroy sight by the pressure which they exert upon the optic nerve—but which they rarely invade—but may cause death by the involvement of the brain.

The following varieties of tumors believed to have had their origin in the lachrymal gland have been observed: adenoma, myxoma, myxo-sarcoma,



lympho-sarcoma, spindle-cell sarcoma, epithelioma, cylindroma, chloroma, and carcinoma.

Early and complete removal of the growth is of course indicated. Whether this can be accomplished successfully without sacrifice of the eye will depend upon the size of the tumor and the extent to which it has invaded the deeper portions of the orbit. (See page 596 for description of operation for removal of lachrymal gland.)

#### DISEASES OF THE DRAINAGE APPARATUS.

All parts of the drainage apparatus are liable to pathological changes, and, whether these changes affect the puncta, the canaliculi, the lachrymal sac, or the nasal duct, a common symptom characterizes them all: the tears are no longer carried from the conjunctival sac to the nasal cavity, as in the normal state, but, instead, overflow the lids, giving rise to the annoying condition known as *epiphora* or *stillitidium lacrymarum*. Not only is this condition, in itself, very annoying, but it leads to chronic conjunctivitis, blepharitis, and not infrequently to eczema of the lids and cheek.

**Atresia of the Lachrymal Puncta.**—This condition is met with as a *congenital* and as an *acquired* anomaly.

*Congenital atresia* of the puncta, of which not many authentic cases have been reported, may be attended by absence of the corresponding canaliculi. The writer has encountered one case of this character, in which, however, only one punctum with its canaliculus was absent.

Complete obliteration of the puncta as an *acquired* condition seldom occurs, except as the result of destruction of neighboring tissue, such as happens, for example, from burns of the eye by lime, etc. It has also been known to follow the cicatrization of a small-pox pustule and of a chancre of the lid.

A superficial occlusion of the lower punctum, which is easily overcome, and which is chiefly due to desiccation of the parts, is often observed in blepharitis marginalis complicated by ectropion.

**Treatment.**—Whether the occlusion be congenital or acquired, it is, as a rule, overcome without much difficulty, provided the canaliculus is not involved. A slight depression usually indicates the site of the occluded punctum, and with a straight, moderately sharp-pointed probe, such as is represented in Fig. 182, an opening may be drilled into the canaliculus at this point and



FIG. 182.—Sharp-pointed lachrymal probe.

kept from reclosing by the occasional introduction of a somewhat larger probe. If, however, the canaliculus as well as the punctum be occluded, or if the latter be everted, the canaliculus will require to be slit up to its point of juncture with the lachrymal sac. (For description of this operation see page 596.)

As *congenital* anomalies *double puncta* and *double canaliculi* have been observed, and in connection with absence of the puncta the canaliculi have been represented by slight furrows along the lid-margin.

**Malpositions of the Puncta.**—In their normal position the puncta lie in contact with the eyeball. Malpositions of the upper puncta are not common, but faulty positions of the lower puncta are frequently met with.

*Eversion* of the puncta is present in nearly all cases of ectropion; it also occurs in inflammatory thickening of the lid-margin, in senile relaxation of the palpebral tissue, and in facial paralysis.

*Inversion* of the puncta is met with in entropion. Occasionally, owing to the small size or deeply-set position of the eyeball, the puncta are not in apposition with it, and epiphora results, as it does when the puncta are everted, through failure of the tears to find their way into the canaliculi.

**Treatment.**—The efficient remedy in all malpositions of the puncta is division of the canaliculus. It not only relieves the epiphora, but usually leads to the rapid disappearance of the conjunctivitis and blepharitis which are its common accompaniments.

**Atresia of the Canaliculi** may occur as a *congenital* defect in connection with absence of the puncta, as has already been mentioned; it may also be of *traumatic* origin.

Circumscribed strictures of the canaliculi, located usually near the juncture of the canaliculi and the lachrymal sac, are of frequent occurrence, especially in association with stenosis of the nasal duct.

When the canaliculi are completely obliterated their restoration by operative procedure is impracticable; but it may be possible to make a passage-way directly into the lachrymal sac, and by repeated probings cause it to remain patulous, as was done in the case to which allusion has been made under the head of Atresia of the Puncta. The circumscribed strictures may usually be overcome by the passage of a small lachrymal probe or of the straight probe shown in Fig. 182. Division of the canaliculus may be called for if the stricture is difficult to overcome or is disposed to recur.

*Dacryoliths* occasionally form in the canaliculi. They were formerly supposed to be simply concretions of lime, but are now known to be composed in great part of a fungus believed by some investigators to be identical with the *leptothrix buccalis*. Cohn, however, denies this, and suggests the name *streptothrix Försteri*. Goldzieher has met with cases in which a cilium occupied the center of the dacryolith, and was probably the exciting cause of its development. The presence of dacryoliths in the canaliculus, which may be detected by the circumscribed swelling to which they give rise, causes epiphora and may excite conjunctivitis. Their early removal, which may necessitate division of the canaliculus, is indicated.

*Polypi* have been known to form in the canaliculi, and may project through the puncta. They should be removed, the canaliculus, if necessary, being divided, as soon as their presence is recognized.

*Foreign bodies*, such as eyelashes, bits of the beard of wheat and barley, occasionally find their way into the canaliculi, where they may remain for a long time, causing considerable annoyance. If they project through the puncta, they may be seized with forceps and easily withdrawn; otherwise division of the canaliculus may be necessary to effect their removal. In one instance (reported by Haffner) an *ascaris lumbricoides* was removed from the lower canaliculus.

**Dacryocystitis.**—Inflammation of the lachrymal sac, or dacryocystitis, occurs as a *chronic* and as an *acute* affection. The former is usually denominated *blepharitis of the lachrymal sac*, while the latter is often spoken of as *abscess of the sac*.

**Etiology and Symptoms.**—Primary inflammation of the lachrymal sac is of rare occurrence. It is oftenest met with in the new-born, usually in the form of a mild blepharitis; it is said to occur in strumous children, and it may be excited by external violence or the entrance into the sac of an irritant

fluid. In the large majority of cases dacryocystitis is secondary to, and dependent upon, stricture of the nasal duct.

Although inflammation of the lachrymal sac frequently gives rise to conjunctivitis and keratitis, the reverse rarely happens. The truth of this statement is strikingly illustrated in gonorrhœal conjunctivitis. Although the gonococci doubtless find their way in great numbers into the lachrymal sac, dacryocystitis as a complication of gonorrhœal conjunctivitis is, so far as the writer can learn, practically unknown.

On the other hand, there is the closest pathological sympathy between the lachrymal sac and duct and the nasal passages, and doubtless in a majority of cases dacryocystitis is traceable, directly or indirectly, to nasal disease. Such being the case, it is not surprising, when one bears in mind how almost universally prevalent catarrhal affections of the nasal mucous membrane are, that inflammation of the lachrymal sac and nasal duct should be of comparatively frequent occurrence.

Watering of the eyes is a usual symptom of acute rhinitis, and probably in most pronounced cases of this affection the mucous membrane lining the lachrymal drainage apparatus participates to a greater or less extent in the general nasal catarrh. With the subsidence of the rhinitis the lachrymal catarrh and the transient occlusion of the nasal duct which has probably accompanied it usually disappear, and the parts return to a healthy condition.

Exceptionally, however, because of the severity of the inflammation, the occurrence of a second or third attack before the first has been recovered from, a congenital narrowness of the nasal duct, or a peculiar susceptibility of the lachrymal passages to disease (a susceptibility which is not infrequently inherited), the inflammation of the walls of the duct does not subside with the nasal affection, and presently assumes a more serious character.

Under such circumstances the inflammation, which at first was simply a catarrh of the mucous membrane, invades the underlying periosteum, and the temporary occlusion of the duct from engorgement of the submucous plexus of veins gives place in time to a permanent stenosis from periosteal and osteal thickening. In this way—and, perhaps, still more frequently from the extension of *chronic* inflammatory affections of the nose to the lachrymal passages—*stricture of the nasal duct*, which, as has been said, is the usual forerunner of dacryocystitis, commonly arises.

The chronic nasal affections of inherited and acquired syphilis, it may be remarked, are especially liable to involve the lachrymal apparatus. Blows upon the bridge of the nose or about the inner angle of the eye may not only cause inflammation of the lachrymal sac, as has been indicated, but may lead to the development of stricture of the nasal duct.

When once the occlusion of the duct is complete, the tears, mucus, and epithelial débris which collect in the lachrymal sac are invaded by bacteria and undergo putrefactive changes. This soon leads to inflammation of the lining membrane of the sac, and the condition known as *chronic dacryocystitis* or *blephorrhœa of the lachrymal sac* becomes established.

This condition does not give rise to pain, but the attendant epiphora and regurgitation of mucus and muco-pus through the puncta into the conjunctival sac not only cause great annoyance, but, as has been stated, may bring on chronic conjunctivitis and blepharitis, and even corneal inflammation.

The accumulation of tears and mucus frequently leads to a perceptible distention of the sac (*mucocœle*), which disappears under slight pressure with the tip of the finger, the contents of the sac usually regurgitating through the

puncta, but exceptionally, when the stenosis of the duct is incomplete, escaping into the nose (Fig. 183).

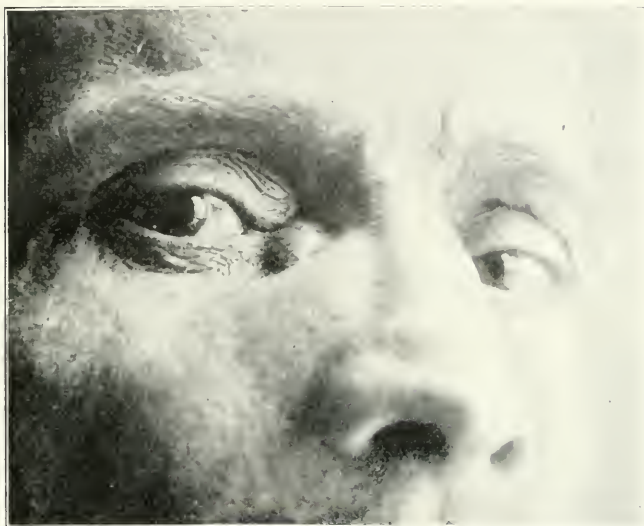

FIG. 183.—Mucocoele: fracture of superior maxilla: exostoses of nasal bones. (Case under care of Dr. de Schweinitz in the Philadelphia Hospital.)

In some instances this state of chronic catarrhal inflammation lasts indefinitely, without undergoing appreciable change; but in others, through the influence of cold, a slight traumatism, the entrance into the lachrymal sac of pyogenic organisms of unusual virulence,<sup>1</sup> some constitutional disorder or, as seems to happen not infrequently, the sudden occlusion of the canaliculi at their point of junction with the sac, the inflammation undergoes a sudden and acute aggravation.

Severe pain, accompanied by great distention of the sac and marked edema of the lids and surrounding parts, comes on, and decided evidences of constitutional disturbance, such as fever, loss of appetite, sleeplessness, etc., manifest themselves. These are the symptoms which characterize *acute dacryocystitis* or *abscess of the lachrymal sac* (Fig. 184), and which in many cases of stricture of the nasal duct recur from time to time so long as the occlusion of the duct is permitted to remain.

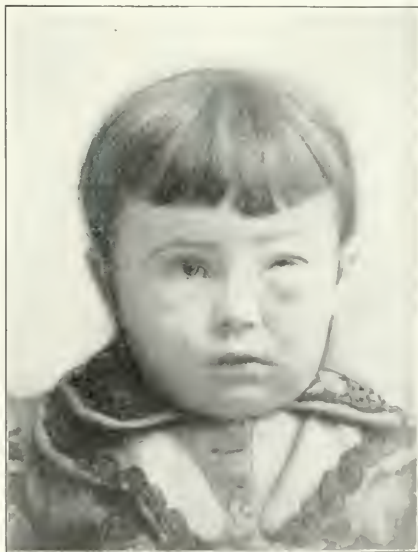

FIG. 184.—Acute dacryocystitis.

After several days of intense suffering the integument over the sac assumes a yellowish appearance, becomes thinned, and, if left to itself, usually gives way at a point just below the

<sup>1</sup> Besides the commoner pyogenic organisms, the streptococcus pyogenes has been found in dacryocystitis, especially, it is claimed, in the acute exacerbations.



internal palpebral ligament, permitting the purulent contents of the sac to escape, and affording the individual immediate and almost complete relief from his sufferings. Exceptionally, the inflammation subsides without perforation of the sac, and the pus ultimately escapes through the canaliculi and puncta.

It is a fact worthy of remark that during an attack of acute dacryocystitis it is scarcely ever possible to empty the distended sac by external pressure, although after the subsidence of the acute inflammation pressure will usually cause the contents of the sac to regurgitate through the canaliculi and puncta, as, in all probability, was the case before its onset. From this it would seem probable that when the sac is unduly distended a valve-like closure of the canaliculi at their point of juncture with the sac occurs; and it may be that this is often a potent factor in the causation of acute dacryocystitis.

After the contents of the acutely inflamed lachrymal sac have been evacuated, either spontaneously or by an incision, the inflammation rapidly subsides, and within ten days or two weeks the opening through which the discharge has occurred usually closes, and the sac resumes its previous condition of chronic blennorrhœa.

Exceptionally, however, the cicatrization of the opening is prevented by the continual discharge through it of tears and muco-pus, and the condition known as *lachrymal fistula* becomes established—to remain, perhaps, for an indefinite period.

**Treatment of Dacryocystitis.**—There is but one effectual and rational way of curing dacryocystitis, and that is by eradicating the stenosis of the nasal duct upon which, as has been stated, it almost invariably depends.

During an attack of acute inflammation of the sac, and for some days after its subsidence, operative interference with the strictured duct is out of the question, and we must, for the time being, content ourselves with the administration of anodynes and such other constitutional remedies as the condition of the patient may seem to call for, and the local application of soothing fomentations, to be followed, in all probability, by an early incision through the anterior wall of the sac, below the internal palpebral ligament. Such an incision, if made in the direction in which the skin tends to wrinkle—that is, from above and toward the nose downward and outward—does not leave a perceptible scar, and gives a freer exit to the retained pus than does an incision into the sac along the canaliculus.

A pad of gauze wet with a lotion of opium and boric acid (ext. opii, gr. x-xv, acid. borice., gr. lx, aq. destil., ℥iv), and covered with a piece of rubber “protective” to prevent evaporation, forms a cleanly and convenient substitute for a poultice, and will be found a very useful application in these cases.

In chronic blennorrhœa of the sac, if for any reason it is not practicable to treat the strictured nasal duct, a considerable measure of relief may be obtained from slitting the lower canaliculus and prescribing a collyrium, either of bichlorid of mercury (1 : 12,000) or of alum (gr. ij) and boric acid (gr. x-xv to an ounce), to be dropped into the eye two or three times a day, explicit instructions being given to empty the sac of its contents by pressure with the finger-tip before each instillation of the drops.

It is well to bear in mind that abscesses occasionally occur in the neighborhood of the lachrymal sac (*pretachrymal abscess*), which, from their appearance only, cannot always be distinguished from dacryocystitis. The history of the case, however, showing the absence of pre-existing symptoms of lachrymal disease, will usually make the diagnosis plain.

**Stricture of the Nasal Duct.**—As to the *etiology* of obstructions of

the nasal duct, little need be added to what has already been said upon this subject in treating of Dacryocystitis. How often syphilis, both inherited and acquired, is a factor in their causation, especially when it has invaded the nasal passages, has already been pointed out.<sup>1</sup> Syphilitic gummata have been met with in the lachrymal sac, as well as in the duct. Tuberculosis of the nose, through extension to the lachrymal passages, has been known to cause stenosis of the duct, and polypi of the lachrymal sac to produce a like effect. The exanthematous fevers—measles, scarlet fever, and small-pox—also may lead to occlusion of the duct through the inflammation of the nasal mucous membrane which attends them.

As to the *location of the strictures*, there is no part of the duct in which they are not frequently encountered, although their most common situation is at its upper extremity. Multiple stricture, at least in cases of long standing, is the rule.

As the strictures are the outcome of periosteal inflammation, they are almost invariably, in part at least, of bony structure. They may be circumscribed and annular in form (a thin bony septum being sometimes encountered), or ill defined and of wide extent, involving a considerable part of the length of the duct. When situated at the lower extremity of the duct their existence is not so easily recognized, and it may happen that a mistake of this kind will render the treatment of no avail.

The stenosis of the lachrymal duct which occurs in the new-born is usually of an entirely different character, being due simply to tumefaction of the membranous walls of the canal, and in consequence it generally yields readily to treatment, operative interference being only exceptionally called for. A similar condition is occasionally met with in adults, and may be suspected if the symptoms of occlusion of the duct are of but short duration.

**Prognosis and Treatment.**—The confessedly poor results which, in the main, have been obtained in the treatment of strictures of the nasal duct are, in the writer's opinion, attributable chiefly to the inadequate size of the probes which are commonly employed to overcome the stenosis. The great merit of the invaluable operation devised by Bowman of slitting the canaliculus as a preliminary step in the treatment of lachrymal strictures (see page 596) is that it permits the passage of probes sufficiently large to overcome entirely the stenosis and restore completely the normal caliber of the canal. Nevertheless, Bowman himself fell far short of appreciating this fact, as is shown by the small size of the probes which he employed,<sup>2</sup> and, owing to an unreasoning conservatism, which those who have emancipated themselves from its influence can scarcely comprehend, the same may be said, even at the present day, of the great majority of those who have followed his plan of treatment. The absurdity of attempting with a probe of 1.50 mm. diameter to restore to its normal dimensions an occluded canal which in health has an average diameter (measured in its shortest axis) of somewhat more than 4 mm.,<sup>3</sup> it would seem should be evident to all; but experience shows that such is far from being the case.

<sup>1</sup> Seventeen out of two hundred and forty cases of stricture of the nasal duct in Galezowski's clinic were found to be of syphilitic origin.

<sup>2</sup> The largest of Bowman's probes, No. 6, had a diameter of about 1.3 mm., or, according to Soelberg Wells, about  $\frac{1}{20}$  of an inch. Dr. Isaac Hays of Philadelphia, it may be remarked, had previously used a slightly larger probe than this (1.50 mm.) without dividing the canaliculus.

<sup>3</sup> See paper by the writer upon "The Use of Large Probes in the Treatment of Strictures of the Nasal Duct," *Trans. Medical and Chirurg. Faculty of Maryland*, 1877, p. 154; also measurements of the nasal duct given by Mr. Henry Power in "Lectures upon Diseases of the Lachrymal Apparatus," published in the *London Lancet*, 1886, vol. ii.

The accompanying illustration (Fig. 185), which represents graphically the results of measurements of the nasal duct made by the writer, and described in the paper to which reference has been given, is in this connection instructive :

- Bowman's No. 6 probe ; diameter = 1.50 mm.
- Theobald's No. 16 probe ; diameter = 4 mm.
- Average size of 10 adult nasal ducts, cadaver ; diameter = 4.47 + mm.
- Largest of 10 adult nasal ducts, cadaver ; diameter = 5.25 mm.
- Largest of 70 bony nasal ducts ; diameter = 7 mm.

FIG. 185.—Diameters of probes and nasal ducts.

Besides the treatment by means of probes, there are other methods of dealing with stenosis of the duct and its accompanying dacryocystitis which have their advocates. Although the *gold canula* of Wathen and Dupuytren is probably scarcely ever used at the present day, there are many who still employ *styles* of different patterns made of lead, silver, or aluminum, and others who practise division of the strictures as recommended by Stilling, to whom the credit of having originated this method of treatment is usually given. The interesting fact, however, has recently come to the writer's knowledge that as early as 1846 the late Prof. Nathan R. Smith of Baltimore dealt with lachrymal strictures in this manner, and devised a knife of peculiar pattern for this especial purpose.<sup>1</sup>

In intractable cases of dacryocystitis dependent upon occlusion of the nasal duct, which have failed to yield to less radical measures, removal of the lachrymal gland (see page 596), and also excision of the lachrymal sac (see page 597) or its destruction by means of caustics or the galvano- or thermo-cautery (see page 597), are practised by some ophthalmic surgeons, and, it is claimed, with excellent results. The writer has had no experience with these last-mentioned procedures, not having encountered cases in which such radical measures seemed to be indicated. As to the employment of styles, his experience with them has not been satisfactory, and leads him to regard them as of limited applicability, being useful only when time will not permit of the proper carrying out of the probing treatment.

Briefly described, the writer's method of dealing with strictures of the nasal duct, which he has employed almost without exception in all cases that have come into his hands during the past twenty years, and which has yielded, as a rule, most gratifying results, is as follows :

The *lower*<sup>2</sup> canaliculus, after having been slightly dilated by the passage of a No. 1 or No. 2 probe (cocain having been previously instilled into the conjunctival sac), is divided well up to its juncture with the lachrymal sac with Weber's beak-pointed canaliculus knife (Fig. 415), or, preferably, with

<sup>1</sup> See the writer's article upon "Diseases of the Lachrymal Apparatus," in a *System of Diseases of the Eye*, edited by Norris and Oliver, vol. iii.

<sup>2</sup> Some surgeons prefer to divide the *upper* canaliculus and to introduce the probes through it, but this seems to the writer a more difficult and comparatively awkward procedure.

the modification of the knife represented in Fig. 416. An effort is then made to pass into the sac and through the duct a No. 5 or No. 6 of the writer's series of lachrymal probes (usually the former)<sup>1</sup> (see Fig. 419, page 598). If the probe enters fairly into the lachrymal sac, any reasonable amount of force which may be necessary to pass it through the occluded duct to the floor of the nose is employed without hesitation, care being exercised that it does not take a wrong course. If, owing to a constriction at the juncture of the canaliculus and the sac (a condition which is not infrequently met with, and which occasionally greatly complicates the treatment), the point of the probe is arrested and prevented from entering the sac, a smaller probe, No. 4 or No. 3, is tried. If neither of these can be introduced, it is best to desist from further efforts and to wait for forty-eight hours, when very often the difficulty previously experienced in entering the sac will be found to have disappeared. If this does not prove to be the case, an opening is drilled through the constriction with the sharp-pointed, straight probe (Fig. 182), or, the lid being kept well upon the stretch, a No. 5 probe is passed along the canaliculus to the point of resistance and is then turned vertically and forced into the sac—a procedure which, if possible, should be avoided, as it may result in the making of a false passage directly from the canaliculus into the duct. Exceptionally, the constriction must be divided with a sharp-pointed knife, the old-fashioned cataract knife of Siehel being especially convenient for this purpose.

The probe, after being passed entirely through the duct to the floor of the nose, is allowed to remain *in situ* for from ten to twenty minutes. The probing is repeated during the early stages of the treatment every other day, usually a size larger probe being passed each time. The size of the largest probe which it is desirable to use will of course vary in different cases, but there are very few in which it is well to stop short of No. 14, for it is to be borne in mind that our purpose is to obliterate the stricture completely (not simply to make a small opening through it) and to restore the normal caliber of the duct. In about two-thirds of all his cases (including children as well as adults) the writer introduces No. 16. In passing the larger probes considerable force is sometimes employed. This has been found not only to be permissible, but, instead of doing harm, as many maintain must necessarily be the case, its effect upon the carious walls of the duct is distinctly curative, the result being not unlike that produced by the curetting of diseased bone in other parts of the body.

When as large a probe has been introduced as is deemed necessary, the interval between the probings is gradually increased, first to three or four days, then to a week, a fortnight, and finally to a month or two months; and when several of these longer intervals have elapsed without any tendency to recontraction having manifested itself, the case is dismissed with full assurance that a permanent cure has been effected. Including these longer intervals the treatment frequently extends over a period of eight or ten months; but the active treatment, involving the frequent probings, is comprised within as many weeks.

*Electrolysis* has been tried by the writer to a limited extent, to promote the more rapid absorption of lachrymal strictures; but, so far as could be judged, its effect was inappreciable. The chloride-of-silver, "dry-cell,"

<sup>1</sup> The series comprises sixteen sizes. No. 1 has a diameter of 0.25 mm., and the sizes increase by 0.25 mm., the largest of the series, No. 16, having a diameter of 4 mm. The smaller sizes, from No. 1 to No. 6, are made of coin-silver; the larger sizes, from No. 8 to No. 16, of aluminium or of copper, nickel-plated.



battery is convenient for this purpose. From eight to twelve cells may be used, the negative pole being connected with a probe which has been introduced into the duct, while a moist sponge connected with the positive pole is held in contact with the cheek.

No attempt is made by means of syringes to inject antiseptic or other solution into the lachrymal sac, but, instead, a collyrium is prescribed, which the patient is instructed to drop into the inner corner of the eye three times a day, after having pressed out the contents of the sac with the finger-tip. The collyria which have been found most useful are a solution of bichlorid of mercury (1 : 12,000) and one of alum and boric acid, containing 2 per cent. of boric acid and one-half of 1 per cent. of alum. Formaldehyd (1 : 2000) is much employed by some surgeons, as are all of the usual antiseptic and astringent collyria.

The presence of a lachrymal fistula, even when accompanied by caries of the underlying bone, has not seemed to call for especial treatment. The fistula has been found to heal promptly, and the carious bone to become re-covered with periosteum as soon as the stenosis of the duct has been overcome by the passage of the large probes.

The frequent dependence of lachrymal disease upon nasal catarrh is kept constantly in mind, and treatment is directed to the nasal passages whenever it seems to be indicated. For this purpose a weak solution of bichlorid of mercury (1 : 5000), to which is added a small quantity of chlorid of sodium and glycerin, applied to the nose several times a day by means of a hand-atomizer, has been found especially efficacious. (For full particulars in reference to measures suited to such conditions see sections devoted to diseases of the rhino-pharynx.)

The length of time during which the probing must be kept up varies considerably in different cases; but it is a safe rule not to discontinue the use of the probe altogether as long as there is any evidence of dacryocystitis or any roughness of the walls of the duct noticeable on passing the probe. In obstinate cases, however, it is well to lengthen the interval between the probings, as it sometimes happens that the inflammation is kept up by the too frequent introduction of the probe. In several instances, when patients from a distance could not remain under treatment as long as was thought desirable, it has been found practicable to teach them to probe their own nasal ducts with the large probes which had been previously introduced, cocain being first instilled to minimize the pain. In this way relapses, which otherwise might have occurred from the too early discontinuance of the treatment, have been



FIG. 186.—Modified form of lachrymal probe for use by patients (actual size).

avoided. The probe represented in Fig. 186 was devised by the writer for this purpose, and has been found very useful.

In the transient occlusion of the nasal duct which occurs in the new-born operative interference, as has been stated, is seldom called for; nevertheless, if the collyria of bichlorid of mercury, of alum and boric acid, and, perhaps, a weak solution (gr.  $\frac{1}{4}$  to  $\frac{1}{5}$ ) of nitrate of silver, have been tried perseveringly without effect, it may become necessary to divide the canaliculus and introduce a probe. The outcome of this treatment is usually very satis-

factory, and it is seldom necessary to repeat the probing oftener than four or five times. In a case of this character in a child fifteen months old recently under treatment, and in which a complete cure was effected, the duct was probed in all ten times, No. 12, the largest probe used, being introduced upon five successive occasions.

The writer's experience with the radical treatment of strictures of the nasal duct by the use of large probes now extends over a period of nearly twenty years, during which time he has employed it in a large number of cases, and has had the opportunity of seeing many of them, from time to time, for long periods after the discontinuance of the probing; and his observation is that the cases in which the treatment is systematically carried out in the manner which has been described are, with comparatively few exceptions, completely and permanently cured.

# DISEASES OF THE CONJUNCTIVA.

BY JOHN E. WEEKS, M. D.,

OF NEW YORK CITY.

**Congenital Anomalies of the Conjunctiva.**—Pigment-patches, like moles, sometimes appear on the conjunctiva, accompanying moles of the face.

Dermoid tumors develop on the ocular conjunctiva (often extending on to the cornea), at the caruncle, and at the upper outer quadrant of the globe (see page 329). They are at times associated with coloboma of the lids. They may be pigmented. Dermoid cysts have also been observed.

Telangiectatic patches may appear on the caruncle and also on the palpebral conjunctiva. They are flat, slightly elevated, bright red in color, and often accompany telangiectatic patches on the lids and face.

Cavernoma of the conjunctiva also exists as a congenital growth. The color is dark blue, and the conjunctiva is bulged forward at the affected part. When the head is lowered or the child cries or coughs the tumor increases in size.

Small subconjunctival lipomata may accompany congenital coloboma of the lids or may exist alone.

Well-developed bone-tissue has been observed situated beneath the ocular conjunctiva, between the margin of the cornea and the outer commissure.

The caruncle may present an abnormal development of hair (*trichosis caruncularis*). Congenital duplication of the caruncle has been reported by Stephenson.

**Hyperemia of the Conjunctiva** (*Dry Catarrh*).—This condition usually affects the palpebral conjunctiva, and is manifested by a persistent redness with no appreciable thickening. The posterior system of conjunctival vessels is involved.

**Etiology.**—The causes of this affection are numerous, and comprise the entrance of minute irritating particles into the conjunctival sac, exposure to strong winds, cold, heat, and glare of light. Conjunctival hyperemia may be produced by use of the eyes with poor illumination, eye-strain from errors of refraction or muscular irregularities, by too continuous use of the eyes on fine work, by indigestion, alcoholic beverages, rheumatic gout, vaso-motor disturbances, nasal catarrh, lachrymal disease, blepharitis marginalis, acute exanthematous fevers, etc.

**Pathology.**—There is little change in the tissues; the blood-vessels are enlarged and overfull, and there is a scanty small cell-infiltration and increase in nuclei.

**Symptoms.**—The lids feel heavy and hot; movements of the eye are painful; there are increased lachrymation and slight photophobia. Attempts to use the eyes by artificial light are accompanied by distress.

**Diagnosis and Prognosis.**—Redness of the conjunctiva without discharge

other than increased lachrymation, and without other appreciable change in the conjunctiva, suffices to establish a diagnosis. The *prognosis* is favorable, provided the cause can be removed.

**Treatment.**—This should include the prevention of the entrance of foreign substances into the eye, and the correction of habits and systemic conditions that contribute to the continuation of the hyperemia. Errors of refraction and muscular defects should be corrected. Bathing the conjunctiva with a solution of boric acid, 2 or 3 per cent., three or four times a day, usually suffices for the local treatment. Strong astringents are not advisable.

**Conjunctivitis (*Ophthalmia*).**—This term embraces a number of diseases of the conjunctiva characterized by increased altered secretion from the surface of the conjunctiva, pronounced distressing symptoms, and transient or permanent pathological changes in the membrane.

**Simple Conjunctivitis (*Catarrhal Ophthalmia*).**—There is a relatively large number of forms of conjunctivitis which are mild in character and tend to spontaneous recovery, without serious complications, which may be placed in this class. They are characterized by slight swelling of the lids and conjunctiva and the presence of a muco-purulent secretion. The specific disease known as *acute contagious conjunctivitis*, usually considered under this head, will be described separately.

**Etiology.**—(a) *Mechanical or traumatic* varieties are caused by the presence of dust or other irritating substances, as certain kinds of pollen, fish-scales, foreign bodies of any description, insects and parts of insects.

(b) *Associate* varieties accompany the eruptive fevers (measles, scarlet fever, small-pox), influenza, acute coryza, facial erysipelas, eczema, and blepharitis marginalis. The *pneumococcus* of Fränkel (Fig. IV., Plate 2) has been described by Morax, Parinaud, and others as an infrequent, and by Gifford<sup>1</sup> as a frequent, cause of simple conjunctivitis.<sup>2</sup>

**Symptoms.**—The development of muco-purulent secretion is preceded by burning sensations, increased lachrymation, hyperemia, and slight swelling of the palpebral conjunctiva and transition fold. More or less marked swelling of the lids occurs, movements of the lids are painful, and photophobia with inability to use the eyes develops. Frequently one eye alone is affected, particularly in those cases having a mechanical origin.

**Diagnosis and Prognosis.**—Often the history of the case is all-sufficient. Examination of the conjunctival sac may disclose the presence of an irritating substance in addition to the muco-purulent secretion. In doubtful cases a microscopical examination of the secretion will serve to decide its character. The prognosis as to duration is favorable in all cases where the cause can be discovered and removed. No serious impairment of vision occurs.

**Treatment.**—The causes that produce the disease should be sought for and removed, when rapid recovery even without local medication often will take place. However, a cleansing wash, as a solution of boric acid, or of sublimate 1 : 15,000, may be used every two or three hours to advantage.

<sup>1</sup> *Archives of Ophthalmology*, vol. xxv., 1896, p. 314.

<sup>2</sup> The affections of the conjunctiva which are due to a known specific micro-organism are: Acute conjunctivitis described by Morax—*pneumococcus*; acute contagious conjunctivitis—small bacillus, first seen by Koch in 1883, and cultivated and proved to be the specific micro-organism by Weeks in 1886, without knowledge of Koch's observation; gonorrheal conjunctivitis—diplococcus of Neisser; diphtheritic conjunctivitis—Klebs-Löffler bacillus; tubercular conjunctivitis—tubercle bacillus of Koch; and leprosy of the conjunctiva—leprosy bacillus.

There are a number of affections of the conjunctiva in which a specific micro-organism probably exists, but which has not yet been positively identified; of these may be mentioned phlyctenular conjunctivitis, trachoma, membranous conjunctivitis, and xerosis epithelialis.



After the acute stage is passed an astringent stimulating collyrium of zinc sulphate, alum, or nitrate of silver, in the strength of one grain to the ounce, may be instilled once daily until all secretion has disappeared.

**Acute Contagious Conjunctivitis** (*Acute or Epidemic Catarrhal Conjunctivitis; Muco-purulent Conjunctivitis; "Pink Eye" (vulgarly)*).—This is an acute, highly contagious, muco-purulent inflammation of the conjunctiva, accompanied by some swelling of the lids. A period of incubation precedes the acute stage; both eyes are usually affected. No age is exempt, except perhaps the first ten days of life. The affection is met with most frequently in the spring and fall months, often becoming epidemic. So far as is known it is prevalent throughout almost if not quite the entire world.

**Etiology.**—This disease is due to the presence of a specific micro-organism, a bacillus, in the conjunctival sac. A careful study of this micro-organism was first made by the writer<sup>1</sup> in 1886, and his work has since been confirmed by Kartulis,<sup>2</sup> Morax,<sup>3</sup> and others. The bacillus resembles that of mouse-septicemia, measuring 0.25 micro-millimeters in thickness (Figs. II. and III., Plate 2).

**Pathology and Pathological Anatomy.**—The posterior and anterior systems of blood-vessels are congested, and there is apparently an increase in the number of capillaries and arterioles. The conjunctiva at the transition folds becomes thickened through the medium of the enlarged vessels, slight serous effusion, and the presence of leucocytes in moderate number in the conjunctival tissue. Small transfusions of blood occur in the ocular conjunctiva from the smaller vessels of the anterior vascular system.

Microscopical examination of the conjunctiva at the fornix discovers a slight infiltration of leucocytes at the base of the epithelial layer and between the epithelial cells, a moderate edematous condition of the tissue, and the presence of a few bacilli disposed in small groups in the epithelial and very superficial conjunctival layers. The secretion contains many bacilli, free and aggregated, on or in the leucocytes.

**Symptoms.**—About thirty-six hours after the inception of the contagium the patient experiences a mild burning sensation in the lids, which are stuck together on waking in the morning; lachrymation is slightly increased. On the morning of the third day the lids are glued together with a thick layer of muco-pus. They are swollen, sometimes intensely so, and the patient suffers from a sensation as of a foreign body in the eye. Some photophobia is experienced. Use of the eyes is accompanied by pain; vision is blurred by the presence of the secretion. The palpebral conjunctiva is deeply injected, the transition fold thickened, and the ocular conjunctiva presents a bright-red appearance, a peculiarity which has given the disease the popular name of "pink eye." At the end of the third day the affection is usually at its height.

In the greater number of cases the swelling of the lids does not become intense, but in a few this symptom is pronounced, and when accompanied by pseudo-membrane the disease may be mistaken for diphtheria.

The secretion seldom loses its ropy character, due to the presence of mucin, but in some cases it becomes quite purulent, resembling the discharge of gonorrhœal conjunctivitis. There is seldom any chemosis, although the ocular conjunctiva is intensely injected. Close inspection will disclose the

<sup>1</sup> *Archives of Ophthalmology*, vol. xv. No. 4, 1886; *N. Y. Med. Rec.*, May 21, 1887.

<sup>2</sup> *Centralbl. f. Bakt. u. Parasitenk.*, 1887, p. 289.

<sup>3</sup> *Récherches bactériologiques sur l'Étiologie des Conjunctivites aiguës, etc.*, Paris, 1894.

PLATE 2.

Fig. I

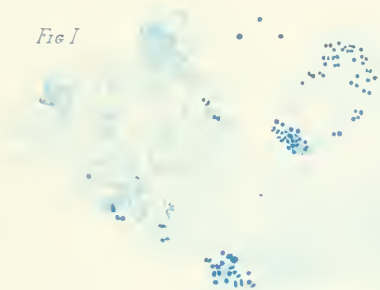

Fig. II



Fig. III

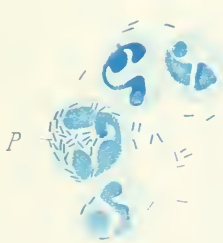


Fig. IV

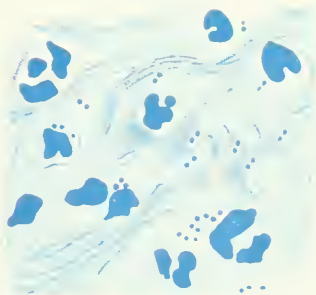


FIG. I.—Discharge from right eye in a case of purulent conjunctivitis: gonococci numerous in cells (Stephenson).

FIG. II.—Bacillus of Weeks in pure culture (from a photograph).

FIG. III.—Conjunctival secretion from acute contagious conjunctivitis: polynuclear leukocytes with the bacillus of Weeks; P, phagocyte containing bacillus of Weeks; immers.  $\frac{1}{2}$ , iii. (Morax).

FIG. IV.—Secretion from a case of conjunctivitis, showing pneumococci; immers.  $\frac{1}{2}$ , iii. (Morax).



presence of many small transfusions of blood in the ocular conjunctiva: this is such a common symptom that Nettleship has given the affection the name of "*hemorrhagic catarrhal conjunctivitis*."

The acute stage, which is often accompanied by slight rise of temperature and frontal headache, lasts from four to ten days. The discharge gradually diminishes in quantity, becomes thicker, and collects in little yellow masses at the inner canthi. The swelling of the lids and conjunctiva and the painful symptoms gradually subside, and recovery usually occurs in from two to three weeks. In the subacute stage the conjunctiva at the transition folds presents a swollen, succulent condition, with enlargement of the papillary body and some follicular hypertrophy.

**Diagnosis and Prognosis.**—A history of the presence of the affection in all or a number of the members of a family, or of its epidemic character in institutions, will aid much in establishing a diagnosis. The very yellow mass of secretion at the inner canthus is quite characteristic. Acute contagious conjunctivitis may be mistaken for purulent conjunctivitis, and, when a pseudo-membrane forms, as it does in about 4 per cent. of the cases, for diphtheritic conjunctivitis. The microscope may be depended on to make the diagnosis clear in doubtful cases.

In the greater number of cases recovery ensues without leaving a trace of the disease; relapses and recurrences are frequently observed. One attack does not ensure immunity. Phlyctenulæ may develop in the later stages or trachoma may follow, but these conditions must be regarded as secondary diseases grafted on the primary disease by added infection. The cornea is rarely affected. In adults the attack is more severe than in children. The disease is contagious as long as secretion is present.

**Treatment.**—As the disease is very contagious, isolation should be resorted to if possible. Bathing appliances should be separate. In all cases where large numbers of individuals are aggregated quarantine should be rigidly enforced, and persevered in until all traces of secretion have disappeared, and even for a few days after that period.

For the first three to five days of the acute stage cold applications are indicated. These may be applied as follows: Thin pads of absorbent cotton,  $1\frac{1}{2}$  inches in diameter, or pieces of linen,  $1\frac{1}{2}$  inches square and two or three layers in thickness, to the number of ten or twelve, should be placed on a cake of ice over which a thin napkin is spread, and a pad transferred to and from the eye sufficiently often to keep the lids cool—every two minutes. In severe cases the cold applications should be continuous; in mild cases it will suffice to keep up the applications through the daytime.

While this is being done the eye should be cleansed every half hour if the secretion is profuse, less often if the secretion is scanty, with some bland antiseptic solution. Boric acid, 2 or 3 per cent., or the bichlorid of mercury, 1:15,000, may be employed. When the acute stage is subsiding the cold applications should be discontinued, the bathing continued, and in addition a more energetic germicidal astringent may be employed. Nitrate of silver, in the solution of 0.5 to 1 per cent., is excellently adapted for this purpose. The application may be made once in twenty-four hours, and may be continued with less frequency until the secretion ceases. Other topical applications are—alum (gr. 1- $f\bar{5}$ ), acetate of lead (gr. 1- $f\bar{5}$ ), sulphate of zinc (gr. 1- $f\bar{5}$ ), peroxid of hydrogen, formalin (Schering's solution—1:200 to 1:500).

Bandaging the eyes and the application of poultices of tea-leaves, oysters, scraped potatoes, bread and milk, and other domestic concoctions should be



avoided. These only serve to retard recovery, and in many cases increase the inflammation.

**Purulent Conjunctivitis** (*Acute Blepharorrhoea of the Conjunctiva*).—The term purulent conjunctivitis properly applies to all forms of conjunctivitis in which the discharge is more or less copious and comparatively free from mucin. This condition obtains in certain cases of acute contagious conjunctivitis, in some cases of traumatic conjunctivitis, in the forms induced by the application of a poultice of tea-leaves in simple conjunctivitis (*tea-leaf conjunctivitis*), and in the later stages of diphtheritic conjunctivitis. As commonly employed, it refers to the conjunctivitis induced by the presence of the *gonococcus of Neisser*, and is usually considered under the terms *gonorrhoeal conjunctivitis* and *conjunctivitis neonatorum*.

**Gonorrhoeal Conjunctivitis**.—This disease occurs in men much more frequently than in women. It is characterized by marked swelling of the lids and copious discharge of purulent secretion from the conjunctiva.

**Etiology**.—The gonococcus of Neisser (see Fig. 1., Plate 2) in secretion from a diseased mucous membrane is brought in contact with the conjunctiva. Probably the most frequent manner of its conveyance is by means of the finger from a urethral or vaginal gonorrhoea. The use of a common washing-bowl, towels, etc. may serve to communicate the disease. It is not probable that the contagium can be carried through the air. The discharge in gleet, as well as in pronounced gonorrhoea, may serve to set up the affection, but it is supposed to be less severe when arising from gleet.

**Pathology and Pathological Anatomy**.—Engorgement of the vessels of the palpebral and ocular conjunctiva rapidly develops. An infiltration of leukocytes into the superficial layers of the entire conjunctiva and edema induced by a serous and in some cases a fibrinous exudation occur early. The conjunctival epithelial layer is swollen and uneven. The pathogenic micro-organism grouped in or on the leukocytes in the characteristic manner is seen

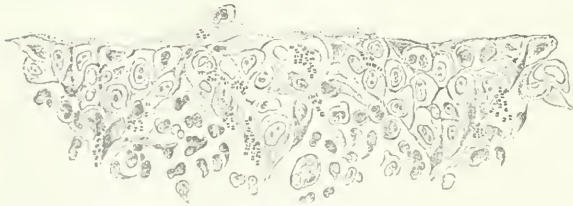

FIG. 187.—Gonococci in the tissues of the conjunctiva (Bumm).

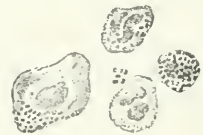


FIG. 188.—Gonococci free and on the cells (Bumm).

in the superficial layers of the conjunctiva (Fig. 187). The secretion contains the gonococci, which are found free and on the pus-cells (Fig. 188).

**Symptoms**.—The *stage of incubation*, which lasts from twelve to forty-eight hours, is succeeded by the acute stage. The lids swell rapidly, and sometimes enormously, taking on a dark-red hue. The vessels of the conjunctiva become deeply congested, the conjunctiva red and swollen. There are a gritty sensation and smarting and burning of the lids. The increased weight of the lids produces a continuous dull pain in the eyes. The *acute stage* reaches its height in two or three days, at which time the swelling of the lids in typical cases is intense. The upper overlap the lower lids; from beneath the margins of the upper lids the secretion, which at first is watery and flaked with pus, and later becomes thick and creamy, oozes out on to and flows down the cheek. At times the secretion is retained in the conjunctival sac, producing much pain by pressure on the globe.

The conjunctiva of the tarsus and transition fold becomes much thickened and presents a deep-red, velvety appearance. The ocular conjunctiva becomes very edematous, marked chemosis develops, and extravasations of blood are observed in this part of the conjunctiva. The chemotic tissue may overlap the cornea, giving lodgement to secretion in the sulcus thus formed, which is difficult to remove, and which serves to macerate and destroy the corneal epithelium, establishing an *ulcer of the cornea*. The chemotic tissue may protrude between the lids.

The acute stage continues from four days to two weeks, and gradually merges into the *subacute stage*. The thickening of the lids is now much less; they are pale, soft, and flabby. The conjunctiva presents a velvety appearance, and is still much hypertrophied; the chemosis is less marked and the secretion less profuse.

What might be termed the *atonic stage* succeeds the subacute stage. The swelling of the lids has subsided, but the conjunctiva of the tarsus and transition folds is left rough, rugose, and presents many papilliform elevations. The secretion is thinner and not so profuse. Use of the eye is difficult. This stage may drift into a *chronic condition* if not treated properly, in which corneal ulcer, trichiasis, entropion, etc. may develop.

Of the complications that develop, *corneal involvement* is most dreaded. Total destruction of the cornea may occur early from interference with the nutrition of that membrane; the cornea loses its luster, becomes gray, and disappears. Loss of the crystalline lens and *panophthalmitis* may follow. Involvement of the cornea is most frequent in the second week of the disease, the ulcer commencing at the margin of the cornea as a grayish, uneven defect which increases in depth and area. *Pseudo-membrane* occurs in a small percentage of the cases. It appears on the palpebral conjunctiva as a result of the deposition of fibrin on a surface from which the superficial epithelial cells have been lost. *Gonorrheal rheumatism* is an infrequent consequence of gonorrhoeal conjunctivitis.

**Diagnosis.**—Gonorrhoeal conjunctivitis presents many degrees of severity. It may be so mild that it readily passes for simple conjunctivitis; or so severe that diphtheria is suspected. The history of the case will assist in making a diagnosis, and microscopical examination will absolutely establish it. The conjunctivitis occurring in young girls with leukorrhœa, which is observed from time to time, is often gonorrhoeal, but, according to some authors, may have other causes.

**Prognosis.**—In spite of all treatment, a large percentage of cases result in impairment of vision, to a greater or less degree, from corneal complications. If an ulcer appears at the margin of the cornea, and the cornea at this point becomes vascular, recovery without perforation may be looked for. Partial ulceration of the cornea, with or without perforation, may be followed by *partial staphyloma* after the ulcer has healed. *Adherent leukoma* follows perforating ulcer of the cornea, and in rare cases the lens may become adherent to the scar. *Panophthalmitis*, as already stated, may be the result.

**Treatment.**—*Prophylaxis* as regards other individuals and in regard to the fellow-eye must be first considered. The disease, through the secretion, is extremely contagious; hence immediate isolation should be secured, and should be persisted in until all secretion has disappeared. All dressings and appliances with which the secretion comes in contact should be destroyed or thoroughly sterilized. To protect the fellow-eye a *Buller's shield*, which consists of a watch-crystal held over the eye by means of strips of rubber plaster, should be applied.

*Local Treatment.*—In the acute stage cold applications should be employed day and night, after the method described on page 277, and the conjunctiva freed from secretion as often as is necessary—every thirty to sixty minutes, with a bland aseptic solution—boric acid 3 per cent. or bichlorid of mercury (1 : 15,000). For the carrying out of this treatment two nurses, a day and a night nurse, are required. If the lids become sore and erosion of the epithelium is threatened, some borated vaselin may be applied after each bathing.

There are many ways of cleansing the eye. The lids may be held gently apart and the warm solution be permitted to run into the conjunctival sac from a piece of absorbent cotton. A pipette may be used to force a stream beneath the lids after they have been gently opened. A speculum with perforated blades has been devised (Andrews) for cleansing the conjunctival sacs, and a lid-retractor which permits the solution to flow through the handle and into the blade, escaping at openings at the margin of the blade, has been made for the same purpose. Except in very skilful hands the instruments devised for cleansing the eyes are dangerous, as they are apt to injure the cornea and induce corneal ulceration.

Applications of cold, which are generally made inadequately, may be made too assiduously and the vitality of the cornea threatened. When too much cold is applied the cornea takes on a steamy appearance and breaks down more easily. If corneal luster fails without evidence of loss of substance, the applications of cold should be intermittent.

*Hot applications* in the acute stage are contraindicated; they serve to increase exudation and the growth of the gonococcus. In the subacute and atonic stages they may be resorted to with benefit.

As soon as the discharge takes on a purulent character and the lids are less rigid, local applications to the conjunctiva may be made. For this purpose a solution of the nitrate of silver, 1 or 2 per cent., is probably the best. The lids are carefully everted, the secretion removed, and, by means of a piece of absorbent cotton wound around the end of a small applicator the solution is applied to the entire surface of the conjunctiva. This should be followed by applications of cold for one or two hours. The treatment outlined above will suffice to effect a cure in the greater number of cases.

Finely pulverized iodoform is sometimes employed by dusting it into the conjunctival surface two or three times daily. Peroxid of hydrogen has been advocated by Landolt; it is of value as a cleansing and germicidal agent. Sublimate solution, 1 : 500, has been employed recently by applying it to the conjunctiva sufficiently often to hold the secretion in check. Aqua chlorini, formalin (1 : 3000), permanganate of potassium in copious irrigations (1 : 500 or 1 : 1000), are used to irrigate the eye. Dr. Wilson of Bridgeport advocates filling the conjunctival sac with a boric-acid ointment (boric acid gr. xlvij, vaselin ʒj) every one to two hours after cleansing, continuing this treatment until the acute stage has passed; he claims excellent results. In some severe cases Noyes has resorted to scarifying the conjunctiva and brushing in a solution of corrosive sublimate, 1 : 500, repeating the operation in two or three days if the discharge returns.

If corneal ulcer develops, atropin (gr. ij to ʒj) should be instilled two or three times daily. Ehrenthaler<sup>1</sup> recommends eserin (gr. ij to ʒj) in those cases of corneal ulcer where congestion of the iris is not present, alternating with atropin in other cases unless perforation is imminent. He avers that the circulation is improved and recovery more certain.

<sup>1</sup> *Münch. med. Wochenschrift*, No. 38, 1892.

When the lids are greatly swollen and tense a free *canthotomy* may be done. This relieves the pressure on the cornea, unloads the blood-vessels, and prevents spasmodic contraction of the orbicularis palpebrarum muscle. In the last stage hot-water bathing, the sulphate of copper or alum-crystal, and tannin may be employed.

*Systemic Treatment.*—The bowels should be kept free by use of calomel and a saline. Rich food and alcoholic beverages should be forbidden. Opium may be administered if there is much pain.

**Conjunctivitis Neonatorum** (*Ophthalmia Neonatorum*).—This is a purulent affection of the conjunctiva, accompanied by great swelling of the lids and thick purulent secretion, occurring within a few days after the birth of the child.

**Etiology.**—That form of the affection which develops within three days after the birth of the child is undoubtedly produced by gonorrhœal infection from the vaginal secretions of the mother at the time of birth. In cases that have developed ten days to three weeks after birth other causes are found: the small bacillus of acute contagious conjunctivitis, the pneumo-bacillus, and the Klebs-Löffler bacillus have been observed. The use of soiled towels or napkins about the infant or the unclean hands of mother or attendant may serve as a means of carrying infectious material to the infant's eye. Exceptionally, inoculation *in utero* may occur (*ante-partum conjunctivitis*).

**Pathology.**—The pathology of ophthalmia neonatorum resembles that of purulent conjunctivitis in the adult, so far as the tissue-changes are concerned.

**Symptoms.**—Slight puffiness of the lids and a tendency to stick together will be noticed twenty-four or thirty-six hours after birth, and on inspec-

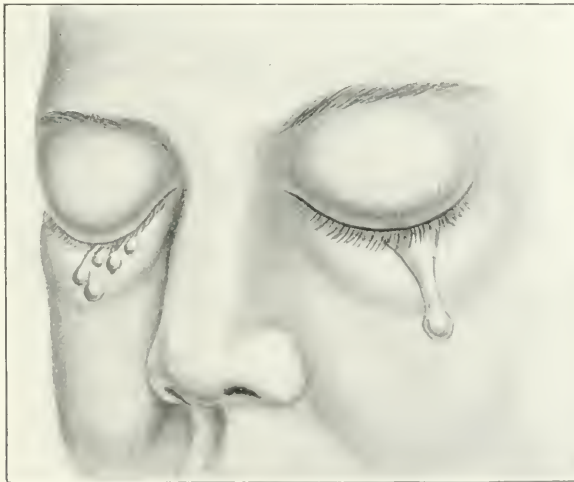

FIG. 189.—Conjunctivitis neonatorum (from a patient in the Philadelphia Hospital under the care of Dr. de Schweinitz).

tion the palpebral conjunctiva will be found to be congested. As a rule, the change in the lids and the presence of secretion are not sufficient to attract attention until the third day, when the secretion has become distinctly purulent and the lids somewhat swollen. At the end of the fourth or fifth day the lids are greatly thickened and of a dusky-red color; the secretion is purulent and quite copious. It either flows out on to the cheek or is retained in greater part by the lids and bursts forth on attempts to separate the lids.



The swelling of the conjunctiva is so intense in some cases that ectropion of the upper lid is produced. Chemosis is not so marked as in purulent conjunctivitis occurring in adults, and involvement of the cornea occurs in a smaller proportion of cases. What has been stated in regard to the symptoms in gonorrhœal conjunctivitis of the adult, except as indicated above, applies to conjunctivitis neonatorum.

**Diagnosis.**—The history of the case and the age of the child will suffice to establish a diagnosis.

**Prognosis.**—If not properly treated the prognosis is grave, but not to such a degree as in the adult. Properly treated, the prognosis is good. Careful observation of many cases has taught the writer that if the patient is seen *while the cornea is still clear* impairment of vision need not occur, except in the cases in which the affection is very severe and the patient's vitality much impaired. Since the retention of vision depends so much on careful and proper treatment, it is of the greatest importance that the infant should be seen by a competent physician as early as possible. Neglected cases have contributed 20 per cent. to the number of the blind.

**Prophylaxis.**—The great work done by Credé in Leipzig in reducing the number of cases of conjunctivitis neonatorum from 10.8 to 0.2 per cent. in the infants born at the Lying-in Asylum under his charge shows what may be accomplished by prophylaxis. Credé's method was to drop two drops of a 2 per cent. solution of nitrate of silver into the conjunctival sac of the infant's eyes very shortly after its birth, having first wiped the lids clean. The reaction is quite severe in some cases.

It has been found that equally good results may be obtained with a 1 per cent. solution of nitrate of silver, also with a solution of bichlorid of mercury (1 : 4000) dropped into the eye in the same manner. Normal saline solution, used a little more freely, is excellent, but not quite as efficacious as either the silver or sublimate solution. Aqua chlorini and carbolic acid (1 : 100) have been advocated.

Those in charge of a case of conjunctivitis neonatorum should be cautioned regarding its contagious nature, and should be instructed to destroy or to disinfect all appliances that come in contact with the secretion. The infant should be removed from the presence of all persons except those in immediate attendance. A protective shield for the unaffected eye is not easily made efficient; more reliance may be placed in the ability of the nurse to keep the fellow-eye disinfected. Almost always, however, the affection is bilateral.

**Treatment.**—If the lids are at all swollen, cold applications, made as described on page 277, and continued until the swelling of the lids partly subsides, are valuable. Three hours of the applications and one hour of intermission is an excellent way of applying cold. After the swelling has markedly diminished applications of cold for one hour, three times daily, may be kept up until little swelling remains.

The pus should be gently removed by lavage with a 2 or 3 per cent. solution of boric acid every half hour or every hour, as long as the secretion is abundant. After the first two or three days applications of a 1 per cent. solution of nitrate of silver may be made by the surgeon on the palpebral conjunctiva, either employing a bit of absorbent cotton on a small applicator or a camel's-hair brush, once in twenty-four hours. As the secretion and swelling diminish the silver solution may be weaker and may be applied less frequently. Should the integument of the lids lose some of its epithelium or become roughened, some borated vaselin may be applied after each cleansing of the eyes.

When ulcer of the cornea occurs, atropin in weak solution (gr. ij to  $\bar{5}$ j) should be instilled twice daily if the ulcer is central; if marginal, eserin (gr. j to  $\bar{5}$ j) may be alternated with the atropin. The treatment may be varied as indicated when considering the treatment of gonorrhœal conjunctivitis of adults (page 280).

**Croupous Conjunctivitis** (*Membranous Conjunctivitis*).—There is a class of cases characterized by a slight swelling of the lids, by a flaky serous discharge, and by the deposit of a fibrinous pseudo-membrane on the surface of the palpebral conjunctiva, extending in some cases on to the ocular conjunctiva, which from a bacteriological or clinical standpoint cannot be included with any other form of conjunctivitis. Graefe<sup>1</sup> terms the disease pseudo-membranous or croupous, in contradistinction to the diphtheritic form. The cases are comparatively rare.

**Etiology.**—No exact cause is known. The affection is regarded as a mild diphtheria by some authors.

**Pathology and Pathological Anatomy.**—The conjunctiva is thickened, and shows on section the presence of leukocytes and an increase in nuclei. The epithelial layer is reduced in thickness; blood-vessels are numerous and are enlarged. The pseudo-membrane consists of fibrin, which includes in its meshwork epithelial cells from the conjunctiva, leukocytes, red blood-corpuscles, and various forms of micro-organisms. The pseudo-membranes found in epidemic conjunctivitis, gonorrhœal conjunctivitis, diphtheritic conjunctivitis, and those that cover the surface of the conjunctiva after burn with acids, steam, or after scarifying the conjunctiva, differ from each other microscopically only in their bacterial contents and the products of the bacterial growth. Thus membranous conjunctivitis has been ascribed to staphylococci, streptococci, Löffler-bacilli, and diplococci.<sup>2</sup>

**Symptoms.**—The symptoms are not severe. The patient complains of obscuration of vision, slight itching, and some burning pain. There is some photophobia. The lids are slightly swollen and somewhat hyperemic. On everting the lids a grayish pseudo-membrane is found. It can be separated from the conjunctiva with comparative ease, but leaves a slightly bleeding surface. The fibrin filaments do not appear to be so numerous or to penetrate so far into the conjunctiva as is the case in diphtheritic conjunctivitis. Removal is followed by rapid regeneration of the membrane, and this tendency may continue for from ten days to many months or even longer.

**Diagnosis.**—The diagnosis is arrived at largely by exclusion. The subacute nature of the disease, the absence of any known specific micro-organism, and the persistence of the affection serve to establish a diagnosis.

**Prognosis.**—The prognosis is good in perhaps 50 per cent. of the cases. Although the disease persists for a long time, appropriate treatment will often produce a gradual diminution in the tendency to reproduce the membrane and the patient will recover. The cornea remains clear for a long time—ten days or perhaps as many weeks. It may finally become the seat of ulcerative processes and be partly or totally destroyed.

**Treatment.**—Unfortunately, treatment appears to be of little avail in some cases; in others a tardy response is secured. It appears to be almost useless to remove the membrane. Frequent and prolonged bathing with some mild antiseptic solution, as carbolized water, corrosive sublimate (1 : 10,000), chlorin-water, or a 4 per cent. solution of boric acid, is indicated.

<sup>1</sup> *Archiv f. Ophth.*, 1854, 1 Abth., i. 168.

<sup>2</sup> For an article on "Pathology of Chronic Membranous Conjunctivitis" by Luelen Howe, consult *Trans. Amer. Ophth. Soc.*, 1897, viii. 36-44.

Some writers believe that it is best to remove the membrane and to treat the surface with the mitigated stick of nitrate of silver; but this measure is of doubtful value. A solution of chlorate of potassium has been suggested, as have also applications of iodoform and quinin.

**Diphtheritic Conjunctivitis** (*Membranous Conjunctivitis*).—This is a severe, acute affection of the conjunctiva, characterized by intense swelling of the lids, which become thick, hard, and smooth, and by the presence of a pseudo-membrane on the surface of the ocular and palpebral conjunctivæ. It attacks individuals of all ages except the new-born (von Graefe), but is most frequent in children. Both eyes are generally involved.

**Etiology.**—The direct cause is without doubt a specific micro-organism known as the *diphtheritic* or *Klebs-Löffler-bacillus* (Fig. 190), which develops on the conjunctiva only when that membrane is in a suitable condition to receive it. A depreciation of the resisting power of the conjunctiva to the inroads of bacteria, the result of malnutrition or an acute illness, as scarlet fever or measles, will favor an attack. The affection is more frequent during the climatic changes of fall and spring and when epidemics of diphtheria of the air-passages occur. Many cases accompany and are secondary to faucial and nasal diphtheria, but the disease may occur primarily in the eye. To produce the disease direct infection of the conjunctiva with secretion containing the bacilli is necessary. Von Graefe<sup>1</sup> states that simple conjunctivitis renders the conjunctiva susceptible to the diphtheritic poison.

**Pathology and Pathological Anatomy.**—A congestion of the blood-vessels of the conjunctiva and lids first occurs, which is soon followed by the transudation of leukocytes and plastic material into the tissue of the lids and on to the surface of the conjunctiva. A partial destruction of the epithelial layer of a portion of the conjunctiva is probably necessary before the plastic exudation can find its way to the surface of the conjunctiva. The circulation is greatly impeded by the presence of the exudation. The pseudo-membrane is composed of layers of fibrin which enclose leukocytes, degenerating epithelial cells, red blood-corpuscles, and various forms of bacteria, prominent among which are the *diphtheritic bacilli*. At the base of the pseudo-membrane fibrillæ of fibrin embrace the superficial epithelial cells and extend between them, causing the membrane to adhere closely during the time of its formation.

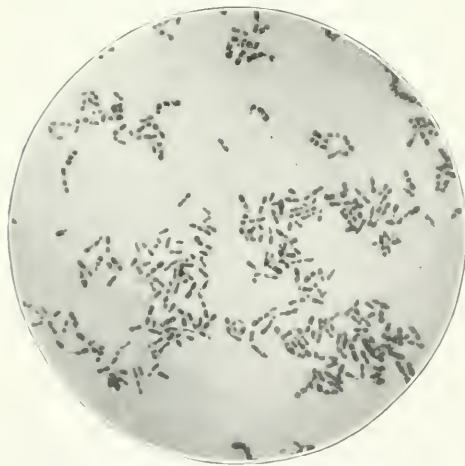


FIG. 190.—Bacillus diphtheriae, from a culture upon blood-serum. 1000 (Fränkel and Pfeiffer).

**Diagnosis.**—In some cases it is difficult to discriminate between membranous conjunctivitis due to diphtheria and that due to other forms of inflammation. Caustic applications in mild forms of conjunctivitis in infants and children may produce a pseudo-membrane and an intense plastic infiltration of the lid that may be mistaken for diphtheria. Severe cases of gonorrhœal and of epidemic conjunctivitis may assume a diphtheritic aspect.

<sup>1</sup> *Archiv f. Ophth.*, 1854, I Abth., p. 168.

The history will aid in eliminating error, but the most conclusive method is that of bacteriological examination. Should the examination of a cover-glass specimen fail to afford positive results, cultivation experiments may be tried.

**Symptoms.**—In a typical case the onset is sudden. Slight discomfort in the lids, increased lachrymation, and congestion of the conjunctiva precede the severer symptoms by a few hours. Swelling of the lids takes place rapidly: at the end of twenty-four hours the upper lid may have attained four or five times its normal thickness. The folds of the skin of the lid are obliterated; it becomes shiny and assumes a dusky-red hue. The lid is hard to the touch, slightly elastic, closes the eye completely, and cannot be easily raised or everted. A little flaky serous secretion, sometimes tinged with blood, oozes from between the lids at this stage. Attempts to open the eye on the part of the patient are futile, and the surgeon will only partly succeed. A sensation of weight and tension on the globe is experienced, but aside from this there is little pain.

On raising the lid from the globe the palpebral and often the ocular conjunctival surface will be found to be covered with a gray membrane, which, in the average case, is about one millimeter in thickness. On attempts to remove this membrane shortly after it has formed, it will be found to be closely adherent: forcible removal leaves a raw, bleeding surface, which is soon covered again by new-formed membrane.

The acute stage, which may last three to seven days, is accompanied by slight rise of bodily temperature, and sometimes by cephalalgia. Gradually the lids become less rigid, the secretion more puriform; the pseudo-membrane comes away in large or small plaques, and finally disappears. Corneal complications in the form of ulcers and extensive sloughing frequently develop, not only when the membranous deposit is extensive, but also when it is moderate in amount. There is great variation in the degree of severity, rapid destruction of the eye occurring in some cases, while others are so mild that the nature of the disease is not recognized.

**Prognosis.**—Diphtheritic conjunctivitis is probably the most destructive disease that affects the conjunctiva. The nutrition of the cornea is often interfered with at an early stage, and the membrane sloughs. Of 40 cases reported by von Graefe occurring in children, 9 eyes were destroyed, in 3 there were adherent leukomata, in 7 simple leukomata, and in 21 the cornea remained unaffected. Of 8 cases in adults, 5 sustained perforation of the cornea, and 3 presented marked simple leukomata after the disease had passed. Symblepharon of varying degrees may result from adhesion of opposing raw surfaces. Tendinous cicatricial bands may form in the conjunctiva. Great changes in the lid may ensue as a result of the formation of cicatricial tissue.

**Treatment.**—The indications are to prevent the communication of the disease to the fellow-eye and to the eyes of other individuals, to limit the infiltration of the lids, to prevent destruction of the cornea by pressure or by infection, and to check the extension of the diphtheritic process to other mucous membranes. Aseptic or antiseptic solutions may be employed to cleanse the unaffected eye at stated intervals, or, better still, Buller's shield may be applied to the sound eye. The patient should be isolated, dressings and secretions from the eye destroyed, and towels, linen, etc. disinfected after use. Cold applications should be made as advised on page 277, until the lids are less tense. A free canthotomy will cause desired depletion and relieve the pressure on the eyeball exerted by the tense lids. The conjunctival sac should be carefully cleansed at frequent intervals with a solution of boric acid, bichlorid of mercury (1:5000 or 10,000), or chlorin-water (one-



half the U. S. P. strength). To prevent extension to the mucous membrane of the air-passages mercury to saturation has been advised. The usual constitutional treatment of diphtheria is indicated.

Recently, *serum-therapy* has been resorted to with results which, if uniformly as brilliant as in the cases reported, will rob the disease of its terrors.<sup>1</sup> As soon as the diagnosis is made, 10 cgm. of Behring's diphtheria-antitoxin is injected into the abdominal wall, and the injection is repeated after forty-eight hours if there is not a marked recession of the disease. In many cases improvement is noted before the end of the first twenty-four hours, and the membrane disappears before the expiration of forty-eight hours. Antitoxin is said to modify favorably the necrotic process in the cornea.

**Phlyctenular Conjunctivitis** (*Lymphatic Conjunctivitis* (Fuchs); *Serofulous Ophthalmia*; *Eczema of the Conjunctiva*).—This disease is characterized by the appearance of one or more small translucent elevations at the limbus or at some point on the ocular conjunctiva, accompanied by an increased local vascularization (Fig. 191). If a single nodule appears, it is situated at the

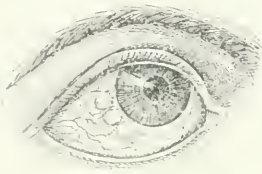

FIG. 191.—Phlyctenular conjunctivitis (De Schweinitz).

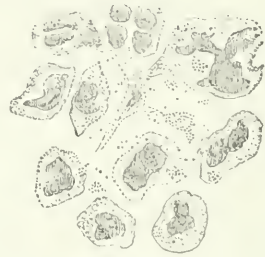

FIG. 192.—Pus with staphylococci;  $\times$  800 (Flügge).

apex of a triangular patch of injected vessels, the base of the triangle being directed toward the equator of the globe. The affection is common in children, never affects the new-born, and is rarely seen in adults.

**Etiology.**—A depraved condition of the system induced by inherited taints, malnutrition, filth, and bad hygienic surroundings predisposes to this affection. Although most frequently met with among the children of the poor, the children of the rich are not exempt. Experiments that have been conducted with cultivations made from the contents of the vesicles permit of but little doubt that the immediate cause is the presence of the *staphylococcus pyogenes aureus* or *albus* beneath the epithelium of the affected portion of the conjunctiva (see Fig. 192). This affection is frequently associated with moist eczema of the lids, face, scalp, ears, or other parts. The nodules of eczema closely resemble those of phlyctenular conjunctivitis, from which the same micro-organism may be cultivated. It is undoubtedly from the eczematous process that the infectious principle is derived in many cases.

Pustular blepharitis marginalis supplies the necessary bacterium in some cases. Phlyctenular conjunctivitis frequently follows the exanthemata, as measles and scarlet fever. Simple and epidemic catarrh of the conjunctiva encourage to the development of phlyctenule, which appear six or seven days after the onset of the acute conjunctivitis due to a secondary infection. Nasopharyngeal disease always accompanies the affection.

<sup>1</sup> Hamilton and Jones: *Brit. Med. Journ.*, 1895, p. 1419; Morax: *Annal. d'Oculistique*, cxiii, p. 360; Coppez: *Revue gén. d'Ophthal.*, Feb., 1896, p. 51; Standish: *Trans. Amer. Ophth. Soc.*, 1897, viii, 44-50.

**Pathology.**—Apparently as a result of the depreciation of the resisting powers of the tissues of the body, the surface cells do not prevent the entrance and development of the pathogenic micro-organisms. The contents of the nodule in the early stage is a thickened fluid containing many leukocytes and some granules; later the contents resemble pus. A section of a nodule shows it to be formed by the elevation of the epithelial layer from the underlying basement-membrane; the vessels in the vicinity are congested, and there is an increased number of leukocytes in the adjacent tissue.

**Symptoms.**—The palpebral conjunctiva is congested; this is also the condition of the ocular conjunctiva in the affected portion. There are slight stinging pain, lachrymation, photophobia, and annoyance on use of the eyes. The photophobia in phlyctenular conjunctivitis is slight compared with that accompanying *phlyctenular keratitis* (see page 305). In almost all cases the preauricular glands are enlarged. Frequently there is marked coryza, the upper lip becoming thickened by the flow of irritating secretions over it.

**Diagnosis.**—Herpes conjunctivæ, vernal catarrh, and trachoma affecting the ocular conjunctiva may be mistaken for phlyctenular conjunctivitis. In herpes the vesicles which spring from the injected conjunctiva are transparent and appear in clusters. They do not select the limbus, and are much more transient. In vernal catarrh the elevations are larger and do not ulcerate. Trachoma of the ocular conjunctiva is associated with trachoma of the palpebral conjunctiva, and seldom affects the limbus conjunctivæ.

**Prognosis.**—When the conjunctiva only is affected the prognosis is favorable, as recovery occurs without leaving a trace of the disease. The duration is variable, from a few days to a number of months, successive phlyctenulæ appearing. Recurrences are frequently observed.

**Treatment.**—This should be local and constitutional. The local treatment consists in keeping the eyes clean by the use of some antiseptic lotion. Bathing with a saturated solution of boric acid in water three or four times a day gives good results. An ointment of the yellow oxid of mercury (1-1.5 per cent.), introduced into the conjunctival sac twice daily after the phlyctenule has broken down, is of much value. Calomel may be dusted on the conjunctiva once daily if the patient is not taking iodin. A mild alterative in the shape of small doses of calomel may be continued for some weeks with benefit. Nourishing food and general tonic treatment—iron, quinin, cod-liver oil, and perhaps strychnin—may be given. The naso-pharynx should receive appropriate treatment. (Consult also *Phlyctenular Keratoconjunctivitis*, page 307.)

**Herpes Conjunctivæ.**—This occurs at times in connection with herpes febrilis or herpes zoster affecting the lids and face. It is seldom that the complete vesicles are found, as they rupture early, and their site is marked by shreds of epithelium which remain attached to the conjunctiva at the margins of the preceding vesicles.

The condition is accompanied by irritation and increased lachrymation. Herpes of the cornea may accompany herpes conjunctivæ. The affection is extremely rare. It calls for no treatment other than that given for the affection which it accompanies (see also page 309).

**Vernal Conjunctivitis or Catarrh** (*Fruchjahr's Catarrh* (Saemisch); *Spring Catarrh*; *Phlyctæna Pallida* (Hirschberg)).—This is a chronic form of conjunctivitis which presents peculiar features. The tarsal conjunctiva is covered by small, closely-placed, flattened, papilliform excrescences, which appear to be covered by a delicate grayish film. At the margin of the cornea the conjunctiva is thickened and unequally raised, forming pale, translucent,

or waxy nodules, which are largest opposite the palpebral fissure, encroach a little on the cornea, but extend to a greater distance outward into the ocular conjunctiva.

**Etiology.**—Nothing definite is known of the cause of the affection. Some writers believe it to be a form of trachoma, and so classify it. Fuchs is of the opinion that it is a specific disease, and that, although no specific micro-organism has been discovered, it is produced by such a micro-organism. Both eyes are affected. The male sex suffers most, the attacks being experienced between the ages of one and thirty-five years.

**Pathology.**—Little is known regarding the development of the papillæ of the tarsal conjunctiva. The elevations about the cornea are preceded by local injection of the vessels; the thickening develops slowly. The papillæ of the tarsal conjunctiva are composed of a central cylinder or cone, made up of connective tissue and a few small blood-vessels, which is covered by a thickened layer of epithelium. Over the nodules, at the limbus, the epithelial layer is uneven, and is thicker than normal.

**Symptoms.**—The ropy nature of the secretion produces a sensation as of a foreign body in the eye. There are photophobia, burning of the lids, and blurring of vision, principally due to the presence of secretion on the cornea. Use of the eyes by artificial light increases the irritation and lachrymation; the redness of the ocular conjunctiva about the cornea and the nodules at the limbus are apparent on inspection. On everting the lid the fine fissures of the tarsal conjunctiva due to separation of the papillæ are recognized. The disease gives but little annoyance during winter months, but is very troublesome during the summer months, at which time there is more or less stringy discharge and the eyes are painful. When cold weather comes on the elevations at the margin of the cornea become much smaller, some disappearing entirely; the tarsal conjunctiva is less thickened, but the papilliform elevations still remain. Burnett states that in the colored race the bases of the nodules are pigmented.

**Diagnosis.**—The history of the case is of great value in making a diagnosis. No other form of conjunctivitis recurs and persists to the same extent during the warm weather. The conjunctivitis that accompanies *hay fever* has none of the anatomical and few of the symptomatic characteristics of this disease.

Vernal catarrh may be confounded with trachoma and with phlyctenular conjunctivitis. The elevations on the tarsal conjunctiva do not have the appearance of the follicles of trachoma, nor do they have the same anatomical structure. The pericorneal elevations differ from those of phlyctenular conjunctivitis in that they are not so transient and do not break down and form ulcers.

**Prognosis.**—The disease recurs for a number of years, and may then disappear entirely. In the greater number of cases no injury is done to the central area of the cornea; however, the nodules may advance for a considerable distance, and in rare cases may cover the cornea, abolishing useful vision.

**Treatment.**—A complete cure by means of treatment must not be expected, but much can be done to relieve distressing symptoms, and the advance of the nodules on to the cornea may be checked. Bathing the eyes with a warm solution of boric acid three times daily will serve to keep them fairly clear of secretion. This, with the application of a smooth ointment of the yellow oxid of mercury ( $1\frac{1}{2}$  per cent.) to the conjunctival sac twice daily, will produce very favorable results. Calomel and solutions of bichlorid of mercury

are useful. If the nodules are large, they may be reduced and their advance checked by destroying them with the cautery; electrolysis has been recommended. Randolph advises salicylic acid applied to the conjunctiva in the form of an ointment (gr. iij- $\bar{5}$ iv) and as a collyrium (gr. v-f $\bar{5}$ j).

**Follicular Conjunctivitis** (*Conjunctivitis Follicularis Simplex*).—This inflammation of the conjunctiva is characterized by the occurrence of small, oval, pale or light-red elevations in the transition folds of the conjunctiva. A few follicles the size of a pinhead are often observed in the tarsal conjunctiva.

**Etiology.**—Follicular conjunctivitis occurs among persons inhabiting crowded quarters and among those whose habits and surroundings are not cleanly. Soelberg Wells states that he thinks that there can be no doubt that the disease is contagious. It is often met with in the young, and is of frequent occurrence in inmates of residential schools.

**Pathology.**—The follicles are due, according to Krause and Schmidt, to an abnormal enlargement of the lymphatic follicles of Krause, which are not visible to the unaided eye in the normal state, but which are situated immediately beneath the epithelium of the conjunctiva. They are supposed to be neoplastic growths. The follicles are composed of a mass of lymphoid cells contained in a delicate network of connective tissue having an incomplete capsule in which a few small vessels ramify.

**Symptoms.**—These are few and not pronounced; indeed, follicular conjunctivitis may exist for months without the knowledge of the individual affected. On inspection the lower lid appears to be slightly thickened; there may be increased lachrymation, some mucoid secretion, and the ocular conjunctiva may be injected. On everting the lower lid the transition fold is found to be reddened, and may be swollen to such an extent that the follicles will not be visible; however, in the greater number of cases the follicles appear as small, oval, translucent nodules, arranged in rows, lying in the transition fold. They may be few or numerous. Although ordinarily confined to the lower, they may be found in large numbers in the upper, transition fold.

**Diagnosis and Prognosis.**—If the conjunctiva is not greatly swollen, the diagnosis is easy. Follicular conjunctivitis differs from typical trachoma in that it is more transient, is more amenable to treatment, and is not followed by cicatricial changes. The *prognosis* is favorable for a return to the normal condition of health in a number of months if medicinal measures are adopted, and in two or three weeks if surgical measures are employed. There is no tendency to involvement of the cornea.

**Treatment.**—The patient should not be allowed to use the same bathing appliances with others, and should be isolated when practicable. The hygienic conditions should be made as good as possible, and cleanliness should be insisted upon. Constitutional treatment in the form of tonics, iron, strychnin, or quinin should be employed. Locally, a mild astringent collyrium of zinc sulphate (gr. j to  $\bar{5}$ j), alum (gr. j to  $\bar{5}$ j), tannic acid, and glycerin (gr. 30-60 to  $\bar{5}$ j) may be employed. The sulphate of copper or alum-crystal may be lightly applied to the follicles every forty-eight hours.

For the *surgical treatment* of this affection see Surgical Treatment for Trachoma, page 563. Expression of the follicles with suitable forceps is the most efficient measure to destroy them.

**Granular Conjunctivitis** (*Trachoma; Granular Ophthalmia; Military Ophthalmia*).—This disease of the conjunctiva presents as its distinctive feature in its early or first stage numerous discrete, oval bodies in the tarsal



conjunctiva and transition fold (*trachoma bodies*). When the conjunctiva is not hypertrophied these granules are prominent, translucent, and resemble frog-spawn, to which they have been compared. Granular conjunctivitis is most common in youth; however, individuals at all ages are affected, except perhaps those in the first year of life.

**Description.**—In describing the clinical features of granular conjunctivitis it is convenient to divide it into three stages.

The *first stage* is that in which the granulations are discrete, in which the cicatricial contraction has not occurred, and may be termed the stage of hypertrophy. It manifests itself in a number of distinct phases which we will consider separately.

1. Cases appear sporadically in which, with little or no previous indication, no secretion, but with perhaps a little thickening of the lids, the granules develop, and the physician is surprised on everting the lid to find the palpebral conjunctiva completely studded with well-formed granulations (Fig. 193). There is scarcely any injection of the conjunctiva and no marked discomfort to the individual. Only one member of a family may be affected or only one or two pupils in a school may show this condition. If this form of granular conjunctivitis is at all contagious, it is only very slightly so, probably because of the very scanty secretion.

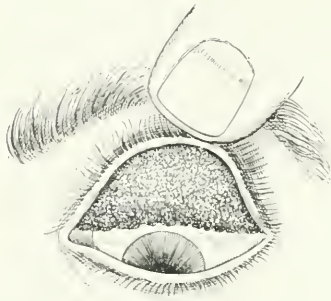


FIG. 193.—Follicular trachoma (Johnson).

2. The clinical picture presented by this phase of the disease is the most common. The onset is not very *acute*, but there is redness of the conjunctiva and of the margins of the lids, accompanied by increased lachrymation, scanty mucoid secretion, and a sensation of burning and itching. In the morning the

lids are stuck together, but can be opened without much difficulty. At the end of a week the conjunctiva at the transition folds is thickened, injected, and presents a few shreds of mucoid secretion in its folds. The pain and irritation have increased. There may be some photophobia. The irritation is aggravated by use of the eyes.

At the end of two weeks, if the hypertrophy of the conjunctiva is not too great, numerous slight elevations which have much the color of the conjunctiva, can be made out, situated in the transition folds and frequently in the tarsal conjunctiva. The conjunctiva is much hypertrophied, and in a small percentage of the cases the granules are so hidden that they are seen only when the hypertrophy subsides. In from three to six weeks the hypertrophied condition of the conjunctiva lessens; a hyperemic condition prevails and becomes chronic. The cases are contagious from the time that the secretion appears until it disappears. The disease often appears in epidemic form. Corneal complications may occur during the second stage, and are not uncommon.

3. The third form of onset is, so far as the writer knows, confined to adults, and begins much the same as an acute conjunctivitis of not a very severe type. The eyelids are considerably swollen; the secretion, which is muco-purulent, is accompanied by much lachrymation; the *hypertrophy of the conjunctiva* is excessive, causing it to lie in large folds in the upper and lower cul-de-sacs. The ocular conjunctiva is injected, but not much hypertrophied; the caruncle and semilunar fold frequently take part in the general

thickening. None of the ordinary forms of treatment have much effect in reducing the hypertrophy, and at the end of two to four weeks it becomes evident that the large rigid folds represent one mass of lymphoid or trachomatous tissue.

Corneal irritation is experienced relatively soon in this form of the disease, and quite marked *pannus* may also occur early. This variety is eminently contagious, the type produced corresponding with this or with the second described.

The first stage of granular conjunctivitis, as described in the three types of onset, merges gradually into the *second stage*, which is one of *commencing atrophy* with the persistence of granulation tissue.

The hypertrophy of the conjunctival tissue has passed away, and bands of cicatricial tissue begin to appear (Fig. 194). The individual follicles have lost their character and have coalesced, forming larger or smaller masses; not infrequently the upper tarsus of the upper lid is one continuous plaque of lymphoid tissue. The area of the conjunctiva is considerably lessened by cicatricial contraction. The tarsus is not so wide, and is more sharply curved from above downward. The margins of the lids are thickened, the palpebral fissure narrowed (partial ptosis) and shortened. Lymphoid tissue may appear on the ocular conjunctiva or even on the cornea.

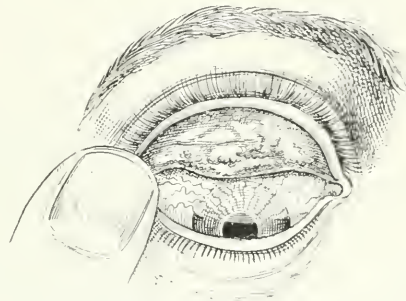


FIG. 194.—Typical granular lid and beginning cicatrization, with *pannus* (Berry).

From irritation by the rubbing of the roughened lids the corneal epithelium is disturbed, and in the effort on the part of nature to protect this membrane *vascular pannus* appears over the parts most seriously menaced (Fig. 194). When the corneal epithelium is disturbed and *superficial ulcers* are established, the irritation to the eye when exposed to light is intense, and marked photophobia is experienced. This brings on contraction of the orbicularis palpebrarum muscle and clonic or tonic spasms, with a forward bending of the head.

With a cicatricial contraction of the inner or posterior surface of the tarsus, which increases the curvature and thickens its lower half, and the forcing down of the marginal fibers of the orbicularis palpebrarum muscle, the eyelashes are made to impinge upon the cornea and *entropion* is established. Slight mucoid secretion and profuse lachrymation accompany this stage; frequently the tears and secretion flow on to the cheeks, causing more or less erosion of the epithelium of the lower lid and face.

The *third stage* is essentially one of atrophy. All lymphoid tissue has disappeared, the cicatricial contraction has partly or wholly abolished the retrotarsal folds, and the conjunctival sacs are rendered very shallow. There may remain some islets of fairly good conjunctiva and sufficient moisture to lubricate the lids. The cornea is partly or wholly opaque. In some cases the eye becomes opaque and dry (*xerosis*). Vision is greatly impaired or wholly abolished.

Although granular conjunctivitis in not a few cases pursues the course outlined above, it may also assume a much more benign type.

**Duration.**—There is great variation in the duration of all the stages of granular conjunctivitis. The first stage may give way to the second stage in

the course of three or four months; it may last six months or a year. The second stage is much more prolonged; it may never pass into the third stage. Seldom fewer than ten years are required to bring the patient to the stage of atrophy, and in most cases the individual has reached middle age before complete atrophy is established.

**Etiology.**—Bad air, overcrowding, poor and scanty food, and filth contribute largely to the development of granular conjunctivitis. It is very probable that a contagium must be added to produce the disease. It becomes epidemic in residential schools, barracks, almshouses, prisons, etc.

A micro-organism supposed to be specific has been described by Sattler and Michel. It is a small double coccus, and may be cultivated from the contents of a trachoma follicle (see Fig. 195). No satisfactory results have been reached by inoculation-experiments. Mutermileh<sup>1</sup> has described a fungus which he terms *microsporion trachomatosum*, with pure cultures of which he claims to have produced trachoma in calves and rabbits. Other micro-organisms have been mentioned as probable causative factors. Although it is thought by all who have studied the disease that it is microphytic in origin, sufficient evidence is not as yet at hand to make the belief indisputable. Parasitic protozoa have been described (Pfeiffer, Ridley).



Fig. 195.—Trachoma coccus (Michel).

So far as is known, there is no constitutional condition that predisposes to the development of granular lids. Individuals of a lymphatic condition are said to be especially prone to trachoma, but there is no good evidence upon which to base this assertion. Among certain peoples, as the Jews, Italians, Egyptians, and other inhabitants of the East, trachoma is prevalent. According to Burnett, the negro of pure blood is immune to trachoma; but his observations have apparently been confined to the negroes of our Southern States. The geographical distribution of granular lids has attracted much attention. In certain regions of the inhabited portions of the earth the disease is of extremely rare occurrence. This is true of the Scandinavian peninsula and of the southern part of California.

**Pathology and Pathological Anatomy.**—In the inflammatory cases the blood-vessels become enlarged, and apparently increase in number, accompanied by an increase in the nuclei and in the cellular elements of the conjunctiva. The papillary body becomes enlarged, the lymphoid tissue is greatly increased, and numerous small lymphoid follicles develop in the palpebral conjunctiva.

An attempt has been made to separate *folliculosis* from trachoma on histological grounds, the claim being made that in folliculosis there is an enlargement of the lymph-follicles of Krause, which normally reside in the conjunctiva. It is affirmed that the follicles in granular conjunctivitis are neoplasms, and, although anatomically identical with the follicles in folliculosis, have no connection with it. In careful studies made by the writer no such distinction has appeared to be possible. The follicle consists of aggregations of lymph-corpuseles situated immediately beneath the epithelium, having a more or less marked fibro-vascular capsule and traversed by very fine trabeculae of connective-tissue fibers; some capillaries may be traced into them. The epithelium over the follicle is irregular and slightly thickened in some parts. After the granules have coalesced the mass resembles a flattened lymphoma (Fig. 196).

The cicatricial tissue is made up of fine connective-tissue fibrillae closely

<sup>1</sup> *Annal. d'Oculistique*, Oct., 1891–May, 1892.



associated, which contract as they mature. Small *cysts* develop in the conjunctiva in the second stage in some cases of granular conjunctivitis.

**Diagnosis.**—Granular conjunctivitis may be confounded with the papilliform swellings of the transition fold which occur in acute muco-purulent and in purulent conjunctivitis, with vernal catarrh, and with the cases of fibroid or fungoid excrescences of the conjunctiva.

In the first a further observation of the case will serve to decide its nature. Vernal catarrh affords by its history, by the fact that the transition folds are relatively free, and by the peculiar character and arrangement of the elevations about the cornea sufficient data to relegate it to another class. *Fibrous* or *horny granulations* may require careful study—microscopically perhaps—to enable one who has not observed other cases to determine their nature. The masses are not *lymphomata*, but are *fibromata* with a much-thickened epithelial layer.

**Prognosis.**—This is favorable if the case is seen before much permanent impairment of vision has resulted. If seen in the first stage, a cure may be

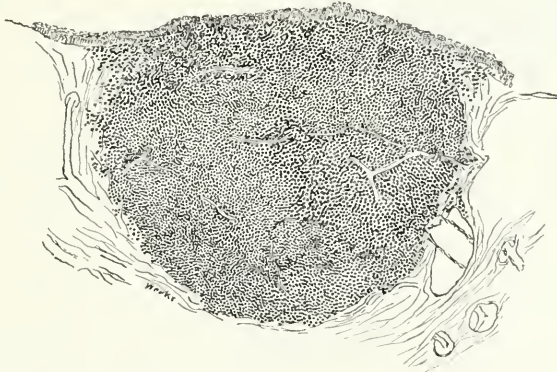


FIG. 196.—Section of a trachoma follicle, showing an ill-defined capsule containing vessels, small blood-vessels in the body of the follicle, and the immediate proximity of the epithelial cells to the lymphoid cells of the follicle (camera lucida).

effected with but little damage to any of the tissue involved. Some cicatricial tissue will develop in the conjunctiva at the site of the follicles, but the function of the eye will be but little interfered with.

In the second stage much can be done to improve the condition if treatment is instituted. If the disease is permitted to take its course, spontaneous recovery will occur in some cases, but in many *corneal ulcer*, *pannus*, *trichiasis*, and *entropion* will develop.

When the third stage is reached little can be done to improve the condition of the eye.

**Treatment.**—This is prophylactic, medicinal, and surgical.

Isolation should be practised, if possible, so long as discharge persists. Cleanliness by irrigating the eye with some bland, antiseptic, or mild germicidal solution is first to be observed, care being taken that bathing appliances used by the patient shall not be used by others. A solution of boric acid or a solution of bichlorid of mercury (1 : 10,000 or 1 : 15,000) or formalin (1 : 3000) may be employed three or four times daily, bathing ten or twenty minutes each time. A solution of bichlorid of mercury (1 : 5000 or 1 : 8000) which contains a few grains of sodium chlorid, or chlorin-water, 50 per cent., officinal, may be dropped freely into the eye after each bathing. Applications



of nitrate of silver (gr. iij to ʒj) once daily will be of much value if there is secretion.

When the acute symptoms have subsided stimulating astringent application may be made. Alum-crystal, sulphate-of-copper crystal, or the mitigated stick of nitrate of silver may be employed to lightly touch the granulations once every second day. Sulphate of copper is most generally used and gives greatest satisfaction. Not all conjunctivæ will tolerate these applications; trial will enable one to decide in which cases to employ them. In the intervals between the applications the patient should continue with the bathing and drops, using them at least three times daily. Corneal complications usually require atropin, but nothing additional. With an improvement in the lids the corneal ulcers will disappear.

Surgical treatment is of the greatest value in the early stage, and is described on page 563.

**Chronic Conjunctivitis** (*Chronic Ophthalmia*).—A thickened, congested, irritable condition of the palpebral conjunctiva sometimes persists for months after an acute conjunctivitis, accompanied by redness of the margins of the lids. A similar condition may accompany blepharitis marginalis, concretions in the lachrymal canals, atrophic or hypertrophic rhinitis, and eye-strain from errors of refraction or muscular abnormalities. The affection is more than a simple congestion, being accompanied by a scanty muco-purulent secretion.

In old people a flabby, slightly congested condition of the conjunctiva sometimes exists, also accompanied by a scanty discharge. Swelling or *hypertrophy of the caruncle* is found in almost all cases of chronic conjunctivitis.

**Treatment.**—The lachrymal and nasal passages should be carefully examined and any abnormal condition properly treated. Errors of refraction should be corrected, and the condition of the margins of the lids made favorable by proper treatment. The conjunctivitis may subside spontaneously after the successful treatment of the source of irritation, but in many cases stimulating and astringent measures must be resorted to. Applications may be made with a solution of nitrate of silver (1 per cent.) once in forty-eight hours until the secretion ceases, or with glycerol of tannin (ʒss to ʒij) sprayed on the conjunctiva once daily. Extremely light applications of sulphate of copper or alum-crystal may be made every second day. These measures, with careful cleansing two or three times daily with a solution of boric acid (3 per cent.), will in many cases effect a cure.

**Egyptian and Military Ophthalmia.**—These terms are used without discrimination to indicate acute or subacute inflammations of the conjunctiva which appear in Egypt or may affect an army. They comprise at least three distinct forms—namely, epidemic acute contagious conjunctivitis, gonorrhæal conjunctivitis,<sup>1</sup> and acute trachoma. The consideration of these diseases is found under their appropriate headings.

**Lachrymal conjunctivitis** is an inflammation of the conjunctiva accompanying dacryocystitis, and due to the presence of the irritating purulent secretion from the lachrymal sac, which contains *streptococci* (Fig. 197). The inner third of the palpebral and ocular conjunctiva is most congested, but the whole lower cul-de-sac is frequently involved. The eye is often suffused with tears and muco-purulent secretions, which, failing to escape by the tear-passages, flow over on to the cheek.

The presence of a dacryocystitis determines the *diagnosis*. It is easy,

<sup>1</sup> Koch: *Wiener med. Woch.*, 1883, 1550.

however, to overlook this cause, and it is therefore advisable to examine the condition of the lachrymal sac in all cases of conjunctivitis.

The *prognosis* is favorable if the dacryocystitis can be corrected. In some cases an ulcer of the cornea forms, becomes infected, and perforation follows, with greater or less impairment of vision.

An early correction of the dacryocystitis is advisable in all cases.

**Lithiasis conjunctivæ** is characterized by the formation of white calcareous concretions in the acini of the Meibomian glands. These concretions penetrate the epithelial layer and produce great irritation by friction on the cornea and conjunctiva. They usually accompany a gouty diathesis, and are apparently of the nature of tophi.

On everting the lids the white concretions are readily seen and recognized. The *prognosis* is good; however, new formations of similar deposits must be expected. The *treatment* consists of liberation of the concretions by incision.

**Toxic conjunctivitis** is a term employed to designate those forms of conjunctivitis that are due to the chemical action of certain substances. The following substances may be mentioned as acting in this manner: Atropin and other mydriatics, the myotics, chrysarobin, calomel, the dust from anilin dyes, fumes from menthol and formalin, and virus introduced by the bites of insects.

The conjunctivæ of some individuals do not tolerate atropin even in very weak solutions. When a few drops of a solution of atropin are introduced into the conjunctival sac of such individuals, a smarting and pricking sensation is soon experienced; the conjunctiva and lids become slightly swollen and congested. The congestion of the lid is confined to the palpebral portion, imparting a peculiar and quite characteristic appearance. More or less dryness of the throat and irritation of the nasal mucous membrane may accompany the conjunctivitis. If no more atropin is instilled, the smarting and swelling subside in twenty-four to forty-eight hours, and recovery ensues. A similar condition may follow the use of hyoseyamin, duboisin, cocain, and homatropin, but is much less apt to occur. Eserin sometimes produces congestion of the conjunctiva. If a non-sterile solution of atropin be used daily for some time, a follicular conjunctivitis, in which the follicles are largely confined to the lower cul-de-sac, may be produced. The condition responds readily to treatment after the atropin is discontinued.

Chrysarobin, when used in the form of an ointment, may produce a violent non-suppurative conjunctivitis which gradually subsides on the discontinuance of the drug.

Calomel when dusted into the eye, as in the treatment of corneal affections in one who is taking iodin in any form, undergoes a rapid change into an iodid through the action of the lachrymal fluid, and may produce marked inflammation of the conjunctiva with superficial ulcers (*calomel conjunctivitis*). If the calomel treatment is withdrawn and the conjunctival sac thoroughly cleansed, recovery will rapidly occur.

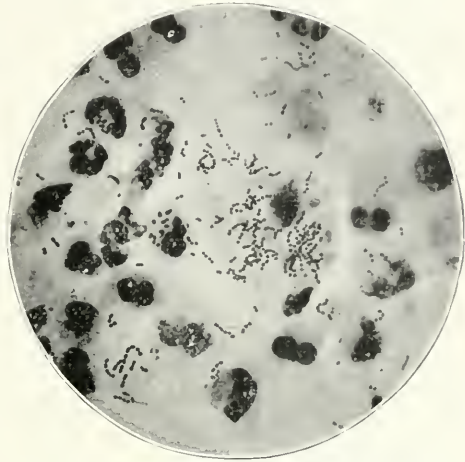


FIG. 197.—Streptococci pyogenes (Fraenkel and Pfeiffer).

The irritation occasioned by the dust from anilin dyes and the fumes from menthol and formalin will subside when the cause is removed.

The sting of the fly produces intense edematous swelling of the conjunctiva and lids, accompanied with but little secretion. Bathing with hot water to which a little biborate of sodium, bicarbonate of sodium, boric acid, or sodium chlorid is added will aid in causing the tissues to resume their normal condition. The irritation caused by caterpillar hairs produces a form of conjunctivitis to which the name *ophthalmia nodosa* has been applied (see also page 327).

**Xerosis** (*xerophthalmos*) of the conjunctiva is a condition in which the surface of the conjunctiva appears to be dry. Two forms are recognized:

(a) Xerosis due to cicatricial degeneration of the conjunctiva (*X. parenchymatosa*, *essential atrophy of the conjunctiva*).

(b) Xerosis accompanying a general disease (*X. superficialis*, *X. epithelialis*, *X. triangularis*, *X. infantilis*).

Xerosis due to cicatricial degeneration of the conjunctiva is most frequently caused by trachoma. Pemphigus, burns, and exposure of the conjunctiva to the atmosphere, as in ectropion and lagophthalmos, may produce it. Xerosis may be partial or complete. In xerosis the conjunctiva is lusterless; the dryness is due to cicatricial obliteration of secreting tissues in or connected with the conjunctiva. This affection is seldom met with in individuals who have not reached mature years. It is incurable.

Xerosis due to general disease appears both in a mild and in a severe form. The mild form is characterized by the appearance of triangular masses of a foamy, lardaceous secretion, not moistened by the tears, which are located at the margins of the cornea in the horizontal meridian. The bases of the triangles are placed next to the cornea. *Nyctalopia* (night-blindness) accompanies this condition. It appears in children and adults, and is the result of malnutrition. Inmates of prisons, soldiers in barracks or field, railroad laborers, sailors on long voyages, and those who eat a poor quality of food with but little variety for long periods of time, suffer from this affection.

A severer form, which attacks infants and very young children only, is often associated with *kerato-malacia* (see page 318). The disease extends from the conjunctiva to the cornea, producing complete destruction of that membrane. The secretion, which is of the same nature as that which appears in the mild form, first develops in the conjunctival sac and extends over the eye.

**Prognosis.**—The prognosis in the mild form is favorable. Infants and young children suffering from the severe form seldom recover.

Microscopical examination of the secretion in these cases discloses the presence in almost pure culture of a plump, short bacillus, which usually appears in pairs. This bacillus has been fully described by Löber, and was thought by him to be the pathogenic factor in the disease. Other observers have not been able to support this view.

**Treatment.**—Improvement in the nutrition of the individual is the essential measure to promote recovery.

**Amyloid Disease of the Conjunctiva.**—This disease is rarely met with in the United States. It is characterized by the appearance of yellowish, waxy, translucent masses in the conjunctival sac, taking their origin most frequently from the retrotarsal fold. The entire conjunctiva may participate in the change, the great thickening converting it into large folds which may overlap the cornea and seriously obstruct vision. The tissue is very friable and is almost devoid of blood-vessels.



**Pathology.**—The tissue is largely made up of lymphoid cells which in certain places, notably near the surface, have lost their distinctive characteristics and have undergone a hyalin degeneration, contributing to the formation of a homogeneous mass. The hyalin stage passes into an amyloid stage (Raehmann), when fresh sections give the starch-reaction in the presence of the iodine test. Sarcomatous tissue may be an element in these growths,<sup>1</sup> and osseous deposits may occur in the mass.

The *diagnosis* is easy, no other growth possessing the same appearance, and the *prognosis* is favorable if no malignant element is present. The development is slow. The treatment should consist of thorough removal of the diseased tissue.<sup>2</sup>

**Pterygium** is a peculiar fleshy mass of hypertrophied conjunctiva which develops most frequently at the inner, but occasionally at the outer, side of the eyeball. It is wedge-shaped, the base lying at the caruncle; its upper and lower borders overlap the conjunctiva, permitting of the introduction of a probe. The apex of the pterygium advances on to the cornea in the horizontal meridian, rarely passing the center of the pupil (Fig. 198). Pterygia are most frequently met with in men, and are peculiar to adult life.

**Etiology.**—Irritating particles that pass the margins of the lids and impinge upon the ocular conjunctiva first produce pingueculæ (Fuchs), and later pterygia. Miners, stone-masons, laborers, and those who inhabit countries where there is much alkali dust present the condition most frequently.

A form of pterygium known as *pseudo-ptyerygium* is also recognized. This is an irregular growth which may encroach upon the cornea from any direction. It follows burns, ulcerative processes, and injuries to the margin of the cornea.

**Pathology.**—A transverse section through the body of a pterygium shows it to be composed of loose connective tissue, rich in blood-vessels, and with more or less small-cell infiltration according to the degree of irritation. The epithelial layer is thickened. The tissue of the preceding pinguecula is embodied in that of the pterygium. At the apex of the pterygium an infiltration of small cells is found which extends for a short distance into the superficial lamellæ of the cornea. A very few fine blood-vessels also precede the advance of the growth. Micro-organisms find suitable lodgement in the folds of the tissue of the pterygium.

Pain is experienced only when the pterygium becomes inflamed. Disturbances of vision result from acquired *astigmatism* and from invasion of the pupillary area. The condition can scarcely be confounded with any other disease. If early operation is resorted to, the *prognosis* is good, but recurrence is not uncommon. After the pupillary area is invaded slight nebulous opacities and irregular astigmatism are present after the pterygium is removed.

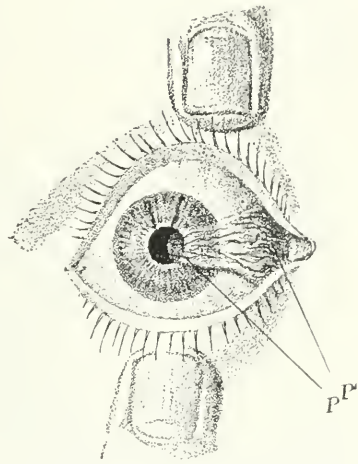


Fig. 198.—Pterygium: P, apex; P', base (Michel).

<sup>1</sup> Prout and Bull: *Archives of Ophthalmology*, vol. viii. p. 73.

<sup>2</sup> Leber has described a recurring and spreading form of conjunctival disease, characterized by the appearance of raised whitish patches, in the center of which is found a deposit of lime, to which he gives the name *conjunctivitis petrificans*.



**Treatment.**—This is always surgical—divulsion, excision, or transplantation. Early operation is advised. (See page 561 for technique.)

**Pinguecula.**—This is a small yellowish elevation in the ocular conjunctiva, situated near the inner margin of the cornea in the horizontal meridian; the growth may also occur near the outer margin of the cornea. Fuchs is of the opinion that pinguecula should be regarded as the early stage of pterygium.

The condition is apparently due to irritation produced by the presence on the ocular conjunctiva of particles of dust and small foreign bodies, and is most frequently observed in those whose occupation brings them in contact with much dust. Formerly supposed to owe its yellow color to the presence of fat-cells, it is now known to be a hyperplasia of the white and elastic connective-tissue fibers of the conjunctiva, together with a colloid substance. Its epithelial layer is considerably thickened.

The diagnosis is made without difficulty, as there is nothing for which it can be mistaken. Pinguecula may degenerate into pterygium, but in many cases remains practically without change.

**Treatment.**—The growth may be excised or destroyed by the cautery. It is not necessary to interfere in ordinary cases.

**Abscess of the conjunctiva** is an extremely rare condition. As a consequence of traumatism small abscesses may develop. A suppurating Meibomian gland may produce an abscess that opens on the conjunctival surface. Pus from a suppurative process, taking place in the orbital tissue, may bulge the conjunctiva forward and form a fluctuating tumor. These conditions, however, belong properly to other tissues. The abscess should be opened in the ordinary manner.

**Ecchymosis of the Conjunctiva** (*Subconjunctival Hemorrhage*).—This is a condition due to the exudation of blood beneath the conjunctiva, and presents the appearance of a bright-red or dark-red spot of varying dimensions with rather sharply-defined margins. The ecchymosis may affect the loose conjunctiva of the globe or lids. The conjunctiva tarsi, because of its close connection with the tarsus, does not permit the blood to pass beneath it.

**Etiology and Pathology.**—The ecchymosis may be *traumatic* in origin, following squint or other operations, blows, the entrance of a foreign body, or it may be due to the spontaneous rupture of a small subconjunctival blood-vessel (see also page 360). The *spontaneous* exudation of blood usually occurs in elderly individuals, in whom the walls of blood-vessels are undoubtedly weakened by atheromatous processes and give way, and may indicate nephritis, but is sometimes seen in children as a result of violent coughing, vomiting, etc. In certain cases of fracture of the skull through the orbit conjunctival ecchymosis occurs in the outer lower quadrant of the ocular conjunctiva. Very small ecchymotic spots accompany acute forms of conjunctivitis. The blood gradually becomes absorbed and the natural color of the tissues is restored.

**Treatment.**—Left to itself, the blood will be gradually absorbed. Absorption may be hastened by bathing the eye with water, at as high a temperature as the individual can bear, three or four times daily, for twenty or thirty minutes each time.

**Chemosis of the conjunctiva** may be active (*inflammatory*) or passive (*non-inflammatory*). It is a condition in which the ocular conjunctiva becomes thickened and raised around the margin of the cornea, forming a uniform shallow pit of which the cornea constitutes the floor.

**Etiology and Pathology.**—Inflammatory chemosis is rarely absent in

purulent conjunctivitis, and often accompanies pronounced keratitis. When the interior of the eye is the seat of an inflammatory process, as in certain forms of iridocyclitis and infection after cataract operations, chemosis is sometimes produced. It may follow the administration of potassium iodid or succeed an attack of urticaria. It is an occasional accompaniment of nephritis.

Passive chemosis is sometimes observed in alcoholic and gouty individuals.

A section of the tissue in inflammatory chemosis presents an intense infiltration of leukocytes into the subconjunctival tissue at the margin of the cornea, some thin-walled, newly-formed blood-vessels, transuded blood, and fibrin (Fig. 199). In the passive variety the leukocytes are very much less numerous, there are no newly-formed blood-vessels, and the condition is more nearly one of simple edema.

The chemosis is so great in some cases that the swollen conjunctiva overhangs the cornea and obstructs the vision; it may even protrude between the lids. There are no other symptoms added to those accompanying the con-

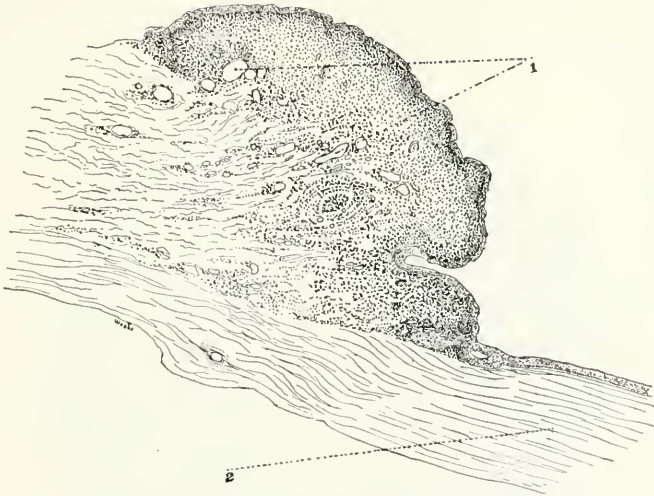


FIG. 199.—Section of the globe, showing chemosis of the conjunctiva (camera lucida). (Extensive small-cell infiltration.) 1, thin-walled blood-vessels; 2, cornea.

dition which has produced the chemosis. The chemosis subsides on subsidence of the accompanying inflammation; if it is intense, scarification may be resorted to.

**Emphysema of the Conjunctiva.**—Subconjunctival emphysema is characterized by a non-inflammatory lobulated swelling of the conjunctiva, which emits a peculiar fine crackling sound on pressure. It is due to the entrance of air beneath the conjunctiva from injuries to the lids, fracture of the margin of the orbit extending into the frontal sinus, ethmoid sinus, or nasal cavity. The air is absorbed and the condition disappears spontaneously.

**Lymphangiectasis conjunctivæ** is a benign condition which affects the ocular conjunctiva, and is of much more frequent occurrence in its outer half than in any other part. It consists of a small chain or cluster of vesicles, which vary in size from very minute ones to those the size of a grain of wheat. They are transparent, and are freely movable over the subconjunctival tissue. The cause is not known. The disease is found most frequently in those who suffer from chronic conjunctivitis. The condition is one of dila-

tation of the lymph-channels, the small pockets containing a clear fluid. The diagnosis is not difficult, as there is nothing else with which it may be confounded. The vesicles may be excised.

**Syphilis of the Conjunctiva.**—Chancre, papular syphilides, copper-colored spots, mucous patches, gummata, nodular syphilides, and syphilitic ulcer may affect the conjunctiva.

*Chancre* appears most frequently on the palpebral conjunctiva near the margin of the lid, where it presents an indurated circular red elevation of perhaps 1 centimeter in diameter, usually with a shallow ulcer at the top, having a gray base. Occurring in the transition fold or in the ocular conjunctiva, the base of the mass is distinctly indurated, and when grasped by the forceps is much like a piece of parchment lying in the mucous membrane.

Grouped *papular syphilides* are of rare occurrence; they accompany the same form of syphilide on the face and lids; the same may be said of the copper-colored spots, which are rarely seen.

*Mucous patches* are more common; they resemble the mucous patches as they appear on other mucous surfaces, are slightly raised, with a gray, even surface, and have a border of injected mucous membrane around them.

*Gummata of the conjunctiva* are extremely rare. Morrow states that they appear as small discrete tumors of the conjunctiva the size of a pea or bean.

*Gummy tumor* of the episcleral tissue and of the lids, affecting the conjunctiva, is met with. The growth is elevated and is soft. It may cause extensive destruction of tissue. It is differentiated from sarcoma by the effect produced on it by anti-syphilitic treatment.

*Nodular syphilides*, manifestations of the later stages of syphilis, sometimes occur in the lids and produce *conjunctival ulcers*. Sloughs of large extent may result. In all of the conjunctival manifestations of syphilis the preauricular and cervical glands are more or less enlarged. Pain is not a prominent feature.

If recognized early, the *prognosis* in all cases of syphilitic affections of the conjunctiva is favorable. The condition responds readily to treatment.

**Treatment.**—If an ulcerated surface exists, it may be cleansed with a weak bichlorid solution (1 : 3000 or 1 : 5000), and calomel dusted on afterward. Vigorous anti-syphilitic constitutional treatment should be given as early as possible.

**Tumors and Cysts of the Conjunctiva.**—**Congenital.**—**Dermoid Tumors.**—These usually develop near or at the sclero-corneal margin; they may be small, slightly elevated, and have a very few fine hairs projecting from them. They may cover a large part of the ocular conjunctiva, be markedly elevated, pigmented, covered with coarse hair, and contain numerous sebaceous glands. A dermoid growth sometimes develops in the conjunctiva and presents between globe and lid at the upper outer quadrant of the globe. It has much the appearance of a thickened nictitating membrane, is flat, has a rounded border, is pale, and often bears a few very fine hairs; movements of the eye downward and inward bring it readily into view. Dermoid tumors may be cystic; they may also contain much lipomatous tissue—*lipomatous dermoids*.

**Vascular Tumors.**—*Telangiectatic tumors* and *cavernomata* are observed. The former are often associated with similar growths on the lids. Both are benign, but tend to increase in size.

**Benign Tumors.**—Those that are not congenital are fibroma, lipoma, myxoma, osteoma, granuloma, papilloma, simple cystic tumors, and cysts due to cysticerci and echinococci.



*Fibromata* develop most frequently on the tarsal conjunctiva of the upper lid as a result of a chronic conjunctivitis; they are multiple, flat, and elevated one to two millimeters. *Lipoma* appears as a yellowish soft mass, usually in the retrotarsal folds. *Myxoma* appears in the form of polypoid masses developing from the margin of a wound or sinus, rarely from the conjunctival surface itself. *Osteoma* is a flat tumor developing in the ocular conjunctiva. *Granuloma* develops from wounds and from ulcerating surfaces. Papilloma is most frequently met with at the caruncle as a soft, villous mass. It may appear on any part of the ocular or palpebral conjunctiva, and is often mistaken for granulation-tissue. It is very prone to recur after removal, provided the removal is not complete. There is no tendency to the destruction of tissue. *Cystic tumors* are observed near the openings of the lachrymal ducts, in the retrotarsal fold, and at the caruncle. They are often due to chronic conjunctivitis. *Cysticercus cysts* are large, and usually present a white spot on the outer wall. *Echinococcus cysts* may be very large and extend far back into the orbit. Daughter cysts and hooklets may be found as part of the contents.

**Treatment.**—The most satisfactory treatment is excision. The vascular tumors should be removed as early as possible—the cavernomata especially—

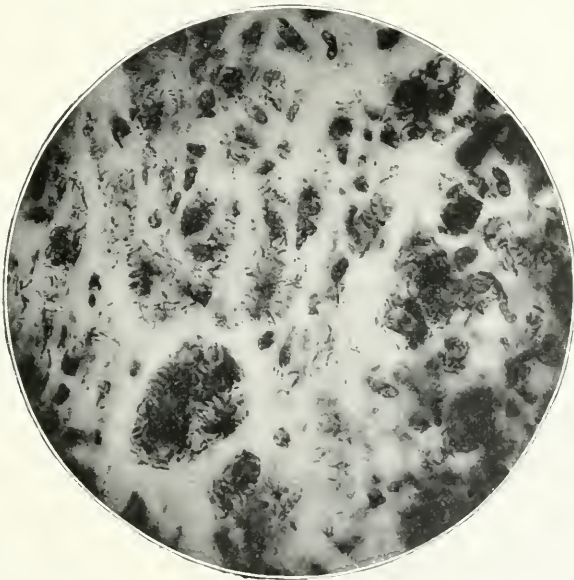


FIG. 200.—*Bacillus lepræ*, seen in a section through a subcutaneous node;  $\times 500$  (Fraenkel and Pfeiffer).

as they may reach such enormous proportions if neglected that subsequent removal is impossible.

**Malignant Tumors.**—Epithelioma and sarcoma are the most common. A peculiar tumor, known as *eylindroma*, has been described by Hensel; it is probably a form of sarcoma.

*Epithelioma of the conjunctiva* accompanies epithelioma of the lid, although it may develop spontaneously from any part of the ocular conjunctiva. It appears as a small reddish elevation which soon presents an irregular, grayish, ulcerated patch with slightly raised borders and a congested base.

*Sarcoma* may develop in the shape of *pigmented* or *non-pigmented* polypoid masses springing from the retrotarsal fold and growing rapidly. It



may also develop at the limbus conjunctivæ. It appears in this location as a small red or pigmented spot; it may develop rapidly, but may also remain in a quiet state for a long period. Metastasis to the cervical glands or to remote parts of the body may occur.

**Treatment.**—Thorough removal of all diseased tissue by knife or cauterly is the only way to make a favorable issue possible.

**Leprosy of the conjunctiva** occurs in connection with leprosy of the general system in nearly all cases; however, it may begin primarily in the conjunctiva. Morrow<sup>1</sup> cites one case in which a leprosy tubercle appeared on the eye and was mistaken for sarcoma. Cutaneous tubercles followed. Nodular masses may form in the conjunctiva which may persist for a long time, and may finally disappear, leaving non-vascular cicatricial tissue. The bacillus lepre, to which the disease is due, is represented in Fig. 200. The writer has observed a mild persistent irritation of the conjunctiva accompanying leprosy, producing slight redness of the palpebral conjunctiva and increased lachrymation. Treatment is of little avail.

**Lupus erythematosus** is mentioned by Bowen<sup>2</sup> as attacking the conjunctiva. It appears as irregular plaques which are covered with small punctate excoriations or with grayish masses of exudation and superficial cicatrices. The condition is accompanied by lupus erythematosus of the face. The etiology is obscure. The disease progresses extremely slowly, and is accompanied by slight irritation and increased lachrymation. When accompanied by the same disease on the face the diagnosis is easy. Treatment is of little avail.

**Tuberculosis of the Conjunctiva.**—This affection presents two quite distinct clinical pictures, which will be considered separately:

*First.* When tuberculosis of the conjunctiva appears as an extension from adjacent mucous or cutaneous surfaces (*lupus vulgaris*) it presents slightly elevated, irregular patches having uneven, ulcerated surfaces, from which small granulations project; the patches may be small or large, and may appear on the palpebral (where they are most frequently met with) or on the ocular conjunctiva.

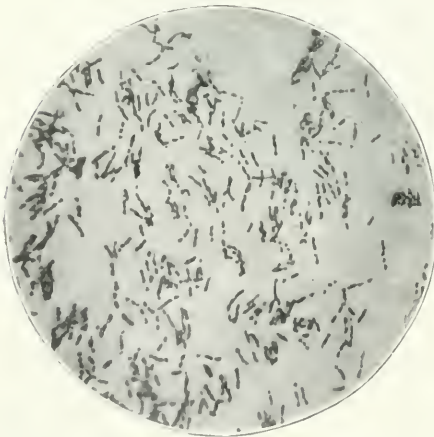


FIG. 201.—Tubercle bacillus in sputum (Fraenkel and Pfeiffer).

**Pathology.**—The tissue of the neoplasm shows loss of epithelium at the site of the ulcer, granulation-tissue, granular detritus, new-formed connective-tissue elements, giant-cells, and numerous leukocytes, which gradually diminish as the normal tissue is entered. A few *tubercle bacilli* are found in the tissue (see Fig. 201). The infection is most frequently by way of the lachrymal canals.

**Symptoms.**—There is slight irritation of the eye, accompanied by a scanty muco-purulent secretion which may persist for many months. Enlargement of the preauricular gland on the affected side is present.

**Diagnosis and Prognosis.**—The coexistence of lupus on the nasal

<sup>1</sup> *System of Diseases of the Skin—Dermatology*, vol. iii, p. 587.

<sup>2</sup> *Twentieth Century Practice of Med.*, vol. v, p. 698.

mucous membrane or on the integument of face or lids, with a history of long duration, is usually sufficient. In a large percentage of the cases the mucous membrane at the inner canthus will be involved as a result of the continuation of the disease from the lachrymal passages. The condition may be confounded with epithelioma. If doubt exists, a piece of the tissue may be excised and examined microscopically, or the iris of a rabbit may be inoculated with the tissue. The prognosis is favorable in nearly all cases.

**Treatment.**—Excision of the diseased parts or destruction by means of the cautery is indicated.

*Second.* When tuberculosis of the conjunctiva is the result of direct inoculation the early stage is marked by a distinct congestion of the conjunctiva and the appearance of numerous small, discrete, grayish nodules in the ocular or palpebral conjunctiva which do not present an ulcerated surface. The *tubercle bacilli* are commonly introduced through wounds in the conjunctiva, made either accidentally or during operation involving the conjunctiva. The nodular masses present all the characteristics of miliary tubercles.

**Symptoms.**—Marked irritation of the eye, redness of the conjunctiva, increased lachrymation, and a muco-purulent secretion are present. The disease advances quite rapidly, producing hypertrophy of the conjunctiva and superficial ulcers. The preauricular and cervical glands on the affected side enlarge and break down. Ulceration of the cornea may develop.

**Diagnosis and Prognosis.**—Acute trachoma and syphilis are the only diseases with which this form of tuberculosis may be confounded. A section of a nodule, stained for tubercle bacilli and examined microscopically, will settle the question beyond doubt. The disease runs a very long and persistent course, and may involve other parts of the system. The eye may be completely destroyed.

**Treatment.**—It is doubtful if anything short of early removal of the affected conjunctiva will have any effect. After the active enlargement of the cervical glands has been established appropriate constitutional treatment, with attention to local symptoms as they arise, is all that can be done.

**Pemphigus.**—This disease of the conjunctiva is characterized by the appearance of very transient bullæ, followed by red, and later by grayish, areas on the conjunctiva of the lids and of the globe. As these areas heal the conjunctiva becomes atrophic, other patches appear, and further atrophy takes place; soon meridional bands between lids and globe are formed, and the condition known as *symblepharon posterius* is the result. The conjunctival surface becomes dry and shiny, the cornea opaque, and vision is lost. The condition is very rare: Horner observed it but 3 times in 70,000 eye cases.

**Etiology.**—Pemphigus usually accompanies *pemphigus vulgaris* or *pemphigus foliaceus*, and depends on a dyscrasia of the system. Individuals of all ages are attacked. A history of syphilis was obtained in only 1 of the 28 cases reported by Morris and Roberts.<sup>1</sup>

**Pathology.**—The red raw surfaces evidently follow destruction of the upper layer of the epithelium due to a process which on the skin would produce blebs. The conjunctival epithelium, being thinner and much weaker, is cast off early. A deposit of fibrin soon forms over the affected area, and the grayish patch is the result. Sections of the atrophied conjunctiva show cicatricial connective tissue containing a few blood-vessels. The epithelium is thin and irregular.

**Symptoms.**—The progress of the affection is extremely slow; there is

<sup>1</sup> *Brit. Journ. of Dermatol.*, 1889, p. 175.

little secretion. With the advance in the atrophy of the conjunctiva dimness of vision increases. Both eyes are attacked.

**Prognosis.**—This is very unfavorable. The disease lasts for years, and usually results in loss of vision.

**Treatment** is of little avail. Arsenic may be given internally. Ointments and mucilaginous remedies may be employed to relieve the dryness of the conjunctiva. Surgical interference is seldom satisfactory.

**Argyria Conjunctivæ** (*Argyrosis*).—Long-continued use of nitrate of silver on the conjunctiva, particularly of a solution dropped into the eye, produces a discoloration which affects the ocular and palpebral conjunctiva, most marked in its lower half. The color varies from a light ochre hue to a deep brown. In some cases slight hypertrophy of the conjunctiva, with slight irritation, results. In one case observed by the writer the hypertrophied, non-inflamed conjunctiva formed a fold which projected into the palpebral fissure. At the request of the patient this fold was excised and the condition corrected. The stain formed is indelible. A solution of hyposulphit of sodium or of iodid of potassium in the strength of 1:10 of water has been suggested for the removal of these stains.

**Affections of the Caruncle and Semilunar Membrane.**—*Inflammation of the caruncle* is sometimes observed as a result of infection of one or more of its sebaceous glands. When this occurs the caruncle swells, becomes enlarged, and is much congested. The abscess opens spontaneously or may be opened with the knife; recovery will follow.

The hairs of the caruncle may become unusually large and numerous (*trichosis caruncular*) and produce more or less irritation. Epilation, or excision of the hair-bulb will give relief.

*Papilloma of the caruncle and semilunar fold* occurs as a pink, soft, villous mass, with numerous papillae, which are bathed in muco-pus. The mass bleeds easily and tends to increase in size. It is attended by a slight sensation as of a foreign body at the inner canthus, but gives little or no pain. Papilloma is prone to recur, and will do so unless thoroughly and completely removed. The knife or cautery should be employed.

*Congenital telangiectasia* of the caruncle has been observed.

The term *canthis* is applied to an enlargement of the caruncle and semilunar fold from any cause. Enlargement of the caruncle accompanies all forms of conjunctivitis, and subsides with the subsidence of the conjunctivitis. Cystoid enlargement is at times seen. *Adenoma* may develop. Chalky deposits may form in the glands of the caruncle, which may cause it to become enlarged. *Carcinoma* and *sarcoma* (*canthis maligna*) may develop primarily at the caruncle.

**Treatment.**—In the case of tumors at the caruncle and semilunar fold early operative procedure should be resorted to.

# DISEASES OF THE CORNEA AND SCLERA.

BY SWAN M. BURNETT, M. D., PH. D.,

OF WASHINGTON, D. C.

**Inflammation of the Cornea** (*Keratitis*).—The cornea, having no vascularization of its own, depends for its nutritive supply on the blood-vessels of the conjunctiva, sclera, iris, and ciliary body. From this it happens—first, that inflammations of these tissues are nearly always accompanied by some change in the nutrition of the cornea; and, second, that defective general nutrition is apt to be felt early in the cornea as a tissue far from the base of supplies. Keratitis, therefore, when not the direct result of a traumatism, is in the vast majority of cases the expression of some depressed general vitality or is the effect or accompaniment of an inflammation in the adjacent parts. A *primary* and isolated keratitis is a rare affection, though the participation of other tissues may be so slight as to escape detection or be veiled by the intensity of the corneal affection.

Corneal inflammations may be studied clinically from the standpoint either of their supposed etiology or by following the anatomical divisions of the affected part. For practical purposes sometimes the one method and sometimes the other has been found the more convenient.

Anatomically, the cornea is a direct continuation of other coats of the eyeball—of the conjunctiva, through its epithelial layer; of the sclera, through the substantia propria; and of the uveal tract, through the endothelial layer of Descemet's membrane. The pathological importance of this connection will be apparent when we come to consider the various individual forms of keratitis.

**Superficial Keratitis.**—The most common form of this affection is that known as *phlyctenular conjunctivitis*, *phlyctenular kerato-conjunctivitis*, or *herpes corneæ*, but more properly as *strumous* or *scrofulous ophthalmia*, because it is usually limited to the conjunctival or epithelial layer of the cornea, and is always associated with the strumous diathesis or some form of defective assimilation.

**Etiology.**—The disease is confined almost entirely to childhood. One eye or both may be affected at the same time, and a recurrence of the affection from time to time is the rule. Evidences of a strumous diathesis are seldom lacking in its subjects. There is often swelling of the preauricular and submaxillary glands; the patients are badly nourished, even when not positively anemic, and the appetite is bad or capricious. In the worst cases the scrofulous cachexia is very pronounced. Running from the nostrils, which are clogged up with dried secretions, swollen alæ nasi, thick upper lip, and excoriated cheeks make the diagnosis before the eyes are inspected. Naso-pharyngeal disease, inflammatory or obstructive, which most frequently accompanies the affection, is the etiological factor in many instances. Phlyctenular disease often follows in the wake of measles and other exanthemata. It is more aggravated in warm and moist weather.



Micro-organisms have been described, but their etiological relationship to this disease has not been established (compare with page 286).

**Objective Symptoms.**—The disease manifests itself by a small yellowish-white elevation (the *phlyctenule*) on the surface of the cornea, varying in size from 1 to 2 or 3 mm. in diameter. It may occur at any place on the corneal surface, but its usual seat is near the scleral edge, and commonly on the limbus itself. It is not uncommon for two or more of these phlyctenules to appear at the same time, and on rare occasions they are so numerous as to form a circle around the corneal base (*marginal phlyctenular keratitis*). The accompanying injection of the conjunctival vessels may be very slight, and is commonly limited to a leash of vessels running up to and ending in the *phlyctenule* (Fig. 202).

On the other hand, and especially when the spot is farther in on the corneal surface and the deeper structures are involved, the conjunctival congestion is more general. Oftentimes the accompanying conjunctivitis assumes

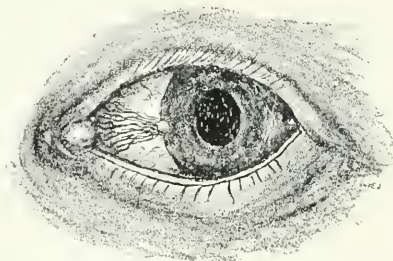


FIG. 202.—Scrofulous ophthalmia (phlyctenula corneae).

the form of a more or less muco-purulent type. The intensity of the accompanying conjunctival participation, however, bears, as a rule, no proportion to the local lesion on the cornea.

**Subjective Symptoms.**—The subjective symptoms vary greatly in intensity. In the milder cases there is little or no pain, and a feeling of discomfort and an inability to use the eyes as much as customary are about all that is complained of.

In severe cases, which occur especially in children, the symptoms are of the most intense kind. There is a photophobia which makes the child keep the eyes tightly shut (*blepharospasm*), and which may persist for weeks, rendering even forcible separation of the lids difficult (see also page 253). The child seeks the darkest corner of the room, buries its head deep in the pillow, and violently resists every effort to bring it into the light. The *lacrimation* is profuse, and the cheeks are excoriated with the constant overflow of irritating tears.

Between this and the mildest form there is every gradation; moreover, the intensity of the symptoms does not bear any proportion to the extent of the pathological change. A single phlyctenule may be attended with more pronounced subjective symptoms than three or four, and the severity differs in different attacks in the same person. This can be accounted for partly, no doubt, by the fact that in the one case the exudate presses on the terminal filaments of the nerve distributed among the cells of the epithelial layer, causing these intense reflex phenomena, and in the other it does not. Another important factor, too, is the generally hyperesthetic condition of the patient, due, most likely, to defective nutrition of the nerve-centers.

**Pathology.** Pathologically, the phlyctenule is not a vesicle with fluid contents, as its appearance would indicate. Under the epithelium there is found a collection of small round lymphoid cells, as shown in Fig. 203. The anterior epithelial wall of the phlyctenule breaks down; the cells are discharged, leaving a *small, superficial ulcer (phlyctenular ulcer)*, which is generally rapidly covered over by a fresh layer of epithelium, and the diseased process is ended for the time, usually leaving no trace unless the deeper

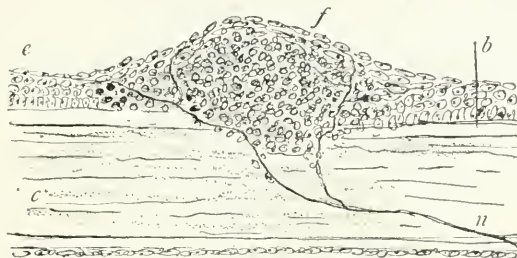


FIG. 203.—Phlyctenule; *b*, Bowman's layer; *c*, corneal substance; *d*, Descemet's membrane; *e*, epithelium; *f*, phlyctenule, consisting of a deposit of round-cells in the epithelial layer and along the course of the nerve; *n*, twig of nerve ending in epithelium (modified from Iwanoff).

structures of the cornea are involved, when there is likely to be more or less opacity remaining for a time or, it may be, permanently.

**Diagnosis and Prognosis.**—Direct inspection reveals the nature of the disease. The *prognosis* depends on the type. It is essentially a relapsing disease; repeated attacks may leave the corneal epithelium roughened and scarred, and sometimes covered with vessels, the so-called *phlyctenular pannus*.

**Treatment.**—In the treatment of the affection attention to the general condition is of greatest importance. A persistent and long-continued use of tonics and nutrients—among which iron (syrup of the iodid) and cod-liver oil are perhaps the best—is the first requisite as regards medication. But most important is the regulation of the diet and habits of the child. Only nutritious food should be allowed—milk, meat (except pork and veal) in moderate quantity, vegetables (except potatoes in excess), with abstinence from sweets and pastries. Good fruit may be allowed in proper quantities.

The child should live out of doors as much as possible in spite of the photophobia, and the function of the skin should be kept in proper order by frequent bathing. Any associated nasal affection should receive prompt and thorough attention, and the naso-lachrymal passages should be kept patulous.

Locally, in the first or acute stage, atropin drops (gr. iv- $\bar{5}$ j) are to be used, and where there is much photophobia an equal amount of muriate of cocain can be added. A drop of this solution is to be put in the eye three times a day or every four hours according to the intensity of the symptoms. The eye should be bathed in water as hot as can be borne for five minutes every four hours.

In the second stage, after the rupture of the phlyctenule and the process of restoration has begun, the insufflation of finely-powdered calomel is a time-honored remedy, as is also Pagenstecher's salve (hydrarg. oxid. flav., gr. j, petrolat.  $\bar{5}$ j or ij) put under the eyelid and rubbed over the ball. In very mild cases, where there is no photophobia, lachrymation, or other sign of irritation, a simple antiseptic collyrium, such as boric acid or borate of sodium, gr. x to  $\bar{5}$ j, will suffice, with care in the use of the eyes. The eyes should never be bandaged, protection from the excessive light being secured by colored glasses or a shade.

In the severest cases the blepharospasm is so intense as to require especial attention. When it has once become a fixed habit it is difficult to break up, and its presence undoubtedly prolongs the disease. It sometimes yields to the instillation of cocain, but in long-standing cases this will not suffice. In these instances the most efficient means is to plunge the face in a basin of cold water and hold it there a few moments. The shock of this violent procedure will usually relieve the spasm, and the child will, on removal from the water, open its eyes widely. Forceible dilatation of the eyelids by an eye-speculum for a short period each day has been recommended. The excoriations at the angles of the lids no doubt keep up the blepharospasm through reflex action, and should be cured as promptly as possible. After the disease has subsided any refractive error should be corrected, as eye-strain may excite an attack in an eye predisposed to this disorder.

**Pannus.**—Vascularity of the superficial layers of the cornea is often an accompaniment of trachoma or of one of its sequels—ciatricial entropion or trichiasis.

When the vascularity and thickening accompany the first stages of the disease, before the period of cicatrization has arrived, there are grounds for believing that the pannus is but an expression of the trachomatous process itself—*i. e.* a true trachoma of the conjunctival layer of the cornea—and not a secondary effect. In such cases the thickening is much greater than when

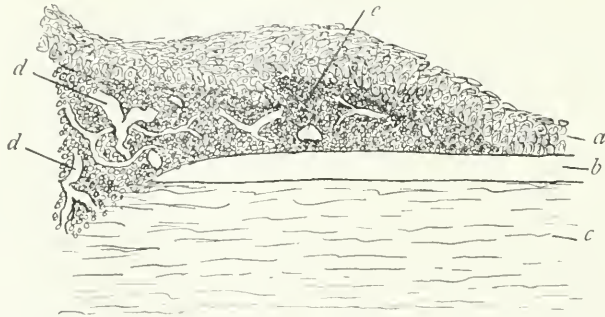


FIG. 204.—Pannus (after Iwanoff): *c*, the cornea; *b*, Bowman's membrane; *a*, thickened layer of epithelium; *d*, blood-vessels; *e*, infiltration of round-cells.

it is due to mechanical irritation by trichiasis or the rough cicatricial conjunctiva (see also page 291).

The denser forms of pannus have been called *pannus crassus*—the thinner, *pannus tenuis*. In *pannus tenuis* the blood-vessels are confined to the superficial layers, and there is not much infiltration or thickening of the epithelial layer; but in the denser form the infiltration may involve the deeper layers of the substantia propria (Fig. 204). The entire surface of the cornea may be covered, and the thickening so dense that the iris can no longer be distinguished. In the lighter forms only a part of the cornea may be involved, and in that case it is usually the upper portion.

It is seldom that a case of pannus runs its course without more or less loss of tissue, or ulceration. Occasionally, however, the pathological condition is one only of *hypernutrition*, characterized by the formation of new blood-vessels and connective tissue, and if there is no destruction of the substantia propria, the process may end with a complete absorption of the foreign material, leaving the cornea quite clear.

**Treatment.**—As the condition is usually secondary to some other patho-



logical process—trachoma, trichiasis, etc.—the treatment must be mainly directed against these affections. The existence of a pannus is no bar to the prompt and energetic treatment of these conditions; on the contrary, it improves *pari passu* with the amelioration of the original cause. Atropin, with cocain sometimes added (atrop. sulph. cocain. mur.,  $\bar{a}\bar{a}$ , gr. iv- $\bar{5}$ ), and hot applications are the remedies proper to the relief of the symptoms of pain and photophobia, of which the corneal trouble is the immediate cause.

When the vascularization and opacity persist in any degree after the removal of the original cause, remedial measures addressed to the condition itself become necessary. These consist in diminishing, or in some manner cutting off, the blood-supply to the newly-formed tissue in the cornea or assisting in its absorption by the natural processes. The former may be accomplished directly by dissecting a narrow band of conjunctival tissue, 2 mm. wide, from around the base of the cornea (*peritomy*), or, as has been suggested, by cauterizing the tissues deeply with the actual or galvanocautery.

The production of a violent inflammation of the conjunctiva by means of an infusion of or the powder of the *jequirity bean* had at one time quite a vogue in the treatment of pannus, but some unfortunate cases of total destruction of the cornea from its excessive action have caused it to fall into disuse except among a very few surgeons. The same may be said of inoculations with gonorrhœal matter, which at one time were used, particularly in Belgium.

*Curetting* the surface of the cornea, especially in the earlier stages and before entropion or trichiasis has set in, can be practised with great benefit. For the less serious cases the ointment of the yellow amorphous oxid of mercury (gr. j- $\bar{5}$ ij), rubbed under the lids once or twice a day, assists in the process of absorption. For the same purpose insufflation of finely-powdered calomel is a remedy of old and established value.

**Resorption or Transparent Ulcer of the Cornea.**—A loss of tissue on the corneal surface, usually not very deep nor extensive, and not associated with any opacity of the corneal substance, is known as a "resorption ulcer."

The distinguishing characteristics are its transparency and the smoothness of its surface, which is covered by normal epithelium.

The usual seat of the ulcer is near the center of the cornea. There is commonly but little lachrymation or photophobia, and there is scarcely any increased vascularization of the conjunctiva. An ulcer of this character is most common among the old and enfeebled, and is usually slow in healing. A slight traumatism is most probably the originating cause.

The ulcer usually heals without other interference than protection—with atropin and hot applications when the subjective symptoms are more pronounced than usual. In the chronic cases eserin has been found useful. The lesion may become converted into a true ulcer, with a tendency to spread through necrosis of the tissue.

When situated over the pupil a transparent ulcer gives rise to great disturbance of vision, quite as much so as an opacity of the same size, on account of the diffraction and diffusion of light through its irregular surface.

**Herpes Corneæ** (*Vesicular Keratitis*).—In those cases of *herpes frontalis* where the nasal twig of the fifth pair is affected and a vesicle is formed along the side of the nose, it is rare to have the cornea unaffected.

A vesicle containing a clear fluid forms on the surface of the cornea, ruptures early, and leaves a *superficial ulcer* or epithelial denudation, with infiltration and opacity of the surrounding parts. It is accompanied with



much pain of a neuralgic character, photophobia, and lachrymation. Occasionally, however, these violent symptoms are absent. The cornea itself is usually more or less anesthetic to touch, and the tension of the eyeball is diminished.

The vesicle differs from a phlyctenule of serofulous conjunctivitis, with which it is sometimes confounded on account of the name *herpes conjunctivæ* by which the latter was formerly known, in that it is larger and its contents are fluid. Some opacity of the cornea nearly always remains (see also page 287).

**Treatment.**—The treatment is palliative—atropin alone or combined with cocain, hot applications, and an anodyne internally when the pain is exhausting. The general condition usually requires tonics and a sustaining nourishment. The author has found the salicylate of sodium in large doses useful in controlling pain and mitigating the severity of the disease. It has been suggested to scrape the ulcers and cauterize them, but unless they show a marked tendency to spread this course is not advisable.

Vesicles on the cornea have sometimes been found associated with *herpes labialis* or *nasalis*, especially in children, to which the name *herpes febrilis* has been given. The symptoms exhibit less intensity than those just described; there is little or no anesthesia of the cornea, and the globe-tension is not changed. These vesicles have been seen during malarial fevers. They all, however, seem to depend on some derangement of the central nervous system.

**Dendritic Keratitis.**—This name has been given to a species of superficial keratitis of a peculiar arborescent form (Fig. 205).

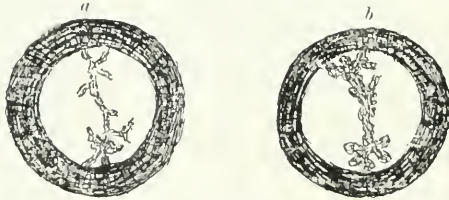


FIG. 205.—Dendritiform keratitis (after Galenga): *a*, first stage; *b*, seventeen days after.

It begins as a small vesicle, and continues its growth by a series of newly-formed contiguous vesicles which break down into small ulcers, forming irregular lines which give the distinctive name to the disease (Galenga, Homer).

**Etiology.**—Some authors regard the affection as mycotic, and no doubt micro-organisms are found in it, but none that are peculiar to it. It has been found associated with malaria (Kipp and others), and syphilis has been assigned as a cause by some writers. It seems most probable that the disease is the expression of a dyscrasia of some kind.

The ulceration occupies by preference the central portion of the cornea. The course of the disease is usually slow, and though, for the most part, not very annoying, is occasionally very painful and associated with severe supra-orbital neuralgia and tenderness, depending on the depth of the ulceration and the amount of involvement of the terminal filaments of the nerves.

**Treatment.**—This consists in rest, protective spectacles, atropin, and hot applications. Should there be a marked tendency to spread or an obstinacy in healing under the above treatment, the ulcer should be scraped and 1 : 60 formalin solution applied, or in severe cases the actual cautery. Quinin and arsenic internally are useful. Galvanism along the supraorbital nerve has been suggested.

**Filamentous Keratitis.**—On rare occasions, after rupture of corneal vesicles, a rope-like body is seen attached to the surface of the ulcer, its free end being frayed (Fig. 206). This is the *filamentous keratitis* of Leber and Nuel. It consists of epithelial cells and coagulated fibrin twisted into the form of a cord.

**Superficial Punctate Keratitis.**—Under the head of superficial keratitis must also be admitted a form of corneal inflammation called by Fuchs *keratitis punctata superficialis* (Syns.: *Keratitis subepithelialis centralis*; *Keratitis maculosa*; *Noduli corneæ*; *Reclapsing herpes corneæ*).

The alterations in the cornea consist of small gray dots arranged in groups or short rows in the superficial layers, mostly near the center. The disease begins with a rather pronounced catarrhal conjunctivitis, and is usually associated with catarrhal disease of the respiratory tract. The dots remain sometimes for weeks. Stellwag has described a similar affection, the foci of larger size being found in the periphery of the cornea. There is much pain, and iritis may develop (*annular keratitis*).

**Treatment.**—Hot applications, atropin, and protection of the eye with dark glasses.

**Fascicular Keratitis** (*Keratitis in Bandolette*).—This affection, which bears a resemblance to the phlyctenular form of keratitis, and of which it may be a modified form, is characterized by a band or leash of vessels, with a narrow border of opaque corneal tissue, which traverses the surface of the cornea to end near the center in a small round whitish-yellow head (Fig. 207).

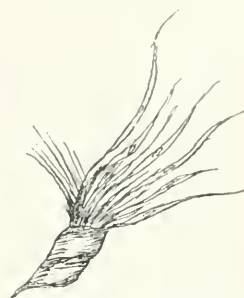


FIG. 206.—Filamentous keratitis (after Panas).

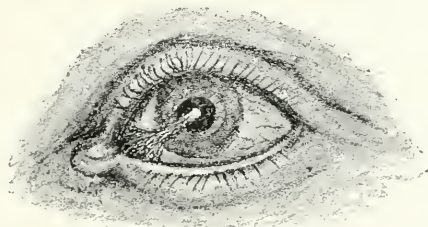


FIG. 207.—Fascicular keratitis.

On disappearance of the vessels a more or less opaque band or streak is usually left on the cornea. More than one of these bands may appear at the same time or develop consecutively. The *treatment* is the same as that suited to keratitis in general.

**Bullous Keratitis.**—In eyes whose nutrition has been seriously interfered with, as it is likely to be in glaucoma, irido-cyclitis, or choroiditis, an extensive elevation of the epithelium is sometimes observed at or near the center of the cornea. The bleb, thus formed, is usually partially filled with a clear fluid which gravitates to the bottom, giving it a baggy appearance. The same phenomenon has also been observed a few times in eyes that are not thus disorganized. There is slight pericorneal injection, but the pain is usually quite severe and of a more or less intermittent character. The anterior layers of the cornea are seldom exempt from implication.

The disease seems to be purely local in character, not depending upon the general condition, as does, for instance, *vesicular keratitis*.

A *recurrent form* following injuries has been noted by Hansen Grut.

Fuchs and some others seem to think that the elevation of the epithelium is due to an obstruction in the lymph-circulation.

**Treatment.**—The disease is to be treated by instillations of atropin, except where glaucoma is present or feared, when eserin ( $\frac{1}{2}$  to  $\frac{1}{4}$  gr.— $\bar{5}$ j) can be used instead, and by hot applications for the mitigation of pain, with an opiate or other anodyne if it does not yield to these mild measures. Should an ulcer form with a tendency to spread, it can be touched with formalin, 1:60, or with the actual cautery. In the milder forms insufflations of iodoform act with good effect on the ulcer and the pain. Cocain can be used in moderation. A protective bandage is usually beneficial.

**Suppurative Inflammations of the Cornea or Suppurative Keratitis.**—Purulent inflammations of the cornea form the most important category of its diseases, because of their immediate and remote dangers.

Suppuration of the corneal tissue is always followed by ulceration or destruction of the substance, leaving invariably an opaque cicatrix as a sequel, thus annulling one of its most necessary qualities—its transparency.

These inflammations may not only eventuate in a total destruction of the cornea itself, but on occasion lead to an involvement of the whole eyeball, ending in its disorganization. They demand our most earnest attention, moreover, from the fact that they are truly infectious in their nature, and are, thus far, to be classed among the preventable diseases.

**Etiology and Pathology.**—We know, since the great work of Leber,<sup>1</sup> that for the genuine infecting process we must have a micro-organism, and that usually it is introduced from without. For this reason these infectious affections of the cornea are common among those working out of doors and in the dust, as laborers, harvesters, etc. But not only must we have the organism, but also the soil made ready for the seed, and the tissue must be in a condition to serve as a proper nidus for the growth and development of the particular micro-organism present.

Few organisms are able to obtain a foothold upon a perfectly healthy tissue, with the power to throw out white blood-corpuscles to act as phagocytes. The wounded normal corneal tissue always heals without suppuration when free from any infecting organism. The epithelium of the cornea, when intact, interposes an almost insuperable barrier to the entrance of germs, and when we find an infection we may be almost certain that a destruction of epithelium has preceded it. The important practical lesson to be learned from this is, that with proper precaution and early attention many, if not most, of these destructive suppurations can be avoided.

All injuries and wounds to the cornea should be promptly treated by disinfection, or at least by thorough and frequent cleansing with an aseptic liquid, as boric acid or mild bichlorid or weak formalin solutions. Bandaging the eye closely under these conditions is of doubtful wisdom. The heat of the bandage hastens the development of what germs may yet remain in the conjunctival sac or on the lid-margins. An absolute disinfection of these parts has not yet been found possible by any safe procedure.

For clinical purposes suppurative diseases of the cornea can be considered under several heads, based on their etiology, course, particular complications, and special features; but the general characteristics are the same in all, and all begin in essentially the same manner.

There is first noted at the place of infection an infiltration of a pearly-gray color which rapidly turns to a creamy yellow. This infiltration spreads to a greater or less extent, remaining circumscribed only in a genuine "ab-

<sup>1</sup> *Die Entstehung der Entzündung*, Leipzig, 1891.



cess." In the eroding or serpiginous forms this extension is sometimes very rapid. On the other hand, it may be slow, but steady in its progress. The part of the cornea affected loses its vitality, sloughs off, and an *ulcer* is formed. This destructive action of the micro-organism is arrested, it is claimed, by the phagocytic power of the white blood-corpuscles. A limit is thus set to the invasion of sound tissue, and the healing begins by the re-formation of epithelium at the edge of the ulcer. The process of reparation goes on, when the loss of tissue is not extensive, to a complete restoration of the original form, but usually with a substance not of the nature of the true corneal tissue. It is cicatricial in character, and not transparent, except perhaps in those cases where the destruction is very limited in extent. The membrane of Bowman is never re-formed when it is once destroyed, but the epithelium is very readily re-established. While the pathological processes in all cases of suppuration are essentially those just recited, for the purposes of clinical study and treatment they have been classified under several distinct varieties.

**Abscess of the Cornea.**—This is a simple circumscribed collection of pus in the corneal substance, usually some distance from the scleral edges.

It is most commonly seen as a sequel or continuation of a phlyctenule on the surface, the throwing off of the epithelium opening up the way to an infection of the deeper parts. The subjective *symptoms* are the same as in other forms of keratitis. It terminates by a breaking down of its anterior wall and a discharge of its contents, becoming thereby an *open ulcer*, which under favorable circumstances heals in a few days, and, if the loss of tissue is not great, leaving little opacity. It may be induced by any other means that destroy the epithelial layer, such as small wounds, foreign bodies, etc. The so-called *ring abscess*, where the suppuration extends around the base of the cornea, is seen mostly after cataract operations.

**Treatment.**—The proper treatment is hot applications, atropin solution (gr. iv- $\bar{5}$ ), a drop three times a day, with rest and protection of the eyes. A spontaneous rupture is usually allowed. When the ulcer is formed its healing is expedited by aseptic applications of weak formalin solution, 1 : 2000, or boric-acid solution, or other means to be mentioned in succeeding paragraphs.

**Ulceration of the cornea**, or destruction of the corneal substance, is the essential feature of all forms of *suppurative keratitis*.

**Varieties.**—The forms of corneal ulceration, from a clinical standpoint, depend upon its seat, its cause, its course, and its association with other pathological conditions. Thus we have the *sthenic* and *asthenic* ulceration, according as the accompanying vascularization and other symptoms of irritation are considerable or mild; *marginal* ulceration, when it is seated near the margin of the cornea; *serpiginous* ulceration, when it creeps over the surface of the cornea, invading successively the adjoining areas; *keratitis with hypopyon*, when associated with the presence of pus in the anterior chamber; and other distinctive titles. Moreover, all these varieties, or any number of them, may be only different or successive phases of the same attack. In all, the essential clinical features are the same, modified, however, by the particular circumstances of individual cases.

Under this head may be mentioned a rare form of chronic *creeping ulcer*, which begins near the margin of the cornea and progresses in a crescentic form without any pronounced suppuration or hypopyon, never leading to perforation, but followed by dense cicatricial opacities. To this the name *rodent ulcer* has been given.

A form of spreading keratitis is observed very often in those engaged in shucking oysters—the so-called *oyster-shucker's keratitis*. It was thought to



be a purely infectious disease until Randolph of Baltimore demonstrated that it was not, but a mechanical keratitis caused by the fine particles of lime of the oyster-shell. The *harvester's keratitis* is probably first mechanical and afterward microbial.

**Etiology.**—The immediate causes of destructive ulcers of the cornea are usually infecting wounds or injuries of some kind, including operations, such as cataract extraction, iridectomy, and other operations involving the cornea. Anything that destroys the epithelium opens up the way to the entrance of infecting micro-organisms. These germs may be introduced at the time of injury or they may enter later. Two factors are necessary for development of the process—the germ and the soil. As there are always germs in the conjunctival sac, or as they can easily get entrance there, some of which may be pyogenic, any injury of the cornea is liable to take on an ulcerative action if the tissue is in a condition of non-resistance, as, for instance, in the case of weak, poorly-nourished people. The progress of the ulceration may be very brief, the reparative process setting in in a few days, or it may continue for weeks without showing any tendency to heal, or may extend itself slowly, but persistently, into the sound tissue.

The germs most commonly found as the active agents primary in corneal ulcerations are the usual pyogenic forms—principally *staphylococcus* and *streptococcus* (see Figs. 192 and 197)—but Uthoff, Axenfeld, and others have recently (1896) found the *pneumococcus* in great abundance in serpent ulcers (Plate 2, Fig. IV.), and Leber has found a form of *aspergillus* in some cases. Probably the most frequent cause of large destruction of the cornea is the *gonococcus* of Neisser found in purulent ophthalmia of gonorrhoeal origin (see article on the Conjunctiva).

**Symptoms and Course.**—An ulcer begins with a focus of infection, noticeable as a superficial defect with ragged edges of a yellow color and surrounded by a zone of infiltrated cornea. Its sides and bottom are covered by a detritus of dead corneal tissue, having a yellow pultaceous appearance. The accompanying vascularization of the conjunctiva varies greatly. In some instances it is pronounced, the swelling of the tissue around the base of the cornea in the vicinity of the ulcer being very marked.

There are at times great photophobia and much lachrymation and pain, which, however, in the indolent forms may be lacking almost entirely.

In the *serpiginous form* the ulceration spreads gradually over the surface, and usually with increasing depth. Then some time during its course there is an appearance of pus in the bottom of the anterior chamber—*hypopyon* (Fig. 208). This may occur while the ulcer is still central and there is yet clear cornea between it and the scleral margin. It was held at one time that it was necessary to have a perforation of the posterior wall of the ulcer through the membrane of Descemet in order that pus might find its way into the anterior chamber. The researches of Leber have shown, however, that the pus-cells may gravitate down through the sound corneal tissue and pass into the anterior chamber at the iris angle, or they may originate at this point from a participation of the nveal tract in the inflammatory process. In certain cases no doubt there is a small perforation of Descemet's membrane.

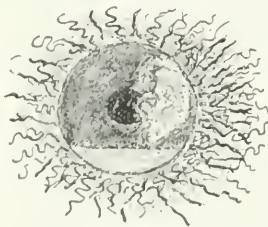

FIG. 208.—Large serpiginous ulcer with hypopyon.

The destruction of tissue may be very extensive, covering the entire anterior surface, leaving the posterior layers and

the membrane of Descemet intact; in which case there will be no *perforation*. In most cases, however, this is the event, and we have as a consequence a new set of phenomena and complications.

With the opening of the anterior chamber the aqueous humor escapes; the iris falls forward against the posterior wall of the cornea, plugs up the opening, and in course of time may become united to it by adhesive inflammation (*anterior synechia*). The anterior chamber then refills, leaving this portion of the iris in front of the mass of aqueous humor. If the opening is large enough, the pressure from behind is sufficient to push the iris through the opening and form a bag of greater or less size in the site of the ulcer. We then have *perforation with prolapse of the iris*.

It may happen that the pyogenic germs entering the anterior chamber find a suitable nidus for their development in the iris, ciliary body, and choroid, and, setting up a purulent inflammation in these tissues, bring about the condition of *panophthalmitis*, leading to final *atrophy of the eyeball*. There is no case of hypopyon probably in which the iris is not more or less affected.

**Prognosis.**—From what has been said it may be inferred that the prognosis depends upon the activity of the morbid agent and the ability of the tissues to resist its encroachment. In the old and feeble it is much more serious than in the young and strong.

**Treatment.**—Suppurative keratitis being an infectious disease, the treatment should be both preventive and therapeutic. Every injury of the cornea should be considered as if it were infected. The conjunctival sac should be thoroughly cleansed with an aseptic liquid, as a saturated boric-acid solution or formalin 1 : 2000, and kept as aseptic as possible. The seat of injury itself should be touched with a 1 : 60 formalin solution, or nitrate of silver (gr. xx- $\bar{5}$ j), or tincture of iodine, when there is strong suspicion of infection, and, where it is reasonably certain, with the actual cautery. The treatment of the ulcer when it has declared itself should be antiseptic and palliative. The surface of the ulcer should be touched with a 1 : 60 formalin solution once a day so long as there seems to be any tendency to spread. Formerly the author was accustomed to use full-strength carbolic acid for this purpose with good effect. Mules recommends iodoform applied on a wafer of gelatin directly to the ulcer, bandaging the eye to keep it in place. The iodoform may be dusted directly on the ulcer, but this is less efficacious. When the serpiginous character becomes pronounced, the actual cautery applied to the edges and bottom of the ulcer becomes necessary. This must be done under cocaine. It is well to scrape away as much dead tissue as possible with a sharp spoon before applying either the cautery or the formalin caustic solution. Tincture of iodine and nitrate of silver (gr. xx- $\bar{5}$ j) are also applied to the curetted area. The cauterization may be repeated every two or three days, according to the urgency of the symptoms. Curetting of the ulcer while a fine spray of a 2 per cent. solution of boric acid is directed against its surface has been recommended. Sämisch recommended an incision into the anterior chamber through the sides and bottom of the ulcer in the serpiginous form, and this operation is still performed by many surgeons. Its performance before a hypopyon is formed is in the majority of cases not advisable, since it makes easy the entrance of germs into the interior of the eye. In cases of hypopyon this objection does not hold to the same extent. It is often necessary to let out the pus when present in large quantity, and in these cases the incision should be made as low down as possible (see also p. 567).

Quite recently the *subconjunctival injections* of bichlorid of mercury have had many advocates. A few drops of 1 : 2000 solution are injected under

the conjunctiva once a day or every other day. The operation is generally very painful, even under cocain. Others have found the injection of a normal salt solution quite as effective. As palliatives atropin and cocain are the main reliance. The latter should be used only for the temporary relief of pain and the lowering of intraocular tension. Eserin in weak solution ( $\frac{1}{3}$  to  $\frac{1}{2}$  gr. ad  $\bar{5}$ j) is used for the same purpose if iritis is not a complication.

As a palliative and curative agent heat is most valuable. As the morbid process is to be stopped, or at least retarded, by the phagocytic action of the white blood-corpuscles, a determination of fresh blood to the part, with dilatation of the vessels, is all important. Heat accomplishes this, and the best form of application is fomentation with water as hot as it can be borne for five minutes every three or four hours. The immersion of the eye in a goblet or glass of hot water, as recommended by Leartus Conner of Detroit, is an elegant and most efficient way of administering heat.

The eye should not be bandaged, except when the ulcer is very deep and there is danger of spontaneous rupture, under which circumstances the *dry antiseptic pressure bandage* is effective.

In cases of perforation the management is little different, except as to the treatment of the *prolapse of the iris*. When the prolapse is not large and is situated peripherally, and does not involve the sphincter, eserin should be substituted for atropin. Its myotic action tends to draw the iris out of the wound, and often quite successfully. If the condition of the conjunctiva warrants it, a pressure bandage aids in reducing a hernia of the iris. The prolapsed iris should not be excised or punctured, certainly not until the suppurative process has ended, and then only under strictest asepsis. Even very large prolapses smoothe down in time.

Careful attention must be paid to the general condition of the patient, particularly in the old and feeble. Tonics, and even stimulants, with the most nutritious diet, are indicated.

There are two forms of secondary purulent keratitis which require a brief separate mention :

(1) **Ulcerations following Purulent Conjunctivitis.**—Under these circumstances the two most potent factors are united in the development of the disease in its most destructive form—namely, the presence of an infecting germ and a denuded and macerated condition of the epithelium, with diminished nutrition of the cornea from the pressure of the chemosis on the surrounding nutritive vessels. The ulceration usually begins at the periphery of the cornea under a fold of overlapping chemosis. Quite often, however, it commences near the center, and occasionally there is a necrosis of the whole cornea at once from the cutting off of its nutritive supply by pressure—a true *sphacelus cornea*—when the entire tissue becomes yellow and breaks down into a pul-taceous mass. The presence of the corneal ulcer, however great its extent, is not a bar to the most energetic treatment of the conjunctival disease (see also page 279). The ulceration is apt to be deeper than in other forms, especially at the periphery, and there is an earlier prolapse of the iris. Often the whole iris seems to bulge forward either as a mass—*keratocele*—or through numerous perforations in the apparently clear cornea—the so-called mulberry appearance—and the eye seems doomed to destruction. There is, however, in many of these cases quite a quantity of sound corneal tissue remaining. The membrane of Descemet resists destruction for a long while, and eyes that seemed lost regain their form and some part of their function.

In cases of peripheral perforation eserin is to be used, while in other



forms atropin and antiseptics, with hot applications, should constitute the main local treatment.

(2) **Neuro-paralytic Keratitis.**—The other form of secondary keratitis is that associated with paralysis of the fifth pair of cranial nerves, the so-called *neuro-paralytic keratitis*. When the fifth nerve, particularly the part containing fibers of the sympathetic, is divided in animals, in a short time the cornea on that side begins to ulcerate, and soon passes on to total destruction. The same thing is likely to occur in man when the fifth nerve is from any cause paralyzed, and particularly when the branch of the seventh going to the orbicularis is at the same time involved.

It has been a point in dispute whether the ulceration is due to interference with nutrition from injury to the trophic filaments in the fifth pair, or is simply the result of the traumatic injuries inflicted on the insensitive cornea on account of its constant exposure from the paralysis of the orbicularis. It would seem from a careful sifting of the evidence that both factors play a part. Injury to the trophic nerves seriously impairs the resisting power of the corneal tissue, and, it may be in some instances, is of itself sufficient to bring about destructive inflammation, independent of serious injury, for we see the ulceration sometimes when the orbicularis is intact. On the other hand, we have paralysis of the orbicularis without corneal ulceration.

The process usually begins as a marginal ulcer, with deep injection of the conjunctiva, and spreads gradually over the whole cornea, the tissue breaking down into a soft yellow mass. On occasion the process seems to arrest itself, and a small amount of clear cornea is left. It is usually painless, and not accompanied by photophobia or lachrymation.

The course is slow and prognosis serious, a total destruction of the cornea being the result to be expected.

**Treatment** is wholly palliative, protection of the eyes by bandage or stitching the lids and cleanliness being the main features in the therapeutics. Tonics and a nutritious diet are nearly always demanded.

After removal of the Gasserian ganglion Dr. W. W. Keen and Dr. de Schweinitz recommend primarily stitching of the lids, and when the first dressing is made the application of a Buller's shield, which remains for a week or more. With these precautions they have prevented corneal ulcer after complete excision of the ganglion. Destructive ulceration of the cornea is the result most to be feared in *diphtheria* of the conjunctiva (page 284).

**Keratitis e Lagophthalmo.**—When the cornea is continuously exposed from any cause its epithelium desiccates and falls off, and there is a liability to the entrance of germs with an infective keratitis as a result.

The affection has been observed in excessive exophthalmos, destruction of, or cicatricial contraction of the eyelids, paralysis of the orbicularis, etc.

The keratitis pursues practically the same course as neuro-paralytic ophthalmia, though not usually with the same rapidity or malignancy, and responds more promptly to treatment.

**Treatment.**—This consists in removing the cause when possible, and usually by some operation on the lids. In case this cannot be done a protective bandage must be constantly used. In the slighter forms of lagophthalmos the bandage should always be applied at night, and all such eyes should be protected against dust, wind, smoke, and other irritating influences. The treatment of the keratitis itself is the same as that indicated for keratitis in general.

**Corneal Ulcers in Small-pox.**—In the days prior to vaccination



destruction of the cornea from small-pox was one of the most common forms of blindness. Happily, it is not often encountered now.

True *vaccinal abscess* differs from ordinary abscess in that it is generally endogenous, being simply the appearance of a variolous pustule on the cornea itself. That it may be due to secondary infection is, however, possible, especially if the cornea becomes involved after the stage of eruption is passed.

The treatment is the same as that for other forms of purulent keratitis.

**Keratomalacia.**—This is a form of destructive corneal trouble met with mostly in badly-nourished infants and children, though adults with vital powers greatly reduced by lack of proper food are also liable to be attacked. It is seen accompanying meningitis, variola, measles, and severe diarrhea or dysentery.

**Symptoms.**—It is always associated with *xerosis of the conjunctiva* (page 296). There is great dryness of the conjunctiva, which is covered in spots with a froth-like material that is found upon examination to consist of fatty matter and epithelial cells. The lachrymal secretion is deficient or entirely lacking. The cornea becomes dry and cloudy from a drying of its epithelium, and soon shows evidences of breaking down at the center. This disintegration is of the color of pus, and sometimes extends very rapidly, destroying the cornea in the course of a few hours. Sometimes, however, it requires several days to accomplish this. It may even happen in mild cases that the whole tissue is not destroyed. There is, in those who are old enough to express themselves, a pronounced *night-blindness* at the beginning of the affection. This, as well as the other characteristic symptoms, gives evidence of a lack of nutrition at the nerve-centers.

Microbes of various kinds have been found in the secretions, but they are probably not the essential cause of the disease, but only find in it a nidus for growth. The one most frequently found is a small bacillus, the so-called *pseudo-diphtheria bacillus*, and is often present in large numbers.

The prognosis is most unfavorable; the patients frequently succumb to the disease which has caused the keratitis or to an intercurrent pneumonia.

**Treatment.**—The first object in treatment is to improve the nutrition as rapidly as possible by the most nourishing foods, tonics, etc. The eye itself should be treated with hot fomentations, mild aseptic washes. Caustics are seldom called for. On account of the insensitiveness of the eyes and the tendency of the lids to remain open, a bandage is necessary for protection.

**Tuberculosis of the Cornea.**—*Primary tuberculosis* of the cornea is a rare affection. The cornea, however, usually participates more or less in the conjunctival form of that affection (page 302).

**Symptoms.**—In the few cases that have been reported it has begun as an interstitial opacification, commencing at the edge and progressing toward the center of the cornea. In this affected area there are to be seen small yellowish-white granules like miliary tubercles, which coalesce and finally break down, and are thrown off, leaving an ulcer usually without hypopyon. A bacteriological examination or experimental inoculation will usually demonstrate the character of the disease.

The treatment is the same as that for other ulcers, only demanding an early scraping or destruction by caustics of the affected tissues.

**Interstitial or Parenchymatous Keratitis** (*Syphilitic, Inherited, Specific, Diffuse Interstitial Keratitis*).—In contradistinction to the destructive forms of corneal inflammation we have been considering, this form does not lead, as a rule, to a loss of corneal tissue. Moreover, it is always the man-

ifestation of a systemic derangement, and usually some form of dyscrasia, hereditary syphilis being the most common. Its association with acquired syphilis is uncommon, nor does scrofula usually manifest itself by this form of corneal inflammation.

**Etiology.**—We owe to Hutchinson the discovery of the intimate connection of keratitis parenchymatosa with inherited syphilis. The ground taken by him nearly forty years ago is still maintained by a large part of the ablest clinicians.

Still, it may be questioned whether all cases of interstitial keratitis are syphilitic. Von Hippel has found the disease very frequent in people of a tuberculous taint with no history of inherited syphilis. Of 87 cases, 23 were syphilitic and 15 doubtful; 18 tuberculous and 8 doubtful—other cases uncertain. Parinaud found 96 per cent. of his cases syphilitic; Despagne, 14 per cent.; Seklassy, 30 per cent.; Bosse, 44 cases in 54.

The syphilitic cases are generally marked by definite and peculiar features. As regards the mother, there are rarely absent histories of abortions or early death of other children, and those now living show more or less evidence of being affected. Probably the most characteristic appearance is on the part of the permanent teeth. The central upper incisors have notched edges and are peg-shaped, the so-called "Hutchinson's teeth." This shape is due to defective nutrition and the breaking away of the enamel. There are often nodosities on the tibia, and the frontal tuberosities are unusually prominent. There are often deep scars around the angles of the mouth and the alae nasi. It is usual to describe the skin as being coarse, but the author's observation is that it is commonly unusually fine and velvety in texture. This is particularly noticeable in the negro race. A less common accompaniment is that of deafness. Synovitis of the knee-joint may be a complication, and there are likely to be other evidences of faulty nutrition. The disease is commonest between the ages of five and fifteen, occurring occasionally as early as the third year and rarely as late as the sixtieth year. A *congenital form* has been described. In female children it is apt to appear about the supervention of menstruation.

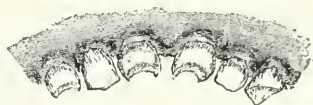

FIG. 209.—Form of the upper teeth in keratitis parenchymatosa (after Hutchinson).

Cases occurring in persons above thirty years of age are not, as a rule, due to syphilis, but to some other dyscrasia, as rheumatism, gout, and possibly tuberculosis, or the climacteric.

**Symptoms.**—The disease begins as a grayish opacity in the substance of the cornea, sometimes at more than one place, and gradually extends in typical cases until the whole of the tissue is involved. This opacity is so dense in fully-developed cases as to entirely veil the iris from view, and is generally quite uniform, though a close inspection will reveal foci of more intense infiltration.

At the beginning the epithelium is intact and the surface of the cornea has its normal glistening look, but later it becomes rough like ground glass, showing a disturbance in the arrangement of its epithelial cells.

In a form to which the name *circumscript* or *discrete* has been given there may be several spots at some distance from each other and apparently unconnected. An examination with oblique illumination and a magnifier, however, will nearly always show some fine streaks of opacity connecting them.

In this discrete form, which is more frequently found in the rheumatic diathesis and in women about the climacteric, there is nearly always a per-

manent opacity remaining after the disease has subsided, more especially when the spots are near the scleral border (Fig. 211).

During the very early stage of the infiltration there is no great increase

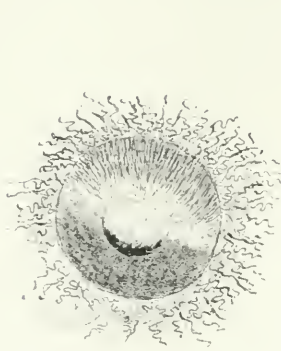

FIG. 210.—Interstitial keratitis, with commencing vascularization.

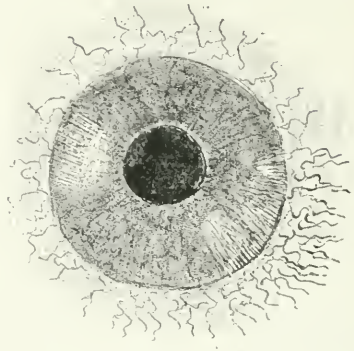


FIG. 211.—Circumscribed interstitial keratitis (author's case).

in the vascularization of the conjunctiva, nor are photophobia and lachrymation very pronounced.

The *second stage*, that of vascularization, is almost always attended with symptoms of irritation. This vascularization of the infiltration is the natural process for its absorption. Its manner of invasion is characteristic and distinctive. The vessels, which are very fine and delicate, are seen to penetrate deeply into the substance of the cornea at its periphery. On account

of their fineness and compactness they seem, as seen through the hazy corneal tissue, almost like an extravasation of blood into its substance—the “salmon patch” of Hutchinson.

The vascularization usually advances *pari passu* with the progress of the infiltration across the cornea, and that is usually from above downward, so that by the time the infiltration reaches the opposite side the cornea looks like a piece of raw beef—the *vascular keratitis* of some writers. This may have required weeks or even months, for tediousness is a prime characteristic of the affection (Fig. 210).

The accompanying symptoms may be mild, giving rise to but little pain. In most cases, however, there are considerable pain of a neuralgic character and lachrymation, and there are generally indications of the




FIG. 212.—Section of the cornea in parenchymatous keratitis: *a*, epithelial layer; *b*, Bowman's membrane; *c*, membrane of Descemet with deposit of round-cells, *c*, on its posterior surface; *d*, blood-vessels; *f*, infiltration and dislocation of the corneal layers (modified from Nordenskjöld).

involvement of the uveal tract. In fact, few cases run their course without an implication of the iris, ciliary body, or choroid, or all three. Stellwag designated the disease as “*anterior uveitis*.” We must remember that the cornea is connected directly with the uveal tract through the endothelial



layer of Descemet's membrane. Unfortunately, the condition of the cornea does not allow us to examine carefully into the state of the iris, but after the opacity has cleared up we are apt to find evidence of iritis. Retinitis and optic neuritis may occur, and secondary glaucoma is not uncommon.

All cases, however, do not run such a typical course. A part of the cornea may be attacked, vascularize, and clear up, and then another and another, until the whole tissue has been successively affected. The process may occasionally stop after an attack on a limited portion. A number of cases of an *atypical form*, which are not properly forms of interstitial keratitis, have been reported in which the opacities are stripe-like or ring-like. These present the appearance of pus in the corneal layers, the so-called *abscess-forms*, or they may appear as a *central annular* lesion. On rare occasions *ulceration* and *hypopyon* are accompanying conditions, but should be regarded as incidental complications.

**Prognosis.**—The course of the disease is invariably slow, and, as the eyes are liable to be affected in succession and the same eye experience more than one attack, many months or even years may not see the end. And yet the prognosis *quoad visum* is generally good, and particularly is this so when the uveal tract is not seriously involved. In many cases the cornea clears up almost perfectly, though an examination with oblique illumination and corneal loup will reveal some faint streaks of opacity; indeed, years after an attack of interstitial keratitis minute vessel-channels, nearly straight, branching at acute angles and short bends, may be detected in the cornea. These are best studied with the ophthalmoscope, after dilating the pupil, through a strong convex glass (+ 16 D.) (Fig. 213). The process of resolution always begins at the periphery of the cornea.

**Treatment.**—The disease is essentially self-limited, and we can do but little to shorten its course. Yet we are not without resource for the allevia-

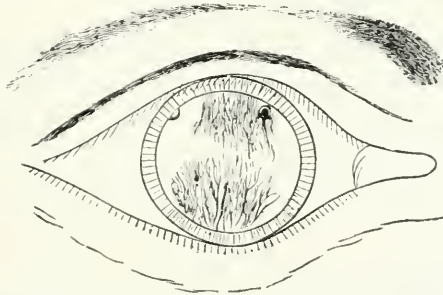


FIG. 213.—Vessel-formation in the cornea after interstitial keratitis (Hirschberg).

tion of its uncomfortable symptoms and measures to encourage a favorable issue of the disease. As resolution takes place through vascularization, means which increase this are in order, and chief among them are hot applications. The eye should be bathed in water as hot as can be borne for five minutes every four hours. This also assists in relieving any pain that may be present. Atropin, 1 per cent. solution, dropped in the eye three times a day is beneficial, not only for the corneal affection, but also for the iritis which may be present. When the long-continued use of atropin sets up a papillary inflammation of the conjunctiva—which it may do on very rare occasions—hyoscyanin, scopolamin, or daturin may be substituted for it. Being a diathetic disease, general treatment is all-important, especially iron, arsenic, and cod-liver oil. Tonics and good nourishment are called for in cases of debility, while



rheumatism and gout and tuberculosis require their appropriate treatment. In those cases where hereditary syphilis is evident or suspected, specific treatment is demanded, but not of a vigorous kind. The simplest form of administration is bichlorid of mercury gr.  $\frac{1}{60}$  and iodid of potassium gr. ij, after each meal. These remedies are well borne for many months. Inunctions of mercury are not usually called for except in very severe and well-pronounced cases. In the practice of some surgeons they constitute the basis of treatment in the majority of cases. The patient should be encouraged to go out of doors as much as possible, protecting the eyes with blue or gray glasses. Recently subconjunctival injections of bichlorid of mercury have been advocated quite strongly in certain quarters, as have those of normal salt solution, used in the same manner. The severe pain which has been found to accompany their employment is a great bar to their general use.

**Results of Corneal Inflammation.**—*Opacities of the Cornea.*—The outcome of an inflammation of the cornea as regards its *restitutio ad integrum* of transparency depends largely upon whether it is of the destructive form or not. A pannus or interstitial keratitis can continue for months or even years, and yet the cornea clear up almost perfectly, provided there has been no loss of substance replaced by cicatricial tissue. But even in the interstitial form there can be an organization of the effused material, taking on the character of connective tissue, which does not become transparent. Indeed, in the most favorable cases there are always fine streaks of opacity to be discovered by oblique illumination and the magnifier (see page 146).

Where there has been any considerable loss of tissue the rule is for an opacity to remain, the cicatricial material which replaces the lost corneal tissue never becoming transparent. The presence or activity of the corneal epithelium seems to exercise a favorable influence on the reproduction of the clear corneal substance. The clearing up of the opacity proceeds from the periphery toward the center.

Opacities have always been classified, according to their intensities, into *nebulae* or *maculae*, the slighter forms, and *leukomata*, the denser forms. When after a perforation of the cornea there is prolapse of the iris, with adhesion to the wound, we have the condition known as *adherent leukoma*.

The amount of damage to perfect vision caused by an opacity depends largely upon its situation, and to some extent upon its density. A small, sharply-defined, dense opacity over the pupil, however, will disturb vision less than a thinner one, which allows a greater amount of light to go through, but diffuses it more.

The course and final condition of a corneal opacity depend largely upon the age of the patient and the depth of the destructive process. In young people the chances of a clearing up are much better than in elderly ones, and the smaller and more superficial the ulcer the greater the probability of an ultimate clarification.

**Treatment.**—The treatment of corneal opacities is directed to an assistance in the absorption of the effused material. This requires usually some means which increases temporarily the vascularization of the part and stimulates the absorbents. Insufflation of finely-powdered calomel once a day is an old remedy. Another form of mercury much used is the yellow amorphous oxid, gr. j ad  $\bar{5}$ j of cosmolin—"Pagenstecher's ointment"—a small bit to be rubbed under the lids once a day or every other day (*massage of the cornea*). Turpentine oil moderated with sweet oil has been used for the same purpose. In fact, everything which increases the blood-supply of the conjunctiva has been used, and with some show of success. The value of

the constant current of *electricity* applied to the cornea for this purpose has doubtless its basis in the same quality.

The attempt to remove opacities by operation is of course futile, since the removed tissue will be replaced by cicatricial tissue, except in those cases where the trouble is limited to the epithelial layer, as where there are deposits of lime, lead, etc., and in some cases of superficial pannus.

For cases of total leukoma of the cornea or large central opacities covering the pupil, with no room for an artificial pupil at the periphery, *transplantation of a portion of the cornea of rabbits* or other animals was first suggested by Reissinger in 1824, and revived by von Hippel in 1876. It cannot be said, however, that any brilliant permanent success has followed the attempts made thus far.

In case of leukoma adherens it may be necessary to loosen the iris from its adhesion to the cicatrix for optical purposes, or to free the eye from a source of constant irritation. An iridectomy is often called for when the opacity covers the pupil, even when there is no incarceration of the iris, for optical purposes.

In permanent opacity the disfiguring appearance can be much mitigated by the process of *tattooing* the white spot with India ink.

**Changes in the Form of the Cornea.**—While inflammations of the cornea may subside without any change in the form of the cornea, even when a considerable opacity remains, in a large number of cases, and especially in those where there has been a considerable loss of tissue or even long-continued infiltration, the original shape is seldom retained, and sometimes the change is enormous. This alteration may be in the manner of *flattening*—or of *bulging*—*staphyloma*.

(1) *Flattening of the cornea* most frequently follows upon total destruction or large losses of the corneal tissue, and especially in those cases where the uveal tract has been involved and the nutrition of the eye interfered with, accompanied by reduced tension of the eyeball. The iris is found in such cases plastered against the posterior wall of the remnant of the cornea, some portion of which may still be transparent. The flattening may be of any grade, from that discernible only by means of the ophthalmometer to that associated with a more or less complete atrophy of the eyeball.

(2) *Bulging of the Cornea.*—*Staphyloma* has various qualifying terms, denoting special characteristics. It may be *partial* or *complete*, *conical*, *globose*, or *racemose*, the latter name signifying a number of small protrusions linked together around the periphery of the cornea. A general enlargement of the eyeball (*hydrophthalmos*) (Fig. 214) is very often associated with these conditions and always indicates the participation of the iris and choroid in the inflammatory process. The iris may be attached to it either partially, as in *adherent leukoma*, or completely, as in some forms of *keratoglobus*.

All staphylomata indicate an increased tension of the eyeball at some time. The structure of a staphyloma is by no means uniform. Its walls may be thin or very thick, and sometimes the apex undergoes ulceration or degeneration of the calcareous or colloid form; and it is always liable to attacks of inflammation.

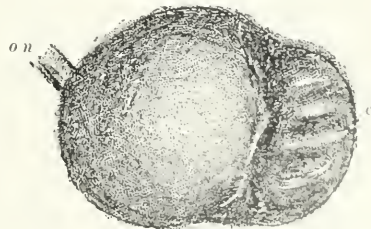


FIG. 214.—Hydrophthalmos after ophthalmia neonatorum: c, cornea; o n, optic nerve. (From a patient in the Children's Hospital, Washington.)

**Treatment.**—The therapeutics of staphylomata is preventive and surgical.

The former is applicable only during its stage of formation, when a pressure bandage should be applied to support the weak tissue. Paracentesis, sometimes repeated, by lessening the intraocular tension, removes an important factor in its production. Eserin can be used for the same end.

When a staphyloma has become so large as to be unsightly, or is a source of annoyance or pain, surgical interference of some kind is the only remedy: enucleation of the eye, abscission of the staphyloma, or evisceration.

Enucleation should be avoided when possible in children, among whom staphyloma so frequently occurs as a consequence of conjunctivitis neonatorum. The presence of the eyeball seems to be necessary to the proper development of the orbit, and an artificial eye is difficult to adapt to very young children. In cases of excessive hydrophthalmos the operation of evisceration finds its best field of application. Evisceration, with the introduction of a glass ball within the sclera (Mules's operation), gives an excellent support for an artificial eye (see page 572).

(3) *Cystoid Cicatrix.*—The condition of union between the tissues at the scleral border in some cases of adherent leukoma can be such as to form a circumscribed cystic elevation the walls of which may give way at times, discharging the contents of the aqueous chamber—the so-called *cystoid cicatrix*; or the opening may not close at all, constituting a *fistula*, through which the aqueous humor constantly leaks, sometimes under the conjunctiva, causing a *chemosis pallida*. Similar phenomena may arise after the operation of iridectomy.

These conditions are usually very rebellious to treatment, which is for the most part surgical, consisting in cauterization, the formation of conjunctival flaps over the parts, or cutting away a part of the walls of the cyst and procuring a firm adhesion between the edges of the wound. An iridectomy sometimes helps much.

(4) *Astigmatism.*—The changes in the form of the cornea are commonly so irregular (*irregular astigmatism*) that it is not possible to correct the optical defect by any form of lens in such manner as to improve vision materially. Changes are occasionally so regular, however, as to allow this to be done, and here the ophthalmometer becomes a valuable aid in diagnosis. With the suggestion afforded by this examination it is often possible to double or treble the visual acuteness (see also page 231).

When the intraocular pressure is reduced to any considerable degree the cornea feels the diminished tension, and manifests it by an altered curvature, sometimes in the nature of *wrinkling*. This is very apparent in many forms of atrophy. In cyclitis associated with reduced eye-tension it is nearly always demonstrable by the ophthalmometer, or Placido's disk. Fig. 215 gives the corneal reflection of Placido's disk in such a case. The cornea resumed its normal shape when the tension was restored.

**Sclerosing Keratitis.**—A special form of corneal opacity is associated with long-continued *scleritis* and *irido-choroiditis*.

It begins in the former case as a triangular bit of bluish-white tint, with its base on the sclera, its apex toward the center of the cornea. The change is interstitial, the epithelium seldom undergoing any alteration. When following long-continued inflammation of the uveal tract, with depressed nutrition of the eyes, the opacity sometimes extends as a band wholly or partially around the corneal circumference, as shown in Fig. 216, taken from a case under the author's own observation. Baumgartner and Berlin have found that the corneal tissue has undergone fatty and hyalin degeneration with what appears to be in some instances adenoïd tissue.



Treatment is of no avail, though the galvano-cautery applied to the base of the lesion has been recommended.

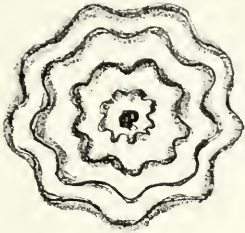


FIG. 215.—Wrinkling of the cornea; reflection of Placido's disk.

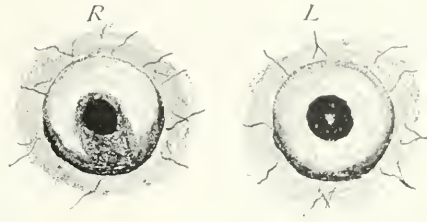


FIG. 216.—Sclerosing keratitis in both eyes from irido-choroiditis (author's case).

**Ribbon-shaped Keratitis** (*Primary Transverse Opacity of Cornea; Zonular Opacity; Keratitis Bandelette*).—This is a rare form of corneal opacity, not due to an inflammation of the cornea itself, but associated with or following some kind of ocular malnutrition, caused by irido-choroiditis, glaucoma, or a gouty tendency.

The lesion is situated directly in the palpebral aperture, where the cornea is most exposed, and consists of finely punctiform opacities under the epithe-

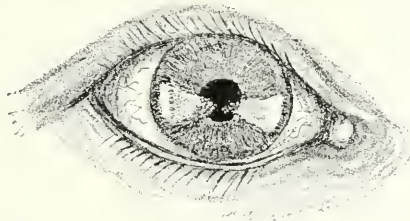


FIG. 217.—Keratitis bandelette (after von Graefe).

lium of the cornea. It begins sometimes on one side, sometimes on the other, leaving a small area of clear tissue at the periphery, and progresses steadily toward the pupil, over which the two bands usually meet in time (Fig. 217). Some cases have been observed in which it began in the center. Both corneae are liable to be affected in time. It occurs mostly in men. After the epithelium is removed the deposit can be flaked off, leaving, as a rule, clear cornea beneath. The deposit is either the phosphate or carbonate of lime. Its removal in this manner is the only treatment. Atropin should be avoided in such eyes, on account of their tendency to glaucoma.

**Striped Keratitis.**—A peculiar form of opacity of the cornea is sometimes noticed after cataract extraction, but has been observed also after other forms of injury or inflammation of the cornea. It consists of fine, straight stripes  $\frac{1}{2}$  to 1 mm. in width, focussing toward the seat of injury. The intervening corneal tissue may be comparatively clear, in which case the lines will appear as grayish stripes against the darker background of the iris (Fig. 218). There may be two or more sets of lines crossing each other, making a sort of panel figure (Fig. 219).

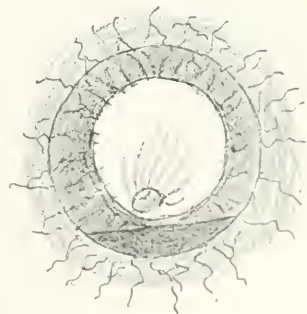


FIG. 218.—Striped keratitis with humor and hypopyon (after Schirmer).

They were once thought to be dilated by lymph-channels (Becker, Reck-



linghausen) or infiltration of the large nerve-canals (Alt). They are caused, however, by a folding of the membrane of Descemet, due to a shrinking of the corneal tissue in cicatrization or its unequal swelling in infiltration (Mull, Hess, Schirmer) (Fig. 220). They usually disappear, but traces of them may

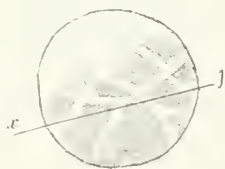

FIG. 219.—Panel-like opacities of the cornea (after Schirmer).

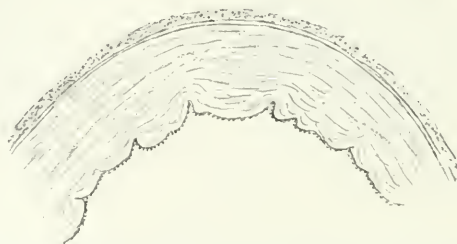

FIG. 220.—Section of the cornea showing the folds of the membrane of Descemet in panel-like opacity of the cornea (after Schirmer).

remain in the form of *geometrical figures* (Fridenberg). The folding of Bowman's membrane may give the same appearance.

**Corneal Opacities due to Metallic Deposits.**—The salts of lead coming in contact with the albumin of the cornea denuded of its epithelium are sublimated in the form of an opaque albuminate. Such deposits were of much more frequent occurrence when lead lotions were used more commonly than now in corneal ulcers. The epithelium usually forms over it. The deposit can be scraped off after the epithelium is removed, leaving usually a moderately clear cornea beneath.

Nitrate of silver also leaves a stain when applied to the substantia propria for a long while. A brilliant metallic luster has also been observed in opacities of the cornea the results of injuries.

**Arcus Senilis.**—An arc of opacity 1 to 1.5 mm. in width is very commonly seen at the base of the cornea in old people. It may entirely circle the cornea. There is usually a narrow strip of clear cornea between it and the sclera. It is sometimes met with in comparatively young persons. In the negro race it is usually very pronounced. It is a colloidal degeneration of the superficial layers of the cornea. When incised it heals as readily as normal corneal tissue.

**Transient Corneal Opacities.**—Sudden and severe pressure on the cornea causes a derangement of its fibers which impairs its transparency. This is observed in severe blows directly on the cornea and in acute attacks of glaucoma. This disappears in a short time when the pressure is relieved.

Rampoldi (1881) has described a temporary form of opacity due to *infiltration of the corneal tissue with lymph*. It occurs in anemic persons or those affected with lymphatism. It may extend to the anterior chamber, forming hypopyon, or into Tenon's capsule. It may be called up or increased by a dependent position of the head.

Cocain causes a dryness and opacity of the epithelium, and even its detachment from Bowman's membrane, when applied too long with exposure of the cornea to air. The corneal epithelium in old glaucoma is nearly always dull and irregular.

**Blood-staining of the Cornea.**—A number of cases have been observed after traumatism in which the cornea has been infiltrated with blood; it is of a chocolate or greenish-brown color at the central parts, passing off into a reddish tinge at the periphery. The appearances closely resemble those of an amber-colored lens dislocated into the anterior chamber. The *hema-*

*toidin* deposited in the substantia propria, which gives this color, is absorbed very slowly, at least two years elapsing before its entire disappearance.

**Keratitis Nodosa.**—When the poisonous spines of certain caterpillars get into the eye, they set up an inflammation which is peculiar in that it is in the form of nodules which very much resemble tubercles. While more commonly found in the conjunctiva, the nodules occur also in the cornea, and pass sometimes into the iris. They never break down and discharge, but in time disappear by absorption (see also page 296).

No attempt should be made to excise the nodes from the cornea. They should be treated as secondary keratitis with heat and atropin.

**Keratitis Punctata** (*Aquo-capsulitis, Descemetitis*).—Small whitish deposits are observed on the posterior surface of the cornea in that form of iritis known as *serous iritis*, and have been considered by some authors as a form of iritis or irido-cyclitis. As the anterior surface of the iris and the posterior surface of the cornea are lined by a continuous layer of endothelial cells, converting, in fact, the anterior chamber into a closed or serous sac, there is some ground for this view; and in these cases, almost without exception, both cornea and iris are involved, sometimes, however, one more than the other. In some instances there is a marked plastic iritis accompanying or following the appearance of the dots in the cornea. Though the dots are usually arranged in a pyramidal shape, base down, they are often irregularly placed (Fig. 221). The deposits vary in size from a millimeter or so in diameter to a microscopic point. They consist of inflammatory exudate with a quantity of endothelial cells (Fig. 222). Snellen, Jr., is reported to have found a microbe in the deposits, but this observation has not been confirmed by others. The exudate is sometimes found in the iris angle and in the choroid. Oblique illumination and a magnifier are often necessary to determine its presence in the cornea. A general haziness of the

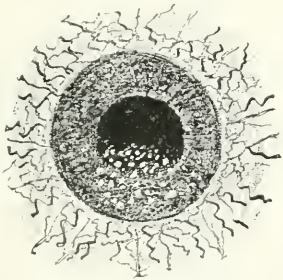


FIG. 221.—Descemetitis or keratitis punctata.

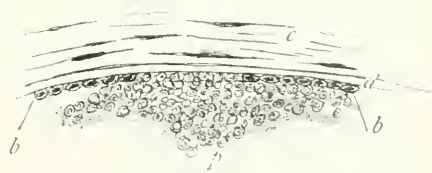


FIG. 222.—Deposit on the posterior surface of the cornea in punctate keratitis; *b*, endothelial cells; *c*, cornea; *d*, Descemet's membrane; *p*, deposit of round-cells (after Fuchs).

cornea or a limited part of it is manifest on illumination of the fundus with the ophthalmoscope. Usually there is no pain, the pupil is commonly somewhat dilated, and the intraocular tension slightly increased. Vision is usually much impaired.

**Treatment.**—Atropin must be avoided unless there is an active plastic iritis. The progress of the disease is usually very slow, months sometimes being required for the disappearance of the deposits. Mild doses of bichlorid of mercury, continued for a long while, seem to be followed by better results than any other therapeutics.

**Non-inflammatory Changes in the Form of the Cornea.**—Changes in the form of the cornea from the normal—which is really that of a triaxial ellipsoid, but not very markedly departing from that of a sphere—are known as *astigmatism*. Those changes which influence the optical properties of the eye that can be neutralized are treated of in the chapter

on Refraction. These forms usually are congenital, and remain unchanged during life.

There are other forms, however, which appear to be acquired, though not associated with any inflammatory affection. They are usually classed under the general heading of *Keratoconus* or *Conical Cornea*, from the fact that they always assume a form approximating that of a cone. The cone, however, is generally quite irregular. One case has fallen under the author's observation in which the curve of the vertical meridian was such that in the upper part of the pupil there was myopic astigmatism, and in the lower half hyperopic astigmatism. The apex of the cone is not always in the center of the cornea.

Except in a few cases, perhaps, keratoconus is not congenital, but begins to develop usually about the seventh or eighth year, though often later, reaching its climax not long after the establishment of puberty. Women are more often affected than men. The appearance of a well-marked case is shown in Fig. 223.

When less pronounced the abnormal curve cannot be detected by simple inspection, but is easily made manifest by the keratoscope (Placido's disk, see page 145). This is held in front of the eye or attached to the ophthalmometer of Javal, and its reflection on the cornea at its different parts observed. Instead of being approximately circular at the center, as it should be in the normal cornea, it has some modification of the appearances shown in Fig. 224.

Illumination of the fundus, as in examination by the "shadow test," shows, instead of a uniform reddish tint of the pupillary area, a dark spot, usually crescentic in form, in the red area, which changes with each movement of the mirror or eye.

The gradual change of form




FIG. 223.—Keratoconus. Pronounced case.

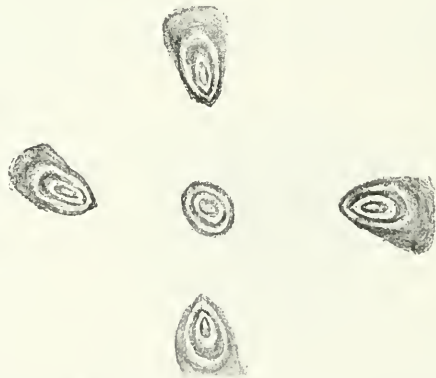

FIG. 224.—Keratoscopic appearance of keratoconus (Placido's disk of rings). Irregularly oval at apex of cornea; drawn out into pointed arches at the periphery.

of the cornea is due to a weakening of the corneal tissue and an increase of the intraocular pressure. The determining cause is not known. Vision is much reduced, and, since both eyes are nearly always affected, though often in varying degree, these patients are always "near-sighted," though not necessarily myopic, having to hold all objects close in order to obtain large retinal images.

**Treatment.**—In many cases vision can be much improved by glasses, a certain amount of regular astigmatism being found by the ophthalmometer. The light coming through the sides of the cone is that generally used, and therefore, as a rule, plus cylinders are preferred. Raehlmann devised *parabolic* glasses to correspond to the corneal curve, but they have not been found of much practical use.

Surgical treatment in the way of flattening the cornea by the knife or a

trephine, or burning it away with caustics, promises better. The stenopaic slit is often of benefit in obtaining better outlines of objects, but the diminution of field and illumination are its drawbacks.

**Morbid Growths on the Cornea.**—Of benign growths, *fibroma* (Fig. 225) is the one most commonly found on the cornea. It may come on independently or it may develop on cicatricial tissue the result of a previous ulceration. There is a tendency to return after removal. *Papilloma* may also find its habitat here.

*Malignant* growths are usually, perhaps always, of the epithelial variety, at least at the beginning, and are commonly secondary to similar growths on the conjunctiva or sclera. A few cases of *sarcoma* appearing primarily on the cornea itself have been reported. *Leprosy* may attack the cornea.

**Congenital Defects of the Cornea.**—The most common of these are *dermoid tumors* of various kinds (Fig. 226). Usually they are seated

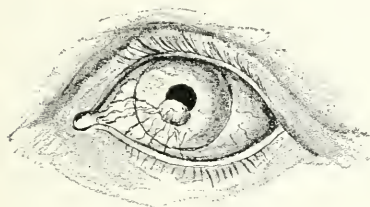


FIG. 225.—Fibroma of the cornea (after Falchi).

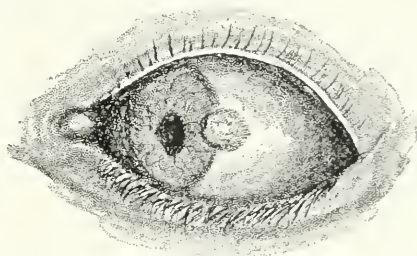


FIG. 226.—Dermoid of the limbus—colored woman aged twenty-one years (from the author's clinic).

on the corneo-scleral margin, and are sometimes associated with some other malformation of the eye, generally coloboma of the lid.

*Congenital opacities* are not common, but a number of cases have been recorded. They may be due to intra-uterine inflammation or to arrest of development: in the latter case the two eyes are apt to be affected in approximately the same manner. *Congenital staphyloma* has been described. It may be associated with a dermoid growth.

*Microphthalmos* is that condition in which the entire eye remains in a rudimentary state, and in which the cornea is reduced in all its diameters.

*Megalophthalmos* (see Buphthalmos, p. 385).

*Sclerophthalmia* is that condition in which, owing to an imperfect differentiation of the sclera and cornea, the former encroaches on the latter, so that only the central part of the cornea remains clear. Sometimes only the upper half of the cornea is affected.

#### DISEASES OF THE SCLERA.

**Episcleritis.**—The most common form of scleral inflammation is that known as *episcleritis*, in which the subconjunctival tissue and superficial layers of the sclera are conjointly affected.

**Symptoms.**—Episcleritis manifests itself as an ill-defined spot of infiltration with an elevation of 1 to 1.5 mm. Its seat of election is from 2 to 6 mm. distance from the corneal edge and to the outer side. Its color is not of a pure deep red, but rather of a bluish or violet hue; it is not movable on the ball and is more or less sensitive to touch. The conjunctival vessels leading up to it are congested, but the remaining part of the scleral surface is usually clear. There are in most cases considerable photophobia and lachrymation. The



disease is tedious in its course, sometimes running for several weeks, and is subject to recurrences, and it may be at different localities on the ball.

A rheumatic or gouty diathesis usually lies at the bottom of it, but it also occurs from exposure and with serofula and menstrual disorders.

**Treatment.**—General treatment must be along these etiological lines. Large doses of salicylate of sodium often have a good effect on the pain and shorten the course of the disease; in some cases pilocarpin sweats are beneficial. Subconjunctival injections of bichlorid of mercury or physiological salt solution have been used with good effect. Scarification of the tissue has also been recommended. Heat is the best local remedy, and may be used in the form of hot bathing or the Japanese hot box. As iritis has been known to develop during its course, atropin should be used at the height of the disease; but if there is no iritis, pilocarpin or eserin locally (gr.  $\frac{1}{12}$ —gr.  $\frac{1}{4}$ ), combined with cocain, is most useful. Galvanism has been recommended.

**Transitory Episcleral Congestion.**—This is the name given to a rather sudden and sometimes intense hyperemia of the sclera and overlying conjunctiva, lasting from a few hours to a day or two.

Fuchs (1895) calls it *episcleritis partialis fugax*. The author has called it *a vaso-motor dilatation of the vessels* (1892). The "hot-eye" of Hutchinson is probably of the same nature. The affection is liable to recur for years, and is not attended with danger to vision. It is usually painful and accompanied by photophobia and lachrymation. Exceptionally it occurs in children.

Heat for the relief of pain is called for, and the careful employment of cocain may be of use. Any dyscrasic condition, especially rheumatism and gout, must be attended to.

**Deep Scleritis.**—Inflammation of the sclera as a whole is very uncommon independently of a panophthalmitis. But the deeper layers of the sclera can become inflamed, though this is seldom the case, except in connection with inflammation of the underlying uveal tract. A very common instance of deep scleritis is what is known as *sclerotico-choroiditis posterior*, nearly always found in high grades of myopia (*posterior staphyloma*) (see page 221). The inflammation affects the anterior part less commonly, when it is known as *anterior scleritis*.

The disease nearly always begins in the uveal tract, and the sclera, becoming soft, yields to the intraocular pressure and bulges, causing a *ciliary staphyloma* which may be *equatorial*. There may be more than one staphyloma, and they may invade the edge of the cornea. They are bluish in color from the pigment showing through the thin scleral tissue. There are considerable congestion, lachrymation, and photophobia, the intensity of the symptoms depending upon the amount of ciliary or iritic involvement.

In a less intense form the disease may be chronic and last for years, with recurrences. Rheumatism, gout, and syphilis (*gummatous scleritis*) are to be counted as its causes, and its general treatment must be directed to the correction of the demonstrated or suspected dyscrasia. Locally, heat, atropin, and, when the staphyloma is thin, a pressure bandage, are indicated.

**Tumors of the sclera** generally are extensions from the neighboring conjunctiva or cornea. The *benign* ones are fibromas enchondromas, and the *malignant* ones are epitheliomas or sarcomas.

**Melanosis of the sclera** is usually congenital, and these dark spots are common in the negro race. Melanosis may occur in Addison's disease.

**Abscess of the sclera** has been observed. It is usually the result of injury, and seldom idiopathic. One or two cases of *osseous degeneration* of the sclera have been reported.

# DISEASES OF THE IRIS, CILIARY BODY, AND CHOROID; SYMPATHETIC INFLAMMATION AND IRRITATION.

BY ROBERT L. RANDOLPH, M. D.,

OF BALTIMORE, MD.

## DISEASES OF THE IRIS.

**Congenital Anomalies of the Iris.**—Heterophthalmos is the condition where the irides differ in color. One iris may be brown and the other blue. These differences in color may exist in the same iris, so that one part will have a distinctly different nuance from its immediate surroundings. The pupillary margin of the iris may be quite different in shade from its peripheral portions. Minute areas differing in color are not infrequently seen, and sometimes these areas assume the form of elevations upon the surface of the iris. (See also page 147.)

**Persistent pupillary membrane** is the remains of the membrane which occupied the pupillary field during fetal life, and, according to Manz, is part of a layer of tissue of the head-mesoderm containing vessels and surrounding the secondary ocular vesicle; this layer becomes differentiated into a posterior portion, the *choroid*, and an anterior portion, the *membrana pupillaris* (see also page 23). What is seen of this membrane consists only of a number of fine (usually pigmented) threads, anastomosing with one another and arising from the anterior surface of the iris and near the free border of the latter; in other words, from the *circulus iridis minor*. The threads are never present in any considerable number, for rarely more than ten or twelve, and usually less, are seen. These threads after converging pass across the posterior chamber and come to a point on the anterior capsule of the lens, this point being frequently

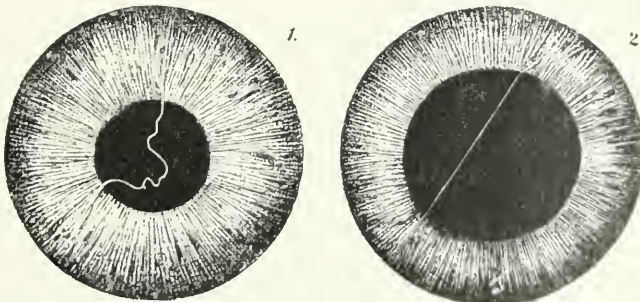


FIG. 227.—Persisting pupillary membrane: 1, pupil contracted; 2, pupil dilated (Wickerkiewicz)

marked by a pigment speck, or they may reach the anterior capsule at different points. It is seldom that the threads spring from all sides of the pupil, but usually from one or two points. They do not invariably pass across to the

lens capsule, but after running out for quite a distance into the pupillary field they return to the iris to be inserted near their point of origin.

A persistent pupillary membrane is not infrequently confounded with the *synchie* which remain after an iritis, but the oblique illumination will reveal the true nature of the affection. Moreover, the pupil dilates symmetrically to its full extent in the former condition, while in the latter case irregularities may be seen in the contour of the pupil (Fig. 227).

According to Fuchs, persistent pupillary membrane is of comparatively frequent occurrence in the new-born. Jacob and others<sup>1</sup> have succeeded in injecting these threads soon after birth, thus showing that the threads are vessels. As is well known, these threads undergo atrophy and are obliterated in the ordinary course of events. This affection is not often seen in both eyes.

The disturbance in vision is slight, depending upon the number of threads and the extent to which the anterior capsule is involved. The condition practically never demands operation, though von Graefe resorted to operation where the vision was  $\frac{1}{100}$ .

**Coloboma of the Iris.**—This is one of the most frequent malformations met with in the eye. It consists of an oval-shaped fissure or gap in the iris, which has the effect of prolonging the pupil in a direction usually downward and a little inward. A *complete coloboma* is where the fissure separates the iris in its entire breadth, and an *incomplete coloboma* is one where the cleft stops short of the ciliary border of the iris. The coloboma is usually smaller at its ciliary end, though the reverse of this has been observed quite often, in such cases the borders being almost parallel instead of convergent. There is often seen just within the pupillary end of the fissure a slight constriction which gives to the pupil and coloboma together the appearance of a keyhole. Sometimes the pupillary ends of the fissure are bridged over by a slender membrane or a thread, forming what has been described as the *bridge-coloboma*. In those cases where a thread has been formed the latter is supposed to be the remains of a pupillary membrane.

Coloboma is generally bilateral, though Manz is of the opinion that the affection is more frequently monolateral. In the latter variety the other eye often exhibits peculiarities, either in the color of the iris or in the shape of the pupil.

The congenital coloboma is distinguished from the artificial coloboma by the presence in the former of the sphincter, while in the latter, *i. e.* in an artificial coloboma (as after an iridectomy), the sphincter has been excised along the margin of the coloboma.

Coloboma of the iris is due to incomplete closure of the ocular fissure (page 22), and along with this condition coloboma of the choroid often exists, and sometimes the fissure is seen in the ciliary body and lens, and even in the optic nerve and macular region. It is not infrequently associated with microphthalmos and cataract (either congenital or acquired), and other fissures which usually close in fetal life may be seen to have persisted, forming harelip and coloboma of the lids.

The direction of the iris-coloboma is usually downward and inward, but exceptions to this rule have been observed; for example, the coloboma may be up and in, up and out, inward, outward, or downward. The accompanying illustration is from a photograph (Fig. 228) of one of the very few cases reported where the coloboma was directed upward. The case was first put on record several years ago by Theobald.<sup>2</sup>

<sup>1</sup> *Med.-Chirurg. Trans.*, London, vol. xii, p. 515.

<sup>2</sup> *Trans. Amer. Ophthalm. Soc.*, vol. v, p. 99.

The possible explanation of the unusual locations for the coloboma is that the ocular vesicle made a quarter or half a revolution about its long axis.

No satisfactory explanation has been offered for the failure of the ocular fissure to close. Some regard it as simply an instance of retarded development, while others think that inflammation must have played a part in



FIG. 228.—Coloboma of the iris with the coloboma directed upward.

producing the defect. The rôle played by heredity in this affection is certainly worthy of consideration.

**Irideremia, or Aniridia.**—This is a condition in which the iris is either completely absent or in which only one or more segments remain. When the irideremia is *complete*, it is possible to see the entire lens, which is often so exposed that even when cataract is present there is good sight, there being space enough between the edge of the lens and the ciliary processes for the light to pass through. When the irideremia is *incomplete* there is an absence of the iris at certain points, so that only a segment remains here and there. The narrow rim of iris which is sometimes seen just behind the corneo-scleral junction all the way around is not incomplete irideremia.

Myopia, hyperopia, astigmatism, and amblyopia are often present in irideremia; also a cloudy cornea. Cataract is not infrequently found associated with it, generally in the form of the anterior or posterior polar cataract, which in these cases is usually congenital. It should be said, however, that eyes affected with irideremia are peculiarly prone to cataract, so that this last-named condition may make its appearance any time after birth.

Irideremia is almost always a binocular affection. As regards its etiology, heredity undoubtedly plays an important rôle. The affection is clearly one of retarded development.

Under this head should be mentioned those cases where there is a narrow rim of iris springing out all the way around in front of the periphery of the lens. This condition is one step removed from irideremia, and is really an instance of *rudimentary development of the iris*.



The wearing of dark glasses in irideremia sometimes gives great relief, or spectacles with a stenopaic slit.

**Ectopia Pupillæ** (*Eccentric Position of the Pupil; Corectopia*).—The normal situation of the pupil is not exactly in the center of the iris, but a little below and to the inner side of the center. Sometimes the pupil is found eccentrically located. It may be near the normal site, and again it may be remote from this situation, as, for instance, near the ciliary border. Such a pupil is long-oval in shape, rarely, if ever, round. The most usual location is downward and inward, though it has been observed upward.

We are completely in the dark as to the origin of ectopia. Some authors believe that the condition is closely allied in its origin to coloboma of the iris, and give as a reason that the misplacement is nearly always at the most frequent location for coloboma. Others hold the opinion that ectopia pupillæ is due to a lack of development of the muscular elements of the iris at a certain point, with possibly an excessive development of the same elements at a point opposite, the effect being to pull over the pupil to the stronger side.

A not infrequent complication of ectopia pupillæ is a dislocated lens.

**Dyscoria** (*Faulty Pupil*).—This is a condition in which the pupil is faulty or irregular in shape, and is usually brought about by the presence of little excrescences on the margin of the pupil. These excrescences may attain such a size as even to meet at different points in the pupillary field, leaving only here and there small openings—a condition called *corestenoma congenitum* (Von Ammon), also *polycoria*. The condition is not infrequently seen in horses. The nature of these excrescences is not known.

**Motor Disturbances of the Iris.**—The movements of the iris consist in dilatation and contraction of the pupil, and a motor disturbance of the iris means an affection which is characterized by some alteration in the size of the pupil.

**Mydriasis and Myosis.**—An alteration in the size of the pupil may show itself in either persistent dilatation (*mydriasis*) or contraction (*myosis*) of the pupil, or in a condition in which the pupil is incessantly dilating and contracting (see also page 149).

**Hippus.**—This condition is one which is characterized by constant dilatation and contraction of the pupil. It is really a clonic spasm of the sphincter pupillæ (see also page 151).

**Iridodonesis** (*iris tremulans*) is a tremulous movement of the iris whenever the eyeball is moved, and is due to loss of, or defective support of, the iris. The condition is often seen after cataract extraction, especially the simple extraction. It is observed in cases of fluid vitreous where trophic changes have taken place in the lens and the latter has become smaller; in congenital cataract where the lens has undergone calcareous degeneration and shrinkage; and, finally, in luxation of the lens. Although not a functional motor disturbance of the iris, iridodonesis is conveniently referred to in this place.

**Hyperemia of the Iris.**—Hyperemia of the iris is characterized by a change in the color of the iris, which assumes a yellowish-red shade, so that a blue or gray iris appears greenish, and a brown iris will have in it a suggestion of red. In dark eyes, however, this discoloration is not so marked as it is in eyes of the blond type. As a rule, this symptom is more noticeable in cases of hyperemia than in conditions of marked iritis, where the iris is the seat of structural changes, and where the aqueous humor is filled with the products of the inflammation. De Wecker remarks upon the frequency with which a similar discoloration of the iris occurs in severe subconjunctival

hemorrhages, and he thinks that in such cases it is due to the fact that either the iris or the aqueous humor has become infiltrated with the soluble coloring matter in the blood.

In cases of *chronic hyperemia* there is a discoloration of the iris due to changes in the pigment-cells, and a complete disappearance of the pigment at the pupillary border, which becomes ragged and notched. These changes are only seen after the hyperemia has existed for a long time. The same appearance of the iris is seen in very old people without coincident hyperemia, and is attributable to *senile changes in the iris*.

In hyperemia of the iris the pupil no longer reacts as it does normally, but remains more or less contracted; and this sluggishness of the pupil is even noticeable when atropin is used, several instillations of the mydriatic being required to secure full dilatation. One of the first symptoms of hyperemia of the iris is the *pericorneal congestion*, which is of the character peculiar to affections of the uvea and cornea, and consists of a number of very fine vessels situated in the episcleral tissue and running out in straight lines from the corneal margin, forming, as it were, a sort of fringe to the latter structure.

**Etiology.**—Hyperemia of the iris often leads to inflammation of the iris; indeed, it might be said that every iritis is preceded by a stage of hyperemia. The cause of hyperemia, then, may be sought for in anything which will produce an iritis. Inflammation in structures anatomically connected with the iris may bring about hyperemia in the latter; for instance, keratitis, particularly the phlyctenular form. A foreign body on the cornea or the effect upon the cornea of a caustic agent will produce very quickly hyperemia of the iris. Inflammations of the choroid and ciliary body are fruitful sources of this phenomenon, and the same may be said of affections of the sclera; for instance, episcleritis.

**Treatment.**—Rest, dark glasses, and the instillation of atropin. An investigation into the cause of the hyperemia will suggest the proper general treatment.

**Iritis (Inflammation of the Iris).**—The two most frequent causes of iritis are probably syphilis and rheumatism, and yet there is no constant and distinctive symptom by which we can infallibly recognize which diathesis is present. Symptoms which one author regards as characteristic of syphilitic iritis are mentioned by another as belonging also to rheumatic iritis, and *vice versa*. If all cases of iritis of syphilitic origin presented the characteristic formation of nodules, it would be reason enough for making syphilitic iritis one grand division of the subject; but, in spite of the fact that by far the majority of cases of iritis are due to syphilis, the appearance of nodules (macroscopically) is the exception rather than the rule.

Iritis of rheumatic origin is supposed by some authors to be peculiar in its great tendency to recurrence, but it is doubtful whether iritis of this type possesses greater liability to recur than the syphilitic form. Exception might be made of those cases of iritis seen with arthritis deformans, especially in young persons. In such cases the prognosis is bad, owing to the persistency of the constitutional affection. Iritis of syphilitic origin is constantly encountered where recurrent attacks have been making their appearance for years. In both syphilis and rheumatism iritis will be apt to reappear so long as the constitutional disease is present. Inasmuch, then, as it confuses the subject to treat it from a diathetic point of view, the old divisions of iritis—*plastic*, *serous*, and *parenchymatous*—although by no means free from objections, will be followed.

**Objective Symptoms.**—The disease in general is characterized by all the symptoms which have been described in connection with hyperemia of the iris, except that these symptoms now are more intense and are associated with an exudate. This exudate may be thrown out from the posterior surface of the iris and into the posterior chamber, causing adhesions between the anterior surface of the lens capsule and the posterior surface of the iris (*posterior synechia*). Sometimes, though not often, there is complete adhesion of the posterior surface of the iris to the anterior surface of the lens—a condition known as *total posterior synechia*.

The exudate on the posterior surface of the iris is found in the pigmentary layer, and the region where the synechiae are most apt to occur is about the pupil, for here the iris is in contact with the lens-capsule. The exudate may be found also on the anterior surface of the iris, and it may be thrown out into the aqueous humor, and, dropping to the bottom of the anterior chamber, form a *hypopyon*<sup>1</sup>; or it may be found in the cornea in the shape of small points situated in the membrane of Descemet (so-called *keratitis punctata*, see page 327). Sometimes the exudate is poured out into the pupillary field, in which case it usually proceeds from the anterior surface of the iris. In such cases the iris-reflex is lost. Finally, the exudate occurs in the substance proper of the iris, and shows itself by swelling of the iris, which is often thrown into folds.

It may be stated broadly that when the exudate is mostly confined to the region about the pupil we are dealing with *plastic iritis*; that when the exudate is found in the anterior chamber and upon the posterior surface of the cornea we are dealing with *serous iritis*; and, finally, that when the iris is swollen and thrown into folds we have before us the *parenchymatous* variety of the disease.

According to De Wecker, neither the plastic nor the serous form of iritis is apt to leave lasting changes in the iris, while in parenchymatous iritis there is more or less obliteration of vessels and disappearance of pigment.

**Iritis Simplex or Plastic Iritis.**—Pericorneal congestion is always present in this form of iritis, and its varying intensity offers good evidence of the grade of the disease. In very light cases of plastic iritis the pericorneal congestion may be so insignificant as easily to be overlooked, while at other times it may show itself in *chemosis*, though this is rare even in the most intense inflammations of the iris. The cornea does not participate, though on superficial glance this does not seem to be the case. Oblique illumination, however, will show that what at first sight seems to be a dulness of the cornea is nothing more than a loss of the iris reflex, due to the exudate upon the anterior surface of the iris and to the slightly cloudy aqueous humor. A cloudy aqueous humor is not a noticeable feature in this variety of iritis, while it is a condition quite characteristic of serous iritis.

The pupil is contracted and sluggish, and shows no response to the usual tests. This condition of the pupil often persists in spite of the use of a mydriatic, and frequent instillations will be necessary to get the same dilatation which ordinarily can be obtained by one instillation. The explanation of this must be sought for not only in the ciliary irritation, and in the diminished activity of the dilator fibers caused by their infiltration with inflammatory products, but also in the necessary loss of activity in a tissue which is inflamed and swollen; and, finally, in the presence of the exudates which bind the border of the pupil to the anterior capsule of the lens. These exudates

<sup>1</sup> Sometimes a gelatin-like mass is deposited in the anterior chamber, which, when it consolidates, resembles a dislocated lens. This is the so-called *spongy iritis*.



may be seen by oblique illumination. Several instillations of atropin will bring out strikingly the deformities in the pupil; those parts of the pupil which are not adherent will respond to the mydriatic, while the points which are bound down to the lens will remain fixed.

Sometimes the entire pupillary margin is adherent to the capsule of the lens—a condition known as *seclusion of the pupil*. This kind of synechia is not usually the result of one attack of iritis, but is found as a sequel of several recurrent attacks. At other times the pupillary field is completely filled with a mass of exudate, producing the condition known as *occlusion of the pupil*. If the adhesions are slight, they can be broken loose by the action of atropin, and when this is done small pigment-specks may be seen on the surface of the lens, marking the points where the iris was adherent.

**Serous Iritis.**—Instead of a plastic exudate, there may be an exudate, serous in character, containing solid elements, which are always to some extent deposited upon the posterior surface of the cornea. There seems to be an increased secretion of the aqueous humor, and the latter is quite cloudy. The deposits upon the membrane of Descemet are sometimes very fine, and are to be seen as small whitish or yellowish-white dots which can be brought out by oblique illumination or by examination with a strong convex lens (see Fig. 221). These deposits are sometimes found on the anterior capsule of the lens. Synechiae are not as prominent symptoms in the earlier stages of this variety of iritis as they are in the plastic form, although they appear ultimately and contribute very materially to the grave prognosis.

Atropin, therefore, will not disclose irregularities in the contour of the pupil to the same extent as in plastic iritis, and frequently the pupil is symmetrically dilated, though never *ad maximum*. The pericorneal congestion is usually slight. The tension, as a rule, is elevated, due, no doubt, to the hypersecretion going on within the eye. The pupil by its dilatation shows the effect of this increased tension.

It is more than probable that in serous iritis the entrance to Schlemm's canal is blocked with exudate—a condition which of itself would be apt to bring about glaucomatous symptoms. As a rule, hypopyon is absent in serous iritis. Opacities in the vitreous body are very common, and degeneration of this part of the eye usually follows sooner or later. Ultimately, the inflammation affects the whole eye.

**Parenchymatous Iritis.**—In this form of iritis the inflammation attacks the iris tissue itself. Instead of an exudate on the anterior or posterior surface of the iris, the exudate is found within the iris. The swelling, which is always present, is often circumscribed, and produces an impression as though there were *nodules* within the iris. The masses of exudate are pigmented, and are found around the pupillary margin, often binding the iris to the anterior capsule of the lens. Sometimes these exudates find their way into the anterior chamber, and, settling at the bottom of the latter, form *hypopyon*; at other times they are thrown out into the posterior chamber. Even the pupil is sometimes filled with these yellowish masses. The appearance of the iris is dull, and pericorneal congestion is usually intense. There often may be seen the formation of little yellowish-red nodules traversed by blood-vessels, practically what is observed in the so-called syphilitic iritis, and designated *iritis papulosa* (Fuchs) when occurring in the secondary stage of syphilis; *iritis gummosa*, in the tertiary stage.

A typical parenchymatous iritis may be produced in rabbits by injecting a drop of a suspension of the *staphylococcus aureus* into the anterior chamber, the inflammation being attended with the formation of small elevations on



the iris and nodular masses at the pupillary border, not unlike the appearances visible in the same disease in man.

In parenchymatous iritis there is often present a pupillary membrane which stretches over the entire pupillary area. Sometimes a purulent infiltration of the iris (*purulent iritis*) occurs, with a deposit of leukocytes in the anterior chamber. Parenchymatous iritis, so long as it confines itself to the iris, may leave the eye unimpaired in its functions.

De Wecker calls attention to the peculiar nature of the *hypopyon* in these cases. It differs from the hypopyon seen in keratitis, because it is much thinner and changes its position with every movement of the head, and is remarkable for the rapidity with which it undergoes absorption, frequently disappearing in the course of a few hours.

**Subjective Symptoms of Iritis.**—While iritis may exist without pain (as is often the case in the serous form), as a rule this is a prominent symptom. The pain is not referred so much to the eyeball as to the temples and forehead and the neighboring regions supplied by branches of the fifth pair, and is of a boring character and apt to be more intense at night. The pain is not only the result of pressure upon the ciliary nerves by the products of the inflammation, but also the result of an actual involvement of these nerves in the inflammatory process. Pain, however, is no absolutely reliable index of the grade of an iritis. Plastic iritis, as a rule, is characterized by more pain than the parenchymatous form, yet one would be disposed to expect the opposite. Fournier,<sup>1</sup> among others, has called attention to the fact that parenchymatous iritis, in spite of the extensive anatomical changes present, is often associated with little or no pain.

Lachrymation and photophobia vary with the ciliary neuralgia. Visual disturbance is always present, and varies in degree with the clouding of the aqueous humor and with the extent to which the pupillary area is occupied with exudates. In serous iritis the disturbance in vision may be explained by changes in the vitreous body and choroid, and even in the optic nerve. Finally, such constitutional symptoms as fever and nausea have been occasionally observed, and a coated tongue is a frequent accompaniment.

**Etiology.**—The causes which give rise to iritis are *local* and *constitutional*. Among the first class are foreign bodies in the cornea, which have remained there for a considerable length of time; the careless and continued use of caustic agents; penetrating wounds of the eyeball; and swollen masses of lens-matter. Iritis may arise from an inflammation of the cornea, sclera, ciliary body, or choroid, in which cases iritis extends by continuity of tissue. Finally, iritis may arise from trouble in the other eye—sympathetic ophthalmitis.

Among the diatheses which give rise to iritis, *syphilis* stands easily first. Indeed, nearly 75 per cent. of all cases of iritis can probably be traced to this source. The iritis is generally of the plastic variety, although the parenchymatous form may occur. It shows itself generally in the secondary stage of syphilis, and when the parenchymatous form of the disease prevails there are often seen small nodules either at the margin of the pupil or at the ciliary border of the iris, and at these points there are usually *synchie*. When the nodules disappear there may remain in the iris atrophic areas. While the presence of these nodules probably justifies the surgeon in diagnosing the case as one of syphilitic iritis, it should be remembered that in the majority of cases of iritis, where a syphilitic origin is clearly demonstrable, apparently no nodules are present. The nodules may attain quite a large size, and several

<sup>1</sup> "Des Affections oculaires d'origine syphilitique," *Journal d'Ophtal. de Paris*, pp. 495-543.

of them may fill the anterior chamber, and, increasing in size, may burst through the envelopes of the eye. This termination is rare. *Hereditary syphilis* seldom gives rise to iritis, and when it does the subjects are usually young people, just as is the case with interstitial keratitis.

*Rheumatism* (articular) is another not infrequent cause of iritis. Two such cases the writer has in mind—one, a boy fourteen years old, who has not walked for four years, and who is completely disabled from articular rheumatism; the other, a young woman nineteen years of age, who has been confined to her bed for eight years. The girl has only light perception, her pupils being entirely bound down by adhesions, while in the case of the boy there is seclusion of the pupil in one eye, and the other eye possesses only sufficient sight to allow him to see large objects. Both these patients have had skilful treatment, which has availed but little, owing to the intensity of the constitutional affection.

It is doubtful whether the rheumatic diathesis gives rise to distinctive ocular symptoms, though some authors speak of the peculiarity of the episcleral and pericorneal congestion. As might be inferred, rheumatism of the character seen in the two cases just mentioned, when associated with iritis, would probably be the occasion of *recurrent* attacks of the eye-affection. In this connection it should be said that *gout* often gives rise to iritis.

*Gonorrhœa* sometimes causes iritis. In such a case no doubt there is a general infection, although it is not at all probable that the gonococcus gets into the intraocular circulation, but its toxins reach the eye and there give rise to iritis. Inflammation of the knee-joint commonly precedes the eye-affection. When iritis is found as a result of gonorrhœa, it shows a tendency to recur, and is frequently associated with a renewal of the pains and swelling in the joint.

*Scrofula* (*scrofulous iritis*) sometimes, but rarely, gives rise to iritis, and, as is the case with hereditary syphilis, the subjects are young persons. According to Fuchs, iritis in these cases is marked by the appearance of lardaceous-looking deposits or exudates, which seem to grow out from the sinus of the chamber. *Anemia* may be associated with an iritis of this character.

*Relapsing fever* (iritis in acute infectious diseases), *typhus* and *typhoid*, *small-pox*, *cerebro-spinal meningitis*, *pyæmia*, and even *epidemic influenza* (grippe), have been known to cause iritis. Inflammation of the iris in *relapsing fever* is very tedious in its course. Iritis is occasionally caused by malaria (*periodic iritis*) and by irregularities of menstruation (*iritis catamenialis*).

*Diabetes* (*diabetic iritis*) is another very rare cause of iritis. In spite of the fact that hypopyon is often observed in this variety of iritis, the course of the disease is usually favorable.

*Tuberculosis* in other organs may give rise to iritis (*tuberculous iritis*), although such an origin is not often seen. Tuberculosis shows itself in the iris either in the form of grayish-red nodules or as a solitary tubercle resembling a neoplasm. Children are usually the subjects. While it is a very rare affection, its nature is well understood, for Colnheim has produced the disease experimentally in rabbits by introducing small pieces of tuberculous material into the anterior chamber. The immediate effect of this operation is apparently negative, but within a month iritis sets in and the characteristic gray nodules appear. These increase in number till they fill up the anterior chamber, when (unless the animal dies) they may break through the coats of the eye. This is the *disseminated* form of the affection.

The little nodules are usually located at the pupillary margin. In man the disease is generally followed by a plastic irido-cyclitis and loss of the eye.

*Tuberculosis of the iris* also occurs as a *solitary tubercle*. This tubercle more often appears alone, though it may exist along with the nodules. When alone the symptoms of iritis can be absent—that is, for a certain period of its history—although iritis ultimately appears. It was regarded by von Graefe at first as a tumor, and described as such under the name of *granuloma*. Haab first demonstrated its true nature.

The *disseminated* form may occur in both eyes, but the *solitary* form has only been observed in one eye. In both varieties the eye is usually lost.

Mention may be made here of what has been called *recurrent iritis*, where the patient for months may be free of the disease and suddenly an outbreak will occur. Both eyes are usually affected, but rarely at the same time. Synechiae are frequently left after an attack, and it has been thought that their presence determined subsequent attacks, but it is more than probable that some persistent constitutional affection (generally syphilis) is responsible for the recurrences. It has been observed that men more often than women are the subjects of this variety of iritis.

*Traumatism* is responsible for a number of cases of iritis. The injury may be accidental, or may be inflicted during the course of an operation, or occur as the result of an operation—*c. g.* after discission of the lens.

No time of life seems exempt from iritis, although it is exceptionally seen in children under ten years of age, and it is not often met with after the seventieth year. According to von Ammon and von Arlt, iritis is more frequent in men than in women.

**Pathological Anatomy.**—The iris is thickened and infiltrated with round-cells. This round-cell infiltration will be found marked along the blood-vessels. The exudate is composed of fibrin filled up with leucocytes and round-cells, and is generally more extensive upon the posterior surface of the iris. When found in the pupillary field the exudate is rich in pigment-granules, although this is the case to a certain extent everywhere. The coats of the blood-vessels are thickened and capillary hemorrhages are abundant. Masses of granular debris, the exact nature of which it is difficult to determine, are always present. In cases where seclusion of the pupil has occurred it will be found that the iris has undergone atrophy in those parts bordering upon the pupil. Where the entire posterior surface of the iris is bound down to the lens, sooner or later atrophy of the whole iris occurs, and it will be found that all that is left is a thin membrane, and here and there within its folds a clump of dis-integrated cells. Sometimes there are scarcely any traces of the structure of the iris; even the sphincter has disappeared.

**Diagnosis.**—The character of the conjunctival congestion, the slightly turbid aqueous, and the sluggish pupil in iritis distinguish it from conjunctivitis. If the two irides are compared, the change of color of the affected iris, due to hyperemia, will be observed. In conjunctivitis the pain is burning in character, is referred especially to the lids, and is quite constant, while in iritis it is usually paroxysmal, is referred to the temples and brows, and often is more intense at night. Vision is never materially affected in simple conjunctivitis, while visual disturbance in iritis is the rule. Iritis may be distinguished from glaucoma (with which it is often confounded by the inexperienced) by the size of the pupil, which in the former disease is contracted, while in the latter it is dilated. The tension, while it may be elevated in iritis (particularly in the serous form), is not so as a rule. The tension in glaucoma is always elevated.



**Prognosis.**—This depends upon the cause and also upon the changes which have already taken place in the iris. If the pupil is completely dilatible with atropin, the prognosis may be regarded as favorable. The presence of numerous synechiæ, especially when one or more fail to yield to the action of the mydriatic, means often a recurrence of the iritis, although cases are not infrequently seen where two or three synechiæ have been present for several years, without recurrence of the iritis; and with good vision. Where there is either *seclusion* or *occlusion of the pupil*, an accumulation of aqueous often occurs in the posterior chamber, and leads to a bulging forward of the iris and ultimately to increased tension (*secondary glaucoma*). Where there is a total posterior synechia, the iris instead of bulging forward may be retracted at its periphery, and here we will have usually diminished tension. Sometimes the iritis runs a *chronic* course, being characterized by sluggishness of the pupil, cloudy aqueous, an occasional synechia, and by usually no marked painful symptoms. The conditions just mentioned mean that the eye has been the seat of disease for a considerable time, that in consequence the integrity of the lens (so-called *inflammatory cataract*), of the ciliary region—in fact, of the whole posterior segment of the eye—has been in a measure permanently impaired. The prognosis then is bad for anything like restoration of good vision.

The condition of the adjacent structures has an important bearing upon the prognosis.

**Treatment.**—In connection with the treatment of iritis the following rather striking sentences seem appropriate: “There is one ground, however, on which I strongly object to this ticketing of iritis with the names of various diseases—namely, that habit is likely to mislead the inexperienced practitioner into an endeavor to treat the name on the ticket, while the iritis may be neglected until it has done irreparable harm. I do not know of any disease which prevents the occurrence of iritis, and hence I do not know of any with which it may not sometimes be associated. . . . We do not understand a given case one whit better for calling it ‘rheumatic,’ and the term tends to relegate to the second place, as a mere accident of another affection, a malady in which all our skill will be necessary if we are adequately to discharge our responsibilities to the patient” (Robert Brudenell Carter).<sup>1</sup>

Rest for the iris is reached by the instillation of atropin. This drug paralyzes the sphincter, stops the incessant movements of the pupil, reduces the hyperemia, and by dilating the pupil breaks loose the adhesions, which are not likely to recur during mydriasis. Atropin is to the eye in iritis very much what opium is to inflammations elsewhere in the body: it is, so to speak, the great anodyne in iritis. Generally, a solution of four grains to the ounce is strong enough to dilate the pupil if instilled every three or four hours; but if a solution of this strength does not produce the desired effect, a stronger one should be employed. Not infrequently success is attained only after using a solution of sixteen grains to the ounce. The surgeon should watch for the constitutional effects of the drug, but an iritis which calls for such a strong solution of atropin is apt to tolerate it without unfavorable results. No more than one drop is instilled at a time, and not oftener than every four hours. If constitutional effects appear, the strong solution should be abandoned at once; but ordinarily two or three instillations will give satisfactory evidence whether any good will follow its continued use. The employment of cocain along with atropin heightens the effect of the latter drug.

<sup>1</sup> *Ophthalmic Surgery*, by R. B. Carter and W. Adams Frost, pp. 180, 181.



The appearance of constitutional symptoms, however, no matter what be the strength of the atropin solution, necessitates a withdrawal of the drug, as well as of other mydriatics, such as scopolamin, duboisin, and hyoscyamin. When a full dilatation of the pupil is obtained, it may be no longer necessary to use the atropin so often; in other words, its use should be regulated by the condition of the pupil.

Hot applications, either moist or dry, are indicated. A small pad of surgical gauze steeped in the following lotion and applied to the eye as hot as can be borne rarely fails to give comfort: Plumbi acetat.,  $\mathfrak{v}$ j; opii pulv.,  $\mathfrak{ss}$ ; aq. bull., Oj. A roll of dry cotton and then a layer of oil silk should be placed over the pad. As soon as this application gets cool it should be renewed. Its good effects are especially evident when the inflammation is of a violent type. Poultices are valuable and are often employed. Cold applications are to be avoided, although some surgeons advise their use in traumatic iritis. Four or five leeches applied to the temples or the artificial leech (Heurteloup) are helpful in bringing about an abatement of the inflammatory symptoms, although this method of treating iritis has become less popular of late years. The Japanese stove or hot box is a most convenient method of applying dry heat. The box should be wrapped in a handkerchief or in any soft material and applied to the eye. A little bag filled with hops or bran and heated in an oven can be used in the same way. These various methods of applying heat are valuable, especially the first one.

According to Fuchs, Schweigger, and other writers, a hypodermic injection of muriate of pilocarpin ( $\frac{1}{4}$  grain) every other day is very beneficial. Bromids and opiates are to be used when needed. So far as possible, the patient should be screened from direct rays of light. The administration of calomel in the earlier stages of the affection usually proves advantageous. Two grains are given in  $\frac{1}{4}$ -grain doses. The good effects of this agent in all forms of iritis are most conspicuous. Not infrequently in cases in which atropin apparently has produced no mydriasis, after a thorough calomel action marked improvement in the condition of the pupil may be observed.

After the action of the calomel has been obtained treatment should be directed to the cause of the iritis. As a rule, the administration of salicylate of sodium in 20-grain doses, every three or four hours, will be found an admirable remedy in the painful stage of iritis. It matters not what be the origin of the disease, this remedy rarely fails to prove serviceable. After the painful stage has passed away this drug may be administered in smaller doses if there be a rheumatic or gouty diathesis present; if the iritis rests upon a syphilitic basis the surgeon should resort at once to biniodid of mercury and iodid of potassium, or innjection of blue ointment may prove the best method of getting the mercury into the system. A mercurial vapor-bath is also an excellent way of administering this remedy. Usually the mixed treatment is adopted in such cases, and, as has been said, this consists in the administration of the biniodid of mercury and iodid of potassium, which is continued not only till all the eye-symptoms have disappeared, but until one can be reasonably certain that the constitutional poison has been eliminated. Subconjunctival injections of bichlorid of mercury have been recommended by Darier and other surgeons; similar injections of physiological salt act equally well.

Iritis is uncommon in children, and is best treated by innjections of mercury. In serous iritis the surgeon should be careful in the employment of atropin, as a glaucomatous condition often exists which the mydriatic would

tend to intensify. *Paracentesis* may be practised in these cases with advantage, and when increased intraocular tension persists iridectomy is indicated.

The majority of cases of iritis, properly treated, get well without adhesions; still, synechiæ may remain and may cause recurrent attacks. The operation of *corelysis*, which is not much practised now-a-days, was designed for the purpose of breaking loose these adhesions (see page 579). Whenever it is necessary to operate upon synechiæ no procedure is superior to *iridectomy* (see page 575). The presence of several broad synechiæ near one another might readily explain the occurrence of frequent attacks of iritis. Such synechiæ should be operated upon by an iridectomy at the point of attachment. One or two synechiæ are rarely responsible for a recurrence of iritis. Operative measures in connection with iritis are rarely demanded during the active inflammation, but rather in the sequelæ of the disease.

In those cases where the iritis has resulted from an injury, if there are any large pieces of iris protruding they should be abscised. A minute hernia, however, will probably do no harm and had best be let alone. The inflammation itself should be treated just as we would treat any plastic iritis. When the lens capsule has ruptured and the swollen masses of lens are pressing upon the iris the lens should be removed. In cases of *seclusion* or *occlusion of the pupil* iridectomy is indicated. Either of these conditions, if neglected, may end in total blindness. In *seclusion*, iridectomy is demanded because it relieves increased tension and re-establishes the communication between the anterior and posterior chambers, and by doing this the nutrition of the eye is at once improved and some vision may be obtained. For the same reasons iridectomy is demanded in *occlusion of the pupil*. But even in those cases where the intraocular tension is lowered and atrophy has set in, as is sometimes the case after total posterior synechiæ, the tendency of iridectomy is to do good by improving the condition of the eyeball. Such eyes may fill out again and regain some sight. Where the entire posterior surface of the iris is bound down to the lens capsule it is difficult to pull away the iris without more or less injuring the delicate ciliary region; hence iridectomy in such cases may be followed by irido-cyclitis, but inasmuch as such an eye will in all probability cause trouble in one way or another, iridectomy should be tried.

#### ANOMALIES OF THE ANTERIOR CHAMBER.

The depth of the anterior chamber varies within physiological limits. In infancy the anterior chamber is very shallow, becoming deeper as adult life is approached, while in old age it again becomes shallow. In myopia the anterior chamber is deeper than in hyperopia.

Pathologically, the anterior chamber shows variations in depth. It may be shallow from the pulling forward of the iris by anterior synechiæ or by the collection of masses of exudate behind the iris in total posterior synechiæ. Sometimes the periphery of the anterior chamber is deeper than the middle after a severe attack of cyclitis, and in these cases the outer zone of the iris is drawn backward by exudates. A shallow anterior chamber occurs in glaucoma, and also after the needling operation for cataract, when the lens swells up and presses against the iris, pushing it forward. A shallow anterior chamber is seen in the later stages of intraocular tumors.

Increased depth of the anterior chamber is seen in staphyloma of the cornea, in luxation of the lens into the vitreous body, in aphakia, and in hydrophthalmos.

The contents of the anterior chamber may be altered by the presence of blood (*hyphema*), pus, masses of lens-substance, foreign bodies, cysticerci, neoplasms, and cilia.

Blood in the anterior chamber as a general thing will disappear under a compress bandage, but if it persists and is evidently acting as a foreign body, paracentesis of the anterior chamber at its lower border should be performed. Hyphema most often follows injuries and contusions of, and operations upon, the eyeball. It is also seen after irido-cyclitis, with seclusion of the pupil and beginning phthisis bulbi, in which case the hemorrhage into the anterior chamber often repeats itself. Paracentesis under these circumstances does no good, the compress bandage being found more serviceable. Hyphema has been observed as a result of dysmenorrhea and purpura hemorrhagica. Mooren and Weber describe patients who could bring on hemorrhage into the anterior chamber at will. Pus in the anterior chamber (*hypopyon*) is always a symptom, and must be treated according as it proceeds from the cornea or from the iris. It usually has its origin in affections of the cornea.

Foreign bodies, as particles of steel and glass, may pass through the cornea and rest in the anterior chamber and on the iris. An eyelash may find its way into the anterior chamber, and after a time give rise to an *implantation cyst* (see page 489).

*Cysticerci* are rarely seen in the anterior chamber. The parasite generally gives rise to symptoms of iritis, and can be seen sooner or later swimming around in the aqueous humor or it may be attached to some point of the iris. The *filaria sanguinis hominis* has also been observed in this locality. The parasites should be removed.

#### DISEASES OF THE CILIARY BODY.

**Cyclitis.**—Inflammation of the ciliary body does not exist as an isolated disease, but is usually an extension of an iritis or choroiditis. As a rule, iritis is present.

**Etiology.**—Inasmuch as the disease is secondary to either iritis or choroiditis, more often to the former, it has the same etiology. When it is not secondary to one of these affections it is the result of a wound or foreign body in the ciliary region, or it may occur in one eye as the result of a traumatic cyclitis in the other (sympathetic ophthalmitis).

**Symptoms.**—The disease is characterized by marked circumcorneal congestion and more or less hyperemia of the iris, which shows itself in dilatation of the blood-vessels and slight discoloration. The anterior chamber is deeper than normal at its periphery, owing to the traction of exudates from behind. These exudates are plastic in character—hence the name *plastic cyclitis*—and usually are not seen in the pupillary field. The pupil is often dilated. The hyperemia of the iris sooner or later passes over into iritis, and finally the choroid becomes involved. Sometimes these symptoms are much less pronounced; indeed, there may be entire absence of plastic exudates, and, while in the beginning the anterior chamber is deep, later on it becomes shallow. A condition may arise very similar to what is seen in serous iritis. Fine opacities make their appearance in the anterior part of the vitreous body—opacities which materially interfere with vision. The tension is decidedly elevated and the pupil dilated. Some authors speak of this somewhat milder aspect of the disease as *serous cyclitis*. Again, we may have the pericorneal

congestion and hyperemia of the iris intensified, and this hyperemia may extend to the retinal vessels, showing itself in tortuosity of the retinal veins. A characteristic symptom is *hypopyon*, which disappears and reappears again in a few days. This is the purulent type of the affection, and it is generally spoken of as *purulent cyclitis*. Just as in the plastic and serous types, the iris is always implicated.

Cyclitis is characterized by the general symptoms of inflammatory irritation—namely, ciliary neuralgia, photophobia, and lachrymation. The eyeball is exceedingly sensitive to the touch over the ciliary region. Vision is invariably impaired.

**Pathological Anatomy.**—Small-cell infiltration of the ciliary body is present, and this condition is especially marked in the purulent variety of cyclitis. Hemorrhages are frequent in all forms of cyclitis. Both the circular and radiating fibers of the ciliary muscle contain exudate, and this exudate (fibrinous) is considerable enough at times to push aside the individual fibers. The neighborhood of Schlemm's canal is always densely infiltrated, and no doubt the inflammatory products in this locality by blocking up the entrance into the canal have not a little to do with the development of glaucomatous tension. The formation of membranes is usually seen. The *cyclitic membranes* may cover the entire posterior and anterior surface of the iris, and also the ciliary body, and even extend into the vitreous body. This membrane not infrequently envelops the lens, and, contracting about it, cuts it off from its sources of nutrition. As a result of this the lens is often found as a small calcareous mass entangled in the meshes of the membrane and bearing no resemblance to its former shape. In the contraction which the cyclitic membrane undergoes the ciliary body is drawn away from its normal site, and is to be seen as a narrow strip of tissue, having lost its natural shape. This cyclitic membrane is composed of connective tissue with interlacing bands. All shapes of cells will be found present. In very light cases this membrane may disappear by resorption. Masses of black pigment are to be seen here and there throughout the diseased parts. According to Pollock, hemorrhages are common in the cyclitic membrane, although the author has not observed any in the specimens which have come under his observation. In the early stage the ciliary processes are thickened; finally, however, they undergo atrophy and become very much thinned. When the process has reached this stage atrophy of the eyeball is usually only a question of time.

**Diagnosis.**—The question is between iritis and irido-cyclitis. The symptoms which determine the existence of a cyclitis have been enumerated by Fuchs as follows: Inflammatory symptoms of considerable degree, especially if edema of the upper lid is present (this edema of the lid does not occur in pure iritis); sensitiveness to touch in the ciliary region; retraction of the periphery of the iris, indicating total posterior synechiae; disturbance in vision more considerable than would be expected from the opacities within the confines of the anterior chamber; and, finally, tension either elevated or lowered.

**Prognosis.**—The prognosis in cyclitis is always grave, especially so in the *plastic form*. The cyclitic membrane usually covers the entire ciliary region, and in the contraction and organization which follow the retina and ciliary body are torn out of position, the lens undergoes degeneration, and atrophy ends the scene.

The *serous form* in its early stages is often characterized by a glaucomatous condition which is followed by softening and atrophy of the eyeball.



The *purulent form* of cyclitis, seen as a result of infection after cataract extraction, as a rule ends in sloughing of the whole eyeball.

**Treatment.**—The treatment is practically the same as that employed in iritis. Heat and atropin, then, should be used locally. The latter remedy is withdrawn when a glaucomatous condition is present. The constitutional treatment which has been suggested in connection with iritis is equally applicable here.

**Injuries of the Ciliary Body.**—Injuries of the ciliary body arise from penetrating and non-penetrating wounds of the ciliary body, and are fully described on pages 364 and 367.

**Irido-choroiditis** (*Chronic Serous Irido-choroiditis*).—This disease usually originates in the iris; that is to say, the presence of posterior synechie may result in chronic iritis which passes backward and invades the choroid. Sometimes the inflammation originates in the choroid and passes forward and involves the iris.

**Etiology.**—Old synechie are generally responsible for this affection. Where the disease starts in the choroid it not infrequently is to be attributed to a dislocated lens which has been either resting upon the retina and choroid or floating about in the vitreous body. Edward Meyer mentions instances where the affection was traceable to menstrual disturbances and to the climacteric.

The **pathological anatomy** is practically the same as that which has been described in connection with Iritis.

**Symptoms.**—Even when the process has originated in the iris the irritative symptoms are never conspicuous, certainly not to the extent in which they are found in iritis. The iris is often bulged forward, and may be pressing against the cornea. This condition, however, is only seen in those cases where the pupil is completely occluded and communication between the two chambers is interrupted. It is caused by the collection of effusions behind the iris. The vitreous body is generally filled with opacities. Pain, as might be expected, is an insignificant symptom. Visual disturbance is always present, and is in proportion to the condition of the pupil and involvement of the choroid.

Where the inflammation has started in the choroid the visual disturbances are more pronounced. Nearly always in this event there are detached retina, dense opacities in the vitreous body, and a degenerated lens. By the time the inflammation reaches the iris sight has been nearly extinguished. From now on the symptoms resemble those seen when the inflammation originates in the iris. Meyer has suggested the following points as important in deciding as to the probable origin of the affection, whether in the iris or choroid: In case the inflammation had started in the iris the patient would be apt to recall some attack of iritis, and it would be noticed that the structure of the iris had undergone changes to some extent, being discolored and atrophied. As a rule, the lens shows no participation in the affection till the process has found its way backward. When visual disturbances are absent one can be reasonably certain that neither the lens nor the vitreous body is to any extent involved.

If the process has started in the choroid, visual disturbances will always be prominent features, owing to the opacities in the vitreous body. Retinal detachment will be noticed, the intraocular tension will be lowered, and the lens will often be found to have undergone calcification. Neither of these forms exhibits acute symptoms, both being very insidious in character.

**Prognosis.**—Where the process has started in the iris and has been

properly treated in the early stages there is, comparatively speaking, hope for restoration of useful sight. But where the disease begins in the choroid the outlook is exceedingly bad. Even if the retina is not detached or the lens opaque, the integrity of the entire uveal tract has been to some extent permanently impaired.

**Treatment.**—Atropin must be employed, but it should be remembered that intraocular tension is sometimes elevated in the course of the disease. When the communication between the anterior and posterior chamber is interrupted, iridectomy should be performed, for a continuance of this condition means blindness. The surgeon should not hesitate to repeat this operation as often as the new pupil is closed with exudates, and should not be deterred even by a condition of diminished tension. The lens being diseased and more or less opaque, its removal is frequently indicated. Constitutional treatment should not be neglected. Mercury should be tried in the form of the bichlorid and in small doses. Iodid of potassium is also indicated.

### SYMPATHETIC AFFECTIONS OF THE EYE.

**Sympathetic Ophthalmitis.**—This disease is one of the most interesting and at the same time the most obscure in the whole range of eye affections.

**Definition.**—Sympathetic ophthalmitis is an inflammation, usually plastic, but sometimes serous, which affects the iris, ciliary region, and choroid of one eye (“the *sympathizer*”), and which originates in a traumatic inflammation of the same parts in the other eye (“the *exciter*”). The three fundamental elements of true sympathetic ophthalmitis are—first, a traumatic irido-cyclitis of one eye; second, a plastic *uveitis* of the other eye; and third, a certain period of time which always elapses before the outbreak of the sympathetic disease—*i. e.* the period of incubation. The existence of these three factors certainly warrants the diagnosis of sympathetic ophthalmitis.

**Etiology.**—Penetrating wounds are chiefly concerned in the production of sympathetic ophthalmitis—wounds either from sharp instruments, such as scissars and knives; or wounds caused by the entrance into the eyeball and the lodgement there of small fragments of steel, percussion caps, particles of stone or glass. Schirmer, Mackenzie, Knapp, and others report cases which followed simply a blow upon the eyeball without a rupture. This mechanism is entirely contrary to the rule, and most of these instances are open to grave criticism.

*Penetrating wounds of the ciliary region* are especially apt to give rise to the disease, and it makes no difference whether the wound is large or small. Mooren has described sympathetic ophthalmitis after the entrance into the eyeball of small particles of iron, and has seen it follow the bursting of the eye by a blow with a stick. According to Mackenzie, protrusion of the iris and its incarceration in the wound are conditions which are peculiarly liable to give rise to the disease.

Wounds which pass through the cornea and the pupillary border of the iris, even though the lens is injured and cataract results, are not as dangerous as when the wound passes through the ciliary border of the iris. Traumatic cataract of itself has no significance in the etiology of sympathetic ophthalmitis, though a swollen lens, by pressing upon the surrounding parts, can certainly aggravate an already existing cyclitis. The *operations* of iridodesis, discission, iridectomy, reclinatio, and cataract extraction have been followed by sympathetic ophthalmitis. Mackenzie states in his book that he never

saw sympathetic ophthalmia follow any of the operations for cataract. Among other causes mentioned by most writers are *intraocular tumors*, particularly the melano-sarcoma, and cysticercus is reported to have given rise to sympathetic ophthalmitis (two cases). There are good reasons, however, for regarding both sarcoma and cysticercus as very doubtful agents in the production of the affection, and the same may be said of *ossification* within the eye.

**Symptoms.**—Accommodative asthenopia is the first symptom, and shows itself on the slightest attempt to fix an object, no matter of what size or at what distance. This symptom may be lacking, and instead of it the patient sees a mist around everything. Pain is usually absent, but pressure on the ciliary region elicits tenderness which is often quite characteristic.

Pericorneal congestion is more or less marked. The media are cloudy. The earlier stages of the affection are associated with slight increase in intra-ocular tension, followed by vacillating conditions of tension, mounting up to a high grade in the glaucomatous stage, while at the last the tension is much diminished. The iris is hyperemic. Pagenstecher has called attention to the fact that in this kind of iritis the pupil can readily be dilated in spite of the synechia. It is possible for the process to disappear at this point and never return, but this is seldom the case. The attacks come at frequent intervals and with renewed intensity. After every recurrence the synechia are firmer and the pupil is harder to dilate. Pain may now develop. Small grayish dots appear on the posterior surface of the cornea. Synechia are to be seen extending all the way around the pupil. Recession of the iris periphery is present.

In nearly every case the primarily affected eye is blind before the outbreak of the sympathetic disease; but cases are on record where vision was still present in the injured eye at the time of the appearance of the sympathetic inflammation. The following constitutional symptoms may be seen: a quickened pulse, thirst, pallid complexion, and obstinate constipation. The course of the disease is usually tedious.

*Sympathetic serous iritis* is a much milder type of the disease. The symptoms are those of serous iritis. This may be regarded as a comparatively benign form of sympathetic ophthalmitis, which may pass over into the pernicious form—*plastic irido-cyclitis*—which has been described above.

*Sympathetic papillo-retinitis* has been observed a certain number of times, and, in contradistinction to the genuine sympathetic ophthalmitis, shows no tendency to relapses. Schirmer states that the disease has never been observed after the enucleation of the injured eye. It is a benign affection, and restoration of sight is the rule. A *sympathetic choroido-retinitis* has also been described.

**Diagnosis.**—The disease has no peculiar train of symptoms by which it can be invariably recognized. If pronounced objective symptoms of a plastic irido-cyclitis appear in an eye which had remained sound for three weeks after the fellow-eye had been the seat of a traumatic irido-cyclitis, the case may be regarded as one of sympathetic ophthalmitis. The diagnosis will be free of doubt if three weeks is considered as the earliest date for the outbreak of the sympathetic affection; later than the fourth month the diagnosis becomes more or less uncertain.

Mackenzie says that the disease may be complicated with scrofula and assume a good deal of the scrofulous character, or it may be complicated with syphilis. Cerebral complications have been mentioned in connection with sympathetic ophthalmia.

**Sympathetic Irritation.**—This condition was once regarded as simply

the forerunner of sympathetic inflammation ; but it is a much more frequent affection than the latter disease, and differs from it in several vital points. Photophobia, lachrymation, pains in the head and orbit, and blepharospasm are frequently present. The affection reminds one somewhat of phlyctenular conjunctivitis. The neuralgia is often remittent in character and very violent. There is concentric narrowing of the field of vision. Shadows and clouds are often seen when an effort is made to look at an object. More or less obscuration of objects occurs from time to time, the obscuration lasting several seconds, and then the objects appear as distinct as ever. The pupil is generally small, but the movements of the iris are intact. According to Noyes, the range of accommodation is diminished.

The disease shows itself at periods ranging from two and three weeks to fifteen and twenty years after the injury of the first eye, and is communicated to the sound eye through the medium of the ciliary nerves.

**Pathogenesis of Sympathetic Ophthalmitis.**—Up to 1858, Mackenzie's views prevailed pretty generally—namely, that the optic nerve was the channel of communication. Müller, however, concluded that the sympathetic disease was due to irritation of the ciliary nerves, together with an influence which affects nutrition, secretion, and accommodation. Müller's views gained many adherents, among others von Graefe ; indeed, the so-called *ciliary-nerve theory* became at once the popular one, and remained so for a long time.

The *optic-nerve theory* was revived by Horner and Knies in 1879.

In 1881, Snellen, Berlin, and Leber advanced the opinion that the disease was of parasitic origin.

Maats, under Donders' direction, in 1869 undertook the experimental solution of this problem, and his experiments were repeated at a later date by Snellen and Rosow. All three of these observers obtained negative results.

Of all the experimental work on this subject, that of Prof. R. Deutschmann of Hamburg has attracted the most widespread attention, and his results were regarded at first as absolutely conclusive. He claimed to have produced sympathetic ophthalmitis in the eye of a rabbit by injecting a drop of a suspension of the *staphylococcus aureus* into the vitreous body of the fellow-eye. Quite a number of experiments were made, and he felt justified in the following conclusions: That sympathetic ophthalmia is a parasitic disease which makes its way from one eye to the other by way of the optic nerves and chiasm. The organisms work their way forward by reason of a certain impetus which comes from their growth, as well as from their power of spontaneous movement. In this way they reach the base of the brain, where they are swept down by the lymph-stream into the sheaths of the opposite optic nerve, and thus reach the second eye. This movement on the part of the lymph-stream explains why the organisms do not spread themselves over the base of the brain and produce meningitis.

The experiments of Deutschmann were subjected to the closest scrutiny, and in spite of the work of Alt, Gifford, Mazza, Randolph, Limbourg and Levy, Schirmer, Greef, Ulrich, and Bach, there has never appeared any evidence to lead us to believe that Deutschmann's experiments are conclusive. In fact, the investigations of these observers strengthen the view which has been held, that sympathetic ophthalmitis cannot be produced in the lower animals, certainly not with the pus-organism. From this it would seem that Deutschmann's work is by no means conclusive, and that it is more than probable that this observer fell into errors of interpretation. The pus-organism probably plays no part in the production of the disease in man,



as is illustrated by the rarity of sympathetic ophthalmitis after panophthalmitis, where the pus-organisms are usually present in such great numbers.

Wounds of the ciliary region have been thought to peculiarly predispose to sympathetic ophthalmitis, but experiments on the lower animals have shown that so long as the instrument was sterilized the wound, no matter if located in the ciliary region, healed invariably with little or no inflammatory phenomena. Experiments of this character show that injuries in the ciliary region are not in themselves sufficient to give rise to sympathetic ophthalmitis, but that something else is necessary, a something modifying the character of the wound itself. A wound, however, which is infected would, for sound anatomical reasons, be more apt to set up sympathetic trouble if located in the ciliary region than if located anywhere else in the eye. Reference here may be made to the works of Bach and Schmidt-Rimpler, both of whom lean toward a somewhat *modified ciliary-nerve theory*.

The uniformly negative results of the various experimenters do not disprove the bacteric origin of sympathetic ophthalmitis, but before regarding the theory as proved the specific organism must be identified.

**Prognosis.**—The prognosis is always a matter of grave doubt. Well-established recoveries are rare. Waldispuhl, summing up the statistics of Prof. Schiess's clinic in Bâle, reports four recoveries in ten years. Cases of recovery are reported by Hirschberg, Laqueur, Schirmer, Rogman, and Randolph. Relapses are the rule, and this fact should lead us to be guarded in holding out the prospect of definite recovery. A patient who has passed two years without a relapse may be regarded as comparatively safe.

**Treatment.**—The *prophylactic* treatment naturally plays a most prominent part in dealing with sympathetic ophthalmitis, and it seems clear that the only certain prophylaxis is the enucleation of the injured eye. When sympathetic irritation exists and there is no special reason for believing that sympathetic inflammation will appear, resection of the optic nerve may be substituted for enucleation. This is often the case in eyes which have been lost from other causes than from penetrating wounds; for instance, in absolute glaucoma or where inflammation has destroyed the entire cornea and phthisis bulbi has followed. It would be safer to enucleate an eye blind from a penetrating wound. When the eye has some vision, it is an exceedingly difficult question to decide. The best guide in such a case is probably the tension and sensitiveness to touch. If the eyeball is sensitive to the touch and the tension diminished, and at the same time only light-perception is present, the chances of improvement for this eye are bad, and especially so if these conditions persist for several days after the injury. In this case enucleation is indicated.

When the injured eye is blind and sympathetic irritation is present in the other eye, it is best to enucleate.

When the injured eye possesses a little vision and symptoms of irritation appear in the other eye, every effort must be made to improve the condition of the injured eye; and this means to apply the rules governing the treatment of an irido-cyclitis.

When sympathetic inflammation has broken out the injured eye, if blind, should be removed; if not blind, the same course should be pursued as suggested when the condition is that of sympathetic irritation in the second eye—in other words, do not enucleate.

As regards medicinal agents, we possess nothing which exercises a specific influence for good in this disease. Atropin should be used, but always guardedly. Absolute rest and darkness are essential. Hot fomentations,

such as have been described in the treatment of iritis, do good service; so also the various ways of applying dry heat. Calomel in small doses is certainly helpful. Injections of pilocarpin have been known to do good. The injection of one drop of a sublimate solution (1 : 1000) has been strongly advocated by Abadie.

The influence of an operation is hurtful so long as there is present any evidence of an acute inflammation. The chief obstacle to vision is the opaque lens, and after all acute symptoms have disappeared Critchett suggests the following procedure: A fine needle is directed to the center of the opaque capsule, and the latter is pierced. Another needle is passed in from the opposite side, and by bringing the penetrating force of one needle to bear upon the other a small opening is made in the capsule. The points of the needles are then separated. In this way quite a rent is made. There is generally an escape of lens matter. Little or no reaction follows. An interval of several weeks is allowed to pass to permit the absorption of some lens substance, and then the operation is repeated, and so on, the operation being performed every time with two needles. Critchett and Story report cases where useful vision was obtained by this operation.

#### DISEASES OF THE CHOROID.

**Congenital Anomalies of the Choroid.**—Coloboma of the choroid is a circumscribed, frequently half-spherical-shaped defect in the choroid and retina, as seen in Fig. L, Plate 3. It presents a brilliant white color (due to the exposed sclera) with the ophthalmoscope, and it will be observed that the surface of the coloboma is distinctly below the plane of the retina; in other words, the surface is concave, and ridges and depressions can be seen upon it. Generally, two or three fine retinal vessels can be seen to dip at the edge of the coloboma, and then pass on over the surface of the latter. The coloboma usually begins a short distance from the optic nerve, or it may take in the papilla, and, assuming the shape described, pass downward and come to a stop at a certain distance from the ciliary body. It may reach a point so far forward that its anterior border can no longer be seen. The border of the coloboma is pigmented, and pigment-spots are often to be found upon its surface. Coloboma of the choroid is generally associated with the same defect in the iris. Such eyes are sometimes microphthalmic. The retina, as well as the choroid, may be absent at the site of the coloboma, and only the sclera remain beneath. At other times the retina may be present, and covers the coloboma in its entire extent. Of course there is always a defect in the visual field corresponding to the location of the coloboma. According to Meyer, myopia, amblyopia, and accommodative asthenopia are often present.

White depressions of various sizes situated in the macular region are regarded by some authors as similar defects, and are spoken of as *macular colobomata*, while Lindsay Johnson describes them as the atrophied remains of nevoid growths in the choroid.

Coloboma of the choroid is due to incomplete closure of the ocular fissure, and it is an affection which in a marked degree is transmissible by inheritance (see also page 192).

**Albinism.**—This is a condition where there is either a partial or complete absence of pigment in the choroid. The affection is congenital. The pupil has a reddish luster, and is somewhat smaller than normal. The iris appears reddish by transmitted light. This latter phenomenon is due to the

fact that much of the light is not absorbed, owing to the lack of pigment. The vessels of the retina and choroid may be plainly seen with the ophthalmoscope. Photophobia is the rule in this condition, and a shady place is always grateful to such patients. Nystagmus, amblyopia, and high degrees of myopia and astigmatism are usually coincident conditions. The cells which usually contain the pigment are present, but the pigment itself is absent. The affection is hereditary. The treatment consists in measures to ameliorate the photophobia and the correction of the refractive error.

There is a condition in which the stroma of the choroid is richly pigmented, while the epithelium is lacking in pigment, and consequently is transparent. Under these circumstances the so-called *choroidal intervacular spaces* exist, which look very dark, owing to the character of the stroma-pigment. This condition is sometimes seen in negroes.

**Hyperemia of the Choroid.**—This condition undoubtedly exists, but is questionable whether it can be diagnosticated. According to de Schweinitz, we may assume hyperemia of the choroid when the nerve-head presents distinct redness, which is imperfectly differentiated from the unduly flannel-red appearance of the surrounding choroid, or when the choroid, instead of exhibiting its usual red color, has changed into what has been denominated a "woolly choroid," with faint dark areas in the periphery, indicating the interspaces between the choroidal vessels and more or less retinal striations surrounding the disk. The condition is ordinarily supposed to be due to "eye-strain," and should be treated accordingly. Dark glasses and complete rest should be ordered until the changes described have entirely disappeared, and then the error of refraction should be corrected.

**Choroiditis.**—Inflammation of the choroid may be either *non-suppurative* (commonly called *exudative*) or *suppurative*.

1. **Exudative Choroiditis.**—*Etiology.*—The most common cause is syphilis, both hereditary and acquired. Any profound disturbance in the nutrition, such as scrofula or anemia, may give rise to the same disease. Meyer mentions the fact that this form of the disease is sometimes found in women who suffer with menstrual disturbances or at the climacteric. Myopia cannot be said to cause choroiditis in the same sense as syphilis, for the changes in the former are more of the nature of degenerative changes than of true inflammatory ones, and are due to the stretching to which the posterior segment of the eyeball is exposed in myopia of very high grade.

**Pathological Anatomy.**—The histological changes are usually sharply defined, and correspond to the ophthalmoscopic picture; that is to say, there is no general involvement of the choroid except in cases of many years' standing. The vessels are frequently engorged, and round-cell infiltration is found near them. Small open spaces containing fibrin and hyalin drops are often seen. Hemorrhages are occasionally observed. The pigment-cells are sometimes devoid of processes, and often have a proliferation of pigment. Later on the choroid becomes atrophied and fibrous, and the pigment-clumps become scarcer and may disappear entirely. In those cases where the exudate has forced its way into the layer of rods and cones, this layer may be completely broken up.

The following interesting changes are mentioned by Schweigger as occurring in *disseminated choroiditis*: Little nodules are seen scattered through the stroma of the choroid, which consist of nucleated fibers and non-pigmented cells. The surface of these nodules is at first covered with very black pigment-epithelium, which gradually disappears from the center outward, so that we have the well-known picture of a white area surrounded

PLATE 3.

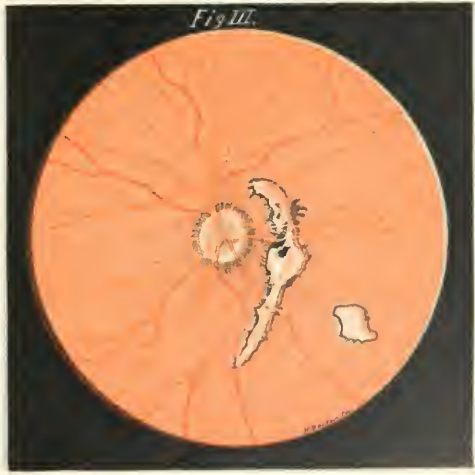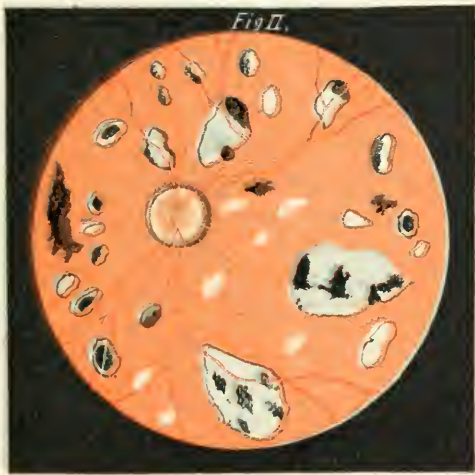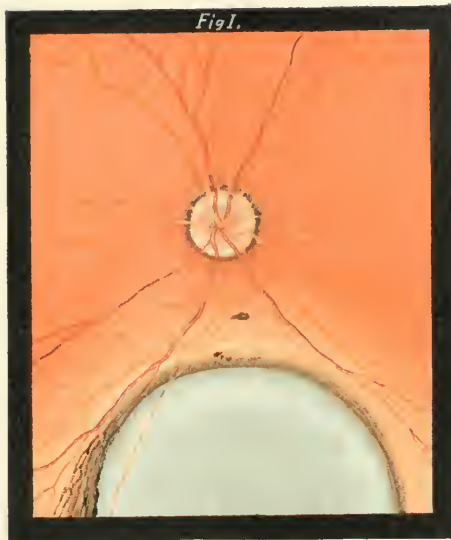


FIG. I.—Coloboma of the choroid ; the case also had a coloboma of the lens.  
FIG. II.—Disseminated choroiditis ; nearly normal, central acuity of vision.  
FIG. III.—Rupture of the choroid from a blow with a ball.





with a black ring. At points we have a proliferation of the pigment-epithelium. The new-formed cells contain no pigment. When the process extends into the retina, we have an elongation of the radiating fibers, and they sometimes bend abruptly and are found bound fast to the choroid.

**Symptoms.**—With the ophthalmoscope will be seen yellowish-white spots scattered over the red fundus and lying under the blood-vessels of the retina (*recent choroiditis*). As time goes on this yellowish color disappears, and gives way to white, which is an indication that the choroid has lost its pigment (*atrophy*) and that the sclera is exposed. Specks of pigment are often to be seen on these atrophic areas. Sometimes the exudates are very small, and are found either isolated or in groups, and located in various parts of the fundus (*disseminated choroiditis*). Dust-like opacities and floating membranes in the vitreous body are common in exudative choroiditis (Fig. II., Plate 3).

Disturbances in vision are always present, showing themselves in narrowing of the field and loss of visual acuity, though it is astonishing how good vision may be in cases where the ophthalmoscope shows an involvement of apparently the entire fundus. The patient complains of seeing specks floating before the eyes. Photophobia, metamorphopsia, and night-blindness are present in a certain number of cases. The disturbances in vision arise partly from the opacities in the vitreous body, and partly from a functional disturbance of the retina, which is always to some extent involved.

In the earlier stages of disseminated choroiditis there is often a coincident dilatation of the retinal blood-vessels, owing to the involvement of the retina. This variety of choroiditis is sometimes called *syphilitic choroiditis* (see page 419).

Again, in the vicinity of the optic nerve rather prominent foci of inflammation, composed of transparent, non-pigmented tissue, may be found; and at these points the retina is atrophic. These areas appear at first as deeply pigmented spots, having a bright yellowish center and surrounded by a red

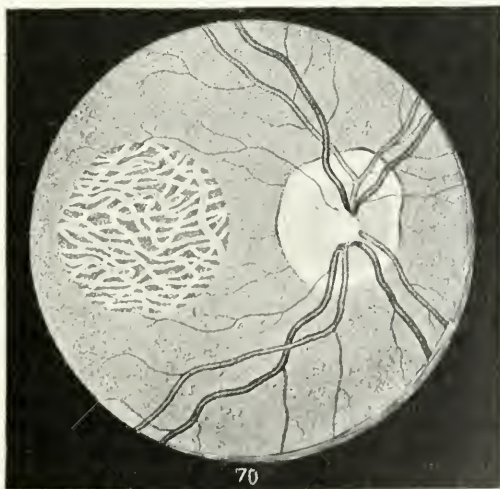


FIG. 229.—Central choroiditis (De Wecker and Jaeger). The circular character of the patch and the exposure and partial atrophy of the deep vessels are well shown.

hyperemic ring. Later on these areas become flatter, are bordered with pigment, and traversed by choroidal vessels. This is *areolar choroiditis* (Förster). In both areolar and disseminated choroiditis the regions of the fundus between the diseased areas are usually sound in the earlier stages of the affection.

Sometimes the exudates are located chiefly in the macular region (*central choroiditis*, Fig. 229). The disturbance in visual acuity in this variety of the affection is very pronounced. While any of the causes mentioned above may give rise to central choroiditis, its most frequent cause is myopia of high grade. Among other special causes are contusions of the eyeball; for instance, a blow which gives rise to rupture of the choroid will often be followed by choroidal changes in the macular region.

The macular region may be the seat of a large white patch, while the rest of the fundus is normal (*senile arcular atrophy of the choroid*).

Again, in the same locality may be found small white, glistening spots closely resembling the changes which are seen in albuminuric retinitis. Generally these changes are found in both eyes. They constitute the *senile guttate choroiditis* of Tay and Hutchinson. The white specks are due to colloid degeneration of the choroid (Fig. 230).

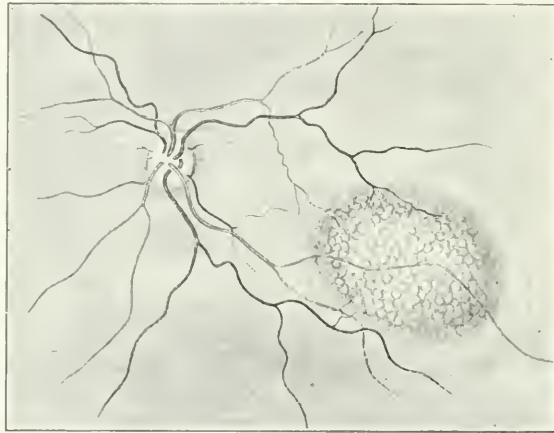


FIG. 230.—Colloid change in the macular region (de Schweinitz).

Changes in the macular region, consisting of white plaques of various sizes and shapes, associated with atrophy of the choroid at the border of the disk, are often seen in high grades of myopia, and are spoken of as *myopic choroiditis*. The peculiar crescent-shaped area at the disk is known as *posterior staphyloma*, and is to be attributed to the protrusion of the sclera backward.

Patches of choroidal atrophy may be found at any point in the fundus, and may result from various causes, as from the action of brilliant light or the glare of heat, or from the so-called *hemorrhagic choroiditis* in young men (Hutchinson). These and other changes in the choroid which are typical of no special lesion are regarded as *unclassified forms of choroiditis*.

**Diagnosis.**—It is certain that in the majority of cases there are changes in the retina, so this condition may be assumed to be present. It is very often a question, however, whether the exudates seen with the ophthalmoscope lie in the retina or the choroid. Retinal exudates are supposed to be more opaque, and to be bordered by fine radiating lines corresponding to the direction of the nerve-fibers (Meyer). The blood-vessels of the retina in retinitis are tortuous, and often disappear under the exudates, while the course of the retinal vessels may be plainly traced when the exudates lie in the choroid; and this rule also applies to the situation of pigment-masses. Masses of pigment resembling bone-corpuscles are always situated in the retina (Nettleship).

**Prognosis.**—When atrophy of the choroid has taken place, the outlook is absolutely bad. Floating opacities in the vitreous body, as a rule, persist in spite of all treatment. As a general thing, the prognosis in choroiditis is unfavorable, and worse when the changes are prominent in the macular region. Of course the earlier the disease is recognized the more may be hoped for from treatment. Those cases clearly due to syphilis offer the best chances for improvement.

**Treatment.**—Antisyphilitic treatment in certain cases is followed by improvement, and even by cure. Recurrences are very common. In cases where syphilis can be excluded the mercurials and iodid of potassium through their absorptive power do good service, and should be used. The application of six or eight leeches or the artificial leech (Heurteloup) to the skin behind the mastoid process has been strongly recommended. Good results have been reported from the injection of  $\frac{1}{4}$  grain of muriate pilocarpin every other night. Cod-liver oil and iron are specially indicated in children. The eyes should not be used for work, and dark glasses are advisable. Subconjunctival injections of bichlorid and cyanid of mercury have been recommended by Darier and others, but are of doubtful value.

2. **Suppurative Choroiditis.**—As the name implies, this is an affection of the choroid suppurative in character, and one which rapidly involves the iris and ciliary body.

**Etiology.**—The most frequent causes are injuries from penetrating foreign bodies. Suppurative choroiditis sometimes follows unsuccessful cataract operations. No matter what kind of instrument produces the wound, after all infection is responsible for the suppurative process. Sloughing ulcers of the cornea and the progress inward of the suppuration may be responsible for the affection.

The disease may result from *endogenous infection*—that is to say, from the organism itself. In these cases septic substances form a focus of inflammation, get into the circulation, and are carried into the choroidal vessels, and here stop and form a septic embolus, which at once gives rise to the choroiditis (*metastatic choroiditis*). This phenomenon is sometimes seen in the pyemia of the puerperal state. Suppurative choroiditis may follow cerebrospinal meningitis and typhus. Inflammation of the umbilical vein and thrombosis of the orbital veins have been known to cause the disease.

**Pathological Anatomy.**—The choroid and retina are enormously thickened and infiltrated with round-cells. In fact, in advanced stages the choroid and retina lose their identity almost entirely, and we simply find large areas made up of coagulated material and round-cells, with here and there a clump of pigment-granules. The exudate having found its way into the vitreous body, the latter is converted into a homogeneous mass of exudate. Round-cell infiltration of the iris and ciliary body is seen with numerous hemorrhages and more or less change in the pigment-epithelium, the latter changes manifesting themselves either in a breaking up or in an entire disappearance of the epithelium.

**Symptoms.**—The lids are red and swollen, so much so that often they cannot be opened, and the orbital tissue is frequently so infiltrated as to interfere with the movements of the eyeball. The conjunctiva is intensely congested, often reaching the grade of chemosis. The cornea sooner or later becomes clouded, but before the media have lost their transparency one can see the characteristic yellowish reflex in the pupil, arising partly from the mass of exudate in the vitreous body and partly from the detached retina. Hypopyon and anterior synechiae are usually present. The intraocular tension is elevated in



the earlier stages, the pupil is dilated, and the anterior chamber shallow. Intense throbbing pain is felt in the orbit and brow, and sight is lost. Chills and fever are frequently present.

**Diagnosis.**—Only one condition simulates the peculiar reflex seen in suppurative choroiditis, and that is glioma of the retina. Apart from the general history, there is this marked difference. In suppurative choroiditis the tension is always elevated in the stage when it is apt to be first seen, and this condition is followed soon by either lowered tension or by bursting of the eyeball. In glioma the tension in its early stages is normal, and increased tension does not make its appearance till the latter stages of the affection. The previous history of the case is probably the most reliable basis for a differential diagnosis (see also pages 400 and 494).

**Prognosis.**—The outlook is absolutely bad. Loss of sight and shrinkage of the eyeball (*phthisis bulbi*) are the rule.

**Treatment.**—It is not possible to put a stop to the process, so all that can be done is to relieve the suffering of the patient—locally by hot applications, and internally by the administration of narcotics. Violent and persistent pain can be remedied by a free incision in the sclera. This may be found necessary in those cases of *panophthalmitis* where spontaneous rupture is slow in taking place.

As to the advisability of enucleation or evisceration in the acute stages of panophthalmitis, there is a difference of opinion. While a few cases of death have been reported after the enucleation, the risk is very slight, and it is by no means certain that the operation was responsible for the unhappy issue in those few cases. Meningitis has been reported after evisceration, and, indeed, where no operation was performed.

**Tuberculosis of the Choroid.**—This condition was first described by Jäger, and later by Manz, Busch, and Bouehut. The tubercles appear as small, round, slightly elevated, reddish or gray nodules, varying in size from 0.3 to 2.5 mm. The spots are sometimes quite numerous, even as many as fifty being noticed, and they are distinguished from somewhat similar choroidal changes in that they are not surrounded with a border of pigment. These nodules are usually found in the vicinity of the optic nerve.

The little nodules on anatomical examination are seen to possess the typical structure of tubercles. A part of them sometimes undergoes caseous degeneration (Manz). Giant-cells have been observed in them (Alt), and the *tubercle bacillus* has been demonstrated. According to Cohnheim, the affection forms one of the symptoms of acute general miliary tuberculosis, and it may aid in diagnosing the constitutional disease.

Sometimes a *solitary tubercle* is observed, which grows like any other intraocular neoplasm, and finally breaks through the sclera. This condition is a rare one, and is usually associated with cerebral tuberculous, and is an affection peculiar to children.

**Treatment.**—Miliary tubercles demand no special treatment, but enucleation is the proper course to pursue in solitary tubercle in order to prevent a general infection.

**Atrophy of the Eyeball.**—Atrophy of the eyeball consists in a gradual diminution in the size of the eyeball, accompanied with diminished intraocular tension and altered shape. The change in the size and shape is to be attributed to the contraction of the exudates within the eyeball—exudates which have resulted from the plastic irido-cyclitis. Fuchs says that this condition differs from *phthisis bulbi* in that the latter affection is a much more rapid one, and results from the rupture of the eyeball and the evacuation of

its contents. After panophthalmitis the eyeball often becomes as small as a hazelnut or even smaller, while in atrophy no such stage is commonly reached.

**Essential Phthisis Bulbi** (*Ophthalmomalacia*).—This is a very rare affection in which there are lowered intraocular tension and diminution in the size of the eyeball without any assignable cause. Photophobia, neuralgic pains, myosis, and partial ptosis are sometimes present. The condition may last for several days, and then disappear without leaving any traces. It is supposed to be due to a lesion of the sympathetic. It may follow injury.

**Rupture of the Choroid.**—Rupture of the choroid is caused by a powerful blow upon the eyeball. The blow has the effect of stretching the sclera. At first it is impossible to make out the exact nature of the trouble, owing to the extravasations in the vitreous body. As soon as the vitreous body becomes transparent one can see a long, bright, sickle-shaped streak on the temporal side of the papilla, and with the concavity of the sickle directed toward the papilla. When first seen the streak is yellowish in color, but it soon becomes white and has a pigmented border. Small spots of choroidal atrophy are frequently seen in the neighborhood of the rent, and these changes may invade the macular region. It is certain that the retina and sclera are both injured. The retinal vessels will generally be seen passing over the injured point, except in those cases where the retina itself participates in the rupture. No good reason has been advanced as to why the posterior part of the choroid is disposed to rupture. We may have the rupture occurring in one spot or in several spots (Plate 3, Fig. III.).

The vision at first is almost extinguished, but after the blood in the vitreous clears away good vision is often restored. Cases are reported by Knapp and Saemisch where central visual acuity returned to almost the normal standard. As a consequence of rupture of the choroid, retinal detachment, glaucoma, and optic-nerve atrophy have been observed. Traumatic cataract and dislocation of the lens are also complications (see page 364). The treatment consists in a compress bandage and atropin. It is doubtful whether the subsequent use of strychnin or iodid of potassium does good.

**Detachment of the Choroid.**—This is an exceedingly rare condition. One observes a round-looking mass projecting into the vitreous body. The surface of this mass is perfectly smooth, and the retinal vessels can be seen upon it. The color of the protuberance is sometimes yellowish, with pigmented areas here and there about it. Meyer says it may be distinguished from detachment of the retina because it does not move with every movement of the eyeball. Detachment of the retina is usually present. The tension in detachment of the choroid is always diminished. Marshall thinks that the following factors are necessary to cause this condition: hyalitis with shrinking; choroido-retinitis leading to adhesions and serous exudation between the choroid and sclerotic.<sup>1</sup> Risley reports detachment of the choroid caused by the concussion at the discharge of a gun.<sup>2</sup>

**Ossification of the Choroid.**—This is not infrequently found in shrunken eyes where sight has been lost many years previously. A thin shell of bone is found in the posterior part of the eyeball, with a small hole in its middle for the passage of the optic nerve; or sometimes simply a spicule is found. The mass possesses all the histological characteristics of bone anywhere else in the body. The eyeball is often painful to the touch, and it may give rise to sympathetic irritation; so enucleation is always advisable. *Calcareous degeneration* is also common in eyes of this character.

<sup>1</sup> "Detachment of the Choroid," by C. D. Marshall, *Trans. Ophthal. Soc. U. K.*, xvi. p. 98.

<sup>2</sup> *Amer. Journ. Ophthal.*, March, 1897.

# INJURIES OF THE EYE AND ITS APPENDAGES.

BY ALVIN A. HUBBELL, M. D., PH. D.,

OF BUFFALO, N. Y.

THE eye may be injured in a great variety of degrees and ways by contact with overheated substances, as hot vapors, liquids, or solids; or with caustics or escharotics, as acids, caustic alkalies, and lime, whereby the parts become burned or corroded; or by mechanical forces or bodies impinging upon it, whereby its tissues are contused, lacerated, abraded, cut, or penetrated.

**Injuries of the Cornea and Conjunctiva from Heat and Chemicals.**—Heat and chemical substances affect the tissues of the eye similarly. The anterior portion of the eyeball is most exposed to these agencies, and is therefore more frequently injured by them, the palpebral conjunctiva suffering only when the injurious substance gets beneath the lids. Burning gases and hot water or oil cool quickly, and seldom reach the surface under the lids. Their effects, therefore, are more superficial and less extended than those of hot or molten metals or of chemicals and lime.

When the injury is superficial a whitish film is formed which is soon thrown off, and the parts rapidly regain their epithelium and their normal transparency (Plate 4, Fig. 1.). When the injury affects the deeper tissues the eschar is thicker, and its elimination leaves a granulating surface, which on healing may contract or lead to adhesions if it is on the conjunctiva, or produce an opacity if it is on the cornea. Should the whole thickness of the cornea be involved, a perforation will take place with all of its consequences.

**Symptoms.**—Besides the appearances above noted, there are, immediately after the injury, severe burning pain, redness of the eyeball, and lachrymation. Later, active inflammation may take place, with increased redness, and even chemosis, of the conjunctiva and swelling of the lids. When a considerable surface of the conjunctiva is affected, the secretion becomes muco-purulent, and sometimes purulent. Implication of the cornea causes much pain and impairment of vision.

**Treatment.**—When the case is seen immediately and the injury is from an acid, it should be neutralized by the application to the affected area of a weak alkaline solution. For this purpose bicarbonate of soda or bicarbonate of potash (saleratus) may be used. The latter has the advantage of accessibility, as it may be found in almost every house. When the offending agent is lime, caustic soda, caustic potash, or other alkali, it may be neutralized by an acid largely diluted, and here vinegar, diluted, answers the purpose, and generally is also within easy reach.

After neutralizing the chemical and removing such foreign substances as may be present, the parts should be cleansed with some mild antiseptic, and

PLATE 4.

FIG. I.

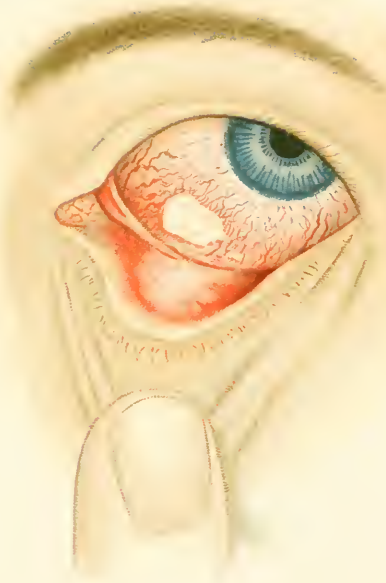


FIG. II

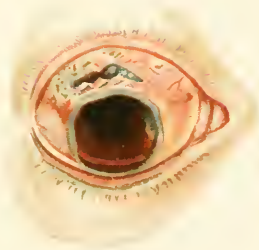


FIG. I.—Burn of the bulbar conjunctiva from bichlorid of mercury.  
FIG. II.—Rupture of the sclerotic, with hemorrhage into the anterior chamber (after Sichel).





iced cloths kept constantly applied over the eye till the burning pain has ceased. Frequent instillations of a cocain solution will contribute much toward the relief of the pain. The subsequent treatment is the same as that of conjunctivitis or of ulceration of the cornea from other causes.

In cases where opposing surfaces of the conjunctiva are denuded, but the retrotarsal fold is unaffected, adhesion, or *symblepharon* (Fig. 231), may be prevented by frequently drawing the lid away from the eyeball or by interposing some smooth, flat substance between the lid and ball. But when the denudation includes the retrotarsal fold, such efforts will be absolutely fruitless and may as well be withheld. Should the lesion of the ocular conjunctiva be limited in extent, it may be covered, either immediately after the injury or after the eschar has sloughed off, by drawing the surrounding conjunctiva over it with sutures introduced from side to side. Sometimes adhesions can thus be very much restricted or even prevented.

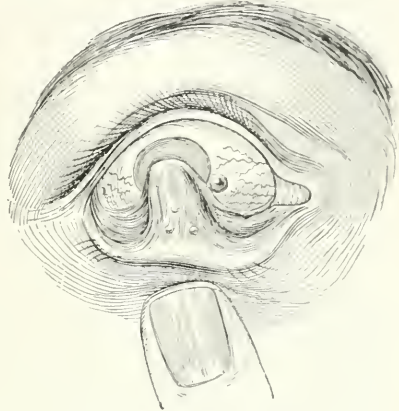


Fig. 231.—Symblepharon (Sichel).

**Mechanical Injuries of the Cornea without the Lodgement of Foreign Bodies.**—These injuries include *scratches*, *contusions*, *superficial punctures*, and *erosions*, and may be inflicted in a multitude of ways.

**Symptoms.**—Injury of the cornea is determined by inspection, aided by oblique illumination, and is shown by loss of epithelium and irregularity of the injured surface. The denuded area may be detected by coloring it with fluorescein (page 145). Should ulceration or suppuration of the cornea take place, there will be added the appearances which these conditions usually present.

There is a scratching, pricking feeling in the eye at first, and afterward there may be severe pain. The eyeball becomes red, there is free lachrymation, and, with a lesion centrally situated on the cornea, vision is more or less impaired.

**Prognosis.**—This depends on the part injured and the progress of the case. There is impairment of sight in proportion to the involvement of the center of the cornea and the distortion of it which the injury and cicatrization cause. Wounds of the cornea are extremely liable to infection, and are therefore prone to ulceration or suppuration.

**Treatment.**—The eye should first be cocainized, and the injured parts gently but thoroughly cleansed with 1:4000 solution of bichlorid of mercury, care being exercised not to rub away or loosen the adjacent corneal epithelium. Atropin solution should then be instilled and a compress bandage applied.

The subsequent treatment consists in using some form of antiseptic, continuing the instillations of atropin, and keeping the eye covered. Should ulceration or suppuration take place, it is to be treated as elsewhere described (see page 315).

**Mechanical Injuries of the Conjunctiva without the Lodgement of Foreign Bodies.**—The conjunctiva may be *cut*, *lacerated*, *punctured*, or *contused* in many ways and by many kinds of objects.

**Symptoms.**—An effusion of blood (*ecchymosis of the conjunctiva*), sometimes only slight, underneath the conjunctiva at the site of the injury is one of the most constant symptoms. The ecchymosis usually spreads, and may even surround the cornea. A puncture or small cut is not always apparent, but when the wound is larger it is recognized by its roughened surface and reddened edges, and later by the whitish appearance of the parts denuded of conjunctiva. There is seldom any pain beyond a scratching feeling, as if a foreign body were beneath the lid, and the inflammatory reaction is seldom marked.

**Treatment.**—When the conjunctiva is cut or torn in such a manner as to gap or produce a flap, the eye should be cocainized and the wound closed by fine silk sutures. Instillations of boric-acid solution afterward are usually all the treatment that is necessary. Should the ecchymosis, however, be large and disfiguring, its absorption may be hastened by bathing the closed eye with water as hot as can be borne for fifteen or twenty minutes at a sitting, repeated two or three times a day.

**Injuries of the Eyeball from Contusion, Concussion, and Compression.**—A blow on the eye by some blunt substance, or striking the eye against some object, or a sudden compression of the eyeball by some peculiarly directed force, or a violent explosion near the eye, may result in a solution of continuity and contiguity of its tissues, without their being penetrated by the offending agent itself. Such lesions are *single* or *multiple*, and consist in general contusions of the ball; rupture of the intraocular blood-vessels; rupture of the outer coat of the eye; laceration of the iris; displacement of the iris; laceration of the ciliary body; detachment of the choroid; rupture of the choroid; detachment of the retina; rupture of the zonula; dislocation of the lens; rupture of the capsule of the lens; iridoplegia; cycloplegia; spasm of the circular fibers of the iris; spasm of the ciliary muscle; anesthesia of the retina; "commotion" of the retina; and pigmentation of the retina.

**Contusion of the Eyeball.**—A blow on the eye may bruise the tissues without causing any apparent laceration or other lesion.

**Symptoms.**—There are redness and tenderness of the eyeball, and sometimes pain. Occasionally there is produced anesthesia of the retina, mydriasis, loss of accommodation, spasm of the sphincter of the iris, or spasm of the ciliary muscle, with the symptoms belonging to each.

*Traumatic amblyopia* or *amaurosis* (Berlin) is said to exist when the vision becomes slightly and transiently impaired or entirely and permanently lost without visible anatomical change in the retina.

A similar condition has been described as *traumatic anesthesia of the retina* (Leber). This is shown by weakness, unsteadiness, and impairment of vision, with restriction of the visual field—conditions which may continue for several weeks or months (see also page 414).

*In mydriasis (iridoplegia)* the pupil is usually widely dilated. The dilatation may disappear in a few days, but it is frequently permanent. While it exists vision is dazzled when exposed to ordinary daylight from the admission of too much light into the eye.

*Paralysis of the ciliary muscle (cycloplegia)* is often associated with mydriasis, although it may exist alone. The patient cannot accommodate for near objects, while the vision for distance may not be affected.

*Spasm of the iris and ciliary muscle* is indicated by a contracted pupil and by apparent myopia.

**Treatment.**—The eye should be given rest, cold applications should be

used, pilocarpin or eserine should be instilled for mydriasis and loss of accommodation, and atropin for spasm. Retinal anesthesia has been treated by "suggestion," on the theory that it is hysterical in its nature.

**Rupture of the Eyeball.**—Rupture of the outer coat of the eye is of rare occurrence, and is produced by extreme violence. Its location is scarcely ever in the cornea, but it is most frequent in the anterior part of the sclera. It is largely determined by the position of the eye at the time of the injury, which is usually upward; the direction of the blow, which is generally from below or from below and outward; and the comparative weakness of the sclera between the margin of the cornea and the ciliary region. It is found, therefore, in most cases from one to three millimeters behind the margin of the cornea in the upper or upper and inner part of the sclera. Sometimes it is in the upper and outer part, or directly inward or directly outward. It is seldom directly outward. The rupture usually spans one-third to one-half of the periphery of the cornea. Partial rupture may occur in which the inner fibers of the sclera are torn, while the outer ones are more or less stretched. Rupture of the eyeball occurs almost exclusively in adults (see Plate 4, Fig. II.).

**Symptoms.**—A rupture of the eyeball is signalized by the following symptoms: immediate loss of sight, which may or may not be regained afterward; softness of the eyeball; congestion and ecchymosis of the conjunctiva; and, when the conjunctiva is not torn or the rupture is not situated anterior to its circumcorneal attachment, the presence of a distinct elevation or "tumor" of the conjunctiva from the extrusion of more or less of the intraocular structures. The edges of the rupture are ragged, and the lens, iris, ciliary body, choroid, retina, or vitreous humor may be protruding through it or entangled in it. Sometimes the iris or lens is entirely expelled from the eye or lodged underneath the conjunctiva. The other appearances are such as belong to rupture of blood-vessels, laceration of the iris, rupture of the choroid, and other lesions.

There is usually very little if any pain at any time, unless, as sometimes happens, severe inflammation supervenes.

**Prognosis.**—The prognosis is usually very unfavorable, although in exceptional cases useful vision has been known to return. The extensive lesions, the large amount of hemorrhage, the excessive loss of vitreous, and the inflammatory reaction are generally sufficient to produce loss of vision and shrinking of the eyeball. Should the wound unite imperfectly, *scleral staphyloma* may follow. Incarceration of the iris or ciliary body in the wound or a laceration extending into the ciliary body may cause *sympathetic ophthalmitis*.

**Treatment.**—When, because of very great injury of the intraocular structures, excessive hemorrhage into the vitreous chamber, or extreme collapse of the eyeball, there is no possible hope of recovery, time and suffering can be saved by enucleating or eviscerating the eye at once. But when there is reason to believe that there is a possibility of the eye being saved with partial vision, the practitioner is justified in making an attempt to do so, at least for two or three weeks, during which time there is scarcely any danger of sympathetic inflammation. At the end of this time, if the symptoms promise well, the effort may be continued. But if not, further risk should not be taken, except under peculiar and pressing circumstances.

If it be decided to try to save the eye, it should be cocaineized, and with strict antiseptic precautions the rupture should be closed. To this end the conjunctiva, if not already ruptured, should be opened (contrary to the old



practice), and all extraneous substances carefully removed, both from the outside and from between the lips of the wound. Protruding iris, ciliary body, or other tissue should be withdrawn and excised or cautiously replaced, as incarceration would interfere with solid union or cause irritation in the future. Any loose shreds hanging from the edges of the wound should also be cut off. Having thus made the wound as clean and smooth as possible, a sufficient number of fine antiseptic sutures, either silk or catgut, should be introduced from within outward and at a depth sufficient to hold firmly, and its edges closely drawn together. After tying and cutting off the threads, the wound should be covered, if possible, by conjunctival flaps held in place by suitably adjusted sutures. Catgut sutures may be allowed to remain, but silk ones should be removed in two to four days.

Having closed the wound, a solution of atropin should be instilled, the eye bandaged, and the patient put to bed and kept quiet for several days. Cold applications are useful, especially if inflammatory reaction threatens. Other conditions and symptoms are to be treated as they arise and according to directions given elsewhere.

When a case is not seen until after the wound has united the practitioner is generally quite powerless. Prolapse of the iris may be reduced by the galvano-cautery. Other lesions must be treated according to indications.

A *rupture of the cornea* is to be treated similarly to that of the sclera, except that it is not usually practicable to introduce sutures or to cover the wound with conjunctival flaps (see also page 569).

**Rupture of Ocular Blood-vessels.**—Contusion of the eyeball may rupture blood-vessels of the iris, causing effusion of blood into the anterior chamber—*hyphema*—or of the choroid or retina, causing effusion of blood into or beneath these membranes or into the vitreous humor—*hemophthalmia*.

**Symptoms.**—There is seldom any pain beyond that produced by the contusion. The presence of the blood usually obstructs the vision, either partially or totally. When the blood is in the anterior chamber it settles to the dependent portion, and its upper edge or surface is straight (see Plate 4, Fig. 11.). It is seen in its natural color or perhaps a little darkened. Blood in the vitreous humor appears with the ophthalmoscope as a dark object, and when large in quantity it may be seen, with the pupil dilated, by oblique illumination as a dark-red reflection.

**Prognosis.**—A hemorrhage into the anterior chamber of a previously healthy eye is absorbed in two to four days, but one into the vitreous humor requires weeks or months for absorption, and when it is of considerable size it often leaves permanent residues and opacities, and may even lead to disorganization of the vitreous humor and shrinking of the eyeball.

**Treatment.**—The treatment is limited to covering the eye, giving it rest, and instilling a weak solution of atropin. In some cases it may be preferable to instil pilocarpin instead of atropin. Hot water or hot fomentations continuously applied over the eye for fifteen to twenty minutes two or three times a day hasten the absorption of the blood. The internal administration of iodid of sodium or similar alterative is useful.

**Contusion-injuries of the Iris; Lacerations or Ruptures of the Iris.**—Aside from hemorrhages, the most common lesions of the iris from blows or contusions are rents or lacerations. In extreme cases the iris may be torn entirely from its peripheral attachment (*traumatic aniridia*), and when the eyeball is ruptured it may be expelled from the eye or a segment of it may be torn away instead of the whole (*traumatic coloboma*). Partial detachment of the iris from its periphery at one or more points (*iridodialysis*)

is the form of rent most frequently found. *Radial lacerations* rarely occur, and are usually at the pupillary border (*rupture of sphincter*).

**Symptoms.**—Hemorrhage is usually present in the anterior chamber at first, and it may obscure the parts. But after its absorption inspection with or without oblique illumination will reveal a laceration or rent of the iris if one exists, or the absence of the iris if it has been expelled. When it has been entirely detached, but not expelled, it will be seen in the bottom of the anterior chamber as a rounded mass, dark in color at first, but soon changing to an ash-gray. It rapidly shrinks to an inconspicuous size.

In a rent of the pupillary border, involving as it does the sphincter of the iris, the pupil is widely and permanently dilated (Fig. 232).

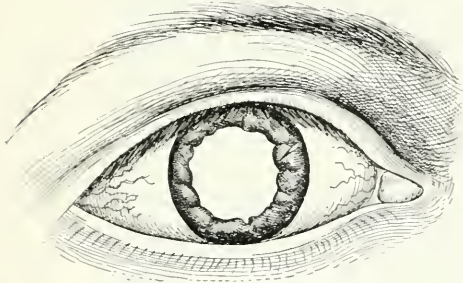


FIG. 232.—Radial laceration of the iris (Harlan).

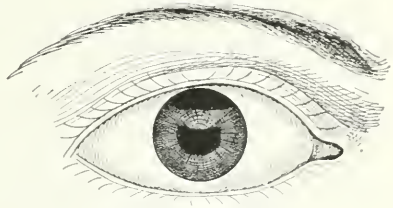


FIG. 233.—Iridodialysis.

*Traumatic coloboma* in connection with rupture of the sclera should not be mistaken for *retroflexion of the iris*.

In *iridodialysis* the rent is easily discerned, unless very small and hidden by the opaque limbus corneae. The portion of the iris detached retracts toward the centre of the pupil, and the latter loses its circular form and becomes somewhat kidney-shaped (Fig. 233). With the ophthalmoscope the fundus-reflex can be seen through the new opening as well as through the pupil.

**Treatment.**—Very little can be done to remedy most of these lesions. Dr. Eugene Smith<sup>1</sup> of Detroit has suggested that iridodialysis be corrected by making a small incision at the corneo-scleral junction at the place of the detachment, and by means of iris-forceps catching the edge of the iris and drawing it into the incision. It is usually held in place by the compression of the lips of the wound; but if this be not sufficient, it may be attached by a delicate suture to the neighboring conjunctiva. Before attempting this operation all irritation from the original injury must have subsided.

**Displacements of the Iris: Retroflexion and Anteversion.**—

Both *retroflexion* and *anteversion of the iris* are very rare. In *retroflexion* a part, sometimes the whole, of the iris is thrown backward, so as to lie against the ciliary body. The pupillary portion alone may be thus displaced, or it may carry with it the whole width of the membrane. It occurs almost exclusively in cases where the lens has also become displaced. Only a part of the circumference of the iris is implicated in most cases, and this part becomes invisible, the appearance being much like that of an iridectomy. When the whole iris has thus receded the appearance is that of aniridia.

In *anteversion* a portion of the iris is torn from its periphery (iridodialysis), and the loosened segment is twisted upon itself or turned over so that its posterior surface is directed forward. The exposure to view of the pigment-surface of the iris and the partial or complete obstruction of the

<sup>1</sup> *Journal of the American Medical Association*, Sept., 1891.

pupil, together with the traumatic opening of the iridodialysis, determine the existence of this double lesion.

These displacements call for no treatment, unless the vision be interfered with in anteversion by the detached membrane lying across the pupil, when it may be excised by an iridectomy.

**Contusion-injuries of the Ciliary Body.**—These undoubtedly may occur, but outside of such as accompany rupture of the sclera their existence is always difficult to ascertain and their diagnosis is doubtful.

**Contusion-injuries of the Choroid.**—These are hemorrhage, detachment, or rupture.

*Hemorrhage* may take place beneath the choroid, into its substance, or into the vitreous humor. In itself it obstructs the visual field, either as a whole or in sections, according to its extent and situation. When the hemorrhage is in or beneath the choroid it may be small or large, and appears with the ophthalmoscope as a bright-red spot of irregular, oval, or circular form. The retinal vessels pass over it without interruption. In extravasations into the vitreous humor the conditions and appearances are those already described.

*Detachment of the choroid* is but the effect of a subchoroidal hemorrhage. It disappears with the absorption of the blood, and unless it is very small a long time will be required to accomplish this result. Spots of localized degeneration and atrophy of the choroid will be left with pigmentary deposits around them (see also page 357).

*Rupture of the choroid* is usually single and situated between the optic disk and macula lutea, and the retina is seldom involved. It is generally curved and runs vertically, its concavity being toward the optic disk. It varies in width from one-third to one-half the diameter of the optic disk, tapering toward its extremities, and in length from one to four diameters. Exceptionally, there may be more than one rupture, or it may be branched and its direction may be oblique or horizontal.

The rupture cannot be seen until the blood, which has generally been effused into the vitreous humor, has been absorbed. It is then shown by the ophthalmoscope as a more or less sharply defined rent, at first yellowish with red margins, and later white with pigmented margins, and with retinal vessels passing unbroken across it (consult Plate 3, Fig. III.). *Detachment of the retina* sometimes follows cicatrization of a ruptured choroid.

In rupture of the choroid vision is at first much reduced or lost. After two or three weeks sight begins to return, but it is seldom fully regained. There is always left a scotoma corresponding to the rupture, and metamorphopsia is a common sequence (see also page 357).

**Concussion-injuries of the Retina.**—A blow on the eye may cause hemorrhage, rupture, detachment, so-called "commotion," or pigmentation of the retina.

A *retinal hemorrhage* is easily recognized by its elongated, irregular shape, by the break of continuity of a retinal vessel, and, if near the macula lutea, by a disturbance of vision and scotoma. The edges of the rent are ragged and the choroidal vessels are sometimes exposed. Whitish cicatricial lines, bordered with pigment, are seen later (Fig. 234).

"*Commotio retina*" is a term used to designate a peculiar effect characterized by edematous swelling and opacity of the retina, usually at the posterior part of the eye at a point opposite to that struck. It begins an hour or two after the injury in disseminated patches as grayish or dotted opacities. These gradually coalesce and become more dense, until there is



one continuous, whitish, and even brilliantly white surface of ten to twelve optic-disk diameters. This opacity is at its height in twenty-four to twenty-six hours, and usually disappears in two or three days. There may be retinal hemorrhages, and the retina may be ruptured or fissured, but its vessels are not hidden by the opacity.

The vision is much reduced or abolished at first. It improves for a short time rapidly, but afterward slowly. The central part of the field is that principally affected, and there seems to be no relation between the state of vision and the extent or depth of the opacity. The vision is further dis-

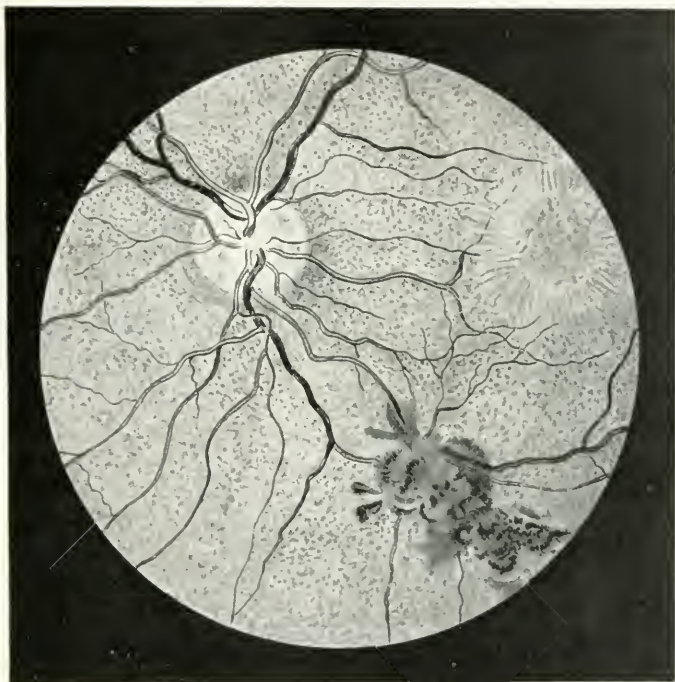


FIG. 234.—Ophthalmoscopic appearance of traumatic rupture of the inferior temporal vein (Oliver).

turbed by astigmatism caused by irregular spasm of the ciliary muscle and iris.

*Detachment of the retina* from a blow is not different in character and symptoms from that due to other causes (page 428).

*Pigmentation of the retina* is another result of contusion, and *choroiditis*, in all particulars resembling the exudative variety of this disease, may have the same origin (see also page 354).

**Treatment.**—In all these lesions the eye should be shaded and given rest. Atropin should be instilled when there is evidence of spasm of the iris or ciliary muscle. Detachment of the retina is to be treated like the non-traumatic form of the disease (see page 430).

**Contusion-injuries of the Crystalline Lens.**—Contusion of the eyeball may cause rupture of the zonula, dislocation of the lens, rupture of the anterior or posterior capsule of the lens, with opacity, or there may be opacity of the lens without rupture of its capsule.

**Rupture of the Zonula.**—This occurs usually in connection with dislocation of the lens. There is loss of accommodation and an increase of the



refraction of the eye. The anterior chamber is sometimes deepened and the iris tremulous.

There is no remedy for this lesion.

**Dislocation of the Lens.**—The lens may be dislocated in different directions and degrees. In rupture of the sclera it may be expelled or lodged beneath the conjunctiva. It may be tipped or turned on its equatorial plane, or thrown partly through the pupil and there held by the sphincter of the iris, or it may be completely displaced forward into the anterior chamber or backward into the vitreous humor. In all cases the zonula is ruptured and the lens sooner or later becomes opaque (Figs. 235 and 236).

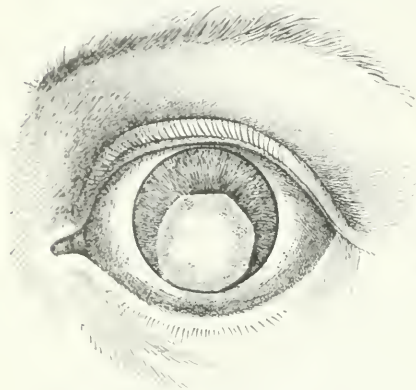


FIG. 235.—Dislocation of lens into the anterior chamber of highly myopic eye (de Schweinitz).

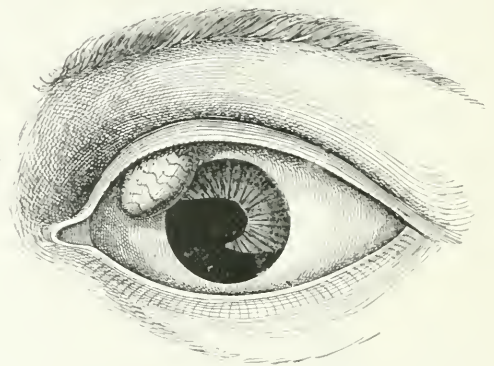


FIG. 236.—Subconjunctival dislocation of the lens (de Schweinitz).

**Symptoms.**—In partial dislocations vision becomes greatly impaired by the irregular refraction of the margin or the obliquity of the lens, or by its opacity. When the lens is dislocated into the anterior chamber and remains transparent the refraction is increased and the vision is myopic. When it is completely displaced into the vitreous humor the refraction is diminished and the vision is that of an aphakic eye.

A transparent lens in any position when seen with the ophthalmoscope gives a reddish or yellowish reflex through its body, while its margins, if they can be seen, are dark or quite black. When in the anterior chamber these appearances are intensified, and it is seen as a pale, yellowish, or "pale-wine yellow" pellucid body with a brilliant reflection from near its edge of a golden luster. When the lens is opaque it is shown both by the ophthalmoscope and oblique illumination as a rounded, smooth, dark or gray body, sometimes becoming quite white. In the anterior chamber it generally causes much irritation, and sometimes severe inflammation, with increased tension and loss of vision. In the vitreous humor it causes a deepening of the anterior chamber and the iris becomes tremulous. Sometimes it is fixed in the bottom of the vitreous humor, and sometimes it moves about. It may remain in this position without doing harm for a long time; but generally, sooner or later, it causes *glaucoma*, *cyclitis*, and other secondary diseases, and even *sympathetic inflammation*.

**Treatment.**—A lens dislocated under the conjunctiva may be left to disintegrate and absorb, or it may be removed through an opening in the conjunctiva.

In a partial dislocation an iridectomy may be made when the margin of the lens lies in the axis of vision. When the lens is incarcerated in the

pupil or it becomes opaque, it may be proper to dispose of it by discission or extraction, according to the age of the patient.

When the dislocation is into the anterior chamber, an effort may be made to reduce it by gentle pressure or rubbing over the cornea, either with or without a scleral incision behind the ciliary body to diminish the tension.

Should reduction be impossible and much irritation or inflammation be present, the lens should be extracted through a corneal incision. It may be supported during the operation by the "bident" of Agnew.

A lens dislocated into the vitreous chamber need not be disturbed unless irritation or inflammation take place, and then attempts may be made to extract it. This, however, is an uncertain procedure, especially with a floating lens, which it is almost impossible to "fish" out.

In any form of dislocation of the lens its extraction is necessarily followed by loss of vitreous humor (see also page 582).

**Rupture of the Capsule of the Lens.**—When the capsule is torn, whether anteriorly or posteriorly, the lens gradually becomes opaque. The rapidity with which this takes place depends upon the size of the rent. In some cases, where the latter is very small, it closes and heals, and the opacity remains partial. To the symptoms of *cataract* are added those of the irritant effects of swelling of the lens or the exuding of its substance into the aqueous humor.

The pupil should be kept as widely dilated as possible by atropin, and the lens should be extracted when its swelling causes dangerous reaction.

**Contusion of the Lens.**—The lens may be bruised or contused without rupture of its capsule. It is followed by opacity, with all the symptoms of non-traumatic cataract.

The treatment is that of spontaneous cataract.

**Penetrating Wounds of the Eyeball.**—Penetrating wounds of the eyeball are generally situated in its anterior part, and most frequently in the cornea or corneo-scleral junction. They assume great varieties of form, size, and shape, some being so small as scarcely to be traced, and others so extensive as to destroy a large portion of the eyeball. They may be limited to the cornea or sclera alone, or they may extend deeper into the iris, lens, and the structures beyond, and even pass through the eye into the orbit.

**Symptoms.**—The symptoms vary with the nature and depth of the wound. When the penetrating object is small only a minute corneal opacity or abrasion or an opacity of the lens will mark its course. But when a wound is of larger size it is readily seen; the evacuation of a portion of the intraocular fluids causes the eyeball to become softened, and there may be prolapse of the subjacent structures. Hemorrhage into some part of the eye usually takes place. Careful examination should be made for rents in the iris, opacities of the lens, and lesions in the fundus when the parts are not obscured, using the ophthalmoscope and oblique illumination for this purpose.

The effect of penetrating wounds upon the state of vision depends upon the nature of the lesions present. These may be so slight as not to disturb vision at all, or, if disturbed, only for a brief time; or they may be so extended that the vision is totally and permanently lost. Very little, if any, pain is experienced, unless inflammation develops.

In all penetrating wounds there is great danger of infection, and inflammation, with or without suppuration, is therefore a frequent sequence. An exuding and swollen lens is also a potent cause of iritis and cyclitis.

**Prognosis.**—The prognosis depends very much upon the situation and nature of the wound. Opacities of the cornea and lens may obstruct vision,

and injury of the retina in the macular region, very large hemorrhages, or great loss of vitreous may at once destroy it. An inflammation of the iris and ciliary body, caused by a wounded lens, is very liable to lead to obstruction or closure of the pupil and softening and shrinking of the eyeball. Punctured, ragged, or gaping wounds of the ciliary body are always serious, and they especially predispose to inflammation of the fellow-eye (page 347).

**Treatment.**—In all cases the strictest antisepsis should be observed. The wound should be freed of all included structures by excision or replacement, made scrupulously clean, and, whenever possible, closed by sutures and conjunctival flaps. When sutures cannot be used the lips of the wound may often be approximated or completely closed by a compress-bandage over the eye.

Hemorrhages and inflammatory reaction are to be treated as elsewhere indicated. In some cases it is best to perform an iridectomy and extract a wounded and swollen lens. This will sometimes save the eye, but it more often fails. On this subject that master of ophthalmology, Arlt, has said: "Such removal of the lens is to be considered more as a doubtful remedy, as we seldom succeed in removing the lens as a whole, or even its greater part, and thus do not obviate the dangers of mechanical irritation or of increased pressure; perhaps, indeed, we even increase them."

The causes of sympathetic inflammation not usually being operative during the first two or three weeks, an effort may be made in some cases to save the wounded eye. Should improvement be rapid during this period, should no symptoms of cyclitis appear, and especially should there be promise of serviceable vision, such effort may be continued, but always with a great deal of caution. On the other hand, should cyclitis of the injured eye develop and continue, and especially should vision be hopelessly lost, enucleation or evisceration should be performed before the expiration of three weeks.

There are cases in which the eye is so seriously wounded that no attempt should be made to save it, but enucleation or evisceration should be done without delay.

**Foreign Bodies on the Conjunctiva and Cornea.**—Minute bodies of various kinds may become lodged on the conjunctiva beneath the lids (usually the upper one near the center), or on the cornea, becoming imbedded in its epithelium. When the force is sufficient, as in explosions, they may be driven deeply into the corneal substance.

A foreign body on the conjunctiva alone is scarcely felt, but when on the cornea or rubbing against it, it produces a scratching or pricking pain, which is not usually severe. There is considerable lachrymation and the eye becomes red. If the body is not removed soon, it may excite inflammation, particularly if it is on the cornea. In the latter case also it may cause ulceration of the cornea at the point where it is lodged. This sometimes extends and causes destruction of the eye.

The foreign body is detected by careful inspection, aided, if necessary, by oblique illumination.

**Treatment.**—A body which is not imbedded deeper than the epithelium of either the conjunctiva or cornea should be picked away with some sterilized, sharp-pointed instrument. When one is driven into or beneath the ocular conjunctiva, it may be excised, taking with it the least possible amount of this membrane. When it is imbedded in the substance of the cornea, it should be picked out with as little injury as possible to the surrounding tissue. It is generally impossible to remove *grains of powder* in this way,



and they can be allowed to remain without danger of ulceration or suppuration. They simply leave black stains. Dr. Edward Jackson of Philadelphia has suggested burning them out with a galvano-cautery point. But such a point must be very small and used with great care, or the effects of the burn will be worse than those of the powder. It should not be forgotten that more than one body may be present at the same time.

**Foreign Bodies within the Eyeball.**—Any small, hard object, such as a splinter of wood, scale of iron or steel, spicule of brass or copper, fragment of stone or glass, may be projected with sufficient force to penetrate the coats of the eye and become lodged at any point within them. It usually enters through the anterior part of the eye, and most frequently through or very near the cornea.

**Symptoms.**—The symptoms are essentially those of a penetrating wound, to which are added such as are caused by the presence of the foreign body. The latter are at first negative, but later unusual irritation and inflammation develop, with corresponding symptoms.

**Diagnosis.**—The history of the accident is of great importance. The circumstances under which it happened, the occupation engaged in, the small size of the object striking the eye, the direction of its course, whether or not it was seen after striking the eye, the immediate effect on vision, and kindred information, should be ascertained, if possible. Unfortunately, such information is often very incomplete.

If, at the time of an explosion of a percussion-cap or the discharge of a shot-gun, or while hammering iron or steel or cutting stone, a small object that was not afterward seen has struck the eye and perforated the cornea or sclera, the probability that it has entered the eye is so strong as to become almost a certainty. The reason of this is apparent when it is remembered that the resistance of the intraocular fluids is not sufficient either to check the course of the body or to cause it to rebound, and a force which was great enough to cause it to cut through the tough, outer coat would carry it farther into the eye after the opening was made.

With such a history and the presence of such a wound most careful search should be made for a foreign body. Hemorrhages, corneal irregularities, and opacities of the lens or vitreous humor greatly obstruct the examination; but when the media are not obscured, and when the object is not hidden by its position or by exudates, the ophthalmoscope and oblique illumination will often convert the suspicion of its presence into a certainty. A metallic object in the vitreous chamber gives a lustrous reflection when seen with the ophthalmoscope.

When, from any cause, a foreign body cannot be seen, it may in rare instances, if of considerable size and near the surface, be felt by a probe; but this should be used with great caution.

When the body is steel or iron the *electro-magnet* will often assist in diagnosis. A strong one applied to the surface of the eyeball will sometimes attract the iron or steel, and the movement of the latter will cause more or less pain. Or, if the wound is so situated as to warrant it, an extension-point of the electro-magnet of suitable size may be carefully introduced into it, when it will sometimes not only attract the body to the surface, but bring it out.

The special adaptation of Röntgen's rays, or skiagraphy, to the eye will oftentimes demonstrate the presence of a foreign body and also its approximate position (see Appendix, pages 607-611).

Should it be impossible by means of sight, touch, the electro-magnet, or



skiagraphy to ascertain the presence of a foreign body beyond doubt, the presumptive diagnosis of its presence based upon the history and conditions above outlined should prevail. In case of delay such symptoms of irritation and inflammation may set in as could scarcely be expected as a result of the wound alone. These will strongly corroborate the other evidence of the presence of a foreign body. The eye may, however, remain quiet in exceptional cases, but this is not sufficient to outweigh the primary evidences and to nullify the diagnosis of a foreign body in the eye.

**Prognosis.**—When a foreign body is lodged in the eye the consequences of a penetrating wound follow which have already been considered, together with those arising from the presence of the foreign body itself.

As regards the latter, it may be said that, however small the body may be, whatever may be its substance, and wherever it may be situated, it sooner or later, with rare exceptions, causes destructive inflammation of the injured eye, and may also induce sympathetic inflammation of the other. The only structure which will tolerate a foreign body without danger of inflammation is the lens. Even here vision is obscured by the lens becoming opaque.

Cases have been recorded in which the membranes of the eye or the iris have tolerated a foreign body for a long period of time, or in which one has become encysted and remained harmless, or in which one has been spontaneously expelled; but they are so rare as not to have material weight in prognosis or treatment. In every case it should be assumed that the eye is sure to be lost unless the offending body is removed. After its removal the eye is in the condition of one with a penetrating wound, and may or may not be saved according to the circumstances of the case.

**Treatment.**—In some cases, although the foreign body may be found and removed, the injury is so extensive that the eye is hopelessly lost. Immediate enucleation or evisceration is then the safest procedure. But when the nature of the injury will permit, all reasonable effort should be made to remove the foreign body and save the eye with as much vision as possible.

When the presence and location of a foreign body have been determined, the course to pursue will depend on what substance it is and on its position. If situated in the anterior chamber or iris, it may be extracted with or without excising a piece of iris through an incision at a suitable point in the cornea. If lodged in the lens, it may be left there until the latter has become fully opaque, and then both may be extracted together. Or, should the wounded lens become absorbed, the foreign body may then be treated as if it were, from the first, lodged in the anterior chamber or perhaps in the vitreous humor.

When a body is lodged in the posterior part of the eye it may sometimes be caught by forceps (without teeth), hooks, or scoops, and drawn out. But such a happy result is not often obtained.

Should the foreign body be steel or iron, the *electro-magnet* (Fig. 237) is of great service, and the chances of extracting the fragment are increased many fold. Very large and powerful electro-magnets, which have lately been introduced by Haab, are not often available, and the smaller instruments give eminent satisfaction. The electro-magnet should be armed with as short, and also as large, an extension-point as can be consistently introduced, since the attractive force is diminished very rapidly as the point becomes smaller and longer. The point should also be flattened or squared, instead of rounded, to give as much surface-contact as possible. A rounded point reduces this to a minimum.

The extension-point may be introduced through the original wound, or,

which is often preferable, through an incision suitably located and made for the purpose. It should be carried, without twisting it or changing its course, toward the supposed or known position of the fragment and reintroduced if necessary. Should it attract the steel or iron or in any way come in contact with it, it will generally produce a distinct click which can be both felt and heard. On withdrawing the point the steel or iron is brought out with it, or perhaps it is held back at the wound, when the point should be partially reintroduced, and the extraction then assisted by forceps made of some other material than iron or steel.

After removal of the foreign body the case becomes one of a penetrating wound of the eye, and should be treated accordingly.

Should it be impossible to remove a foreign body whose presence is extremely probable or definitely determined, the vision being without doubt permanently lost, the eye should be enucleated or eviscerated. A delay, however, may be made for a short time, as in penetrating wounds, when there remains some vision and the diagnosis is doubtful. Rapid improvement and absence of symptoms which point to sympathetic disease may justify still further delay, but with a continuance of inflammatory symptoms and a progressive deterioration of sight, if this was not destroyed at first, the delay

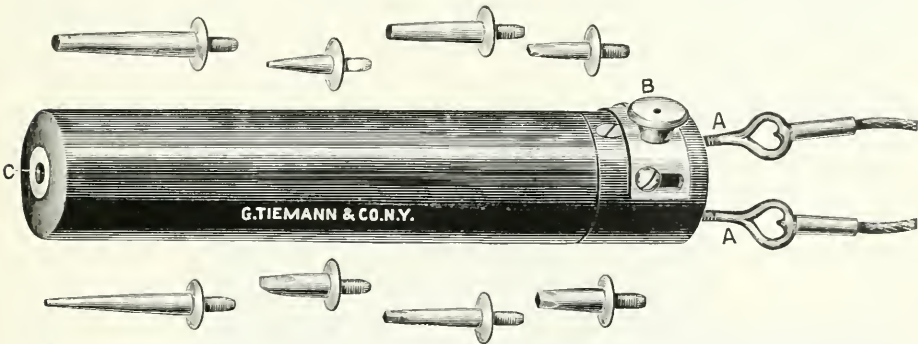


FIG. 237.—Hubbell's electro-magnet, actual size: A, A, ends of cords connecting the magnet with a galvanic battery; B, slide for opening and closing electric circuit; C, end of core tapped to receive the extension-points. The extension-points, a few of which are shown, may be of any desired length, shape, curve, or size.

should not extend beyond two or three weeks, as after this time sympathetic inflammation becomes imminent at any moment.

**Injuries of the Eyelids and Lachrymal Passages.**—*Echymosis of the eyelids* follows contusions and wounds, and also hemorrhages into the orbit and around the eyeball. The discoloration of the skin varies in depth and extent with the amount of blood extravasated. There is, occasionally, swelling of the parts and a feeling of stiffness, but no pain. The blood is absorbed, and the skin regains its normal color in from one to three weeks.

Very little treatment is necessary. Absorption of the blood may be hastened by bathing the parts with water as hot as can be borne and by gentle frictions.

*Emphysema of the eyelids* may take place when the mucous membrane of the nose becomes torn in connection with a fracture or injury involving the nasal cavities, and a communication is established between the latter and the cellular spaces of the lids, and air is forced into them by blowing of the nose. The parts are immediately puffed up into a soft, crepitating, and painless swelling.

The patient should be cautioned against further blowing of the nose till

after the wound is healed. A compress-bandage should be applied over the lids, and the air will be absorbed in a few days.

*Contusions of the lids* are generally followed by ecchymosis with some swelling and soreness. They should be treated by cold applications, unless suppuration takes place, and then warm fomentations should be used, and the abscess opened early by incision.

*Punctured wounds* are generally of little consequence, but the *incised* and *lacerated* varieties, especially the latter, require careful attention. When a wound runs parallel with the edge of the lid it will unite without deformity. But when it extends across the orbicularis muscle or through the margin of the lid, the wound gaps, and if not closed by surgical measures leaves a depression of the surface or a permanent cleft through the edge of the lid. When the lachrymal canals are severed they become permanently closed.

The utmost care should be taken to close all gaping wounds and to restore to proper position displaced parts. The loss of skin may call for a plastic operation. When a lachrymal canal has been severed, it should, if possible, be searched for and slit up and kept open.

*Foreign bodies* may become lodged beneath the skin, and should be removed by cutting down upon them and picking them out.

They may also get into the lachrymal punctum or canal, and cause irritation of the ball by rubbing against it, or stillicidium by obstructing the passage. They are easily withdrawn when they are in sight, but when not it will be necessary to slit open the canal and then remove them.

*Injuries from hot substances and escharotics* produce the same symptoms and require the same general treatment as those occurring elsewhere on the surface of the body (see Fig. 238). The unsightly and distressing deformity



FIG. 238.—Ectropion following a burn.

and loss of function which follow cicatrization should be prevented by skin-grafting, preferably by Thiersch's method. To this end, as soon as the eschar is thrown off and the granulating process is well established, the affected surface should be scraped, and the grafts applied as described in surgical treatises. This part of the treatment cannot be too forcibly urged.

# GLAUCOMA.

BY J. A. LIPPINCOTT, A. B., M. D.,

OF PITTSBURG, PA.

**General Considerations.**—The term “glaucoma” is applied to a group of phenomena, the most prominent of which, apart from a greater or less degree of impairment of vision, are an increase in the *hardness of the eyeball* and an *excavation in the head of the optic nerve*. Brisseau in the last century and Weller and Mackenzie early in the present directed attention to the first of these two characteristics, the great English observer especially dwelling on its importance and systematically employing a rational method of relieving it—viz. puncture of the sclera and of the cornea.

To determine the pressure and degree of abnormal tension palpation is employed in the manner described on page 170. A number of *tonometers*, or mechanical substitutes for the fingers, have been devised, but, owing to defects which are possibly irremediable, they are not in general use.

In recording the results of palpation of the globe the method usually employed is that suggested by Bowman, according to which T. stands for normal tension; T. - ? tension probably increased; T. + 1 and T. + 2 still higher degrees; while T. - 3 indicates stony hardness. Care is required not to mistake the rigidity of a thickened eyelid or that of an abnormal sclera for an actual increase in intraocular tension. In doubtful cases the finger-tips may be placed on the naked eyeball. In investigating ocular tension the *tactus eruditus* is an essential qualification, and no opportunity of acquiring it should be neglected.

The *excavation of the optic nerve* in glaucoma involves the whole or nearly the whole surface of the disk, and attains a considerable depth. Its sides are steep or even undercut, so that the cavity is ampulliform—*i. e.* bulging in its deeper portions.

Viewed with the ophthalmoscope, the blood-vessels are crowded toward the nasal side, and, as they dip into the pit, make a sharp bend, and frequently disappear behind the overhanging margins. When they reappear on the floor of the excavation they are less distinct and lighter in color, and their continuity is apparently broken, owing to *parallax displacement*. From the same cause they appear to move more slowly in response to lateral movements of the object lens used in the indirect examination than they do

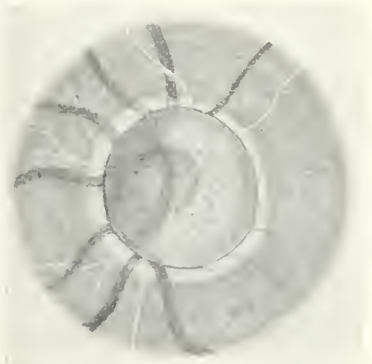


Fig. 239.—Glaucomatous excavation.



at the level of the retina. On making use of the direct method a stronger concave or weaker convex lens is required than the one used for the neighboring retinal surface. This difference in refraction constitutes a means of accurately measuring the depth of the excavation, an interval of three diopters corresponding to about 1 mm.

*Arterial pulsation* is either spontaneous or is easily induced by light pressure with the finger. This phenomenon is a result of the increased intraocular pressure, which is sufficient to retard the arterial current, except when the latter feels the onward thrust of the cardiac systole. The blood thus enters *per saltum*, instead of continuously as under normal conditions. Spontaneous *venous pulsation* is common.

The disk shows a bluish or greenish pallor, and is surrounded by a more or less complete ring, which sometimes appears yellow, probably by contrast with the color of the disk. This ring is due to atrophy of the choroid and is known as the *glaucomatous halo* (Fig. 239). A *low-grade neuritis* is commonly to be detected in the nerve-head containing the pathologic excavation.

In common with most of the symptoms in glaucoma, the cupping of the optic disk is a consequence of the increased intraocular tension, the latter

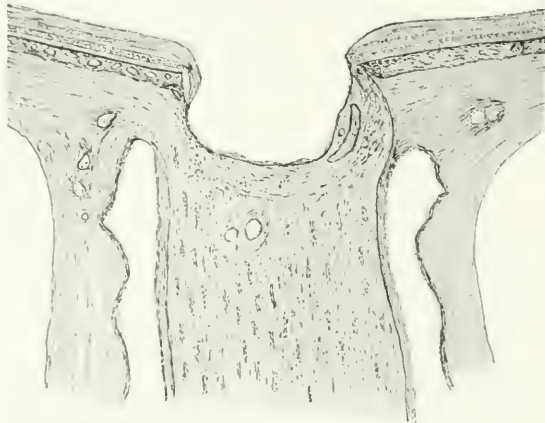


FIG. 240.—Glaucomatous excavation, microscopic section.

taking most effect at the least resisting portion of the ocular envelope—viz. the lamina cribrosa. It is probable that the process is favored in many cases by inflammation with softening and, later, cicatricial contraction of the tissues in this region; and this factor would appear to be sometimes sufficient in itself to produce an excavation indistinguishable ophthalmoscopically from one known to result from abnormally high pressure (Fig. 240).

**Varieties of Glaucoma.**—Glaucomatous manifestations range themselves in three principal groups:

(I.) Primary glaucoma, the pathology of which is not positively determined.

(II.) Secondary glaucoma, which obviously depends upon some pre-existing morbid condition.

(III.) Congenital glaucoma, usually described as buphthalmos.

**I. Primary Glaucoma.**—This variety, which may or may not exhibit signs of inflammation or congestion and is subdivided accordingly, will be first described.

**Etiology.**—The *predisposing* causes of glaucoma have reference to age, sex, race, systemic condition, and the conformation and refraction of the eye.

It is rare in the young,<sup>1</sup> and most frequent in the fifth and sixth decades of life. More women than men suffer from *inflammatory glaucoma*, whereas more men than women are affected with the *non-inflammatory* form of the disease. In the analysis made by William Zentmayer and William Campbell Posey of 167 cases of *glaucoma simplex*, men were found slightly more liable than women. The extremes of age noted were thirteen and ninety-six years. These facts are represented graphically by these authors in the following diagram. A disproportionate number of cases are seen in the Jewish race

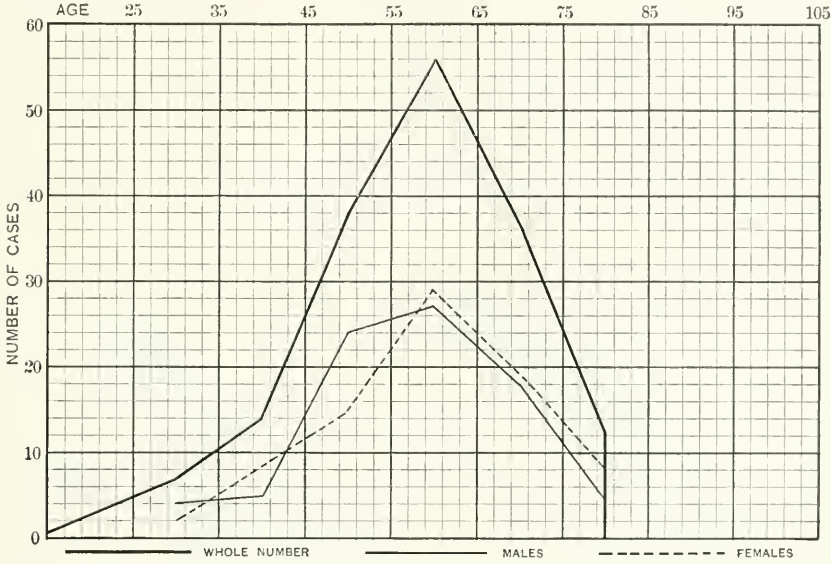

FIG. 241.—Chart showing the relationship of glaucoma simplex to age and sex (Zentmayer and Posey).

(Knapp), and Egyptians are said to be peculiarly liable. There appears to be a tendency to hereditary transmission. When this is the case the period of life at which the outbreak occurs in each succeeding generation (De Wecker). The gouty and rheumatic diatheses favor the development of the malady, and those who suffer from arterial sclerosis, chronic bronchitis, or heart disease are liable to the disease. A causal relationship between influenza and non-inflammatory glaucoma has been recorded. The author has observed catarrhal disease of the nasal passages in a large proportion of cases of inflammatory glaucoma. Small, hyperopic eyes are more likely to be affected than emmetropic or myopic eyes. This is explained by the limited circumferential space due to the hypertrophy of the ciliary muscle in hyperopia, and also to the excessive and practically continuous contraction of this muscle in accommodation.<sup>2</sup> The progressive increase in the diameter of the lens throughout life noted by Priestley Smith is claimed by this author as an important etiological factor. There is a relation between

<sup>1</sup> According to Priestley Smith, not 1 per cent. of the cases begin earlier than the twentieth year. A few, generally monolateral, cases are seen in children.

<sup>2</sup> Zentmayer and Posey's figures in regard to the refractive condition of the eye in their 167 cases are as follows:

Hyperopia = 140 eyes;  
 Myopia = 28 eyes;  
 Emmetropia = 21 eyes.  
 Twenty eyes were astigmatic.

smallness of the cornea and glaucoma (normal average horizontal diameter, 11.6; glaucoma, 11.1).

Among the *exciting causes* may be mentioned various emotions—joy, grief, anxiety, etc.—producing ciliary congestion, and the incautious use of mydriatics, which, by thickening the peripheral portion of the iris, directly diminish the filtrating area in the anterior chamber. An onset of the disease has been precipitated by exposure to cold, by loss of sleep, worry, neuralgia, and by the ingestion of a hearty meal. Nettleship relates a case which was always worse in warm weather, and a lady under the author's care can always bring on an attack by abruptly entering a dark or dimly-lighted room. Over-use of ametropic or improperly corrected eyes may excite glaucoma in an eye predisposed to the disease.

**Pathology and Pathological Anatomy.**—The pathogenesis of glaucoma is not definitely settled. Because of the overshadowing importance of the increase in intraocular tension the aim has mainly been to account for this phenomenon; but half a century of active investigation, clinical, experimental, and anatomical, has not resulted in a completely satisfactory solution of the problem.

The hypothesis that glaucoma arises from hypersecretion, produced, according to v. Graefe, by choroidal inflammation, and, according to Donders, by nervous irritation, has been discarded, and various "retention theories," which explain the increased hardness of the eyeball by an obstruction to the escape of the intraocular fluids, have taken its place. The obstruction, in accordance with the views enunciated by Knies, and soon afterward by Weber, is generally considered to be situated at the angle of the anterior chamber, and to consist in a blocking up of this angle by apposition or adhesion of the peripheral portion of the iris to the adjacent sclero-cornea, the iris having been crowded forward by the hyperemic and swollen ciliary processes. Knies believed the condition to be one of adhesive inflammation of the iris periphery, while Weber regarded this adhesion as secondary to pressure. In his most recent communication on the subject Knies makes a sharp distinction between *glaucoma simplex*, which he conceives to be an *optic nerve-atrophy with excavation*, and *true forms of glaucoma*, which should be considered as an *irido-cyclitis anterior*—an inflammation which may occur in varying degrees of intensity. It has been demonstrated by Leber and others that the ciliary region constitutes the principal outlet for the lymph-current, which, starting at the ciliary processes, proceeds forward through the zonula and pupil into the anterior chamber, and thence through the pectinate ligament into the canal of Schlemm, from which it finds its way into the venous system. In the cases in which the iris occupies its normal position it is possible that filtration may be hindered by serosity of the liquids (Priestley Smith) or by a choking of the meshes of the pectinate ligament with pigment-cells from the ciliary processes and the posterior surface of the iris (Niesnamoff).

Priestley Smith, as already intimated, thinks that an important element is a narrowing of the circumferential space, due to a senile increase in the size of the lens or to a small ciliary circle as seen in hyperopic eyes—hence a forward displacement of the lens and blocking up of the excreting angle.

Stilling's view, that glaucoma may be produced by tissue-changes which tend to hinder the exit of fluids by way of the optic-nerve entrance, may have a limited field of application, as may also that of Rheindorf, who claims that the obstacle to the nutritive current consists in a sclerosis of the lenticulo-zonular diaphragm. Laqueur and others think that glaucoma depends

upon obstruction of the intraocular lymphatics, which find their way out with the vena vorticiosa.

The *anatomical conditions* which have been observed in glaucomatous eyes are, among others, the following: (1) Edema, and at a later stage ulcerative processes in the cornea. (2) Scleral changes, including rigidity, fatty degeneration, and equatorial staphylomata. (3) Obliteration (with or without adhesive inflammation) of the angle of filtration, of the spaces of Fontana, and of the canal of Schlemm (Fig. 242, *A*). (4) Atrophy of the iris, chiefly of the external layers, with destruction of the vessels. (5) Sometimes swelling and sometimes atrophy of the ciliary processes. In the latter case these bodies shrink backward, and frequently leave the iris in contact with the cornea (Fig. 242, *B*). (6) Glaucomatous cataract—*i. e.* cataract which is a direct result of the disease. (7) Fluidity of, and opacities in, the vitreous. (8) Marks of choroidal inflammation, such as atrophy and loss of elasticity of the choroid, and periphlebitis with reduced lumen of the veins, especially the vasa vorticiosa. (9) Destruction, partial or complete, of one or more of the retinal layers and detachment of the retina. (10) Lastly, the excavation of the

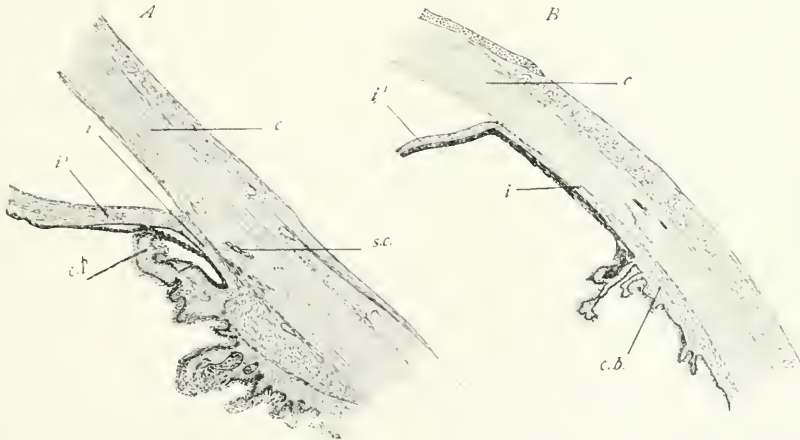


FIG. 242.—*A*, absolute glaucoma: *c*, cornea; *s. c.*, Schlemm's canal, partially closed; *i*, iris adherent to sclera and closing angle of filtration; *i'*, free portion of iris; *c. p.*, ciliary process, reaching forward and in contact with iris. *B*, absolute glaucoma at a more advanced stage; *i*, iris extensively adherent. Schlemm's canal is entirely obliterated. The ciliary body and processes are decidedly atrophied.

optic nerve, which may or may not show traces of a low-grade neuritis.<sup>1</sup> The precise relation of the changes just enumerated to the glaucomatous process cannot in the present state of our knowledge be dogmatically stated. Some of them are probably etiological factors, while others are doubtless results of the continued pressure.

Primary glaucoma may be *inflammatory*, or *simple i. e. non-inflammatory*.

*Inflammatory* or *congestive glaucoma* (glaucoma irritatif) is classified as (*a*) *acute*, (*b*) *subacute*, or (*c*) *chronic*, according to the severity of the symptoms.

(1) **Acute Glaucoma** (*Acute Inflammatory or Congestive Glaucoma*).—(*a*) *Period of Incubation, or Prodromal Stage*.—The prodromal or intermittent stage is characterized by mild attacks, in which the cornea is slightly steamy and anesthetic, the pupil moderately dilated and sluggish, and the

<sup>1</sup> Marked hyperemia and edema of the nerve-head, which afterward becomes cupped, is an early symptom in glaucoma (Knies), and actual neuritis in primary glaucoma, usually precedes increased tension (Brailey and Edmunds).



anterior chamber somewhat diminished in depth. There is noticeable, but not pronounced, pericorneal injection, and palpation shows some increase in tension. The vision is smoky from the corneal haziness, and rainbows are seen around lights from the same cause. The ophthalmoscope may reveal pulsation of the retinal arteries, but as yet there is no cupping of the disk. When the attack is ended the eye returns to its normal condition, except that the accommodative power is apt to be lessened, the patient requiring stronger reading-glasses than before.

The stage of prodromata may last months or years, the intervals between the attacks growing gradually shorter, and may terminate in an acute attack.

(b) *Period of Attack.*—The glaucomatous attack, whether preceded or not by an intermittent stage, is suddenly ushered in by violent and excruciating pain in the eye and the corresponding side of the head, with vomiting, fever, and even loss of consciousness. The lids become edematous and the ocular conjunctiva reddened and swollen. The cornea is decidedly hazy, owing to edema of its superficial layers. The haziness is generally most pronounced in the center, and is sometimes accentuated in spots, giving a dotted appearance to the surface. Corneal sensibility is more or less completely abolished, as shown by touching it with a bit of twisted cotton. The pupil is dilated and immobile and shows a greenish or grayish-green reflex<sup>1</sup> from the lens. The dilatation is not uniform, so that the pupil is rarely perfectly circular. The iris is discolored and its markings are blurred. There may be, according to most authors, some turbidity of the aqueous and vitreous humors, although this turbidity is considered by others as far from proven. The sight, owing partly to the corneal edema and partly to the compression of the retinal arteries, rapidly fails until fingers can scarcely be counted. In the rare cases in which a view of the fundus is obtainable hyperemia of the disk with pulsation of the arteries is observed, but no change in the disk level is to be expected. Lastly, careful palpation will disclose, even through the edematous lids, a decided hardness of the eyeball—a condition which accounts for most if not all of the other phenomena.

The intensity of the symptoms described above begins to subside after a few days or weeks. The pain, corneal haze, palpebral and ocular edema, etc. diminish greatly or disappear; but the pupil remains dilated and sluggish, the pericorneal region somewhat injected, the anterior chamber abnormally shallow, and the vision is usually considerably reduced. Tension continues elevated. This condition is known as the *glaucomatous state* (*habitus glaucomatosus*).

After a longer or shorter period of comparative quiet another outbreak may occur, and then another, until the sight is wholly destroyed—a condition described as *absolute glaucoma*. The eye assumes a dull, expressionless look. The cornea is surrounded by a zone of livid or slaty hue. The pupil displays a border of black pigment (*ectropium ureæ*). The lens and the narrow atrophic rim of the iris are crowded against the cornea. The tension of the globe is usually excessive. The ophthalmoscope now generally reveals the characteristic glaucomatous excavation. With the advent of blindness the patient in some cases obtains surcease of suffering; in others the attacks continue until relief is afforded by surgical means.

*Glaucomatous Degeneration.*—After the glaucoma becomes absolute striking tissue-changes sooner or later begin to manifest themselves. The atrophied sclera succumbs to the intraocular pressure, and bluish-black swellings appear between the cornea and the equator. The lens may become

<sup>1</sup> Hence the name glaucoma—from *γλαυκός*, sea-green or grayish green.

opaque (*glaucomatous cataract*). The eyeball may go on to atrophy, with detachment of the retina, and may show deep furrows in the line of the recti muscles, or the morbid process may end with sloughing of the cornea and panophthalmitis.

In some cases of acute glaucoma vision is suddenly and irretrievably lost at the first attack, constituting what is known as *glaucoma fulminans*.

(2) **Subacute Glaucoma.**—This variety presents the phenomena of the acute form of the disease in a much less intense degree, and might not improperly include the prodromal stage of that form. But, whether intermittent or continuous at the outset, it passes by insensible gradations into the third and most common variety—viz.:

(3) **Chronic Inflammatory or Congestive Glaucoma.**—The appearance of the eye in this affection is very characteristic. The dull-livid or dusky-red color of the sclera with its swollen and tortuous veins, the smoky look of the cornea, the irregular dilatation and eccentric position of the pupil, the obvious atrophy of the visible portion of the iris, the marked shallowness of the anterior chamber, and the greenish reflex from the lens, combine to form a picture which, once seen, can always be recognized. The pain, though sometimes severe, is not so intense nor is the corneal insensibility so complete as in acute glaucoma.

Central vision slowly fades, and the visual field gradually contracts, especially on the nasal side. In the later stages cupping of the disk is revealed by the ophthalmoscope. The disease, if unchecked, proceeds, as does acute glaucoma, to the establishment of absolute glaucoma, and later to one or more of the phases of glaucomatous degeneration.

**II. Simple Glaucoma** (*Glaucoma Simplex, Chronic Simple or Non-inflammatory Glaucoma*).—This is one of the most insidious of maladies. If untreated it usually terminates in blindness; nevertheless, at least in its early stages, it presents no external signs of the grave changes going on within the eye. After the lapse of months or years there may be slight dilatation and inactivity of the pupil and moderate distention of the anterior ciliary veins.

Increased tension, while seldom pronounced, can in most cases be detected on careful and repeated examination; but it may be entirely absent. In doubtful cases the eye should be tested at different times of the day and under various circumstances, especially after a full meal or in the condition of depression following a restless night. It should be remembered also that there is no fixed and universally applicable standard of physiological tension. A careful comparison of the two eyes, especially if one is still unaffected, will tend to eliminate doubt.

The *objective phenomena* just described may occur in attacks resembling those of the prodromal stage of inflammatory glaucoma. At such times the cornea may be hazy and its sensibility may be impaired and rainbow vision may be observed. These attacks in certain cases appear to mark a transition from the simple to the congestive form of the disease.

The *cardinal symptom* of simple glaucoma is a slow but steadily progressive failure of vision, especially peripheral vision. In some cases a good degree of central visual acuity is preserved for a long time, while the field of vision is so encroached upon that the patient, although able to distinguish fine print, may not see well enough to walk about. In such cases blindness comes on suddenly, as by the abrupt drawing of a curtain.

The *field of vision* is almost always restricted. The nasal side generally suffers most, but the limitation is very often concentric (according to Zentmayer and Posey this is the most frequent phenomenon), or the field may

assume any one of a great number of bizarre forms. Frequently sector-like defects are seen. *Scotomata* partial or total are often found. According to Bjerrum, areas of special visual acuity, taking the form of rings or segments of rings with a width of  $10^{\circ}$  to  $20^{\circ}$ , and touching the blind spot at their inner margin, are sometimes observed.

In the following visual fields the boundaries for white are represented by a continuous line, those for blue by an interrupted line, those for red by a line of dashes and dots, and those for green by a dotted line:

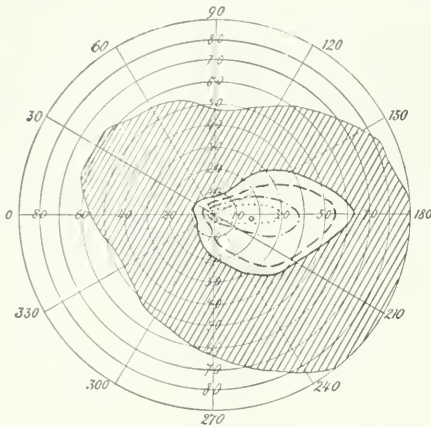


FIG. 213.—Simple glaucoma, R. E.  $V = \frac{15}{XL}$ . Nasal side of field almost obliterated.

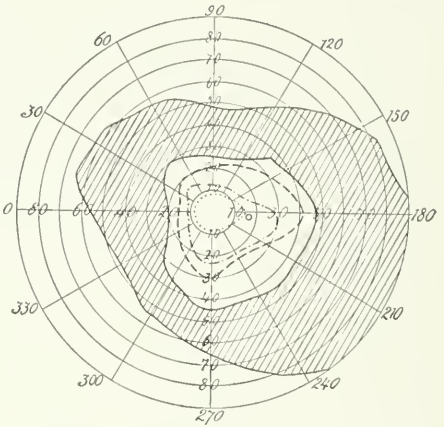


FIG. 244.—Chronic inflammatory glaucoma, R. E.  $V = \frac{2}{CC}$ .

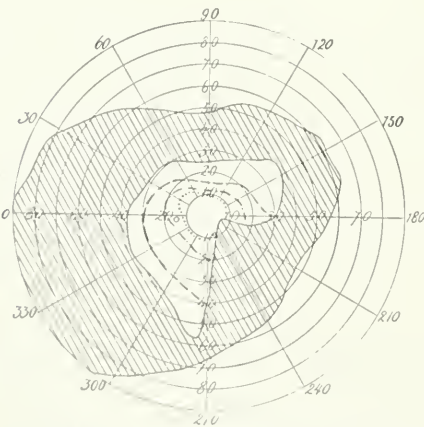


FIG. 215.—Simple glaucoma, L. E. The visual field simulates that form of hemianopsia in which one quadrant is cut out. The field of the other eye shows concentric limitation.

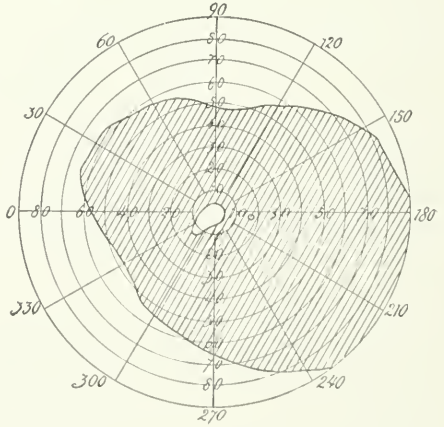


FIG. 246.—Simple glaucoma, R. E. Duration two years,  $V = \frac{15}{XL}$ . Fair appreciation of blue. Field of other eye still more contracted.

As a rule, the *color-fields* show no disproportionate loss. The field for blue may even be coextensive with that for form. It is also true, however, that the *color-fields* may be contracted, while the *form-field* is intact—a fact which tends to diminish the value of the evidence derived from examinations of the visual field in diagnosing between glaucoma and optic-nerve atrophy.



As in the early stages of inflammatory glaucoma, *premature presbyopia* is commonly seen.

*Excavation of the optic nerve* is the most striking objective, as visual impairment is the leading subjective, feature of the disease. The cupping is rarely absent when the patient presents himself for examination, which is usually after the malady has made decided progress. Furthermore, the de-

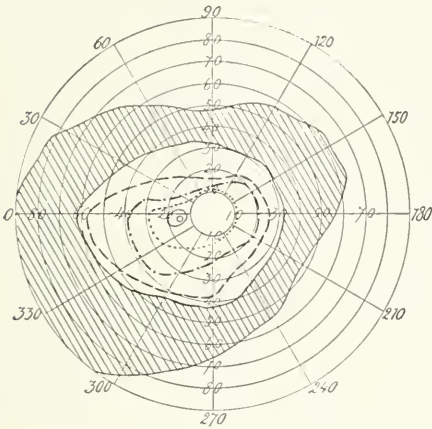


FIG. 247.—Subacute inflammatory glaucoma, L. E. Four weeks after iridectomy,  $V = \frac{15}{XL}$ . Absolute scotoma in region of "blind spot."

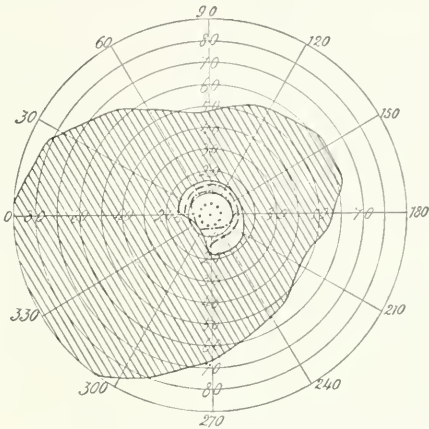


FIG. 248.—Chronic inflammatory glaucoma, L. E. Duration one year,  $V = \frac{15}{XL}$ . Patient has arthritis deformans.

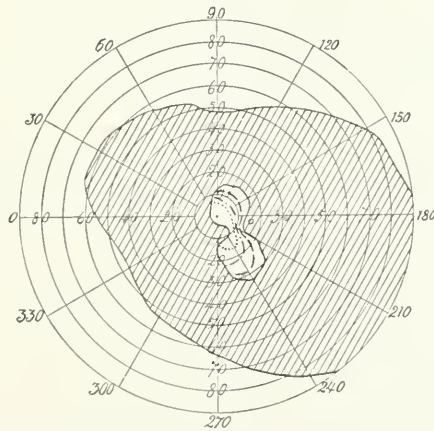


FIG. 249.—Simple glaucoma, R. E.  $V = \frac{15}{C}$ . Dumb-bell field. The notch on the left side was doubtless a scotoma at an earlier stage of the disease.

pression is now generally found to be characteristic, as described at the beginning of this chapter, although it is sometimes shallow (Fig. 239).

**Diagnosis.**—Rapidly increasing presbyopia, occasional mistiness of sight, and "rainbow vision," so frequently the harbingers of glaucomatous trouble, should arouse suspicion.

*Inflammatory glaucoma* has been mistaken for *iritis*. The dilated pupil and the hardness of the eyeball in the former affection ought generally to make such a mistake impossible. The pupil may, however, be bound down



by adhesions due to a previous inflammation of the iris, and the author has seen one case of intermittent glaucoma in which the pupil, though free, was of normal size. We must in such cases be guided by the history and by the other symptoms, especially the abnormal hardness of the globe. That increase of tension, rainbow vision, and shallowness of the anterior chamber are, as pointed out by Schweigger, sometimes observed in iritis, should be borne in mind, but other symptoms of iritis will then not be lacking.

*Simple glaucoma* when typical is easily recognized. When the tension is not perceptibly elevated, and other external symptoms, such as sluggishness of the pupil and fulness of the ciliary veins, are absent, reliance must be placed on the character of the excavation of the optic nerve, which in glaucoma, as already pointed out, covers the whole surface of the disk, has steep sides, and is deeper than the normal level of the lamina cribrosa. Physiological excavation involves only a portion of the disk, while the remainder of the surface presents a healthy appearance. The excavation due to atrophy of the nerve affects the entire disk surface, but it is shallow and slopes gradually to its deepest point. Moreover, the nerve-head is much more anemic, proportionately to the depth of the cup, than in glaucoma (consult Fig. 131). The greatest difficulty arises when an atrophic process attacks a nerve which is the seat of an extensive physiological pit. Flatness of the disk in the sound eye is evidence of glaucoma, since physiological cupping is bilateral (Schweigger).<sup>1</sup> The absence of the knee-reflex as indicative of central disease would point to atrophy.

The shape of the visual fields, especially the color-fields, and their relation to the acuity of vision are of decided, though not unqualified, diagnostic importance. In atrophy of the optic nerve good central vision and color appreciation are not so apt to be retained with a contracted field for form as in glaucoma. (Compare with page 448.) In doubtful cases the totality of the phenomena must be considered, and sometimes a positive diagnosis should be reserved and the course of the affection carefully watched.

The unfortunate mistake of regarding the gray or green reflex from the lens as indicating incipient cataract, and the consequent advice to wait for ripening which never comes, are happily much rarer now than they were before improved methods in medical teaching, including instruction in the use of the ophthalmoscope, were inaugurated.

**Treatment.**—Had v. Graefe done nothing else for ophthalmology, his discovery in 1856 of the curative power of iridectomy in glaucoma would alone have secured for him an imperishable fame. Other remedial measures operative and medicinal have been since devised, but they are almost universally considered to be of secondary importance.

In performing iridectomy<sup>2</sup> for glaucoma the coloboma should be made upward, so as to be covered by the upper lid, unless the superior portion of the iris appears to be specially atrophic, and therefore more difficult to remove. The incision should lie in scleral tissue, should be of ample size, and should be completed with deliberation in order to prevent too sudden a reduction in tension, which might be attended with intraocular hemorrhage, rupture of the zonula, or other disastrous consequences. The bit of iris excised should be extensive, and should embrace the whole width of this tissue up to its ciliary margin. The angles of the wound should be left entirely free, an iris-repositor being used if necessary.

<sup>1</sup> This statement of Schweigger's is not without exceptions, as a unilateral physiological cup may exist.—Ed.

<sup>2</sup> The operation for iridectomy is described on page 575.

The operation, which should of course be made with precautions against sepsis, requires in inflammatory cases the use of a general anesthetic, as cocaine under these circumstances is very imperfectly absorbed. Hemorrhage into the anterior chamber is not infrequent, but the blood usually undergoes absorption in a few days. Retinal hemorrhages are also occasionally seen. These are generally not extensive, and they soon disappear.

*Cystoid cicatrix* from imperfect apposition of the lips of the operation-wound is sometimes unavoidable. Moreover, though a blemish, it may serve to facilitate filtration.

The most brilliant results of iridectomy are obtained in acute inflammatory glaucoma, especially when the operation is done without delay. The pain, high tension, and corneal cloudiness promptly disappear, and the vision is rapidly and decidedly improved—sometimes, indeed, entirely restored.

In the chronic forms of the disease the operation, owing to the degeneration and excavation of the optic nerve, does not accomplish so much. In chronic inflammatory glaucoma, however, the morbid process is usually checked unless the iris-tissue has become degenerated (Grüening).

In simple glaucoma the experience of v. Graefe, Bull, Nettleship, Fuchs, and others shows that by means of iridectomy the existing vision is preserved or slightly improved in about half the cases. In some of the remaining half the influence of the operation is negative; in others it seems to expedite the morbid process; while in a small proportion—estimated by some authors at about 2 per cent.—the iridectomy is followed by perieorneal injection, steaming of the cornea, and great increase in tension. The anterior chamber remains empty and vision is almost always destroyed. This condition, which is very rarely observed in the congestive types of the disease, has received the name of *malignant glaucoma*. The predisposition to it seems to affect both eyes. Hence the propriety of Schweigger's rule to operate on the worse eye first, even if it be blind. If this heals smoothly, the other may be expected to follow a similar course, but, as Friedenwald has shown, it may occur even where the operation on the first eye has healed without complication.

Absence of increased tension and a greatly restricted visual field diminish, although they by no means annihilate, the chances of benefit from iridectomy in simple glaucoma.

The *modus melendi* of iridectomy is not understood. The explanations so far attempted are merely of speculative interest.

Of the numerous operative procedures devised to substitute iridectomy in the treatment of primary glaucoma, the majority, including those of Hancock, Knies, Nicati, Pflüger, Vincentis, Badal, and Parinaud, and the combined sclerotomy of De Wecker, serve chiefly to illustrate the ingenuity of their inventors. Iridectomy has only one serious rival—viz. *sclerotomy*, and this is by almost universal consent relegated to a subordinate place. Sclerotomy, the technique of which is described on page 569, ought to be performed when the symptoms persist after a well-executed iridectomy, and preferably opposite the latter. It may also be resorted to when the iris has undergone degenerative changes which would be likely to preclude a satisfactory excision of this tissue. If done in a case of simple glaucoma with a contractile pupil, eserine should be previously instilled in order to prevent prolapsus iridis. Priestley Smith and Harold Gifford strongly recommend scleral puncture 5 mm. behind the cornea as a preliminary step to iridectomy in cases where the anterior chamber is very shallow.

In cases of absolute glaucoma which are attended with great pain unre-

lieved by iridectomy, or in which this operation is impossible of performance, enucleation, or, according to some, optico-ciliary neurotomy, becomes necessary.

The *non-surgical treatment* of glaucoma consists principally in the instillation into the conjunctival sac of solutions of eserine or pilocarpin of moderate strength, gr.  $\frac{1}{8}$  to  $\frac{1}{2}$  to f[5], although much stronger solutions are frequently required. Myotics are most serviceable in the prodromal stage of inflammatory glaucoma, but they will often hold an acute attack in check, and thus permit of delay if circumstances prevent an immediate operation. They are useful in many cases of simple glaucoma, especially with increased tension, in which an operation is contraindicated or is rejected by the patient. It is known that iridectomy in a case of unilateral glaucoma is sometimes suddenly followed by the appearance of the disease in the normal eye. The use of eserine in the latter at the time of the operation is believed to be an efficient means of averting the danger. As regards the use of myotics, the general consensus of opinion is that they are rarely more than palliative in their action. They should not be employed too long, because, apart from the external irritation often produced by them, they tend to increase ciliary congestion, and they do not always retard the progress of the excavation in the optic nerve.

The efficacy of *massage of the eyeball*, recommended by Gould and other observers, has not yet been sufficiently tested. It might be useful in deepening a shallow anterior chamber previously to operating.

*Constitutional remedies* for glaucoma do not have much vogue, but the reports of Sutphen and Friedenwald indicate that sodium salicylate in large doses has decided therapeutic value.

Glaucomatous tendencies should be combated by the correction of refractive errors, by the avoidance of constipation and of over-indulgence in eating and drinking, by regular open-air exercise, and, above all, by the cultivation of self-control, since a glaucomatous attack so frequently means the explosion of emotional dynamite.

II. **Secondary glaucoma** is the name employed to describe a condition in which the more striking phenomena of glaucoma—increased tension, shallowness of the anterior chamber, etc.—are developed as consequences of some antecedent disease or injury.

The pathological conditions which most frequently give rise to secondary glaucoma are perforating wounds of the cornea, either accidental or surgical (*c. g.* hypopyon-operations), suddenly closed corneal fistulae, corneal cicatrices, especially with staphyloma or incarceration of the iris, serous iritis and irido-choroiditis, occlusion of the pupil, traumatic cataract with swelling of the lens, dislocation of the lens, either forward against the cornea or backward into the vitreous, intraocular tumors, and contused wounds of the eyeball. The author has observed glaucoma follow a blow causing rupture of the choroid.

1. **Hemorrhagic glaucoma** is consecutive to retinal hemorrhage due to atheromatous or hyaline disease of the blood-vessels. It may appear with albuminuric retinitis. The intensity of the symptoms varies very much in different cases, as does also the time of their appearance after the discovery of the extravasations. It is difficult in many cases to decide whether the glaucoma is produced by the hemorrhage or the hemorrhage by the glaucoma. In severe cases hemorrhage into the vitreous entirely obliterates the fundus reflex.

2. **Complicated glaucoma** comprises those cases of the disease which

arise during the progress of some other affection, but in which the causative influence of the latter is doubtful. The most noteworthy of such complications are *cataract*, *atrophy of the optic nerve*, *pigmentary retinitis*, and *myopia* of high degree.

**Treatment.**—The treatment of the different forms of secondary glaucoma depends upon etiological considerations. A swollen or dislocated lens should be removed, an incarcerated iris set free, and an occluded pupil remedied by a generous iridectomy.

Hemorrhagic glaucoma responds badly to any form of treatment. Iridectomy is dangerous, being liable to be followed by increased retinal hemorrhage. Anterior sclerotomy or eserin may prove of service. In some cases posterior sclerotomy has been found beneficial. General treatment should not be neglected—ergot, cautious use of cardiac sedatives, the alteratives, and strict regulation of diet and mode of life.

**III. Buphthalmos.**—*Kerato-globus*, *Congenital Hydrophthalmos* (*Glaucoma Congenitum*).—This is a form of glaucoma pertaining to childhood, and characterized not only by elevated tension and cupping of the optic disk, but also by enlargement of the globe. The cornea, which may be either clear or opaque, is usually very thin and its diameter greatly increased. The anterior chamber is deep, the pupil dilated, and the iris tremulous from stretching or rupture of the zonula. The lens remains small. The pathology is obscure, but the condition is supposed to be due to an inflammation of the uveal tract dating back to intra-uterine life and causing an obstruction to excretion. The distention of the eyeball is explained by the fact that the sclera of the child is more yielding than that of the adult.

**Treatment.**—Iridectomy is contraindicated. Stölting reports favorable results from repeated sclerotomies, and Snellen from frequent puncturing of the anterior chamber. Eserin and pilocarpin should be tried. The prognosis is very unfavorable.



# DISEASES OF THE CRYSTALLINE LENS.

BY WILLIAM E. HOPKINS, M. D.,  
OF SAN FRANCISCO, CAL.

**Cataract.**—The general term “cataract” is accepted in modern medicine as meaning any opacity of the crystalline lens. A capsular opacity is denominated a *capsular cataract*, and an opacity involving both capsule and lens substance a *capsulo-lenticular cataract*.

**History.**—While cataract was well known to the ancient Greek and Roman physicians, our knowledge of its true nature dates from the beginning of the last century. Even before this one or two savants, as Mariotte and Boerhaave, recognized the real situation of the opacity, but their doctrines failed to obtain general acceptance. In the year 1705, Brisseau, a French surgeon, had the opportunity of making an autopsy upon the body of a soldier who had a mature cataract. Brisseau performed depression of the cataract upon the cadaver and then opened the eye, when he found that the opacity which he had depressed into the vitreous was the lens. He laid his observations, together with the conclusions drawn from them, before the French Academy, but they obtained no credence. The Academy confuted him by holding up the doctrines of Galen in regard to cataract. It was not till three years later, when new proofs had been brought forward, that the Academy recognized the new doctrine, which soon found general acceptance.

**Varieties of Cataract.**—Cataract may be *primary*, or *secondary* to some ocular disorder, or it may be *symptomatic* of systemic disease or local injury.

It may be *progressive* or *stationary*, *partial* or *complete*, and in color *black*, *white*, or *amber*.

Various classifications of cataract have been adopted by different authorities, the simplest divisions being into the soft, hard, secondary, and irregular and special forms, with their subdivisions:

|               |                                                                                                                                                           |                                                                                    |                                                                                                            |
|---------------|-----------------------------------------------------------------------------------------------------------------------------------------------------------|------------------------------------------------------------------------------------|------------------------------------------------------------------------------------------------------------|
| Soft,         | $\left\{ \begin{array}{l} \text{Congenital} \\ \text{or} \\ \text{Juvenile,} \\ \text{Complicated} \\ \text{or} \\ \text{Traumatic.} \end{array} \right.$ | $\left\{ \begin{array}{l} \text{Complete,} \\ \text{Partial,} \end{array} \right.$ | $\left\{ \begin{array}{l} \text{Lamellar, or zonular.} \\ \text{Pyramidal, or polar.} \end{array} \right.$ |
| Hard,         | Senile,                                                                                                                                                   | $\left\{ \begin{array}{l} \text{Cortical.} \\ \text{Nuclear.} \end{array} \right.$ |                                                                                                            |
| Secondary,    | $\left\{ \begin{array}{l} \text{Anterior Polar Cataract.} \\ \text{Posterior Polar Cataract.} \\ \text{After-cataract.} \end{array} \right.$              |                                                                                    |                                                                                                            |
| Irregular and | Special Clinical Forms.                                                                                                                                   |                                                                                    |                                                                                                            |

**I. Congenital or Juvenile Cataract.**—While the congenital or juvenile cataract is the commonest form of the soft variety, developing idiopathically, its complete variety is not frequently encountered, De Wecker having noted but 36 in 40,000 cases of ocular disease.

(a) **Lamellar or Zonular Cataract.**—This is the most frequent variety of congenital opacity of the lens. The opacity exists only in certain layers of the lens, between which are perfectly clear spaces. It is distinctly seen with oblique illumination, the opacities appearing of a light-gray color with translucent interspaces. When partial, little beyond a gray blur can be detected by close examination. Through the dilated pupil the ophthalmoscope will reveal, however, a sharply-cut, well-defined opacity, surrounded by a reddish circle due to reflection from the fundus.

*Constitutional conditions* are important factors in the development of this variety of cataract, rachitis, hereditary syphilis, or serofula often being associated with it. There may be imperfect cerebral development, and Arlt found in 29 such cases that 25 were affected with convulsions. Dental defects are common, the incisors and canines being marked with transverse lines, furrows, or terraces. Usually lamellar cataract is *double*, but it may be *monolateral*, and is either congenital or forms in early infancy. The former variety may be ascribed to developmental defects; the latter, to disturbances of nutrition dependent upon the causes just enumerated.

Congenital cataract may be found with other abnormal ocular states, coloboma, microphthalmos, irido-choroiditis, and choroido-retinitis being the most common. Disturbances of nutrition during intra-uterine life, arrest of development, and the influence of heredity are factors in the production of congenital cataract. In forms of cataract developing during early life the influence of heredity is strong, and notable examples of the affection appearing in many members of the same family are on record.

(b) **Complete Cataract of Young Persons.**—This is a soft cataract of milky or bluish-white color. It has no yellow reflex; it belongs to youthful life and rarely occurs after thirty-five years, before which period the lens is "soft"—*i. e.* the nucleus is small. It may degenerate and become fluid, or cholesterol crystals or chalky deposits may be found in it. It may arise without known cause, and often is monolateral.

**II. Traumatic Cataract.**—This may develop from direct laceration of the capsule and lens-fibers, and the rapidity of its progress is dependent upon the amount of surface exposed by the torn capsule. A normal lens, freshly removed and placed in water, very soon will absorb abundant fluid, and in the process of doing so will swell and become opaque and disorganized. This is exactly what takes place when the capsule is wounded. If the anterior capsule is opened, the aqueous is absorbed; if the posterior capsule, the vitreous.

Within a few hours after the accident the lens in the vicinity of the injury becomes slightly puffed and cloudy. Soon this soft, pulpy mass forces itself through the capsular wound and protrudes into the anterior chamber. It may be absorbed, but in the mean time mass after mass of the swollen fibers follows and the entire lens becomes opaque and gradually disappears. Hence in favorable cases a clear, black pupil with good vision may be the result. In unfavorable cases some inflammatory complication arises—iritis or cyclitis—and if there is any infection through the corneal wound, a purulent process may develop which will probably destroy the eye. At best, adhesions result which may lead to detachment of the retina or increase of tension. A lens which swells very quickly may produce a pressure-inflammation.

Cataract may develop from an indirect injury, without apparent rupture of the capsule, such as a blow on the head or side of the face, or as the result of an explosion, and it is then termed "*concussion cataract*." In these cases there is a slight rupture of either posterior or anterior capsule. Occasionally, after both direct or indirect trauma of the lens, the opacity is limited and remains stationary.

**III. Complicated Cataract.**—This may develop as the result of pathological changes in almost any of the tissues of the eye. It is commonly associated with iritic adhesions, cyclitis, irido-choroiditis, glaucoma, opacity of the vitreous, and detachment of the retina. The *prognosis* of complicated cataract is far less certain than in ordinary cases, and operation more difficult. Indeed, operative treatment is frequently contraindicated, or some special method of surgical procedure must be devised to meet the indications.

**IV. Senile Cataract.**—Hard (because the nucleus is large), simple, gray, or senile cataract, as it is variously designated, develops after middle life, most commonly after forty-five years.

The rate of development varies greatly. Sometimes the cataract will

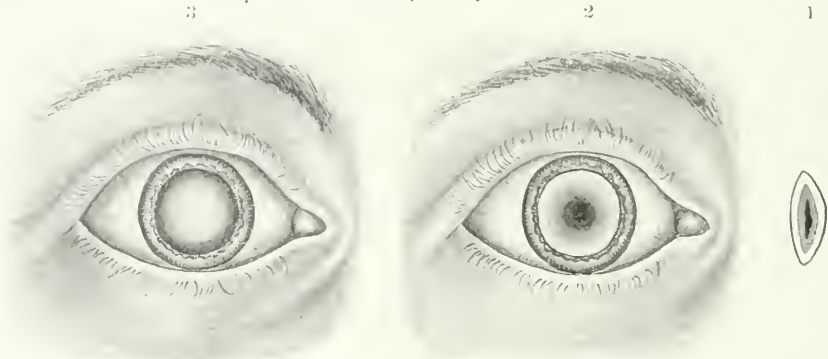


FIG. 250.—Nuclear cataract: 1, section of lens, central position of opacity; 2, appearance by transmitted light; 3, appearance by oblique illumination. (Modified from Nettleship.)

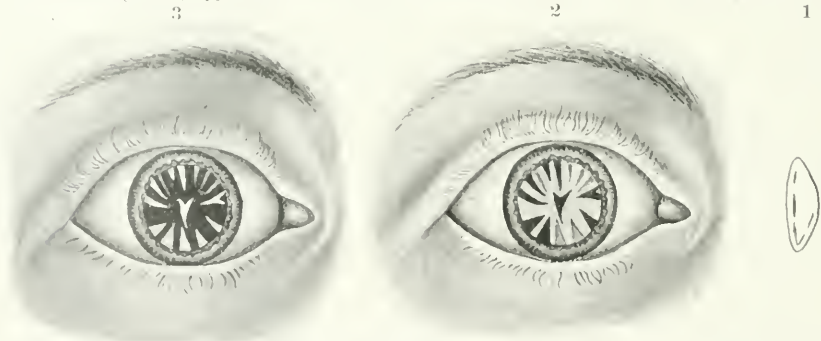


FIG. 251. Cortical cataract: 1, section of lens, opacities beneath the capsule; 2, opacities seen by transmitted light (ophthalmoscope mirror); 3, opacities seen by reflected light (oblique illumination). (Modified from Nettleship.)

remain stationary for years; again, it will ripen completely in a few months. It may progress rapidly for a time, then remain stationary for years, and finally resume its rapid progress. It nearly always affects both eyes, but usually one considerably in advance of the other.

Almost from birth there is greater density in the deeper or more central layers of the lens than in the superficial. This is not appreciable until after

the age of thirty-five. Then close examination will discover that the lens consists of a dense, hard, more opaque, central part, the *nucleus*, and a softer and more transparent surrounding mass, the *cortex*.

This physiological condition may continue indefinitely, with perfect vision, or the central part may become denser, more deeply stained and opaque, and form a *nuclear cataract* (Fig. 250). But pure nuclear cataract is rarely found. The cortex almost invariably is involved in the cataractous process (*cortical cataract*) (Fig. 251), but the conditions of hard interior and softer surface continue in greater or less degree in all cases.

The commencement of a senile cataract is somewhat variable. It may first appear in dark, linear striations passing from the margin to the center of the lens, or it may proceed from the anterior to the posterior surface. There may be stellate opacity or irregular and unequal dotted spaces. The cataract may commence at the *equator* or edge of the lens, or *centrally* at the nucleus. In some cases these linear striations remain stationary for many years. While evidently indicating beginning cataract, they have received the name of "gerontoxon lentis" or "arcus senilis lentis."

**V. Secondary Cataract.**—This includes three chief varieties:

(a) **Anterior polar or pyramidal cataract** results from a central perforating ulcer of the cornea (Fig. 252). It may appear as a conical mass projecting

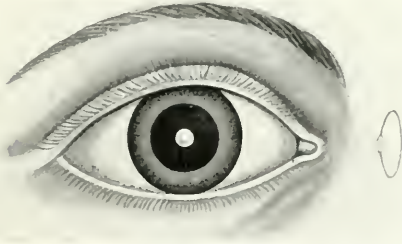


FIG. 252.—Anterior polar cataract (after Nettleship).



FIG. 253.—Posterior polar cataract seen by transmitted light (from a case of pigmentary degeneration of the retina).

forward from the surface of the lens, attached to the margin of the ulcer, or having a thread-like connection with it, or as a small white dot on the capsular surface. This condition is extremely unsatisfactory in regard to treatment, and its effect on vision is most serious.

(b) **Posterior polar or pyramidal cataract** is dependent on choroidal disease, especially disseminated choroiditis. It is found as a star-shaped opacity associated with high myopia, and often with extensive opacities in the vitreous, and less frequently with pigmentary degeneration of the retina (Fig. 253). It is also caused by the vestigial remains of the hyaloid artery at its lenticular attachment. Small posterior capsular opacities from this source are common and do not disturb vision. Among 1884 patients examined by Mittendorf, 44 were thus affected. In the course of posterior polar cataract the lens itself will often become opaque, the opacity manifesting itself as a general cloudiness or as innumerable dots scattered throughout the lenticular tissue.

(c) **After-cataract** (also called *secondary cataract*) is the condition usually left after the operation of extraction of cataract. The changes occur in the capsule; the opening may be closed by a delicate veil; the capsule-cells may proliferate, resulting in increased thickening; or there may be a plastic deposit, leading to occlusion of the pupil.



**VI. Capsular Cataract.**—This name is applied to any thickening or hyperplasia of the capsular epithelium, which resembles connective tissue. It may be congenital or result from ulcerative processes in the cornea, either with or without perforation of the cornea. According to Mules, cretified remains of the pupillary membrane explain some cases.

**VII. Capsulo-lenticular Cataract.**—Not only is there lenticular change in this variety, but there is hyperplasia of the cells on the posterior surface of the anterior capsule, causing thickening of that membrane, commonly in its center.

**VIII. Special Clinical Forms of Cataract.**—*a. Diabetic Cataract.*—This is usually of the *soft* variety, is rapid in its formation, and almost invariably affects both eyes. If it develops in elderly persons, it may be more consistent and have a more or less firm nucleus. It is often accompanied by lesions of the deeper tissues of the eye, as retinitis or optic neuritis. If possible, prior to operation these facts should be carefully ascertained on account of their bearing on the prognosis.

*b. Albuminuric Cataract.*—Although changes in the lens are sometimes found in association with Bright's disease, they are infrequent, and no direct connection between the two can be traced. It is well known that, as a rule, cases of cataract attributed to albuminuria make good recoveries after operation, and a fair degree of vision is secured. Other uncommon forms of cataract are—

*c. Central lental cataract,* which consists of a white opacity in the center of the lens, due probably to faulty development at an early stage of intra-uterine existence.

*d. Punctate cataract,* in which the opacities present themselves in the form of fine points and dots, either occupying the center of the lens or distributed throughout its substance. Punctate cataract may be congenital or develop in later life. Usually it remains stationary for a long time, but occasionally progresses to maturity.

*e. Fusiform cataract,* which is characterized by an opaque stripe passing from the anterior to the posterior pole of the lens.

**Pathology and Pathological Anatomy of Cataract.**—While the exact process which produces cataracts is still obscure, the development of opacity of the crystalline lens, most frequently associated with old age, is undoubtedly dependent upon some error of nutrition or upon some nutritive change secondary to disease in the deeper-seated tissues of the eye. This is evident from its frequent origin in some inflammatory disease in the iris, choroid, ciliary body, or vitreous humor. Any process which interrupts or diminishes the vascular supply to the anterior region of the globe, or interferes with the osmotic action of the nutritive fluids, will directly affect the normal conditions of healthful stability.

This interruption of natural conditions leads to slow but progressive changes in the lens-fibers. There is primarily a slight contraction, followed by increase in volume, owing to the imbibition of fluids; cholesterin is increased in amount, and the albuminoids diminished. The new cell-production from the intracapsular cells can be plainly seen with the microscope. Later, the lens-fibers atrophy, their volume diminishes, and irregular interspaces are formed, within which large amounts of fluid accumulate (Morgagni's globules). Often the fibers show punctate cloudiness, transverse striations, molecular degeneration, fat-globules, and cholesterin (Fig. 254).

Förster states that in the process of transformation of the inner layers of the lens into a nucleus the layers diminish in volume. Normally, this

process is so slow and gradual that the cortical layers adapt themselves to the contracting nucleus. If, however, the shrinking progresses rapidly or irregularly, there is extreme pulling or traction, with consequent separation of the layers which lie between the nucleus and cortex. In this condition fine fissures are formed and fluid accumulates in them; the adjacent lens-fibers become opaque and form the initial impulse which leads to complete lenticular opacity.

**Etiology.**—Cataract may be considered a disease of old age. While complete cataract is found at almost any period of life, it is comparatively rare before the fiftieth year.

*Sex* does not influence the development of cataract, except in the zonular variety, in which greater liability of females has been recorded. *Occupation* has but little influence on the development of the disease, although it has been observed to occur more frequently in those who are constantly subjected to intense heat, as laborers in Turkish bath-houses, glass-blowing factories, smelting-foundries, etc. *Heredity* has an undoubted influence.

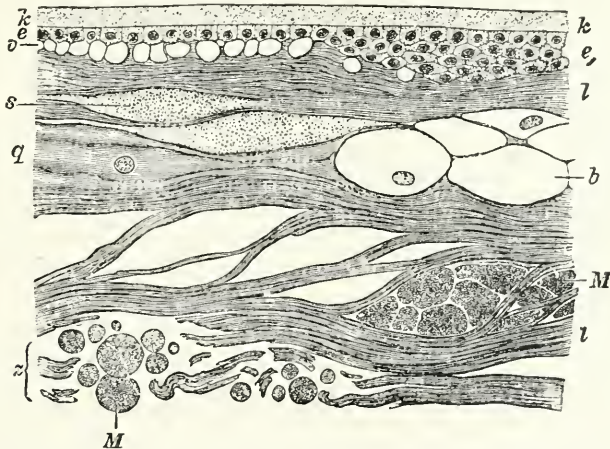


FIG. 254.—Cataracta capsulo-lenticularis,  $\times 170$ : *k*, anterior capsule of the lens; *e*, epithelium, occurring at *e*, in several layers because of proliferation; *l*, normal lens-fibers; *r*, light-colored vacuoles (drops of liquor Morgagni) between *l* and the epithelium. The fissures originating through the separation of the lens-fibers are filled with a granular mass (coagulated fluid), *s*, which in places forms the spheres of Morgagni, *M*. The lens-fibers themselves are swollen up (*q*), or transformed into vesicular cells (*b*), or entirely disintegrated (*z*) (Fuchs).

There are examples where many members of the same family are afflicted. The author has met with cataract in the four children of one family, both father and mother having developed the disease at an early age. Hasket Derby has recorded 8 cases of rudimentary double cataract among 10 members of the same family, and John Green 21 cases of cataract among 71 persons belonging to 6 successive generations of one family.

Both *acute and chronic diseases of the eye*—iritis, irido-choroiditis, iridocyclitis, glaucoma, diseases of the vitreous, and most commonly extensive and long-standing detachment of the retina—frequently cause cataract. It is especially apt to develop after purulent processes, such as hypopyon-keratitis or purulent choroiditis.

Such diseases as idiopathic fever, typhoid fever, diabetes, albuminuria, atheroma of the carotid, gout, syphilis, influenza, rachitis, bronchoecle, meningeal inflammation, and convulsive seizures have been associated with cataract formation. It has been attributed to pregnancy and prolonged lactation.

In epidemics of *ergotism* cataracts are frequently found (*raphanic cataract*), and artificial cataract may be induced in animals by feeding them with naphthalin (*naphthalin cataract*). For that form of cataract found in diseases of the uveal tract and in anemia and marasmus the name "starvation cataract" has been suggested.

The influence of *accommodative strain* on the production of cataract, as well as other serious ocular disturbances, is not thoroughly understood. A large proportion of cataractous eyes are ametropic. It is probable that the constant effort of the ciliary muscle unfavorably influences the nutritive processes of the lens.

The influence of *traumatism* in the production of cataract has been described. Some cases have followed a lightning stroke, but have also been associated with optic neuritis, rupture of the choroid, iritis, or irido-cyclitis.

**Symptoms.**—During the development of cataract, especially the senile form, the chief *subjective symptom* is a gradual but steady loss of vision. In those cases where the periphery of the lens is first affected very extensive opacity may form without great loss of vision; but if the opacity invades the center or nucleus, the interference with sight becomes marked at an early stage. This may be beautifully demonstrated by the instillation of a mydriatic—improvement in vision will at once appear. It is in this latter class of cases that an iridectomy may prolong vision for years.

The presence of floating spots or muscæ, diplopia, often monocular, or polyopia, changes in refraction with the development of astigmatism, or the alteration of the axis of a pre-existing astigmatism, are exceedingly common, and are mainly due to the irregular swelling of the lens-substance. This is so great at times as actually to produce a true myopia (the "second sight" of the aged), and necessitates a greatly diminished convex, or at times a concave, glass (see also page 222).

Among the *objective symptoms* will be found a narrowing of the anterior chamber in the early stages, consequent upon the advancement of the iris and due to the swelling and bulging of the lens; photophobia, due to the iritic irritation caused by the same pressure; striae or opaque spots, demonstrable by oblique illumination; and, finally, the changed pupil, which is altered from a brilliant black to a staring yellow, white, or brown. Sometimes the lens becomes so deeply stained as to appear dark brown or black (*cataracta nigra*); sometimes it is of a milky, bluish-white color; and sometimes the cortex degenerates, becomes fluid, and the hardened nucleus sinks to the bottom of the shrivelled capsule (*Morgagnian* or *overripe cataract*).

For clinical study Fuchs divides the periods of the development of a progressive cataract into four stages, as follows:

1. *Stage of Incipience (Cataracta Incipiens).*—In this stage opacities are found throughout the lens, usually in the shape of sectors or spokes, with spots still transparent. The anterior chamber is of normal depth.

2. *Stage of Swelling (Cataracta Intumescens).*—The lens has now absorbed more fluid, swelled up, and has pushed the iris forward and reduced the depth of the anterior chamber. The opacity becomes total in this stage. The lens is bluish-white and has a silky luster. The markings of the stellate figures are very distinct.

3. *Stage of Maturity (Cataracta Matura).*—Contraction has now taken place, and most of the fluid absorbed has been lost. The anterior chamber has resumed its normal depth, and the lens, losing its brilliant, iridescent look, has a dull-gray or brownish appearance.

4. *Stage of Hypermaturity (Cataracta Hypermatura).*—If the change



continues, the cortex undergoes disintegration and becomes either a soft, pulvaceous mass without structural elements, or, if the fluid is absorbed, a dry, inspissated, flattened, cake-like body. The anterior chamber is normal, and the surface of the lens is homogeneous, or reveals irregular dots instead of the usual radial markings.

**Diagnosis.**—The old *catoptric test* may still be used to detect the presence of cataract, as well as to determine the presence of the lens or of a black cataract. In a darkened room a lighted candle is moved before an eye with properly dilated pupil. If two erect images and one inverted image are reflected respectively from the anterior surface of the cornea and the anterior and posterior surfaces of the lens, the lens is intact. If, however, the posterior inverted image is absent, there is some opacity behind the anterior capsule, and if the deeper erect image is wanting, the opacity involves the anterior capsule.

With *oblique illumination* the opacities appearing as gray spots or striations may be easily recognized. The use of the *ophthalmoscope* has caused all other methods to be abandoned. It has rendered the detection of cataract a matter of immediate and certain demonstration. The patient, with pupil dilated with cocaine or homatropin, is taken to a darkened room and placed in the position for ordinary ophthalmoscopic examination. Light is reflected from the mirror through the enlarged pupil, and the interruptions to the normal reflex from the choroid will indicate the lenticular opacities, which appear as black spots or as lines or streaks radiating from the margin to the center. The nucleus may be hazy, or the center may appear clear with opaque rings surrounding it. The sectors of the lens may be denser than normal, or lenticular flaws, resembling cracks in glass, may be seen. Finally, there may be entire absence of the reflex due to complete opacity of the lens body.

**The Process of Ripening.**—The *course* and *development* of cataract vary greatly. In the simple or senile form the time from incipency to ripeness may vary from a few months to many years; the usual time is from one to four years. Cortical cataract may remain immature for a prolonged period (fifteen to twenty years); hence the wisdom of a guarded prognosis. Finally, when the entire substance of the lens has become opaque, when the swelling has subsided, and the anterior chamber has resumed its normal depth, the cataract is *ripe*. This period may be determined by illuminating the pupil and carefully observing if the shadow of the margin of the iris is reflected from the lens. In case no shadow is seen the cataract is complete and ripe; if the shadow is present, there is still a transparent reflecting layer of the lens beneath the capsule (Fig. 255).

A mature cataract has the property of separating readily from its connection with its capsule. As suggested by Arlt, it lies in its capsule like a ripe fruit in its rind. The cause of this will probably be found in the preliminary swelling and contracting of the lens-substance, and the consequent loosening of the surface from the capsule.

**Prognosis.**—This should be guarded in immature cataracts of all varieties, but especially in the linear cortical variety, with which good vision may be retained for a period varying from fifteen to twenty-five years. The following considerations should influence the prognosis with reference to the

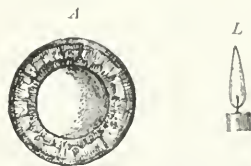


FIG. 255.—Shadow of the iris seen from the front, appearing on that side of the iris which is toward the light, L (Fuchs).



result of operative procedure: The want of health in surrounding tissues; disease of the nasal or lachrymal passages; various forms of inflammation of the conjunctiva and margins of the lids; the size and consistence of the nucleus; the degree of maturity of the cataract; the general condition of the patient and the presence of general disease, such as diabetes, chronic nephritis, or bronchitis, with constant cough; the presence of extreme myopia or hyperopia; immobility or tremulousness of the iris; and contraction of the light-field, or want of light-perception due to serious ocular disease, such as glaucoma or retinal detachment. The presence of diabetes or Bright's disease, while complicating, does not contraindicate operation. Extreme age does not necessarily complicate the result.

The *light-field*, upon which the final prognosis is based, providing other complicating circumstances enumerated are absent, is thus tested: Place the patient before a lighted candle about four meters distant; the flames should be distinctly recognized. This gives evidence that the macular region is probably free from coarse disease. Now cause the eye under examination to fix the flame attentively, and move a second lighted candle radially through the field of vision. The flame should be recognized as soon as the rays strike the edge of the cornea, and the patient should be able to indicate the direction in which the light is coming. Thus the "light-field," or the "projection of light," is tested, and, if the answers have been accurate, "projection of light is good in all parts of the field."

Even after complete absorption of congenital cataract under the influence of repeated dissections, useful vision is not always restored, because of associated optic nerve-atrophy, choroidal disease, or changes at the macula. The functional condition of an eye with total congenital cataract is usually less favorable than one with the zonular variety of the disease.

**Treatment.**—From the earliest period ophthalmologists have eagerly sought some method of absorbing or dissipating the cataractous lens. Various suggestions have been made, and various methods of procedure, such as *massage* and passing the *electric current*, have been tried, but with negative results. So long as glasses, changed in accordance with the altering refraction of the eye, improve vision, they may be worn. Tonics are useful as adjuvants, and various alteratives—*e. g.* iodid of potassium—to relieve choroidal congestions may be exhibited. During incipency moderate mydriasis may assist vision. At the proper time, however, surgical interference becomes necessary.

Various important questions arise in determining the best course to be followed to bring the treatment of cataract to a happy conclusion. When should extraction be made? Are we justified in hastening the process of ripening, and should we interfere when one eye is intact and has normal vision?

1. **Extraction of Immature Cataract.**—Most ophthalmic surgeons delay extraction until the process of ripening is complete. While this is, perhaps, the wisest plan, everything considered, it is by no means the only one. The danger of an early operation—the swelling of the softened unripe cortex—can be largely overcome by washing out the cavity with warm saline solutions, after the method of Panas and other operators, subsequent to extracting the nucleus.<sup>1</sup> About the sixtieth year of life, and even earlier, an unripe cataract may be successfully extracted.

<sup>1</sup> Irrigation of the anterior chamber, in the opinion of the editor, is an unwise procedure. If the capsule is properly opened (see page 581), the danger of swelling of cortical remnants is small—smaller than that which follows irrigation.

2. **Artificial ripening of cataract** is rarely justifiable. It subjects the patient to a second major operation on the eye, with the attendant dangers. When this operation is determined upon it may be performed according to one of the methods described on page 584.

3. **Extraction of Monocular Cataract.**—Unless the cataract is hypermature or a cosmetic effect is greatly desired, we are hardly justified in extracting an opaque lens when the other eye has normal vision. The advantages of a successful operation are that the field of vision of the affected side becomes more extensive, and the patient possesses an eye ready for use should vision in the other eye become involved from any cause. On the other hand, while binocular vision is possible, objects are constantly blurred and sharpness of contour is wanting. The operated eye sometimes lags behind the other, giving an awkwardness of expression more grotesque and less pleasing than the presence of the cataract.

4. **Operations for Cataract.**—For soft cataracts *discission*, the *method of suction*, a combination of these methods, or *linear incision* may be practised. The use of the needle, repeated if necessary, will suffice in the usual soft varieties, while the suction method will quickly extract the contents when of semifluid consistency. It is not wise to delay the removal of a congenital cataract beyond the early weeks of life, as interference with the development of the retina and other deeper tissues of the eye may result.

Partial congenital cataracts are treated by *optical iridectomy* or *discission*. The former method is applicable to those cases whose vision is improved by dilating the pupil.

*Discission* is practised for the after-cataract, not to produce absorption, but to open a passage for the light-rays (see page 585).

For the removal of the hard or senile cataract one of the various *methods of extraction* should be followed. The results of this operation are such that the older method of *couching* has been completely abandoned. While the exact technique of the various operations will be found elsewhere (see chapter on Operations, p. 580), several important points may be properly referred to here. The corneal incision should be ample in size, and should be completed with as few motions as possible, the subsequent rapid union of the cut surfaces being somewhat dependent upon this. The question of an iridectomy is much discussed, each individual operator having finally to determine the method from his own experience. Probably simple extraction (without iridectomy) is now performed in 60 per cent. of the cases, the maturity of the cataract, the condition of the iris, and the question of drainage determining the method. A wise rule is to perform simple extraction, examine the eye within twenty-four hours, and, if the conditions are not favorable, separate the lips of the wound and resect the iris. The extrusion of the vitreous during the operation is usually due to insufficient rupture of the capsule and excessive pressure in delivering the lens. Unless it is so great as to cause total collapse of the globe the removal of the lens may be successfully attempted by other means. A degenerated or fluid vitreous may instantly force the operator to desist.

**Aphakia.**—In the normal eye the removal of the lens (aphakia) causes a high degree of hyperopia, about 11 D. In myopia the degree of hyperopia will be lessened, and, indeed, in myopes of high degree emmetropia may result from extraction of the lens, or, if the myopia has been very great, a portion will remain unneutralized by the artificial hyperopia. In addition to the hyperopic refraction which results from cataract extraction, regular astigmatism is often found. It is probably produced by the irreg-

ular contraction of the cicatrix, and is usually "contrary to" or "against the rule." It is always greatest in the early months after the operation, and slowly diminishes. These conditions can be much relieved by the application of suitable glasses. In the average case a simple sphere of from 8 D. to 12 D., with the addition of a cylindrical glass of from 2 D. to 3 D., axis contrary to the rule, will usually suffice for good distant vision. For reading an additional sphere of from 4 to 6 D. must be added.

Perfect vision—*i. e.*  $\frac{6}{6}$ —is often secured after extraction, but  $\frac{1}{6}$  or even  $\frac{1}{10}$  of normal vision is sufficient to place the case within the list of successes. Frequently the vision can be materially improved by splitting the capsule. Glasses should not be adjusted until all signs of irritation have subsided.

**Changes of Position of the Crystalline Lens.**—The various changes which the position of the crystalline lens may assume, termed *luxation* and *subluxation*, may be congenital or acquired. The lens is supported firmly in its natural position by the zonula of Zinn or the suspensory ligament, and displacement of the lens is only possible by relaxation or elongation of the zonula fibers or by their destruction.

1. *Congenital dislocation, or ectopia lentis*, is almost invariably a subluxation, and is due to the unequal length of the zonula in various directions. The zonula being shortest above, the lens will be found displaced upward or upward and outward. Later in life the displacement may become complete. Both eyes are usually affected, but monocular cases are reported. Heredity appears to exert a marked influence on the production of congenital dislocation.

2. *Acquired dislocations* are the result of injury, usually a concussion which forces the aqueous backward and ruptures the delicate membrane of the zonula. The displacement may be complete or incomplete, the lens being forced forward into the anterior chamber or backward into the vitreous, or through a laceration of the external coverings of the eye beneath the conjunctiva, and even under Tenon's capsule. Occasionally it is completely expelled (see also page 366).

**Symptoms.**—In *subluxation* the anterior chamber is found of unequal depth, the iris being pushed forward at one point by the margin of the lens. The iris, losing its support in part, is no longer stationary, but trembles with every motion of the eye. With the ophthalmoscope the edge of the lens is seen as a dark grayish line. There may be loss of accommodation and monocular diplopia. In *complete luxation forward* the lens will be easily recognized by its shape as it rests in the anterior chamber or bulges out beneath the conjunctiva. In *posterior dislocation* the conditions simulating extraction are present. With every form of luxation very considerable changes in vision are noticed. In subluxation myopia may be present, and a considerable degree of astigmatism. In complete dislocation backward the extreme hyperopia of the aphakic eye is produced. The lens almost invariably undergoes cataractous changes, and by pressure may produce very serious inflammatory changes in the other tissues of the eye—iritis, cyclitis, and choroiditis—or by closing the angle of the anterior chamber, giving rise to glaucoma (see also page 366).

**Treatment.**—In partial dislocations the vision should be improved as much as possible by appropriate glasses. In complete anterior dislocation the lens should be removed through a proper incision. Where the dislocation is backward, unless there is some irritation, no attempt at removal should be made. When there is danger to the eye an effort should be made to press the lens forward into the pupil space by passing a needle through the

selera behind the lens, and then extracting it through a corneal wound (see also page 582).

**Congenital Anomalies.**—Congenital cataract and congenital ectopia lentis have been recorded. In addition, there remain to be described—

1. *Congenital Aphakia.*—Total absence of the lens at birth is a condition of which there is no recorded example. Total absence of the lens has been found, however, in rare instances, as the result of some intra-uterine disease.

2. *Coloboma of the Lens.*—Coloboma of the lens almost invariably accompanies a similar condition of the iris or choroid, especially the former. The evenly rounded margin of the lens is replaced by a straight border or, it may be, by a notch of greater or lesser depth. Heyl states that the coloboma is almost invariably found in the lower segment of the lens. It may considerably disturb the visual acuteness.

3. *Lenticonus.*—This rare anomaly consists of a conical projection from the surface of the lens, usually from the *posterior surface*, or it may simply be an exaggerated curvature of the lens. On examination with the ophthalmoscope it resembles a drop of oil resting on the surface. It may or may not be associated with lenticular opacity. *Anterior lenticonus* also occurs.



## DISEASES OF THE VITREOUS.

BY FLEMMING CARROW, M. D.,

OF ANN ARBOR, MICH.

**Hyalitis** (*Inflammation of the Vitreous*).—This disease appears in two forms—one characterized by *suppuration* (*suppurative hyalitis*), and the other by either *fixed* or *floating opacities*.

**Etiology.**—All opacities seen in the vitreous, however, are not to be regarded as the result of pathologic conditions peculiar to that body, for they are usually dependent upon some structural change in the uveal tract or retina. On account of the absence of blood-vessels and nerves in its structure the vitreous was at one time supposed to be incapable of inflammation, but recent investigation has developed the fact that *idiopathic* or *spontaneous inflammation* may occur without change of a textural character in any other part of the eye. It is true, however, that hyalitis of the suppurative variety is generally a secondary disease, being caused by an injury (penetrating wound) to some adjacent structure, or by previously existing choroidal disease which had its origin, primarily, in consequence of some operative procedure upon some other part of the eye (as after cataract extraction).

Suppurative hyalitis may also be due to microbic invasion of old operative scars of several years' standing, to exhaustion following any lengthy debilitating disease, especially the continued fevers, relapsing fevers, the exanthemata, or may result from metastatic choroiditis after inflammation of the umbilical cord in new-born children.

**Symptoms.**—Since suppurative hyalitis is usually secondary to disease of other structures, we will find evidences of the presence of this primary affection in adhesions of the pupillary margin to the anterior capsule of the lens, and a history of iritis and cyclitis. Pus once having formed in the vitreous (the cornea and media being clear), it is readily seen with the ophthalmoscope occupying a circumscribed area (*pseudo-glioma*), while the rest of the vitreous may appear perfectly clear and healthy. This condition closely resembles a true glioma of the retina; but the history of the case, with the symptoms of iritis and diminished tension, will serve to distinguish them (see also page 356).

The disease may remain confined to some peripheral portion of the vitreous body, but usually the suppurative process extends until the entire vitreous becomes involved, and through a resulting *panophthalmitis* the eye is lost. The history of some pre-existing eye-disease and the ophthalmoscopic appearances will sufficiently indicate the location and gravity of the affection.

**Prognosis and Treatment.**—The result of suppurative inflammation of the vitreous is usually not only the loss of the affected eye, but the atrophied globe after panophthalmitis may be a source of menace to the sound eye. Should the health of the sound eye be threatened at any stage of the disease, enucleation of the affected organ must be at once performed.

During the course of any lengthy debilitating disease, should suppurative hyalitis supervene, it may be possible to save the eye with some degree of vision by vigorous tonic treatment. Intraocular injections of chlorin-water have been recommended on experimental grounds (Berry).<sup>1</sup>

**Opacities of the Vitreous.**—That variety of inflammation of the vitreous characterized by the formation of *fixed* or *movable* opacities may be either *acute* or *chronic*.

**Etiology.**—As this form of vitreous disease, like the suppurative variety, is secondary to affections of other portions of the eye, the refraction of the eye and the condition of the lens, of the ciliary body, choroid, and retina, must be examined for its cause. High degrees of myopia associated with posterior staphyloma constitute a frequent cause of this trouble. Again, in choroiditis, and especially in the specific variety, a fine dust-like mist (*hyalitis punctata*) can be detected, through which there are distributed larger flake-like opacities of irregular shape, which give individuality to the primary disease which caused them.

Exhaustion of the general system from long-continued fevers, gout, constipation, anemia, interference with the function of the liver by congestion, irregular menstruation, syphilis, and the action of drugs (arsenic), all may, and often do, produce opacities in the vitreous. Injuries to the eye causing *choroidal hemorrhage* will also result in the formation of opacities, and, if extensive, may lead to suppuration.

Benson has described a form of opacity in which the vitreous is filled with minute, light-colored spheres (*asteroid hyalitis*). The condition is congenital, and does not interfere with normal visual acuity.

From the foregoing statements it is evident that opacities in the vitreous are generally the result of some pre-existing disease of some other part of the eye, although there may be a primary inflammation of this body to which they owe their origin.

**Symptoms.**—Patients readily see opacities of the vitreous, either as *fixed* or *movable* black spots, and are quite able to describe their situation, size, and shape. There may be no diminution of vision, although central vision may be entirely lost if there is a large centrally situated fixed opacity. Should there be pain or evidences of external inflammation, it must be taken for granted that the vitreal disease is complicated by some other affection, and probably the result of it.

The ophthalmoscope offers the one certain method of making a positive diagnosis if the media are clear. The patient is directed to move his eye quickly in all directions, and then to hold it quite still. The floating opacities are then seen to move in the vitreous, and gradually to sink to the lower portion of the chamber. Not only can the size of the opacities be correctly estimated in this manner, but a very good idea of the degree of fluidity of the vitreous can be obtained. It will be noticed, when the interior of the eye is illuminated by reflected light and the patient directed to move his eye, that these opacities move in a direction opposite to the movement of the eye: when the eye is turned to the right, the opacities move toward the left, and in this way they can be distinguished from opacities in the lens or cornea, which, being fixed, move with the movements of the eye. Fixed opacities in the vitreous may be discovered by using a strong convex lens (+16)

<sup>1</sup> The editor has also found that in experimentally induced suppurative hyalitis in dogs intravitreal injections of chlorin-water seemed to check the process, but is in entire accord with the author that intraocular injections are measures ordinarily to be condemned (see page 400).

behind the ophthalmoscope, the observer holding his eye quite close to that of the patient (see also pp. 178, 179, 183).

**Treatment.**—While treatment is not generally effective in entirely removing opacities of the vitreous, much may be done for the relief of the patient. If myopia is found to be their cause, its correction to the full degree of the error should be ordered. Irregularities of the menstrual function, disorders of the liver, or exhaustion from protracted illness of any kind must be corrected. For syphilitic varieties the mercurial preparations employed in the form of intramuscular injections promise more than when given in any other way. The protiodid of mercury, combined with iron, also gives excellent results, as do iodid of potassium and sodium. Gout, constipation, and anemia should be treated for the share they may have had in the production of the disease. Diaphoresis with pilocarpin hydrochlorate (gr.  $\frac{1}{10}$ — $\frac{1}{6}$  hypodermically) is of service, and, according to de Schweinitz and Spaulding, small doses of the same drug, even when sweating is not produced, are valuable. Electricity in the form of galvanism has been reported to be of use.

Various medicinal agents, such as the soluble mercurial salts, solutions of potassium iodid, and carbolic acid, have been injected into the vitreous chamber in the hope that absorption of vitreous opacities and other effused inflammatory products might follow. The writer does not believe that such treatment is warranted, except where vision has been reduced to a mere quantitative perception of light, which no remedy, however severe, can make worse, for disorganization and dense opacity of the vitreous body are almost certain to follow its use. Furthermore, the hyaloid and retina become affected, and panophthalmitis usually results.

A large fixed and more or less central membranous opacity may be divided by passing a discission needle into the vitreous in front of the equator of the eye, entering it just below the lower border of the external rectus muscle, care being exercised to watch the movements of the instrument with the ophthalmoscope.

**Pseudo-glioma**, so called from its resemblance to glioma of the retina, is a circumscribed suppurative inflammation of the vitreous, generally occurring in the periphery of the chamber near the ciliary region.

With the ophthalmoscope a yellowish-white reflex can be seen, but as there are abundant evidences of a pre-existing irido-choroiditis, there can scarcely be excuse for mistaking this for a true glioma of the retina. Diminished tension, followed by shrinking of the globe, sometimes with subsequent ossification of the choroid, marks the distinction between this and true glioma.

The treatment is to be directed to the primary disease standing in a causal relation to this affection (see also page 355).

**Musæ Volitantes.**—*Myodesopsia.*—There are in the vitreous certain amoeboid cells, most abundant at its periphery, which are of normal occurrence, and are not disturbing to vision, as they are transparent and readily transmit light. On account of their constant presence the mind usually disregards them, but occasionally, when looking at some white surface, as the page of a book, and while there are no other retinal images with which to compare them, they force themselves upon the notice of the patient and cause more or less distress. They may be seen *entoptically* by closing the eyelids and turning the face toward a bright light. They appear as fine threads and specks of various size, which float across the field of vision when the eye is being moved, but do not in any way disturb visual acuity. Occasionally they assume curiously fantastic shapes.

**Treatment.**—As most patients annoyed by musæ volitantes have some

error of refraction, this should be corrected with suitable lenses. At the same time, they should be assured that the presence of these floating opacities has no clinical or pathological significance.<sup>1</sup>

**Hemorrhage into the Vitreous.**—This most frequently follows a rupture of some of the vessels of the choroid at its anterior portion where the retina is thinnest, thus allowing a freer extravasation than would be the case should a vessel rupture at its posterior part, where the retina is thicker. Schweigger doubts if extravasation of blood into the vitreous can occur as the result of a rupture of the vessels of the retina, because, owing to the arrangement of its connective-tissue fibrillæ and the strength of its internal limiting membrane, hemorrhage from it would generally extend toward the choroid and not toward the vitreous. However this may be, we are able to see with the ophthalmoscope, if the hemorrhage is slight, a bright red reflex indicating the seat of the extravasation, or a red veil if the blood is thinly distributed over a considerable extent of the vitreous.

*Spontaneous hemorrhage into the vitreous* may occur, particularly in the case of young male adults who are subjects of irregularities of the circulation (Eales) and of gout (Hutchinson). Such hemorrhagic effusions are not, as a rule, entirely absorbed, but leave opacities in the vitreous very damaging to vision if centrally situated.

If the hemorrhage is extensive, the sight is immediately lost, and it is impossible to obtain a view of the interior of the eye. After absorption of the effused blood, and when the vitreous has become clear, numerous fixed and floating opacities may be seen, which become less and less distinct as absorption goes on, only to be followed by other extravasations, and perhaps finally by detachment of the retina. Permanent opacities are usually left behind, even in those cases where the hemorrhages do not recur, and vision is always very considerably impaired.

**Treatment.**—The mercurial preparations, iodid of potassium, pilocarpin, and the saline mineral waters are indicated in the treatment of these cases. Ergot may also be employed, especially early in the disease. Abadie has directly galvanized the vitreous, passing a platinum needle in the chamber, in a case of chronic vitreous hemorrhage. This procedure is of doubtful value.

**Synchisis Corporis Vitrei** (*Fluidity of the Vitreous*).—During the progress of certain diseases of the eye, notably retinitis, choroiditis, and very high degrees of myopia, the nutrition of the vitreous is so seriously impaired that its proper framework is destroyed, and it loses its normal consistency and becomes a straw-colored liquid. In extracting a cataractous lens we frequently have to guard against this condition, which has been developed by a previously existing disease of some other part of the eye. There are always diminished tension, and frequently a tremulous condition of the iris. Treatment is of no avail.

**Synchisis Scintillans** (*Cholesterin Crystals in the Vitreous*).—The presence of minute crystals of cholesterin and tyrosin in the vitreous produces a very interesting ophthalmoscopic picture, but does not interfere with vision if that body is otherwise healthy. The crystals are seen in the

<sup>1</sup> For an interesting and suggestive study of mnceæ the reader is referred to a paper by Geo. M. Gould, M. D. (*Medical News*, Sept. 15, 1895). Dr. Gould believes that there is a chamber, which he calls the aqueo-vitreous chamber, situated between the vitreous posteriorly and the lens, its ligament, and the ciliary body anteriorly, and which contains the mnceæ-genetic particles in suspension. These particles he regards as the débris of vitreous katabolic change. Based on entoptical studies, Dr. F. P. Pratt believes that so-called mnceæ are caused by the lymphatic capillaries of the vitreous.



eyes of the aged, usually in connection with vitreal opacities. They are not of frequent occurrence. They appear as small luminous bodies which reflect the light from the ophthalmoscope in the form of a shower of sparks, and do not yield to treatment.

**Blood-vessel Formation in the Vitreous.**—Observation with the ophthalmoscope has occasionally revealed the formation of new blood-vessels in the vitreous, and their presence is presumptive evidence of a previously existing inflammation of that body or of former hemorrhages. Becker relates that he observed them in a case of purulent infiltration of the vitreous, while Hirschberg has seen them in connection with specific disease of the eye. They start from the nerve-head, which they partly obscure, and pass

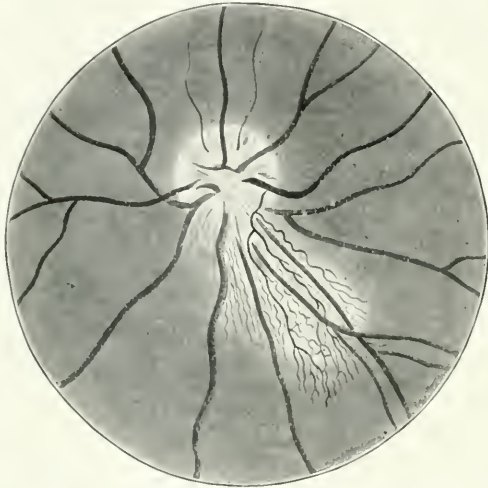

FIG. 256.—Blood-vessels in the vitreous (Hirschberg).

forward into the vitreous as a more or less well-formed veil of freely communicating capillaries, without, however, having any connection with the vessels of the retina (Fig. 256).

**Entozoa in the Vitreous.**—Two distinct parasites have been found in the vitreous of the human eye—the *cysticercus cellulosa* and the *filaria sanguinis hominis* (Manson).

The former, while rare, has been seen most frequently in North Germany. It is the scolex of the *tenia solium*, the eggs of which, having obtained entrance into the stomach, find their way into the blood-channels, whence they are carried to the eye and deposited under the retina. In the course of its development it is provided with hooklets, by means of which it perforates this tunic and is set free in the vitreous. Here it may appear encysted in a membrane which will mask its distinctive characteristics and prevent a correct diagnosis. If, however, it is quite free, it is of a pale, greenish-blue color, having a short neck surmounted by a round head ornamented with minute suckers, which may be seen to move in undulating lines.

Von Graefe attempted the removal of a *cysticercus* through an incision, following his method of the extraction of a cataractous lens. After delivery of the lens he passed a blunt hook into the vitreous, and by alternately advancing it toward the entozoon and then withdrawing it, he succeeded in delivering the parasite, without, however, restoring vision.

The *filaria sanguinis hominis* in the human eye is of such rare occurrence that it requires only passing mention.

**Detachment of the Vitreous.**—The vitreous is subject to degenerative changes which produce a shrinkage in its volume, thus removing it from direct contact with, and support of, the limiting membrane of the retina. As is readily seen, this condition is followed by detachment of the retina and loss of vision. The author has enucleated a painful atrophied eyeball in which this condition was beautifully illustrated. The vitreous had shrunk to half its size, and was closely enveloped by the retina, and consisted of bands of connective tissue stretching from the nerve-head to the posterior surface of the lens. This condition results from injury to the vitreous, followed by choroiditis and hemorrhage, or from extensive posterior staphyloma. The treatment is enucleation.

**Fatty Degeneration of the Vitreous.**—Under this heading Dr. D'Ench and Dr. Valk have reported cases the diagnostic features of which

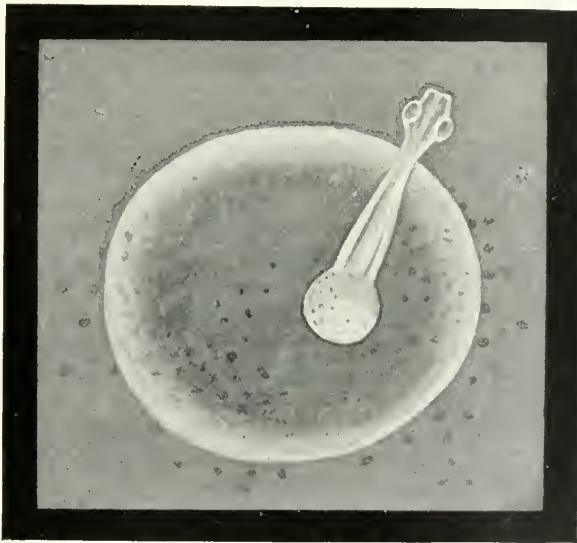


FIG. 257.—Cysticercus in the vitreous (Liebreich).

seem to resemble those described by Iwanoff and called by him fatty degeneration of the stroma and cells of the vitreous.

The ophthalmoscope furnishes a picture of numerous white, glistening spots very evenly distributed throughout the vitreous, and having slight motion when the eye is moved—not, however, an independent motion, but one seeming to depend upon the quivering or tremulousness of the normal vitreous when the eye is quickly moved in any particular direction. Iwanoff does not regard this condition as a pathologic change, but a quasi-physiologic state due to senile decay. The vision is slightly reduced, but not to an extent requiring special treatment, further than the correction of any existing error of refraction.

**Persistent Hyaloid Artery.**—The *hyaloid artery* (an extension of the central artery of the retina) during fetal life passes from the optic nerve-head forward across the vitreous body, sometimes terminating in the vitreous and sometimes extending as far forward as the posterior surface of the lens. It

occupies a canal (the *canal of Cloquet*), which, with the artery, shrivels up and disappears about the sixth month of gestation. (See page 24.)

In exceptional cases, however, it remains, and, according to De Beek, may be seen floating in the vitreous in one of the following forms: a filamentous strand attached to the disk, the free end floating in the vitreous; a strand attached to the lens, and the end floating in the vitreous; a strand attached to the disk, and a like strand to the posterior surface of the lens, each terminating in the vitreous; a strand passing across the vitreous and attached to the disk and the lens; a distinct vessel containing blood, passing entirely across the vitreous; and the canal of Cloquet, not containing any vessel.

The remains of this artery are also sometimes seen as irregular minute bodies on the surface of the disk, and its vestigial remains doubtless produce that variety of congenital cataract called posterior capsular cataract (page 389) when situated on the posterior surface of the lens. (Consult Figs. 137, 138 on pages 190, 191.)

# DISEASES OF THE RETINA.

BY LUCIEN HOWE, M. D.,

OF BUFFALO, N. Y.

**Congenital Peculiarities of the Retina.**—As it is often difficult to define the limit between health and disease, it becomes an important question to determine what should be considered a normal retina. Therefore attention is first directed to those congenital peculiarities which cannot be classed as pathological. These are usually described last in chapters on the retina, but some repetition and confusion are avoided if they are considered first.

Such variations from the normal type are to be seen (1) in the vicinity of the optic nerve; (2) in the retina; and (3) in the macula.

*First.*—Variations near the nerve are due to—

(a) *Insufficient pigment*, which should not be confused with the actual atrophy of the retina and choroid in the vicinity of the nerve. The latter diseased condition shows itself as a crescent more or less marked, or even as a complete white circle (see Fig. 136).

(b) *Excess of pigment* may be seen in brunettes, and sometimes amounts to a dark, well-marked ring of deposit about the nerve.

(c) *Absence or abundance of blood-vessels* at the edge of the nerve may simulate disease and yet be within normal limits.

(d) *Opaque nerve-fibers* may present an appearance which at first glance may be mistaken for neuro-retinitis. It is well to bear this in mind in connection with that disease (see also pages 189, 190, 194).

*Second.*—Variations in the retina are due to—

(a) *Insufficient Pigment.*—When of slight degree this gives rise to a peculiar appearance in which the vessels of the choroid simply become unusually prominent. When, however, pigment is lacking entirely, as in albinos, a network of vessels distributed over a pink or an absolutely white field is apparent.

(b) *Excess of Pigment.*—In this condition the fundus is not only dark and the vessels difficult to distinguish, but occasionally the pigment is unequally distributed, giving rise to a peculiar mottled appearance. In some of these cases the choroidal vessels are particularly prominent, manifesting themselves as red lines distributed over rather a dark field.

Any of the above variations from the usual type are easily recognized as physiological, unless the diminution or excess of pigment is confined to a certain part of the retina, when it may give to the fundus an appearance which is readily mistaken for an abnormal condition.

*Third.*—Variations in the macula.

In typically normal eyes nothing can be seen of the macula except the red reflex of the fundus, the area usually being darker than the rest of the background and uncrossed by retinal vessels. But there are variations from this which should be noticed. In blonds and in retinas having an unusually small amount of pigment the macula can often be distinguished as a light



spot on a darker field, its edges being well defined, or, again, as a dark area, the edges of which blend imperceptibly with the red of the retina near it. The latter is the more common form. In exceptional cases the macula is dark, and its edges are marked by a ring (macular reflex), the center being then light or almost white (foveal reflex) (see also page 188).

Small, white, glistening dots are occasionally found in the vicinity of the macula. These are known as "*Gunn's dots*." Sometimes they are quite numerous, but they do not interfere with perfect vision. They are to be taken into account in making a differential diagnosis in cases of commencing albuminuria.

A simple and easy plan of studying the diseases of the retina is to begin with disturbances of the circulation—*First*, when the supply of blood is diminished, as in anemia, or entirely shut off, as in embolism; and *second*, when the supply is simply increased, as in hyperemia, or increased with other signs of inflammation. This will lead to the consideration of the various forms of retinitis, after which will follow a description of degenerative changes.

**Anemia of the retina** means properly that the lack of blood is merely the local expression of a general condition, while *ischemia* indicates that the causes of the altered circulation are in the eye itself.

**Etiology.**—Retinal anemia occurs in ordinary syncope or from any cause—as, for example, vaso-motor spasm—which contracts the arteries of the brain or lessens the amount of blood sent there. Retinal anemia, with contracted arteries, may occur in migraine, and may be associated with hemianopic blindness.

**Symptoms.**—While very marked decrease or increase in the blood-supply of the retina can be distinctly recognized, it must be admitted that the slighter variations from the normal standard are not easily diagnosed. However, the contracted vessels, the lighter color of the retina, the unusual whiteness of the nerve, and the functional disturbances, if present, tend to establish the diagnosis.

**Treatment** should be directed to the removal of the cause producing the general anemia. As strychnin has long been used hypodermatically for a diminished supply of blood in the optic nerve, as in atrophy, so has it been suggested for the same reason in retinal anemia. Nitrite of amyl may be used to relieve spasm of the arteries of the retina. A method of treatment well worthy of trial is to arrange the position of the patient, for as long a time daily as can be borne comfortably, so that the head is lower than the rest of the body. The contracted or emptied vessels of the retina are filled by the force of gravity.

**Embolism of the Central Artery of the Retina.**—**Etiology.**—The most frequent cause of embolism is valvular disease of the heart, especially when complicated with fresh endocarditis. It also occurs with various forms of arteritis, with aneurysm of the aorta and carotid, with Bright's disease, and with pregnancy; occasionally it complicates chorea. It may occur at any period of life, and has been recorded from the fifteenth to the eightieth year. Simultaneous embolic plugging of the central artery in each eye has been described, but it is an exceedingly rare condition. It is more frequent on the left than on the right side, and has occurred more times in men than in women.

**Pathological Anatomy.**—In the earliest case observed with the ophthalmoscope (von Graefe) an opportunity was afforded to secure a post-mortem examination one and a half years later (Schweigger). Sections of

the eye showed that the central artery was completely blocked just behind the lamina cribrosa. The embolus may be granular in nature, or consist of a hyalin plug, or may be covered with layers of endothelium. Sometimes it only partially blocks the lumen of the vessel; at other times it completely occludes its caliber. Atrophic changes may be found in the retina, the optic nerve, and the choroid, according to the date of the examination after the embolus has occurred.

The clot does not always block the central artery itself, but may lodge in one of the branches of the main retinal artery, and there produce over a limited area the same symptoms, the same appearance, and the same pathological conditions which are found when the central artery is affected.

Re-establishment of the circulation may occur because the lumen of the blocked vessel again becomes free, and the presence of cilio-retinal vessels may be the means of preserving good acuity of central vision. According to Ward Holden, with single embolism of a branch of the central retinal artery there may be a field of irregular form which to a considerable extent is explainable by variations of the arterial distribution, and in cases where the lumen of an artery remains blocked there may be a collateral restoration of its circulation by anastomosing vessels.

**Symptoms.**—The patient may be entirely ignorant of the existing condition if the embolus occurs in one eye only, for there is no special pain nor other peculiarity following, which calls attention to the difficulty, except the loss of vision, which occurs with characteristic suddenness. In other cases, however, the subjective symptoms in the form of a species of aura are peculiar. There are scintillations before the eyes or dark rings appear. In a very typical case which the writer observed the patient remembered peculiar flashes which called her attention to the rapidly departing vision.

The ophthalmoscopic picture is quite characteristic, being that of an almost pure and well-marked *ischemia of the retina*. The arteries are small, and the corresponding veins considerably reduced in size, or they may reveal unequal distention, the terminal endings of both being to a great extent lost. Pressure from before backward causes a regular current to flow through the vessels, which consist of broken cylinders of blood separated by clear spaces, moving sluggishly along. In the veins, directly after the lodgement of the embolism, an *intermittent blood-stream* is often visible. The optic disk is blanched almost as it appears in atrophy, and the retina, especially in the neighborhood of the papilla and the macula, is of a whitish appearance (the so-called *fog-like edema*), in marked contrast with that of the other eye. A very characteristic feature of this disease is the color of the macula. The rest of the retina may appear of a normal color or even decidedly whitened, but the macula stands out in contrast with its surroundings as a clear *cherry-red spot* which attracts attention at the first glance. The reason for this peculiar color is by no means fully explained. The general conclusion, however, is that it is not entirely an extravasation, but is due partly to an engorgement of the choroidal vessels beneath the macula, and partly to the effect of contrast which this spot then presents to the neighboring retina (Loring). There are also changes in the pigment epithelium. In dark-skinned races the cherry spot may be replaced with a coal-black one. This macular appearance is more apt to arise in stoppage of the main trunk than when only a branch is plugged. Occasionally, if the embolus lodges in a branch of the main artery, it is visible to the ophthalmoscope as a small yellowish body, or it may be assumed to be present because at one point in the artery there is a swelling, while beyond it the vessel is obliterated or

greatly contracted. In the course of several weeks, in complete cases, the retinal edema subsides, the disk undergoes atrophy, and the vessels are converted into white lines.

The *subjective symptoms* are, in complete cases, sudden loss of vision, unless the presence of a *cilio-retinal vessel* permits the preservation of good acuity of sight, as reported by Wadsworth, and occasionally headache and giddiness. According to C. F. Clark,<sup>1</sup> the evidence is not sufficient to warrant the conclusion that true cilio-retinal vessels are the means of preserving the integrity of the papillo-macular region of the retina. In obstruction of a branch, vision may be very good, or, indeed, even normal. The *field of vision* depends upon the extent of the circulatory obstruction. If only a branch has been occluded, that portion of the retina which receives its blood-supply from this source will be paralyzed and the opposite area of the field darkened. Occasionally there is a central scotoma. The tension may be raised, lowered, or normal.

**Diagnosis.**—These cases may simulate anemia of the retina, because the condition of the heart produces some general anemia, but the history is usually sufficient to separate one disease from the other. While the ophthalmoscopic appearances already detailed indicate interruption of the retinal circulation, it is often difficult, and even impossible, to distinguish between thrombosis and embolism of the artery. Similar appearances may be produced by hemorrhage into the sheath of the optic nerve (see page 453).

**Prognosis.**—This depends upon the rapidity with which the collateral circulation is established, a greater or less tendency to this being apparent almost from the first. In complete embolism of the central artery the prognosis is most unfavorable.

**Treatment.**—Paracentesis has been tried in order to change the amount of blood-pressure, but in general more depends upon improving the condition which has caused the embolus than upon any attempts at local medication. Nitrite of amyl inhalations are recommended by Gifford, and massage of the eyeball, in the hope of dislodging the embolus, should be faithfully tried. This has been effected in some cases.

**Thrombosis of the Retinal Artery.**—Thrombosis may occur under the same conditions which are active in the production of embolism, and the thrombus may form either in the central artery itself or in one of its branches.

Ophthalmoscopically, it is difficult or impossible to distinguish between thrombosis and embolism. According to Priestley Smith, previous attacks of temporary blindness in the affected eye, a simultaneous attack of temporary blindness in the unaffected eye, giddiness, faintness, and headaches are apt to be associated with thrombosis, and not with embolism.

The *treatment* is the same as that recommended for embolism.

**Hyperemia of the Retina.**—By this term is understood an abnormal and equal increase in the amount of blood throughout the entire retina. Hyperemia of the larger blood-vessels is easily recognized. When, as is usual, this is accompanied by *capillary hyperemia*, the condition is indicated by a change in the color not only of the retina itself, but especially of the surface of the optic nerve, which becomes redder than normal. Should the hyperemia exist in a marked degree, the overflowing arteries have a tortuous appearance, such as would naturally be expected when an elastic vessel is filled beyond its normal capacity. Two forms of hyperemia are to be distinguished, the active and the passive.

1. *Active hyperemia* may be produced by a variety of causes. One of

<sup>1</sup> *Archives of Ophthalmology*, xxvi. 1897. pp. 395-404.



these, for example, is long-continued effort at accommodation, especially when made by artificial light or when the refractive condition of the eye necessitates an unusual amount of straining of the ciliary muscle. De Wecker has noticed that a solution of the tincture of opium dropped into the conjunctival sac will also produce a certain amount of active hyperemia. It is commonly present in eyes exposed to glare of light and heat—*e. g.* in puddlers. The same condition occurs in several of the inflammations of the eye, especially when the uvea is involved.

**Symptoms.**—These are more or less pronounced, varying from slight sensations of discomfort to considerable photophobia and lack of eye-endurance.

**Diagnosis.**—This is not so easily made as might be imagined. As the subjective symptoms, even if present at all, are usually by no means prominent, the diagnosis in a large proportion of cases must be determined by the ophthalmoscopic appearance. But it should be borne in mind that the blood-supply to the retina may seem to vary from the normal standard when in reality this is not the case. In some individuals the retinal vessels are much more abundant than in others, just as we find complexions of a florid type or with decided pallor. Particularly does the condition of the refraction change the apparent size of the vessels when examined by the ophthalmoscope. Again, a decided astigmatism may distort the vessels in different meridians. Indeed, the beginner with the ophthalmoscope must be careful not to fall into the common error of diagnosing a “retinal congestion” when, in reality, there is nothing of the kind present. Only a careful study of the case, with due regard to errors of refraction, will enable one in certain instances to decide as to the presence or absence of hyperemia of the retina.

2. *Passive Hyperemia.*—Any cause which interferes with the egress of blood from the eye may produce this condition; for example, in glaucoma, where, as a result of the pathological condition accompanying that disease, the veins are enlarged to a considerable degree, the finer branches are more numerous, and the larger trunks more tortuous, especially near the margin of the papilla. Another example is furnished by the condition known as “choked disk.” Stasis hyperemia is also present in mitral disease, emphysema, convulsive seizures, and, indeed, in any state which prevents the veins of the head and neck from emptying their contents into the venous channels of the chest.

**Symptoms.**—These are similar to those which occur in active hyperemia. The same care should be exercised in making the diagnosis, although in this form, mistakes are not so liable to occur as in active congestion.

The prognosis and treatment depend upon the causes.

Somewhat analogous to *congestion or hyperemia of the retina* is the condition known as *hyperesthesia of the retina*, or, to employ the term suggested by Jaeger and Loring, *irritation of the retina*.

Ophthalmoscopically, may be seen undue redness of the nerve-head, veiling of its nasal margins, and delicate edema of its surface. Often the entire fundus is ill defined, and the details of the background of the eye are imperfectly seen.

**Etiology.**—Cases of this character are caused by errors of refraction and anomalies of muscle-balance. They are often associated with chronic headache, neuralgia, and their subjects suffer from photophobia, blepharospasm, and marked asthenopia. In some instances there appears to be a distinct relation between retinal irritation and changes in the naso-pharynx, particularly those characterized by a hypersensitive mucous membrane and vaso-



paretic and infiltrated turbinals. Loring believes that retinal irritation may be a forerunner of organic optic-nerve disease.

**Anesthesia of the Retina** (*Neurasthenic Asthenopia*).—This condition is really a symptom of a complicated neurosis rather than a special disorder of the retina. Its phenomena have been specially studied by Wildbrand, who records the subjective symptoms as follows: Peculiar contraction of the field of vision, indicating retinal fatigue and the development of the so-called *counter-field* (see page 486); rapid disappearance from view of any object which is fixed; diminution of central vision; sudden attacks of obscuration of vision and processions of scotomas; visual hallucinations; lack of fixation of the optical memory-images; and marked asthenopia. The subjects of this affection are chiefly women, and often those afflicted with ovarian and uterine disease, hysteria, and chlorosis. Pure types are also seen in men, and are often connected with sexual derangements.

**Treatment.**—This must be directed toward the general condition, although any error of refraction should be corrected and the proper glasses worn constantly. It must be remembered that neither in this type of retinal affection nor in hyperesthesia of the retina are spectacles alone sufficient. A consideration of the etiological factors only will supply indications for the proper constitutional and local measures.

**Thrombosis of the retinal veins** has been observed as the result of syphilis and with heart-disease. Thrombosis of the central vein is sometimes seen with hemorrhagic retinitis, of which it may be the cause, and also in a few other conditions in which the walls of the veins have undergone some degeneration.

**Symptoms.**—As these lesions can be seen ophthalmoscopically, it is natural to expect with them certain symptoms more or less well marked. These are a scotoma of varying size, corresponding in extent and location to the part affected by the thrombus, and usually floating bodies in the vitreous (*hyalitis*), causing *muscæ volitantes*. Complete thrombosis of the central vessel causes great engorgement of the veins, interrupted venous circulation, strong venous pulse, streaked disk-margins, and numerous retinal hemorrhages.

The **diagnosis** is comparatively simple when the vitreous is sufficiently clear to enable the lesions to be recognized by the ophthalmoscope.

No local treatment is of any value, but potassium iodid, mercuric chlorid, and other alteratives may be given to encourage absorption of the effused blood.

*Telangiectasia of the retinal vessels, aneurysm of the central artery, and varicose veins of the retina* have also been observed, but they are so rare as to deserve only mention here. They show, in general, that while we have in hyperemia the first step toward a real inflammation, the vessels of the retina also undergo the same variations from the normal standard as occur in other parts of the body.

**Retinitis.**—Under this general term are included the various types of inflammation of the retina.

**Forms of Retinitis.**—These are not always properly described by the names given to them, nor is the term itself always exactly applied. Thus, it sometimes expresses a pathological condition—for instance, serous, parenchymatous, or suppurative retinitis; or it is used to denote the results or accompaniments of such inflammations—for example, hemorrhagic retinitis; or, again, it is employed to describe the cause—*e. g.* syphilitic or albuminuric retinitis. Again, retinitis pigmentosa and other names indicating inflammation

are given to retinal lesions which are not inflammations at all, in the true sense of the word. Therefore, it is desirable to keep in mind the three types of inflammation to which the retina is subject—namely, the *serous*, the *parenchymatous*, and the *purulent*.

These types, more or less modified, are met with in conjunction with certain systemic conditions: thus the serous type is often found with syphilis, while the parenchymatous type occurs principally with changes in the kidneys. The different retinal inflammations can best be understood, therefore, by considering these types first, and later their modifications, after which another group—the scleroses—of which the so-called retinitis pigmentosa is a type, will be described. That is, all forms of retinitis may be arranged into four groups:

I. *Simple or Serous Retinitis*.—Allied to this are—

- (a) Syphilitic retinitis;
- (b) Sympathetic retinitis;
- (c) Retinitis from concussion.

II. *Parenchymatous Retinitis*.—In this are included—

- (a) Albuminuric retinitis;
- (b) Diabetic retinitis;
- (c) Leukemic retinitis;
- (d) Syphilitic chorio-retinitis;
- (e) Hemorrhagic retinitis;
- (f) Macular retinitis.
  - α. Retinitis albescens;
  - β. Retinitis circinata;
  - γ. Solar retinitis;
  - δ. Symmetrical changes at the macula lutea.

III. *Embolie or Septic Retinitis*.

IV. *Retinal Sclerosis*.

- (a) Retinitis pigmentosa, typical form;
- (b) Retinitis pigmentosa, atypical form;
- (c) Retinitis proliferans.

**Serous Retinitis** (*Retinitis Simplex; Edema of the Retina; Peripapillary Retinitis*).—Retinal inflammation of slight degree, marked only by hyperemia and exudation, is known as *simple retinitis*. When, however, there is besides an alteration of the deeper tissues (hyperplasia), the term *parenchymatous* is used. It is evident that the two forms may merge into each other by imperceptible gradations under certain circumstances, and that a process which begins as simple retinitis may pass into the parenchymatous form. Practically, however, the first type or stage retains its own characteristics so constantly that it may be properly considered a distinct disease.

**Varieties**.—As the retinitis may vary according to the depth to which the layers are invaded, it may also vary in the extent superficially or in the secondary changes accompanying it. When the edema is limited to that region where the retina is the thickest—namely, about the edges of the optic nerve—the appearance presented is so peculiar as to warrant the name *peripapillary retinitis*.

*Diffuse retinitis* is more common. The edema, extending over the entire retina, veils to a greater or less extent the features of the fundus.

**Etiology**.—The causes to which simple retinitis has been ascribed are

manifest. Among these have been enumerated excessive use of the eyes under unfavorable conditions, refractive error, dazzling light, exposure to cold, chill, etc. In many cases, however, it is due to syphilis. It may be the initial change of other forms of retinitis presently to be described.

**Pathology.**—The term inflammation ordinarily is applied to nutritive disturbances accompanied by redness, swelling, heat, and pain; but it is necessary to modify this definition in accordance with the alterations to which this pathological process is subjected by the different structures of the body in which it occurs. Especially is this the case in retinitis. In the early stages of the inflammation a hyperemia, more or less well defined, is present. This corresponds to the redness which accompanies an inflammation elsewhere. As a result of the distention of the vessels there is naturally edema, with some infiltration of the leukocytes into the inner layers of the retina, particularly into the nerve-fiber and ganglionic layers, or even into the vitreous humor. Similar lesions would produce swelling if they occurred in other portions of the body. These two pathological changes constitute practically all which are present in pure, simple retinitis.

**Objective Signs.**—The ophthalmoscopic changes are as slight, proportionately, as are the pathological alterations. They are—

(1) *Edema of the retina.* The features of the retina can usually be distinguished, but they appear as if seen through a mist. The retina often has a somewhat grayish aspect, almost invariably the vitreous is more or less clouded by the infiltration, and the details of the retina are consequently indistinct.

(2) *The vessels, especially the veins, are altered.* They are more tortuous and have a greater number of branches than usual. They are distended at some points or disappear under the swollen retina at others. Sometimes the arteries appear reduced in size from compression.

(3) *Hemorrhages* are occasionally met with, but are not common with the serous variety of inflammation; nor, indeed, are any other of the more extensive alterations present which are found when the deeper layers of the retina are affected.

**Subjective Symptoms.**—(1) The first and most important symptom is a diminution in the acuity of central vision, often associated with greater or less contraction of the field. Occasionally, in the circumscribed variety of retinitis, only one spot is involved, perhaps near the equator, and then not only is it easily recognized because of the contrast which this area presents to the surrounding tissue, but an exact examination of the field shows a well-defined scotoma corresponding to the affected part.

(2) Distortion of vision due to the altered retina. The exudation into the retina changes the position of that membrane more or less, and, together with the unequal pressure upon the rods and cones, produces peculiar distortions of the retinal image. Thus, objects may appear larger than normal (*megalopsia*), or the patient may describe them as being distinctly smaller (*micropsia*), or, finally, they may be distorted in various ways (Loring). When the difficulty exists in both eyes it is not always easy to decide what the peculiarities are in each, unless one eye be covered or diplopia is produced with a prism.

(3) A symptom occasionally present in this type of retinitis is the ability to see better by imperfect illumination—for example, in the evening—than where the light is bright. This condition has been called by Arlt *nyctalopic retinitis*. Evidently, however, it is only a symptom.

(4) As there are no sensitive nerve-fibers in the retina, often a high

degree of inflammation passes without pain, imperfect and distorted vision being about the only symptoms which attract the attention of the patient.

**Diagnosis.**—This is easily made, especially in cases not far advanced, there being then no danger of confusing the serous with the parenchymatous form. The veiling of the fundus when the inflammation is *diffuse*, or the grayish patches when it is *circumscribed*, together with the changes in the vessels, or swelling of the retina, with the corresponding diminution of vision, furnish a characteristic picture.

**Prognosis.**—This is uncertain and depends somewhat upon the cause. It can never be safely foretold that a serous inflammation thus begun will not assume the parenchymatous form. When the inflammation is not present in a marked degree, or when it has existed for a comparatively short time, absorption is apt to take place; or when the serous inflammation is dependent upon syphilis the prognosis is more encouraging, inasmuch as this variety frequently yields readily to treatment.

**Treatment.**—Whenever the cause can be determined, it is of course necessary to combat that first. Where there is a distinct history of syphilis, or when the serous retinitis is apparently connected with any systemic disturbances, the plan to be pursued is plain enough; but, unfortunately, the causes are by no means always clear, and in those cases only local treatment remains. Usually much attention is given to protecting the eyes from bright light, colored glasses or even a dark room or a bandage being advised; but in this disease, as in others requiring confinement in a dark room, the patient should be given a certain amount of exercise daily in the open air. The artificial leech, cold applications, and, in general, an antiphlogistic form of treatment are advisable in inflammations of the sthenic type. Mydriatics are not usually mentioned in this connection, but it is undoubtedly the case that atropin often assists in keeping the eye entirely at rest, and, although the dilated pupil allows more light to enter the globe, the improvement following the use of atropin is too common to warrant its omission.

**Syphilitic Retinitis** (*Specific Retinitis*).—It is a question whether an inflammation of the retina occurs primarily as a result of syphilitic infection. Desmarres, among the French, and the English practitioners generally, are inclined to regard syphilis as commencing always in the choroid, and affecting the retina only secondarily. However this may be, a serous inflammation of the retina often results from syphilis.

In the **pathological anatomy** of this disease there is nothing sufficiently characteristic to distinguish it from serous retinitis due to other causes. Still, one peculiarity may be remarked—viz.: a tendency of the inflammation to be circumscribed instead of general. For this reason it is also known as *retinitis with exudative spots* (Galezowski), but these may exist at the same time with considerable general edema of the retina.

**Symptoms.**—The ophthalmoscopic picture is such as has been described under Serous Retinitis, varied only by the *local edemas* which are common in addition to the *diffuse exudation*. This, as before stated, obscures the whole fundus more or less, rendering indistinct the outline of the disk and the course of the arteries and veins, which are veiled by lines of grayish opacity. The papilla is discolored, and has been compared to a yellowish-red oval seen through a covering of fog (Plate 5, Fig. 1).

The *subjective symptoms* are also the same as those of simple retinitis. The "mist" before the eyes thickens slowly, and usually steadily. While there is no decided pain in the eyes, photophobia is sometimes present, and photopsies and scintillations are common. Indeed, some authors consider the



last-named symptoms as regular accompaniments of the serous form of syphilitic retinitis. Irregular and concentric contraction of the visual field, as well as various forms of scotomas, are commonly to be observed.

**Date of Occurrence.**—Diffuse syphilitic retinitis may occur in congenital and acquired syphilis. In the acquired form of the disease it appears from one to two years after infection, sometimes as early as the sixth month, and, according to Alexander, is found in about 8 per cent. of the patients. One eye alone may be affected, but usually the second eye is also involved.

**Diagnosis.**—There is no appearance or symptom diagnostic of syphilitic retinitis. The tendency to develop circumscribed spots of edema, in addition to the diffuse exudation, may perhaps point to syphilis, but a history of the case giving conclusive evidence of the general infection is the only testimony on which reliance can be placed.

**Prognosis.**—This is much more favorable than in cases of retinitis arising from other sources.

**Treatment** is of course governed by the cause; for, although the same precautions are to be taken locally as in serous retinitis, much depends upon the antisyphilitic remedies. Hirschberg insists that it is not safe to rely on potassium iodid, and that mercurials should always be given, for they probably have a beneficial effect upon such forms of inflammation, in addition to their specific action. The use of tonics is also desirable, and every effort should be made to improve the general condition of the patient.

**Central relapsing retinitis**, a rare form of syphilitic retinitis, appearing in the form of gray or yellow areas in the macula, or as numerous yellowish-white spots and pigment-dots, or as a diffuse opacity of this region, is a late manifestation of syphilis. Relapses are frequent.

**Sympathetic Retinitis.**—Before leaving this group of retinal inflammations mention should be made of that form which accompanies sympathetic iridocyclitis (Graefe). While the ophthalmoscopic appearances and symptoms of this variety are virtually the same as in other forms of serous retinitis, this is specially important as being sometimes one of the early manifestations of approaching sympathetic ophthalmitis. Its recognition furnishes indications as to the advisability of removing the eye first affected, should that question arise (see also page 348).

**Concussion of the Retina** (*Commotio Retinae*; *Edema of the Retina*).—This condition may follow injuries of almost any variety, but especially a blow on the eye from a cork, rubber ball, or other similar substance. It is characterized by slight retinal changes and more or less loss of vision.

The **pathology** of this condition has not been satisfactorily settled, for in some cases blindness results when the ophthalmoscope shows an almost normal retina, and in others very marked variations from the standard of health seem compatible with good vision. Whatever other effects may be produced by the injury, it is certain that after the blow—which is not necessarily directly on the eye—there often appear small points of edematous exudation in the retina, or these may coalesce, and the typical cloudy exudation seen in serous retinitis may cover a considerable area of the fundus.

Corresponding to this or extending beyond it is a *scotoma*, more or less well marked. Such an exudation can be seen best a day or two after the injury, but ordinarily it soon begins to absorb, and, though it may disappear entirely, the blindness, partial or total, may persist. Decided retino-choroiditis, the result of concussion, may occur. These cases are often of interest from a medico-legal point of view, and when malingering is suspected

the tests for detecting that must be made with unusual care. An important complication in these cases is the development of transitory astigmatism.

The treatment locally is similar to that for edema of the retina. Stress is laid on the good effect of long-continued mydriasis (see also page 364).

**Parenchymatous Retinitis** (*Retinitis Perivascularis*).—In the serous type of retinal inflammation, as already stated, hyperemia and edema are present, but little or no further structural change. When, however, there is hyperplasia, and when the deeper parts of the membrane become affected, the condition is generally called *parenchymatous* inflammation. It will be seen at once that in some respects this is like the type just mentioned, except that this process is more advanced.

**Etiology.**—The causes are sometimes easily traced, especially when dependent upon albuminuria, intracranial disorders, or certain general diseases, but at other times they are difficult to determine.

**Pathology.**—The same changes occur as in the serous variety—namely, hyperemia with edema, but the latter is frequently wanting, and there develops instead an infiltration of cells or metamorphosis of the connective tissue. This infiltration takes place, by preference, in the inner granular or in the intergranular layer (Arlt). At the same time alterations occur in the walls of the capillaries. It has not yet been clearly established which is cause and which is effect; and from the fact that the walls of the vessels so often undergo degeneration, this form of retinitis has also been called *retinitis perivascularis* (Iwanoff).

After these early stages there results—(1) an entire absorption of the inflammatory process; or (2) partial absorption with partial destruction (namely, *partial atrophy of the retina*); or (3) a *total atrophy*—*i. e.* the retinal elements pass into a form of cicatricial tissue, and other alterations go on in the nerve-tissues.

**Ophthalmoscopic Appearances.**—The vitreous being free from exudations, and edema usually being absent, the features of the fundus are distinct. The increased amount of blood causes the arteries to appear full, often tortuous, and the terminal branches extended, while the optic nerves take on a reddish hue. The veins give similar evidence of the hyperemia, and occasionally, as an accompaniment of such a distention of both arteries and veins, extravasations into adjacent tissues occur.

This is especially true in certain forms of retinitis of nephritic origin. In these cases the hemorrhages extend into neighboring parts of the retina as small reddish points. Where the vessel gives way through a considerable portion of its extent there results a linear extravasation. This form has been described as a separate kind of retinitis, called *hemorrhagic retinitis*. In fact, there is an endless variety in the position, form, and extent of these hemorrhages, so common in some types of retinitis.

**Subjective Symptoms.**—These are similar to those described in connection with serous retinitis. The same diminution of vision is always present, but in a much more marked degree. When the parenchymatous inflammation is general there may be total blindness, or, if it is circumscribed, there is a well-marked scotoma in the corresponding portion of the field.

Distortion of objects or similar visual disturbance is unusual, the retinal changes being too deep and extensive, but photopsies and scintillations are not uncommon. With this form of retinitis also there is no pain. Indeed, the advance of the disease is so entirely free from this symptom that when the inflammation affects only one eye the patient sometimes discovers the

blindness by chance, or often not until the same process in the other eye makes him aware of his condition.

**Diagnosis.**—A distinction between this and the serous form of retinitis is not difficult in typical cases, but there are intermediate stages in which it is unwise to decide with certainty. Indeed, it is possible to see the serous and parenchymatous type of inflammation present in the same retina at the same time.

**Prognosis.**—This is grave. Absorption does occur, and in certain instances normal vision returns, but this is very rare, except in the retinitis of pregnancy. In the large majority of cases the cell-infiltration is followed by connective-tissue changes, with subsequent atrophy, the vessels appearing later as whitish threads.

**Treatment.**—Locally this is the same as that already advised for serous retinitis. The general treatment depends on the systemic condition which is producing the disease.

**Nephritic retinitis** is a generic term including retinitis albuminurica and certain other forms of retinal changes accompanying diseases of the kidneys. These have been grouped under a single term, because they are the result of disease of the kidney, because the ophthalmoscopic appearances are similar and the pathological anatomy is in some respects identical. Diabetic retinitis is sometimes described under the same generic term, but inappropriately, as it is not the result of renal disease. For a clearer understanding of the subject it is better to consider each of these varieties in order.

**Albuminuric Retinitis** (*Retinitis Gravidarum*; *Renal Retinitis*; *Retinitis of Bright's Disease*).—This form of retinitis is characterized by imperfect vision, by definite ophthalmoscopic changes—among which those in the region of the macula are most noticeable—and by certain alterations in the structure of the membrane.

**Etiology.**—Even before Helmholtz gave us the ophthalmoscope, Bright, Landouzy, and others had called attention to the frequency with which so-called amaurosis accompanied albuminuria. It remained for later observers, however, to determine more exactly the dependence of one upon the other—a relationship which has been frequently and carefully studied.

If this disease is the result of albuminuria, the question naturally arises, Why do so few albuminuric patients complain of imperfect vision? The failure of vision usually escapes observation, because there is seldom or never any pain in the eyes, and, as the macula itself is often the last to be affected, the actual condition of the retina is neglected, attention being directed to other symptoms. But ophthalmoscopic examination of a large number of albuminuric patients, whether complaining of imperfect vision or not, indicates that the retina is affected in as many as one-fifth (Lécorché) or one-third of them (Galezowski). Indeed, it may happen, exceptionally, that the retinitis shows itself in a typical form before it is possible to detect albumin in the urine (Dixon, Abadie), as was illustrated also by a case reported by the writer.<sup>1</sup>

Although chronic granular kidney is the usual cause of albuminuric retinitis, it also occurs with large white kidney and lardaceous disease. But attention should be directed specially to the albuminuria of pregnancy as a very frequent and important etiological factor. The relation between the two is as uncertain in this variety of the disease as in the former, but without doubt a considerable proportion of pregnant women who have albuminuria suffer also from the form of retinitis under consideration. Moreover, it is well known that

<sup>1</sup> *Trans. Med. Soc. State of New York*, 1893.



patients afflicted in this way during one gestation are apt to have a recurrence of the same symptoms when pregnant again. The fact that the retinitis may result in partial or total loss of vision, which can last permanently, even though the cause be temporary, indicates the importance of this phase of the subject. It will be referred to again when the question of treatment is considered.

**Symptoms and Pathology.**—The pathology can be studied to best advantage by first noting the symptoms and the ophthalmoscopic changes upon which these depend. It should be remembered, however, that the process is essentially a parenchymatous inflammation. The increased vascularity to be described later tends to result in hemorrhages, and while edema is slight and the vitreous clear, there is hyperplasia in the deeper layers or fatty degeneration of cells into those portions. Even a sclerosis of the nerve-fibers may also occur in spots (Müller).

The only local symptom of which the patient complains is imperfect vision. Sometimes this begins gradually and increases slowly; sometimes the onset is sudden and the advance rapid. The amount of inconvenience does not correspond necessarily to the extent of the retinitis, but rather to the degree in which the macula lutea is involved. Sometimes only the macula itself remains intact, and the patients are surprised to find that, although the central vision is practically normal, they are otherwise blind. The impairment of vision, like the retinal changes, is usually about the same in each eye; but *unilateral albuminuric retinitis* is not a rarity. The lesions may, exceptionally, remain monolateral till death. More commonly a monolateral case is converted after a time into the ordinary bilateral variety.

The ophthalmoscopic appearances of retinitis albuminurica are—

(1) *Fatty deposits*, more or less numerous, in the posterior segment of the retina. These white or yellowish-white plaques are usually well-defined, although the edges shade off gradually into the natural color of the retina. They may be limited to the vicinity of the macula from which they radiate, or may cover most of the posterior pole of the eye, according to the extent to which the retina is involved. Sometimes these spots of exudation are exceedingly small, with edges so sharply defined as to look like minute white dots. In nearly every case of retinitis albuminurica a group of these dots can be seen more or less completely surrounding the macula. In that vicinity their arrangement and form are so characteristic as to present a picture quite diagnostic of this disease. In the macula itself there is often a white spot, and almost invariably radiating from that point are numerous thin dashes of nearly glistening white which stream off in different directions, this appearance being due to the arrangement of retinal fibers (Schweigger). The lesion is sufficiently peculiar to be easily recognized when once seen (Plate 5, Fig. II.). If the average physician appreciated how readily this picture of retinitis could be detected, it is probable that the ophthalmoscope would be used much more frequently. Such spots about the macula may persist long after every other trace of the disease has subsided. This is especially the case in the albuminuric retinitis of pregnancy.

(2) The *retinal hemorrhages* which accompany albuminuric retinitis are peculiar. They are linear and flame-shaped, and they extend along the arteries, which are perhaps obliterated in parts, the extravasations being due primarily to changes in the walls of the vessels. Round, dotted, and sheet-like hemorrhages may also occur.

(3) Next to the alterations in the retina itself, those which involve the optic nerve should be mentioned. As would naturally be inferred, the edges



of the nerve become indistinct; it is often swollen, pushed into the vitreous, apparently, or streaked with diverging vessels; in a word, it presents the picture of *neuritis* or *papillitis*.

The foregoing is a description of a typical case, though of course each stage of its development can seldom be seen. Many variations occur. The disease may be characterized by small white spots, associated with comparatively inconspicuous hemorrhages in the fiber-layer—the so-called *degenerative* type; or it may manifest itself as a violent *neuro-retinitis*, with extensive hemorrhagic extravasations—the so-called *inflammatory* type. Sometimes comparatively small dots in the macula and single small hemorrhages may be the signs of renal retinitis.

**Diagnosis.**—This is not difficult in typical cases. To recapitulate, the chief signs are—(1) Imperfect vision in both eyes, either central, or with contracted field, or with scotoma. (2) Fatty deposits in the retina, especially in the vicinity of the macula. (3) Retinal hemorrhages, striated in form. (4) Secondary neuritis.

**Prognosis.**—This depends upon the variety and extent of the lesion in the kidney. It is comparatively good when the amount of albumin is slight or variable, as occurs in the milder forms of typical Bright's disease or frequently in the last stages of pregnancy.<sup>1</sup> The question becomes more serious, however, when the renal changes are extensive. Then the retina becomes more and more involved as the kidneys become disorganized, and the slowly but steadily increasing darkness foretells the fatal end. While the albuminuric retinitis of pregnancy usually ends with gestation or soon after, the prognosis in certain instances is grave in the extreme, for with vision greatly impaired, or perhaps lost, the patient may still live on for years.

**Treatment.**—Locally, there is little or nothing to be done. It is well to protect the eyes from bright light by means of colored glasses, and to abstain from prolonged efforts at accommodation, but with these instructions to the patient the therapy of the ophthalmologist ends. After that he may watch with interest the progress of the retinitis; he may prescribe iron, alone or with bichlorid of mercury, advise steam baths, etc.; but the important part of the treatment belongs rather to the province of the physician or, in certain cases, to the obstetrician.

When this retinitis occurs in a pregnant woman another and very important question arises; that is, whether premature labor or even abortion may not be induced if by that means it is probable that the vision, and perhaps the life, of the patient can be saved. In the space here available it is impossible to give even the principal arguments for or against such a procedure. Suffice it to say that in certain rare instances this procedure is permissible when the complaint or relapse appears in the earlier months, or when the history of former pregnancies shows a tendency to severe attacks of albuminuric retinitis.

<sup>1</sup> The prognosis, so far as life is concerned, is always grave in renal retinitis, cases occurring with pregnancy being excepted. The very presence of retinal lesions indicates either serious renal disease or decided general arterio-sclerosis, which is its constant associate.

The following statistics bear upon the duration of life after the development of albuminuric retinitis: In C. S. Bull's examination of 103 cases, 57, or more than 50 per cent., died within the first year; exceptionally, cases lived five or even seven years after the retinal disease had appeared. According to Possaner, patients in good social position and hygienic surroundings succumb less rapidly than those who are not so favorably placed.

E. O. Bell's statistics, gathered from various sources, are as follows: *Cases in private practice*, 155. Of these 62 per cent. died within one year, 85 per cent. in two years, and 14 per cent. lived more than two years. *Cases in hospital practice*, 75. Of these 85 per cent. died within one year, 93 per cent. within two years, and 6 per cent. lived for more than two years.

**Diabetic Retinitis.**—Another variety of retinitis is that known as *retinitis diabetica* or *glycosuric retinitis*. In the typical form it occurs, as a rule, only with *diabetes mellitus*, but it has also been known to be caused by *diabetes insipidus* (Bowman, Bader, Hansell). It occurs late in the disease, when other serious complications may be present—*c. g.* gangrene.

**Pathology.**—This is not well understood. As the vessels are probably affected primarily in all these forms of retinitis by a form of perivasculitis, this produces, directly or indirectly, most of the changes in the retina which characterize the disease. The *pathological anatomy*, as shown by the few sections thus far made, does not differ greatly from that of albuminuric retinitis. There are similar deposits of fatty degeneration, similarly situated with respect to the layers of the retina, but they are in general small, the edges are well marked, and especially is it to be noted that they are not grouped about the macula in the manner so distinctive of albuminuric retinitis. As for hemorrhages, these are small, if existing at all.<sup>1</sup>

The secondary neuritis is either lacking or atrophy begins very early, the latter condition being apparently a feature of the pathological picture.

**Symptoms.**—These are similar to those of albuminuric retinitis—*viz.* imperfect central vision with contraction of the field—and the ophthalmoscopic appearances also resemble those of the latter disease very greatly; indeed, they are in many respects identical, except that the hemorrhages are less in size, and, as before remarked, there are few or none of the peculiar white radiating spots about the macula.

**Diagnosis and Prognosis.**—The appearances above mentioned may be sufficient to render it possible to separate this from other varieties of nephritic retinitis, irrespective of tests for sugar. The *prognosis* is grave.

**Treatment.**—As diabetes is counted among diseases difficult to treat successfully, reliance must be placed on proper diet. Nothing can be accomplished by local treatment. The general precautions mentioned under serous or parenchymatous retinitis should be observed.

**Leukemic retinitis** belongs to this group of inflammations, and is almost exclusively caused by splenic leukocythemia. Both eyes are affected. Leukocytes not only invade every portion of the retinal tissue, but opaque deposits, sometimes fringed with a reddish border, are seen extending from the macula to the equator. These have been found by Leber to consist almost entirely of lymph corpuscles.

The color of the vessels in the retina is also peculiar. The arteries are small, pink, or even yellowish, the veins large, broad, and rose-red, and the retinal tissue pale yellow. Considerable swelling of the papilla is usually present, and occasionally spots develop near the macula similar to those found in albuminuric retinitis. The symptoms are those of parenchymatous retinitis.

**Diagnosis** is usually easy; exceptionally, however, there is difficulty in distinguishing this disease from albuminuric retinitis, but a count of the blood-corpuscles of course determines the cause. In place of the typical appearances there may be a diffuse opacity of the retina.

There is no **treatment** except to protect the eyes and improve the general condition, if possible.

**Syphilitic Chorio-retinitis.**—Syphilis, as before stated, tends to show itself first in the uvea, and the retina is probably affected later; or else inflammation develops simultaneously in the retina and choroid. Indeed,

<sup>1</sup> According to Hirschberg, there is an exudative as well as a hemorrhagic form.

sometimes in the same person a serous retinitis may be found in one eye and a chorio-retinitis in the other, or the two diseases may exist in the same eye. It occurs from six months to two years after primary infection.

The **pathological anatomy** combines the features of perhaps the serous, or always of the parenchymatous retinitis, or of both, with those of a choroïditiis.

**Symptoms.**—In pure chorio-retinitis of certain types the vitreous is clear, and the usual absence of marked edema renders the details of the retina distinct. In this class of cases retinal hyperemia, and often hemorrhages, are found, or a neuro-retinitis. But the most characteristic appearances are *spots of exudation* of various size and irregularly distributed. When these first appear they may be like spots of edema—whitish or elevated; later more or less complete atrophy of the retina takes place, and there results a dark or black area showing the choroid with corresponding distinctness. These spots, when small, are similar to those seen in retinitis pigmentosa. If the choroid also undergoes atrophy, white spots (the sclerotic), fringed with the black cells of the choroid, are visible. Should an artery or vein happen to cross such a spot, the vessel can be easily distinguished in the early stage, but later its outlines become indistinct; it is cut off, and atrophies there with the surrounding tissue (Plate 5, Fig. III.).

In other varieties of syphilitic chorio-retinitis in the early stages there is diffuse punctate opacity (*hyalitis punctata*) of the vitreous, especially in its posterior layers, and marked edema of the peripapillary retinal layer. Occasionally the iris and posterior layers of the cornea participate in the inflammation. Later the ophthalmoscopic changes are similar to those described in the preceding paragraph (see also page 353).

The *subjective symptoms* are analogous to those of other types of retinitis—lessening of central vision, contraction of the visual field, scotomas, diminished light-sense, and sometimes night-blindness. Photopsies, micropsia, and megalopsia are present.

**Treatment.**—This consists in the use of mercurials internally or by inunction, and the administration of potassium iodid. The eyes should be protected, and occasionally the artificial leech is advisable.

**Hemorrhagic Retinitis** is often described as a separate disease, but really it is only a form occasionally assumed by inflammations of the serous type, but most frequently by those of the parenchymatous type. For the latter reason it is mentioned in this connection. Again, variously shaped hemorrhages may appear in the retina and occasion sufficient irritation in surrounding fibers to create a retinitis.

**Etiology.**—The hemorrhages may be dependent upon syphilis, and in that case the walls of the vessels are altered (endarteritis, formation of thrombi), so that the hemorrhages, often small and fine, stream off, as it were, in irregular lines from the region of the nerve.

Most frequently, however, the hemorrhages are found with nephritic retinitis and with other types of retinitis dependent upon constitutional diseases. Then they are rather linear in form, but often large and irregularly distributed. Hemorrhagic retinitis may also accompany cardiac disease, general arterial sclerosis, suppressed menstruation, and the climacteric.

**Hemorrhages into the retina** without signs of retinitis (*apoplexy of the retina*) may be the result of senile changes in the walls of the vessels. Then the extravasations are apt to be large, irregular, and to appear even from the first, of a darker hue than that otherwise seen. The region of the macula is liable to be the seat of such extravasations as the arrangement of



PLATE 5

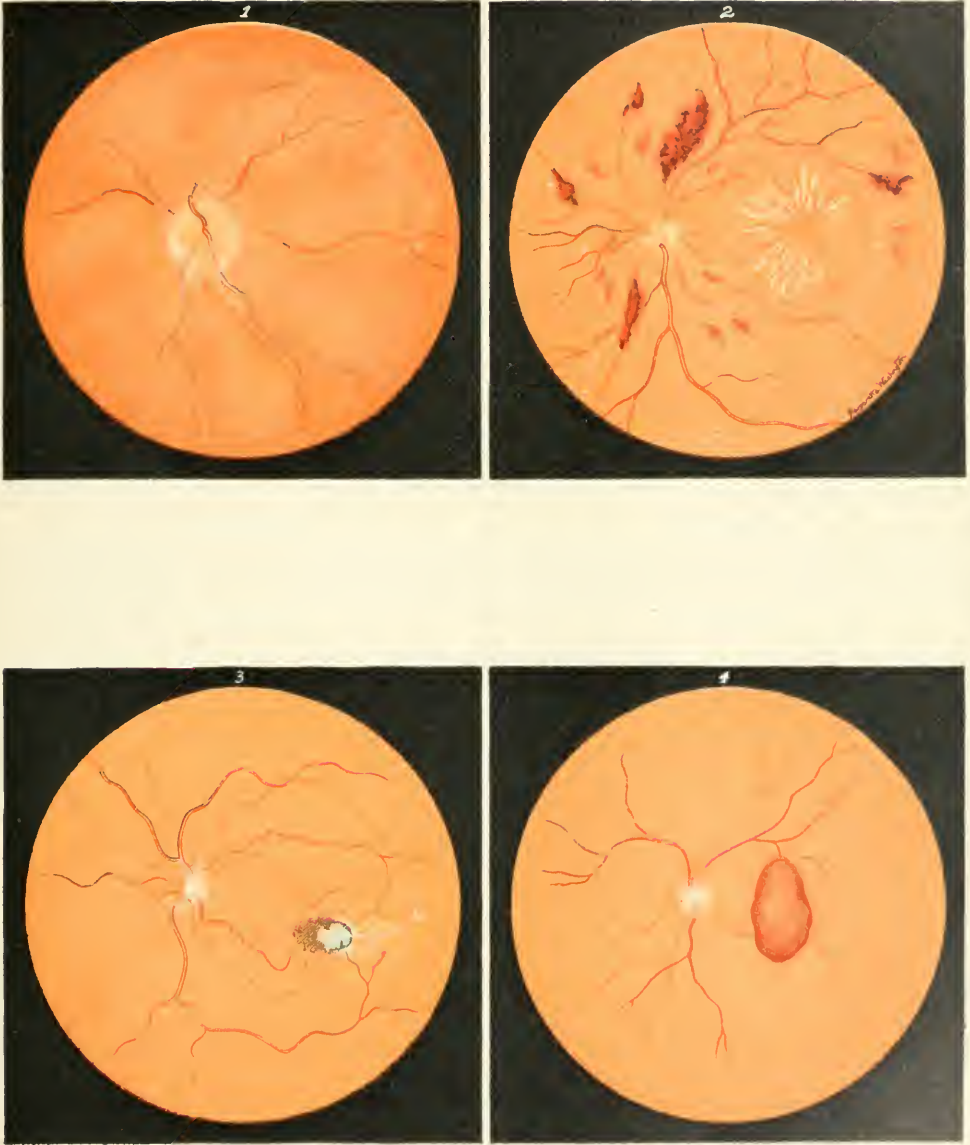


FIG. I.—Syphilitic retinitis (serous type).

FIG. II.—Albuminuric retinitis (parenchymatous type).

FIG. III.—Syphilitic chorioretinitis, late stage, following hemorrhagic retinochoroiditis (de Schweinitz).

FIG. IV.—Subhyaloid hemorrhage in the macular region.





the fibers in this locality predisposes to them. When they occur there they produce an irregular blotch or oval, usually with the longer diameter vertical, and a corresponding central scotoma. Hemorrhages of large dimensions and drop-like form usually mean an extravasation between the internal limiting membrane of the retina and the hyaloid membrane of the vitreous. Recent investigations by J. Herbert Fisher indicate that the blood is poured out from a retinal vessel—probably a minute artery—and detaches the internal limiting membrane from the retinal layers, accumulating in the space thus formed. These are the so-called *subhyaloid* hemorrhages, which occur at the yellow spot more than at other parts of the fundus (Plate 5, Fig. IV.).

Although many of the causes of retinal hemorrhage have been enumerated, a summary based upon Dimmer's classification may be added:

(a) Hemorrhages caused by changes in the composition of the blood and the tissues of the blood-vessel walls: Pyemia, septicemia, ulcerating endocarditis; diseases of the liver, spleen, kidney, and atheroma of the vessels; loss of blood (menorrhagia, hematemesis), anemia (simple and pernicious), hemophilia, purpura, and scurvy; diabetes and gout; malaria and recurrent fever.

(b) Hemorrhages caused by disturbances in the circulation: Hypertrophy of the heart and stenosis of the valves; thrombosis of the central vein of the retina and embolism of the central artery; suffocation, compression of the carotid, hemorrhages in the newly-born; and menstrual disturbances.

(c) Hemorrhages caused by sudden reduction of the intraocular tension—*e. g.* after iridectomy in glaucoma and by traumatism: Among the latter may be classed retinal hemorrhages after large cutaneous burns.

**Pathology.**—A *perivasculitis* or fatty degeneration of the walls of the retinal vessel, produced by the general or local disturbance, permits rupture of the artery or vein and consequent extravasation. Sometimes the hemorrhage is caused by diapedesis of blood-corpuscles. In some cases the hemorrhages are superficial, and leave the retina healthy, but in other instances atrophy results and a scotoma permanently marks the spot. Hemorrhages may take place in any layer of the retina, and by preference follow the larger blood-vessels. Sometimes they burst through the limiting membrane and pass into the vitreous. The macula, as before stated, is a favorite spot for these lesions. With the hemorrhages may be the pathological changes incident to the various types of serous and parenchymatous retinitis.

**Prognosis.**—At times, as already noted, superficial retinal hemorrhages are absorbed without leaving permanent scars; but if the macula is attacked, the visual disturbance is apt to be severe and lasting. Not only in this sense is the prognosis unfavorable, but the retinal hemorrhage, in most instances a sign of serious constitutional disturbance, may be the forerunner of extravasations in vital centers. Secondary changes in the optic nerve may result; sometimes glaucoma is a consequence (see page 384).

**Treatment.**—This should be directed toward removing the cause whenever possible to determine it. Internally, if not otherwise contraindicated, iodid of potassium may be given, ergot, small doses of pilocarpin, and bichlorid of mercury, according to various indications.

**Macular retinitis** is a term which, though often used for only one form of retinal inflammation occurring in the macula lutea, is really more general in its application, and may include several types of inflammatory retinal change specially located in this region. The details of these alterations are not yet clearly understood, and consequently they cannot be separated from each

other, neither by their ophthalmoscopic features nor by what we know thus far of their pathology; for it will be remembered that the appearances of the macula lutea vary considerably within normal limits.

Mention has already been made of the so-called "Gunn's dots," and these are ordinarily considered as non-pathological variations of the macula, for the reason that normal vision is found when they exist. Very nearly allied to them we have

**Retinitis Punctata Albescens** (*Central Punctate Retinitis*).—This affection is classed as a pathological condition, not so much because it differs materially in appearance from the Gunn's dots, but because central vision is more or less impaired. Fuchs and Liebrecht call attention to the similarity which this disease may bear to retinitis pigmentosa, in so far that it may occur in children, affecting several members of the same family, and, moreover, in children of blood-relations. Occasionally there are night-blindness and contraction of the visual field. Other cases have been reported in middle-aged patients with unchanged peripheral fields.

The most prominent feature is a group of fine, shining dots in the vicinity of the macula, often extending toward the optic nerve. Sometimes the dots are present in great numbers. A central scotoma, more or less marked, can be found, though often exact measurements are necessary to determine it; the peripheral field is unaffected. Sometimes vitreous hemorrhages occur.

Nieden and Landesberg think the spots can be made to disappear by the administration of potassium iodid and mercury, but the real effect of any treatment is uncertain.

**Retinitis circinata** is a term recently used by Fuchs to describe an appearance of the macula somewhat similar to that found in albuminuric retinitis. A yellowish-gray opacity is found in the macular region, surrounded at some distance by a zone of white spots or larger white patches. It is probable that this is not an inflammatory process, and that it is due to hemorrhages taking place in this locality. Some writers regard these points only as accompaniments of albuminuric retinitis (Spicer Holmes), but in a typical case recently described by Hartridge no albumin could be found.

**Solar Retinitis.**—Since the sight-purple in the retina was discovered by Boll, what before appeared a mysterious action of the light upon the retina is better understood. When an excessive amount of light enters the eye for a considerable time the sight-purple is destroyed to such an extent that it is not renewed either promptly or entirely. These changes in the retina when slight are not visible with the ophthalmoscope. Their effect is shown by considerable loss of central vision, though this is not necessarily complete, and by more or less limitation of the visual fields.

When, however, the crystalline lens has focussed the rays from a strong light, with the accompanying heat, upon the retina—as, for example, when an eye has been directed toward the sun—the changes produced in the yellow spot are not only more lasting, but they can often be seen with the ophthalmoscope. This has occurred particularly during observations of an eclipse of the sun, or the effect of such strong light has been shown by experiments on animals. A distinct exudation in the form of small spots of retino-choroiditis can be seen in the vicinity of the macula, and, although these appearances gradually subside, a central scotoma may persist, which indicates that the alterations in the retina were extensive.

The pathological changes are not clearly understood, but they are probably more nearly allied to the parenchymatous type of inflammation than to any other.

No treatment has been found of value in even lessening the size of the scotoma, although the protection and rest of the eye are indicated.

**Symmetrical Changes at the Macula Lutea in Infancy.**—This peculiar and rare condition was first described by Waren Tay, the clinical appearance being in every way similar to that which exists in cases of embolism of the central artery. The cherry-red color of the macula, in the center of a grayish-white zone about the size of the papilla, is here, as in embolism, a very marked feature of the ophthalmoscopic picture.

The condition of the patient is always peculiar, the mental and physical condition being decidedly below the normal. It is not certain what gives rise to this appearance of the retina, although the changes are probably in the deeper layers, and examinations after death show a degeneration of the spinal cord and the pyramidal cells of the cortex. The disease is always fatal, death occurring in from one to two years. In most of the cases reported the children were of Hebrew parentage.<sup>1</sup>

**Suppurative Retinitis** (*Purulent Retinitis; Embolic Retinitis*).—This usually occurs in connection with severe inflammation of the choroid, but in rare instances the process can be noticed beginning in the retina before the vitreous has become cloudy.

**Etiology.**—It may be caused by injury (*c. g.* foreign body), but the typical forms are due to cerebro-spinal meningitis or to septic or puerperal conditions. It is also known to exist with a gouty or rheumatic diathesis. In some cases it is not easy to understand how infection occurs; but it is also beyond question that bacteria may be transported from other parts of the body into the circulation, and, finding lodgement in the retina, give rise to a purulent inflammation.

**Symptoms.**—It may happen that imperfect vision first attracts the attention of the patient, but ordinarily the iris or choroid has previously become involved, giving rise to ciliary injection, pain, etc., the decrease in the field of vision or in the more important central vision resulting from the general inflammation. The disease is often limited to one eye. An ophthalmoscopic examination shows changes in the retina only in the early stages. These are exudations and hemorrhages which usually extend into the vitreous, the latter soon becoming so turbid as to obscure the details of the fundus.

The diagnosis is easily made on account of the acute symptoms, or when these are absent the appearance of the fundus is sufficiently characteristic.

The prognosis is extremely unfavorable. After suppurative retinitis is well established cure is impossible. Occasionally the more acute symptoms will subside, but the retina is always left thickened, more or less detached, and shrinks finally into a band of connective tissue.

**Treatment.**—This is similar to that employed for an iritis or an irido-choroiditis. It is antiphlogistic. Atropin is of undoubted benefit in solutions strong enough and used often enough to keep the pupil dilated. Protection of the eye from light gives comfort, and the use of cold applications is necessary. When it is possible to reduce the temperature of the globe, it is probable that the development of the microbes is either temporarily or permanently arrested. In making cold applications to the eye they should be used only for a few minutes at a time, and care should be taken that the cloth or gutta-percha bag or coil is not kept on the globe long enough to become warm.

Attempts have been made recently to carry out the principles of anti-

<sup>1</sup> For a summary of the literature of this unusual disease consult an article by Koller in the *Transactions of the American Ophthalmological Society*, 1896, vol. vii., Part iii., p. 661.



sepsis in the treatment of these suppurative conditions. We know that sublimate solutions may be injected under the conjunctiva with but little inconvenience, and efforts have been made to extend the same plan of treatment to inflammation of the choroid or retina. Thus far, the method has met with indifferent success, but it is probable that *intraocular injections*, in some form, will prove of value, and, theoretically, they give promise of a brilliant future (see also page 400).

#### RETINAL SCLEROSES.

Thus far, the forms of retinitis which are more or less of an inflammatory nature have been considered. In addition to these, however, there are pathological changes which take place in the retina, not associated with any of the cardinal signs of inflammation, but which can be recognized by the ophthalmoscope, and which are characterized by certain symptoms. They are usually described as forms of retinitis, although it is a question whether that term should be applied to them. It is therefore better to class them together as forms of *retinal sclerosis*. In this group we have *retinitis pigmentosa* of the typical variety and of the variety with little or no pigment, and with these may also be classed the so-called *retinitis proliferans*.

**Pigmented Sclerosis of the Retina** (*Retinitis Pigmentosa; Pigmentary Degeneration of the Retina; Pigmented Retina and Choroiditis*.—The term *retinitis pigmentosa* is usually applied to an affection characterized by deposits of pigment in the retina of more or less peculiar form and location, the appearance being accompanied by certain definite symptoms.

As this term is ordinarily used, without qualification, it probably includes two and perhaps three diseases. The study of a large number of these cases shows that the retinas vary much from each other, and also that, while there is a certain type of symptoms to be expected, these are by no means always constantly present. As for the pigment, this not only varies in form and in the abundance with which it is found, but in some cases, where the subjective symptoms are particularly well marked, the *pigmentation is absent* entirely. In defining retinitis pigmentosa, therefore, we must consider that this is simply the name of a group of pathological processes nearly allied to each other, the exact nature of which is still unknown.

**Etiology.**—The etiology of the disease is also obscure. It was formerly considered that *cousanguinity* was the most important element in its production, and the evidence undoubtedly shows that it is a factor in the causation of certain varieties. But it is probable that the importance of this has been overestimated, while that of hereditary syphilis and some other conditions has been overlooked. It is markedly hereditary. The affection has been found among deaf-mutes, idiots, and epileptics. The disease is either congenital or begins in childhood.

**Pathology.**—In considering the pathology of retinitis pigmentosa it is proper to describe the morbid process which goes on in a typical case, but it is equally necessary to remember that this process is liable to many variations. It consists, in general—(1) Of a proliferation of the connective-tissue cells which form part of the supporting structure of the retina; (2) a sclerosis in the walls of the vessels, and consequently a contraction of their diameters; (3) atrophy of the nerve-elements, with the destruction of the rods and cones; (4) usually pigmentary degeneration, taking on certain shapes which will be referred to later.

**Symptoms.**—The symptoms and the ophthalmoscopic appearances of retinitis pigmentosa are—

(a) *Night-blindness.*—This symptom is the one which ordinarily first attracts attention to the disease, although it is seldom noticeable until the ophthalmoscope shows changes in the retina already well advanced.

(b) *Diminution of the Central Vision.*—This is almost invariably present, although occasionally good visual acuity remains for a long time. Sometimes

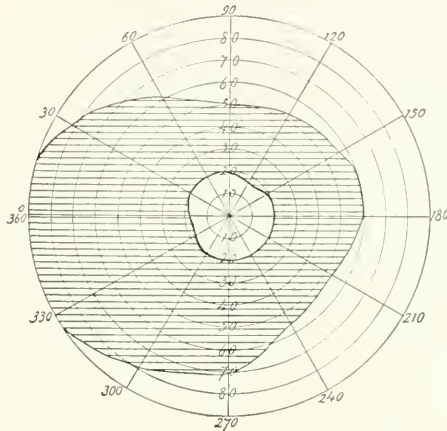


FIG. 258.—Visual field in retinitis pigmentosa.

it is associated with a true myopia, but more frequently the myopia is only apparent; for the patient approaches close to objects in order to obtain as large a retinal image as possible.

(c) *Contraction of the Visual Field.*—In typical cases this contraction is peculiar, because the concentric restriction occurs with almost perfect regu-

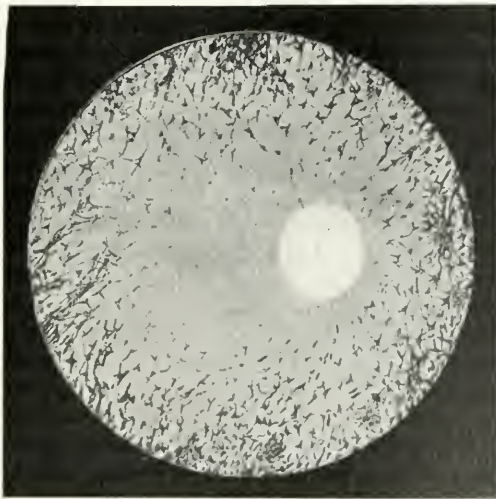


FIG. 259.—Pigmentary degeneration of the retina (Jaeger).

larity (Fig. 258). The contraction may be extreme, only a small central area of the field remaining. It is, however, liable to many variations.

(d) *Occasional Color-blindness.*—Failure to recognize red and green is the usual variety of this defect.

*Ophthalmoscopic examination* reveals the pigment, especially along the

lines of the vessels, and always more abundant in the periphery than near the center of the retina. The temporal side of the fundus is generally more affected than the nasal side. The pigment-masses assume an appearance resembling bone-corpuscles, and by the frequent union of their processes simulate the Haversian canals. This results in a picture so peculiar as to be easily recognized when once it has been seen (Fig. 259).

The papilla is usually yellowish-gray in color, with only slight mixing of red, and, as Leber has noticed, it sometimes has a glistening, tendon-like whiteness, such as is seen in extraocular atrophy. The lamina cribrosa is also more or less covered, and the whole papilla is, in general, smaller than is ordinarily the rule. The vessels are greatly contracted and their number is diminished. Often their walls contain white patches or are edged with white lines. The general fundus is frequently wainscotted on account of the absorption of the retinal pigmented epithelium. Posterior polar cataract may be a complication. Opacities in the vitreous are rare.

**Diagnosis.**—This is usually easy. The symptom of myopia might lead one to suspect this defect of vision at first, but in the typical forms it is only necessary to examine the periphery of the retina, when the peculiar star-like pigment-dots which characterize the disease become apparent. The diagnosis is further confirmed by the presence of the other symptoms detailed, especially the night-blindness. The disease is distinguished from disseminated choroiditis by the difference in the pigmentation. There is some resemblance between this affection and certain types of syphilitic retino-choroiditis; but in the latter the pigment-spots are not of characteristic form, they do not follow the blood-vessels, and vitreous opacities are usually present. Pigmentary degeneration of the retina is always bilateral.

**Prognosis.**—The disease invariably progresses from bad to worse. In certain cases it remains at an apparent standstill for many years, but gradually new spots appear, nearer and nearer the center of the retina and associated with a corresponding contraction in the field. The night-blindness becomes more annoying, and by the time middle life is reached or old age approaches a large proportion of the sufferers cannot find their way about without assistance.

**Treatment.**—Thus far, this has been equally unsuccessful in all forms. It is true that the subcutaneous injection of strychnin seems to retard the disease in some cases, and reports of the good effect of electricity, in the form of galvanism, have appeared, but, nevertheless, the treatment may be summed up by saying there is none thus far to be relied upon.

**Non-pigmented Sclerosis of the Retina** (*Retinitis Pigmentosa Atypica; Pigmented Retinitis without Characteristic Pigment*).—This form has been referred to when considering the typical disease, and the differences between the varieties have been noticed. While it may occur in extreme cases, as before stated, that all the subjective symptoms of retinitis pigmentosa are present, with no pigment, so also are there various degrees between these two extremes in which the ophthalmoscopic picture agrees more or less completely with what might be expected from the symptoms.

The *pathological process* in these atypical forms is not difficult to understand. The disease apparently passes through three of the stages described when considering the usual form, but the last is omitted—little or no pigmentary degeneration takes place. This is the only essential difference in the two forms, the clinical history, course, and prognosis being the same.<sup>1</sup>

<sup>1</sup> Gould (*Annals of Ophthalmology*, vi., 1897) thinks these cases, which may be designated non-pigmented retinal atrophy, are more numerous than is suspected. In his paper the literature is reviewed.

Other *atypical varieties* have been described: massing of the pigment in the macular region and corresponding central scotoma; irregular distribution of the pigment, associated with clear, shining spots lying beneath the vessels; and pigment degeneration accompanied with broad peripheral zones of choroidal atrophy. In rare instances the disease is complicated with chronic glaucoma.

**Retinitis Proliferans.**—This disease, like retinitis pigmentosa, is not a true inflammation of the retina, but has been considered by Manz to represent a proliferation of the connective tissue of that membrane. Indeed, there is a proliferation of Müller's fibers and a formation of new connective tissue among them. It presents itself as feathery, bluish-white expansions of tissue, often extending from the retina into the vitreous. These bands may occur in any portion of the fundus, and may follow the course of the vessels, but they are usually situated near the optic nerve, and bend about it in more or less concentric curves (Denig). New-formed blood-vessels occasionally lie above the masses. Vision is usually seriously disturbed.

The cause of the affection is not well known; syphilis and traumatism are etiological factors. Leber attributes the formation of these masses to repeated hemorrhages in the vitreous or retina. As a complicating circumstance there may be detachment of the retina. The ophthalmoscopic appearance is striking. In one case of retinitis albuminurica which the writer has observed these bands of connective tissue almost encircled the entrance of the nerve, and, curving thence toward the macula, presented a highly

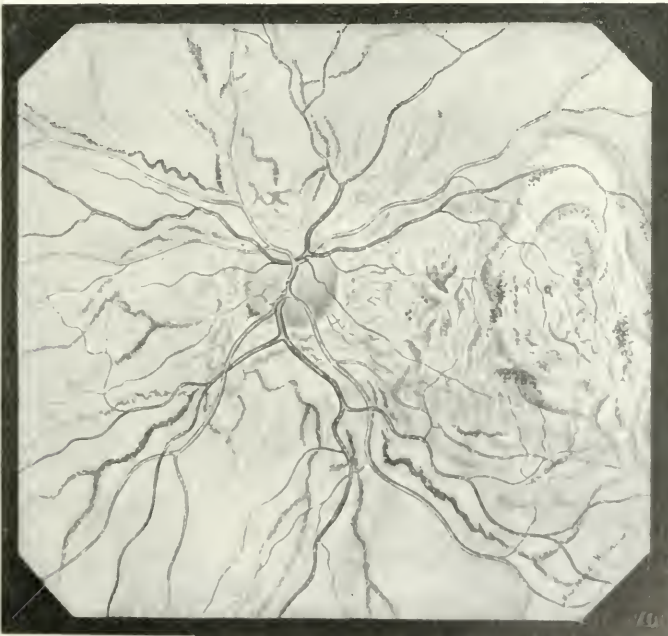


FIG. 260.—Angioid streaks in the retina (from a case under the care of Dr. de Schweinitz).

characteristic picture. As far as known, they continue unchanged in spite of all treatment.<sup>1</sup>

**Angioid Streaks in the Retina** (*Retinal Pigment Stria*).—Pigment

<sup>1</sup> For an excellent account of retinitis proliferans consult an article by Weeks, *Trans. Amer. Ophth. Soc.*, viii., 1897, p. 158.



striae, the result of the metamorphosis of retinal hemorrhages, diffused, according to Ward Holden, in a linear manner through the deep layers of this membrane, present a striking ophthalmoscopic picture, resembling, in many respects, a system of obliterated vessels. Dark, reddish-brown, somewhat granular bands or striae, lying beneath the retinal vessels, often in the neighborhood of the disk, extend over a considerable area of the fundus. Their direct connection with hemorrhages has been demonstrated by Plange, Knapp, Holden, and de Schweinitz (Fig. 260).

**Retinitis Striata.**—This name was proposed by Nagel to describe an affection originally pictured by Jaeger, and characterized by light or yellowish-white stripes, often branched, lying beneath the retinal vessels. The stripes extend from the periphery toward the disk. They may be bordered by lines of pigment. The etiology of the stripes is unknown, but, like the angioid streaks, they probably have their origin in the metamorphosis of retinal hemorrhages (Holden). L. Caspar contends that all retinal striations—or, as he calls the affection, chorio-retinitis striata—represent the final stages of spontaneously cured detachments of the retina.

**Detachment or Separation of the Retina** (*Ablatio sive Amotio Retinae*).—This consists in a separation of the choroid from the retina, causing the latter to float in the vitreous.

**Etiology.**—The causes of detachment of the retina may be—

1. Stretching of the sclerotic and choroid. To this can be attributed the greatest number of cases. It occurs in high degrees of myopia (*malignant myopia*). The retina is attached only loosely to the choroid, and firmly about the optic nerve and near the ciliary processes. As the globe increases in size, the sclerotic and choroid, each being somewhat elastic, are stretched more and more, until the circumference of the retina becomes less than the space which it should fill, and there is, consequently, separation of the retina from the adjacent choroid throughout a part or the whole of its extent.

2. The retina may be pushed from the choroid into the vitreous. This may be due to (*a*) a solid substance, as a tumor or cysticercus; or (*b*) a fluid, such as an exudation from the choroid. It is possible that a serous inflammation of the choroid is, in many cases, a cause of the retinal detachment. Hemorrhages in the choroid would, of course, produce the same result, this occurring, for example, in operations for glaucoma or as the result of injury.

3. The retina may be drawn away from the choroid into the vitreous. Leber and Nordenson hold that the changes commence primarily in the vicinity of the ciliary body. A fibrillary degeneration of the vitreous commences, and as that humor shrinks the retina is gradually drawn away from the choroid. Rupture of the retina occurs, and the fluid from the vitreous passes beneath it through the opening. Detachments of the retina of a similar kind may also occur when, from injury or operation, there has been any considerable loss of the vitreous humor.

Retinal detachment is more frequent in men than in women.

**Symptoms and Pathology.**—The morbid conditions vary according to the causes above mentioned. Where the membrane has been pushed away and still rests on a solid base, as, for example, on a sarcoma of the choroid, it is immovable, still retains more or less of its normal color, and in parts may be found to be more vascular than usual. Ordinarily, however, there is fluid behind the retina, and it floats in a fluid vitreous. Then it has lost its usual color, and, although the vessels retain their place with regard to the retina, both may float together, moving with the motions of the globe. As the retinal vessels rise over the separated portion, they first lose the light

streak, and finally appear as dark, tortuous cords, and are apparently smaller than normal. The border of the detachment is usually sharply marked from the normal fundus, and may be accentuated by a yellowish or even pigmented line. The fluid tends to gravitate toward the lower portion of the globe, and even if the detachment, which may be *partial* or *complete*, occurs originally at the side or above, the fluid finds its way between the retina and choroid, usually to the lower portion of the eye. Sometimes the detachments are quite small, like a series of furrows; at other times an almost circular separation occurs.

Important changes also take place in the tissue of the retina itself (Klebs). As the rods and cones are macerated by the fluid in which they float they become swollen, entirely losing their original structure and consequently their function. The bearing of these facts on attempts to replace the retina is evident.

The *ophthalmoscopic picture* of extensive retinal detachment is one which cannot be mistaken for anything else. With the upright image the observer sees the grayish-white fold waving as the eye moves in various directions, and in the undulations the branches of the vessels are brought into view.

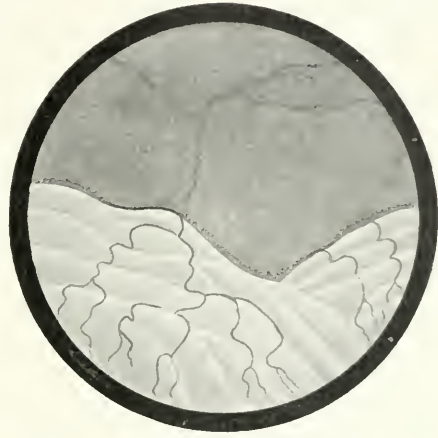

FIG. 261.—Detachment of the retina.

The inverted image gives a general view of the condition, and often the whole or most of the detached area is brought into the field at once, showing still better the arrangement of the retinal vessels. They spread over

the surface of the floating retina, sometimes appearing on the surface or again depressed beneath it, where it may be covered with a whitish cloud, probably due to local extravasation of the subretinal fluid. The other portions of the retina are often almost normal, although the papilla may appear more congested than usual (Fig. 261).

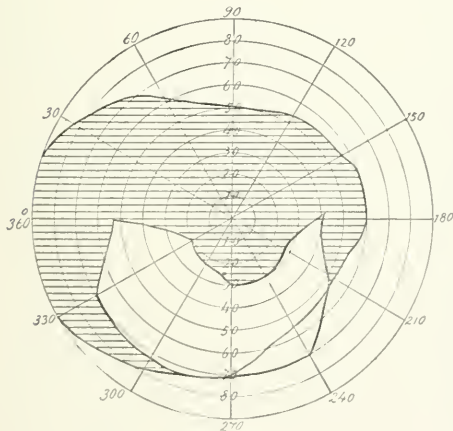


FIG. 262.—Visual field in detachment of the retina. The shading indicates where vision was lost.

corresponding loss of vision, and consequently the field assumes every possible variety of form (Fig. 262; see also Figs. 287 and 288).

2. *Metamorphopsia*.—This is not of the slight degree found in serous

retinitis, but is so great as to cause the lines of a page to be zigzag or the letters to be separated widely from each other.

3. *Dyschromatopsia* is also present, and the difficulty in recognizing colors is noted even in parts of the field apparently unaffected.

*Scintillations* or *phosphenes* cannot be produced by pressure on the eyeball over the separated retina.

Other alterations are not infrequent with detached retina; opacities may appear in the vitreous humor, and with these or independently of them iritis, irido-choroiditis, or cataract.

**Diagnosis.**—Extensive detachment, as before stated, is easily recognized, both because of the clearness of the ophthalmoscopic picture and from the subjective symptoms. If the vitreous is filled with opacities and obscures the details of the fundus, an examination of the visual field gives diagnostic proof. The difference between a retina separated by fluid or by a solid growth—*e. g.* a tumor—has been pointed out.

**Course and Prognosis.**—Usually the detachment extends more and more, and the portions of the retina which at first remained comparatively healthy either become detached or undergo pathological changes. In certain rare instances, however, the fluid is absorbed, and the retina is reappplied to the choroid with a corresponding improvement in the vision. It is not at all certain under what circumstances such an improvement occurs.

**Treatment.**—Inasmuch as many of the cases of improvement have occurred when the patient was in a recumbent position for a considerable time because of illness or for other reasons, the plan of treatment usually advised first is rest in bed for days or even weeks. This is much easier to prescribe than to accomplish. Various other plans have therefore been suggested, which have for their object—

(a) Absorption of the fluid by medication. This includes the administration of laxatives, salicylate of sodium, iodid of potassium, the hypodermic use of pilocarpin, mercurial inunctions, etc.

(b) Absorption of the fluid or coagulation by *electrolysis*. Attempts have been made by Wray and others to produce absorption of the subretinal fluid by means of the electric current. Clavelier recommends a strength of five milliamperes continued one minute, and many excellent results have followed this method. More testimony is necessary, however, before definite opinions can be formed as to the relative value of this agent.

(c) Removal of the fluid by operation. Again, numerous attempts have been made to give exit to the subretinal fluid, with the hope that as the retina came in contact with the choroid it would be reappplied and resume its function. But whether that fluid was drawn away with a syringe or allowed to escape through a puncture in the sclerotic, the results have been for the most part unsatisfactory. Equally unreliable has been the plan suggested by de Wecker of passing a gold wire through the sclerotic and keeping up a constant drainage. Closely allied to this plan of treatment is that recommended long ago by von Graefe. In this method two needles are passed through the sclerotic, and, transfixing the retina as is done with the lens in laceration of the capsule, an opening is thus made in the detached membrane, the subretinal fluid being allowed to escape into the vitreous. Although this is one of the oldest methods, it still gives as good results as any other. Deutschmann has recently recommended division of the retina and vitreous humor, all strands between the retina and the shrinking vitreous being thoroughly separated. He has also assisted his laceration-operation by transplanting the vitreous humor of a rabbit into the affected eye. Finally, attempts have

been made to set up an inflammation which by exudation should bring the separated membranes together. For this purpose iodine solution has been injected beneath the retina (Schoeler's method), but the reaction is so great that the plan is only mentioned to be condemned. Charles Stedman Bull's conclusion in regard to treatment is that no better means for dealing with retinal detachment has been devised than rest on the back in bed, atropin, a bandage, and the administration of some drug which may induce absorption of the subretinal fluid.

**Glioma of the Retina.**—This growth is fully described in the section on Morbid Intraocular Growths, on page 494.

**Subretinal Cysticercus.**—This is occasionally met with, especially in Germany, but is practically unknown in America. When the entozoön is thus lodged beneath the retina, it develops there, pushes out into the vitreous, and the different stages of its growth can be easily studied with the assistance of the ophthalmoscope. These parasites have been removed with comparatively little injury to the eye or detriment to vision.



# DISEASES OF THE OPTIC NERVE.

BY HAROLD GIFFORD, M. D.,

OF OMAHA, NEB.

IN this section it is not proposed to discuss the affections commonly classed as amblyopias or amauroses, although in many of them the optic nerve is primarily or secondarily affected: they will be considered in another article (page 457), as will also many of the congenital peculiarities of the optic disk (pages 191-195).

**Hyperemia of the Optic Nerve.**—A *congestion* of the optic nerve can only be diagnosed with any approach to accuracy when the intraocular end of the papilla is involved; and the color of the normal papilla is subject to such wide variation in different individuals that a positive diagnosis of hyperemia, even where it is strongly suspected, is frequently difficult, unless the papilla has been previously examined under normal conditions or unless the nerve in question can be compared with that of the other side. It shows itself in a deepening of the normal, slightly rosy tint of the papilla, the larger vessels remaining unchanged, or, at most, the veins showing enlargement. Its diagnosis is chiefly of value as a premonition of approaching inflammation or of inflammation already existing farther back in the nerve. It also occurs in many cases of choroiditis or with inflammation or irritation of the iris, cornea, or ciliary body. Where, in addition to a decided congestion, the outlines of the papilla become at all indistinct, it is preferable to speak of slight or incipient optic neuritis.

**Optic Neuritis.**—Where an inflammation of the optic nerve is plainly revealed by the ophthalmoscope, it is commonly called *papillitis*, although in many cases the retro-ocular portion of the nerve is also involved, sometimes very extensively.

Where from the severity of the disturbance of vision in comparison with the negative or slightly pronounced character of the ophthalmoscopic symptoms an inflammation of the nerves between the eye and the chiasm is diagnosed, the condition is termed *retro-bulbar neuritis*.

**Papillitis, or Intraocular Optic Neuritis.**—Soon after the invention of the ophthalmoscope permitted intraocular lesions to be studied during life, v. Graefe was led to divide inflammations of the optic disk into two classes: papillitis from stasis (*Stauungspapille*), commonly called *choked disk*, which he supposed to be due to edema and hyperemia of the disk from increased intracranial pressure; and *descending neuritis*, sometimes known as *simple optic neuritis*, in which he believed that the inflammation spread down the nerve-trunk from the intracranial lesion. The experience of subsequent years has shown that the lines between these two forms cannot be drawn sharply, either from a pathological or an etiological standpoint, although for practical purposes the distinction is a useful one.

**Objective Symptoms.**—In its pronounced form choked disk is charac-

PLATE 6.

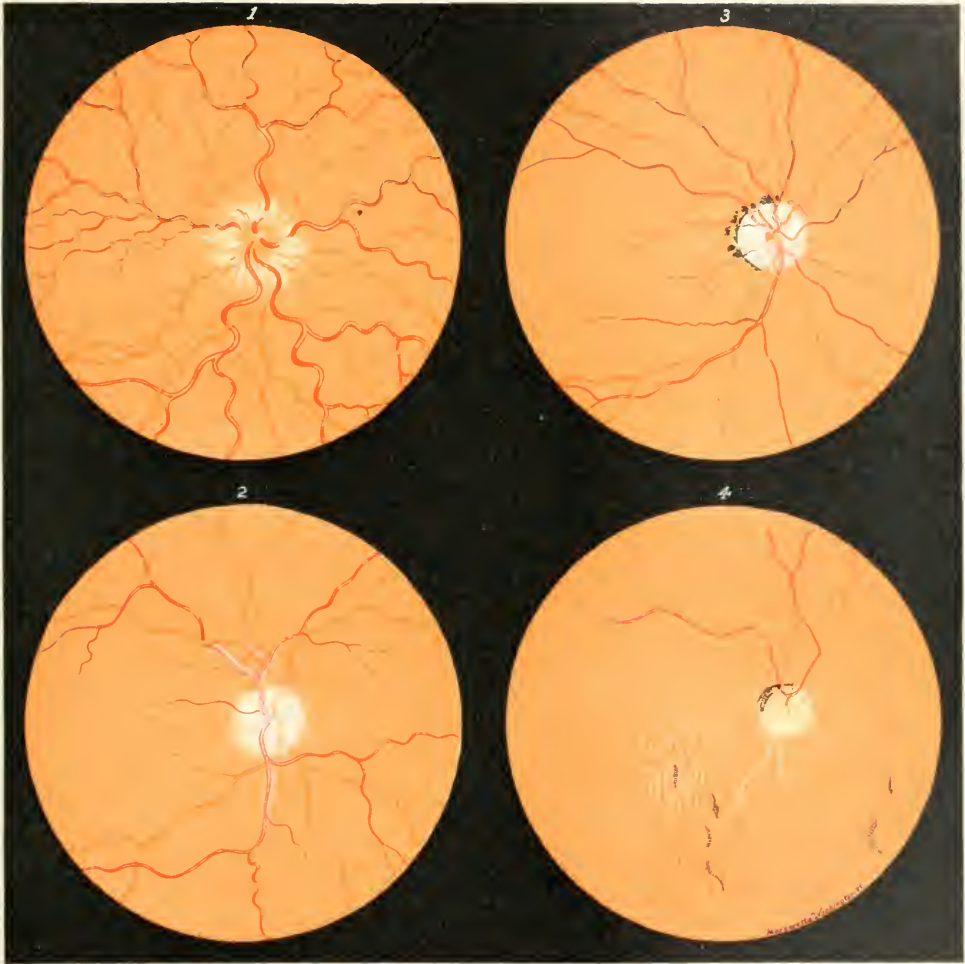


FIG. I.—Papillitis (choked disk) (modified from Haab).

FIG. II.—Post-papillitic atrophy of the optic disk (modified from Haab).

FIG. III.—Simple or gray atrophy of optic disk (from a case of locomotor ataxia).

FIG. IV.—Embolic atrophy of the optic disk, with secondary retinochoroidal atrophic changes (de Schweinitz).



terized by entire obliteration of the outlines of the papilla, an elevated mass of tissue, marked on the surface by radiating striæ which fade off gradually into the surrounding retina, taking its place; near the center of this the larger retinal vessels appear, the veins being generally large and tortuous, while the arteries often are apparently reduced in size. On and close beneath the surface of the elevation may generally be seen numerous enlarged capillary vessels, while on its borders and in the surrounding retina small patches of whitish *exudate* and *hemorrhages*, often flame-shaped, are not uncommon. Very rarely *pulsation of the retinal arteries* has been seen (Plate 6, Fig. I.).

When the hemorrhages and patches of exudate are large and numerous in proportion to the elevation of the disk, the condition is more often termed *neuro-retinitis*, and in such cases opacities may develop in the posterior portion of the vitreous, sometimes with *newly-formed blood-vessels* leading out to them. The height of the elevation, measured with the ophthalmoscope, varies from 1 D. to 6 D. If it is less than this, the term choked disk hardly applies, and the condition verges into that of *simple papillitis*, where, with less complete obliteration of the borders of the papilla, with much less strongly marked striation, hemorrhages and exudate may occur even more extensively than in cases of pronounced choked disk.

In some cases the condition of choked disk may persist with little change for months or even for a year or more, but sooner or later, if the patient lives, the elevation recedes; the striation of the tissue becomes less marked; the hemorrhages and exudate, if any existed, are absorbed; and the outlines of the papilla begin to show dimly. With the continuation of this retrogressive process the picture generally changes to that of *neuritic atrophy*, to be described later on. In some cases, however, where the inflammation has not been very severe nor prolonged, the nerve may gradually assume an almost normal aspect.

**Subjective Symptoms.**—While, in general, it may be said that in cases of choked disk the disturbance of vision increases with the evidence of stasis in the papilla, this rule is subject to great exceptions. The vision of eyes presenting the same ophthalmoscopic picture is found to vary between the normal and complete blindness; occasionally marked choked disk persists for many months without any perceptible impairment of sight. This fact and the fact that the sight may be subject to sudden changes without any corresponding difference in the ophthalmoscopic picture suggest that much of the disturbance of vision may be due to accompanying *retro-bulbar* or *intra-cranial* lesions. The occurrence of normal vision with marked choked disk, where the development of the papillitis is not too sudden, may be explained, as Leber suggests, on the ground that the nerve-fibers may accustom themselves to the changed position and increased pressure without impairment of function.

Where, as is common, the sight is seriously interfered with in the course of the papillitis, there is generally a gradual reduction of the central acuity, sometimes with a central *scotoma*, more often with a *contraction of the field* at the periphery, and frequently more marked at the nasal side; but the mode in which the field of vision is interfered with is subject to all sorts of variations. The *color-sense* necessarily suffers greatly in the severe cases, but if the amblyopia is not extreme it may be very little affected. Sometimes with marked peripheric contraction of the field for white the color-limits in the remaining portion of the field may be normal. Disturbances of the normal relations of the color-limits may be observed—*e. g.* red in certain areas may be seen farther toward the periphery than blue.



Some patients complain of flashes of light and other subjective phenomena indicating irritation of the optic-nerve fibers.

With the subsidence of the ophthalmoscopic symptoms an improvement of vision generally sets in, which will be considered more fully when treating of the Prognosis.

**Pathology.**—Pathologically, the distinction between *choked disk* and *descending* or *simple neuritis* is found to be entirely arbitrary. In some cases in which, during life, there was a choked disk, *post-mortem* examination reveals that the inflammation is limited almost entirely to the intraocular part of the nerve, with a distention of the intervaginal space by serous fluid as almost the only retro-ocular symptom. In others there is marked, sometimes purulent, inflammation in the intervaginal space and the nerve-sheaths, with very little affection of the nerve; while in still others the nerve-trunk is the seat of an intense interstitial inflammation, and the intervaginal space and outer sheath are normal. Conversely, the ophthalmoscopic picture of simple neuritis or neuro-retinitis may coexist with inflammation of the nerve-trunk or with a normal nerve-trunk and extensive *hydroops* or inflammation in the intervaginal space and its walls.

Microscopically, a choked disk in the early stages shows severe venous hyperemia, with some edema, although on account of post-mortem changes

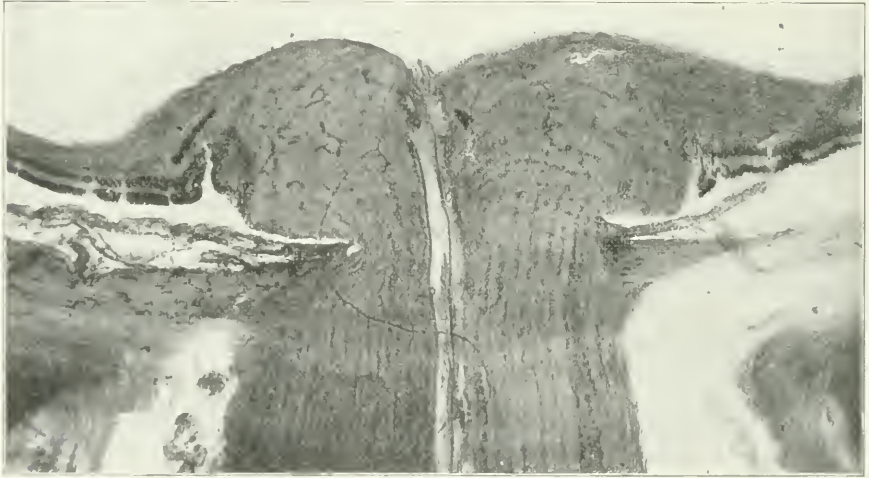

FIG. 263.—From a photo-micrograph by Dr. James Wallace of a section of a choked disk prepared by Dr. William Thomson.

the latter lesion is less marked than would be expected from the ophthalmoscopic appearance; and a marked swelling of the nerve-fibers. Later, the tissues become infiltrated with leukocytes, and accumulations of these at points corresponding to the areas of whitish exudate seen during life are found to have undergone granular or fatty degeneration. Fresh hemorrhages are, of course, visible as such, while older ones are suggested by patches of pigment. Still later, the formation of new connective tissue becomes apparent, especially along the blood-vessels, the walls of which are often much thickened. The nerve-fibers atrophy to a greater or less extent, their place being taken by granules and minute fat-like globules, which in their turn become absorbed (Fig. 263).

The changes in the retro-ocular portion of the nerve-trunk are mainly those of an *interstitial neuritis*, the septa of connective tissue being infiltrated

with leukocytes and, later, thickened from new formation of connective tissue. From the resulting pressure, and perhaps from the direct influence of the *ptomain*s, the nerve-fibers, if the process continues long, undergo degenerative changes and atrophy. The degenerative changes in the nerve-fibers, sometimes described as *medullary neuritis*, are probably, as Alt suggests, merely secondary to interstitial inflammation or to degeneration elsewhere.

Where, with the main lesion in the nerve-head, the signs of inflammation extend into the nerve-trunk for a short distance toward the brain, the condition is termed *ascending neuritis*. In such cases edema of the nerve-trunk has been frequently found. Besides the hydrops of the intervaginal space, which is so common, *optic perineuritis* often occurs in the form of more or less inflammation of the opposing surfaces of the pial and dural sheaths and of the arachnoidal framework between them. This may be slight, or so severe as eventually to obliterate the intervaginal space with a mass of new-formed connective tissue.

**Etiology.**—The most frequent cause of typical choked disk is the development of an *intracranial tumor*, some observers stating that it occurs in 95 per cent. of all cases of such tumors. The nature of the tumor seems to be of very little importance: it may occur with any of the neoplasms, whether of the brain-substance, of the meninges, or of the bony walls, or with gummata, tubercles, cysts (whether of entozoic or other origin), abscesses, or aneurysms. Tumors of the cerebellum are especially apt to produce it.

The method in which brain-tumors cause optic neuritis is a matter still in dispute. Von Graefe supposed that, owing to the increase of intracranial pressure, an abnormal amount of fluid was forced into the intervaginal space, and produced a stasis in the papilla which tended to become exaggerated on account of the unyielding nature of the walls of the channels through the lamina cribrosa. These acted, it was supposed, like the abdominal rings in a case of strangulated hernia, the pressure, naturally, having a greater effect upon the outflow through the yielding veins than upon the inflow through the stiffer-walled arteries. This theory received considerable support from the observation of Manz and others, that in many cases of brain-tumor there actually existed a distention of the intervaginal space with cerebro-spinal fluid.

The other most widely accepted theory is that of Leber and Deutschmann, who hold that the optic neuritis in these cases is not merely a stasis, but is an active inflammation caused by the passage of irritating substances, produced either directly or indirectly by the tumor, from the cranial cavity down to the nerve-head. In favor of this view it may be said that, as a rule, a certain amount of meningitis can be demonstrated in the neighborhood of most brain-tumors, and that in many cases no hydrops of the intervaginal space can be found, but, on the contrary, a normal intervaginal space with marked interstitial inflammation of the nerve-trunk. The alleged production of the symptoms of choked disk in animals by injections into the cranial cavity or into the vaginal space are not admitted as evidence by the supporters of the inflammation-theory, on the ground that higher pressures were used than probably ever occur in the human being. The objection that typical choked disk is seldom observed in cases of acute meningitis is met by the suggestion that the slight neuritis which is often observed does occasionally develop into a choked disk if the patient lives long enough.

A careful review of all the available facts leads one to believe that while, in certain cases, the element of intracranial and intervaginal pressure plays an important part in the production of choked disk, in the majority of cases the latter depends upon an active inflammation.

In addition, there should be mentioned the theory of Parinaud, who holds that choked disk results from an extension, through the trunk of the optic nerve to the papilla, of the interstitial edema of the brain-tissue which is so commonly found in intracranial troubles. This edema of the nerve-trunk is also recognized by Ulrich, but he holds that its effects upon the papilla are produced not directly, but by compressing the central retinal vein.

The importance of optic neuritis as a symptom of brain-tumor can be appreciated from the fact that, aside from its frequency, it is sometimes the first symptom to attract the notice of the patient; in fact, the progress of the tumor may be so slow that, as in a case reported by Leber, a slight optic neuritis may even pass over into atrophy without the knowledge of the patient, years before death occurs. The occurrence of a double choked disk, then, without other grounds for its explanation, is always sufficient reason for a strong suspicion of brain-tumor. As a source of error in such cases, may be mentioned the unique case of Krohn, in which a double optic neuritis was caused by a small metastatic tumor from an ovarian carcinoma developing in the optic nerve immediately behind each globe.

In rare cases the optic neuritis accompanying brain-tumor is *one-sided*, and may even occur on the side opposite to the growth. This is explained by the supporters of the pressure theory of choked disk on the ground of a localized meningitis or hemorrhage.

Of extreme rarity also is the occurrence, in a case of suspected brain-tumor, of a *second attack* of *papillitis* some time after the first has subsided. In the case of de Schweinitz and A. Thomson the neuritis, headache, and epilepsy disappeared after a simple trephining, but all returned at the expiration of a year.

With reference to the diagnosis of brain-tumor, it should not be forgotten that, occasionally, a tumor may cause a neuro-retinitis precisely like that generally considered diagnostic of *albuminuria*.

Discarding the distinction between choked disk and simple or descending neuritis, it may be said that all tumors or inflammations within the cranial or orbital cavities may cause a papillitis; this naturally includes all the varieties of *meningitis* and *infectious thrombosis of the brain-sinuses*.

Optic neuritis has also been observed in the greatest variety of *infectious* and other *general diseases*. It has been most commonly noticed in the course of measles, typhoid fever, and "la grippe," but it has also been mentioned in connection with scarlatina, variola, malaria, whooping-cough, beri-beri, pellagra, typhus, typhoid pneumonia, rheumatism, diphtheria, and myxedema. In some of these cases the neuritis is undoubtedly secondary to a nephritis; in others, to a meningitis; but there is no reason for supposing that some of them may not indicate an actual infection of the trunk or intervaginal space of the nerve, while still others may result simply from the general toxemia. Neuritis also occurs with various disorders of *menstruation*, generally with a sudden checking of the flow, and with *premature menopause* and atrophy of the uterus. The fact that in adults, as well as children, *hydrocephalus internus* may cause double-sided neuritis is of importance, because, on account of the unyielding character of the skull, the diagnosis is much more difficult than in children, and the neuritis might be thought to confirm an erroneous diagnosis of brain-tumor.

Optic neuritis has also been observed in various marked *deformities of the skull*, particularly in the high and narrow variety known by the Germans as "*Touranschädel*" (tower- or steeple-skull). A post-mortem examination in one such case (Michel) showed signs of pachymeningitis, with marked hyper-



ostosis of the skull-bones, both optic foramina being decidedly narrowed. With multiple foci of *cerebral softening* the nerve has, in the early stages, been found to be inflamed, atrophy setting in later, though it seems probable that the hemorrhagic meningitis which often accompanies such cases is the more direct cause of the inflammation of the nerve.

With various other brain and *spinal diseases*, to be considered more fully in connection with atrophy of the nerve, a slight optic neuritis has been observed as a forerunner of the atrophy.

*Syphilis* may cause optic neuritis, either by attacking the nerve directly or by producing a gumma in the cranial cavity.

Whether the cases of neuritis which have been observed in the *puerperal state* have been due to a general infection, or whether they are more akin to the cases which Valude and Bull have reported, in which the optic nerve has been attacked in several successive pregnancies, apparently without any kidney complications, is uncertain. It is possible, also, that some of the cases which have been described as neuritis during *lactation* may belong here, although others are more probably akin to the neuritis which has been observed in the course of *chlorosis*. The anemia produced by the too abundant or too long-continued lactation, as well as that occurring in the chlorosis, produces neuritis, probably through hemorrhages resulting from malnutrition-changes in the walls of the blood-vessels. In other cases the affection of the optic nerve has seemed to be due to a sudden checking of the flow of milk.

The neuritis which sometimes follows *severe hemorrhages* is also probably due to alterations in the blood-vessel walls, the malnutrition caused by the extreme anemia so weakening the coats of the vessels that, when the blood-current begins to resume its normal force, transudations and hemorrhages occur which may either give rise to the picture of optic neuritis directly, or possibly indirectly, through pressure in the intervaginal space. A striking case of this character is that reported by Gessner, in which three weeks after a severe post-partum hemorrhage the vision suddenly became affected, the difficulty progressing within three days to complete blindness; the ophthalmoscope revealed a marked choked disk in each eye. This was immediately followed by the onset of an *ascending myelitis*, which caused the death of the patient at the end of two weeks.

A cause of neuritis which has been insisted upon by Panas is *gonorrhoea*, though, in the case which he reports, the connection between the urethral affection and the neuritis is less obvious than in the more recent case of Campbell-Highet. In Panas's case one eye remained blind, the other being scarcely affected, while in Campbell-Highet's case the affection was one-sided and ended in complete recovery.

In treating of the effects of *nephritis*<sup>1</sup> upon the eye the main stress is usually laid upon the retinitis, though, so far as the functional disturbance is concerned, the optic neuritis is probably of greater importance. The retinitis is much more apt to clear up without leaving permanent damage, if the nephritis is of the curable variety, than is the affection of the nerve. The writer has a case on hand at present in which the retinitis has been cured for months, while the nerves are still far from normal. It should be remembered, too, that nephritis may reveal itself in the eye by the typical appearance of choked disk without any of the ordinary retinitis albuminurica. It is probable also that nephritis may cause serious damage to the optic-nerve trunk through retro-bulbar hemorrhages or localized areas of edema.

<sup>1</sup> The neuro-retinitis which occurs in lead-poisoning is generally secondary to the lead-nephritis, though sometimes the nerve may be affected directly in this as in other sorts of poisoning.



Since *intra-nasal cauterization* occasionally causes meningitis, it can easily be understood how it might also cause an optic neuritis, although in the case of Alt, in which one-sided papillitis developed immediately after cauterization of one of the turbinated bones on the same side, there were no decided symptoms of meningitis, and a nearly complete recovery followed rapidly on the subsidence of the intra-nasal irritation.

While *aeromegaly* generally causes atrophy by pressure of the enlarged pituitary body on the chiasma, it not infrequently produces optic neuritis.

The cases of double optic neuritis which develop immediately after *sun-stroke* or some *violent physical exertion* are probably due to hemorrhage or effusion within the cranial cavity, with secondary meningitis. In the only case following sunstroke which the writer has seen dementia and permanent blindness resulted. In a case following a violent run to catch a car useful sight was recovered after complete blindness had persisted for months.

*Carious teeth* or the reaction following their extraction may cause optic neuritis, apparently through the extension of a phlebitis directly to the orbit or through the intervention of an abscess of the antrum of Highmore with secondary orbital cellulitis.

After taking account of all the known causes, there remain quite a number of cases of optic neuritis for which no probable cause can be ascertained. These cases, in the experience of the writer, are frequently *monocular* and may be slight or severe, but they offer, on the whole, a relatively good prognosis.

**Diagnosis.**—The diagnosis of intraocular optic neuritis rarely offers any difficulty where the media are clear; the only conditions which are liable to be mistaken for neuritis are hyaline bodies in the papilla (to be discussed later) and an obscuration of the borders of the disk by opaque nerve-fibers. Where these opaque fibers occur in solid patches they can hardly be mistaken for anything else, but where they occur sparingly mixed in with the ordinary sheathless fibers, the margin of the disk may be more or less completely obscured by a grayish striation, reminding one strongly of the appearance in a mild case of choked disk.<sup>1</sup> A careful examination of the direct image, showing the absence of enlarged capillaries and other signs of stasis, will almost invariably clear up the diagnosis, but where there is some functional disturbance this condition may occasionally cause some uneasiness, as is shown by a case seen by the writer in which an ophthalmologist of the utmost ability diagnosed neuritis; subsequent continued observation showed that the cause of the blurring of part of the disk-margin was due to this admixture of opaque fibers. If the media are not perfectly clear, it is not always possible to determine whether the cause of the blurred image of the disk is due entirely to the interference with the passage of the light. If the opacities in the media are easily detected, the observer will naturally be on his guard, but where the want of transparency is due to the extremely fine opacities which sometimes exist in the vitreous or upon the posterior surface of the lens, the beginner might easily overlook these, and, thinking the media clear, diagnose an incipient neuritis with blurred disk-margins. To avoid this error one should, of course, examine the cornea, lens, and anterior vitreous with a strong convex lens.

**Prognosis.**—This must always be guarded. There is absolutely no means of determining whether a case of neuritis, seen for the first time, will result in total blindness or in the restoration of normal vision. Where the ocular disturbance depends upon some general affection the prognosis will

<sup>1</sup> Cases, probably of this nature, have been described as *false* or *spurious optic neuritis*.

depend upon the course taken by the latter: aside from the nature of the ultimate cause, the rule, as would naturally be expected, is that the greater the severity of the neuritis the greater the permanent damage to the sight, through the destruction of nerve-fibers, during the neuritis or in the course of the subsequent atrophy. In general, it may be said that where the ultimate cause of the disease is not of a hopeless character the prognosis is relatively good, since useful central vision is often left, though frequently with more or less contracted fields. The writer has certainly seen and committed more errors on the unfavorable than on the favorable side of the question. Where the course of the neuritis has been rapid the vision is apt to improve with the subsidence of the ophthalmoscopic symptoms, sometimes becoming worse again when the secondary atrophy sets in. On the other hand, where the neuritis has run a long chronic course, with only a moderate amblyopia, the vision sometimes fails rapidly and continues to fail throughout the retrogressive stage. In still a third class of cases the writer has seen useful vision restored at the retrogression of a marked papillitis which had persisted with absolute blindness for several months.

**Treatment.**—If the disease depend upon some general affection, the latter, of course, should first engage the attention of the physician, and the ocular condition may need no special treatment. Occasionally, however, it does, on account of the danger that while waiting for remedies to act upon the general condition permanent damage might be done to the sight, which could perhaps be prevented by a more vigorous line of treatment. Where the optic-nerve lesion is not secondary to any other affection which requires attention, it is very uncertain what line of treatment will have most influence upon it. Full doses of salicylate of sodium or of iodid of potassium, mercurial inunctions (even in non-specific cases), and the various forms of sweat-cures have all been used with apparently good results in some cases, while in others they have had no influence. In very critical cases the writer has used the iodid of potassium, inunctions, and pilocarpin at the same time, with apparently good results. Those who use mercury in non-specific cases generally recommend it, in particular, where there is evidence of active inflammation, while others use large doses of iodid in precisely similar cases. A sweat-cure, either with pilocarpin, salicylate of sodium, or the Turkish bath, is always in order. Where neither pilocarpin nor the salicylate, nor a combination of the two, can be borne in a sufficiently large dose to produce free diaphoresis once a day, and circumstances do not permit visits to a Turkish bath-house, the writer has found an improvised hot-air bath, obtained by the use of a small lamp and enough rubber sheeting to cover two chairs, to be of great service, particularly in cases of nephritic origin. If mercury is used at the start in preference to the iodid, it may be exchanged for the latter when signs of mercurialization appear; and its use, in any case, should be continued off and on for months unless a complete cure should result sooner. Cupping or leeching the temples is still recommended by many and can do no harm. It is more than doubtful whether the use of setons in the temple or at the nape of the neck is even justifiable. In syphilitic lesions of the optic nerve, rapidly produced mercurialization by inunctions, repeated at intervals, with iodid in full doses during the intervals, gives the best results.

In the way of direct operative interference de Wecker's plan of incising the dural sheath may be mentioned as a curiosity.<sup>1</sup> From the standpoint of

<sup>1</sup> Von Hoffman in one case evacuated pus from the intervaginal space. The operation did not prevent atrophy.

v. Graefe the proposal was a rational one, but the difficulties and dangers attending the operation have prevented its general adoption. More promising is the performance of trephining the skull, with or without the puncture of a lateral ventricle, where the neuritis is due to hydrocephalus internus, whether the latter be caused by brain-tumor or by something else. Several cases of this kind are on record in which the operation has been followed by a marked improvement of the neuritis and of the vision. This treatment is of course resorted to only where the intracranial disease itself is of a very serious nature; and the relief and any improvement of vision obtained are not likely to be permanent, since the primary disease is generally incurable.

Where the neuritis depends upon the pressure of a brain-tumor which can be removed completely, it may be permanently cured. Operative treatment may also cure a neuritis caused by an orbital tumor or by an inflammation or tumor of one of the accessory sinuses, or by any of the intracranial inflammations of otitic origin.

**Acute or Fulminant Retro-bulbar Neuritis.**—In the cases which v. Graefe originally classified here, blindness came on suddenly, the ophthalmoscope showing very small but still permeable retinal arteries and a very slight blurring of the edges of the disk. He considered that the symptoms were due to a compression of the central vessels by the products of a retro-bulbar neuritis. Some of his cases would now probably be called simply thrombosis of the central artery.

**Etiology.**—In quite a number of cases severe exposure or rheumatism can be adduced as a cause of this affection; it has also followed infectious diseases, of which influenza seems particularly liable to produce it. In many cases no sufficient cause can be discovered. The disease seems to be one of the forms of multiple neuritis which may be produced by any of the toxins circulating in the blood. *Acute or subacute myelitis* is frequently accompanied by this same set of eye-symptoms, excepting that the ophthalmoscope shows a marked neuritis or a choked disk; hence it is manifestly arbitrary to make a separate group of the cases in which the neuritis happens not to reach as far toward the distal end of the nerve as it does in others.

**Symptoms.**—At the present day the diagnosis of acute retro-bulbar neuritis is made when one meets the following complex of symptoms: Pain back of the eye, spontaneous or upon movement of or pressure on the eyeball; obscuration of vision, progressing in the course of from one to eight days to complete or nearly complete blindness; ophthalmoscopically, a normal disk or a hyperemic nerve-head with or without slight haziness of the surrounding retina; and, rarely, minute retinal hemorrhages and small grayish or yellowish spots in the neighborhood of the macula. With these symptoms are not unfrequently associated others pointing to acute myelitis or, more rarely, multiple neuritis. Death may occur within a few weeks of the onset of the disease.

Before amaurosis becomes absolute the sight may undergo sudden variations; thereafter it gradually improves slowly until, occasionally, normal vision is restored. More frequently the restoration stops short of this, and a certain degree of amblyopia remains either with a contracted field or with central scotoma, or with both. The color-sense is apt to be severely affected throughout the disease. As the process begins to decline more or less complete atrophy of the disk occurs.

The affection may be one-sided, or both nerves may be affected simultaneously, or there may be a very short interval between the attacks. In other

cases recurring attacks at intervals of a month or more affect both nerves or one nerve after the other.

**Pathology.**—What is known of the pathology of this affection we owe almost entirely to Achard and Guinon, Elsehnig, Dreschfeld, and Katz, who have found interstitial neuritis generally throughout the whole diameter of the nerve, in some cases from the chiasma to the globe, with secondary degeneration of the nerve-fibers. Whether similar symptoms may not be produced by a perineuritis or by a periostitis in the optic canal remains to be seen. As Elsehnig suggests, the latter condition might cause a compression of the ophthalmic artery, and thus produce the ophthalmoscopic picture seen by v. Graefe. It is probable that still other cases are caused by a pachymeningitis spreading into the optic canals. Thus, in a case observed by the writer the patient had several attacks of complete double-sided blindness at intervals of several months; the attacks were preceded for some time by severe headache, and after the last attack an almost constant headache persisted for nearly a year.

**Prognosis.**—The prognosis is favorable so far as the regaining of useful sight is concerned, complete blindness remaining very rarely, if ever. Serious permanent visual disturbances, however, are not unusual, and are apt to be worse in those cases in which the ophthalmoscopic symptoms of neuritis have been most pronounced.

**Treatment.**—The same treatment as that recommended for optic neuritis in general should be ordered, especial stress being laid upon large doses of salicylate of sodium where the affection seems to be of rheumatic origin.

**Chronic Retro-bulbar Neuritis.**—Perhaps some of the cases mentioned in the preceding section, where a succession of acute attacks occur, might properly be considered chronic. Besides these there are others which pursue a slower course, the loss of vision progressing during several weeks or months in the form of a *central scotoma*, at first relative (*i. e.* some or all colors being mistaken within its borders). Some cases are complicated by a peripheral contraction of the field, which in rare, severe instances may meet the central scotoma so as to produce absolute blindness. The ophthalmoscope in the early stages may show nothing abnormal, or there may be congestion of the disk and slight haziness of the surrounding retina. Later, if the disease continues long, atrophy of the outer quadrant or half of the optic disk becomes evident, and occasionally the whole disk appears atrophic, even where the defect of vision is limited to a *central scotoma*.

**Etiology.**—Some of these cases can be attributed to rheumatism or exposure; in others chronic meningitis or periostitis in the optic canal may be assumed; and sometimes no probable cause can be assigned. But the great majority are caused by systemic poisoning with alcohol, tobacco, lead, or some other drug or substance taken into or developed within the body, and they have been so long classified as *toxic amblyopias* that they and their pathology will be considered fully in another article (see page 459).

A special form of retro-bulbar neuritis, commonly known as *hereditary nerve-atrophy*, is one which appears in members of the same family, generally between the ages of eighteen and twenty-two, though it may occur as early as five years or as late as forty-three. In the great majority of cases males alone are attacked, and, where the disease can be traced through several generations, it is generally transmitted by the unaffected females to their male offspring.

The course and ophthalmoscopic symptoms of the affection are those of a subacute retro-bulbar neuritis, a permanent simple scotoma with more or less



amblyopia almost always remaining, total blindness persisting very rarely. The cause of the affection has only been surmised.<sup>1</sup>

**Prognosis.**—In the cases caused by systemic poisoning the prognosis for the restoration of normal vision is good if the poisoning can be stopped before actual destruction of nerve-tissue has taken place, and even where the ophthalmoscopic appearance and the duration of the affection would render complete recovery improbable, normal vision is restored in some cases.

In the non-toxic cases the prognosis is not so good, owing to the doubt which generally exists as to the cause, and as to the possibility of any line of treatment really having much influence upon the course of the disease. Permanent blindness rarely results, however, and the more rapid the course of the affection and the less pronounced the ophthalmoscopic symptoms, the better the result to be expected.

**Treatment.**—In the toxic cases the poisoning should be stopped, while in the others the same treatment recommended for the acute cases is in order.

**Atrophy of the Optic Nerve.**—By atrophy of the optic nerve is meant, strictly speaking, the disappearance of a larger or smaller proportion of the nerve-fibers, but practically the term is also used for any condition in which the ophthalmoscope shows the papilla or a considerable part of it to have permanently lost its normal tinge of pink, through the disappearance of a large proportion of the normal number of capillary blood-vessels or through the formation of new connective tissue within it.

If the reduction of blood-supply be only temporary, we may speak of *anemia of the disk*, or, if it occurs suddenly and is very extreme, of *ischemia of the disk*.

**Varieties and Objective Symptoms of Optic-nerve Atrophy.**—If the atrophy develop without previous inflammation of the nerve, it is called *simple* or *primary* or *non-inflammatory* atrophy.<sup>2</sup>

The distinctions made by many writers between *white* and *gray* atrophy and between *cerebral* and *spinal* atrophy are not well grounded, for the first refers merely to an appearance of the nerve which may be transient, a white atrophy sometimes passing over into a gray, and either being sometimes produced by the same cause; while the second depends upon the assumption that the optic-nerve atrophy in a large class of patients is the consequence of spinal disease, whereas it is now known that the optic atrophy, while dependent upon the same cause as the spinal disease, originates quite independently of it and often antedates it.

In simple atrophy the nerve is white, bluish white, or grayish white, with clear-cut edges, and frequently with a shallow excavation which may

<sup>1</sup> Of interest is the apparent connection with the brunette type. Thomson reported a family in which the blue-eyed children retained normal sight, while the dark-eyed ones were affected with atrophy of the optic nerve. This recalls the observation from the pre-ophthalmoscopic times of Travers, who says (*Synopsis of Diseases of the Eye*, London, 1821, p. 302): "I know a family of several well-formed children, three of whom have dark hair and eyes, the others light hair and blue eyes. Toward puberty all the dark-haired children have become epileptics and gradually lost their sight, the eyes, except in the expansion and immobility of the pupils, retaining every appearance of health."

<sup>2</sup> Much confusion exists in the terminology of optic-nerve atrophy. By the term *simple* some authors designate those cases for which no probable cause can be assigned. Others separate from simple atrophy, as used in this work, the cases in which the atrophy depends upon some definite retro-bulbar lesion, classifying these as *descending* atrophy. In general, by *descending* atrophy is meant simply that the lesion is back of the eye, so that it must descend before becoming evident in the disk, while in *ascending* atrophy the primary lesion is more peripheral and leads to a degeneration passing up to the higher centers. The term *cerebral* is sometimes applied to the cases depending on an intracranial lesion. *Progressive* atrophy simply means that the process progresses steadily.

extend to the temporal margin, but which is generally not sharply defined. The vessels often show some reduction in size, but this is seldom extreme, as it is in some other forms of atrophy. In some cases the lamina cribrosa shows plainly, in others it does not (Plate 6, Fig. III.).

The atrophy occurring after inflammation of the intraocular end of the nerve (*neuritic* or *post-neuritic atrophy*) differs from the preceding form by more or less marked narrowing of the arteries, by the presence of white streaks of connective tissue along the large blood-vessels, by more or less irregularity or obscuration of the margin of the disk, and by a chalky, opaque whiteness in contradistinction to the clear somewhat translucent appearance which is seen in most cases of simple atrophy (Plate 6, Fig. II.). With the lapse of time, however, these differences are apt to become much less pronounced, and sometimes they disappear altogether. In some cases of neuritic atrophy a network of newly-formed blood-vessels is left upon the disk; and this symptom, when it occurs, is, in the writer's experience, the most permanent of all the signs of a previous neuritis. A moment's consideration will show that some cases of atrophy secondary to a neuritis will be classed, from the ophthalmoscopic appearances, with simple atrophy—namely, those due to a pure retro-bulbar neuritis, so that in speaking of a primary or secondary atrophy this exception should be borne in mind.

A third type of optic-nerve atrophy is that described by Leber as *retinal atrophy*. This results from any extensive disturbance with the nutrition of the retina, and depends generally upon retinitis pigmentosa or extensive retino-choroiditis. In this class of cases we find the most extreme changes in the blood-vessels. In advanced cases of retinitis pigmentosa the vessels are very small, and sometimes are so reduced as to be indiscernible with the ophthalmoscope. The disk has a dirty-bluish or yellowish-gray hue.

In the various forms of retino-choroiditis the changes in the vessels and the appearance of the disk are not apt to be so extreme; but where there is a large area of destruction, particularly at the macula, a corresponding sector of the nerve is generally atrophic.

The atrophy which follows embolus or thrombosis (*embolic atrophy*) of the central artery is also largely retinal in its origin—*i. e.* it depends not so much upon the interference with its own blood-supply (for this is in good part derived not from the central vessels, but from those of the sclero-choroidal ring) as upon a degeneration following the death of the nerve-elements in the retina. It gives the nerve a dense, opaque whiteness or a yellowish-white tint (Plate 6, Fig. IV.).

**Subjective Symptoms.**—Except in the cases following retro-bulbar neuritis of the macular bundle of fibers the *disturbance of vision* most commonly takes the form of a reduction of central acuity with contraction of the field at the periphery, but central and ring-shaped scotoma, sector-shaped defects, or spurious hemianopsia, all may occur (for visual fields see page 477). The *color-sense* is apt to suffer early in the course of the disease, the outer limits of the color-fields sometimes being irregular or contracted before the field for white shows any abnormality. A diminution of the *light-sense* is also common, the periphery of the field often showing a contraction, if it be tested with gray paper or by reduced light, when the ordinary test with a white object shows no abnormality (see page 168). On the other hand, some patients, especially in the atrophy accompanying retro-bulbar neuritis, see better in proportion by a moderately dim light. In the occasional cases where the functions are normal and the disk decidedly atrophic-looking, we have to assume either some congenital peculiarity or that the connective tissue

has been changed chiefly in appearance, without sufficient increase in volume to cause atrophy of the nerve-fibers.

**Etiology.**—It is evident that any of the causes which have been enumerated as producing optic neuritis may produce atrophy, and, as the signs of neuritis may have disappeared by the time the patient is first examined, the results of the cause may be set down as atrophy without any knowledge of the neuritis. Besides neuritis, any other cause that cuts off communication between the retina and the higher nerve-centers will produce atrophy.

*Brain-tumors* may cause atrophy, by the production of neuritis, by direct pressure on the nerve, chiasma, or tracts, by the pressure upon the chiasma and tracts of the accumulation of fluid in the ventricles which often accompanies them, or by raising up the chiasma and nerve, and thus causing them to be constricted by the arteries at the base of the brain.

*Injuries to the nerve-trunk* are followed by atrophy, both ascending and descending, while all the various processes which destroy the function of the retina, whether it be removal of the globe, the various conditions which produce phthisis bulbi, inflammations of the choroid or retina, detachment of the latter, or cutting off its blood-supply through thrombosis or embolism, and, finally, abnormal pressure both upon the retina and the disk, as in glaucoma, produce ascending atrophy of the nerve-trunk, chiasma, and the tracts leading to the higher cerebral centers.

The atrophy which sometimes follows *erysipelas* of the face is undoubtedly caused by the accompanying inflammation in the orbit, since any severe *orbital cellulitis* may cause atrophy, probably either by direct pressure on the nerve-trunk, by thrombosis of the retinal vein, as pointed out in particular by Knapp, or by producing a neuritis. Some authors doubt whether atrophy may result simply from *hemorrhage into the orbit*, but the writer has seen at least two cases in which this undoubtedly occurred; in one a hemorrhage followed an extirpation of the lachrymal gland and led to atrophy, with the typical picture of thrombosis of the retinal vein and paralysis of all the ocular muscles; this indicating that even if the vein had not become obstructed, atrophy might have resulted directly from the pressure.

In a number of cases optic-nerve atrophy follows *falls* or *blows upon the head*, without any signs of meningitis or optic neuritis. The first rational explanation of these cases was given by Hölder and Berlin, who found that in many cases, without any external signs of fracture, fissures of the walls of the orbit were produced which extended into the optic canal, the nerve in some cases apparently being injured immediately by pressure from fragments of the bone or by hemorrhages into the optic canal, or later by pressure from the development of callus. In the first two instances blindness develops at once; in the last it comes on gradually after several days or weeks. These cases are generally one-sided, and apparently may be produced through *contrecoup* by violence to distant parts of the body. Whether the cases described by Schweigger as *concussion of the optic nerve* were due to fractures of the bone is uncertain. In them violence to the head was followed by immediate and complete one-sided amaurosis. A certain amount of useful vision (in one case nearly approaching the normal, the nerve showing partial atrophy) returned after some days or weeks. It is possible, also, that some of the atrophies which follow *spinal injuries* are produced in this way; about the real significance of these cases there has been some dispute, some authors leaning to the view that they were the result of a trophic disturbance, while others assume that they result from an ascending meningitis; but since it has been shown that a fall upon the trochanter, for instance, can produce a frac-



ture through the optic canal by contre-coup, it seems probable that at least some of the cases have this origin.

The numerous cases of optic-nerve atrophy in various forms of *spinal disease* also led to the belief, at one time prevalent, of a trophic connection between the spinal column and the optic nerve; and because the disk in many of these cases (though by no means in all) was of a grayish hue, it was common to speak of *gray* or *spinal atrophy*. The spinal affection in which atrophy is most commonly observed is *tabes*. Out of 109 cases of *tabes* which Berger examined he found optic-nerve atrophy in 44, and amblyopia with normal disks in 7. It may be one of the earliest symptoms of the disease, occurring entirely independently of the spinal lesion, and beginning, apparently, near the peripheral end of the nerve. In the early stages the ophthalmoscope sometimes shows a decided congestion of the disk, though the ophthalmologist seldom sees the patient early enough to observe anything but atrophy, which may be either of the gray or white variety. The disturbance of vision generally takes the form of a peripheric contraction of the field with reduced central acuity, but central scotomata sometimes occur. The affection almost always ends in complete blindness if the patient live long enough.

In *disseminated sclerosis* the frequently occurring atrophy, which is often confined to the other half of the disk and produces a relative central scotoma oftener than a contraction of the field, is sometimes preceded by moderate papillitis, and is much less likely to lead to blindness than the atrophy of *tabes*. The disturbance of vision is more subject to variations, and is not infrequently accompanied by *nystagmus*, which becomes more marked or shows itself only on *voluntary* movements of the eye.

In *progressive paralysis*, also, optic atrophy is quite common, and that it may be a very early or perhaps an initial symptom is indicated by the fact that a large proportion of patients in whom apparently idiopathic optic atrophy occurs sooner or later become demented. Here, too, Allbutt has observed a stage of congestion preceding the atrophy.

According to Michel, the atrophy occurring in multiple foci of *cerebral softening* as a rule affects only the temporal side of the disk. Atrophy has also been observed in *chronic bulbar paralysis*, in *chorea*, in *epilepsy*, where it is probably only a coincidence, and in nearly all of the general affections which have been mentioned in connection with neuritis.

Atrophy is quite common in *diabetes mellitus*; it also has been noted with *diabetes insipidus*. One important cause of atrophy is *pressure upon the nerve or chiasma* at the base of the brain or within the optic canal by enlarged arteries. The enlargement may be aneurysmal, but commonly it is merely the result of arterial sclerosis, and the resulting pressure on the nerve may spread the latter out in the form of a semi-cylinder or even divide it into two bundles.

The atrophy which follows severe *hemorrhages* is sometimes preceded by neuritis. The blindness is often complete and generally double-sided. It comes on sometimes at once, but, as a rule, several days after the hemorrhage, and, according to Fries, out of 90 cases the highest degree of amaurosis attained in the course of the case underwent no improvement in 43; in 28 partial recovery took place, while full vision was restored in 19 cases. The sources of the hemorrhages are most frequently the alimentary canal (stomach and intestines), the uterus, veins (venesection), the nose, accidental wounds, the lungs, and the urethra, in the order named. Women are attacked with only slightly greater frequency than men. The immediate cause of blindness



is probably, in the cases occurring at once, ischemia of the nerve and retina; in the others hemorrhages into the nerves, nerve-centers, or intervaginal space from malnutrition of the vessel-walls. In one case a microscopic examination showed fatty degeneration of the nerve-fibers and retina.

Incurable atrophy has occurred in some cases of *lightning-stroke*, while in one reported case the pallor of the optic disks, the small retinal vessels, and the great reduction of sight improved to normal or nearly so on the use of nitro-glycerin.

The atrophy from *affections of the accessory sinuses* will be discussed later on.

Under the head of *congenital atrophy* are grouped a number of cases, probably of various origins, which have been observed in infants. Some of these are doubtless the result of neuritis or of hydrocephalus *in utero* or soon after birth; in others, judging from the entire absence of retinal vessels, there is a fault of development; while still others, which have been observed especially after *forceps delivery*, are probably the result of injury to the bones of the head.

*Hydrocephalus internus*, although, as has been mentioned, it sometimes produces neuritis, is generally found to have produced atrophy, probably by direct pressure upon the chiasma and tracts.

In quite a large proportion of cases—Leber estimates it as high as 50 per cent.—the most careful examination fails to reveal any cause for the atrophy. In these cases and in those occurring in the course of spinal diseases men far outnumber the women, and old persons the young. In all forms of atrophy, except where caused by affections of the orbit, globe, or accessory sinuses, double-sidedness is the rule.

**Pathology.**—In the atrophy following neuritis, largely as the result of pressure both from the edema and the new connective tissue, the nerve-fibers degenerate, their sheaths (in the medullated portions) being first transformed into fatty-looking globules and granules, leaving only the nerve-fibrils, which themselves become varicose, and then shrink into very fine homogeneous fibrillæ or disappear altogether. The new connective tissue may fill up the papilla entirely, and the larger vessels running through it generally have much thickened walls.

In the simple or gray atrophy (“gray atrophy,” in a pathological sense, refers strictly to the macroscopic appearance of the cut surface of the nerve) a similar process of degeneration takes place without any ascertainable preceding inflammation. It may occur in isolated foci or may affect the greater part of the nerve at once. In old, extreme cases, either of simple, neuritic, or direct-pressure (from tumors, etc.) atrophy, all signs of nerve-substance may disappear entirely, and only a cord of connective tissue remain.

In a certain sense “normal” optic atrophy has been reported by Fuchs in the form of degeneration of a number of the most peripheric bundles of fibers in a large proportion of healthy adults. This observation is disputed by Michel.

**Diagnosis.**—The variations in the normal color of the disk are such that it is sometimes impossible to say whether an observed pallor is abnormal or not. Here the subjective tests are of great importance, the *examination of the field* for white and for colors being made with the utmost care both by full and by reduced light. To illustrate the importance of this a case may be mentioned in which, with decided atrophy of one-quarter of the disk of one eye, with an absence of one quadrant of the field for white and of the nasal half of the field for colors, no trouble was suspected with the other eye,

it being apparently normal both subjectively and objectively. But, while the vision was practically normal and its field showed no defect for white, an examination of the color-limits showed that in the nasal half of the field both quadrants had lost the perception of green, and one quadrant that of red, thus indicating with the greatest probability the implication of both nerves or of the chiasma.

In other cases, as mentioned above, an eye showing no defect in the field by good light will, when tested in a moderately dim light or by using a gray paper as a test object, show marked abnormalities. In many cases, where there is no question about the existence of atrophy, a careful consideration of the symptoms is of importance in the attempt to determine the location of the primary lesion or to decide on the nature of the general disease of which it is but one of the manifestations. Where the trouble is entirely one-sided the lesion must, in the great majority of cases, be peripheral to the chiasma, but not necessarily, for an intracranial lesion might affect one side of one optic tract so as to produce a one-sided disturbance of sight, either crossed or on the same side. In nearly all cases, however, any affection of the chiasma or tracts will produce a double-sided disturbance in the fields, generally more or less symmetrical, pressure on the chiasma in front or behind tending to produce defects in the temporal halves of the fields; while symmetrical defects in the nasal halves indicate pressure on or lesion of the outer side of the chiasma, tracts, or intracranial portions of the nerves (see pages 480 and 481).

An *enlargement of the blind spot* may indicate the existence of the so-called normal atrophy of Fuchs (granting that this actually occurs), or a mild peripheral perineuritis, or some other affection attacking only the fibers close to the periphery toward the distal extremity of the nerve. A *central scotoma*, either relative or absolute, indicates, of course, an affection of the papillo-macular bundle of fibers, but, unless there have been symptoms of congestion of the disk to indicate an implication of the distal extremity of the nerve, we have no way of judging whether the lesion is nearer the globe or the brain unless there occur with it an enlargement of the blind spot; in which case, as Berger has recently pointed out, we may with some certainty diagnose *distal perineuritis*, either present or past. In deciding between atrophy from tabes and from disseminate sclerosis it should be remembered that disorders of the pupil-reaction are much more common in tabes, while nystagmus of recent origin and paresis of other than ocular muscles strongly indicate disseminate sclerosis. The partial atrophy occurring in cerebral softening has already been referred to. In all cases of atrophy, as of neuritis, the importance of as thorough an examination as is practicable of the general system, reflexes, urine, etc. should not be forgotten.

**Prognosis.**—The prognosis of *post-neuritic atrophy* is, like that of the neuritis itself, relatively favorable, since the sight that is left after the neuritis has run its course is apt to be retained. In some cases normal vision is kept, but, as a rule, there is a reduction of central acuity with contraction of the field, except in cases in which the lesion has mainly affected the papillo-macular bundle, where a central scotoma with normal peripheric field-limits is the rule.

In the cases of *simple atrophy* the prognosis will depend upon the cause if this can be ascertained. In tabes it is almost unqualifiedly bad: once having set in, the loss of sight generally progresses until the patient is blind. In disseminate sclerosis blindness is rare, and in some cases the vision, after being much reduced, undergoes considerable improvement. In the other

cases of simple atrophy the prognosis must always be dubious if there is evidence of recent progress. The majority of them sooner or later, in spite of all treatment, end in blindness. Yet the surgeon must be careful not to be too positive in his expressions of pessimism, for every now and then one sees a patient apparently doomed to blindness, one eye being already practically blind, with marked symptoms of progressive atrophy in the other, where to his surprise the process stops and useful sight is retained for years.

In *toxic amblyopia*, the papilla occasionally presents the appearance of a general atrophy, and where this occurs, with some slight contraction of the field, with myotic pupils, and with peripheral paralysis due to alcoholic neuritis, the diagnosis of some grave incurable disease may be erroneously made in spite of the central scotoma, since such scotomata are not infrequent in some such diseases, and sometimes, though rarely, occur in tabes. On the other hand, a too favorable prognosis may easily be made with patients who have atrophy of the outer quadrant or half of the papilla, with a central scotoma, relative or absolute. In such a case, if the patient happen to use tobacco or alcohol freely, it would be natural to think of toxic amblyopia and give a relatively good prognosis, although the use of these stimulants may be a mere coincidence, and the trouble may continue to progress in spite of total abstinence, the atrophy being due to some entirely different cause. In two cases of this kind, which the writer has seen, the central scotoma was decidedly less marked, in proportion to the amount of atrophy and reduction of vision, than is usual in toxic amblyopia. The only safe plan, if there are no indications of disseminate sclerosis, cerebral softening, or other serious nervous disease, is to await the result of abstinence before making a diagnosis or prognosis.

In the rare cases of *spurious hemianopsia*, when, with *progressive atrophy*, the fields happen temporarily to closely resemble those in homonymous hemianopsia, the beginner might consider it to be a case of cortical hemianopsia and give much too good a prognosis as to the chance of progression. In such cases the history, the more pronounced atrophy of the disk, the undue reduction of the central vision, and the disturbance of the light- or color-sense in the remaining halves of the fields, will almost certainly allow the proper distinction to be made.

Where from the previous existence of a large physiological excavation, or from an unusually high normal intraocular pressure, or from the nature of the initial lesion, a case of simple atrophy exhibits a deep, sharp-bordered excavation, the problem of distinguishing it from *simple glaucoma* with no appreciable hardness of the globes may arise, and its solution may be very difficult or, in some cases, at first impossible. There are no points of difference upon which absolute reliance can be placed. The most valuable are the occurrence in glaucoma of an unusually good color-sense in proportion to the contraction of the field, and the ease with which pulsation of the retinal arteries may be produced by light pressure on the globe. All the conditions have to be carefully weighed in such a case, and occasionally no positive diagnosis can be made at once. If, after continued observation, the doubt should persist, it is better to use a myotic, or even to operate, than to allow the patient to go blind by default. (Compare with page 382.)

**Treatment.**—The results of the treatment of optic-nerve atrophy are extremely unsatisfactory. It is entirely probable that, except where it depends upon some still active inflammatory process, upon some toxemia, or upon some neoplasm which can be removed, no form of treatment has any influence upon it. This does not mean, however, that nothing should be



done for the patients. In the hope that there may still be some active process capable of being influenced, large doses of iodid of potassium may be tried, or mercury may be used if there is any suspicion of syphilis, though, as a nerve-poison, it should be used with great care if there is any spinal trouble. It is common to use strychnin in many of these cases, and it is probably well to try it in full doses (increasing from  $\frac{1}{20}$  grain three times a day, if given by the mouth, to the limit of toleration, or injecting from  $\frac{1}{40}$  to  $\frac{1}{20}$  grain under the skin of the temple. It often causes a slight temporary improvement of central acuity or of the extent of the field, and a number of cases have been reported in which its effects have seemed almost miraculous. In conjunction with strychnin, nitroglycerin should be exhibited.

*Electricity* in the form of a mild constant current may be used for a few minutes every day or two, though little more can be said for it than that it gives the patient the benefit of the doubt. Nitrate of silver is another remedy in common use which is supposed by some observers to have a particular value in checking post-neuritic atrophy, and cyanid and arsenite of gold, phosphate of zinc, and numerous other remedies have received enthusiastic recommendations. Where there are evidences of active inflammation at the base of the brain a vigorous course of salicylate of sodium, iodid of potassium, inunctions of mercury, or some form of sweat-cure, or any two or three of these together, should never be omitted. The writer's plan is generally, as in the case of neuritis, to give the salicylate a trial of about a week (15 grains eight to twelve times a day in brandy); then, if no decided effect has been produced, to change to large doses of iodid in connection with the sweat-cure (pilocarpin  $\frac{1}{5}$  to  $\frac{1}{3}$  grain in a glassful of hot whiskey and water, with the addition of 15 grains of salicylate of sodium if the pilocarpin alone does not produce free diaphoresis).

It is in these cases of meningitic atrophy that Valude has recommended antipyrin.

**Tumors of the Optic Nerve.**—The *primary tumors* of the optic-nerve trunk are most frequently of the sarcomatous type, with a tendency to myxomatous degeneration. Sarcoma, myxo-sarcoma, myxoma, and myxo-fibroma are the commonest types, in the order named, though glioma, psammoma, endothelioma, and neuroma have also been described, the last named very rarely.

The point of departure seems to be the pial sheath and the septa of connective tissue running off from it into the interior of the nerve, the tumor sometimes developing uniformly throughout its diameter, but more frequently with a tendency at first to spread along the pial sheath in the form of a cylinder, through the center of which the more or less degenerated trunk of nerve-fibers runs, though at the oldest portions its identity is often entirely lost. These tumors are generally somewhat spindle-shaped, tapering at least at one end. They never invade the globe (unless a recent case of Risley is an exception), and when they grow forward close to it a sharp constriction separates them from it; when the tumor is continued into the cranial cavity there is a narrowing corresponding to the optic canal.

From a pathological standpoint, though not necessarily differing in the symptoms which they produce, are to be distinguished the growths which take their origin in the dural sheath. They are apt to be fibromata, endotheliomata, or sarcomata; they generally affect the nerve-trunk only by direct pressure or by interfering with its blood-supply.

As *secondary tumors* glioma and melanomatous sarcoma, spreading from the interior of the globe, are most common. Carcinoma has also been



observed, in one case as metastasis from the kidney; in another, that of Krohn, already referred to as unique, a metastasis from a carcinomatous ovary occurred in each optic nerve immediately behind the globe. Gummata and sometimes very extensive tuberculosis of the optic nerve have also been reported. In the case of Sattler the tuberculosis of the nerve and its sheaths produced a tumor 18 mm. in diameter by 25 mm. in length. Michel has reported an unique case in which a patient, suffering from elephantiasis of the leg, but with good sight, was found after death to have the chiasma and the intracranial portion of one nerve very much thickened by the uniform distribution, between the bundles of fibers, of numerous fibrils similar to those of elastic tissue.

**Symptoms.**—Tumors of the nerve are apt to occur in children, and there is a certain amount of evidence to indicate that contusions of the eye and its vicinity play a part in their etiology, though sometimes their beginnings are probably congenital. Their growth is slow, and pain occurs, if at all, only after they have attained considerable size. If the patient is a child, usually the first symptom to attract attention is protrusion of the globe. This is at first, and sometimes throughout, straight forward, but as the tumor gets larger its impingement upon the upper and inner walls of the orbit sometimes forces the eye slightly down and out. In this stage the general motility of the globe is sometimes impaired, while in the early stages it is remarkably well preserved.

If examined early, the eye may show signs, sometimes very pronounced, of optic neuritis; later on, of atrophy. The pupil may be wide through pressure-paralysis of the oculo-motor or from the loss of sight. In older patients the existence of the tumor is frequently first suspected from the loss of sight, which generally progresses rapidly, though to this there are occasional marked exceptions, as in the case of v. Graefe, where the chiasma and adjoining portions of the optic nerve were found converted into a gliomatous tumor in which it was difficult to make out any of the scattered nerve-fibers, although up to a short time before death the sight had been more than normal. In a more recent case of Wiegman, a well-developed tumor of the trunk of the nerve, spreading the bundles of fibers widely apart, existed with a vision of  $\frac{2}{20}$  (in the other eye  $\frac{20}{20}$ ) and a normal field. In such cases the development must have taken place very gradually, so as to allow the nerve-fibers to accustom themselves to the pressure and change of position.

**Diagnosis.**—The main points in the diagnosis between these and other tumors of the orbit are the slow and relatively painless progress (though this may apparently be hastened by an injury), the propulsion straight forward or nearly so, the long-retained motility of the eyeball, and, with the exceptions noted above, the early loss of sight.

**Prognosis.**—Prognosis as to sight is of course unqualifiedly bad, that as to the chance of retaining the globe fair, while as to the prevention of recurrence after removal it is decidedly good unless there be involvement of the extra-orbital part of the nerve. To help decide this point, an examination of the field of the other eye is very important, for if it show a well-marked defect, without other cause, an implication of the chiasma is probable; and, while this should not necessarily contraindicate an operation, the prognosis should be very carefully guarded.

**Treatment.**—Removal is the only treatment allowable, and it is probable that this can, in the majority of cases, be done with retention of the eyeball, although hitherto the globe has in most cases been sacrificed also. In 8 cases, beginning with one of Knapp's, the nerve has been cut close to the eyeball and

at the extreme apex of the orbit, and the intervening portion of the nerve with the tumor removed, the eye being left in place. In most cases, the internal or external rectus muscle was cut to aid in exposing the tumor, but in one case (Knapp's second one) the tumor could be brought into view through an incision between the internal and inferior rectus and removed without cutting any muscle. In 4 of these cases the eye retained its normal appearance, in 3 it became more or less phthisical, and in 1 there was sloughing of the cornea through exposure from extreme protrusion. The method to be recommended is that of Lagrange,<sup>1</sup> who enlarges the external commissure, cuts the external rectus, leaving attached to it a long thread, puts a thread through the tumor by which it is drawn forward as far as possible while the nerve is being cut at the external optic foramen. The nerve is then cut close to the globe, the tumor removed, and the external rectus and conjunctiva reunited. Since one of the subsequent dangers is sloughing of the cornea from exposure (in Knapp's case this occurred in spite of repeated suturing of the lids), it is well to check the bleeding as quickly as possible by pressing back the ball firmly before stopping to suture the muscle; this is to be followed by a pressure bandage and prophylactic lid sutures.

**Hyaline Bodies in the Optic Disk.**—These bodies (known also as *colloid bodies*, *verrucosities*, or "*Drusen*") were first discovered in microscopical specimens examined by Müller and by Iwanoff, and for years little was known of the ophthalmoscopic picture which they presented.

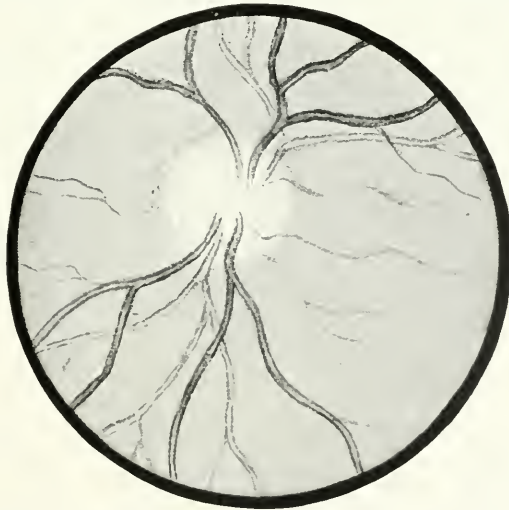

FIG. 264.—Moderate development of hyaline bodies at border of optic disk.

**Symptoms.**—When seen during life, if there are but few of them and they are rather deep-seated, they can be barely distinguished as somewhat spherical bodies of a lighter hue than the rest of the disk. In this case they are best seen, as Liebreich suggested, by throwing the brightest part of the light a little to one side of them. When nearer the surface they may be scattered through the disk or occur more commonly in groups at its periphery (Fig. 264). They are somewhat translucent, and in some cases give back quite a brilliant reflection. When they project well above the surface of

<sup>1</sup> Krönlein's plan of temporarily resecting the outer bony margin of the orbit may be employed, but it probably is very seldom necessary in optic-nerve tumors.

the disk they often remind one of half-soaked grains of tapioca. In other cases they are of a denser or slightly yellowish white. In the direct image, they appear to be about 2-3 mm. in diameter, but occasionally bodies two to three times as large are seen. The entire border of the nerve is occasionally obliterated by them, and sometimes they encroach upon the disk so as to entirely conceal its normal tissue, in its place appearing a mulberry-like mass, from the center or sides of which the blood-vessels appear. A slight encroachment upon the retina is common, and occasionally isolated granules are seen well out from the main body. More rarely large masses of them develop out from the edges of the disk into the retina. Fig. 265 represents such an

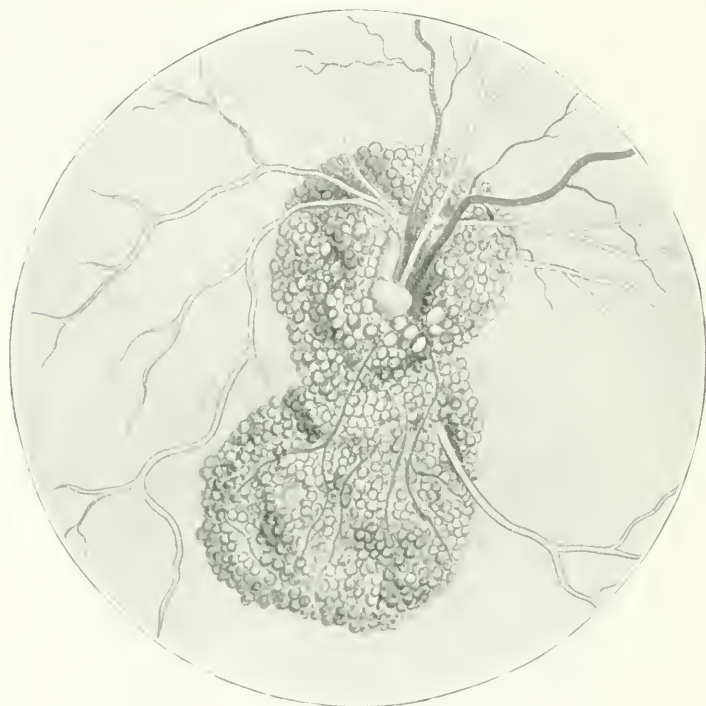

FIG. 265.—Extreme development of hyaline bodies in optic disk and retina.

extreme case, in which some of the arteries appeared as white cords with a very minute column of blood in the center. In this case, repeated small hemorrhages took place from the retinal vessels.

The affection is a rare one, occurring in the writer's experience in 1 out of about 2000 cases. It is met most frequently in cases of retinitis pigmentosa, but, aside from this, the eyes in which it is seen with the ophthalmoscope are, in other respects, often entirely normal, though there is some rather unsatisfactory evidence tending to connect its origin with injuries to the eye, with neuro-retinitis, and with Bright's disease.

Few cases have been observed long enough to note any change in the ophthalmoscopic appearance, but where this has been done a gradual increase in the number of the bodies has sometimes been noticed. It is generally stated to be a double-sided affection of advanced life, but the writer has seen it quite as often in young adults as in older patients (in one case at nine years), and in one disk alone as often as in both disks.

**Pathology.**—Our knowledge of the more intimate character of these bodies we owe chiefly to Hirschberg and Cirincione, Gurwitsch, de Schweinitz, and Sachsalber. They are found to be made up of a rather hard hyaline substance, the smaller bodies, on cross-section, showing well-marked concentric lines, the larger bodies being made up of a number of the smaller ones more or less blended together. At points they show a tendency to calcareous degeneration. Tincture of iodine gives the substance a yellowish color, and no amyloid reactions are obtained with saffranin and methyl-violet. The earlier view was that these bodies had the same origin as the colloid excrescences of the *lamina vitrea* of the choroid, while the tendency at present is to regard them as something entirely different. It is certain that they have no necessary connection with the *lamina vitrea*, for, while a favorite place for the development of the largest masses is just between the termination of this membrane and the central vessels of the nerve, they may also occur well out in the retina and in the nerve, posterior to the lamina cribrosa. Granting this, it has not been shown that their composition differs essentially from that of the "Drusen" of the choroid (consult Fig. 318, page 496).

**Diagnosis.**—In the less pronounced cases, the affection is easily overlooked, for it is only by careful examination by the direct method that the rounded outlines of the bodies can be made out. In a more pronounced form, especially where they are grouped around the periphery of the disk, they may be and have been mistaken for optic neuritis, from which, however, a careful direct examination will always enable them to be distinguished. The most pronounced cases look like nothing else to be seen at the disk, but they might easily puzzle the beginner, especially since, in many text-books, they are not mentioned.

**Prognosis.**—In the cases observed during life, the vision has usually been found to be normal (except in the cases accompanying retinitis pigmentosa), in some, even where they were so abundant as to nearly conceal the disk; and where moderate development of them is discovered by accident, as is generally the case, they need cause no alarm, but it remains to be seen whether in extreme and progressive cases they may not cause serious trouble. The case represented in Fig. 265 was one-sided, and the eye was entirely blind, but it is not certain that the blindness may not have been due to some other cause.

**Treatment.**—Treatment is not necessary in the great majority of cases, and it is not easy to understand how anything could be used that would affect them.

#### **Hemorrhages in the Optic Nerve or in the Intervaginal Space.**

—After a hemorrhage at the base of the brain or in the optic canal, or even from a more peripheral source (after a contusion of the eye), the blood may flow into the intervaginal space and distend it widely at its distal extremity.

In such cases the sight may be suddenly lost, the ophthalmoscope showing a somewhat blurred disk, with the central vessels reduced in size, sometimes with a red spot at the macula surrounded by a grayish area, as in embolus of the central artery, and, later on, the dissolved hemoglobin may find its way into the disk, so as to be seen with the ophthalmoscope, leaving deposits of pigment there by which the nature of the original process may be recognized after months or years. The nerve atrophies, and the vision does not return at all, or does so but imperfectly. Where there is no history of violence the affection might be mistaken for a rapidly developing neuritis or for embolus or thrombosis of the central artery, which latter may indeed possibly be produced by it.



Much more rarely a hemorrhage occurs within the pial sheath, and may find its way along the septa of the nerve-trunk. This has been observed in connection with Bright's disease.

**Optic-nerve Lesions from Affections of the Accessory Sinuses.**

—Inflammation of any of the sinuses or of the ethmoid cells may cause optic neuritis and atrophy, by spreading to the orbital tissue or to the cranial cavity; or by the direct pressure of their distended walls upon the orbital tissue, in the case of the ethmoid cells, and possibly of the maxillary and frontal sinuses.

Affections of the sphenoidal sinus have an especial significance for the ophthalmologist on account of the intimate relation between the walls of this cavity and the optic nerve. Fig. 266 shows part of a coronal section

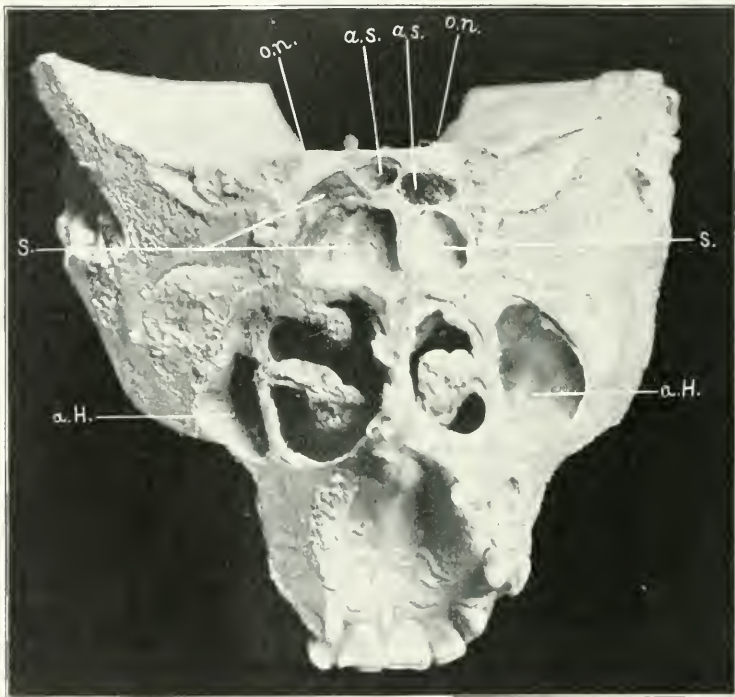


FIG. 266.—Coronal section through posterior part of optic canal: *o.n.*, optic nerve; *s.*, sphenoidal sinus; *a.s.*, anterior sphenoidal or posterior ethmoid cell; *a.H.*, antrum of Highmore.

through the skull passing through the optic canals. A glance at the left side of it, with a realization of the fact that the thin bony partition separating the optic canal from the sinus is sometimes imperfectly developed, will show how easily an inflammation of the sinus might cause localized neuritis, with subsequent descending atrophy, through the diffusion of ptomaines into the nerve, or an actual infection of the intervaginal space, leading to perineuritis and choked disk; or an atrophy through direct pressure, if the walls of the sinus were distended by fluid or by a tumor. These considerations should lead one to take the sphenoidal sinus into account in all cases of obscure optic-nerve trouble, especially since at least one case has been reported (Holmes) in which a puncture of the anterior wall of the sinus drew off a collection of pus and cured an optic neuritis.

The right side of the section represented in Fig. 266 illustrates a point

which seems to have attracted very little attention—namely, that in some heads, on at least one side, the cavity in closest proximity to the optic canal is not the main sphenoidal sinus, but an entirely separate cell, opening into the nose by an independent foramen which is sometimes so large that the cell could, with propriety, be described as the upper extremity of the nasal cavity. A collection of pus in this space might cause a disturbance of sight, with symptoms of suppuration of the sphenoidal sinus, although an operation on the latter would give no relief. To operate on this anterior sphenoidal cell or prolongation of the nasal cavity would be more difficult and dangerous than to puncture the main sphenoidal sinus, but a knowledge of its occasional relation to the optic canal may serve to explain some cases of optic-nerve trouble in which an ordinary sphenoidal operation gives negative results.

**Congenital Anomalies of the Optic Nerve.**—Aside from *congenital atrophy* of the optic nerve due to intra-uterine neuritis, hydrocephalus, and other causes, the nerve in the various degrees of *microphthalmos* and *anophthalmos* shows more or less marked signs of imperfect development. It may be entirely absent, or represented only by a cord of connective tissue, or it may simply have an abnormally small proportion of nerve-fibers. Even more interesting is the case cited by Manz, which, though old, is apparently quite authentic, of entire absence of any decussation of the optic nerves, the latter running direct to the respective sides of the brain, without any sign of a chiasm.

Some of the anomalies of the nerve which have been discovered with the ophthalmoscope are discussed in the section on the Ophthalmoscopic Examination of the Fundus (pages 191–195). Of these, the condition known as *coloboma of the optic nerve* or *coloboma of the optic-nerve sheath* is the most important. In the most common type, one sees in place of the disk an excavation several times as large as the ordinary papilla, generally much deeper and with a sharply-excavated border below, while, above, its floor comes gradually up to the level of the surrounding retina; the main vessels curve abruptly over the lower edge, while the bottom of the excavation may be entirely free from them or may have some running across it to the upper part of the retina, crossing the upper border without any break in their continuity at that point. The excavation is surrounded by a generally complete pigment ring, outside of which there is often a narrow white zone or crescent. If there is any sign of normal disk-tissue, it is apt to be above. More rarely, the entire floor of the excavation is deep below the retina, with vessels curving sharply around its border at various points, though chiefly below and above (consult Fig. 141).

The few microscopical examinations which have been made of the common form of this anomaly show that it depends upon the non-closure of the fetal optic-nerve fissure; the central vessels enter the nerve proper only in part, or more commonly not at all, but enter the eye through the mass of connective tissue which takes the place of the dural sheath below. In one case (Magnus) the fissure seems to have been at the nasal side instead of below the nerve. The deep atypical excavations which are sometimes seen within the borders of otherwise normal papille are probably due to a less-marked failure of development of the same nature.

Another type of anomaly, which has also been described as *coloboma of the nerve*, consists in the absence of a zone of choroid (often wider below) around the otherwise moderately normal papilla, the blood-vessels appearing near the center of the latter and passing across the borders of the zone without any displacement or other sign to indicate any considerable excavation. These cases, in the opinion of the writer, would be more accurately designated

*circumpapillary coloboma of the choroid*, and to this class the cases exhibiting mere crescents of choroidal absence below the papilla are most probably allied.

Coloboma of the nerve is generally associated with imperfect sight and often with nystagmus or microphthalmos. It may affect one or both eyes, and its etiological relationship to coloboma of the choroid is shown by its

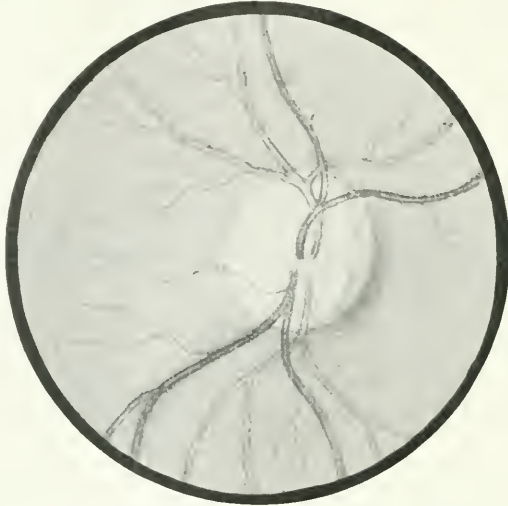

FIG. 267.—Band of connective tissue in optic disk.

occurring sometimes in the same eye with the latter, or in one eye of an individual having coloboma of the choroid and iris in the other eye.

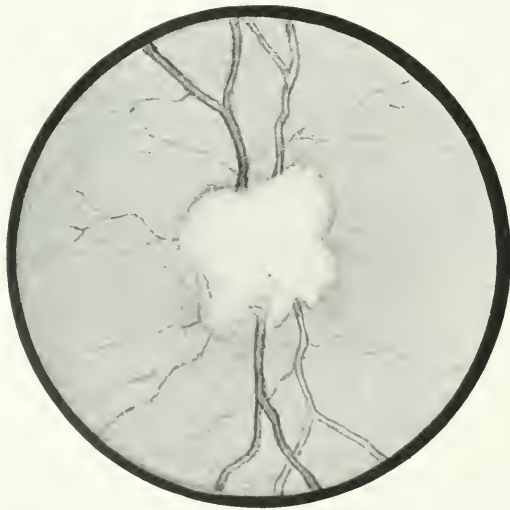

FIG. 268.—Extreme development of connective tissue in optic disk.

The *bands of connective tissue* not infrequently seen upon the disk may be, as Masselon suggests, prolongations of the lamina cribrosa, though they sometimes, as in Fig. 267, appear to have no connection with it. In extreme cases, as shown approximately in Fig. 268, the entire disk may be concealed by a pearly, bluish-white mass of connective tissue.

# AMBLYOPIA, AMAUROSIS, AND DISTURBANCES OF VISION WITHOUT OPHTHALMOSCOPIC CHANGE.

BY CASEY A. WOOD, M. D.,

OF CHICAGO, ILL.

THE terms *amblyopia* (*ἀμβλύωσις*, dull, and *ὄφθαλμος*, the eye—*i. e.* obscurity of vision) and *amaurosis* (*ἀμαυρωσις*, dark, a marked blindness) have, since the days of Hippocrates, been applied to different degrees of loss of sight without sensible change in the ocular structures. The invention of the ophthalmoscope and the use of the microscope have greatly diminished the number of these affections, but there still remain "functional" diseases of the eye designated either by the dimness of vision (*amblyopia*) or decided loss of sight (*amaurosis*) that forms the most prominent symptom. Eyes blind from inflammatory diseases, as well as from certain congenital changes in the fundi, may also be described as *amaurotic*.

**Congenital Amblyopia.**—When an eye has never taken part in the visual act, as in cases of early squint, congenital cataract, corneal scars, or other obstruction to the light-rays, the accompanying dim vision may be altogether or partly the result of simple non-use; hence the terms *amblyopia*, *exaopsia*, and *argamblyopia* (Gould). In such cases, especially in squint, where the defective sight is largely due to the presence of high degrees of hyperopia or astigmatism, or both, correction of this ametropia, with exercise of the eye, may result in much improvement of sight or even in a return to normal vision. In other instances, however, correcting lenses do not help, and we may then conclude, even in the absence of positive signs, that structural changes or defects exist, probably in some portion of the extra-bulbar nervous apparatus.

In still another class of cases careful examinations with the mirror show in the nerve-head, retina, or choroid slight departures from the normal appearances. The papilla especially may be irregularly shaped or dimmed in outline, while the perimeter reveals *scotomata* and peripheral contractions of the field. Such anomalies as colobomata of the opticus, choroid, retina, and iris, as well as non-development of the whole eyeball (*microphthalmos*), are usually associated with, and are described as, examples of congenital amblyopia. Many of the ocular diseases of extra-uterine life also affect the fetal eye. Among these are glaucoma, iritis, chorio-retinitis, and diseases of the optic nerve, all of which have been classed with the congenital amblyopias.

**Congenital Amblyopia for Colors** (*Subnormal Color-sense; Color-blindness*).—Total absence of the color-sense (*achromatopsia*) is rare as a congenital condition and apart from disease, but it occurs to some extent and for some colors in about 3 per cent. of the whole population. It is quite rare (0.20 per cent.) in women, is sometimes hereditary, and is almost always bilateral.

By far the commonest form of color-blindness is exhibited when the



individual fails to detect the red and green in mixtures containing these colors. As a result of this defective color-sense, or *dyschromatopsia*, the pure greens are readily mistaken for grays and shades of red, and *vice versa*.

A less numerous class name correctly most of the saturated primary colors, but are very liable to miscall all or most of the color mixtures. They see little or no difference between orange and red, blue and purple, or violet and blue. In other words, they perceive in a compound only the predominating color. Artificial light generally adds to the difficulty which these persons experience in selecting colors.

The nomenclature of color-blindness is built upon various theories of color-perception; thus, the two forms of *dyschromatopsia* just described may be designated "red-green" and "blue-yellow" blindness, or we may, with propriety, speak of red, green, and violet *dyschromatopsia* (see also pages 98-100).

Whether the structural defects that give rise to the various forms of sub-normal color-perception exist at the periphery or in the central portions of the optic tract, they are equally incurable (see also Appendix, page 603).

**Reflex Amblyopia.**—Both amblyopia and amaurosis have resulted from "reflex irritations" conveyed from remote organs, but such cases are rare. Loss of sight has been attributed to diseases of the reproductive organs, spinal cord, and digestive apparatus. Well-authenticated examples of amblyopia from intestinal worms, decayed teeth, diseases of the nasopharynx and its neighboring cavities (especially neoplasms and muco-purulent collections) have also been recorded. In most of these cases there were no fundus changes, and improvement or cure followed successful treatment of the distant lesion.

The **etiology** of reflex amblyopia is very obscure, and we must, for the present, continue to hold to the vague hypothesis of vaso-motor disturbances, affecting the nutrition of the retina in some instances and of the central ganglia in others, until similar mysteries of "functional disorders" elsewhere are cleared up. Probably some of these alleged reflex manifestations are really unrecognized cases of hysterical amblyopia.

**Uremic Amblyopia, or Amaurosis.**—This loss of vision occurs occasionally in the toxemia of Bright's disease, but is most frequently noted in those states of the system where albuminuria is found as a transient condition—viz. in pregnancy and the late stage of scarlatina. It affects both eyes, comes on suddenly, often lasts but a short time, and disappears as quickly as it came. It is almost always associated with other uremic symptoms, especially with convulsions, headache, vomiting, and coma. The blindness, which may be complete, is probably due to a temporary affection of the visual centers produced by the uremia.

The **prognosis** is uniformly favorable. Permanent blindness results only when organic lesions of the nerve and retina (albuminuric retinitis and optic neuritis) are present.

*Ophthalmoscopically*, nothing is to be seen in the retina, although several writers describe fulness of the vessels and a swollen appearance of the papilla.

The **treatment** is that of uremia.

**Glycosuric Amblyopia.**—Apart from the cataract of diabetic patients and those retinal and optic-nerve lesions that so closely resemble the fundus changes found in Bright's disease, there is sometimes observed a dimness of vision that simulates the amblyopia from tobacco and alcohol. There are, in these cases, no alterations visible with the mirror, but central scotomata for red and green can always be mapped out.

As the writer has elsewhere<sup>1</sup> pointed out, the *diagnosis* is somewhat difficult when the diabetic patient is a smoker, but in such instances the color-defect often extends to blue and white. In time white becomes involved at the periphery of the field also—a condition of things never found in pure tobacco or alcohol amblyopia.

The *pathology* is obscure, but Horner's views of the causation of alcohol-tobacco blindness may find acceptance in the case of glycosuric amblyopia—viz. that it is due to malnutrition of the macular fibers, in this instance brought about by glucose in the blood.

The *prognosis*, unlike that of tobacco amblyopia, which it resembles, is grave; in spite of treatment (of the diabetes) the case usually goes on to simple optic-nerve atrophy and terminates in total loss of sight.

**Malarial Amblyopia.**—It has been observed that during the course of intermittent fever and other diseases of malarial origin an amblyopia accompanied by fundus changes, and usually affecting one eye, may set in. The attacks are generally of short duration, but in some instances persist for weeks. The dim vision is commonly attributed to the action of the malarial poison upon the optic nerve and retina. It must not be forgotten, in this connection, that quinin, so universally administered in malarial diseases, is known to produce a temporary amblyopia quite apart from the well-known, serious fundus lesions of quinin-amaurosis, and the writer is convinced that some of the reported cases of malarial amblyopia are merely examples of the ocular symptoms of a mild quinin-intoxication.

True malarial amblyopia improves under quinin and other antiperiodics, and complete recovery is the rule.

**Amblyopia from Loss of Blood.**—The optic nerve bears even a temporary anemia very badly, and many secondary alterations in its tissues may be directly traced to malnutrition of a kind that would be successfully resisted by other nerves of special sense. Instances of a temporary loss of vision following excessive hemorrhage are quite common, especially from ulcer of the stomach or intestines. *Post-partum* floodings may also produce this form of amblyopia. An attack of dim vision may be the forerunner of *optic atrophy* (usually preceded by *optic neuritis*) setting in a week or ten days after the loss of blood. The papilla, at the time of the bleeding, is quite pale and the arteries are small.

**Treatment.**—The treatment of the primary amblyopia is the transfusion of blood or the intravenous injection of physiological salt solution. Diffusible stimulants and rest in bed, with small and repeated quantities of easily assimilated food, should be prescribed. These should be followed by tonic mixtures of iron and strychnin. The remedies employed for the relief of the later eye-troubles following profuse hemorrhage must be regulated by the form the fundus lesions assume.

**Amblyopia from the Abuse of Drugs.**—The poisonous agents that produce ocular symptoms are so numerous that anything like a complete account of all of them would be inappropriate here. In the following list the most important ones are italicized: *tobacco*, *alcohol*, *carbon disulphid*, *iodoform*, *lead-salts*, *quinin*, salicylic acid and other salicylates, cocaine, snake-venom, *mydriatic alkaloids*, *ptomaines*, carbolic acid, *male-fern*, aconite, chloral, santonin, picric acid, digitalis, tea, coffee, chocolate, gelsemium, ergot, coal-

<sup>1</sup> *The Toxic Amblyopias*, v. p. 14. For a full account of this matter see Dr. W. O. Moore's paper on "Diabetic Affections of the Eye," *N. Y. Medical Journal*, Mar. 31, 1888; Dadd: *Archives of Ophthalmology*, vol. xxiv. No. 2; Hirschberg: *Deutsch. med. Wochenschr.*, Mar. 26, 1891.

tar products, arsenic, naphthalin, potassium bromid, ergot, amyl nitrite, nitrobenzol, mercurial compounds, silver nitrate, antipyrin, curare, and a large number of other drugs.

**Etiology and Pathology.**—*Tobacco-, alcohol-, and tobacco-alcohol* intoxications present by far the commonest examples of toxic amblyopia. It is now admitted that alcohol or tobacco alone may produce partial loss of vision, but inasmuch as the smoker is usually a drinker and as the alcoholic commonly smokes, we almost always have to deal with mixed examples of intoxication.

Sachs (with the English school) believes that alcohol predisposes to tobacco-poisoning by producing dyspepsia. Horner is convinced that neither alcohol nor tobacco, as such, produces the pathological changes found in the opticus. Together these drugs produce a chronic gastric catarrh, which, in its turn, brings on a chronic anemia of the optic nerve, terminating in the retro-bulbar neuritis characteristic of alcohol and tobacco amblyopia.<sup>1</sup>

Samelsohn, Ulthoff, and others have demonstrated by autopsies that the essential lesion in this disease is an axial, interstitial neuritis, beginning somewhere between the papilla and brain, and probably extending thence both toward the center and the periphery (see Plate 7). The fibers affected are those that supply the macular region—one-fourth or one-third of the whole number. The axis-cylinder and the true nervous elements mostly escape. The trabecular tissues enclosing these increase both as to number and size and press upon the nerve-fibers, bringing about their partial atrophy, just as the connective elements in cirrhotic liver and fibroid phthisis encroach upon the more highly organized tissues of the liver and lungs.

Recently, Nuel has revived the theory that central toxic scotoma is not primarily a neuritis of the macular bundle, but a disease of the macula lutea, causing degeneration of its cells, and that the optic-nerve changes are secondary to the destruction of the nerve-cells of the macula. Usher and Dean have observed macular-fiber degeneration follow experimentally-produced retinal lesions.

The majority of these cases occur in persons over forty years of age; examples of the disease in the female sex are uncommon, and we must remember that this form of toxic amblyopia occurs only in those who have an idiosyncrasy toward tobacco or alcohol.

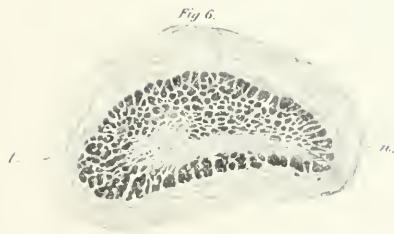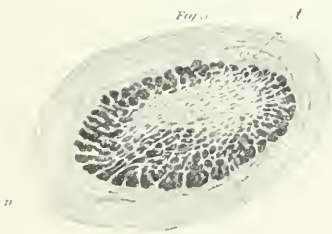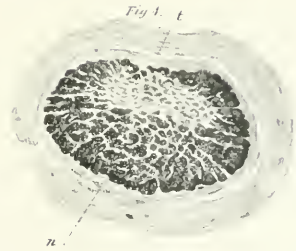
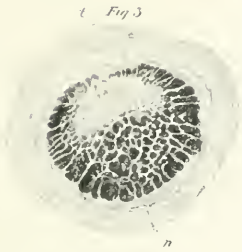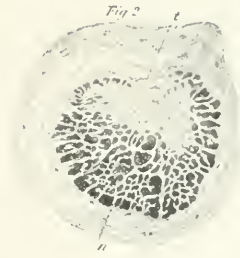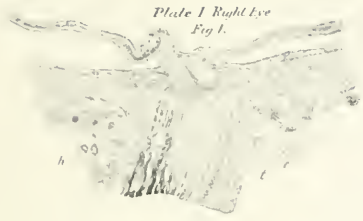
**Symptoms.**—The symptom most complained of is "misty" vision; the patient speaks of "seeing through a fog" or "through smoke." Even earlier than this he finds difficulty in reading or doing any other form of near work, for which he usually seeks glasses or requests to have his reading lenses changed. His visual acuity for both distance and near may fall as low as  $\frac{6}{200}$  and J., 14. He now fails to distinguish red and green objects, and on examination with the perimeter negative central scotomata, in the form of horizontal ovals extending from the blind spots and including the fixation-points, can be mapped out (Figs. 269 and 270). Blue and white are rarely affected in pure cases of tobacco amblyopia.

Owing to the situation of the scotomata, most patients are *day-blind* and see best with a dilated pupil—*i. e.* toward evening or in a dimly-lighted room.

The mirror sometimes reveals alterations in the disk. When these are absent it may be assumed that the atrophic changes have not yet reached the

<sup>1</sup> The reader is referred, for a full description of all that is known of the toxic amblyopias, to Dr. Geo. E. de Schweinitz's work on that subject. A smaller and less complete monograph by the writer of this article, bearing the same title, appeared two years earlier.

PLATE 7.



Sections of the right optic nerve in a case of toxic amblyopia, showing degeneration of the papillomacular bundle; Weigert's stain (de Schweinitz).

FIG. I.—Longitudinal section of the posterior half of the right bulbus and five millimeters of the optic nerve.

FIGS. II, and III.—Transverse sections of the optic nerve, eight and thirteen millimeters, respectively, behind the globe.

FIGS. IV, and V.—Transverse sections of the optic nerve in the region of the optic foramen.

FIG. VI.—Transverse section of the nerve in the intracranial region.





nerve-head. The most constant signs are hyperemia of the papilla in the early stages of the disease, and later a *triangular atrophic* area, occupying the temporal third of the nerve-head and corresponding to the macular bundle of fibers.

**Diagnosis.**—The diagnosis of the retro-bulbar neuritis produced by tobacco and alcohol rests upon the account just given.<sup>1</sup> The disease may

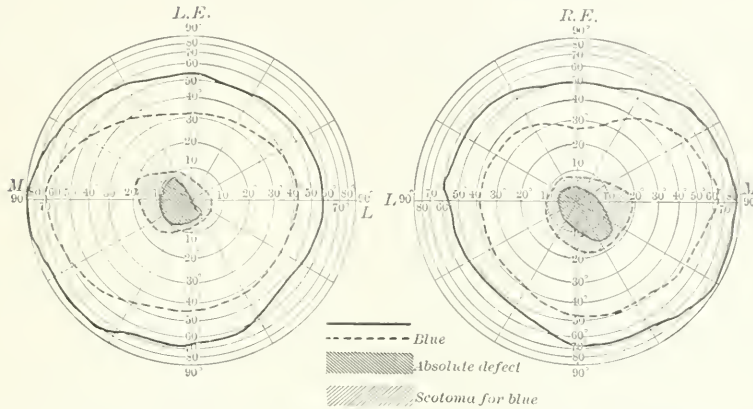


FIG. 269.—Alcohol amblyopia. Small absolute central defect, surrounded by a scotoma for blue (Uthoff).

be mistaken for non-toxic orbital axial neuritis, disseminated sclerosis, locomotor ataxia, and scotomatous atrophy of the optic disk. Everything considered, it is not difficult to differentiate these forms of ocular disease (see also page 447).

Uthoff thus summarizes the points of diagnosis between the retro-bulbar neuritis of tobacco and alcohol and that due to other causes, such as syphilis,

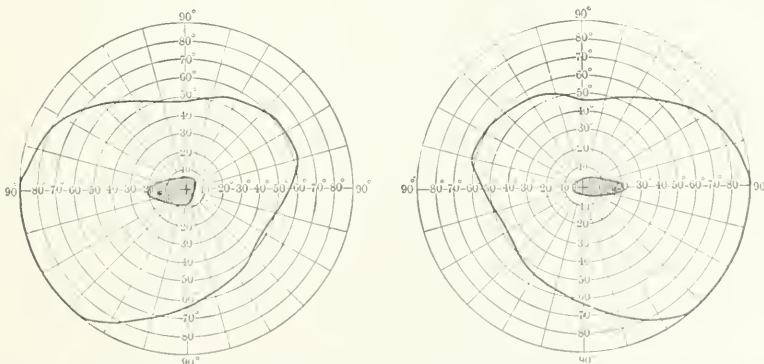


FIG. 270.—Typical oval scotomata from a case of tobacco-amblyopia. The patient, aged sixty, had smoked four pipes of tobacco daily, and an occasional cigar, since he was nineteen: a moderate beer-drinker (de Schweinitz).

rheumatism, disorders of menstruation, cold, diabetes, etc., as follows: 1. In true toxic amblyopia the central scotomata are almost invariably confined to red and green. 2. The scotomata and visual disturbances are bilateral, and the former are confined to the center of the field. 3. Vision does not fall

<sup>1</sup> For the differential diagnosis between the various forms of central amblyopia, see de Schweinitz, *loc. cit.*, pp. 85, 86.

below  $\frac{2}{20}$ . 4. The form of the scotoma is that of an oval, including both blind spot and fixation-point, with its long axis lying above the horizontal meridian. 5. The vision becomes *gradually* less. 6. The disease affects men above forty years of age. 7. *Pain is noticed on extreme ocular movements in essential retro-bulbar neuritis*, but is invariably absent in the toxic form.

De Schweinitz says of the non-toxic variety that there is a history of chilling of the body, excessive exertion, suppression of menses, or of infectious diseases, rheumatism, etc.; there is no special relation to sex or age. The visual acuity is greatly disturbed; sometimes there is complete blindness. Often there is a positive scotoma tending to pass to the nasal side of the fixation-point, and not specially oval or horizontal. Peripheral contraction of the field for white and colors may be present, with woolliness of the whole disk and distention of the veins. It is often rapid in onset, and is frequently slow in responding to treatment.

**Prognosis.**—This is favorable, even when the blindness has lasted for a long time. When total abstinence from the toxic agent is persistently practised and there is no other optic-nerve disease, sight should, with judicious management, be restored in from six weeks to three months.

**Treatment.**—This consists, first of all, in stopping the use of tobacco and alcohol in all their forms. It must be remembered that the amblyopia is but part of a general intoxication, and that chronic gastric catarrh is usually present. The digestive power is consequently often weak, and it should be fortified by appropriate means. Proper food, exercise, bathing, and regulation of the bowels are valuable adjuncts to tonic remedies. The Turkish bath has a decided value, especially in alcoholic cases. The chief aim should be to furnish a supply of good blood to the badly-nourished optic nerve. Most of the so-called specifics, nux vomica and strychnin particularly, are very useful, especially with pallor of the disk and when general toxic symptoms are present. Usually full doses of the elixir of pepsin, bismuth, and strychnin may be given internally. This treatment is accompanied by hypodermic injections of strychnin, that are gradually increased in strength until toxic symptoms are produced. The dose is then to be diminished one-fourth, and so continued for several weeks. When there is an edematous or hyperemic papilla, potassium iodid may be substituted for the strychnin. When not otherwise contraindicated and the Turkish bath cannot be readily taken, the hot pack, combined with hypodermic injections of pilocarpin (gr.  $\frac{1}{8}$ ) twice a week, is very useful, and certainly cuts short the duration of the amblyopia.

**Lead-amblyopia.**—Lead and its salts not infrequently produce amblyopia and amaurosis. These cases are most commonly found in painters, employes of paint- and lead-works, plumbers, as well as in persons poisoned from eating canned food or drinking water polluted with plumbic compounds.

The poison brings about so many changes in the brain and kidneys, as well as in the optic nerve, that it is often difficult to say whether the eye alterations are due to the direct action of the lead on the optic nerve, retina, and visual centers, or whether they are secondary to the other organic lesions. In any event, it is probable that the ocular changes *begin* in the terminal vessels of the eye as a fatty metamorphosis or obliterating endarteritis, and that subsequently the tissues supplied by these vessels undergo secondary metamorphoses.

These alterations affect the retina and papilla, and may be studied ophthalmoscopically. The commonest sign is *optic-nerve atrophy* with woolly disks and small vessels. Vision is always greatly affected, both at the center and

periphery. In another class of cases there is *optic neuritis*, with the usual appearances in and about the nerve-head; in still another a *retro-bulbar* degeneration sets in. Finally, there are states of *transient amblyopia* without ophthalmoscopic change; indeed, patients suffering from atrophy due to lead-poisoning often give a history of antecedent "attacks" of dim vision. These Gowers regards as analogous to the temporary amaurosis of diabetes and uremia, and thinks they are due to the direct effect of the lead salts upon the visual centers. In doubtful cases the excreta should be examined for lead. Oliver relates a case of progressive blindness where the urine, saliva, and nasal mucus revealed the presence of lead. In a case reported by the

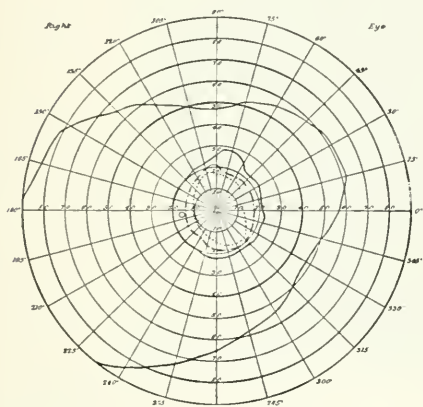


FIG. 271.—Visual field in lead-amblyopia.

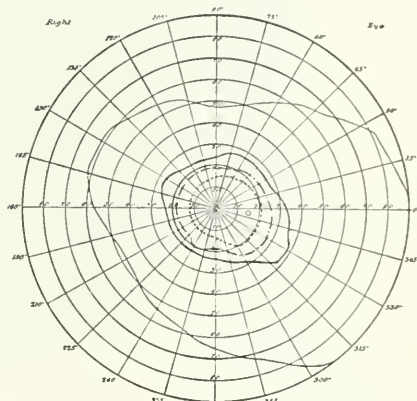


FIG. 272.—Visual field in lead-amblyopia.

writer there were marked optic-nerve atrophy, with restricted fields (see Figs. 271 and 272), and almost complete oculo-motor paresis on the left side.

**Prognosis** is favorable in the early stages of transient amblyopia, but very unfavorable when optic inflammation or atrophy has set in.

**Treatment** consists in the instant removal of the source of the poison, the administration of small doses of magnesium sulphate, the use of Turkish baths, and pilocarpin injections. Strychnin before a meal and potassium iodid after it are usually employed, but the former should be omitted when active inflammation is present.

**Quinin-amaurosis.**—Quinin, like lead, may be responsible for both a *temporary amblyopia* and an *amaurosis* with characteristic fundus changes. The blindness, in the latter instance, comes on suddenly, is often complete, and may last for several days. The pupils are widely dilated, and do not react to light, although they may to accommodation.

The ophthalmoscope shows an *absolute anemia of the fundus*. The papilla is chalky-white, and no trace of retinal vessels can be discovered. This remarkable condition is accompanied by other signs and symptoms of cinchonism, although permanent blindness is excessively rare. In severe cases the optic nerve rarely recovers entirely from the poisonous effects of the drug, and the patient henceforth exhibits decided limitations of the field (Fig. 273), often defective central vision, and usually evidences of retinal ischemia. Usually, large doses of the drug are required to produce amaurosis; but in some susceptible individuals even physiological doses have produced temporary blindness.

We are mainly indebted to Brunner and de Schweinitz for experimental proof that the amaurosis is due to a species of "edema of the optic-nerve



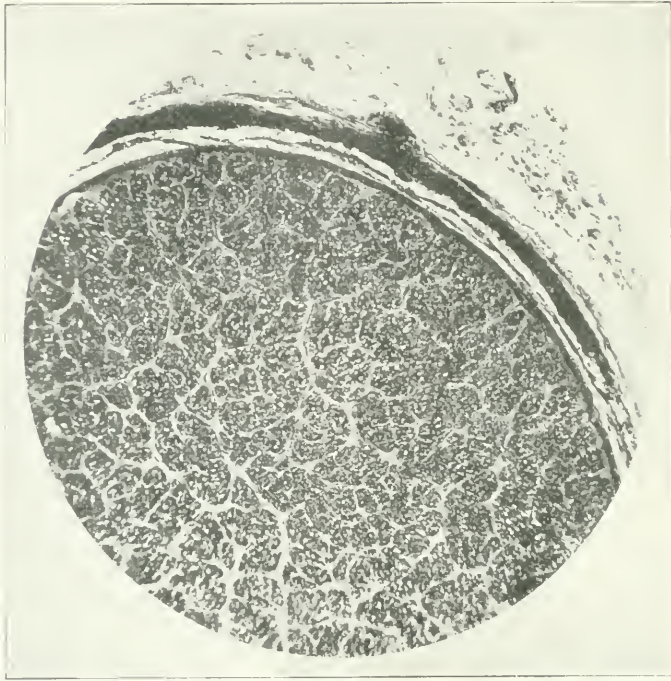


FIG. 273.—Normal optic nerve of a dog, transverse section;  $\times 125$ , Weigert stain (de Schweinitz).

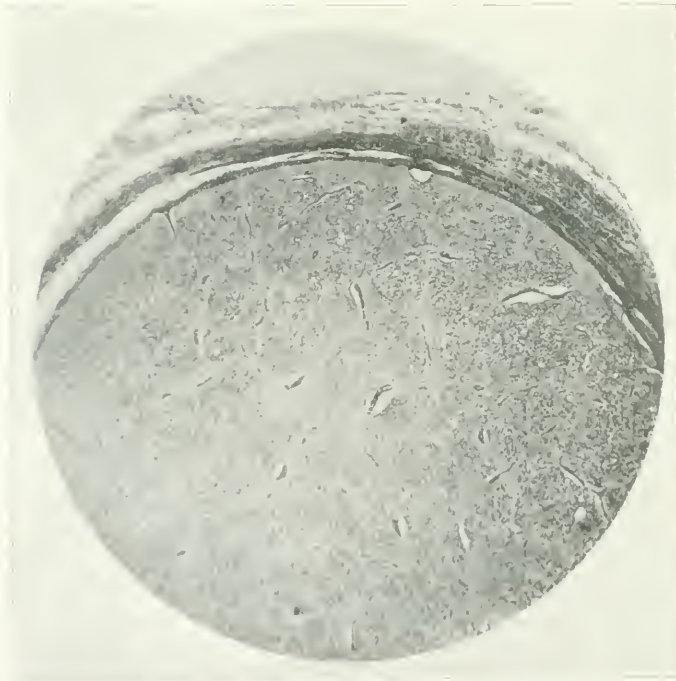
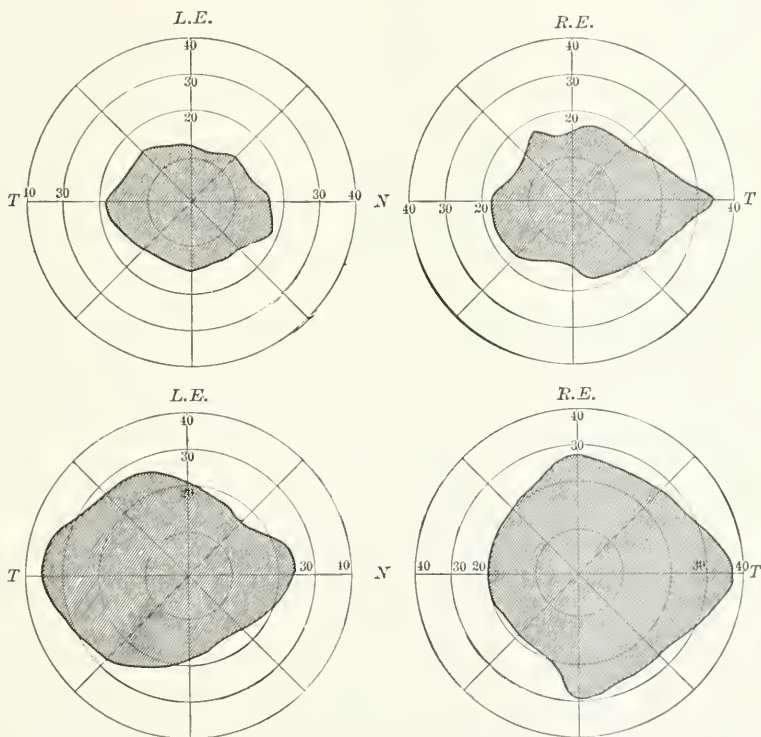


FIG. 274.—Optic nerve of a dog blind from the effects of quinin, showing almost complete atrophy;  $\times 125$ , Weigert stain (de Schweinitz).

tissue between the chiasm and eyeball and the influence of quinin on the vaso-motor apparatus, which cause excessive constriction of the peripheral circulation, and finally local changes in the vessels (endovasculitis) and atrophy of the optic-nerve fibers" (Figs. 273 and 274). De Bono believes that quinin intoxicates the protoplasmic elements of the retina, acting as a depressant poison on the rods and cones. Holden has demonstrated that the *primary* action of the drug is upon the ganglion cells of the retina.

The treatment of quinin-amaurosis is much the same as that of tobacco-amblyopia. Nitrite-of-amyl inhalations give temporary relief.



FIGS. 275, 276.—Visual fields from Gruening's case. The shaded areas represent the limits of the fields, the upper map three and the lower one six months after recovery from complete blindness.

**Ptomain-poisoning; Botulismus; Allantiasis.**—The putrefactive alkaloids found in "high" game, decomposed sausage, uncooked meat, and rotten fish (as well as the leukomains of poisonous fungi, snakes, and shell-fish) occasionally produce amblyopia as one of the symptoms of intoxication. Brieger found *ethylendiamin* to be the active principle in several cases of poisoning from decomposed food.

**Symptoms.**—These closely resemble those of belladonna-poisoning; the dim vision is transitory, and it is uniformly due to bilateral paresis of accommodation with marked mydriasis. Ptosis is also a common symptom. All the extrinsic ocular muscles may be paralyzed, from bilateral and nearly complete ophthalmoplegia externa to paresis of a single muscle. There are no fundus changes. When death does not occur and the paralyzes persist, these are the result of basilar meningitis or nuclear hemorrhages. The treatment is the same as that suited to atropin-poisoning.

Male-fern amblyopia and amaurosis are not uncommon from acute poisoning with this drug, but the ocular symptoms (except that of blindness) and the fundus changes recorded have been far from uniform. Widely-dilated pupils, followed by optic-nerve atrophy, are most commonly observed. De Schweinitz and others have experimented on the lower animals with negative results; but Nuel and others have produced optic-nerve degeneration by administering extract of male-fern to animals.

**Toxic Asthenopia.**—Some time ago the writer ventured the opinion that the employment of certain intoxicants, some of them drugs and beverages in every-day use, is not infrequently followed by minor defects of vision, the true nature of which is unsuspected by the patient or his medical attendant. These symptoms, which are commonly included in the term "asthenopia," show themselves especially as a decrease in the amplitude of accommodation and convergence. Evidences of this muscular weakness may be seen in the transient intoxication from quinin, the salicylates, iodids, bromids, alcohol, tobacco, coffee, tea, chocolate, and such forms of decomposed food as "high" game, "strong" cheese, etc. The asthenopic symptoms occasionally observed in some forms of dyspepsia probably also constitute a toxic amblyopia due to ptomain-poisoning. They properly belong to those milder types of allantiasis where the eye-signs are not sufficiently marked to be recognized by the unskilled observer.

**Hysterical Amblyopia.**—This curious form of blindness is most commonly observed in girls and women, but typical examples are not unusual in men and children. The most constant symptom is amaurosis of one eye without fundus changes. This peculiar loss of visual power sometimes follows injuries (*traumatic hysteria, traumatic neurosis*) in hysterical subjects, but it more frequently comes on without warning. The pupil usually reacts to light, but it may be dilated and motionless. The patient is often partially or totally color-blind. Sometimes there is a central scotoma.

There are nearly always other hysterical symptoms present, especially hemianesthesia (usually variable and incomplete) of the affected side, loss of the pharyngeal and corneal reflexes, ptosis, monocular diplopia, micropsia and megalopsia and blepharospasm. *The field for red and green is often larger than that for white.* Sometimes there is complete reversal of the natural order of the color-fields, blue or white being smallest, red next in size, while the field for green is largest of all (for diagrams see page 487).

**Diagnosis.**—This is sometimes difficult, especially in recent cases. It is well known, for example, that the hysterical amblyope can be made to see. An instance of this occurred in a case known to the writer where an hysterical subject sued for damages on account of injury to the head causing blindness to the right eye. Malingering was set up as a defence, because it was shown that the patient saw with the supposed blind eye when examined by prisms and a light at twenty feet. In all cases of unexplained monocular blindness without fundus alterations hysteria should be suspected, and one should be on the lookout for its other manifestations.

**Prognosis** is favorable, but the amaurosis may persist for years. **Treatment** should be directed to the hysterical state generally. Electricity, massage, outdoor exercise, and tonics furnish the best results.

**Pretended Amblyopia; Malingering.**—It is comparatively easy to detect a pretended monocular amblyopia or amaurosis, but difficult to uncover the deception of the person who claims to be blind in both eyes. He may be exposed by watching him when he does not expect it, by flashing a bright light on his face, or by making feints to strike him, for the purpose of elicit-



ing the lid or iris reflex. As Swanzy points out, one cannot depend, for detection of the malingerer, upon the pupillary reactions, because the pupils contract to light, even when the patient is quite blind, if the lesion be situated at the cortical center or in the fibers that connect it with the corpora quadrigemina. Recently Priestley Smith and E. Jackson have suggested a simple test for feigned *binocular blindness*: Place a lighted candle in front of the subject; now hold a six-degree prism with its base to the temple before one eye; if both eyes see the one behind the prism will move inward, and on removing the prism will move outward, the other eye remaining fixed.

Many plans have been devised for the detection of simulated *monocular blindness*, but, on the whole, *Suellen's colored-letter test* for distant binocular vision is the most valuable. *The suspect should be watched that he does not close the alleged blind eye during the examination.* A frame holding transparent letters, colored alternately red and green and adapted to five or six meters' distance, is hung in a window or is highly illuminated from behind. A reversible spectacle-frame, fitted with a plane red glass on one side and a green glass on the other, is placed on the subject's face. The red letters can be distinguished only by the eye covered with the red glass (which shuts out the green rays), and the green letters can be read through the green glass only, because the red glass cuts off the green rays. If the subject reads red and green types with both eyes open, or during several trials, reads letters of a color that does not correspond with that of the glass in front of his admittedly sound eye, he must have seen with the alleged blind eye.

Dr. Harlan has suggested that a +16 D. lens be placed before the eye acknowledged by the subject to be normal, and a -0.25 D. sphere before the alleged blind eye. The suspect is now asked to read the ordinary distant-test types. If he succeeds, he is a malingerer, because the high-degree convex lens has made it impossible for him to see with the sound eye, and of course the weak concave glass does not interfere with vision. An additional control test may now be made by placing a book or a towel over the +16 D. lens. The malingerer will declare his inability to read any of the letters, thus further exposing his attempted fraud.

*Prism or diplopia tests* are advised by some observers. The subject is seated before a point of light six meters distant. The supposed blind eye is covered with a frosted glass, and the apex of a 6° prism, directed up or down, is slowly advanced to the pupillary center of the sound eye, and the suspected person is asked to recognize the double images of the monocular diplopia thus produced. This maneuver is repeated, with the prism pointed in various directions, until he becomes accustomed to the idea of diplopia. A weak concave lens is now substituted for the frosted glass, and the suspect is examined by Stevens's phorometer or by simple prisms in the manner commonly advised for testing the extrinsic ocular muscles. If he now perceives double images, he must see binocularly, and may be pronounced a malingerer.

**Snow-blindness.**—This is a form of amblyopia produced by the blinding reflections of the sun upon the naked eye of persons (usually strangers) exposed to the brilliant snow-fields of northern latitudes or mountain-resorts. The dazzling at length causes contracted pupils and retinal congestion. Central and peripheral limitations of the field of vision have been observed, as well as a lessening of the visual acuity, especially for near work.

The most common effect of this exposure is, however, a peculiar form of *hyperemia* and *edema* of the conjunctiva. This is accompanied by swollen lids, lachrymation, burning pain in the eyeballs, photophobia, and blepharo-



spasm—symptoms attributed to “sun-burn” rather than to the effects of the light-rays. The writer has had occasion to study various grades of snow-blindness in Northern Canada and among the members of a party who spent some time on the Mer de Glâce.

The light-rays from electric furnaces and arc candles are capable of producing practically the same symptoms, constituting the so-called *electric ophthalmia*. Those who are much concerned with the Röntgen X-rays may suffer in a similar manner.

The eyes remain sensitive to light and show signs of retinal fatigue for some days, and the conjunctivitis may persist, requiring treatment proper to that condition. Rest in a darkened room, with atropin and hot applications, seems to give most relief to the retinal and corneal symptoms.

**Erythropsia**, or *red vision*, is most commonly seen after cataract extraction. It has also been observed in poisoning by santonin (which may also produce *xanthopsia* or *yellow vision*), and as a phosphene-experience in persons suffering from optic-nerve atrophy and glaucoma. These exhibitions of color may be due both to central irritation and to excitation of the retinal elements.<sup>1</sup> Potassium bromid has been recommended for this symptom. After cataract extraction patients often complain of a “glaring white haze” which seems to cover all objects. An uncommon phenomenon, described by Becker and Swan M. Burnett, is *kyatopsia*, or *blue vision*. According to the latter author, it is especially observed by patients with more or less amber-colored cataractous lenses, the blue appearance depending upon fatigue of the retina from long-continued exposure to yellow light, giving blue as a residual sensation in white light.<sup>2</sup>

**Micropsia and Megalopsia**.—In hysteria, in some diseases affecting the macular region, and after the correction of marked ametropia, objects may appear smaller or larger than usual, and these visual abnormalities are sometimes accompanied by distortion of the images. In the foregoing class of cases the rods and cones are either actually separated or pressed together as a consequence of retinal infiltration, or the contrast effect of corrected refractive errors may convey the impression of altered size. As Parinaud has shown, when these phenomena are experienced by hysterical amblyopes they are probably the effect of a variable accommodative spasm.

**Night-blindness** (*Functional Night-blindness*; *Hemeralopia*,<sup>3</sup> preferably *Nyctalopia*).—This symptom is seen as a functional disturbance, probably due to diminished sensibility of the retina or rather imperfect adaptation-powers of the retina, unassociated with visible change in the background.

It has been observed as an epidemic affecting scorbutic soldiers and sailors who, in addition to insufficient feeding, have been exposed for a long time to the glare of the sun. Simeon Snell has seen it among the pupils of the English public schools. Among the poor and ill-nourished Russian peasants night-blindness has been frequently noticed, particularly during the fasts of Lent. It has been attributed to miasmatic influences by Adamüek. Not only do nyctalopes see badly on dull or dark days and well on bright days, but they suffer from other ocular troubles, the chief of which is a peculiar wasting disease of the conjunctiva—xerophthalmia (see page 296).

The treatment of the condition that gives rise to the night-blindness is

<sup>1</sup> The reader will do well to consult Fuchs's paper on this subject in *Graef's Archiv für Ophthalmologie*, Bd. xlii., abth. iv., or the review of it by W. Dudley Hall in the *Ophthalmic Record*, Feb., 1897.

<sup>2</sup> *Ophthalmic Record*, vii., N. S., 1898, p. 17.

<sup>3</sup> See a discussion of the derivation, authoritative employment, and proper definition of these terms in the *Royal London Ophthalmic Hospital Reports*, vol. x. Part ii., June, 1881, p. 284.

called for—a generous diet, ferruginous tonics, cod-liver oil, hygienic surroundings, and protection from bright light.

**Day-blindness** (*Nyctalopia*, preferably *Hemeralopia*).—In almost all the forms of central amblyopia (see page 460) patients see best on dull days or in a dimly-lighted room. The explanation of this is that with a weak illumination the pupils are dilated, and most rays fall upon unaffected portions of the retina: bright light, on the other hand, contracts the pupils and the asensitive foveal region only is presented to objects. Persons from whom light has long been excluded exhibit this symptom, and it is said to be congenital in others.

Hemeralopia also occurs in retinitis nyctalopia, coloboma of the iris, and in albinism.

# AMBLYOPIA OF THE VISUAL FIELD, SCOTOMAS, AND HEMIANOPIA.

By H. V. WÜRDEMANN, M. D.,

OF MILWAUKEE, WIS.

## THE NORMAL FIELD.<sup>1</sup>

The field of vision is that space perceived when the visual axis is directed to a stationary point. When both eyes are used the fields overlap, forming the binocular field or field of fixation (Figs. 277, 278).

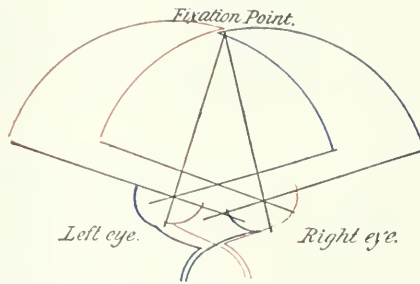


FIG. 277.—The binocular field of vision (after Foerster).<sup>4</sup> The tracts from the right brain are in red, those from the left brain in blue. The corresponding retinal halves and their fields of vision are correspondingly colored.

The object fixed is within the range of direct vision, the rays of light falling directly upon the macula; those coming from surrounding objects fall upon other parts of the retina which have indirect vision. The visual acuity diminishes as images are removed from the macula to the periphery of the field. The normal field of vision is more or less constricted at the upper and nasal sides by the eyebrows and nose, forming the upper, inner, and lower limits of the field, the outer proceeding in normal eyes to a little beyond 90° from the fixation-point. Form and white are most eccentric, followed in order by blue, yellow, red, and green (Fig. 279). Overhanging eyebrows or a large nose materially limit the field. If the chart be improperly taken, as when the patient does not hold his head erect, does not fix the sight-hole of the perimeter, or nips the eyebrows or eyelids, variation may be found.

At the temporal side of the fixation-point from 10–20° is the physiologic blind spot, or scotoma of Mariotte (Fig. 279). By careful examination with very small test-objects other blind spots may be found which correspond to the places of division of the large retinal vessels. The physiologic scotoma may be larger or smaller according to the size of the nerve-head. In case of con-

<sup>1</sup> The field of vision has been fully discussed on page 99 and on pages 162–169; but for the convenience of the reader and to facilitate comparison with the abnormalities of the visual field which follow, a brief résumé of the subject is here introduced (Ed.).

tinuance of the medullary fibers of the disk the spot may be very large, including even the fixation-point (Figs. 280 and 296). As this is covered by

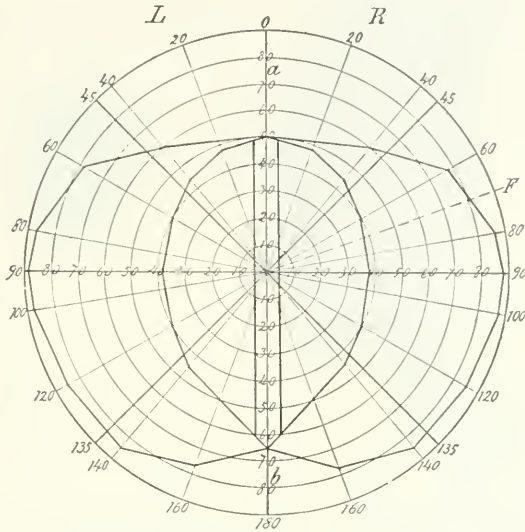


FIG. 278.—Binoocular field of both eyes (after Knies): *L*, left, *R*, right half of the field of vision divided by the vertical line *a-b*, which passes through the point of fixation *P*. The vertical strip is the overlapping portion of the field of vision.

the visual field of the other eye in binocular vision, the existence of this spot is not noticed.

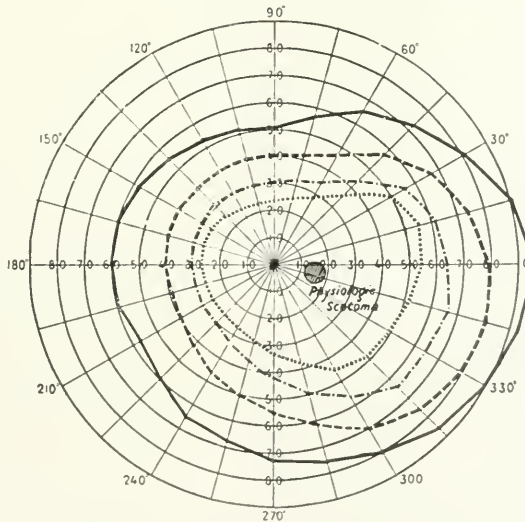


FIG. 279.—Diagram of normal field for form, white, and colors: The outer continuous line indicates the limit of the field for form and white, the dotted lines for the colors, blue, red, and green

Although the fovea centralis is the point of best vision, yet astronomic observation has shown that feebly-reflecting stars are better seen when the vision is directed a little to one side, for the fovea is less sensitive to both



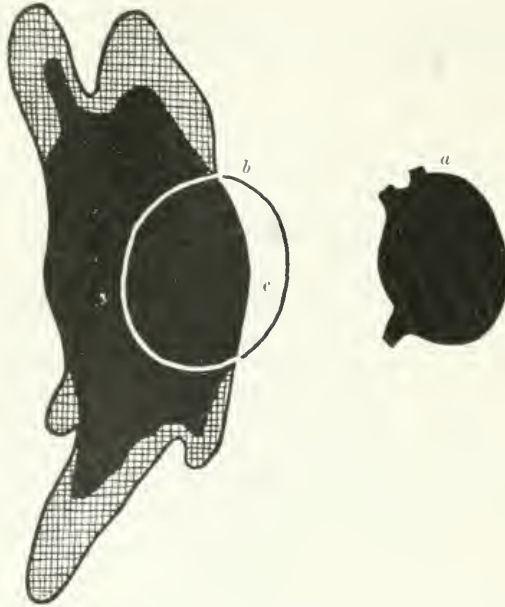


FIG. 280.—Physiologic scotoma (after Baas): *a*, normal blind spot (after Helmholtz); *b*, persistent opaque nerve-fibers; *c*, normal blind spot.

light and color in diminished light than the retina immediately surrounding it.<sup>1</sup>

#### ANOMALIES OF THE VISUAL FIELD.

Anomalies of the visual field occur as symptoms of disordered conditions which themselves are manifestations of well-recognized affections, such as diseases of the eye, of the visual centers, or of their connections, which may be due to trauma, cerebral or spinal affections, and which may in their turn be part of some general infection or condition.

Besides *amblyopia* (loss of vision) and *amaurosis* (blindness), which occur in connection with actual anomalies of the visual field, there exist two distinct groups of anomalies (for *amblyopia* and *amaurosis*, see page 457).

I. **Contraction of the visual field**, which may be *regular* (concentric), *irregular* (eccentric), and *sectoral*. These defects may be due to local as well as central lesions. There is also a characteristic form occurring in both eyes, with symmetrical obliteration of halves of the visual field—true *hemianopia*—due to lesion within the cranial cavity.

II. **Scotomata**, a group characterized by formation of scotomata or blind spots in one or both eyes, in some instances having a hemianopic aspect. The *positive* scotoma is seen by the patient as a dark or black spot upon objects. In the former case it is *relative*, in the latter *absolute*.

The *negative* scotoma is not at first recognized by the patient, but is developed through the examination. A typical example of this is the normal blind spot. The scotoma may occupy various positions, be single or multiple, central, para- or pericentral, or may have a circular form, the so-called ring scotoma (see also page 169).

The special affections of the organ of vision in which anomalies of the visual field occur are—

I. Optic hindrance in the refractive media; II. Diseases of the retina;

III. Diseases of the choroid; IV. Glaucoma; V. Diseases of the optic nerve; VI. Diseases of the chiasm; VII. Diseases of the optic tract from the chiasm to the visual centers; VIII. Functional diseases and nerve-lesions of different kinds.

**Changes in the Visual Field due to Optic Hindrance.**—Foreign bodies or opacities in the cornea, lens, vitreous (Fig. 281), or outer layers of the retina may be attended by obscuration of vision through optic hindrance, and cause amblyopia, contraction of the visual field, and scotoma.

Trauma of the eyeball may be followed by either destruction of tissue and bleeding, or both, causing changes in the visual field. Pre-retinal hemorrhage causes diminution of the visual field and absolute or relative scotoma (Fig. 282).

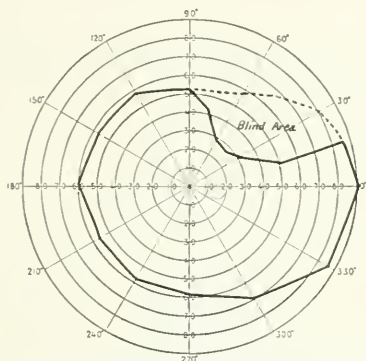


FIG. 281.—Sectoral contraction due to pre-retinal hemorrhage and foreign body in vitreous after injury by gunpowder explosion.

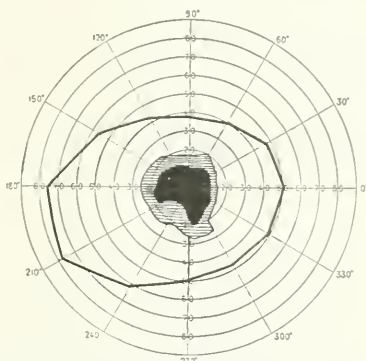


FIG. 282.—Central absolute and relative scotoma due to retinal hemorrhage in congenital syphilitic chorio-retinitis.

**Changes in the Visual Field in Diseases of the Retina.**—

Changes in the nutrition of the retina and choroid, such as occur in night-blindness, produce amblyopia, which is especially noticeable in diminished light, together with contraction of the visual field, particularly noticeable for blue<sup>6</sup> (Figs. 283 and 284 (see also page 468)).

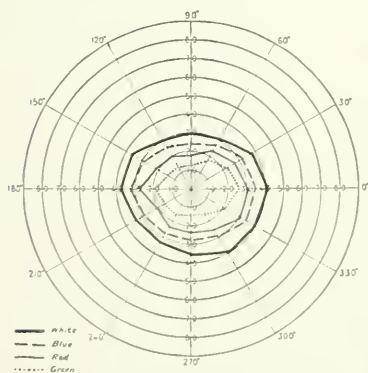


FIG. 283.—Concentric contraction in chronic night-blindness.

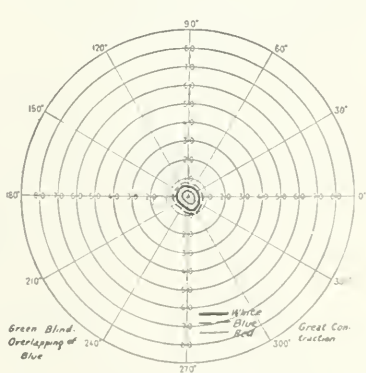


FIG. 284.—Great concentric contraction with overlapping of blue field and green blindness in chorio-retinitis pigmentosa, with nyctalopia

*Embolism* of the central artery of the retina and *thrombosis* of the central vessels give rise generally to amaurosis, proceeding to complete blindness, but where the blood-stream is not completely cut off the vision is diminished and

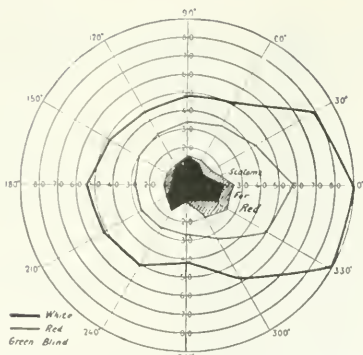


FIG. 285.—Central scotoma in partial embolism of the central retinal artery, occurring during menstruation.

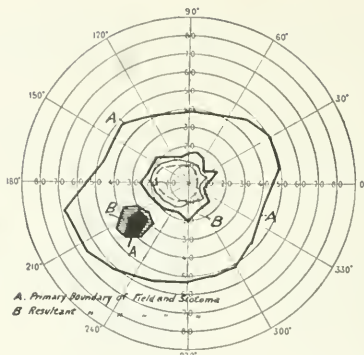


FIG. 286.—Paracentral scotoma with secondary contraction of the visual field and enlargement of the scotoma, following foreign body in the retina (after Baas).<sup>1</sup>

the field contracted, together with formation of scotoma, which is generally central (Fig. 285).

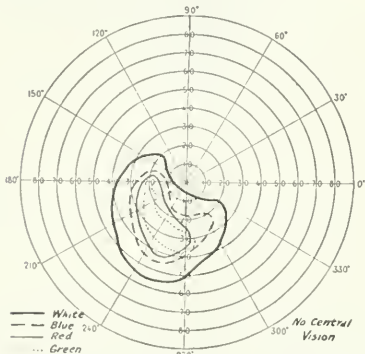


FIG. 287.—Typical constriction of field due to peripheral detachment of the retina.

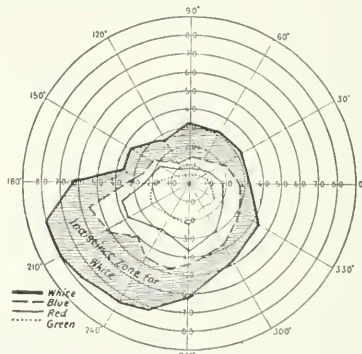


FIG. 288.—Typical contraction of visual field due to circular detachment of the retina.

Hemorrhages into the retinal structure produce scotoma or irregular contraction of the visual field, the amount depending upon the extent of the lesion.

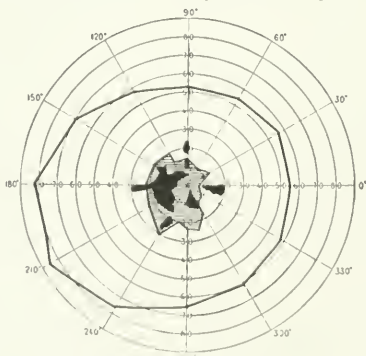


FIG. 289.—Absolute and relative para and pericentral scotomata in neuro-retinitis albuminurica occurring during pregnancy.<sup>18</sup>

*Foreign bodies in the retina cause scotoma (Fig. 286).*

*Detachment of the retina from traumatism or in myopia is attended by characteristic defects according to its extent (Figs. 287, 288).*

*Retinitis albuminurica*,<sup>18</sup> *diabetica*, and *circinata* are attended by scotoma (Fig. 289), usually central, and are followed in their retrogressive stages by atrophy of the retina and nerve, with amblyopia or amaurosis and contraction of the visual field.

**Changes in the Visual Field in Diseases of the Choroid.**—*Circulatory disturbances* and changes in the nutrition of the choroid produce characteristic changes (Figs. 290, 291). Coloboma of the choroid is attended by sectoral defects and usually scotoma (Fig. 290). Rupture, hemorrhage, and tumor<sup>21</sup> of the choroid give rise to defects depending upon the extent of the lesion (Fig. 291).

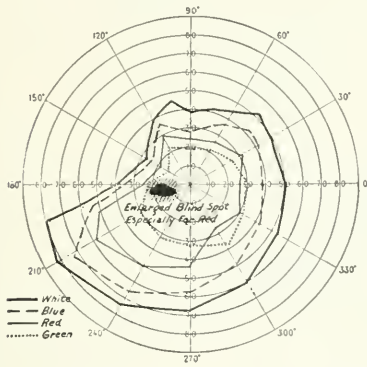


FIG. 290.—Sectoral contraction of the visual field and enlarged blind spot due to typical coloboma of the choroid and staphyloma posticum.

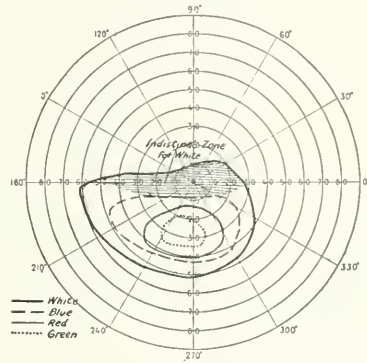


FIG. 291.—Sectoral contraction of the visual field simulating vertical hemianopia in sarcoma of the choroid.<sup>21</sup>

*Choroiditis*, especially the exudative form, usually causes multiple scotomata (Fig. 292) which are absolute or relative. By their coalescence larger scotomata are formed which may even take a peculiar ring form (Fig. 293). The visual fields may likewise be greatly reduced. If the choroiditis be at the macula, central scotoma will be developed.

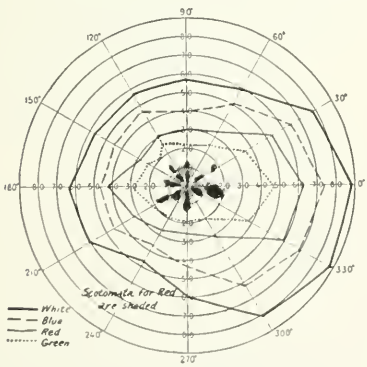


FIG. 292.—Para- and pericentral scotomata in exudative disseminated choroiditis.

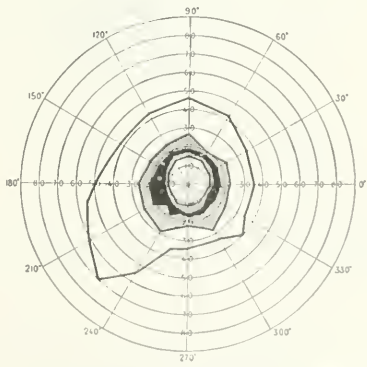


FIG. 293.—Absolute and relative ring scotoma in syphilitic chorio-retinitis.

Chorio-retinitis pigmentosa is usually attended by great contraction of the visual field and amblyopia (Figs. 294, 295). In myopia staphyloma posticum may develop, and the blind spot be rendered abnormally large thereby, so that it may even extend to the fixation-point. In senile atrophy of the choroid central scotoma and reduction of the visual fields, with am-



blyopia, result (Fig. 295), the shape of the scotoma bearing a relation to the shape of the atrophic area.

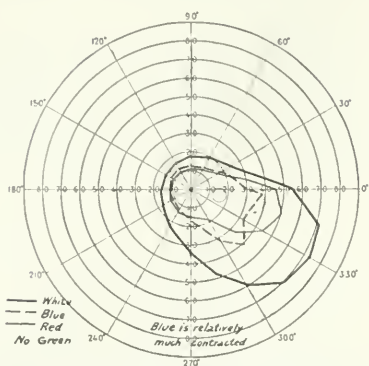


FIG. 291.—Contraction of field and loss of vision for green in chorio-retinitis pigmentosa.

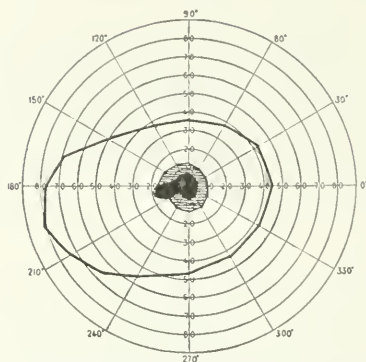


FIG. 295.—Absolute central and relative paracentral scotoma in central senile atrophy of the choroid and retina.

**Changes in Glaucoma.**—In glaucoma there is often a characteristic reduction of the fields toward the nasal side; but many other types of visual-field disturbance are common (for visual fields, see pages 380 and 381).

**Changes in Affections of the Optic Nerve.**—Changes in the visual fields generally occur in affections of the optic nerve. The principal congenital defect is coloboma of the nerve and its sheath, and is attended by enlargement of the blind spot (Fig. 296).

In traumatism with rupture or bleeding into the nerve (Fig. 297) and in

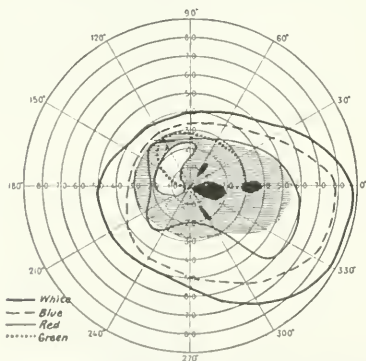


FIG. 296.—Central and paracentral absolute scotomata, with large relative central scotoma and preservation of small sector of superior nasal quadrant in coloboma of the optic nerve and retina with persistent opaque nerve-fibers.<sup>17</sup>

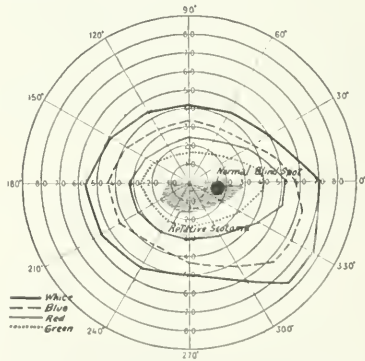


FIG. 297.—Relative sectoral scotoma from traumatism of the optic nerve and hemorrhage in the optic foramen.

tumors of the nerve there is usually found a sectoral defect, with amblyopia and contraction of the visual field resulting in atrophy. Diseases affecting the intraocular end of the optic nerve, such as papillitis, cause decided changes in the visual field, depending upon the amount of optic interference caused by the swelling and bleeding into or destruction of the nerve-tissue. The blind spot is usually much enlarged<sup>17</sup> (Fig. 298). The relation between the ophthalmoscopic appearances and the visual acuity is frequently not commensurate. These cases usually terminate in atrophy with contraction or sectoral defect and scotomata.

*Retro-bulbar neuro-retinitis*, or *toxic amblyopia* is usually attended by central scotoma due to implication of the axial fibers. (It is fully discussed on page 461.)

*Atrophy of the Optic Nerve*.—Many cases coming under the foregoing result in sclerotic changes in the optic nerve. However, it is known that a

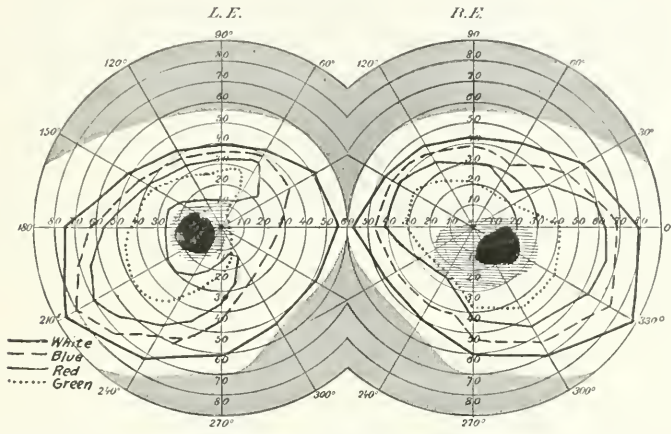


FIG. 298.—Visual fields in papillitis, due to gumma at the base of the brain, showing great enlargement of the blind spots.

large proportion of cases with diminished vision, due to atrophy of the nerve-fibers, are associated with sclerotic changes in the spinal cord. Among these is atrophy due to tabes, which in many instances is a premonitory sign of this disease.<sup>10</sup> Various forms attended by non-characteristic changes in the visual field occur in multiple sclerosis, progressive paralysis, syringomyelia, amyotrophic lateral sclerosis, exophthalmic goiter, cerebral syphilis, degenerative changes, and different mental diseases.<sup>1</sup>

The visual field in optic-nerve atrophy is usually constricted, and the contraction for color greater than that for form and white (Fig. 299). The

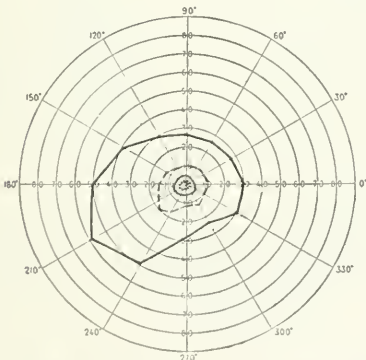


FIG. 299.—Contraction of the field especially marked for color occurring in secondary atrophy after syphilitic neuro-retinitis.

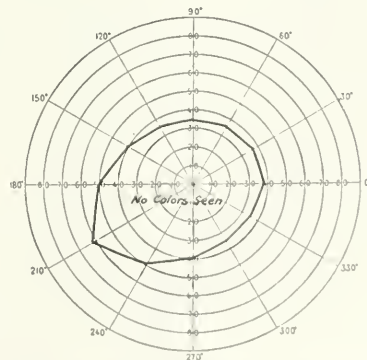


FIG. 300.—Moderate contraction in tabetic atrophy with abolition of the color-sense.

color-sense may be entirely absent, and yet the field be of moderate extent (Fig. 300). Scotomata may appear. The atrophy and consequent loss of sight may proceed for a while (*stationary optic-nerve atrophy*), and then

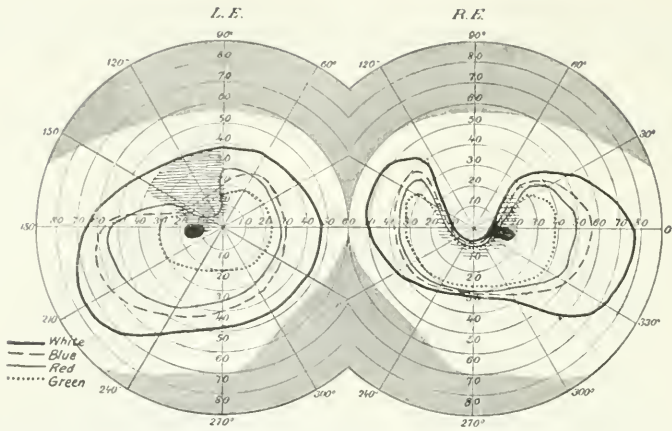


FIG. 301.—Fields of vision in hereditary atrophy showing sectoral defect of the right and relative scotomatous defect of the left. The latter is progressing and will terminate in the same form of field as that of the right.

definitely stop, or may progress to absolute blindness (*progressive optic-nerve atrophy*). A peculiar progressive form associated with scotoma (*hereditary atrophy*) comes on usually between twenty and thirty years of age (Fig. 301).

#### THE VISUAL PATHWAY.

The visual tract or pathway (see Fig. 302) proceeds from the retina to its final termination in the brain, the separate subdivisions of nerve-fibers lying in different relations at different portions of its course.

The peripheral percipient elements in the retina are the rods and cones, which are connected by fibers with the outer and inner granular layers, which in the region of the macula lutea are very fine and anastomose freely, and cannot, as elsewhere, be separately traced. The anatomic relations of the optic nerve-fibers, as given by Henschen and described by Wilbrand,<sup>23</sup> are as follows:

(a) The macular bundle lies ventro-laterally in the papilla and also immediately behind it. At the latter place it forms a keystone-shaped sector, with its base turned toward the pial sheath and its point toward the central vessels.

Farther back this bundle is halfmoon-shaped. Still farther back it takes the form of an upright oval and approaches nearer the axis of the optic nerve. In the optic foramen it assumes an axial position, and in front of the chiasm the form of a horizontal oval. The macular bundle contains crossed and uncrossed nerve-fibers. In front in the papilla the crossed fibers lie ventrally and the uncrossed ones more eccentrically, being in proximity to the other uncrossed fibers. The fibers spread over the retina. Farther back the macular fibers become drawn together toward the center. The dorsal half of these fibers goes to the dorsal half of the retina, whilst the ventrally-placed fibers go to the ventral half.

(b) The uncrossed (not the macular) bundle is divided in the anterior division of the optic nerve into two fascicles—a dorso-lateral uncrossed dorsal part and a ventro-lateral uncrossed ventral portion. In the lamina cribrosa these fibers are separated by the macular bundle. Behind the entrance of the central vessels the fascicles approach one another and form a united halfmoon-shaped bundle, which includes the lateral periphery and lies somewhat ventro-laterally.

(c) The crossed bundle (not macular) forms a closed cord in the whole optic nerve. In the papilla it is situated dorso-medially, and retains this position until it passes the chiasm.

The papillo-macular bundle, which reaches the chiasm in the shape of an oval lying horizontally, retains its central position until it reaches the chiasm. Farther back toward the center of the chiasm it almost reaches the periphery, and here the fibers belonging to the fasciculus cruciatus cross one another. It sinks once more and lies ventro-centrally in the tract. The crossed fibers of this bundle lie more centrally, and the uncrossed ones more laterally.

When a cross-section of the optic tract is made immediately in front of the chiasm,



it will be found that the crossed fibers occupy the dorso-medial part of the periphery of the section, and the uncrossed fibers are situated in the ventro-medial portion of the periphery of the section. The bundles then become divided into a number which are flattened horizontally, and these intermix with one another. The crossed fiber-bundles come together again at the ventro-lateral margin of the chiasm, forming the tract. Then there is a displacement. The crossing does not take place all at one point, but the dorsal nerve-fiber bundles first cross, followed by the more centrally-situated ones. At the posterior angle of the chiasm the commissural nerve-fibers, described by von Gudden, Meynert, and Forel, which have no influence on vision, are found.

The macular bundle courses centrally in the tract. The uncrossed bundle lies dorso-laterally, forming a close cord. The bundles retain this position until they enter the corpus geniculatum, where they separate into a mass of separate fibers. The crossed bundle lies ventro-medially, and forms a bundle which lies slantingly and hangs loosely together.

The tractus winds around the *crus cerebri*, and terminates in two roots upon the *corpora geniculata externa et interna*, and upon the posterior part of the *optic thalamus*, called the *pulvinar*. Fibers also go to the anterior part of the *corpora quadrigemina*, but these organs are not regarded as concerned in vision, but in the activity of the pupil. The parts just referred to are called the *primary visual ganglia*, or *primary optic centers*.

In them are found innumerable ganglion-cells in which the fibers of the tractus lose

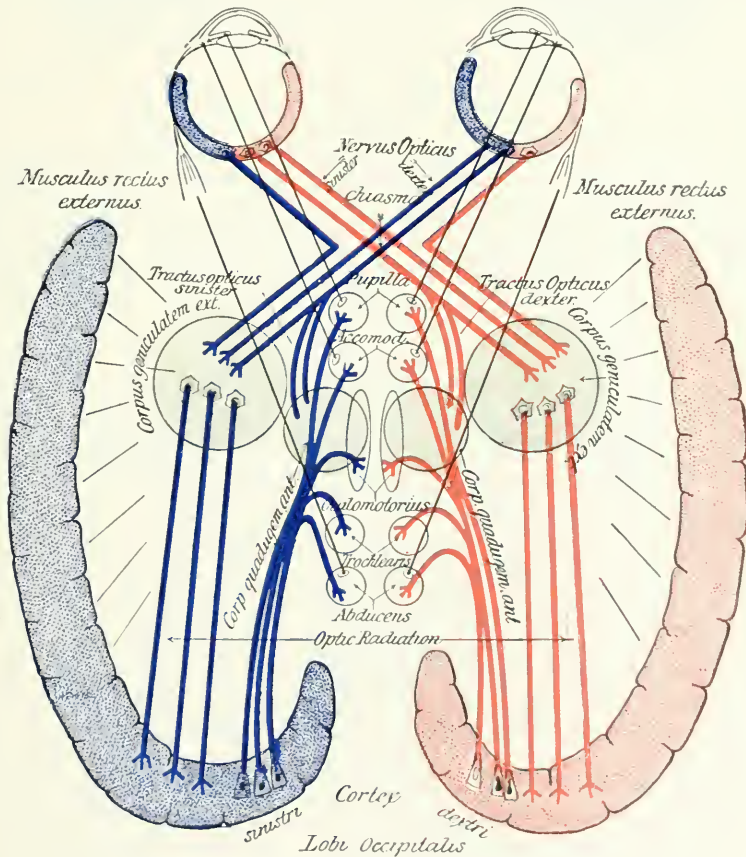


FIG. 302.—Scheme of the optic tract (after von Monakow).<sup>4</sup>

themselves, and thereafter a new set of fibers proceeds backward through the posterior part of the internal capsule to the cortex, under the name of the *visual radiations*, or *fibers of Gratiolet* or of *Wernicke*. Passing through the internal capsule, they cross the sensitive fibers coming down from the hemisphere, are rather closely massed, and then, spreading out like a fan, rise upward, wind outside the tip of the lateral ventricle to reach their destination at the lower part of the median surface of the occipital lobe (Fig. 302).



## DISEASE WITHIN THE CRANIUM.

Diseases of the brain affecting the optic nerve or tracts give rise to characteristic lesions. Optic neuritis is common, although not a constant symptom of brain-tumor. It is attended by changes in the visual field, already described.

**Hemianopia or Hemianopsia.**—Hemianopia, or half-blindness of the visual field, resulting from a localized cause, is common to both eyes. If the obliterated half be toward the same side in both eyes, it is called *homonymous* (lateral hemianopia); if the opposite sides be affected, it is called *heteronymous* (nasal or temporal). The term hemianopia should be limited to half-blindness affecting *both* eyes.<sup>1</sup> Sectoral defects simulating hemianopia may arise in one or both eyes (Figs. 281, 287, 290, 291, 297) from diseases of the optic nerve or retina, but are not to be considered in this connection.

The hemianopia may include half of the fields (*complete*), or affect sectors (*incomplete* or *partial*), or involve one-half of the field on one side and a sector in the other, or the blindness may occur in the whole of one eye and part of the field in the other eye. In the hemianopic field the vision may be totally obliterated (*absolute*) or partially retained (*relative*). Pressure upon the hemianopic sides of the eyeball does not cause phosphenes, and this fact may be of importance in cataractous patients with hemianopia.<sup>5</sup>

The *condition and reaction of the pupils* are of diagnostic importance in cerebral diseases, and especially in those accompanied by ocular lesions and changes in the visual field. Illumination of both eyes in uncomplicated diseases of the centripetal portion of the optic-reflex are never produces unequal pupillary reaction. Both pupils may fail to react to light, though sight remains good (involvement of Meynert's fibers), or both pupils may react alike, though there be complete anaurosis (lesion in some part between the Gratiolet fibers and psycho-optical cortical center).<sup>2</sup> In the case of hemianopia, when light is cast into the eye upon the seeing side of the retina, if the lesion be anterior to the primary optical ganglia, the pupil will contract, but if light is directed upon the blind side there will be no contraction. If the lesion be beyond the thalamus, such hemianopic pupillary inaction cannot occur. This reaction is often called *Wernicke's symptom*.

## DISEASE OF THE CHIASM.

**Heteronymous Hemianopia.**—1. *Nasal hemianopia* has never been shown to be due to disease behind the chiasm.<sup>3</sup> Since these fibers do not decussate and are never in contact, it is almost impossible to conceive of a bilateral cerebral lesion of the same extent and size affecting the function equally on both sides (Fig. 303). In the few reported cases a bilateral affection of the trunks of both optic nerves in front of the chiasm, extending to these and chiefly intense symmetrically at each side, has been found or diagnosed.<sup>3</sup> The visual fields are obliterated at the nasal sides of the fixation-point. The dividing-line is apt to be irregular and not precisely in the vertical meridian. The obliterated areas are not entirely deficient in light-perception, and there is hemianopic pupillary inaction. Usually evidences of inflammatory changes will be seen on ophthalmoscopic examination in disturbances of circulation, swelling, or hemorrhages on the disk, followed later by atrophic changes. Disturbance of vision as regards walking about is not very great.

2. *Temporal hemianopia* (Fig. 304) is caused by disease of the chiasm where the decussating fibers of both tracts interweave. The visual fields are

obliterated at the temporal side of the fixation-point. The dividing-line is usually irregular and the blind areas may retain some perception of light. Hemianopic pupillary inaction is present. Ophthalmoscopic examination is usually negative except in the later stages, when atrophy of the optic nerve

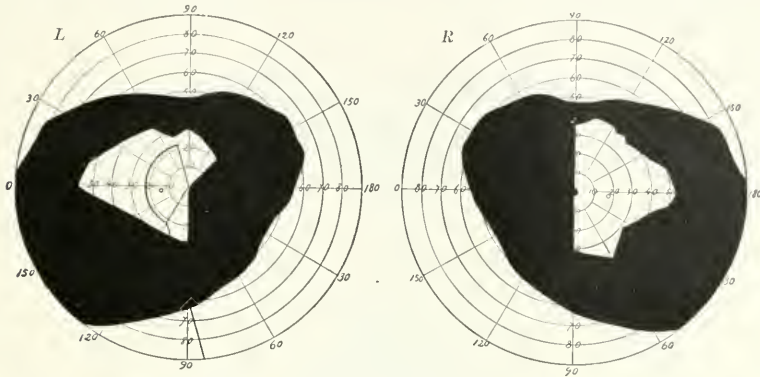


FIG. 303.—Nasal hemianopia (after Veasey).<sup>14</sup>

may occur. Disturbance of the vision is great, as the patient may only see directly ahead and has difficulty in orientation.<sup>20</sup>

**Diseases of the Optic Tract from the Chiasm to the Visual Centers.**—*Lateral or homonymous hemianopia* is due to disease affecting the optic tract behind the chiasm. Corresponding sides of the visual fields are affected (Fig. 305). The dividing-line between the seeing and the blind

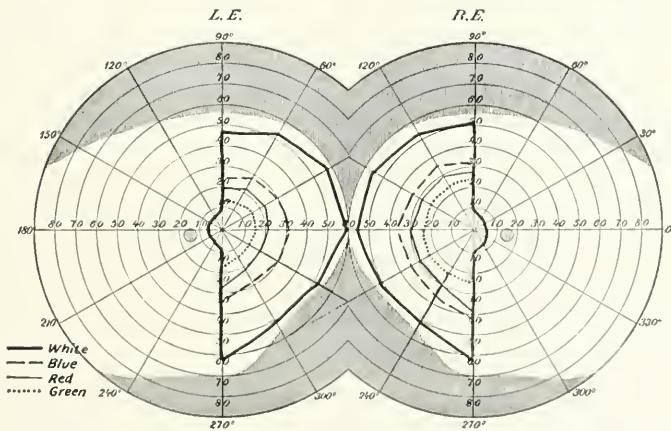


FIG. 304.—Temporal hemianopia occurring after hemorrhage at the optic chiasm, with preservation of central vision.

areas is usually well defined, running perpendicularly through the fixation-point, the visual acuity and color-sense being normal up to the edge of the obliterated area, the hemianopic field having no perception. In many it will be found that the central vision has either remained or is entirely obliterated, this being due to the fact that the macula in these cases receives fibers through both optic tracts (also proved by the occurrence of double hemianopia),<sup>10</sup> and if the field be carefully taken it will be found that there is a bulge in the line of demarcation between the hemianopic and the seeing field. If the

fixation-point lies in the obliterated field, there will be central blindness; if in the remaining field, the central vision will remain. Right-sided hemianopia causes more disturbance than left-sided, as we read from left to right.<sup>4</sup> Patients see and walk fairly well by turning the head to one side.

At first no lesion will be found on ophthalmoscopic examination, although signs of atrophy ultimately appear. If the left tract be affected, producing

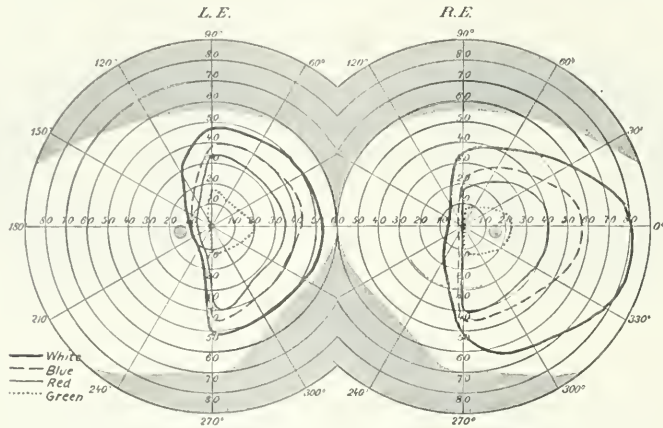


FIG. 305.—Lateral hemianopia occurring in multiple sclerosis.

right hemianopia, the right optic nerve will in time become wholly atrophic, and the left optic nerve look normal for the reason that in the left eye the tract-fibers are diminished and the crossing fibers are good; the former are covered by the whole of the disk. In the right eye the crossing fibers (derived from the left tractus) are injured and the direct-tract fibers are sound. The crossing fibers are in front, and they give the disk a look of general atrophy, with lesion of the left tract (with right homonymous hemianopia). The left nerve looks normal; the right nerve will appear atrophic.<sup>7</sup>

A few cases of *hemi-achromatopia*, in which the sense of color is lost for corresponding halves of either eye, have been reported. The cerebral character of the lesion may be established by paresis and unconsciousness. The site is supposed to be in the cortex.<sup>8</sup> A separate color-center, however, is denied by Ole Bull, Dahms, and Ward Holden.

Recently several cases of *double homonymous hemianopia*, with preservation of small central field in each eye, show that there is a cortical visual center which supplies the macula lutea.<sup>3</sup>

*Monocular hemianopia* is supposed to be caused by lesion of part of one tract involving only a portion of its fibers, but no cases have been well established.<sup>1</sup> The same may be said of *vertical hemianopia* (Figs. 291 and 297). Many diseases of the nerve and retina simulate a hemianopic field, but cannot be considered under the classical definition. The causes of the three varieties of hemianopia include traumatism, hemorrhages, embolisms, periostitis, tumors, softening and sclerosis of that portion of nerve lying within the skull.

**The Significance of Hemianopia.**—Hemianopia is not in itself a localizing symptom. There are usually other symptoms which assist in the diagnosis. Seguin's rules are as follows:

"1. Lateral hemianopia always indicates an intracranial lesion on the opposite side from the dark fields. 2. Lateral hemianopia with pupillary immobility, optic neuritis, or atrophy, especially if joined with symptoms of basal disease, is due to lesion of one



optic tract or of the primary optic centers of one side—*i. e.* the corpora quadrigemina and parts included within primary optic centers (including corpora quadrigemina, corpora geniculata, and pulvinar of the thalamus opticus) (Fig. 306). 3. Homonymous sector-like defects of the same geometric order, with hemianesthesia and choreiform or ataxic movements of one-half of the body, without marked hemiplegia, are probably due to lesion of the caudo-lateral part of the thalamus or of the posterior (caudal) portion of the internal capsule, fasciculus opticus, and radiating visual fibers of Gratiolet in the internal capsule. 4. Lateral hemianopia with complete hemiplegia (spastic after a few weeks) and hemianesthesia is probably caused by an extensive lesion of the internal capsule in its knee and caudal part (pulvinar)—*i. e.* farther back and more profound than in supposition 3. 5. Lateral hemianopia with typical hemiplegia (spastic after a few weeks)—aphasia if the right side be paralyzed and with little or no anesthesia—is quite certainly due to occlusion of the middle and adjacent cerebral arteries with extensive superficial lesion, softening of the motor zone and of the gyri lying at the extremity of the fissure of Sylvius—*viz.* the inferior parietal lobule, the supra-marginal gyrus, and the gyrus angularis. There may also be alexia, word-blindness. 6. Lateral hemianopia with moderate loss of power in one half of the body, especially if associated with impairment of the muscular sense, would probably be due to a lesion of the inferior parietal lobule and gyrus angularis with their subjacent white substances, penetrating deeply enough to sever or compress the optic fasciculus on its way posteriorly to the visual center. If mental blindness exists, the lesion would lie in the more anterior central parts of the occipital lobe. 7. Lateral hemianopia, without motor or common sensory or any accompanying symptom, is due to lesion of the cuneus only, or of it and the gray matter immediately surrounding it, on the mesial surface of the occipital lobe in the hemisphere opposite the dark half-fields. The lesion may be partial or total. Most surgical cases come at once or after convalescence within this rule or within rule No. 6. In all cases coming under rules 3 to 7, inclusive, the pupils react normally, and rarely does the ophthalmoscope show any lesion of the optic nerve, except, of course, in some tumor cases, where neuro-retinitis may be expected."<sup>12</sup>

**Amaurosis Partialis Fugax** (*Transient Hemianopia*).—*Flickering scotoma* is a form of temporary blindness of a hemianopic character usually associated with unilateral migraine, which is accompanied by malaise, vertigo, and sometimes disturbances of memory or speech. It is supposed to be due to disturbance of the circulation from spasm in the vessels of the brain, and, when accompanied by headache, in those of the dura mater.<sup>1</sup> A typical attack usually begins with a dark spot in both eyes in the same part of the visual field. This spreads, but remains in the nasal half of one visual field and the temporal left of the other. Silvery flickering points or shadows move in a zigzag manner. Part of the dark spot extends toward the end of the visual field. The blindness usually lasts a quarter to a half hour and disappears. If the visual field be examined during the attack, a defect will be found. In one case<sup>13</sup> the scotoma appeared as in the illustration (Fig. 306), growing larger and larger, finally obliterating the object and then disappearing. In another case<sup>1</sup> central scotoma with loss of light-, color-, and form-sense was found. In only one case in the writer's experience has this condition been associated with hysteria, the others happening in persons of nervous organization whose general state of health was somewhat lowered. In one case,<sup>9</sup> of a physician who was subject to the flickering scotoma, an attack was followed several weeks later by hemianesthesia, hemiplegia, and death with bulbar symptoms. At the autopsy the right vertebral artery was found thrombosed and obliterated. In this case the "flimmer scotom" was certainly due to disturbance of the circulation.

The *scotoma scintillans* of Listing is a peculiar subjective visual sensation of the same character. In some cases there is a kind of after-image of the true scotoma appearing at night or in dim light, lasting but half an hour, which consists in a rapid succession of luminous figures with dark intervals. In one case<sup>22</sup> these appeared in the upper right quadrant of the binocular field as a glittering figure quite close to the fixation-point, of an irregular,



cresecentic shape, increasing for a while and gradually receding from the center of the field, growing larger and dimmer and finally fading away. Reading was not materially interfered with.

I remember, I remember, the house where I was born;  
 The little window where the sun came peeping in at morn.  
 He never came a wink too soon, nor brought too long a day,  
 But now I often wish the night had borne my life away.  
 I remember, I remember the fir trees dark and high;  
 I used to think their very tops were close against the sky  
 It was inchildish innocence, but now 'tis little joy  
 To know I'm farther off from Heaven than when I was a boy.

2  
 I remember, I remember the house where I was born,  
 The little window where the sun came peeping in at morn.  
 He never came a wink too soon, nor brought too long a day  
 But now I often wish the night had borne my life away.--  
 I remember, I remember the fir trees, dark and high;  
 I used to think their very tops were close against the sky  
 It was a chindish innocence but now 'tis little joy,  
 To know I'm farther off from heaven than when I was a boy.

3  
 I remember, I remember the house where I was born  
 The little window where the sun came peeping in at morn.  
 He never came a wink too soon, nor brought too long a day,  
 But now I often wish the night had borne my life away.--  
 I remember, I remember the fir trees, dark and high;  
 I used to think their very tops were close against the sky  
 It was in childish innocence but now 'tis little joy,  
 To know I'm farther off from heaven than when I was a boy

4  
 I remember, I remember the house where I was born;  
 The little window where the sun came peeping in at morn.  
 He never came a wink too soon, nor brought too long a day,  
 But now I often wish the night had borne my life away.  
 I remember, I remember the fir trees dark and high;  
 I used to think their very tops were close against the sky  
 It was in childish innocence but now 'tis little joy,  
 to know I'm farther off from heaven than when I was a boy.

5

too soon  
 the night

6

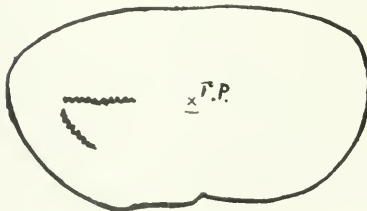


FIG. 306.—Appearance of printed page in amaurosis partialis fugax (after Stirling). (23)

Treatment of this condition consists in restriction from brain-work, regulation of diet and daily life. The administration of antipyrin, phenace-

tin, or caffeine may cut short the duration of the attack and relieve the symptoms. Bromid of potassium and quinin have been advised.

### FUNCTIONAL DISEASES.

(*Retinal Anesthesia; Neurasthenic Asthenopia; Hysterie Amblyopia.*)

**Anesthesia of the retina** (see also page 410) is characterized by reduction of the visual acuity and concentric contraction of the visual field or other changes, together with functional disturbances in other parts of the body.

It occurs for the most part in anemic women who are often the subjects of uterine and ovarian disease or chlorosis, or in children at puberty; occasionally cases are seen in young men. The loss of sight is usually partial, although it may be total, and in some cases the apparent loss is heightened by malingering. It is purely an hysterical manifestation, and as such may last from a few hours to days, weeks, or months. Indeed, patients have been known to shut themselves up in dark rooms for a long time, especially if attended by sympathizing friends or relatives. The subjects usually complain of considerable eye-pain, dazzling and photophobia, headache, and blinding by artificial light, haziness, dimness of letters and lines on reading, lachrymation, and occasional diplopia.

The causes of the condition are over-exertion at school or over-work, traumatic neurosis from injuries which are often trifling, general ill-health, and diseases of the genital organs (*kopiopia hysterica*), and other manifold causes of hysterical conditions. The location of an hysterical symptom is frequently more or less dependent upon an actual local lesion. Thus it is that

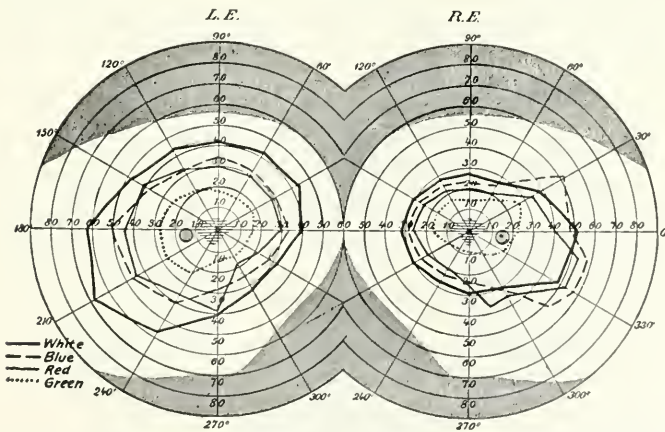


FIG. 307.—Visual fields in hysterical amblyopia, showing concentric contraction with overlapping color-fields and relative central scotomata.

the cause of hysterical blindness in a neurasthenic person may depend upon eyes that are already weak from an error of refraction or actual extrinsic muscle-weakness, conjunctival trouble, etc. There are cases in which these causes may not be found, and a diagnosis of true nervous asthenopia may here be made. There is usually weakness of accommodation and the extrinsic muscles, especially deficient adduction (insufficiency) or imbalance of the muscles (heterophoria). The levator is sometimes likewise affected (pseudoptosis). There may be sensory motor paralysis and parasthesia or anesthesia in various parts of the body.

There is generally concentric contraction of the visual field, usually

more on one side than on the other (Fig. 307). The extents and shapes of the fields will vary, depending upon the size of the test objects and the condition of the patient. The contraction may be more pronounced if a second field (the *counter-field*)<sup>15</sup> be taken immediately after the first, the difference being caused by nervous exhaustion (*Ermüdungs-Typus*);<sup>15</sup> or the second field may overlap the first (*Verschiebungs-Typus*)<sup>15</sup> (Fig. 308), or the colors

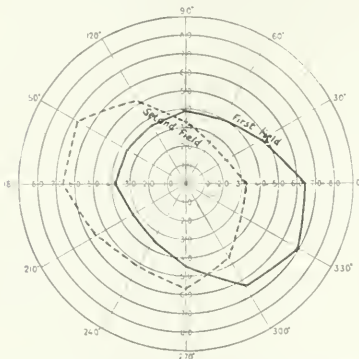


FIG. 308.—Fields for white of right eye taken fifteen minutes apart in a case of neurasthenia with diminished vision, showing overlapping of the second field, the fixation-point remaining the same (*Verschiebungs-Typus*).

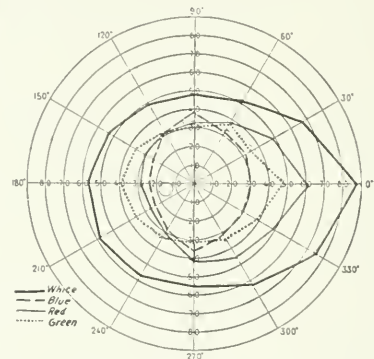


FIG. 309.—Reversal of color-fields in hysteria.

may overlap or be reversed (*reversal of the color-fields*)<sup>11</sup> (Fig. 309). Mixed forms are common and the boundaries are frequently not sharply defined. A relative central scotoma is sometimes found. The field may even have a

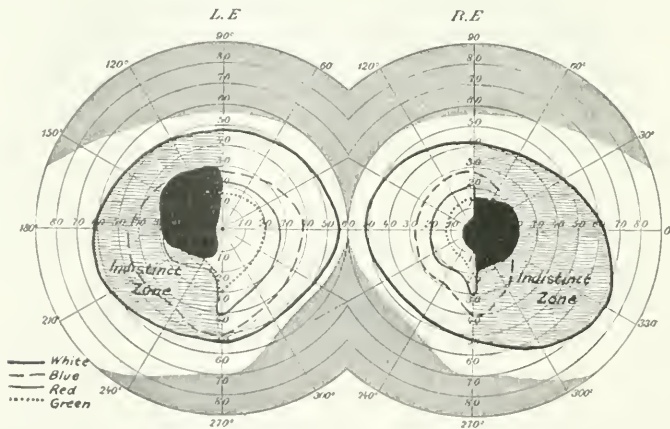


FIG. 310.—Hysteric field simulating temporal hemianopia.

hemianopic character, or be greatly contracted, or show sectoral defects (Figs. 310 and 311). A peculiar form is the *oscillating field*,<sup>16</sup> in which the patient first recognizes an object at one meridian, then loses it for a moment, only to see it again.

The *diagnosis* may be made by the accompanying general symptoms and the absence of actual ophthalmoscopic signs of disease. The pupils are active to light and accommodation and the visual fields are usually typical. The amblyopia is usually of sudden occurrence and disappears quickly.<sup>11</sup>

**Treatment** is directed toward restoration of general health, and should include massage, exercise, good food, and tonics, with rest of the eyes from work, and the use of tinted glasses, care being taken that the subject does not

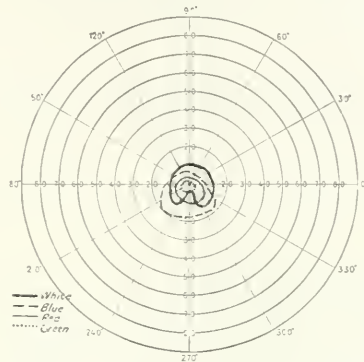


FIG. 311.—Great concentric contraction, with overlapping of the color-fields in hysteric amblyopia.

depend too much upon their use. Although subject to constant relapses, many cases may be rapidly brought from complete or partial blindness to full visual acuity and restoration of the visual field by suggestion, electrical treatment, or simple medicines.

*Nerve-lesions* and general diseases are sometimes attended by disturbance of vision and changes in the visual field.

**The Significance of Amblyopia and Changes in the Visual Field.**—The diagnostic importance of loss of vision depends upon its nature. If the disease be found in the eye, it will depend upon the extent of the lesion. If the blindness be associated with symptoms of spinal or brain disease, diagnostic points of value will be determined from study of the visual acuity, of the character and extent of scotomata, and of alterations in the field. If the latter be hemianopic in character and associated with other symptoms, a definite localization of the lesion may be assigned, although in themselves these are not diagnostic, as such may be simulated by hysteria. The character of scotomata is sometimes diagnostic, especially those of central nature which occur in toxic amblyopia. The peculiar vacillations in the visual field associated with functional disease are characteristic.

#### BIBLIOGRAPHY.

- <sup>1</sup> Baas, Karl: *Das Gesichtsfeld*, 1896.
- <sup>2</sup> Baas, Karl: "Die Semiotische Bedeutung der Pupillenstörungen," 1896, *Samml. Abhdl. d. Gebiete d. Augenheilkde*, i. 3, 1896.
- <sup>3</sup> Eales: "A Case of Binasal Hemianopsia," *The Ophthalmic Review*, July, 1895.
- <sup>4</sup> Fick, A. Eugen: *Lehrbuch der Augenheilkunde*, Leipzig, 1884.
- <sup>5</sup> Knies, Max.: *Die Beziehungen des Sehorgans und seiner Erkrankungen zu den übrigen Krankheiten des Körpers und seiner Organe*, Wiesbaden, 1893.
- <sup>6</sup> Krienes, Hans: *Hemeralopia*, 1896.
- <sup>7</sup> Mauthner: *Gehirn und Auge*, 1881.
- <sup>8</sup> Noyes, H. D.: *Diseases of the Eye*, 1890.
- <sup>9</sup> Reinhold: "Beiträge z. Path. d. acuten Erweichung d. Pons, u. d. Medulla Oblongata," *Deut. Zeitschr. f. Nervenheilk.*, 5, 1894.
- <sup>10</sup> De Schweinitz, G. E.: *Diseases of the Eye*, 1892.
- <sup>11</sup> De Schweinitz, G. E., and Mitchell, J. K.: "A Further Study of Hysterical Cases and their Fields of Vision," *Jour. of Nerv. and Ment. Dis.*, Jan., 1894.



<sup>12</sup> Seguin: "Contribution to Pathology of Hemianopsia of Central Origin," *Journ. of Nerv. and Ment. Dis.*, 1886.

<sup>13</sup> Stirling, A. W.: "On Certain Subjective Visual Sensations," *Journ. Amer. Med. Assoc.*, Dec. 5, 1896.

<sup>14</sup> Veasey, C. A.: "Binasal Hemianopsia," *Ophthal. Record*, Feb., 1897.

<sup>15</sup> Wilbrand, H.: *Die Hemianopischen Gesichtfeldformen und das Wahrnehmungszentrum*, 1890.

<sup>16</sup> Wilbrand, H.: *Die Erholungs Ausdehnung d. Gesichtsfeldes unter normal u. path. Bedingungen*, 1896.

<sup>17</sup> Würdemann, H. V.: "Coloboma of the Optic Nerve and Retina, with Persistent Opaque Nerve-fibers," *Annals of Ophthal. and Otol.*, July, 1896.

<sup>18</sup> Würdemann, H. V.: "Albuminuric Retinitis in Pregnancy," *Ophthal. Record*, Sept., 1895.

<sup>19</sup> Würdemann, H. V.: "Occurrence of Optic-nerve Atrophy in General Disease," *Journ. Amer. Med. Assoc.*, Oct., 1896.

<sup>20</sup> Würdemann, H. V.: "Temporal Hemianopia, with Recovery followed by Right Lateral Hemianopia and Ophthalmoplegia," *Arch. of Ophthal.*, xxii. 2, 1895, and *Arch. f. Augenhkde*, xix., 1895.

<sup>21</sup> Würdemann, H. V.: "Illustrative Cases showing the Indications for Enucleation of the Eyeball, etc.," *Annals of Ophthal.*, October, 1897.

<sup>22</sup> Zehender, N.: "Das Siehelförmige Flimmerscotom, Listing's," *Klin. Monatsbl. f. Augenhkde*, Jan., 1897.

<sup>23</sup> Wilbrand, H.: "Perimetry and its Clinical Value," *System of Diseases of the Eye*. Edited by Norris and Oliver, Philadelphia, 1897.

## INTRAOCULAR GROWTHS.

BY WARD A. HOLDEN, A. M., M. D.,  
OF NEW YORK CITY.

**Tumors of the Iris.**—Strictly speaking, tumors of the iris include cyst, sarcoma, simple granuloma, pigmented granuloma or melanoma, and angioma, although besides these primary tumors there are the nodules of tuberculosis and lepra, the condylomata and gummata of syphilis, and the lymphomata of general leukemia, which will not be treated of in this article.

**I. Cysts of the Iris.**—(1) *Cyst of the stroma of the iris* usually follows a perforating wound of the cornea, and appears, some months or years after the trauma, as a smooth, round tumor, translucent and non-inflammatory, projecting from the surface of the iris and distorting the pupil.

In color the cyst ranges from bluish-gray to yellow according to its size, the thickness of its walls, and the consistency of its contents.

The cyst as it grows preserves its globular form until it impinges on the cornea, when it flattens and moulds itself to the shape of the anterior chamber. At the outset it is not accompanied by signs of inflammation, but as it increases in size, particularly if the increase is rapid, there appear evidences of irritation, soon followed by true irido-cyclitis. The latter, which is associated often with glaucoma or even with sympathetic disturbance, destroys the sight and at length necessitates enucleation.

Since the growth, if neglected, is fatal to the eye, an early attempt at removal should be made, but, owing to the impracticability of extirpating the cyst entire, recurrence is usual, although cures are reported.

These cysts may be either *serous* or *epithelial*. The former are true cysts, having a wall lined with one or more layers of epithelium (or rarely endothelium), and enclosing liquid contents. When the wall is thin and the liquid clear, such a cyst may be perfectly transparent (Fig. 312).

The *epithelial cysts*, on the contrary, are composed in the periphery of stratified epithelium, which toward the center of the tumor gradually passes over into an atheromatous mass of broken-down epithelium, fat, and cholesterolin. From their appearance when cut these epithelial cysts have been called *pearl tumors*, and, from their pathogenesis, *epithelial implantation tumors*.

The theory now accepted as adequate to explain the genesis of most of these tumors, and certainly of all those lined with epithelium, is that epithelial particles from the cornea, lashes, or lids are carried by the penetrating body



FIG. 312.—Serous cyst of the iris nine months after a perforating injury (from a patient of Dr. H. Knapp's).

into the eye, and, proliferating there, form a cyst. Cysts may readily be produced experimentally in this way.

For the rare cases in which there is no history of perforation of the cornea Schmidt-Rimpler has advanced the plausible theory that the mouth of one of the crypts in the anterior surface of the iris becomes occluded, thus forming a sac lined with the endothelium that normally covers the surface of the iris. This sac, undergoing a progressive distention with liquid, becomes a serous cyst.

(2) *Cysts of the pigment-layer of the iris* occur in eyes with broad posterior synechiae, and are usually not discovered until the eye is cut open, although this condition has been diagnosed twice in life, the cyst presenting in the pupil as a pigmented, vibrating, translucent tumor.



FIG. 313.—Cyst of the pigment-layer of the iris, due to membranous irido-cyclitis following a perforating injury of the cornea and lens.

Although usually small, they may involve the pigment-layer in its entire extent (Fig. 313).

**Sarcoma of the Iris.**—This is usually an extension of sarcoma from the ciliary body, which, passing through the head of the ciliary body, presents in the angle of the anterior chamber (Fig. 314, D).

Sarcoma may, however, be *primary* in the iris, and it then appears in middle life as a very vascular tumor, soon leading to iritis and glaucoma. It is more common in women than in men.

If *pigmented*, as it usually is, it can only be confounded with *melanoma*, which is non-vascular and non-progressive.<sup>1</sup> If *not pigmented*, sarcoma may be mistaken for the irregular non-vascular nodules of *tuberculosis*, which develop with a chronic iritis in young persons (see page 339).

**Treatment.**—In the early stages, when the growth is circumscribed, favorable results follow excision of the diseased portion of the iris by means of a broad iridectomy. It should be remembered, however, that there may have been extension into the ciliary body, even at a time when the growth still seems localized in the iris. If this point should be positively ascertained, or if extension should have taken place, thorough enucleation is the only remedy.

**Tumors of the Ciliary Body.**—These are *sarcoma*, *myo-sarcoma*, *primary* and *metastatic carcinoma*, *adenoma*, *nevus*, and *cyst*. Sarcoma is the most common, and only a few cases of each of the others have been reported.

**Myoma and Myo-sarcoma of the Ciliary Body.**—These are names given several times to tumors composed of long fusiform cells which were taken to be smooth muscle-cells springing from the ciliary muscle. The differentiation between smooth muscle-cells and the long fusiform cells of sarcoma is difficult, and it is not improbable that in some of the reported cases the tumor was an ordinary sarcoma.

**Primary carcinoma and adenoma of the ciliary body** may arise from the proliferation of the cells of the pars ciliaris retinae, which is of epithelial origin. The new structure is likely to be of a glandular type. Theoretically,

<sup>1</sup> Benign melanoma here, as elsewhere, may in later life become sarcomatous.

similar growths could arise from the posterior pigment-layer of the iris, and such a case has been reported by Hirschberg, but he admits that the character of the growth was questionable.

**Cysts** may be formed in the ciliary body or choroid, or there may be detachment of the choroid with rotation inward of the ciliary body. Such conditions are readily mistaken for sarcoma of the ciliary body. Oblique illumination of the sclera in the ciliary region will show translucency in the former case, but opaqueness if a tumor is present. The tension is also of importance.

**Tumors of the Choroid.**—These are *sarcoma*, which is the most common; *metastatic carcinoma*, which is seen occasionally; and *cyst* and *nevus*, which are rare.

**I. Sarcoma of the Choroid and Sarcoma of the Ciliary Body.**—These growths may be described together. The course of the disease has been divided by Knapp into four stages.

**Symptoms.**—In the *first stage*, that of latency, the patient, who is usually past middle life, complains simply of a defect in the visual field. The media are clear, and there is seen a smooth, rounded elevation of the retina, without folds, not undulating with movement of the eye, not extending in most cases to the ora serrata, and with an overhanging margin in all or most of its extent. If the sarcoma is unpigmented, its vessels may be recognized beneath the retinal vessels. Sarcoma of the choroid usually appears of a reddish color, and sarcoma of the ciliary body black. The tension is normal and the eye is otherwise healthy.

While this condition lasts—and it may persist for years—the disease usually can be distinguished easily from spontaneous *detachment of the retina* and from *detachment of the choroid*, the two conditions that resemble it.

Spontaneous detachment of the retina is preceded by the perception of *musee volitantes*, and comes on suddenly. It extends to the ora serrata, and the folds into which the retina is thrown undulate with every movement of the eye. The vitreous is cloudy, signs of choroiditis are usually found in the affected eye or the other, and the tension is reduced (see page 428).

Detachment of the choroid is a very rare condition, of sudden onset, and caused, as a rule, by hemorrhage, and more rarely by exudation. Tension may be increased. The characteristic vessels of the choroid, however, can usually be recognized beneath the vessels of the retina, thus establishing the diagnosis (see page 357).

Toward the end of the first stage of the course of sarcoma the vitreous grows cloudy and a general detachment of the retina ensues, producing complete blindness. Detachment, however, is longer delayed when the tumor is in the ciliary body or near the posterior pole of the eye. The tension may still be normal for a time, and the diagnosis will then be exceedingly difficult. This is true particularly of those rare cases in which the tumor is flat, for such a growth will sometimes perforate the globe posteriorly before it presents much of a tumor in the interior of the eye. The opaque tumor can, however, sometimes be made out beneath the floating retina by using intense illumination, and its plastic features may be recognized by means of *Bellarmínoff's device* of pressing a moistened plane glass upon the cornea, thus eliminating the refraction of the cornea and permitting objects in the interior of the eye to be seen more nearly in their natural size and relief. The final test of tumor is puncture. If a sarcoma is present, blood will be withdrawn, but if the condition is merely one of simple detachment of the retina, only a serous liquid will appear.



Soon after the general detachment of the retina has occurred the *second stage* of the disease is ushered in, that of *glaucoma*. The anterior ciliary veins are now dilated, more particularly on the side corresponding to the tumor, the anterior chamber is shallow, the media are cloudy, the tension is increased, and the eye is painful. There is occasionally hemorrhage into the eye, and at times the glaucomatous symptoms may mask every sign of tumor. Then the fact that the patient was blind before the glaucoma will arouse suspicion of tumor, and the coexistence of increased tension and detachment of the retina is almost pathognomonic. Cyclitis may supervene in this stage, or sarcoma may develop in an eye already shrunken from eyelitis; but these cases will be distinguished from those of uncomplicated eyelitis by the increased tension.

In the *third stage*, that of local extension, the growth spreads to parts outside of the eyeball. When the tumor is located in the anterior portion of the ball, it extends into the ciliary body, presenting in the angle of the anterior chamber, and thence passes out along the anterior ciliary vessels to form nodules in the episcleral tissue. When it is located posteriorly, the growth passes out along the *venae vorticosae*, or the posterior ciliary vessels and nerves, or the optic nerve, extending in the substance of the latter or between its sheaths, and then forms nodules in the orbit which cause exophthalmos.

In the *fourth stage* metastatic tumors develop in other organs, notably the liver. Even when the eye has been enucleated early, metastases occur in from 20 to 40 per cent. of the cases, and death then follows, usually within three years.

**Pathological Anatomy.**—The shape of the sarcomatous tumor varies with the relations of the inner layers of the choroid, which overlie it like a capsule. Rarely the tumor is diffuse and only slightly elevated, but, as a rule, it preserves a spheroidal form as long as the choroidal capsule is intact (Fig. 314, *A*). When the capsule is ruptured, however, the tumor assumes the shape of a sphere springing from a flatter base (Fig. 314, *B*), and later the entire mass may again become spheroidal (Fig. 314, *C*).

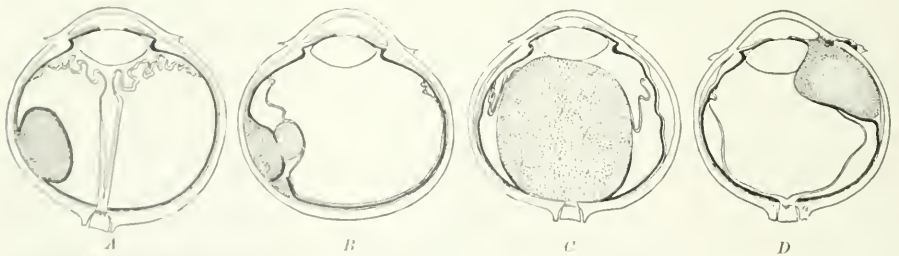


FIG. 314.—Diagrams of sarcoma of the uveal tract, the heavy line representing the tumor-capsule.

A second nodule developing near the first may remain permanently separated from the other by its capsule (Fig. 314, *B*). When the tumor is in the ciliary body, the anterior portion breaks through the capsule early and impinges on the lens, dislocating and distorting it (Fig. 314, *D*). The retina, which in the normal state is but loosely attached to the choroid, may readily undergo a total funnel-shaped detachment while the capsule is still intact (Fig. 314, *A*). But when the growth perforates the capsule the retina becomes adherent at the point of perforation, and remains attached there, although it may otherwise be detached entirely (Fig. 314, *B* and *C*).

The consistency of sarcoma is generally firm, although the tumor may be

PLATE 8.

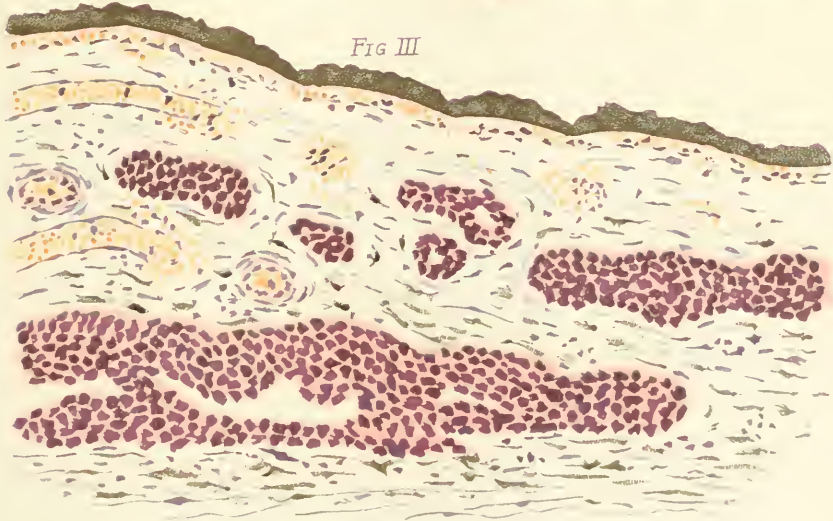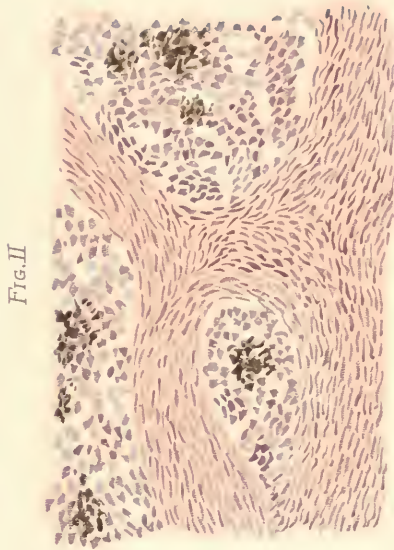
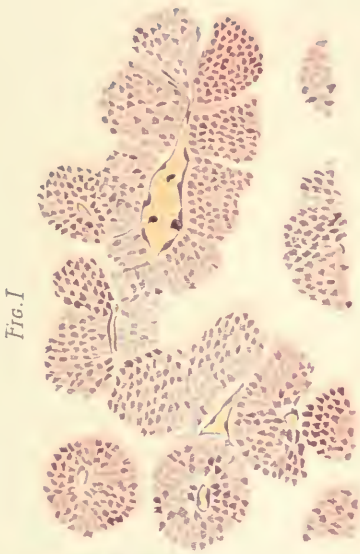


FIG. I.—Vascular round-celled sarcoma of choroid.  
FIG. II.—Non-vascular spindle-celled sarcoma of choroid.  
FIG. III.—Metastatic carcinoma of choroid.



gelatinous, and it may undergo fatty, myxomatous, cartilaginous, or osseous degeneration.

The pigmented variety (*melano-sarcoma*) is much more frequent than the unpigmented (*leuko-sarcoma*). The pigment of melano-sarcoma may lie only in a few cells along the vessels, or may color single tracts of cells, or every cell in the tumor may be black with pigment. The pigmentation is usually denser in the periphery of the tumor than in the center.

Sarcoma of the uveal tract may occur in many of the protean forms in which sarcoma is found elsewhere, and more than one type of structure may be represented in the same tumor. The cells are usually small, and the spindle-cell is commoner than the round. There are all degrees of vascularity, from the type in which the tumor is made up of thin-walled vessels, each surrounded by a sheath of epithelioid cells arranged in concentric layers (Plate 8, Fig. I.) to the type in which tracts of spindle-cells run in various directions, and often in a considerable field the only trace of a vessel to be seen is a spot of pigment in the center of a tract cut transversely, representing the remains of a previously-existing vessel about which the tract developed (Plate 8, Fig. II.). Alveolar forms of sarcoma are also found occasionally, and these in former days were sometimes described as carcinoma.

**Prognosis.**—If an eye with sarcoma of the uveal tract is enucleated before there are visible evidences of extension, the chances of local return are slight; the prognosis as regards metastasis, however, is grave. If we take the average of the statistical tables that have been published, it appears that there is eventually a fatal result in about 30 per cent. of cases.

**Treatment.**—The treatment is prompt enucleation as soon as the diagnosis of sarcoma is made. The optic nerve is to be resected far back, and evidences of extension are to be looked for, since the presence of nodules outside of the eyeball usually calls for evisceration of the orbit.

**II. Metastatic Carcinoma of the Choroid.**—This growth has been seen a score of times at the posterior pole of the eye as a broad, flat patch of dull yellow mottled with white and some spots of pigment, with fine vessels running through it, elevated some millimeters in its central portion, and at its periphery passing over into the healthy choroid without a sharp line of demarcation. Not infrequently more than one patch is present, and the patches then tend to coalesce and surround the optic disk.

At first glance carcinoma might be mistaken for an exudation in the choroid, but the details of the growth are too clearly defined for this, and there are wanting the congestion and edema of the disk and retina that would accompany an inflammatory exudation. Carcinoma has a slow progressive course, first elevating the retina and producing hyperopia, then interfering with its function and causing a scotoma. Later, the retina is detached. In nearly every case the primary carcinoma has been located in the breast, and in a number of cases both eyes have been affected.<sup>1</sup>

The epithelial cells from the primary growth are carried into the eye through the posterior ciliary arteries, and, lodging in the chorio-capillaris, they proliferate and invade all the layers of the choroid (Plate 8, Fig. III.).

As with metastatic tumors elsewhere, nothing can be gained by operative interference, although in the glaucomatous stage enucleation has been done for the relief of pain.

Flat tumors of the choroid have proved in a few instances to have the character of *angioma* or *cavernoma*, and the designation *nevus* seems fitting.

<sup>1</sup> It may be noted here that in the rare cases in which sarcoma of the choroid is metastatic the tumor is likely to assume this same flat form.



**Tumors of the Retina.**—These are *cyst* and *glioma*.

I. **Cysts** are found occasionally in the detached retinas of degenerated eyes, but since the media in such eyes are cloudy, the cysts are rarely discovered until after enucleation. It may happen, however, if the cysts lie far forward and the lens is not entirely opaque, that they may be indistinctly seen in life, as they were in the eye represented in Fig. 315; and the cysts might then be mistaken for tumors of the ciliary body did not the reduced tension and the clinical history oppose that diagnosis.

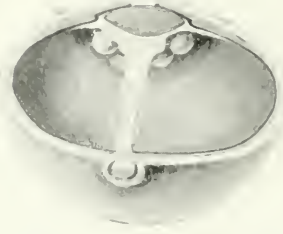

Fig. 315.—Multiple cysts of the detached retina in an eye with plastic cyclitis from a non-perforating injury.

These cysts are due to disturbances of circulation whereby a liquid transuded from the retinal vessels collects in little cysts, until at length the retina, for some distance, is split into two layers.

II. **Glioma of the Retina.**—This is the most malignant tumor of the eye, and is sometimes present at birth, but usually appears within the first two years of life and never later than the eleventh year. In one-fifth of the cases the disease affects both eyes.

**Symptoms.**—The clinical course of glioma may be divided into four stages, like that of sarcoma:

In the *first stage* the attention of the parents is attracted by a dilated pupil and a whitish reflex from the interior of the eye. If the glioma has grown from the posterior surface of the retina backward (*glioma exophytum*), the commoner form, it will push the retina forward, so that the latter will be seen, with its characteristic vessels, forming the nodular and uneven surface of the tumor. Portions of the retina not involved in the growth may be detached and undulating. The color of the tumor is bright pale yellow or pink, with scattered spots of white. If the glioma has grown from the anterior surface of the retina forward (*glioma endophytum*), a much rarer form, there will be seen a number of light-colored nodules projecting forward into the vitreous in front of the retina, which is thickened and uneven.

When the growth has reached a considerable size the *glaucomatous stage* comes on, with injection of the eyeball, shallow anterior chamber, cloudiness of the media, and increased tension. In this stage cyclitis may supervene, causing a temporary shrinking of the ball and masking the presence of the growth—a condition known as *crypto-glioma*.

In the *third stage* there is extension, usually first along the optic nerve, and then through the cornea, which is destroyed. The orbit thus becomes filled with a fungoid mass, and at the same time the tumor attacks the glands of the head, and scattered nodules form on the bones of the skull.

Finally, in the *fourth stage*, metastases develop in other organs.

**Diagnosis.**—This is often exceedingly difficult, but, owing to the malignancy of the growth, enucleation is usually done when there is a reasonable assurance that the disease is glioma; consequently, many of the eyes enucleated with this diagnosis are found on examination not to contain a glioma, but to represent one of the several conditions called pseudo-glioma.

*Pseudo-glioma* may consist in a malformation of the anterior portion of the vitreous, with persistence of the embryonic hyaloid artery and vascular sheath of the lens—a condition whose nature can usually be recognized. It may be solitary tubercle, and then, as in glioma, enucleation is indicated if the tuberculosis is limited to the eye and sight has been destroyed. But in

the great majority of cases pseudo-glioma is an exudation into the vitreous chamber following meningitis.

An infant has fever with meningeal symptoms, and shortly afterward a whitish reflex is noticed from the pupil. The iris is normal or only atrophied in spots, but its ciliary margin is retracted by cyclitic membranes, so that the periphery of the anterior chamber is very deep, while the pupillary margin of the iris is pushed forward by the lens, rendering the center of the anterior chamber shallow. The pupil is usually small, and the iris, as a whole, has the peculiar appearance of a truncated cone, which is characteristic of membranous cyclitis.

In the vitreous chamber a smooth exudation will be found, dull yellow or gray in color, and without visible blood-vessels. The tension is generally reduced. Later small vessels may appear in the exudation, the retina may become detached, and the eyeball may even shrink. This condition is brought about by a metastatic uveitis or retinitis due, as a rule, to meningitis, but also coming on in pyemia and various other infectious diseases. Syphilis and penetrating wounds may also give rise to a similar exudation.

Glioma, however, is distinguished from these conditions by the normal or increased tension, the dilated pupil, the normal or uniformly shallow anterior chamber, and by the nodular surface of the growth with its characteristic retinal vessels (see also pages 356 and 400).

**Pathological Anatomy.**—Glioma of the retina is a soft vascular tumor, composed of small cells with a large nucleus, imbedded in a delicate mesh-work of cell-processes and fibers. It readily undergoes fatty and even calcareous degeneration. In the hardened specimen thick sheaths of healthy cells are seen surrounding the thick-walled and often degenerated blood-vessels, while the cells farther from the nutritive supply are degenerated and do not take the nuclear stains.

Virehow first thought glioma to be a proliferation of neuroglia tissue; others have put it in the category of sarcoma; and there has been much discussion as to what layer of the retina glioma really springs from, and what is its true nature, some contending that a simple proliferation of neuroglia tissue could not have the extreme malignancy of glioma, which spares no tissue in the body.

Sections of glioma stained by the Golgi-Cajal silver-impregnation method have recently shown us that glioma is composed of neuroglia-tissue and a few nerve-cells of various sizes (Fig. 317). Glioma in rare instances contains tubules composed of a thin elastic membrane surrounded by long cylindrical cells, each sending a process through the membrane into the lumen of the tubule. The elements of these tubules are histologically analogous to the cone-nucleus, membrana limitans externa, and cone-body of the normal retina, and such tumors have been called *neuro-epithelioma*.

The **prognosis** of glioma is very bad, only about 10 per cent. of the patients being permanently cured by operation, the others dying mostly within a year, from local recurrence.

**Treatment.**—Enucleation should be done early and the optic nerve resected far back. If the disease has extended into the orbital tissues behind the eyeball, only complete evisceration of the orbit with removal of the periosteum can be of any avail.

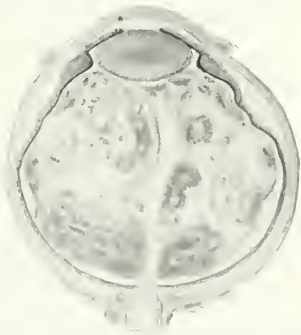

FIG. 316.—Glioma exophytum.

**Tumors of the Intraocular End of the Optic Nerve.**—These include *hyaline bodies* and *sarcoma*.

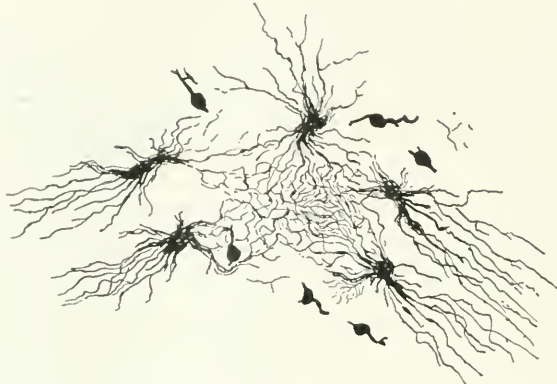


FIG. 317.—Glioma stained by Golgi's method, showing neuroglia-tissue and scattered small nerve-cells.

I. **Hyaline bodies** are found in the optic disks of young persons with eyes otherwise healthy and having normal vision, and also in eyes with optic neuritis or with pigmentary or albuminuric retinitis. In most cases a few discrete, lustrous, pearly globules are seen in the disk, but these globules may be present in such number as to cover the disk, and even spread beyond it in a confluent mass like frog-spawn (see Fig. 265).



FIG. 318.—Hyaline bodies in the nerve-head.

Microscopically, we find laminated hyaline masses lying among the fiber-bundles. The exact pathogenesis of these bodies is unknown, the old view, that they are products of the retinal pigment-epithelium, like the so-called colloid excrescences on the lamina vitrea, now being given up, since the bodies are often present in the disk when the pigment-epithelium is healthy (Fig. 318), and they are never surrounded by pigment like the others (see also page 453).

II. **Sarcoma of the optic disk** has been seen a few times as a hemispherical tumor involving the adjacent retina and projecting forward into the vitreous. It is always an extension from sarcoma farther back in the optic nerve, and it can be differentiated from a tumor of the choroid overlapping or involving the disk by the fact that the retrobulbar tumor from which it extended must have caused an exophthalmos before the tumor appeared in the eye.

# MOVEMENTS OF THE EYEBALLS, AND THEIR ANOMALIES.

BY ALEXANDER DUANE, M. D.,  
OF NEW YORK CITY.

**Physiological Action of the Ocular Muscles.**<sup>1</sup>—The actions of the external ocular muscles, deduced partly from our knowledge of their origins and insertions, partly from the results produced by their paralysis, are as follows:<sup>2</sup>

The external rectus (abducens) rotates the eye directly outward (*abduction*).

The internal rectus rotates the eye directly inward (*adduction*).

The superior rectus carries the eye upward, adducts it, and rotates the upper end of the *vertical meridian* of the cornea inward (*inward torsion, intorsion*). Its power of producing adduction and torsion increases as the eye is adducted, and decreases as the eye is abducted; its elevating power, on the contrary, is greatest when the eye is abducted between 20° and 30°, and diminishes to zero as the eye is adducted.

The inferior rectus carries the eye downward, adducts it, and causes outward torsion of the vertical meridian of the cornea (*extorsion*). As in the case of the superior rectus, the power of producing adduction and torsion increases and the vertical action diminishes the more the eye is carried inward; and, contrariwise, it acts most powerfully as a depressor (and not at all as an adductor) when the eye is abducted 20° or 30°.

The superior oblique (trochlearis) depresses the eye, abducts it, and rotates the vertical meridian inward. The power of producing abduction and torsion increases and the vertical action decreases in proportion as the eye is abducted. In positions of adduction, on the contrary, the superior oblique serves mainly to depress the eye, its action in this regard increasing as that of the inferior rectus diminishes.

The inferior oblique elevates the eye, abducts it, and rotates the vertical meridian inward. The power of producing abduction and torsion increases in proportion as the eye is abducted, while the elevating action increases as the eye is adducted, the effect of the muscle in this regard becoming constantly greater as that of the superior rectus grows less.

It will be seen from this that elevation and depression of the eye are effected mainly by the obliques when the eye is adducted and by the superior and inferior recti when the eye is abducted; also that the adducting action of

<sup>1</sup> See also pages 41, 42, and 100.

<sup>2</sup> The researches of Volkmann and Fuchs upon the insertion of the ocular muscles have shown that slight variations from the actions here laid down may occur; but such variations are inconstant, and in no case great enough to invalidate the statements of the text.



the superior and inferior recti increases (and the opposing action of the obliques diminishes) in proportion as the eye is adducted; and that the abducting action of the obliques increases (and the opposing action of the recti diminishes) in proportion as the eye is abducted. Hence, while abduction is performed mainly by the external rectus, the latter is reinforced especially toward the end of its course by the obliques; and the internal rectus is similarly reinforced by the superior and inferior recti, which, when the eye is already much adducted, will carry it appreciably farther in.

Lastly, it will be seen that, in directions of the gaze up and in, the torsion-action of the superior rectus will predominate; in directions up and out, that of the inferior oblique; in directions down and out, that of the superior oblique; and in directions down and in, that of the inferior rectus. Consequently, when we look up and in or down and out, the vertical meridian of the cornea is tilted toward the nose; when we look up and out or down and in, it is tilted toward the temple. When we look straight up or straight down (and also when we look straight to the right or left), the torsion actions of the oblique muscles and of the recti counteract each other, and hence the vertical meridian remains vertical.

**Movements of Each Eye.**—By the combined action of two or more ocular muscles the eye may be moved in any direction whatever. Thus a movement obliquely upward and inward requires the co-operation of three muscles—*i. e.* of both elevators and of the internal rectus, the latter (assisted by the superior rectus) carrying the eye inward, while the inferior oblique and, to a moderate extent, the superior rectus carry it upward.

In moving the eye obliquely up or down three muscles are always called into play (*viz.* both elevators or both depressors, combined with either the external or the internal rectus); in moving the eye straight upward, four (*i. e.* all except the two depressors); in moving the eye straight downward, four (all except the two elevators); in moving the eye directly inward, five (all except the external rectus); and in moving it directly outward, five (all except the internal rectus).

All these movements start from a position of rest, or *primary position*. When the eye is in this position the muscles are all balanced—*i. e.* if all six contract simultaneously to an equal extent, they will keep the eye fixed where it is. In all other directions of the gaze (*secondary positions*) the eye is so placed that some one muscle or pair of muscles works to greater advantage than the antagonistic muscle or pair. In this case, if all six muscles contract simultaneously, the muscle that works to greater advantage will exert a preponderating action, and will hence tend to displace the eyeball away from the position it occupies, and in such a manner always as to carry it back toward the primary position.

For most eyes the primary position is that in which the visual line is directed horizontally or nearly so and straight ahead (*i. e.* is perpendicular to the line joining the centers of rotation of the two eyes).<sup>1</sup> The eyes should always be placed in this position when any tests are made for ascertaining whether or not the muscles are in equilibrium.

**Field of Fixation.**—By passing from the primary to all possible secondary positions the eye is enabled to fix a great number of objects—*i. e.*

<sup>1</sup> The primary position is more exactly defined as being the only position from which both vertical and horizontal movements can be executed without affecting the position of the vertical meridian of the cornea. Movements from one secondary position to any other in general cause a rotation of the vertical meridian (torsion movement), which can be demonstrated by means of the after-images. This fact is utilized in determining experimentally when the primary position has been reached.

bring the images of these objects successively upon the macula. The portion of space occupied by all such objects that can thus be fixed by movement of the eye alone without moving the head is called the *field of fixation*.

Its limits represent the limits of excursion of the eye in all possible directions. These limits can be best determined by fixing the patient's head upon the rest of a perimeter in such a way that the eye when in the primary position is directed toward the zero of the perimetric arc, and then carrying along the latter a card with two fine dots set close together upon it. The patient is told to follow the dots with his eye without moving his head. The moment when he fails to do so is evidenced objectively by the wavering of the eye, and subjectively by the fact that the two dots are no longer seen distinctly as two, but run into one. Then the point on the perimetric arc to which the card has been carried indicates the amount of excursion of the eye in the given direction.

The limits of the field of fixation have been variously stated. My own observations (37 measurements of 18 different subjects) gave—

*Field of Fixation.*

|                   | Up. | Up<br>and out. | Up<br>and in. | Out. | In. | Down. | Down<br>and in. | Down<br>and out. |
|-------------------|-----|----------------|---------------|------|-----|-------|-----------------|------------------|
| Average . . . . . | 43° | 46°            | 49°           | 51°  | 53° | 63°   | 54°             | 61°              |
| Minimum . . . . . | 35° | 35°            | 35°           | 40°  | 40° | 35°   | 32°             | 38°              |

Reduction of the excursion of the eye (*contraction of the field of fixation*) to less than 30° in any direction must, if substantiated by repeated tests, be regarded as distinctly pathological (see also page 169).

**Binocular Vision and Diplopia.**—We ordinarily use both eyes in seeing (*binocular vision*), and the eyes are involuntarily so adjusted that the image of the object looked at falls simultaneously upon both maculae (*binocular fixation*). Under these conditions we see singly because the two images are by our consciousness fused into one image, which has somewhat different characters from either of its components (*binocular single vision*). When one eye fails to fix simultaneously with the other, diplopia generally results. But diplopia will be absent if, as often happens, the image formed in the non-fixing eye is not taken account of by the consciousness (*monocular vision from suppression of image*); and one image may be thus suppressed even when both eyes are properly directed—*i. e.* there may be binocular fixation, but only monocular vision.

The *diplopia* produced by the fact that one of the eyes deviates from the object that the other eye is looking at is directly proportional to the amount of deviation. It may be *corrected* by an appropriate movement of the deviating eye or by placing before the eye a prism so directed as to make the rays coming from the object change their course and fall upon the macula.

*Per contra*, *diplopia may be produced without any deviation of the eyes* by putting before the latter a prism which will deflect off from the macula the rays that would otherwise be concentrated upon it. In this case the artificial diplopia may be corrected (or the *prism may be "overcome"*) by turning the eye until the macula is so directed as to meet the deflected rays.

When an eye either is deflected to the right or has placed before it a prism with its base directed to the right, an object situated straight ahead will form its image to the right of the macula, instead of upon the latter. But experience and the sense of touch continually teach us that an object which forms its image on the right of the macula is itself situated to our left;

hence, under the conditions noted the object no longer appears straight ahead, but deflected to the left, and by as great an amount as the eye itself is deflected to the right. So also when the eye is deviated up, an object straight ahead appears lower than it is; and in general, however an eye may be deflected, the apparent position of objects seen with it is deflected in the contrary way.

These facts may be expanded for the particular cases as follows :

*Varieties of Diplopia.*

| NAME.                            | CHARACTER:<br>Image of R. eye as compared with that of L. is | CAUSED BY                                                          |                                                       | CORRECTED BY                                                     |                                                       |
|----------------------------------|--------------------------------------------------------------|--------------------------------------------------------------------|-------------------------------------------------------|------------------------------------------------------------------|-------------------------------------------------------|
|                                  |                                                              | (1) A natural deviation of                                         | (2) Artificially by a prism placed, base              | (1) Turning                                                      | (2) Prism placed, base                                |
| Homonymous diplopia.             | On R. side.                                                  | Either eye <i>inward</i> (esophoria, strabismus convergens).       | <i>In</i> , before either eye.                        | Both eyes <i>outward</i> . (Divergence.)                         | <i>Out</i> before either eye.                         |
| Heteronymous (crossed) diplopia. | On L. side.                                                  | Either eye <i>outward</i> (exophoria, strabismus divergens).       | <i>Out</i> , before either eye.                       | Both eyes <i>inward</i> . (Convergence.)                         | <i>In</i> before either eye.                          |
| Right diplopia.                  | Below.                                                       | R. eye <i>up</i> or L. eye <i>down</i> (R. hyperphoria).           | <i>Up</i> before R. eye or <i>down</i> before L. eye. | R. eye <i>down</i> , and L. eye <i>up</i> . (L. sursumvergence.) | <i>Down</i> before R. eye or <i>up</i> before L. eye. |
| Left diplopia.                   | Above.                                                       | R. eye <i>down</i> or L. eye <i>up</i> (L. hyperphoria).           | <i>Down</i> before R. eye or <i>up</i> before L. eye. | R. eye <i>up</i> , and L. eye <i>down</i> . (R. sursumvergence.) | <i>Up</i> before R. eye or <i>down</i> before L. eye. |
| Homonymous torsion-diplopia.     | Tilted to R.                                                 | Either vertical meridian <i>inward</i> (convergence of meridians). | . . .                                                 | Both vertical meridians <i>outward</i> . (Distorsion.)           |                                                       |
| Heteronymous torsion-diplopia.   | Tilted to L.                                                 | Either vertical meridian <i>outward</i> (divergence of meridians). | . . .                                                 | Both vertical meridians <i>inward</i> . (Contorsion.)            |                                                       |

**Associated Movements of the Two Eyes : Parallel Movements.**

—As has been stated, binocular single vision is attained only when both eyes are directed precisely at the object of fixation, and under normal conditions the two eyes invariably move together in such a way as to effect this end, and that, too, at once and with the utmost precision. In the case of a distant object the movements of the eyes must be such as to keep the two visual lines strictly parallel (*associated parallel movements*). The typical movements of this class are shown in the following table :

*Associated Parallel Movements.*

(a) *Both eyes move directly to R. (Dextroversion).*

R. eye carried to R. by external rectus, assisted, especially toward the end of its excursion, by the two obliques. The latter, together with the superior and inferior recti, by their equal counter-traction steady the eye, and thus both maintain it in the horizontal plane and keep its vertical meridian vertical.

L. eye carried to R. by internal rectus, assisted, especially toward the end of its course, by the superior and inferior recti. The latter, together with the obliques, by their equal counter-traction steady the eye and keep its vertical meridian vertical.

(b) *Both eyes move directly to L. (Lævoersion).*

R. eye carried to L. by internal rectus, assisted, especially toward the end of its excursion, by the superior and inferior recti. The latter, together with the obliques, by their equal counter-traction steady the eye and keep its vertical meridian vertical.

L. eye carried to L. by external rectus, assisted, especially toward the end of its course, by the obliques. The latter, together with the superior and inferior recti, by their equal counter-traction steady the eye and keep its vertical meridian vertical.

(c) *Both eyes move directly up (Sursumversion).*

R. eye carried up by superior rectus and inferior oblique. These muscles exactly neutralize each other in their lateral tendencies and their action upon the vertical meridian, so that the eye goes straight up and the vertical meridian remains vertical. The external and internal recti steady the eye.

L. eye carried up by superior rectus and inferior oblique, and steadied by external and internal recti, as in the case of the R. eye. Vertical meridian remains vertical.

(d) *Both eyes move obliquely up and to R.*

R. eye carried up mainly by superior rectus; to R. mainly by external rectus, assisted by inferior oblique. The torsion action of the latter preponderating over that of the superior rectus, the vertical meridian is rotated out (to the R.).

L. eye carried up mainly by inferior oblique; to R. by internal rectus, assisted by superior rectus. The torsion action of the latter preponderating over that of the inferior oblique, the vertical meridian is rotated in (to the R.).

(e) *Both eyes move obliquely up and to L.*

R. eye carried up mainly by inferior oblique; to L. by internal rectus, assisted by superior rectus. The torsion action of the latter preponderating over that of the inferior oblique, the vertical meridian is rotated in (to the L.).

L. eye carried up mainly by superior rectus; to L. by external rectus, assisted by inferior oblique. The torsion action of the latter preponderating over that of the superior rectus, the vertical meridian is rotated out (to the L.).

(f) *Both eyes move directly down (Deorsumversion).*

R. eye carried down by inferior rectus and superior oblique. These muscles exactly neutralize each other in their lateral tendencies and their action upon the vertical meridian, so that the eye goes straight down and the vertical meridian remains vertical. The external and internal recti steady the eye.

L. eye carried down by inferior rectus and superior oblique and steadied by the external and internal recti, as in the case of the R. eye. Vertical meridian remains vertical.

(g) *Both eyes move obliquely down and to R.*

R. eye carried down mainly by inferior rectus; to R. by external rectus, assisted by superior oblique. The torsion action of the latter preponderating, the vertical meridian is rotated in (to the L.).

L. eye carried down mainly by superior oblique; to R. by internal rectus, assisted by inferior rectus. The torsion-action of the latter preponderating, the vertical meridian is rotated out (to the L.).

(h) *Both eyes move obliquely down and to L.*

R. eye carried down mainly by superior oblique; to L. by internal rectus, assisted by inferior rectus. The torsion action of the latter predominating, the vertical meridian is rotated out (to the R.).

L. eye carried down mainly by inferior rectus; to L. by external rectus, assisted by superior oblique. The torsion action of the latter predominating, the vertical meridian is rotated in (to the R.).

An inspection of the foregoing table will show that the twelve muscles that serve to carry the two eyes in parallel directions may be divided into six pairs, one muscle of each pair being in the right eye and the other in the left, and the two moving their respective eyes in the same direction and to the same extent. The muscles constituting such a pair are called *associated antagonists*.



*Associated Antagonists.*

| R. eye.           | L. eye.           | Moves eye to which it belongs—                                                                                                                                                                        |
|-------------------|-------------------|-------------------------------------------------------------------------------------------------------------------------------------------------------------------------------------------------------|
| External rectus.  | Internal rectus.  | To R. (dextroduction). No vertical nor torsion action.                                                                                                                                                |
| Internal rectus.  | External rectus.  | To L. (levoduction). No vertical nor torsion action.                                                                                                                                                  |
| Superior rectus.  | Inferior oblique. | Up, to L. (levoduction), and rotates vertical meridian to L. (levotorsion). Elevating action increases as eyes are carried to R.; lateral and torsion movements increase as eyes are carried to L.    |
| Inferior oblique. | Superior rectus.  | Up, to R. (dextroduction), and rotates vertical meridian to R. (dextrotorsion). Elevating action increases as eyes are carried to L.; lateral and torsion actions increase as eyes are carried to R.  |
| Inferior rectus.  | Superior oblique. | Down, to L. (levoduction), and rotates vertical meridian to R. (dextrotorsion). Depressing action increases as eyes are carried to R.; lateral and torsion actions increase as eyes are carried to L. |
| Superior oblique. | Inferior rectus.  | Down, to R. (dextroduction), and rotates vertical meridian to L. (levotorsion). Depressing action increases as eyes are carried to L.; lateral and torsion actions increase as eyes are carried to R. |

The amount of excursion in every direction made by a pair of eyes in following a more or less distant object which they simultaneously fix determines the *field of binocular fixation*; and the amount of excursion that they can make and yet preserve parallelism of their axes, so that no diplopia ensues, determines the *field of binocular single vision*. This latter extends not less than  $40^\circ$  (normally from  $40^\circ$  to  $50^\circ$ ) in every direction from the primary position; and diplopia, occurring uniformly when the eyes have been carried less than  $30^\circ$  from the primary position, is distinctly pathological.

The tendency to maintain parallelism of the visual lines is so great as to persist even when one eye is excluded by blindness or by being covered with a screen; so that one eye keeps moving with the other, and binocular fixation is maintained in all directions of the gaze, although only one eye sees the object fixed. Upon this fact depends the test by alternate covering (*screen test*).

The associated parallel movements are apparently governed by a *nervous mechanism* distinct from the nuclei that supply the nerves for the ocular muscles; and each of the typical movements (*dextroversion*, *sinistroversion*, *sursumversion*, *deorsumversion*, and perhaps the *oblique movements* also) seems to have its separate center. The precise location of these centers, however, has not yet been satisfactorily determined.

**Movements of Convergence.**—By means of the associated parallel movements both eyes can be simultaneously directed at any distant object situated within the limits of the field of fixation. To direct them both at once at some near object requires a greater or less degree of *convergence* of the visual lines, and this is effected by a simultaneous equal contraction of the two interni. This movement, which under normal conditions takes place invariably, immediately, and with the utmost precision, and which, as in the case of the associated parallel movements, takes place even when one eye is excluded from seeing, is apparently governed by a *nerve-center* distinct from the nerve-nuclei of the internal recti.

When the object looked at is situated not straight ahead, but to one side or above or below, binocular fixation is effected by a combination of convergence with an associated parallel movement. Thus, in looking at an object situated near the eyes and  $45^\circ$  to the right of the median line, the two eyes first move, each,  $45^\circ$  to the right by a simultaneous equal contraction of the

right externus and the left internus (*dextroversion*); then by a simultaneous equal contraction of the right internus and the left internus (*convergence*) the right eye is turned somewhat to the left again and the left eye somewhat farther on to the right, until both visual lines are properly directed.

Even without being adjusted for near objects, the eyes tend to converge somewhat when directed downward.

The amount of convergence is measured by the distance from the nose of the point (*convergence near-point, Pc*) upon which the eyes can by the utmost effort be made to converge. This should be from 1 to  $1\frac{3}{4}$  inches from the nose. The convergence is also measured by the degree of prism, placed base out before the eyes, which the latter can overcome by turning inward (*prism-convergence*, improperly called the *adduction*). The prism-convergence, when a distant test-object is used, is represented by prisms of  $60^\circ$  to  $90^\circ$  total refracting angle (= a convergence of the visual lines of  $35^\circ$  to  $60^\circ$ ).

The maximum amount that each eye turns inward in performing convergence (*convergence-adduction*) is about  $30^\circ$ – $35^\circ$ . It is somewhat less, therefore, than the amount ( $40^\circ$ – $50^\circ$ ) by which each eye can turn inward when moving parallel with its fellow (*associated adduction* or *adduction proper*).

**Movements of Divergence.**—In passing from the consideration of near objects to those more remote the eyes diverge from each other. They can even diverge beyond parallelism (*i. e.* become absolutely divergent), as, for example, when they look at a distant object through a prism placed, base in, before them, and then overcome the diplopia which the latter produces. The amount of this absolute divergence or diverging power (*prism-divergence*, improperly called the *abduction*) is from  $6^\circ$  to  $8^\circ$  prism (= an actual separation of the visual lines of only  $3^\circ$  to  $4^\circ$ ). The absolute diverging power (*divergence-abduction*) of each eye, therefore, amounts to only  $2^\circ$ . It must not be confounded with the *abduction proper* (*associated abduction*), or absolute degree of rotation of each eye outward in performing associated parallel movements, which is  $40^\circ$ – $50^\circ$ .

The movement of divergence consists either in a simultaneous equal relaxation of the two interni, or, more probably, in a simultaneous equal contraction of the two externi. It is often combined with associated parallel movements. Thus, if a prism of  $8^\circ$  is placed, base in, before the left eye, each eye will turn out through an angle of  $2^\circ$  in order to fuse the double images (*divergence*); then, in order to bring the images on the maculae of the two eyes, each eye will turn  $2^\circ$  to the left (*sinistroversion*), so that the right eye is directed straight ahead, the left eye  $4^\circ$  to the left.

A slight divergence of the visual lines occurs normally when both eyes are directed upward.

**Movements of Sursumvergence.**—Divergence of the visual lines in a vertical plane, so that one rises above the other, is called *sursumvergence*,<sup>1</sup> and this, again, is denoted as *right* or *left* according as the right or left eye is the higher. Right and left sursumvergence are normally equal, but are very limited in amount (= only  $2^\circ$  prism, or  $1^\circ$  of actual separation of the visual lines). The movement is undoubtedly distributed equally between the two eyes, so that a movement of right sursumvergence is the same thing as a movement of left deorsumvergence—*i. e.* in both cases the right visual line moves up and the left visual line moves down, and each moves to an equal extent. Neither the upward movement of one visual line nor the downward movement of the other can be regarded as a measure of the power of the

<sup>1</sup> Usually called sursumduction, but this term is properly applied to mean the absolute degree of movement of either eye upward—a movement of some  $40^\circ$  in extent.

elevators and depressors of the eye, which is determined rather by the sursumduction (in the proper sense of the term)—*i. e.* the absolute ability of either eye to move upward (= about  $40^\circ$ ), and the deorsumduction, or ability of either eye to move downward (=  $50^\circ$ – $60^\circ$ ).

*Right sursumvergence* is measured by the degree of prism placed base down before the right eye (or base up before the left eye), and *left sursumvergence* by the prism placed base down before the left eye (or base up before the right eye), which the eyes can overcome.

#### VARIETIES, CLASSIFICATION, ETIOLOGY, AND GENERAL SYMPTOMS OF MUSCULAR ANOMALIES.

**Varieties of Deviations.**—All the movements of the eyes, described above, may be deranged pathologically, and the derangement may take the form of over-action, under-action, or perverted action. The result of these derangements is that binocular fixation and binocular single vision are interfered with, so that one of the eyes deviates or tends to deviate from the object looked at.

**Strabismus and Heterophoria.**—A marked deviation which the patient cannot in general overcome is called a *squint* or *strabismus* (heterotropia, manifest deviation); one which, being moderate in amount, is habitually overcome by muscular effort, and hence is elicited only by special tests, is called a *heterophoria* or *insufficiency* (latent squint, latent deviation).

A deviation is further classed as *constant*, if present all the time; *intermittent*, if sometimes present, sometimes absent; and *periodic*, if regularly recurring under certain conditions (*e. g.* if the accommodation is used).

**Measurement of Deviations.**—The magnitude of the deviation may be measured directly by ascertaining either how far the deviating eye stands in or out when the other eye is looking straight ahead, or how far it has to turn in or out in order to perform fixation when the other eye is screened (*screen-test*). The amount of this deflection or of this movement may be got at by taking a linear measurement along the edge of the lower lid,<sup>1</sup> or it may be determined directly in degrees by means of a perimeter or a tangent scale. Objective measurement performed in this way is termed *strabometry*.

*Indirectly*, the amount of a deviation is determined by the amount of diplopia which it produces, this latter, again, being measured either by the actual distance between the double images or by the strength of the prism required in order to unite them (see *Table of Diplopia*, p. 500). When no diplopia exists spontaneously, the artificial diplopia produced by the various forms of *phorometer* and the amount of *parallaxic displacement* that the object looked at undergoes when a screen is shifted from one eye to the other, serve as a precise measure of the deviation.

It frequently happens, especially in constant and periodic squint, that the deviation is confined to one eye, the other performing fixation all the time. In this case the non-fixing eye is apt to be amblyopic; but whether the poor sight is congenital and gives rise to the deviation, or whether it is itself the result of the latter and springs from the habitual suppression of the visual image (amblyopia from disuse, *amblyopia exanopsia*) or from the injurious effects of the diplopia upon the squinting eye, is not certain.

In many cases, especially in intermittent squint, and almost always in

<sup>1</sup> Each millimeter = about  $4\frac{1}{2}^\circ$  actual deviation.

heterophoria, fixation is performed by each eye alternately (*alternating deviation*).

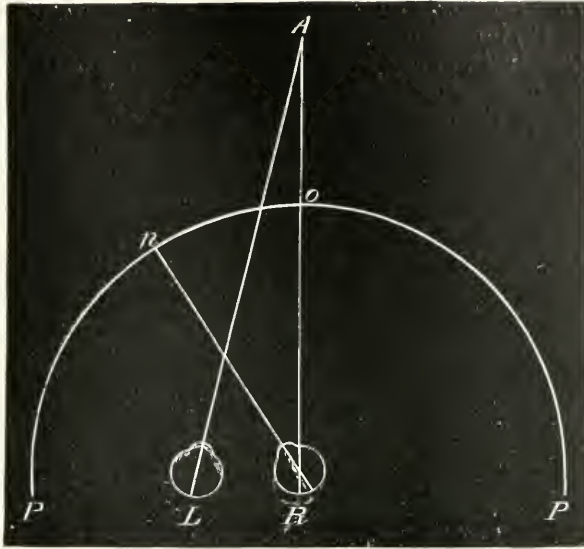


FIG. 319.—Measurement of squint with a perimeter:

The deviating eye *R* is placed at the center of the graduated arc of the perimeter *PP*, the arc lying on the plane of the deviation. The patient is then required to fix with *his two eyes* a distant object, *A*, situated along the central radius *RoA*. This is the direction which the deviating eye should have in the normal condition. The point *n* to which the eye in reality is directed should now be determined; the angle *ORn*, formed by the deviating line of sight *n* with the normal line of sight *AoR*, is the *angle of the strabismus*. In order to obtain this angle, it would be necessary only to determine the precise direction of the line of sight of the deviating eye. As this is not an easy matter, it is sufficient in practice to determine the direction of the corneal axis; this differs from the former only by a small angle, which, in comparison with the large angle of the strabismus, may be neglected. The flame of a candle is moved along the arc of the perimeter until its reflection is in the center of the pupil. This will occur when the flame is at *n*. The corneal axis has now been found, and the size of the angle of strabismus may be read off.

Deviations are also classed according to the *direction* of the deviating eye, as follows:

| Deviating eye turns | Deviation apparent or manifest (squint, strabismus).                                            | Deviation latent (elicited only by special tests); eyes usually perform binocular fixation. |
|---------------------|-------------------------------------------------------------------------------------------------|---------------------------------------------------------------------------------------------|
| In.                 | Strabismus convergens (convergent squint, esotropia).                                           | Esophoria.                                                                                  |
| Out.                | Strabismus divergens (divergent squint, exotropia).                                             | Exophoria.                                                                                  |
| Up.                 | Strabismus sursumvergens; hypertropia (R. or L., according as R. or L. visual line is higher).  | Hyperphoria (R. or L., according as R. or L. visual line is higher).                        |
| Down.               | Strabismus deorsumvergens; hypertropia (R. or L., according as R. or L. visual line is higher). | Hyperphoria (R. or L., according as R. or L. visual line is higher).                        |

The condition in which there is no tendency to deviation in the primary position is called *orthophoria*.

**Etiology of Ocular Deviations; Etiological Classification.**—Ocular deviations may be grouped according to their etiology, as follows:



## CLASSIFICATION.

- I. Anomalies of the individual muscles :
  - (a) *Under-action*, due to faults in (1) structure, (2) insertion, and (3) innervation.
  - (b) *Over-action*, due to faults in (1) structure, (2) insertion, and (3) innervation.
- II. Anomalies of the association-centers for parallel movements :
  - (a) *Under-action*, producing an impairment of the movements of both eyes either (1) up, (2) down, (3) to the right, (4) to the left, or (5) obliquely (*associated paralysis, conjugate paralytic deviation*).
  - (b) *Over-action*, producing an equal excessive movement or equal spastic deviation of both eyes in the same direction (*associated spasm, conjugate spastic deviation*).
  - (c) *Perverted action*, clonic spasm of associated movements (*nystagmus*).
- III. Anomalies of the center for convergence movements :
  - (a) *Under-action*, convergence-insufficiency, either (1) accommodative or (2) non-accommodative.
  - (b) *Over-action*, convergence-excess, either (1) accommodative or (2) non-accommodative.
- IV. Anomalies of divergence movements :
  - (a) *Under-action*, divergence-insufficiency.
  - (b) *Over-action*, divergence-excess.
- V. Anomalies of sursumvergence :
  - (a) *Under-action*, sursumvergence-insufficiency.
  - (b) *Over-action*, sursumvergence-excess.

## SUMMARY.

- I. *Associated parallel deviations* (conjugate deviations) may be due to—
  - (a) Under-action of one of the centers for producing associated parallel movements (conjugate paralysis).
  - (b) Over-action of one of the centers for producing associated parallel movements (conjugate spasm).
- II. *Convergent deviations* (esophoria, convergent strabismus) may be due to—
  - (a) Over-action of one or both internal recti or of the other adductors of the eye (superior and inferior recti).
  - (b) Under-action of the external rectus or of the other abductors (the obliques).
  - (c) Under-action of divergence movements (divergence-insufficiency).
  - (d) Over-action of the center for producing convergence movements (convergence-excess, which in turn may or may not be due to excessive accommodative action).
  - (e) Two or more of the above causes combined.
- III. *Divergent deviations* (exophoria, divergent strabismus) may be due to—
  - (a) Under-action of the internal rectus or of the other adductors (superior and inferior recti).
  - (b) Over-action of the external rectus or of the obliques.
  - (c) Under-action of the center for producing convergence movements (convergence-insufficiency, which, in turn, may or may not be due to insufficiency of accommodative action).

- (d) Over-action of divergence movements (divergence-excess).
- (e) Two or more of the above causes combined.

IV. *Upward and downward deviations* (hyperphoria, strabismus sursumvergens and deorsumvergens) may be due to—

- (a) Over-action of an elevator or depressor muscle.
- (b) Under-action of an elevator or depressor muscle.
- (c) Under-action or over-action of sursumvergence.
- (d) Two or more of the above causes combined.

V. *Mixed forms* (hyperphoria combined with exophoria, hyperphoria combined with esophoria, and esophoria in one part of the field of view combined with exophoria in another) are frequent.

**Comitant and Non-comitant Deviations.**—Ocular deviations are divided into *comitant*<sup>1</sup> and *non-comitant*. In the former, one eye, even when deviating from the other, always deviates by the same amount, so that the two eyes in all their excursions maintain the same angle with each other. The most typical example of comitant deviations is afforded by the anomalies of the associated parallel movements (associated paralysis, associated spasm, nystagmus).

The ordinary forms of divergent and convergent squint are also generally comitant when they come under observation, although probably for the most part non-comitant in their origin, the comitaney in this case having developed as a result of the evolutionary tendency, described in the next section, by which new compensatory conditions are gradually superadded to the old ones.

In *non-comitant* deviations the deflection of the non-fixing eye keeps varying as the direction of the gaze is shifted, so that the angle between the two visual lines is continually changing. The most marked examples of non-comitance are furnished by disorders (under-action and over-action) of the individual muscles.

Anomalies of convergence and divergence, when uncomplicated, occupy a middle ground between the comitant and the non-comitant deviations. They are comitant in that for any one distance the deflection remains the same whether the eyes are carried up or down or from side to side, but are non-comitant in that the deflection changes in amount in proportion as the object looked at is brought nearer to the eyes or away from them. They are, however, usually classed as comitant.

The *differential diagnosis* between comitant and non-comitant deviations may be thus stated:

*Comitant Deviations.*

Due to some condition affecting the movements of both eyes equally.

Hence, if simple, are due to derangement of one of the centers which effect the movements of both eyes together (association-centers, centers governing divergence and convergence movements).

Often complex, and then due to compensatory changes (contractures, etc.) gradually developing in an eye that was formerly the seat of a non-comitant deviation.

*Non-comitant Deviations.*

Due to some condition affecting the movements of one eye more than the other.

Due to an anomaly in structure or insertion of the muscles of one eye, or to an anomaly of the nerves and nerve-nuclei which supply these muscles and which subserve unioocular movement.

Usually simple.

<sup>1</sup> The term "comitant," already used by others, has been adopted here (at the suggestion of Dr. H. Knapp), instead of the more usual "concomitant," which is less wieldy, and also not as well formed from an etymological point of view.

*Comitant Deviations.*

Deviating eye follows the other in all its movements, maintaining the same angle with it. The total range of excursion and total extent of the field of fixation of one eye equal those of the other, but in the deviating eye both are limited in some one direction, and are increased to a like amount in the opposite direction.

Diplopia often absent, or, if present, readily ignored. Patient often fails to recognize double images produced by prisms.

Deviation behind screen, parallax, deviation measured by the phorometer, diplopia (if present), and other symptoms same in amount in all directions of the gaze.

Deviation behind screen of the deflected eye equals that of the non-deflected eye.

*Non-comitant Deviations.*

Deviating eye lags behind or shoots ahead of the other for certain directions of the gaze. The angle of deviation keeps continually changing. The range of excursion and field of fixation of the deviating eye are either abnormally large or abnormally small in some one direction of the gaze, and in other directions are normal. Total range of excursion abnormally large or small.

Diplopia usually present and apt to persist.

Deviation behind screen, parallax, deviation measured by the phorometer, diplopia, and other symptoms increase markedly and progressively as the eyes are carried in some one direction, and diminish when the eyes are carried in the opposite direction.

Deviation of the two eyes behind the screen unequal, that of the sound eye being the greater if the affected eye is paretic or otherwise limited in action, and that of the affected eye being the greater if the affected eye is the subject of spasm or over-action.

**Conversion of Non-comitant into Comitant Deviations.**—In non-comitant deviations the deflection is marked for some directions of the gaze, while for other directions the conditions are normal. If, now, some new condition is superadded by which the deflection is made equally marked for all directions of the gaze, the deviation will become comitant. This, in fact, is what tends to take place naturally in all non-comitant anomalies.<sup>1</sup> Thus, a paresis of the right external rectus produces an inward deflection of the right eye, which at the outset is marked only when the eyes are directed to the right. After a time, however, spastic contracture of the right internus develops, which causes an inward deflection of the right eye when the eyes are directed to the left, as well, so that ultimately a condition is produced closely simulating a comitant strabismus convergens.<sup>2</sup> Again, an exophoria due to a convergence-insufficiency is at first present only when the eyes are directed at near points; but after this condition has persisted for a long time the action of divergence for distance, hitherto normal, becomes excessive (divergence-overaction), and the exophoria becomes marked for distance also. So, too, a periodic convergent squint, in which the eyes are straight for distance, but, owing to convergence-overaction, converge excessively when directed at near objects, is finally converted into a constant squint—*i. e.* becomes marked for distance, too, through the development of an insufficiency of the diverging power or perhaps of an insufficiency of the external recti. In this way a deviation that was comitant only for one range becomes comitant for all.

**Subjective Symptoms of Deviations.**—The subjective symptoms produced by ocular deviations are—(1) diplopia and blurring of sight, (2) false projection and apparent motion of objects, (3) vertigo, (4) asthenopia, (5)

<sup>1</sup> Except in cases of congenital paralysis or absence of a muscle.

<sup>2</sup> In fact, probably a number of cases of comitant squint are produced in this very way.

pain in the eyes with conjunctival irritation and blepharitis, (6) headache and neuralgia, and (7) other reflex disturbances, including backache, nausea, impairment of nutrition and energy (sometimes considerable in amount), choreiform spasms, and occasionally graver conditions, such as epilepsy.

1. *Diplopia* is homonymous, heteronymous, or vertical (right or left) according as the deviation is convergent, divergent, or vertical (right or left hyperphoria) (see *ante*, *Table of Diplopia*). Its amount, measured in degrees, is equal to the amount of the deviation present at the time. In ordinary comitant squint (insuperable deviation) it is usually absent, because the image formed by the non-fixing eye is either too indistinct to be noticed or is actually suppressed;<sup>1</sup> in non-comitant squint it is usually present, at least in the earlier stages of the affection; and in superable deviations (heterophoria) it is present at times, although generally overcome by appropriate forced movements of the eyes (see *Table of Diplopia*).

In slight deviations the amount of diplopia is just sufficient to cause overlapping of the double images, producing thereby a considerable *blurring* of the object looked at. This is particularly marked for reading, in which the letters, as they double, become superimposed, and hence appear run together. This confusion of sight is distinguished from that due to an error of refraction by the fact that it disappears as soon as either eye is covered.

In general the slighter degrees of diplopia, and especially those that can be corrected by voluntary effort, are less readily negligible than is a diplopia of larger amount, and hence give rise to more confusion and trouble.

2. *False projection of objects* (*i. e.* the seeing of objects in the wrong place) is particularly noticeable in deviation due to paresis or spasm of an ocular muscle. In this case, when the eye has to use the affected muscle in order to look toward an object, the amount of energy put forth by the muscle is out of proportion to the amount of nerve-impulse sent to it, and hence the patient feels as if the eye had moved much farther or much less than it really has. Thus a patient with a paresis of the right externus when looking at an object situated to his right would regard the object as much farther to the right than it really is, because he has to make a very great effort with the paretic muscle to move the eye as far as he needs to do; and this excessive effort corresponds in his experience to an excessive movement of the eye to the right—*i. e.* to the act of looking at an object that is situated very far to the right. The same thing would take place if he had a paresis of the dextroversion-center (the association-center for turning both eyes to the right). On the contrary, if he had a spasm of the right externus (or of the dextroversion-center), an object situated on his right would appear less far to that side than it really is.

One consequence of this false projection is that objects whose place is thus wrongly conceived of *appear to move* when the eyes are turned or when the patient approaches them. The reason of this is that the amount of displacement of an object from its true situation, produced by false projection, varies with the different positions of the eyes, so that when we change the position (by turning the eyes or by approaching the object) the object appears to be at one moment in its true place, at the next moment out of it—*i. e.* appears to have moved from one place to another.

This apparent movement of objects, together with the diplopia and the unequal strain put upon the eye-muscles, is the cause of the *vertigo* that so often accompanies ocular deviations.

<sup>1</sup> Suppression implies that the image produces its proper impression upon the sensorium, but that the patient by some mental process excludes this impression from his consciousness.



If binocular single vision is lost, the power of appreciating depths and distances is necessarily much impaired (*loss of stereoscopic vision*).

3. The remaining symptoms (*asthenopia, headache, eye-pain*, and the various *reflex disturbances*) are due to the strain imposed upon the muscles when overcoming a deviation. They are hence more pronounced in heterophoria and in squint of low degree and in intermittent squint (in all of which conditions the patient tries with more or less success to overcome the deviation), than in a marked, constant strabismus, in which, as the deviation is insuperable, the patient makes no attempt to overcome it. Furthermore, the amount of asthenopia and reflex disturbance is roughly proportional to the amount of effort that the patient has to exert in overcoming the deviation. Hence these troubles are more marked in cases of insufficiency than of over-action;<sup>1</sup> and in cases requiring exercise of the comparatively weak diverging power (*e. g.* cases of divergence-insufficiency), and of the still weaker sursumverging power (*e. g.* cases of hyperphoria), than in cases such as those of divergence-excess, that demand exercise of the strong converging action for their compensation. In general, asthenopia is a marked feature of convergence-insufficiency, and eye-pain, with conjunctival irritation and blepharitis, is apt to be associated with the same affection; while headache, neuralgia, nausea, and disturbances of digestion and general nutrition are particularly prone to occur in connection with divergence-insufficiency and the vertical deviations.

#### CHARACTERS AND DIAGNOSIS OF THE INDIVIDUAL ANOMALIES.

**Affections of Individual Ocular Muscles** (*Paretic and Spastic Squint*).—**Etiology.**—Over-action or under-action of an ocular muscle may be due to three causes.

(a) Over-development or under-development of the muscle itself (*structural squint* and *heterophoria*). Thus, congenital non-development of the external rectus occurs, producing a convergent deviation; also congenital non-development of the superior rectus, producing a downward deviation of the eye, which may or may not be associated with ptosis. Again, over-growth of the externus, combined or not with non-development of the internus, is at the bottom of a number of cases of divergent squint or of exophoria; and a similar preponderance in muscular development of the internal recti accounts for many cases of convergent squint.

(b) Faulty insertion of the tendon of the muscle, causing undue laxity or tension of the latter, and giving a point of application for the muscular force, which is more advantageous or is less advantageous than normal (*insertional squint* or *heterophoria*). Examples of this are—(1) the deflection produced by a tenotomy or an advancement; (2) the over-action of the antagonist of a paralyzed muscle after structural changes (true contracture) have taken place in the former; and (3) the exophoria or divergent squint that develops in childhood as a result of increasing divergence of the orbits, a process which gives the externus a more favorable area of application than the internus. This process, which is a normal feature of development in childhood, may, if occurring in children that originally have the orbits set very close together, abrogate a convergent squint, or even cause the latter to pass gradually into a strabismus divergens.

(c) Paresis or spasm of a muscle due to an affection of its nerve or nerve-nucleus (*innervational anomalies, paretic and spastic squint, and heterophoria*).

<sup>1</sup> Because in insufficiency compensation is effected by means of weakly-acting muscles, and in over-action by means of normal muscles; and it is harder to bring weak muscles up to the normal than to make normal muscles act with extra energy.

The common causes of paresis are tertiary syphilis and its consequences (especially tabes), meningitis (especially tuberculous), pachymeningitis, tumors of the brain and skull, abscess and hemorrhage of the brain, exposure to cold (so-called rheumatic paralysis), traumatism, and hysteria. Paresis may also, although rarely, be due to diphtheria, diabetes, influenza, whooping-cough, and the action of poisons; and slight impairment of power occurs in neurasthenia and other conditions of nervous depression. Spasm, which is much less frequent than paralysis, is due to irritative lesions (meningitis, etc.), chorea, epilepsy, and hysteria; rarely is idiopathic. Spasm also occurs sooner or later in the antagonist of a paralyzed muscle, and ultimately leads to structural changes in the latter (contracture). A false or apparent spasm is the over-action which regularly occurs in the associated antagonist of a paralyzed muscle when an attempt is made to move the latter; the over-action in this case being the result of the excessive stimulus imparted to both muscles. Thus, a patient with a paralysis of the right externus who tries to look to the right makes an excessive effort, which effort causes the right eye to move to the right feebly and the left eye to move to the right very greatly and in an apparently spasmodic way, although, of course, spasm in the true sense of the word is not present here at all, since the eye is simply reacting normally to an excessive stimulus.

*One or several* muscles may be affected. In insertional and structural deviations isolated affections are frequent, and the muscles most apt to be involved are the external, internal, and superior recti. In innervational deviations, if but one muscle is affected, this is usually the external rectus (*abducens paralysis* or *spasm*), although isolated paralysis of the superior oblique (*trochlear paralysis*) is not uncommon. Isolated paralysis of the other muscles is less often met with, but combined paralysis of some or all of the muscles supplied by the third nerve (*oculomotor paralysis*) is frequent. Complete oculomotor paralysis causes loss of power in four out of the six exterior muscles of the eyeball, and also in the levator palpebræ (causing ptosis), the sphincter iridis (*iridoplegia*), and the ciliary muscle (*cycloplegia*). In some cases, caused generally by syphilis or by the action of poisons such as atropin, the paralysis is confined to the sphincter iridis and the ciliary muscle (*ophthalmoplegia interna*); in others to the sphincter iridis, producing mydriasis without any other symptoms; in others, especially when due to diphtheria, to the ciliary muscle, producing paralysis of accommodation alone; and in still other cases these muscles are exempt, but some or all of the exterior muscles of the eyeball are paralyzed (*ophthalmoplegia externa*). In rare cases all the muscles of the eyeball, exterior and interior, are paralyzed at the same time (*ophthalmoplegia totalis*).

**Symptoms.**—The symptoms of muscular under-action and over-action are—(1) limitation or excess of movement of the affected eye in some one direction—*i. e.* as the two eyes move together in that direction one of the two lags more and more behind the other, producing a constantly increasing deviation. This symptom gives rise to all the others—namely, (2) diplopia, (3) false projection of objects seen with the affected eye, (4) apparent movement of such objects when the patient approaches them, and (5) vertigo. The explanation of these symptoms has already been given. The characteristic feature about all of them is that they increase as the eyes are carried in some one direction—*increase*, namely, in that position of the eyes in which the affected muscle when normal acts most effectively in moving the eye (see *Table*, p. 502), and decrease as the eyes are carried in the contrary direction. For example, in an affection of the right superior oblique the diplopia, vertigo,

etc. are absent when the patient looks up, begin to appear when he looks down, increase rapidly when he looks down and to the left, and are much less marked when he looks down and to the right; because, in the first place, the superior oblique, being a depressor, acts normally only when the eyes are directed down, and because, in the second place, it acts much more energetically as a depressor when the eyes are directed down and in.

This characteristic feature of these conditions gives rise to another symptom—(6) namely, altered position of the head, the patient in each instance holding it in such a way as to prevent the development of diplopia, etc. Thus, if the deviation is such that diplopia occurs when the eyes are turned to the right, he gets over the difficulty by turning his head to the right, so that the eyes themselves are directed to the left.

The symptoms vary in intensity from a slight, transient diplopia, elicited only by the different tests for heterophoria, to the complete immobility produced by total paralysis.

In ophthalmoplegia interna (7) mydriasis and (8) paralysis of accommodation will occur; and in complete oculomotor paralysis both these symptoms together with (9) ptosis.

**Course and Prognosis.**—Structural deviations, particularly if congenital, show little tendency to increase or decrease. Insertional deviations are apt to increase, except when the result of a tenotomy or advancement, in which case they usually decrease because of the contraction that takes place in the process of healing.

Paretic or spastic deviations may recover spontaneously or as the result of treatment. This is always the case in hysterical affections, and is the rule in the cycloplegia due to diphtheria. On the other hand, in diphtheritic paralyzes of the external muscles and in paralyzes due to exposure to cold the condition often persists for a long time or even permanently; and ophthalmoplegia interna, except when due to the action of drugs, is usually incurable.

In chronic paralyzes the prognosis is uncertain, the condition being sometimes recovered from, often remaining stationary, and in yet other cases advancing progressively. The tendency to advance is particularly marked in the slowly developing paralyzes of nuclear origin affecting isolated muscles, and especially in the variety of paralysis known as ophthalmoplegia externa (see page 511). In these cases one muscle after another is, in the course of months or years, successively involved (*progressive ophthalmoplegia*), the process often extending to other centers besides the nuclei of the eye-muscles, and causing death through involvement of the respiration or other vital action.

Paralyzes of sudden development, on the other hand, do not usually show this tendency to advance, and often indeed disappear completely. It is, however, to be remarked that those cases that get well rapidly and spontaneously are particularly apt to be the precursors of tabes, disseminated sclerosis, and general paresis.

To two classes of acutely developing ophthalmoplegia, however, this grave prognosis does not apply. In one (*recurrent ophthalmic migraine*) a total oculomotor paralysis, preceded usually by violent migraine, recurs at more or less periodical intervals, and, after lasting for a day or two in some cases and two or three months in others, disappears almost or quite completely. In the other (*transient bilateral ophthalmoplegia*) a paralysis, usually, but not always, affecting all the ocular muscles and always bilateral, develops rapidly, and disappears completely after lasting one or two months.

Under-action of an ocular muscle, whether due to paralysis or not, after lasting for a time leads to over-action, and finally to permanent *contracture* of the opposing muscle in the same eye. In like manner, continuous over-action of a muscle leads to enfeeblement of its antagonist. The deviation in both instances is thus gradually converted into a comitant one (see page 508). Contracture of the opponent does not, however, usually take place in congenital paralysis.

The symptoms, especially the false projection and vertigo, gradually grow less pronounced as the patient accommodates himself to his new experiences. The diplopia often remains for a very long time, and may even persist after the deviation has become comitant.

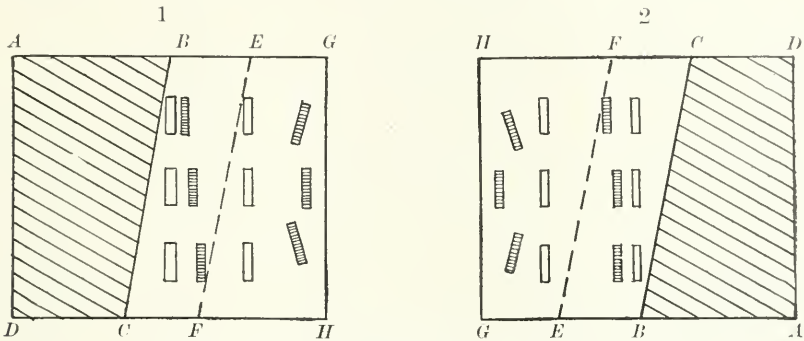


FIG. 320.—1, right external rectus; 2, right internal rectus.

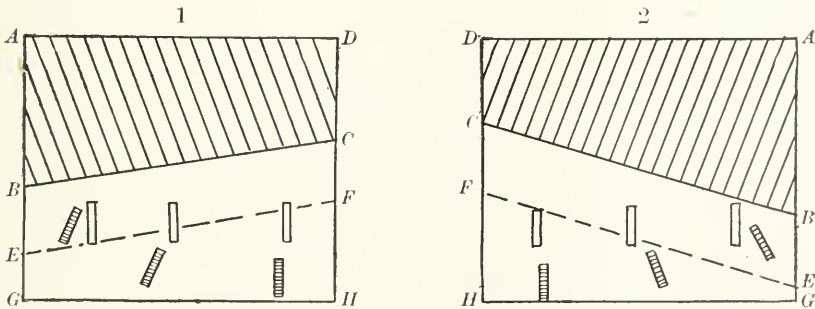


FIG. 321.—1, right inferior rectus; 2, right superior oblique.

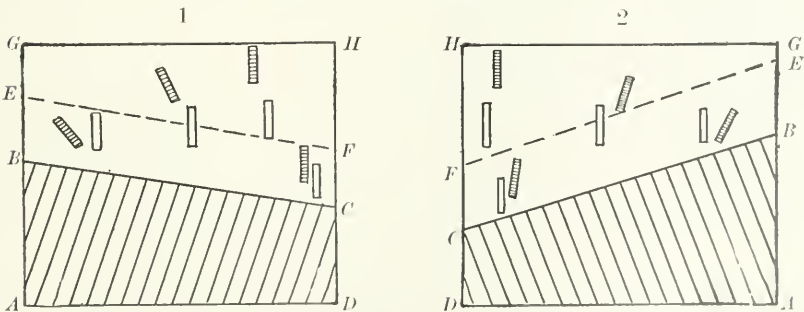


FIG. 322.—1, right superior rectus; 2, right inferior oblique.

FIGS. 320-322.—Scheme of double images in paralysis of the ocular muscles (modified from Mauthner and Berry): *A G H D*, field of binocular single vision of normal eyes; shaded area, *A B C D*, field of binocular single vision in complete paralysis; unshaded area, *B G H C*, field of double vision in complete paralysis; area, *A E F D*, field of single vision in partial paralysis; area, *E G H F*, field of double vision in partial paralysis. Shaded image is that belonging to the right eye.



*Diagnosis of Muscle Affected.*

| Characteristic diplopia. | Diplopia and the discrepancy in the position of the eyes, <sup>1</sup> as the eyes are carried to | Subsidiary diplopia (frequently absent or not to be made out). | Subsidiary diplopia, increasing as eyes are carried to | Head turned to | Under-acton (paralysis) of | Diagnosis, Or over-acton (spasm) of |
|--------------------------|---------------------------------------------------------------------------------------------------|----------------------------------------------------------------|--------------------------------------------------------|----------------|----------------------------|-------------------------------------|
| Homonymous               | R. L.                                                                                             | .....                                                          | .....                                                  | R.             | R. externus.               | L. internus.                        |
| Homonymous               | L. R.                                                                                             | .....                                                          | .....                                                  | L.             | L. externus.               | R. internus.                        |
| Crossed                  | R. L.                                                                                             | .....                                                          | .....                                                  | R.             | L. internus.               | R. externus.                        |
| Crossed                  | L. R.                                                                                             | .....                                                          | .....                                                  | L.             | R. internus.               | L. externus.                        |
| Right <sup>2</sup>       | L. and up.                                                                                        | R.                                                             | Crossed (and heteronymous torsion). <sup>5</sup>       | L. and up.     | L. superior rectus.        | R. inferior oblique.                |
| Right                    | R. and up.                                                                                        | L.                                                             | Homonymous (and homonymous torsion). <sup>4</sup>      | R. and up.     | L. inferior oblique.       | R. superior rectus.                 |
| Left <sup>3</sup>        | R. and up.                                                                                        | L.                                                             | Crossed (and heteronymous torsion). <sup>5</sup>       | R. and up.     | R. superior rectus.        | L. inferior oblique.                |
| Left                     | L. and up.                                                                                        | R.                                                             | Homonymous (and homonymous torsion). <sup>4</sup>      | L. and up.     | R. inferior oblique.       | L. superior rectus.                 |
| Right <sup>2</sup>       | R. and down.                                                                                      | L.                                                             | Crossed (and homonymous torsion). <sup>4</sup>         | R. and down.   | R. inferior rectus.        | L. superior oblique.                |
| Right                    | L. and down.                                                                                      | R.                                                             | Homonymous (and heteronymous torsion). <sup>5</sup>    | L. and down.   | R. superior oblique.       | L. inferior rectus.                 |
| Left                     | L. and down.                                                                                      | R.                                                             | Crossed (and homonymous torsion). <sup>4</sup>         | L. and down.   | L. inferior rectus.        | R. superior oblique.                |
| Left                     | R. and down.                                                                                      | L.                                                             | Homonymous (and heteronymous torsion). <sup>5</sup>    | R. and down.   | L. superior oblique.       | R. inferior rectus.                 |

<sup>1</sup> Evidenced by the lagging of one eye behind the other and by the degree of deviation behind the screen.

<sup>2</sup> That is, vertical diplopia with the image of the right eye below (or left eye above).

<sup>3</sup> That is, vertical diplopia with the image of the left eye below (or right eye above).

<sup>4</sup> That is, image of R. eye tilted to R. (or of L. eye tilted to L.).

<sup>5</sup> That is, image of R. eye tilted to L. (or of L. eye tilted to R.).

**Diagnosis.**—The diagnosis of *the muscle affected* may in the case of (1) under-action or over-action of a *single muscle* be made from the double images by means of the table on page 514. (See also Figs. 320–322.)

2. A diplopia increasing in more than one direction indicates an *affection of more than one muscle*, the diagnosis of the specific muscles being made from the table. *E. g.* a right diplopia increasing both in looking up and to the left and up and to the right indicates weakness of the left superior rectus and the left inferior oblique; and a left diplopia increasing in looking up and to the right, combined with a right diplopia increasing in looking up and to the left, indicates a paralysis of both superior recti or a paralysis of one superior rectus, combined with spasm of the inferior oblique in the same eye.

3. Crossed diplopia (with the image of the affected eye somewhat below), combined with inability of the eye to move upward, inward, or to any great extent downward, although it can still move out well, indicates *oculomotor paralysis*. The latter is complete if there are also ptosis, mydriasis, and paralysis of accommodation.

### Convergent Deviations; Esophoria and Convergent Squint.—

A convergent deviation may exist in all degrees, from an esophoria of  $2^\circ$  or  $3^\circ$ , elicited only by careful tests with the phorometer, to a constant convergent squint. In any case it may be due to—

1. Weakness of one or both externi or over-action of one or both interni, or to both these causes combined (*muscular deviation*). The weakness or over-action, which may be structural, insertional, parietic, or spastic in origin, produces a more or less non-comitant deviation having the characters already given of a purely muscular anomaly (see pages 510 and 511). Briefly stated, these characters are as follows:

Outward movements of one or both eyes diminished, or inward movements of one or both increased, the increase in the latter case being equally marked whether the eye turns inward in obedience to a convergence-impulse, or in performing an associated parallel movement with the other eye. In performing associated parallel movements the restriction of outward movement and the increase of inward movement are marked for distance as well as for near. The amount of restriction or increase usually differs for the two eyes, and the sum of the inward and outward movements, or total range of excursion, is greater in one eye than in the other, and in one eye, at least, is absolutely greater or less than normal (enlargement or contraction of the field of fixation). Degree of convergence or esophoria (as measured by the diplopia, deviation behind the screen, parallax, and phorometer) is not materially different for distance and near, but changes noticeably as the eyes are moved to the right or to the left. Near-point of convergence usually closer to the eyes than normal, but often nearer when the object looked at is carried from one side obliquely inward toward the nose than when it is carried inward from the other side.

The determination of the specific muscle affected can by means of the table on page 514 be deduced from the direction of the gaze in which the diplopia or deviation increases the most.

2. *Convergence-excess.*—The signs of this are—

For distance, convergence or esophoria less than for near, and usually slight. Prism-divergence (so-called abduction) normal or at least not disproportionately low (*i. e.* with an esophoria of  $3^\circ$ – $4^\circ$ , not below  $4^\circ$ ). Prism-convergence (adduction) readily performed. Associated parallel movements normal and equal in the two eyes. Total range of excursion normal in both eyes.

For near-points, convergence or esophoria marked (by all tests). Convergence near-point excessively close to the nose, and equally so whether the object looked at is carried toward the nose from the right or from the left. Eye moves farther inward in response to a convergence-impulse than when executing a parallel movement in conjunction with the other eye. Excess of inward movement same for each eye.

Convergence-excess is often due to excessive accommodative action exerted to overcome hyperopia or astigmatism, the association between accommodation and convergence being so intimate that one function can hardly be brought into play without bringing in the other with it. In this accommodative convergence-excess the signs above enumerated will tend to disappear upon the instillation of atropin and the continuous wearing of the proper correcting glasses. But cases of non-accommodative convergence-excess also occur, and in these glasses afford no relief.

3. *Divergence-insufficiency*.—The signs of this are—

For distance, convergence or esophoria marked. Prism-divergence (abduction) disproportionately low, absent, or even negative (*i. e.* there is homonymous diplopia that the patient cannot overcome, except when prisms, base out, are placed before the eye). Prism-convergence (adduction) normal or often subnormal. Associated parallel movements and range of excursion equal in both eyes, and normal or nearly so.

For near-points, convergence or esophoria slight or absent or even replaced by exophoria. Convergence near-point not abnormally close to the nose, and about equally far from the latter when the object looked at is carried inward from the right or from the left.

In rare cases the insufficiency may be so great as to constitute an actual *divergence-paralysis* (Parinaud, Uthoff, Straub). These cases are characterized by homonymous diplopia for distance, with marked convergent squint when the eyes are directed straight ahead; both the diplopia and the convergence diminishing progressively as the eyes are carried to the right or to the left. Such cases may be secondary to an abducens paralysis.

4. A convergence-excess which has lasted a long time is regularly followed by a divergence-insufficiency, and a divergence-insufficiency of long standing is followed by a convergence-excess. The *mixed form* thus produced is characterized by marked esophoria (and often by homonymous diplopia) for both distance and near, excessive approximation of the convergence near-point, and limited, absent, or negative prism-divergence (abduction). The constant over-action of the convergence seems to lead to actual over-development of the interni, and the under-action of the divergence to actual insufficiency of the externi, thus causing still further increase of the deviation. When the deviation becomes too great for the patient to overcome, so that binocular vision can no longer be maintained, a squint develops, which, at first intermittent, afterward becomes constant.

This conversion of an esophoria into a convergent squint is favored by the presence of any condition (amblyopia of one eye, anisometropia) which renders binocular vision of little value.

A convergent squint thus developed is prone to increase. But in children such a squint often diminishes and sometimes disappears, owing to the tendency that the eyes have to become divergent during the age of growth (see page 510).

The symptoms of convergent deviations are—homonymous diplopia (especially in cases that are passing from the state of a heterophoria to that of a squint); unilateral amblyopia and loss of stereoscopic vision (in true squint);

and asthenopia, headache, neuralgia, and nutritive disturbances in esophoria proper (especially in divergence-insufficiency).

**Divergent Deviations; Exophoria and Divergent Squint.**—A divergent deviation, whether a slight exophoria or a marked divergent squint, may be due to—

1. Weakness of one or both interni or over-action of one or both externi, or to both these causes combined (*muscular deviation*). The weakness or over-action may be structural, insertional, or innervational, and produces, particularly when unilateral, a more or less non-comitant deviation having the following characters, indicative of a purely muscular anomaly (see pages 510 and 511).

Outward movements of one or both eyes increased or inward movements of one or both diminished, the diminution in the latter case being equally marked whether the eye turns inward in obedience to a convergence-impulse or in performing an associated parallel movement with the other eye. In performing associated parallel movements the restriction of inward movement and the increase of outward movement are marked for distance as well as for near. The amount of restriction or increase usually differs for the two eyes; and the sum of the inward and outward movements, or total range of excursion, is greater in one eye than in the other, and in one eye, at least, is absolutely greater or absolutely less than normal. Degree of divergence or exophoria (as estimated from the diplopia, deviation behind the screen, parallax, and phorometer) not materially different for distance and near, but changes noticeably as the eyes are carried to the right or to the left. Near-point of convergence often more remote from the eye than normal, but may be much farther when the object looked at is carried from one side obliquely inward toward the nose than when it is carried obliquely inward from the other side.

The determination of the specific muscle affected may be deduced (by means of the table on page 514) from the direction of the gaze in which the crossed diplopia or the exophoria increases the most.

2. *Convergence-insufficiency*.—The signs of this are—

For distance, but slight divergence or perhaps orthophoria. Prism-divergence (abduction, so called) not usually above  $10^\circ$  and often subnormal ( $6^\circ$ ). Prism-convergence (adduction) often performed with difficulty even after a number of trials. Associated parallel movements and total range of excursion normal or nearly so, and equal in both eyes.

For near-points, exophoria of  $6^\circ$  and upward and divergence marked (by all tests). Convergence near-point over  $3''$  (often from  $6''$  to  $10''$ ) from the nose, and equally distant from the latter whether the object looked at is carried toward the nose from the right or from the left. Maintenance of convergence for more than a moment difficult. Eyes turn farther inward in performing associated parallel movements than in performing convergence movements (*i. e.* when the convergence near-point is reached either eye can turn still farther inward, but the other eye will then diverge). Limitation of movement inward same for each eye.

In some cases the insufficiency is so great as to constitute an actual *convergence-paralysis* (Parinaud, A. Graefe). The characteristic sign of this is that, while either eye can move inward to a normal degree, provided the other eye moves outward, it cannot move inward at all in response to an impulse of convergence. Hence, the convergence near-point, instead of receding to only  $6''$  or  $7''$ , is situated a yard or more from the eyes, and when the object looked at is brought nearer than this, insuperable crossed diplopia develops.



Owing to the intimate relation existing between accommodation and convergence, those who use their accommodation but little in looking at near-points will tend to converge less than they should. Hence, convergence-insufficiency occurs in myopes who wear no glasses for near, and also in hyperopes and presbyopes who wear too strong convex glasses for near. This *accommodative insufficiency* will disappear if the myope is made to wear concave glasses for near, and if, in the other conditions, the strength of the convex glass is lessened. But a non-accommodative convergence-insufficiency, not corrigible in any such way, also exists.

3. *Divergence-excess*.—The signs of this are—

For distance, exophoria or divergence marked. Often spontaneous crossed diplopia. Prism-divergence (abduction) high (in pure cases disproportionately so—*i. e.* with an exophoria of  $4^{\circ}$  or  $5^{\circ}$  there may be a prism-divergence of  $13^{\circ}$  or  $15^{\circ}$ ). Prism-convergence (adduction) usually normal. Associated parallel movements and range of excursion equal in both eyes and normal or nearly so.

For near-points, exophoria or divergence slight. Convergence near-point and power of maintaining convergence normal. Convergence near-point same whether the object looked at is carried from the right or from the left obliquely toward the nose.

4. A convergence-insufficiency which has lasted a long time is regularly followed by a divergence-excess, and a divergence-excess which has lasted a long time by a convergence-insufficiency. The *mixed form* thus produced is characterized by marked exophoria (or divergent squint) and often by crossed diplopia for both distance and near, excessive prism-divergence (abduction), and marked recession of the convergence near-point. Here, as in esophoria, the constant over-action of the divergence produces apparently an actual over-development of the externi, and the under-action of the convergence an actual insufficiency of the interni, thus causing still further increase of the deviation. Here also, when the deviation becomes too great for the patient to overcome, so that binocular vision can no longer be maintained, a squint develops, at first intermittent, afterward constant. As in the case of the convergent deviations, the presence of anisometropia or unilateral amblyopia favors this conversion of an exophoria into a divergent squint.

A divergent squint thus developed usually increases.

The symptoms of divergent deviations are—crossed diplopia (especially in cases that are passing from the state of a heterophoria to that of a squint); unilateral amblyopia and loss of stereoscopic vision in cases of confirmed squint; and asthenopia and conjunctival irritation with pain in the eyes in exophoria (particularly in convergence-insufficiency). Headache is less frequent and other symptoms are rather rare.

**Vertical Deviations; Hyperphoria and Vertical Squint.**—Vertical deviations, whether superable (hyperphoria) or productive of an actual squint, are either comitant or non-comitant.

1. *Non-comitant hyperphoria* is occasioned by under-action or over-action of one or more of the elevators or depressors. As in this case the deviation (determined by the vertical diplopia, deflection behind the screen, parallax, and phorometer) varies noticeably in different directions of the gaze, the diagnosis of the specific muscle affected can readily be made from the table on page 514. In a number of these cases the hyperphoria is apparently due to spasmodic action of the muscles, since it changes in amount from one examination to another, and after a time disappears altogether.

2. In a *comitant hyperphoria* the deviation (determined by the diplopia,

deflection behind the screen, parallax, and phorometer) remains sensibly the same in all directions of the gaze. Some of these cases may be due to a vertical separation of the visual axes, due to excessive sursumvergence, but most are probably examples of a non-comitant hyperphoria which has become comitant through the agencies already described (see pages 508, 513). In this case the diagnosis of the muscle affected is usually no longer possible.

The deviation is often slight (only  $1^\circ$  or  $2^\circ$ ). When slight it can be overcome by the action of sursumvergence. In well-marked cases it will generally be found that there is a difference of  $1^\circ$  or more between the right and left sursumvergence, the former predominating in right hyperphoria and the latter in left hyperphoria.

Hyperphoria does not, in general, show any great tendency to increase, and cases of actual vertical squint—*i. e.* of a vertical deviation so great that binocular fixation can no longer be performed, and but one eye fixes—are rare. Such a squint is called a *strabismus sursumvergens* if the deviating eye stands higher, and *strabismus deorsumvergens* if it stands lower, than the one which regularly performs fixation.

The symptoms of vertical deviations are vertical diplopia, blurring of binocular vision, asthenopia, headache, neuralgia, nausea, vertigo, disturbance of nutrition, choreiform twitchings, and other evidences of reflex trouble. The symptoms in general are more frequently present, more varied in character, and more severe in this form of ocular deviation than in any other.

**Associated Parallel Deviations.**—Associated parallel deviations comprise—

1. **Associated Paralysis and Spasm.**—Paralysis of the movements of both eyes to the right or of both eyes to the left frequently occurs in destructive lesions of the brain, and especially in apoplexy. This condition is not due to paralysis of the externus of one eye and the internus of the other, since the internus may still act in movements of convergence, but it is due to the involvement of the higher (association) center governing the movement of both eyes to the right or to the left (dextroversion and sinistroversion). Paralysis of the movements of both eyes up and of both eyes down has also been observed, but is rare.

Spasm of the associated parallel movements occurs in irritative lesions of the brain involving the association centers or tracts, and also in hysteria. It produces a spastic deviation of both eyes in the same direction (right, left, up, down, or obliquely).

2. **Nystagmus.**—Nystagmus consists in a very rapid oscillating movement of the eye in some one direction. Almost invariably both eyes take part in the movement, the oscillations of the two being equal and in the same sense. According to the direction of the movement nystagmus is called horizontal, vertical, rotary (when both eyes roll like wheels in the same direction), or mixed (when oscillations of two different kinds are combined). Horizontal nystagmus is much the most frequent form.

Nystagmus is due to alternate discharges from the association centers for parallel movements. For example, in horizontal nystagmus there is first a discharge from the center for turning both eyes to the right (dextroversion center), followed at once by a discharge from the center for turning the eyes to the left (sinistroversion center). In those who are subject to it it is often set up by the attempt to fix the eyes on an object or to turn them in some special direction. It occurs—

(a) As a result of visual defects (such as cataract, opacities of the cor-

nea, diseases of the retina and choroid, and albinism), which, being either congenital or acquired soon after birth, have prevented the patient from ever seeing well or from learning to direct his eyes properly.

(b) As a late acquired affection in disseminated sclerosis, in hereditary ataxia, and in hemorrhage, degeneration, inflammation, and tumors of the meninges, cord, and brain (especially the cerebellum). A special acquired form occurs in miners (*miner's nystagmus*), who work by a bad light and with their eyes in a strained position. Nystagmus may also be produced by a rapid rotation of the body or any other cause affecting the functions of the semicircular canals (auditory disease).<sup>1</sup>

In some of the forms acquired late in life, particularly miner's nystagmus, the oscillation of the eyes produces an apparent movement of objects looked at, with consequent vertigo. Otherwise the disease causes no symptoms.

Nystagmus occasionally disappears spontaneously or as a result of the removal of the optical defect that caused it; and miner's nystagmus may disappear on removal of the patient from the hurtful conditions under which he lives. Otherwise the condition is not susceptible of amelioration.

**Treatment of Ocular Deviations.**—The first indication to be fulfilled where possible is—1, to *remove the cause* of the deviation. Hence in paralysis or spasm due to syphilis, meningitis, periostitis, and exudative processes in general we use iodids and mercurials; in rheumatic paralyses we employ the iodids, salicylates, and diaphoresis; in diabetic paralyses, the appropriate diet; and in miner's nystagmus we remove the patient from his hurtful surroundings.

2. The next indication to be fulfilled in all cases causing symptoms is to *correct the refraction*. Such correction will in many cases (*e. g.* those of accommodative convergence-excess and insufficiency) remove the deviation itself; in others, while having no effect upon the deviation, it will do away with the symptoms. In esophoria (particularly in convergence-excess) the total amount of hyperopia and astigmatism (determined under a mydriatic) should be prescribed and the glasses worn constantly. In exophoria (particularly convergence-insufficiency) the myopia present should be fully corrected, and the concave glasses worn for near as well as for distance. On the other hand, it is often proper to more or less under-correct hyperopia or presbyopia coexisting with convergence-insufficiency.

In ophthalmoplegia interna it is often necessary to prescribe a convex glass for the affected eye to supplement its lost accommodation.

3. Exercise, tonics, and other *corroborant measures* are frequently required in debilitating affections, neurasthenia and hysteria, which by causing a temporary enfeeblement of the muscles either produce a deviation directly or, in case one is already present, interfere with its proper compensation.

4. The *bromids* may be of use in certain cases of spasm. Other remedies, such as *strychnin*, *electricity*, etc., which are supposed to act directly upon the muscles or nerves, are of little value, except in so far as they improve the general nutrition. The same may be said with even more force of electricity and eserin in ophthalmoplegia interna.

5. Exercise of the prism-convergence (so-called adduction) with *prisms*, base out, is often useful in exophoria (particularly convergence-insufficiency), but often fails. Exercise with prisms, base in, in esophoria is of no service.

<sup>1</sup> Nystagmus-like twitchings of a muscle (especially a parietic muscle) may also occur when the latter is carried to the extreme limit of its excursion, but this is not nystagmus in the proper sense of the term.

Prisms for continuous wear may be useful, particularly in slight and stationary vertical deviations. Their employment in lateral deviations is to be avoided, except as a temporary measure, since prisms, base in, tend to produce convergence-insufficiency, and prisms, base out, a convergence-excess, so that in both cases they ultimately increase the deviation which they are designed to correct.

6. The muscles may be exercised, not only by means of prisms, but also by making forced movements of the eyes in different directions, up, down, right, and left; by making forced movements of convergence in looking at near objects; by forcing the eyes to overcome a natural diplopia of small amount; and by forcing the eyes to move so as to unite the images of two objects which are some distance apart. These *orthoptic exercises*, as they are called, should not be kept up for more than a few minutes at a time, but may be repeated several times a day.

7. An operation is to be done only when the symptoms are marked and when it is apparent that all other measures will fail. In structural and insertional muscular anomalies an operation is generally indicated, and does good service. In parietic and spastic deviations it is indicated only when we are assured that the condition has become stationary. In convergence and divergence anomalies it is usually indicated when the deviation is marked and when correction of the refraction after long trial has afforded no relief. In all cases the rule is to perform tenotomy of an over-acting muscle and advancement of one that is under-acting, provided always that the latter is capable of acting at all. The specific operations to be employed are—

(a) In esophoria (or convergent squint), when due to over-action of one or both interni or to convergence-excess, tenotomy of one or both interni; when due to weakness of the externi or to divergence-insufficiency, advancement of one or both externi combined, especially if there is over-action of convergence or over-action of the interni, with tenotomy of the latter.

(b) In exophoria, when due to over-action of one or both externi or to divergence-excess, tenotomy of the externi; when due to convergence-insufficiency or to actual insufficiency or paresis of one or both interni, advancement of the latter, combined, if necessary, with tenotomy of the externi.

(c) In non-comitant hyperphoria, when due to weakness of the superior or inferior rectus, advancement of the weak muscle; when due to over-action of the superior or inferior rectus, tenotomy of the over-acting muscle; when due to weakness (paresis) of the superior oblique, tenotomy of the inferior rectus of the other eye; when due to over-action of the superior oblique, advancement of the inferior rectus of the other eye; when due to weakness of the inferior oblique, tenotomy of the superior rectus of the other eye; and when due to over-action of the inferior oblique, advancement of the superior rectus of the other eye. A comitant hyperphoria is generally best remedied by tenotomy of the superior rectus of the higher eye.

In performing either a tenotomy or an advancement the precise amount of the deviation should be measured (when possible by the phorometer) before and during the operation, the latter being done in successive steps, and its effect gradually increased until just the desired amount of correction is obtained. As the ultimate effect is somewhat less than the primary, it is advisable in operations upon the lateral muscles<sup>1</sup> (especially advancements)

<sup>1</sup> Operations upon the superior and inferior recti, if carefully performed, do not need to be overdone.



to produce an over-effect of about  $3^{\circ}$ .<sup>1</sup> An exception is in the convergent squint of young persons, in which we prefer to leave a slight amount of convergence, so as to prevent a possible over-correction later, and in large deviations, in which the best plan is to divide the operation between the two eyes.

In the author's experience the best results are secured if the tenotomy is performed by the open method, the incision being made in the middle of the tendon, near its insertion, and carried gradually up and down until the tests show that the fibers are sufficiently detached. A bandage is not applied in the case of a simple tenotomy, and the patient is encouraged to use his eyes for distant vision directly after the operation, for then the directive influence of binocular fixation, exerted upon the tissues when they are still plastic, tends to make the eyes assume their proper position with regard to each other.<sup>2</sup> In advancement a bandage is required to prevent sudden movements of the eye, which would produce loosening of the sutures.

If an excessive over-correction is produced, the surplus should be at once removed by inserting a suture and making the proper traction.

<sup>1</sup>The operation, however, should not be carried so far as to reduce the diverging power (abduction) to below  $5^{\circ}$  or increase it to above  $12^{\circ}$ .

<sup>2</sup>This tendency may be reinforced by exercises with prisms performed systematically while the tissues are healing.

# INJURIES AND DISEASES OF THE ORBIT.

By F. BULLER, M. D.,

OF MONTREAL, CANADA.

## CONGENITAL ANOMALIES.

CONGENITAL faults in the development of the orbits have been described in all degrees, from trifling defects in limited portions of their bony walls to complete absence of these cavities, one or both; in the latter case the structures they are designed to enclose are also wanting. In the lesser defects the orbital contents may be modified in various ways. Such modifications as affect the eyeballs are of special interest. Of these there are four well-known conditions. They are—*anophthalmos*, *microphthalmos*, *megalophthalmos*, and *cyclopia*. The first three of these are not, however, necessarily associated with anomalies in the construction of the orbits. Although congenital defects of this class are usually bilateral, one-sided faults are by no means uncommon.

**Anophthalmos.**—Congenital absence of both eyes is a rare condition (still more rarely is this condition unilateral—*monophthalmos*). In most of these cases the palpebral fissure has been found closed or very narrow, the conjunctival sac small, of a pale-red color, and the eyeball totally absent or only represented by a soft, irregular flesh-like mass. Several or all of the extrinsic ocular muscles have been found in connection with this rudimentary mass. The orbital cavities are always smaller than normal, and the *aducra* of the eye, when present, are small and ill-developed. The faulty development in these cases is not confined to the orbits and their contents, but involves also the chiasma, optic tracts, corpora quadrigemina, and sometimes adjacent parts of the cerebrum.

A few instances of monolateral anophthalmos have been observed. In one of these the single eye was normally developed. This anomaly is explained by failure of the primary optic vesicle to bud from the anterior primary encephalic vesicle, or, having budded, it has failed to form a secondary optic vesicle. In every case the eye was properly situated, even when very imperfect—a feature which justifies the use of the term *monophthalmos* in describing this deformity, and distinguishes it from the more common monstrosity known as *cyclopia*.

**Cyclopia.**—This anomaly is a fusion of both orbits and their contents, with a single eyeball situated in the middle line just above the ordinary position of the root of the nose. This single eye may be larger or smaller than normal for the general development, but always shows unmistakable evidence of an imperfect fusion of the two eyes. The same is true of the *aducra* of the eye. In all such cases the ethmoid is absent or only rudimentary. The olfactory nerves are wanting, and the cerebrum is so imperfectly formed that,

although some cyclops have been living when born, all that the writer has been able to find records of have died within a very short time after birth.

**Microphthalmos.**—Eyes which at birth are considerably smaller or larger than normal are seldom, if ever, sufficiently normal in other respects to admit of useful vision. These peculiarities are probably the result of some pathological process *in utero*, rather than a mere arrest or excess of development. Either condition may be found in one or both eyes.

In microphthalmos the whole globe is uniformly spherical, sometimes flattened below; the cornea is usually very much smaller than normal, its margins ill-defined, and curvature of the same radius as the adjacent sclerotic; the anterior chamber, iris, and pupil are correspondingly diminished. The palpebral fissure is narrow, and the lids, unsupported by the globe, are partly deprived of their ordinary functions. The changes in the interior of the globe have not been fully studied. According to Manz, they are often of a degenerative character, such as occur in phthisis bulbi from other causes. In the higher grades of microphthalmos vision is, of course, entirely wanting.

**Megalophthalmos** is a rare congenital anomaly in which the cornea and anterior chamber are larger than normal (*hydrophthalmos anterior*). The explanation of this is probably to be found in some intra-uterine pathological condition in which the intra-ocular tension has been increased at a time when the cornea possessed less resisting power than the sclerotic, and therefore became distended, whilst the posterior segment of the eyeball remained relatively unaffected in its development (see also pages 329 and 385).

#### DISEASES OF THE ORBIT.

A glance at Fig. 323 shows that the eyeball is rather loosely slung in the conical bony cavity of the orbit, well toward its anterior part. The bony walls

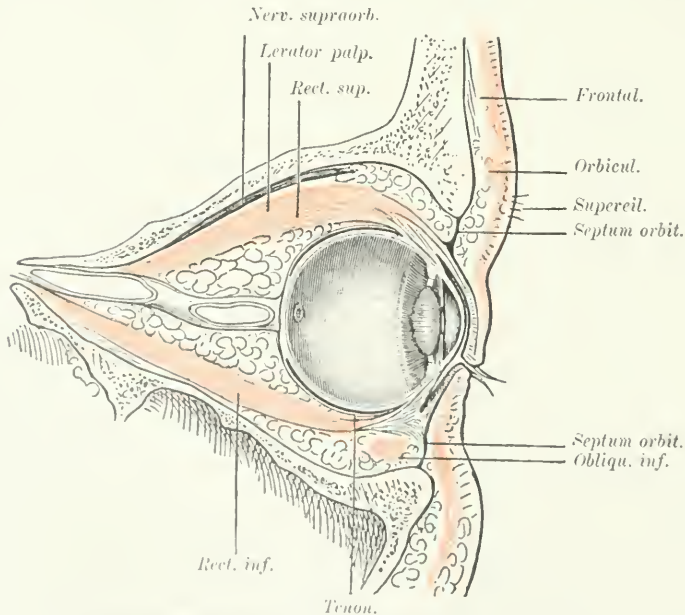


FIG. 323.—Sagittal section of orbit (De Wecker and Landolt).

of this hollow cone are so unyielding that any considerable augmentation of its contents or encroachment from without will have the effect of displacing the

eyeball. The displacement will naturally be greatest in the direction of least resistance, which, in a general way, is obviously forward.

**General Symptoms of Orbital Disease.**—Most of the pathological conditions met with in the orbit either increase its contents or come from encroachment upon some part of its walls; hence a more or less forward displacement of the eyeball—*proptosis*—is the most usual sign of disease of the orbit.

In the normal state the eyeball is freely movable in every direction by means of the three pairs of ocular muscles, each one of which is situated entirely within the orbit, and therefore liable to loss of function from changes in the tissues surrounding them; hence another common sign of orbital disease is *alteration in the mobility of the eye*. Inflammatory processes or morbid growths, which cause infiltration of the tissues surrounding the muscles, are especially liable to result in fixation of the eyeball. Periostitis, even of a limited extent, at the apex of the orbit may have a similar effect by pressure upon the motor nerves as they pass through the Sylvian fissure, thus causing a paralytic immobility.

On the other hand, a high degree of proptosis, caused by non-infiltrating growths arising within the orbit or projecting into it from adjacent parts, is compatible with free mobility of the eyeball, as in certain orbital cysts and other encapsuled new growths. Only in case of one-sided exophthalmos can a fairly accurate estimate of the displacement be made by comparison with the position of the eyeball in the normal orbit. If the displacement is bilateral, its degree is a matter of conjecture, and allowance must be made for the fact that a wide palpebral fissure simulates *exophthalmos*, whilst a narrow fissure may simulate the opposite condition or *enophthalmos*.

The differential diagnosis of orbital disease will be greatly facilitated by a careful consideration of the following less constant signs:

(1) *Redness, swelling, and edema of the lids*, especially conspicuous in the inflammatory affections of the cellular tissue of the orbit.

(2) *Chemosis of the conjunctiva*, either general or localized, over a certain portion of the globe nearest the area of disease.

(3) *Fluctuation* is likely to be present when an abscess of the orbit has formed, but cannot always be made out with certainty.

(4) *Pain*, intensified when the patient attempts to rotate the eyeball or when it is pressed backward, and the surroundings are palpated by the surgeon. Tenderness on pressure of the orbital margins is a common sign in periostitis of the orbit, and frontal headache is often intense during the acute stages of inflammation in the orbital tissues, or of the frontal sinus.

(5) *Disturbance of vision* is often absent, but becomes a valuable sign when associated with changes in the fundus oculi, such as papillitis, pallor of the optic nerve, or retinal hemorrhages. Diplopia is also common.

**Periostitis.**—Periostitis of the orbit occurs in two forms, *acute* and *chronic*. The terms *circumscribed* and *diffuse* are applicable according to the supposed periosteal area involved in either variety.

**Etiology.**—Certain diathetic states predispose to this disease. They are—scrofula, syphilis, and rheumatism. Injuries and sudden changes of temperature are recognized exciting causes, but in many cases the exciting cause cannot be positively determined.

This disease attacks by preference the margin of the orbit (especially the outer margin), and extends more or less widely; suppuration (abscess) is prone to occur.

**Symptoms.**—The symptoms of an ordinary acute marginal periostitis



are—swelling, edema, and redness of the lids; chemosis of the conjunctiva, commencing at the equator of the globe; pain and tenderness on pressure at the part of the orbital margin affected. Sometimes a highly sensitive, tense spot may be discovered with the finger, or fluctuation if pus has formed.

*Acute parietal (deep-seated) orbital periostitis* is difficult to distinguish from cellulitis. The symptoms are violent and severe—intense headache, pyrexia, sometimes nausea, vomiting, and great prostration. The local symptoms are—swelling of the lids, chemosis, pain, increased when the eyeball is pressed backward, and more or less displacement and immobility of the eyeball.

*Chronic orbital periostitis* is far more frequent than the acute form, and is nearly always distinctly circumscribed. Its course is tedious, lasting for months or years. All the symptoms are less intense, though similar in other respects, except that the swelling of the lids is more a simple edema and the patient complains of a dull pain, usually worse at night. It commonly results in *abscess of the orbit*, occasionally in gradual resolution. Whenever pus has formed beneath the periosteum *caries* or *necroses* of the bone are liable to occur, and there is always danger of extension to the cranial cavity or septic infection, particularly when the disease is parietal. If the consecutive bone-disease involves the orbital margin, adhesion and retraction of the adjacent skin may cause eversion and distortion of the eyelids. This result is very common in children.

**Prognosis.**—This must be based chiefly on a recognition of the foregoing facts, and, in acute cases, on the immediate effects of treatment.

**Treatment.**—If the case is seen before pus has formed, leeches applied to the temple, cold compresses over the eyelids, and other antiphlogistic measures may arrest the inflammation. If pus is present or its formation seems to be inevitable, hot applications may be used, but incision should not be long delayed (see *Operations on the Orbit*); and in no case, acute or chronic, should an abscess-formation in the orbit be allowed to undergo spontaneous rupture. After an opening has been established suitable drainage and careful daily cleansing will be required so long as the discharge continues from the opening.

Appropriate remedies for the underlying constitutional cause must be administered in all cases. If syphilitic, the judicious use of mercury and iodid of potassium may be expected to give excellent results. In rheumatic or strumous cases constitutional treatment, although undoubtedly beneficial, is not so distinctly curative.

**Caries** and **necrosis** of the orbit are probably always preceded by periostitis, of which they are, therefore, common sequels.

Caries affects by preference the lower outer orbital margin, but may attack any part of the orbital walls, when deep-seated brain-complications are not unlikely to occur. It is seldom seen in adult life; often in children. A fistulous opening, surrounded by granulations, leads to an area of softened bone, which may be detected by careful use of a probe. Retraction of the skin and deformity of the lid, usually ectropion, ensues in most cases.

Necrosis is far less frequent than caries, and belongs to adult life. It is apt to follow denudation of a large area of bone from periostitis, or a fragment of bone detached by traumatism from the orbital margin may become necrosed (Fig. 324).

**Treatment.**—The fistulous opening and sinus should be gently cleansed two or three times daily with some antiseptic fluid. Mineral acids may be cautiously employed locally for the purpose of gradually dissolving the

diseased bone. Meddlesome surgery and the injudicious use of probes are harmful, and may induce orbital cellulitis or an extension of the disease. Removal of diseased bone may only be undertaken when near the surface or obviously completely detached; when the roof of the orbit is the part affected, the surgeon should be extremely careful in the use of instruments.

This disease is essentially chronic, and, besides the local treatment, appropriate constitutional remedies will be in order until a cure is effected.



FIG. 324.—Syphilitic caries of the inner wall of the orbit.

The case represented in Fig. 324 recovered without a trace of deformity, after a course of mercurial inunctions followed by potassium iodid in large doses.

**Cellulitis** (*Phlegmon of the Orbit*).—This disease does not always present the same clinical picture. In all its forms the soft tissue surrounding the eyeball is inflamed, but the inflammation may be *acute*, *subacute*, or *chronic*, *monolateral* or *bilateral*. The inflammatory process may terminate in *resolution*, but commonly leads to *suppuration* and *abscess*.

In mild cases the symptoms are—moderate swelling of the lids, some exophthalmos, diplopia, dull pain, and little or no constitutional disturbance.

*Acute phlegmonous orbital cellulitis* comes on with chills, pyrexia, and deep-seated pain, aggravated by movements of the eyes. Intense headache is a common symptom. Loss of mobility of the eyeball may be complete. The lids become greatly swollen, red, and edematous; the conjunctiva is chemosed and hyperemic, suggesting a violent purulent conjunctivitis or a panophthalmitis; but the absence of profuse suppuration of the conjunctiva and the preservation of a normal red reflex from the pupil will prevent such an error of diagnosis (Fig. 325). Vision may be unaffected for some time, but it is not unusual for neuro-retinitis to appear, and this, in turn, may pass over into atrophy of the optic nerve and blindness. The pressure on the eyeball may cause dilatation of the pupil, anesthesia, or ulceration of the cornea, and, occasionally in bad cases, panophthalmitis.

In certain cases of an *erysipelatous type* extensive intra-ocular changes have

been observed, due probably to arrest of the circulation in the retinal blood-vessels, and consequent edematous exudation and hemorrhages in the retina.

Finally, an *abscess* forms, with characteristic fluctuation, usually below the inner portion of the supra-orbital ridge. Sometimes the inflammation

leading to abscess-formation is of a more chronic character, and may not involve the entire orbital cellular tissue, as where the disease originates in the bone or periosteum in scrofulous subjects, or in the vicinity of a foreign body imbedded in the orbit.

**Etiology.**—When orbital cellulitis cannot be traced to any definite cause, it is said to be idiopathic. Among the many recognized causes are—exposure to excessive changes of temperature, certain febrile conditions, such as scarlatina, typhoid fever, meningitis, and facial erysipelas. The last disease is responsible for the most violent types of orbital cellulitis, which is then apt to be bilateral. Diseased teeth and suppuration in adjacent cavities have been known to cause the affection. It occurs as a metastasis in pyemia and in puerperal septicemia, and in all cases of

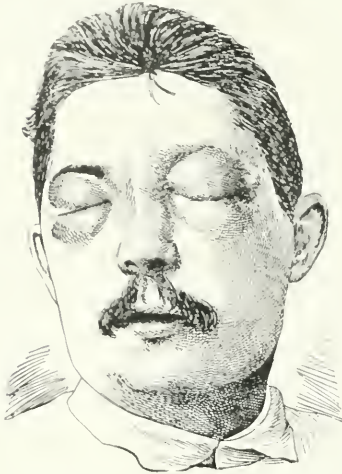

FIG. 325.—From a photograph of a patient in the Philadelphia Hospital, under the care of Dr. de Schweinitz, suffering from double orbital cellulitis the result of erysipelas.

acute panophthalmitis there is more or less diffuse inflammation of the tissues surrounding the eyeball.

**Prognosis.**—This is favorable in mild cases and those of a more chronic character, and recovery is likely to be perfect when the disease terminates in resolution.

Although purulent collections in the orbit usually tend toward the surface, there is always a liability to cerebral complications, which almost certainly terminate fatally. These are—meningitis, cerebral abscess, and the extension of phlebitis of the orbital veins to the cerebral sinuses. In this way the other orbit may become involved through the intervention of the cavernous sinus. In double cases of this nature a fatal issue is to be expected. If orbital cellulitis originates from pyemia or septicemia, the chances of recovery are of course exceedingly limited.

The danger to vision is to be estimated by the character and extent of the ocular complications already mentioned.

**Treatment.**—Absolute rest in bed is essential. In the early stage of acute inflammation cold compresses, leeches to the temple, aconite, and derivatives may be employed. If these measures are not effective in a short time, a change must be made to hot fomentations and general supporting treatment, or this plan must be adopted at the outset if there is evident depression of the vital forces.

If there is reason to believe that suppuration has taken place, no time is to be lost in making one or more incisions deep enough to reach the suspected pus. Incisions are best made with a Graefe knife, through the conjunctiva, the flat of the blade facing the eyeball. If pus is discovered, drainage must be maintained by means of rubber tubing or strips of iodoform gauze, and systematic cleansing of the cavity with antiseptic solutions will be necessary

until all suppuration has ceased. Ocular complications which threaten loss of vision demand operative interference even when there is no positive evidence of suppuration.

**Inflammation of the Oculo-orbital Fascia** (*Tenonitis*).—As a primary affection this disease is exceedingly rare, and is supposed to be an inflammatory, serous exudation into Tenon's capsule of rheumatic origin, but a few cases have been observed in connection with diphtheria and during attacks of influenza.

Its characteristic feature is a watery chemosis of the ocular conjunctiva, partial or complete, and out of proportion to other local manifestations of disease. There is, however, more or less edema of the eyelids, some loss of mobility of the eye, perhaps diplopia, exophthalmos, and a feeling of tension about the eye, and pain when its ordinary movements are attempted.

The **treatment** consists in hot fomentations and the administration of potassium iodid, salicylates, or the subcutaneous injection of pilocarpin.

A *secondary tenonitis*, with more solid exudation, is associated with any violent inflammation of the eyeball, and occasionally follows certain traumas, such as squint-operations performed without anti-septic precautions.

**Thrombosis of the cavernous sinus**, as already stated, may result from phlebitis of the orbital veins during phlegmonous inflammation of the orbit, or it may be of intercranial origin, as in caries of the petrous portion of the temporal bone resulting from middle-ear disease, with infection of the superior petrosal and cavernous sinus.

A fetid discharge from the ear, with or without edema over the mastoid, and evidences of an orbital cellulitis and grave cerebral symptoms, are characteristic of this condition, which probably always terminates fatally.

**Tumors of the Orbit**.—The scope of this article admits only of a brief outline of this extensive subject, which, for convenience, may be arranged according to the following headings:

1. Tumors of the tissues of the orbit ;
2. Tumors arising from the periosteum or bony walls of the orbit (exostosis, etc.) ;
3. Tumors arising in the cavities or tissues close to the orbit ;
4. Pulsating exophthalmos.

New growths originating within the eyeball are not classified as orbital tumors, except when met with as local recurrences after removal of the eye.

The terms *primary*, *metastatic*, *congenital*, *malignant*, and *benign*, as applied to tumors of the orbit, have the same significance as in other departments of surgery, and are intended to convey an idea as to the nature of the growth.

All orbital tumors that have attained appreciable dimensions are likely to cause displacement of the eyeball. When confined within the funnel of the straight muscles the proptosis is in a forward direction ; displacement in any other direction will depend upon the size and position of the tumor according to the position or point of origin of the growth. Special symptoms in any case will depend upon the size, position, nature, and density of the growth. As the eyeball becomes pushed out of its natural position, the lids become distended and apparently enlarged ; occasionally, in high degrees of proptosis, they fail to close over the eyeball, and sometimes even recede beyond its equator.

**Prognosis**.—This depends on the nature, position and size, density, rate of growth, and possibility of successful surgical interference and its complete removal.





FIG. 326.—Fibroma of the optic nerve. The morbid growth in this case extended into the optic foramen, at which point chlorid-of-zinc paste was applied after removal of the eyeball and growth without exenteration. Ten years later there had been no recurrence.

**Treatment.**—In most cases treatment should consist in complete removal of the growth by operations conducted on general surgical principles. Cer-

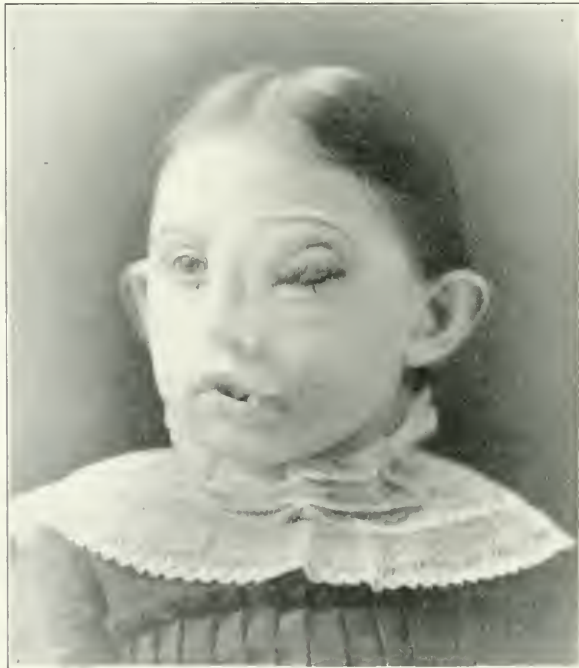

FIG. 327.—Lymphangioma of the orbit.

tain growths originating in some vascular disease cannot be safely extirpated. Benign tumors may often be removed without sacrificing the eyeball, but

those of a distinctly malignant type call for complete exenteration of the orbit.

I. Tumors Originating in the Tissues of the Orbit.—Of these the *cystic formations* supply a large contingent. They are sebaceous, serous, blood and dermoid cysts, echinococci and cysticerci. Besides these there are



FIG. 328.—Lipoma of both orbits, stationary for many years. Patient died at an advanced age; orbital condition unchanged.

simple and cavernous angiomas, lymphangiomas (Fig. 327), lipomas (Fig. 328), enchondromas, lymphomas, and a variety of sarcomata which may take their origin from fibrous or connective tissue anywhere within the orbital cavity (Fig. 330).

Carcinoma as a primary tumor has been met with in connection with the lachrymal gland. Tumors originating in the lachrymal gland are, however, mostly of the adeno-sarcomatous type and non-malignant.

The *differential diagnosis* is not always an easy matter, but can generally be achieved by a careful study of all the signs and symptoms.

**Treatment.**—Cysts with fluid contents may be cured by simple incision followed by astringent or irritant injections.

Dermoid cysts should be thoroughly evacuated and the lining of the cavity destroyed with strong pigment of iodine or with nitrate of silver: excision of deep-seated cysts should never be attempted, since the cyst-walls can readily be destroyed by either of the drugs just named without damaging other structures. Many of the solid growths can be shelled out without much disturbance of the surrounding tissues.

*Electrolysis* has been found efficient in treating orbital angiomas. Some of them are sufficiently circumscribed to admit of removal by careful dissection.

II. Tumors which Arise from the Periosteum or Bony Walls of the Orbit.—These comprise the following:

(1) *Sarcomata* or *fibro-sarcomata* occasionally spring from the periosteum.

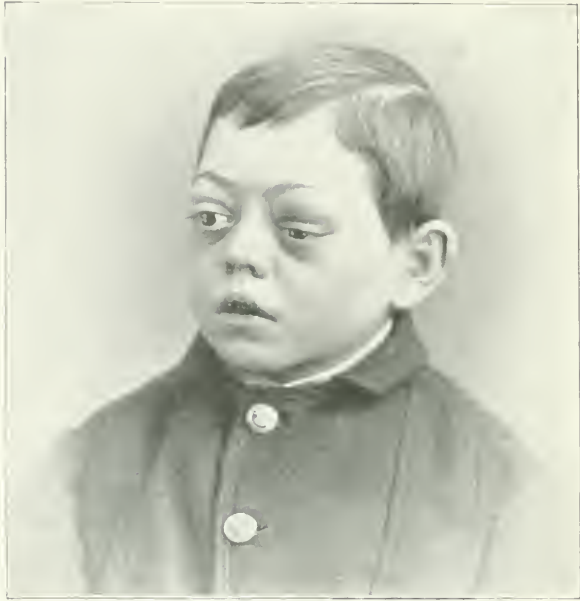

FIG. 329.—Fibro-sarcoma of both orbits.

Figure 329 represents a case of the latter occurring in a boy of fourteen, in whom the entire periosteum of both orbits became involved. Some months



FIG. 330.—Sarcoma of the orbit originating in the tissues of the apex

after removal of these growths death resulted from metastatic formations elsewhere.

(2) *Thickening of the periosteum* of an inflammatory nature sometimes

simulates a neoplasm, especially if localized and associated with hyperostosis of the underlying bone.

(3) *Exostoses* are a somewhat rare form of orbital tumor, characterized by slowness of growth, extreme hardness, and evident continuity with the adjacent bone. They may attain so large a size as to occasion great deformity. Most of these growths spring from the periosteum at or near the orbital margin or from neighboring cavities. They consist of an outer layer of ivory-like hardness and an inner more spongy structure. Some are of congenital origin, others may be traced to injury, or there may be no discoverable cause.

**Treatment.**—The only effective operation for exostoses is ablation by means of drill, hammer, and chisel. This operation is likely to be difficult and dangerous if the growth involves the roof of the orbit.

III. Tumors which Arise in the Cavities or Tissues close to the Orbit.—These are—

(1) *Encephalocele* or *meningocele* is an exceedingly rare form of tumor, containing cerebro-spinal fluid, with or without a hernial protrusion of brain-substance. It is of congenital origin, the result of defective ossification at some part of the orbital wall, by preference the anterior part of the fronto-ethmoidal suture, and appearing as a smooth, fluctuant, sometimes pulsating swelling, not adherent to the skin, and existing since birth at the upper inner angle of the orbit, is liable to be mistaken for a dermoid cyst.

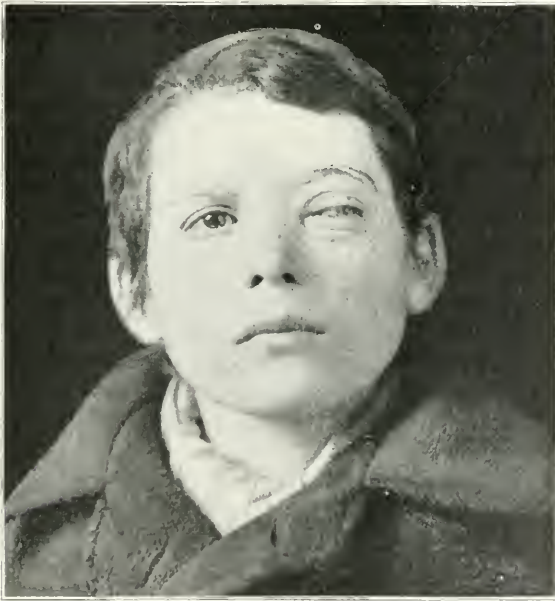

FIG. 331.—Ethmoidal mucocele.

Unlike the latter, it is not amenable to any form of operation or treatment. A correct diagnosis is therefore of paramount importance if an operation is contemplated.

(2) *Nevi*, *lupus*, and *epithelioma*, originating in the skin of the eyelids or face, may extend into the orbit.

(3) *Polypoid growths*, originating in the nasal cavities, sarcomatous, cancerous, or *osteoid growths* in the frontal, sphenoidal, or maxillary sinuses, *ethmoidal mucocele* (Fig. 331), or, even distention of these cavities by



fluid secretion, may, by invasion, simulate orbital tumors. An exact diagnosis may be difficult or impossible. The character of the proptosis, the condition of adjacent parts, and a careful consideration of all the signs and symptoms present will, however, usually reveal the true nature of the affection (see page 454<sup>1</sup>).

**Pulsating exophthalmos** is a form of orbital tumor which results from some vascular disease within the orbital cavity, the primary lesion being commonly situated within the cranial cavity immediately behind the orbit.

**Symptoms.**—The ordinary signs of pulsating exophthalmos are—protrusion of the eyeball (occasionally both), and pulsation, which may sometimes be both seen and felt. The stethoscope reveals a distinct *bruit* when placed upon the brow or closed eyelid. There are swelling and a passive hyperemia of the latter and of the subconjunctiva, sometimes presenting an appearance not unlike that of orbital cellulitis. The retinal veins are usually distended and tortuous, and there may be retinal hemorrhages, optic neuritis, and more or less impairment of vision. The protrusion, fulness of the vessels, and pulsation are increased by stooping the head.

The subjective symptoms are pulsating tinnitus or noises in the head, and pain, likewise increased by stooping, and diminished by compression of the carotid artery.

This assemblage of symptoms is nearly always due to the formation of *aneurysmal varix* in the cavernous sinus, the internal carotid thus directly pumping blood into the orbital veins. The initial lesion is in most cases caused by traumatism, such as falls or severe blows upon the head or face; not very rarely, however, especially in women, the arterio-venous communication (rupture of the carotid in the sinus) has occurred spontaneously.

Some other lesions, so rare as to constitute pathological curiosities, have been known to cause pulsating exophthalmos: they are—aneurysm of the ophthalmic artery within or behind the orbit, or of the carotid in the sinus, pulsating angioma, and medullary osteo-sarcoma of the orbital walls.

**Treatment.**—Spontaneous cure is possible: so long, therefore, as there are no urgent symptoms, such as severe pain, attacks of epistaxis, or impairment of vision, with extensive or increasing intra-ocular changes, there is no necessity for active interference. Rest in bed, full doses of potassium iodid, and intermittent but frequent compression of the common carotid may arrest the disease; but in the presence of urgent symptoms ligation of the common carotid should not be delayed. The results of this operation have been satisfactory in a large percentage of cases so treated.

**Exophthalmic Goiter** (*Basedow's Disease, Graves's Disease, Cardiac Exophthalmos*).—This disease comes rather more appropriately within the domain of general medicine, since the ocular symptoms are but a local manifestation of a more serious general disturbance or form of debility, which is associated not only with exophthalmos, but also with enlargement of the thyroid gland and increased action of the heart (*tachycardia*). Any one of this trio of symptoms may be in abeyance or may predominate over the other two. For this reason there is a lack of uniformity in the signs which indicate the presence of this disease.

**Symptoms.**—With regard to the ocular symptoms, the exophthalmos, almost always bilateral, is much greater in some cases than in others, is subject to a certain amount of spontaneous variability, and may, in the early stages at least, be temporarily diminished by pressure. The eyeballs are pushed

<sup>1</sup> For a detailed description of this class of tumors the reader is referred to an article by Chas. S. Bull in the *New York Medical Journal* for Dec. 19, 1891.

straight forward; their mobility is not impaired. In extreme cases the lids may not sufficiently cover them to secure adequate protection, and damage to the cornea may ensue.

Vision is unimpaired, and intra-ocular changes have not been observed, except occasionally visible pulsation of the central artery of the retina, and sometimes the retinal arteries appear relatively larger than they should be as compared with the veins.

The exophthalmos, even when slight, is characterized by a peculiar staring appearance of the eyes, giving the patient an astonished or frightened look. This is due to a retraction of the organic levator of the lid. The resulting widening of the palpebral fissure is known as *Dalrymple's sign*.

On looking downward the upper lids do not perfectly follow the movements of the eyeballs, as in health; consequently the sclera above the corneal margin becomes visible (*v. Graefe's sign*). This symptom is not always present, and it may exist without exophthalmos in the early stage, or be persistent after the latter has disappeared if a cure has been effected. Diminished or imperfect winking movements of the lids are often noticeable (*Stellweg's sign*). These, together with the widened palpebral fissure, may induce a tendency to desiccation of the cornea, and probably account for the sense of heat and discomfort in the eyes of which these patients often complain.

The enlargement of the thyroid body, primarily due to enlargement of its blood-vessels, may be slight or very considerable. As a rule, it is evenly distributed, but there are some marked exceptions to this rule; in these the right side is apt to be the larger. The enlarged thyroid feels soft and elastic in most, but not in all, cases. The chief point of distinction between exophthalmic and other forms of goiter is that in the former the hand detects a whirring sensation and strong pulsatory movement with each cardiac impulse. These circulatory phenomena are associated, as might be expected, with a loud rasping *bruit*.

The carotids are probably distended and pulsate strongly. This pulsation is visible, as well as audible, along the course of these arteries, and the patient often complains of a beating sensation communicated to the head. Signs of engorgement of the large cervical veins are also often present. Pulsatory phenomena sometimes also exist in the thorax and abdomen. The action of the heart is increased both in frequency and intensity; the pulse, never less than 100, becomes considerably accelerated by the slightest exertion or mental excitement.

Some enlargement of the heart, especially of the left ventricle, is not uncommon, and variable cardiac murmurs may be present; but if recovery takes place, these signs disappear: they are therefore assumed to be of a functional character.

Persons suffering from Basedow's disease are often irritable and excitable; most of them are anemic, some chlorotic; a tendency to emaciation even when the appetite and digestion are unimpaired has often been observed.

**Etiology.**—This disease belongs almost exclusively to adult life, and in women rarely develops after the menopause. The male sex is comparatively exempt from it. As recognized exciting causes may be mentioned diseases of the genital organs, worry, mental excitement, anxiety, and fright.

Although exophthalmic goiter has been known to come on suddenly, this is the exception; as a rule, the onset is gradual—first palpitation, later enlargement of the thyroid, still later exophthalmos; often months or years elapse before the disease is fully developed. Innumerable functional nervous

disturbances, often of an hysterical type, come and go during the course of the disease. After a long period of sameness a gradual improvement may take place, ending in recovery, or there may be indefinitely repeated periods of improvement, and relapse or gradual exhaustion, with intercurrent complications, may end in death.

**Prognosis.**—The prognosis is said to be least favorable when the disease attacks elderly persons of the male sex. As far as vision is concerned, the source of danger has already been alluded to. An excessive exophthalmos, with imperfect closure of the lids, may lead to *keratitis e lagophthalmo*, and the resultant corneal opacity or ulceration may lead to partial or complete blindness of one or both eyes (see also page 317).

In the absence of definite and constant pathological lesions discoverable after death, we are, for the present, constrained to class exophthalmic goiter as a functional disease which seems to depend upon a disturbance of innervation, especially that of the sympathetic. The present tendency is to regard certain parts of the central nervous system (medulla and upper part of the spinal cord) as the primary seat of this strange disease.

**Treatment.**—For the general treatment the reader will find this part of the subject elaborately discussed in most of the standard works on general medicine and neurology. The ophthalmic surgeon may, however, be called upon to deal with corneal complications. Undue exposure of the cornea may be obviated by an operation for narrowing the palpebral fissure (tarsorrhaphy, see page 547). Slight degrees of corneal irritation may be relieved by the use of a carefully adjusted compressive bandage and by soothing applications, such as vaselin, or mucilaginous collyria containing a small quantity of sodium borate or boric acid. Refractive error should always be corrected.

#### INJURIES OF THE ORBIT.

Injuries may be limited to the soft parts or involve the bony walls as well. The danger of such injuries depends upon their nature and extent. It is often impossible to estimate either of these factors exactly, except in the light of subsequent events.

With injury of the soft parts there may be more or less damage to the lids and eyeball. The appearance of orbital fat in the wound is proof positive that the orbit has been penetrated. Extravasation of blood with ecchymoses of the conjunctiva and integument, and exophthalmos, are commonly present. Paralysis of ocular muscles and loss of vision from damage to the optic nerve are significant. Foreign bodies of considerable size remaining in the orbit may displace, or even completely luxate, the eyeball.

**Foreign bodies** thrust into the orbit may be difficult to discover, and when aseptic have been known to remain for an indefinite period without creating serious reaction. Small foreign bodies—*e. g.* shot-grains—not readily discoverable by ordinary examination, may be located by means of the *x*-rays (see Appendix, page 607). Pointed or blunt objects withdrawn after penetration not infrequently have pierced the cranial cavity, the gravity of the lesion only being discoverable when cerebral complications occur.

**Injuries to the bones of the orbital margins** are a common result of crushing blows upon this part. The diagnosis is not difficult if the injured bone is sufficiently displaced to cause distinct unevenness or if a portion of the margin is detached. Mere sensitiveness to pressure is not diagnostic of fracture, though always coincident with it. The marginal fracture may extend as a fissure to any part of the orbit, even to the optic



foramen; in the latter case blindness may result from laceration of the optic nerve or hemorrhage into its sheath, or fissure of the orbital walls may occur from fractures of the base of the skull.

Emphysema of the lids and orbital tissues is quite common even where the violence has not been great, and indicates fissure of the thin walls between the nasal or ethmoidal cavities and the orbit: a suddenly developed elastic and crepitant swelling is quite characteristic of this. Exophthalmos due to this condition can be reduced by pressure with the finger. If due to extravasation of blood, as it often is in orbital fractures, the swelling cannot be reduced in this way.

Injuries of the orbit may recover perfectly after absorption of extravasated blood or air, but lesions of the eyeball, the optic or the third nerve, or the ocular muscles, often cause permanent impairment of function; or phlegmon of the orbit, with its attendant danger, may set in; or the contents of the cranial cavity may be involved directly or become so in consequence of the extension of septic inflammation following the injury. A fatal issue is then to be expected.

**Treatment.**—In recent injuries of the orbit, if there be an open wound it must be carefully and thoroughly cleansed and disinfected. Exploration for suspected foreign bodies is a matter which can only be left to the judgment and skill of the surgeon. Exploration with the finger, when practicable, is always to be preferred. Small and probably aseptic foreign bodies should on no account be searched for. Suitable provision for drainage of the wound may be required, and an antiseptic dressing is to be applied. Should suppuration ensue, the treatment will be that of orbital cellulitis. Rest in bed is essential if the injury is still severe.

**Hemorrhage into the orbit** when at all abundant causes an immediate exophthalmos, later ecchymoses of lids and conjunctiva; this latter may be the only sign of atrophic hemorrhages. It is a common result of severe injuries of the orbit, often occurs with fracture of the skull implicating the orbital roof, occasionally without this lesion.

*Spontaneous orbital hemorrhages* have occasionally been seen in scorbutus, hemophilia, and during violent paroxysms of coughing. A copious bleeding into Tenon's capsule is an accident, fortunately rare, in operation for squint.

**Injury of the Optic Nerve.**—Laceration of the optic nerve may occur, as has been stated, in connection with fracture of the bony walls of the orbit. But, independently of such an association, the optic nerve may be injured by a sharp stick, as in a case reported by Noyes, by a knife-thrust, or by a bullet. Atrophy of the nerve and blindness are the results of such accidents, which are not frequent, twenty-one cases having been collected by Aschman in 1884. Laceration of the nerve and the central retinal blood-vessels may be followed by retinitis proliferans, as in the case recorded by C. Zimmermann.

**Dislocation or luxation of the eyeball** exists when the eyeball has been pushed so far forward that the lids remain contracted behind it.

Traumatisms, such as when a large foreign body has been driven into the orbit from the outside, the use of an assailant's thumbs in certain brutal assaults—the so-called gouging—and a similar self-mutilation by insane persons, have been known to cause this condition, which would probably be less rare if the eyeball did not usually rupture at the time of injury. Traumatic dislocation is apt to cause blindness from rupture or laceration of the optic nerve.

The luxations that readily occur during the continuance of any morbid



condition attended with excessive exophthalmos are a mere complication of a more serious condition.

**Treatment.**—The eyeball should be replaced as soon as possible. To effect this division of the outer canthus may be necessary. After reposition a compressive bandage may be required, and in the second class of cases *tarsorrhaphy* (page 547) may be done to prevent recurrence.

**Enophthalmos** (*Idiopathic and Traumatic*).—A condition in which the appearance of the eye is the opposite of exophthalmos, the eyeball being retracted, is met with under various circumstances, as in wasting diseases with extreme emaciation and absorption of orbital fat; in Asiatic cholera because the enormous waste of fluids causes shrinkage of the orbital as well as other tissues; as one of the symptoms of paralysis of the cervical sympathetic; in neurotic anaesthesia of the face, as in *lepra anaesthetica*; and, finally, in a form distinctly traumatic in its origin.



FIG. 332.—Traumatic enophthalmos, patient looking straight forward; sunken appearance, resembling a badly-fitting artificial eye, well shown (de Schweinitz).

In some cases immediately—in others weeks or months—after traumatism, such as a blow upon the upper margin of the orbit without direct injury to the eye, enophthalmos appears, and may be due to paralysis of (Müller's) retractor of the lids—*i. e.* a local lesion of the sympathetic—or to trophic disturbance with atrophy of the orbital tissues. It has also been

ascribed to fracture with depression of the orbital floor, and to cicatricial contraction of the orbital tissues following certain injuries (Fig. 332).

## OPERATIONS.

---

### I. PREPARATION OF THE REGION OF OPERATION, THE INSTRUMENTS, AND THE DRESSINGS; ANESTHESIA.

BY G. E. DE SCHWEINITZ, A. M., M. D.,  
OF PHILADELPHIA.

---

ALL the principles of clean surgery and the main practices of aseptic surgery are necessary in all ophthalmic operations.

1. **Preparation of the Hands of the Operator.**—Scrub the hands thoroughly with soap and warm water; then clean the spaces beneath and around the nails; soak the hands in 95 per cent. alcohol for not less than one minute; on removing them place them without drying in a solution of 1 : 1000 corrosive sublimate, and allow them to remain there for at least one minute.

2. **General Preparation of the Patient.**—Necessarily, each patient preceding an operation should be placed in the best possible physical and mental condition. Usually a laxative is advisable. The author is accustomed to give calomel on the night preceding the operation and a saline in the morning.

The nares of patients requiring corneal section should be sprayed either with a mixture of listerin and Dobell's solution or with equal parts of water and the peroxid of hydrogen, which flushes out the passages and probably, largely by mechanical effect, gets rid of infectious material. Independently of the fact that chronic bronchitis by virtue of the cough which it produces is a complicating circumstance, it is perfectly possible that pathogenic germs may migrate from the lower respiratory tract and destroy the effects of an operation. Under these circumstances it has been advised to administer capsules of oil of eucalyptus, which is a good stimulating expectorant and plays the part of a mild antiseptic. It is almost needless to point out the necessity of ridding the patient of any inflammation of the conjunctiva, margins of the lids, or lachrymal passages preceding operative interference on the ocular tissues. If there is dacryocystitis, the usual treatment of this affection is indicated (page 268). Haab has recommended sealing the lachrymal puncta with a galvano-cautery needle. The inner corner of the eye may be covered with sterile iodoform powder to prevent access of infected fluid from the lachrymal passages to a corneal incision.

3. **Preparation of the Skin of the Region of Operation.**—The skin should be treated first with soap and water, then with alcohol, and finally with corrosive sublimate, 1 : 2000. These irritating substances must not enter the conjunctival sac, but the face, surface of the closed lids, eyebrows, brow,

and scalp should be thus prepared. The ciliary margins should be cleansed with soap and water followed by bichlorid of mercury, 1:5000. The parts should be kept covered with a compress of lint soaked in a bichlorid solution, 1:5000, which should remain in place for at least one hour before the operation begins.<sup>1</sup>

**4. Preparation of the Conjunctival Cul-de-sac and the Ciliary Margin.**—The method to be employed depends upon the nature of the operation. In enucleation, for example, the ordinary rules of antiseptic surgery are applicable, and the same is true, for instance, in an advancement, save only that the strength of the bichlorid solution commonly employed by general surgeons must be decreased. A solution of a grain to the pint is quite sufficient. Numerous investigations have demonstrated that it is impossible to sterilize the conjunctival sac. Therefore the object is to reduce the vitality of the microbes that cannot be washed away, and the mechanical effect of the fluid used is quite as potent as any germicidal value which it may exercise. Strong germicidal solutions are likely to be deleterious to the delicate epithelium of the corneal tissue. For irrigating purposes the surgeon may employ, provided the fluid reaches all portions of the conjunctival cul-de-sac and thoroughly scours out the folds of the conjunctiva, boric acid, 4 per cent., or physiological salt solution, which may be prepared by adding a heaping teaspoonful of salt to a pint of sterilized water, bichlorid of mercury, 1:10,000, or any of the other anti-septics mentioned in the footnote. The author prefers either the physiological salt solution or the solution of boric acid. As a final precaution the lids should be turned and gently mopped with a pledget of cotton soaked in the antiseptic solution, especial care being particularly taken to cleanse the region of the inner canthus.

The experiments of Bernheim, Stroschein, and many others have demonstrated the impossibility of completely sterilizing the ciliary margin; hence careful cleansing with soap and water, followed by the salt solution or one of the antiseptics mentioned, accomplishes the only practical result—namely, diminution of the vitality and number of the cocci. All of these preparations should be made immediately preceding the operation (see also page 575).

**5. Preparation of the Instruments.**—All coarse instruments, such as hooks, scissors, etc., should be cleansed first with soap and water, then boiled, and finally placed in an antiseptic bath, where they remain until required, and they should be covered with this fluid for not less than twenty minutes before the operation. The antiseptic bath may be carbolic acid, 1:20, or absolute alcohol, preferably the latter. Immediately preceding the operation the instruments may be removed from the antiseptic bath and placed in a dish of sterile water. Sharp instruments—cataract-knives, keratomes, cystotomes, etc.—must be cleansed with great caution, lest damage be done to their edges. First, the edge of the instrument is inspected with a magnifying-glass; then the instrument, wrapped in cotton, is put in the boiling water, and from this transferred to a dish containing absolute alcohol. When the operator is ready the knife is removed from this fluid and the blade freed from alcohol by dipping it momentarily in a vessel containing boiling water. Stroschein and others believe that antiseptics is secured if the blade is rubbed with cotton wool soaked in a mixture of equal parts

<sup>1</sup> In place of sublimate solution the following antiseptics have been recommended, especially in ophthalmic work: aqua chlorinata; trichlorid of iodine, 1:2000; cyanuret of mercury, 1:1500; oxycyanid of mercury, 1:1000; and especially formaldehyd, 1:2000. Of this list the cyanuret of mercury and formaldehyd have most to commend them, the latter substance being a most efficient ocular antiseptic, and the author has been most favorably impressed with its value.

of absolute alcohol and ether, to which a few drops of ammoniac have been added. Subsequently the knife may be washed in a 5 per cent. solution of carbolic acid. Instead of placing the instruments in absolute alcohol or carbolic acid, it is the practice of some surgeons to put them in a physiological salt solution or in sterile water;<sup>1</sup> or they may be used directly after removal from the boiling water. Perfect sterilization of non-cutting instruments made of platinum may be secured by bringing them to a white heat in the flame of a lamp just before the operation (Grœning).

Dr. E. A. de Schweinitz recommends sterilization of instruments with the vapor of formaldehyd. The practical value of formaldehyd in the disinfection of small instruments has also been demonstrated by H. O. Reik and W. J. Watson,<sup>2</sup> who have designed a special sterilizing apparatus.

**6. Dressings.**—These must be modified according to circumstances. In plastic operations about the lids the ordinary antiseptic dressing is usually applied—protective and antiseptic gauze covered by a wet or dry bichlorid roller. Iodoform is also used under these circumstances, although some surgeons—for example, Noyes—do not consider it an advantage. Dressings impregnated with antiseptic substances bought ready made from the various shops are not satisfactory. Sterilization with steam is the proper method. If a wet dressing is desired, the fabric may be soaked in one of the antiseptic fluids, usually bichlorid, 1:5000, or in a physiological salt solution which has been sterilized by boiling. Bits of gauze prepared by sterilization with steam are much more desirable than cotton for removing blood, etc. from the area of operation. If the lighter forms of cataract dressing are employed, such as isinglass plaster or small wads of cotton held in place by strips of surgeon's isinglass plaster, these should be properly disinfected before application.

When the eye is bandaged, either the single (Fig. 333) or the double

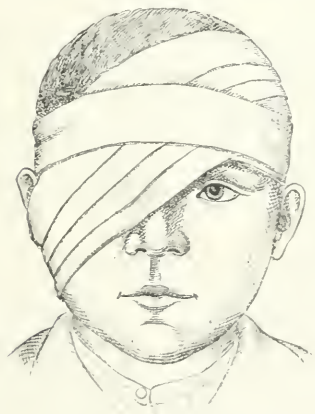

FIG. 333.—Figure-of-eight of one eye.

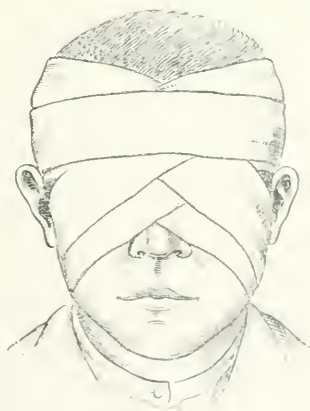

FIG. 334.—Figure-of-eight of both eyes

bandage (Fig. 334) is employed, or a modification of Liebreich's bandage (Fig. 335). In most cases a dry, absorbent material—for example, gauze sterilized by heat, is most useful, although there is no objection to a flannel

<sup>1</sup> For a valuable paper entitled "Absolute Alcohol as a Disinfectant for Instruments" by Robert L. Randolph, consult *Transactions of the American Ophthalmological Society*, vol. vii part 3, p. 631.

<sup>2</sup> *Johns Hopkins Hospital Bulletin*, No. 81, Dec., 1897.



roller, if it is desired, when this is placed over a properly applied antiseptic pad. The dressings applicable to the different operations vary according to the desire of the surgeon. Cataract dressing is described on page 581. In addition to the dressing recommended there, Ring's ocular mask (Fig. 336), which covers the bandage, and which may be understood by a reference to the figure, is of great advantage.

**Sutures.**—These may be of catgut or silk. The latter is usually black, ordinarily known as iron-dyed, although for delicate sutures in the conjunctiva

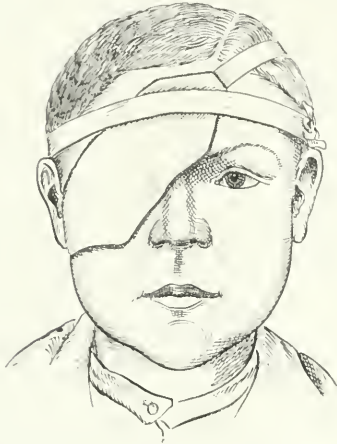

FIG. 335.—Modified Liebreich's bandage.

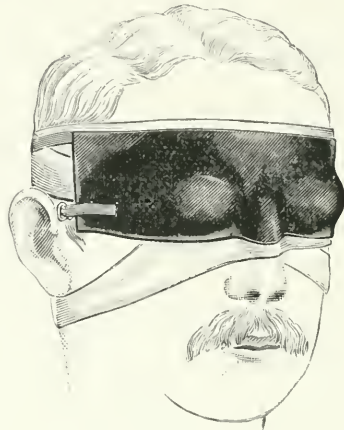


FIG. 336.—Ring's ocular mask.

the white silk—such, for example, as comes in Stevens's tenotomy case—is of great advantage. These sutures should be soaked in an antiseptic bath preparatory to their use.

Catgut specially prepared by the instrument-maker may be purchased, but it is better for the surgeon to prepare this for himself. The author is accustomed to use a delicate sulpho-chromic surgical gut, which is kept in a solution of bichlorid of mercury in alcohol, 1:1000. If sponges are used in plastic operations or in enucleations, they should be properly disinfected by the ordinary processes. Generally, the area of operation may be kept clean by gently touching it with cotton soaked in bichlorid solution, or by gauze which has been sterilized by heat.

**General Anesthesia.**—The indications for general anesthesia in ophthalmic surgery are limited. In children or in very nervous adults, and for enucleations, blepharoplastic operations, occasionally in advancements, and usually in cases of glaucoma, general anesthesia is necessary. The surgeon must decide between ether and chloroform. The author prefers the former, believing it safer than chloroform or the A. C. E. mixture. Bromid of ethyl has been recommended and much employed, but the author has not been favorably impressed with its value.

**Local Anesthesia.**—When local anesthesia is required, usually *hydrochlorate of cocain* is employed in 2 or 4 per cent. solution (some surgeons use a 10 per cent. solution). Various fungi grow readily in solutions of this alkaloid, and, indeed, in solutions of any of the alkaloids commonly used in ophthalmic practice. A number of methods of sterilization are employed—namely, sterilization by heat, by the addition of an antiseptic (1:5000 solution of bichlorid of mercury, 4 per cent. of borie acid, formaldehyd, as

recommended by Valude, or trikresol, 1 : 1000, as recommended by E. A. de Schweinitz of Washington), or by a combination of these two methods. The most satisfactory procedure is to boil the solution. A number of convenient flasks for this purpose are in the market, among the best being those introduced by Stroschein of Wurzburg (Fig. 337), and the one devised by Llewellyn

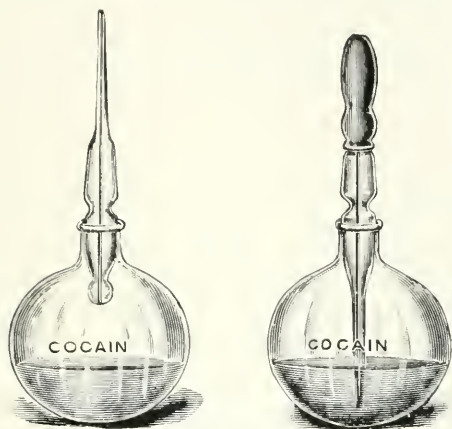

FIG. 337.—Stroschein's flasks.

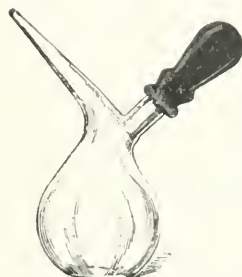

FIG. 338.—Flask for sterilizing collyria.

lyn of Philadelphia (Fig. 338). The Stroschein flask may be understood by a reference to the figure. The solution is placed in the Llewellyn flask and boiled. After the liquid is cool and ready for use the warmth of the hand causes the fluid to drop from the end of the pipette. If it is desired to preserve the solution after boiling, a portion of one of the antiseptic substances previously mentioned may be added.

In order to avoid the drying and roughening of the corneal epithelium caused by cocain the lids should be kept closed after each instillation. The drug should not be used too freely or it may, according to Mellinger, prevent closure of the corneal wound. Three instillations of a 4 per cent. solution, five minutes apart, are sufficient for a corneal section. Gelatin disks impregnated with cocain, as recommended by some surgeons, have no advantage over the solution, and general anesthesia is preferable to strong solutions of cocain, which have been recommended in the operation of curetting lupus and similar growths.

In addition to cocain, a number of other substances (for example, *tropacocain*) have from time to time been recommended as local ocular anesthetics, but without establishing claims to special favor. Three may be briefly described :

(1) *Hydrochlorate of eucain* "A," like cocain, is a local anesthetic, and may be employed in 2 per cent. solution. Its application is followed by very considerable smarting and conjunctival congestion. It has little or no effect upon the pupil, and is said not to cause drying of the corneal epithelium. The anesthesia begins in a few minutes and lasts from ten to fifteen minutes. The author has been unable to see in what way it possesses any advantages over cocain.

(2) *Hydrochlorate of eucain* "B" is related to eucain "A," and also to cocain and tropacocain. It is not decomposed by boiling, and is less irritating than the older eucain, according to Silex. A 2 per cent. solution causes local anesthesia in from one to three minutes, which lasts about fifteen minutes.

It does not dilate the pupil, apparently does not decrease intra-ocular tension nor cause clouding of the corneal epithelium.

*Holocain* (*p*-diäthoxyäthenyl diphenylamidin), introduced into ophthalmic therapeutics by Hirschberg and Gutmann, and originally known as "amidin," is an active local anesthetic closely allied in its general properties to phenacetin. A 1 per cent. solution causes anesthesia in from fifteen seconds to one minute, which lasts for ten minutes, preceded by a moderate burning sensation. Hasket Derby considers it advantageous because it does not enlarge the pupil, does not affect the accommodation, does not increase intra-ocular tension, and is itself bactericidal. *Holocain* is highly recommended by H. V. Würdemann.

**Infiltration-anesthesia.**—In lid-operations cocaine solution, 2–4 per cent., is sometimes injected beneath the skin, but a more efficacious and safer procedure is the so-called infiltration-anesthesia introduced by C. L. Schleich.<sup>1</sup> This consists of an intracutaneous (not subcutaneous) injection, with a hypodermic syringe or with one specially devised for the purpose, of a  $\frac{1}{5}$  per cent. solution of sodium chlorid, which is reinforced by the addition of from  $\frac{1}{100}$  to  $\frac{1}{50}$  per cent. of cocaine. The fluid injected produces edema, and the anesthesia is strictly limited to the edematous area.

Eucain has been much employed hypodermically, and also by the infiltration method. The general toxic effects which sometimes follow hypodermics of cocaine do not appear with eucain, but sloughing of the tissues has been reported.

---

## OPERATIONS UPON THE EYELIDS.

By F. C. HOTZ, M. D.,  
OF CHICAGO.

THE operations upon the eyelids may be divided into two groups. The *first group* embraces a number of surgical procedures which every practitioner having a general training in surgery may easily employ. The *second group* embraces those operations requiring a degree of dexterity and judgment which can be acquired only by special training.

### MINOR OPERATIONS.

1. **The Removal of Eyelashes.**—The simplest procedure for removing eyelashes is (*a*) epilation by means of a *cilium-forceps*.

With the fingers of the left hand a gentle steady pressure is made upon the lid, and with the forceps, held in the right hand, the eyelash is seized as near as possible to the skin and drawn out with a steady traction. Jerking must be avoided, lest the hair-shaft break off; also not more than one eyelash must be grasped at one time, because extraction of several eyelashes together is very painful.

Eyelashes so removed usually grow again; epilation, therefore, is the proper procedure only where a temporary removal of cilia is indicated. If a permanent removal is desired, we must have recourse to electrolysis or the scalping operation.

<sup>1</sup> For a full consideration of this method of inducing local anesthesia, together with the various formulæ suitable for injection, the reader is referred to a lecture by Schleich, published in the *International Clinics*, 1895, vol. ii. 5th series.

(b) **Electrolytic removal of cilia** requires a mild galvanic current and an electrolytic needle set in a convenient handle.

The eyelid being well steadied in the manner described above, the point of the needle connected with the negative pole of the battery is inserted along the shaft of the eyelash until it reaches the root, about 3 mm. under the surface. The other electrode, represented by a moist sponge, is placed upon the temple or the hand of the patient; this closes the circuit, and at once a whitish froth makes its appearance around the needle. After a few seconds the needle is withdrawn, the eyelash seized with forceps, and extracted. If it offers the slightest resistance, the electrolytic needle should be reinserted, for only if the eyelash is perfectly loose are we sure of the complete destruction of its root.

This procedure is quite painful; hence if a great number of cilia are to be removed, it is advisable to treat three or four eyelashes only at one sitting and to repeat the operation at intervals of a few days. As the operation produces no scars, it does not disfigure the lid. In this respect it is far preferable to the extirpation of the cilia by the scalping operation.

(c) **Scalping** consists in the excision of the whole ciliary border. The instruments required for this operation are a fine scalpel, forceps, small curved needles, a needle-holder, fine silk, and a lid-plate made usually of shell or hard rubber.

The surgeon, putting the thumb of his left hand upon the lid supported by a plate, makes a slight pressure upon it to turn the lid-border into full view. With the scalpel in his right hand he then makes an incision all along the lid-border just behind the eyelashes (Fig. 339), and deepens this incision by repeated strokes of the scalpel until the

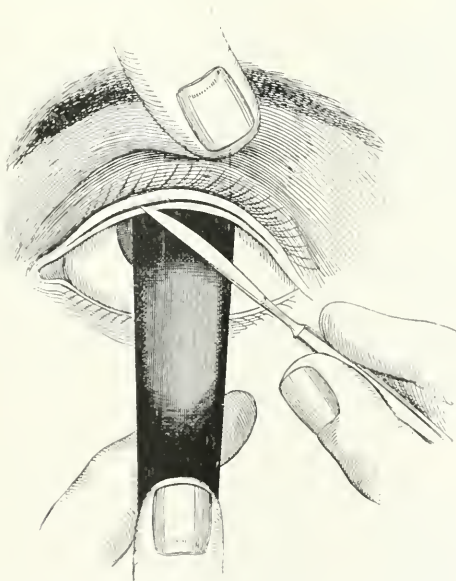


FIG. 339.—Making the intermarginal incision.

bulbs of the cilia are exposed as small black dots in the anterior margin of the wound. This incision is known as the *intermarginal incision*. Its correct execution requires a steady hand and watchful eye, for it is essential that no hair-bulbs shall remain behind in the posterior margin of the incision.

The next step consists of a transverse incision through the skin, made just behind the eyelashes; at both ends this incision is continued into the intermarginal incision, the two incisions thus including a long and narrow strip containing all eyelashes. This



strip is seized with fine forceps, and dissected up by deepening the cutaneous wound until it meets the internasal incision behind the hair-bulbs. After a careful inspection has convinced the operator that no hair-bulbs are left behind, the wound is thoroughly cleansed and closed by fine silk sutures, which are removed after three days.

In former years scalping was frequently performed, but since the introduction of electrolysis and improved modern operations for entropion it is seldom required, and fortunately for the patients, as it produces a very hideous and permanent disfigurement of the eyelid.

*Abscesses of the lid* are opened by a *transverse* incision through the skin and treated according to the general principles of surgery.

*Hordeolum* (or styé) is opened by a small incision and its contents are expelled by gentle pressure.

2. **Removal of a chalazion** (tarsal tumor, Meibomian cyst) can, in the majority of cases, be performed by an incision through the conjunctiva; but if it is very large, causing a decided protuberance of the skin, it is more

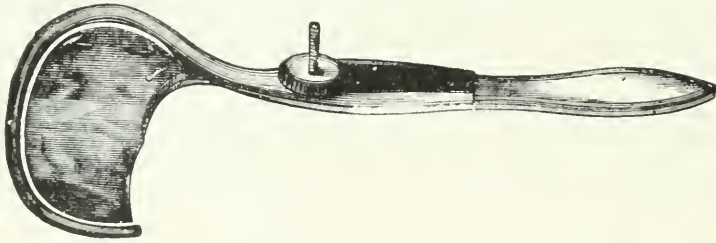


FIG. 340.—Knapp's lid-clamp.

convenient to attack the tumor through the external integument. In either case the use of the lid-clamp (Fig. 340) is very advantageous, as it makes the operation practically bloodless.

If the surgeon decides to remove the chalazion by incision through the skin, the lid is secured in a clamp and the tumor is exposed by a transverse incision through skin and muscular layer, and is cut open from within outward by transfixing its base with the narrow blade of a small scalpel. The contents of the cyst are removed, and each half of its wall is successively seized by a fine forceps and excised by small curved scissors. Upon the removal of the lid-clamp there is a free oozing of blood, which, however, is easily checked by pressing a compress gently upon the lid; next the lid is cleansed and the wound covered with iodoform; a bandage is not necessary. As these transverse incisions, following the natural creases of the lid-skin, have no tendency to gape, it is not strictly necessary to use sutures; but if the wound is very large, it is perfectly proper to close it by one or two sutures.

If the chalazion is to be removed by an incision through the conjunctiva, the position of the lid-clamp is reversed, its plate being put upon the outer side and its ring upon the conjunctival side of the lid (Fig. 341).

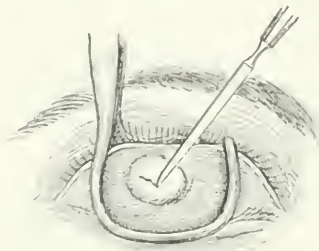


FIG. 341.—Incision of chalazion.

If the chalazion is very small, the clamp may be omitted, and the operation still be made almost bloodless if the lid is everted and firmly pressed against the handle of a scalpel or the nail of an assistant's finger.

The clamp being screwed down the lid is everted; the cyst, marked by a dark red, prominent patch in the conjunctiva, is opened by an incision; a small curet is introduced and the contents are scraped out. Overhanging edges of the cartilage may be trimmed off without fear of producing a contraction. The cartilaginous walls of the chalazion often contain small pockets filled by the same granulation-tissue; these side-pockets should always be

searched for and thoroughly scraped out, for if overlooked they form the nucleus of a new tumor, and often account for the recurrence of the chalazion at the site of the operation.

When the clamp is removed the cyst-cavity fills with blood, producing more or less tumefaction of the lid; but in a few days the blood is absorbed and the lid-swelling is gone. No special dressing is needed, except perhaps the application of a warm wet compress for a few hours to allay pain.

Dr. Agnew's method of removing the contents of the chalazion through an intermarginal incision has no material advantage over the other methods.

To remove chalky deposits in the Meibomian glands, the lid is everted and the conjunctiva over the white deposit is punctured, and the chalky grain picked up on the point of a Graefe cataract-knife.

*Polypoid granulations* on the conjunctiva, warty excrescences at the lid-border, and similar growths are excised with curved scissors; if necessary, the small wound is touched with liquid chromic acid at the end of a probe.

**3. Operations for Making a New Canthus; Canthoplastic Operations.**—The object of these operations is either to reduce or to increase the transverse diameter of the palpebral aperture.

(a) **The Operation for Shortening the Palpebral Fissure** (*Tarsorrhaphy* or *Blepharorrhaphy*).—This accomplishes its object by uniting the opposing lid-borders for a short distance at the outer or inner canthus (*external* or *internal tarsorrhaphy*). The operation, as applied to the outer canthus, is performed as follows:

The surgeon seizes the border of the lower lid with a forceps near the outer canthus, and transfixes it with a narrow scalpel 2 mm. below the eyelashes in such a manner that the back of the blade is turned toward the canthus and its point emerges from the intermarginal surface of the lid-border just in front of the orifices of the Meibomian glands; pushing the blade along the lid-border by a steady sawing movement, the operator cuts from it a narrow strip, from 4-6 mm. in length, which must contain all the eyelashes. In the same way a similar flap is removed from the opposite border of the upper lid; the two opposing denuded surfaces (Fig. 342) are carefully united by two or three fine silk sutures, and the lids are kept immobilized by a bandage for two or three

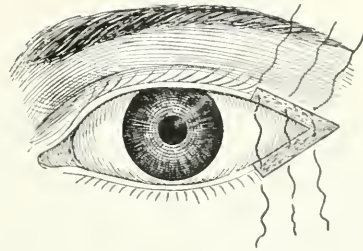


FIG. 342.—External tarsorrhaphy.

days, when the sutures are removed.

*Internal Tarsorrhaphy.*—In a case of paralysis of the orbicularis muscle, causing eversion of the lower tear-point, Dr. Arlt<sup>1</sup> has relieved the troublesome epiphora by a tarsorrhaphy at the inner canthus. From the tear-points toward the inner canthus a narrow strip of cutis was pared off and the wounds were united by two sutures.

Dr. H. D. Noyes<sup>2</sup> operated for the same purpose in the following manner: "I dissected up a parallelogram of skin above and below the canaliculi for a space which reached from the commissure to 3 mm. beyond the puncta. I turned the raw surfaces of the little flaps, raised from the respective lids, against each other and stitched through them. The puncta were thus turned inward and out of sight."

(b) The operation for enlarging the palpebral fissure (*canthotomy* or *blepharotomy*) is performed at the external canthus only.

If the enlargement of the fissure is required only temporarily for relieving the eyeball of the pressure of excessive lid-swelling in acute blephorrhoea,

<sup>1</sup> Graefe and Saemisch: *Handbook*, vol. iii. p. 446.

<sup>2</sup> *Text-book of Ophthalmology*, 1894, p. 2-4.

or for the removal of an enlarged globe or a retrobulbar tumor, the operation consists simply in a horizontal incision through the commissure, the wound being allowed to close up again (*temporary canthotomy*).

But if the enlargement of the fissure is to be permanent, the reunion of the wound-edges must be prevented by lining them with conjunctiva (*permanent canthotomy*). The steps of the operation are as follows:

An assistant draws the temporal portions of the lids apart to make the external commissure stand out as a firm vertical ridge. The surgeon inserts the one blade of

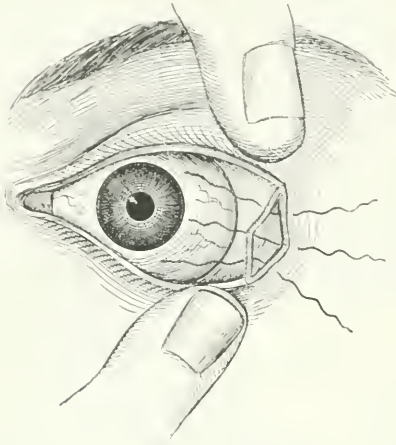


FIG. 313.—Canthotomy.

blunt-pointed straight scissors between the commissure and globe, and pushes it in a horizontal direction toward the wall of the orbit; next the scissors are shut, and with one firm stroke the entire thickness of the commissure is cut through. The bleeding is usually profuse, but easily controlled by pressure; sometimes, however, it is necessary to use torsion upon a small artery. Owing to the traction of the assistant upon the eyelids, the transverse incision is immediately changed to a vertical rhomboid wound (Fig. 343), whose temporal side is represented by the skin and the bulbar side by the conjunctiva. Skin and conjunctiva are then united by sutures to keep the palpebral fissure permanently enlarged. Three sutures are applied—one uniting the center of the wound where the new canthus is to be, and one suture above and one below it.

Before these sutures are passed it is necessary to loosen the conjunctiva from the underlying tissues. Seizing the conjunctival border of the wound with forceps, the surgeon draws upon it until he distinctly feels the resistance of the ligament; then, passing the closed blades of curved scissors into the wound, he feels for the ligament, and when he has found it opens the scissors just far enough to get the ligament between the blades, and cuts it by one quick stroke. As soon as the ligament is cut the conjunctiva is so movable that it can easily be united with the skin-borders of the enlarged fissure. The sutures should be tied rather loosely, lest they cut through the swollen tissue too soon. Bandaging is not necessary. On the third or fourth day the sutures can be removed.

*Operation for Epicanthus.*—The best results are obtained by the modified v. Ammon's operation, devised by Dr. Knapp<sup>1</sup> in 1873.

A rhomboidal piece of skin, over an inch in length and nearly two-thirds of an inch in width at its broadest part, is excised on the root of the nose. The skin at both sides of the wound is carefully undermined, and when the bleeding has subsided the wound is united by silk sutures. Dr. Knapp covers the wound with plaster strips to protect it from the child's hands, for immediate union is of the greatest importance to avoid unsightly scars on the nose.

#### MAJOR OPERATIONS.

This group comprises operations—

1. For the correction of malposition of the eyelids (entropion and ectropion);
2. For the reconstruction of the partly or totally destroyed lid;
3. For the relief of ptosis.

1. **Operations for Entropion and Trichiasis.**<sup>2</sup>—Instruments.—Small scalpels, curved scissors, mouse-toothed forceps, needles, needle-holder,

<sup>1</sup> *Archives of Ophthalmology*, vol. iii. p. 53.

<sup>2</sup> The so-called trichiasis represents merely the most advanced stage of entropion.



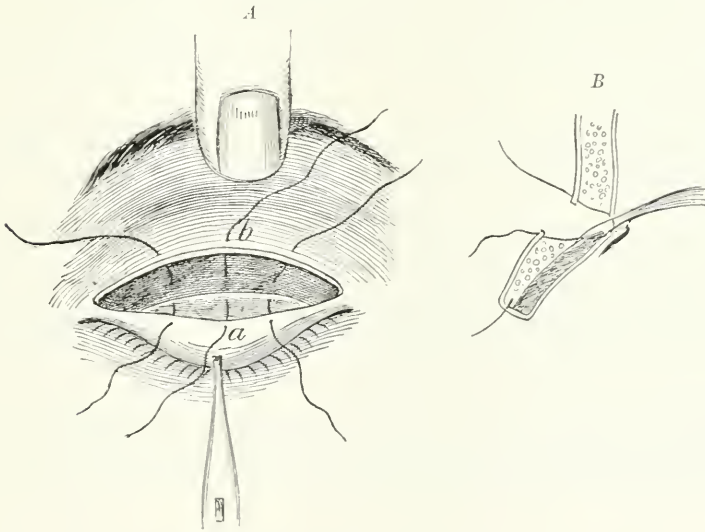
and silk Nos. 1 and 3. The lid-clamp and lid-plate are not absolutely required, though used by many operators.

The chief object of all entropion-operations is to remove the offending eyelashes from contact with the eyeball. This can be accomplished in two ways: either the whole inverted lid-border is turned up and secured in its normal position by a permanent tension from a fixed point above, or the eyelashes alone are turned up to their normal direction and supplied with a support below to prevent their reinversion.

1. The principle of relieving entropion by permanent tension upon the lid-border finds its most correct and successful application in the operation of *Anagnostakis and Hotz*.<sup>1</sup>

The operation is performed on the upper lid as follows:

While an assistant fixes the skin at the supra-orbital margin the operator, seizing the center of the lid-border with fingers or forceps, draws the lid downward to put its skin well on a stretch, and makes a transverse incision through skin and orbicularis muscle from a point 2 or 3 mm. above the punctum lacrymale to a point 2 or 3 mm. above the external canthus. This incision (Fig. 344, *A*) divides the lid-skin in a line



FIGS. 344, 345.—*A* and *B*, operation of Anagnostakis and Hotz.

parallel to and a little below the upper border of the tarsal cartilage, and is therefore from 4 to 8 mm. distant from the free border in the center of the lid. The skin and muscular layer are now dissected from the incision down to the roots of the eyelashes, and, while an assistant is holding the edges of the wound well separated, the operator seizes with forceps and excises with curved scissors the muscular fibers running transversely across the upper border of the tarsus. Next the sutures are inserted. Three sutures are usually sufficient—one in the center of the wound and one at each side of the central suture. The curved needle, armed with black silk No. 3, is first passed through

<sup>1</sup>To the former belongs the credit of having been the first (*Annales d'Oculistique*, 1857) to declare that in order to be effective, uniform, and lasting the skin-tension applied to the lid-border must proceed from a fixed point so located that it maintains the same distance from the lid border in all the various positions and movements of the lid, and the only point which fulfils these anatomic conditions is the opposite border of the tarsal cartilage. But this valuable suggestion and the operation based upon it did not find among the oculists the recognition they deserved. Twenty years later Dr. Hotz was led by his own independent investigations to adopt the same views (*Arch. of Ophth.*, viii. p. 249), and to suggest an operation in its chief features identical with that of Anagnostakis.



the wound-border of the lid-skin (Fig. 344, *a*); then it is thrust through the upper border of the tarsus and returned through the tarso-orbital fascia just above this border; and finally it is carried through the upper wound-border (Fig. 344, *b*). When these sutures are tied the skin is drawn upward and fixed to the upper tarsal border (Fig. 345, *B*), and this slight traction is sufficient to turn the inverted lid-border and eyelashes to their normal position; and, as the skin becomes firmly united with the tarsal border, the tension thus produced upon the lid-border is permanently secured.

The sutures should, of course, not be tied until all bleeding has ceased and the wound is thoroughly cleansed; they may be removed on the third day. Under aseptic dressings the wound heals by first union, even if, as sometimes occurs, secondary hemorrhage or edema causes considerable swelling for several days. Should, however, suppuration occur, the sutures should at once be taken out to give free exit to the pus; and if the suppuration is promptly subdued, a fair result may still be hoped for, because the contraction of the cicatrix unites the skin with the tarsal border.

This operation can be performed also on the lower lid; only that on account of the smallness of the tarsus the sutures are passed entirely below it through the tarso-orbital fascia.

In the higher degrees of entropion (trichiasis) additional surgical measures are often necessary: if the palpebral fissure is abnormally contracted, canthotomy should be done in connection with the entropion operation; and if the tarsus is much shrunken and rigid, the reposition of the lid-border cannot be accomplished without *grooving the cartilage* (*Streetfeild-Snellen's operation*).

Just above the roots of the eyelashes a transverse, narrow wedge-shaped strip is removed from the cartilage; the resulting groove makes it easy for the lid-border to turn up under the traction of the skin when it is sutured to the upper border of the tarsus.

2. The second principal method of relieving entropion may be called the *reconstruction of the lid-margin*. It consists in turning up the inverted eyelashes alone, and supporting them in their normal position by a new lid-margin. This operation, first suggested in 1873 by Spencer Watson's complicated double-transplantation, has gone through numerous changes before it was evolved into the present simple procedure.

The inverted lid-border is split by the intermarginal incision, great care being taken that *all* cilia are contained in the anterior layer. This incision is deepened so much that the anterior layer with the lashes can easily be everted, thereby converting the intermarginal incision into a gaping wound (Fig. 346) several millimeters in depth.

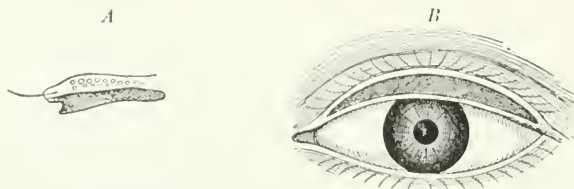

FIG. 346.—Reconstruction of lid-border.

This groove is to be filled either by a strip of mucous membrane or a skin-graft. The graft must be of the same length and width as the intermarginal wound.

The strip of mucous membrane is cut out with a few clips of a pair of curved scissors from the inner surface of the under lip, and placed at once on the wound and pressed into position with a pledget of cotton wool or gauze.

The skin-graft is cut out from the integument behind the ear, the incisions penetrating obliquely just into the corium. It is at once transported to the lid and pressed into the groove. If the graft should be too large, it should be trimmed down with a pair of small curved scissors until its edges are even with the margin of the wound. Sutures are unnecessary, but both eyes should be bandaged for twenty-four or forty-eight hours, until the graft is adherent.

The writer prefers skin-grafts, because the normal intermarginal space is lined by skin, not by mucous membrane; because skin-grafts are less likely to mortify; and because filling the entire depth of the wound makes a more substantial new lid-border. The use of skin-grafts is often objected to on the ground that the fine hairs in the transplanted strip would irritate the eye, but if the grafts are cut as described above, they never grow any hairs. If subsequently any hairs are found in the newly-made lid-margin, a careful inspection will prove that they grow from the posterior edge of the lid-margin, or, in other words, they are cilia which the operator when making the intermarginal incision has left in the posterior margin of the wound.

The two methods of entropion-operation here described can relieve all degrees of entropion; in the worst forms the best results are obtained by the combination of both methods.

This latter plan is certainly superior to the *Jausche-Arlt operation*, in which also skin-tension is combined with the transplantation of the cilia.

The lid-margin is split by the intermarginal incision; next a second incision is made 5 mm. above and parallel to the ciliary edge, and a third incision is carried in a curve from one end of the second incision to the other end, and the semilunar piece of skin is removed. The bridge containing the eyelashes is detached from the underlying cartilage by careful dissection, so that when the margins of the gaping skin-wound are drawn together by fine sutures the bridge is shifted upward. This produces along the lid-margin a gap which is covered by a piece of skin (Waldauer's modification).

The objectionable features of this operation are that the new intermarginal space is abnormally broad, and that the excision of the lid-skin seriously disturbs the natural appearance and movements of the lid. In many instances the shortening of the lid-skin has made the closure of the lids impossible.

Burow, Green, and others, believing in an incurvation of the tarsus as the chief factor in the production of entropion, practise a transverse incision from the conjunctival side through the entire thickness of the tarsus to straighten the supposed incurvation. These operations are seldom permanently successful, and leave on the conjunctival surface a thick scar which is often the source of a persistent irritation to the eye.

**II. Operations for Ectropion.**—The eversions of the lid calling for operative correction are the senile ectropion and the various forms of eversion from the contraction of cicatrices following extensive tissue-destruction in the lid and its vicinity (*cicatricial ectropion*).

**Senile ectropion** occurs only in the lower lid from a relaxation of its tissues associated with a lengthening of its free border. Unless the lid-border is shortened, the reposition of the everted lid cannot be successfully accomplished. This accounts for the unsatisfactory results attained by the suture-operations (Snellen, Argyll-Robertson, and others) which attempt to overcome the eversion by the traction of sutures carried from the conjunctiva near the fornix through the entire thickness of the lid, and tied upon the cheek over a piece of small rubber tubing.

*Shortening the lid-border* is accomplished by *Adams's operation*:

A wedge-shaped piece is excised from the entire thickness of the lid and the margins of the wound drawn together by sutures. If, as originally practised, the piece is excised from the center of the lid, the contraction of the scar produces an unsightly notch in the lid-border: this disfiguration is avoided by making the excision at the external canthus (Fig. 347).

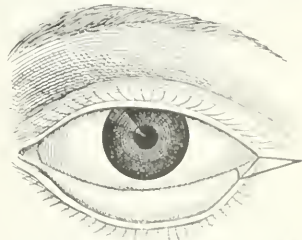


FIG. 347.—Shortening of the lid-border.

*The Kuhnt-Müller Operation.*—A very neat operation for the same purpose was designed by Prof. Kuhnt in 1883, and modified by L. Müller in 1893.

A deep incision is made by an iridectomy-knife into the center of the lid-margin to split the lid-substance into two portions—the one portion containing the conjunctiva and tarsus, and the other portion containing the soft tissues and the skin. From the first portion a triangular piece is dissected out by two incisions (Fig. 348, *A*, *ac* and *bc*) converging toward the fornix. The two portions of the lid are further separated toward the external canthus by carrying the lance from and under the margin *bc* toward *d*. Now the V-shaped wound of the tarsus is closed by one or two sutures, and then the long stretch of the skin-margin (*da*) is “gathered up” with the much shorter margin *db* of the tarsus by sutures; the proper mode of their application is best understood by a reference to Fig. 348, *B*. Where these sutures are tied the skin puckers a little between each suture, but the process of cicatrization will efface every trace of this unevenness and restore a perfectly smooth lid-margin.

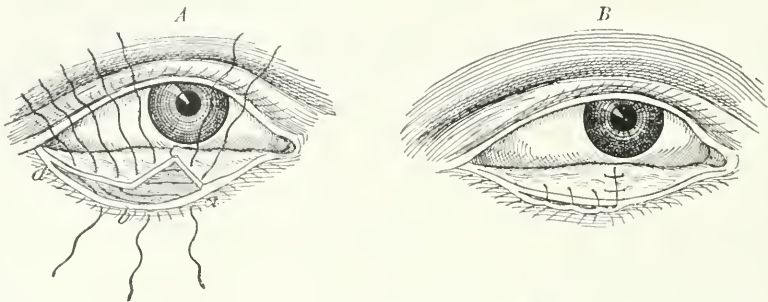


FIG. 348.—*A*, shortening of lid-border after manner of Kuhnt and Müller; *B*, Kuhnt-Müller operation, final stage.

In the operations for *cicatricial ectropion* the first step should always be to liberate by careful dissection the everted lid from all cicatricial adhesions so thoroughly that its reposition is possible without the least restraint or resistance.

*Cicatricial ectropion of the lower lid* presents two problems:

1. Its border, being stretched and abnormally lengthened, must be reduced to the proper size.

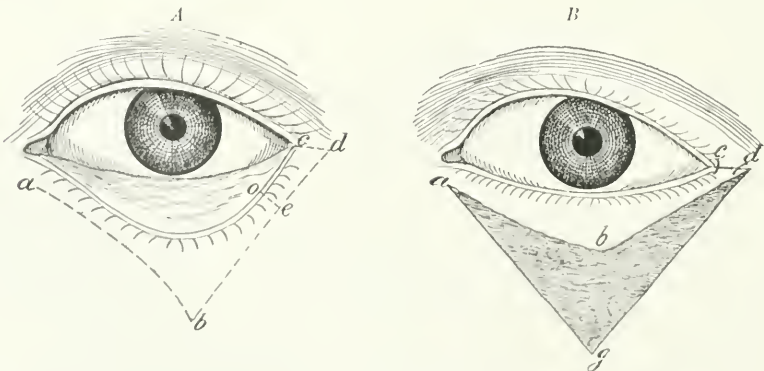


FIG. 349.—*A*, Arlt's operation for cicatricial ectropion of lower lid; *B*, final stage.

2. The replaced lid must be provided with a solid support below to hold it in its normal position.



In many instances these problems can be successfully solved by *All's operation* (Fig. 349, *A* and *B*).

The incisions *ab* and *bd* are made so that they form at *b* an acute angle. These incisions are carried right through the cicatricial tissues; the flap *abd* is carefully dissected up to the lid-border, and the lid released from all cicatricial restraints, so that it can easily be brought into its normal position. Next the lid-border is shortened at the external canthus by removing the piece *coed*, making an incision *co* along the edge just behind the eyelashes on the conjunctival side and the crosscuts *cd* and *oc*. If now the lid-border is lifted up into its proper position, the wound-margins *oc* and *ed* are brought in apposition and held together by two sutures.

The reposition of the lid leaves below it the open wound *abdg* (Fig. 349, *B*), which must be filled with some solid material to furnish a good support to the lid according to the second indication stated above. If the adjacent integument is sound and elastic, the support of the replaced lid can be furnished by drawing the margin *ag* and *gd* together from *g* upward, and by uniting also a portion of the margin *ag* with *ab* and *gd* with *bd* to a Y-shaped cicatrix.

If this plan cannot be adopted, *Wolfe's method of grafting a skin-flap without a pedicle* upon the wound should be practised.

The edges of the lower and upper eyelids are united by three ligatures, and the ends of the ligatures are drawn up and fixed upon the forehead by strips of adhesive plaster. The shape and size of the skin required must be carefully cut out in lint. A piece of lint is then laid upon the forearm and the shape traced by the point of the knife, *making it one-third larger all around to allow for shrinking*. This flap is excised and spread out on the left forefinger to remove from it with sharp scissors all areolar tissue to leave a white surface. The flap so prepared is put upon the wound and moulded into position. No sutures are used; several pieces of lint or gauze wrung out of hot water are laid upon the flap and secured by a bandage. *The eye should not be disturbed for the first three days*, after which the dressing should be carefully removed, the last layer being well soaked with hot water in order that it may be removed easily without deranging the flap. It may then be dressed every twenty-four hours. The ligatures of the eyelids should not be removed before six weeks.

This operation is superior and preferable to all the numerous ingenious methods of transplanting flaps with pedicles from the face, for it is free from the serious disadvantage they possess—to wit, that if the flap sloughs the disfiguration of the face is worse after the operation than before.

*Operation for cicatricial ectropion of the upper eyelid* presents an additional problem of great interest—namely, to restore its mobility. On this account the selection of a proper material to replace the lost skin of the lid is of the greatest importance. This material should be so thin as to mould itself to the surface of the lid, and so light and pliable as not to impede the movements by its weight and thickness. For these reasons the transplantation of skin-flaps from the temporal region cannot be recommended. *Wolfe's flaps* have been used with fairly good results, but the lid always looks heavy and cannot be elevated to the full extent.

*Thiersch's method of skin-grafting* yields better cosmetic results.

The lid, being completely liberated from the cicatricial adhesions, is drawn down and fastened to the cheek by three ligatures passed through the lid-border. The wound is temporarily covered with a gauze compress wrung out of a warm solution of sodium chlorid ( $\frac{1}{2}$  per cent.) while the grafts are being cut from the flexor side of the arm. The surgeon grasps the arm between the thumb and fingers of the left hand to draw the skin tense, and, holding the razor in his right hand, he lays its blade flat upon the well-wetted surface of the arm, and presses it down just enough to make its sharp edge bite into the skin, but no deeper than the papillary layer. By slow and short sawing motions the blade is steadily pushed on in the papillary layer until a piece of epidermis of the desired size has been gathered on the razor-blade.

During this "shaving process" an assistant drops salt solution upon the blade and pushes with a probe the skin-shaving back from the edge of the razor. To cut the



shaving off, the edge of the knife is turned up, while the assistant presses the probe flat down upon the shaving near the edge of the razor-blade. Now the compress is removed from the lid, the wound is carefully cleansed of all coagulated blood, and the skin-shaving is transferred directly from the razor to the lid-surface. For this purpose plenty of salt solution is dropped on the razor to keep the graft floating; if, now, the edge of the razor near its point is brought in contact with the border of the wound, the solution will run off from the razor and carry the graft with it; but as soon as the solution begins to flow and the edge of the graft has come in contact with and clings to the wound-border, the razor is drawn from under the graft across the wound, by which maneuver the skin-graft floating from the razor is at once spread out smoothly over the lid-surface. It is not difficult to cut shavings from  $1\frac{1}{2}$  to 2 inches in length and from 1 to  $1\frac{1}{2}$  inches in width if only the knife-blade is operated by a steady hand and moved in the same plane. When the whole wound is well covered with these skin-shavings two layers of strips of silk protective, moistened with the salt solution, are placed in position. They should be half an inch wide and long enough to lap over the wound-border on both sides; one layer is placed in a transverse direction and the second layer in a longitudinal direction. These strips are covered with a compress which is to be kept wet with salt solution. The sound eye should also be bandaged.

This first dressing should remain undisturbed for two days. To remove it the compresses and strips of protective are thoroughly soaked with salt solutions; the grafts are rinsed with the same solutions, and fresh strips and compresses are applied. After four or five days the bandage may be removed from the sound eye, at the end of one week the ligatures may be cut, and during the second week the grafted lid needs only to be daily rubbed over with iodoform ointment. After the second week no further treatment is required. The grafted skin undergoes a gradual contraction of about one-fourth of its area, but if this shrinkage has been anticipated by the operator, it will not affect the perfect cosmetic success of the operation.

*Transplantation of Cicatricial Skin to Replace the Integument of the Lid.*— For cases where the eyebrow is partially destroyed and the supraorbital region largely covered by cicatricial tissue the author has made the new skin of the replaced lid from this cicatricial skin.

In case of complete ectropion of the upper lid (Fig. 350) the procedure was as follows:<sup>1</sup>

The border of the everted upper lid of the left eye was drawn up and fixed to the temporal portion of the supraorbital margin, and above it a large stretch of cicatricial skin extended far into the frontal and temporal region. The absence of the temporal



FIG. 350.—Showing restoration of the upper lid.

half of the brow made the following operation possible: From a point (*a*, Fig. 351) near the inner canthus an incision was carried obliquely upward past the end of the eyebrow,

<sup>1</sup> Case reported to the *American Medical Association* in 1896.

well up into the cicatricial skin above the supraorbital margin, and then continued at a considerable distance from the lid-border in a curved line downward to a point (*c*) about 6 mm. from the external canthus. The large skin-flap (*abc*) mapped out by this

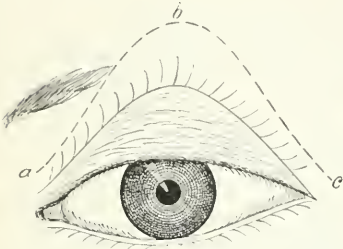


FIG. 351.—Hotz's transplantation of cicatricial flap.

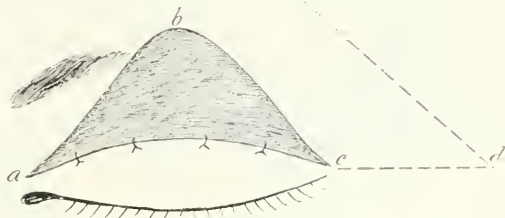


FIG. 352.—Second stage of Hotz's transplantation of cicatricial flap.

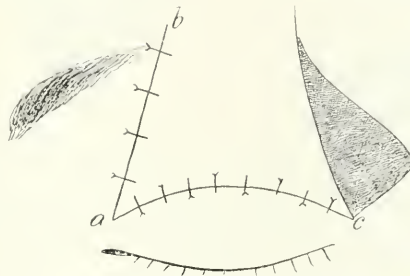


FIG. 353.—Final stage of Hotz's transplantation of cicatricial flap.

incision was carefully dissected from the underlying scar-tissue down to the lid-border, with which it was left connected. The lid then was released from all cicatricial adhesions and replaced in its normal position.

The cicatricial skin-flap (*abc*, Fig. 351) contracted considerably as soon as it was detached from its basis; but as this shrinkage was anticipated by cutting the flap of very large dimensions, it was still sufficiently large to cover the whole surface of the lid. It was spread over this surface, and its margin (*ac*, Fig. 352) was fixed by four sutures to the upper border of the tarsus, and the resultant wound (*abc*) above the lid was covered by a skin-flap (*bcd*) from the temporal side, the margin *bc* being united to *ab*, and *dc* to the margin *ac*, Fig. 353.

The great advantage of this operation lies in the fixation of the new lid-skin to the upper tarsal border. This union makes the new skin an integral part of the lid, and constitutes a protective barrier to prevent tissue-contraction, which may take place in the supratarsal region, from disturbing the position of the lid.

**III. Operations for the Restoration of the Lid (Blepharoplasty).—**If the lid is partly or totally destroyed (by injuries, extirpation of tumors, ulcerations, etc.), the defect is repaired by the transplantation of skin-flaps from the vicinity. The operative procedures are as numerous as the lesions vary in character and extent, and each case must be studied well to designate the method best suited for its conditions. In general, it may be said that the results of blepharoplasty present a far better appearance on paper than in flesh.

The following methods may serve as working patterns :

*Eversbusch's Method for Making an Entire New Lid.*—A skin-flap of suitable shape and size is cut in the vicinity, and the wound as well as the under surface of the flap is covered with Thiersch skin-shavings. A piece of silk protective being placed upon the

wound, the flap is put back in its original place, and left there under proper aseptic dressings until the Thiersch grafts are adherent. Then the cicatrix along the orbital margin is excised, and the skin-flap being laid across the eyeball, its edge (which has been previously freshened up) is sutured to the wound along the orbital margin.

If a portion of the conjunctiva is preserved, this is carefully dissected up from the cicatricial adhesions and used for lining the transplanted flap.

For the reconstruction of the upper lid a tongue-shaped flap is taken from the temporal region—*Fricke's method* (Fig. 354).

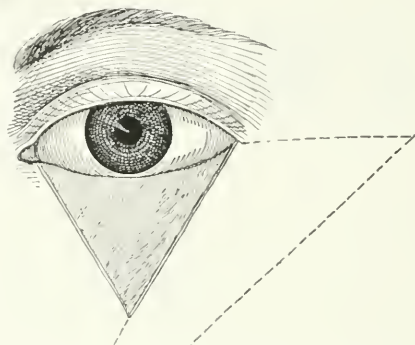
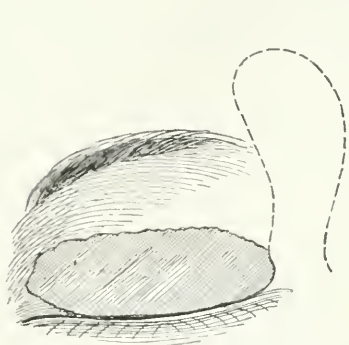
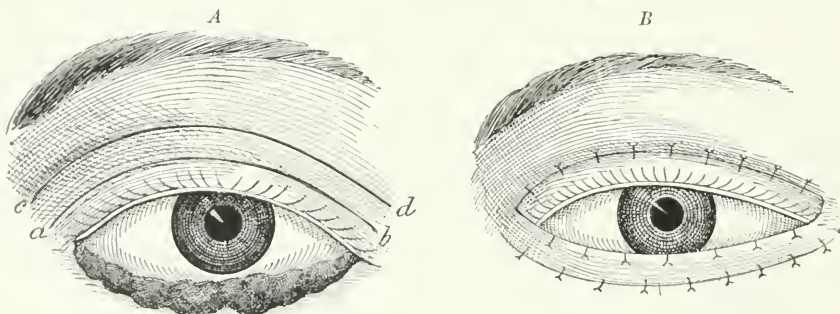


FIG. 354.—Fricke's method of blepharoplasty. FIG. 355.—Dieffenbach's method of blepharoplasty.

The lower lid can be restored by *Dieffenbach's method* of sliding a flap taken from the cheek upon the triangular wound (Fig. 355), or by



FIGS. 356, 357.—Landolt's method of blepharoplasty.

*Landolt's Method* (Figs. 356, 357).—Two parallel incisions (*ab* and *cd*), which at both ends reach a few millimeters beyond the canthi, are made through skin and orbicularis of the upper lid, and this bridge, being dissected from the tarsus, is drawn down to take the place of the lost lower eyelid. The lower edge of the flap is sutured to the skin along the infraorbital margin, and its upper edge is united with the conjunctiva. After union has taken place the connections of the skin-bridge with the upper lid are divided.

If only a portion of the lower lid is lost, the remaining portion may be moved over into the defect, and, if the defect is very large, a skin-flap can be drawn over from the opposite side to be joined with the transplanted lid-portion—*Knapp's method* (Fig. 358).

For partial destruction of the upper lid Landolt has devised the following ingenious method (Fig. 359):

The nasal portion of the upper lid being lost, the surgeon splits the remaining lid-portion in its entire extent into two layers, the anterior layer containing the skin and muscle, the posterior layer containing the tarsus and conjunctiva. An incision made



through the anterior layer from the external canthus obliquely upward to the eyebrow allows the anterior layer to be shifted toward the nasal side, where it is united by sutures with the nasal margin of the original lid-defect; sutures are also put into the

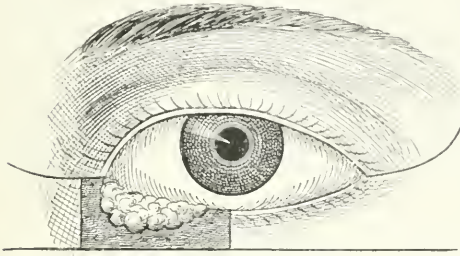


FIG. 358.—Knapp's method of blepharoplasty.

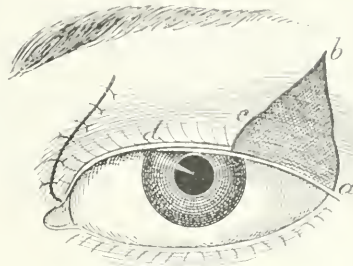


FIG. 359.—Landolt's restoration of a partially destroyed upper lid.

lid-margin from *c* to *d* to reunite the transplanted anterior layer with the posterior layer. The triangular wound (*abc*) resulting from the sliding of the anterior layer is covered by Thiersch's skin-grafts.

**Operations for Coloboma of the Lid.**—Congenital and traumatic colobomata of moderate extent can usually be rectified by a careful union of the freshened edges. Extensive lacerations of the lid, however, often produce so great a displacement of the severed lid-portion that its reposition requires a regular transplantation, as, for instance, in the following case :

In September, 1886, a young man received a deep cut by a piece of glass, completely dividing the temporal third of the upper lid of the left eye. In November he presented himself with a long oblique scar in the upper lid, with its temporal portion so displaced that its edge ran straight upward. To relieve this deformity the scar was excised from *a* to *e*, and a flap was formed by the deep incisions *ce* and *eg*. This flap, being well

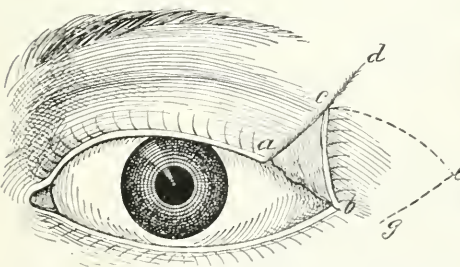


FIG. 360.—Replacement of lacerated lid according to Hotz.

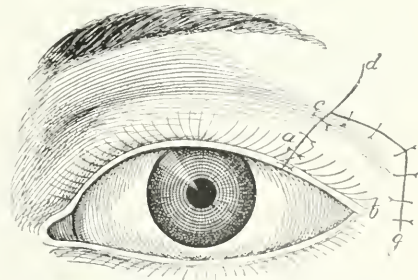


FIG. 361.—Result of replacement of lacerated lid.

mobilized, was then turned so as to bring the lid-edge *bc* into its normal position; the wounds were then closed by uniting the edges *ce* with *ac* and the neighboring skin with *ge*. The result was very satisfactory.

**IV. Operations for Ptosis.**—Patients suffering from paralysis of the levator palpebrarum instinctively learn to elevate the lid to a certain degree by the aid of the frontalis muscle. Its contractions, drawing the eyebrow and the integument between the brow and eyelid upward, exert indirectly a traction upon the lid by which a moderate elevation of the lid is accomplished. To increase this vicarious action of the frontalis muscle upon the upper lid is the aim of the following ptosis operations :



*Panas's Operation.*—The upper lid being stretched upon a horn plate, a transverse incision, following the furrow above the lid, is made through skin and muscle to expose the tarso-orbital fascia. From near either extremity of this incision a vertical incision (Fig. 362) is carried downward to a point 2 or 3 mm. below the upper border of the tarsus, where the one incision is continued in a horizontal direction to terminate near the tear-point, and the other one horizontally outward to terminate near the external canthus. The rectangular flap thus mapped out is dissected up from above downward, so as to expose the upper tarsal border. Next a transverse incision, slightly convex upward and about 2 cm. in length, is made just above the eyebrow. This incision is carried through all the tissues down to the periosteum. The cutaneous bridge between the two horizontal incisions above and below the brow is undermined, and the rectangular skin-flap is pushed under this bridge upward and attached by sutures to the upper edge of the upper incision. In order that the traction of these sutures shall not pro-

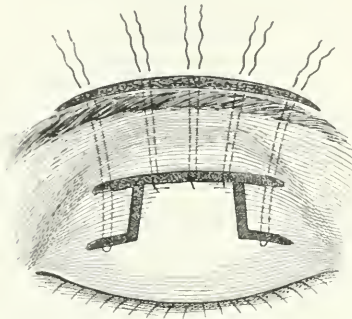


FIG. 362.—Panas's operation for ptosis.

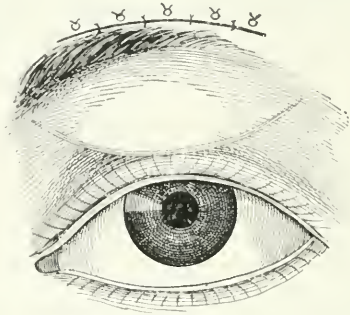


FIG. 363.—Panas's operation concluded.

duce ectropion, an additional suture is applied at each side. These lateral sutures are passed through the tarso-orbital fascia and conjunctiva near the upper tarsal border, but do not include the skin, and carried under the skin upward to emerge from the upper margin of the frontal incision. The wound is dressed with antiseptic dressing, and the sutures are removed after four or five days.

The effect of the operation depends on the length of the rectangular flap. If it is too long, the elevation of the lid will be insufficient; if too short, a marked degree of lagophthalmos is produced.

*Wilder's Operation* (Fig. 364).—Dr. W. H. Wilder of Chicago has in a

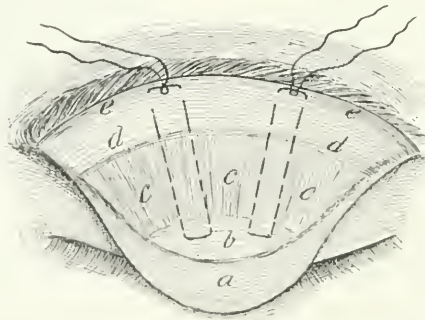


FIG. 364.—Wilder's operation for ptosis: *a*, lower lip of wound drawn down, exposing *b* tarsus and (*c*) tarso-orbital fascia, in which gathering stitches are placed; *d*, orbital margin; *e*, upper lip of wound, into the deep parts of which sutures are finally passed

number of cases relieved the ptosis by folding upon itself the tarso-orbital fascia ("the suspensory ligament of the upper lid") and by establishing a firm adhesion between the fascia and frontalis muscle:

An incision  $1\frac{1}{2}$  inches in length is made a little above and parallel with the orbital margin through all the tissues down to the periosteum, and should be so placed that the resulting scar will be concealed by the eyebrow. Retractors being used to draw down the lower lip of the wound, the skin and orbicularis muscle are separated from the fascia by careful dissection until the tarsus is brought into view. Two fine sutures of sterilized catgut or silk, armed at each end with a curved needle, are then passed in the following manner: the needle is introduced deep enough into the tarsus to secure a firm hold at a point about at the junction of the outer and middle third and a little distance from its upper edge. It is then drawn through, and several gathering stitches are taken upward in the tarso-orbital fascia, after which the needle is made to pass through the muscle and connective tissue of the upper lip of the wound. The other needle on the same suture traverses a parallel course in the same manner, entering the tarsus about 3 mm. from the point of entrance of the first, and emerging in the tissue above, thus making a loop by which the lid may be drawn up. The second suture is passed in the same way, making a loop at the junction of the middle and inner thirds of the tarsus. The requisite elevation of the lid may be now secured by drawing on the loops and tying the sutures, after which the ends may be cut off. The lower lip of the wound is now replaced and united to the upper with fine sutures. The slight scar that remains after healing is almost entirely hidden when the eyebrow grows again. As the buried sutures become capsulated additional strength is given to the bands that hold up the lid.

The various operations aiming at increasing the effect of the frontalis muscle by subcutaneous ligatures are unreliable and uncertain in their effect, like all operations done in the dark. But the excision of an oval piece of skin should never be practised for this purpose, because it produces a hideous lagophthalmos.

If the action of the levator muscle is not entirely lost, the principles of tendon advancement and tendon resection as practised in squint operations may be employed, and are made the basis of the methods of Eversbusch, Snellen, and Wolff.

In *Eversbusch's operation* the advancement is produced by folding the tendon upon itself, like the advancement of Tenon's capsule.

Midway between the lid-margin and the eyebrow a horizontal incision is made through all the tissues down to the fascia. The edges of the wound are dissected up to expose well the tendon, which there is blended with the tarso-orbital fascia. Four mm. above the upper border of the tarsus a small vertical fold of the center of the tendon is then taken up in the loop of a double-armed thread, and both needles are passed vertically downward between the tarsus and orbicularis, brought out at the lid-margin 2 mm. from each other, and tied over a small bit of rubber tubing. A similar suture is passed through the nasal and temporal portions of the tendon respectively; the skin-wound is closed by sutures before the tendon-sutures are tied.

*Snellen's operation*<sup>1</sup> is a tendon resection.

The upper border of the tarsus is exposed by a transverse incision and the orbicularis fibers are pushed upward and downward. The exposed fascia is then incised at some distance above the tarsal border, and three or four needles are thrust through the tendon and passed from above downward to emerge again through the upper border of the tarsus. But before the needles are drawn out the piece of tendon between the tarsal border and the point of entrance of the needles is excised. Then the needles are drawn through and the threads tied.

*Wolff's operation*<sup>2</sup> combines tendon resection with tendon advancement, and is a decided improvement over Snellen's method.

The surgeon makes an incision through all the tissues along the upper border of the tarsus, and, lifting up in a vertical fold the central portion of the tendon expansion on the anterior surface of the tarsus, he cuts at each side a vertical buttonhole, through

<sup>1</sup> Report of the German Ophthalmol. Society, at Heidelberg, 1883.

<sup>2</sup> *Ibid.*, 1896.

which two strabismus-hooks are slipped under the tendon, so that the one hook is placed close to the insertion and the other hook so far above it that the distance between

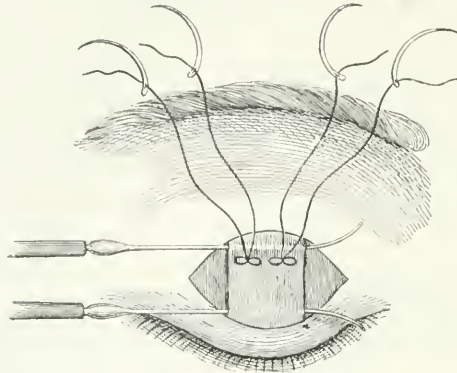


FIG. 365.—Wolff's operation.

the two hooks represents the piece of tendon to be resected. Two double-armed catgut sutures being put through the tendon just below the upper hook, the tendon is cut transversely below the sutures. Both ends of each suture are then carried behind the tendon-stump and passed through the line of insertion, tied, and cut short; the skin-wound is closed over them by silk sutures.

The success of the operation depends upon the accurate dosage of the tendon-resection; the resected piece should measure exactly as many millimeters as the vertical diameter of the palpebral aperture of the affected eye is smaller than that of the normal eye.

**Operation of Ptosis Adiposa or Atonica.**—In this affection the lid shows neither any superabundance of adipose tissue nor any imperfect action of the levator muscle; but the skin has lost its connection with the aponeurosis and the upper border of the tarsus, and therefore is not drawn back with the tarsus when the lid is opened, but falls down over the lid-border like a heavy curtain (Fig. 366). To relieve the deformity by cutting away this skin-curtain would be a grave mistake, because it would leave the skin so short that the lid could not be closed. But

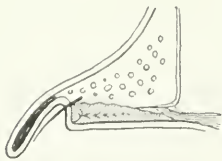


FIG. 366.—Operation for ptosis adiposa.

the deformity can be perfectly relieved by reattaching the skin to the upper border of the tarsus by means of the sutures employed in the author's operation for entropion (see page 549).

# OPERATIONS UPON THE CONJUNCTIVA, CORNEA, AND SCLERA; ENUCLEATION AND EVISCERATION.

By CHARLES W. KOLLOCK, M. D.,

OF CHARLESTON, S. C.

THE conjunctiva, being a highly vascular membrane, heals rapidly after injury, and so loosely is it attached to the eyeball that an extensive loss may be replaced by dissecting it from the ball in the vicinity of a wound and drawing the flaps together by sutures. No evil effects are produced by this procedure, and in many cases no visible cicatrix remains. With the conjunctiva of the lids, however, less liberty can be taken, for a loss of the covering in this part may result in entropion, or perhaps a narrowing of the palpebral fissure. Large wounds of the conjunctiva, after thorough cleansing, should be closed by sutures, and require but little after-treatment beyond cleanliness and protection by closing the lid.

**Foreign bodies** that pass through the conjunctiva are often difficult to remove on account of their entanglement in its meshes, and when a sharp instrument is used in the attempt to remove them *subconjunctival hemorrhage* generally occurs and obscures the field of operation. This is especially the case with grains of powder. The easiest method of dealing with such cases is to seize the body with forceps through the conjunctiva and snip off the entangling part, which causes but a small loss of tissue, and the wound heals without leaving a scar. Grains of powder may be removed in this way when not too numerous; otherwise by *electrolysis*, as advised by E. Jackson (see also page 368).

**Operations for Pterygium.**—The instruments used in these operations are a stop-speculum, fixation- and dissecting-forceps, sharp-pointed knife, small scissors, strabismus-hook or probe, needles, needle-holder, sutures, etc.

*Operation.*—The anesthesia produced by cocain is sufficient for this operation, which is performed as follows: (1) Thorough removal of the corneal portion of the growth may be accomplished by shaving or dissecting it away with a sharp knife, and then scraping (Deschamps) off the remnants carefully, or by destroying them with the thermo-cautery or by the application of pure carbolic acid (Alt). The method advised by Prince is also effective, and consists in grasping the growth with forceps near the corneal attachment, and by a series of slight jerks its roots or prolongations are withdrawn from beneath Bowman's membrane and even from between the corneal layers. No opacity remains when this is carefully done, nor does the cornea become inflamed. Next to division, the method of scraping the remnants from the cornea with a knife is preferable to the use of the cautery, as it is difficult to limit the action of the latter agent.

The next step is the disposition of the body of the growth. It may be separated at its borders from the conjunctiva proper as far back as the caruncle, and then *excised*; or it may be *transplanted* beneath the conjunctiva, loosened for this purpose either above or below, and fixed in its new position by a suture passing through the growth and its conjunctiva; or it may be split from apex to base, and one-half transplanted above and the other below the opening, as advised by Knapp.

Others (Boeckmann, Hotz) advise unfolding and spreading out the growth after separating it from the cornea, first removing all subconjunctival tissue; which is a most important step in any procedure. Boeckmann fastens the reposed conjunctiva (pterygium) to the head of the internal rectus muscle by a suture, and leaves the small tri-



angular and denuded space near the cornea to heal by cicatrization, which, he contends, will prove an effectual barrier to a future growth. Hotz, after reposition, covers the

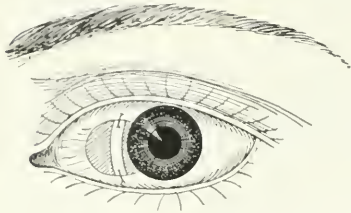


FIG. 367.—Showing position of graft, narrower than wound, but long enough to reach across it.

denuded spot with a graft taken, after the method of Thiersch, from the inner surface of the forearm or from behind the ear. This graft is cut slightly smaller than the area to be covered, and is placed in position with or without sutures according to circumstances.

Hobbs and others advise removal by means of the *electro-cautery*. The growth is grasped by forceps near the cornea and lifted from the sclera; a curved needle or probe is passed beneath it, and then the neck is burned through with the cautery-tip at a cherry-red heat. The subconjunctival tissue is drawn out and excised, and the corneal end is scraped away or touched

by the cautery. A cross-stitch unites the conjunctiva near the cornea.

In all cases of removal or transplantation of the growth the conjunctiva should be loosened above and below and the edges closely united by sutures.

*Dressing.*—After thorough cleansing with warm bichlorid or boric-acid solution the eye is closed with sterilized gauze and cotton, which are held in place by any form of light bandage or by adhesive strips. The dressing may be renewed every day, and sutures should remain as long as they do not irritate, which is usually four to five days. When removing sutures it is advantageous to have the eye under the influence of cocain, for a sudden movement may cause the edges of the wound to separate. The simple introduction of the speculum may also cause this accident, so that whenever possible it is safer to have the lids held apart by the fingers of an assistant or even by the patient if he is not too nervous. After the removal of the sutures the dressing may be left off, and the eye, which is often quite sensitive, protected by tinted glasses.

**Complications** are rare after this operation. Ulceration of the cornea has occurred, and should be treated by the usual methods. Occasionally a small growth of granulation-material springs from the wound, but it is easily snipped off with scissors or it may be contracted by astringent solutions. When the growth has extended well over the cornea a hazy spot is apt to remain after its removal. Pterygium often returns, and may, under ordinary circumstances, be again removed.

**Symblepharon.**—Instruments necessary for the operation are—stop-

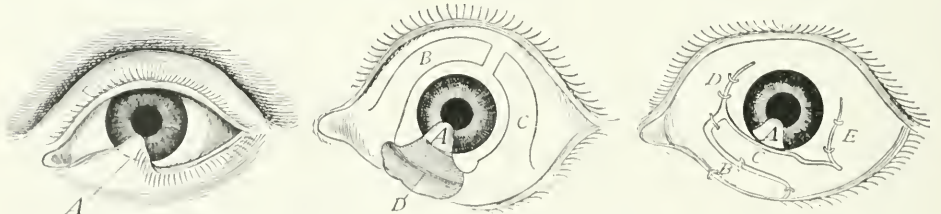


FIG. 368.—Teale's operation for symblepharon.

speculum, vulcanite spatula, fixation- and dissecting-forceps, probe, scissors, sutures, needles, needle-holder, etc.

For the simpler operations cocain may be used, but when the adhesions are extensive ether or chloroform is more satisfactory.

*Operations.*—The slight forms of symblepharon known as *symblepharon anterius* are easily cured by separating the attachment and preventing its recurrence by the frequent passage of a probe between the points. Pooley and Scarles each report a case in which the formation of symblepharon was prevented by using a glass or rubber shield which fitted over the globe between the lids, and which was left in place, except during short intervals for cleansing, until healing took place.

There are several methods of operating when adhesions are extensive and involve the fornix (*symblepharon posterius*). *Symblepharon* is often incurable.

(1) The lid is separated from the ball and the dissection is carried well back to the fornix (Arlt). A suture armed with two needles is passed through the separated end; the needles are then passed from the bottom of the cul-de-sac through the lid to the cheek. Tightening the suture draws the flap down and brings the conjunctival surface next to the raw surface of the ball. The ends of the suture are tied over a piece of cork or drainage-tube.

(2) *Teale's Operation*.—Sliding flaps from the adjacent conjunctiva are brought over the denuded portions and sutured in position (Noyes and Teale). The operation is readily comprehended by attention to the accompanying illustrations (Fig. 368).

(3) Riverdin covers denuded surfaces with small pieces of mucous membrane taken from the mouth.

(4) Harlan has devised the following operation where there is extensive adhesion to the lower lid: The adhesion is freely dissected until the upward movement of the ball is entirely unimpaired, and an external incision, represented at *AB* in the accompanying cut, along the margin of the orbit is carried through the whole thickness of the lid, which is thus separated from its connections except at the extremity. A thin flap, *CD*, is then formed from the skin below the lid, care being taken to leave it attached at its base-line by the tissue just beneath *AB*, as well as at the extremities. On this attachment it is turned upward as on a hinge, bringing its raw surface in contact with the inner surface of the lid, and its sound surface presenting toward the ball, and held in this position by suturing its edge to the margin of the lid. In dissecting up the flap the incisions are carried more deeply into the orbicularis muscle when the base-line *AB* is nearly reached, to enable it to turn more readily. The bare space left by the removal of the strip of skin is nearly covered without strain by making a small horizontal incision, *DE*, at its outer extremity and forming a sliding flap (Fig. 369).

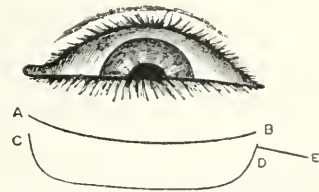


FIG. 369.—Lines of incision in Harlan's operation for symblepharon.

(5) For very extensive adhesions an opening may be made below the attachment and a piece of lead wire inserted, which is left until a fistulous opening is formed, when one of the above operations may be performed (Himly).

(6) Large raw surfaces from extensive adhesions may also be covered by skin-grafts after Thiersch's method (Hotz).

*Dressings*.—After minor operations it is sufficient to bandage the eye, and it should be kept closed until the sutures are removed. After transplantations the eye should not be disturbed for three or four days, unless there are signs of irritation, and both eyes should be bandaged.

Complications are due to the failure of grafts to unite and to renewal of adhesions.

*Symblepharon posterius* due to trachoma is scarcely amenable to surgical treatment.

**Transplantation of Rabbit's Conjunctiva.**—Wolfe first suggested this mode of dealing with extensive adhesions between the lid and eyeball, and several operators have performed the operation with beneficial and even surprising results. General anesthesia is necessary, as the operation is tedious.

The eye and appendages are cleansed and the adhesions are divided. Bleeding is controlled by pledgets of absorbent cotton saturated with hot water and placed in the cul-de-sac. Two rabbits are anesthetized, in case any accident should happen to one. The size of the graft having been calculated, four sutures are introduced at its corners before it is separated, because after removal it rolls upon itself and it is rather difficult to recognize the proper surface. The graft having been separated, it is rapidly transferred to the denuded area and carefully stitched in position.

Ankyloblepharon is readily relieved when the edges of the lids only are united, but when the adhesions involve the ball also, treatment is of little avail.

**Operations for Trachoma.**—*Expression* of trachomatous bodies is

performed in various ways by different surgeons and according to the gravity and duration of the case. The roller-forceps devised by Knapp (Fig. 370)

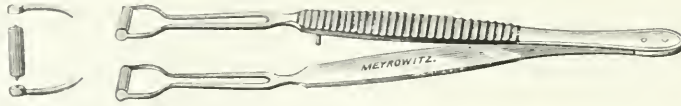


FIG. 370.—Knapp's roller-forceps.

and the modifications of this instrument have aided very much in the thorough performance of this operation.

Where follicles are discrete, as in follicular disease, they are easily expressed between the thumb-nails, or preferably by dissecting-forceps.

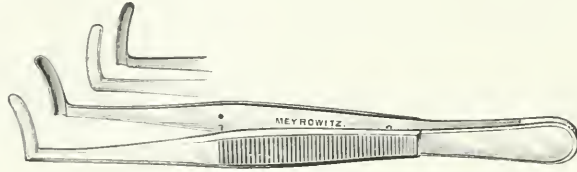


FIG. 371.—Noyes's trachoma-forceps.

General anesthesia is desirable for the surgical treatment of trachoma, though there are those who prefer to operate under the influence of cocaine.

*Operation of Expression.*—The lid is grasped with forceps near the ciliary border and rolled upon itself until the conjunctival surface is well exposed. The roller-forceps are then used as follows: one blade is pushed well up into the retrotarsal folds while the other is placed near the ciliary edge. The morbid material in the conjunctiva is then thoroughly expressed by a milking process, each portion being subjected to the squeezing. The retrotarsal folds may be treated separately by still further everting the lid and drawing them out. When the conjunctiva near the edge of the lid is to be expressed, one blade should be placed upon the cutaneous surface. The surgeon should wear protecting glasses, as the expressed material often flies out suddenly and to a considerable distance.

*After-treatment.*—After careful cleansing with warm bichlorid solution iced compresses are applied to the lids for several hours to prevent pain and swelling. The conjunctiva is not as much mutilated as might be expected by this rough handling, and but little reaction follows. Adhesions are very apt to form, and should be broken down by the daily passage of a probe through the cul-de-sac. The subsequent treatment of the case requires the application of a solution of nitrate of silver (gr. v- $\frac{1}{3}$ j), and later that of a crystal of sulphate of copper.

George Lindsay Johnson has described the following operation for trachoma:

The lid is everted over a vulcanite spatula and held tense in this position by a double hook inserted near its edge. With a tri-bladed scalpel the conjunctiva is incised parallel to the free border of the lid from end to end. The instrument is then moved



FIG. 372.—Three-bladed scissor.

so that the last blade shall pass through the foremost cut, and so on until the entire surface has been incised. The thicker the lid the deeper the cuts, and *vice versa*. Bleeding is controlled by cotton compresses saturated with hot water. An *electrolizer*, connected with a Stöhrer's battery of twenty cells and having two platinum blades, is next used. The blades pass through the incisions made by the scalpel. About thirty milli-



ampères are used, and a thick foamy cream at once arises about the blades. Strong currents should be avoided. The lids are then washed, sprinkled with a 5 per cent. solution of cocaine, dusted with calomel, and smeared with an ointment of hydronaphthol and vaselin, 1 to 800. Inflammation and swelling are controlled by iced compresses. There is considerable discharge and sloughing for forty-eight hours. Care should be taken not to injure the cornea.

The after-treatment consists in using boric-acid wash and the ointment of betanaphthol and vaselin. No entropion or ectropion has resulted.

*Grattage* is an operation recommended for trachoma by Abadie, Darier, and other French surgeons. As the operation is necessarily quite painful, ether or chloroform should be used.

The lid is everted and held by forceps (Fig. 373), as in the operation for expression, and the conjunctiva is freely incised from the ciliary border to the fornix, and from end to end of the lid, by the tri-bladed scarificator (Fig. 372) or a similar instrument. The

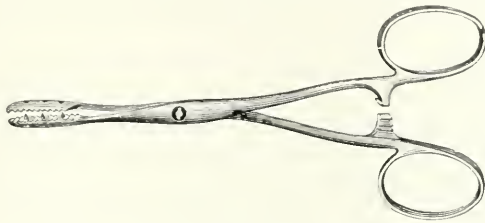


FIG. 373.—Forceps for grattage.

incised surface is next thoroughly scrubbed with a nail-brush that has been saturated in a strong solution (1 : 500) of bichlorid of mercury. By this proceeding all trachomatous material is washed out, and the lids are then treated by cold applications, as described on page 564. The same care must be exercised to prevent the formation of adhesions.

*Excision of the Cul-de-sac.*—This method of treatment is very old, but Galezowski in 1874 brought it again prominently before the profession. Stephenson also advocates its performance in certain cases, and reports a number of successful operations. The operation advised by him is as follows :

The lid is everted, and two moderately strong sutures are passed through the extremities of the fold. The sutures are held by an assistant, who by their manipulation keeps the parts "on the stretch." An incision is now made along the attachment of the fornix to the tarsal conjunctiva with blunt-pointed scissors, but should never go beyond the anterior layer of the fold. This layer is freed from its attachments, and the dissection into the subconjunctival layer is carried as far back as is deemed necessary. The operation is completed by cutting transversely through the posterior layer of the cul-de-sac, which comes away with the sutures. Bleeding is often profuse, but may be arrested by twisting the vessels. Sutures are never employed to close the wound. The eye is cleansed and closed, and is not inspected for five or six days, unless complications arise.

**Complications** are of two kinds—viz. wound-granulations and ptosis. The former should be snipped off with scissors. The latter may be due to the swelling of the lid which naturally follows, and will soon disappear, or to interference with the tarsal insertion of the levator palpebrae muscle. Stephenson always excises the upper cul-de-sac, as it is more difficult to reach for treatment than the lower, and never advocates the operation for cases that can be cured by other means.

**Choice of an Operation.**—Expression is especially valuable in cases of spawn-like granulations and diffuse hyaline infiltration. It may be used in cicatricial trachoma with patches of hyaline infiltration. Grattage may be employed in cicatricial trachoma and in cases characterized by sclerotic masses of trachomatous tissue. It is inferior to expression preceded by scarification. The indications for excision of the cul-de-sac have been given.



Peritomy, or syndectomy, is performed for getting rid of a thick pannus. A narrow strip of conjunctiva 2 to 4 mm. in width is removed from around the cornea, and all vessels going to the cornea are divided.

Kenneth Scott proposes a substitute for peritomy, as he believes the latter operation is rarely a success, in cases of vascular cornea. By the aid of a magnifying-glass he is enabled to divide with a Graefe knife every vessel passing to the cornea. He slits them throughout their entire length, which destroys the vessel and further anastomosis is prevented.

**Subconjunctival Injections of Germicides.**—After thorough conjunctival antiseptics and anesthesia have been secured, a fold of conjunctiva is seized with a pair of forceps about 8 mm. from the corneal margin, and the point of a hypodermic or Pravaz syringe charged with the germicide is introduced, very much in the same manner as when an ordinary hypodermic injection is given, and 2 to 4 minims of the fluid are injected. The strength of the solution varies with different operators. Of bichlorid 1 : 2000 or 1 : 4000 may be employed. Trichlorid of iodin and cyanuret of mercury may be used in the same way.

Precisely the same results follow similar injections of physiologic salt solution, and it is probable that all of these injections act by stimulating the lymph-channels, and therefore promoting absorption. They act favorably at times in iritis, irido-cyclitis, scleritis, and corneal ulceration. They have also been recommended in diseases of the retina and optic nerve, but the author doubts their value under these circumstances.

#### OPERATIONS UPON THE CORNEA.

**Foreign Bodies in the Cornea.**—Small particles of dust, cinders, iron, steel, emery, stone, etc. frequently adhere to or become partially or wholly imbedded in the cornea.

When simply adherent to the corneal surface or but slightly imbedded the foreign body is easily wiped off with a wisp of cotton or scraped away by a sharpened match-stick or *clean* wooden toothpick. Such means are preferable to steel instruments in these cases, as they are less liable to injure the cornea. When the body is more firmly fixed, however, it is necessary to use the ordinary steel spud or cataract needle (Fig.




FIG. 374.—Spud.




FIG. 375.—Angular lance-knife.



FIG. 376.—Lance-knife.

374). Bodies which have sunk below the surface are by no means easy to extract, for a slight pressure suffices to force them into the interior chamber.




FIG. 377.—Johnson's magnet for removing foreign bodies from cornea.

When, therefore, such a condition exists, a small lance-knife (Figs. 375, 376) should be entered beneath the body to prevent its going nearer the chamber. It is then cut down

upon and grasped by forceps or pushed from its position with a small probe or spud. W. B. Johnson has devised a magnet for such cases. Cocain anesthesia is sufficient.

**After-treatment.**—Especial care should be taken in the after-treatment of these corneal wounds, for it not infrequently happens that poisonous germs are introduced and infectious ulcers follow, causing abscess and loss of vision from resulting leukoma or loss of the entire eye from panophthalmitis. After removal of the body the wound and eye should be carefully cleansed with an aseptic solution, atropin instilled, and the eye closed by a bandage to prevent reinfection from the air; all instruments should be carefully sterilized.

**Removal of Gunpowder Grains from the Cornea.**—E. Jackson treats these cases by the galvano-cautery, as follows:

A small cautery-tip, such as is used for cauterizing corneal ulcers, is brought to a white heat and the imbedded powder-grains are touched in rapid succession, sufficient time being allowed for destroying tissue. The resulting scars are not worse in appearance than the stains. When possible the operation should be done early and before diffusion of the carbon takes place (see page 368).

**Paracentesis of the Cornea.**—The instruments required for this operation are a stop-speculum or elevator, fixation-forceps, paracentesis-needle, and a small spatula.

**Operation.**—The anesthesia of cocain is sufficient, except with children, for whom ether, chloroform, or bromid of ethyl should be used. The eye is fixed by grasping the conjunctiva with the forceps as near the point to be opened as is possible, because by this means the eye can be held more firmly, the opening made gradually, and a sudden evacuation of the aqueous humor prevented. The needle is entered within the



FIG. 378.—Paracentesis-needle.

corneo-scleral border at right angles to the surface, and as the blade is pushed onward the handle is slightly depressed in order to avoid wounding the iris and lens-capsule. Next the needle is gently withdrawn, allowing at the same time a gradual escape of the aqueous, so that the iris shall not be swept into or against the wound. Careful cleansing, the instillation of atropin or eserin, as the case may be, and a light bandage, which should be worn two or three days, generally comprise all measures needful in the way of treatment. The operation may be repeated when necessary.

**Complications.**—Prolapse of the iris into the wound may occur, and when it cannot be replaced with the spatula, it should be excised, unless the prolapse is very small or the iris rests against, rather than falls into, the incision.

**Curetting the Cornea.**—A small curette or spud may be used for this operation, which is done for indolent or spreading ulcers.

By the aid of a curette the necrosed tissue is carefully scraped from the sides and bottom of the ulcer, after which the ordinary treatment for corneal ulceration is followed. De Wecker and Santarnecchi (Cairo) advise what is called "*hydraulic curetting*" as a substitute for the ordinary methods and the use of the cautery. A syringe having a small nozzle is filled with a solution of bichlorid of mercury (1:1000), which is then thrown in a steady stream upon the ulcer and gradually washes away the necrosed tissue. Santarnecchi claims that it is more thorough and less dangerous than ordinary curetting and the use of the cautery, as injury to the sound tissues is much less likely to occur.

**Application of the Actual Cautery.**—For this purpose a platinum-tipped probe of the galvano-cautery may be used.

The point, having been brought to a red heat, is lightly applied to the floor and sides of the ulcer, care being taken not to perforate the anterior chamber. The area to be cauterized is colored green by dropping upon it a solution of fluorescin (see page 145).

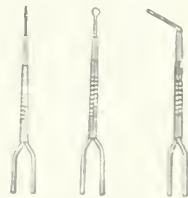

FIG. 379.—Galvano-cautery points.

The **after-treatment** consists in the use of atropin and mild aseptic washes, such as boric acid and salt. The application of a bandage depends upon the quantity of the discharge.

**Saemisch's Section.**—The instruments necessary are a stop-speculum, fixation-forceps, v. Graefe knife, spatula, and perhaps a small syringe.

*Operation.*—The pupil should be dilated as much as possible, and if the patient is a child general anesthesia is necessary. The eye is steadied by grasping the conjunctiva with the forceps while the knife is entered, edge out, in the healthy tissue near the ulcer. The point is passed through the anterior chamber and emerges at a corresponding spot beyond the ulcer, when the intervening corneal tissue is cut through, allowing the pus and aqueous humor to escape.

Sometimes the pus is caught between the lips of the wound, but is easily removed with a spatula or iris-forceps, or by washing out the chamber with any specially devised syringe charged with normal salt solution. The iris should be replaced as well as possible, but synechie are likely to result.

The **after-treatment** consists in cleanliness, the instillation of atropin, and the application of a bandage until the cornea has healed. The operation may be repeated as often as the pus re-forms.

**Complications** are synechie and the resulting leukoma, which latter is due to the ulceration rather than the incision. Panophthalmitis and entire destruction of the cornea may result if the ulceration is not checked.

**Conical Cornea; Staphyloma Pellucidum.**—There are various operations for this deformity, all of which have for their object the removal of the cone. Von Graefe shaved off the apex of the cone and applied the solid nitrate-of-silver stick to the wound, which, as it healed, caused contraction and diminution of the cone. Bowman accomplished the same result by means of a trepan, and Knapp has devised a special point for the galvanocautery, with which the cone is cauterized as deep as Descemet's membrane, avoiding, if possible, entrance into the anterior chamber (Fig. 380).



FIG. 380.—Knapp's cautery-point for conical cornea.



FIG. 381.—Tattooing-needle.

After healing, an iridectomy is usually necessary. The sear left by the cautery may be tattooed—a procedure which not only improves the appearance of the eye, but also the vision, by excluding unnecessary light. It may be necessary to repeat the operation, which is preferable to running the risk of destroying the eye by attempting too much at first.

**Tattooing the Cornea.**—The instruments required are a stop-speculum, fixation-forceps, and tattooing-needle (Fig. 381).

*Operation.*—Thorough anesthesia of the cornea is essential in order that the ink may be driven well into its layers. The India ink should be of the consistency of paste and plentifully applied to the leukoma, as it soon fades when thinner. The pigment is then pricked into the cornea over the area to be covered, after which the excess is washed away by a boric-acid solution. Atropin is next instilled and a light bandage is applied. The reaction subsides within a few days, and the operation may be repeated, if necessary, after all inflammation has disappeared. Different colored inks may be used to match the varying colors of the irides. Tattooing is also useful for covering colobomata which admit too much light to the eye.

**Wounds of the Cornea.**—Incised wounds usually heal without trouble, it being simply necessary to cleanse the eye carefully, to bring the lips of the wound accurately together, to replace the iris if it has fallen into the wound, and to apply a bandage. Eserin or atropin may be used accord-

ing to the position of the wound. If the prolapse continues and cannot be replaced, it should be excised. Large gaping wounds, whether incised or lacerated, may be closed with sutures, which should be composed of very fine silk.

De Wecker has advised the following method for closing and protecting large wounds of the cornea: The conjunctiva is dissected from the corneal limbus and beyond the attachments of the recti muscles. A suture is then passed in and out near its edge, which, when tightened like a string at the mouth of a bag, draws the conjunctiva over and entirely covers the cornea. It should remain until the cornea has healed, when it may be dissected loose. Adhesions do not take place, except, perhaps, in the line of the wound, and these are readily freed.

**Von Hippel's Operation for Transplanting the Cornea.**—In cases of central leukoma von Hippel has transplanted a graft from the cornea of a rabbit, but the results have not been very satisfactory, because the transplanted cornea has also finally become opaque. He restricted the operation to those cases where the entire corneal thickness was not involved—in other words, where the leukoma was not totally adherent.

*Operation.*—A general anesthetic should be used for patient and rabbit. The eye having been prepared, the trepan is gauged so that it shall not enter the anterior chamber. It is placed accurately over the center of the cornea, and by touching the spring the cut is quickly made. The plug is lifted out by the aid of special forceps and cut off with a Graefe knife. In a like manner the plug is cut from the rabbit's eye and quickly transferred to the patient's. After cleansing, both eyes should be bandaged and the patient kept quiet in bed for a few days.

**Complications** may be ulceration of the cornea and general infection of the eye.

**Operations for Closing Scleral Wounds.**—Wounds of the sclera are common near the corneal border, over the ciliary body, and on the upper surface of the ball. Owing to the frequent involvement of the ciliary body, extreme care must be exercised in their management.

Small punctured wounds require no special care beyond the usual antiseptic precautions; but if exposed, they should be covered with the conjunctiva. Small incised and lacerated wounds, when inclined to gape or when their edges are separated by a bead of vitreous humor, should be closed, after the prolapsed vitreous has been excised, with small animal sutures introduced through the outer layers in order to avoid wounding the inner coats of the eye. The conjunctiva is to be sutured over the scleral wound with animal or silk sutures. Large scleral wounds may at times be approximated simply by closing the conjunctiva over them, but it is probably safer to suture the sclera to avoid the danger of staphyloma. Care must be taken that the ciliary body and choroid are not imprisoned in the wound. The subsequent treatment requires cleanliness and bandaging until healing is complete.

**Complications** arise from injuries to the ciliary body, choroid, and retina, which may cause sympathetic ophthalmia and separation of the retina. Prolapse of the vitreous interferes with healing.

**Sclerotomy.**—The instruments for this operation are a stop-speculum, fixation-forceps, Graefe knife, and spatula.

*Operation.*—A Graefe knife is entered in the sclera about 1 mm. from the cornea, and, passing through the anterior chamber, emerges at a corresponding point on the opposite side. The cut is made upward by a to-and-fro motion, as in the operation for removing cataract, until a narrow bridge is left connecting the sclera with the cornea. The knife is then withdrawn carefully to prevent, if possible, the prolapse of the iris, which is apt to occur, and which should then be excised (Fig. 382).



This operation is not as effective as iridectomy, and Fuchs says should only be performed under the following conditions: 1. Glaucoma simplex, with a deep anterior chamber and without distinct elevation of tension. 2. Inflammatory glaucoma, when the iris through atrophy has become so narrow that one cannot hope to perform excision of the iris that would be according to rule. 3. Hemorrhagic glaucoma. 4. Hydrophthalmos. 5. Instead of a second iridectomy in those cases of glaucoma in which the increase of tension returns in spite of an iridectomy performed according to rule (compare with page 578).

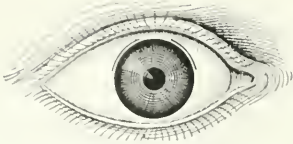


FIG. 382.—Lines of incision in sclerotomy.

*Posterior Sclerotomy.*—The incision should be placed so as not to wound the ocular muscles or endanger the ciliary body, and should, therefore, not approach the cornea nearer than 6 or 7 mm. The cut is made with a Graefe knife from behind forward, so as to correspond with the direction of the scleral fibers. There is probably less danger from infection if the incision in the sclera is not directly under that in the conjunctiva. When it is desired to produce a fistulous opening the incision should be made near the equator, as healing is less likely to take place here than farther forward.

Posterior sclerotomy is indicated in cases where the anterior chamber has been obliterated and iridectomy or anterior sclerotomy cannot be performed, for separation of the retina, for staphyloma, and for those cases in which reduction of tension is indicated and other operations are not available. In cases of corneal staphyloma it may be necessary to repeat the operation a number of times before satisfactory results are obtained.

**Sclerectomy**, as described by H. Parinaud, is for the purpose of obtaining less resistance from the sclera, more efficacious drainage, and the formation of a staphyloma when desired.

*Operation.*—At a point near the equator a curved needle is plunged into the external layers of the sclera, which are then slightly elevated. With a Graefe knife, held parallel to the needle, a flap is cut, at the bottom of which the choroid should be visible. It is advisable not to cut entirely through the sclera, though this may be punctured later if thought necessary.

**Operations for Staphyloma.**—Small staphylomata of recent formation may frequently be cured by pressure from well-applied bandages, which should be kept in place until the cornea has regained its tonicity. When this proves unsuccessful an iridectomy may be performed at or near the point of bulging; after this the eye must be bandaged until healing is complete and the parts are strong.

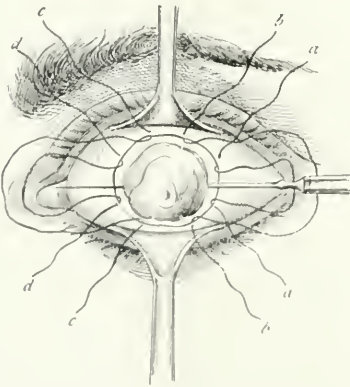


FIG. 383.—De Wecker's operation for staphyloma.

A staphyloma involving the entire cornea is difficult to treat successfully, and many methods of operating have been devised. Probably the most effective is entire excision of the growth; though the safer, but more tedious method, which sometimes succeeds admirably, is by posterior sclerotomy.

For the operation by excision the following instruments are necessary: a stop-speculum, fixation-forceps, Beer's knife, seissors, needles, and sutures. Ether or chloroform should be administered.

De Wecker and Critchett both, after having inserted needles or sutures through the base of the staphyloma to prevent loss of vitreous, excise the staphyloma with the knife and scissors and allow the lens to escape. De Wecker closes the wound by drawing the conjunctiva together over it, while Critchett passes the sutures through the sclera and draws its edges accurately together. The conjunctiva is then closed over the scleral wound. Reference to the figures will make the steps of these operations evident, which are not now much practised, as evisceration with insertion of artificial vitreous is preferable (Figs. 383-385).

**After-treatment.**—The eye is dressed and kept closed for several days unless there are symptoms of inflammation. Healing is slow.

**Complications.**—Wounding the ciliary body may cause sympathetic ophthalmia, and a general infection may be followed by panophthalmitis.

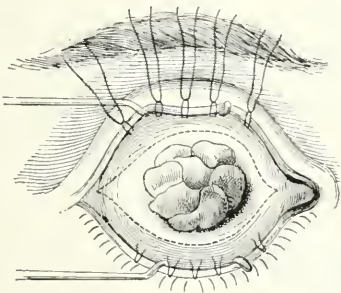


FIG. 384.—Critchett's operation for staphyloma.

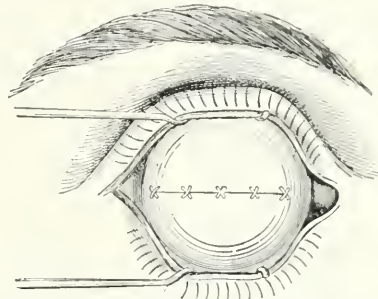


FIG. 385.—Stump after Critchett's operation for staphyloma.

**Enucleation of an Eyeball.**—Most operators prefer general anesthesia for this operation, but there are a few who advise cocaine. J. J. Chisolm

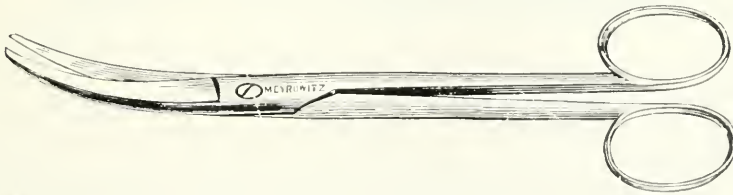


FIG. 386.—Enucleation-scissors.

speaks highly of bromid of ethyl. The instruments required are a stop-speculum, fixation- and dissecting-forceps, strabismus-hook, and enucleation-scissors (Fig. 386).

**Operation—Bonnet's Method.**—The conjunctiva is grasped by the forceps near the cornea, and with the scissors is loosened entirely around the latter and as near to it as possible. The dissection is then carried well back in every direction. The recti muscles are next caught up separately by a strabismus-hook and their tendons divided close to the ball. The scissors are now pressed close to the ball and dissect it from the orbital tissues on every side. The enucleation-scissors are then passed well back into the orbit until the points touch the optic nerve, when they are separated and the nerve is severed as far back as possible. The scissors may be entered from the nasal or temporal side. Care should be taken not to divide the nerve too close to the ball or the sclera may be perforated.

**Vienna Method.**—By this method the operation is much more quickly performed, but there is greater loss of orbital tissue, which prevents the

accurate fitting of an artificial eye. This operation, however, is to be recommended when for any reason a quick manipulation is necessary.

The conjunctiva is opened near the outer or inner margin of the cornea and dissected away over the attachment of the rectus muscle, which is caught up and divided. The scissors are then passed rapidly around the ball, dissecting it from the orbital tissues until the nerve is reached and divided. The arms of the speculum are opened and pressed back to force the ball from the socket. The conjunctiva, muscles, and orbital tissues are then easily divided by rotating the ball. If hemorrhage is profuse after enucleation, it should be checked at once by hot water to prevent the orbital tissues from becoming infiltrated. The hot water is best applied by saturating balls of absorbent cotton and forcing them into the orbit. Some operators suture the edges of the conjunctiva, though this is unnecessary.

After bleeding has ceased the orbit should be flooded with hot bichlorid solution (1 : 5000). A piece of sterilized gauze is placed next to the lids, upon this a good-sized pad of absorbent cotton (sterilized), and over these a roller bandage is tightly applied, care being taken to make the turns from below upward, so that the compress shall be forced into the orbit.

**After-treatment.**—When possible the dressing should be changed a few hours after its application, as it adds much to the comfort of the patient. The eye should be dressed every day, and the orbit thoroughly flooded with warm bichlorid solution. Rest in bed for two or three days after the operation is a safe plan to follow, though many surgeons do not require it. After three or four days the roller bandage may be replaced by a lighter form.

**Complications.**—Secondary hemorrhage rarely occurs, and may be controlled by applying hot water and tightening the bandage. Cellulitis, meningitis, acute mania, and tetanus have followed enucleation. In cases of cellulitis and meningitis deep incisions should be carried to the back of the orbit, hot applications should be made to the lids, and a free evacuation from the bowels should be encouraged.

**Exenteration or Evisceration.**—This operation should under no circumstances be performed upon an eye that may be capable of causing sympathetic ophthalmitis, and is therefore applicable to but a few cases.<sup>1</sup>



FIG. 387.—Scoop for evisceration.

The instruments required are a stop-speculum, fixation-forceps, Beer's knife, small scissors, curette or scoop, sutures, etc.

**Operation.**—The conjunctiva having been dissected to the equator of the eyeball, the cornea is excised by passing a Beer's knife through the corneo-scleral junction from side to side and cutting up above, then reversing the knife and cutting down, or after the first incision with the knife the remaining flap is removed with the scissors. The contents of the globe are evacuated and the inner coats scraped away with scoop or curette. Hemorrhage is controlled by hot water and the cavity cleansed with hot bichlorid solution (1 : 2000 or 3000). It is very essential that every portion of the contents should be thoroughly removed and hemorrhage completely controlled, for under these conditions healing, which is necessarily slow, progresses more favorably. Prince advises cauterizing the scleral cavity with 95 per cent. carbolic acid to relieve pain and to hasten healing. The edges of the sclera are approximated accurately with catgut sutures, and the conjunctiva is closed with silk sutures.

*Dressings* and the *after-treatment* are the same as for enucleation, but the period of recovery is more protracted.

**Evisceration of the Eyeball, with Insertion of an Artificial Vitreous (Mules's Operation).**—Mr. Mules has modified the operation of

<sup>1</sup> In the opinion of the Editor, the sphere of evisceration is by no means so limited, although if in a case of sympathetic ophthalmitis or irritation already developed it was decided to remove the exciting eye, he would perform enucleation.



evisceration by the introduction of a glass ball into the cavity of the sclera. In general terms the operation is performed in the same manner as an ordinary evisceration, but certain special precautions require to be noted.

The conjunctiva having been dissected from the corneo-scleral attachment in all directions to the equator of the eyeball without disturbing the muscles, evisceration is performed, after abscission of the cornea, in the ordinary manner. A perfectly clean white scleral cavity must be secured, and hemorrhage absolutely controlled by packing the cavity with sterilized gauze saturated with a hot solution of bichlorid of mercury, 1:2000, and by frequently irrigating it with a tepid solution of the same drug. Sometimes the hemorrhage is more readily controlled with repeated dry packings of sterilized gauze than with hot solutions. A glass sphere (Fig. 389), of such size that it may be introduced within the scleral cup without difficulty, is selected, its introduction being facilitated by slitting the sclera vertically for about  $\frac{1}{4}$  mm. at the upper and lower corneo-scleral margins. The introduction of the sphere is further facilitated by the use of an instrument specially devised for this purpose (Fig. 388). The concluding steps of the operation consist in stitching the sclera vertically, the conjunctiva horizontally, dusting iodoform within the socket, and applying a full antiseptic dressing. Indeed, the greatest care should be exercised to secure absolute antisepsis during the operation and at the subsequent dressings.

**After-treatment.**—The patient should be confined to bed for at least three days, and both eyes should be band-



FIG. 388.—Instrument for introducing the glass sphere.




FIG. 389.—Glass balls for introduction into scleral cup after evisceration.

aged for forty-eight hours. At the end of this time there may be a daily dressing, and at the end of five or six days, or at most at the end of a week, the patient may be discharged from his room. Usually an artificial eye can be worn at the expiration of two weeks.

**Complications.**—Severe reaction occasionally follows, with marked edema of the lids and chemosis of the conjunctiva. The chemotic conjunctiva may be incised, and the reaction controlled by continuous iced compresses.

Early absorption of the sutures, if catgut is used, may cause the scleral wound to separate and the glass ball to extrude. Should this happen, the ball may be removed and the operation converted into an ordinary evisceration, or a still smaller ball may be placed in position and the scleral wound once more closed with catgut sutures.

The stump after a successful Mules's operation is so superior to that furnished by any other method that, if no contraindication exists, there should be no hesitancy in performing this operation; for even if the accident of extrusion of the ball should take place, the remaining stump is far preferable to any that could be formed after an ordinary enucleation. The danger that the glass ball may be broken is remote, although this accident has happened.

**Other Operations for Support of Artificial Eye.**—Claiborne and Belt advise *sponge-grafting* in the orbit for the support of an artificial eye. After removal of the eye a globe of sponge, about three-fourths the size of the eyeball, is inserted into the socket or Tenon's capsule. The recti muscles are then united over it and the conjunctiva over all. Saker prepares the



stump for an artificial eye by suturing the recti muscles together with catgut and the conjunctiva with silk.

L. W. Fox describes an operation for *implanting a glass ball* in an orbit from which the globe has been enucleated at some previous date. A horizontal incision is made through the conjunctiva and tissues of the orbit, which should be slightly less than the diameter of the ball to be inserted. The upper lip of the conjunctival wound is raised and dissected away by sharp scissors until a pouch is made for the ball, which is inserted after bleeding is controlled, and the opening closed by sutures. This operation is practically identical with the suggestion of Frost and Lang to introduce a Mules's sphere into Tenon's capsule after ordinary enucleation, and close the muscles and conjunctiva over it in the usual way.

**Optico-ciliary Neurectomy.**—This operation, like evisceration, was proposed as a substitute for enucleation, but has not, for two reasons, filled the place to which it was assigned: 1. It does not replace enucleation, because the danger of infection from such an eye is by no means prevented, as cases of sympathetic ophthalmia have occurred after its performance. 2. The operation is rather difficult to perform, and has been followed by softening and atrophy of the globe.

*Operation.*—An opening is made between the superior and external recti muscles, and the scissors, pressed close to the ball, divide the tissues until the optic nerve is found. This is caught by a strabismus-hook as far back as possible and divided. The optical end is then seized by forceps or hook and drawn to the opening. The nerve and all surrounding tissues are then cut close to the ball. There is considerable hemorrhage, and it is difficult to replace the ball. There is some prominence of the ball for a time, but it usually resumes its normal position after a shorter or longer period.

**After-treatment** consists in cleanliness and bandaging the eye until healing is complete.

**Complications.**—Abscess of the orbit and meningitis may follow from infection during the operation.

---

## OPERATIONS ON THE IRIS AND THE CRYSTALLINE BODY.

By HERMAN KNAPP, M. D.,

OF NEW YORK.

**General Precautions.**—The patient should be free from acute disease and from exacerbations of chronic general disease. The time of the year makes a difference only in so far as constitutional infirmities are influenced by it; for instance, fat persons should avoid the hot season, patients with pulmonary and kidney disease the coldest winter months, etc. Cleanliness of the skin and hair, as well as regularity of the bowels, should receive due attention.

The operations on the iris and lens can be most conveniently performed on an operative chair, which can be moved (on casters), so that the best illumination of the eye, either by day or by artificial light, can be readily secured and disturbing reflexes avoided. For cataract-extraction it is of advantage to operate on the patient in his bed, if the bed can be moved to the source of light, because the patient will not be disturbed by taking him

from the chair to his bed. This advantage is counterbalanced by the greater ease the surgeon and his assistant enjoy when the patient is placed upon a chair.

The patient should keep as quiet as he can during the first twenty-four hours after the operation, for quietness is an important factor in obtaining primary union of the wound. He may, however, sit up in bed for his meals and get up for calls of nature. In case he is not nervous and his attendance good, the degree of success of the operation will be greater if for one or several days both eyes are bandaged; otherwise, the non-operated eye may be covered with a patch which the patient occasionally may raise.

No *septic condition should be present* in any organ of the patient at the time of the operation; in particular, the conjunctiva and the lachrymal sac must be free from suppuration. Chronic non-suppurative disease of these parts is no absolute counter-indication.

The operations should be done under aseptic conditions as perfect as we can have and make them. Immediately before the operation the eye and its surroundings are washed with soap, then with a 1 : 5000 solution of corrosive sublimate, with which also the edges and mucous surfaces of the everted eyelids are washed by means of pledgets of absorbent cotton.

Cocain-anesthesia is sufficient and preferable in most cases; only in children, nervous and unruly adults, and in cases of high eyeball tension, complete general anesthesia should be administered.

Besides a nurse, the operator should have at his disposal two or three trained assistants—one to take charge of the instruments, the second to hold

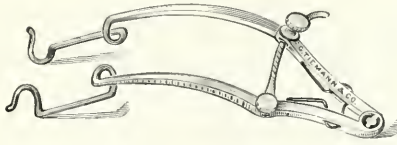


FIG. 390.—Eye-speculum.

the fixing-forceps and cleanse the wound, the third to throw day or artificial light on the eye with a hand-lens, which is indispensable in at least 50 per cent. of the operations.

The eyelids are kept open by a *wire speculum* that does not press on the eyeball, and is strong enough to prevent the spasmodic closure of the lids.

The eyeball is steadied with *fixing-forceps*, the teeth of which are numerous and large enough to be firmly inserted into the episclera. They

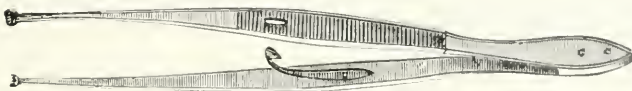

FIG. 391.—Fixing-forceps.

are provided with a catch that closes them fast, yet can be opened without a jerk.

#### OPERATIONS ON THE IRIS.

I. **Iridectomy**—*i. e.* *Excision of a Piece of the Iris*.—Its indications are twofold.

1. To Make a New Passage for the Rays of Light.—Artificial or Optical Pupil.—This is done—

(a) When the natural pupil is more or less occluded by malformation or disease.

(b) When the axial portions of cornea or lens—*i. e.* those situated right before or behind the pupil—are so opaque or misshaped as to intercept the rays of light or cast on the retina a less defined image than would be formed by light passing through a peripheric portion of the cornea and lens. This is the case in closure of the pupil, and opacities, or abnormalities of curvature in the center of the surfaces of the cornea and lens (keratocornus and lenticornus). An artificial pupil should, however, never be made before an examination with a stenopeic apparatus by dilated pupil has positively demonstrated that the new pupil will afford better sight than the old. This precaution applies particularly to maculæ corneæ.

2. To Relieve and Cure Inflammations of the Eye and their Sequels.—Antiphlogistic or Curative Pupil.—This is done—

(a) In *chronic recurrent iritis*, when broad or circular synechiæ impede or prevent the current of the aqueous humor from the posterior to the anterior chamber. The strongest indication for an iridectomy is furnished by the so-called crater-shaped pupil, which when left alone will not only cause blindness, but the ruin of the eye by irido-cyclo-choroiditis, and may even have a prejudicial effect on the other eye.

(b) In all affections in which prolonged increase of eyeball tension is a pronounced symptom—*i. e.* in *primary and consecutive glaucoma*.

(c) To remove tumors (*cysts, sarcomata, etc.*) and foreign bodies if they are located in the anterior part of the eye, and cannot be removed without sacrificing a piece of the iris. Foreign bodies in the iris formerly were never removed without excising the piece in which they lay imbedded.

(d) As a step in ripening immature cataract, and as a preliminary operation for subsequent extraction of cataract (see later).

(e) To remove prolapses of the iris after injuries and operations. When a patient consults us with a fresh wound through which iris protrudes, it may be left alone if the lens is not injured and the wound is not situated in the ciliary region near to and concentrically with the border of the cornea. In prolapses, which happen frequently after cataract extraction, the protruded iris is apt to swell, become cystic, and in all cases produce a high degree of astigmatism. In such instances clean removal of the prolapse, and, if the latter is not fresh, deep excision of the iris, is the best treatment. Also in recent prolapses of the iris through a corneal wound a clean iridectomy, if it is still possible, can appropriately be done. If the iris cannot be disentangled from the wound and the prolapse is let alone, we frequently see an undisturbed recovery, with permanently good sight, follow the natural, clean elimination of the protruded iris by a process of constriction of the base and snaring off of the protruded part.



FIG. 392.—Lance-shaped knife.



FIG. 393.—v. Graefe's knife.

The special instruments for iridectomy are—a lance-shaped (Fig. 392) or a small (v. Graefe) cataract-knife (Fig. 393); an ordinary iris-forceps, curved



FIG. 394. Curved iris forceps.




FIG. 395.—Mathieu's iris forceps.



FIG. 396.—Curved iris scissors.



FIG. 397.—Grooved spatula and probe.

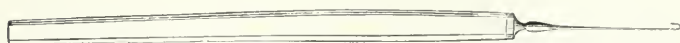

FIG. 398.—Tyrrell's hook.

(Fig. 394), or its modification by Mathieu (Fig. 395); a pair of curved (Fig. 396) or straight iris-scissors; a metal spatula and flexible probe (Fig. 397); a blunt hook (Tyrrell's) (Fig. 398).

#### EXECUTION OF THE OPERATION.

**1. Opening of the Anterior Chamber.**—Suppose that the surgeon has to perform an upward iridectomy, the most frequent case. The patient is reclining on the operating-chair near a window or an Argand gas-lamp. An assistant throws light on the eye with a hand-lens. The operator, standing behind the head of the patient, separates the eyelids with a wire speculum, steadies the eyeball with the fixing-forceps, which he holds in his right hand, the thumb near the button of the catch, the second and third fingers on the other branch of the forceps opposite the catch. With the lance-shaped knife, which he holds in the same way as the forceps, he makes an incision in the upper part of the cornea at or near its transparent margin (the limbus).

The point of the lance, applied at a point directly opposite to the implantation of the forceps, is thrust through the cornea, at first somewhat perpendicularly, then, when it has entered the anterior chamber, which is recognized by the bright luster the blade assumes, it is pushed forward in a direction parallel to the plane of the iris as deeply as the intended size of the incision requires. Now it is withdrawn slowly, advancing the point toward the cornea as the aqueous escapes. This maneuver should be executed with a steady hand, so that the blade of the knife advances as if moved by machinery, and avoids injuring the iris and the lens-capsule on the one hand or the cornea on the other. Wounding the capsule would produce cataract, and grating the posterior surface of the cornea mostly leaves an indelible streak.

It is necessary that the tip of the knife be sharp and flexible, otherwise we may have difficulty in pushing it through the tough lamellæ of the cornea. Afraid of wounding the iris, we have a tendency to lower the handle of the knife; the tip, if flexible, becomes curved, with the concavity toward the iris, and can only with undue force be moved forward.

**2. Excision of the Iris.**—The operator, entrusting the fixing-forceps to the hand of an assistant, takes a pair of scissors in the right and the iris-forceps in the left hand. He closes the forceps and introduces their branches into the anterior chamber as far as the pupillary edge of the iris. He opens the forceps, the iris passes between the branches; the operator closes the forceps again and draws the iris out of the wound (more or less



of it according as a larger or smaller portion is to be removed), and cuts it off close to the cornea, the blades of the scissors parallel to the wound, or, if he wants to make a small incision, at right angles to it. In most cases the cutting can be done with one stroke; in some we may cut in two or three successive strokes.

The iris-forceps should be delicate; the tips of the branches should close nicely and remain closed when the branches are pressed together. Some forceps close at the tip when only moderate pressure is applied, but under stronger pressure they close at a posterior point and diverge at the tip. This is a great fault, for the instrument, after having seized the iris, loses it again when the operator presses the branches more firmly together.

The tips of the branches should be carefully rounded off. They frequently have sharp edges, which make the points liable to engage in the tissue of the iris, drag it along, and produce irido-dialysis and hemorrhage. Hemorrhage may also be produced if, while drawing the iris out, we exert not a straightforward, meridional traction, but a lateral one, which causes dialysis and rupture of the large arterial circle of the iris.

**3. Adjustment of the Lips of the Wound.**—No foreign substance, in particular no iris-tissue, must be left in the wound. It disturbs the healing, and may cause, in consequence of the angular entanglement of the iris, very unpleasant irritative processes—cystoid scar, corneal fistula, glaucoma, suppurative iritis, irido-cyclitis, and sympathetic ophthalmia.

The adjustment of the lips of the wound can be made satisfactorily in most cases by passing a spatula over the wound, flat and at right angles to the line of the section, so that the columns of the coloboma are moved back into the anterior chamber. Should we fail to accomplish this by outward pressure, we must pass the spatula through the incision, push the stump of the iris back of the wound, and particularly stroke the iris out of the corners, so that the sphincter is clear in the anterior chamber at a good distance from the wound.

During and after the operation a few drops of a mild antiseptic may be dropped over the line of incision and the cornea, as the latter, owing to the action of the cocain, becomes dry.

**4. Dressing.**—Both eyes are covered with pieces of corrosive-sublimate gauze, upon which are placed pads of absorbent cotton, which are held in position by the classic binocular (double figure-of-eight bandage), and the patient is put to bed.

The *recovery* in the great majority of cases is without disturbance. The eye is inspected every twenty-four hours, but need not be opened each time, unless some irregularity takes place. The patient is discharged in from seven to fourteen days, which, of course, does not mean that he shall have his full liberty so early.

**Different Methods of Performing Iridectomy called for by Special Morbid Conditions.**—(a) *Optical pupils* should be small. The incision is situated 2 mm. from the limbus in the clear cornea, and is 3 to 4 mm. in length; the iris is seized with a Mathien forceps (Fig. 395) or a blunt hook (Fig. 398), and only the central portion excised. The coloboma should be situated where the optical conditions of the cornea as to curvature and clearness are best. If we have the choice, the situation nasally and a little downward gives the best sight.

(b) The *glaucoma pupil* should be large and peripheric, 1 mm. at least behind the limbus. In acute glaucoma with high tension cocain-anesthesia is mostly insufficient and perilous; because the diffusion-currents being directed peripherally, prevent the cocain from penetrating into the eye sufficiently to produce much effect. If the cornea be made tolerably insensible by it, the iris is not affected at all. The patient does not feel the corneal incision very much, but as soon as the forceps touch the sensitive iris he is apt to give a sudden jerk with his head, which may drive the tip of the iris-forceps into the lens. General anesthesia is to be preferred in these cases.

If one iridectomy in glaucoma gives only temporary relief, a subsequent one is better than a sclerotomy (compare with page 570).

Glaucoma occurs in about 1 per cent. after extraction of primary or discission of secondary cataract. If instillations of a myotic—eserin 1 per cent. solution or pilocarpin 2 per cent.—do not cure the attack, an iridectomy is sure to succeed (probably also a paracentesis of the anterior chamber). The

iris in such cases, as in all aphakial eyes, frequently escaping the ordinary forceps, should be seized with Mathieu's or other forceps the teeth of which are at the lower surface near the tip, not straight at the tip. If even these (capsule) forceps fail, a blunt hook, passed into the pupil, will grasp the pupillary portion of the iris and draw it out of the anterior chamber, where it can be abscised.

II. Other operations performed on the iris are—

1. Iridotomy is practised when, after a cataract operation, the pupil is closed and drawn toward the scar left by the wound.

The so-called pince-ciseaux of De Wecker (Fig. 399), a kind of cutting forceps, are introduced into the anterior chamber through a small corneal incision. The sharp-pointed branch is thrust through the iris, the other remains in the anterior chamber,



FIG. 399.—De Wecker's pince-ciseaux.

and in this way one or two incisions are made through the iris and pseudo-membranes that may be adherent to it. If successful, an artificial pupil can be obtained.

The author's personal experience is not sufficient to pass judgment on the value of this operation. After several trials, which were not very satisfactory, he has returned to—

2. Irido-cystectomy in such cases, which have become very rare in his practice.

An incision is made with a Beer's cataract-knife (Fig. 400) through the cornea, iris, and the adherent thickened lens capsule; next a Tyrrell's hook, or one branch of a pair of capsule-forceps (Mathieu's, Fig. 395) is passed into the opening in the iris; the




FIG. 400.—Beer's cataract-knife.

edge of the iris is seized, drawn out of the wound, and cut off close to the cornea. The results of this procedure have in general proved successful.

3. Corelysis (*synecchiotomy*), the detachment of posterior (Streatfeild) or anterior (Lang) synecchia, has not been found sufficiently beneficial to be regarded as a standard operation.

4. The iridencleisis of earlier surgeons and the iridodesis of George Critchett, by which pieces of the iris were healed into a corneal wound, and thus the iris drawn away from a central opacity, have been abandoned in favor of the easier and less hazardous iridectomy.

## OPERATIONS ON THE CRYSTALLINE BODY.

The crystalline body, consisting of the lens and its capsule, gives occasion for two kinds of operative procedures which, as to delicacy and precision of execution and to brilliancy of results, are excelled by no other department of surgery.

1. **Operations on the Lens.**—When the lens becomes opaque in some way or other, either partially or totally, it intercepts the rays of light on their way through the pupil. If the lens is removed from behind the pupil,

the object of the surgeon is obtained. This can be done by displacement, by extraction, or by solution.

I. **Displacement** at the present time is only exceptionally practised—namely, for certain forms of shrunken or secondary cataract. It is described by Celsus, and was used long before him. It was practised in two ways—(a) by *depression* (keratonyxis). A broad needle was introduced through the lower part of the cornea into the upper part of the pupil, where by the raising of the handle it dislocated the lens into the lower part of the vitreous. (b) by *reclination* (couching, scleronyxis). The needle was introduced through the sclerotic and lateral part of the lens into the upper part of the pupillary area, from where, by a curvilinear movement, it turned the lens back and down into the vitreous.

The immediate results of displacement were often brilliant, but in most cases sight was subsequently lost by ascension of the lens, or by irido-choroiditis and glaucoma.

II. **Extraction** also seems to be an old method, but has been systematically practised only since the French surgeon Jacques Daviel in 1845 re-discovered it. It soon obtained favor, and for the last forty years has been the chief operation for cataract.

The following instruments are required: A wire speculum (see Fig. 390); fixing-forceps (Fig. 391), as for iridectomy; a narrow (v. Graefe, Fig. 393) or a triangular (Beer, Fig. 400) knife, with a firm, non-flexible point, which, like the cutting edge, is of the utmost sharpness; a cystotome, the shaft of which may be straight or bent at an obtuse angle, in which case two are necessary—one for the right, the other for the left, eye (Fig. 401), and the point of which, with its short cutting edge very fine and sharp, is to be cautiously handled in cleansing and sterilizing; a Daviel spoon, flexible (Fig. 403); a blunt (olive-tipped) flexible probe (Fig. 397); a curved, flexible, and slightly grooved spatula (Fig. 397), and a wire loop, curved like a spoon (Fig. 404).




FIG. 401.—Right and left cystotomes.



FIG. 402.—Cystotome and spoon.




FIG. 403.—Daviel's spoon.



FIG. 404.—Wire loop curved like a spoon.

#### EXECUTION OF THE OPERATION.

*First Step.*—**The Corneal Section.**—The eye is cocaineized. The operator, standing behind the patient, inserts the teeth of the fixing-forceps firmly into the episcleral tissue, and makes the corneal incision with a narrow Graefe knife held between the thumb and

the index and middle fingers of the other hand. We suppose we have to extract, by a superior section, a hard, mature, senile cataract, the anterior chamber being of normal depth. The knife pierces the cornea (*puncture*) in its transparent margin (*limbus*) slightly above the horizontal meridian, passes straight through the anterior chamber, and emerges (*counter-puncture*) on the other side at a point corresponding to the puncture. The section is continued by advancing the knife its whole length, and at the same time cutting upward without changing its direction, parallel and close to the iris, until it emerges at the upper end of the vertical meridian, where a small conjunctival flap is formed.

*Second Step.—The Opening of the Capsule.*—The cystotome is introduced, with its point backward, gently into the anterior chamber as far as the pupil; then its tip is pushed under the upper part of the iris, turned backward, and drawn across the capsule of the lens, so as to incise it 1 or 2 mm. below the equator, concentrically with the corneal margin. This maneuver requires some judgment in order to be sure that the capsule is opened without displacing the lens or rupturing its suspensory ligament, which would favor escape of vitreous during the operation and prolapse of iris later.

*Third Step.—Expulsion of the Lens.*—The speculum is removed; the operator takes the wire loop in one hand, and Daviel's spoon in the other. The patient looks steadily down; the convex surface of the spoon is applied to the lower portion of the cornea and pressed gently and steadily toward the *centre of the eyeball*, which causes the wound to gape widely and the lens to slip out gradually. When the greatest diameter of the lens has passed out of the wound the lower part is followed up with the spoon, so that the whole cataract is expelled. If during the expulsion the pupil does not dilate well and the upper part of the iris is pushed out bulgingly, the operator enlarges the pupil by pressing the bulging part of the iris backward with the wire loop.

*Fourth Step.—Cleansing of the Wound.*—During the operation and cleansing of the wound it is desirable to instil a few drops of an antiseptic solution, which will keep the eye wet and wash small particles away. Remnants of lens should be driven out by pressing with the finger the edge of the lower lid upward over the cornea. Neither the upper nor the lower lid should touch the open wound. Pieces of cataract lying between the lips of the wound must be removed with a well-sterilized spatula. Also small particles of lens lying still in the anterior chamber can be stroked out with the spatula.

If the iris does not return into its normal position spontaneously or by gently pressing a few times the lower lid with the finger on the lower margin of the cornea, the tip of a blunt probe has to be introduced from the side into the anterior chamber and passed onward along the iris-angle beyond the vertical meridian, in order to disengage the iris from the sinus of the anterior chamber, where it is crowded, and stroke it toward the center of the pupil. If this maneuver should not succeed or the iris should show a tendency to become displaced again, it is best to excise a small portion of it, and with a probe carefully push the corners of the defect out of the wound back into the chamber. Care should also be taken to stroke the conjunctival flap out of the wound.

*Fifth Step.—Dressing of the Wound.*—When the patient is put to bed the wound is inspected once more, and, if everything is satisfactory, both eyes are bandaged. A piece of sterilized gauze is put wet on each eye; upon it is placed a thin pad of absorbent cotton, the whole held in position by a roller bandage or strips of isinglass plaster.

The patient should lie quietly on his back as long as he feels comfortable; otherwise he may lie on the side of the non-operated eye. It is advisable to give an anodyne to the majority of patients soon after the operation.

*Modification of the Operative Procedure.*—The *corneal section* is placed *more or less in the opaque border* of the anterior chamber. This favors prolapse of iris and vitreous, as well as inflammations of the ciliary body.

The section is placed *within the transparent cornea*. This, by closing less accurately, tends to adhesions of the iris to the scar, especially at the corners of the wound, and is more liable to *primary* and *secondary* infection.

The section is made *downward*. This section is less protected by the lids, and optically at a disadvantage if an iridectomy has to be made.

The *opening of the capsule* is made with a cystotome or a hook, *extensively and in different directions*. In this way the capsule is torn, not incised. It has the advantage that in a certain number of cases the shreds of the capsule are drawn to the periphery and leave a sufficiently clear pupil, but the laceration and promiscuous opening often cause posterior synechie, and not rarely more or less obstruction of the pupil by inflammatory products which



it is difficult and risky to deal with. The opening of the capsule by a periph-  
eric incision permits as easy and complete an expulsion of the lens as the  
central opening, and tends much less to iritis and capsular deposits. If later  
we wish to give the patient permanently the greatest possible sight his case  
admits of, we can do it by a simple dissection of the wrinkled but not  
thickened capsule.

A *piece of iris is excised* either before (*preliminary iridectomy*, Mooren) or  
during the operation for cataract (*combined extraction*, von Graefe). This is  
indicated in all the cases—about 10 per cent.—in which the natural pupil  
does not admit of an easy exit of the lens or in which the protruded iris  
cannot be reduced or is likely to form a subsequent prolapse. That combined  
extraction is a safer operation than simple extraction is an assertion not con-  
firmed by the writer's practice (in more than 1000 carefully recorded cases of  
each method). Simple extraction has the disadvantage that it is followed by  
prolapse of the iris in 5 to 10 per cent. of the cases. This can be remedied  
without much trouble and danger by excision of the prolapse within 24 hours  
after its occurrence. In all other respects simple extraction is superior to  
combined extraction.

The expulsion of the lens can also be accomplished as follows :

*Cataracts may be extracted with the capsule.* A. and H. Pagenstecher  
have tried this old operation as a general method, but had to limit it to  
hypermature cataracts where the capsule is thickened and the zonula Zinnii  
frail or ruptured. For such cases it is the best method.

In *soft and traumatic cataracts*, including those produced by operative  
interference—*c. g.* dissection—in excessive myopia, zonular cataract, etc., the  
so-called linear extraction is appropriate.

With a lance-shaped knife the cornea is cut to the extent of 5 or 6 mm. near its  
border, and the capsule opened by piercing it with the lance, or it may be lacerated  
with a cystotome. The soft lens-substance is let out by backward pressure with the tip  
of the lance. If this is not sufficient, the posterior lip of the wound is pressed back by  
a wire loop, and as much of the cataract is coaxed out as will follow a moderate pressure.  
The reaction is mostly insignificant, but a subsequent capsulotomy is needed in  
most cases.

In *tremulous and dislocated cataracts*, or when *vitreous escapes before the  
lens*, the fixing-forceps and speculum should be removed immediately after  
the opening of the capsule and the *lens expelled by pressing with the edge of  
the lower lid toward the center of the globe*, while the upper lid is pressed gently  
on the sclerotic above, near the section. In this way the lens is moved into  
the wound, plugs the gap, and by a little additional pressure mostly comes  
out without, or with but little, loss of vitreous.

If, in exceptional cases, these external manipulations do not succeed, the  
lens has to be drawn out by a traction-instrument—a spoon, a curved wire  
loop (Fig. 404), or a sharp hook—introduced behind the lens, beyond the  
posterior pole. The introduction of traction-instruments should be avoided  
as much as possible.

For the *cleansing of the pupil* from remnants of cataract a Daviel's spoon  
has been used; the remnants also have been washed out with a syringe by  
injecting a very mild antiseptic lotion (*irrigation of the anterior chamber*).  
These procedures do not often succeed, nor are they free from danger. In  
expelling them by external manipulation care should, however, be taken lest  
by an unusual degree of pressure vitreous protrude.

**Mistakes and Accidents during the Operation.**—*Insufficiency of the  
corneal section* leads to stripping off of the cortex and bruising of the wound,

with deleterious consequences. Its presence is recognized if the lens presents in the wound, but does not advance. No forcible pressure should be used, but the section should be enlarged by a strong pair of strabismus-scissors (those of Stevens answer well).

If the knife on its passage through the anterior chamber engages in the iris, or if the counter-puncture is not at the right place, the knife should be drawn back and its direction corrected.

If the iris falls over the knife when the knife, after the counter-puncture, is moved upward, in many cases the iris can be re-dressed by turning the edge of the knife slightly forward; but if this fails to push the iris back, it is best to continue and to complete the section. The excision of a small piece of iris does not much interfere with a good recovery.

**Disturbances of the Healing Process.**—Profuse intraocular hemorrhage during or after the operation is followed by the ruin of the eye, do what we may.

*Prolapse of iris* is treated in the manner already described (page 576).

*Iritis* is treated as usual—leeches, atropin, anodynes, etc.

*Cyclitis with capsulitis*, which mostly manifests itself in the second week by pain, marked, deep-seated circumcorneal injection, with a round, clear pupil and good sight, is commonly tedious and requires patient treatment for from three to six weeks. Then the sclera gets white, the vitreous clears up, the capsule is more or less opaque, but the vision is commonly not greatly damaged, and can be improved by a subsequent discission.

*Irido-cyclitis*, especially after combined extraction, is more deleterious. It lasts weeks, and sometimes months, damages sight greatly, leads to closure of the pupil, and dense pseudo-membranes behind the iris. We should not tire in treating such cases, for not infrequently, even if sight is reduced to perception of light, a cystectomy will restore useful vision.

*Irido-cyclitis ruins, in rare cases, the other eye by sympathetic ophthalmia.*

*Suppuration* may occur in the cornea, the iris, and the vitreous. In almost all cases it destroys the eye by extension to the deeper tunics—*panophthalmitis*.

In some cases a corneal suppuration is limited to the lips of the wound and the adjacent parts. The result is partial preservation of the cornea, indrawn scar, and closure of the pupil. If the eyeball is not soft and the light-perception good, an iridectomy may restore a moderate degree of vision.

Whether a beginning suppuration of the flap will be limited or progress to total destruction of the cornea seems to depend more on the nature of the individual case than on the medication employed. The author has not found that galvano-cautery or any other means has a controlling, or even favorable, influence on the morbid process. Of the many modes of treatment recommended and praised, the best seems to be to open the wound and establish drainage of the anterior chamber by reopening the wound with a spatula once every day or oftener. Eyes with *ring abscess* and *panophthalmitis* are beyond rescue. Our endeavor should be to relieve the atrocious pain and establish a safe and non-irritable stump suitable for wearing an artificial eye. This is best accomplished by poulticing and incisions giving free vent to the pus.

The result of cataract extraction is restoration of useful sight in about 95 per cent. of the uncomplicated cases, perception of light in 3 per cent., total blindness in 2 per cent.

**III. Ripening Operations for Immature Cataract.**—A cataract may be mature—*i. e.* opaque in all its parts—and yet not in the best condition for extraction. This is the case when the lens is swollen by imbibition, which, through the shallowness of the anterior chamber, renders it difficult to pass the knife through the aqueous humor without injuring the iris, and to make the counter-puncture at the right place. Usually in from three to six months the imbibed liquid will be absorbed, the lens will be smaller and compact, and the anterior chamber of normal depth. This is the time for the extraction.

On the other hand, cataracts may be immature and yet can be extracted easily and cleanly. This is the case when the nucleus is opaque and the transparent cortex pervaded by gray lines situated in the layers next to the capsule; or when the cortex is transparent, but the nucleus amber-colored, and the patient has reached the age of sixty years. Frequently enough in cataracts not coming under the above categories the natural ripening is so slow as to cause the greatest discomfort and render the patients unfit for work. Under these circumstances artificial ripening has been resorted to in different ways:

1. Opening of the capsule with a needle, as in discission of soft cataract (see later on). This is the oldest and perhaps most efficient method, yet it has the disadvantage of ripening the anterior cortex only, so that after the extraction we are surprised by finding a considerable quantity of lens-matter left behind. This may not be the case if, as Schweigger recommends, the discission goes deeper into the lens-substance.

2. Iridectomy and trituration of the lens by rubbing a blunt instrument over the cornea (Förster).

3. Paracentesis of the cornea and trituration of the lens with a blunt probe (Born), spatula (Sasso and Piscaldi), or trowel (B. Bettman) introduced into the anterior chamber.

4. Paracentesis of the cornea and trituration of the lens through the cornea (T. R. Pooley, J. A. White).

The writer has used some of these methods, with little satisfaction. He advises his patients to wait till Nature ripens their cataracts—which she always does harmlessly—and if they cannot wait, he in most cases would rather remove an unripe cataract (provided the anterior chamber is not shallow), and deal with the remnants later, than subject the patients to preliminary ripening procedures, which are unreliable and require operations for secondary cataract not less frequently than where immature cataracts are removed.

**IV. Discission of the lens** is indicated—1. In all cataracts of young people up to fifteen years of age.

2. In soft cataracts of adults as long as there is no hard nucleus. In these the discission has frequently to be followed by extraction on account of the advent of glaucoma.




FIG. 105.—Knife-needle.

3. In transparent lenses in younger people suffering from excessive myopia, 16 D. and over.

*Instruments.*—Fixing-forceps, a discission-needle, or small knife-needle (Fig. 405).

*The execution of discission varies under different conditions.*

For division of *soft, zonular, and partial cataracts* the operator chooses a short knife-needle, thrusts it through the cornea midway between center and circumference, and through the capsule, 2 mm. beyond its center; draws it back to make a horizontal incision of 4 mm. through the capsule; then he rotates the instrument 90°, transfixes the capsule 2 mm. above the horizontal incision and cuts down into the horizontal incision; now he turns the needle 180°, transfixes the capsule 2 mm. below the horizontal incision, and cuts upward into the latter. In this way the capsule is opened by a crucial incision of 4 mm. in either direction. The cuts should be superficial, lest the lens by too rapid imbibition swell too much and cause glaucoma. Yet a small particle of lens-substance may be pushed with the needle into the anterior chamber, for small and superficial openings of the capsule may close again and have no effect. In most cases the discission has to be repeated several times, and the last time the posterior capsule should be divided, otherwise it will by wrinkling and dotting obstruct the pupil subsequently.

For the removal of the transparent lens in cases of *excessive myopia* the same precautions and repeated operations have been made, but Dr. Fukala, the chief advocate of the "operative treatment of myopia," now recommends breaking up the lens in the first operation by extensive discission, soon to be followed by extraction. The writer has no personal experience in removing the transparent lens in myopia. The operation has been practised of late by a number of eminent European oculists, and, on the whole, favorably commented upon. It is like operating on zonular cataract, and said to have no influence on the fundus changes. Hemorrhage in the vitreous and detachment of the retina have been noticed after the operation. In a large number of cases the visual tests after the operation have discovered a remarkable increase of the sharpness of vision (see also page 224).

**B. Operations on the Capsule, the so-called Secondary Cataract.**—For secondary cataract many operative procedures have been recommended.

1. *Discission* is indicated for all obstructions of the pupil that can be cut with a small knife or a needle. It is rarely that the capsule, when partially or totally left in the eye, remains permanently clear; it wrinkles, dots, and thickens, diminishing the vision more and more. Discission should be done if the vision is less than  $\frac{2}{5}$ . The best time to do it is from six to twelve weeks after the extraction, when all irritation has passed and the capsule has not yet become thick and tough. It can be done, however, at any later period. For many years the writer has operated in the following way:

The eye is cocainized, the pupil dilated. An assistant throws the focal point of an intense pencil of light (Argand gas-burner, incandescent gas, or electric light; large hand lens) on the capsule, leaving half of the cornea, through which the operator looks, unilluminated. The operator has previously examined the eye with focal light and the ophthalmoscope to ascertain how much diminution of sight is attributable to the capsule. If he gets a clear image of the fundus, cystotomy is out of the question; further, he has to find out where the capsule is least tough in order to determine where and in which direction it should be split. The plan of the operation is the same as in discission of soft cataract (see above).

A straight knife-needle with a sharp point, a sharp cutting edge and a rounded back is used. The blade and shaft should be so proportioned that the shaft just fills the wound made by the blade. Sickle-shaped needles do not readily stab the delicate, elastic, and readily escaping pieces of capsule when the first incision has been made. Needles of so little width as here required cannot be made sharp if they have two cutting edges instead of one and a back, as on a knife. With a well-made knife-needle three incisions can be made without escape of aqueous humor or bruising of the edges of the puncture-canal in the cornea.

The capsule must be divided by two incisions (no tearing), T-shaped; sometimes three incisions, +, crucial. Bands offering resistance must be left alone; it suffices to clear the space beside them. The needle should not be entered more deeply into the



vitreous than is necessary to split the capsule. The incision should be effected by the simultaneous movement of a lever and a knife which is gradually withdrawn, the corneal puncture being the fulcrum. The handle of the knife-needle is to be held between the brawn of the thumb on one side and that of the index and ring fingers on the other, so that an axis rotation of  $180^\circ$  can be easily and securely made. If by some accident or other the splitting of the capsule has been insufficient, no harm is done by introducing the needle again, from another point of the cornea, in the same sitting or later on.

The reaction of this operation is mostly insignificant. The writer has done this operation seventeen or eighteen hundred times and never lost an eye by it, and rarely ever damaged one. Suppuration has never followed, but glaucoma occurred every now and then, in about 1 per cent. of the cases. It has always been cured by a myotic or an iridectomy. The results for sight have been most satisfactory, and the sharpness of sight, once acquired, was not lost again by a disease that was in causal connection with the operation, if exception is made of cases of subsequent glaucoma which were inaccessible to treatment. The patients should be warned not to let themselves be deluded by the absence of discomfort during the first days, but avoid exposure and over-exertion, and, should irritation occur, at once consult an oculist and have a myotic instilled or an iridectomy made if glaucoma be present. The cases are very rare, however.<sup>1</sup>

2. *Cystectomy, iridectomy, iridotomy, or irido-cystectomy* should be done if the pupil is occupied by tough pseudo-membranes or closed altogether. The operations are described before (see pages 577-579).

3. In cases of tough capsules a *double-needle dilaceration* may be done. One needle is introduced with one hand through the nasal side of the cornea and thrust through the center of the lens, and held there; another is introduced with the other hand through the temporal side of the cornea, and thrust through the aperture in the capsule which the first needle has made. By approaching the handles to each other the points diverge, and tear a hole into the capsule without dragging on the ciliary processes. By this procedure we often succeed in making a permanently good opening in the capsule. It is not hazardous.

<sup>1</sup> Operations on the capsule for secondary cataract are dreaded by many experienced operators, who have lost eyes (which had obtained useful vision through extraction of primary cataract) by the severest inflammations, including suppuration and panophthalmitis. The reason why the writer thus far has escaped such sad experience probably is that he performs the extraction with a view to supplement it by a discission—namely, in such a way as to exclude, as much as is in his power, any reaction that may lead to the deposition of inflammatory products in the pupil. This object, he thinks, is obtained, more than by anything else, by the peripheric incision of the capsule, which is rarely followed by iritic processes. His statistics of many hundred cases show the average acuteness of sight to be  $\frac{2}{3}$  before and  $\frac{2}{3}$  after the secondary operation. The latter is done in about 70 per cent. of the cases, and consists nearly always in a discission. In less than 2 per cent. has he had occasion to make another operation for secondary cataract.

The after-treatment of cataract operations has been mentioned above in different places, the dressing on page 578, the operative treatment of prolapse of the iris on page 576. To prevent accidental injury, in particular iris-prolapse, various kinds of masks are in use. Some masks imply danger by themselves, all are more or less uncomfortable, and many patients of the author have preferred to have their hands tied. It is advisable to inspect the eye the day after the operation and remove an iris-prolapse, if there should be any, at once. The bandage may be removed from the non-operated eye on the third or fourth day, from the operated eye several days later. The patient may be kept in bed for five or six days, old people less, for fear of hypostatic pneumonia. Attacks of mania are combatted by hypodermic injections of hyoscin, gr.  $\frac{1}{100}$  pro dosi.

## OPERATIONS UPON THE EYE-MUSCLES.

BY S. C. AYRES, M. D.,  
OF CINCINNATI.

---

OPERATIONS upon the ocular muscles may be necessary for the relief of concomitant and paralytic strabismus, as well as for want of balance in opposing muscles where squint does not exist.

The surgical correction of strabismus includes tenotomy of one or more of the ocular muscles, or advancement combined with tenotomy. Partial and complete tenotomies are also performed to correct various types of heterophoria, and advancement may be employed for the same purpose. Finally, advancement preceded by tenotomy of the opposing muscle is utilized to relieve the faulty results of strabismus operations, or in certain cases to counteract the deviation produced by paralytic squint.

**I. Complete Tenotomy.**—(a) **Tenotomy of the Internus.**—The operation for convergent strabismus which has been very generally adopted is the one devised by v. Graefe. It is the easiest of all the operations, and has only one disadvantage, if it may properly be so called—namely, the necessity of a suture in the conjunctiva. It is performed in the following way :

After the conjunctiva is cocainized the lids are separated by a spring speculum, and an assistant seizes the conjunctiva close to the outer side of the cornea and rotates the eye directly outward in the axis of the commissure, in order to prevent the natural tendency of the patient to turn the eye upward. The operator grasps the conjunctiva with a pair of forceps directly over the tendinous insertion of the muscle, raises it, and makes an opening, either in a vertical or horizontal direction, large enough to admit the easy introduction of the hook. Next, the subconjunctival tissue is incised, so as to expose the tendon of the muscle, and the hook is passed beneath the tendon, care being exercised to secure the entire tendon. The muscle is severed close to its insertion in the sclera with two or three cuts of the scissors.

An examination should now be made with the hook, above and below, to determine whether the tendon has been entirely severed, and also to ascertain whether any offshoots remain which may limit the motion of the eye outward. If the patient is not anesthetized, this may be readily determined by directing him to forcibly rotate the eye outward. The patient should next be directed to "fix" an object near by—the point of a pencil or the tip of the finger. If convergence still remains, the effect of the operation may be increased by incising the capsule of Tenon. This should be done with care, and, after snipping the capsule above and below the severed tendon, adduction and abduction should be tested. If the effect is satisfactory, the conjunctival wound should be closed with one or two sutures, both eyes bandaged, and the patient required to remain within doors until the following day, when the bandage may be removed.

If too much effect has been produced, a suture should at once be inserted in the cut end of the muscle from within outward and brought out through the conjunctiva close to the cornea. It should be securely tied, and then a bandage applied, as above directed, until the following day, when the eye should be opened and allowed to take part in the visual act. The primary suture may be removed on the second day after the operation, but when a suture is introduced to counteract excessive effect it should remain for two or three days.

(b) **The subconjunctival operation,** commonly known as Critchett's operation, is done in the following way :

The eye having been cocaineized, the lids are separated by a spring speculum (it is supposed the internal rectus is to be operated upon), and an assistant firmly seizes with forceps the conjunctiva and subconjunctival tissue near the outer edge of the cornea to prevent rotation of the eye on its axis. The operator next raises the conjunctiva with a fine-toothed forceps over the lower border of the rectus muscle, and makes an opening sufficiently large to admit easy insertion of the scissors and hook. It is better to have this opening too large than too small. After the incision of the conjunctiva the subconjunctival tissue is divided by successive short snips with the scissors, and undermined in the direction of the caruncle, until an opening is made in the capsule sufficiently large to enable the operator easily to introduce the hook. The hook, held in the right hand, is inserted on the flat, its point in contact with the sclera, and is passed under the muscle and drawn toward the insertion of its tendon. Then the point is elevated until it raises the conjunctiva in a tent-like manner. The hook is now grasped by the left hand of the operator, the assistant removes the forceps, and the tendon is severed by a series of short snips until the lessening of resistance and the elevation of the hook under the conjunctiva indicate complete division of the tendon. Where the tendinous insertion is broad it may not be entirely taken up on the hook, and another attempt to secure it should be made. After the section has been performed the hook should be swept through the opening in order to catch any strands which may have escaped division. If a decided effect is desired, the opening in the capsule, above and below, may be enlarged.

The conjunctival wound does not need a suture to close it, and only a compress bandage for a day is necessary. It is more difficult to perform this operation than the one previously described, because the tendon cannot be seen, but only felt. Sometimes with an unruly patient the cutting is not smooth; occasionally the tendon slips off the hook. Straight scissors are better in this operation than curved, although the operator may use the kind he prefers.

(c) **Snellen's Method.**—Snellen makes a vertical incision in the conjunctiva directly over the middle of the tendon of the muscle. After the opening has been sufficiently enlarged and the tendon exposed he seizes it with a pair of forceps and makes an opening or buttonhole in it, through which he passes the hook and cuts the upper portion, and then the lower portion, of the tendon in succession, close to the sclerotic. The subsequent dressings are the same as after the Graefe operation. He claims that this method does not interfere with the capsule of Tenon or with the indirect insertion of the muscle in its connection with the capsule.

In order to increase the effect of a tenotomy, in certain cases Knapp inserts a suture through the superficial layers of the sclera at the outer side of the eye and passes it through the skin beyond the outer canthus, where it is tied and allowed to remain a few hours. If insufficient effect is found to exist the day after the operation, it can be remedied in some cases by again cocaineizing the eye and opening the wound, and passing the hook under the tendon and separating it from the sclera.

There is a marked difference in the size and strength of internal recti muscles. The hook can be readily pushed beneath most of them, but occasionally a tendon is found which is thick and broad, and apparently drawn very tightly over the sclerotic, and which presents an unusual amount of resistance. In such cases only the point of a hook can be inserted underneath the tendon, which must be severed by successive short snips. In these cases there is danger of perforating the sclerotic.

**Choice of Operation.**—It is probable that most of the tenotomies of the internal rectus are performed either by Graefe's or Critchett's method. The judgment and experience of the operator will be his guide in choosing the one best suited to each individual case. The writer prefers the subconjunctival operation.

(d) **Tenotomy of an Externus.**—This is accomplished in a manner identical with that described in connection with the internus. The external rectus is inserted farther from the cornea (7 to 8 mm.) than the internus, its insertion is not so broad, and it is more lax than the inner muscle. The effects of its division are not so marked as those seen after tenotomy of the

internus, and hence are often disappointing. Not infrequently it is necessary to tenotomize both externi simultaneously.

(e) **Gruening's Method.**—In absolute divergent strabismus Dr. Gruening tenotomizes both external recti at one sitting, as follows :

Where the divergence is not more than 2 mm. the tendons are divided at their insertion. Whenever the deviation measures more than 2 mm. the tendons are divided at a distance from their insertion, this distance corresponding to the degree of squint. When the deviation amounts to 5 mm. by the corneal reflex, both tendons are divided at that distance from the points of insertion. After closing the conjunctival wound a silk suture is passed through the conjunctiva over both interni muscles in a line with the horizontal meridian of the cornea, and tied over a pledget of cotton on the bridge of the nose. This position is maintained twenty-four hours.

(f) **Tenotomy of the Superior and the Inferior Rectus.**—In operating on the superior and the inferior rectus muscles the same precautions are required as in operations on the internal and external muscles. It is better to employ the open method by cutting down upon and exposing the insertion of the tendon.

**II. Graduated or Partial Tenotomy.**—Operations on the internal, external, and vertical muscles for esophoria, exophoria, and hyperphoria are made by partial or graduated tenotomies, as devised by Dr. Geo. T. Stevens. The tendon of the muscle is partially severed, and then a test of the effect produced is made and the operation continued until the desired result is obtained. Dr. Stevens operates as follows :

If the right internus is to be operated upon, the patient is directed to turn his eyes well to the right. The surgeon, with a pair of fine forceps (Fig. 406, *A, B*), takes a

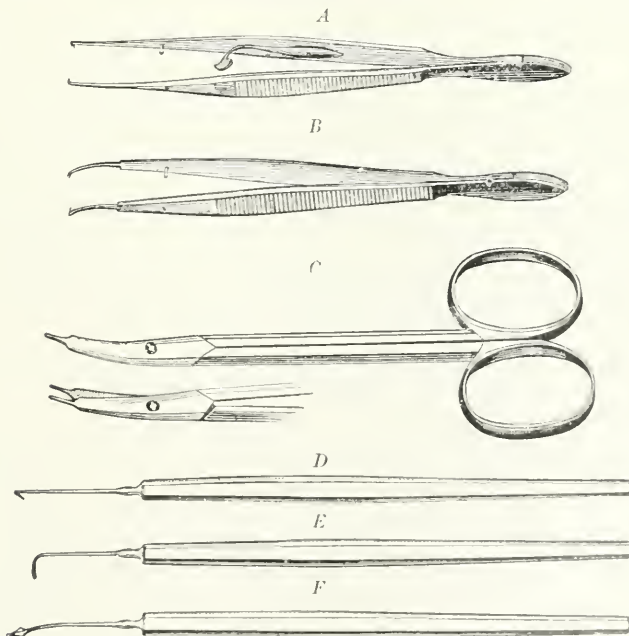


FIG. 406.—Instruments used in graduated tenotomy.

minute fold of the conjunctiva at the center of insertion of the tendon. Drawing this little fold of conjunctiva slightly away from the eyeball with the extreme point of the tenotomy-scissors (Fig. 406, *C*), the operator snips the fold transversely, so that an opening  $\frac{1}{2}$  mm. in extent is made through the membrane. Now the forceps,



the points being closed, are pressed into the little opening and slightly backward, where the points are permitted to spring apart, after which they are again closed, this time holding a small fold of the tendon just behind the insertion. This being put upon the stretch, the scissors by little snips dissect the tendon from the eyeball between the layers of the capsule (which should remain intact) toward one border of the insertion. Then the tendon is cut toward the other border of its insertion. After this the tests for adduction and abduction are made, and further operative interference regulated according to the results. In like manner, the tendon of the external, superior, or inferior rectus may be partially divided.

This operation has received commendation and criticism, and it is open to both. It is suitable to cases where a very slight effect is desired. The fact that it has to be repeated several times is an argument against it, and in favor of a more pronounced effect which can be gained in one or two partial tenotomies.

**III. Advancement or Readjustment and Resection.**—In this operation the tendon of a rectus muscle is brought forward to a new attachment.

(a) **Advancement to Correct Faulty Strabismus Operations.**—Operations for advancement after squint operations present difficulties and complications not found in other cases. The conjunctiva over the incision is generally firmly cicatrized to the subconjunctival tissue and sclera. This may be due to the fact that the original incision was not closed by a suture and that the exposed scleral surface had granulated. Again, the insertion of the muscle is sometimes very thin and cord-like, and is attached to the sclera by a mere thread. The retraction of the muscle may have been very great, and one must search carefully for its new and abnormal insertion.

First, the cicatricial surface should be denuded by cutting away this tissue until the sclera is exposed and the muscle brought into view. A hook is now passed beneath the muscle, which is raised up until it can be seized with catch-forceps, when its insertion is severed. If the muscle is atrophied and cord-like, it will be necessary to insert the needles very far back in order to secure the necessary purchase, and the difficulties of passing the needles under these conditions are sometimes very considerable, owing to the cicatrization above mentioned. If the muscle is thin, a thread armed with three needles, as described elsewhere (de Wecker's advancement operation, see below), should be used; but where it is broad enough for the insertion of one thread through its upper and another through its lower border, this is the better plan to adopt, because it spreads the muscle and gives it a more secure attachment to the sclera. Both eyes should be bandaged for two or three days after the operation. As soon as the eye is firmly fixed in its new position, providing no inflammation has ensued, both eyes should be opened and the patient allowed to walk as usual around the ward or house.

(b) **De Wecker's Method of Advancement.**—De Wecker's operation is performed in the following manner:

A vertical incision is made in the conjunctiva close to the cornea, and the subconjunctival tissue cut away until the tendon of the muscle is exposed. One branch of a de Wecker's clamp is now passed under the tendon of the muscle, and when it is in the proper position the other branch is pressed down, thus holding it by the forceps (Fig. 407). The tendon is now severed close to the sclera, and an exploration is made with a small hook to ascertain whether any fibers or offshoots of the muscle remain. A thread armed with three needles, one in the middle and the other two not far from the ends of the suture, is prepared for the second step of the operation. The middle needle is passed through the center of the tendon from its under surface, and comes out through the conjunctiva. The location of this stitch is regulated by the effect to be produced, being inserted nearer the caruncle when more effect is desired. The two needles are then passed deeply under the conjunctiva, coming out in the vertical meridian of the eye at a distance of 4 mm. from the cornea, one above and the other below. The clamp-forceps are now removed, and, if the muscle is to be shortened, that portion of the muscle within the clamp is severed. The middle needle having been cut off and the others also removed, the two sutures are tied as follows: The operator and his assistant

each take one of the threads and simultaneously tighten them. When the desired position has been attained the knots are tied and the ends of the thread cut off. An over-correction is made, because after removal of the threads the tendon recedes from the original position.

If after two or three days there is an over-correction, the threads are removed, and,

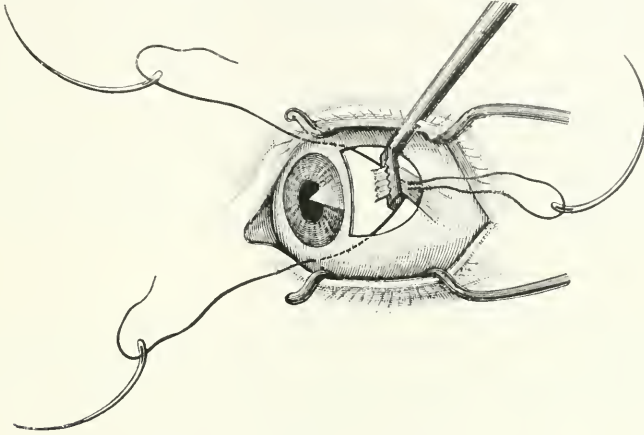


FIG. 407.—De Wecker's advancement.

after cocainizing the eye, a delicate hook is introduced into the wound and the attachments of the muscle loosened sufficiently to overcome the defect. If this is not necessary, the stitches are allowed to remain until the fifth or sixth day.

(c) **Noyes's Operation for Advancement.**—Dr. Noyes describes his operation as follows:

“Suppose the right rectus internus is to be advanced. The right rectus externus is first divided; then seize the insertion of the rectus internus with fixation-forceps, taking a deep bite to include all that can be lifted; sever the insertion freely, and cut down above and below into the conjunctiva to the extent of 10 to 15 mm.; have the forceps fast to the tissues by shutting the spring catch, lay it aside and then remove a vertical oval of conjunctiva in front of the insertion, leaving a strip 6 mm. wide next the cornea. Lift the muscle and pass a curved needle from within outward at its middle and as far back as the proposed effect will demand. With the needle in place cut off superfluous material in front of it, and then draw it through. The other two needles are introduced in succession and the tissues in front are cut off. This is done to avoid the danger of cutting off the sutures. We now have three threads through the muscle-fascia and conjunctiva. The needles at the other ends of the thread are next to be passed forward beneath the remaining conjunctival strip, taking hold of the outer layer of the sclera, so that the points emerge at the limbus corneæ. The middle thread is tightened first, and then the others in succession. The double knot is not tied until the threads have been successively tightened, and the eye is in a proper position. If there is much crumpling of tissue, it must be cut away, leaving the parts smooth. The stitches are allowed to remain from four to seven days. A bandage is applied for twenty-four or forty-eight hours.”

The author does not think it necessary, except in rare cases, to cut away the conjunctiva as recommended above. He has found that it usually smooths down in a short time.

(d) **Schweigger's Operation of Resection of a Rectus Muscle.**—Schweigger incises the conjunctiva vertically, as well as the tissue of Tenon's capsule over the insertion of the muscle to be advanced. A hook, curved on the flat and with an olive point, is passed underneath the muscle and lifts it, exposing to view the entire tendon. A second hook is passed under the muscle in the opposite direction. One hook is pressed toward the corneal margin as far as the insertion of the tendon will permit, and the other one to that point where it is desired to insert the threads, thus exposing the muscle from 3 to 10 mm.

Two double-armed catgut threads are now prepared. One needle is passed under the upper edge of the muscle and pierces the same below the middle. The second is passed from the lower end and pierces the muscle above its middle. Each thread is then tied, thus including the entire muscle. The amount to be tied off is measured with a millimeter rule. That portion of the muscle between the catgut threads and its insertion is then resected. Then the two needles are passed through the insertion or stump of the muscle and superficially through the sclera. Both the threads are now tied and cut off and the conjunctival wound closed with silk sutures. The antagonistic muscle is always tenotomized before the sutures in the muscle to be advanced are tightened.

(e) **Prince's Single-suture Advancement.**—Dr. A. E. Prince has devised what he calls the "pulley operation." An anchor or pulley loop is made in the dense episcleral tissue about 1 mm. from the corneal margin. The sutures inserted into the muscle are passed through this loop, and, being fixed and solid, it affords an unyielding point of resistance. This method was later modified by its author to a single-suture operation, which is performed in the following manner:

A conjunctival incision is made over and parallel to the attachment of the tendon of the muscle to be advanced. The tendon is secured by an advancement-forceps (Fig. 408), separated from the sclera, and advanced, allowing the conjunctiva to retract. Two slender eye-needles (Tiemann No. 25) on either end of a No. 3 iron-dyed silk suture are passed from within outward, perforating the capsule, muscle, and conjunctiva at a variable point depending upon the amount of displacement to be effected, thus securing the middle portion of the muscle in a sling from which it can neither slip nor escape. With the exception of cases requiring a small amount of advancement of the muscle, as those in which the suture is used as a control to prevent an over-correction following a tenotomy, the portion of the tendon in the grasp of the forceps is excised about 2 mm. anterior to the sling. The sclera being now fixed, preferably with Critchett's short fixation-forceps, an unyielding anchorage in the form of a fibrous pulley is secured in

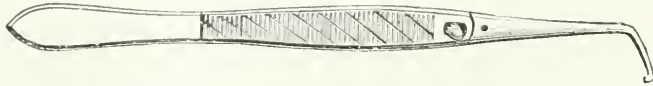

FIG. 408.—Prince's advancement-forceps.

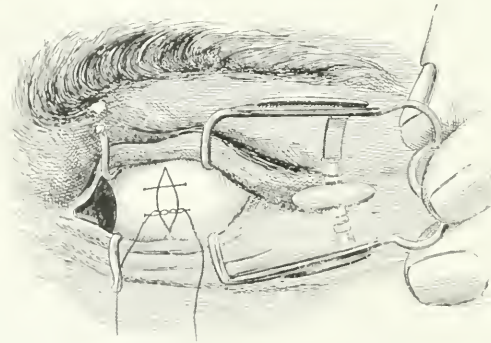


FIG. 409.—Prince's advancement.

line with the rectus by introducing either needle into the dense episcleral tissue 2 mm. from the sclero-corneal junction (Fig. 409).

Both ends of the suture are now brought together, forming the first portion of a surgical knot, and tightened to effect a slight over-correction. This suture is permitted to remain four days, unless it is desired to diminish the effect, which may be safely done after forty-eight hours by removing the suture and opening the wound with a small strabismus-hook. Tenotomy of the opposing muscle is made as in other operations.

This operation is better than the one first described by Dr. Prince, and gives very satisfactory results.



Dr. E. E. Holt has devised a somewhat similar operation.<sup>1</sup>

(*j*) **Landolt's Operation for Advancement.**—Landolt is a firm believer “in the incomparable superiority of the advancement of the muscle over its setting back.” He says: “There is more than one good method which leads to the same end. The essential point in all advancements consists in always bringing the muscle and its surrounding part as near the cornea as possible, and firmly fixing them there.”

After exposing the muscle the surgeon inserts two threads, one through the upper and one through the lower border of the muscle, more or less behind its attachment according to the effect desired. After division of the tendon the threads are passed under the superior and inferior borders of the cornea, and, when necessary, as far as its vertical diameter. The threads are then knotted, bringing the tendon forward toward the corneal margin. An assistant turns the eyeball in the direction of the muscle to be advanced. When resection of the muscle is necessary, allowance for this is made before the muscle is cut off, and then that portion of the muscle still adherent to the tendon is removed.

Landolt's argument for advancement is that “it causes the eye to enter its muscular investment, from which the tenotomy causes it to escape.” He does the operation in cases of strabismus in preference to tenotomy. Since advancement is so seldom followed by any reaction, he believes that it will come into more general use for strabismus.

The writer believes that this method of operating will be and should be more generally adopted. With the present aseptic precautions, it is no more dangerous than a simple tenotomy, although more difficult. The final cosmetic results will be more satisfactory. It better preserves the function of the muscle and prevents any advancement of the eye.

(*g*) **Stevens's Operation of Tendon-shortening or Advancement.**—Dr. Stevens's operation for advancement is as follows: The opening in the conjunctiva is the same as for tenotomy (page 589). Then, lifting the border of the conjunctiva nearest the cornea by the fine forceps, a little pocket is made by the points of the scissors or the lance-probe (Fig. 406, *D*), extending under the conjunctiva more or less toward the cornea in proportion to the greater or less effect which we propose to induce. The forceps seizes the central portion of the tendon, and it is dissected from the eyeball entirely or partially as the case may be. The fine tendon crochet (Fig. 406, *F*) or the fixation-forceps with catch now seizes the tendon behind the section and draws it forward through the conjunctival opening, when one needle on a double-armed thread is passed through the central portion of it from  $\frac{1}{2}$  to 1 mm. behind the cut extremity. The other needle is made to penetrate the conjunctiva at the extreme end of the pocket and the thread drawn through. Another thread is inserted in a similar manner a little to one side of the first, in order to allow between the two threads a little bridge of tissue. Now the surgeon draws upon the ends of the threads, forcing the cut end of the tendon into the little pocket, and fastens the threads by tying them across the little bridge. The sutures are removed on the third or fourth day.

**Choice of an Operation.**—The choice of an operation will depend much on the method one has practised or has seen practised. No one method has all the good qualities to recommend it, but, as all are intended to accomplish the same purpose, the surgeon can choose the one best suited to his own ideas. The method of resecting the muscle as performed by Schweigger, Noyes, and others produces excellent results. In this way the muscle is permanently shortened, and the cut end of the muscle attaches itself to the sclera at the point where the original insertion existed. It is not, however, always necessary to resect the muscle. In Noyes's operation the thread is passed underneath the conjunctiva of the severed muscle. It is probable that the Noyes operation is freer from the possibilities of danger than

<sup>1</sup> *Transactions of Am. Ophth. Society*, vol. iv. p. 123.



Schweigger's, owing to the deep insertion of the needle in the sclera in the latter. The former is the one the writer prefers, but he considers the two threads in the upper and lower edges of the muscle sufficient, without the use of the third or middle thread. In the limited space allowed it has been impossible to mention many of the operations devised by different surgeons. A choice had to be made from the many, and it has been done without any intended discourtesy to those omitted.

**IV. Advancement of the Capsule; de Wecker's Method.**—This operation is performed as follows:

A vertical incision as long as the corneal diameter is made through the conjunctiva over the tendon. The excision of a half-moon-shaped piece of conjunctiva is only necessary in very high degree of deviation. An opening in the capsule is made, and through this the hook is inserted from above downward. The hook is passed completely under the tendon until its point is free on the opposite side. At the same time the capsule is incised above and below. Next, two double-armed threads are employed in the following way: One end of the thread is passed through the incision in the capsule from the inner surface, so that it pierces muscle, capsule, and conjunctiva. The point at which the muscle is pierced is regulated by the effect to be produced. The other end of the thread is carried through the incision under Tenon's capsule forward toward the corneal margin, through the superficial layers of the sclera, until it emerges from the conjunctiva at the vertical meridian of the eye, about 5 mm. from the cornea. There the two threads are tied simultaneously by the operator and his assistant. A surgical knot is first made, and when the eye is in position the double knot is completed. The conjunctiva is then closed by three sutures.

Knapp modifies this operation by the use of a third, middle suture passed through the equatorial flap of the conjunctiva, through the tendon (which was held up, drawn forward, and folded with a squint-hook), underneath the squint-hook, and through the episcleral tissue and the flap of conjunctiva near the cornea.

Advancement of the capsule is inferior to the advancement or resection operations described above. It leaves, for a while at least, an ugly knot or elevation under the conjunctiva, and its final results are not as certain and free from danger as other methods.

**Accidents and Complications.**—*Subconjunctival hemorrhage* is more or less abundant in every case of tenotomy or advancement, but it is readily absorbed and needs no treatment other than the use of hot fomentations.

*Retrolbulbar hemorrhage* or *hemorrhage into Tenon's capsule* occurs occasionally. It is not likely to lead to serious results, but may vitiate the immediate effects of the operation. A compress-bandage should be applied over the eye, and on this ice-d compresses laid and changed frequently. Retrolbulbar hemorrhage may be caused by vomiting during anesthesia.

*Granulations* occasionally spring from the incision in the conjunctiva. They are readily controlled by snipping them off with scissors close to the sclera or touching them with a crystal of copper sulphate or alum. Dr. Noyes reports a case where diphtheritic inflammation attacked the wound after a strabismus operation, and resulted in divergence.

*Ulceration of the margin of the cornea* from the end of the thread, which was cut off too long, occurred in the experience of the writer. It was promptly relieved by cutting off the thread. The breaking of a thread during an advancement operation is a very uncomfortable accident. It should be avoided by carefully testing the thread, which should be strong enough to stand the traction.

*Panophthalmitis* and *orbital inflammation* have been known to follow advancement operations, but the occurrence is extremely rare. *Perforation of the sclerotic* during the operation for strabismus occurs occasionally, even

in the hands of the most skilful operators. Cases are reported by Drs. Hasket, Derby, Knapp, E. Williams, and others. Panophthalmitis has followed this accident.

Instruments and dressings for an ordinary tenotomy of one of the recti muscles are—a spring speculum, two pairs of fixation-forceps (Fig. 410), two strabismus-hooks (Fig. 411), the one smaller than the other, two pairs of scissors, one curved (Fig. 412) and one straight (Fig. 413), a needle-holder (Fig. 414), and two or three needles threaded with fine black silk which



FIG. 410.—Fixation-forceps.

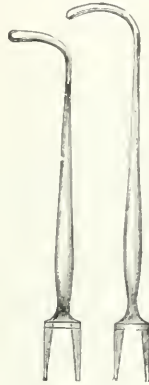

FIG. 411.—Strabismus-hooks.

has been waxed, absorbent cotton sponges, and dry absorbent cotton, fine gauze bandages, and a compress.

As the cornea becomes dry during exposure from the influence of cocain,

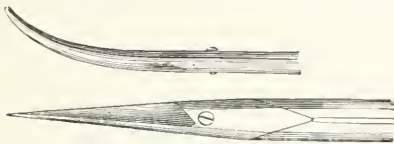


FIG. 412.—Curved scissors.



FIG. 413.—Strabismus-scissors.

it is well to have a dropper and some sterilized water in a glass dish close by, so that the cornea can be moistened in case it is necessary.

For advancement operations, in addition to the above, it is necessary to

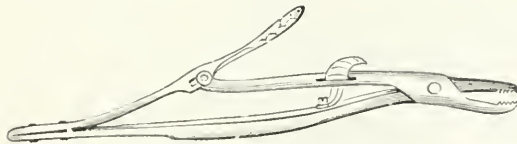


FIG. 414.—Needle-holder.

have long black silk thread or catgut sutures, armed with two or three needles, as described in the various methods devised by different operators.

Local anesthesia by cocain is much more desirable than general anesthesia, for the reason that the effects can be at once tested and any under- or over-correction remedied; but in children it may be necessary to administer an anesthetic. It is especially desirable to operate for advancement under cocain, for we want the aid of the patient to determine the effect produced. Eucain is recommended by Silex in squint operations.

## OPERATIONS UPON THE LACHRYMAL APPARATUS.

BY SAMUEL THEOBALD, M. D.,

OF BALTIMORE, MD.

**Removal of the Lachrymal Gland.**—This may be accomplished by either of two procedures :

The gland may be exposed by an incision through the integument of the upper lid parallel with the orbital margin, drawn out by means of a tenaculum and, with a knife or scissors, separated from its attachments. The objection to this method is that it involves a more or less complete division of the levator palpebræ superioris muscle, which may result in the production of ptosis.

The other, and probably better, plan, suggested by Velpeau, is to divide the external canthus, evert the upper lid, and cut down upon the gland from the superior conjunctival cul-de-sac. This method does not endanger the integrity of the levator muscle, and leaves a less conspicuous scar than the first-described procedure.

**Bowman's Operation for Fistula of the Lachrymal Gland.**—The purpose of this operation is to convert an external, cutaneous fistula into one opening into the conjunctival sac, and hence causing little or no annoyance.

A threaded needle is passed a short distance into the fistula, and is then made to transfix the lid, being brought out upon its conjunctival surface. A second needle, upon the other end of the thread, is next passed through the lid at a point close to the orifice of the fistula. The two ends are then tied tightly, and the thread is left to cut its way out. To promote the closure of the external fistula its edges are freshened.

**Division of the Canaliculus.**—In performing this operation it is important that the edge of the knife should not be inclined forward ; otherwise a slight perceptible deformity will result, and, besides, the position of the divided canaliculus will not be the most favorable for carrying off the tears. Weber's beak-pointed canaliculus-knife (Fig. 415), or the modification of it shown in Fig. 416, is usually employed.



FIG. 415.—Weber's beak-pointed canaliculus-knife.



FIG. 416.—Probe-pointed, straight canaliculus-knife.

The operator should stand behind the patient, letting the patient's head (covered with a napkin) rest against his chest, the left hand being used for the left eye and the right hand for the right eye. The lid being kept upon the stretch with the thumb of the opposite hand, the probed tip of the canaliculus-knife is introduced vertically into the punctum (which, together with the canaliculus, should have been dilated previously by the passage of one or two of the smallest-sized probes), and then, the direction of the knife having been changed, it is passed horizontally along the canaliculus until its progress is arrested by the inner wall of the lachrymal sac (Fig. 417). This point having

been reached, and the edge of the knife being directed upward or upward and slightly backward, the lid being kept still on the stretch, the canaliculus is divided by simply elevating the handle of the knife. If the operation is done as a preliminary step to the introduction of lachrymal probes, the canaliculus should be divided well up to its juncture with the sac; but if done for some other purpose, such as eversion of the punctum or stricture of the canaliculus, it may not be necessary to carry the division quite to this point.

The edges of the divided canaliculus usually show for several days a disposition to grow together, and to overcome this they must be separated every day or every other day by the passage of a greased probe. A few instillations of cocain render the operation of division of the canaliculus almost painless.

The foregoing description applies especially to division of the lower canaliculus; but the upper canaliculus, which, in the writer's experience, seldom needs to be divided, may be operated upon by essentially the same procedure.

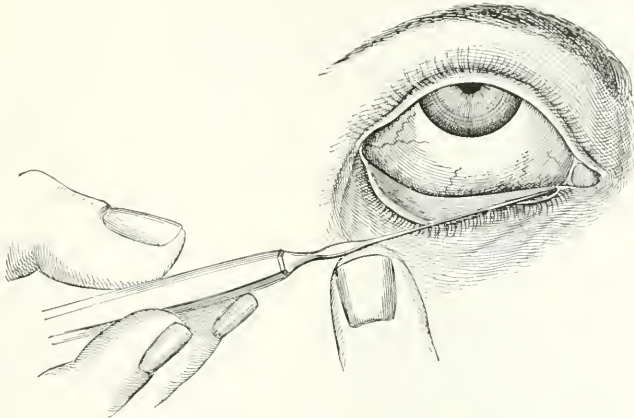


FIG. 417.—Passage of canaliculus-knife.

**Excision of the Lachrymal Sac.**—Owing to the delicate structure of the walls of the sac, this is not an operation easy of performance.

A vertical incision of sufficient length is made through the skin and the internal palpebral ligament down to the sac, which is then dissected out as carefully and completely as possible with a scalpel or a pair of blunt-pointed scissors. After this the cavity left by the removal of the sac and the upper part of the nasal duct are scraped with a sharp spoon, and, the wound having been cleansed with an antiseptic solution, the edges of the incision are closed accurately with stitches and a suitable aseptic dressing applied.

#### **Destruction of the Lachrymal Sac by Caustic Agents, etc.**—

Destruction of the lachrymal sac by the actual cautery is an operation of classical origin, having been practised by the Romans nearly two thousand years since. In more recent times the obliteration of the sac has been effected by the use of caustic agents, such as nitrate of silver, chlorid of zinc, nitric acid, Vienna paste, caustic potash, etc., and still more recently by the thermo-cautery and the galvano-cautery. The merit claimed for this procedure (and also for excision of the sac) is that it not only relieves the patient of the dacryocystitis and its unpleasant consequences, but that in some cases it cures the epiphora through the inhibitory influence which it appears to exert upon the activity of the lachrymal gland.

The usual method of performing this operation is to make a free incision into the sac through the external integument and the palpebral ligament, and through this to introduce the caustic or the tip of the galvano- or thermo-cautery, a Manfredi's speculum being employed to protect the lips of the incision.



**Introduction of Lachrymal Probes.**—Small probes are sometimes passed through the undivided canaliculus (to overcome occlusion of the puncta, etc.), but division of the canaliculus always precedes the passage of probes for the cure of occlusion of the nasal duct. Cocain lessens, but does not entirely do away with, the pain. It should always be used, however, and the probe should be anointed with vaselin containing 10 : 100 of cocain.

The writer prefers to stand behind the patient, using the left hand for the left eye and the right hand for the right eye, as in division of the canaliculus, since the patient's head can be more easily steadied in this position. The probe is passed horizontally along the canaliculus, the lid being kept upon the stretch with the thumb of the opposite hand, until its point comes in contact with the inner wall of the lachrymal sac; it is then turned into a vertical position and passed slowly through the duct until the floor of the nose is reached (Fig. 418). No especial difficulty attends the introduction of the large probes commended by the writer, provided they are properly constructed. It is of the first impor-

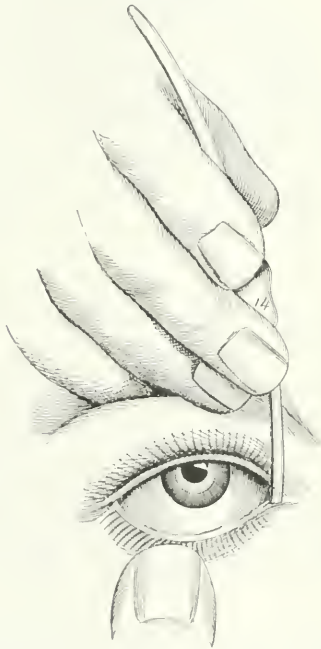


FIG. 418.—Introduction of lachrymal probe.

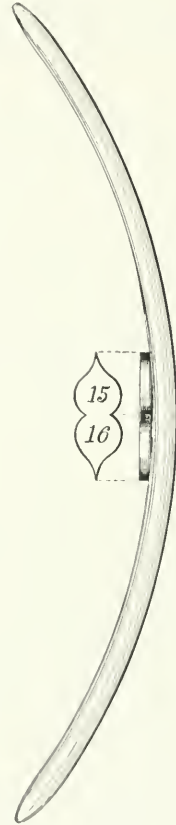


FIG. 419.—Theobald's lachrymal probe.

tance that their tips should not be too square and blunt. The accompanying illustration (Fig. 419), which represents the actual size of the largest probe of the series, Nos. 15 and 16, shows the proper shape of the ends as well as the curve which has been found most convenient.

## OPERATIONS ON THE ORBIT.

By F. BULLER, M. D.,

OF MONTREAL, CANADA.

ALL operations on the orbital tissues should be performed in accordance with the strictest principles of antiseptic surgery. Even when septic conditions are present, they will in this way be favorably modified; if absent, the surgeon will himself be to blame if they follow his manipulations. It will not be sufficient to take these precautions merely during the operation. Every time the wound is dressed, and until healing has been fully accomplished, the same vigilance is imperative. The momentary use of an unclean probe may inflict more injury than the disease would have done if left to itself.

**Abscess of the Orbit.**—If an *abscess* has formed in the orbit, there should be no unnecessary delay in opening it. For this purpose a straight, narrow bistoury may be used, the incision being made at the point of greatest tenderness and swelling, or, if there be fluctuation, where this is most distinct, close to and parallel with the margin of the orbit. There need be no hesitation about thrusting the point deeply into the orbit, but only the external wound should be wide. An opening in the skin and oculo-orbital fascia half or three-quarters of an inch in length is desirable to relieve tension, unload engorged blood-vessels, evacuate pus if present, and facilitate keeping the wound open as long as may be necessary.

This is best done with a tent of borated gauze or lint inserted after thorough cleansing with some warm antiseptic solution, such as a 1 per cent. solution of pheno-salyl or any other that the surgeon may prefer. Compresses of sterilized gauze soaked in warm solution of sublimate 1 : 5000 or boric acid 3 per cent., frequently changed, are to be used till the inflammatory symptoms subside. The wound itself and the eye must be thoroughly cleansed at least two or three times daily. In severe cases of phlegmonous inflammation of the orbit early and free incision before the formation of pus, both above and below, conducted on the same principles, may be the means of saving the patient's vision or even his life.

**Enucleation of the eyeball, eviscerations, and Mules's operation** are described on pages 571–573.

**Introduction of an Artificial Eye** (*Prothesis Oculi*).—An *artificial eye* should be inserted as soon as the tissues are firmly healed and are able to bear the shell, which is usually from ten days to one month after the operation.

In order to insert an artificial eye the upper lid is seized between the fingers of the left hand and drawn gently down and out, and the larger end of the shell is inserted vertically beneath it, then brought to a horizontal direction, while at the same time the lower lid is pulled down, when the shell slips into place. In order to remove an artificial eye the head of a large pin is inserted beneath its lower margin, the lower lid being at the same time

depressed, while the eye is tipped upward and forward, when the pressure of the upper lid will force it out. Very soon patients become exceedingly expert in taking out and introducing artificial eyes, and do not require the aid of a pin in making the manipulation just described.

Until the tissues become accustomed to the artificial eye it should not be worn constantly, and should never be allowed to remain in the socket at night. If the enamel of the shell becomes rough, a new one should be substituted. If the socket or the stump upon which the eye rests becomes irritable or inflamed, the shell should be removed and the tissues treated with antiseptic lotions and mild astringents until they recover their healthy condition. It should be remembered that badly fitting artificial eyes have occasioned sympathetic inflammation.

**Operations for Prosthesis in Cases of Cicatricial Orbit.**—Under certain circumstances, particularly after lime-burns and trachoma, contraction of the conjunctival sac and the formation of cicatricial bands may render it impossible for the patient to wear an artificial eye. A number of operative procedures have been devised to overcome these difficulties, but the results have been confessedly disappointing. Incisions made to admit the shell always close by cicatrization, and, if anything, increase the contraction. A few successes have followed transplantation of the conjunctiva of a rabbit, the skin of a frog, or Thiersch's graft. Operations based upon the principles of blepharoplasty (page 555) have also been tried.

**Harlan's Operation.**<sup>1</sup>—In a case of cicatricial contraction of the cul-de-sac after enucleation Dr. Harlan proceeded as follows: "A heavy lead wire was inserted beneath the cicatricial bands and passed around the bottom of the cavity, and the ends brought together to form a ring. Way was made for the wire with a pair of fine sharp-pointed scissors curved on the flat, and it was inserted behind the lower band, brought out at the outer canthus, reintroduced, and passed in the same way above. The wire was worn for about two months, when it was cut down upon, its track found cicatrized, and the upper sulcus satisfactory. The lower sulcus was deepened by reintroduction of a wire. A thin leaden shell, formed so that its edges would rest where the wire had been, was afterward introduced and left in position constantly, except when the orbit was cleansed with boric-acid solution. After the lead shell had been worn for a few weeks, an artificial eye could be worn without difficulty."

**Exenteration of the orbit** is performed as follows:

The eyeball, if present, is to be removed in the ordinary way. Then the outer canthus is divided to the orbital margin, the lids drawn strongly upward and downward respectively, and the soft tissues back of them and the periosteum just within the orbital circumference divided with a scalpel. A strong pair of curved scissors is now used to peel off the entire periosteum to the apex of the cavity, where the whole mass is detached by means of a rounded raspatorium guided by the forefinger of the left hand. Bleeding from the ophthalmic artery, if considerable, may be checked by pressure with the finger, or by the use of Paquelin's cautery. When bleeding has ceased, the writer applies a thin layer of chlorid-of-zinc paste, spread on lint, to the shreds of tissue left in the spheno-maxillary fissure and apex of orbit, packs the cavity lightly with iodoform gauze, and applies a retention bandage. This dressing may be allowed to remain for several days.

If the malignant growth for which exenteration is proposed has involved the skin of the lids, these may require to be removed more or less widely, as well as the orbital structures. The gaping cavity thus produced may at the same operation be greatly diminished by sliding flaps of skin from the neighborhood in such a way as to partly conceal the deformity, or by Thiersch grafts.

**Removal of Tumors from the Orbit.**—The most suitable method of dealing with *orbital cysts* has already been mentioned (see page 531).

<sup>1</sup> *Trans. Amer. Ophthalm. Soc.*, 1897, vol. viii, p. 63.

For *neroid* or *erectile tumors electrolysis* gives the best results in young subjects, and may be repeated as often as necessary, every two or three weeks.

The most rapid effect is obtained by introducing two platinum needles, one for each pole. If the growth is large, the needle should be two or three inches in length. The skin is protected by coating the distal half of the needle with collodion. During the operation the needle attached to the positive pole is first introduced to the desired depth and held *in situ*. The negative needle is made to penetrate the tissues in several places around this, in each of which it is held in position for two or three minutes. There is some danger of injury to the optic nerve if the needles are passed deeply into the orbit.

General anesthesia is required, and, as reaction may be severe, it is best not to attempt too much during one sitting.

In adults these tumors may be partly, or, if encapsulated, completely, excised, and in some cases the *electric cautery* or *thermo-cautery* may with advantage supplement the knife and scissors.

*Osteoid growths* springing from or involving the roof of the orbit may be removed, but the operation is somewhat difficult and decidedly dangerous. A large percentage of such cases have died from consecutive intercranial disease—abscess or meningitis. Many of these, however, date from pre-antiseptic days. If the bony growth belongs to the inner or inferior walls, the danger is much less.

The growth must be exposed as freely as possible by suitable incisions of the soft parts covering it, including the periosteum, which must be carefully detached. Then the base of the growth is attacked with hammer and chisel, cutting the bone with tiny rapid strokes until the mass is detached.

The ivory-like masses which sometimes project into the orbit from adjacent cavities may be detached and "shelled out" by cutting completely through the normal bone immediately around them: when thus isolated they may be lifted out of the cavity with suitable forceps—a procedure which does not require much force in the absence of firm, deep attachments.

Tumors of the orbit which are extensively adherent to the globe or infiltrate the surrounding tissues cannot be removed without sacrificing the eyeball; for these the operation requires no special description.

In all other cases an attempt may be made to spare the eyeball. In any doubtful case the surgeon should have an understanding that he may sacrifice the eyeball if necessary.

*Tumors of the optic nerve* may be reached by a vertical wide incision of the conjunctiva over the inner side of the globe, detachment of the internal rectus tendon, which is to be secured and identified by a black silk thread, and held out of the way by an assistant. With the closed blades of curved scissors the tissues are to be separated down to, along, and around the growth quite to the apex of the orbit. With a strabismus-hook passed around the nerve at this point as a guide, use the scissors to cut the nerve close to the foramen. Then with small vulsellum-forceps bring the growth forward, reversing the globe, and detach close to the sclerotic. Bleeding must be arrested by pressure with the fingers or hot-water injections, and the parts irrigated with perchlorid solution 1:3000 before the tendon and conjunctiva are sutured into place.

Tumors outside the muscle-funnel are to be reached by free incision parallel to the orbital margin over the most accessible part of the tumor, doing all the deep dissection, if possible, with the closed scissors-blades or handle of the scalpel. Many growths may be successfully "dug out" in this way, with very little loss of blood or injury to the surrounding parts. All bleeding must be arrested before the wound is closed with fine silk sutures, and dressed antiseptically, with suitable provision for drainage.

*Krönlein's Operation.*—Tumors situated far back in the orbit may be exposed to view and removed without sacrificing the eyeball by a method devised by Krönlein, in the following manner: A crescentic incision is made around the outer circumference of the orbit. The periosteum is then divided at this part to a similar extent, and freely detached from the outer wall of the orbit as far as may be necessary. A temporary resection of a wedge-shaped portion of the orbital wall can then be made. The base of the wedge corresponds to the outer orbital margin, its apex to the anterior extremity of



the inferior orbital fissure. To accomplish this the zygomatic process of the frontal bone is chiselled through, as well as the intervening bone between this and the fissure, near its anterior extremity. In the same way the base of the orbital process of the malar bone is divided, and this second incision through the bone is continued backward to the fissure. The loosened portion of bone, together with the tissues attached to its external surface, may now be drawn toward the temple to such an extent that the orbit is freely exposed at its outer side, and a growth even at the apex is rendered quite accessible, and may be readily removed. After this has been accomplished the triangular flap of bone is replaced, the skin-wound united with sutures, and a suitable dressing applied.

It is said that recovery is complete in eight or ten days. The operation is neither difficult nor dangerous, and would seem to merit greater favor and have a wider range of application than it has yet received. It will be found useful in the extirpation of deeply-seated orbital tumors, as an exploratory operation in some doubtful cases of exophthalmos, and is an efficient means of relief in violent phlegmonous inflammation of the orbit. Should the exposed orbit be found in such a condition that complete exenteration is deemed advisable, this may be done at the same sitting.

**Distention of the frontal sinus**, if recent and of a purulent character, may be relieved by a free opening through its lower external (orbital) wall and subsequent drainage through the same aperture; but in chronic distention (mucocele), the cavity or cavities having become much wider than in their normal state, simple incision will not suffice. Under these circumstances the surgeon proceeds as follows:

The orbital wall must be so freely removed that the little finger can be passed into the cavity after its thorough evacuation by syringing with some warm antiseptic solution. The little finger of the other hand or a strong probe is to be pushed up the nostril to a point where the finger in the sinus can be felt. Then an aperture of considerable size is to be made with a sharp scoop at this point, and a drainage-tube carried through from the orbit and worn until the discharge has ceased or the cavity has sufficiently contracted to justify its removal. Thorough cleansing at least twice daily must be practised for weeks or months to achieve this end.

This operation has the disadvantage of almost certainly injuring the pulley attachment of the superior oblique—an accident which may be avoided by making an opening with chisel or trephine in the forehead, a little to one side of the median line, and the counter-opening into the nose in the manner just described.

The opening in the forehead may with advantage be sufficiently enlarged to include the entire anterior wall of the sinus; but the disadvantage of this method is the somewhat unsightly resultant scar.

**Orbital fistula**, if found to extend into the frontal sinus, will heal when the sinus has been dealt with after one or other of the foregoing methods; that is, after the sinus has been effectually drained into the nose.

Should the fistula be found to lead into the ethmoidal cells, a free opening may be made down to these parts along the fistulous tract, and any accumulated secretion or other inflammatory debris removed by syringing and the gentle use of small euettes. A drainage-tube should then be inserted, and the cavity kept clean by daily syringing until healing takes place. This treatment may be required for several months. Gruening has effected cure of a fistula leading to the ethmoid cells by forcing, with a strong probe, an opening through the base into the nasal cavity, thus facilitating drainage through the nose.

## APPENDIX.

### THE METHODS FOR DETECTING COLOR-BLINDNESS, WITH SPECIAL REFERENCE TO THE EXAMINATION OF RAILROAD EMPLOYÉES.

BY J. ELLIS JENNINGS, M. D.,

OF ST. LOUIS, MO.

MANY PERSONS suppose that all that is required to test the color-sense of railroad employé is to display the flags and lanterns used as signals and demand the name of the color exposed.

The experienced observer knows, however, that many color-blind subjects can name colors correctly; hence, any test to be effectual must ascertain, not whether the employé can name colors correctly, but how he sees them, and whether he can safely be trusted to distinguish between the various signals on all occasions. We determine this, first, by making him pick out and place together those colors which appear to him to be the same, and second, by having him recognize colors at a distance under various degrees of illumination, thus simulating, as far as possible, the various atmospheric conditions under which railway signals may present themselves.

**Holmgren's Method.**—The set of worsteds consists of three large test-skeins: (1) *light pure green*; (2) *rose (purple)*; (3) *red*, and of about one hundred and fifty small skeins of the following colors: red, orange, yellow, yellow-green, pure green, blue-green, blue, violet, purple, pink, brown, gray, including several shades of each color and at least five gradations of each tint from the deepest to the lightest.

**First Test.**—The worsteds are placed in a confused heap on a large plane surface in a good light, and the *light pure-green* test-skein laid a little to one side. The candidate is now requested to pick out those skeins most resembling it in color and place them by the side of the sample. The examiner must explain that there are no two skeins exactly alike, and that an endeavor must be made to find something similar of a lighter or darker shade. The candidate is not to compare narrowly or to rummage much among the heap, but to select with his eyes, and to use his hands chiefly to change the position of the selected skeins.

A person with a *normal color-sense* will pick out the lighter and darker shades of green rapidly and without hesitation. He may, perhaps, include in his choice a few green skeins inclining to yellow or blue; but this is no evidence of color-blindness, but rather of a lack of practice with colors.

The person *completely color-blind*, whether to red or green, will select, with or without the greens, some confusion colors—grays, drabs, stone-colors, fawns, pinks, or yellows.

The person *incompletely color-blind*, or with a *feeble chromatic sense*, will add to the selection of greens one or more light fawns or grays; or he may pick out a skein, hesitate, add it to the greens, and then withdraw it, and so on. When confusion colors have been selected the examiner knows that the candidate is either completely or incompletely color-blind. In order to determine its nature and degree a second test is employed.

**Second Test.**—The worsteds are mixed again, and the large *rose* test-skein is laid to one side. The candidate is requested to pick out all the lighter and darker shades of this color; if color-blind he will always select deeper colors. Those subjects who by the first test were found to have a *feeble chromatic sense* will make no mistakes in this test. Those who are *incompletely color-blind* will match the rose with deeper purples. The *completely red-blind* candidate will select blue or violet, either with or without

purple. The *completely green-blind* subjects take green or gray or one alone, either with or without purple. The *violet-blind* subjects (rare) show a strong tendency to select blue in the first test, and red and orange, either with or without purple, in the second test. As this examination has decided the character and degree of the defect, it is not necessary to resort to the third test; but as the red skein used corresponds to the danger-signals, it may occasionally be of value in convincing the officials that the candidate is unfit for duty.

**Third Test.**—The sample for this test is a skein of *bright red*, to be used in the same way as the green and rose. The *red-blind* subjects select, besides the red, green and brown shades darker than the red. The *green-blind* subjects select green and brown shades lighter than the red. Only marked cases of color-blindness will show their defect with this test.

**Thomson's Method.**—This consists of two different sets of worsteds, which are kept apart in a double box. The *first set* consists of a large *green* test-skein and twenty small skeins, each marked with a bangle having a concealed number extending from one to twenty. Among these numbers the odd ones are different shades of green, while the even numbers are grays, light-browns, etc. The *second set* consists of a large *rose* test-skein and twenty small skeins, which are numbered from twenty-one to forty. Here the odd numbers are different shades of rose, while the ten even numbers consist of blues, greens, and grays.

In testing the worsteds are taken from the green part of the box and placed upon a table in a confused mass. The candidate is requested to select ten tints to match the large green skein. When this is done and the numbers recorded on a blank, the worsted is removed and the examiner proceeds with the second set.

**Author's Method.**—Realizing that any test which is limited to a small number of match and confusion skeins curtails the choice and makes the defect more difficult to discover, the author has endeavored to combine the good points of Holmgren's and Thomson's methods. The set consists of five large test-skeins: *light pure green*, *rose*, *red*, *blue*, and *yellow*, and eighty-four small skeins, each marked with a bangle having a concealed letter and number. The letter denotes the color, and the number (1 to 6) denotes the shade. For example, A1 indicates the lightest shade of pure green; K6, the darkest shade of brown.

The examination is conducted in a manner similar to the Holmgren method, with the addition of the blue and yellow tests. A record of one test is made before proceeding to the next. In matching the *blue* skein the color-blind person first takes the darkest shades of blue, and then adds the rose skeins, because he recognizes the blue in the mixture of red and blue. In matching the *yellow* he adds all the green skeins that have yellow in them.

**Pseudo-isochromatic Plates of Stilling.**—The remarkable facility with which the color-blind distinguish colors to which they are blind is due to an acute sensitiveness to differences in tint and intensity of light. In the pseudo-isochromatic plates Stilling seeks to deprive the color-blind of any aid in matching colors by selecting those which appear identical not only in tint, but also in intensity of light. On a colored surface of convenient size he painted a spot of the color mistaken for it; he then toned or modified this spot until the color-blind eye could not distinguish between the spot and the surface. Stilling then constructed ten plates, each plate containing four squares filled by small, irregular colored spots, among which other spots in a confusion color, made to conform to an Arabic figure, are placed. The test-plate is held in a good light and the candidate required to distinguish the tracings. An important feature of this test is that there is no inquiry as to color.

**Lantern-test.**—An ordinary switch lantern with a four-inch opening should be so arranged that pieces of colored glass can be placed in front of the light. The colors to be used are standard red, yellow, pure light-green, standard green, blue, and purple. The luminosity of the light can be varied by having at hand pieces of white (ground), ribbed, and different thicknesses of London-smoke glass. As red and green appear to the color-blind as one and the same color, only lighter or darker than the other, it is easy to deceive him by changing the luminosity of the light without altering its color. This can be done by diminishing the light or by placing pieces of ground or London-smoke glass before the colored light. The candidate should be seated at a distance of fifteen feet from the lantern, and, according to Dr. Edridge-Green, should be rejected—(1) if he calls the red green or the green red under any circumstances; (2) if he calls the white light under any circumstances red or green, or *vice versa*; (3) if he calls the red green, or white light black, under any circumstances.

**Quantitative Estimation of the Color-sense.**—The lantern may also be used to make a quantitative estimation of the color-sense by placing in front of the light a metallic slide with perforations ranging from one to twenty millimeters in diameter.

Having tested and recorded the average size of the opening required by the normal eye to distinguish each color at fifteen feet, the candidate is placed at this distance and is asked to name the colors. If he recognizes them through the one-millimeter opening, his color-sense is normal =  $\frac{1}{1}$ . If an opening of twenty millimeters is needed, his color-sense =  $\frac{1}{20}$ . If he fails to recognize the color through the largest opening, he is told to approach the light slowly, and if he sees it at three feet, his color-sense =  $\frac{1}{100}$ , etc.

Oliver's apparatus is designed to test the color-sense of employes upon the railway-grounds at a distance of 1000 feet. It consists of twenty-three shallow open wooden boxes, painted dead black, containing colored bunting placed upon a horizontal beam 15 feet from the ground. Arranged above the middle of these boxes is a large revolving box with five partitions for the test-colors. The pure-green test-color is displayed, and the candidate, employing one eye at a time, is asked to write upon a piece of paper the number of the color in the lower row (going from left to right) that to him is the nearest match to the upper color. This experiment is repeated with the other test-colors. If the apparatus is to be used at night, transparent colored glass is substituted for the colored bunting.

**Chibret's Photometer.**—An examination for color-blindness is not complete without making a test of the light-sense (see page 154). The most accurate instrument for this purpose is Chibret's photometer.

The candidate faces the window and looks with one eye into a tube, where he sees two equally bright disks. The eye-piece is now turned until he can detect a difference in the illumination of the two disks, when the *light-difference* is indicated on the scale. A normal eye recognizes the difference within five degrees. The *light-minimum* is measured by making one disk entirely dark, and then turning the eye-piece until he perceives the disk coming from the darkness. The scale should not register more than one or two degrees (see also page 152).

### THE DISPOSITION OF THE COLOR-BLIND.

Having ascertained that the color-sense of an employe is defective, the surgeon must decide whether the defect is of such a nature as to warrant his discharge, or whether he can with safety be allowed to retain his position. If the person in question is an applicant for employment, even a slight defect of the color-sense should be sufficient ground for rejection. If, however, we have to deal with an old employe, one who, perhaps, has discharged his duties in a satisfactory manner, justice demands that his interests be studied so far as is consistent with safety. Every case of *complete red- or green-blindness* should be dismissed. Those who are *incompletely* color-blind, and in the first test merely confound gray with the sample color, may be retained if the *visual acuity* and *light-sense* are normal.

---

## STANDARDS OF FORM AND COLOR-VISION REQUIRED IN RAILWAY SERVICE.

By A. G. THOMSON, M. D.,  
OF PHILADELPHIA.

LAWS regulating the examination of railroad employes for form- and color-vision have been adopted in several States, but there is no official standard established by the United States Government for such examinations as exists in Continental countries. The State undertakings in this behalf have not been uniformly successful, as witness the experiment tried some years ago in Connecticut by which scientific experts were to be appointed by the governor and paid by the railroads. This undertaking proved a failure, as the railroad officers would not submit their employes to the scrutiny of State officials, who, by adopting their own standards, could practically discharge perhaps 15 per cent. of the railroad employes, disturb the discipline, and impair the organization of the roads.

As most of the large railroad lines run through several States, to save complications which may arise out of separate State legislation it is found more expedient for the cor-



porations to make their own rules and regulations for examination of their employés, using their own methods and appointing their own examiners.

It is found impracticable for corporations, owing to the large force of ophthalmic surgeons it would require, to study the refraction and make the examination as scientific as, from a medical point of view, is admittedly desirable. So it is, therefore, the endeavor of the railroads to devise and establish a general system of examination for protection of the public and its property that can be put in force by a division superintendent, acting through an intelligent assistant, under the general supervision of an ophthalmic surgeon. To this supervising surgeon all information collected could be transmitted, and he would thus be enabled to decide all doubtful cases and to protect the railroad from any danger arising from incapable employés, and at the same time to save good and faithful men from being discharged from the company's service without sufficient cause.

Such a system has been perfected by Dr. William Thomson, authorized by the Pennsylvania Railroad Company since 1880, and has been adopted by other roads from time to time, until it is protecting an aggregate total mileage to-day of over one hundred thousand miles. This system has been, as here indicated, subjected to the test of experience, and has proved very satisfactory.

**Visual Acuity.**—The standards of form-vision in Continental countries and also in this country vary from  $\frac{20}{XX}$  in one or both eyes to  $\frac{20}{XX}$  in one and  $\frac{20}{L}$  in the other, in the first class—that is, for employés on the head end of an engine, while in Class II, representing the yard and train service, the range is anywhere from  $\frac{20}{XX}$  in one to  $\frac{20}{CC}$  in the other.

A railroad should require for its safety two standards for entrance into its service: The standard of Class I, representing engineers, firemen, and towermen, should require  $\frac{20}{XX}$  in one eye, and not less than  $\frac{20}{XL}$  in the other—vision taken separately without glasses.

Hyperopia over 2 D. should ensure rejection—astigmatism being eliminated. This can be readily ascertained by placing a trial frame containing 2 D. spherical-lens, before the patient, and if he has with these lenses full acuity of vision, the optical defect is demonstrated. This practical test saves many complications, as a man may enter the service as a young man with strong accommodation, and when he becomes a skilled engineer, at the presbyopic age, he will not have vision sufficient to reach the standard.

Periodic examinations should be made at intervals of five years, or after an injury which may in any way affect the vision, and also after serious illness and on promotion.

The standard of Class II, representing trainmen, conductors, brakemen, switchmen, and yardmen, should require  $\frac{20}{XX}$  in one and not less than  $\frac{20}{LXXX}$  in the other eye, with or without glasses, and the same rules regarding re-examination apply to them.

Old employés not reaching the proper standard of the class to which they belong on re-examination should be corrected and required to use glasses if they be permitted in that class or transferred to other duties.

**Color-sense.**—The color-sense is requisite to enable any employé to govern his actions by day or night by colored signals.

The standard should require three points:

I. Test with colored signal-flags.

II. Test by comparison of colored worsteds—Holmgren's, Thomson's, Williams's, or Oliver's.

III. Test with colored light.

I. *Test with Colored Flags.*—The man subjected to this test should recognize four flags, one of each color, red, white, green, and blue, and, at a distance of twenty feet, tell their color and meaning. A colored flag should also be given him to match with worsteds.

II. *Test by Comparison of Colored Worsteds, Matching their Colors without Telling their Names.*—Here one of the recognized tests should be used—Holmgren's or some modification of this test. Holmgren's test consists in testing the power of the person to match various colors which are conveniently used in the form of colored yarns. About one hundred and fifty tints are employed in confused mixture, and three test-colors—viz. light-green, rose-purple, and red—are placed in order before the person examined, who is directed to select similar colors from the mass. By this manner the examiner can judge whether selections are correct or not from the prompt or hesitating manner in which the selection is made.

Tests which are modifications of this, as, for example, Thomson's stick-test, are much simpler and more expedient for use on railroads.

III. *Test with Colored Light.*—The ordinary railway-lanterns of different colors may be used.

If the employé be found defective in his color-sense, he will undoubtedly be detected by these tests. He is then allowed to go before the ophthalmic expert for final examination, who may use any other confirming test he may choose.

It is to be remembered that this is not an official standard—simply the requirements to operate a railroad without danger to the public and destruction to property.

## THE RÖNTGEN RAYS IN OPHTHALMIC SURGERY.

BY WILLIAM M. SWEET, M. D.,

OF PHILADELPHIA.

WITH the development of improved methods of generating and employing the Röntgen rays speedy and accurate means have been furnished by which not only the presence of a metallic body in the eye may be determined, but also its exact position. The early employment of the new form of radiant energy in experiments on animals' eyes gave little promise of the successful application of the method in ophthalmic surgery until Charles H. Williams of Boston and C. F. Clark<sup>1</sup> of Columbus, Ohio, each reported a case of the removal of a piece of metal from the living eye which had been previously located by the rays. Shortly afterward Max J. Stern, at the Philadelphia Polyclinic, located metallic bodies in the vitreous in four cases, and demonstrated the possibility of obtaining shadows on the photographic plate of foreign bodies situated in any part of the eyeball or orbit.

**Practical Application of Rays.**—While numerous methods have been suggested and employed for determining the exact position of the body in the eye, the writer has

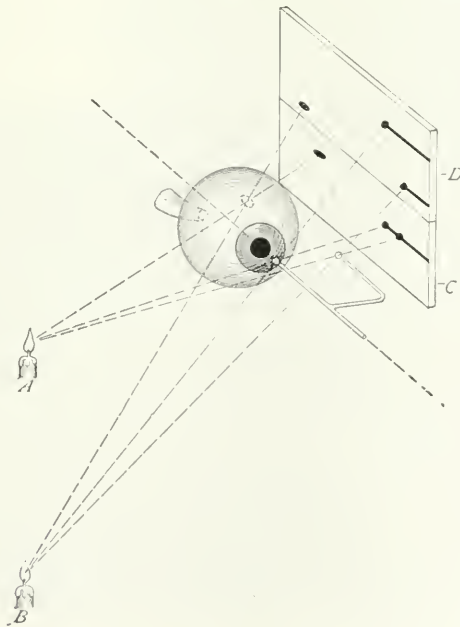


FIG. 420.—Principle of method of localization.

found the use of two metal indicators, one pointing to the center of the cornea and the other situated to the temporal side at a known distance from the first, to be simple in application and accurate in results. Two radiographs are made to give different rela-

<sup>1</sup> *Trans. Amer. Ophth. Soc.*, vol. vii. part iii.

tions of the shadows of the indicators and the body in the eyeball or orbit—one with the tube horizontal or nearly so with the plane of the indicators, and the other with the tube at any distance below this plane.

The principles of this method may be understood from the drawing (Fig. 420), in



FIG. 421.—Indicating apparatus and plate-holder.

which a candle-flame is used to represent the x-ray tube. Rays of light coming from the candle when at *A*, in casting shadows upon a flat surface of two ball-pointed rods and an object in a sphere representing the eye, give the view as shown on the surface *C*.

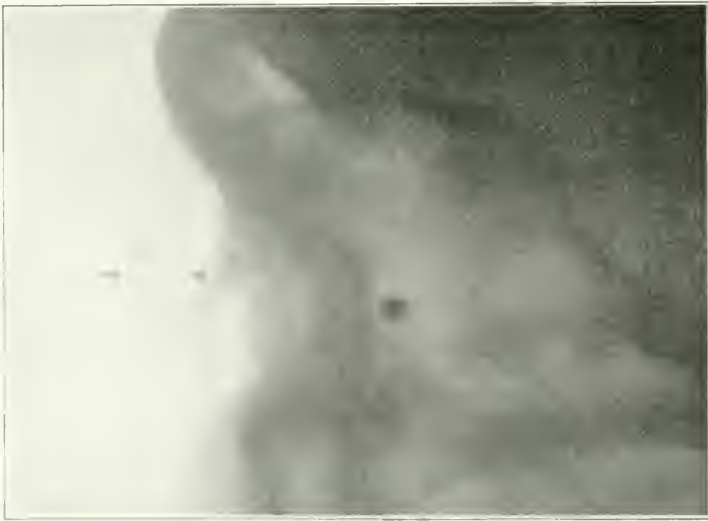

FIG. 422.—Radiograph made with the tube horizontal with the plane of indicators.

When the source of light is carried below the horizontal plane of the two rods to *B*, the shadows of the indicators take the position shown on the surface *D*, while the relative position of the body also changes. Knowing the distance of one of the balls from the center of the cornea and the distance between the balls, the position of the metal in the

eye may be readily determined, since the shadow of the body preserves at all times a fixed relation with respect to the shadows of the indicating balls in whatever position the candle is placed.

In practice it is essential that the axis of the eyeball shall be parallel with the two indicators and with the photographic plate; that one of the indicators points to the center of the cornea and be at a known distance therefrom; and that the two indicating balls be in a perpendicular line with the plate and at a known distance from each other. Simplicity has been secured by combining the plate-holder and indicators into a special apparatus which is bound to the side of the head, as shown in Fig. 421.

The determination of the position of a foreign body in the eye by the method described may be understood from the two radiographs which are reproduced in Figs. 422, 423. These were made of a man who was shot in the face by a rabbit-hunter, one of the shot penetrating at a point about 3 mm. below the superior border of the orbit of the

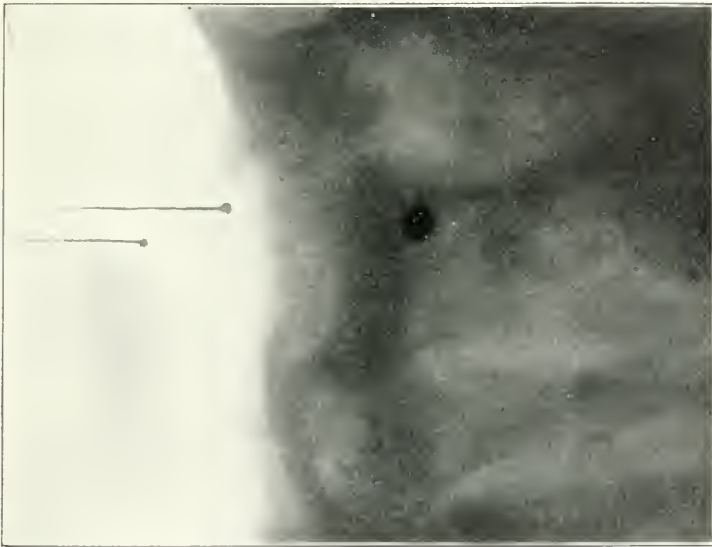


FIG. 423.—Radiograph made with tube below horizontal plane of indicators.

left side. No view of the fundus of the left eye was possible, owing to the denseness of the vitreous, although a slight red reflex was present in the upper portion of the eye.

In determining the position of the body in the eye two circles, 24 mm. in diameter, are drawn upon paper, one to represent a horizontal and the other a vertical section of the average adult eyeball. Upon these circles are noted the positions of the balls of the indicators when the exposures were made.

Measurements are made upon each of the radiographs of the distance that the shadow of the foreign body is above or below the shadows of the indicators, and these distances are entered above or below the spots representing the two indicating balls on the circle showing the vertical section of the eye. Lines drawn through the points of measurement from the two radiographs (*C* and *D* and *E* and *F*) indicate the plane of shadow of the foreign body at each exposure. Where the two lines cross, therefore, must be the location of the body as measured above or below the horizontal plane of the eyeball and to the temporal or nasal side.

The location of the foreign body back of the center of the cornea is determined by measuring the distance that the shadow of the body is posterior to the shadows of the two indicating balls on the radiograph made with the tube horizontal to the plane of the indicators, marking off the measurement perpendicular to each of the spots representing the indicators on the horizontal section of the eye, and drawing a line through these points. Since this represents the plane of shadow of the foreign body when the radiograph was made, the metal must be situated at some point on this line. The location of the body as respects the vertical section of the eyeball having been determined, where a line drawn perpendicular to this position intersects the plane of shadow on the horizontal section is the situation of the body back of the anterior portion of the eyeball. When the distance of the platinum plate of the tube from



the center indicating ball is known, the plane of shadow of the body on the horizontal section of the eye is determined by drawing a line directly from a point representing the tube to the spot of measurement of the shadow of the body back of the external indicator. In order to render the various measurements clear, outline drawings of the two radiographs, reduced one-third in size, are shown in Figs. 425 and 426, the lettering corresponding to that employed on the diagrammatic circles.

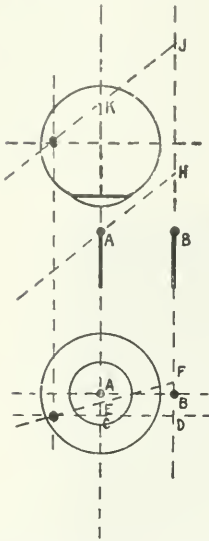


FIG. 424.—Diagrammatic circles representing the eyeball: upper circle, horizontal section; lower circle, vertical section (reduced one-third in size).

When the photographic plate is in place at the side of the head, it is necessary in the majority of cases to arrange the point of fixation so that the cornea is rotated slightly inward, in order that the visual axis shall be parallel with the plane of the photographic plate. This rotation of the eyeball in no way affects the method of locating bodies within the globe, but when the body has penetrated into the orbit outside of the eyeball, the convergence necessary to ensure parallelism of the visual axis and the plate leads to error in the determination of the position of the metal. To eliminate this factor of error necessitates a knowledge of the angle of the orbit with the plate, or, what is equivalent, the amount of deviation of the eyeball from the primary position, and the employment of this angle in plotting the diagrammatic circles representing the eyeball. Another error arises from the false projection of the shadow of the body in the orbit in relation to the shadows of the indicators, owing to greater divergence of the rays as the distance between the center indicator and the foreign body increases. This false projection may be allowed for by noting the distance of the platinum plate of the tube from the center indicator, and employing this measurement in determining the plane of shadow of the body on the horizontal section of the eye.

In making the exposures the plate is to the side of the head corresponding to the injured eye, and the tube is placed about 12 inches to the opposite side and slightly forward. The patient should lie upon his back, as this position ensures greater steadiness of the head and body than when sitting upright with some form of head-rest. An exposure of four minutes is ample to secure clear shadows of bodies in the eyeball or orbit, and with efficient apparatus good radiographs may be secured in one-half this time. As the best results are achieved when the tube is run

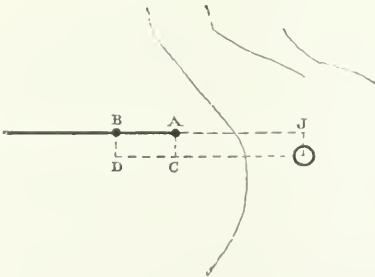


FIG. 425.—Outline drawing of radiograph made with tube horizontal with plane of indicators (reduced one-third in size).

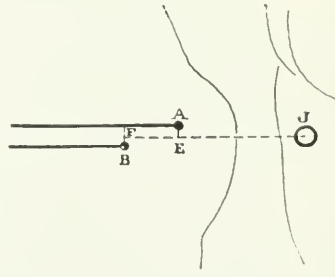


FIG. 426.—Outline drawing of radiograph made with tube below horizontal plane of indicators (reduced one-third in size).

at a high vacuum, a tube should be selected which may be so operated that the resistance offered to the passage of the current does not reach a point to interfere with the generation of the rays. The cathodal terminal should be ground and polished, so that the rays are focussed to a small point upon the platinum, which ensures sharper outlines of the foreign body than when the focus-point is large.

**Accuracy of the Method.**—It has been conclusively shown in actual work that the X-rays may be relied upon to determine in nearly every instance the presence or absence of a foreign body in the eye. The difficulties of shadowing the body on the plate increase with the smallness of the object, especially if it is situated to the nasal side of

the eye and therefore some distance from the sensitive surface. It is evident that cases may occasionally be seen where the body is so small as to fail to cast a shadow of sufficient distinctness to be recognized in comparison with the shadows of the orbital bones, although chips of metal which are too minute to be shown by the rays seldom strike the eye with sufficient force to overcome the resistance of the ocular structures and penetrate deeply into the globe. In cases of doubt as to the presence of a metal body in the eye, several exposures should be made with the tube in various positions, in order to cause the body, if present, to be shadowed through the thinnest portion of the orbital bones, and thereby exhibit sufficient contrast to assist in revealing its presence.

**Dangers.**—The introduction of more powerful apparatus for the generation of the rays has reduced to a minimum the dangers of severe injury of the superficial structures of the body by decreasing the time of exposure. Persons of fair complexion are particularly susceptible to the action of the rays, although a slight redness of the skin is all that may be expected in any case in the short period required in making the negatives. It is a safe plan, however, to limit the exposures at one sitting to four, which at the most would subject the patient to the action of the rays for a period of sixteen minutes. In this way it is possible to note the effect on the skin, and, if additional radiographs are desired, postpone the second sitting for several days in case marked redness follows the first exposures.

**Influence on Vision of Blind Eyes.**—The experiments made by Hansell,<sup>1</sup> by Wilkinson of the California School for the Blind, and by Hilgartner and Northrup conclusively show that the X-rays have no power whatever of exciting vision or even light perception in an eye, diseased or normal, and are without beneficial effect in the treatment of diseases leading to blindness. These investigations were made upon a number of patients who were blind from dense opacities of the cornea, congenital cataract, or complete optic atrophy.

---

## THE PRACTICE OF OPHTHALMIC OPERATIONS ON ANIMALS' EYES.

By CLARENCE A. VEASEY, A. M., M. D.,

OF PHILADELPHIA.

**Introduction.**—The frequent practice of ophthalmic operations upon animals' eyes is of the greatest importance to the beginner in operative ophthalmology, as it enables him to become acquainted with the use of the various instruments, to recognize the difference in the density of the tissues which have to be cut, to become thoroughly familiar with the technic of each operation, and to lose a certain amount of the timidity which is almost invariably present when beginning operative work upon the human eye.

**Instruments.**—A set of instruments should be obtained and used for this purpose alone. The following are all which are required for practising most of the operations on the eyeball and muscles: An eye-speculum, a pair of fixation-forceps, an angular keratome, a v. Graefe cataract-knife, a pair of iris-forceps, a pair of iris-scissors, a cystotome and Daviel's scoop, a cataract-needle, a strabismus-hook, a pair of strabismus-scissors, a canaliculus-knife, a small scalpel, and a few curved needles.

**Choice of Eyes.**—Pigs' eyes are the most useful for practising the various operations. They more nearly resemble human eyes in size and density of tissue than do the eyes of other animals that are readily obtainable, and they can be easily fastened in the various masks. Sheep's eyes are too large for the latter purpose, and bullocks' eyes, while useful for demonstrations before a large class, possess tissues which are too dense and are themselves too large for the instruments which are commonly employed in operations on the human eye to make them of practical value.

For operations upon the muscles, the orbits, and the lids it is necessary to have a head with the eyes in their natural positions. For this purpose the head of a young pig, about six weeks old, is perhaps the easiest obtained and answers the purpose very well. The butcher must be cautioned, however, to allow the head to remain in scalding water for the shortest possible time preparatory to removing the bristles, or the eyes will be too shrunken to answer the purpose. Even with these precautions the corneas will be a trifle hazy, but if the eyeballs retain their firmness, this defect will not interfere with the subsequent practice of the operations.

<sup>1</sup> *Amer. Journ. of Med. Sciences*, Nov., 1897.

If possible, all the operations should also be practised upon the head of a cadaver; but, unfortunately, it is difficult to obtain material of this character outside of the dissecting-rooms of medical schools, and even when it is at hand the eyes are often so shrunken and collapsed, and have undergone such great changes, that it is fully as satisfactory, if not more so, to practise on the animal's eyes. To obtain correct ideas, however, of the topography of the parts practice on a cadaver as fresh and well preserved as possible is essential.

After practising for a time upon eyes placed in a mask and upon eyes in their natural positions in a pig's head, it is advisable to obtain some experience in operating upon the eyes of live animals. Dogs, cats, or rabbits may be used, the latter being perhaps the least expensive and most easily handled. The animals should be anesthetized with chloroform before operating, and at the conclusion of the operation the anesthesia should be pushed sufficiently far to produce death.

**Time of Removal of Eyes from the Animal.**—As eyes always undergo various changes shortly after death which render them less valuable for operative work, they should be removed from the animal as soon as it is killed. It is especially important that they be removed before the animal is scalded preparatory to scraping off the bristles, otherwise the corneas will become so opaque and shrunken as to render them useless.

**Method of Preserving Eyes for Operating Purposes.**—Fresh eyes are by far the best and most satisfactory for operative work. They impart to the hand a more natural sense of resistance of the tissues, and the corneas are much clearer than they can possibly be after preservation in any liquid. If it is impossible, however, to obtain them fresh when desired, they can be preserved for operating purposes for about one week by placing them in a  $\frac{1}{10}$  of a 1 per cent. solution of formaldehyd. A stronger solution, though excellent as a preservative, hardens them too much for operative work. Should

it be desired to preserve them even longer, they may be transferred to a solution of thymol (1:5000), in which they will keep for several weeks (Andogsky). No matter whether fresh or preserved eyes are employed, the corneas will be found to be more or less dry, so that before beginning any operation they should be moistened with water.

**The Operating Mask.**—It is customary when practising operations upon animals' eyes to place the latter in masks especially constructed for the purpose. The best of these is the Viennese mask seen in Fig. 427. This represents a human face with most of its relations preserved, and in the orbital cavities are placed removable sockets in which the animal's eyes can be firmly held. These sockets permit the eyes to be moved in all directions, and by turning a central screw on which the eye rests the latter can be tightened or loosened, so that the intraocular tension may be decreased or diminished at will. The face is so attached to its base that it can be placed at different angles, and is made of hard rubber to prevent absorption of the various ocular fluids. Other masks known as "phantom faces" and made of *papier maché* may be also used for the same purpose.

**The Home-made Mask.**—If the student does not possess the Viennese mask or a phantom face, a fairly satisfactory substitute may be constructed at home from a small box and a piece of cork. The latter should be sufficiently thick to enable the hand to move freely without striking the lid of the box, and is glued to the latter as shown in Fig. 428. An eye is readily

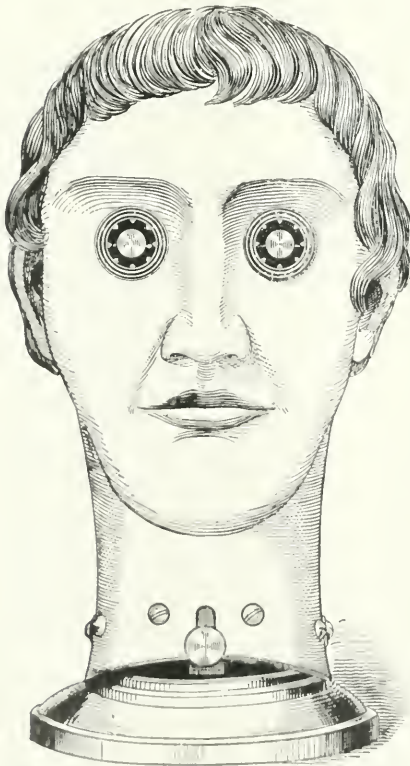


FIG. 427.—Vienna mask.

fastened to this by means of four tacks or stout pins, and the lid can be placed at any angle desired.

Should no mask be at hand, an eye can be wrapped in a towel and held in the hand



of an assistant, which rests firmly on a table while the different operations on the eyeball are being practised (Fig. 429). The greatest objection to this method is the impossibility of holding an eye firmly without making considerable pressure, which spoils, to a certain

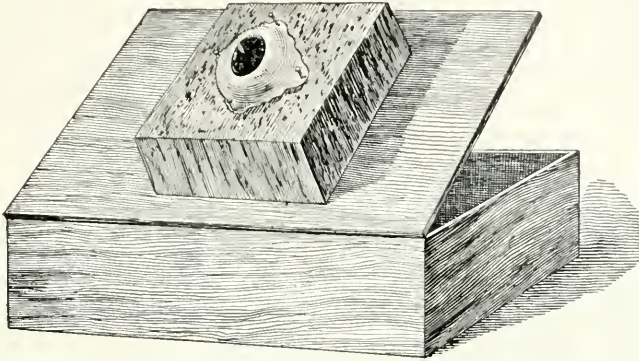


FIG. 428.—Home-made mask.

extent, most operative procedures. The method is of great value, however, in practising puncture and counter-puncture and the different varieties of corneal sections, and in these the assistant may be dispensed with, the eye being held in one hand while the knife is manipulated with the other.

**Preparation of the Eye for the Mask.**—When the eyes are removed from the pigs

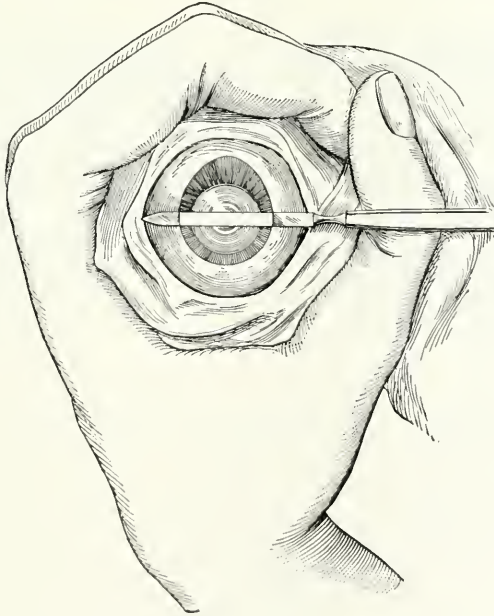


FIG. 429.—Eye in towel.

they have attached to them, as a rule, the stumps of the muscles, some conjunctiva, and more or less of the orbital fat. Enough of this should be trimmed off, to enable the eye to fit easily into the socket of the mask, but at the same time care must be exercised not to remove too much or the eye cannot be held sufficiently tight for the satisfactory performance of an operation. A little practice will soon enable the student to know just how much tissue to remove, so that the strongest possible grasp may be maintained during the whole operation.



The shape of the pig's cornea differs somewhat from that of the human cornea, and in placing pigs' eyes in the mask-socket the round end should be turned upward. In this manner the shortest diameter of the eye is horizontal, and the iris is less apt to fall in front of the knife in making corneal sections than when placed in any other position.

Before attempting to fit an eye into the mask-socket the latter should be removed from the mask and the cavity made as large as possible by means of the screw on which the eye is to rest. After this an eye is placed in position, and a small circular metal band containing several teeth is pushed over it to hold it in place.

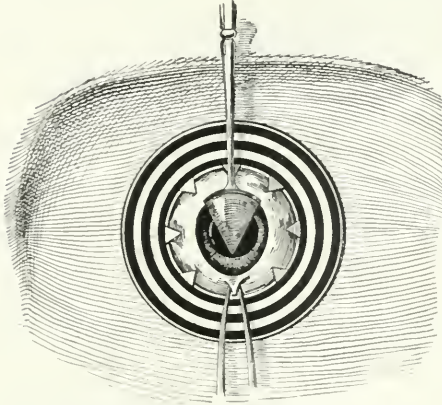


FIG. 430.—Position of the keratome in iridectomy.

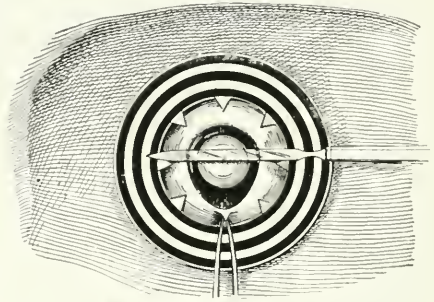


FIG. 431.—Cataract-knife making section.

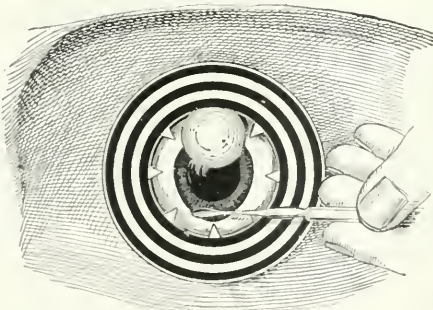


FIG. 432.—Delivery of the lens.

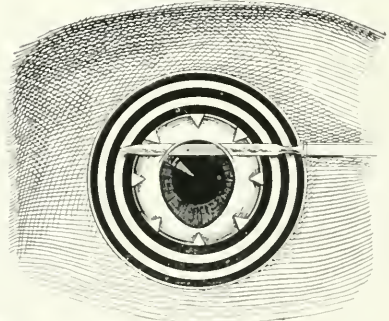


FIG. 433.—Anterior sclerotomy.

**General Directions.**—Before beginning to practise any operation the instruments required for that operation should be selected and placed within easy reaching-distance in the order in which they are to be used. If some one is assisting, the operator should not remove his eyes from the field of operation more than is absolutely required, the assistant placing in his hands each instrument as it is needed and removing the ones that have just been employed. The operator should also be careful to assume only such positions in relation to the animal's eye, or to the mask, as could be easily attained if operating on the human eye, and should studiously avoid any but the proper manner of holding the instruments. In other words, as much attention should be paid to detail as if the operation were being performed on a human eye. Thus only proper habits will be formed, for the habits formed in this work will adhere to the student in his later work upon human eyes, and, if they be incorrect, will be difficult to overcome.

**Operations which can be Practised.**—In general, most of the operations which are performed on the human eye may be practised on animals' eyes employed as previously described. Figs. 430-433<sup>1</sup> are sufficiently illustrative of some of the main operations.

<sup>1</sup> Taken from the author's work, *Ophthalmic Operations as Practised on Animals' Eyes*.

# THE MOST IMPORTANT MICRO-ORGANISMS HAVING ETIOLOGICAL RELATIONSHIP TO OCULAR DISEASES.

BY G. E. DE SCHWEINITZ, A. M., M. D.,

OF PHILADELPHIA, PA.

THE normal conjunctiva always contains bacteria, no less than ten or twelve varieties having been isolated. If these organisms have pathogenic characteristics they are very slight (Randolph); indeed, it is probable that only two or three varieties should be classified as at all pathogenic (Weeks). Non-pathogenic conjunctival bacteria, however, may become harmful if the tissues in which they exist are bruised or irritated (Randolph).

Pathogenic bacteria, especially those related to suppuration, are frequently found along the ciliary margins and in the secretion of the lachrymo-nasal passages.

The etiological relationship of micro-organisms to various ocular affections has been fully described, especially in the articles on Diseases of the Conjunctiva, Diseases of the Cornea, and Sympathetic Ophthalmitis. For the convenience of the student a brief description of these organisms, together with the stains by which they may be recognized, is here inserted.

**Koch-Weeks' Bacillus.**—According to Weeks, this bacillus resembles that of monse-septicemia in form, and measures 1 to 2  $\mu$  in length and about 0.25  $\mu$  in thickness. It is often associated with a clubbed bacillus (*pseudo-diphtheritic* or *xerosis bacillus*). It stains readily with ordinary anilin dyes, and may easily be demonstrated in the secretion of affected eyes. (See Plate 2, Fig. III.)

As reagents Weeks uses methylene blue, basic fuchsin, or gentian violet.

This bacillus has been found by Weeks, Morax, Beach, and others to be the etiological factor in acute contagious conjunctivitis, as it is fully described on page 276.

**Pneumococcus** (*Diplococcus pneumoniae* (Weichselbaum); *Micrococcus Pasteuri* (Sternberg); *Micrococcus lanceolatus* (Talamon); *Fränkel's pneumococcus*).—This organism appears in the form of oval cocci each about 1  $\mu$  in its longest diameter. The cocci are often arranged in pairs (hence the name diplococci), and sometimes in chains of three to ten elements. The free ends of the cocci may be pointed (hence the name diplococcus lanceolatus), and they are often surrounded by a capsule (hence the term capsulated diplococcus). (See Plate 2, Fig. IV.) The organism stains with the ordinary anilin dyes, and also by Gram's method.

Pneumococci were first described as a cause of acute conjunctivitis by Morax and Parinaud, who supposed the disease was peculiar to early childhood. The later investigations of Gasperini, Harold Gifford, and others show that the affection is distinctly contagious, may attack adults, may be transferred from one eye to another, and may originate acute inflammation of the conjunctiva, clinically very difficult to differentiate from the Koch-Weeks' bacillus conjunctivitis (see also pages 275, 276).

According to the researches of Uthoff and Axenfeld, which have been abundantly confirmed, pneumococci are the most important etiological factors in true serpiginous ulceration of the cornea (see page 314). They are also one of the causes of panophthalmitis.

**Gonococcus** (*Gonococcus* of Neisser; *Micrococcus gonorrhoeae*; *Merismopedia gonorrhoeae*).—This organism is found in gonorrhoeal pus, in the form of a micrococcus about 0.7  $\mu$  in its long and 0.5  $\mu$  in its short diameter. It often occurs in a diplococcus- and sometimes in a tetrococcus-form, the individual cocci being ovoid in shape, with their opposing surfaces flattened or slightly concave. The organism appears in characteristic groups within the leukocytes. (See Plate 2, Fig. II.; also Figs. 187 and 188). Gonococci stain readily with watery solutions of the basic anilin dyes—*e. g.* methylene blue, fuchsin, etc.—but are decolorized by Gram's method.

They are the etiological factor in gonorrhoeal conjunctivitis and in severe cases of conjunctivitis neonatorum (see pages 278, 281).

**Klebs-Löffler Bacillus** (*Bacillus diphtherie*; *Löffler's bacillus*).—This organism occurs in diphtheritic products as a slender bacillus, with round, occasionally distinctly clubbed ends, about  $3 \mu$  in length. The bacilli may be irregularly scattered, may appear in clusters, or may assume a parallel grouping; often two bacilli are joined end to end (see Fig. 190). The organism stains readily with the ordinary anilin dyes, by Gram's method, and, best of all, with Löffler's methylene blue. It is the cause of diphtheritic conjunctivitis (see page 284).

The *pseudo-diphtheritic bacillus* morphologically closely resembles the virulent bacillus diphtherie, but is not fatal to animals. It is found in several varieties of conjunctivitis—*e. g.* follicular conjunctivitis.

**Xerosis Bacillus**.—This organism was first found in xerosis of the conjunctiva, and morphologically, as well as in cultures, closely resembles the diphtheritic bacillus, but is non-virulent to animals (see also page 296). It is said to be present in the normal conjunctiva, and is found in a variety of conjunctival diseases, either alone, or, as in Koch-Weeks' bacillus conjunctivitis, associated with the specific organism.<sup>1</sup>

**Tubercle Bacillus** (*Bacillus tuberculosis*; *Koch's tubercle bacillus*).—This organism occurs in tuberculous tissue or sputa, in the form of a slender rod with rounded or slightly curved ends  $3$  to  $5 \mu$  in length and  $0.3 \mu$  in breadth. Sometimes, when stained, the bacilli present a "beaded" appearance. In the tissue they are irregularly scattered or are arranged in small masses. They may be single, or an angle may be formed by an end-to-end attachment of two of them (see Fig. 201). Tubercle bacilli do not stain readily with ordinary watery solution of basic anilin dyes; anilin-water solution of gentian violet or fuchsin must be used. One of the best preparations is the Ziehl-Neelsen carbol-fuchsin. Once stained, the bacilli retain the dye tenaciously. They are the cause of tuberculous lesions in the ocular coats (see page 302).

**Leprosy Bacillus** (*Bacillus lepra*).—This organism occurs in the leprous tubercles, in the form of a bacillus which closely resembles the tubercle bacillus, but is slightly more slender (Fig. 200). The bacilli stain readily with the ordinary anilin dyes and by Gram's method.

**Staphylococcus Pyogenes Aureus** (*Micrococcus pyogenes aureus*).—This organism is one of the bacteria of suppuration, and occurs as a spherical coccus from  $0.5$  to  $0.9 \mu$  in diameter, and grows in clusters and masses, but is also met with singly and in pairs (see Fig. 192). It stains readily with all the anilin dyes, and also by Gram's method.

Staphylococci are related to numerous inflammatory conditions of the cornea and conjunctiva, being found, for example, on the ciliary margins in blepharitis, in phlyctenular conjunctivitis, in simple conjunctivitis, and in association with specific organisms—for instance, with Löffler's bacillus in diphtheria of the conjunctiva, and with gonococci in gonorrhoeal conjunctivitis. They are freely present in suppurative conditions of the lachrymo-nasal passages, are one of the varieties of micro-organisms found in mixed infections in corneal ulcers which are not typically serpinginous, and have been claimed by Deutschmann to be the cause of sympathetic, or, as he called it, migratory ophthalmitis (see page 349). In addition to staphylococcus pyogenes aureus may also be found the varieties which are known as *S. pyogenes albus* and *S. pyogenes citreus*, which differ from the preceding organism in the color of their growth, as is designated in the name. They are also said to be less pathogenic than the first one.

**Streptococcus Pyogenes**.—This organism occurs as a coccus slightly larger than the preceding varieties, being about  $1 \mu$  in diameter. It forms chains (see Fig. 197) which sometimes are composed of numerous members. It may be demonstrated by the usual stains.

Streptococci are found in various suppurative processes which occur in the eye, either alone or in association with specific micro-organisms, and they are the cause of certain varieties of corneal ulcers. They are especially frequent in the purulent secretion which comes from the lachrymal sac, being the cause of the conjunctivitis which is associated with this condition. This form of conjunctivitis may also be complicated, according to Parinaud, with hypopyon and irido-cyclitis (see also page 294).

There is one variety of *membranous conjunctivitis* due to streptococci which occurs

<sup>1</sup> The terms "pseudo-diphtheritic bacillus" and "xerosis bacillus" have been much confused, because the *pseudo-diphtheritic bacilli of Hoffmann*, which are found in the nose and throat, are not identical with the *pseudo-diphtheritic bacilli of the conjunctiva*, which, by some authorities, are made to include the xerosis bacilli, the bacilli septati (Gelpke), the chalazion-bacilli (Deyl), etc.

The investigations of D. H. Bergey indicate that there is a large group of micro-organisms, at the head of which is the *virulent Löffler-bacillus*, which may occur in several distinct variations, and at the other extreme is the *xerosis bacillus*. Between these extremes are many variations in type, as shown by modifications in biological and morphological characters, for example, the pseudo-diphtheritic or Hoffmann's bacilli.



in children in connection with the exanthemata, but which, according to Morax, may appear independently of febrile complications. The disease is often mistaken for diphtheritic conjunctivitis, and is sometimes called "*streptococcus diphtheria of the conjunctiva*." Microscopic examination will decide the diagnosis. The prognosis is exceedingly unfavorable.

In this connection a brief mention of a remarkable form of conjunctivitis, known as *Parinaud's conjunctivitis* or *infectious conjunctivitis of animal origin*, may be made. Its main characteristics, as summarized by Gifford, who has studied it in this country, are sudden onset, thickening of the lids, mucopurulent discharge, the formation within a week or two of large polypoid and pediculated granulations on the conjunctiva, between which occur numerous smaller yellowish ones, and inflammation of one or both of the groups of lymph-glands on the same side, the pre-auricular and retromaxillary groups being most frequently involved. The affection is practically always one-sided. Bacteriological investigations have generally been lacking in results, but streptococci have been found in the pus in the eye and in the inflamed lachrymal glands. The treatment suited to trachoma would seem to be indicated.

**Trachoma Coccus.**—This organism has been described by Sattler and Michel, and may be cultivated from the trachoma follicle. It forms a small diplococcus (Fig. 195). Its specificity has not been demonstrated (see page 292).

**Diplo-bacillus** (*diplo-bacillus of Morax and Axenfeld*).—This organism was first described by Morax in 1896 as a frequent cause of subacute or chronic conjunctivitis.

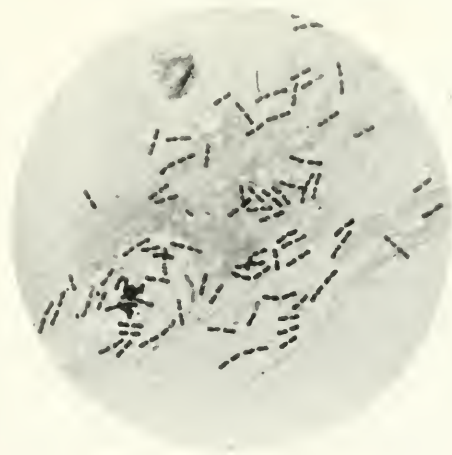


FIG. 433a.—The diplo-bacillus of Morax and Axenfeld (from a preparation by Dr. Harold Gifford).

According to Harold Gifford, who has investigated it in this country, "the germ commonly occurs in the form of a diplo-bacillus, each member of which measures 2 to 3  $\mu$  in length and 1 to 0.5  $\mu$  in breadth. Chains of these diplo-bacilli are not infrequent, and, in cultures, form sometimes as long as three or four of the single bacilli with no apparent sign of division." It stains readily with most of the ordinary dyes, but is decolorized by Gram's method.

The conjunctival affection which this diplo-bacillus causes in general is insidious in character. It runs a course of from six weeks to six months, during which the main symptoms are slight redness and hypersecretion of the conjunctiva with moderate subjective symptoms. Often the only sign of its presence is a persisting agglutination of the lids in the early morning. The secretion of stubborn subacute conjunctivitis should always be examined for this bacillus. The best local application for relief of *diplo-bacillus conjunctivitis* is a  $\frac{1}{2}$  per cent. solution of chlorid of zinc. According to Gifford, diplo-bacilli may also originate a condition closely resembling subacute trachoma, and sometimes they are the active organisms in corneal ulcers.

**The relation of micro-organisms to infective or sloughing ulcers of the cornea** has been briefly referred to several times in the preceding paragraphs, and the most important bacteria described. Uthoff and Axenfeld thus summarize our knowledge on this subject:

(1) Typically serpiginous ulcer of the cornea with hypopyon is practically always caused by the pneumococcus, which may frequently be found in these ulcers in almost pure cultures.



(2) Ulcers not typically serpiginous are caused by infection with staphylococci and streptococci and by mixed infection. Occasionally, pneumococci originate ulcers which are not characteristically creeping.

(3) About one per cent. of sloughing varieties of keratitis is due to a schizomycetal infection—*aspergillus fumigatus*.

The following organisms have also been found at times in association with keratitis: *Pfeiffer's capsulated bacillus*, *Bacillus pyogenes fetidus*, *Bacterium coli*, *Bacillus pyocyaneus*, *Ozena bacillus*, and a number of other varieties which have not again been discovered or which could not be identified.

It is interesting to observe that in general suppurative inflammation of the entire eyeball (panophthalmitis), although the ordinary bacteria of suppuration may be present, not infrequently there are found special forms of bacilli.

It would be manifestly out of place to describe in detail bacteriological examinations (which are essential in all carefully-studied inflammatory affections of the conjunctiva and cornea) in this place; but for the convenience of the reader the formulæ of a few of the stains to which reference has been made are appended. These formulæ (with one exception) have been taken from Hewlett's admirable *Manual of Bacteriology*, which has been frequently consulted in the preparation of this section.

Löffler's alkaline methylene blue.

|                                             |           |
|---------------------------------------------|-----------|
| Concentrated solution of methylene blue,    | 30 c.c. ; |
| Solution of caustic potash, 0.01 per cent., | 100 c.c.  |

This will stain cover-glass specimens in from three to ten minutes.

Anilin gentian-violet.

|                                                |           |
|------------------------------------------------|-----------|
| Saturated alkaline solution of gentian violet, | 30 c.c. ; |
| Anilin-water,                                  | 100 c.c.  |

This preparation will stain cover-glass specimens in two or three minutes.

Carbol-fuchsin (Ziehl-Neelsen solution).

|                                                   |            |
|---------------------------------------------------|------------|
| Fuchsin,                                          | 1 part ;   |
| Absolute alcohol,                                 | 10 parts ; |
| Five per cent. aqueous solution of carbolic acid, | 100 parts. |

It should be diluted with 2 to 6 parts of water for cover-glass specimens.

In Gram's method the cover-glass specimens are stained for five or ten minutes in anilin gentian-violet solution, and then immersed for one or two minutes in a solution of iodine 1 part, potassium iodide 2 parts, distilled water 300 parts. When the specimens are removed from the iodine solution and drained, they are immersed in methylated spirit. After decolorizing, the specimen may be washed in water, dried, and mounted.

E. A. de Schweinitz's method for staining tubercle-bacilli with Sudan iii. (red-fat dye) is a selective one. A saturated alcoholic solution is used. This preparation, made in the ordinary way, is stained for five minutes in this solution and washed with 70 per cent. alcohol.

THE EAR.



# THE EAR.

## THE ANATOMY OF THE EAR, INCLUDING EMBRY- OLOGY AND HISTOLOGY.

By BURTON ALEXANDER RANDALL, M. A., M. D., Ph. D.,  
OF PHILADELPHIA.

**Embryology.**—The human organ of hearing first appears in early embryonic life on each side of the head posteriorly as a pit-like involution of the epiblast (Fig. 434), which closes in to form a spherical “otic vesicle” (Fig. 435). Bud-like hollow processes grow out from this—inward, to form the endolymphatic duct and sac; forward, as the spirally-coiled cochlear tube (Fig. 436); outward, upward, and backward, in curving course to meet and coalesce with similar outgrowths and form the three semicircular canals, each with a flask-like dilatation where one of its ends springs from the vesicle. This has meanwhile lost its spherical form, dividing into a more spherical anterior “sacculæ,” connected with the cochlear tube by a narrowed “*canalis reuniens*” and an ovoid “utricle” communicating with the semicircular canals by five openings—one non-sacculated termination being common to the vertical and the posterior canal. The tissue which effects this cleavage

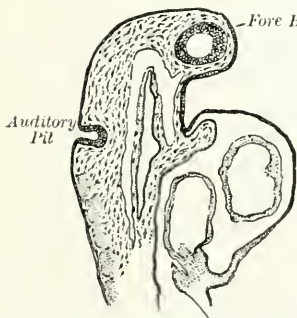


FIG. 434.—Sagittal section of embryo, showing involution of epiblast to form the otic vesicle.

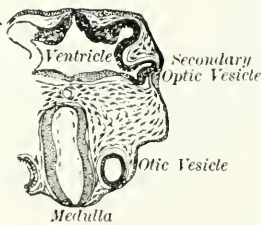


FIG. 435.—Horizontal section of head through the developing eye and full-formed otic vesicle; third week in human.

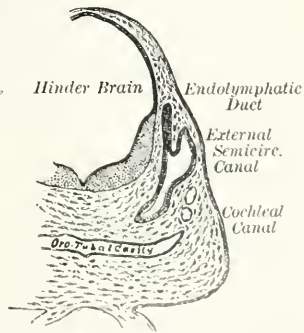


FIG. 436.—Horizontal section through developing labyrinth, medulla, and mouth; fifth week.

extends up into the endolymphatic duct (Fig. 437), so that the two sacs, although in contact, communicate only by this now Y-shaped tube.

Within the otic sac, which has now come to deserve the name of membranous labyrinth, there has been marked differentiation of the cells; while



externally a fibrous envelope has been formed from the mesoblast, splitting into a perichondrium sheathing the cartilaginous tissues which have been encasing the structure, separated by spaces of growing complexity from the delicate basement-membrane which supports all parts of the labyrinth. Supported by this, the simple rounded neural cells, generally in single layer, flatten into pavement-cells throughout most of the extent of the semicircular canals, the utricle, the saccule, and part of the cochlear tube; but at each point where the developing acoustic nerve sends fibers the cells assume a columnar form, surmounted by short, stiff cilia, the "hair-cells," above which floats a layer of gelatinous material of doubtful function, but invariable and

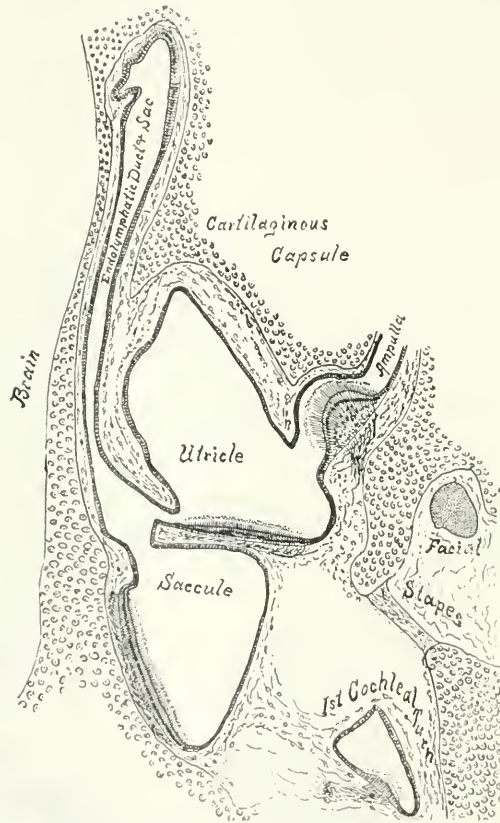


FIG. 437.—Labyrinth nearly developed, showing division of vestibular sacs, their hair-cell areas, and the similar structures in the ampulla of the external semicircular canal and first turn of the cochlear tube (half-schematic).

early presence. Each of the flask-shaped ampullae of the semicircular canals presents such an area, the "acoustic crest," upon its concave side; larger areas are present in the saccule and in the utricle, as shown in Fig. 437, the gelatinous "blanket" of each of the latter loaded with small crystals of lime—the *otoliths*. In the cochlear tube the corresponding structure, called after its discoverer "Corti's organ," is extremely complex and merits more extended description.

Within the open spiral of the cochlear tube there forms a cartilaginous, early-ossifying conical axis, "the modiolus," permeated with openings for the fibers of the cochlear branch of the nerve, which fills the end of the internal

auditory meatus at the base of the cochlea and sends its separated fibers through a spiral series of openings into the windings of the structure (Fig. 438). From this conical axis a delicate ossifying shelf is pushed out, ensheathing the diverging nerve-fibers to their entrance into the cochlear tube, and by a fibrous extension underlying the inferior (mesial) surface of this tube. These structures, winding spirally like the other portions of the cochlea, vary greatly in their relative size from the base to the apex: for the "basilar membrane," with its stiff radiate fibers, is narrowest below, where all the other structures are at their largest, and broadens progressively upward at the expense of the bony "spiral lamina." As its tense radiate fibers are probably comparable to the strings of a harp or piano, respond-

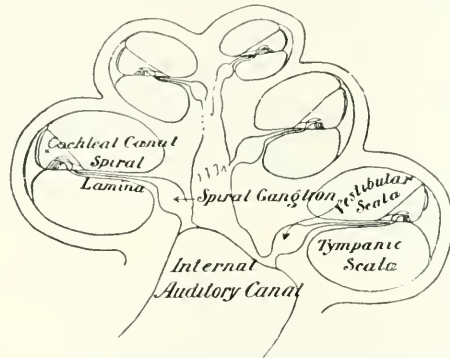


FIG. 438.—Section of the human cochlea showing the two and a half windings of its scala.

ing to notes higher and higher in proportion to their shortness, this is a fundamental fact in the anatomy and physiology of the organ, as proven by a growing amount of pathological investigation (see pp. 644 and 773).

The cochlear tube, originally cylindrical, has now been compressed to a triangular section, one side of it, as stated, being flattened by the basilar membrane. Below and above this, the cavities formed between the layers of surrounding mesoblast constitute parallel channels winding spirally upward and known as "tympanic and vestibular scala;" beyond these the ossifying cartilage forms a firm protecting spiral, which gives the ultimate snail-shell form from which the cochlea is named. Similar spaces about the sacculus, utricle, and semicircular canals hold away the bony walls which ultimately surround them, except at some one point, generally the convexity, as in the cochlea and the semicircular canals. At the attached point, where the vascular supply is best, the neural epithelium is modified to form secreting cells of the endolymph, those in the cochlear tube being a gland-area of cylindrical cells on the outer wall—the "stria vascularis" (Fig. 439). The upper wall of the tube becomes exceedingly delicate ("Reissner's membrane"), the neural cells flattening to a delicate pavement, separated by thin fibrous tissue from the endothelial pavement without. The lower wall shows the greatest modification both of the cells and of the supporting mesoblastic tissues. A fibrous crest forms by thickening of the periosteum of the osseous lamina, ending outward in projecting teeth, to which is attached the gelatinous membrane (*m. tectoria* of Corti) before mentioned as present above all hair-cells. Of these four or five rows are present, supported inward and outward by spheroidal cells, large, vacuolated, and piled upward. Within, two more modified rows of pillar-cells (Corti's rods) form a tunnel beneath their arch.

Each set has broadened feet and heads, the outer set nearly twice as numerous as the inner, and connected outward with a network of phalanx-shaped elements—"reticular membrane"—through the meshes of which the outer hair-cells protrude. These latter are double cells—the lower fusiform and firmly attached below to the basilar membrane by a slightly broadened foot, while the upper process adheres to the side of the peg-shaped hair-cell, and probably is attached to the reticular membrane. The acoustic nerve-fibers pass out between the plates of the osseous spiral lamina after emerging from the "spiral ganglion," which occupies a canal in the modiolus at the root of the lamina. Losing their sheaths, the axis-fibers are sent through a row of openings below the Corti teeth to split into ultimate fibrils, which pass, some

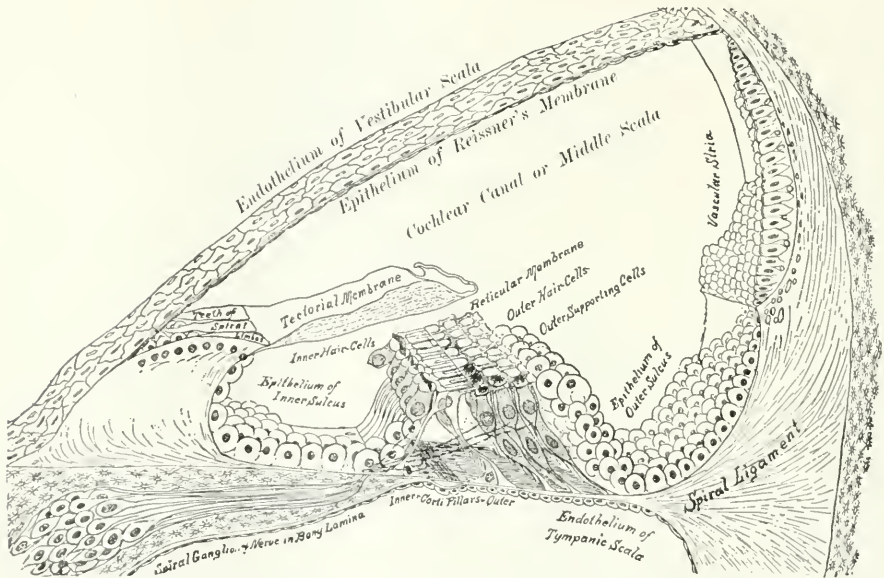


FIG. 439.—Scheme of section of cochlea in perspective, from human specimens.

up to the inner hair-cells, some across the tunnel to the outer hair-cells, while some wind upward along the spiral tunnel.

**Osteology.**—Embryological study has made clear the greater importance, formatively as well as functionally, of the membranous labyrinth. Yet the bony labyrinth was much earlier known and described, and was deemed the structure giving shape to its softer contents (Fig. 440). Its beauty, when carved out of its setting in the dense petrous bone, as is easy in infancy, or of its cast in metal when liberated by corroding away the bone, has attracted to it study which it does not otherwise deserve. It communicates with the middle ear by two fenestræ. The lower "round window," closed by the delicate in-drawn *membrana tympani secundaria*, connects with the lower cochlear scala, hence called tympanic; while the upper "oval window," normally occupied by the foot-plate of the stapes, communicates with the vestibule, which contains the utricle and sacule, separated from the oval window by a space of nearly 2 mm.—the "cisterna perilymphatica." This space is directly continuous with the upper "vestibular scala" of the cochlea. Depressed cribriform areas on the mesial wall of the vestibule admit the

nerve-fibers to the sacs of the membranous vestibule, the saccule occupying the hemispherical and the utricle the hemielliptical fossa (Fig. 441).

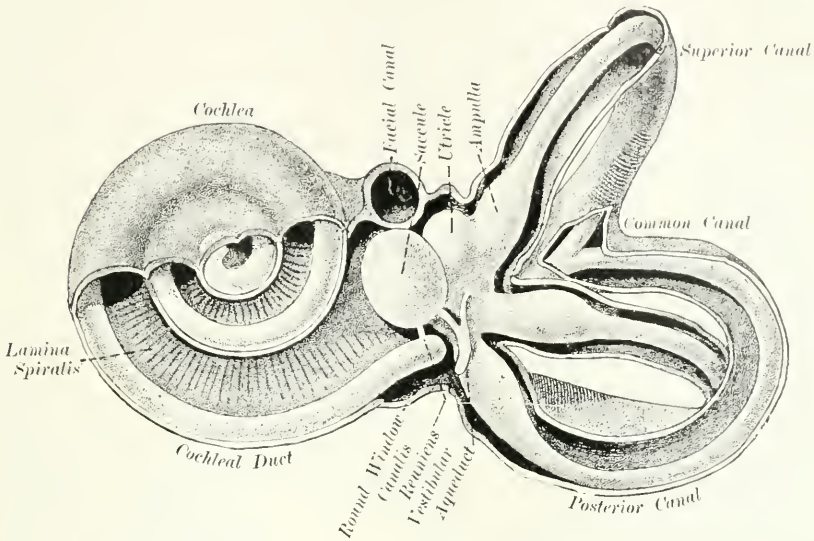


FIG. 440.—Bony and membranous labyrinth (schematic).

Inward the ossifying cartilage grows around the acoustic and facial nerves, forming the internal auditory meatus, shallow in infancy, but becoming a deep narrow canal later.

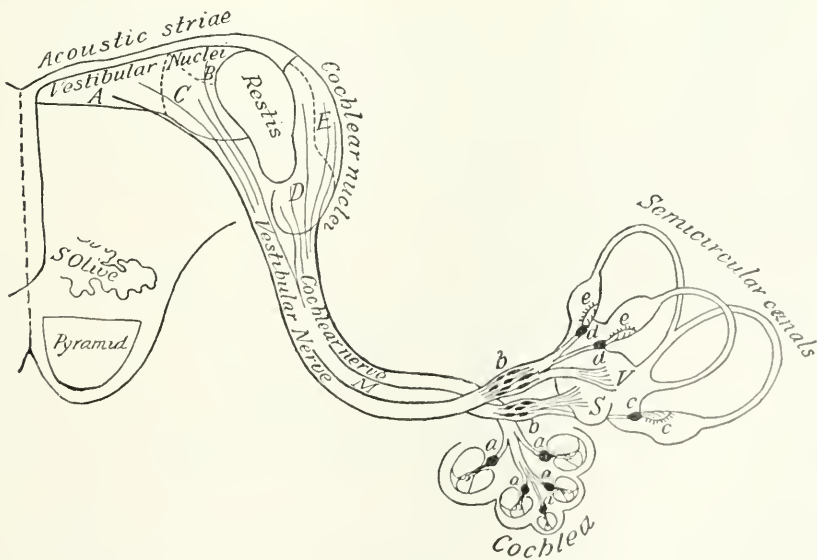


FIG. 441.—Diagram of the origin of the acoustic nerve and its distribution to the organ of hearing (Mills).

The first inner branchial furrow of the embryo early narrows at its outer portion leaving little lateral extension to represent the future Eustachian



tube, which does not begin its development until the labyrinth is almost full formed; then it extends outward as a narrow cleft, gradually separating the labyrinth from the tissues without, in which the ossicles are developing, largely from Meckel's cartilage (Fig. 442). Near the closed outer extremity of the cleft, seven little cartilaginous nodules grow to form the auricle; while in their midst an invagination of the surface forms the external auditory meatus, which presses inward until only the handle of the malleus and the thin *membrana propria* of the drumhead intervene between the cutaneous lining of the meatus and the mucous membrane of the tympanum. The old theory

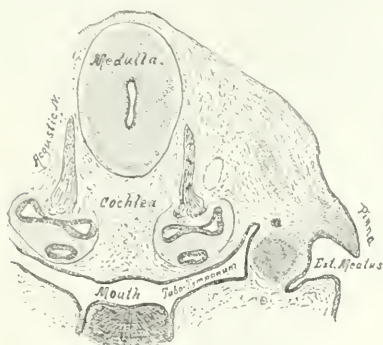


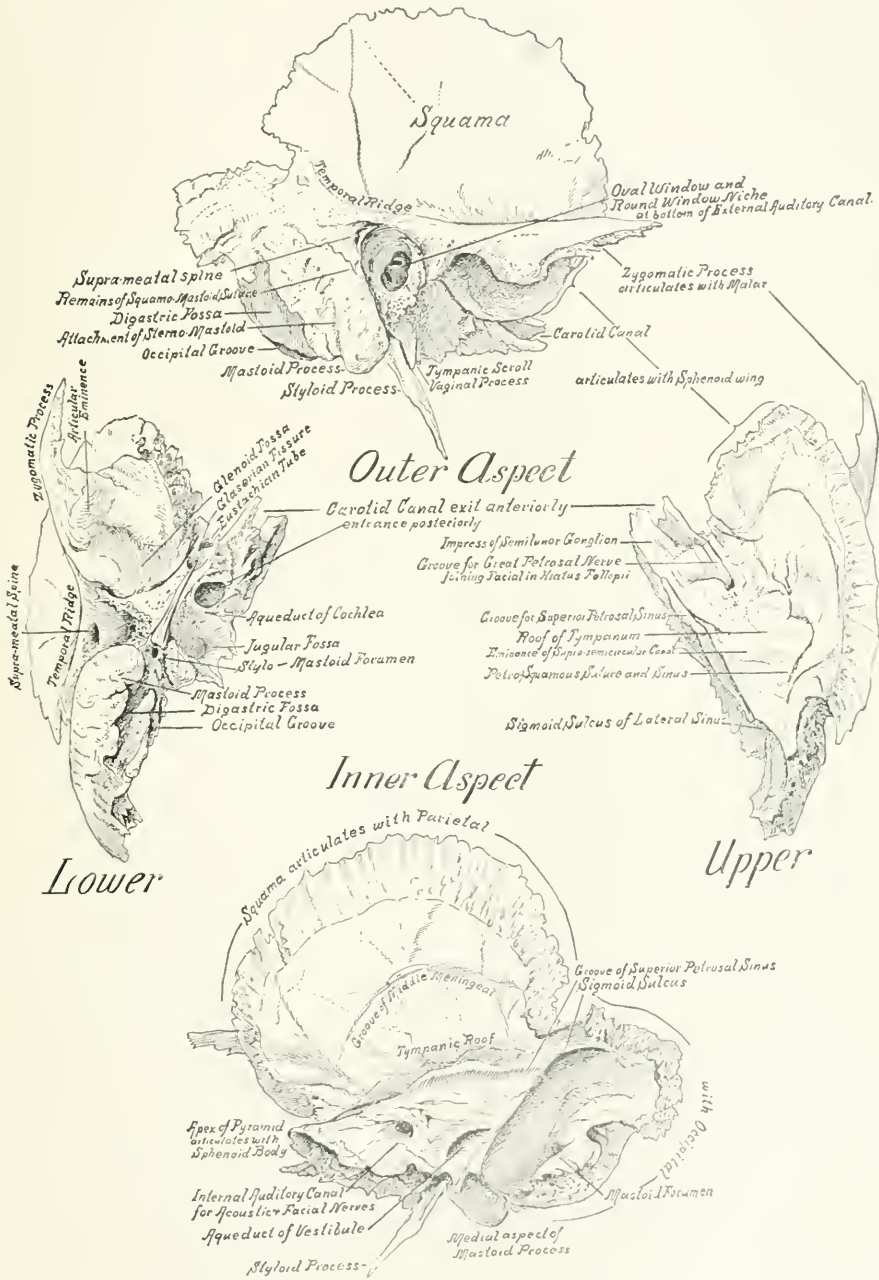
FIG. 442.—Horizontal section through cochlea, tympanum, and external ear of rat (half-schematic).

is baseless that the drumhead grows as a septum across the canal, and might fail to do so, leaving a colobomatous opening. When a fistulous opening persists, it is almost always from imperfect closure of the branchial cleft, and shows above the tragus, at the root of the helix, as a tiny fistula (see Fig. 483).

Besides the ossifying centers of the labyrinth three principal adjacent foci form—one in the petro-mastoid cartilage to imbed the inner ear and inwardly bound the tympanic portion. A second, called the "annulus" in the infantile form, is a ring incomplete above (Fig. 443), but develops into an extensive scroll later, forming all but the upper posterior wall of the auditory meatus. A third center in the membranes above the ear forms the squama, the zygomatic process, the outer half of the tympanic roof, and the *scutum*—the plate which roofs in the external meatus and forms the outer wall of the attic and antrum portions of the tympanum. Another (post-natal) center forms the styloid process. The temporal bone at birth is readily separated into annulus, squamous, and petro-mastoid portions, the last of which is still spongy, and can be cracked away from the enclosed labyrinth as a nut-shell from its kernel. Later the sutures unite almost completely, and the bony labyrinth blends imperceptibly with its strong, hard envelope, and we obtain the temporal bone as usually described in the anatomical treatises, with which the reader is supposed to be familiar. The further notes on the adult temporal bone will therefore be topographical and surgical.

*The Adult Temporal Bone* (Plate 9).—The outer aspect of the bone looks much more downward than is generally realized, although presenting as many minor variations in this as in all other particulars. One important "orientation point" is the upper edge of the zygoma, which is almost invariably horizontal. Less definite for determining its true position in the vertical plane is the auditory canal, the axis of which (so far as the line can be determined for so curved and tortuous a tube) points on an average  $10^\circ$  below and  $10^\circ$  back of the horizontal transverse axis of the head. Its deviation in each direction varies from  $0^\circ$  to  $20^\circ$  in individual cases. Sharing the general proportions of the cranium, the temporal bone varies hugely in size, massiveness, and configuration, its structure rarefying with advanced life to a delicacy like that of childhood, while its mastoid process corresponds to the muscular development to which its growth is a response. The pneumatic cells within hardly appear before adolescence, and probably enlarge and coalesce progressively throughout life; and nature's economy of material

PLATE 9.



The adult temporal bone from without, within, below, and above



gives to the large process the more pneumatic structure. Diploë is present, as in all the cranial bones, but is in inverse proportion to the air-spaces. The type of the cranium and the external configuration of the temporal afford no criterion as to the topography of the bone, except that we may generally expect to find a large mastoid, thin-walled and large-celled. The mastoid may be said to extend up to the curving temporal ridge which extends backward and upward from the root of the zygoma, and has been used as an index of the level of the middle cerebral fossa within, as in Macewen's chosen "post-meatal triangle;" but this cannot be relied upon as a landmark. Up and back from the canal a small spine with a depression back of it can be almost invariably recognized as marking the back margin of the meatus. This is a most important surgical landmark, as the point of election for opening the mastoid is close behind it. The floor of the middle fossa at the nearest point averages 6 mm. above it and is probably never lower than this spine: I have found it as low but 5 times in 1000.

This fossa, which constitutes most of the superior aspect of the bone, is of uneven surface, marked with the gyri of the cerebrum, and shows the

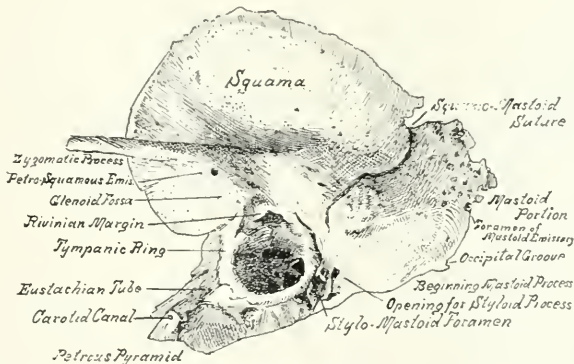


FIG. 443.—Temporal bone of infant; lower-outer surface showing squamous, tympanic, and petro-mastoid segments.

petro-squamous suture in childhood and sometimes into adult life. It is covered with thin, strong *dura mater*, which sends fibrous prolongations into the suture, and is most firmly attached along the back edge of the pyramid, where it passes into the tentorium and is split to form the superior petrosal sinus (see Plate 10, Fig. 1). Another sinus follows the petro-squamous suture, after which it is named, and emerges at the root of the zygoma, large in fetal life, but generally tiny after birth, and shrinking to a fibrous thread, although occasionally persisting of good size through life, and burrowing more or less under bridges of the inner surface of the bone. A groove more mesial in the floor accommodates the great petrosal nerve as it passes from the sphenopalatine ganglion backward to the facial canal to blend with the facial nerve at the geniculate ganglion—structures which are often devoid of bony covering (at the *hiatus Fallopii*) in infancy, and at times in adult life. Below the tentorium is the posterior or cerebellar fossa, bounded forward by the posterior aspect of the petrous pyramid. Here the internal auditory meatus, of very varying width and depth, is in close relation with the apparent origin of the facial and acoustic nerve in the pons; and, hidden close by in the layers of the *dura*, the endolymphatic sac communicates through a long cleft—the vestibular aqueduct—with the interior of the membranous labyrinth. Far-



ther outward and backward the lateral sinus, leaving its course in the edge of the tentorium, sweeps downward and in to find exit into the bulb of the jugular, forming the sigmoid sulcus upon the base of the pyramid, and a still more marked turn as it passes through the foramen lacerum (Plate 10, Fig. 2). No point in human anatomy is subject to greater variation as to size and position than this sinus and the jugular bulb continuous with it. Formed at the *torcular* by the confluence of the longitudinal sinuses, the lateral sinus, generally quite unequal in size on the two sides, passes out and forward (transverse sinus) to receive the superior petrosal as it curves down at the posterior end of the crest of the pyramid, to give off the mastoid emissary as it turns inward, and to receive the inferior petrosal as it passes forward at the *foramen lacerum*. As most of the blood-current of the superior longitudinal sinus usually flows to the right, this is oftener the larger and grooves more broadly and deeply the temporal bone at the sigmoid sulcus, extending farther forward and outward with its stronger curves. This cannot be counted upon, however, as rendering the left temporal any safer for easily avoiding the sinus in surgically opening the mastoid. The space between the sigmoid sulcus and the antrum is smaller, actually as well as relatively, in adult life, but rarely exceeds 5 mm., while some 10 mm. usually intervene between it and the posterior wall of the external canal. A large curved or bulbous sinus always approaches close to the canal and to the mastoid cortex, and little or no bone may protect it in one or both of these directions. The fossa in which the bulb of the jugular is lodged is also of infinite variation. Its depth occasionally carries it actually into communication with the internal auditory meatus: it generally closely approaches the lower back part of the tympanic cavity (Fig. 446), with the intervening bony septum at times dehiscient, and it so trenches, in rare instances, upon the labyrinth that its walls are marked by the semicircular canals. The mastoid emissary vein curves in variable fashion out and back from the lower curve of the sigmoid and passes by single or multiple channels through the bone, to emerge at or near the occipito-temporal suture. It varies from a tiny vessel hardly more than a nutrient of the bone to a large sinus carrying all the blood of the sigmoid sinus to the external jugular.

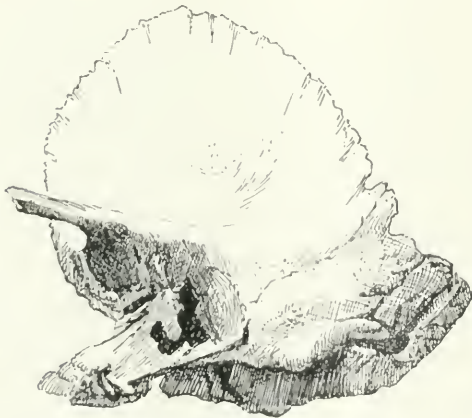

FIG. 444.—Temporal of child, showing growing mastoid process and fenestrated development of the tympanic scroll; sutures almost obliterated.

sigmoid sinus to the external jugular. The inferior petrosal sinus, like the superior, passes back from the cavernous and transverse sinuses, gathering the flow of the efferents of the pyramid and adjacent parts. It follows the line of the petro-occipital suture, and is probably of great importance in some cases as the channel of infections from the diseased tympanum.

The lower aspect of the temporal bone is marked by the canals of the carotid artery and the fossa for the head of the jugular, beginning in close proximity, but curving strongly in opposite directions. The first bend of the carotid presses its convexity into close relation to the forward part of the tympanum, and the wall, sometimes dehiscient, is always penetrated by vascular twigs. The outer wall of the canal is

PLATE 10.

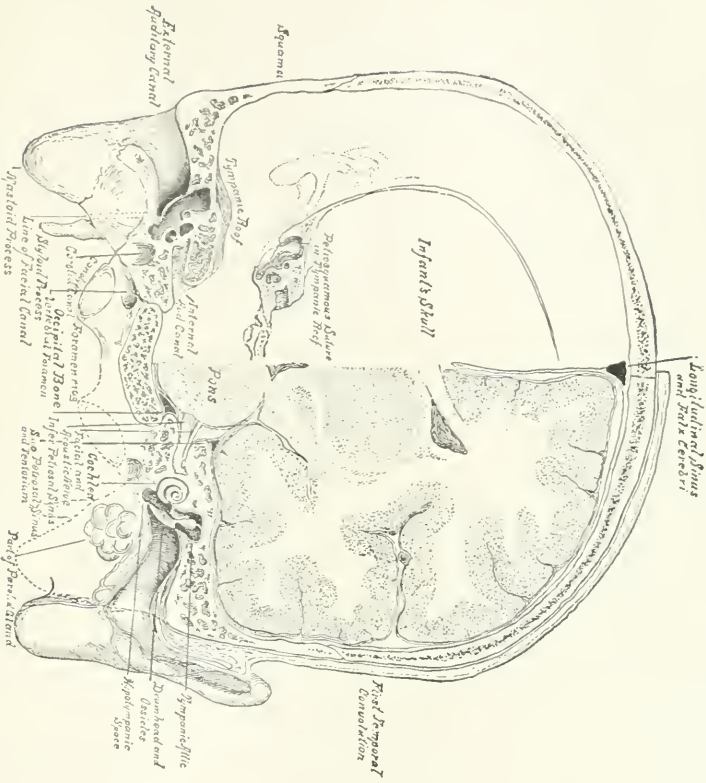


FIG. I.—Vertical section through auditory canals, showing the soft parts on the right, the macerated parts on the left.

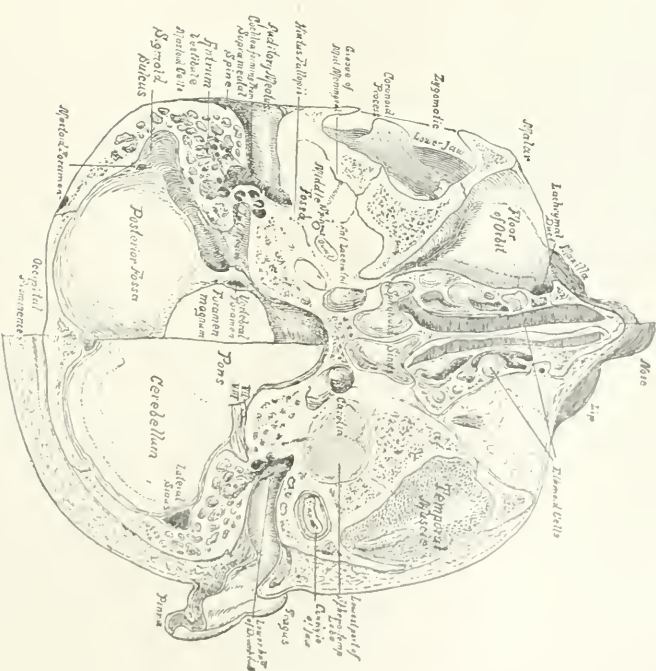


FIG. II.—Horizontal section through orbit, middle ear and occipital condyles, with the soft parts on the right, the macerated parts on the left.



in like proximity to the Eustachian tube, and dehiscence is here more frequent—a fact to be borne in mind in bougieing this passage. External to this is the glenoid cavity, its posterior boundary formed by the tympanic sceroll—its juvenile foramen often persistent (Fig. 444)—constituting the anterior wall of the auditory canal. The open Glaserian fissure at its inner extremity marks the sutural line and gives place to the gracilis process of the mallens, vessels, and the chorda tympani. The fossa of the digastric grooves deeply the under surface of the mastoid, paralleled mesially by that for the occipital nerve and vessels. While the tip of the mastoid process is wholly external to these, it must not be forgotten that thin-walled pneumatic cells commonly occupy the mesial boundary and may be the source of pus burrowing in the digastric fossa.

The styloid process, partially ensheathed by a lamina of the tympanic sceroll, extends down, in, and forward toward the lesser horn of the hyoid. It represents the cartilaginous and fibrous axis of the second branchial arch, undergoing no ossification during the early years of life, but sometimes developing almost to the form of the stylo-hyoid of the dog. It may thus become 10 cm. in length, with articulations, real or suggested, in its length. It may occasionally be recognized clinically in the lateral wall of the pharynx. Between it and the mastoid lies the foramen of exit of the facial nerve. The deep notch between the apex of the pyramid and the lower anterior margin of the squama is occupied by the tip of the great wing of the sphenoid, with its spinous foramen, from which the middle meningeal artery courses over the inner surface of the squama.

**The External Ear.**—The auricle, pinna, or helix is formed by the outward growth of the cartilage, carrying the skin-covering in close contact with it. Its form, subject to many minor variations, is fairly constant, and, except at the lobule, closely moulded upon the cartilaginous framework. Its apparent attachment to the head posteriorly is some 20 mm. back of the supra-mental spine, and fairly corresponds to the region of the mastoid where the lateral sinus is most near the surface (see Plate 10). The rest of the mastoid surface is hairless, and seems to cling closely to the surface which it reveals beneath; but its marked swelling in diseased conditions proves the presence of much areolar tissue and a chain of lymphatic glands connected with those below and in front of the ear. These are frequently involved in ear-disease, acute or chronic, and may need evacuation or extirpation—steps complicated by the passage of the facial nerve through the superficial group forward and by the adhesions of the deeper set to the sheath of the jugular and carotid. The layers of the cervical fascia concern the aural surgeon greatly in his work, and explain why rupture of mastoid empyema into the digastric fossa lifts the sterno-mastoid and all the neck-tissues, and how it may burrow to the posterior pharynx-wall, down to the clavicle or even into the mediastinum or pericardium. Parotid abscess is also said to endanger the ear by bursting through the fissures of Santorini of the cartilaginous canal—a path about as easily forced were the cartilage devoid of such gaps.

The external muscles of the ear are rudimentary and unimportant, although many have ability to call the attollens into play. The others are occasionally seen in spasmodic action, twitching generally without the consciousness of the person.

The auditory canal, as has been stated, varies greatly in its direction and size, with the result that the structures clinically visible at its bottom are inconstant. The lower anterior segment of the drumhead cannot always be brought to view; while up and back the incus-shank, stapes, and stapedi-



tendon, and down and back the niche of the round window with its prominent anterior lip may often be looked for in vain. The length of the upper back wall usually concerns the surgeon, since it marks the depth of the structures which he may have to attack, while it also gives, as above noted, a clue to the depth of the facial and horizontal semicircular canals which he must avoid (Fig. 445, Pl. 10). This length to the *spina suprameatum* is from 12 to 17 mm., and the soft tissues of the canal lengthen it to about 25 mm. The front wall is longer, since the oblique plane of the annulus places the lower anterior parts of the drumhead some 5 mm. farther in; while the tragus protrudes a little outward, making it some 35 mm. long. The impression is common—based upon the position of the drumhead as part of the under surface of the prepared head of the infant—that the infantile canal is much shorter than the adult, and the drumhead more superficial. This has hardly any truth, although accepted and taught by many authorities; for the length of the undeveloped bony meatus is fully represented by its fibrous precursor (Plate 10). Only in so far as the cartilaginous canal is smaller may we look for a few mm. less depth of the drumhead. The caliber is smaller in infancy, and the rather collapsed tube follows the upward curve of the squama, requiring a *downward* and outward traction to straighten it. The adult meatus is very tortuous, as a rule, although occasionally broad and straight. Its lumen is usually oval; vertically at the exit, but inclining obliquely forward as it passes in, until the axis may be less than  $45^\circ$  from the horizontal. With this there is curvature in the vertical plane and sometimes in the horizontal, so that the inner portion has often a downward trend, although the axis of the outer part pointed  $10^\circ$  to  $20^\circ$  upward. There is commonly some widening of the inner, anterior part, constituting a sulcus close to the drumhead—a difficult place from which to remove wax and foreign bodies, as many have found. The diameter of the canal is very various, as is the type of its oval, the narrowest “isthmus” being generally the most compressed portion, with a

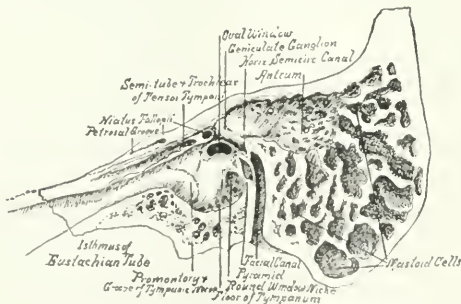


FIG. 445.—Inner wall of tympanum and tube.

naked bony meatus. In clinical cases, where free access is needed or the widest exit for a foreign body, the jaw must be dropped so as not to press upon the front wall of the canal. That it compresses the outer parts is demonstrable at a glance or by moving the jaw with the finger thrust into the meatus; but it is generally forgotten that the bony wall often presents in adult life the foramen of lacking ossification near the drumhead, which is a constant feature in the early years of life, and that pressure of the jaw-condyle may be exercised here also.

**The Middle Ear.**—The Tubo-tympanic Cavity.—The drum-cavity, like the labyrinth, although varying much in its dimensions in individual cases, is practically of full size at birth, and undergoes little or no change in

the unmacerated canal the strong curves of the soft parts (Plate 10) still farther complicate the tortuosity, although these can be largely eliminated by good traction, usually up and back and out. Yet the gain is great in getting access surgically to the depths of the canal, if we lay forward the soft parts and work in the shorter, broader tube of the

the development of the temporal bone as a whole. Its full significance anatomically and pathologically is partly lost by those who do not follow Leidy in recognizing its threefold division—in considering the *antrum* as much a part of it as is the *attic* or *atrium*. Much good surgical comprehension and practice has crystallized about the name *attic* for the epitympanic space, and further clarification will be general when the antrum is no longer considered as one of the mastoid cells. The loose vagueness of ideas and terminology which calls the tympanic membrane “the drum” is only less manifest when we ignore this and the relation of the *scutum* (*pars ossca* of the drumhead, Walb) to the upper and posterior tympanic cavities.

Embryology shows us that the Eustachian tube, tympanum, and mastoid cells are one complex and slowly developing structure; and, while the last are possibly merely adventitious adnexa, we may yet learn to better appreciate their unity. Absent, however, at birth, when the organ is otherwise so complete, we may now regard them as unimportant. The tubo-tympanic cavity is a portion of the upper air-passages as much as are the accessory cavities of the nose—lined with an extension of the same nasal mucous membrane with all its pathological attributes. Much of this mucous membrane is at the same time virtually a periosteum, which magnifies its importance physiologically and increases greatly the importance of its lesions.

The tympanum or drum-cavity is in man situated in the midst of the temporal bone, some 20–35 mm. from the opening of the external canal. Its lower portion, the drum-cavity proper, or *atrium*, is bounded outward and down by the annulus and tympanic membrane, and has somewhat the shape of the body of a vertebra—a short cylinder with concave ends: the inward traction of the center of the drumhead and the protrusion of the promontory opposite bring these walls within about 2.5 mm. of each other. This dimension might well be called the height, as it is more vertical than the longer line

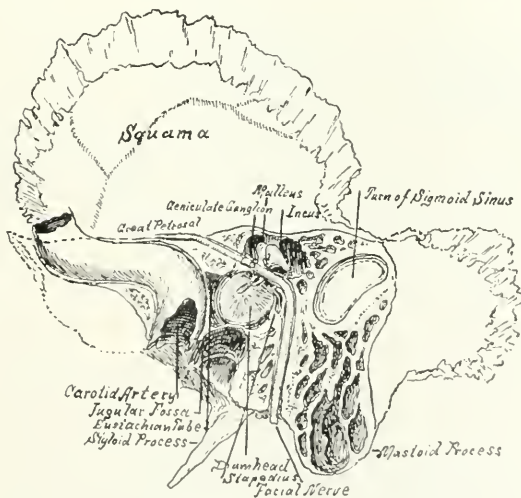


FIG. 446.—Outer wall of drum-cavity and relations of carotid, jugular, lateral sinus, and facial nerve to the tympanum.

from floor to roof, which is conventionally so called, the extreme obliquity of the annulus being forgotten. From front to back it measures some 12 mm., of which 9 mm. is bounded by the drumhead. Roof the atrium has none, for the attic is continuous with it above, defined externally by the tympanic

margin of the squama, but less definitely elsewhere. Including the 5 mm. of the attic, there is a distance of about 15 mm. from floor to roof, but only two-thirds of this belong to the atrium. The attic space above is broadest at the top, and overhangs markedly the inner end of the canal, with the *scutum*, which separates them, but a thin wedge of bone. It merges almost imperceptibly into the antrum out and back, an hour-glass contraction (*aditus*) being made by the protrusion of the facial and horizontal semicircular canals.

As viewed by the clinician, the drum-cavity seems bounded by the annulus, and through the transparent drumhead or any perforation various inner structures are seen. Anteriorly, the opening of the Eustachian tube makes a deep depression, as its lumen is nearly in line with the axis of the external meatus (they meet at 150° on an average). Down and back the dark niche of the round window (see Fig. 445) is bounded in front by the prominent lip of the promontory (*l*), marking the large beginning of the first turn of the cochlea. Up

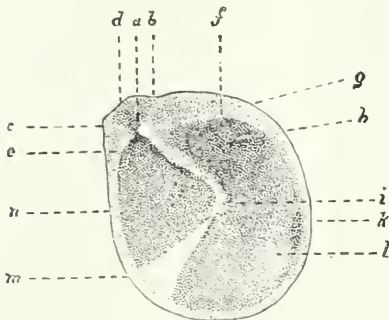


FIG. 447.—Drumhead showing light triangle, malleus handle, and folds about the short process.

and back more or less of the shank or descending process of the incus can be seen (*f*, Fig. 447), commonly parallel to the malleus handle, with a horizontal line stretching back from it—the stapedius tendon (*h*). Of the stapes little or nothing can be normally seen in the depths of the *pelvis oralis*. The curved line of Troeltsch's posterior pocket seems to broaden the handle of the malleus as it spreads upward, until at the incus-shank it meets the whitish line of the *chorda tympani*, which edges the backward sweep of the rest of it. This helps to shadow the stapes, the head and anterior crus of which are hidden by the incus, and come to light only when its shank is displaced or lost. In the floor posteriorly small depressions between trabeculae of bone give irregularity to what has been called the *recessus hypotympanicus*, important as being often almost or quite trenced upon by the head of the jugular. Above the short process (*a*) and the anterior (*e*) and posterior folds, which can generally be discerned even in the normal drumhead, is the *flaccid membrane*—sometimes defined into anterior (*e*), middle (*d*), and posterior (*g*) portions by visible “suspensory folds”—occupying the gap between the extremities of the annulus, where the tympanic margin of the squama completes the ring. This “Rivianian segment” is usually strongly notched, but varies, and gives varying size to the “Shrapnell's membrane,” as it is called after the Englishman who first pointed out its flaccid character. “Rivianian” it is also termed, as the site of the tiny pinhole which Rivinus, following Riolanus, pointed out as a frequent “foramen” here, and which Bochdalek and others have claimed to be congenital. Embryology offers no explanation of its occurrence, and anatomists and clinicians generally unite in denying its usual presence. Unknown in fetal or infantile specimens, it grows more common through childhood, averaging 10 per cent.; and in adult life it may be clinically recognized as a scar or patent opening in 25 per cent. of cases—frequently symmetrically. It is almost certainly the remains of a pathological perforation in spite of any negative history.

This upper region, like many other parts of the tympanum, varies much in its visibility; as the conformation and direction of the canal may render



illumination and observation difficult or easy. Especially is this the case in the region of the stapes, which is hidden more or less completely when the canal is horizontal, but shows better the more upward is its inclination. Non-transparency or variability of the drumhead structures has influence in concealing these important parts; but the surgeon who desires access to them should note carefully the axis of the canal in relation to the horizontal plane of the head, as given by the eyebrows, eyes, etc., since it is a criterion for what he may expect as to their apparent location.

The drumhead or *tympanic membrane* is the thinned remains of the tissues which separated the ingrowing external meatus from the outgrowing tubo-tympanic space. Long before birth it has become a delicate *membrana propria* of strong, slightly elastic fibers, the denser, outer layer radiating from the malleus handle, while the inner layer is circular. Both sets merge peripherally into the fibrous tissue of the tendinous annulus which forms the thick margin inserted into the sulcus of the bony tympanic annulus. To the circular fibers, which are most numerous near the annulus and least numerous in the intermediate portion, is largely due the characteristic funnel-shape of the drumhead, which increases when the structure is cut loose from its attachments. They also explain the maintenance of depressed conditions of the drumhead after the cause has been removed. This fibrous basis is clothed externally by the thin skin of the external canal and internally by the mucous membrane of the tympanum. This basis is present only throughout the extent of the *membrana tensa* filling the tympanic annulus. Above, in the Rivinian notch, the flaccid membrane of Shrapnell is almost devoid of fibrous tissue interposed between skin and mucosa. The normal membrane is capable of sustaining a pressure upon either of its surfaces of 15 pounds to the square inch, but will generally rupture under greater stress.

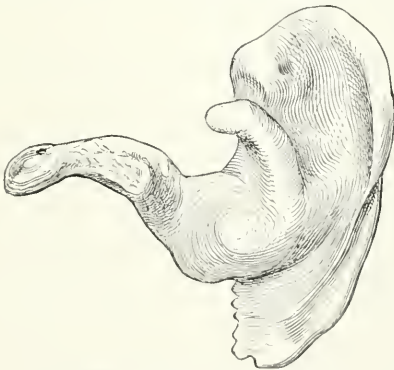


FIG. 448.—Metal cast of the external ear, showing the curves of the canal.

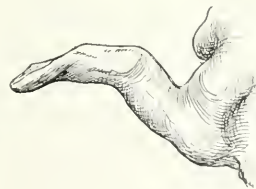


FIG. 449.—Cast of the canal in profile.

The handle of the malleus, partly sheathed in cartilage, is inserted between the layers of the *membrana propria*, although protruding much upon the mesial surface. Folds of the mucous membrane, with more or less of fibrous basis, run backward and forward from the manubrium, in relation in part with the *chorda tympani*, but forming with the drumhead inverted pockets, anterior and posterior. Much variability marks these, like many other tympanic structures, but generally they are well defined and can be seen through the transparent membrane. The annulus is very obliquely set—its plane (not a true plane, as it is slightly spiral) facing downward, outward ( $37^\circ$ ), and forward ( $37^\circ$ ). The planes of the two drumheads extended down-



ward and forward would meet at  $128^{\circ}$ . As the external canal is nearly transverse, averaging  $10^{\circ}$  upward and  $10^{\circ}$  forward as it passes inward, but with its innermost portion sometimes curving downward below the horizontal, it meets the drum membrane at a very acute angle. This is best measured upon casts of the canal, which show the upper back wall to pass without demarcation into the drumhead (Figs. 448, 449), while downward and forward the angle may be as small as  $30^{\circ}$  or less. This depends in part upon the indrawn funnel-shape of the drumhead, which does not lie in the plane of the annulus, but bulges slightly outside of this plane peripherally. It is centrally drawn 1 mm. or more within it by the traction of the *tensor tympani*.

**Ossicles.**—The two larger ossicles (see Fig. 457) develop from the axis of the first branchial arch (Meckel's cartilage), and are gradually insulated by the development of the tympanic cavity around them. The gracilis process of the malleus, "long" in infancy, but often absorbed or fused to the Glaserian fissure in adult life, is in the seventh week the largest part of the chain. The malleus handle, or manubrium, has been seen to develop in closest relation with the drumhead, which partly ensheathes it; and with the major blood-supply along its posterior border there must be very serious destruction to impair its nutrition. The head is suspended and vascularized from the roof, so that it is less prone to caries than the neck, in contact with which septic collections are apt to be held by Prussak's pouch; so the ossicle may be cut in two. The incus articulates with the saddle-shaped surface by a sort of clutch-joint, engaging snugly when the handle moves inward, but loosely at other times. Neither this nor the incudo-stapedial joint has a definite structure: equally careful students find it a synchondrosis, a true synovial joint with interposed meniscus or an intermediate form. There is a firm capsular ligament with a strong reinforcing band mesially, which constitutes the major support of the incus. When this is destroyed, the delicate attachment to the stapes, if not already severed by the erosion of the incus-shank, the most vulnerable part of the chain, and the stronger semi-articulation of the tip of the horizontal process to the mouth of the antrum, rarely retain the incus in place. The stapes is the virtual key to the value of the chain, and in the absence of the rest can fulfil most of the needs of hearing. Its annular ligament may be considered a synchondrosis with the edge of the oval window, and its foot-plate can be torn away without necessarily tearing the membranous closure of this fenestra. Membranous bands unite the crura with each other and the sides of the niche in most variable manner; but these may be the most important factors in the great majority of impairments of hearing, and their minute and extended study is greatly needed.

The Eustachian tube, some 35 mm. in length in the adult, is a trumpet-shaped canal extending from the pharynx to the tympanum. It is usually collapsed, and presents on transverse section a narrow vertical fissure capable of no great lateral distention. The distal third of its length is supplied with bony walls by the temporal bone; but the longer mesial portion has only cartilaginous support furnished by the "hook cartilage" above (Fig. 450), which in the median half extends down on its posterior wall and constitutes the basis of the prominent posterior lip of the pharyngeal mouth (Fig. 451). The tympanic end also broadens from the narrow isthmus at the junction of the bony and cartilaginous portion, to merge imperceptibly into the anterior part of the tympanum. The tube is lined with columnar ciliated epithelium and its submucosa is full of racemose glands. The basement membrane is in close relation with the cartilage throughout its extent; but where cartilage is lacking, is in like relation to the

membranous wall. Two important muscles act upon the tube, the so-called *tensor*, and the *levator veli palati*. The latter lies beneath the tube, and acts upon it only by reason of the upward pressure of its shortening belly, per-

mitting rather than causing the walls to separate. The tensor is more complex in its structure and relation. It arises in part from the hook of the cartilage, which it tends to open by its contraction; other fibers arise from the membranous anterior wall of the tube and tend to draw it away from contact with the opposite wall. Still other fibers arise from the basal carti-

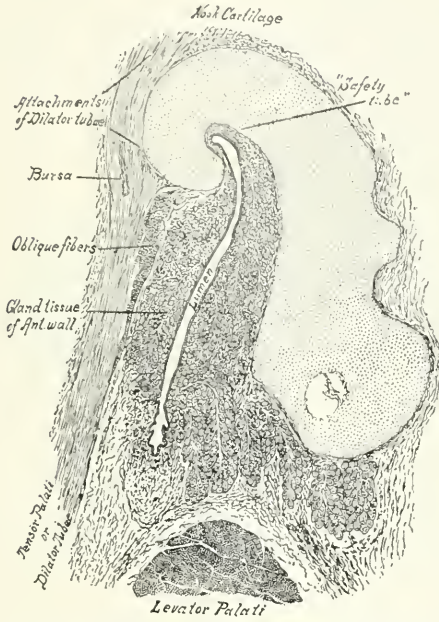


FIG. 450.—Vertical section of Eustachian tube in the middle third, showing the tubo-palatal muscles.

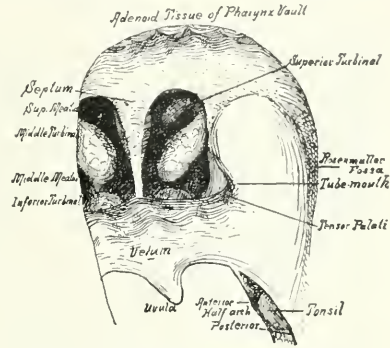


FIG. 451.—Pharyngeal tube-mouth as seen by posterior rhinoscopy.

lage above; but any compressive action upon the hook is probably slight, and I have found a bursa interposed in some cases to facilitate play. Passing downward and forward, the tensor fibers converge to the hamulus of the sphenoid, where the tendon turns inward and spreads in the velum. Weber-Liel has shown that some of the fibers of the tensor are inserted upon the hamulus, and could act, therefore, only as a *dilator of the tube*. Some of the fibers which arise from the hook of the cartilage seem to merge with the fibers of the *tensor tympani* which extend in the opposite direction; and certainly they have common enervation and consonant action. The latter muscle occupies with its belly the canal, partial or complete, which lies along the roof of the bony Eustachian tube, and extends backward and out to the inner wall of the tympanum, where the little tube-like trochlea (Fig. 445) permits its tendon to turn directly outward and, crossing the drum-cavity, to insert itself upon a tiny tubercle on the handle of the malleus nearly directly in from the short process. Disadvantageous as is its leverage, it has abundant power to keep tension on the drumhead through the manubrium. The stapedius, the other intratympanic muscle, is still more snugly lodged in a bony case—the pyramid (see Fig. 445) at the back part of the drum-cavity, between the facial canal and the round window niche. Below, this is open to receive nerve-supply from the facial—above, its cavity curves forward to give exit to its thread of a tendon close to the head of the stapes, to which it is attached. Its action is supposed to be rather antagonistic to the *tensor tympani* and to limit the pressing of the stapes into the oval window.

Plications of the mucous membrane serve with their fibrous basis to sus-

pend the malleus and incus from the roof of the tympanum, to form an external ligament fastening each to the upper tympanic margin and to accompany each of the tensor tendons and the gracilis process respectively. Themselves variable, these bands are reinforced by others less constant, which serve to subdivide the attic space more or less completely into several or, at times, many cavities. One fairly constant "pouch" lies between the neck of the

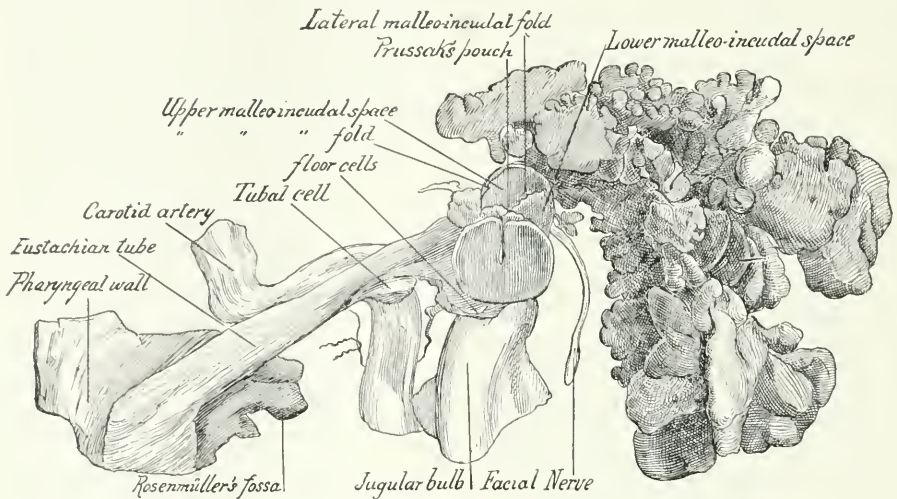


FIG. 452.—Metal cast of the middle-ear spaces, lateral side (Siebenmann).

malleus and the flaccid membrane, having the short process for its floor, as described by Prussak. Politzer has found this often subdivided, while Kretschmann thinks the usual condition is for the pouch to extend backward along the body of the incus. Much in the pathology of inflammation in the attic depends upon the individual variations of these parts and the retention of secretions within the spaces thus isolated (Fig. 452).

In the antrum comparable septal bands are often present; and its lining mucous membrane, which extends into the communicating pneumatic cells of

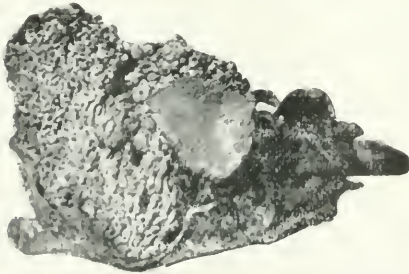


FIG. 453.—Metal cast of very diploëtic mastoid, with pneumatic cells only close about the antrum.

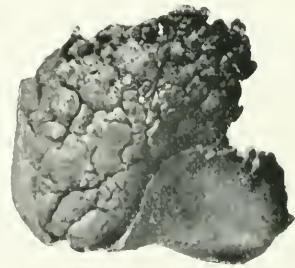


FIG. 454.—Cast of wholly pneumatic mastoid.

the mastoid, often narrows greatly the entrances of these. Although sufficient for good drainage in health, these openings are apt to become stenosed by inflammatory swelling, and by retaining the secretions give rise to mastoid empyema. There is usually a radiate or racemose arrangement of the *pneumatic cells* about the antrum, due to the fact that they are outgrowths of the



tubo-tympanic space. At birth there is merely diploëtic structure of the tiny mastoid and adjacent pyramid; and in the developed bone this may never be wholly displaced (Fig. 453), although probably steadily decreasing as the pneumatic cavities enlarge. Little of it remains in the great majority of adult bones which I have examined (Fig. 454); and study of a thousand indicates that hardly 2 per cent. could be classed as diploëtic, and only some 10 per cent. as combining a notable amount of diploë with the pneumatic spaces. No mastoid is absolutely pneumatic, although some senile bones show a single thin-walled cell occupying the greater part of the process; but no demarcation can be drawn as to how far the air-cavities may be expected to extend. In some specimens they invade the occipital bone backward; they may occupy the zygomatic process and hollow out the pyramid to its very tip anteriorly—usually they pass close to the sigmoid sinus. Some generally connect with the beginning of the Eustachian tube, lying in its floor in close relation to the carotid. Bordering on the digastric fossa, they are thin-walled and large on the mesial as well as on the distal side. The *paramastoid* or *paracondyloid* outgrowth sometimes seen upon the occipital, as well as even the condyle itself, may be occupied by these pneumatic extensions of the tympanum. Their function, if any, is doubtful; and they probably show merely Nature's economy of material and only rarely these structures within as they grow externally larger. Too utterly variable for the condition on the one side to form much of a criterion for the other, they have no very great surgical importance. Hyperostotic inflammation can solidify the bone with equal promptness whether it be pneumatic or diploëtic—caries is apt to be equally destructive and extensive in each; possibly pyemic extension is less ready from the pneumatic mastoid than when considerable diploë is present. When aural surgery regarded the antrum as merely one of the mastoid cells, the others seemed of little inferior importance; but more precise views of the anatomy and pathology are now dissipating this view. The surgeon, in undertaking to open a mastoid empyema, acts upon the indications as to the location of the pus, whether in the antrum alone, in the mastoid-tip, or throughout the process, and considers the cell-spaces met only as holding out of his way the more important dural structures which he desires to avoid in opening his track—usually to the antrum. His concern is principally that no anomalous forwardness bring the sinus into his field nor undue lowness of the middle fossa expose the dura to unintended attack. He must know that while 10 mm. is the average width of his field, the lateral sinus may wholly occupy it; that above the *spina* there may be none of the 6 mm. of space usually to be expected; and that every bone, whether left or right, in brachycephalic or dolichocephalic, must be treated as though presenting the most dangerous relation possible, until exploration has proved the contrary. Boring instruments must give place, therefore, to gouge and spoon; and the mastoid surface must be bared and well scrutinized, and not blindly attacked even at the well-chosen point. For the antrum this is usually about 5–10 mm. horizontally back of the suprameatal spine, and the cavity should be reached at a depth of 10–15 mm. by a channel parallel to the meatus, but directed slightly more upward. Probably the facial and semicircular canals on the farther side of the antrum are never less than 15 mm. from the mastoid surface; but they are rarely more than 25 mm.—a depth which may be taken as the maximum permissible penetration.

Much important anatomical detail has been here omitted, such as the origin and course of the fibers of the acoustic nerve and their distribution. Those wishing more than is shown in Fig. 441 are referred to the exhaustive works.



# THE PHYSIOLOGY OF THE EAR.

BY FRANK ALLPORT, M. D., AND R. O. BEARD, M. D.,  
OF CHICAGO, ILL. OF MINNEAPOLIS, MINN.

THE physiology of the ear is one of those functional problems the solution of which depends upon the application of physical principles to the operations of the living tissue-cell. It involves, essentially, the translation of physical phenomena into forms of physiological activity. Nevertheless, a clear distinction must be made between the physical laws under which auditory stimuli are conditioned and the physiological laws under which auditory impressions are developed and interpreted.

**The production and propagation of sound-waves** are governed by these physical laws. Matter, in direct ratio to its elasticity and inversely to its density, is susceptible of vibratory motion. Those forms, phases, or degrees of vibratory motion to which the organs of hearing are responsive are termed sound-waves. The limitations of this term are dependent upon the capacity of the auditory apparatus, and vary, therefore, with the degree of auditory development in the particular species or individual.

Waves of sound may be defined, under these limitations, as the to-and-fro or oscillatory movements of particles of matter, each particle similarly affecting its immediate neighbors, so that alternating condensations and rarefactions of these particles of the sound-transmitting medium are produced. These vibratory movements occur in a direction either longitudinal or transversal to the axis of the propagation of the sound, according to the nature and arrangement of the conducting agent.

Particles of matter which are at similar points of condensation or rarefaction are said to be in the same "phase." The distance between such particles in similar phase is termed the wave-length. This distance—and therefore the wave-length—varies with the velocity of the wave-movement and with the rate of the sound-vibrations—*i. e.* the degree of velocity per second, divided by the number of vibrations per second, gives the measure of a particular wave-length. The velocity of sound-waves is determined by the relative elasticity and density of the transmitting medium.

A wide variance is discovered in the sound-propagating qualities of different media, such as air, water, solids, etc. ; but the superiority of a medium as a conductor of sound-waves does not altogether overcome the difficulty of their transference from one medium to another, as from air to water.

The impact of sound-waves upon substances of suitable form and position will cause a reflection of sound ; that is, a reprojection of sound-waves of similar character to a distant focus. Echo is an illustration of sound-reflection from a reflector so distant that the primary waves die away before the secondary or return waves reach the ear at the focal point.

Sound-waves, passing through a substance of biconvex form and of greater density than the air, may be refracted, as light is in passing through

a lens, to a focus in front of the refractive body. The expansion or diffusion of sound-waves is limited in their conveyance through tubular passages, and thus sound may be said to be susceptible of collection.

Sound-waves are possessed of certain physical properties which are the subjects of recognition by the organs of hearing. The accurate analysis of these qualities is dependent upon the degree to which the specialization of auditory function has been carried.

Sound-waves are measured (1) by their *amplitude*; that is, by the energy of the movement of the vibrating particles—by the degree of their excursion upon either side of a position of rest. This property marks the force of the stimulus to which the auditory nerve-terminals are subjected, and, together with the degree of responsive irritability possessed by these terminals, determines the *loudness* or *intensity* of a sound.

Sound-waves are measured (2) by that property which is termed *pitch*—a feature determined by the number of vibrations per second which the particles of the sound-transmitting medium undergo. The range of variability in this vibration-rate possible of appreciation by the human ear is a very wide one, although its limits vary widely with the degree of auditory development. The appreciable extremes of vibration are placed between 24 per second and 40,000 per second,<sup>1</sup> but the more usual limits of discernment are between 33 and 16,000.

Sound-waves are characterized (3) by the presence or absence of rhythm in the recurrence of their vibrations. If the vibrations have a regular periodicity, they are said to give *musical sounds*; if they are of irregular rhythm, they constitute *noises*.

Waves of sound, and particularly of musical sound, are distinguished (4) by their *quality* or timbre, a property which rests upon the fact that they are usually of a compound character—*i. e.* they are associated or consist not of single, but of several, waves. This association is usually of a *fundamental* or dominant *tone*, characteristic of the vibrations of the conducting medium as a whole, with *partial* or over-tones produced by the coincident vibrations at a more rapid rate, and therefore of a higher pitch, of different portions of the conducting medium.

When the vibration-rates of associated tones, whether fundamental or partial, are in the same arithmetical relation as small whole numbers are to each other (*e. g.* as 4 to 5, or as 6 to 8)—that is, when their relationship of rate cannot be expressed in integral multiples—the resultant note is termed a harmonic.

When the vibration-periods of coactive or associated sound-waves are not coincident, or in this relationship of small whole numbers to each other—whether they give rise to fundamental or to over-tones—a phenomenon termed *beat* ensues. The beat is due to an increased intensity of sound whenever the waves are in the same phase—that is, when they are alike in the phase of condensation or alike in the phase of rarefaction—and to an interference with or diminution of the sound when the waves are in opposite phases—that is, the one in rarefaction and the other in condensation.

The number of these beats depends upon the difference in the vibration-rate of the associated waves. When this difference is not great and the beats are therefore few, they are readily appreciated by the ear and do not produce unpleasant effects upon it. As the difference of vibration-rate increases and the beats become more numerous, they introduce a discordant element, and at length (when about 33 per second) they produce a sort of vertigo of the

<sup>1</sup> Blake and others cite the appreciation of tones to 80,000 or more.

auditory sensations which we translate as *dissonance*. Further increasing in number, the beats become gradually fused and the roughness of sound lessens, until they reach the extreme time-limit of distinct sensations (132 per second) and are lost. So that sound-waves whose vibration-periods are widely different, and which give rise to a very large number of beats very frequently repeated, afford no appreciation of beats whatever to the human ear.

Of especial bearing upon the physiology of hearing are the physical principles of sound-selection. Certain substances have a capacity for *sympathetic vibration*. They are inherently endowed with a definite vibration-period, and whenever sound-waves of this particular pitch approach them, they are excited to vibrations in harmony with the stimulating waves, and thus serve to swell the volume of the primary sound. To vibrations of period variant from their own they are dumb. So marked is this tendency to sympathetic vibrations in certain media that they are termed resonators, and the quality which they possess is called *resonance*.

Sympathetic vibration is so acute a quality in some agents—as, for instance, in the strings of a piano-forte—that a complex musical note sounded in their near neighborhood will be resolved into its component tones by their selective power, each string responding to its own intrinsic tone. In this quality lies the foundation of the analysis of sound, unquestionably one of the physico-physiological functions of highly specialized organs of hearing.

These functions of the auditory apparatus will be best understood if the close relationship between physical principles and physiological conditions, which this term implies, is borne in mind.

**The Sound-collecting Apparatus.**—The external ear, consisting of the pinna and the meatus, has the primary duty of collecting, reflecting, and

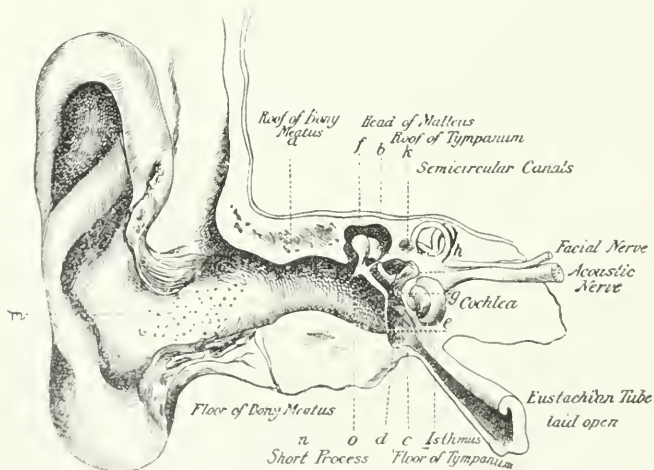


FIG. 155.—Frontal section of the organ of hearing (modified from Politzer).

perhaps, to a degree, resonating the waves of sound. The auricle with its cone-like form and its labyrinthine depressions is essentially a sound-gatherer. In this function it is assisted in some animals, although rarely in man, by a group of muscles—the *attollens auriculæ*, moving the ear upward; the *attrahens auriculæ*, drawing it forward and upward; and the *retrahens auriculæ*, pulling it backward. Slighter alterations in the form of the auricle may be effected by a second group—viz. the *tragicus*, the *antitragicus*, the



helices major and minor, the transversus, and the obliquus auriculæ. By the tragus and by means of the curvature of the meatus the drumhead is protected from the too severe impact of powerful vibrations or currents of air, and the canal from the too easy entrance of insects and foreign bodies. The presence of hairs and of the cerumen in the meatus also guards the ear from these invaders.

The position of the tragus and the form of the curvature of the canal also suggest that from the center of the conch sound-waves may be reflected to the inner face of the tragus, from that surface to the roof of the meatus, and thence to the tympanic membrane. The tubular passage of the meatus indicates its sound-collecting and, possibly, its sound-resonating qualities.

**The Sound-conducting Apparatus.**—The middle ear, including the tympanic membrane, the chain of ossicles, the intratympanic muscles, and the fenestræ ovalis and rotunda, together with the perilymph enclosed by the bony labyrinth of the internal ear, is pre-eminently the organ of sound-conduction. To this function the appendages of the middle ear, the Eustachian tube, the antrum, and the mastoid cells indirectly minister. In the process of conduction the sound-waves which break upon the tympanic membrane are transmuted, through its agency, into a mechanical movement, a molecular vibration, which involves both the chain of ossicles and the perilymph, and is retransmuted, through the medium of the latter, into sound-vibrations in the internal ear.

The **tympanic membrane**, a small, thin, membranous sheet, tautly stretched across the junction of the external with the middle ear, with its slight irregular convexity, with its radial and circular fibers centering at the *umbo* and giving it a certain fixity of form, with its tensity increased by muscular action, is admirably adapted to its purpose. The longitudinal vibrations of the sound-waves which reach it through the column of air in the external meatus excite in it, as they do in other bodies similarly stretched and whose cross-section is of similarly small dimension, vibrations of a transversal form. Thus the drumhead vibrates inward and outward between the cavities it divides. Through the attachment of the handle of the malleus to its umbo it is not only put into direct relations with the chain of ossicles, but is controlled by the tensor tympani muscle. This muscle, the tendon of which is attached to the upper third of the handle of the malleus, and traverses a portion of the middle meatus, executing around a bony eminence near the Eustachian canal a turn almost at right angles to the body of the muscle, takes its fixed point in a groove running above the lumen of that canal. The contraction of this muscle, controlled by efferent branches of the fifth nerve, serves, in all probability, a double purpose. It draws the malleus inward, and thus increases the tensity of the tympanic membrane, rendering it more acutely responsive to sound-waves of high pitch. It also increases the contact between the handle of the malleus and the drumhead at the umbo, the former serving, in consequence, as a "damper" by which the fundamental tone of the tympanic membrane—which in bodies of such structural form would tend to be over-prominent—may be diminished.

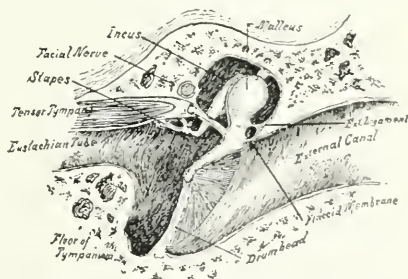


FIG. 456.—Vertical section of the middle ear, drumhead, and external canal, showing the ossicles and tendons of tensor and stapedius.



This suggests the fact that the vibrations of this membrane are of a composite character. It is susceptible of simultaneous response to sound-waves having a very wide range of variance both as to pitch and quality.

**The Ossicular Chain.**—These delicate vibrations of the drumhead are brought to bear upon the chain of ossicles (Fig. 457) through the handle

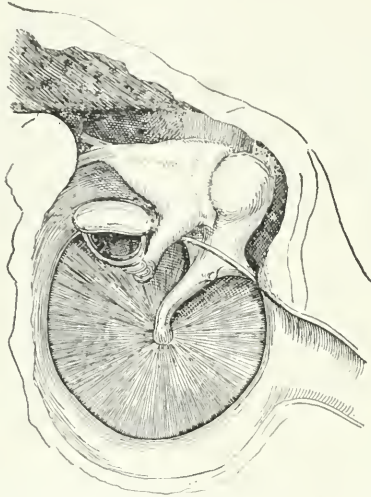


FIG. 457.—Ossicles from within, showing attachment of malleus handle to drumhead, the insertion of the tensor tendon below the chorda, the axis of rotation through the gracilis process and the posterior ligament of the incus, and the tooth of its articulation with the malleus head.

of the malleus. The ossicles—which, taken as a whole and physiologically, must be regarded as a continuous chain—are too minute, in all their dimensions alike, to encourage the theory that they are a medium of sound-conduction by molecular vibration. The shortest of wave-lengths is long as compared with their greatest measurements. Moreover, the mutual arrangement of the malleus, the incus, and the stapes, and their relations to the drumhead at one extremity of the chain and to the oval window at the other, are such as to indicate their performance of an excursion upon the principle of a lever of the second class. A line drawn from the tip of the horizontal process of the incus through the incudo-stapedial joint of the same bone to the end of the handle of the malleus represents this lever (Fig. 458). The handle of the malleus is the point of applied power, begotten by the vibrations of the tympanic membrane; the end of the short process of the incus is the fulcrum, and the incudo-stapedial joint is the point of the effect, which is transmitted through the attached stapes and causes its impact upon the oval window. The unity of this lever is secured by the interlocking of the tooth of the incus with the groove of the malleus. At the same time, the ossicular chain is safeguarded from undue rigidity by the loose capsular ligament attaching the head of the malleus to its articulation with the incus.

Thus in the event of excessive pressure developed within the middle ear, pushing out the drumhead and carrying the malleus with it, the ossicles no longer act as a whole, since the reversal of the lever would tend to tear the stapes away from the fenestra ovalis. Instead, a separation occurs between the articular surfaces of the malleus and the incus, the head of the former gliding out of its socket and the tooth of the latter tending to unlock. Should this outward movement of the drumhead be so extreme as to carry a part of the head of the malleus back upon the incus again, the point of most forcible

contact would again be at the tooth, which would then serve as a fulcrum, converting the ossicles into a lever of the first class and carrying the stapes back again upon the fenestra.

In the ordinary action of this physiological lever the movement of the short arm is materially less than that of the long arm, while the energy of the movement is multiplied two and a half times between the point of its application and the point of its discharge. As Helmholtz states it: "The mechanical problem which the apparatus within the drum of the ear had to solve was to transform a motion of great amplitude and little force, such as impinges on the drumhead, into a motion of small amplitude and great force, such as had to be communicated to the fluid of the labyrinth." Thus a sharp and relatively forcible blow is struck by the stapes upon the oval window. The effect of this blow may be accentuated or diminished by the action of the stapedius muscle. This muscle from its origin in the pyramid in the back wall of the tympanic cavity passes to its insertion upon the capitulum of the stapes. It is efferently controlled by fibers of the seventh nerve. Under ordinary circumstances its contraction draws the foot of the stapes outward toward the drumhead, while the heel is thus brought more sharply into contact with the fenestra. A more forcible contraction, which may be excited reflexly by too powerful vibrations of the tympanic membrane, would tend to draw the whole foot-plate away from the oval window, and would thus diminish the pressure upon the contents of the labyrinth.

Sound-vibrations may reach the middle ear through the bones of the skull instead of by the ordinary path of the meatus, or they may be transferred from one side of the head to the other; but in either case it appears to be true that the tympanic membrane receives these sound-waves and transmits their effects through its own transversal vibrations to the chain of ossicles.

It is possible that to some small degree—and especially in the event of fixity of the ossicles—the air contained in the tympanic cavity may be thrown into vibrations, and that these may affect the perilymph through the oval or round window.

**The Appendages of the Middle Ear.**—A thin mucoid fluid is secreted by glands imbedded in the submucous lining of the tympanic cavity, or more probably formed by the deliquescence of its effete cells. The ciliated epithelium, which constitutes the mucous membrane of the cavity, excepting upon the surface of the ossicles and the tympanic surface of the drumhead, and is found also in the Eustachian tube, with which the tympanic cavity is continuous, serves to carry the excess of fluid toward and through the tube into the pharynx.

The Eustachian tube has an irregular lumen, and in its lower portion its walls are in somewhat loose contact, and appear to be, as a usual thing, closed. The tube opens for the discharge of the mucous secretion of the middle ear into the pharynx; it is opened also during the act of deglutition, when air finds its way into the middle ear. Its most important and, perhaps its sole, functions are thus to drain the tympanic cavity and to preserve an equilibrium of pressure between the gaseous contents of the cavity and the atmosphere. Should the contained gases become absorbed and the tube be impermeable, a vacuum results which may cause retraction of the drumhead and disease of the intratympanic tissues. The opening of the tube during acts of deglutition is sufficient, as a rule, to maintain this equilibrium of intratympanic and extratympanic pressure.

The antrum and the mastoid cells are, physiologically, extensions of the tympanic cavity, although their communications with that cavity are not always patent. Their functions are still a matter of conjecture. They proba-

bly serve as pneumatic spaces within which a supply of air may be retained as an additional means of maintaining the air-pressure within the tympanum. They have been supposed also to serve as diffusion-chambers for excessive sound-vibrations, which may be communicated to the air in the tympanic cavity, and which might otherwise fall with undue energy upon the windows of the labyrinth. There is little evidence, however, in support of this view, since sound-waves, within ordinarily wide limits, and whether conveyed through the external meatus or through the bones of the head, are transmitted to the tympanic membrane, and, centering at the umbo, are forwarded through the movements of the ossicular chain rather than through the air of the cavity.

**The Bony Labyrinth and the Perilymph.**—By means of the fenestra ovalis and the fenestra rotunda, the windows of the bony labyrinth, increase and decrease of pressure in the perilymph are provided for. The influence of the sound-vibrations of the drumhead, through what may be called the sound-movement of the ossicles, is conveyed to the perilymph by the impact of the stapes upon the membrane which curtains the oval window and divides the tympanic cavity from the vestibule. The shock which is thus transmitted to the fluid of the bony labyrinth follows the course of its cavity, and is finally expended upon the membrane of the round window, which curtains the cochlear canal from the middle ear. Thus in the round window a safety-valve is afforded for any excess of pressure.

What has been said of the chain of ossicles with reference to their insusceptibility to molecular vibrations is equally true of the perilymph, enclosed as it is in a bony cavity of minute dimensions, of labyrinthine form, and with resistant walls. The impact of the stapes upon the oval window produces, not waves of sound travelling through the particles of this fluid, but a wave-movement which involves the perilymph as a whole. So difficult is the transference of sound-vibrations from one kind of medium to another, that the vibratory movement of the perilymph more readily develops sound-waves in the walls of the membranous labyrinth than would a series of molecular vibrations passing through the particles of this fluid. Such a movement has, in fact, an advantage over sound-vibrations of the molecular form as a means of communicating to the sensitive structures of the internal ear the influence of the sound-waves which break upon the drumhead.

**The Sound-recording Apparatus.**—The utricle, the semicircular canals, the saccule, and the cochlear canal make up the membranous labyrinth, enclosing the endolymph and surrounded by the perilymph within its bony sac. These organs are concerned not merely with the receipt of auditory impressions in general, but with the analysis and synthesis of sound. The impressions which they record are destined for the development of auditory sensations, which, in their turn, give rise to auditory perceptions and judgments relating to intensity, rhythm, pitch, quality, distance, location, etc. The part which each portion of the membranous labyrinth plays in the attainment of these physiological ends is not yet sufficiently well worked out to justify much in the way of precise statement. Certain propositions may be established, however, with some measure of confidence, and these form the basis for certain safe conclusions.

The principles of sound-conduction indicate that the walls of the membranous labyrinth, with their fibrous structure, are a better medium for the development and transmission of sound-waves, as the result of the impact of the perilymph upon them, than the endolymph contained within these membranous walls can possibly be. The endolymph is a viscid fluid whose density would prove an obstacle to acute vibratory motion. In variable



quantity it bathes the specialized auditory epithelium of the cristæ, the maculæ, and the cochlear spiral (Fig. 458). From its contact with a highly vascular membrane, the stria vascularis, from its identity with the cerebral fluid and the continuity of its channels with those of the brain, from its homology with nutrient fluids in other localities, it may fairly be considered as an agent of nutrition to these epithelial cells, rather than as a medium through which sound-waves are conveyed to them. A difficulty, too, and a quite unnecessary one, is involved in the idea of the transmission of vibrations through the walls of the membranous labyrinth to a medium of so markedly different a character and vibratory quality as the endolymph.

It would seem that the auditory epithelium resting upon the inner surface of these membranous walls must be more readily affected by sound-vibrations

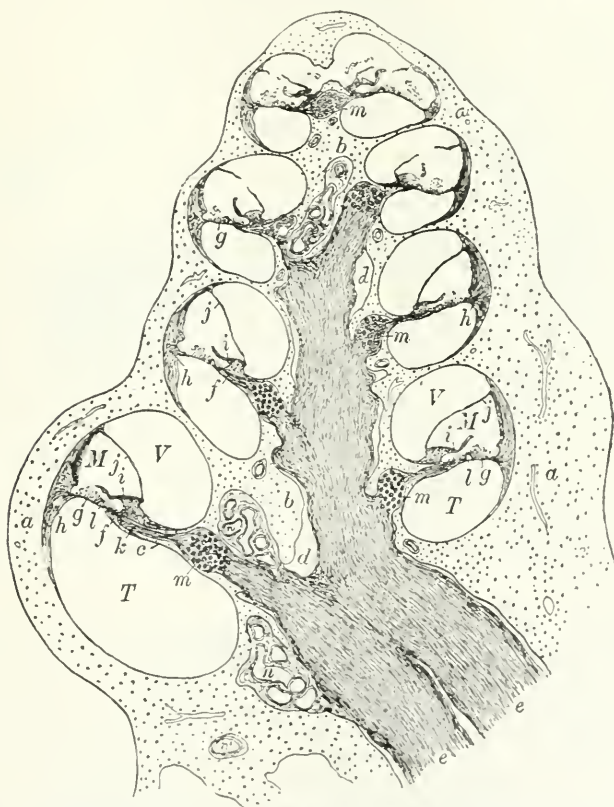


FIG. 458.—Section of guinea-pig's cochlea, with its scala media (*M*) winding from base to apex between the vestibular (*V*) and tympanic (*T*) scalæ (Piersol).

directly transmitted to it from beneath than by vibratory movements in the endolymph above (Fig. 459).

The peculiar form of the bony labyrinth, as related to the points at which the sweep of the perilymph begins and ends—viz. at the two fenestræ—indicates that the force of the movement of the perilymph is probably conveyed across the membranous labyrinth, and bears strongly upon the ampullæ, the utricle and saccule, and the walls of the cochlear canal.

The functions of the internal ear are of a more varied character than is suggested by the general term auditory impressions. There are reasons, still



under debate, but perhaps sufficiently conclusive, for regarding the semi-circular canals, or the terminals of the vestibular nerve in their crista, as well as in the macule of the utricle and saccule, as the source of afferent impressions which assist in the preservation of both static and dynamic equilibrium.<sup>1</sup> Whether these impressions arise from the movements of the endolymph within the semi-circular canals, and are therefore dependent upon position, or whether they are the effect of vibrations transmitted through the walls of the ampullæ to the vestibular terminals, is a question still *sub judice*; but there remains little doubt that these terminals are, in one way or the

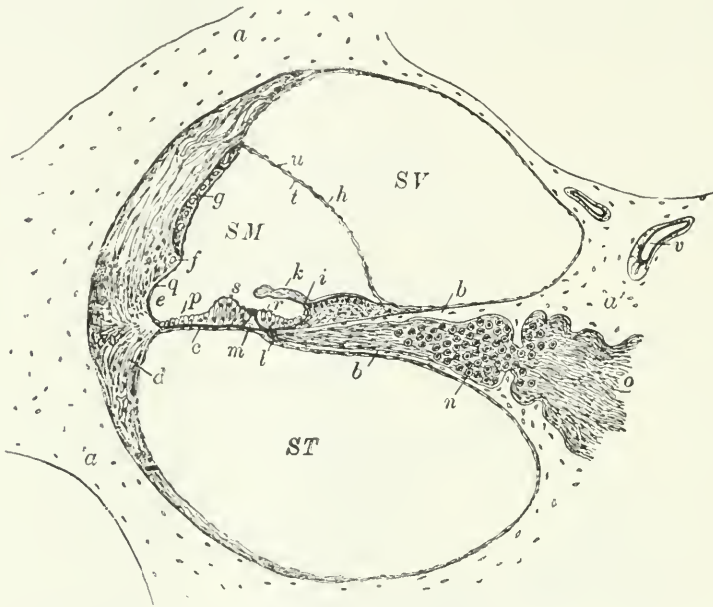


FIG. 459.—Transverse section of a lower turn of the cochlea, showing the structure and relations of the cochlear canal, SM (Piersol).

other, concerned in the development of equilibrar impressions. The presence of the so-called otoliths or otoconia in the walls of the labyrinth has given rise to the suggestion that they are concerned in the causation of these impressions. Recent experiments tend, however, to prove that the vestibular portion of the labyrinth is not, in an exclusive sense, an organ of equilibration. It is simply an afferent field from which the centers of co-ordination receive a certain measure of instruction.<sup>2</sup> In the event of its injury or removal, leading to temporary symptoms of vertigo, compensatory phenomena have been developed, which, in their readiness of appearance and their measure of substitutive function, are in direct ratio to the degree of cerebral development.<sup>3</sup> One distinct phase of the equilibrar functions of the internal ear is observed in its afferent regulation of compensatory movements in the eyeball.<sup>4</sup> But while the evidence holds good that the auditory epithelium and the nerve-terminals of the crista and the macule are the recipients of other than purely auditory impressions, it is not necessary to dissociate the equilibrar from the auditory functions of the vestibule, or to consider it

<sup>1</sup> Howell: *American Text-Book of Physiology*.

<sup>2</sup> Fano and Marini: *Sperimentale*, Parts 5 and 6, 1893.

<sup>3</sup> Ewald: *Pflüger's Archiv*, lx, p. 492.

<sup>4</sup> Crum-Brown: *Lancet*, May 28, 1895.

exempt from auditory duties. The fact that this organ is of some physiological service in co-ordinating the movements of the body does not even argue a separative function for this purpose. The sense of equilibrium is not wholly independent of the sense of hearing. Loud or peculiarly harsh noises, and those extreme disturbances of rhythm which are incident to the occurrence of numerous beats in musical sounds, often beget sensations of a vertiginous character. Extremely deaf persons have a characteristic uncertainty of gait, which in deaf-mutes often amounts to actual insecurity. Forty per cent. of the unfortunates of this class who have been examined have been found faulty in co-ordination.<sup>1</sup> An absence of nystagmus is frequently observed in such persons (Crum-Brown). While these facts do not conclusively prove the interdependence of equilibrar and auditory functions, they suggest a very close relationship between them.

Furthermore, the absence of the cochlea or its very rudimentary form in certain animals who possess the sense of hearing to a marked degree, compels the recognition of the vestibular portion of the internal ear as a receiver of auditory stimuli of at least certain kinds. Conversely, the form and the arrangement of the cochlea (Fig. 460) indicate unmistakably that it is an organ of sound-analysis and perhaps of sound-synthesis, but do not offer equally good evidence of its capacity to develop those auditory impressions which create sensations and judgments relating to intensity, rhythm, dissonance, etc.

It is altogether probable that the auditory epithelium and the nerve-terminals of the macule, and perhaps of the cristæ, are the media by which are appreciated those qualities which pertain to so-called *noises*, and which establish the differentiation between rhythmic and arhythmic sounds (Howell). It is, in fact, these primary auditory functions with which those animals are conspicuously endowed who have only the vestibular portions of the internal ear, while we have little or no evidence that they are possessed of the faculties of sound-analysis and synthesis.

These most highly specialized of auditory functions by which the variations in pitch and quality of sound-waves are recognized, by which composite notes are resolved into their component tones, and by which individual tones

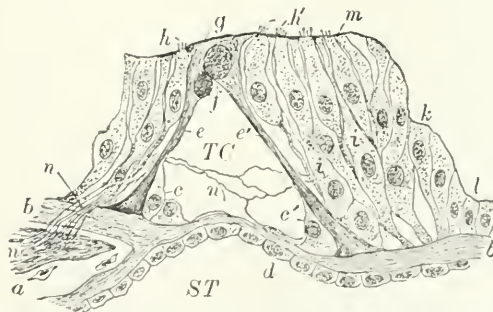


FIG. 460.—Corti's organ, showing the inner (*h*) and outer (*k*) hair-cells, the supporting pillars (*f*, *g*), and basilar membrane (*b*) (Piersol).

are fused into complex sensations, are unquestionably possessed by the cochlea.

In the basilar membrane (Fig. 460), upon which the organ of Corti rests, is found the only structure in the highly developed ear which satisfactorily accounts for the faculty of tone-selection. Although in man it is of small

<sup>1</sup> Bruck: *Archiv f. d. ges. Physiol.*, vol. lix, p. 16.

dimensions as a whole, its radial tensility, together with its longitudinal laxity, the sufficiently wide range of difference in the radial lengths of its fibers, and the number of these radial fibers, estimated at 24,000, are qualities which suggest its vibratory function and endow it with ample possibilities of selective vibration. By selective or sympathetic vibration is meant the possession by its individual fibers of intrinsic pitch, in consequence of which each will vibrate only in harmony with a sound-wave whose vibration-period is identical with its own.

To the rods and cells of the organ of Corti these vibrations are certainly transmitted; in them they are intensified perhaps, and by them are conveyed as impressions of sound to the terminals of the auditory nerve. Physiology has not yet gone so far as to differentiate the several functions of the rods, 9450 in number, of the inner and outer hair-cells, numbering 15,500 (Howell), of the twin-cells of Deiters, or of the cells of Hensen and of Claudius, which all enter into the delicate structure of this organ. They are doubtless the media of communication between the basilar membrane and the terminals of the auditory nerve, but they are probably far more than this. Their structure and mutual arrangement suggest a mechanism for the execution of vibrations of rapid period or high pitch, and for the differentiation of varying vibration-rates. They may serve not only as a means of analyzing composite sound-waves, but as a means of synthesizing complex auditory impressions.

In the tectorial membrane exists, seemingly, a physiological "damper" by which excessive vibrations or too dominant tones are diminished. While it is difficult to demonstrate its possession of this function, its form, situation, and relations to the organ of Corti and to the overarching membrane of Reissner justify the conclusion. Excessive wave-movements within the vestibular scala would necessarily bear upon the stretched membrane of Reissner, and would subject the endolymph beneath it to a pressure which, operating upon the upper surface of the tectorial membrane, would depress its free extremity toward or upon the delicate hair-cells which it surmounts.

That such highly elaborated functions as these attributed to the organ of Corti exist in the human ear is predicated on the remarkable development of many individuals in the faculties of sound-analysis and synthesis—faculties which, while resting lastly upon the possession of specialized nerve-centers which develop sensations and beget auditory perceptions and judgments, must needs require some mechanism upon which the sound-waves may be registered and in which these varying auditory impressions arise.

**The Mechanisms of Auditory Sensation, Perception, and Judgment.**—The specialized auditory epithelia of the cochlea, the maculae, and the cristae are the media of communication between the recording apparatus of the ear and the terminations of the auditory nerve.

There is neither satisfactory evidence nor physiological analogy in support of the theory that auditory impressions are developed elsewhere than in these nerve-terminals or conveyed to the nerve-centers by other than auditory nerve-paths. The apparent reaction to high notes or to loud low tones which has been observed in animals which have been deprived of the membranous labyrinth is doubtless a matter of general sensation rather than audition (Bernstein).

In view of the varied character and location of the auditory epithelium, and the finely specialized quality of these nerve-terminals, it cannot be doubted that they, in common with other special-sense nerve-endings, have a selective action upon auditory stimuli. They must have something to do

with determining the nature of the impression which a given stimulus excites. Conversely, their responses must be conditioned, as are those of other nerve-terminals, by the character and the mode of application of the stimulus.

Not only with the recognition of the qualities of intensity, periodicity, and pitch, but with the fixation of the limits of this recognition, they must be partially concerned. That such limits of function exist has been clearly shown. Fatigue-phenomena, incident to excessive intensity, too rapid repetitions, and extremes of vibration in sound are shared by the auditory terminals. Wundt<sup>1</sup> has successfully disputed the doctrine of the specific nerve-energy of the conducting fibers of the auditory nerve; but to carry this contention down to a denial of the specific functions of the terminals would be a physiological *reductio ad absurdum*, since it would deny all utility to the highly differentiated structural forms of these receiving cells.

The degree of irritability manifested by the auditory terminals varies physiologically with hereditary conditions, age, training, and functional fatigue. An illustration of this variation with age is seen in the marked contraction of the compass of the human hearing incident to advanced years.<sup>2</sup>

The specific functions of the nerve-centers of the bulb, of the basal ganglia, and of the cortex, which are in anatomical relations with the fibers of the cochlear and vestibular branches of the auditory nerve, are not, as yet, well understood. The fact that a portion of the vestibular division is traceable to the cerebellum re-emphasizes the probability of an equilibrar function in the vestibule. The deep centers of the bulb and of the lateral nucleus, to which the cochlear and vestibular nerves are primarily traced, are possibly of purely trophic function.

The decussation of the auditory fibers in large part, by which the trapezoid bodies are formed, is suggestive of a fusion of the binaural auditory impressions in the nerve-centers of the two sides—an event which Schäfer, however, denies.

In the posterior quadrigeminal body and the internal geniculate body we find evidence of the existence of auditory centers to which the major portion of the auditory fibers pass from the olivary body through the fillet. These are, clearly, the seats of auditory sensation. In this localization there is a striking homology to the visual sensory centers of the anterior quadrigeminal body.<sup>3</sup> The posterior nucleus of the thalamus is possibly involved also in the registration of sensations of hearing.<sup>4</sup>

Of the manner in which auditory sensations are developed in response to a varied range of auditory impressions but little can be said at present. It is unlikely that each vibration-wave which produces an impression upon the nerve-terminals is represented by a separate and distinct sensation. In all probability, certain fusions of sound-wave impressions are received by the nerve-endings, having been synthesized perhaps in the cochlea, and these are translated into composite primary sensations analogous to the primary visual impulses, and then out of these integers of sensation, as it were, other and more complex sensory groups are developed. These centers are susceptible of an increase of irritability dependent upon stimulation. By the receipt of an impression, or perhaps of a series of similar impressions, the auditory centers are awakened to the appreciation of a succeeding and dissimilar

<sup>1</sup> *Philos. Studien*, vol. viii.

<sup>2</sup> Zwaardemaker: *Archives of Otology*, July, 1894. Partly ascribable, probably, to changes in the conducting apparatus.

<sup>3</sup> Starr: *Atlas of Nerve-cells*.

<sup>4</sup> *Ibid.*



impression. With the binaural conduction of sound there appears to be an alternating centric increase of sensation upon the two sides.<sup>1</sup>

There is not only a close homology, but a functional relationship, between the auditory and the visual centers of the quadrigemina. Acoustic stimulation of the posterior body leads to a quite apparent increase of irritability in the cells of the anterior body, and to such a degree that more distinct visual sensations, especially in the color-field, are induced.<sup>2</sup>

The functions of sound-perception, of auditory judgment, and of auditory memory are localized in the cerebral cortex. In a portion of the first and second temporal convolutions lying ventral to the Sylvian fissure, and in direct communication with the auditory sensation-centers of the basal ganglia<sup>3</sup> by fiber-tracts which pass in both directions,<sup>4</sup> lie the centers which constitute the auditory brain.

These cortical functions have to do with the analysis and synthesis of sound, with the recognition of rhythm, with the determination of distance, and sound-location, and with the recollection and re-creation of sounds previously registered. The remarkable development of the faculties of sound-analysis and synthesis in certain individuals predicates a high order of specialization in this seat of the musical mind. The judgments of sound-distance and location are largely instructed by a comparison of the sensations begotten of impressions made, simultaneously or alternately, upon the two sides. In the estimate of distance the intensity of a sound is a governing and an often misleading guide. Thus a low, feeble sound produced in the near neighborhood will often convey the impression of distance, and *vice versa*. In making up the judgment of distance it is not so much the total intensity as the intensity of the component elements of a sound which gives the most correct conclusions (Bloch).

The location of a sound is almost wholly dependent upon binaural hearing. Bloch has shown that it is more readily determined in the horizontal and frontal planes than in the sagittal plane. A comparison by the nerve-centers of the several characteristics of intensity, continuance, pitch, and quality in the sounds received by the organs of hearing upon the two sides is the major factor in the case. The degree of sound-collection achieved by the two auricles is a minor influence in informing the judgment of the locality of a sound.

The function of sound-memory is but imperfectly developed in the majority of persons, while in a very few individuals it reaches a high degree of perfection. The existence of a memory-center for auditory perceptions, apart from the temporal centers of sound-perception and judgment, is undemonstrated.

Any tendency to dogmatic statement in regard to the specific functions of auditory centers is arrested by the promise of new light which is suggested by the recent investigations of Kölliker, v. Lenhossék, and Held into the origins of the auditory nerve-fibers, and by the late demonstration by Ramón y Cajal of a new auditory nucleus in front of the convexity of the upper olivary body.

<sup>1</sup> Bloch: *Archives of Otol.*, xxiv, 2.

<sup>2</sup> Epstein: *Zeitschr. f. Biol.*, xxxiii, N. F., B, XV.

<sup>4</sup> C. v. Monakow: *Archiv f. Psychiatrie*, Bd. xxvii.

<sup>3</sup> Starr: *Op. cit.*

# ETIOLOGY AND PATHOLOGY.

BY C. R. HOLMES, M. D.,

OF CINCINNATI, OHIO.

## ETIOLOGY.

**Age.**—Infancy and childhood, the latter of which we shall consider as ending at fifteen years, furnish relatively a much larger percentage of ear-affections than youth and adult life. In childhood there is greater tendency to purulent inflammation, while later the chronic catarrhal form predominates. The percentage of ear-affections in childhood, as given by different authors, varies considerably: Bezold found it to be 23 per cent., while Hesse puts it at 43 per cent. Difference in locality, climate, altitude, etc. must naturally produce diverse results in affections so readily influenced by external surroundings.

**Heredity** plays an important part in ear-affections: especially is one impressed with this when examining the reports of our deaf-mute institutes, where 25 per cent. or more are so attributed. From extensive observations, however, I am satisfied that quite a number of these cases are not congenital, but acquire deafness during the first and second years of life as a result of adenoids, which cause inflammation and hyperplasia, with extension to the middle and internal ear.

**Predisposition.**—The transmission from parent to child of a predisposition to catarrhal or purulent inflammations of the mucous membranes in general, and of those lining the cavities of the middle ear, nose, and pharynx in particular, while first recognized and most ably described by v. Tröltsch, has not as yet received the attention due its importance; for by an early recognition of this the physician may by prophylactics, such as early treatment, removal of adenoids and hypertrophied tonsils, favorable climatic influences, etc., limit or entirely prevent the development of ear-affections.

*Anatomical development* is an important factor in predisposition to ear-affections: deep niches in which are set the round and oval windows, unusual development of the promontory, extra thickness of the tegmen tympani, and general reduction in the size of the attic necessarily favor adhesions and deafness after inflammation.

**Sex.**—Up to the twelfth year the percentage of aural diseases is about equally divided between the sexes, but in youth and adult life men are more frequently affected than women, which may readily be accounted for by intemperance, excessive use of tobacco, and greater amount of exposure to wet and cold.

Bürkner found, from statistics of nearly 100,000 ear-patients of various observers, that in 24.44 per cent. the disease involved the external ear, in 68.52 per cent., the middle ear and tympanic membrane, in 7.04 per cent., the internal ear.

**Seasons.**—Winter and spring, the seasons when pneumonia is most prevalent, furnish about 66 per cent. of acute middle-ear affections. While

bacteriology has proven that "catching cold" is not so frequent a cause as formerly supposed, yet the fact still remains that it predisposes through vasomotor disturbances, paralyzing the action of the ciliated epithelium, etc., and causing secretions favorable to the development of bacteria. Violent and rapidly developing middle-ear inflammations are frequently due to imprudent exposure when overheated, to drafts, standing with thin-soled shoes on damp and cold earth or stones, etc. Chronic catarrh involving the ear is perhaps always associated with a similar condition of the naso-pharynx.

**Injuries.**—Injuries are either followed directly by ear-affections or predispose to them. Those of the external ear are least dangerous, rarely leading to permanent defect. Bruises of the auricle, as from a blow, may cause hematoma and resulting deformity; injuries supplemented by infection directly to the external meatus lead to localized or diffused inflammation, which may extend to the membrana tympani and middle ear, with extensive destruction. Rupture of the tympanic membrane may result from direct injury, such as clumsy efforts at the removal of foreign bodies from the meatus; also from violent explosions, or a blow upon the ear with the open hand, causing sudden condensation of the air in the external meatus.

Injuries involving the base of the skull generally extend to the inner and middle ear, with rupture of the tympanic membrane—although the latter may not rupture, and may prevent the escape of blood and cerebrospinal fluid. The line of fracture runs usually either transversely or parallel to the long axis of the petrous portion. In a specimen in my collection, taken from a man fifty years of age who fell from a high scaffold, there are extensive fractures at the base, involving both temporal bones, with hemorrhage into both tympanic cavities. The right temporal bone has a fracture extending from the orifice of the internal carotid between the foramen spinosum and hiatus Fallopii, passing outward through the Eustachian tube and anterior portion of the tympanic cavity. Another irregular fracture runs at right angles to the first, passing through the apex of the petrous bone and through the canal of the internal carotid, immediately internal to the internal auditory meatus, down to, but not opening, the jugular bulb; and yet *both tympanic membranes are intact and normal*. Where death does not result from the primary injury, inflammation and suppuration have frequently followed, which I believe to be largely due to subsequent infection in examining or treating the parts with non-aseptic instruments.

Occupations involving much noise, such as those of boiler-makers, copersmiths, machinists, locomotive engineers and firemen, etc., often cause deafness. Aeronauts and divers at times suffer from tinnitus, dizziness, and deafness due to hemorrhages into the labyrinth, tympanum, or meatus.

#### GENERAL DISEASES AND AFFECTIONS OF SPECIAL ORGANS, AND THEIR INFLUENCE UPON HEARING.

**Nervous System.**—Hemorrhagic pachymeningitis may cause sudden loss of hearing through extensive hemorrhage into the internal ear; or repeated small hemorrhages may take place, with resulting nerve-degeneration and progressive loss of hearing, until total deafness results, associated with various noises, hallucinations and dizziness. According to Moos, the disturbance of hearing in multiple cerebral sclerosis in all probability results from sclerotic degeneration of the nucleus and trunk of the eighth nerve.

Cerebral tumors may indirectly cause disturbance of hearing. The

interesting experiments of Gellé, Berthold, and Baratoux demonstrated that cutting of the trunk of the trigeminus led to inflammatory symptoms, hyperemia, and exudation of pus in the middle ear. Kirschner also demonstrated that *irritation* of the fifth caused increased secretion of mucus in the middle ear. Gradenigo has proven that with increased intracranial pressure we may have changes of the acusticus similar to those observed in choked disk. Ladame and Bernhardt found that disturbance of hearing as a result of tumors of the pons occurs in about 27 per cent., and, as a rule, on one side only. Tumors of the cerebellum may cause disturbance of hearing on the side affected, opposite, or both sides. Ladame found disturbance of hearing in 9 per cent. In cases where tumors of the corpora quadrigemina existed Bernhardt found the ears involved 4 times in 11 cases, or 36.36+ per cent.; in 2 total deafness, in 1 subjective noises, and in 1 case noises and partial deafness. In tumors of the base the disturbance is seldom limited to any individual nerve, because of the close proximity of the origin of all the cranial nerves; the eighth is involved in about one-third of the cases, while the optic nerve is more frequently affected than any of the others. Tumors involving the eighth nerve are sarcoma, neuroma, glioma, gummata, tubercular nodules, psammoma, and fibroma (see p. 769).

*General Symptoms.*—It is difficult to make a diagnosis of brain-tumors from aural symptoms alone, especially if we find disease existing in the middle or internal ear; but subjective noises, dizziness, unsteady gait, partial or total deafness affecting one or both sides or crossed, are important aids.

Tischkow has demonstrated that in progressive paralysis there is a formation of new blood-vessels in the cartilage of the ear, growing into it from the perichondrium: it is from these easily ruptured vessels that the hemorrhages take place in hematoma.

Epilepsy and hysteria have each some influence upon the ear, but as yet the results and conclusions are too much at variance to follow up the finely-spun theories in the brief space of this article.

**Respiratory Organs, and their Relation to Ear-affections.**—The respiratory organs are by far the most important causative factors in inflammations of the ear. Bürkner found 22.6 per cent. of acute middle-ear catarrh and 26 per cent. of the chronic variety ascribed to cold in the head. Nasal and pharyngeal catarrh is responsible, according to various authors, for from 33 per cent. to 60 per cent. of ear-affections. My belief, based upon a careful investigation of this point, is that the higher percentages are more nearly correct. We are daily more forcibly impressed with the great importance of the above-named disease as a cause of ear-affections. Pertussis, hay-fever, measles, etc. have their influence on account of the extension of catarrhal inflammation to the middle ear. Hemorrhages into the ear can occur as a result of whooping-cough.

**Vascular System.**—Atheromatous changes not infrequently cause subjective noises in the ears, which are constant and increased by circulatory disturbances. Where there is no other middle-ear affection, hearing is, as a rule, normal in this class of cases.

Many aural inflammations are ascribed to dentition with as much probability as the concurrent intestinal involvement; and others are doubtless influenced by dental irritation.

Nephritis, whether interstitial or parenchymatous, frequently leads to disturbances of hearing. Doumergue found it in 35 per cent. The symptoms vary from subjective noises to partial and total deafness, either one or both sides becoming affected, the causes being hemorrhages, inflammatory



changes of the mucous membrane, or pressure from edema, while the purely nervous manifestations can be caused by the uremic poisons. The subjective symptoms and the hearing often improve temporarily after the elimination of poisonous products and the reduction of arterial tension and edema by medication.

**Sexual Organs.**—Disturbance of menstruation, especially its cessation, influences the ears. Levy reports a typical case of complete deafness on both sides after cessation of the menses, without any other symptoms. Upon return of menstruation, three months later, hearing was completely restored.

Hemorrhage from the ear (vicarious menstruation) can also occur with or without perforation of the membrana tympani and without existing inflammatory symptoms. In the unperforated cases the hemorrhage comes from the surface of the membrana tympani and external meatus (probably out of ceruminous glands) (Gradenigo).

**General Conditions.**—Rachitic children are frequently affected with ear-disease, which is probably due to malnutrition and catarrhal predisposition. Eitelberg examined both ears of 250 children belonging to this class, and of the 500 tympanic membranes only 39 were normal.<sup>1</sup>

Gouty deposits are, according to Garrod, more frequently found in the ear than in any other organ. These deposits vary in size from a pinhead to half a pea, of pear-like appearance, generally located in the folds of the auricle, hard or soft, and contain a milky or creamy fluid. Victims of this disease generally suffer lancinating pains in the ear before and during a gouty attack. Gout predisposes to the formation of exostoses of the external meatus, and these are found more frequently among the English than any other nationality.

Eczema, hemorrhage, purulent inflammation, and rapid necrosis of the temporal bones are encountered as a result of diabetes; the rapid destruction is accounted for by the lowered resisting power of the tissues, combined with extensive arterial sclerosis. This explains why in these cases violent mastoiditis can rapidly develop from a simple naso-pharyngeal catarrh. The arterial changes favor excessive hemorrhages—a fact to be remembered when operating. The diplococcus of pneumonia is often found in the acute purulent secretion of these cases, and is generally associated with the streptococcus pyogenes and staphylococcus pyogenes albus. Habermann demonstrated the staphylococcus pyogenes aureus in the walls of the blood-vessels; the resulting toxin may lead to necrosis of the vessel-wall and hemorrhage.

Caries of the teeth not infrequently causes otalgia, either constant or intermittent. The pain may radiate to the ear, shoulder, and from there to the fingers of the affected side (Urbantschitsch).

**Acute and Chronic Infectious Diseases.**—Bacteriological studies of the effect of acute and chronic infectious diseases upon the ear have during recent years been pursued with much energy by many able investigators. The principal bacteria which so far have been studied as causative factors of inflammation of the ear are—

- a. The diplococcus of pneumonia;
- b. Staphylococcus pyogenes albus and aureus;
- c. Streptococcus pyogenes;
- d. Bacillus pyocyaneus.

Each may be found alone or two or more varieties (mixed forms) may be

<sup>1</sup> Four hundred boys, generally healthy and athletic, in a Philadelphia school, showed hardly two dozen normal drumheads.—Ed.

found at the same time, making it impossible to state which is the primary causative agent.

**Pathogenic Germs.**—The various streptococci are divided into two main groups—*streptococcus brevis* and *longus*: the first is non-pathogenic (saprophyte); the second is virulent, and may be found in the different inflammatory processes. Furuncles of the external meatus can be caused by any of the staphylococci, although the *staphylococcus aureus* is the most frequent cause, gaining an entrance by the hair-shafts. The middle ear may, according to the cause and character of the inflammation, harbor any of the above-named varieties. In inflammation of the internal ear we find principally the streptococcus.

**Avenues of Infection.**—There are several paths by which the micro-organisms may enter the ear:

1. Through the Eustachian tube;
2. Through the external meatus and perforated *membrana tympani*;
3. Through the dural process in the petro-squamous fissure;
4. Through the lymph- and blood-vessels.

While the Eustachian tube is the most frequent avenue for the bacteria to enter, nature has provided an important barrier against invasion from the nose and pharynx in the ciliated epithelium, *whose motion is from the tympanic cavity toward the pharynx*; it is when this epithelium is rendered defective by pathological changes that the exciting cause may enter. The main defence against bacterial invasion is a perfectly healthy organism. Infection of the internal ear occurs most frequently through the lymphatics, especially those of the periosteum.

The character of the inflammation, whether catarrhal or purulent, active or passive, depends largely upon the virulence and number of the invading bacteria and the resisting power of the invaded mucous membrane. If the bacteria enter in small numbers and slowly, they may cause only an irritation with lymph-exudation, division of the lymph-nuclei, but not of the protoplasm (Moos), formation of giant-cells, blood-vessels, connective and even osseous tissue. If, however, they enter suddenly in large numbers, then the resulting disturbance of nutrition causes a rapid breaking down of the parts; reaction may begin and new tissue develop, resulting in hyperplasia and partial or total obliteration of the original anatomical relations.

Whether the disease shall promptly run its course or change into the chronic form depends upon the continued activity of the germs present or upon the gradual dying out of the first culture, and implantation of new varieties upon the now affected membrane. The general health is often impaired by previous disease and permits only slow restoration. We also find, especially in measles and diphtheria, that there are extensive changes in the endothelium of the blood-vessels—fatty degeneration and thrombosis, with necrosis of the vessel-walls, resulting hemorrhages, and extensive or total loss of hearing. Minute capillary hemorrhages may also result, causing the death of a limited area only of the nerve-tissues, with temporary or permanent *partial* deafness.

**Diphtheria and Scarlet Fever.**—Bürkner found acute otitis media purulenta resulting in 1.5 per cent. of all cases of primary diphtheria of the pharynx, and nerve-deafness in 7 per cent. The ear is, however, more frequently involved in diphtheria than would appear from statistics, because in fatal cases of diphtheria (average duration six days) death results before the ear-affection has become fully developed. The authorities nearly all agree that purulent otitis media results in about 5 per cent. of all scarlet-fever

cases. Bezold found in 185 cases of purulent otitis media from scarlet fever 30 times total destruction of the tympanic membrane, with loss of one or more ossicles, and 59 times destruction of at least two-thirds of the membrane.

The author found, in an examination of 500 children at the Institute for Deaf-mutes in Jacksonville, Ill., that their deafness was ascribed to scarlet fever in 7.2 per cent. and to diphtheria in 0.8 per cent.

The rapidity with which destruction may result to the ear from diphtheria is almost incomprehensible. Where death has occurred sixty to seventy-two hours after the beginning of the disease the microscopic examination of the middle and internal ear has revealed numerous micrococci, not alone in the blood-vessels, but also in the deeper layers of the mucous membrane and in the lacunæ of the *adjoining bone*, often leading to extensive or circumscribed necrosis.

In measles we find that while the ears are frequently involved, there is much less tendency to extensive destruction than in diphtheria or scarlet fever, the disease rarely going beyond an acute catarrh. Solomonson found deaf-mutism caused by measles in 5.6 per cent., Hartmann, 3.6 per cent. Tobeitz found otitis media in 21.9 per cent. in *convalescent* children. Of 22 children dying from measles, the ears of 17 were examined post-mortem, and in every one the mucous membrane of the middle ear was found to be diseased, although in only 7 of them had there been any clinical manifestation of ear-complication.

Typhoid fever is at times accompanied by aural inflammation varying from a slight catarrhal to a violent purulent form. This is, however, often overshadowed by the severity of other symptoms, and not noticed until convalescence has begun. The severe deafness at times present may be due to weakness of the nerve-centers, and in a few cases to changes in the labyrinth: mastoiditis may also occur; while with parotid suppuration discharge of pus into the external meatus is not an infrequent occurrence.

**Cerebral Origin.**—Disturbance of hearing of cerebral origin is frequent, and includes a wide range of manifestations, which may be caused by morbid processes of the brain or its membranes, but most frequently by involvement of the internal ear. By far the largest number are found as sequelæ to cerebro-spinal meningitis: according to Knapp and Moos, the deafness develops in most cases in the first or second week.

The percentage of cases where the ears are involved in cerebro-spinal meningitis varies greatly in different epidemics. Competent observers have reported on epidemics where disturbance of hearing seldom occurred, while in others nearly all who recovered were deaf. In Ziemssen's *Handbuch* Dr. Roth reported that from the district of Oberfrank, with 55,000 inhabitants, there were during a period of two years 58 cases sent to the Bamberg Deaf and Dumb Institute as a result of cerebro-spinal meningitis, and Moos reports that in his own practice 59.3 per cent. became deaf-mutes.

In the Jacksonville Institute for Deaf-mutes I found cerebro-spinal meningitis given as the cause of deafness in 14 per cent. of the cases.

Larsen reports the following carefully examined case: "A girl aged seven years became hard of hearing on the tenth day of an attack of cerebro-spinal meningitis, totally deaf on the sixteenth day, and died on the thirty-first day. Section showed the tympanic membrane normal; fine and intense injection in the *entire middle ear*, with muco-purulent contents. In the internal auditory canal the nerves were imbedded in pus. The membranous labyrinth could not be recognized; the semicircular canals were filled with

a soft reddish tissue (connective tissue with fatty degenerated round cells and blood-corpuseles); the same condition was found in the vestibule and in the cochlea; and in the vestibule of the left ear also a small quantity of pus; extensive purulent meningitis of the convexity and base; the medulla was also surrounded by purulent exudations. The microscopical examination of the acoustic, the facial, cochlear, and vestibular nerves revealed no pathological changes. The otitis was evidently caused by direct infection from the meningitis."

**Micrococci.**—The diplococcus of pneumonia is frequently found in middle-ear secretions, often in pure cultures, even in cases where there is no evidence of involvement of the lungs.

Since the appearance of influenza otologists have had abundant opportunity to study its influence upon the sound-conducting apparatus, and the resulting inflammations of the ears have been classified into four varieties (Moos):

1. Swelling and hyperemia of the lining of the middle ear, with little or no interference with hearing.

2. Pain, fever, diffuse redness of the tympanic membrane, and exudation into the middle ear, at first sero-mucoid, later muco-purulent.

3. "The hemorrhagic" (myringitis hæmorrhagica bullosa), the most typical of the four varieties; bullæ varying from bright red to a dull venous color are usually situated on the tympanic membrane, but at times found in the osseous portion of the canal; there are much pain, fever, and deafness.

4. The form characterized by violent purulent inflammation of all parts of the middle ear, generally involving the mastoid, with fever, pain, and great prostration.

The author has had occasion to study all of these forms, and, while the first two varieties have nothing very distinctive by which to differentiate them from similar affections due to other causes, those of the third and fourth classes are characteristic when taken in connection with the general symptoms. The hemorrhages which are so frequent in this affection, not alone in the ear, but in other parts of the body, are perhaps to be attributed to necrosis of the vessel-walls by the toxin of the influenza bacillus, which seems to have been positively identified by Pfeiffer, Kitasato, Canon, and others. This bacterium is not easy of isolation, and appears always to be found in connection with one or more pathogenic germs, or, as Ribbert states it, "the exciting germ of influenza is everywhere the quartermaster for the various pathogenic organisms."

Mumps is probably due to a bacterium which A. Ollivier claims to have isolated. In recent years quite a number of cases have been reported with severe involvement of the ears. Complete deafness of *both ears* has been reported, even where the parotitis was limited to *one side*.

**Tuberculosis.**—Suppuration of the middle ear is a frequent affection in the later stages of lung-tuberculosis. The ear-affection usually develops *painlessly*: the first symptom noticed is more or less marked deafness, followed by a slight discharge of a watery consistency; the disease in the severe form may, however, be accompanied by the usual symptoms of acute otitis. In case the chronic form becomes painful, we have to deal with a mixed infection of tubercle bacilli and streptococcus, with resulting increase of offensive purulent secretion, often leading to total destruction of the ossicles and necrosis of the mucous membrane, the bony walls becoming denuded, especially the promontory. There is nearly always extensive breaking down of osseous tissue, which may cause facial paralysis and even cro-



sion of the carotid. (Seven deaths have been reported from carotid hemorrhage.)

Microscopically, we may find it a very difficult task to demonstrate the tubercular nature of the affection by examination of the secretions from the ear alone, the tubercle bacilli often being absent, while the sputum contains them in great abundance. In many cases this is due to the development of the streptococci upon the soil first occupied by the tubercle bacilli, the new arrivals flourishing, while the others become few or are not at all present in the discharge. But we must also remember that a non-tubercular suppuration of the middle ear may occur in a patient suffering from phthisis pulmonalis.

**Syphilis.**—Strange as it may seem, considering the prevalence of *acquired* syphilis, there are no reliable data as to the frequency of this factor being a causative agent in ear-affections. That it is one of importance is well understood; but so long as the statistics of authorities vary from 20 per cent. to less than 1 per cent., we must consider them of little value. The following changes have been observed: Condylomata of the external meatus; while inflammation of the middle ear often results from syphilitic infection of the nose and pharynx. In the internal ear we may find hyperemia, small-cell infiltration, connective-tissue formation, chalk deposits, ossifying periostitis, stapes ankylosis, and primary suppurative inflammation of the labyrinth. In inherited syphilis the disease chiefly attacks the labyrinth, developing most frequently between the ages of eight and twenty years. Hutchinson teeth and other stigmata are generally present.

**Toxicants.**—The abuse of certain drugs has a marked influence upon the ears, quinin, salicylic acid, and tobacco being the most important. Every one is familiar with the effect of large doses of quinin. The tinnitus and deafness have in some cases proven permanent. The subjective noises are caused by labyrinthine hyperemia in the first instance, but may later be due to ischemia. The action of salicylic acid is similar, but less marked than quinin. The direct action of tobacco upon the nerve of hearing has, so far, not been clearly established, but is perhaps similar to the action upon the optic nerve. Its deleterious effect upon the mucous membrane, causing dryness, brings about or greatly aggravates existing catarrhal troubles, involving the Eustachian tube and middle ear, causing tinnitus and the usual labyrinthine complications in advanced cases.

## PATHOLOGY.

**Auricle.**—Transitory hyperemia of the auricle occurs not infrequently in patients suffering from chronic tympanic catarrh or from a healed purulent middle-ear inflammation associated with naso-pharyngeal catarrh, and is referable to the sympathetic nerve.

*Intertrigo* is an excoriation of the skin behind the ears, accompanied by secretion of serum and formation of crusts. It is often caused by keeping the ears pressed firmly against the head by infant caps, and is favored by a lack of cleanliness and a tender skin in a strumous subject.

**Eczema.**—The various classifications of eczema mark, after all, only different stages of the same disease, and here we need only recognize the affection as acute and chronic. Every exciting cause giving rise to hyperemia is capable of producing eczema by favoring development of bacteria. Gout, rheumatism, etc. predispose to this disease, in adults generally limited to the external meatus.

*Herpes auricularis* is a rare affection, distinguished by the formation of vesicles, generally located upon the anterior surface, and caused by irritation of the trophic nerves supplying the affected area.

*Plegmonous inflammation* may result from infected wounds or infectious diseases, as typhoid (suppuration of the parotid), erysipelas, measles, scarlet fever, and diphtheria, and may develop primarily or by extension from the throat and middle ear.

*Diphtheria* may involve the aural region through the infection of open surfaces. In two patients, males, eighteen and thirty years of age, upon whom the author had performed the radical mastoid operation, there was diphtheritic infection of the wounds; in the younger, preceded by tonsillar and pharyngeal involvement; in the other the wound only was affected; both cases, however, experienced but slight constitutional disturbances. Cultures and microscopic examinations gave the typical Klebs-Löffler bacilli.

*Perichondritis* of the auricle is not often encountered. The cause is frequently obscure, sometimes resulting from injury or metastatic infection, as from furuncles or otitis externa diffusa. A swelling similar to othematoma develops, and a synovial-like fluid, which later becomes purulent, separates the perichondrium from the cartilage. Deformity usually results through chondromalacia. *Othematoma*, or blood-tumor of the auricle, is formed by an exudation of blood between the perichondrium and cartilage, but may occur between the perichondrium and skin. The affection is either traumatic or idiopathic, the former resulting from direct injury, causing rupture of the blood-vessels. The idiopathic variety is generally encountered in the insane, in whom the intracranial lesion, with degeneration and softening of the vessel-walls and formation of calcareous deposits, favors spontaneous rupture under increased blood-pressure during maniacal excitement or from slight self-inflicted bruises when violent. The theory of intracranial disease as a cause of the idiopathic variety has found strong support in the experiments of Brown-Séquard, who caused hemorrhage in the ears of animals in from twelve to twenty-four hours after section of the restiform bodies. The lobule is rarely affected, but may suffer. It is more frequently the seat of *abscess* from infection after piercing for ear-rings.

*Keloids (fibromata)* occur now and then as a result of wearing heavy ear-rings of impure metal; the growths may vary in size from a pea to a chicken's egg (Knapp), and are more common in the negro.

*Atheromatous cysts* are also found upon the auricle, generally upon the posterior surface (see Fig. 461). The serous variety also develops, although less frequently.

There are a number of affections which so rarely involve the external ear that it would be out of place to describe them at length in this article, and I shall merely name them—to wit: syphilis, lupus, hypertrophy of a part or all of the auricle, necrosis, chalk deposits, ossification, and injuries.

**The External Meatus.**—Hyperemia is often found in connection with inflammation of the auricle or middle ear, and may be quickly evoked by the speculum; and hemorrhage of the external meatus may result from injuries, careless removal of inspissated cerumen, or foreign bodies.

*Furuncles* are circumscribed glandular inflammations; hence they are most frequently situated in the cartilaginous portion of the meatus, but may also be found in the osseous canal. The central mass breaks down, forming a necrotic slough surrounded by pus; left to itself, it usually evacuates spontaneously. It is now generally accepted that the cause is in most, if not all, cases due to a bacterial infection, the staphylococcus aureus being found much

more frequently than any of the other bacteria. The point of entrance is along the hair-shafts and by the mouths of the sebaceous or sweat glands.

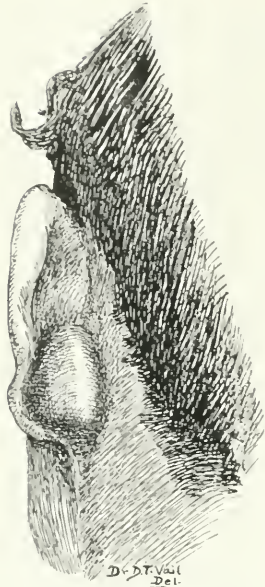


FIG. 461.—Sebaceous cyst of thirteen years' duration in a man of twenty-eight, from whose right ear a similar growth had been removed.

Abrasion of the skin by finger-nails, ear-curettes, hair-pins, etc. is a frequent cause of infection. Transmission by failure to disinfect the syringe-nozzle was observed in the Cincinnati Hospital in 1892. A typical case of furuncular inflammation of the external meatus was admitted, and within a short time eight cases developed among ear-patients in different parts of the house, who up to this time had not suffered from the affection. In searching for a cause I found that the same syringe had been used for all of these cases without disinfecting the nozzle; after correcting this no more cases of furuncles developed in the service.

Reflex tropho-neurosis is also cited as a cause. The inflammation may in severe cases extend deeply, giving rise to perichondritis of the canal and auricle; even in the less severe cases we at times find extension to the tympanic membrane and middle ear. The author recently observed a case where two furuncles of the cartilaginous portion, accompanied by only slight swelling and pain, caused marked deafness, tinnitus, and the loss of a calcareous plaque in the anterior half of the tympanic membrane, with resulting perforation. When located on the posterior wall and near the orifice of the external canal, they may lead to great edematous swelling behind the auricle,

even causing the latter to stand out at right angles—closely resembling, and being mistaken for, acute mastoiditis.

*Otitis externa diffusa* is a general inflammation of the external ear which may result from the causes given under "Furuncles." The whole lining of the canal becomes a deep red, swollen, and covered with more or less seropurulent secretion. In severe cases there is swelling and inflammation of the auricle, even extending over the mastoid and parotid, with enlargement of the

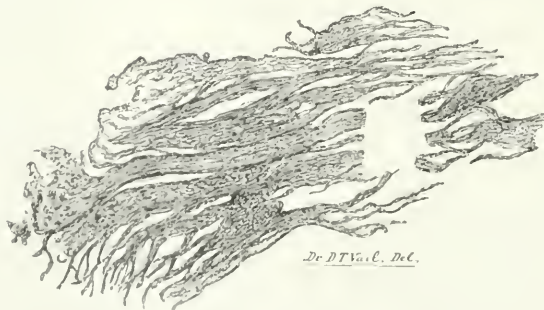


FIG. 462.—Section of cholesteatoma mass from canal.

glands about the ear. The middle ear is seldom involved, yet perforation of the tympanic membrane and purulent otitis media and mastoid complications may result; but the inflammation in the external meatus is not infrequently secondary to involvement of the tympanic cavity, attic, and mastoid cells.



From the latter there may be a direct opening through the posterior wall of the canal, with protrusion of granulations and discharge of pus.

*Cholesteatoma* (or pearl tumor) of the external canal is rare. The growth results from prolonged inflammation of the epithelium, causing excessive proliferation of the rete mucosum and exfoliation of the epidermal layer, forming laminated mother-of-pearl colored masses, in which are found numerous cholesterol crystals. Fig. 462 clearly shows the laminated structure of the growth. The ear from which this specimen was taken showed extensive changes secondary to an arrested otitis media purulenta. The external meatus was almost filled with the epithelial mass, imbedded in which were three firm globular pearl tumors from 3 to 6 mm. in diameter. Removal of these left three corresponding depressions in the floor of the meatus, equal in depth to about one-half the diameter of the round masses, and lined with a pearly membrane.

*Neoplasms*.—*Exostoses*, and *hyperostoses*, or bony growths of the external canal, are most frequently situated on the posterior wall, at the junction of the cartilaginous and bony canals (Figs. 463, 494). In structure they are generally of ivory hardness, but may be cancellous. They are ascribed to the irritation of discharge in some cases, and in the British upper classes, among whom they are not uncommon, to gout or inordinate bathing.

Lupus, syphilis, cysts, angioma, osteosarcoma, and epithelioma have been reported.

*Otomycosis*.—A number of vegetable parasites develop in the external meatus, especially the *aspergillus niger*, *flavus*, and *fumigatus*. Macroscopically, they appear in the deeper part of the meatus and on the tympanic membrane as brownish-black, grayish-white, or yellowish punctated masses. The germs cannot develop in the normal ear, but maceration of the epithelium from any inflammatory cause favors their growth. Examination of a fragment placed under the microscope reveals irregularly interlaced threads or hyphæ (mycelium (*a*), Fig. 464), covered more or less densely by globular masses of fallen spores (*b*); here and there a flower-like mass is found, supported upon hyphæ—*i. e.* the sporangium or fruit-capsule (*c*), consisting of the central receptaculum (*d*), upon which are the long radiating cells (sterigmata), (*e*); bearing the round conidia or spores.

*Ceruminous masses* consist of secretion from the ceruminous and fat-glands, exfoliated epithelium, hairs, and dust: their formation primarily depends upon hypersecretion, due to an excitation of the glands secondary to middle-ear congestion or inflammation. It is also claimed that subnormal secretion, comparable to the dry pharyngitis often present, is responsible for the unnatural




FIG. 463.—Hyperostosis of canal and trephining of mastoid (Randall).

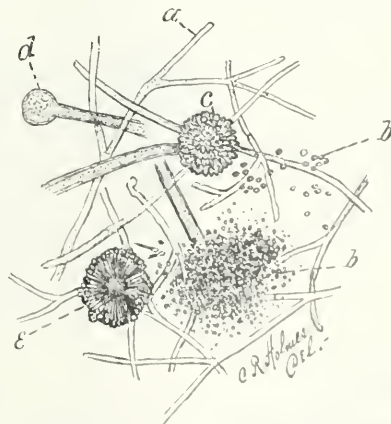


FIG. 464.—*Aspergillus nigricans*: *a*, mycelium fiber; *b*, spores; *c*, sporangium; *d*, receptaculum; *e*, sterigmata.



consistence and faulty exit. When large they may lead to pathological changes by pressure, erosion of the external meatus, atrophy, ulceration, and even perforation of the tympanic membrane.

**The Tympanic Membrane.**—Vascular engorgement, especially along the hammer-handle and Shrapnell's membrane, results readily from undue pressure of a speculum while making an examination or after syringing and forcible inflation.

Primary inflammation is rare. In mild cases the dermal or mucous layers only are affected, according as the inflammation originates from the meatus or tympanic cavity; while in the severer forms the fibrous layer is also affected with round-cell infiltration and softening, favoring perforation. Chronic inflammations lead to hypertrophic changes in the cuticular and mucous layers, with increased growth of the rete Malpighii and exfoliation of the epithelial layers. Granulations may also form. Practically, the same changes occur in the mucous layers, but here the granulations become larger, even polypoid. The changes in the membrana propria or middle layer are of an atrophic character: the infiltration and softening, aided by pressure of the pent-up exudation, soon lead to perforation, the size of which depends much upon the virulence of the bacterial infection. The seat of perforation is most frequently in the anterior lower quadrant. When the attic and mastoid cells are involved the opening is often in the upper and posterior portion. The healing of perforations is participated in only by the epidermic and mucous layers, hence the secondary membranes are always flaccid, unless, as frequently occurs, infiltration and formation of calcareous plates have resulted. When the openings are very large or repeated ruptures have taken place, the perforations become permanent, especially if the patient is past thirty.

Atrophic changes of a part or all of the drumhead are found in chronic middle-ear catarrh. The membrane is thin and drawn in sometimes in scar-like areas, strongly suggesting past perforation.

Chalky deposits are generally located in the middle portion of the anterior or posterior half of the tympanic membrane; they are most often half-moon- or horseshoe-shaped, and rarely reach to the hammer-handle or tympanic ring. The deposits may be found only in the membrana propria, but in

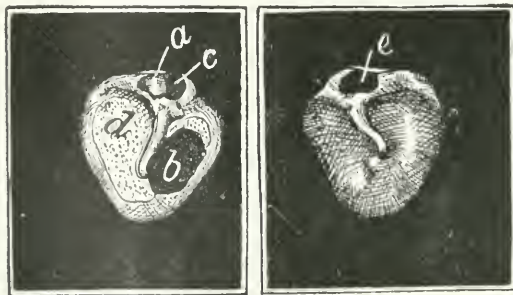


FIG. 465.—Drumheads showing perforation in the flaccid membrane (*c* and *c'*); on the right, uncovering the malleus-head, and with chalk crescents (*ab*) posteriorly and in the edge of the lower perforation (*b*) (Holmes).

severe cases all layers are involved. The pathological changes found in the tympanic membrane are of themselves of little value as an index of hearing (Fig. 465), as witness the right and left drumheads of a man twenty-four years of age who suffered for many years from chronic purulent otitis media.

Hearing distance, watch, right ear, whispered voice, at 20 feet,  $\frac{28}{40}$ ;  
 Hearing distance, watch, left ear,  $\frac{3}{40}$ ; only low voice spoken into the  
 external canal.

**Tympanic Cavity.**—From a pathological point of view we find the most important factor in middle-ear inflammation to be its *mucous membrane*. It is in this that the inflammation must begin, and because of its *peculiarly intimate relation with its underlying periosteum* do we so frequently find that the pathological changes extend to the bone, resulting in hyperostosis or necrosis. There is great tendency to thickening of the mucous membrane, favored by the many irregularities—slit-like passages and depressions due to the chain of ossicles, ligaments, and numerous bony projections within this small space. Various classifications have been attempted; the most practical is a clinical basis, where we divide the inflammations into—

- a. Sero-mucous middle-ear catarrh.
- b. Proliferous inflammation of the middle ear.
- c. Muco-purulent inflammation of the middle ear.
- d. Acute purulent inflammation of the middle ear.
- e. Chronic purulent inflammation of the middle ear.

(a) **Sero-mucous Middle-ear Catarrh.**—*Synonyms.*—Acute middle-ear catarrh; Secreting form of middle-ear catarrh; Otitis media serosa; Catarrh of the cavum tympani and Eustachian tube.

This form most frequently results as an extension from the nose and pharynx through the Eustachian tube. There is congestion of the mucous membrane and exudation of serum, which may be mixed with mucus, the latter resulting from the beaker-cells of the epithelium, as mucous glands are rare or entirely absent in the middle ear. A few pyogenic organisms may also be found, having entered through the tube, and may in most cases be regarded as the exciting cause. The exudation may fill a part or all of the cavity. The picture frequently presented is shown in Fig. 466. The drumhead seldom ruptures in this affection.



FIG. 466.—Serous fluid within the tympanum showing through the unchanged drumhead.

Resorption, aided by paracentesis or spontaneously, with complete restoration of the parts, is the usual result if properly treated and the exciting cause corrected. The affection, having once developed, is liable to recurrence and may pass into the chronic form.

(b) **Proliferous Inflammation of the Middle Ear.**—*Synonyms.*—Otitis media catarrhalis chronica; Otitis media sclerotica; Otitis media catarrhalis sicca.

This form, as stated above, may also develop from the acute variety, but very often it begins without any active inflammatory symptoms. There is a general or circumscribed involvement of the mucous membrane, the former most often after the exudative variety; localized forms frequently involve the oval and round windows or their immediate surroundings. The mucous membrane becomes swollen by round-cell infiltration and proliferation of all its structures, which is later followed by connective-tissue formation, sclerosis, atrophy, or calcareous changes. The ossicles may be completely imbedded and the niches filled with the swollen membrane; even the space between the stapes-crura and the niche-wall may be obliterated. The opposing surfaces of the membrane press upon each other, the inflamed epithelium becomes eroded by pressure, and adhesions form which may completely fill the round-window niche. Adhesive fibrous bands may form between any or all of the

Ossicles and their surrounding walls. Even calcareous changes take place in the mucous membrane, generally limited to the promontory.

*Ankylosis* of the foot-plate of the stapes with the oval window is unfortunately a condition frequently encountered in this form of middle-ear inflammation, caused by calcification and ossification of the ligamentous ring of the foot-plate or by the formation of bony masses involving the foot-plate, niche, oval window, or in the vestibule (Politzer).

In most cases progressing toward stirrup-ankylosis there is intense hyperemia of the wall of the promontory (Schwartz); and Hartmann found in this class of cases purulent naso-pharyngeal catarrh, with intense hyperemia and swelling of the mucous membranes of these parts.

(c) **Muco-purulent Inflammation of the Middle Ear.**—*Synonyms.*—Acute catarrhal inflammation of the middle ear; Otitis media acuta.

The differentiation between this form and otitis media serosa is best shown in the following table:

| <i>Otitis Media Serosa.</i>                                                                      | <i>Otitis Media Acuta.</i>                                                                                                                                               |
|--------------------------------------------------------------------------------------------------|--------------------------------------------------------------------------------------------------------------------------------------------------------------------------|
| Tympanic membrana remains transparent, and with only very slight or no injection.                | Intense injection; inflammatory exudation, with partial or complete opacity of the tympanic membrane.                                                                    |
| Mucous membrane of middle ear only moderately inflamed, with very slight, if any, proliferation. | Intense congestion and swelling of the mucous membrane, due to interstitial exudation and proliferation; epithelium opaque and swollen.                                  |
| The exudate is a clear serous fluid or transparent mucus.                                        | Opaque mucus, mixed with great quantities of pus-cells, or purulent fluid tinged with blood from the torn capillaries, due to the sudden swelling and great engorgement. |
| Absence of, or only slight, inflammatory symptoms.                                               | Much reaction, with resulting symptoms.                                                                                                                                  |
| Absorption, as a rule, slow.                                                                     | Absorption rapid when patulency of tube is restored.                                                                                                                     |

(d) **Acute Purulent Inflammation of the Middle Ear.**—*Synonyms.*—Acute suppurative of the middle ear; Otitis media acuta suppurativa seu perforativa.

The pathological changes are very similar to otitis media acuta, described above, but much more intense, the purulent exudation much more copious, with breaking down of the mucous membrane in circumscribed areas and early perforation of the tympanic membrane. The inflammatory changes are not limited to the lower tympanum, but the attic, antrum, and even the mastoid cells, are affected. The internal ear is generally not involved; but the free anastomosis between the vessels of the middle and inner ear may lead to great hyperemia in the labyrinth and serous effusion, seldom to purulent inflammation (Politzer). On account of the intimate relation between the mucous membrane and the periosteum we frequently see *subperiosteal abscesses and bone- necrosis*. This condition may run its course and end in resolution, with scarcely any visible changes of the tympanic membrane and middle ear, and with or without marked changes of hearing power; or the disease may continue and pass into the chronic stage.

(e) **Chronic Purulent Inflammation of the Middle Ear.**—*Synonyms.*—Otitis media suppurativa seu perforativa chronica; chronic otorrhea.

For convenience of study we may divide the pathological changes occurring in this disease into five headings:

1. We encounter formation of connective-tissue bands, membranes, and



masses filling the round window, partially imbedding the ossicles, and in rare cases even filling all of the tympanic cavity.

2. Cystoid spaces are nearly always found in the enormously hypertrophied mucous membranes (see *a*, Fig. 467). The formation of numerous bands and membranes within the middle ear results in the formation of spaces between

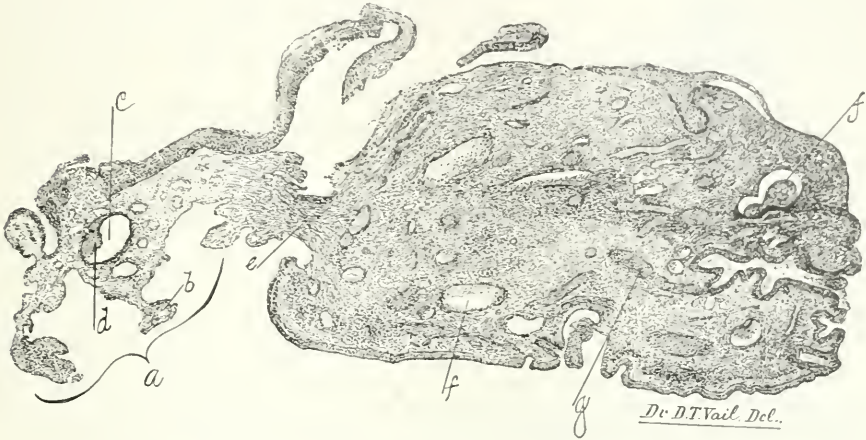


FIG. 467.—Section of aural polypus from the promontory, showing cystic spaces (*f*).

them, either entirely closed off or as irregular canals which become lined with cubical or cylindrical epithelium (*b c*). These spaces are often filled with mucus and degenerated epithelial masses (*d f*).

3. *Aural Polypii*.—These tumors originate from the mucous membrane or periosteum of the middle ear, or in rare instances from the dermoid layer of the tympanic membrane. Practically, we need only recognize two varieties: (*a*) The round-celled polypus (*synonymus*, Mucous polypus, Cellular polypus, Granulation tumor); and (*b*) Fibroma.

The former variety is by far the more frequent, and consists of a hyaline, homogeneous, myxomatous stroma, sustained by a delicate fibrous structure enclosing numerous round-cells. They are very vascular, the vessel-walls being of the embryonal type. The epithelial covering may occur in single or multiple layers of columnar or squamous cells, and varies according to the location from which the growth has its origin (see Fig. 467).

The *fibroma*, as its name indicates, contains a denser fibrous framework and is less rich in blood-vessels. Its surface is covered with several layers of pavement epithelium, which penetrate into the stroma with finger-like projections.

4. *Cholesteatoma*.—There is still no unanimity among authors as to the origin of cholesteatoma, but the best theory is that advanced by Haberman, Politzer, and Bezold, that it is due to an extension of the epithelium from the external canal or outer surface of the tympanic membrane through an opening in the latter into the tympanic cavity, attic, and mastoid cells.

In cholesteatoma of the middle ear we find the rete Malpighii in most intimate anatomical relation with the periosteal layer (see Fig. 468), the blood-vessels in the former being in direct connection with those of the latter. Continued irritation from existing otitis causes rapid proliferation of epidermic cells, resulting in the "throwing off" of pearl-colored layers from



the stratum corneum, which explains the laminated structure of the cholesteatomatous mass.

Complete epidermization of the middle ear (including the mastoid cells) can, according to Schwartz and Politzer, occur without leading to the formation of cholesteatoma if the inflammatory process is arrested early. This is also proven in those cases where the radical mastoid operation has been

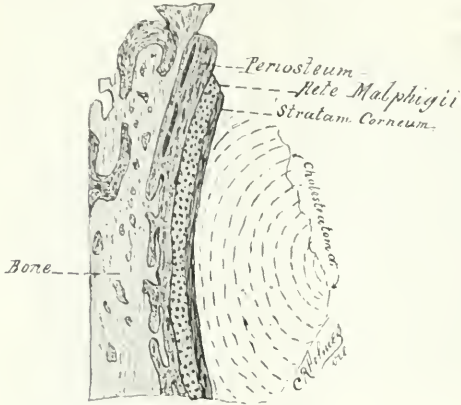


FIG. 468.—Section through osseous wall of antrum, showing periosteum, rete Malpighii, and stratum corneum (and cholesteatoma, diagramatic) (after Kuhn—Z. f. O. xxi.).

performed on patients suffering from extensive cholesteatoma-formation in the middle ear. Here we aim to “paper” the whole of the bony cavity with an epithelial lining, taking its origin from the transplanted flaps formed from the external meatus: notwithstanding these conditions we are now enabled to cure most of this class of cases. I have operated upon several cases from three to five years ago, which can now be classified as cured, since there is no sign of any return up to date.

The epithelial invasion may also take place through a fistulous opening of the mastoid cortex or posterior bony meatus (Politzer).

The size of the cholesteatomata may vary from a pinhead to a pigeon's egg. When large they cause absorption of the bony walls in any direction. In two of my cases the cortical plate of the mastoid had been entirely absorbed, so that when making the incision the knife cut directly through the skin and into the cholesteatomatous mass.

5. *Bone-involvement.*—Because of the intimate relation of the mucous membrane of the middle ear and its periosteum we frequently encounter superficial or deep bone-involvement in purulent inflammations. The hammer and anvil (rarely the stirrup) are often eroded or even totally destroyed (Fig. 469).

**Suppurative Middle-ear Inflammation with Tuberculosis.**—Middle ear suppuration is frequently associated with lung-tuberculosis, and is characterized by the formation of one large or several small perforations

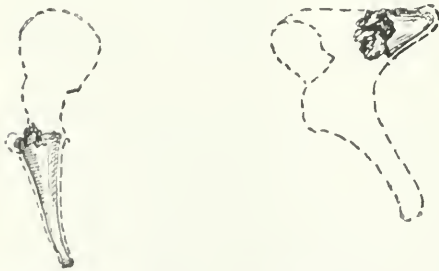

FIG. 469.—Remains of ossicles from a boy of twelve. Dotted lines indicate loss of bone by caries.

in the tympanic membrane, with extensive tissue-changes, *without the usual pain* and inflammatory symptoms. But we must bear in mind that we may find non-tubercular purulent otitis media in a patient suffering from tuberculosis in other parts of the body. Neither must we conclude that the aural affection is non-tubercular when we fail to find the tubercle bacilli in the secretion: their presence or absence in the ear may depend upon the period of the

infection and upon the number and activity of the streptococci (Moos). The mucous membrane first becomes infiltrated by cellular proliferation, followed

by ulceration, tubercle formation, and caseous degeneration. This may extend deeper, involving the bone, which becomes denuded or carious; the ossicles are also generally involved, even the foot-plate of the stirrup may be eroded and the disease extend to the internal ear and cranial cavity.

**Eustachian Tube.**—The mucous membrane of the Eustachian tube is subject to the same changes that we find in the naso-pharynx, and disease may extend to the middle ear by continuity of tissue or by the entrance of infected secretion through its lumen during violent acts of coughing and sneezing, by Valsalva's method, or by the use of unclean catheters and bougies.

To guard against infection the movement of the ciliated epithelium is directed *from* the tympanic cavity *toward* the pharynx; while the isthmus, or narrowest portion of the tube at the junction of the bony and cartilaginous portions, forms another barrier. If the disease has once passed beyond these, and especially the chronic catarrh, then we cannot hope for a cure in the middle ear until the inflammation of the nose and pharynx has been relieved (see pp. 727 and 747).

Where the inflammation becomes chronic, there is thickening of the mucous membrane, with increased prominence of the normally existing folds in the tube, which, with increased secretion from the glands, causes occlusion of the lumen, preventing free ventilation of the middle ear. This condition may continue for years, but sooner or later the atrophic changes begin, with partial destruction of the glands, and reduction or obliteration of the folds; the mucous membrane becomes thin and the tube patulous. Occlusion of the tube is observed as a result of ulceration from syphilis, diphtheria, and tuberculosis.

**The Mastoid.**—The intimate communication between the tympanic cavity and mastoid cells, and direct continuation of the mucous membrane from one to the other, explain why in severe inflammation pathological changes are found both in the antrum and adjoining cavities. There is great tendency to periosteal involvement and necrosis of the bone (see Fig. 50 $\frac{1}{2}$ ), with formation of abscesses—subperiosteal or extradural as well as truly empyemic: especially is this likely to occur if through swelling of the mucous membrane the passage is closed between the antrum and the rest of the tympanic cavity.

Where the inflammation is chronic we may have hyperplasia of the osseous tissue, which gradually obliterates all of the pneumatic spaces, resulting in sclerosis or even in eburnation of the bone. At the same time, periosteal irritation may lead to hyperostosis of the exterior of the mastoid (see p. 751).

**Labyrinth.**—In general anemia we observe disturbance of the internal ear. The symptoms are at times especially marked where there has been great and sudden loss of blood. Diminution of the caliber of the labyrinthine vessels, due to endarteritis, is also a factor. Hyperemia may result from a number of causes, such as general congestion, inflammation of the middle ear, meningitis, and the various infectious diseases.

Hemorrhage into the labyrinth may result from injury, infectious disease, meningitis, pernicious anemia, and abuse of various drugs. The hemorrhages may be small and quickly absorbed, with restoration of function, or more extensive, with partial or total loss of hearing. The apoplectic forms of Ménière's disease are regarded as due to hemorrhage or acute exudation.

Secondary inflammation of the internal ear is frequent and may result from—

a. Inflammation of the middle ear, the avenue of infection being generally through the windows, external semicircular canal, lymph- and blood-vessels.

b. Meningitis, often resulting in total deafness and, if in early childhood, deaf-mutism. In this disease we often find thrombosis of the smaller vessels and erosion of their walls, due to bacterial toxin, while the acoustic nerve is often infiltrated with small hemorrhages and bacterial colonies. If the patient survives the meningeal attack, the inflammation in the labyrinth may run a chronic course, granulation-tissue forms, which again changes to connective tissue associated with development of new bone, partially obliterating the spaces within the labyrinth (see Fig. 514, p. 768).

*Acquired Syphilis.*—Considering the frequency of this disease, we must regard labyrinth complication as rare, and in cases where it does occur we nearly always find that the patient has previously suffered from catarrhal or purulent otitis, which caused congestion of the internal ear, acting as a predisposing factor.

The syphilitic inflammation of the labyrinth may develop in one or both ears at almost any period after the infection, but most frequently during the first two years. The chief pathological changes found consist of endarteritis, with partial or total obliteration of the vessel lumen. The inflammation may lead to necrosis or the formation of new osseous deposits, causing synostosis of the stapedio-vestibular articulation: strangulation of the auditory nerve by periostitis and bony deposits in the internal auditory canal are also encountered.

*Hereditary syphilis* generally attacks the internal ear between the eighth and twentieth years, and is found from three to five times more frequently in the female than in the male. It is generally associated with interstitial keratitis, but the latter often exists without affection of the labyrinth. Hutchinson found deafness only 15 times in 102 patients suffering from syphilitic keratitis. The pathological changes found in the internal ear as a result of inherited syphilis are very similar to those resulting from the acquired infection.

**Internal Auditory Canal.**—Inflammation of the acoustic nerve is encountered as a result of extension from the labyrinth to the brain, or the process may be reversed. In 14 cases of mixed forms of meningitis examined by Gradenigo he found that the inflammation involved the nerve in the internal meatus 13 times, the one exception being in a case where the meningitis had existed only a few hours.

# EXAMINATION OF PATIENTS; SYMPTOMATOLOGY AND DIAGNOSIS; INSTRUMENTS NEEDED, AND METHODS OF THEIR EMPLOYMENT.

BY JOHN E. SHEPPARD, M. D.,

OF BROOKLYN, N. Y.

THE clinician must always bear in mind the embryological and physiological division of the organ of hearing into a sound-conducting and a sound-perceiving apparatus, as contrasted with the anatomical division into three parts, the external, middle, and internal ear—the sound-conducting apparatus consisting of the external and middle ear; the sound-perceiving apparatus including, of course, the internal ear, the auditory nerve, and the perceptive centers in the brain. While a consideration of the function requires only the division into conducting and perceptive portions, the threefold anatomical division is, on the other hand, necessary for examination: since for the external ear, including the periotic region, the auricle, external auditory canal, and membrana tympani, we depend principally on inspection and palpation; for the middle ear, including the Eustachian tube and tympanic cavity, we must rely largely on pneumatic measures; and for the internal ear on acoustic methods.

The general plan which it is proposed to follow in this chapter is to describe the methods, in the order in which they come, which I have for years followed as a routine in my daily examination of patients. These may be divided according to the following general arrangement:

- I. Clinical History, with General Symptomatology;
- II. Functional Examination;
- III. The Periotic Region;
- IV. Otoscopy;
- V. Examination of Nose, Naso-pharynx, and Pharynx;
- VI. Examination of the Middle Ear.

By a general adherence to this plan it is believed that accuracy of diagnosis, the *sine qua non* of proper treatment, may be most uniformly attained. As an incentive to uniformly thorough examination in every case the writer is a firm believer in some form of history blank, which each aurist may develop by experience to suit his own needs. The one shown at the end of this chapter is the result of the combined experience of my colleague, Dr. Alderton, and myself, and is the one which we have used for several years with eminent satisfaction. The blanks are printed on moderately stiff cardboard, so that they may be kept for reference after the manner of a card catalogue.

## I. THE CLINICAL HISTORY, WITH SYMPTOMATOLOGY.

A record should first be made of the patient's name, address, age, date of the first visit, occupation, whether previously treated, and, if so, to what



extent; after which the patient's general condition of health should be inquired into. The patient should then be asked to state what is the most *troublesome symptom, the principal cause of complaint*, this statement to be followed by a careful inquiry into the *duration* of the trouble. My reason for thus commencing the investigation is that in routine cases much time will be saved through thus early getting information which will result in the following questions being asked more intelligently. The so-called *cardinal symptoms*, of one or more of which the patient will complain, and as to the general significance of which a few words are demanded, are the following: (*a*) Defect of hearing, (*b*) tinnitus, (*c*) pain in or around the ear, (*d*) discharge from the ear, (*e*) visible alterations in the external parts, (*f*) vertigo. It should be remembered that most of these symptoms may arise from extraural causes; defect of hearing may be due to intracranial lesions; pain is frequently felt in the ear when the trouble is at a distance; tinnitus may be due to increased arterial tension, anemia, toxic, or other general causes; and vertigo has a varied origin. On the other hand, serious constitutional disturbance may arise from unobserved ear-disease—*e. g.* some obscure pyemias.

**Defect of Hearing.**—The quantitative and qualitative determination of this will be described later. As having a certain symptomatic value may be mentioned the following generalizations: An insidious onset, without definite cause and with early occurrence of tinnitus, is suggestive of middle-ear catarrh (sclerotic form). Relatively rapid loss of hearing (from good hearing to great deafness within a month), with but few or no accompanying symptoms, suggests the possibility of labyrinthine syphilis. Sudden deafness without symptoms points to the probability of cerumen impaction. "Hearing better in a noise" (*paraensis Willissii*) means, as a rule, a special form of middle-ear disease; while those with nerve-deafness—boilermakers and others—usually hear worse in a noise. Autophonia or tympanophonia, that condition in which the patient's voice seems to him to go out through the ear instead of the mouth, indicates, as a rule, some pathological condition of the Eustachian tube, but is occasionally present in other conditions of the middle ear or in impacted cerumen. It is, on the contrary, so far as my knowledge goes, never met with in internal-ear troubles.

**Tinnitus** should next be inquired about. It is variously described by patients, but two general classes may be made out: 1. Pulsating, due to arterial congestion which is probably in either the external or middle ear if it is stopped by pressure on the common carotid, and in the internal ear if stopped by pressure over the vertebral artery in the suboccipital triangle; 2. Non-pulsating, or continuous, with varying characteristics: the high-pitched sounds, hissing, singing, etc. are often due to increased tension in the middle ear, irritating the auditory nerve, and often relieved by inflating the tympanum; the deep humming sounds, worse after exertion, relieved after lying down a little time, are often due to anemia; the rushing sounds are often due to venous congestion, are worse on lying down, and may be relieved by purgation. Finally, it should not be forgotten that the hearing by the insane of bells, music, voices, etc. may be caused by aural disease, at times remediable. It is of course easy to locate in the middle ear the little crackling due to swallowing, the crackling caused by air entering a tympanic cavity containing fluid, the loud pulsating sounds accompanying acute inflammations of the membrane, the tympanum, or the mastoid cells, or the loud, at times rhythmic, noises due to contraction of the palatal muscles, generally with participation of the tensor tympani or stapedius muscles (often perceptible to others).

**Pain—earache**—is an important symptom, and should be carefully investigated. It accompanies acute inflammatory affections of the external and middle ear, the exacerbations common in chronic middle-ear inflammations, with extension of caries or development of cholesteatoma, as well as mastoiditis and mastoid periostitis. In inflammation of the external ear the pain is usually accompanied by tenderness in front of or below the auricle, and is increased by motion of the jaw. If it is the tympanic membrane or tympanum that is involved, the pain is accompanied by more or less deafness, and is increased by sneezing, coughing, blowing the nose, or by inflation. Pain in the course of a chronic middle-ear suppuration usually indicates pus-retention, and is described by the patient as deep-seated. In inflammation of the mastoid or its covering periosteum the pain is more or less radiating in character, and is commonly attended by tenderness over all or part of that process. Reflex pain, neuralgic in character, is often felt in the ear, all the other cardinal symptoms of ear-disease being absent, and is caused by diseased teeth, inflammatory conditions about the throat and tongue, and by malarial poison and the rheumatic diathesis.

**Discharge.**—Inquiry should be made whether there is discharge, and, if not, whether it has previously existed. If there has been discharge which has ceased, then it is only natural to expect to find the results of such suppuration in the shape of cicatrices in the membrane, old dry perforations, or more or less binding down of the structures in the tympanic cavity by cicatricial tissue; if there is discharge, note the quantity, the time since it commenced, the nature of it—that most frequently found is pus—and if this be in considerable amount, and particularly if it contain mucus, it is safe to say the trouble is in the middle ear and that the membrane is perforated; when mixed with blood it usually indicates granulations or polypi; a copious hemorrhage late in a chronic suppurative case usually means erosion of a blood-vessel, internal carotid or bulb of the jugular. A scanty discharge, at first watery, then purulent, attended with itching, would indicate the external canal as the source. Fetor of the discharge is of relatively little diagnostic value unless very persistent under treatment, when it becomes suggestive of diseased bone or retention of putrefactive material in the antrum or mastoid cells. Duration of discharge and mode of onset are significant. A recent sudden discharge, preceded by pain, indicates acute middle-ear inflammation; but if *not* preceded by pain in an ear which has not previously discharged, suspicion of tubercular trouble should be at once aroused. A history of discharge recurring at intervals of from two weeks to two months, lasting but a short time, and usually preceded by pain, is good ground for suspecting attic trouble with perforation in Shrapnell's membrane. The long standing of a suppuration indicates most often neglect; in other cases granulations, polypi, carious ossicles, involvement of the antrum or mastoid cells, and at times naso-pharyngeal disease or constitutional dyscrasia.

**Vertigo.**—Under this heading may be mentioned not only the disturbances of equilibrium, but, as being closely allied thereto, the nausea, vomiting, and loss of consciousness which at times accompany conditions and manipulations of the ear. Since we see these symptoms with pathological conditions of the several parts of the ear, they cannot be said to indicate any particular disease, excepting possibly in the case of a patient having a tendency to fall always in the same direction. As a rule, the patient falls away from the affected ear, and in such a case it is presumptive evidence in favor of a lesion of the internal ear, probably some portion of the semicircular canals. An attack which from the suddenness and severity of its first

appearance seems almost apoplecticiform in character, attended by deafness, tinnitus, and often vomiting, suggests, of course, hemorrhage into some portion of the labyrinth. Less violent vertigo arises from increased tension of the labyrinthine fluid secondary to middle-ear disease—*e. g.* pressure of a granulation or a cholesteatomatous mass upon the stapes, or from syringing too forcibly or with too cold water. There are various other sources of vertigo, however, besides the ear, which must be excluded.

**Cause.**—Having thus gone through with the symptomatology, the patient should next be interrogated as to the *supposed cause*—whether there may have been an injury to the ear or head; in regard to bathing, to head-colds, throat-affections, mouth-breathing, exanthemata, or whether he has had syphilis, rheumatism, or gout; or if he has been taking large doses of medicine, such as quinia or the salicylates; and finally, whether or not the occupation may have any bearing on the case. Under this heading information of great value will be frequently obtained as regards both diagnosis, prognosis, and treatment. As the next step, may be summed up, as briefly as possible, the *course* of the trouble, a recapitulation, as it were, of the history as gained up to this time—the principal complaint, its mode of onset, its duration, and the necessary data with regard to the symptoms. The final step in this part of the examination, which in very many cases may be omitted, is an inquiry into the family history with regard to deafness. Since in some cases important information is obtained, it seems well to have a space in the history blank devoted to *heredity*. Following this is another space for “Remarks,” which should be a part of every record blank, in which should be noted anything of interest peculiar to the case and for which there is no place elsewhere.

## II. FUNCTIONAL EXAMINATION.

Having thus finished the preliminary examination, the next thing to investigate is the function of the organ. How much is the hearing impaired? Where is the lesion that causes the deafness?

**I. Quantitative Tests.**—To determine *how much* the hearing is affected compare the distance the ear under examination hears a given sound with the distance the same sound is heard by a normal ear. This is conveniently expressed in fraction form, as suggested by Prout, the denominator representing the hearing distance, in feet or inches,

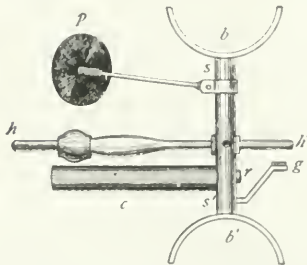


FIG. 470.—Poltzer acoumeter, with the steel rod *c* to be struck by the hammer *h* falling just the distance permitted by the stop *g*, while the thumb and index finger grasp it at *bb'*, and can rest the disk *p* against the bone of the head.

of the normal ear; the numerator, that of the ear being investigated. The sounds most used as tests are the tick of a watch and of Politzer's acoumeter, the voice, and the vibrations of the tuning-fork. The watch-tick answers very well for observations by the same individual, but does not permit a comparison of results with those of other observers. To meet this objection Politzer devised his *acoumeter* (Fig. 470), so that all might have an instrument giving a sound of uniform quality and intensity. In testing the hearing with either of these they should be gradually brought from beyond the limit of hearing *toward* the ear until heard. The ideal test for impaired hearing, however, is the human voice, and the different degrees of deafness are represented as hearing for whispered words, for ordinary, loud, or shouting



conversation. For different observers to obtain as nearly as possible a uniform result in the test with whispered words the so-called "reserve-air" method should be used, the reserve air consisting of what is left in the lungs after a forced inspiration followed immediately by a normal expiration. Since patients become rapidly accustomed to test-phrases if repeated, this should be avoided—*e. g.* by using numbers, of two figures, interspersed at times with words or phrases of another character. To avoid error if one ear is very deaf and the other but slightly so or not at all, with the latter stopped tightly with the moistened finger of the patient, or, better still, of an assistant, and the deaf ear toward the examiner, note the result; then have in addition the deaf ear tightly stopped and repeat the tests. If, now, the patient hears the same as with the deaf ear unstopped, it is evident that deafness is complete, and that the hearing in the first test was with the stopped ear. Since the mere sound may be heard, the patient should be made to repeat the words in all the tests.

**2. Qualitative Tests.**—Having with the preceding tests found the amount of deafness, the purpose of the following measures is to locate the lesion either in the sound-conducting or the sound-perceiving apparatus, for which purpose we use the Galton whistle and tuning-forks of various pitch. The normal ear perceives vibrations as musical notes when repeated at regular intervals from 16 up to 32,500 vibrations to the second, and these may be called the lower and upper limits of audition. These limits vary in a characteristic way with disease of the conducting or perceiving apparatus. Again, there is a fairly definite ratio in the normal ear between the duration and loudness of tuning-fork vibrations by air- and by bone-conduction, and this ratio is altered more or less definitely according to the part of the ear affected by disease. The lower tone-limit, or rather any lack of hearing for the lower notes, may be determined with sufficient accuracy by means of the C<sup>v</sup> large-clamp tuning-fork (Fig. 471), whose range of vibrations is from 26 to 64 to



FIG. 471.—Dench's large tuning-fork with clamps at ends, giving 64 v. s., and without clamps 26 v. s.

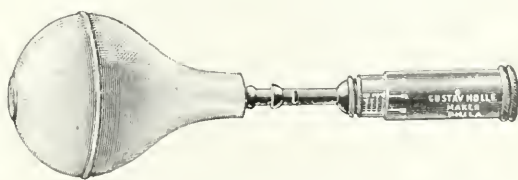


FIG. 472.—Galton's whistle with rubber bulb. The pipe below the opening is filled by a plunger advanced or withdrawn by a screw, each turn being shown by the scale upon the enlarged tube, and its tenths by that on the revolving collar. It gives an audible sound from 0.5 (theoretically, 81,000 v. s.) to 10 or 12 (4200 or 2500).

the second. The upper tone-limit can be most accurately determined by König's rods, but these are too time-consuming for daily use, and Galton's whistle (Fig. 472) gives the same result much more quickly and with sufficient accuracy.

To properly compare air- with bone-conduction we need the absolute duration of each and the relative intensity of the two. To obtain the former a freshly struck tuning-fork is held in front of the external auditory canal,



the time in seconds being taken from the moment it is struck until it ceases to be heard by the patient; duration of bone-conduction is obtained in the same way, except that the handle of the vibrating fork is rested firmly upon the mastoid process until it is no longer heard. Relative intensity is obtained by placing a freshly struck tuning-fork in rapid succession two or three times upon the mastoid and opposite the meatus, and having the patient determine whether air- or bone-conduction is louder. By air-conduction the sound-waves reach the perceptive centers through the sound-conducting apparatus; by bone-conduction the path is through the cranial bones. In the normal ear the duration of air-conduction is, roughly speaking, about double that of bone-conduction. In obstructive trouble in the conducting apparatus the duration of air-conduction is lessened as compared with that of bone-conduction. In trouble with the perceptive apparatus the duration of both is lessened, that for bone- relatively more than that for air-conduction, especially for the higher forks. Aided by these facts, the methods of locating the lesion may be briefly reviewed.

**Weber's Test.**—Weber found that if a vibrating tuning-fork was placed upon the middle line, antero-posteriorly, of the head, either on the vertex, forehead, or upper incisor teeth, and one ear stopped, the fork was heard louder in that ear. Reasoning from this, in any given case, if the hearing is impaired in one ear only or unequally in the two ears, and a vibrating fork on the vertex is heard *better* in the worse-hearing ear, it follows that the lesion in the bad ear is an obstructive one—*i. e.* in the sound-conducting apparatus; and, *vice versa*, if it is heard *worse* in the worse-hearing ear, then the trouble is in the perceptive apparatus.

**Rinné's Test.**—If the conducting apparatus in any given case is normal and a vibrating fork is pressed upon the mastoid until it ceases to be heard by bone-conduction, and is then held opposite the meatus, it is again heard by air-conduction. If the conducting apparatus is affected to any marked extent, the vibrating fork, allowed to die away on the mastoid, is not heard when brought opposite the meatus. In the former case (air-conduction exceeds bone-conduction, A.-C. > B.-C.), and Rinné's test is said to be positive (R. +), and indicates, as a rule, no marked trouble with the conducting apparatus (middle ear). In the latter case bone-conduction preponderates (B.-C > A.-C.), and Rinné's test is negative (R. -), indicating disease of the conducting parts (middle ear).<sup>1</sup> In many cases, undoubtedly, Weber's and Rinné's tests give valuable information; yet there are many, the doubtful or border line, cases in which they cannot be relied on for diagnosis.

**Schwabach's Test.**—In this method the Hartmann series of five forks is used: C = 128 v. s., C<sup>i</sup> = 256 v. s., C<sup>ii</sup> = 512 v. s., C<sup>iii</sup> = 1024 v. s., C<sup>iv</sup> = 2048 v. s.; and of these the absolute duration and the relative intensity of both air- and bone-conduction are noted. When compared with the results obtained from examination of a series of normal ears this furnishes data which, in my judgment, are most valuable for diagnostic purposes. The C<sup>i</sup> fork, 26 to 64 v. s., may be added to the series. As Alderton has shown, for routine work a sufficiently accurate result in the majority of cases may be obtained by using the low fork C<sup>i</sup> or C and the C<sup>iii</sup> fork, these indicating

<sup>1</sup> The terms "R. +" and "R. -" in themselves mean nothing; in fact, I have reason to believe that experienced aurists have not infrequently to stop and mentally translate them. As substitutes, for general adoption, I propose the following formula, which I know are, in practice, largely used: viz. for Rinné +, A.-C. > B.-C. (air-conduction greater than bone-conduction), and for Rinné -, B.-C. > A.-C. (bone-conduction greater than air-conduction). These formulæ convey a definite idea, and their use is not attended with any more consumption of time or space.

pretty clearly the location of the trouble. A diagnosis of middle-ear trouble, having eliminated by inspection obstructive trouble in the external auditory meatus, may be made after going through with some or all of the above tests—*I.* If there is loss or impairment of hearing for the lower notes of the scale, with elevation of the lower tone-limit; *II.* If air-conduction only is diminished, bone-conduction remaining unchanged or even increased—the normal ratio of B.-C. < A.-C. being thus changed, particularly so for the lower notes. If the lesion is marked, B.-C. becomes louder and longer than A.-C.; *III.* If with the impaired hearing the upper tone-limit by A.-C. is but little, or not at all, affected. Diseases of the internal ear are recognized in the same manner by—*I.* No elevation of the lower tone limit; *II.* The maintenance through the lower notes of the normal ratio between A.-C. and B.-C., the absolute duration of both being, however, reduced, and very markedly so, that for the higher notes by B.-C.; *III.* Lowering of the upper tone-limit, with frequently entire deafness for certain of the higher notes.

To illustrate the manner of recording in compact form the result of tuning-fork investigations, I have subjoined a record for normal hearing, for chronic middle-ear catarrh, and for disease of the sound-perceiving apparatus. The relative intensity is shown in the horizontal space marked Rinné—A.-C. being louder than B.-C., it will be observed, throughout the series in normal hearing and in nerve-deafness; the reverse being true for chronic catarrh, B.-C. being louder than A.-C., except for the highest fork, in which the intensity by A.-C. and by B.-C. are about equal. The figures represent absolute duration in seconds, the upper line representing the duration by A.-C., the lower one that by B.-C. :

|       |       |                |                 |                  |                 |        |            |                |                 |                  |                 |       |
|-------|-------|----------------|-----------------|------------------|-----------------|--------|------------|----------------|-----------------|------------------|-----------------|-------|
| 1.    | A.-C. | A.-C.          | A.-C.           | A.-C.            | A.-C.           | Rinné. | 2.         | B.-C.          | B.-C.           | B.-C.            | B.-C.           | Equal |
| A.-C. | 25    | 15             | 33              | 32               | 22              |        | Schwabach. | A.-C.          | 6               | 6                | 10              | 11    |
| B.-C. | 13    | 7              | 13              | 13               | 14              | B.-C.  |            | 15             | 11              | 16               | 13              | 9     |
|       | C     | C <sup>i</sup> | C <sup>ii</sup> | C <sup>iii</sup> | C <sup>iv</sup> |        | C          | C <sup>i</sup> | C <sup>ii</sup> | C <sup>iii</sup> | C <sup>iv</sup> |       |

1. Typical of normal hearing.

2. Typical of obstructive trouble in the sound-conducting apparatus.

|       |       |                |                 |                  |                 |            |
|-------|-------|----------------|-----------------|------------------|-----------------|------------|
| 3.    | A.-C. | A.-C.          | A.-C.           | A.-C.            | A.-C.           | Rinné.     |
| A.-C. | 17    | 15             | 19              | 11               | 10              | Schwabach. |
| B.-C. | 8     | 7              | 3               | 3                | 1½              |            |
|       | C     | C <sup>i</sup> | C <sup>ii</sup> | C <sup>iii</sup> | C <sup>iv</sup> |            |

3. Typical of trouble in the sound-perceiving apparatus.

To those who wish to get along with the smallest possible number of diagnostic instruments for ear-work it may be said that fairly accurate opinions may be formed with the use of but three instruments—viz. a low-pitched tuning-fork (C<sup>-1</sup>), 26 to 64 v. s., to determine the lower tone-limit, and thereby the presence of trouble in the conducting apparatus; a Galton whistle, to determine the upper tone-limit, and thereby the presence of disease of the perceptive apparatus; finally, another tuning-fork, of 512 or 1024 v. s. (with such a group of instruments, I should say the one of

1024 v. s. would give the most information), for the determination of absolute duration of A.-C. and B.-C. To one determined to get along with but one fork I would recommend C<sup>m</sup> of 512 v. s., but with this alone accurate diagnostic work is impossible. Other tests have been devised to aid in locating diseases of the ear.

**Gelle's Test** (*Pressions Centripetals*).—In the normal ear, if a vibrating tuning-fork be placed on the vertex, and then the air in the external auditory canal be compressed, the sound dies away, to return again with removal of the compression. This is believed to prove mobility of the chain of ossicles, but particularly of the foot-plate of the stapes in its niche, and Gelle's test is positive, +; otherwise it is negative, —; *i. e.* in rigidity of the ossicular chain (trouble in the conducting apparatus).

**Bing's test** or *experiment* is essentially a modification of Weber's test. A vibrating tuning-fork is held on the vertex until it ceases to be heard; then either external auditory canal is closed with the finger, and the fork is again heard for an interval which is called the period of secondary perception. With a normal conducting apparatus this interval of secondary perception is well marked; hence if the interval is shortened a lesion of the sound-conducting apparatus is to be inferred. If the interval be normal and yet deafness is present, the seat of the trouble must be in the perceptive apparatus.

Other tests, a detailed description of which is forbidden by lack of space, are those of Iteberg and Gradenigo relative to the "fatigability" of the perceptive apparatus; that of "binaural synergy" of Gelle; the "interference otoscope" of Lucæ; and the reaction of the auditory nerve to the electric current.

### III. THE PERIOTIC REGION.

Having thus finished the preliminary history and the functional examination, we may now investigate the parts surrounding the auricle, making use of inspection and palpation for this purpose. The *supra-auricular* region is at times the seat of subperiosteal abscesses in adults as well as in children. The *preauricular* region may be the seat of mumps, lymphadenitis, parotitis, or pus-burrowing. In the *infra-auricular* region lymphatic inflammation with redness and swelling is common in acute inflammatory affections of the external ear. A hard, cord-like, tender swelling along the anterior border of the sterno-mastoid muscle should arouse suspicion of sinus-disease involving the jugular. A more diffuse, hard swelling in this region is a common accompaniment of the Bezold form of mastoid abscess, breaking into the digastric fossa. The *postauricular* or *mastoid* region should always receive careful attention, particularly in cases attended by pain or suppuration. There may be pain, tenderness, redness, swelling, fluctuation, sinuses, or cicatrices. *Pain*, with or without other evidence of underlying trouble, is one of the most important symptoms of mastoid inflammation. The *point of greatest tenderness*, whether *on* or *behind* the mastoid process, should be noted, remembering that tenderness of the mastoid itself usually means underlying inflammation, while tenderness behind it, particularly if at the seat of the mastoid foramen, may mean disease of the lateral sinus. *Swelling* is either circumscribed and movable, when it indicates an inflamed gland, or diffused, as in subperiosteal abscess, etc. *Fistula* and *sinuses* must be carefully investigated. When congenital they usually open anteriorly, and are often attended by other malformations. When acquired they are most often postauricular, and may lead to the remains of a superficial (glandular)



abscess, forward to the external auditory canal, to the periosteum, to the underlying bone, to the interior of the petrous bone, to the groove for the lateral sinus, or into the cranial cavity. The presence of *cicatrices* may throw light on the nature of previous troubles.

IV. OTOSCOPY.

Now that we approach the examination of the ear itself, it should be remembered of the external auditory canal that it is somewhat oval in section, about  $1\frac{1}{4}$  inches in length, its general direction inward, forward, and upward, and that it is somewhat angled at the junction of the cartilaginous with the bony portion. Hence to straighten the canal for purposes of examination the auricle must be pulled outward, backward, and upward, except in infants and young children, in whom, owing to the absence or shortness of the bony portion, it should be pulled downward instead of upward (see Plate 10). The relation of the tympanic membrane to the inner end of the canal should also be borne in mind, the plane of the membrane being from above and behind in a direction downward, forward, and inward, in the very young approaching more nearly the horizontal than in the adult (? Ed.), so that the posterior superior quadrant is nearest to the outer end of the canal, and may easily be injured, particularly in children, by the careless introduction of a small speculum.

**Illumination.**—To examine an ear it is necessary to have some means of illuminating it, and, since direct illumination is for various reasons unsatisfactory, we now use altogether the reflecting mirror, preferably so fixed with a band as to be used as a head-mirror, which may, if desired, be used as a hand-mirror. It should be provided with a double ball-and-socket joint (Fig. 473); may vary in size from 2" to 4" in diameter; should have a hole in the center, through which the examiner may view the ear; should be concave, and, most important of all in making a selection, should have a focal length of not less than 6 nor more than 10 inches.

Of next importance to the mirror is the speculum. This may be made of metal (German silver, aluminum), hard rubber, glass, or celluloid; it may be round or oval in section, with or without a curve between the large and small ends, may be long or short, and made up in sets or "nests" of three or four different sizes. The choice of material may depend largely upon personal preference. Each kind has its advantages and disadvantages. My own preference is for the hard rubber, or, still more, for the pinkish (flesh-colored) celluloid, which I have now used for two years with great satisfaction.

Other instruments needed for the routine examination of the ear are such as are used for the removal of the frequently-found obstructions in the canal—cerumen, hairs, epithelial flakes,

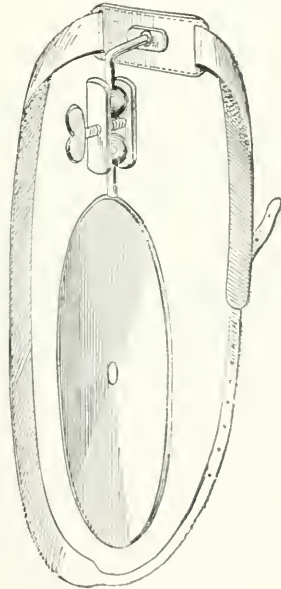


FIG. 473.—Forehead mirror.

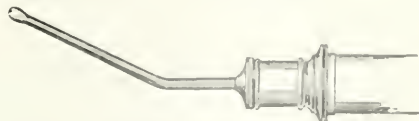

FIG. 474.—Angled syringe-tip.



cotton, etc. These, when small or in the cartilaginous portion may often be pushed aside by the speculum, but, if large or in the bony canal, must be removed by other means. Should the canal be blocked by a large ceruminous or epithelial plug, a foreign body, or with pus, it is best cleansed by the use of a syringe and warm water. The most satisfactory form of syringe for office use is one with either glass or metal barrel, of two to four ounces capacity, and having an angular tip of small diameter (Fig. 474). Other instruments for this purpose are the cotton-carrier, the probe, the blunt hook, the Gross ear-scoop and hook, and some form of ear-forceps. An ordinary steel cotton-carrier answers the purpose. In using it wrap a small pledget of cotton tightly, leaving about  $\frac{1}{4}$  inch of the cotton beyond the end of the carrier to protect the canal-walls from injury. With this much loose débris can be easily mopped from the canal, as well as small quantities of pus, etc. As a rule, entirely too large a pledget of cotton is used: much better results can be obtained from a few small pledgets intelligently used in a well-illuminated canal than from an unlimited number of the large pledgets that are so much in vogue. The probe and blunt hook, as combined in the Hartmann instrument (Fig. 475), are very useful in clearing out a canal and

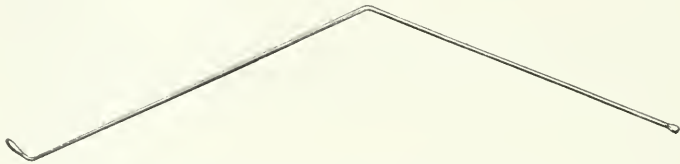

FIG. 475.—Hartmann's combined probe and blunt hook.

investigating the condition of its walls as well as of the tympanic membrane. The Gross ear-scoop and hook, found in many of the minor surgical pocket-cases, is also a decided aid in many cases, but must be used with great caution and with good illumination of the canal. A good pair of ear-forceps

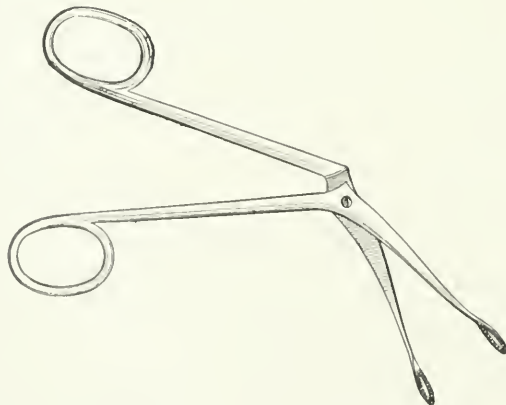


FIG. 476.—Hartmann's ear-forceps.

is a necessity—their number and forms approach legion: that which has served me most usefully is the Hartmann dressing-forceps (Fig. 476).

It may not be out of place to make one more general remark about all

ear-instruments which permit of it—*i. e.* they should be bent at an angle of about  $135^{\circ}$ , instead of being straight, because this shape allows of easier and more skilful use, and avoids the objection which holds against all straight instruments—*viz.* that with them the index finger must of necessity intrude more or less upon the line of vision.

**Source of Light.**—In ear-work this is a matter of importance. Sun-light, daylight from a northern window, the reflection from white clouds, a white wall or fence, cannot any of them, be used at all times. Hence artificial light, which may be had constantly and of uniform intensity, must be our standby. The oxyhydrogen flame, the incandescent electric light, gas-light plain or modified by the Welsbach burner, the kerosene lamp, the old-fashioned tallow-dip, have all of them their uses; but for routine work my preference is for the Welsbach burner.

**Technic of Examination.**—The ear to be examined should be turned away from the light and toward the examiner, the light being about on a level with the patient's ear. The examiner should always use the same eye, thus training it to do the best possible work, and should with the chosen eye always make the observations through the perforation in the center of the head-mirror. The other eye should always be kept open, both to avoid fatigue and to locate the direction of the reflected light and to aid in focusing it more quickly upon the ear. This being done, the auricle, the concha, and so much as possible of the canal should be carefully observed before a speculum is introduced; otherwise affections of these parts may be hidden by the speculum and entirely overlooked. Should pieces of epithelium or cerumen be in the way, remove them carefully; should the canal-walls be found swollen, as from furuncle, introduction of the speculum may be too painful and have to be postponed; in such a case the evident swelling, together with the history, perhaps sufficing for a diagnosis.

Having the light properly focussed, and having chosen a speculum of appropriate size, it is introduced as follows: Seize the upper outer part of the patient's auricle, if the right one, between the middle and ring fingers, if the left one, between the index and middle fingers, of the left hand, and, supposing the case to be an adult, pull the auricle firmly upward, outward, and a little backward to straighten the canal; then with the right hand introduce the speculum, with a slight rotary motion, inward past the frequently existing hairs, etc. in the outer portion of the canal, and grasp it between the left thumb and index finger, the right hand being thus left free for other manipulations. Epithelial flakes, cerumen, pus, etc. obstructing the view must be removed by the appropriate instruments, so that an unimpeded view of the tympanic membrane may be obtained. An occasional difficulty is an unduly prominent antero-inferior canal-wall, but practice in changing a little the line of vision and the position of the speculum will overcome this. In exceptional cases the presence of the speculum in the ear gives rise to a troublesome ear-cough, and still more rarely to a feeling of faintness or positive fainting, or even to epileptiform attacks. As a rule, however, the patient becomes rapidly accustomed to the presence of the speculum.

**Appearances of the Canal.**—The epidermis lining the normal canal has an opaque whitish color. Under *pathological* conditions the walls may become hyperemic, may be the seat of localized or diffuse swellings, or may show serous or purulent excretions, ulcerations, or fistulae, while the lumen of the canal may be more or less filled with serous, mucous, or purulent secretions, with collections of cerumen or thrown-off epithelium, with foreign

bodies, or with tumors (exostoses, polypi, etc.) which arise either from its walls or from the tympanic cavity.

**Appearances of the Tympanic Membrane.**—The normal membrane

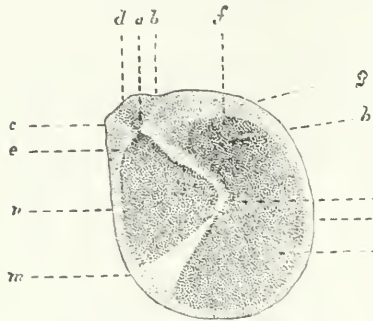


FIG. 477.—The normal drumhead.

is somewhat oval in shape, pearly gray in color, and translucent, with certain prominent landmarks—the short process of the malleus, antero-superiorly, looking much like a small pustule (*a*, Fig. 477), with the *manubrium* or handle of the malleus running from it downward and backward to the center of the membrane, the *umbo* (*i*); antero-inferiorly from this is the triangle of light, “cone of light,” or light-reflex (*m*), due in shape and position to the concavo-convex face of the membrane and its general oblique position relative to the axis of the canal, whereby the rays of

light from the observer’s mirror strike only here upon a surface at right angles to the line of vision—the rule being that *any point which appears brightly illuminated is on a plane at right angles to the line of sight*. The margins of the membrane are set in the bony tympanic ring, which encircles it completely except at its upper part, where there is a notch, the notch of Rivinus. Filling in this space above the short process is the *flaccid membrane* or *Shrapnell’s membrane*, separated from the other portion of the membrane, the *tense or vibrating membrane*, by the anterior and posterior folds (*c.g.*), whiter than the rest of the membrane and running forward and backward from just above the short process.

Pathologically the tympanic membrane may present—

(*a*) **Changes in Color.**—The luster may be lost, with general dullness and indistinctness of the landmarks, from soaking, loosening, or thickening of the outer layer of the membrane (drops, syringing, superficial or underlying inflammation). *Opacity* results from thickening of any or all the layers, either of the whole membrane or of circumscribed yellow or white patches, single or multiple, large or small, due to fibrous or calcareous degeneration, and indicating, as a rule, severe preceding inflammation. A bright, coppery appearance is due to a congested tympanic mucosa. A dark, hair-like line, concave upward across the whole membrane or across either anterior or posterior half, or both (see Fig. 467), indicates fluid in the tympanic cavity. In hyperemia the individual blood-vessels, not normally seen, become visible along the malleus-handle (see Fig. 8, Plate 11) over Shrapnell’s membrane, or radiating in a thick network over the rest of the membrane, which, in the higher grades of inflammation, becomes pink or even bright red, all the landmarks being lost.

(*b*) **Changes in Surface.**—The normally smooth surface of the membrane may become irregular through the projection of ecchymoses, vesicles, interstitial abscesses, granulations, polypi, or through the wrinkling due to large cicatrices, or to atrophy, or to loosening of the superficial epithelial layer, from disturbance of its nutrition, seen occasionally in acute underlying inflammation.

(*c*) **Changes in Position.**—The membrane may be retracted or bulged, either in part or in its entirety. Retraction, as a whole, is usually due to insufficient ventilation of the tympanic cavity, and is recognized by the following changes in appearance: the anterior half is thrown into deeper shadow;

the short process is unduly prominent, as are the anterior and, to a greater extent, the posterior folds; the malleus-handle is fore-shortened, the light-reflex lessened in size and brilliancy or absent, and at times the tympanic cavity's inner wall and other structures become unduly visible—viz. the promontory posteriorly, the round-window niche postero-inferiorly, and postero-superiorly the descending process of the incus, the head and posterior crus of the stapes, the tendon of the stapedius muscle, and, finally, the chorda tympani nerve crossing the tympanic cavity just below the posterior fold. Circumscribed retraction is due to the indrawing either of atrophic areas, which usually have ill-defined margins, or, much more frequently, of thin cicatrices, which may be large or small, single or multiple, adherent or non-adherent, with margins, however, as a rule, definite and cleanly cut. These localized depressions appear thinner, more translucent, and, when not adherent, more movable than the surrounding membrane, and they not infrequently present at their deeper portions a larger or smaller light reflex. Bulging of the membrane, either localized or general, is usually caused by fluid in the tympanic cavity.

(d) *Loss of Substance.*—Perforations vary in size from a pinhole to absence of almost the whole membrane. They may occur in any part of either the *vibrating* or the *flaccid membrane*, or be present in both simultaneously. They present as circular, elliptical, oval, kidney- or heart-shaped openings, through which the tympanic mucous membrane becomes visible. Two, three, or four perforations of the same membrane are occasionally seen, and among the great rarities may be mentioned the sieve-like perforations which at times accompany tubercular or diphtheritic otitis media. It should be noted whether the margins of the perforation are red and raw, as in recent active perforations, or white and cicatricial, as in permanent openings. In examining for suspected perforation it is of the greatest importance that the whole surface of the membrane should be swept over with the eye, particularly near the margins; and on no account should Shrapnell's membrane be overlooked, that part from which we obtain evidence of the most serious of middle-ear troubles (see Plate 11).

The diagnosis of perforations is, as a rule, easy, but is at times difficult, particularly so of the very small and the very large ones—in the former because the size permits the edges to completely overlie one another, making a diagnosis by unaided inspection at times impossible; in the latter, in which—*c. g.* the whole vibrating membrane, including the malleus-handle and short process, have been destroyed by the suppurative process, because we have not the edges of the perforation sufficiently in evidence to aid the eye to establish the two planes—that for the perforation margins and that for the inner tympanic-cavity wall. In the difficult cases the following aids to diagnosis may be mentioned:—1. A perforation whistle can usually be obtained by forcing air, by some of the methods to be described, from the nose, through the Eustachian tube, out through the perforated membrane. 2. If before using the air-douche in a given case the external canal is thoroughly dried, and after using it fluid is found, its presence is almost certain proof of a perforation. 3. Another proof is furnished by the passage of fluid into the naso-pharynx when syringing an ear. 4. A perforation is indicated by the presence of mucus in the water with which an ear has been syringed. 5. A pulsating light-reflex seen in the depth of a canal means with the greatest probability a perforated membrane.

To distinguish perforations from cicatrices and atrophic spots, in addition to the above guides, there are two instruments which, as *aids to*



*diagnosis*, should be the constant companions of the aurist. The first of these is the *bent probe* and *blunt hook* (see Fig. 475), whose use is to determine the point of insertion, consistence and mobility of tumors or inflammatory new growths (polypi, exostoses, furuncles), to determine the presence of fistulous openings or of bone-caries, as well as by actual touch to investigate the surface of the membrane (perforations, etc.). The other instrument is *Siegle's pneumatic speculum*, or *suction speculum* (Fig. 478).

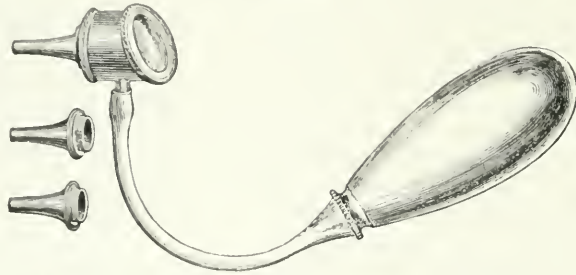


FIG. 478.—Siegle's speculum, the small end made to fit air-tight into the canal, and the large end closed by a glass set in at an angle and fitted with means to condense and rarefy the air in the auditory canal.

To the examiner illuminating the canal through the air-tight speculum will thus be disclosed whether the mobility of the malleus is impaired or whether the membrane is relaxed; sunken cicatricial pouches can be distinguished from open perforations, adhesions of the membrane or of depressed cicatrices, or of the malleus-handle to the inner wall of the tympanic cavity can be made out; and not infrequently collections of pus in the attic or antrum can be detected and emptied by this apparatus.

#### V. EXAMINATION OF NOSE, NASO-PHARYNX, AND PHARYNX.

Since so many of the middle-ear diseases have their origin in the approaches to the Eustachian tube, the examination of the nose, naso-pharynx, and pharynx may well be made preliminary to an investigation of the middle ear. For the details of such examination the reader is referred to the appropriate chapters, special attention being given to the following points: 1. In the examination of the fauces, to the activity of the palatal muscles during phonation, these being also tubal muscles; 2. To the appearance of the naso-pharynx, and especially of the mouths of the Eustachian tubes, by posterior rhinoscopy; 3. To the patency of each nostril in relation to respiration, ventilation, and Eustachian catheterization.

#### VI. EXAMINATION OF THE MIDDLE EAR.

As preliminary to, and really a part of, investigation of the middle ear must first be considered the different means of determining the patency of the Eustachian tube. For the accomplishment of this, three methods may be used:

1. As giving a valuable preliminary idea of the condition of the tubes may be tried Politzer's experiment of holding a vibrating tuning-fork in front of the patient's open nostrils, when, during the act of swallowing, if the tubes are patulous, the vibrations are more distinctly heard by the patient. The rationale is of course plain: the act of swallowing opens the tubes when they are normally patulous, and the sound passes through them into the tympanic cavity. Negatively, if under these conditions the patient hears the

vibrations on one side only or fails to hear them on either side, it is evidence in the former case of tubal obstruction on the side on which the fork was not heard; in the latter case tubal obstruction on both sides is to be suspected.

**2. Inflation of the Ear, with Auscultation.**—Several methods of inflation are in vogue, with all of which auscultation may be carried out, with by far the most success, however, in the first method to be described—viz.:

**1. Inflation by means of the Eustachian Catheter.**—The instruments necessary for this are—(a) Eustachian catheter, made of metal or hard rubber (to the latter I give the preference),  $5\frac{1}{2}$  to 6 inches long, and made in three sizes; its last inch, the tip or beak, is gently curved till the point makes with the shank an angle of  $140^\circ$  to  $150^\circ$ ; the large end is funnel-shaped to fit a corresponding tip on the air-bag, bottle, etc., and has on it a ring pointing in the same direction as the tip of the catheter. (b) An air-bag, single or double. (c) The auscultation-tube, which has been miscalled an “otoscope,” consisting of a piece of light rubber tubing 24 to 30 inches long, having at the ends olive-shaped pieces—one white, the other black, so that they may be distinguished from one another, and the same one always used by the examiner. With this the sounds caused by the passage of air through the Eustachian tube into the tympanic cavity are observed. Before describing the introduction of the catheter the following general remarks may be in place: Catheterization should be performed with both patient and physician in the sitting position; the patient’s head should be in such position that the floor of the nose will be as nearly as possible horizontal. While a head-rest is useful, it is by no means necessary; secretion should be, as far as possible, removed (by blowing, etc.) from the nose and naso-pharynx; a dash of cocain may without disadvantage be applied to the nostrils. The patient should keep the eyes open, should on no account hold the breath, but should breathe through the nose; it is well to occupy the patient’s hands by giving them the air-bag to hold; then with the diagnostic tube in place, dip the already disinfected catheter into water or oil, blow through it to empty it and to see that the lumen is clear, and proceed to *introduce the catheter*.

With the fingers of the left hand resting on the patient’s forehead and nose, where they should remain until the end of the procedure, the tip of the nose being moderately elevated by the left thumb, the catheter is held like a pen between the thumb and first two fingers of the right hand, and is entered, in almost a vertical position, into the nostril until the beak passes over the initial eminence on the floor of the nose. It is then rapidly brought to a horizontal position, and passed gently backward until the beak is felt to touch the posterior pharyngeal wall; if the catheter is brought too slowly to the horizontal position, the tip, instead of passing along the floor of the nose, may easily enter the middle meatus. Another important consideration is to hold the catheter as lightly as possible, not firmly grasped, when, with almost inappreciable force from behind, it will in the majority of cases find its own way through the nostril. Up to this point—viz. finding the posterior pharyngeal wall with the beak of the catheter—the two methods to be described of finding the mouth of the tube are identical. By the first and certainly the easier method the beak, as indicated by the ring at the outer end of the catheter, is turned toward the side to be catheterized into the fossa of Rosenmüller; it is then drawn gently outward for from  $\frac{1}{3}$  to  $\frac{3}{4}$  of an inch, when the impression is given, and after a little practice readily recognized, of the beak turning downward as it passes the prominent posterior lip of the tubemouth, followed, as it enters this, by a distinct feeling of turning upward

again. It should now, the ring pointing toward the outer angle of the eye, be firmly grasped between the thumb and index finger of the left hand, the other fingers remaining in position on the patient's nose; the operator's hand, the catheter and the patient's head becoming thus, as it were, one body, so that movements of the latter do not displace the catheter. By the second method, instead of turning the beak of the catheter toward the side to be

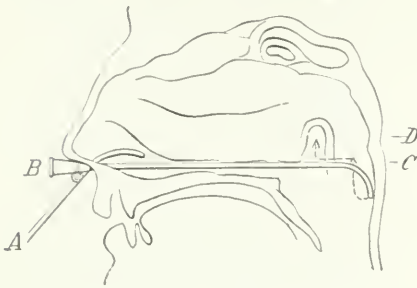

FIG. 479.—Introduction of catheter, first method.

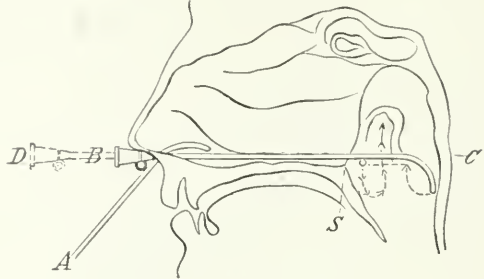


FIG. 480.—Second method.

catheterized, it is turned toward the opposite side, drawn forward until the beak is felt to impinge against the posterior edge of the nasal septum, and is then rotated downward through an arc of  $200^{\circ}$ , when it will, as a general rule, enter the mouth of the tube, and is to be grasped as before. Air is now blown through the catheter and Eustachian tube into the tympanic cavity, and the important information gained from the auscultation-tube is to be noted.

**Auscultatory Sounds.**—These are produced either at the pharyngeal end of the Eustachian tube, in the tube itself, or in the tympanic cavity. With the parts in a normal condition there is heard with each compression of the air-bag a soft, dry, blowing sound, together with a slight thud or impact sound of the current of air against the tympanic membrane. Pathological conditions in the tympanic cavity, in the tube, or in the naso-pharynx change the character of the sounds heard in a more or less characteristic way—*e. g.* the crackling rales of fluid in the tympanic cavity, the whistle with a perforated membrane, the high-pitched rather distant sounds due to a narrowed Eustachian tube, the coarse distant rasping due to mucus in the pharyngeal end of the tubes. These sounds are worthy of careful study, practice enabling one to localize their source and to gain important knowledge of the conditions present.

**Obstacles to Catheterization.**—These are met with in the nose in the form of deflections, ridges, and spurs of the nasal septum; and in the naso-pharynx in the form of variations in the location and prominence of the pharyngeal extremity of the Eustachian tube in different cases; and on the two sides of the same case in the varying width of the naso-pharynx, and from muscular contraction due to the presence of the catheter in the naso-pharynx. Skill and patience will usually succeed in getting the catheter past the nasal obstructions; if not, a catheter with a larger curve to the tip may be passed through the other nostril. Delicate manipulation with differently curved catheters or with the same catheter differently moulded, at the same time insisting that the patient breathe through the nose, will overcome the obstacles met with in the naso-pharynx. Timidity of a patient when catheterized for the first time, and the discomfort to all patients in whom difficulties are encountered, may be greatly lessened or entirely avoided by the use of a small quantity of cocain solution.



**Dangers of Catheterization.**—Emphysema, even fatal in its consequences, has resulted from the use of the Eustachian catheter with highly condensed air; but with the hand apparatus, some form of which is at present almost universally used, even slight emphysema should never result. The experience of one of my colleagues leads me to utter a word of warning against the careless use of the catheter in elderly persons with fragile blood-vessels and an apoplectic tendency. A rare but not dangerous result of catheterization is severe dizziness or even momentary unconsciousness, due to sudden disturbance of labyrinthine pressure. It may be avoided by beginning the inflation very gently, when, if no unpleasant symptoms follow, the strength of the air-current may be increased. Another occasional result, never in my experience attended with serious consequences, is rupture of the tympanic membrane, although this accident is more frequent with Politzer's method of inflation.

**Substitutes for Catheterization.**—The other methods of inflation in common use are those known as Valsalva's and Politzer's.

*B. The Valsalva method* consists of an attempt to blow the nose with the mouth tightly shut and the nose closed with the finger and thumb, when, if one or both of the Eustachian tubes are normally patulous, the air will enter one or both of the tympanic cavities. This method has a certain diagnostic value, because it permits the examiner to watch the tympanic membrane during the act of inflation and to note the effect of the increased intratympanic pressure.

*C. Politzer's method* requires an air-bag, the Politzer bag (8 oz. capacity), and a nose-piece, preferably a conical hard-rubber one large enough to occlude one nostril, which is best connected with the air-bag by means of from 8 to 12 inches of rubber tubing. The idea of the original Politzer method and of its many modifications is to blow air into one nostril, the other being occluded, at the moment when the soft palate and uvula are by some maneuver forced back against the posterior pharyngeal wall, shutting off the naso-pharynx from the throat below it. Politzer accomplished this by having the patient take a small mouthful of water and swallow it at a given signal (nodding the head, the word "now," or counting up to three); simultaneously, one nostril being closed by the nose-piece of the Politzer bag, the other by pressure of the operator's fingers, the air-bag is compressed, when the air, being shut off from going elsewhere, passes through the Eustachian tubes and penetrates the tympanic cavities. Another plan, which almost always succeeds, and which I greatly prefer because of its freedom from discomfort to the patient, is to have the patient close the lips and puff the cheeks out forcibly, or he may be directed to utter in rapid succession the syllables "hieck," "hack," "hock." The crying of very young children usually accomplishes the same purpose. Auscultation in the Valsalva and Politzer methods does not give very much information as to the condition of the middle ear, excepting only if there is a perforation of the tympanic membrane, when the perforation-whistle becomes very evident, often without, as well as with, the auscultation-tube.

**Comparative Value of Catheterization and Politzerization.**—Inflation with the catheter has, as a diagnostic measure, the following advantages over Politzerization: It enables the surgeon to measure the force needed to propel air into the tympanum; he can, by repeating the inflation, study the auscultation-sounds and make therefrom valuable deductions; it depends for success upon the skill of the surgeon, and not upon the patient's attempts to close the naso-pharynx. Catheterization of children under twelve years



of age is difficult, however, and in them, fortunately, the Eustachian tubes being relatively shorter and of larger caliber, more information can be gained from the auscultatory sounds with Politzerization than in the adult. Hence Politzer's method as a means of diagnosis should be limited to children, and of course to those few adults in whom, owing to nasal obstruction, catheterization cannot be carried out. The diagnostic value of inflation lies in the comparison of the patency of the Eustachian tube and the effect produced, and has been so well summarized by Grant that I quote from him: "*Patency much diminished and improvement on inflation very considerable would indicate a narrowing (catarrhal) of the Eustachian tube without significant tympanic disease. Patency much diminished and improvement on inflation very moderate would indicate simultaneous affection of the tube and tympanum, in the more favorable exudative form of chronic catarrh of the middle ear. Patency normal and improvement on inflation little or none would indicate a primary affection of the tympanum, as in the obstinate dry or sclerotic form of chronic catarrh. Patency normal and hearing made worse by inflation would indicate a healthy middle ear and pure nerve-deafness. Immense improvement on inflation, followed by speedy or almost immediate return to the previous degree of dulness of hearing, is characteristic of relaxation of the membrane.*"

3. **The Eustachian Bougie.**—The third method of investigating the patency of the Eustachian tube is that by means of the *Eustachian bougie*. If an obstruction exists, the procedures already outlined will have demonstrated the fact, the diagnostic use of the bougie consisting in locating the seat and degree of such stenosis. My preference is for the flexible, probe-pointed celluloid bougies, which come in four sizes. The smaller sizes should always be tried first. Before introduction two marks should always be made, with ink or otherwise, on the end of the bougie toward the operator, one indicating when it is leaving the catheter to enter the tube, the other,  $1\frac{1}{4}$  inches farther back, indicating the point beyond which the bougie should not be introduced. The catheter having been fixed in the mouth of the tube, the bougie is passed rapidly down to the first mark, then very gently pushed farther, when, if it is entering the tube, the sensation conveyed to the finger becomes, after a little practice, easily recognizable, the patient having at the same time a sensation of sticking directly in the ear. If an obstruction is met requiring considerable force to overcome, the bougie must be withdrawn and a smaller one substituted. Stenoses are most frequent in the first inch (the cartilaginous portion), there being always moderate narrowing at the isthmus of the tube. Having thus located the stricture, and at the first attempt, or after repetitions gotten the bougie past it, air will be found to enter the tympanic cavity after its withdrawal much more freely than before. One precaution never to be forgotten is to examine the bougie carefully after withdrawing it, and, if the slightest trace of blood is found, *not to inflate*, thus avoiding the danger of emphysema. Another general precaution as to passing the bougie is that the whole operation must be performed with the utmost patience, gentleness, and caution, the patience extending, if necessary, to four or five sittings before the stricture is finally overcome.

|                          |  |                  |  |                  |  |                                                                                                          |  |        |  |       |  |
|--------------------------|--|------------------|--|------------------|--|----------------------------------------------------------------------------------------------------------|--|--------|--|-------|--|
| No. ....                 |  |                  |  |                  |  |                                                                                                          |  |        |  |       |  |
| Name .....               |  |                  |  |                  |  | Age .....                                                                                                |  |        |  |       |  |
| Address .....            |  |                  |  |                  |  | Date .....                                                                                               |  |        |  |       |  |
| Occupation .....         |  |                  |  |                  |  | Nativity .....                                                                                           |  |        |  |       |  |
| Diagnosis .....          |  |                  |  |                  |  |                                                                                                          |  |        |  |       |  |
| General Condition .....  |  |                  |  |                  |  |                                                                                                          |  |        |  |       |  |
| Previous Treatment ..... |  |                  |  |                  |  |                                                                                                          |  |        |  |       |  |
| A.S.                     |  |                  |  | A.D.             |  |                                                                                                          |  | RIGHT. |  | LEFT. |  |
|                          |  | Pres. Comp.      |  |                  |  | Ant. Rhinoscopy<br>Sept., Turb., Meatus<br>Post. Rhinoscopy<br>Naso-Pharynx.<br>Fauces<br>Tonsils-Uvula. |  |        |  |       |  |
|                          |  | Durat.           |  |                  |  |                                                                                                          |  |        |  |       |  |
|                          |  | Tinn.            |  |                  |  |                                                                                                          |  |        |  |       |  |
|                          |  | Pain             |  |                  |  |                                                                                                          |  |        |  |       |  |
|                          |  | Disch.           |  |                  |  |                                                                                                          |  |        |  |       |  |
|                          |  | Cause            |  |                  |  |                                                                                                          |  |        |  |       |  |
|                          |  | Course           |  |                  |  |                                                                                                          |  |        |  |       |  |
|                          |  | Hered-ity        |  |                  |  |                                                                                                          |  |        |  |       |  |
| Remarks:                 |  |                  |  |                  |  |                                                                                                          |  |        |  |       |  |
|                          |  | Peri-otic Region |  |                  |  | Mucous Membrane Generally .....<br><br>Treatment:                                                        |  |        |  |       |  |
|                          |  | Auricles         |  |                  |  |                                                                                                          |  |        |  |       |  |
|                          |  | Ext-Can.         |  |                  |  |                                                                                                          |  |        |  |       |  |
|                          |  | M.T. & Tymp      |  |                  |  |                                                                                                          |  |        |  |       |  |
|                          |  | Eust. Tube       |  |                  |  |                                                                                                          |  |        |  |       |  |
|                          |  | Before           |  |                  |  |                                                                                                          |  |        |  |       |  |
| Speech                   |  | Whisper          |  | Watch            |  |                                                                                                          |  |        |  |       |  |
|                          |  | T                |  | Watch            |  |                                                                                                          |  |        |  |       |  |
|                          |  | After            |  | Whisper          |  |                                                                                                          |  |        |  |       |  |
|                          |  | Rinne            |  |                  |  |                                                                                                          |  |        |  |       |  |
|                          |  | Before           |  |                  |  |                                                                                                          |  |        |  |       |  |
| C <sup>I</sup>           |  | C <sup>I</sup>   |  | C <sup>I</sup>   |  |                                                                                                          |  |        |  |       |  |
| C <sup>II</sup>          |  | C <sup>II</sup>  |  | C <sup>II</sup>  |  |                                                                                                          |  |        |  |       |  |
| C <sup>III</sup>         |  | C <sup>III</sup> |  | C <sup>III</sup> |  |                                                                                                          |  |        |  |       |  |
| C <sup>IV</sup>          |  | C <sup>IV</sup>  |  | C <sup>IV</sup>  |  |                                                                                                          |  |        |  |       |  |
|                          |  | T                |  | C <sup>I</sup>   |  |                                                                                                          |  |        |  |       |  |
|                          |  | After            |  | C <sup>II</sup>  |  |                                                                                                          |  |        |  |       |  |
|                          |  |                  |  | C <sup>III</sup> |  |                                                                                                          |  |        |  |       |  |
|                          |  |                  |  | C <sup>IV</sup>  |  |                                                                                                          |  |        |  |       |  |
| Notes.                   |  |                  |  |                  |  |                                                                                                          |  |        |  |       |  |
|                          |  | Pol.H.M. Galton  |  | Pol.H.M. Galton  |  |                                                                                                          |  |        |  |       |  |
|                          |  | Weber            |  | Weber            |  |                                                                                                          |  |        |  |       |  |

# THE GENERAL THERAPEUTICS OF EAR AFFECTIONS.

BY CLARENCE J. BLAKE, M. D.,

OF BOSTON, MASS.

THE therapeutics of disease in the ear, while conforming to that of surgical and medical practice in general, still presents certain points of difference which may be briefly noticed for practical purposes of reference.

In local medication departures from the general rules are necessitated by the peculiar structure of the external and middle ear, the comparative inaccessibility of the latter, its intimate relation to other important structures and cavities, and the necessity of choice made important by these conditions; while in general medication the internal administration of drugs, the selection and method of administration, have to be considered, not only in regard to the general therapeutic effect in which the ear may participate, but also with reference to the special effects which may be induced in the organ of hearing itself. In the local application for the treatment of eczema, for instance, while the rules to be observed are those which deal with the treatment of eczema in other parts of the body, attention must be paid to the fact that the external auditory canal is not only a passage which may be easily obstructed by the detritus of the skin mixed with a hard ointment, but that the lining of the canal itself is a skin which changes its characteristics from a thick hairy, glandular structure to a thin pavement epithelium within a shorter space than does the skin in any other part of the body. An example of general medication may be taken in that administration of pilocarpin which seeks to produce an effect in the limited area of the labyrinth at the expense of a very general constitutional disturbance.

Following the usual course of arrangement in treatises on diseases of the ear, and proceeding from without inward, the diseases of the external ear for which other than surgical treatment is demanded are anomalies of secretion, inflammations of the external ear and of the external auditory canal, eczema, herpes, lupus, and syphilitic inflammations.

The **anomalies of secretion** include, usually, the evidence of mechanical disturbance in the accumulation of the secreted mass, and a simple ceruminous plug mixed with particles of desquamated epithelium may sometimes require more than the use of warm water, which is usually its sufficient solvent, to effect its entire removal. Under these conditions the addition of sodium bicarbonate to the water used in syringing, or the previous instillation of some weak alkaline solution, properly warmed, or of a solution of potassium iodid in a mixture of equal parts of glycerin and water, will serve to facilitate the removal of the accumulation. In the cases of dense accumulations of epidermis where the ceruminous secretion serves only as a mask on the outer surface of the deeper-seated and more serious obstruction, or forms an unimportant element in the epithelial plug, it may be necessary, especially

if the plug has been so long retained as to have become at all lardaceous, by the use of such stronger alkalis, as solution of caustic potash, carried on a cotton-tipped probe into the center of the mass, for the purpose of forming with the fatty acids resulting from the lardaceous degeneration of the epithelium, a soap which can be easily washed away, to favor the breaking up of the epithelial mass and its removal piecemeal by syringing or the forceps. In all cases of the use of the caustic potash in this manner the skin of the external canal should be moistened with weak acetic acid to neutralize the effect of any excess of caustic potash which would otherwise irritate the skin.

In the **fluctuating hyperemias of the auricle**, which are often a great source of discomfort in neurotic subjects, there is demanded not only the local application of cold and mild astringent solutions, but also an attention to the general health which comes more distinctly within the domain of the general practitioner; while for the chronic hyperemia the application of astringent solutions and of cooling ointments may be further accompanied by galvanization of the sympathetic.

As **primary erysipelas of the auricle** is very rare, and as the implication of the skin of the auricle occurs usually in the course of an attack of erysipelas originating elsewhere, the general treatment is that indicated by the demand for antipyretics and antiphlogistics; and the local treatment may be limited to the application of cooling solutions, antiseptic or astringent, as, for instance, of oleates and powders, oxid of zinc, and starch—exception being taken to such as discolor the skin, and thereby interfere with local observation of the progress of the case.

In the treatment of **eczema** the different manifestations of this skin-disease must be considered, and these vary not only with the stage of the disease, but in the external auditory canal with the portion of the skin implicated. At the outer end of the canal, for instance, where the skin is thick and studded with cerumen and oil-glands, a very considerable edema sometimes marks that stage of the affection in which the skin of the inner portion may be bathed in a serous exudation or firmly encased in dried serum crusts. In the moist stage the surface should be carefully dried and powdered, either with simple rice-powder or rice-powder mixed with equal parts of powdered calomel; and in the cases of intertrigo in children, in addition a light gauze compress may be placed behind the auricle, in order to support it and prevent the apposition of the denuded surfaces of the posterior portion of the concha and mastoid region. Where crusts have formed as a result of the drying of the serum mingled with the desquamated epidermis, they should be removed only with care, and may require softening to effect this, which may be done with vaselin applied by means of the cotton-tipped probe or a camel's-hair brush. After removal of the crusts the exposed parts should be smeared with a diachylon ointment or with some astringent ointment having vaselin for its base, the auricle being protected at night by compresses soaked in ointment, and the external auditory canal carefully anointed in a similar manner by means of a cotton-tipped probe. In cases of obstinate exudation at the inner end of the canal pencilling with weak solutions of nitrate of silver are of service, and this application is also especially useful in the squamous stage. Internal treatment, except in so far as directions as to general hygiene and diet are concerned, is rarely demanded, except in children, in whom the administration of tonics, especially iron, the iodids, and arsenic are sometimes indicated.

**Herpes**, which is an exceedingly rare disease and which requires very little local attention, is accompanied by very severe pain, which may be sometimes



relieved by local application of solutions of cocaine, or, in default of the operation of the local remedy, by the internal administration of a narcotic.

In cases of **lupus**, in addition to, or sometimes as a substitute for, the surgical procedure of curetting, applications may be made of caustic potash, nitrate of silver, or of the thermocautery, the surfaces to be treated having been previously cocaineized.

The most common manifestations of **syphilis** in the external ear are those occurring in the form of condylomata and ulcerations of the external canal, which require, in addition to the general treatment, cauterization of the granulations with silver and dusting with calomel, the latter powder being especially useful in cases in which the granulations and ulcerations are accompanied by an eczema of other and adjoining portions of the skin.

In **furunculosis** of the external canal, in addition to the surgical treatment and the application of ear-baths, carbolized oil or oleate of morphia saturating a soft pledget of absorbent cotton, is of service. The possibility of infection from the micro-organisms which have been found in the boils should always be borne in mind; and where this is the case instillation of sublimate alcohol, of borated alcohol, and insufflation of boric acid should be resorted to in addition to the surgical treatment. After subsidence of the follicular inflammation the skin is very apt to be somewhat thickened, dry, and desquamating, and there is, as would be expected under these circumstances, often considerable itching, the attempt to relieve which by ordinary methods of scratching or rubbing often serves only to bring about a further infection of the skin and a repetition of the furunculosis. Under these conditions, the gentle application, on a cotton-tipped probe, of an ointment of salicylic acid and tincture of benzoin with vaselin, lightly smeared over the skin, is often of service; while other interference on the part of the patient than this should be limited to pressure upon the tragus or rubbing only of the external ear.

**Diffuse inflammation of the external canal** usually occurs as the result of injury or in the course of a follicular inflammation. The prognosis is speedily favorable, and treatment, in addition to instillation of warm antiseptic solutions and cold applications about the ear, may include the application of leeches in front of the auricle in the severe cases, or the more distinctly local phlebotomy of incisions into the skin of the canal itself.

The **plant-growth** most commonly found in the external auditory canal is the aspergillus, but in all cases of parasitic otitis externa the prognosis is good, as the plant-growth is speedily and effectually removed by frequent and judicious syringing, and, after drying of the ear, the instillation of alcohol and the insufflation of powdered boric acid.

In **acute inflammation of the middle ear** internal medication sometimes plays a very important part when it is made to include the attention which should be given to the general causative condition, as well as to the local manifestation in the ear.

In the acute congestion of the tympanum accompanying the closure of the Eustachian tube, incident to coryza in childhood, as well as in the congestions which occur in the course of the exanthemata, bromid of potassium or of sodium, given in small and repeated doses, is an important adjuvant to other treatment; while in more prolonged congestions of the lining membrane of the mastoid cells consequent upon acute otitis media in the adult, a small and continued dose of calomel has seemed to have a favorable effect.

So large is the supply of blood to the lining membrane of the tympanum and mastoid cells, and so subject is it to vaso-motor influences, that the

demand for relief in acute cases is one which sometimes requires medical as well as surgical interference; and, while the latter affords certainly the readiest and often the most efficient remedy, the fact that the intimate relationship of the middle ear through the circulatory and nervous systems with the general economy makes the influence to be exerted upon it by general medication a peculiarly favorable one. The experiment of Roosa and Hammond upon the effects of quinin internally, as shown by ocular observation of the blood-vessels in the tympanic membrane, is an illustration of the effect of a drug internally administered under actual observation of its ultimate effect; and similar observations upon the action of bromid of potassium in cases of artificially produced congestion of the middle ear show that while the larger doses, from 15 to 50 gr., according to the age of the patient, produce a more immediate effect in the lessening of the capillary circulation, the smaller and continuous doses, from 1 to 5 gr. every hour, have a cumulative effect in the same direction, which is desirable in the more protracted cases. In the simple, uncomplicated acute congestion of the middle ear in childhood, in addition to the administration of the bromids, there may be instilled into the painful ear, providing always that no perforation of the tympanic membrane exists, the solution of sulphate of atropin in equal parts of glycerin and water—the purpose of this mixture being to provide a fluid which shall not only retain heat, but shall furnish on the outside of the tympanic membrane a fluid of greater density than the serum, and one which, therefore, will favor exosmosis through the dermoid layer; while such absorption of the atropia as is possible under the conditions of blood-tension tends to allay pain. How far the relief experienced in the cases of acute earache in childhood on instillation of this solution of atropia, as recommended by Theobald, is due to the absorption of the atropia, and how much to the simple effect of a warm application, it is impossible to say; but the clinical observation of its use certainly commends it. Where there is much swelling of the nasal mucous membrane, with acute closure of the Eustachian tube, the intranasal injection of a few drops of a weak solution of cocain, by causing temporary subsidence of congestion and swelling, favors the opening of the Eustachian tube, the drainage of fluid from the middle ear, and makes inflation by means of the Politzer air-douche or catheter more easily possible. The treatment here indicated applies equally to those cases of implication of the middle ear in the acute stages of the exanthemata, but internal medication may be of service also in the aural sequelae of these diseases. In the persistent swelling of the tympanic mucous membrane which sometimes follows measles in young children, and which apparently lays the foundation for a permanent and progressive thickening of the mucous and submucous tissues of the middle ear in later life, the administration of the iodids, or, preferably of the syrup of hydriodic acid, is apparently of marked benefit: the administration of the latter drug may begin shortly after recovery from measles. It should be given in doses of a teaspoonful twice or thrice daily between meals, and in prescribing may be combined with one-fourth part of sherry wine or other alcoholic stimulant. The effect of the drug should be watched, and in the event of the appearance of an acute coryza or facial eruption its use should be suspended until these symptoms have disappeared; and, as a rule, better effects are obtained by giving it only two and three weeks at a time, with intervals of one and two weeks' abstinence. This same remedy has also been found useful in the cases of nasal and naso-pharyngeal catarrh which are apt to have an important and deleterious influence upon the middle ear; and even in adults

in cases of chronic catarrhal inflammation, with gradual thickening of the mucous membrane in the tympanum, the continued use of the syrup of hydriodic acid has seemed to be of service.

In cases of **acute perforation of the tympanic membrane** in very young children, as well as in the suppurative processes accompanying and following the acute exanthemata, more especially scarlet fever, local medication, which accompanies the process of cleansing, needs to be adapted to one or more of two or three conditions. In the serous discharge from the ear which in infants, mingling with the particles of desquamated epidermis in the canal and with light-colored cerumen, often, to superficial observation, simulates pus, syringing with a warm weak solution of the sulphocarbolate of zinc is more serviceable than the alkaline washes, because the congestion at the inner end of the canal incident to the congestion of the middle ear favors an exfoliation of the delicate epidermis, and renders a slightly astringent application acceptable. In cases of perforation, with distinct mucous or muco-purulent discharge from the ear, especially if the discharge has, as is not infrequently the case, a slightly acid reaction and an irritating effect upon the skin of the external canal, syringing with mild alkaline waters or with a weak solution of bicarbonate of soda has often a more serviceable effect than the use of astringent solutions or the insufflation of astringent and antiseptic powders. In this connection it may not be improper to express an opinion in regard to the forcible inflation of the middle ear by Politizerization in cases of acute suppurative inflammation of the middle ear with perforation of the tympanic membrane in very young children. This procedure, which is sometimes strongly advised, and which has for its purpose the passage of a column of air through the Eustachian tube into the middle ear and out through the opening in the tympanic membrane, carrying with it the accumulated products of the mucus-secreting glands, and of a suppurative process—while effective in its purpose in temporarily emptying a cavity of small capacity—subjects the structures of the middle ear to an indefinite degree of disturbance; and the cavity, moreover, if the secretion is copious, immediately refills. Where the perforation in the tympanic membrane is sufficient to permit a free egress to secretions from within, the outflow of fluid will correspond in degree to the degree of its production; and the complete emptying of the cavity, therefore, has for its purpose the opportunity afforded for the intratympanic instillation of medicated solutions which may have a favorable and deterrent effect upon the freely secreting lining of the middle ear. The attempt to effect both these purposes, as proposed by Van Millingen, in syringing through the Eustachian tube into the middle ear, with exit for the fluid through a perforation in the tympanic membrane, was found to result in a degree of violence to the affected parts entirely inconsistent with their delicacy of structure. In the acute suppurative process in the middle ear, both in children and in adults, it being had in mind that congestion and edematous infiltration are prominent conditions of the early stages, it stands to reason that palliative measures, both local and general, are first in order. Locally, these may include, in addition to the direct surgical phlebotomy, the instillation into the ear of mild alkaline and antiseptic solutions, the application of dry warmth or, in cases of early mastoid congestion with pain and rise of temperature, the application of cold to that region either by means of compresses, the ice-bag, or the Leiter coil, with internal administration of the bromids, of opiates, if necessary, of saline laxatives (upon the value of which much stress is laid by the early English authorities), and the observance of a light,



non-stimulating diet. In these cases in the adult also the freeing of the bowels, followed by the continuous administration of a mild laxative like calomel, is apparently a useful adjuvant to other treatment. The use of calomel in the small and continued dose in cases of localized inflammation was suggested by the late Dr. E. H. Clarke, whose administration of this drug was based upon long experience at a time when a much higher value was put upon its effect than at present obtains.

In **chronic suppurative disease of the middle ear**, in addition to the ordinary cleansing process for the removal of the discharge both from the external and middle ear, and the use of the alkaline solutions for that purpose, as already indicated in the more acute cases, it is sometimes necessary to apply astringent solutions or powders for the purpose of acting upon the inflamed or ulcerated surfaces of the mucous membrane of the middle ear or the dermoid lining at the inner end of the external auditory canal, or to act as a deterrent to the undue formation of granulatata. In all cases, after the cleansing has been effected either by the ordinary syringe or the middle-ear syringe, the surfaces to be medicated should be dried as thoroughly as possible by means of a cotton-tipped probe or by pledgets of absorbent cotton; and in old cases of chronic suppurative disease, especially where the epitympanic space has become involved or where there are evidences of caries of the bony wall of that cavity or of the ossicles, the drying process should be made the occasion for a careful examination of the parts with a view to more direct local application of astringents, acids, or other escharotics.

In the **simple uncomplicated chronic suppurative disease**, after cleansing and drying, insufflation, with or without packing, of antiseptic powders, preferably boric acid, acetanilid, or a combination of the two, may suffice as treatment; although the instillation of a saturated solution of boric acid in alcohol or of alcohol alone diluted with water to a point at which it can be easily borne in the ear, will serve to shrink the smaller granulatata, which, springing from ulcerated surfaces, both tend to increase the volume of purulent discharge and sometimes, by their unfavorable position to block its exit. Further and localized applications to the granulations or polypi may be made by use of a saturated solution of nitrate of silver on a cotton-tipped probe, or of such astringents as muriated tincture of iron, ferric alum, or, in the case of firmer polypi, of escharotics; while weak sulphuric acid, the contiguous surfaces being guarded by moistening them with a weak alkaline solution, may sometimes be employed as an application to carious bone and as a substitute for the use of the curette.

In cases of **chronic non-suppurative disease of the middle ear** local medication, except such as is limited to applications through the Eustachian tube, is of comparatively little service, unless we may include under this head the mechanical operations which affect the circulation in the tympanic membrane and the middle ear, such as the use of the Politzer method of an air-tight seal at the outer end of the external auditory canal, absorption of the enclosed air by the dermoid lining of the canal producing a partial vacuum. This not only results in a preponderating atmospheric pressure on the inner surface of the drumhead, but also in an increase of the capillary circulation of the lining, not only of the external canal, but also in a lesser degree of that of the middle ear. The various processes of massage, having for their purpose an increase in the mobility of the drumhead and other portions of the sound-transmitting apparatus, tend also by increasing the circulation in these parts to stimulate the absorbent glands, and so favor a decrease



of the thickening already existing in the mucous and submucous tissues of the middle ear.

In the course of a **progressive non-suppurative middle-ear disease**, however, general medication and attention to general hygiene sometimes play an important part, since the effects of faulty nutrition which result from general overtire and nervous overstrain, increased still further by the fatigue incident to a considerable degree of deafness, interfere with the nutrition of the more delicate structures of the body, and so favor trophic changes which are evidenced in the ear by still further impairment of hearing. The circulatory tinnitus, which accompanies many cases of chronic progressive middle-ear disease, often becomes an important factor in the general nervous condition of the patient; and remedies tending to decrease the cerebral circulation or to lessen the sensibility of the nervous system are often of important temporary benefit. This is especially the case where the neurasthenic condition makes both the impaired hearing for sounds aërially conveyed, and the correspondingly increased hearing of the cerebral and intra-aural circulation a matter of grave annoyance and sometimes of detriment. While they need not be specified here, the measures applicable to the treatment of abnormal conditions in the nose and naso-pharynx are very important considerations as a part of the treatment of the aural disease.

In **diseases of the internal ear** where local medication is out of the question, and dependence for an effect upon this portion of the organs of hearing and of equilibration must be placed upon such drugs, internally administered, as materially affect the circulation in these parts, the range of remedies at our disposal is necessarily limited—aside from those which may be employed in improving the general hygienic condition of the patient. One decided exception must be made in those cases of syphilitic disease of the labyrinth where, in the event either of an affection of the cochlea with impairment of hearing, or of the semicircular canals with disturbance of equilibrium, prompt administration of the iodids and mercurials sometimes has a markedly favorable effect: as has been shown by Politzer and other observers, the use of muriate of pilocarpin in these cases is also especially serviceable. In the non-specific cases of high grades of deafness and vertigo the drug must often be administered for a longer time and in larger doses than in the specific cases; and Dr. Gorham Bacon cites a case of a high degree of deafness, with vertigo, following a chronic suppurative disease of the middle ear in a man of middle age, in whom the daily administration of this drug in gradually increasing doses up to three-quarters of a grain finally resulted in a marked improvement in hearing and in stability. In simple congestion of the labyrinth, remedies which serve to decrease the cerebral and also the intralabyrinthine circulation, such as the bromids and ergot, and in cases of anemia, tonics and stimulants are indicated; while in cases of auditory vertigo, with occasional sharper vertiginous attacks, consequent upon sudden suspension of vaso-motor inhibition, the sulphate of quinin, given in the small and continued dose, is often of value in equalizing the circulation.

# AFFECTIONS OF THE EXTERNAL EAR.

By SAMUEL THEOBALD, M. D.,  
OF BALTIMORE, MD.

DISEASES of the external ear—that is to say, of the auricle and external auditory canal—constitute about 26 per cent. of the total of affections of the auditory apparatus as met with in hospital practice;<sup>1</sup> diseases of the auricle are of comparatively infrequent occurrence, and make up but 2 per cent. of the total; while affections of the auditory canal are common and constitute about 24 per cent.

## AFFECTIONS OF THE AURICLE.

**Congenital Malformations.**—Many minor congenital defects of the auricle have been described, such as anomalies of the helix, the antihelix, the lobule, the tragus, etc., but they are not of sufficient importance to demand here especial consideration. The major defects, such as microtia and polyotia, have frequently associated with them anomalous conditions of the auditory canal (atresia, etc.), and even of the middle and internal ear. They may be unilateral or bilateral, and are said to be due to incomplete closure of the two upper branchial clefts, insufficient turning up of the auricle during its development, etc.

**Microtia.**—In pronounced cases of this defect the auricle is so misshapen and rudimentary as to present scarcely any resemblance to the normal ear, and in some instances the deformity involves the face as well as the ear. The condition is well shown in the accompanying illustration (Fig. 481), for which, as well as for a number of other illustrations in this article, I am indebted to Dr. Randall. The changes of form are manifold and at times fantastic. Knapp, for example, has met with cases in which the rudimentary auricle was hook-shaped or spirally curved, and other cases have been reported by Moos and Steinbrügge in which it resembled a cauliflower exerescence.



FIG. 481.—Microtia: puckered helix, isolated tragus, and imperforate meatus.

<sup>1</sup> Based upon analyses of 19,568 cases—9670 observed at the Newark Eye and Ear Infirmary, 4486 at the Baltimore Eye, Ear, and Throat Charity Hospital, and 5412 tabulated by Dr. Randall, from his practice. At the Newark Infirmary diseases of the external ear comprised 30 per cent. of the total; at the Baltimore Eye, Ear, and Throat Hospital, not quite 28 per cent.; and of Dr. Randall's cases, 17½ per cent. Diseases of the auricle constituted not quite 1½ per cent. of the total at the first-named institution, slightly more than 3 per cent. at the second, and a little over 1½ per cent. of the cases tabulated by Dr. Randall.

**Polyotia.**—This term is applied not only to cases in which two or more auricles exist upon the same side, but also to cases of microtia which are accompanied by multiple growths in the immediate neighborhood of the auricle, but distinct from it. The most common form is that of a wart-like excrescence or more complex “auricular appendage” situated upon the cheek

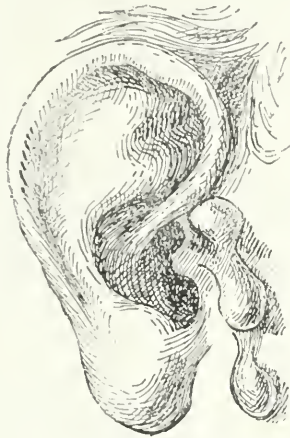


FIG. 482.—Polyotic growth present bilaterally in a woman of 22.

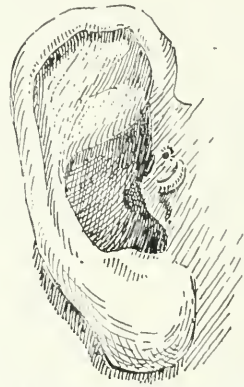


FIG. 483.—Horn-like auricular appendage with congenital aural fistula.

in front of the external meatus (Figs. 482 and 483). These multiple growths, in exceptional instances, are found associated with a normal auricle.

Cartilaginous outgrowths from the auricle, known as *auricular appendages*, are occasionally met with, their most frequent location being upon the tragus (Fig. 483).

**Congenital fissure or cleft of the lobule** has been observed, and is said by Politzer to be “quite common,”<sup>1</sup> a statement which, as to this part of the world at least, hardly holds good. A variety of *congenital fistula*, usually located just above the tragus (Fig. 483), and said by Burnett to connect in some instances with the tympanic cavity, is an anomaly of not very infrequent occurrence. Dench describes a case which presented an opening about one-sixth of an inch in diameter, into which a probe could be passed to the depth of half an inch.<sup>2</sup> Retention-cysts have been known to develop in them, and they may be the seat of purulent inflammation. The depth is usually slight and the direction downward and forward.

The writer has met with an instance of marked congenital difference in the conformation of the right and left auricles, one being larger and more prominent than the other, in which the defect was transmitted, although in a less noticeable degree, to the children and grandchildren—an appreciable difference in the auricles being observable in four out of six children and in several grandchildren.

As to the treatment of congenital anomalies of the auricle there is not much to be said. Auricular appendages, supernumerary auricles, and multiple growths about the ear may be readily removed, and cleft of the lobe may be satisfactorily dealt with by operation; but attempts to remedy by operative procedure, plastic or otherwise, the more grave defect of microtia have been attended by very unsatisfactory results, and in high degrees of

<sup>1</sup> *Diseases of the Ear*, Eng. trans., Philada., 1894, p. 698.

<sup>2</sup> *Diseases of the Ear*, New York, 1895, p. 179.

this deformity removal of the rudimentary auricle and the substitution of an artificial ear are recommended. Congenital aural fistula does not require treatment unless it be the seat of inflammatory or other changes. Undue prominence of the auricle, if seen in infancy, may be corrected in great measure by any simple device which will keep the ear constantly in close apposition with the side of the head. Glueing the auricle to the head with collodion has been recommended. In adults such procedures are ineffectual, and the operation described on page 783 is called for.

**Eczema of the Auricle.**—This is a condition of frequent occurrence, especially in ill-nourished, strumous children. It often exists in association with phlyctenular ophthalmia, and under such circumstances may be accompanied by suppurative middle-ear inflammation. In adults the auditory canal is usually involved in the inflammatory process, and the disease, which is frequently dependent upon a gouty diathesis, is less amenable to treatment than it is in children. In bad cases the whole auricle, and the neighboring portions of the scalp as well, may be affected, but oftener the inflammation is limited to the line of juncture of the auricle with the head, to the concha, and to the fossa helix.

The treatment should be directed to the general condition of the patient as well as to the local affection. In adults the probable existence of lithemia should be borne in mind, and the patient's diet and his bowels should be regulated, and the remedies usually employed to combat this condition should be prescribed. In children a brisk calomel cathartic is often indicated, to be followed by the administration of the elixir or the syrup of the phosphates of iron, quinin, and strychnin—a much more efficacious remedy, in the writer's experience, than the more frequently prescribed syrup of the iodid of iron. The most useful local remedies are the oxid of zinc with boric acid and the yellow oxid of mercury. The latter should be used in the form of an ointment (gr. ij to  $\bar{5}$ j), and the former either as an ointment (1 drachm of powdered boric acid being added to an ounce of the officinal oxid-of-zinc ointment) or as a powder (equal parts, by weight, of boric acid and oxid of zinc), to be dusted upon the auricle, and, when indicated, blown lightly into the auditory canal. When scabs are present they should be removed by maceration as a measure preliminary to other treatment. Painting the affected part with a solution of nitrate of silver (gr. x-xxx to  $\bar{5}$ j) is a remedy which is at times of value, especially in the moist conditions, and subnitrate of bismuth (in ointment or powder), oil of eade, salicylic acid, aristol, and the different preparations of lead are remedies which may be tried should those first named fail to effect a cure. A tendency to relapse is characteristic of the disease: too early discontinuance of the treatment, therefore, is to be avoided.

**Herpes zoster** of the auricle is a rare condition, but cases have been reported by J. Orne Green, C. H. Burnett, Anstie, Auspitz, Gruber, and others.

**Erysipelas** of the auricle is occasionally encountered, usually as an extension of facial erysipelas. The indications for treatment are the same as when these affections occur in other regions of the body, and there is nothing in their clinical course worthy of especial note.

**Abscess** of the auricle, especially of the lobule, where it is often the result of piercing the ear, and where, particularly in the colored race, it may become cystic, is of rather common occurrence. It is also a usual accompaniment of perichondritis (Fig. 484).

The treatment consists in free incision, which in the cystic cases may



require to be supplemented by curetting or, better still, by cauterizing the cyst-wall with a bead of nitrate of silver fused upon the tip of a probe.

**Perichondritis of the Auricle.**—This condition is commonly of traumatic origin, but may be due to the extension of inflammation from the auditory canal, while occasionally it occurs without evident cause. The idiopathic cases are usually met with in persons who are in a poor state of health and in whom there is general malnutrition. Its starting-point under such circumstances is probably in certain degenerative changes in the cartilage, which have been described by Ludwig Meyer and others, and to which the name chondromalacia has been given (Buck). The traumatic cases usually owe their origin to blows, or may arise from exposure of the auricle to extremes of heat or cold (as in frost-bite). The symptoms are a burning sensation in the ear, followed by severe pain, which is accompanied by swelling and marked injection of the auricle. The swelling, which

may increase until the normal configuration of the auricle is completely obliterated, is due to an effusion of fluid—usually serous at the outset, but tending quickly to become purulent—beneath the perichondrium. The ear feels hot, and is often very sensitive to the touch. Left to itself, the fluid tends to escape spontaneously, but may be slowly absorbed. A high degree of deformity of the auricle is a frequent consequence of uncontrolled perichondritis (Fig. 485).

An effusion of blood, more or less extensive, between the perichondrium and the cartilage (*hematoma auris*; *othematoma*) (Fig. 486) is a not infre-

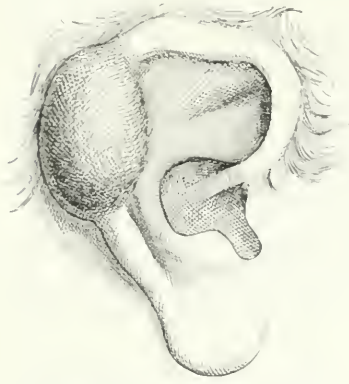

FIG. 484.—Abscess of margin of helix; sequel of hematoma in pertussis.

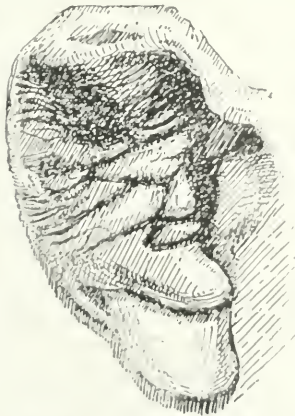

FIG. 485.—Deformity after perichondritis (Pomeroÿ).

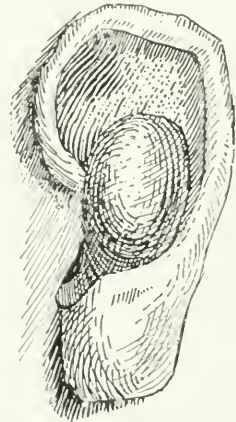


FIG. 486.—Hematoma of auricle filling the concha.

quent accompaniment of perichondritis, usually preceding the onset of the inflammatory process in traumatic cases (being a direct consequence of the injury), and following closely or accompanying it in non-traumatic cases. The etiology and pathology of this condition have been widely studied,

especial interest attaching to the subject because of the frequent occurrence of tumors of this character in the insane. Some investigators have attempted to explain this association upon the theory that hematoma auris is usually of traumatic origin, and that the insane are especially liable to injuries such as might give rise to it, either self-inflicted or received through efforts to control them. Others maintain that the lesion is more directly connected with the insanity of the subject, and that it is dependent upon the pathological condition of the brain; while Virchow, Ludwig Meyer, Pollak, and others contend—and apparently with greater justification, since their views are based upon more exact pathological study—that it has its origin in degenerative changes found in the cartilage of the auricle, not only in the insane, but in other ill-nourished individuals as well—changes which they point out are accompanied by the development in the neighboring tissue of capillary vessels of unusually large size and having very thin walls. With such conditions as these existing, it can be readily understood how hemorrhage might result from the most trivial violence to the auricle or even without such provocation.<sup>1</sup>

**Treatment.**—If seen at an early stage, the application of cold in the form of the aural ice-bag may be productive of good results in acute perichondritis. If, in spite of this measure, the effusion beneath the perichondrium increases, aspiration may be resorted to under strict antiseptic precautions, to be followed by the application of firm pressure upon the auricle, to prevent if possible—what is very apt to occur—a re-effusion of fluid into the aspirated cavity. Should the fluid reaccumulate after, perhaps, a repetition of the aspiration, or should suppuration supervene, the sac must be laid open by a free incision and packed with iodoform gauze. Should necrosis of the cartilage have occurred, the necrotic parts must be thoroughly removed by curetting. The application of tincture of iodin to the cyst-like walls of the cavity may be called for to promote its obliteration. Massage is useful after healing has taken place or to bring about the absorption of inflammatory products when incision has not been resorted to; and the external application of iodin is also of value under similar circumstances.

In hematoma compression and massage may be tried if the tumor be small. If it be of considerable size, aspiration, followed by compression, may be employed, or the sac may be freely opened and dealt with as a perichondritis unaccompanied by extravasation of blood. Tonics and a change of diet are usually indicated. The likelihood of considerable deformity of the auricle resulting, even when the case has been judiciously treated, should not be lost sight of, and should be impressed upon the patient.

**Syphilis of the Auricle.**—The primary lesion of syphilis, as might be supposed, is rarely located upon the auricle, yet cases of this character have been reported by Pellizzari, Zucker, Hermet, and others, the cause of the infection being usually a bite by a syphilitic individual. The eruptions of secondary syphilis are frequently observed upon the auricle, accompanying similar eruptions upon the face and scalp. Gummata and syphilitic ulcerations are rare, but cases have been observed by Buck, Burnett, and Politzer.

The indications for treatment are simply those which apply to syphilis affecting other portions of the body.

**Lupus.**—In lupus vulgaris of the face the auricle is frequently involved, but cases in which this disease originates in or is confined to the auricle are extremely rare. The auricle may be affected in any of the various types of

<sup>1</sup> For a fuller consideration of this subject see *Manual of Diseases of the Ear*, by Dr. Albert H. Buck, p. 56 *et seq.*, New York, 1895.

lupus. In the ulcerative forms of the disease it may be partially or even totally destroyed, and the auditory canal and middle ear may be invaded.

**Treatment.**—In removing the diseased tissue with the curette, the galvano-cautery, or with caustics, care should be exercised not to sacrifice healthy structures, otherwise marked deformity of the auricle will ensue. To prevent involvement of the auditory canal and deeper structures of the ear, complete removal of the auricle may at times be required.

**Frost-bite.**—In cold climates frost-bite of the auricle is of common occurrence, and even actual freezing of the ear may take place. Under such circumstances the auricle may become fragile, and must, therefore, be manipulated with care.

In the **treatment** of this condition, to prevent too sudden reaction, it is advised that the ear should be “thawed out” gradually by the application of snow, pounded ice, or cold water, the individual being kept for a time in a cold room or even out of doors. Subsequently the case must be treated much as one would treat a burn—by the application of an emollient, such as linseed oil and lime-water or vaselin. Perichondritis, with more or less extensive necrosis of the cartilage, may result from prolonged exposure of the auricle to cold.

**New Growths of the Auricle.**—The auricle is occasionally the seat of malignant as well as of benign tumors. The most frequently met tumor of the auricle is fibroma or keloid. It is usually located in the lobule, and owes its origin almost always to the operation of piercing the ear or to the irritation accompanying the wearing of an ear-ring. It is of especially frequent occurrence in the negro race (Fig. 487), and is said to exhibit a decided

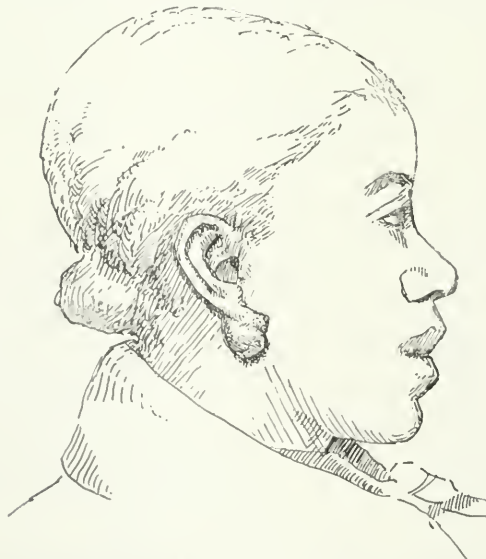

FIG. 487.—Fibroma (keloid) of lobule (bilateral) in a negro girl after piercing for ear-rings.

tendency to recur after removal, although the writer's experience with such growths—not very extended, it is true—would not lead him to endorse this view. The tumor is quite firm and the surface is usually nodular. Both ears are not infrequently affected, the exciting cause in each instance being the same.

Other benign growths which have been observed are *lipoma*, *angioma*, *papilloma*, and *sebaceous cyst* (see Fig. 462).



**Horny Growths** springing from the auricle have been encountered by Buck, Burnett, Pomeroy, Roosa, and others. In a case reported by Buck the growth, which was attached to the upper and posterior portion of the helix, is described as "a blunted, horn-like protuberance,  $\frac{3}{4}$  inch long and nearly as broad at its base." The writer has never met with a growth of this character upon the ear, but several years since saw a precisely similar growth upon the upper eyelid near its free margin. It was somewhat curved, nearly  $1\frac{1}{4}$  inches in length, and was said to have been only two months in forming. Like the growth observed by Dr. Buck, it was longitudinally striated.

Of malignant growths, **epithelioma** (Fig. 488) is the one which has been oftenest met with, cases having been reported by Gruber, Wilde, Kramer, Toynbee, Demarquay, J. Orne Green, Brunner, Burnett, Roosa, Buck, and others. More rarely sarcoma of the auricle has been observed. Malignant growths of the auricle tend to invade the auditory canal and middle ear, and death may be brought about in this way.

**Treatment.**—In malignant tumors of the auricle early operative interference is of course indicated, and complete removal of the auricle may be called for. Lipomata, angiomata, sebaceous cysts, etc. should be dealt with as when they occur elsewhere. Fibromata of the lobule, even when of considerable size, may be readily removed, and with little resulting deformity, by an approximately (inverted) V-shaped incision carried through the whole thickness of the lobe.

**Wounds of the Auricle.**—Lacerated and incised wounds of the auricle are occasionally met with, and exceptionally the whole auricle may be torn or even bitten off. The writer's grandfather, the late Prof. Nathan R. Smith, of Baltimore, once had a singular experience of this latter kind. A man, carrying an ear in his hand, rushed excitedly into the office, exclaiming that one of his ears had been bitten off in a fight, and that he wished it replaced. A few moments later another equally excited individual, with an auricle missing and carrying an ear in *his* hand, made his appearance, and loudly protested that the first man had taken the wrong ear and that he had brought the one which belonged to him. In the modern game of football, as in the German duel, injuries of the auricle are of such frequent occurrence that special contrivances for protecting the ear are worn.

**Treatment.**—When parts of the ear are cut cleanly off (as happens in the duels at the German universities), they may be replaced with every prospect that union of the divided surfaces will occur, and even when the entire auricle is cut or torn off an effort should be made to replace it, as reunion has occurred under such circumstances.<sup>1</sup> In closing wounds of the auricle or in

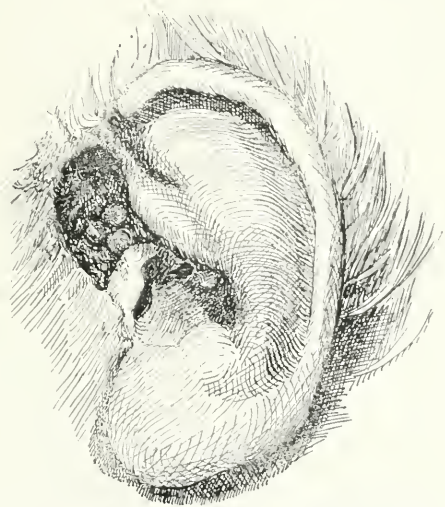

FIG. 488.—Epithelioma of auricle of 20 years' standing, with cicatricial contractions.

<sup>1</sup> Von Trötsch states that "in India, where, as is well known, the ears are sometimes cut off in war and as a punishment for crime, they are said to be sometimes replaced by transplantation from a living person" (*Diseases of the Ear*, New York, 1869, p. 51).



reattaching severed parts stitches should be used as sparingly as possible, and should never penetrate the cartilage. Collodion, reinforced by bits of crêpe-lisse or of lint, will usually suffice to maintain the parts in apposition. Aseptic precautions are of course essential, but strong antiseptic agents should be avoided.

**Cleft of the Lobule.**—This condition is of frequent occurrence, and is almost always due to that relic of barbarism, the wearing of ear-rings. Occasionally it results simply from a heavy ear-ring gradually wearing its way through the lobe, but more often it is produced by the ear-ring being accidentally or intentionally torn from the ear. The writer has seen instances—and many such have been reported—where the lobe had been cleft in this way several times, and was represented by three or four teat-like projections. The deformity, even from a single cleft, is considerable, and it not infrequently happens that the aural surgeon is applied to to remedy it.

The treatment is by operation (see page 782).

#### AFFECTIONS OF THE EXTERNAL AUDITORY CANAL.

**Congenital Malformations.**—Congenital atresia of the external auditory canal has been mentioned as an occasional accompaniment of microtia and polyotia (see Fig. 481). Cases have been observed in which this defect existed without accompanying malformation of the auricle, but they are comparatively rare. The atresia may involve a part or the whole length of the canal, and may be of osseous or membranous character. A shallow depression or a somewhat deeper cul-de-sac, reaching perhaps to the point at which the bony meatus should normally begin, exists in some instances, while in others no trace of the meatus is to be found. Politzer mentions having dissected a case of atresia of the auditory canal associated with microtia in which the osseous and membranous labyrinth were perfectly formed, but in which the external meatus was represented by a fibrous cord 1 cm. long, and the tympanic cavity was entirely absent.<sup>1</sup> Cases of congenital narrowing of the auditory canal, and also of hour-glass contraction of the canal (Wilde), have been observed.

Even with complete bony occlusion of the auditory meatus the hearing may be fairly good if the deeper parts of the ear are normal. The writer has reported a case of complete osseous occlusion of both auditory canals (not, however, of congenital origin), in which the patient could carry on a conversation very satisfactorily if spoken to in a slightly raised tone of voice.<sup>2</sup> In a case of congenital occlusion of both auditory canals with microtia<sup>3</sup> the patient could distinguish words spoken in a low voice at a distance of six feet, even with the eyes, nose, and mouth tightly closed, as can almost every one with normal ears slightly stopped by the fingers.

**Treatment.**—In congenital atresia of the auditory canal it seldom happens that anything can be done to ameliorate the patient's condition, which, however, as has been indicated, is not usually as unfortunate as might be supposed. If the atresia be limited in extent, involving but a small part of the canal (which is not often the case), whether it be osseous or membranous, an effort may be made to overcome it by suitable cutting or boring instruments; but if it be more extensive, experience has shown that operative interference is of no avail, since the atresia invariably recurs. Possibly, skin-grafting by Thiersch's method might under such circumstances render the chances of

<sup>1</sup> *Diseases of the Ear*, p. 698.

<sup>2</sup> *Trans. Amer. Otol. Soc.*, vol. iii. p. 45.

<sup>3</sup> Reported by Dr. W. H. Robb in the *Amer. Journ. of Otol.*, vol. iii. p. 278.

success somewhat better. When there is simply congenital narrowing of the canal, especially if it be circumscribed, much may be accomplished in time by having the patient wear continually in the meatus an elastic plug of absorbent cotton, sponge, or some similar material.

As much rarer congenital anomalies *unduly capacious auditory canals* are met with, and also *a doubling of the canal*. Sometimes there is a second canal, terminating in a cul-de-sac, behind the true canal and having no connection with it, as in the cases observed by Velpeau and Macaulin; and again, as in Bernard's case, there may be two separate canals, which after a short course unite to form a common canal.<sup>1</sup>

**Impacted Cerumen.**—Occlusion of the auditory canal by a mass of inspissated cerumen is the affection of the external ear which most frequently demands the attention of the aurist. Usually the patient is entirely unconscious of the presence of the mass until the canal is completely occluded by it. Then the hearing, which before had not been appreciably diminished, although the ceruminous plug may have all but filled the lumen of the canal, becomes at once greatly impaired, autophony manifests itself, and very frequently tinnitus makes its appearance to add to the discomfort and alarm of the patient. Although the mass develops very slowly, many months usually elapsing before it becomes inconveniently large, the symptoms just enumerated generally manifest themselves suddenly. The usual explanation of this is that water has run into the ear in washing or bathing, or in warm weather perspiration has found its way into it and has caused the plug, which previously had nearly filled the canal, to swell up sufficiently to make the occlusion complete. Occasionally it is a fluid which the individual has intentionally dropped into the ear or some manipulation on his part of the ceruminous mass, which brings about the sudden change. Exceptionally the same symptoms may result, accompanied, perhaps, by pain, from a smaller mass of wax (which left undisturbed might not have caused inconvenience for a long time) being dislodged and pushed down upon the drumhead by the efforts of the patient to remove it. Again, when the plug is very hard and occupies the outer portion of the meatus, it may, through the movements of the jaw, exert sufficient pressure upon the canal-walls to cause pain, and perhaps inflammation, before it has become so large as to interfere with audition.

The plug varies greatly in consistency and in solubility, and frequently contains innumerable short, pale hairs (from the walls of the canal). Very often it is in part made up of pieces of exfoliated epidermis, and exceptionally it has as a nucleus some small foreign body which has found its way into the ear, or an old scab left by a former otitis. More frequently than not both ears are involved, so both should invariably be examined.

Among the rarer symptoms produced by the presence of impacted cerumen in the ear may be mentioned dizziness, reflex cough, perturbation of the mental faculties with inability to concentrate the mind in intellectual pursuits, disturbances of gait simulating those of locomotor ataxia (Risley), epileptiform convulsions, and, in a case reported by the writer,<sup>2</sup> inability to swallow, accompanied by a feeling of oppression about the heart. The added danger which results in otitis media from a pre-existent occlusion of the meatus by impacted cerumen should also not be lost sight of.

With good illumination it is usually a very easy matter to detect the presence of a ceruminous plug in the auditory canal. It is seen as a dark-brown mass filling the lumen of the canal, and with its outer surface situated usually at about the line of juncture of the osseous and membranous portions

<sup>1</sup> Politzer: *Diseases of the Ear*, p. 698.

<sup>2</sup> *Trans. Amer. Otolog. Soc.*, vol. v. p. 508.

of the meatus. Touched with a probe, it may appear quite hard, or may be soft and easily indented. Generally the inner extremity of the mass reaches to, and rests upon, the tympanic membrane.

The etiology of this affection has received considerable attention, and, while it cannot be claimed that it is as yet fully understood, there is a general agreement at least as to two points: in the first place, that, probably through reflex influence, the ceruminous glands are frequently abnormally active in the presence of chronic inflammatory affections of the naso-pharynx; in the second place, that under such circumstances and often perhaps independently of such conditions, there is a disturbance of the normal outgrowth of the epidermis which covers the external surface of the drumhead and lines the walls of the meatus. This in health tends to transport the cerumen from the deeper portions of the canal to its external orifice, where it falls out or is removed in the ordinary daily ablutions. That catarrh of the naso-pharynx is frequently present when there is a disposition to the formation of ceruminous plugs in the ears is a fact of daily observation, and there can be little doubt that it is an important factor in their causation. And the composition of many masses of impacted cerumen—made up, in great part, of layers of exfoliated epidermis, and sometimes enclosed in a thin pouch of epidermis which has been cast off entirely from the tympanic membrane and the walls of the meatus—would seem to show that under certain circumstances there is not only an arrest of the normal outgrowth of the epidermis, but an actual reversal in the direction of its growth, tending to a heaping up of epithelial debris in the deeper parts of the canal, as well as to an impaction of cerumen.

**Treatment.**—It would seem that as to the manner of dealing with so simple a condition there could be but little room for difference of opinion, still less for contention. Such, however, is far from being the case, for one very high authority tells us in his excellent treatise upon diseases of the ear that the syringe should rarely be used for the removal of cerumen, and that with the curette and the angular forceps one may accomplish in ten or fifteen minutes what cannot be done with the syringe in an hour's time; while another excellent authority tells us in his book that in four or five years he has not met with a single instance in which by means of the syringe he has failed to remove impacted cerumen from the ear in one sitting of five minutes or less, and that as to the euretting method he feels that he cannot seriously argue the question. At the risk of seeming to be contentious himself, the writer cannot refrain from saying that this last expressed sentiment meets with his fullest endorsement. But still another very high authority, whose example in most things we are glad to follow, actually commends the introduction of a strong solution of caustic potash into the ear (of course with the exercise of extreme caution) in order to saponify quickly the ceruminous mass and so to facilitate its removal. As to this procedure, it may be remarked that in kindling, and especially in rekindling a fire, petroleum is a great saver of time; but, even so, it is not the part of wisdom to commend its general use in this way.

The method of dealing with impacted cerumen which the writer has found most convenient, and which he has employed for many years, is as follows: In the great majority of cases the syringe is chiefly relied upon. When, however, the ceruminous mass proves obdurate and does not easily undergo disintegration, the angular probe or the instrument for the removal of foreign bodies represented in Fig. 490 is brought into requisition and the mass is partly broken up or separated from its attachment to the canal-wall.



After this the syringing is resumed, and usually with much better effect. Bicarbonate of soda is invariably added to the warm water (105°–110° F.) with which the syringing is done, as it unquestionably facilitates the removal of the wax and certainly does no harm to the syringe, as has been suggested. The quantity used is never accurately determined, but is approximately half an ounce to a quart. The ear is inspected from time to time to make sure that there is still cerumen in it, and that the syringing is not being kept up unnecessarily. As the mass diminishes in size and there is a likelihood that the stream of water may impinge upon the drumhead, the force with which it is thrown into the ear is lessened. The exact direction in which the stream strikes the impacted mass is not thought to be of especial moment, and no apprehension is felt that this may result in the plug being driven by the force of the water more deeply into the meatus, as some have imagined. When both ears are affected, unless the mass first attacked comes out very readily, the syringing is alternated from one ear to the other, as this saves time and appreciably diminishes the amount of syringing required. The intermittent stream of a piston syringe is employed, and is thought to be more efficacious than the continuous stream of a fountain syringe. The hard-rubber, kidney-shaped basin commonly employed by aurists has been long since discarded, because it is concave where it should be convex, and so does not fit well into the hollow beneath the ear, and because, moreover, it is so long and shallow that a very slight movement on the part of the patient is likely to cause its contents to slop over upon the clothing. Instead of this, a china bowl (one made of hard rubber or metal might be better, because less fragile) of the shape represented in Fig. 489 is used, and has been found much better adapted to the purpose, since it is free from both of the faults mentioned. It is always held by the patient, over whose shoulder a napkin is spread, rather than by an assistant, unless the patient be a young child. When inspection with the speculum and mirror shows that all of the cerumen has been removed, two or three syringe-fuls of plain warm water are gently thrown into the ear to wash out the previously-used soda solution. The ear is then dried with a spill of soft linen and closed with a bit of absorbent cotton, which in cold weather the patient is advised to wear until bedtime.

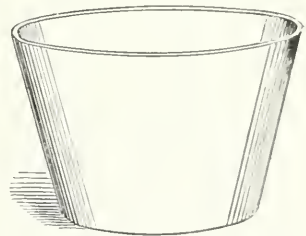


FIG. 489.—Deep cup to catch the outflow in syringing the ear.

If the plug proves to be exceptionally refractory or time be pressing, the patient is told to report the next day, and in the meantime to drop into the ear several times a little warm sweet oil, or, if it be inconvenient for him to do this, the ear is filled with a saturated solution of soda, and after perhaps a half-hour's wait the syringing is resumed. The cases in which the plug cannot be removed at one sitting are very exceptional, but the writer is compelled to admit that with the best skill he can command it is not unusual for him to spend many more than "five minutes" in accomplishing this result.

It occasionally happens that upon inspecting the ear it can be seen that the mass of cerumen does not extend into the deeper parts of the canal. Under such circumstances, if it is found to be of its usual firmness, it is often possible with the traction instrument (Fig. 490) to draw out the whole mass at a single effort, and so to save both time and trouble. If, however, even in such a case, the cerumen proves to be of such consistency that it can be removed only bit by bit, it is better to resort to the syringe without further ado.



The writer knows of no means by which the well-recognized disposition of impacted cerumen to recur after having been removed can be overcome,

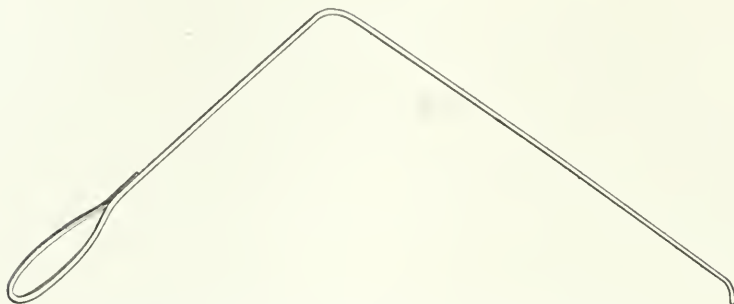


FIG. 490.—Foreign-body traction-hook made of a steel hair-pin.

except in so far as the cure or amelioration of any accompanying inflammation of the naso-pharynx tends to this result.

**Circumscribed Inflammation** (*Furuncle*).—Furuncular inflammation of the external auditory canal is of very frequent occurrence. The furuncles almost always form in the outer third of the meatus, and their starting-point is in the ceruminous or sebaceous glands or in the hair-follicles which are situated in this portion of the canal. Oftener than not several furuncles occur at the same time or in quick succession, and occasionally, in the absence of proper treatment, they may recur at brief intervals for weeks. They give rise to severe pain, and to so much swelling of the membranous portion of the meatus as to occlude it completely, and so produce a transient impairment of hearing. The discharge is slight and thick, differing markedly from the more copious and thinner discharge which is usual in acute purulent inflammation of the middle ear. The swelling and sensitiveness of the meatus are commonly so great as to preclude an inspection of its deeper parts and of the tympanic membrane; but the location and appearance of the swelling, the scantiness and character of the discharge, the history of the onset of the attack, and the absence of tinnitus, and of such a degree of deafness as commonly attends acute inflammation of the middle ear, usually render a differential diagnosis from this latter affection a matter of no great difficulty.

Furuncular inflammation of the meatus is in most instances traceable to a pre-existing, perhaps very slight, dermatitis or eczema of the membranous portion of the canal. This gives rise to itching, which the individual attempts to relieve by scratching the ear with the finger-nail or with a tooth-pick, a match, a bodkin, a hair-pin, or some such instrument, and sooner or later he succeeds not only in producing an abrasion of the canal-wall, but in implanting upon this denuded surface, which in all probability involves the orifices of several of the ceruminous or sebaceous glands, a pyogenic organism (usually the staphylococcus aureus or albus), the subsequent development of which brings on the furunculosis. In other instances the furuncular inflammation is secondary to otitis media purulenta—a localized infection, from the entrance of the micrococci into the hair-follicles or into the ceruminous or sebaceous glands, resulting from the walls of the canal being constantly bathed in the pus which flows from the middle ear. A depressed state of the general health is also frequently an important factor in the etiology of furunculosis of the external ear as it is in furunculosis occurring in other regions.

Exceptionally, small abscesses are met with in the deeper portion of the meatus. These usually run a more protracted course, being often dependent upon caries of the underlying bone or upon tympanic or mastoid disease.

**Treatment.**—If seen in its incipiency, furuncular inflammation of the auditory meatus can occasionally be aborted by the application to the walls of the canal of an ointment of yellow oxid of mercury and vaselin (gr. j–ij to ʒj) and the administration of a brisk calomel cathartic; and, it may be added, in the occasional application of this same ointment we have a prophylactic measure of great value, for the chronic dermatitis, which, as has been said, is so often the precursor of furunculosis, may by this means almost always be cured or kept in abeyance, and thus the disposition to acute outbreaks be removed.

When the furuncle is more fully developed, so favorable a result is not to be anticipated, but the yellow-oxid ointment is still useful in lessening the likelihood of the inflammation invading other follicles. For the relief of the severe pain, the head (in lying down) should be kept as high as practicable, dry or moist heat (a Japanese “stove” or a pad of gauze wrung out in hot water, freely sprinkled with laudanum and covered with a piece of rubber protective or oiled silk) should be applied to the ear, and six or eight drops of a solution of atropia and cocain in almond oil<sup>1</sup> (atrop. alk. gr. j, cocain alk. gr. ij, ol. amyg. dule. ʒij) should be dropped into the canal (and retained by a pledget of cotton) three or four times in twenty-four hours, or the “baume tranquille” of the French Codex may be similarly employed. The application of a 10 to 20 per cent. solution of menthol in albolene or olive oil is also recommended. Should these measures fail to relieve the pain, as, it must be admitted, not infrequently happens, morphin may be administered hypodermically or by the mouth.

The writer is inclined to agree with those (Wilde, Buck, and others) who think that a very early incision of the furuncle is uncalled for, and may do more harm than good. When, however, it is evident that pus has formed, its escape should be facilitated by an incision, which may be conveniently made with the knife represented in Fig. 491, which some years since the writer



FIG. 491.—Writer's knife for incising furuncles of the external auditory canal (to be used with the angular handle shown in Fig. 523).

contrived for this purpose. The local abstraction of blood hardly seems to be called for, although it is claimed for it that, if employed at the outset, it often proves of much value. After the furuncles have opened or been incised, douching or gently syringing the ear with a saturated solution of boric acid is a useful measure. The state of the bowels and the general condition of the health should be looked to, and tonics or laxatives should be administered when they seem to be indicated.

**Diffuse Inflammation.**—Diffuse inflammation of the external auditory canal occurs as an acute and as a chronic affection. It differs from furuncular inflammation in that it tends to involve the whole extent of the auditory canal, the osseous as well as the membranous portion. The pain which usually is present only in acute cases is, as a rule, not so severe, and the swelling,

<sup>1</sup>This solution has been prepared, at the suggestion of the writer, by Messrs. Hynson & Westcott, of Baltimore, as a substitute for the aqueous solutions of the salts of cocain and atropia. It has been found especially valuable in the treatment of acute otitis media.

especially at the orifice of the meatus, not so marked, as in furunculosis. The discharge is slight and generally serous or sero-purulent in character. In the chronic cases especially, itching is a prominent symptom. The dermal layer of the tympanic membrane is frequently involved in the inflammatory process, and, like the neighboring walls of the meatus, may be markedly hyperemic. There is also a disposition to exfoliation of the epidermis from the drumhead as well as from the canal-walls.

Frequently the disease is essentially an eczema of the external ear, and the auricle, as well as the auditory canal, may be involved in the inflammatory process. It is often present in chronic otorrhea, being excited by the continual flow of pus through the meatus. In other cases it is of traumatic origin, arising perhaps from the entrance of some irritant substance or foreign body into the ear; and in still others it is due to the presence in the auditory canal of a fungous growth, usually the *aspergillus nigricans*, and less often the *aspergillus glaucus* or the *aspergillus flavescens*. For this variety of inflammation of the external ear Virchow has suggested the name *otomycosis*.

A variety of diffuse otitis externa which deserves especial mention, and the etiology of which is not very well understood, is that which is denominated *desquamative inflammation of the auditory canal*, and which leads to the condition known as *keratosis obturans* or *cholesteatoma*. Primarily, this is a diffuse dermatitis characterized by an excessive proliferation and desquamation of epithelium; but at a later stage the periosteum and underlying bone are not infrequently involved,<sup>1</sup> and areas of caries and necrosis, sometimes accompanied by the development of polypi, may occur; while in some instances marked absorption of the bony walls of the meatus takes place, resulting in a great increase of its caliber. Eventually, the auditory canal becomes completely occluded by the exfoliated epithelium, which forms into a tough, laminated plug containing between its layers an admixture of inspissated cerumen. For a time this may give rise to no inconvenience other than deafness, probably accompanied by tinnitus; but sooner or later, through the invasion of bacteria (which seems to be Nature's method of ridding the economy of such an incensus), an acute outbreak of inflammation occurs, accompanied by pain, suppuration, and partial disintegration of the laminated mass. It is at this time that medical advice, if it has not previously been obtained, is usually sought.

**Treatment.**—As may be inferred, the treatment of diffuse inflammation of the auditory canal will necessarily vary with the origin and character of the attack. For the relief of pain the anodyne applications which have been described in treating of furuncular inflammation, and especially the solution of the alkaloids of cocain and atropin in the oil of sweet almonds, will be found useful. In otomycosis the intruding fungus must be gotten rid of as soon as possible—in the first place, mechanically, by means of the syringe, forceps, and traction-hook; and, in the second place, by the insufflation of the powder containing equal parts of oxid of zinc and boric acid which has already been spoken of, and which was recommended for this purpose by the writer many years since.<sup>2</sup> The efficiency of this remedy, which depends upon the drying effect of the oxid of zinc as well as upon the proven specific action of boric acid in preventing the growth of *aspergillus* and other related fungi, is so marked that, in the experience of the writer, a second application is only exceptionally required to completely destroy the varieties of *aspergillus* which are usually encountered in the ear. It has, moreover, the great additional advantage of being one of the best possible agents for the

<sup>1</sup> Perhaps the primary lesion [Ed.] <sup>2</sup> *Amer. Journ. of Otology*, vol. iii. p. 119, April, 1881.



relief of the inflammation of the auditory canal excited by the presence of the parasite, in this respect certainly being far better than alcohol, which has been widely commended for the destruction of aural fungi. With the eradication of the aspergillus the inflammation usually subsides promptly; and, as a rule, no other treatment than the insufflation of the zinc and boric acid, which may require to be repeated once or twice, is called for.

In desquamative inflammation the removal of the mass of exfoliated epithelium, which sometimes is a difficult task, requiring several sittings, is of course the first thing to be accomplished. This can best be effected by the syringe, aided by the forceps, traction-instrument, and probe. The removal of the plug should be followed by the insufflation of boric acid and oxid of zinc, which the writer has found especially useful in these cases. A powder containing equal parts of aristol and boric acid has also been found of service. In the uncomplicated forms of diffuse inflammation of the auditory canal—which, as has been said, are frequently eczematous in character—these same applications are indicated if a drying effect is desired; while in other cases the yellow-oxid-of-mercury and vaselin ointment, previously mentioned, is often of great value; and so also is an ointment composed of oxid of zinc, boric acid, and vaselin, to which a small quantity of balsam of Peru may at times be added. (Zinci oxide gr. xxx–lx, acid. boric.  $\bar{s}$ j, vaselin  $\bar{s}$ j). Strong solutions of nitrate of silver ( $\bar{s}$ j–ij to  $\bar{s}$ j) are highly commended by Buck and others. Tonics, laxatives, and other constitutional remedies, such as the salts of lithia, arsenic, etc., may often be prescribed with advantage. Polypi, if present, should be removed with the forceps or snare

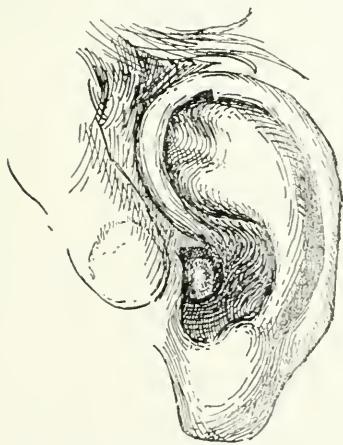


FIG. 492.—Myxomatous polyp filling the canal.

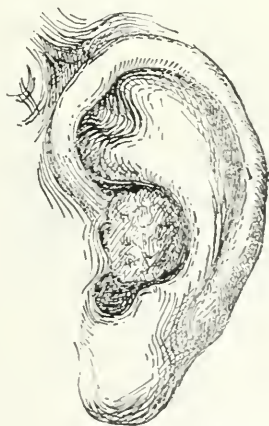


FIG. 493.—Large polypoid mass growing out from depths of the canal and filling the concha.

(they are usually quite small, but may be multiple), and any areas of carious bone should be carefully curetted, or, better still, perhaps, if limited in extent, should be touched with muriatic acid diluted with two or three parts of water, which seems to do good not only by its stimulant action, but by its solvent effect upon the necrosed bone.

**Polypi.**—In most instances where a polypus is found occupying the external auditory canal it has its origin in the tympanic cavity, and grows from there (the drumhead being partially or completely destroyed) into the meatus. Exceptionally, however, the polypi which form in the course of chronic otorrhea spring from the walls of the canal, usually in the neighbor-



hood of the membrana tympani. They also are occasionally met with in the absence of perforation of the drumhead, as after injuries of the meatus, caries of its walls, furuncular inflammation, and, as has just been indicated, in the course of desquamative otitis externa. Poulticing is at times responsible.

Their treatment consists in early removal (with forceps if they are small, or with the snare if they are larger and their point of attachment cannot certainly be made out), the application of chromic acid to the pedicle, and the insufflation of boric acid by itself or in combination with aristol or oxid of zinc. Properly carried out, these measures render a recurrence of the polypus very unlikely.

**Exostosis and Hyperostosis.**—The term exostosis is applied to those bony growths upon the walls of the external auditory canal which are circumscribed and fairly well defined in contour (Fig. 494); while by hyperostosis is meant that condition in which the caliber of the bony meatus is gradually encroached upon (see Fig. 464), probably throughout a considerable part of its length, by a diffuse growth of bone, which is usually the result of a chronic periostitis secondary to long-standing otorrhea. In extreme cases of hyperostosis a complete bony occlusion of the canal may result, which, from its appearance only, cannot always be distinguished from congenital atresia. A case of this character observed by the writer has already been referred to in treating of congenital anomalies of the external auditory canal. The growths denominated exostoses are met with in all parts of the osseous canal, vary greatly in shape, being usually mound-like, with a broad base,

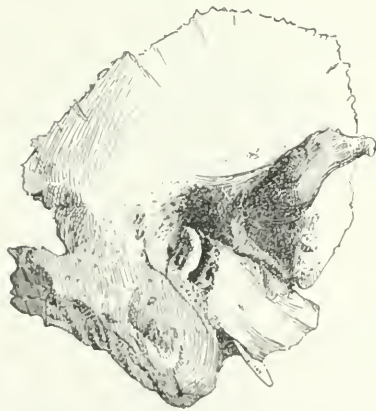

FIG. 494.—Exostosis arising from the back wall of the canal.

but occasionally distinctly pedunculated; may occur singly or in groups, and differ markedly in structure, being sometimes of ivory-like hardness and at other times composed of soft cancellous tissue. They may be present in the auditory canal for years without their existence being known, for they are usually of very slow growth and quite painless. Their presence is frequently revealed by some intercurrent aural affection, such as acute otitis media or an accumulation of cerumen, which affections, as may be readily understood, they may greatly complicate. Gout, rheumatism, and syphilis have been regarded as having to do with their causation, but this has not been clearly demonstrated. That there is a racial predisposition to growths of this character is certainly true. They are said to be more frequent among the inhabitants of England than among our own people, are of very common occurrence among the natives of the Hawaiian islands, and have been observed very often in the skulls of the Mound-builders.

Treatment.—When occlusion of the meatus is threatened from a diffuse hyperostosis every effort should be made to cure the otorrhea which usually coexists, as this of itself may arrest the progress of the affection. It will also permit the continuous wearing of an elastic plug in the canal, which in time may be expected to effect something in the way of dilatation. The plug should not be harsh in its action, however, or it may do more harm than good. Fine sponge and absorbent cotton have already been mentioned as being useful for this purpose. When complete bony atresia of the canal

exists, operative interference is not indicated unless there is good reason to believe that the septum is quite thin, for under other circumstances it is almost sure to prove of no avail.

As to the treatment of the circumscribed osteomata, non-interference is generally advised, unless there be some especial indication for operation; as, for example, when the enlargement of the growth is interfering with audition or when some intercurrent trouble, such as otitis media suppurativa, complicates the situation. When the exostosis is pedunculated and is so situated that its removal is not a difficult matter, the writer thinks that it is judicious to get rid of it without waiting for possible future complications. His experience in the removal of such growths is limited, but, so far as it warrants deductions, is distinctly favorable to the use of the gouge and mallet rather than the dental lathe, which has been recommended for this purpose.

**False Membranes.**—An occlusion of the auditory canal of much less formidable character than that which may result from hyperostosis is occasionally met with. The occluding membrane is sometimes composed simply of the epidermal layer of the drumhead, which has been cast off entire, and of course is without vitality. When such a membrane is located near the inner extremity of the meatus, it is not always easy to distinguish it from the true tympanic membrane altered by disease. It interferes in some measure with the hearing, and should be broken through with a probe and removed with the traction-hook or forceps. In other cases the membrane is of quite a different character, being supplied with blood-vessels and possessing a low vitality. Such septa, as Buck has pointed out, are usually the result of granulation-tissue springing from opposite points of the walls of the canal and uniting in time to form a continuous membrane.<sup>1</sup>

**Treatment.**—As septa of this character interfere materially with hearing, their removal is indicated. This may be effected by any suitably shaped knife, and, as they show at times a disposition to recur, the subsequent application of chromic acid or other caustic agent to the marginal remains of the membrane may be called for. In the writer's case, to which reference has been made, the removal of the membrane and the subsequent wearing of a vaselin and cotton artificial drum resulted in very marked improvement in hearing (see page 784).

**New growths,** having their origin in the external auditory canal, apart from osteomata and polypi, are extremely rare. Sebaceous cysts upon the walls of the meatus are met with occasionally; chondromata have been observed by Launay and Politzer; and cases of cylindroma, pedunculated papilloma, and of epithelioma and sarcoma have been reported.

The indications for treatment are simply those which apply to similar tumors located elsewhere.

**Syphilis** does not often invade the external auditory meatus, but one case at least of primary infection at this point has been observed. Condylomata and syphilitic ulcers are more frequently encountered. The diagnosis is facilitated by the presence of syphilitic lesions in other parts of the body.

**Treatment.**—Knapp recommends dusting condylomata with calomel, and subsequently painting them with a 1 per cent. solution of nitrate of silver. Politzer touches them with nitrate of silver or a concentrated solution of chromic acid, and afterwards applies a 1 : 30 solution of corrosive sublimate. For syphilitic ulcers he uses tincture of iodine, painting it upon the ulcer sev-

<sup>1</sup> For a report of several interesting cases of this character observed by Dr. Buck see his *Manual of Diseases of the Ear*, p. 110 *et seq.*, and for an account of a similar case met with by the writer see *Trans. Amer. Otol. Soc.*, vol. iv. p. 541, 1890.

eral times. He also mentions a case in which healing was brought about by keeping a plug of mercurial plaster in the meatus. Calomel and the yellow oxid of mercury suggest themselves as remedies likely to prove useful.

**Wounds** involving only the external auditory canal are rare. Buck speaks of the tendency to persistent hemorrhage which characterizes such wounds, and gives as an explanation that the blood-vessels of the cartilaginous framework of the canal are capable of contracting and retracting to but a limited extent. Slight abrasions of the walls of the meatus from efforts to remove cerumen or to relieve itching are common, and are of importance only because, as has been stated, they so often lead to furuncular inflammation. Fractures of the base of the skull not infrequently involve the walls of the bony meatus.

The indications for **treatment** are to free the canal from blood and any extraneous substances which may be present by syringing with a warm antiseptic solution (boric acid), and then, by the insufflation of boric acid or boric acid and aristol, and closing the meatus with a cotton plug, to keep the parts as nearly aseptic as possible.

**Foreign Bodies.**—Although the position and conformation of the auditory canal do not favor the entrance of foreign bodies, they not infrequently find their way into the ear. Children have a habit of thrusting such things as beads, beans, cherry-stones and the like into their own ears or into the ears of their playmates, while inanimate objects of a different character, such as grains of wheat, small pebbles, etc., sometimes find accidental entrance into auditory canals of adults. Living insects also occasionally invade the ear—sometimes by accident and sometimes by design, being perhaps attracted by the odor of a purulent discharge. Many cases, for example, have been reported in which dead flies have been found in suppurating ears, and others in which the living larvæ of the fly were present.

The common belief is that the presence of a foreign body in the ear, without reference to its character or its mode of lodgement, is necessarily a serious matter. It is hardly necessary to say that this belief is groundless. Usually, unless the object be tightly impacted in the canal, or be pressing upon the drumhead, or be of such shape or nature as to cause exceptional irritation, its presence in the ear is scarcely appreciated. On the other hand, if the substance which has entered the ear be of an irritant or caustic nature, or be jagged in shape and so wedged in the canal that the movements of the jaw cause it to wound the walls of the meatus, it may give rise to severe pain and quickly produce inflammatory reaction. The entrance of living insects into the ear usually causes great discomfort, and sometimes intolerable agony, for the contact of their wings and feet with the tympanic membrane is not only very painful, but produces noises which are almost as unbearable. Maggots when they enter the ear cause severe pain, and are difficult to remove, because, as Blake has pointed out, they attach themselves to the walls of the canal by a peculiar hook-like apparatus which they possess, and feed upon the inflamed integument. The writer once removed from the ear a living tick which had attached itself to the wall of the meatus. It had entered the ear about two weeks previously, and for some days a black, granular substance (its excrement) had been coming from the canal, while a sound "like broiling" had been heard from time to time, and pain was beginning to make itself felt. He has also removed flies, maggots, cockroaches, and "bugs" of various kinds and sizes. Stiff hairs from the head or beard occasionally find their way into the ear, and if so placed as to press upon the drumhead, may cause much discomfort.



It should be mentioned that the presence of a foreign body in the ear may excite marked reflex phenomena. Cases have been reported, for example, in which cough, vomiting, excessive salivary secretion, hemierania, facial paralysis, and epileptiform convulsions have been produced in this way (Poulet).

**Treatment.**—The question of how best to deal with a foreign body lodged in the ear depends upon a variety of circumstances, and especially upon the skill and experience of the operator. Doubtless it is best not to allow any foreign body to remain indefinitely in the auditory canal; but, as in most instances it is not at all likely to produce immediate ill consequences, hurried and unskilful attempts at removal without proper instrumental aid, whether undertaken by layman or physician, are to be discouraged. The need for interference is seldom so urgent that time cannot be taken to obtain expert assistance, and it should be borne in mind that the cases which prove to be serious and which tax the ability of the aural specialist are almost invariably those which have previously been subjected to the well-meant but injudicious efforts of the unskilful.

At the outset it is of the utmost importance to make sure that there really is a foreign body in the ear, for it not infrequently happens that misapprehension exists upon this point; and patients are brought to the physician for the removal of a foreign body which has no existence except in their imagination or in the imagination of those who have them in charge. If it be lodged near the orifice of the meatus, it can scarcely escape detection at a glance, but if it be near the tympanic membrane, an ear-mirror and speculum will usually be needed for its discovery; and, indeed, in some ears (in which the upward bend of the floor of the meatus is exceptionally pronounced) it may be impossible, if the foreign body be a small one and be lying in the angle at the lower margin of the drumhead, to bring it into view even with the best means at command for aural inspection. It ought not to be necessary to utter a word of warning against mistaking the bright surface of the tympanic membrane itself for a foreign body; but, as mistakes of this kind have occurred, and at the cost of serious damage to the hearing apparatus, such a warning is perhaps not altogether superfluous.

In unskilled hands or with a very unruly patient the syringe is the safest instrument to employ for the removal of foreign bodies from the ear, and it is one which usually will be found to accomplish the end in view. If, however, the foreign body be tightly wedged in the canal, from having swollen, as beans, peas, and such like objects are likely to do after entering the ear, from inflammatory swelling of the canal itself, or from awkward efforts to remove it, the syringe is not likely to prove effectual. Whether, under such circumstances, the physician unfamiliar with operative procedures upon the ear should desist from further instrumental interference and refer the case to an aural surgeon, must of course depend in a great measure upon whether such skilled assistance can be readily obtained or not. To introduce any form of instrument into the ear and grope blindly about in the hope of extracting a foreign body is a most reprehensible procedure, and one so much more likely to do harm than good that it can hardly be justified under any circumstances. Such awkward manipulations have been known to result not only in loss of hearing, but even in loss of life. Without exception, when any instrument is introduced into the ear for the removal of a foreign body, the auditory canal should be illuminated with the ear-mirror (artificial or diffuse daylight being used as may be preferred), and the foreign body itself and every movement of the instrument should be kept constantly in view.



For the removal of foreign bodies which are not spherical in shape and do not fill the lumen of the canal—such as insects, bits of wire, chips of wood, and the like—the angular forceps are extremely useful; but when a glass bead, a pea or bean, or other roundish body is impacted in the meatus, they are worse than useless, for they cannot be opened wide enough to grasp the object, and every unsuccessful attempt to accomplish this only serves to drive it more deeply into the ear. For the extraction of such bodies—and they are among those most frequently encountered—the writer has found a traction-hook similar to Fig. 490, but stronger, extremely valuable. The body can scarcely be so tightly wedged in the ear as to prevent the bent tip of this instrument (which is serrated upon its under surface to make it catch the better) being at some point insinuated between it and the walls of the canal; and when this is accomplished and the hooked extremity, now beyond the body, is turned so as to catch hold of it, there can be little excuse, unless one's efforts are balked by unruly behavior on the part of the patient, for failing to rid the ear of the intruding body, either by simple traction or by rolling it over and over.

There is nothing which so facilitates manipulations of this character as co-operation on the part of the patient, and nothing which so complicates them as the lack of it. Ordinarily, with a ruly patient, the extraction of a foreign body from the ear is not a painful procedure; but if the walls of the canal have been lacerated by previous rough usage or have become swollen and inflamed from the presence of the intruding body, the infliction of some pain can hardly be avoided. Under such circumstances the previous instillation of a strong solution (10 per cent.) of cocain diminishes the pain in some measure. In unruly children the administration of a general anesthetic is not infrequently called for. In the absence of such an instrument as above indicated, or the loop of a snare, an excellent substitute may be improvised from a steel hair-pin of good quality. The writer is rather fond of making traction-hooks in this way to suit his fancy, and the improvised instrument shown has done most excellent service.

When an insect or other animate object has entered the ear, since its movements are likely to cause much suffering, it is important that an end should be put to its life as quickly as possible. Ordinarily the most efficacious and convenient way of accomplishing this is by pouring into the ear olive oil or any other bland oil that may be at hand. Maggots, however, live for a long time in oil, which, therefore, is not useful when they are present. Dr. Roosa has recommended for their destruction the vapor of chloroform and also Labarraque's solution. If a caustic substance has entered the auditory canal, the ear should be syringed with a neutralizing solution—in the case of an alkaline caustic, vinegar, which is usually at hand, diluted with warm water may be used, and in the case of an acid, the bicarbonate of soda.

Probably, in dealing with foreign bodies in the auditory canal, the writer has had more than his share of good luck; for he does not recall an instance in which he has failed to remove a foreign body from the ear at one sitting—some one of the methods which have been described having been always relied upon. Hence he has felt no temptation to resort to the rather radical procedure (see page 786) of displacing the auricle and cartilaginous meatus, which has been recommended to facilitate the extraction of foreign bodies from the ear. Some years since, in writing of this operation, he stated that he could "scarcely conceive of a case which would warrant recourse to such an expedient;"<sup>1</sup> and later experience has not served to change materially the opinion then expressed.

<sup>1</sup> Buck's *Reference Handbook of the Medical Sciences*, vol. i. p. 425.

# INJURIES AND DISEASES OF THE DRUMHEAD.

BY H. V. WÜRDEMANN, M. D.,

OF MILWAUKEE, WIS.

**Traumatic Lesions of the Drumhead.**—Considering the delicacy of the tympanic membrane and the relative frequency of accidents to the head it is seldom liable to injury, thanks to its protected situation within the skull at the bottom of the external auditory canal.

*Hemorrhage.*—Sneezing or coughing, especially in pertussis or in asthmatics with arterio-sclerosis, may produce circumscribed hemorrhages in the membrane (Plate 11, Fig. 2). Patients experience transient, slight pain, and examination reveals dark red or brown, circumscribed spots, which cannot be wiped away. Such may occur after Politzer's method of inflation, catheterization, after sudden condensation or rarefaction of the air in the external meatus, and from direct injury without perforation of the membrane. *Hyperemia* and hemorrhage occur in the course of myringitis and otitis media from acute infectious disease<sup>1</sup> (due to rupture of the small blood-vessels causing true hemorrhage in the dermal layer), in dense or rarefied atmospheres from the same cause, as in the case of miners or divers, and mountain-climbers or aeronauts, or in persons who have not been accustomed to sudden changes of atmospheric pressure. It is also an occasional accompaniment of scorbutus, typhus, dengue, bubonic plague, and other infectious diseases.<sup>2</sup> Vicarious hemorrhage has also been reported.

*Direct injuries* to the membrane are oftenest observed after unskilful attempts to remove foreign bodies by patients, their friends or physicians (Plate 11, Figs. 3, 4). Slight injuries are sometimes self-inflicted by persons who are accustomed to remove wax or scratch the canal with ear-spoons, tooth-picks, etc. (Plate 11, Fig. 5), or who have acquired the habit of scratching their ears<sup>3</sup> with pencils or pen-holders while deep in thought (Plate 11, Fig. 6). Ill-considered attempts at removal of foreign bodies and of inspissated cerumen (Plate 11, Fig. 7) by forceps, scoops, or syringes with long nozzles may cause dangerous injuries. In cases of myringitis or after gentle removal of impacted cerumen, the simple application of a cotton pledget for drying the ear may rub away the epidermal layer. If aseptic, such slight injuries heal within a few hours. The forcible entrance of water or foreign bodies, such as insects, twigs, etc., into the canal gives rise to superficial or deep injury. The instillation of strong medicinal solutions, as caustics, the use of very hot or very cold solutions, as hot glycerin (Plate 11, Fig. 8), olive oil, etc., may cause lesion of the canal and external layer. A means of torture in ancient times was pouring of hot wax or lead into the ears, which produced effects

<sup>1</sup> Haug: *Krankheiten des Ohrs in ihren Beziehung zu den Allgemeinen Erkrankungen*, 1893.

<sup>2</sup> Richardson: "Hemorrhage from External Auditory Canal," *Annals of Ophth. and Otol.*, July, 1896.

<sup>3</sup> Politzer: *Lehrbuch der Ohrenheilkunde*, 1888.

varying from superficial injury to death; and the membrane may now be injured in metal-workers by the splashing of molten metal. Direct injury and even perforation from the tympanic side has been produced by the Eustachian bougie (Urbantschitsch). Direct injuries, such as punctures and abrasions, are usually found in the anterior half, as pointed objects slide off the more obliquely placed posterior portion of the membrane (Politzer).

*Rupture* of the drumhead is frequently caused by slapping the face and ears of children for punishment by teachers or parents, thus producing sudden compression of air in the external meatus. It occasionally occurs in sparring (Plate 11, Fig. 9), and is common from injuries caused by explosions of gunpowder, dynamite, fire-arms, and boilers. Improper inflation methods, such as the use of compressed-air apparatus at high pressure, the catheter or Politzer bag by unskilled hands or in improper cases, may produce rupture of the drumhead. Spontaneous perforation frequently occurs in acute catarrhal or suppurative otitis media. Fracture of the base of the skull is generally attended by bleeding from the ear and rupture of the membrane (Plate 11, Figs. 10, 11). A diseased, inflamed, or weakened drumhead is more liable to injury than if normal, especially where there has been misplacement or thinning of its structure. The normal drumhead is resilient, and cannot be ruptured under a pressure of 4 or 5 atmospheres (Gruber). The flaccid membrane is seldom broken, as it is less tense and plays an important part in preventing ruptures.<sup>1</sup> The so-called Rivinian foramen does not commonly exist in the normal subject, and is not the safety-valve which has been supposed. The situation of the rupture is indifferently placed in the anterior or posterior halves of the tense membrane, usually near the handle of the malleus. It may be single or double, depending upon the character of the injury. Both large and small perforations may follow slight blows upon the head. The handle of the malleus (Plate 11, Fig. 11) is rarely fractured, although cases have been reported, as well as of dislocation<sup>2</sup> (Plate 11, Fig. 3).

**Symptoms.**—At the time of the injury there is sharp pain, which may last for several hours, and is usually accompanied by dizziness and sometimes by nausea. If the upper part of the drumhead be injured, disturbance of the sense of taste may occur, as where the chorda tympani nerve is divided in operations, but recovers after several weeks. If seen shortly after lacerating injuries, there will be found fresh blood or clots in large or small amount in the meatus or on the drumhead, or, if the perforation be large, in the middle ear. The edges of the wound are at first irregular and covered with fresh blood. Twenty-four hours after the injury, however, there is usually hyperemia, especially of the edges of the perforation, which appear more even. If the ear has been tampered with or not occluded from the atmosphere, infection followed by acute suppuration and sometimes persistent perforation may occur. Simple puncture by clean instruments, such as the paracentesis knife, in ears that are aseptic and not inflamed, will frequently in a few hours heal and close without cicatrix.

The **diagnosis** of traumatic injury, perforation, or rupture may generally be made by its appearance and the history. If seen shortly after the accident, the edges of a rupture are found gaping, so that the yellowish-red lining membrane of the tympanic cavity may be seen. Fresh bleeding is of course diagnostic. A differential symptom is the character of the sound on inflation, as in traumatic perforation the whistle is said to be deep and harsh, while in pathologic perforation it is sharp and shrill (Politzer). It is of forensic im-

<sup>1</sup> Bacon: *Burnett's System*, i. p. 256.

<sup>2</sup> Theobald: *Trans. Amer. Otol. Soc.*, 1891.





## DESCRIPTION OF PLATE 11.

FIG. 1.—Normal tympanic membrane.

FIG. 2.—Hemorrhage into the dermal layer after brisk inflation in a man aged thirty with chronic aural catarrh and adhesions of membrane to promontory. Sketch made two days afterward. The clots did not become entirely absorbed, and pigment could be seen for two years.

FIG. 3.—Destruction of the drumhead and dislocation of malleus into canal from impaction of pebble in middle ear, due to attempts at removal with wire loop, which was broken in the operation, in a child aged three. Removal by snare, and healing under antiseptic dressing.

FIG. 4.—Large rupture of drumhead and impaction of glass bead in tympanum, caused by attempts at its removal by members of the family and physicians, in a child aged four. Removed by snare and rat-tooth forceps. Suppurative otitis with permanent perforation and partial deafness ensued.

FIG. 5.—Self-inflicted wound of dermal layer from hair-pin used for removing "artificial drumheads," in a woman aged forty-six, subject of chronic catarrhal otitis. Healing in two days under antiseptic dressing.

FIG. 6.—Penetrating wound of drumhead from slate pencil in a girl aged eight. Healing in one week.

FIG. 7.—Abrasion of dermal layer and canal from forceps and ear-scoop used by a physician in attempted removal of impacted cerumen. Healing in three days.

FIG. 8.—Acute myringitis from instillation of hot glycerin in a man aged forty-seven with chronic aural catarrh and vertigo. The usual appearances were restored in five days.

FIG. 9.—Double rupture, seen one hour after the accident, in a man aged twenty-six who had received a box on the ear during a sparring contest. Healing in two weeks.

FIG. 10.—Rupture of drumhead in a man aged twenty-seven who had fracture of the base of the skull following fall on back of head. Total and persistent deafness with vertigo and tinnitus. Slight suppuration stopped in four days, but perforation persisted. Sketched one week after accident.

FIG. 11.—Fracture of the malleus and canal in a man who committed suicide by being run over by a locomotive, sustaining fracture of the skull, and death twenty-four hours afterward. (Adapted from Kirchner.)

FIG. 12.—Acute myringitis in stage of maceration, in a woman aged twenty-three, caused by aspergillus growth in the canal after lake-bathing.

FIG. 13.—Acute myringitis bullosa in a boy aged thirteen, due to pond-bathing. Healing in one week after puncture of vesicles and antiseptic treatment.

FIG. 14.—Acute myringitis with sanguineous abscess or hematoma in a man aged thirty. Paracentesis with healing in several days.

FIG. 15.—Acute myringitis with multiple abscesses under the dermal layer in a man aged twenty-six. Healing in about one week after puncture of the abscesses, without implication of the middle ear.

FIG. 16.—Chronic myringitis granulosa in a boy aged fifteen who had discharge from the ear for several years. Healing under cauterization of the granulations and antiseptic treatment.

FIG. 17.—Chalk-formation in chronic suppuration of twenty years' standing in a man aged forty-seven. Small perforation in lower anterior quadrant.

FIG. 18.—Chalk-formation in chronic aural catarrh of long standing in a woman aged thirty-five. The membrane is greatly retracted, thickened, and nearly immovable, and with the ossicles is sclerosed.

FIG. 19.—Chalk-formation in an otherwise normal membrane in a physician aged thirty-five who had full hearing and no other evidence of ear disease.

FIG. 20.—Sclerosis of the middle ear with thickening and retraction of the membrana vibrans in a woman aged forty-eight who had chronic aural catarrh of long standing.

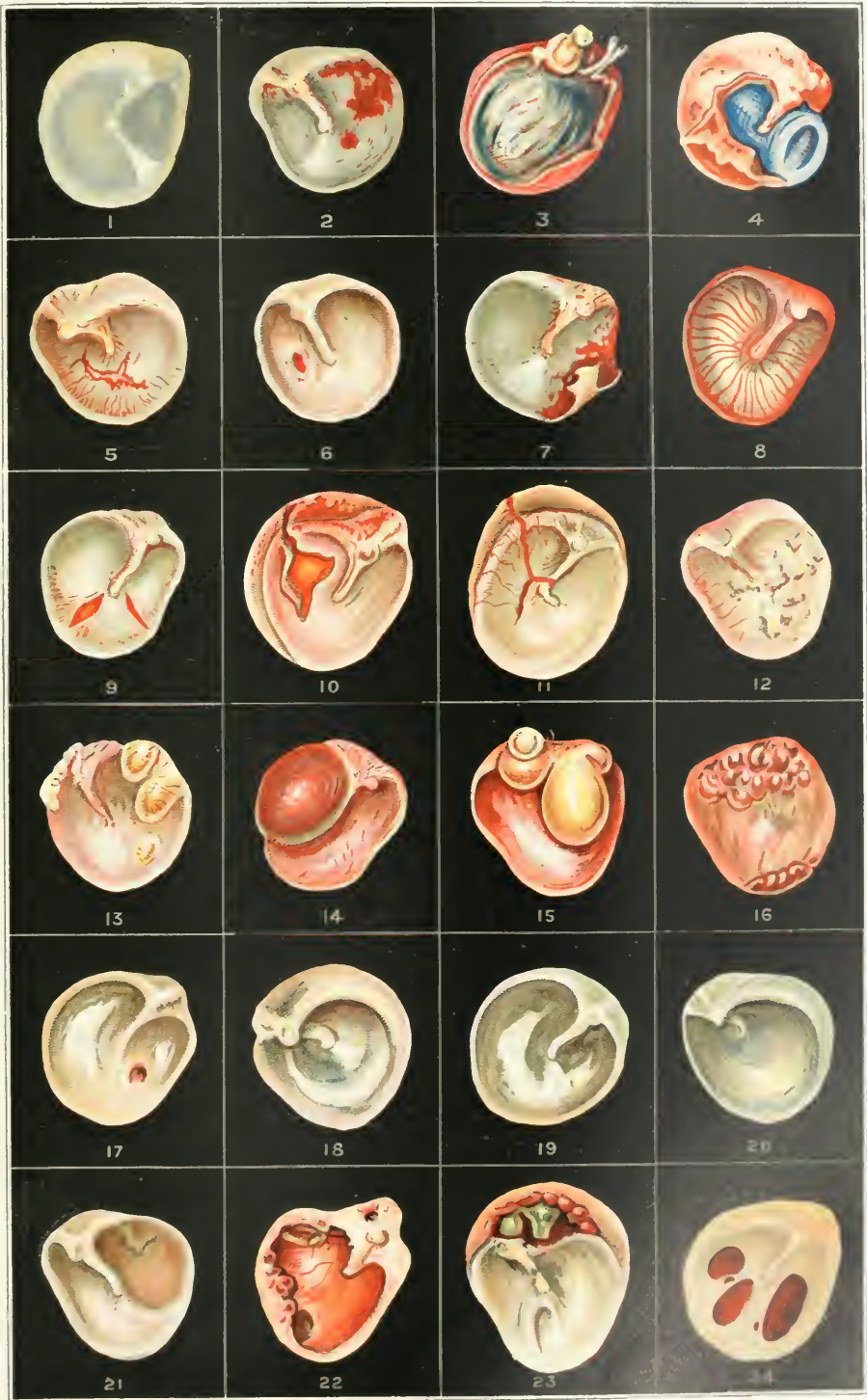FIG. 21.—Atrophy of posterior segment of the membrana vibrans in a man aged thirty-five who had normal hearing and no history of ear disease. The membrane is translucent and retracted, showing the incudo-stapedial joint.

FIG. 22.—Large perforation of the membrana vibrans and small perforation of the membrana flaccida of the right ear in a man aged thirty-four who had scarlatinal suppurative otitis since infancy. The malleus-handle is shortened by necrosis; the stapes and incus with the chorda tympani nerve show through the upper part of the perforation; the promontory and fenestra rotundum with the engorged and swollen mucous membrane of the tympanum are likewise visible; exuberant granulations show on the posterior rim of the perforation.

FIG. 23.—Extensive destruction of membrana flaccida with cicatricial changes in membrana vibrans of left ear of same person (Fig. 22). The necrosed incus, head of malleus, and granulations of the tympanic attic and osseous ring show through the perforation; the malleus-handle is shortened through previous curies.

FIG. 24.—Three large and two small perforations occurring in the pallid right drumhead of a man of thirty-five with tuberculous laryngitis.

PLATE II.



Injuries and diseases of the drumhead.



portance to determine whether or not a perforation be traumatic or due wholly or in part to disease, especially in cases following blows upon the head and boxing the ears, as the statements of patient and friends are frequently influenced by personal motives. Study of the other ear may give valuable light.

The prognosis of simple injury and perforating wounds is good if the ear be clean and secondary infection does not take place, as the drum membrane quickly regenerates; in fact, it is the experience of most surgeons that it is difficult to maintain a permanent opening. Simple injury of the drumhead, as in surgical perforation, seldom has any deleterious influence upon the hearing. In fracture of the base of the skull attended by bleeding from the ear, rupture of the drumhead and lesions of the labyrinth usually occur; the prognosis is unfavorable as regards the hearing and sometimes as to life.

The treatment of most injuries of the drumhead after removal of foreign bodies and cleansing consists in letting well enough alone; the ear should not be douched, nor should solutions be instilled. The canal may be syringed or wiped out with warm saturated boric acid or 1:5000 sublimate solutions, etc., dried and dusted with impalpable boric acid, aristol, or iodoform powder, and the canal stopped with iodoform gauze and absorbent cotton. After twenty-four hours the dressing may be removed and renewed. Within a few days the healing will usually have so far progressed that unless extensively destroyed the membrane has been restored. Even after extensive operations involving the removal of the drumhead and ossicles, although necrosis may have occurred, and after the mastoid operation, if treated in this manner, infection and suppuration rarely ensue.

**Acute Primary Inflammation of the Drumhead (Myringitis Acuta).**—A diagnosis of acute inflammation of the drumhead is less often made than formerly. Its most common causes are said to be due to the entrance of cold draughts or cold water into the external canal. I have more often seen it after attempted removal of cerumen, foreign bodies, or water from the ears, after instillation of irritating or hot solutions (Plate 11, Fig. 8), or in connection with aspergillie inflammation of the canal (Plate 11, Fig. 12). There is slight pain, tinnitus, and a throbbing sensation, with but little deafness. At first there is hyperemia and later effusion of clear or bloody serum from the breaking down of vesicles, which may involve a portion or all of the dermal layer (Plate 11, Fig. 13). Some cases of otitis attended by slight serous discharge, followed by resolution after a few days, are of this form. Sometimes abscesses (Plate 11, Fig. 15) develop under the outer layer, but are usually followed by perforation, presenting a picture similar to acute suppurative otitis media. After the vesicular stage the membrane will have a macerated appearance, more or less of the dermal layer peeling and the redness disappearing (Plate 11, Fig. 12).

The treatment depends upon the cause. In all cases it is necessary to cleanse the canal by antiseptic solutions to prevent infection. The vesicles may be punctured, the ear insufflated with boric powder, and the meatus occluded by iodoform gauze and cotton. In severe cases, cupping, leeching, and hot applications to the side of the head may be necessary. Opiates may be given if the pain be severe, although when such is the case there is usually development of abscess, the puncture of which will relieve the pain.

**Chronic Inflammation of the Drumhead (Myringitis Chronica).**—Chronic inflammation of the middle ear is generally accompanied by implication of the drumhead. Chronic myringitis alone is very rare, although it is possible that such may be found after acute myringitis which has not



gone on to resolution.<sup>1</sup> After inflammation of the canal has disappeared the drumhead sometimes remains affected, and this may be considered an independent disease.<sup>2</sup> The clinical signs are maceration of the dermal layer, redness and sometimes granulations upon the surface (Plate 11, Fig. 16). There is but little pain, and the hearing is but little affected. Tinnitus and slight malodorous purulent discharge usually exist. Middle-ear suppuration with unseen perforation is to be suspected and sought. In perforation of the drumhead polypi and granulations may form upon the edges.

The **treatment** is antiseptic. It consists in cleansing the canal and membrane by injections or brushing with solutions of boric acid, bichlorid of mercury, etc., after which a small quantity of finely powdered boric acid or aristol may be insufflated, or a small pledget of cotton saturated in salol-camphor or naphthol-camphor may be placed in the canal, to remain twenty-four hours and then be renewed. Granulations may be touched with tincture of chlorid of iron, nitrate of silver, chromic or trichloroacetic acids. Instillations of solutions by patients are to be discouraged.

**Infectious and skin-diseases**, as well as the exanthemata, may affect the drumhead (Haug); the eruption of these and of syphilis is sometimes to be seen in the dermal layer. The pustule of small-pox may have been the cause of several cases of middle-ear suppuration which I have seen after this affection. Condylomata<sup>3</sup> of the auditory canal and drumhead have been reported by the writer and others.

**New Growths.**—Warts (Burnett) rarely occur on the drumhead, and are usually due to instillation of fluids. I have seen true epithelioma of the canal involving the drumhead. Pearly growths consisting of cholesterin crystals and molecular débris were found in a case of chronic suppurative middle-ear disease; true cholesteatomata are rare (Gruber). Calcification in the drum membrane is frequently found in the course of chronic otitis media (Plate 11, Figs. 17, 18), although it is seen when there is no other evidence of ear-disease (Plate 11, Fig. 19). The membrane becomes thickened (Fig. 20), thinned (Plate 11, Fig. 21), or opaque and perforated (Plate 11, Figs. 17, 22, 23, 24), as the result of chronic inflammation in the middle ear and canal. They are likewise due to trauma and ulcerations, such as occur in syphilitic or tubercular (Plate 11, Fig. 24) middle-ear disease.

Polypi usually arise from the tympanic mucous membrane; but are sometimes on the edges of perforations—most frequently at the posterior superior quadrant. Mucous polypi and myxomata are most common, although fibromata and angiomatica<sup>4</sup> are seen. These growths are accompanied by malodorous otorrhea, and are but part of a chronic suppurative process which is usually attended by necrosis of the walls of the tympanum and of the ossicles, and their removal may be a needed preliminary to treatment for the chronic suppuration. Granulations are preferably removed by the small curette, and polypi by the cold snare, and their pedicles cauterized by tincture of the chlorid of iron, nitrate of silver, chromic or trichloroacetic acid on a small pledget or fused on the end of a probe; but with these or with the galvano-cautery care should be taken that nothing but the growth be touched. Granulations recur unless the suppurative disease be healed.

<sup>1</sup> Steiner: *Die häufigsten Ohrenkrankheiten im Bilde*, 1895.

<sup>2</sup> Politzer: *Atlas der Beleuchtungsbilder des Trommelfells*, 1896.

<sup>3</sup> Würdemann: *Arch. of Otol.*, xxi., p. 303, 1892.

<sup>4</sup> Buck: *Trans. Amer. Otol. Soc.*, 1870.

# ACUTE AFFECTIONS OF THE TYMPANIC CAVITY AND EUSTACHIAN TUBE.

By HORACE G. MILLER, A. M., M. D.,

OF PROVIDENCE, R. I.

THE acute affections of the middle ear are of great importance, for three principal reasons: First, on account of the pain which usually accompanies them; Second, because of the deafness produced, which may become permanent; and Third, because they may endanger life by extension to the brain. Each of these reasons would be sufficient to demand the earnest attention of the physician. Together, they present a subject which he cannot possibly afford to neglect.

**Pain.**—Usually the first symptom to appear is “*carache*,” so common in some families as to be thought one of the necessary ills of childhood. In nearly every case this is evidence of an actual inflammation of the mucous membrane lining the middle ear. A child “*subject to carache*” is in danger of deafness, and no care should be spared, not only for the relief of present distress, but in ascertaining and removing the cause. It will rarely be found, even after a single attack of pain, that the hearing of the affected ear is normal. This fact is likely to escape attention if one ear only be affected. After the suffering is allayed, all anxiety on the part of the parents and friends ceases. But if the hearing be compared with that of the healthy ear, the simplest test will show the defect; and a new interest should be at once awakened, and a new sense of responsibility aroused.

The pain may vary from a dull ache to the most intense anguish. Often the pain is most severe at night, causing loss of sleep to the patient and his family. It may nearly or wholly subside by day, leaving only a tenderness when the auricle is touched, which is discovered by the nurse or mother when making the child's toilet. In children too young to tell the cause of distress, its seat will often be pointed out by unconscious movements of the hand to the affected part. Frequently in young children, after several days of suffering, a discharge of pus from the meatus reveals the diagnosis to the astonished friends; so that when a child cries and shrieks from an unknown cause, the ears should be among the earliest organs to be investigated. The pain is not always confined to the ear itself, but extends to the adjacent parts; almost all the nerves of sensation on the affected side of the head may share in the distress, which is further aggravated by movements of the muscles, as in mastication. Eructation, coughing, and sneezing are greatly dreaded. All loud sounds increase the suffering. Frequently the pain extends to the teeth, especially if any of them are decayed, until the patient scarcely knows whether toothache or *carache* most predominates. The severity of the pain is to some extent a gauge of the violence and character of the inflammation, the severer form, especially when constant, indicating the probability of suppuration with all its attendant dangers. As in many other diseases, the

presence of pain, when rightly interpreted, is fortunate, for it comes as a warning of impending danger to the hearing, demanding measures for instant relief, which at the same time shall furnish a safeguard against the rapid impairment of a delicate and sensitive organ.

**Deafness.**—Next in importance to the urgent necessity for the relief of pain comes the prevention and cure of deafness. Much has recently been written to impress upon the profession the need of the most careful attention to this subject; but it is a matter upon which too much cannot be said, and reiteration cannot be too frequent, since it has become known how much can be accomplished in this direction by preventive medicine and surgery. Heredity in this direction means the existence of local causes which may be successfully controlled; and no child should be allowed to acquire deafness because, as is said, "it runs in the family." On the contrary, such a tendency should lead to the earlier and more active fight against such a fate. The baleful influence of poor hearing upon the development of children is so disastrous as to call for our warmest sympathy for its victims and our most earnest efforts for their rescue. Blamed and misunderstood by his teachers for supposed inattention, neglected and ridiculed by his companions, the child who is deaf often actually becomes the stupid and useless creature which he is at first only in appearance. He becomes ill-natured and peevish in disposition, stunted and undeveloped in intellect. His whole career is blighted. But few forms of employment or industry are open to him. Even his physical development is hindered by his inability to engage in the athletic sports which his fellows delight in; and from the resulting debility and malnutrition he readily becomes a prey to any cachexia to which he may be constitutionally inclined, or any disease to which he may be exposed. Many of these evils might be avoided or relieved by a wise prophylaxis or by proper treatment. But owing to the prevalent ignorance on the subject most of the cases in the schools are neglected until the proper season for interference is passed. It is to be hoped that the time is soon coming when the examination of the ears and hearing of children by competent physicians will be a matter established by law, not only as a preliminary to the beginning of a course of education, but from time to time subsequently as promotions are made to higher grades. The result of this would, of course, be the enforced attention of both teachers and parents to this vital matter and the consequent medical treatment of those capable of improvement; the better understanding on the part of the teachers of some scholars whose slowness to learn has been ascribed to a different cause; and the elimination of those scholars who would require the special training in lip-reading, so useful to those whose hearing is defective. It is true that but few children would be found suffering from an acute attack of inflammation of the middle ear at the moment of examination; but most of those found to be deaf will have acquired their deafness from an acute attack; and many of them will be liable to future accessions of the trouble if preventive measures are not promptly taken.

**Danger of Extension.**—The third principal point of interest in acute affections of the middle ear lies in the fact of their liability to extend to the surrounding parts. Primary inflammation of the antrum and mastoid cells may occur, but in nearly every case the disease comes by extension from the middle ear proper. This may be followed by caries and necrosis of the bony walls of these cavities, and the disease may then extend inward to the membranes of the brain, causing a meningitis or abscess of the brain, with lethal result. There may be a like extension still more directly



through the tegmen tympani, where the attic portion of the tympanum is separated from the brain only by the thinnest layer of bone, perforated by foramina for vascular anastomosis. Thrombosis may also result from contact of the diseased bone with the walls of the venous sinuses, with a result equally fatal. General pyemia may also ensue, either by absorption of purulent products or by rupture into the walls of a sinus. These possibilities should lead us to look seriously upon every painful manifestation of ear-trouble, and make us willing to submit to criticism for too much zeal rather than have to blame ourselves for not having taken prompt and efficient measures at the time when they could most avail. Let us then remember that in every case of acute otitis media we may by proper treatment be the means of saving patients from pain, from deafness, or from death. Too often they have been treated with indifference or neglect, resulting in the tacit permission for the use of remedies often both inefficacious and far from harmless. That these affections are trivial no one who has once witnessed the suffering or its results can for a moment maintain. It is not true that the diagnosis is very difficult. Any intelligent physician may feel himself competent for it. The use of that most important aid in physical diagnosis, the head-mirror, should be familiar to every medical man, not for the ear alone, but for the illumination of every orifice of the body, especially at night; and under many circumstances where both hands are needed for operation and manipulation. With this mirror, and the light from a window by day, or the light from the ever-ready kitchen-lamp by night, the inspection of the drum-membrane is usually easy. But nowhere in the physician's practice is gentleness and delicacy of touch more necessary. One careless thrust of the speculum or ungentle pull on the concha, and all intercourse between a young patient and the doctor may be at an end, except by the aid of a general anesthetic. The old-fashioned bivalve ear-speculum should never be used. It is awkward and apt to cause pain, and requires one hand to retain it in its proper position. Should it be necessary in order to complete a full inspection for the purpose of diagnosis, it is proper to resort to general anesthesia; and if operative interference be found necessary, this condition may be taken advantage of to complete the procedure.

**Types.**—As to the usual distinction between catarrhal and purulent inflammation of the middle ear, it is difficult to draw the line in making the diagnosis. Only after the disease has run its course can we tell which form we have had to deal with. If we could always know the cause of infection, this, with the severity of the symptoms, would furnish an early indication. But this is not always possible. It is therefore better simply to look upon cases as more or less severe and not of a wholly different character.

**Causes.**—The acute affections of the middle ear come most frequently by extension from the naso-pharynx. Consequently the exanthemata, and especially scarlet fever, are among the most frequent causes of a systemic nature. A large percentage of the inmates of the institutions for the deaf date their infirmity from an attack of scarlet fever in childhood. In measles the ear is still more frequently affected. It has recently been shown that the ears are probably involved in every case of measles. An exudation containing the specific organism of measles is formed on the lining mucous membrane of the tympanum by the eruption. But unless this be mixed with one of the pyogenic germs, this exudation is rapidly absorbed without perforation of the drumhead and without injury to the hearing. The deafness of typhoid fever is caused usually by a catarrhal condition of the middle ear; but in this



case also it seldom goes on to suppuration. As one result of the recent epidemics of influenza there has been a great increase of acute otitis media. This has been characterized by great intensity of pain and a greater tendency to suppurate, and consequently spread to the mastoid, than is usually the case in acute otitis media. Diphtheria may also produce inflammation of the middle ear, the characteristic bacilli being found in the discharge. The same is true of tuberculosis. Here the onset of the disease is comparatively painless; but it may result in great destruction of the tissues, both soft and bony, contained within the tympanum. Both a rheumatic and a gouty diathesis may favor or superinduce acute otitis media, either primarily or by extension from inflammation of the pharynx. Syphilis, in the secondary stage, when the naso-pharynx is involved, is often productive of acute otitis media, varying in all degrees of intensity. Later on, when the bones of the nose are diseased, the same result may ensue. Of all external causes, taking cold, in the ordinary sense of the expression, from exposure to draughts of air, or in any way productive of coryza, is by far the most frequent. Whooping-cough and the catarrhal affections commonly classed under the head of hay fever may also result in acute inflammation of the middle ear. Sea-bathing, if too frequent or long continued, is a common cause; and the same is true to a less extent of bathing in cold, fresh water. But it seems that the surf, either from its violence or from its saltiness, is directly dangerous to the ear, especially if a perforation of the drum membrane exists. Perforation of the drumhead also admits air, which, from its temperature or from being laden with any of the infectious germs, produces inflammation of the mucous membrane. Acute otitis media may be the result of *adenoid vegetations* of the pharyngeal vault; and many children who are subject to earache will be found to have this cavity closely packed with this form of hypertrophic growth. This may act by causing a retention of the natural secretion through obstruction of the orifices of the Eustachian tubes, or by predisposing to naso-pharyngitis which is propagated by extension, until it reaches the cavity of the tympanum. The importance of the recognition of this condition cannot be overestimated.

Hypertrophied tonsils undoubtedly have a similar effect upon the ear; but the adenoid growths which so often coexist with them are no doubt more frequently responsible. Otitis media may also follow the intratympanic hemorrhage of Bright's disease. It may be produced by the extension of erysipelas from without. Trauma figures among the less common causes of middle-ear disease of acute form; the tympanum by its situation being greatly protected from external violence. But when a wound admits infectious germs, or when infection occurs from a rupture of the drum membrane by an explosion, a blow, or any other violent cause, inflammation of the middle ear may follow. The same is true of the destruction of the drum membrane by scalding or corrosive liquids or molten metals. Fracture through the temporal bone may also form an avenue for infectious germs. Among the rarer causes, perforations produced by mycosis or vegetable fungi of the meatus, or by accumulations of dried wax and epithelium, may lead to the same result. The teeth, both at the time of their development and eruption, and when diseased, are productive of much middle-ear trouble. During the first and the second dentitions, at the eruption of the sixth-year-molars, and at the appearance of the wisdom teeth, the ears are peculiarly liable to suffer from reflex irritation and inflammation. At all times of life caries and necrosis of the teeth and alveolar processes, with their accompanying ulcerations and suppuration, are closely connected with the production of disease of the tympanum. The

examination of the teeth should, therefore, be a constant matter of routine in the examination of these cases.

That the causes, both immediate and remote, of the disease under consideration are so numerous and varied, shows the need of diligent research in every case, that we may avail ourselves of all indications from such sources, both for present treatment and for prophylaxis.

**Symptoms.**—Of the symptoms of acute otitis media, next to the pain, which we have already considered, comes tinnitus. Subjective noises of some kind are rarely absent. A thumping, pounding, or beating sound, synchronous with the heart's action, is most common in the earliest stage of the disease. Children often mistake these sensations for real, objective noises; and an inquiry as to their meaning or cause is sometimes the first indication of the existence of disturbances in the ears. Later, the tinnitus is of a more steady and continuous character, described as rushing, roaring, singing, or buzzing. Those sounds of a pulsatory or rhythmic character are due to the increased circulation in the arteries and dilated capillaries in close contiguity to the sound-perceiving termination of the auditory nerve. Those of a steady and continuous character are due, at first at least, to increased venous circulation, which is heard by the ear itself in the same manner. In a later stage there may also be tinnitus due to pressure on the contents of the labyrinth through the oval and round windows from swelling or retained secretion in the middle ear. To children these noises are often terrifying. In all cases they are productive of a greater or less degree of nervousness and distress.

Deafness is the next objective symptom noticed by the patient. In the milder cases some days may elapse before the hearing becomes much impaired. Slight degrees of deafness may not at first be noticed by the patient, especially if the affection be unilateral. But soon familiar sounds, like the ticking of a clock, become inaudible, then the patient begins to ask for a repetition of what is said by those around him, and finally hearing is for the time almost totally abolished. The degree of deafness, in the earlier stages at least, depends much upon the localization of the affection. Should the attic of the tympanum be most affected, the hearing may suffer but slightly at first, although the pain be most severe. When the Eustachian tube is most affected, the stopped-up feeling predominates over the deafness. When the whole lining of the atrium is involved at the outset, the deafness is most marked. Besides deafness there may be the modified hearing of autophony, in which the patient hears his own voice strongly changed and resonant. There may also be diplacusis, or hearing sounds in a different pitch from that perceived by the unaffected ear.

The constitutional symptoms are sometimes ushered in by a chill. There is general uneasiness, loss of appetite, and increased temperature; sometimes headache, dizziness, and possibly nausea are present. As in other acute diseases, the general disturbances will be greatest in patients of a nervous temperament.

If a tuning-fork in a state of vibration be now applied to the vertex or to the teeth, the sound will be heard more clearly in the affected side, the closed cavity with its thickened walls acting as a sounding-board to intensify the effect of the vibrations. Examination of the drum membrane usually reveals more or less redness; even in the early stages of the attack the hyperemia shows itself by beginning at the tympanic margin and extending toward the center with more or less rapidity. The vessels which follow the handle of the malleus, unseen in a state of health, now become visible. All the landmarks may be lost, as the hyperemia involves the adjacent portion of

the dermoid meatus; swelling shows itself at any point according to the localization of the inflammation, and may also extend to the inner end of the meatus (see Plate 11, Fig. 8).

As in all inflammations of the mucous membrane, the secretion soon begins to increase. A serous exudation is poured out, which may sometimes be distinguished through the still transparent membrane, partially filling the cavity of the tympanum, like the liquid in a spirit level (see Fig. 495). In severe cases the cavity quickly becomes filled, and a few hours may suffice for the pressure of the confined liquid to cause a rupture of the drum membrane. As the Eustachian tube has been closed by the swelling of its lining membrane, the drumhead affords the point of least resistance, and becoming softened, yields to the pressure from within. Often the liquid takes on a purulent character, and may be seen pointing at some bulging portion of the membrane before a rupture takes place (Fig. 496). After the evacuation of the secretion, whether from spontaneous giving-way (Fig. 497) of the mem-

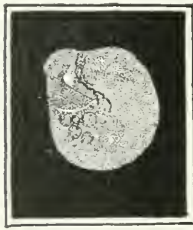

FIG. 495.—Acute catarrh of the middle ear, with bubbles in the fluid which nearly fills the drum cavity.

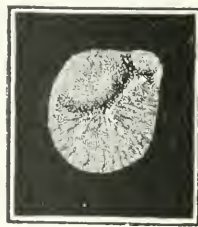

FIG. 496.—Injected drumhead bulging in the upper back of quadrant and above the short process.

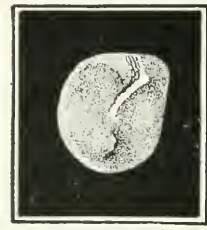

FIG. 497.—Pouling perforation of the lower back quadrant, showing a mere pin-hole at the apex of the nipple.

brane, or from surgical interference, there is usually great relief from pain. The amount of discharge may be very slight, but is at times most profuse and continuous, so as to moisten many thicknesses of compresses and bandages. Often at first the secretion is tinged with blood, or there may be quite a free hemorrhage. In favorable cases the untoward symptoms now rapidly subside. The pain diminishes and disappears, the noises become less violent and annoying, the temperature falls, the patient is able to obtain rest, and the general recovery is rapid. The deafness, the last effect to disappear, gradually or sometimes quite suddenly gives place to perfect hearing. Unfortunately, many cases do not end so happily.

**Treatment.**—The first point in the treatment is to *remove, so far as possible, the cause.* But in most cases the patient is not seen until the disease is well developed, and preventive measures are now of no avail. However, when a naso-pharyngitis which has spread to the middle ear is still active, it should receive prompt and appropriate attention. Anything unfavorable in the patient's surroundings should be looked after, a mild and equable temperature should be established and the patient placed in bed; and quiet, both as regards freedom from noise and from excitement, maintained. If there be a rise in temperature, a saline cathartic should be administered. Tincture of aconite may be given in small and frequent doses, where the pulse is full and hard, until the feverishness is reduced. Opiates should be used but sparingly, except at the outset, when a full dose may be employed. When given later, by their anodyne effect, they mask the symptoms, and may deceive into a fancied security when the danger is not yet passed. Inflation



by Politzer's method should be tried with care and gentleness. It sometimes gives great relief to pain by equalizing the pressure of air within and without the tympanic cavity. With closure of the Eustachian tube, absorption of air takes place through the mucous membrane lining the tympanic cavity. This produces a partial vacuum, draws inward the drum membrane, causing pressure through the chain of ossicles upon the labyrinthine contents, and at the same time retards the flow of blood, causing or increasing venous congestion in the lining mucous membrane and exudation into the cavity. When the effect of this procedure is favorable, it may be repeated once or twice daily; but when it increases pain or gives no relief, its use must be postponed until later in the treatment of the case. No simple measure is so helpful as the application of "dry heat." The hot-water bag of India-rubber is the readiest means of applying heat. This, when filled, should be covered with soft cloth and laid upon the pillow in contact with the ear. But still better, because of its lightness, is a bag loosely filled with common salt and heated in an oven. Moist and warm applications, like poultices in all forms, are to be avoided. They soon become uncomfortable by evaporation, and tend by maceration of its dermoid layer to promote rupture of the drumhead, already perhaps softened in its inner layer. They may also serve as the means of conveyance of all sorts of infectious germs, and in the end complicate far more than they benefit the disease. For this reason are injurious most of the popular remedies and poultices of all the vegetables in the kitchen-garden. So, too, all the varieties of vegetable oils and animal greases are harmful, their sole value having been to carry heat. The vapor of chloroform may be used with much benefit in mild cases in children. A few drops of the liquid may be placed in a spoon, and the vapor, which is much heavier than air, be poured like a liquid into the ear. Chloroform liniment applied about the ear with a bit of flannel is also valuable. Aseptic aqueous solutions containing local anodynes and anesthetics may be used judiciously in the early stage of an attack. The sulphate of atropia, four grains to the ounce of solution, is efficacious. Cocain hydrochlorate, in solution of from four to twenty grains to the ounce, is still more effective transiently; and better still is the combination of these two with morphin, *e. g.*:

|                               |           |
|-------------------------------|-----------|
| ℞. Sol. cocain hydrochlorat., | 10 % ℥ʒj; |
| Atropiæ sulph.,               | gr. j;    |
| Morphiæ sulph.,               | gr. ij.   |

Of this, five or six drops from a spoon previously dipped into hot water may be poured into the ear.<sup>1</sup>

The local abstraction of blood furnishes one of our most effective measures. The application of two or three leeches to the tragus, or just in front of it, may cut short the whole trouble. After they have filled themselves with blood and fallen off, the bleeding from the bites may generally be allowed to continue until it ceases spontaneously. This subsequent bleeding makes the natural leech more effective than wet-cupping. When leeches are not at hand, the artificial leech furnishes an excellent substitute, or any small knife can puncture the skin in front of the tragus, and any small cupping-glass will serve if the special instrument be not at hand. An ounce or two of blood may be taken, and if the relief experienced be but temporary, the process may be repeated. But when the simpler measures tried in quick succession have failed, or when the onset of the disease is such

<sup>1</sup> Smaller dosage must be adopted if perforation be present.



that it is not likely to yield quickly to the other remedies, or when we find the earlier stages of the inflammation have passed before we have seen the case, paracentesis of the drum membrane must be made. This may be done with any long, slender knife, such as v. Graefe's cataract-knife, or a delicate bistoury, which should be first carefully sterilized. The most convenient instrument for the purpose is the spear-shaped knife (Fig. 498). The double-edged point

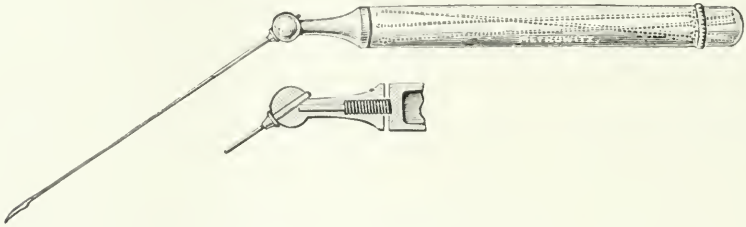


FIG. 498.—Sprague's pocket-case and handle for paracentesis, etc.

should be longer than is usually made, so that in penetrating deeply it will continue to cut, and not, after pricking through the membrane, fail to enlarge the opening. The meatus should be disinfected by gentle irrigation with a 1:5000 warm solution of mercuric bichlorid, followed by mopping with absorbent cotton moistened with alcohol. A pellet of cotton dipped in a 10 per cent. solution of cocain should then be laid against the drum membrane for a few minutes to produce local anesthesia. This will not always be complete in an inflamed membrane, but the pain of the cut will usually be very slight and momentary. The point of selection for the incision may be where any swelling or tendency to point seems to indicate; but if there be no such local indication, the posterior inferior segment is usually chosen as the region where less injury is likely to be done by the knife to the structures within. The cut should be a free one of several millimeters' length and carried down to the tympanic margin for the purpose of drainage, and so as to divide the plexus of engorged vessels which is usually present there.

If the opening be made very early, there may be little or no secretion, and even the hemorrhage may be very scanty. If there be a purulent discharge, this may be gently washed away with the warm bichlorid solution, otherwise no syringing or other interference is necessary. A wick of absorbent cotton, moistened with bichlorid solution, should be inserted, a small compress of iodoform gauze should be placed over the meatus and a larger one over the whole ear, and secured by a loose bandage. Every kind of meddling interference which might cause reinfection should be avoided. The progress of the disease may now be arrested. The opening made by incision quickly heals, the pain is relieved, and the swelling is soon dissipated. The subjective noises cease, and the patient's voice as heard by himself resumes its natural tone. The hearing regains its normal acuteness; and in a few days there may be no remaining sign, either physical or subjective, of the serious disturbance which has taken place. When the process of resolution is less rapid, especially if the pain returns on the following night, more active after-treatment may be necessary. An anodyne may be given internally, and iodid of potassium should be administered, or a mercurial inunction used, or both. If, owing to a too rapid healing of the incision there be retained secretion, the operation may be repeated. If an abundant discharge occur, it must be removed by irrigation with warm antiseptic solution. When the deafness does not quickly disappear, the use of the Politzer's bag may again be indi-

ated. For some weeks at least after an attack the patient should exercise unusual precaution against the effects of exposure to the weather, and over-fatigue. Should the ear be sensitive to the cold, a bit of absorbent wool should be tuiked into the meatus before driving or exposure out of doors.

### SALPINGITIS.

Thus far we have considered the acute affections of the middle ear, with reference to the principal cavity, the atrium. The disease may be especially localized in the accessory cavities, the Eustachian tube, or the attic of the tympanum. When the Eustachian tube is the seat of the inflammation, the most marked subjective symptoms are produced by the sudden closure of the isthmus of the tube by swelling. The effect of this obstruction is the formation of a partial vacuum, causing retraction of the tympanic membrane inward and the transmission of pressure to the labyrinth, producing annoying tinnitus and dizziness, which may be distressing. Autophony is produced most frequently by this cause. The pain is located under the ear and inward toward the throat or at the root of the tongue, rather than deeply in the ear itself. All these symptoms may be productive of great malaise and general disturbance of the nervous system. Often there is a sensation as of a plug in the ear, which the patient endeavors to remove by thrusting the finger into the meatus. Cracking sounds are common, at times rhythmical. The tympanic membrane may show little if any hyperemia, but only great retraction. At first there may be a thin serous secretion, and later the tube may be distended by a viscid and tenacious muco-purulent exudation, which may be discharged into the throat and from the mouth. By the rhinoscopic mirror the mucous membrane at the mouth of the tube may be seen to be swollen and covered with secretion.

The object of treatment will be first to relieve the local congestion and inflammation of the tube itself; and then by opening the closed passage to restore the rest of the apparatus of the middle ear to its normal condition. Mild aseptic sprays may be used through the nose and fauces, with gargles of a similar character and of hot alkaline solutions, to modify any existing catarrhal conditions of the nasal and pharyngeal cavities. The gentle use of Politzer's bag should then be tried, and if the obstruction is not too great, may be followed by immediate relief. Should the air not penetrate by this means, the Eustachian catheter should be employed. An instrument of pure silver which can be bent to any curve should be used, and should be heated to redness in the flame and plunged in a cold boric solution. Its use should be preceded by spraying or mopping the nose and the mouth of the tube with a 6 to 10 per cent. solution of cocain. The air should be thrown in very gently at first to evacuate the secretion from the tube and not to force it onward into the middle ear. Soon the air will be heard through the auscultation tube entering the cavity of the drum. Sometimes the sudden change of pressure causes transient giddiness or faintness. The hearing is improved at once, the tinnitus ceases or is diminished, the feeling of fulness is relieved, and the tympanic membrane will return more or less completely to its normal plane. At the same time proper remedies may be applied through the catheter to the mucous membrane of the tube. Of these, none is more effective than the weaker solutions of nitrate of silver. From 5 to 15 grains to the ounce will usually be sufficiently strong. Only a few drops should be used, and but little force applied in driving it through the catheter, as the effect is to be localized in the tube itself. This treatment

should be repeated daily at first, and then at greater intervals until no longer required. In a few days, in most cases, the normal hearing will be restored as the swollen mucous membrane returns to its natural state. When, as sometimes happens, there is more permanent thickening or even stricture of the tube, dilation by means of delicate bougies passed through the catheter may be required.

#### INFLAMMATION OF THE ATTIC.

It is evident from this description that localized inflammation of the tube is less serious and less dangerous to the hearing than that of the atrium. When the lining membrane of the attic becomes inflamed, the condition is much more serious. The anatomical conditions are such that even slight swellings cut off the communication of this space from the atrium below. The bulkier portions of the malleus and incus, with their ligamentous attachments and folds of mucous membrane, nearly fill the communicating space between the two chambers, and but little swelling is required to complete the closure. The pain from the tension caused by the hyperemia alone soon becomes excruciating. As soon as inflammatory products appear, the pressure is still further increased. The flaccid membrane, already intensely reddened and contrasting strongly with the drum membrane proper below, becomes bulging and swollen over its whole extent, or forms pockets on one or both sides of the malleus along the anterior and posterior folds (see Fig. 496). This condition admits of little or no delay for tentative treatment. Although spontaneous rupture may give ease, it may be only temporary. A permanent opening in the flaccid membrane may result, with necrosis of the bony walls of the attic and of the ossicles, and the formation of adhesions which may impair the movements of the ossicles. Here a free and prompt use of the knife, under the same antiseptic precautions enjoined for the incision of the lower portion of the drum membrane, is both necessary and effective. Beginning just above the short process of the malleus, the knife, with one cutting edge turned backward, should be plunged deeply in, until it reaches a bony obstruction; then the cut should be prolonged until it strikes the posterior insertion of the membrane. Then with the other edge of the knife the division should be continued upward and backward for a quarter of an inch or more along the superior margin of the membrane, still cutting deeply, and dividing all the tissues until the bony wall is felt. This can be done in a satisfactory way only under general anesthesia. After the incision—which will be followed by free bleeding and the evacuation of pus if suppuration be already present, and oozing of serous effusion—the wound should be irrigated with warm bichlorid solution of 1:5000. A mesh of absorbent cotton should be left in the meatus to promote drainage, and the whole ear covered with iodoform gauze, as before described. The result is usually prompt improvement. The hyperemic tissues are relieved of their engorgement, and the pain will have nearly disappeared when the patient returns to consciousness. The incision, although extensive and deep, heals with remarkable rapidity and leaves no visible cicatrix. The after-treatment is the same as in simple paracentesis. However harsh and radical this operation may at first sight appear, it is so generally efficacious that its performance will never be regretted.

In the light of our present knowledge of bacteriology, nearly if not quite all the causes of acute inflammation of the middle ear are only the sources or excitants of bacteriological activity. No cavity of the body lined with mucous membrane is free from organisms of morbid character, which are

ready to develop with amazing rapidity under favoring conditions ; and the mucous membrane is a soil always ready to receive and nurture germs of the most virulent character. The nose and the fauces are always exposed to infection through the air ; and that such infection is not always taking place shows what a wonderful defensive power against such morbid germs must exist when not in abeyance owing to disturbing influences. Usually the infection is at first by a single organism, either that of the systematic disease, of which the nasal trouble is a local manifestation, or by one of the less virulent forms, which has for some reason been called into activity. After the opening of the drum cavity by spontaneous or artificial means reinfection may take place, and a variety of the most dangerous cocci, with their foul odors and poisonous products, complicate the disease. Hence the necessity of maintaining the strictest antiseptic and of abandoning many of the remedies and means of treatment which formerly seemed to be most strongly indicated.



# CHRONIC CATARRH OF THE MIDDLE EAR.

BY EDWARD B. DENCH, PH.B., M.D.,  
OF NEW YORK CITY.

THE term *chronic catarrh* has, in my opinion, led to a very general misunderstanding among the medical profession in regard to the changes which take place in the middle ear in the disease under consideration. It would be much better to designate this affection as *chronic non-suppurative inflammation* of the middle ear. The word *catarrh* is so universally associated with some affection of the upper air-tract, that both the profession and the laity have come to look upon a chronic catarrhal otitis media as the result of an extension of an inflammatory process from the nose and naso-pharynx into the tympanum by contiguity of structure. Catarrh is not a disease, but a symptom, and from its derivation means a discharge. It may, therefore, result from various local lesions, and the idea so commonly entertained that catarrhal inflammation of the middle ear is always due to the extension of an inflammatory process from the nose or naso-pharynx is entirely unwarranted. The influence exerted by any affection of the nose or naso-pharynx is usually purely mechanical. Thus, in the case of adenoid vegetations within the naso-pharynx, the middle ear may suffer either from the direct pressure of the lymphatic tissue upon the mouth of the Eustachian tubes, causing a rarefaction of the air within the tympanum; or this lymphatic tissue may interfere with the return circulation from the tympanum, thus causing a dilatation of the veins within this cavity, and consequent congestion of the lining membrane. The obstructive lesions of the nose and naso-pharynx cause chronic middle-ear disease chiefly through their influence upon the tympanic blood current.

**Etiology.**—Chronic non-suppurative inflammation of the tympanum may follow an acute inflammation of the middle ear, or may be the result of repeated mild attacks of acute congestion of the parts, each successive attack slightly impairing the function of the organ. On the other hand, the disease may be so insidiously progressive from its beginning as to give no symptoms until it has existed for many years.

Heredity is supposed to be an important etiological factor. From my own observation, I am inclined to attach less importance to heredity than do most writers. It is true that we often find impaired hearing in successive generations of the same family. When we examine these cases, however, we not infrequently learn that the impairment in hearing has not been due to similar middle-ear conditions. The history is an unsafe guide in determining the etiological importance of heredity. The patient simply remembers that other members of the family have suffered from an affliction similar to his own, but can naturally give no information as to the nature of the local lesion. It would be absurd to suppose that a suppurative otitis media, causing impairment of hearing in one member of the family, should be at all responsible for

interference with audition in successive generations. My own belief is that certain conditions of the nose and naso-pharynx, such as enlargement of the pharyngeal tonsil, relaxation of the turbinal tissue, enlargement of the faucial tonsils, etc., are hereditary. Any of these conditions predispose to inflammation of the middle ear; yet, in many instances, they exist without producing this result.

Occupation exerts an important influence, in that those who are obliged to endure exposure to sudden and severe changes in the weather are more commonly affected than those whose vocation enables them to guard against such unfavorable conditions. For this reason we find that the disease is more common in males than in females.

The various general diatheses, such as the rheumatic or gouty diathesis, can scarcely be looked upon as influencing the occurrence of the affection. The habits of life are factors, however, in producing disease. The abuse of alcohol or tobacco, prolonged mental or physical exertion, or, in fact, anything which tends to lower the general condition, may act indirectly as a cause for the disease under consideration. In certain slowly progressive cases the local affection seems to be due to interference with the trophic nerve-supply of the middle ear. This causes an impairment in nutrition of the tissues, and certain structural changes follow which lead to either a perversion or impairment of function.

As before stated, a large proportion of cases are associated with some obstructive lesion of the upper air-tract. This is particularly true where the chronic process follows repeated attacks of acute inflammation.

Of these local causes, the most important is probably enlargement of the pharyngeal tonsil. Enlargement of the faucial tonsils alone is seldom responsible for middle-ear involvement. As enlargement of the faucial tonsils is almost invariably accompanied by a similar condition of the pharyngeal tonsil, the etiological importance of the former can hardly be determined with certainty.

Affections of the nasal cavities, such as hypertrophic rhinitis, nasal polypi, deformities of the nasal septum, etc., act essentially in the same way as does enlargement of the pharyngeal tonsil. These conditions either cause a rarefaction of the air within the tympanum, or interfere with the blood supply directly.

In atrophic rhinitis I am inclined to believe that the process within the middle ear is a simple concomitant of the nasal disease, and not a sequel to it. Atrophic rhinitis depends upon impaired nutrition of the lining membrane of the nasal chambers. A similar condition in the middle ear would be more probably due to a cause similar to that producing the nasal lesion than to this local disorder itself.

**Pathology.**—Non-suppurative inflammation of the middle ear may be either hypertrophic or hyperplastic in character. By the hyperplastic form I mean a condition ordinarily known as *sclerosis of the middle ear*, which may occur either as an idiopathic affection or as the result of a preceding hypertrophic condition.

*Hypertrophic Inflammation.*—The mucous membrane within the tympanum is swollen, the blood supply is increased, and at length, actual tissue hypertrophy occurs. The Eustachian tube, forming as it does a portion of the middle ear, participates in these changes. The mucous membrane is edematous, and the lumen of the tube is diminished in caliber. In the earlier stages the membrane of the tube is simply swollen, there being no tissue hypertrophy. This is particularly true of those cases which follow

acute catarrhal otitis media, or where there have been recurrent attacks of acute congestion. If this engorgement continues, there is a development of new connective tissue within the walls of the tube, and the passage gradually becomes more and more contracted. As a result, the intratympanic pressure is diminished, and the drum membrane and ossicular chain are forced inward toward the inner bony wall of the middle ear. The drum membrane is gradually stretched, so that when the caliber of the tube is restored, the drum membrane is much relaxed. Certain inflammatory changes take place in the middle ear, depending directly upon the displacement of the tympanic membrane and of the ossicular chain. The crowding of the ossicles against each other and against the internal tympanic wall aggravates the inflammatory process within the middle ear. As a result, adhesions are formed between the inner wall of the tympanum and the ossicular chain. The tensor tympani muscle gradually atrophies from disuse, the muscular fibers disappear and are replaced by connective tissue. After this has occurred, even if the Eustachian tube regains its normal caliber, the malposition of the ossicles and membrane persists owing to the rigidity of the atrophied tensor tympani. If the drum membrane is atrophic, it may bulge into the canal upon inflation beyond the plane of the annulus, the ossicular chain remaining immovable.

We have spoken of the development of adhesions between certain portions of the ossicular chain and the adjoining bony walls of the middle ear. While this process may take place in any portion of the cavity, it occurs most frequently in the region of the oval window. The adhesions are most frequently found either between the posterior crus of the stapes and the corresponding wall of the oval niche or between the crura and inferior wall. Less frequently adhesions develop above the stapes or in front of it.

In certain instances the inflammatory process is exceedingly slow. It is in these cases that we often find a serous effusion in the tympanum, the engorged vessels unloading themselves of the fluid elements of the blood. Such an effusion may fill either the entire tympanic cavity or may be sacculated in the reduplications of the mucous membrane.

When the hypertrophic process changes to the hyperplastic variety, the cellular elements of the newly-formed connective tissue are changed into dense fibrous tissue. In the Eustachian tube this transformation causes the stenosis to disappear, and the canal may become even abnormally wide. We frequently find, therefore, that although the tube is perfectly free, the hearing is greatly impaired. Where the process is hyperplastic from the first, the lining membrane of the middle ear is gradually transformed into dense fibrous tissue.

Increased tension within the middle ear causes increased labyrinthine pressure; and in cases of long standing the perceptive portion of the auditory apparatus seldom escapes entirely.

The actual changes which take place within the labyrinth are sometimes the result of a chronic inflammatory process induced by this increased pressure. Where no pathological lesion can be demonstrated by microscopic examination, it seems that the function of the auditory nerve is to an extent ablated from disuse.

The disease in question is seldom unilateral, both ears, as a rule, being involved. Rarely, however, are both organs affected to the same extent, the disease usually beginning upon one side, and attacking the other at a later period. In the slowly progressive cases the disease may be so insidious as to entirely escape the patient's attention until the second organ is involved.



This secondary process seems to particularly affect the perceptive apparatus, although the middle ear does not entirely escape.

**Symptoms.**—These depend upon the particular course pursued by the disease. Those cases following acute inflammation will naturally give a history of successive attacks of otalgia. In the slowly progressive cases, however, pain is not a prominent symptom, whether the disease is of the hypertrophic or hyperplastic variety. The symptom which first attracts the patient's notice is usually the appearance of subjective noises. These vary greatly in character in different cases. The patient will sometimes complain of a pulsation in the ear, synchronous with the cardiac pulsations. In other instances the noise may be described as a deep rumbling sound; again, it may be high-pitched, and is often compared by the patient to the sound of escaping steam. These noises may be constant or intermittent. They are usually exaggerated by physical or mental exertion, by a cold in the head, or by impairment of the general condition. Especially in the hyperplastic form of the disease the subjective noises may attract the attention of the patient before any defect in hearing is discovered; but sooner or later the impairment in audition will be recognized.

The hearing may be considerably impaired before the patient becomes conscious of the fact. For this reason, cases seldom present themselves in the very early stages of the disease, but only when the hearing has fallen considerably below the normal standard. Patients usually notice that, while in dialogue the hearing is fairly perfect, they are unable to hear clearly when several are talking at the same time. Various sounds, such as the tick of a watch, the sound of the acoumeter, etc., may be perfectly heard, and yet the patient will be conscious of a certain deficiency in hearing. It often happens that the power of audition fluctuates greatly. At times the hearing will be excellent, while at other times the impairment will be quite pronounced. A common complaint is that the hearing becomes less acute whenever the patient has a "cold in the head," and not infrequently that after each successive attack it remains less acute than before. It is not uncommon for the hearing to be greatly influenced by certain muscular movements; thus, many hear less acutely while masticating the food than at other times. The acts of mastication and deglutition may also be accompanied by clicking or snapping sounds in the ear due to the separation of the walls of the Eustachian tube by the contraction of the palatal muscles.

Again, the hearing may vary with the position of the head. In the erect posture it may be perfectly normal, while on lying down or on tilting the head far back it may be greatly impaired. This symptom usually indicates the presence of fluid in the tympanic cavity. When the head is tilted backward, the fluid flows into the posterior portion of the tympanum and covers the oval and round windows, thus interfering with sound-conduction. When, however, the head is bent forward or held erect, the fluid changes its position, leaving these regions free.

While vertigo is not a common symptom in these cases, it is occasionally met with, and may be very pronounced. This is particularly true where there is a collection of fluid in the tympanic cavity, the vertigo becoming very severe when the position of the head causes the fluid to cover the oval and round windows.

It must not be understood that the presence of fluid in the middle ear is the sole cause of tympanic vertigo. While dizziness is not a common symptom in these cases, it is by no means a rare one, and is sometimes exceedingly severe. The pressure upon the labyrinth, due to increased tension of the



ossicular chain from the development of adhesions, is sufficient to cause the symptom. It may be said, in this connection, that the length of time which a vertigo has persisted is no indication that relief will not be obtained by relieving the middle-ear condition. If examination by means of the tuning-forks shows that the middle ear alone is involved, the results of treatment are usually satisfactory. It might appear that, in cases of long standing, relief of the increased labyrinthine pressure could be obtained by surgical measures only. This is not the case, however; and we often find that the restoration of the Eustachian tube to its normal caliber will immediately relieve the vertigo.

Most of these patients hear better in a noise than in a quiet place; and, under the same conditions, the subjective noises are often less severe. This is explained by the fact that, when the ossicular chain is rigid, a certain amount of force is necessary to set it in vibration. When, however, the resistance has been overcome, very slight variations in this force are recognizable. For this reason, these patients usually hear better in a railroad train than does an individual with normal hearing (paracousis Willisii).

As the disease advances, the subjective noises, which at first have been distressing, may become less severe or disappear entirely. This is usually indicative of labyrinthine involvement, and is probably due to the fact that the portion of the perceptive apparatus concerned in the recognition of sounds of this particular character has been destroyed.

The appearance of tinnitus in the previously healthy ear should always be looked upon as a grave symptom. The sounds are generally of a high pitch, and probably depend upon certain changes in the cortical auditory area. As we know, each cortical auditory center receives fibers from both auditory nerves, but chiefly from the nerve of the opposite side. When the labyrinth of one side is involved as the result of chronic middle-ear inflammation, the opposite cortical auditory center is affected, and, as the disease progresses, this cortical lesion interferes with the function of those fibers from the labyrinth of the same side, so that the disappearance of tinnitus in the ear first involved is usually followed by subjective noises in the opposite ear.

**Diagnosis.**—**Physical Examination.**—The changes visible upon speculum examination often give no indication of the degree of impairment of function. The drum membrane may appear fairly normal as regards position, color, luster, and structure, and yet the hearing may be very much impaired. On the other hand, fairly good hearing may exist where the drum membrane and ossicular chain give undoubted evidence of intratympanic inflammation. The most common change is displacement of the drum membrane inward. The handle of the malleus is fore-shortened, and the short process is unduly prominent. The tympanic membrane itself may be thickened over certain areas and atrophic in other parts. A fore-shortening of the handle of the malleus indicates displacement of the ossicular chain inward. In many cases this retraction is but slight, and yet extensive changes have taken place in the middle ear. Adhesions within the tympanic cavity may cause a rotation of the malleus upon its long axis, so that the manubrium may appear broader than normal. Here the direction of rotation is from behind forward. Rotation in the opposite direction is accompanied by considerable retraction of the tympanic membrane, and the manubrium appears narrower than normal from the fact that the edge of the prismatic shaft is presented to view instead of the broader external border.

The presence of adhesions can be demonstrated by the use of the Siegle speculum. Examination with this instrument will show that the drum mem-

brane and ossicular chain no longer move outward as a whole, when the air in the canal is exhausted. With each act of rarefaction, certain portions of the drum membrane will be drawn outward, while the ossicular chain will either remain immovable, or more frequently the handle of the malleus will seem to rotate upon its long axis, motion outward being prevented by adhesions to the internal tympanic wall.

In the hyperplastic variety of the disease, atrophy of the tympanic membrane is commonly present. This may be so marked as to render the structures in the middle ear clearly visible. In the upper posterior quadrant the descending process of the incus, the posterior ends of the stapes, and the tendon of the stapedius muscle can frequently be recognized. Owing to the tenuity of the membrane it is often found to be relaxed as the result of sudden and violent changes in the intratympanic pressure.

Catheterization in the hypertrophic cases shows a narrowing of the Eustachian tube, most marked upon the more affected side. If there is fluid in the tympanum, its presence will be characterized by bubbling or crackling noises as the air enters the cavity. Extensive adhesions within the tympanum will occasionally produce creaking and strident sounds upon catheter inflation.

In the hyperplastic variety of the affection the Eustachian tube will be found abnormally wide, air entering the middle ear very freely. Sometimes one tube will be abnormally patent, while the other is narrow. This simply means that the process has advanced farther on one side than on the other, and that in the ear first affected the hypertrophic process has changed to the hyperplastic form.

**Functional Examination.**—In investigating the hearing, we have to deal first, with quantitative, and, second, with qualitative, audition.

By quantitative audition we mean the distance at which any given sound, such as the tick of the watch, the click of the acoumeter, or the sound of the human voice, is heard, as compared with the distance at which the same sounds are perceived by the normal ear. Qualitative audition, on the other hand, is the perception of all sounds of the musical scale between the certain limits—these limits being known as the lower-tone limit and the upper-tone limit. The lowest musical tone perceived by the human ear is one in which the sounding body makes sixteen double vibrations per second, and the highest musical note recognizable is one in which the vibrations are repeated not less than 32,500 times per second. All intermediate notes between these limits are perceived under normal conditions. Obstruction to sound-conduction is characterized by the imperfect audition of particular notes in the musical scale, no matter whether this obstruction is located in the external auditory meatus or in the middle ear. The conducting mechanism is chiefly concerned in the transmission of the lower notes of the musical register, and in disease of the conducting apparatus hearing is first impaired for the lowest notes of the scale.

(1) *Quantitative Examination.*—In the disease under discussion, tests will show a diminution in the hearing distance, both for sharp sounds, such as the watch or acoumeter, and for the human voice. Of these two means of testing, the human voice is always preferable, and for purposes of comparison the whisper should be used. The patient should not be allowed to become familiar with particular words or sentences, and, therefore, numbers of two figures are commonly employed in testing. In examining one ear the patient should be directed to close the other with the finger, and to close the eyes also, in order to avoid the possibility of lip-reading. The patient is then

requested to repeat whatever is whispered to him. In addition to numbers, it is also well to employ short sentences. The average distance at which the various test numbers and sentences are heard should be taken as the whispering distance.

It will be found that these patients hear sharp sounds relatively better than they hear the human voice.

(2) *Qualitative Examination.*—To determine the limits of audition, vibrating tuning-forks of various pitch are held close to the ear to be tested, the opposite ear being closed with the finger. The lowest fork heard marks the lower-tone limit. In chronic non-suppurative otitis media the lower-tone limit will always be elevated, the lowest notes of the scale not being perceived. It is noticed, however, that the elevation of the lower-tone limit bears a certain relation to the whispering distance; that is, where the whispering distance is much reduced, the lower-tone limit will be very high; while, if the impairment in function is slight, the lower-tone limit will be more nearly normal. The upper-tone limit may be determined with a fair degree of accuracy by means of the Galton whistle. In cases where the labyrinth has not been involved secondarily, the upper-tone limit will be normal; any appreciable reduction at this end of the scale is indicative of labyrinthine involvement. In uncomplicated cases bone-conduction will be relatively or actually increased, and Rinné's test will be negative. The vibrating tuning-fork placed upon the forehead will be usually referred to the poorer ear, although this is not an invariable rule. This test is of less value in cases of long duration than in those that have existed for a shorter time. It is well known that in cases of long-standing the hearing may be better upon the side first affected than upon the opposite side; in other words, the progress of the disease is much more rapid in the organ involved secondarily. In such cases, Weber's test might be negative; but would still indicate the side upon which the intratympanic changes were more marked.

**Prognosis.**—The prognosis in these cases varies according to the age of the patient, the station in life, occupation, environment, and the duration of the disease. The prognosis is better in the hypertrophic than in the hyperplastic variety. In the hypertrophic form the condition of the upper air-passages is also an important factor in determining the course which the tympanic inflammation will pursue. Where the disease appears late in life the progress is much less rapid than where it affects children or young adults. The station in life is of importance, in that the disease will be less likely to advance in a patient so situated as to be able to guard against exposure to inclement weather, and to avail himself of the advantages of a favorable climate, than in one by whom these precautions cannot be taken. While I do not believe that it is possible to secure permanent improvement in these cases by a temporary change of residence, there can be no question that, if a patient can live permanently in a dry and equable climate, he will be able materially to retard or possibly to stop the progress of the disease.

The length of time that the disease has existed affects to a great extent the prognosis. If of long duration, certain structural changes have probably taken place in the tympanum which cannot be removed by treatment. On the other hand, in the early stage of the disease, when structural changes are less marked, proper treatment may restore the parts to a more normal condition, and will at least stop the further progress of the inflammatory process.

The rapidity with which the affection has advanced must be considered in giving a prognosis. Where the progress has been rapid and both ears have become involved in a short time, a much less favorable opinion can be



given than where the same changes have taken place only after many years. In women any increase in the symptoms at the time of the menopause always warrants a guarded prognosis.

The condition of the upper air-passages exerts an important influence upon the progress of the disease within the middle ear. In many of these cases we find either hypertrophy of the turbinal tissues or a chronic inflammation of the naso-pharyngeal mucous membrane. In the younger patients the pharyngeal vault is often filled with adenoid vegetations. All of these obstructive conditions tend to aggravate the pathological process within the tympanum; and no treatment will be efficacious that does not include the relief of the upper air-passages.

Hyperplastic otitis is but little influenced by nasal and naso-pharyngeal conditions, and very little can be expected from treatment of the throat or nose. Most of these patients give little history of catarrhal trouble. It is quite possible that some pre-existing condition of the nose or naso-pharynx may have induced the aural affection, but in the atrophic stage this influence is no longer active.

**Treatment.**—The treatment depends upon the local condition found on physical examination in connection with the information obtained by a careful functional examination. The measures to be employed are radically different in the hypertrophic and hyperplastic variety of the disease.

It must be borne in mind that the general condition influences the progress of any local inflammation. Therefore, the patient must be kept in the best possible general condition; excessive mental and physical exertion must be avoided, as well as indiscretions in diet, the abuse of alcohol, tobacco, etc. In many of these cases the aural symptoms are aggravated by colds; certain hygienic measures should be adopted, therefore, to render the patient less susceptible to sudden changes in temperature. To this end the daily use of the cold bath should be advised, as well as the complete protection of the body by woollen undergarments.

In the hypertrophic cases one of the first objects of treatment should be to relieve any obstructive lesion in the upper air-passages. Adenoid growths in the naso-pharynx should be removed by operation, and normal nasal respiration should be secured by the correction of nasal obstruction. I do not mean by this that slight deformities of the septum must be corrected by surgical interference. It is only where the abnormality prevents free respiration that surgical interference is necessary.

Regarding the treatment of the middle ear, we find in these hypertrophic cases that the Eustachian tube is narrow. This must be restored to its normal caliber, in order to secure the proper ventilation of the tympanum. While many obtain satisfactory results by inflating with the Politzer bag, I freely confess that in my hands this instrument, as compared with the catheter, has been of little value in chronic cases. By inflation we not only restore the intratympanic pressure, but are able to medicate both the tube itself and the lining membrane of the tympanum by the introduction of various vapors. The current of air acts as a mechanical stimulant to the mucous membrane, both of the tube and tympanum, and this stimulating effect may be increased by the introduction of various vapors, as of menthol, eucalyptol, camphor, benzoïn, iodin, etc.

The introduction of stimulating vapors causes an increased flow of blood to the parts, thus favoring the absorption of any recent inflammatory deposits or relieving chronic congestion due to the lack of vascular tone. When any stimulating vapor is used, it is wise to inflate first with air, until the tube is



fairly patent, and to then introduce the vapor. In this way comparatively little of the vapor escapes into the throat, and irritation of the air-passages is avoided. The particular vapor to be used is largely a matter of individual preference. I have employed for a long time, with considerable success, the vapor given off by the following mixture :

|             |            |
|-------------|------------|
| ℞. Menthol, |            |
| Camphor,    | āā ʒj ;    |
| Tr. Iodi,   | ad. ʒj.—M. |

A pledget of cotton saturated with this mixture is placed in the middle-ear vaporizer. This instrument enables the operator to inflate first with air and then with the vapor, without disturbing the catheter.

If the obstruction in the Eustachian tube is of long standing, it will scarcely yield to inflation alone, and mechanical dilatation by means of Eustachian bougies will be necessary. Bougies of celluloid, whalebone, cat-gut, etc. are objectionable, as they cannot be rendered aseptic by boiling. They are also liable to break during the operation, thus leaving a foreign body in the Eustachian tube. For the last few years I have resorted to the following device : A piece of No. 5 piano wire, two or three inches longer than the Eustachian catheter, is selected, and at one extremity is bent so as to form a small hook about one-sixteenth of an inch long. The hook is then flattened upon the longer portion of the wire so that at this end the wire is doubled upon itself for a distance of about one-sixteenth of an inch. The wire is then passed through the Eustachian catheter until this doubled portion protrudes beyond the tip of the instrument for the distance of an inch and a half. The other end of the wire is then bent at right-angles as it leaves the conical portion of the catheter, so that its further passage through the instrument is impossible. Both the catheter and the wire are boiled to render them aseptic. A little cotton is then wound tightly about the doubled extremity of this wire, which is then drawn backward into the catheter, so that the cotton-tipped end protrudes just beyond the mouth of the instrument. The catheter is then introduced into the mouth of the tube in the ordinary way, and the cotton-tipped bougie is gradually passed through the Eustachian canal until it is felt to enter the tympanum. As the isthmus of the tube lies about an inch beyond the pharyngeal orifice, resistance is felt when the bougie has been introduced about an inch. This resistance is perfectly normal, and should remind the operator that he is approaching the tympanic cavity. A moderate amount of pressure forces the instrument through the bony portion of the tube and into the tympanum. As the Eustachian canal varies somewhat in length in different subjects, great care should be used in the final stage of the operation. If the wire is so bent that it cannot be introduced more than an inch and a half beyond the mouth of the catheter, it is practically impossible to do any damage. It is sometimes necessary to carry the instrument a little further, in order to be certain that it has entered the tympanum. If this operation is performed carefully, it is impossible to do any harm. The operator usually recognizes by the sense of touch that the bougie has entered the tympanum. Frequently the cotton-tipped extremity of the bougie can be seen in the tympanic cavity, through the drum membrane, on speculum examination. The tip of the bougie, under these conditions, appears as a white, opaque object, just behind and a little below the short process of the malleus. Pressure upon the bougie causes the drum membrane to move slightly outward, as can be easily recognized by the observer.

One of the advantages of this device is that, when the cotton is tightly wound upon the wire and introduced into the tube, it absorbs a certain amount of moisture from the membrane, and thus becomes larger; an additional amount of dilatation is secured in this way. Another advantage is, that there is but slight friction between the wire and the catheter, and any resistance to the passage of the instrument must certainly be due to an obstruction in the Eustachian canal.

It is frequently of advantage to saturate the cotton pledget with a solution of nitrate of silver of a strength of from ten to sixty grains to the ounce. In this way the tube is medicated as well as subjected to mechanical stimulation. In hypertrophic cases of long standing, the careful use of the bougie is attended by the most gratifying results.

The injection of fluids into the middle ear through the Eustachian tube has been attended with doubtful benefit. Personally, I have no experience with this method of treatment. There is no reason why solutions should not be introduced into the middle ear in this manner, if both the solutions and the instruments are aseptic. It has always seemed to me to be more simple to medicate the middle ear directly through an opening in the drum membrane, rather than to inject the fluids through the tube.

When the tympanum contains fluid an attempt should first be made to evacuate this by means of catheter inflation. During the procedure the patient's head should be flexed on the chest, and, at the same time, should be inclined toward the opposite side. The current of air entering the middle ear will then displace the fluid and force it out through the Eustachian tube into the naso-pharynx. The use of stimulating vapors in these cases is also of advantage in hastening the absorption of the effusion.

As the persistence of an effusion depends usually upon some obstructive lesion of the nose or naso-pharynx, these parts must be put in the normal condition before permanent relief can be hoped for. If these measures fail, the fluid must be evacuated by incising the drum membrane. The incision should lie in the posterior segment of the tympanic membrane, close to its periphery, and should extend from below the tip of the handle of the malleus upward to the posterior fold. The term so often used, of "puncturing" the tympanic membrane to evacuate fluid, is responsible for many unsatisfactory results. A small opening allows but little of the fluid to escape, and does not empty the cavity. A free incision is necessary in order to secure the desired result. In performing this operation it is well also to incise the mucous membrane over the inner tympanic wall, thus depleting the engorged vessels and rendering recurrence less probable. Such incision is absolutely free from danger if the canal is sterilized before the operation, and if the instruments and the hands of the operator are aseptic. Moreover, the procedure causes but very little pain if a sharp knife is used.

After incising the tympanic membrane, it is often wise to inflate by means of the catheter to completely evacuate the fluid; and in some cases, where the effusion is viscid, it is well to wash out the tympanic cavity, with normal salt solution, through the Eustachian catheter. The incision heals in from twenty-four to thirty-six hours if aseptic precautions have been observed. At the end of twenty-four hours, if the margins of the incision have become agglutinated, it is well to guard against the accidental rupture of the freshly-formed adhesions by means of a paper disk applied to the surface of the drum membrane so as to cover the line of incision. The disk need not be removed by the surgeon, as it will be discharged spontaneously by the outward growth of the epithelium covering the tym-

panic membrane. It may be removed, however, at any time by the use of the ear-syringe.

A favorite plan of treatment in chronic catarrhal otitis media has been the systematic use of passive motion for the purpose of either breaking up or of stretching adhesions which have developed between the ossicles themselves or between these bonelets and the inner tympanic wall.

Lucae<sup>1</sup> has met with considerable success in these cases by the use of the "pressure probe." The device consists of a small tube, through which a rod terminating in a cup-like extremity passes. Within the tube is a small spiral spring pressing against the other end of this rod. The shaft of the instrument is introduced into the canal, and the cup-shaped extremity is applied to the short process of the malleus. By a rapid to-and-fro motion of the instrument the short process is pressed inward and then allowed to spring outward, the amount of pressure being regulated by the tension of the spring. In this manner it is claimed that the adhesions within the tympanum are stretched, and that the function of the ear is, in many cases, improved. I have had no experience with this method, and can, therefore, give no personal opinion as to its efficacy. The procedure is somewhat painful, and has never seemed to me to be free from danger. This I believe to be especially true where the process within the middle ear is not quiescent. Any attempt to forcibly manipulate the ossicles must cause a certain amount of mechanical irritation, and, therefore, must aggravate the condition which it is intended to overcome. This same criticism applies, I think, to modifications of Lucae's method of massage, advocated by Lester<sup>2</sup> and by Garnault,<sup>3</sup> who employ a small electric motor for actuating the masseur.

Systematic massage of the ossicles by alternately condensing and rarefying the air within the external auditory meatus, either by the method of Hommel,<sup>4</sup> by pressure in front of the tragus, or by the use of either the Delstanche masseur or the Siegle otoscope, has also been looked upon with much favor by some. Experience has not taught me that valuable results are obtained by these methods.

As the motions of the ossicular chain under the normal conditions are caused by aerial vibrations, it would seem reasonable that the most proper method of employing massage would be through the agency of some sounding body, and within the last few years various vibrometers, vibrophones, etc. have been devised. All instruments constructed for this purpose have, I think, been useless and worse. There is no question, however, that in certain cases the systematic exercise of the ear by means of the human voice may be of great benefit in improving the function of the organ, and the method has been successfully used by Urbantschitsch.<sup>5</sup> In employing this method it has been my practice to have an attendant read to the patient for a period of from five to fifteen minutes in a voice sufficiently loud to enable him to understand distinctly. Where the impairment of hearing is very marked the conversation-tube may be used, although this should be avoided if possible. It is advantageous, in case the patient understands more than one language, to read in different languages on succeeding days, to accustom the patient to recognize sounds varying widely in character. Such a method is tedious, but is often attended with excellent results. It is particularly advantageous where the ear has been practically useless for a long time and has then improved somewhat from local treatment. Under these conditions

<sup>1</sup> *Archiv für Ohrenheilk.*, vol. xxi, p. 84.

<sup>2</sup> *N. Y. Med. Journ.*, June 8, 1895.

<sup>3</sup> *Précis des Maladies de l'Oreille*, Paris, 1895, p. 246.

<sup>4</sup> *Archiv für Ohrenheilk.*, vol. xxiii, p. 17.

<sup>5</sup> *Horübungen bei Taubstummen*, Wien, 1895.



the auditory nerve seems to have suffered from disuse, and, although perfectly healthy, requires a certain amount of education before it can again perform its function. Here, of course, the procedure is one not only of massage, but, to a certain extent, one of education, familiarizing the patient with the significance of imperfect auditory impressions conveyed to the cortical centers.

**Intratympanic Operations.**—I have endeavored to detail briefly the various methods at our command for the treatment of these cases. When seen in the early stages, inflation, the use of the Eustachian bougie, and the treatment of the upper-air passages often yield excellent results. We frequently, however, meet with cases in which all of these measures fail, the middle-ear changes being so advanced as to render absorption of the new tissue impossible. The Eustachian canal is perfectly patent, the upper air-passages are normal, and the patient is suffering either from the result of a previous inflammatory condition or from a profound trophic disturbance within the middle ear.

I am aware that I stand almost alone in advocating surgical interference in these cases. My opinion is the result of my own personal experience, which has, perhaps, been extensive enough to warrant the position which I take. Where other methods fail, and where careful functional examination shows that the perceptive mechanism is not greatly involved, I believe that it is always wise to do an exploratory tympanotomy. Cocain anesthesia suffices to render the procedure painless, and at the same time is free from the objections attending ether or chloroform narcosis. For purposes of exploration, the tympanic cavity is best entered in the posterior and upper quadrant. In order to gain access to the middle ear, a flap of the drum membrane should be reflected downward and forward, so as to allow inspection of the incudo-stapedial joint and of the regions of the oval and round windows. When done under local anesthesia, the hearing can be tested at various stages during the operation, and if it improves the surgeon may complete the operation. On the other hand, if, after the stapes has been liberated by the division of adhesions in the oval niche and by disarticulation at the incudo-stapedial joint, there is no improvement in the hearing, the flap of the membrana tympani can be replaced and retained in position by means of a paper disk. Under aseptic precautions this operation is absolutely free from danger. If liberation of the stapes improves the hearing, the operator may proceed at once to remove the membrana tympani, malleus, and incus to secure permanent improvement. Excision of the two larger ossicles is performed with perfect ease under cocain anesthesia. I have not infrequently operated upon both ears in the same patient at different times. Had the operation been painful, the patient would scarcely have submitted to a second operation without general anesthesia.

One of the advantages of the procedure above mentioned is its value as a diagnostic measure. There are certain doubtful cases in which functional examination does not enable us to exclude labyrinthine involvement, and yet in which the condition in the middle ear seems to be sufficient to account for the functional impairment. An exploratory tympanotomy enables us to determine exactly how much improvement can be expected from removal of the drum membrane and of the two larger ossicles. If the exploratory operation gives negative results, the flap can be replaced, leaving the ear in the same condition as before operation. We are then certain that the impairment of function is due to some lesion of the perceptive apparatus. We often find, however, that we have underestimated the effect produced by the



middle-ear lesion—the hearing improving beyond our expectations after the stapes has been liberated. In these cases completion of the operation yields very gratifying results.

Middle-ear inflammation upon one side usually leads to impairment of audition on the opposite side. We have to consider, therefore, not only the possible improvement in the ear operated upon, but also the effect of the procedure upon the opposite organ. From a number of my own cases I am convinced that the relief of increased tension in the conducting apparatus upon one side either checks or retards the involvement of the opposite organ, and in many cases improves the ear not operated upon. I should attach no importance to these cases, had they not been so frequent and the fact confirmed by other observers, notably Urbantschitsch.

Operative procedures of this character have been fairly satisfactory in my own practice, and after stating plainly to the patient that improvement cannot be absolutely promised, but that an operation offers the only chance for improvement, and that in a large proportion of the cases this is obtained, I still continue to perform these operations. My own results under cocain anesthesia are as follows: of 64 cases operated upon, 32 were greatly improved, 24 moderately improved, and 8 unimproved. In three of the above cases in which no improvement followed the operation, I should say that I did an exploratory operation only. The functional examination had seemed to demonstrate that the labyrinth was seriously involved, and operation was undertaken only as a forlorn hope. Disarticulation at the incudo-stapedial joint and liberation of the stapes being followed by no improvement, the flap of tympanic membrane was replaced and the ear left in its original condition. In one instance, where functional examination also seemed to show extensive labyrinthine involvement, the hearing was notably improved, not only in the ear operated upon, but also in the opposite ear. The improvement in general audition was so noticeable as to be remarked upon by the patient's friends.

A certain number of cases have been operated upon under ether anesthesia, and the results have been reported in my recent work.<sup>1</sup> For the reasons already stated, I always prefer to operate under cocain anesthesia.

Concerning the efficacy of constitutional treatment in chronic catarrhal otitis little can be said. Measures for improving the general health of the patient will naturally suggest themselves to the medical attendant. Where the labyrinth has been involved secondarily, the internal administration of pilocarpin may be tried. The results, however, are much less satisfactory than in cases of primary labyrinthine disease. In neurasthenic patients general medication and attention to hygiene will often do much to improve defective audition. Here strychnin in large doses and long continued is particularly valuable. I ordinarily begin with  $\frac{1}{40}$  grain three times daily, and gradually increase the dose until the patient is taking  $\frac{1}{20}$  grain four times daily. A fact which is often lost sight of is the fatigue which impairment of hearing causes, the patient making every exertion and fixing his whole attention in order to overcome his affliction.

Certain drugs have been recommended for the relief of tinnitus. My own experience has been that all are usually unsatisfactory. We may except, perhaps, large doses of hydrobromic acid, which afford sometimes relief. Naturally, if the general condition of the patient indicates the necessity for certain medication, such medication may incidentally relieve the subjective noises; but where the general condition of the patient is normal, very little relief can be obtained by internal medication.

<sup>1</sup> *Diseases of the Ear*, New York, 1894, p. 512.

# CHRONIC SUPPURATION OF THE MIDDLE EAR.

BY ALBERT H. BUCK, M. D.,  
OF NEW YORK CITY.

---

**Etiology.**—The causes of a chronic discharge from the middle ear are generally to be sought for in some primary acute inflammation of this region. In a few instances—as in the case of tubercular disease, there may be an entire absence of anything like an antecedent acute stage; and if present, our knowledge of the probable protracted continuance of the discharge justifies us in placing these cases at the very start in the category of chronic suppurative affections.

It was a widely accepted doctrine, ten or fifteen years ago, that a chronic suppuration of the middle ear almost invariably indicated either neglect or a lack of skill, experience, or courage on the part of the medical man who had the management of the primary acute attack. To-day, our better knowledge of the all-potent influence of micro-organisms in inflicting those lesions which determine, in most cases, the feature of chronicity, leads us to pass a more lenient judgment upon these men. Nevertheless, this earlier doctrine must still be accepted as fundamentally correct.

Aside from these few direct etiological factors, there are others which, although by no means direct causes, nevertheless play an important part in perpetuating the suppuration. There are three such favoring factors, viz.:

1. Lowered vitality.
2. Stagnation (intratympanic) of the fluid and solid constituents of the discharge.
3. The presence of a mass of hypertrophied lymphoid tissue in the vault of the pharynx.

Farther on in this article I will return to this subject and give it further consideration.

The influence of diabetes mellitus in favoring the development of wide-spread and deep-seated inflammation of the middle ear has doubtless received due consideration in the article relating to acute suppuration. It is in these cases, rather than in those of a chronic character, that this influence makes itself chiefly felt.

**Pathology.**—The cases of chronic suppuration of the middle ear which are encountered in practice may readily be subdivided, for our convenience in studying them, into three different and fairly distinct types or groups:

Group I. includes all those cases in which the tympanic membrane is usually perforated somewhere in the lower half, and in which no evidences of active inflammatory disturbance are discoverable. The discharge is scanty and free from any unpleasant odor. It is sero-purulent in character, but often has some admixture of mucus. At times it may cease altogether for a period of several days or weeks. Adults are affected less frequently than children.

This is the mildest type of chronic middle-ear suppuration of which I

have any knowledge; and the cause of the non-subsidence of the discharge may be set down as a lack of tone in the blood-vessels of the tympanic mucous membrane—a *vaso-motor paresis*. In so far as this lack of muscular tone affects the blood-vessels of the mucous membrane of the Eustachian tube, we may expect to find a greater or less quantity of mucus intermingled with the discharge. In many of these cases a depreciated condition of the general health—a *lowered vitality*—plays an appreciable part in the persistence of the disease.

Group II. differs from the preceding group in only one essential respect: the discharge consists largely of ropy mucus, and the main cause of its persistence is to be found in the *presence of hypertrophied lymphoid tissue in the vault of the pharynx*. The latter condition not only excites a catarrhal inflammation of the tubal mucous membrane, but also causes the lower portions of these channels to become so narrowed that the secretion—the ropy mucus—cannot escape in the natural manner into the pharynx, but finds an easier outlet for itself in the opposite direction—*i. e.* into the middle ear and through the perforation into the external auditory canal. In these cases, as in those of the preceding group, the discharge is apt to be intermittent, sometimes stopping altogether during the summer months, and is entirely free from any unpleasant odor.

Group III. is characterized by several features which distinguish it fairly well from the other two groups. In the first place, the discharge is more distinctly purulent in character, but not necessarily any more abundant in quantity. It is apt also to have an unpleasant odor—sometimes positively fetid in character. An admixture of blood is not rarely observed; and, in addition to the fluid pus, we occasionally find some which has become inspissated until it resembles soft cheese.

In cases of long standing, desquamated epithelium is apt to form and accumulate in the recesses of the middle ear. Small flakes of it are also often found in the discharge, and at times even larger masses may escape spontaneously from the tympanum.

The actual lesions which lie at the foundation of the manifestations just described are localized areas of proliferative activity on the part of the tympanic mucous membrane, and often, at the same time, a more or less limited caries of the adjacent bone-tissue.

The location of the perforation in the membrana tympani is usually higher in this third group than in the other two. The posterior half, or

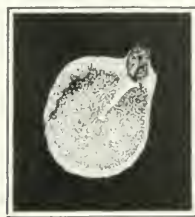

FIG. 499.—Right *mt.* showing malleus-head through a Shrapnell perforation, and up and back a slit-like opening with granular posterior lip, such as commonly marks caries of the incus and the adjacent tympanic margin.



FIG. 500.—Reniform perforation at umbo and smaller opening above short process. Hyperplasia down and back, marking probable caries at this margin and in the "hypo-tympanic space."

the posterior superior quadrant (Fig. 499), is the common site in a large number of instances. The flaccid membrane is perforated (Figs. 500, 501)

in a much smaller number of cases; and, finally, in comparatively rare instances a sinus in the bone, above or behind the tympanic membrane, serves as the outlet channel—the mechanical equivalent of the perforation—for all the products of intratympanic inflammation.

Finally, sclerosis of the mastoid process is so uniformly found to be associated with chronic suppuration of the antrum and vicinity that we are warranted in setting it down as one of the fixed characteristics of this third

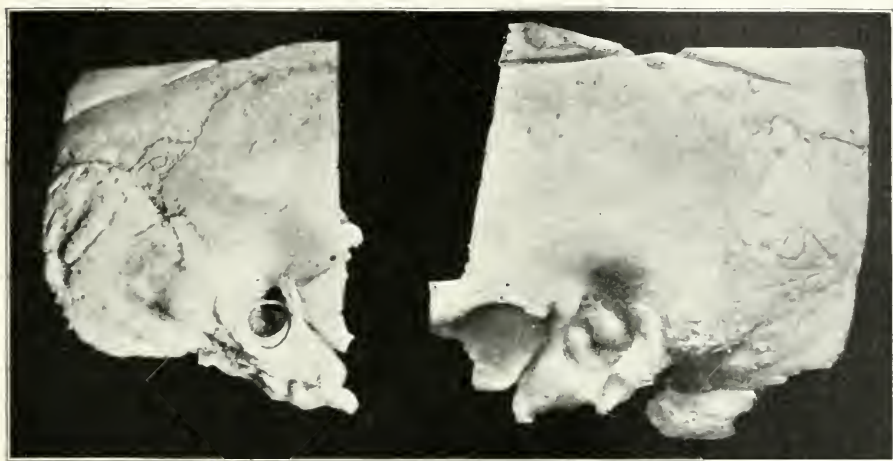

FIG. 501.—Left temporal of a child (right figure), showing bulging of upper back and lower front portions of drumhead. On the right a large central perforation is separated by a narrow band from the upper opening due to total loss of the flaccid membrane. All trace of the malleus is lost, but the incus and stapes seem normal (Dr. Randall's collection).

group. The practical importance of this fact becomes apparent when an attempt is made, in a case of chronic suppuration of the middle ear, to determine how seriously the antrum and neighborhood are involved. Before this law of mastoid bone sclerosis, or hyperostosis, was known, it was a frequent thing for physicians to deny the existence of any serious disease of the antrum because there were absolutely no outward manifestations of any such disease—no redness or swelling of the skin, no tenderness upon pressure over the mastoid process. The sclerosed condition of the overlying bone (Fig. 502), as we now know, offers an impenetrable wall to the advance of any such central focus of inflammation; and this sclerosis, as I have just stated, may be assumed to exist in every one of the cases belonging to this third group. It is therefore clear that in estimating the gravity of the deeper-lying disease in this class of cases we are not permitted to attach the slightest importance to the absence of outward evidences of inflammation.

The following pathological alterations and products observed in the cases which belong to this third group deserve further consideration: granulation-growths or polypi, bone caries, desquamated epithelium, and accumulations of cheesy pus.

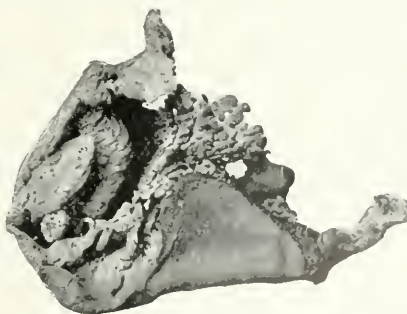


FIG. 502.—Metal cast of sclerosed mastoid in which but two large cells near the tip remain pneumatic. Contrast with Figs. 453, 454 (Randall).



*Granulation-growths* are extremely common in the middle ear in cases of chronic suppuration. They may develop at almost any point, but they are found oftenest, I think, at the lower margin of the entrance to the mastoid antrum. Their size is very variable, the largest one I have ever encountered measuring an inch and three-quarters in length. They are the product of an irritation applied to the tympanic mucous membrane at the localities from which they spring. This irritation may have been applied at the time of the original acute inflammation—an invasion of micro-organisms, for example, having stimulated the connective tissue of the mucous membrane to assume proliferative activity. Or the irritation may be of later date, and may even still, at the time when the growth is discovered, be in active force. Thus, for example, a small area of bone caries in the antrum, or at the point where it becomes merged in the cavity proper of the tympanum, is apt to secrete a very irritating pus of an almost corrosive character; and the constant flow of this over the tympanic mucous membrane soon causes the latter to proliferate and ultimately to form a mass of granulation-tissue, or a “polypus”—the term commonly employed when the mass has attained fairly large proportions. Then again, stagnating pus (independently of bone caries), in which the bacteria of decomposition are active, may also exert an irritating influence strong enough to cause proliferation of the mucous membrane with which it comes in contact.

In dealing with cases of this character, therefore, we are warranted in attributing the presence of the granulation-tissue either to bone caries or to stagnating and foul pus escaping from some point close at hand, and we should accordingly search for these conditions in every such case.

Superficial areas of *bone caries* are very often encountered in cases of chronic suppuration of the middle ear; in fact, it is no exaggeration to say that this lesion is the main if not the exclusive cause of the chronic discharge in the great majority of instances.

While the promontory or inner wall of the tympanic cavity and the region bordering on the tympanic orifice of the Eustachian tube are rarely the seat of a bone caries, every other part seems to be predisposed to the disease to an almost equal degree. The most extensive areas are doubtless those which involve the antrum. Smaller ones are found in the tympanic roof, at the posterior end of the tympanic cavity, on its floor, and finally on either the body of the anvil or the head and neck of the hammer. When caries involves such slender structures as the long process of the anvil, the lower half of the handle of the hammer, and the crura of the stirrup, these soon disappear altogether.

It is a very difficult matter to determine to what extent the ulcerative action is progressive. One thing, however, is certain, viz., that if foul pus, cheesy material, and desquamated epithelium be not allowed to remain for any great length of time upon the surface of such an area of bone ulceration, all carious activity promptly ceases.

It is also not entirely clear how bone caries is originally established in the middle ear. In former years it was customary to look upon the prolonged continuance of a high degree of intratympanic pressure as the chief cause of the trouble. Such pressure is undoubtedly competent to interfere seriously with the nutrition of the mucous membrane thus pressed upon, and ultimately with that of the underlying bone, which derives a large part of its nourishment from this mucous membrane. But it is now believed that the pressure simply plays the part of a favoring circumstance, and that the active factor in the process is the streptococcus or some other variety of

micro-organism. These harmful agents first destroy the mucous membrane at a given point by entering into its blood- and lymph-vessels, thus shutting off its supply of nutriment, and then, as is almost certain, they in turn invade the adjacent bone-tissue and destroy that to a certain depth.

Accumulations of *desquamated epithelium* in the form of concentric laminae or sheets are occasionally found in the antrum or in the epitympanic space. Such masses are often bulky enough to interfere seriously with the drainage of the cavity which they may happen to occupy, and by thus imprisoning the pus and other matters discharged they favor the development in them of putrefactive changes, which in turn stimulate the further production of epithelial laminae. There is also reason to believe that the persistent expansive pressure exerted by such an elastic mass is competent to cause an absorption of the surrounding bony walls, thus leading ultimately to the formation of one of those large cholesteatomatous cavities containing cheesy material, cholesterol crystals, and concentric layers of desquamated epithelium which are occasionally encountered in dispensary, but rarely in private, practice (see pages 661 and 753).

Accumulations of *cheesy pus* owe their existence to those different factors which interfere with good drainage, as, for instance, a small perforation in the tympanic membrane, an indirect or tortuous outlet channel (a sinus in the bone, or an opening in the flaccid membrane), granulation-tissue, desquamated epithelium, etc. This condition and that described in the preceding paragraph go hand-in-hand and are scarcely separable.

**Diagnosis.**—The first duty of the diagnostician is to ascertain to which of the three groups enumerated above the case in hand belongs. If he begins, as very many men are apt to begin, by syringing the external auditory canal with tepid water, he will not gain as much knowledge in regard to the character of the discharge, its total quantity, and the particular direction from which it comes, as he would if he were to quietly remove it, little by little, with the aid of a cotton-carrier and small mops of absorbent cotton. By means of these he should have no difficulty in removing every particle of free fluid discharge from the walls of the canal, from the outer surface of the drum membrane, and even from a large part of the middle ear, when an adequately large perforation gives access to the cavity. In addition to whatever fluid may be present, there are often crust-like formations which must be removed before the tympanic membrane and surrounding portions of the auditory canal can be satisfactorily seen. Delicately constructed ring-shaped cures with nicely rounded edges will be found to greatly facilitate the task of removing these obstructions. When once this has been accomplished, the physician will be in a position to determine more or less accurately the source of the discharge. If he has found, on removing the latter with his mops of absorbent cotton, that it is free from any unpleasant odor and is either sero-purulent or muco-purulent in character; and if, besides, the perforation be found to occupy a position in the lower half of the membrane, he may consider this part of the examination as practically completed. If the perforation is of small size—as it is very apt to be in the cases which belong to the first two groups—polypoid masses or granulations are very unlikely to be present in the cavity of the middle ear, and he may therefore abstain from attempts to explore the latter with a probe. The vault of the pharynx is the region which next demands attention, and upon the results of the examination of this region will depend the settlement of the question whether the case belongs to the first or to the second of the groups mentioned.

As already stated, the presence in the external auditory canal of a bad-smell-

ing discharge, or of one which is distinctly purulent (like creamy pus) in character, suggests the likelihood that bone caries, or granulation-processes, or both, exist somewhere in the middle ear; and that with these pathological processes is associated some kind of obstruction to the free escape of the resulting fluid and solid products. In this third group, therefore, the physician is called upon to enter the drum cavity with a suitable probe and to ascertain, if he can, just what are the true relations of things in each individual case.

When the perforation is located in the lower half of the drum membrane, the physician will not be able to explore the epitympanic space and the vicinity of the antrum, and fortunately these are the very cases in which such exploration is least often needed. If, however, it should seem necessary to explore these upper regions, what remains of the posterior half of the drum membrane may be excised and the required amount of room obtained in this manner. When this has been accomplished, or when the perforation already existing occupies the posterior superior quadrant, the entrance to the antrum and a large part of the epitympanic space or vault of the drum cavity may be reached with the end of the probe bent at nearly a right angle. The anterior end of this vault and the head of the hammer can only be reached when there is a perforation in the anterior superior quadrant or in the region of Shrapnell's membrane.

Granulation-growths or polypi, collections of cheesy pus or of cast-off epithelium, and an exposed surface of bone, or perchance a loose fragment of bone are the objects whose presence may be demonstrated by the skilful employment of a slender bent probe. The same instrument may also give information in regard to the absence of one or more of the ossicles, and it is competent to reveal to us the existence of pockets or sinuses in the bone, or of enlargements of pre-existing cavities (like the antrum) through destruction of the surrounding bony walls.

Probes made of coin silver are sometimes a little too stiff for use in exploring the middle ear. We should therefore have in our supply some which have been made of pure (unalloyed) silver, which can be given any desired curve with great ease. The tip should be expanded into a small knob; the stem should be very slender for a distance of at least two inches and a quarter; and, finally, the handle part of the instrument should be either four- or six-sided, and, proportionately to the stem, fairly thick.

It seems scarcely necessary to add that the physician who thus explores the recesses of the middle ear with a bent probe should have in his mind a well-defined picture of the relations of all the different parts; and the importance of delicacy of touch in the safe management of such an instrument must also be emphasized. The main thing is not to disturb the connections of the stirrup, through fear of injuring the hearing. But if this little bone has already been destroyed by disease, the need for such special care, as a matter of course, disappears.

**Prognosis.**—The cases which belong to the first group are of a mild and harmless nature. Even the hearing may be impaired to only a trifling degree; and besides, the interests of the fellow-ear are in no degree dependent upon the one which is affected with a discharge. Furthermore, if the disease is allowed to run its course without any treatment, the worst that may happen is, that the discharge will continue indefinitely to annoy the patient to a greater or less extent. The outlook, therefore, is not in any sense bad in cases of this kind. On the other hand, the arrest of the discharge may usually be obtained by proper treatment, but the permanency of this arrest cannot be guaranteed; for so long as a perforation in the drum membrane exists,



the middle ear will show an increased sensitiveness to sudden changes in temperature, and will be liable to the entrance of irritating matters by way of the external auditory canal. Consequently, relapses will be likely to occur.

Equally mild and harmless are the cases which belong to the second group, but nevertheless they cannot always be considered—as may generally be done in regard to those which belong to the first group—solely with reference to the interests of the discharging ear. The fellow ear, if it possesses an intact drum membrane, is even more seriously imperilled by the presence of a mass of hypertrophied lymphoid tissue in the vault of the pharynx; and on this account, if not in behalf of the discharging ear, the physician is not permitted to speak of the case as being of a mild and harmless character.

On the whole, I believe that treatment is more uniformly successful in these cases that belong to the second group than in those belonging to the first. The perforation is more likely to heal after the mass of lymphoid tissue has been removed, and relapses are less frequent; for the lack of tone or the lowered vitality, which plays so important a part in the cases of the first group, is not an essential characteristic in these.

Very few cases which belong to the third group can be spoken of as being entirely free from elements of danger. When the perforation in the tympanic membrane is large enough to afford ample drainage outward into the external auditory canal, and when the source of the discharge is located at the posterior end of the middle ear proper (*i. e.* outside of the antrum) or at some point in the floor of that cavity, we may pronounce the case to be reasonably free from danger to life or health, even if no treatment whatever be carried out. But when the lesions upon which the discharge depends are located in the vault of the tympanum or in the antrum, the danger to life and health must be looked upon as—from this point alone—greater; and the precise degree of the danger depends upon the extent to which the free escape of the discharge is interfered with.

Certain danger-signals sometimes appear in the course of these chronic cases of suppuration of the middle ear, and show us the necessity of interfering promptly and radically if we wish to avert a fatal catastrophe. Intercurrent attacks of pain in or around the affected ear, paresis or paralysis of the corresponding facial nerve, evidences of disturbance of the circulation in the fundus of the eye, the development of metastatic abscesses or of the condition known as septicemia—these are the more important danger-signals which cannot safely be disregarded and which call for a grave prognosis. They indicate that at last the barrier which separates the focus of disease from the dura mater, or from the facial nerve, or from one of the venous sinuses which are so closely related to the bony surroundings of the middle ear, has been or is about to be broken down. In rare cases the signals are lacking, and the catastrophe arrives before we have time to ward off the danger.

Finally, the conditions present in these cases of chronic suppuration, especially in the young, are often such as to invite an invasion of tubercle bacilli; and tubercular disease of the bone in this part of the skull, if not eradicated, is sure sooner or later to infect the neighboring meninges or remoter parts of the body.

**Treatment.**—**First Group.**—In cases that belong truly to the first group the leading indication for treatment is to overcome a parietic condition of the muscular walls of the blood-vessels of the tympanic mucous membrane—metaphorically speaking, to brace them up, to give them tone. This



may be accomplished in two ways—viz., by the employment of both constitutional and local measures.

*Constitutional Measures.*—The so-called tonics often answer the desired purpose in the class of cases which we are now considering. Cod-liver oil stands foremost on the list. Teaspoonful doses—disguised in the matter of flavor by a few drops of *crème de menthe*—should be taken two or three times a day for a period of several weeks. Strychnin in small doses ( $\frac{1}{100}$  grain to  $\frac{1}{50}$  grain) may also be utilized to advantage, either independently or in combination with the cod-liver oil. Finally, where the patient's means will permit, the stimulating effects of a change of climate or of a life in the open air may be taken advantage of in our efforts to secure a cure.

*Local Measures.*—Nitrate of silver is the most efficient vaso-motor stimulant of which I have any knowledge. A solution of this drug having a strength of from one-half of 1 per cent. to 1 per cent. will best answer the desired purpose in the cases now under consideration. It may be injected into the middle ear by means of a slender glass instrument called a "middle-ear pipette," the sharply-curved tip of which is passed through the perforation in the membrana tympani. After the solution has been injected, it should be allowed to remain undisturbed in the cavity, in order that it may be gradually absorbed by the mucous membrane, and in this way reach either the muscle-cells of the blood-vessels or the nerve-ganglia which control their action.

The same thing can be accomplished in a less perfect manner by first cleansing the external auditory canal thoroughly and then filling it (while in an upturned position) with the silver-nitrate solution. At the end of a few moments, when the solution has become somewhat warmed, pressure should be exerted, first backward and then directly inward, upon the tragus, thus forcing the solution through the perforation. By performing the act of swallowing, the patient may aid the physician in his effort to force the remedial solution into the middle ear and through the Eustachian tube.

Very often a single injection suffices to arrest the discharge, but in some cases it is necessary to repeat the operation several times, either daily or on alternate days.

The introduction of a very small mass of finely powdered burnt alum—as much as can be made to cling to the wet end of a slender probe—into the middle ear will sometimes prove effectual where the silver nitrate has failed.

As the blood-vessels in the vault of the pharynx are apt to be in the same paretic condition as those of the middle ear, it is well to make applications of silver nitrate to this region also. The mop employed should be saturated with a solution somewhat stronger than that injected into the middle ear. A 2 or 3 per cent. solution (10 or 15 grains to the ounce of distilled water) will be found sufficiently strong for most cases.

If the discharge is very scanty, as it usually is, no special provision need be made to remove it by the employment of the douche with tepid water. Nor is it advantageous to instruct the patient, as many physicians seem to be doing, to introduce powdered remedies—more particularly boric acid—into the external auditory canal. There are no processes of decomposition to combat, and the different powders thus prescribed possess no power, so far as I am aware, to give tone to the paretic blood-vessels of the middle ear. But even if these powders did possess such stimulating powers, it is not likely that they could effect any good, as it is more than doubtful whether they ever, when introduced in this manner, reach the middle ear.

**Second Group.**—The main indication in this class of cases is to remove

the hypertrophied tissues from the vault of the pharynx and to restore this region to as nearly normal a condition as we can. How this is best to be accomplished is a question which doubtless has been fully answered in another part of this work (see page 1203). In all other respects the treatment is precisely the same as that described in the preceding section.

**Third Group.**—These cases present so many therapeutical problems for the physician to solve that only general principles can be laid down here for his guidance.

The *removal of all foul products* should be his first care. The slender probe, bent at a suitable angle and introduced into the middle ear directly upward toward the tegmen tympani, or upward and backward in the direction of the antrum, will be found of great assistance in loosening and dislodging solid matters like desquamated epithelium and cheesy pus. Hydrogen dioxid may then, by means of the slender glass pipette, be injected in the same directions, not merely for the sake of its germicidal properties, but also because it effervesces with such vigor that if some of it can be forced up beyond the mass loosened by the probe the expanding bubbles will often drive it down within reach of the slender angular forceps. By the aid of these two procedures one may gradually rid the vault of the tympanum, and sometimes even the antrum, of all the obstructing matters which interfere with the drainage, and so perpetuate the processes of suppuration. When the hydrogen dioxid almost ceases to effervesce—as it often does on the occasion of the third or fourth injection—it may be assumed that the middle ear has been fairly well cleansed of its foul accumulations. In any event it is not advisable to prolong one of these mining and scavenging sittings beyond a period of thirty or forty minutes. Before dismissing the patient for not longer than two or three days it is well to stow away in the newly cleansed cavity a few grains of iodoforn, aristol, nosophen, or other powder of a character discouraging to germ life.

Often, after three or four sittings such as I have just described, the most careful examination will fail to reveal any evidence of newly formed pus. The powder will be found lying dry upon the parts, and we may dismiss the patient as relieved, if not cured. In a goodly number of instances the term "cure" is almost warranted in speaking of the results obtained by this plan of treatment, for I have known the relief thus promptly obtained to persist for a period of several years. In other cases a relapse will occur in the course of a few months, and the same brief course of treatment will have to be repeated.

It is only in very exceptional cases that the results which I have just mentioned can be obtained only after the removal of the malleus and incus, together with some still existing remnant of the drum membrane. It is claimed by some that it is better to perform this operation in every case of this kind, as by means of it a really permanent cure may be obtained in a larger percentage of cases. So far as I can judge from the published reports, relapses are about as frequent in the excision cases as in those in which the ossicles have been allowed to remain. The better plan, it seems to me, is to resort to excision only when the simple cleansing method described above fails to arrest the discharge.

In a certain number of cases we find the soft parts above and behind the limits of the drum membrane a good deal inflamed. In the presence of such a periostitis, and presumably osteitis, one must be very cautious about indulging in prolonged intratympanic manipulations. It is better to do only a very little of this sort of work at one sitting, and the patient should be

instructed to douche the affected ear once or twice a day with as hot water as can be borne. Then, when this more active inflammation has been subdued, we may proceed with the regular routine as already described.

The second guiding principle in the treatment of these cases which belong to the third group is *the necessity of cutting or tearing away all granulation-tissue or polypoid growths* which project above the level of the surrounding mucous membrane. Such imperfectly formed tissue is of itself a source of suppuration, and then, besides, it often interferes by its mere bulk with the drainage of parts situated more deeply.

The various mechanical procedures which are employed for the removal of polypoid growths are discussed in another article of this work. Caustics, like chromic acid, nitric acid, silver nitrate, etc., are of very little use except in cases where the mass is too small to be removed by mechanical means.

The last principle to which I ought perhaps to call attention is *the desirability of scraping the surface of an area of bone caries*. This principle—at least in its applicability to caries of the middle ear—is so far inferior in importance to those of cleanliness, good drainage, and removal of all granulation-tissue, that a few words in relation to the matter will suffice in the present article. In the first place, there are not many cases in which effective scraping can be carried out; and then, on the other hand, in the great majority of instances, proper cleansing measures followed by the application of a suitable antiseptic powder seem to be sufficient to bring about the desired cure. These facts, it seems to me, show plainly that the scraping of a carious spot of bone in the middle ear is not a matter of very great importance.

When our efforts to cure a case belonging to this third group fail, it may be safely assumed that the disease is not confined to the middle ear, but has involved other parts in the neighborhood. This allied subject has been confided to another writer, and I therefore do not need to say anything further with regard to it in this place.

# COMPLICATIONS OF TYMPANIC INFLAMMATION.

BY HERMAN KNAPP, M. D.,

OF NEW YORK CITY.

PATHOLOGICAL research, as well as clinical observation, demonstrates that inflammations of the tympanic cavity, as a rule, extend more or less to the mastoid process. This occurs in two ways, either through the Rivinian notch on the outside of the adjacent bone (*mastoiditis superficialis*), or through the *aditus ad antrum* into the interior of the mastoid (*mastoiditis profunda*). Both may be *acute* or *chronic*. They are infective diseases, produced by the various kinds of pyogenic micro-organisms, in particular the staphylococcus aureus and albus, the streptococcus, and the pneumococcus, which find their way into the cavities of the middle ear by way of the Eustachian tube.

The superficial mastoiditis, also called mastoid periostitis, is in the great majority of cases only the burrowing of muco-purulent secretion from the tympanic attic and neighboring cavities—especially the pneumatic cells in the squamous portion of the temporal bone *above, behind, and before* the outer ear-canal—on and beneath the periosteum on the outer side of the temporal bone. This variety is frequently seen in children, and most often runs an acute course. The periosteal and cutaneous swelling around the upper part of the ear pushes the auricle forward and outward. If the purulent exudation finds an outlet, either by spontaneous perforation or by an incision of the skin, in the ear canal or behind the ear, there is often a rapid and permanent recovery.

This happy termination does not occur so frequently in the other variety, the *mastoiditis profunda* or *interna*, also called mastoid empyema, which of all diseases of the ear is, on account of its consequences, the most dangerous. We shall describe the acute and the chronic forms separately.

## ACUTE MASTOIDITIS INTERNA.

**Etiology.**—The causes are those producing acute middle-ear disease—viz. *acute rhino-pharyngitis*, as produced by various kinds of exposure, sea-bathing, rapid changes of temperature, and different general diseases, scarlet fever, measles, diphtheria, influenza, pneumonia, typhoid, etc. Some modes of treatment may produce mastoiditis—viz. violent inflation, the nasal douche, forcible syringing, operation in the nose and naso-pharynx—*e. g.* for adenoid vegetations, especially if followed by douching.

A particular disposition for the propagation of the inflammation into the mastoid cavities depends—

(a) On the anatomical structure of the mastoid: the pneumatic variety, it appears, being more disposed than the diploic and the compact; and when once invaded, this favors more than the two other varieties the extension of the suppuration into the cells remoter from the antrum and to the adjacent structures.

(b) On the kind of the pathogenic microbe. It seems that the pneumo-



coccus and streptococcus are more prone to produce the severer and more extended forms of disease than the staphylococcus.

(c) On the nature of the primary disease—scarlet fever, diphtheria, and influenza being the worst. Among the constitutional dispositions tuberculosis and diabetes should be mentioned as favoring the development of mastoiditis.

**Pathology.**—In suppuration of the tympanum and attic the pus may by simple gravity or chemotaxis enter into the antrum and adjacent cells without producing an active suppuration in the mastoid, just as in a corneal abscess pus accumulates at the bottom of the anterior chamber. To wake up an active inflammation infective microbes or their toxins must enter the mastoid; ripe pus, like hypopyon, is inert. Infective purulent matter may enter from the naso-pharynx through the Eustachian tube and the tympanic cavity directly into the mastoid even without causing perforation of the drum membrane. In the mastoid it produces, according to its virulence, a *catarrhal* inflammation—congestion, edematous swelling, sero-mucous exudation—or a destructive, *purulent* inflammation of the mucous membrane, the periosteum, and the bone. In the first the mucous membrane is swollen, presenting many folds and depressions and scant, ropy secretion; in the second there are larger and smaller cavities filled with thin or creamy pus (abscesses), usually communicating with one another by narrow passage-ways (fistulae); but not infrequently the abscesses in the course of the disease appear in different parts of the mastoid, first in the antrum, then either in the basal or apical, or in the anterior or posterior cells. In many cases these different foci develop successively, and when the suppuration is exhausted in the antrum, it appears in the upper, posterior, and anterior recesses or in the tip. In very severe cases the suppuration invades with great rapidity the whole interior of the mastoid, destroys the mucous membrane, breaks down the bony partition walls, and converts the mastoid into one large cavity filled with pus, shreds of mucous membrane, granulation-tissue, and decayed bone. The knowledge and diagnosis of these varieties of the morbid process are of great importance, for they indicate the direction in which the disease progresses.

**Varieties of the Morbid Process.**—The *catarrhal* form may terminate by resolution—the most frequent case—or may only be a preliminary stage of the *suppurative form*. The latter in a multitude of cases ends by evacuation of the pus into the tympanum or by perforation of the outer table of the mastoid, most commonly in the region behind the ear—the long-known *post-aural abscess*—or it may perforate the inner table, giving rise, according to the different regions it occupies, to the epidural abscess of the posterior or middle cranial fossa, or to the cervical abscesses, all of which we shall have to discuss later.

**Symptoms.**—Pain is usual and occurs (*a*) *spontaneously* in all degrees; in some cases, particularly in tuberculous patients, insignificant and not at all in proportion with the gravity and extent of the morbid changes; in other cases it is so severe that the patients have no rest day and night, commonly worse at night. The pain extends over the head, especially in the parietal region, but also in the occipital and frontal regions, and not infrequently shoot down the neck to the shoulder.

(*b*) *Pain on pressure* (tenderness). This symptom is very important, as it demonstrates not only the presence but also the location of the suppurative foci. If the outer bony table of the mastoid is thick and not affected, only firm (deep) pressure may elicit the pain when moderate pressure and percussion have failed.

As a localizing symptom the tenderness is most valuable. In the beginning of the affection pain from pressure right behind the upper wall of the meatus (the *fossa mastoidea* or antrum pit) will rarely be absent. It indicates suppuration in the antrum. Next in frequency is pain over the tip, the base, the posterior and anterior borders of the mastoid process.

**Fever.**—The temperature rising from 99° F. to 102° F., sometimes higher, with moderate acceleration of pulse, thirst, general malaise.

**Profuse discharge** from the ear; creamy, thin, sanguinolent, the latter in the severer cases; often suddenly lessening.

**Redness and prominence** (*bulging*) of the posterior and upper part of the tympanic membrane and the adjacent portion of the ear canal. This symptom is absent when the inflammation has left the antrum and continues in other parts.

**Redness and swelling of the integument of the mastoid process**, differing greatly in degree, in some cases being almost absent (see page 741), in others excessively developed, so that the knife enters 1 to 2 cm. before it touches the bone.

**Course and Termination.**—Spontaneous recovery in many instances occurs in one or several weeks; but the cases are not rare where it takes months, particularly when the course of the inflammation is not continuous, but intermittent.

**Perforation**, spontaneous or by operation, behind the ear or in the ear canal. Even in these cases the intermittent character is frequently manifest. It means that the suppuration exhausts itself in the antrum and appears in another place later on. Not rarely do we see cases in which the opening of the antrum is followed by an immediate improvement, but this does not lead to a permanent recovery; the fever returns, the painfulness moves to another place, and on opening there we strike another abscess, macroscopically without any communication with the antrum. This is particularly exemplified by collections of pus in the tip.

**Caries** in greater or less extent. This is commonly a protracted process, but in some cases of unusual severity it may develop over a large area in a few weeks.

Transition into the chronic state may lull us into false security.

**Extension into the Neighboring Parts.**—This and the preceding condition will be considered presently.

The **prognosis** of acute mastoid empyema is good if the proper treatment (rest, antiphlogosis, operation) is not neglected. If, however, the disease becomes chronic, it is dangerous to life in a degree we shall point out in treating of the intracranial complications of ear disease. Mastoid disease proper has no direct influence on audition.

### CHRONIC MASTOIDITIS INTERNA.

We distinguish the following varieties:

**Condensing Mastoiditis; Eburnation.**—When muco-purulent mastoiditis runs a chronic course without external perforation, or with recurrent otorrhea and outward perforation, as we notice so often after the scarlatinal otitis, the mastoid process by plastic osteitis is gradually converted into a mass of compact bone, perhaps of reduced dimensions (see page 741). Before or after the condensation of the bone is completed or comes to a standstill, many patients complain of neuralgic pain, radiating from behind the ear over the adjacent side of the head (*mastoid neuralgia*), incapacitating them for prolonged men-

tal labor (*aproxexia*). Neither by palpation nor pressure can any focus of disease be detected, and the otorrhea has stopped for months or years. The distress of such patients is so great that they willingly consent to surgical treatment. If the operation is done, the supposed deep-seated focus of pus is not found, even if, as I have done, the chiselling is pushed through the whole thickness of the bone, laying the [healthy] dura mater bare; yet these patients, according to the testimony of many aurists, lose their pain and *aproxexia*. It is not even necessary to go through the whole thickness of the bone to obtain this welcome effect.

**Empyema of the Anterior Mastoid Cells, with Perforation into the External Meatus.**—The preliminary symptoms are those of acute suppurative otitis media with mastoid involvement, the swelling and pressure-pain, however, being not so much over the mastoid as on the posterior wall of the ear canal. The swelling is diffuse and the painfulness rather dull when compared with the pointed swelling and the sharp pain of the furuncle. Any doubt in the diagnosis can be dispelled by a large and deep incision down to the bone in the whole length of the posterior wall of the meatus, as it was done in a successful case of mine reported in a paper published in 1893.<sup>1</sup> If such an opening does not give permanent relief, the diagnosis should be verified by the usual opening of the mastoid, as was done by A. Broca.<sup>2</sup>

This variety is apt to complicate a more frequent and graver extension of mastoid suppuration—viz.:

**Empyema of the Apex of the Mastoid with Perforation into the Digastric Fossa, the so-called Bezold Variety.**—When the purulent tympano-mastoiditis has lasted several weeks or months or longer, there is swelling and sharp painfulness over the tip of the mastoid, the head of the sterno-cleido-mastoid muscle, and in the grave cases along the muscle down the neck into the mediastinum (terminating fatally, case of Voltolini). In a case of Guye's<sup>3</sup> pressure on the neck and on the mastoid brought forth pus through a fistula in the posterior meatal wall. Guye opened the swelling at the head of the muscle and liberated a great deal of pus. Water injected into the abscess cavity escaped through a fistula in the ear canal; recovery. The perforation of the bone shows usually only a small opening in the lower medial wall of the tip. When the mastoid is opened and the tip laid bare by detaching the tendon of the muscle, pus occasionally will ooze through the upper end of the detached muscle when the latter is held between the fingers and stroked from below upward.

In some cases the pus escaping through a perforation at the medial surface of the tip of the mastoid into the digastric fossa does not travel down the neck along the sterno-mastoid muscle, but backward toward the spinous processes of the cervical vertebrae. Of this variety the writer has seen only two cases. The pus followed a deep and wide fistulous canal from the mastoid underneath a thick layer of muscles, which were laid bare by a long incision, with recovery. A good case is published by Dr. Henry F. Swain of New Haven, Conn., under the name of splenius abscess.<sup>4</sup>

**Caries and necrosis of the mastoid** are in the majority of cases the results of a chronic destructive, usually suppurative, inflammation which breaks down the bone and forms smaller or larger cavities filled with cheesy

<sup>1</sup> "Otitic Brain Disease; its Varieties, Diagnosis, and Treatment, illustrated by Cases from the Writer's Practice," *Archives of Otolaryngology*, vol. xxii, pp. 143-162.

<sup>2</sup> See A. Broca et Lubet-Barbon: "Les Suppurations de l'Apophyse Mastoïde," Paris, 1895; Observation X: "Mastoiditis restricted to the Anterior Cells," p. 64.

<sup>3</sup> *Arch. of Otol.*, xxi, p. 320.

<sup>4</sup> *Arch. of Otol.*, xxvi, No. 1, 1897.



masses—débris of mucous membrane and bone mixed with putrescent or dried-up products of secretion. They keep up a steady or intermittent offensive discharge.

A peculiar formation is the so-called **cholesteatoma** of the ear. This formation has been found as a globular mass in the temporal bone, a genuine tumor independent of any inflammation of the ear; but by far the greater number of cases present a scaly deposit which lines the cavities of the middle ear, especially those of the mastoid, and is always connected with chronic otorrhea. If the scaly masses form only thin layers lining the cavities, they represent the initial stage of cholesteatoma which Wendt has termed *desquamative otitis*. The theory of Bezold and Habermann is that epidermis penetrates through a perforation of the tympanic membrane into the middle ear, proliferates, and gradually fills and expands the neighboring cavities, forming *scaly masses* of a pearly color in concentric layers like an onion.

Their course varies in three directions: (1) They produce purulent inflammation, destroy the structures of the auditory apparatus, creating on the one hand large sinuses by converting mastoid, tympanum, and meatus into one large cavity which communicates with the air through the meatus or through a permanent opening in the mastoid—spontaneous recovery.

(2) They lead by proliferation of bone-tissue to eburnation of the mastoid—spontaneous recovery.

(3) They penetrate the cranial cavity and cause death by one of the otitic complications.

Another consequence of caries and necrosis is the separation of larger or smaller *portions of bone* (sequestra). Their formation in the mastoid is common. They are eliminated through perforations of the skin (fistulæ) either spontaneously or artificially. Exfoliation of larger portions of the meatal wall and the petrous bone, including the whole inner ear, have been observed, and it is surprising how people can live and how severe and fatal consequences are absent in so many cases and for so long a time.

In my collection there is a specimen of which the accompanying illustrations (Figs. 503, 504) give a true and life-size illustration.

Fig. 503 presents the *outer surface* of the left temporal bone of an adult. On the posterior part the mastoid process is totally corroded from the posterior wall of the external auditory meatus (*b*) up to the base of the process (*c*). In the center a strip of the outer bone table (*a*) is preserved, the tip (*x*), however, and the whole lower (*d*) and medial (*e*) surface of the tip, as well as the adjacent bone substance, are totally corroded. The tip itself has a large hole (*x*) leading into the interior of the mastoid.

Fig. 504 shows the internal surface of the petrous bone evenly and deeply corroded from the base (*f*) along the anterior surface to the hiatus Fallopii (*g*). The corroded part extends on the anterior surface to the medial side of the eminence of the superior semicircular canal (*h*), to the middle of the sigmoid groove (*i*), backward almost to the meatus audit. int. (*n*). Laterally the sigmoid groove is deeply and coarsely corroded (*k*), and fistulous passages lead through the decayed bone into the digastric fossa (Fig. 504). The tegmen tympani (*l*) et mastoidei (*m*) is corroded in its full extent. On the whole the mastoid process is totally decayed and the petrous bone in its entire lateral half.

It is a wonder that people can live when the caries has produced such ravages. A greater wonder it is that we can operate on such people in such a state, preserve their lives, and stamp out the destructive disease. In a child I operated on more than twenty years ago, the whole mastoid was destroyed, the place was occupied by crumbling pieces of bone and exuberant lardaceous granulations. I removed the whole decaying mass of morbid overgrowth. The dura lay extensively bare. The operation seemed to be an ante-mortem autopsy, yet the child recovered. Ten months ago I removed carious and necrosed bone from the mastoid and petrous bone of a child, which



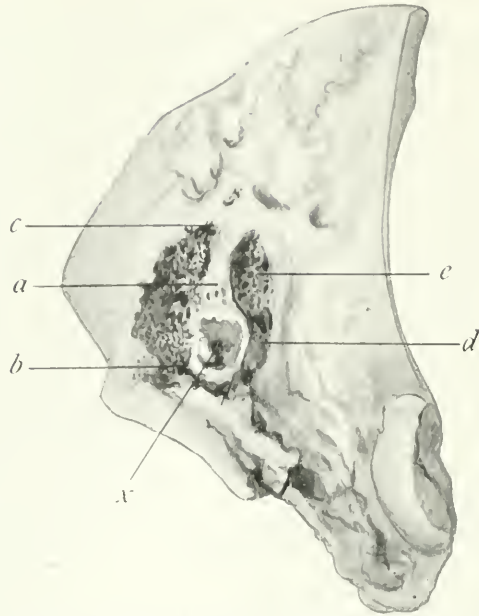

FIG. 503.—Caries of the mastoid and lateral half of the petrous bone of an adult (life size): Outer surface showing *a*, part of the outer table, preserved; *b*, posterior wall of external meatus; *c*, base; *d*, lower wall; *e*, medial wall; and *x*, tip of the honeycombed mastoid process.

in the living presented all the symptoms exhibited by the specimen depicted above; and, although tuberculous was at the bottom of the affection, the child was perfectly cured. The tolerance by the organism of such deep and exten-

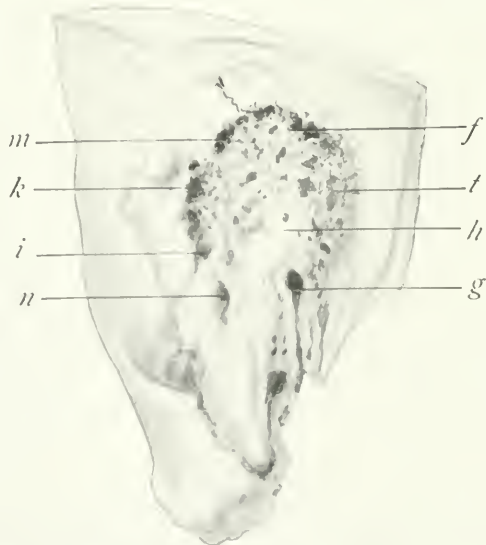


FIG. 504.—Inner aspect of specimen shown in Fig. 503, showing *b*, base of pyramid; *a*, hiatus Fallopi; *c*, eminence of superior semicircular canal; *d*, sigmoid groove; *e*, deep holes in corroded bone; *f*, tegmen tympani; *g*, tegmen mastoidei; *h*, *i*, *m*, *n*.

sive ravages cannot be depended on, however, and these destructive processes are the chief causes of the disastrous intracranial complications of ear disease which we shall now discuss.

## INTRACRANIAL COMPLICATIONS OF PURULENT OTITIS MEDIA.

**Etiology.**—The intracranial complications of ear disease are almost exclusively produced by the propagation of purulent inflammation of the different parts of the middle ear.

**Occurrence.**—They are met with in only a small percentage of ear diseases, but are most dangerous. According to Bürkner,<sup>1</sup> who found 104 deaths in 33,107 ear cases, as well as according to Randall,<sup>2</sup> who found 15 in 5000, three-tenths of one per cent. of all the ear patients die from otitic intracranial disease. Schwartze<sup>3</sup> found in the Prussian army 30 deaths in 8425 diseases of the middle and inner ear—*i. e.* 0.35 per cent.

The death-rate from purulent ear disease, compared with the death-rate from all diseases treated in a large general hospital, has been ascertained by N. Pitt,<sup>4</sup> who found among 9000 successive autopsies in Guy's Hospital (London) during the years 1869–1888, 57 deaths from purulent ear disease, which is 1 out of 158, or very nearly  $\frac{2}{3}$  of 1 per cent.

Prof. J. Gruber<sup>5</sup> examined the *post-mortem* records of the Vienna General Hospital and found 232 deaths from otitic intracranial disease among 40,073 autopsies—*i. e.* 0.58 per cent.

**Propagation.**—In the great majority of the cases ear disease extends into the brain through destructive inflammation of the bone (Fig. 505), by which infective material enters the cranial cavity, accumulates between bone and dura, and causes pachymeningitis, leptomeningitis, sinus thrombosis, cere-

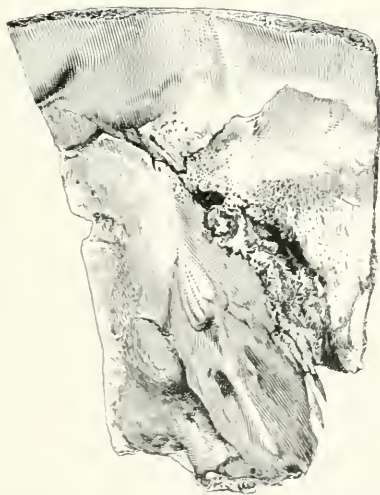


FIG. 505.—Caries of the tympanic roof. The openings were sealed by the thickened dura and the brain was not here involved. Death by basal meningitis from infection through internal meatus.

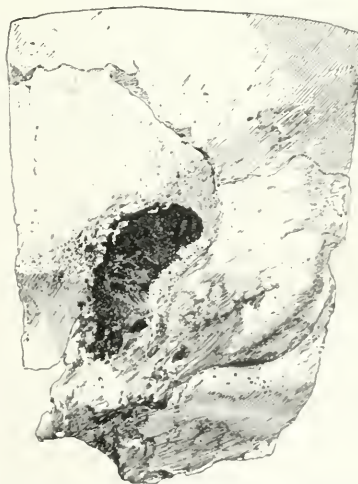


FIG. 506.—Outer aspect of the same specimen, showing loss of the back wall of the canal and openings into the facial and semicircular canals above the empty oval window.

bral and cerebellar abscess. The infective material may, though rarely, be conveyed into the skull by offshoots of the dura mater, the aqueducts (Fig. 506), and the canals through which blood-vessels, lymphatics, and nerves pass from the tympanic into the cranial cavity.

The infective material consists of the different species of pyogenic micro-

<sup>1</sup> *Arch. f. Ohrenh.*, xx, p. 81.

<sup>2</sup> *Trans. Am. Otol. Soc.*, v, p. 101.

<sup>3</sup> *Arch. f. Ohrenh.*, xxi, p. 221.

<sup>4</sup> *Brit. Med. Journ.*, 1890, vol. i, pp. 643, 771, 827

<sup>5</sup> *Arch. of Otol.*, xxv, p. 401, 1896.

organisms—staphylococcus pyogenes, streptococcus, pneumococcus, and others, the same that cause the primary ear disease—and their products, the toxins.

**Causes.**—Generally only the severer forms of otitis media are complicated with brain disease, such forms as are caused either by certain acute general diseases—scarlet fever, diphtheria, influenza, measles, variola, and typhoid—or by some chronic, debilitating, constitutional affections—tuberculosis, diabetes, syphilis. Sometimes grave cases of purulent otitis, terminating fatally by brain complications, are caused by accidental atmospheric, chemical, and mechanical influences; for instance, blizzards, sea-bathing, foreign bodies in the ear, rough and unclean methods in removing foreign bodies and diseased deposits from the ear, forcible syringing in acute suppuration, all devices and remedies tending to pen up secretions, such as tampons and coagulating powders, morbid formations in the middle ear and auditory canal—*e. g.* polypi, sequestra, exostoses, cutaneous membranes, cystic and other tumors.

*Acute purulent otitis leads more rarely to intracranial complications than chronic; yet by no means so exceptionally as was formerly believed.*

**Passageways of Infection.**—The channel of invasion of the skull cavity most frequently passes through the medial and superior walls of the *mastoid* into the posterior cranial fossa; next in frequency it passes through the *tegmen tympani* into the middle cranial fossa, then through the *medial wall* of the drum by way of the labyrinth and the internal-ear canal, or directly through the posterior wall of the petrous bone into the posterior cranial fossa; rarely through the lower and *anterior walls* upward along the fossa for the bulb of the jugular vein or the carotid canal. Exceptionally the infective material travels through the tympanic ostium of the Eustachian tube or the semicanal for the tensor tympani muscle forward and inward, forms a retro-pharyngeal abscess, and penetrates through one of the crevices at the base of the skull into the cranial cavity, as in a case of Tröltsch<sup>1</sup> and another of the present writer.<sup>2</sup>

#### INFLAMMATION OF THE MENINGES.

Meningitis in general may result from a constitutional infective disease, such as tuberculosis or syphilis, or it may originate in a neighboring structure, from a wound of the skull, or, what concerns us here, a diseased—*i. e.* suppurating ear. We may distinguish pachymeningitis from leptomeningitis.

Pachymeningitis may be external, the common kind, or internal.

**Pachymeningitis Externa; Epidural or Extradural Abscess.**  
—The infection may be carried

(*a*) Through vascular and membranous canals from the inflamed tympanic cavity through healthy bone into the cranial cavity, which is very rare; (*b*) through a fine, fistulous canal, not always macroscopically discoverable, through apparently healthy bone; or, the most frequent condition and (*c*) through bone broken down by caries, necrosis, or erosion and atrophy from cholesteatoma and tumors. Jansen<sup>3</sup> describes a peculiar channel—namely, through the labyrinth and the *aqueductus vestibuli* to the posterior surface of the petrous bone with formation of an empyema in the endolymphatic sac.

As pachymeningitis externa leads to thrombophlebitis and abscess, the reverse course may occur; thrombophlebitis and abscess may induce pachymeningitis and leptomeningitis, which then commonly prove fatal in a short time.

<sup>1</sup> *Arch. f. Ohrenh.*, iv. p. 121, Fall 6.

<sup>2</sup> *Arch. of Otol.*, xxiv. p. 125, 1895.

<sup>3</sup> *Berl. klin. Woch.*, 1891, No. 49.

**Pathology.**—When we expose the dura in cases of acute purulent otitis media we usually find it either normal or slightly reddened and dull; in more advanced inflammation it is vascular, thickened, and beset with granulations. In chronic cases, with circumscribed caries or necrosis of the underlying bone, it is blackish like the bone, softened, gangrenous, and perforated, bathed in serum. In purulent destruction of the bone it is separated from the latter by pus which has the characteristics of the pus in the middle ear, creamy and sweet in the acute, thin, greenish, and offensive in the chronic, cases. In a very chronic course the dura may be greatly thickened and fibrous or sarcomatous looking. Zaufal<sup>1</sup> describes a case in which the dura was 1.5 cm. thick; and the writer has seen a similar case where chronic empyema of the sphenoidal and ethmoidal sinuses showed perforation of the optic groove at the sella tureica and the greatly thickened fleshy dura looked like a flat sarcoma, but gradually thinned down and was attached to the healthy neighboring bone. The pus between dura and bone does not collect in a circumscribed cavity, but spreads in different directions, following readily the sigmoid sulcus into the jugular foramen, and up along the transverse sulcus toward the *torcular Herophili*, also at the bend of the sinus into the middle cranial fossa.

Epidural abscess may be recovered from by a spontaneous opening into the ear through the medial wall of the mastoid, the roof of the tympanum, the squama temporalis, or through the occipital bone above and behind the ear canal. The writer has seen spontaneous perforation of the occipital bone 4 or 5 cm. behind and about 1 cm. above the ear canal in two cases. He opened the subperiosteal abscess, and could introduce a probe through the bone fistula into the posterior cranial fossa. One case made a spontaneous recovery,<sup>2</sup> and has been under observation these three years; the other died from sinus thrombosis and leptomeningitis fifteen years ago. The autopsy showed<sup>3</sup> that the bone fistula was about in the middle of the transverse sulcus. In the great majority of cases of epidural abscess the dura perforates and the patient dies from consecutive cerebral abscess or purulent sinus thrombosis and leptomeningitis. All these grave affections may occur together in one case.<sup>4</sup>

**Diagnosis.**—In most cases the presence of an epidural abscess is ascertained only during the operation, when the broken-up medial wall of the mastoid or a fistula either in this wall, in the roof of the drum and mastoid or in some other part of the skull leads into the collection of pus. In many cases symptoms of meningeal irritation are present—namely, headache, slight rise of temperature, pressure-pain, somnolence, slowing of pulse, vomiting, stiffness of the neck, choked optic disk; but these symptoms are too indefinite to make a diagnosis. If after the opening of a subperiosteal abscess a probe can be passed through a bone fistula into the cranium, we may be assured of the presence of an epidural collection of pus. In a number of cases, however, doughy swelling and tenderness on pressure about one inch behind the ear canal, the place of exit of the mastoid emissory vein, and the history and other symptoms make a cranial complication probable, and we may fairly suppose that we have to deal with an epidural abscess.

**Prognosis.**—If we know that, with the few exceptions of a spontaneous perforation, epidural abscess is always fatal, the *indication* of operative interference is imperative. As in the majority of cases the diagnosis is uncertain, the operation should be begun in an exploratory way, and desisted from or

<sup>1</sup> *Prager Med. Woch.*, 1893, No. 50.

<sup>3</sup> *Arch. of Otol.*, xii, p. 44, 1883.

<sup>2</sup> *Arch. of Otol.*, xii, p. 155, 1893.

<sup>4</sup> *Arch. of Otol.*, vol. xxi, p. 239, 1892.



continued and terminated according to the conditions revealed. When operated on, almost all cases recover.

**Pachymeningitis interna** (*subdural, or intradural abscess*) is not often met with. When in a circumscribed place the externally inflamed dura is corroded, softened, and perforated, exudation is deposited on its inner side in the subdural space. If during this process the arachnoid and pia are agglutinated to the dura, pus may accumulate in this place and form a subdural abscess, with softening and ulceration of the adjacent brain-substance—circumscribed encephalitis. W. Macewen, in his classical treatise on the "Infective Diseases of the Brain and Spinal Cord," described several cases of this variety, one of which (Case X., p. 75) was cured by an operation.<sup>1</sup> If, on the other hand, this agglutination does not occur, the infective exudation spreads in the subdural space and leads to

**Purulent Leptomeningitis.**—The pathogenic substances may be carried into the arachnoid space in various ways—(a) after perforation of the dura, as we have seen, or (b) without perceptible perforation. Leptomeningitis is developed chiefly in the neighborhood of the diseased dura, on the base of the brain, travelling thence to the convexity of the same side, and to the base and convexity of the other. In rare cases the convexity only shows macroscopic changes, whereas the base appears healthy, as it was in the case described and depicted by the writer in the *Archives of Otolaryngology*, 1895, p. 125. The pus is collected in the furrows between the convolutions and also in disseminate patches. The pia is hyperemic and edematous. In addition to the purulent meningitis we frequently find the tubercular kind; and lately attention has been called by Quincke, Levi, and others to *serous meningitis*.

Meningitis purulenta may be *general* or *partial* (circumscribed). It has been found oftener on the right side than on the left (Körner).

**Etiology.**—Meningitis may be induced as well by acute as by chronic purulent otitis, with or without caries. It may be uncomplicated or accompanied and caused by sinus thrombosis and cerebral abscess. Otitis in tubercular and syphilitic subjects leads more readily to meningitis than otitis in healthy subjects. It rarely occurs in small children, which is remarkable. The author has operated on children between one and four years old where the greatest ravages—caries and necrosis—destroyed the mastoid and petrous and laid the dura bare to a very large extent; yet the children had no symptom of leptomeningitis and recovered.

**Duration.**—Otitic meningitis may be *acute*—in exceptional cases fulminating, setting in almost suddenly and terminating fatally in four or five hours or in several days—or *chronic*, with mild symptoms and intermissions at first, then developing into the regular course, which usually lasts one week or less, more rarely two or three weeks.

**Symptoms.**—*Headache* is, as a rule, the earliest and most pronounced symptom. At first it is parietal, occipital, or frontal, and on the same side, later general.

*Dizziness*, restlessness, irritability, auditory and visual hyperesthesia, mental weakness, loss of appetite, constipation, drowsiness without regular sleep, nausea, vomiting, optic neuritis (rare), more or less constant acceleration of pulse and elevation of temperature, delirium, convulsions, and coma are the chief symptoms of the regular course. They may be modified by complication with abscess (temperature high, pulse slow) and septic sinus thrombosis (rapid diurnal changes of temperature).

**Prognosis.**—Purulent meningitis due to ear disease, like that due to other

<sup>1</sup> See a good case by Jas. F. McKennon, *Arch. of Otol.*, June, 1898.

causes, terminates fatally in the great majority of cases. How numerous in well-established diagnosis the exceptions are must be left to future observations in brain surgery to decide. The cases of *diffuse* purulent meningitis thus far reported as cured by operation do not stand criticism; whereas *partial* meningitis, epidural and subdural abscess, and the serous meningitis, which shows a majority of the symptoms of diffuse meningitis, have undoubtedly been cured by operation, and some have recovered spontaneously.

**Sinus Thrombosis and Pyemia.**—Pathology, Course, and Termination.—The destruction of mucous membrane and bone-tissue in the middle ear and mastoid process by way of pachymeningitis, epidural abscess, and phlebitis frequently induces sinus thrombosis. If the thrombus is parietal and *uninfected* it causes no appreciable disturbance of the patient's health; if, however, it becomes contaminated with pyogenic matter through perviousness of the vessel-wall by erosion, softening, and perforation, the thrombus becomes septic, decays, and causes pyemia. The lateral sinus is the one most exposed, but small bone veins may carry the infective material into the sinuses from different parts of the temporal bone. The thrombus may be partial or total (occlusive), uninfected or septic, single or multiple, limited to one sinus, or extending over almost all sinuses and veins of both cerebral and cerebellar hemispheres. The lateral sinus is more frequently thrombosed than any other, particularly its sigmoid segment; then the inferior and superior petrosals, the cavernous sinus, the bulb and the whole length of the internal jugular.

*Non-infected* thrombi may disappear by absorption, or may by a kind of "organization" obliterate the vessel and do no harm. *Infected thrombi* may in rare cases, by destruction of the sinus-wall, be evacuated through a fistula of the destroyed bone, without causing disastrous consequences. Not quite so rarely they are carried by the blood-current into distant organs, especially the lungs, and produce larger and smaller metastatic abscesses and pyemia. Even in such cases recovery by and even without surgical interference is possible. In the majority of cases, however, if the affected sinus is not operated on, septic sinus thrombosis proves fatal by metastatic abscesses, pyemia, cerebral or cerebellar abscess, and purulent meningitis.

Sinus thrombosis is more frequent in men than in women, and more frequent on the right than on the left side. It occurs more rarely in acute than in chronic cases, and the predisposition to it is greatest in the second and third decades of life.

**Symptoms.**—Arranged according to their frequency and importance we note: (1) *Headache.*—It corresponds more or less to the situation of the thrombus, usually 2 or 3 cm. behind the upper edge of the external ear canal, over the knee of the lateral sinus where infective otitic thrombosis most often begins. It may, however, radiate over the parietal region of the head or be marked in the occiput, rarely in the forehead of the same side. The headache may be most intense, depriving the patient of all sleep during twenty-four hours.

(2) *Acceleration and weakness of the pulse*, more or less constant.

(3) *Rapid changes of temperature*, running from near the normal up to 104°–106° F. in several hours, and falling again to the original level the same day—the characteristic steep-peaked temperature chart of pyemia. See the accompanying chart (Fig. 507), taken from a recent publication of Fred. Whiting of New York: "Three Successfully Operated Cases of Pyemic Sinus Thrombosis."<sup>1</sup>

<sup>1</sup> *Arch. of Otol.*, xxvii, p. 26, 1898.

(4) *Rigors*.—Quotidian or tertian chills lasting half an hour or longer, followed by profuse perspiration.

(5) *Swelling and tenderness over and behind the posterior edge of the mastoid* (sigmoid sinus thrombosis); further back, half-way between the ear and the occipital protuberance (transverse sinus); in the depth and around the

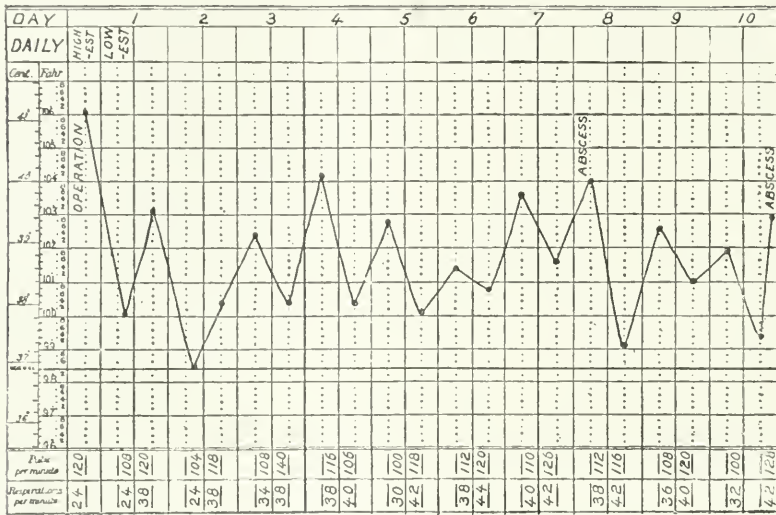


FIG. 507.—Typical chart of pyemic sinus-thrombosis in one of three successfully operated cases (Whiting).

orbit with protrusion of the eyeball (cavernous sinus); below the tip of the mastoid and down the anterior border of the sterno-cleido-mastoid muscle (bulb and internal jugular vein, which in its upper portion and sometimes in its whole extent is felt as a hard and tender cord.

(6) *The tongue is dry and coated, and the appetite lost*, in marked cases to the refusal of all food.

(7) *Diarrhea* in most cases, *constipation* in some.

(8) *Comprehension slow*; *stupor* and *optic neuritis* only in complication with *encephalic abscess* and *meningitis*.

The *diagnosis* in uncomplicated infective sinus thrombosis is easy; in complicated cases (abscess and meningitis) the marked and characteristic symptoms (steep-peaked temperature curve and rigors) of pyemia overshadow those of abscess and meningitis, so that in complicated cases it is easier to recognize the presence or absence of thrombosis than that of abscess and meningitis.

The *prognosis* is bad if the disease is allowed to take its natural course; only a few well-established cases of spontaneous recovery are on record. The prognosis is much better since the advance of otology and surgery has led to the early recognition and the operative cure of this disease. The mortality even now is still considerable, and the records of well described cases at present at our disposal do not suffice reliably to express the percentage of mortality. The prognosis in any given case, short of deep coma, is not absolutely hopeless, since even patients with the severest cephalic symptoms and severe metastatic pneumonia have recovered.

Prof. O. Körner, in his exhaustive monograph: "The Otitic Affections of the Brain, the Meninges, and the Venous Sinuses," describes two additional varieties of pyemia:



**Osteitic Pyemia with Sinus Phlebitis (Osteo-phlebitis of the Temporal Bone).**—This disease is rare. It is caused by the entrance of pus from the primary focus in the ear or the temporal bone into the general circulation through small veins. The symptoms are like those of pyemia from sinus thrombosis. Its existence as distinct from the latter is doubted, but any one who has ever seen, like the writer, a fatal case of pyemia from osteo-myelitis of the thigh, will ask with Körner: Why should such a disease not originate in an acute inflammation of the mastoid? Rigors are not so frequent as in sinus thrombosis; metastases are rare in the lungs, but occur in the joints, muscles, and the subcutaneous connective-tissue, and the streptococcus has been found in them as the pathogenic germ. The prognosis is better than that of sinus phlebitis; and the treatment should be conducted according to general surgical principles; some cases in which the internal jugular was ligated have ended fatally (Lane, Deansley, Langenbuch).

**Septic Affections from Suppuration of the Ear and Temporal Bone.**—This variety is distinguished by a very rapid course (sometimes in a few days), severe cerebral symptoms, especially delirium, high continuous fever, septic endocarditis and nephritis, hemorrhages in the endocardium, the muscles, the retina, etc. Körner describes two cases of his own practice in which he dwells on the rapidly increasing edema in the region of the diseased bone and the infected cervical glands, while the sinuses and emissary veins were entirely intact. In a case under Fränkel's care, which ran its fatal course under the picture of a dermatomyositis, the tissue-juice and the muscles were filled with streptococci in pure culture. Körner says that this supports the supposition that these septic processes spread chiefly through the lymph-channels, not like the pyemic through the blood-vessels. The present writer cannot suppress his impression that the above observations might have been cases of primary otitis purulenta complicated with erysipelas.

**Brain-abscess (Cerebral and Cerebellar).**—This severe affection is induced in the great majority of the cases, not by disease of the mucous membrane, but "by disease of the bone which almost always extends to the dura mater. In 9 per cent. it has been caused by acute, in 91 per cent. by

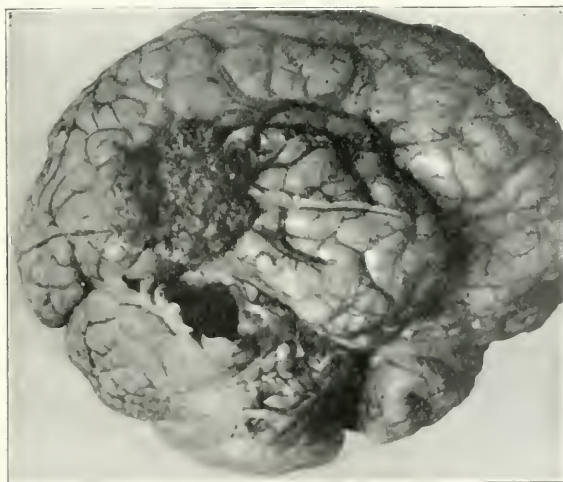


FIG. 508.—Right antero-inferior aspect of brain, showing cerebellar abscess and sphenotemporal hernia cerebri.

chronic otitis. The dura is almost always united to the surface of the brain at a point where the cerebral abscess is nearest to the diseased bone. The brain-substance which separates the abscess cavity from the place of union between dura and bone is, as a rule, only a few millimeters broad, and has almost always—in 84 out of 90 cases—been found diseased" (Körner).

The abscesses are found in the neighborhood of the diseased bone, about 66 per cent. in the temporo-sphenoidal lobe, over the tegmen tympani et mas-



toidei, upon which the fusiform gyrus is situated; 30 per cent. in the cerebellum, near the sigmoid groove, where the anterior surface of the cerebellar hemisphere is situated (Fig. 508); the remaining 4 per cent. are found in the crura cerebelli ad pontem, the pons, or very rarely in the occipital or frontal lobes. In children, statistics show that 82 per cent. are in the cerebrum, 18 per cent. in the cerebellum; in advanced years we find 63 per cent. in the cerebrum, 37 per cent. in the cerebellum, all of which is explained by the development of the pneumatic spaces in the mastoid with advancing years.

In 15 per cent. more than one abscess has been found in the brain.

The size of the abscess varies from the smallest dimensions to the occupancy of almost the entire temporo-sphenoidal lobe. Among the largest is the one described and depicted by the writer in 1895.<sup>1</sup> It was 8 cm. long and 6 cm. high. They contain usually the same kind of pus as the otorrhea shows, thick and creamy or thin, frequently greenish and offensive. The majority being chronic are capsulated. The capsule has been found from 1 to 5 mm. in thickness. Those non-capsulated are commonly surrounded by a zone of softened brain-substance, which easily ruptures when the brain is removed. Not only abscesses that are free from, but also most of those invested with, a capsule continue to grow nevertheless.

Abscesses may in their growth communicate with the mastoid or the middle ear and give off continuously some of their contents; they may also

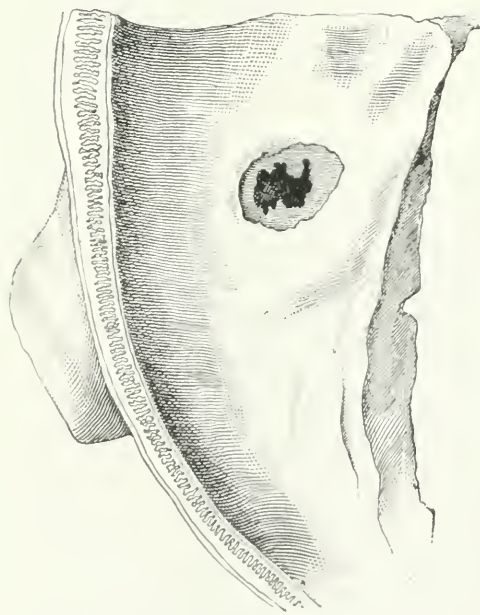


FIG. 509.—Caries of the tympanic roof, with ulceration through the dura, communicating with a large abscess in the overlying temporal lobe, emptying through the tympanum just before death.

erode and perforate the cranial capsule and discharge pus through a fistula, as in the case of Schede, one of the earliest to be successfully operated on. Spontaneous evacuation through the ear has been noticed by Randall<sup>2</sup> (Fig. 509) and many others, yet it did not cure the abscess. A notable fact is that a constant otorrhea from central abscess often suddenly stops during the course of an operation without any significance as to the result. The only case of spontaneous recovery of a cerebral abscess on record is by Sutphen, of Newark, N. J., who found at the autopsy of a patient dead from arrosion of the carotid an old abscess which had emptied itself previously by a carious perforation of the temporal bone. The almost unexceptional termination of an encephalic abscess, if not operated on, is death, caused either by cerebral pressure and

edema, by perforation into the ventricles or the subarachnoid space, or through complicating sinus thrombosis and meningitis.

**Symptoms, Course, and Termination.**—In many cases we may distinguish four stages: the *initial*, with fever, headache, vomiting, etc.; the *latent*, with milder discomfort; the *manifest*, with the full development of a severe

<sup>1</sup> *Arch. of Otol.*, xxiv, p. 121.

<sup>2</sup> *Trans. Amer. Otol. Soc.*, 1892.

brain disease; and the *terminal*, with exhaustion and coma, or sudden appearance of the fatal phenomena from perforation into the ventricular or arachnoid cavities.

According to v. Bergmann<sup>1</sup> three groups of symptoms may be distinguished—viz.:

1. *General Symptoms*.—Weakness, loss of appetite, foul tongue, pale or yellow color as in all grave diseases; fever moderate or absent.

2. *Cerebral and pressure symptoms*, generally more pronounced in cerebellar than in cerebral abscess.

*Headache* is the earliest, most conspicuous, and most constant symptom. It is usually in the neighborhood of the abscess, but not infrequently in other regions, particularly the occiput and forehead and all over the head.

*Tenderness on percussion* is frequently but by no means generally present. Macewen's symptom, that one ear applied to the vertex of the patient hears the percussion-sound stronger from the diseased than from the healthy side, is, as far as my experience goes, unreliable. *Nausea and vomiting* are almost always present, but not characteristic. *Dizziness and disturbance of equilibrium* are frequent.

*Disturbance of the functions of the brain* is a frequent and marked symptom. Slow comprehension, apathy, incoherence of ideas, weakness of memory; at night frequently great mental excitement, crying, restlessness, delirium, alternating with drowsiness, optic neuritis, earlier and more pronounced on the diseased side; convulsions; *elevation of temperature*, moderate, usually with evening exacerbations; pulse slow; respiration regular.

3. *Localizing Symptoms*.—*Deafness in the non-suppurating ear* has been observed several times, and is explained by the fact that the auditory center of the right ear is situated in the temporal lobe of the left side, and *vice versa*. *Word-deafness*—mental or sensory deafness—*i. e.* the patient hears the word but does not understand it. *Annesic aphasia, agraphia, anurythmia* are rare, and motor aphasia has not yet been noticed in uncomplicated brain-abscess. *Word-blindness, dyslexia* (Berlin), *letter-blindness*, and "word-" without "letter-" *blindness*,<sup>2</sup> conditions in which with normal vision the patients cannot understand written or printed language, are referred to the visual memory center situated in the angular and supramarginal gyri on the left side of the brain.

*Crossed paresis, crossed clonic and tonic spasms, and convulsions, crossed facial paresis and crossed hemianesthesia*, all due to a lesion of the internal capsule, are occasionally met with.

*Homonymous hemianopsia* has been recorded seven times. It would probably have been found oftener had it regularly been sought after. In a case of abscess of the temporo-sphenoidal lobe operated on by the author, December 11, 1893, it was one of the determining symptoms.<sup>3</sup> The abscess was found at the first exploratory puncture and the patient is now perfectly well, but the homonymous hemianopsia is permanent. This symptom is produced by a destruction of the optic tract, somewhere along the optic radiation between the region around the calcarine fissure and the optic chiasm. In cerebral abscess it refers chiefly to the optic radiation in its subcortical passage through the temporo-sphenoidal lobe.

*Cerebellar ataxia and vertigo* are due to lesions of the worm.

<sup>1</sup> *Die chirurgische Behandlung der Hirnkrankheiten*, 2d edition, p. 40, 1889.

<sup>2</sup> See a case reported by J. Hinschelwood, *Lancet*, Feb. 12, 1898, and one of Optical Aphasia, a symptom of speno-temporal abscess cured by operation, described by P. Manassee, *Arch. of Otol.*, April, 1898.

<sup>3</sup> *Arch. of Otol.*, vol. xxiii, p. 155, 1894.

Opisthotonos, partial or total paralysis of the motor communis oculi and the abducens nerves, conjugated deviation of the eyes in some cases toward the affected, in others toward the unaffected, side, and nystagmus, are rare and indefinite symptoms.

**Differential Diagnosis of Purulent Mastoiditis and its Different Intracranial Complications.**—In children it is often difficult to ascertain whether the mastoid is diseased alone or together with the intracranial structures. Meningeal irritation caused by congestion and edema is not rare, but difficult to distinguish from infective intracranial inflammation. The course will show; and if on account of the persistence of alarming symptoms an operation is decided on, the conditions exposed by the chisel will lead to the diagnosis.

In children and adults the most important helps in the diagnosis are the kind and seat of the original (ear) affection. Here also an exploratory operation will frequently be the decisive step. The diseases in the middle cranial fossa are induced by disease of the *tegmen tympani* and *tegmen tube*. (The author has seen purulent meningitis of the anterior and middle lobes imitating a brain-abscess from attic suppuration with extension to the pharynx by way of the semicanal of the tensor tympani muscle.) Disease of the cerebellum is produced chiefly by mastoid suppuration, rarely by disease of the petrous bone, in which case the infection is carried through the labyrinth and inner auditory meatus into the cerebellum. The latter variety can be recognized by the total deafness it produces in the affected ear.

The *diagnosis is difficult if tuberculosis, nephritis, diabetes, etc. are complicated with chronic otorrhea*. The author, in a case of supposed brain-abscess, decided to open the skull, but desisted when he found that the inner table of the mastoid was healthy. The patient died of tuberculous meningitis (autopsy).

If *cerebral disease* exists together with *suppuration in both ears*, it may be difficult to ascertain in which hemisphere the brain lesion is. Local pain, tenderness on percussion, and other local symptoms such as edema and redness over mastoid, etc., may help in making the diagnosis.

A *cerebral tumor* may coexist with purulent otitis media. The diagnosis will usually be possible. The tumor has a slow development, no fever, no rigors, almost always optic neuritis, and constant headache.

The diagnosis between *abscess and meningitis* is made by the high temperature and acceleration of the pulse, without remissions, and the irritability, general excitement, restlessness, and hyperesthesia of the organs of sense in meningitis, contrasted with the slow cerebration, apathy, and drowsiness in abscess. Slow pulse with meningitic temperature, etc., may indicate coexistent abscess (Randall).

*Infective sinus thrombosis* is characterized by mental depression, rigors, constipation, anorexia, apathy, and the steep-peaked pulse chart.

Two, three, or all the intracranial complications may be present in the same patient. The writer has had under observation a patient in whom the autopsy showed mastoid empyema, perforation of the lower mastoid wall and extension of the pus down the neck, epidural abscess in middle and posterior cranial fosse, septic thrombosis of all the sinuses of both internal jugular and most of the cerebral veins, an abscess in the temporo-sphenoidal lobe, another in the cerebellum, and to render the morbid collection complete, diffuse purulent meningitis.<sup>1</sup>

<sup>1</sup> Described in *Arch. of Otolaryngology*, vol. xxi. p. 239.



# DISEASES OF THE SOUND-PERCEIVING APPARATUS.

BY HENRY A. ALDERTON, M. D.,

OF BROOKLYN, N. Y.

THE sound-perceiving apparatus consists of all those portions of the acoustic nerve-apparatus central to the peripheral nerve-cells in the labyrinth, but is usually considered to include all of the labyrinthine structures. About 10 per cent. of all aural cases show evidences of pathological changes in some part of this apparatus, or of functional disturbances of the same; some authors (Bürkner, Randall) make this percentage rather less. Middle age is the period of life relatively most free from such alterations.

**Morphology.**—Complete absence of the labyrinth (Michel, Schwartze) or of the auditory nerve (Michel) may exist congenitally, or there may be an

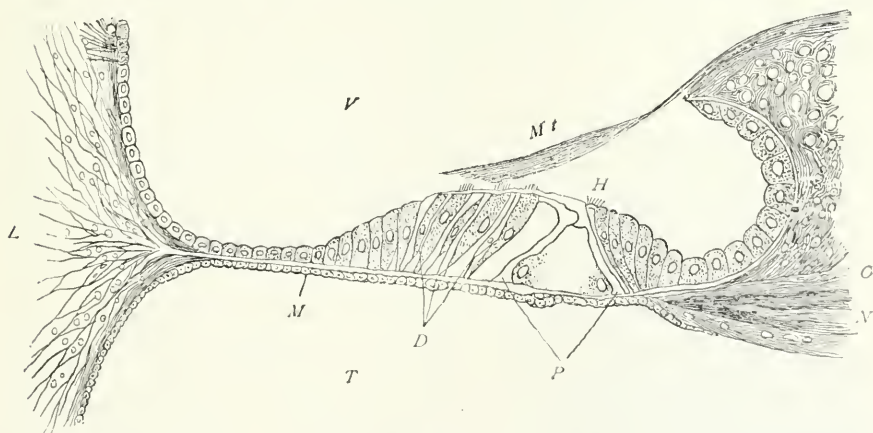


FIG. 510.—Section of normal Corti's organ: *M*, basilar membrane; *Mt*, tectorial membrane; *N*, fibers of cochlear nerve; *O*, osseous spiral lamina; *P*, pillars of Corti; *D*, Deiters' cells; *H*, hair cells.

arrest of development in these parts producing corresponding deformities. Arrested labyrinthine development rarely occurs; but when it does, the cochlea is the part most frequently affected (H. Mygind). Malformation of the osseous labyrinth has heretofore been found most frequently, but it is probably true that with further observations the membranous labyrinth (Figs. 510, 511) will be found to be the part most commonly malformed; in fact, it is possible for the arrest in development to be confined to it (A. Scheibe). The malformations, when congenital, are usually the same on both sides (Michel and Claudius), and may or may not be associated with similar changes in the sound-conducting apparatus. Should these defects be slight in character, the hearing ability may be very little, if at all, impaired,



as in a case of Voltolini's; but when the defects are more extensive, they are generally combined with great or total deafness (A. Politzer).

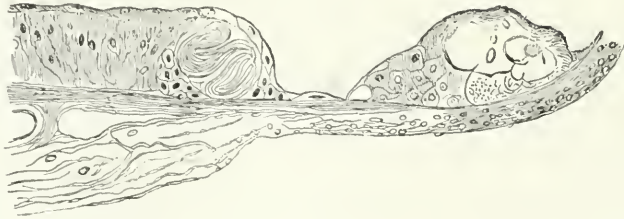


FIG. 511.—Section through the organ of Corti of a deaf-mute, showing arrest of development (Scheibe).

**Pathology.**—Of the circulatory disturbances occurring in the labyrinth, *oligemia* or *anemia*, if of limited duration, produces very little, if any, alteration in the anatomy of the part. It is possible that prolonged oligemia or anemia may give rise to degenerative changes (A. Politzer). *Hyperemia* of moderate intensity and duration is not likely to induce anatomical alterations, but, if long continued, may lead to increased pigmentary deposits (a moderate quantity of which, however, may be considered as not abnormal), to deposit of calcareous salts, to hypertrophy of the membranous labyrinth, to dilatation of the vascular structures, to serous saturation. If of great intensity, hyperemia may cause rupture of the vascular walls with consecutive hemorrhage. *Hemorrhages and ecchymoses* (Fig. 512) may occur in any part of the labyrinth, and there may have been no pre-existing hyperemia. Hemorrhagic extravasation may either be completely absorbed, become organized, undergo fibrous or calcareous degeneration, may cause atrophy and degeneration of the epithelium, connective tissue, and nerve elements, with an abundant formation of granular cells, hyaline corpuscles, and pigmentary deposits, or may induce inflammatory changes terminating in suppuration. *Emboli* may lodge in the labyrinth, as in Friedreich's case of embolus of the arteria auditiva interna, or infectious thrombi may form.

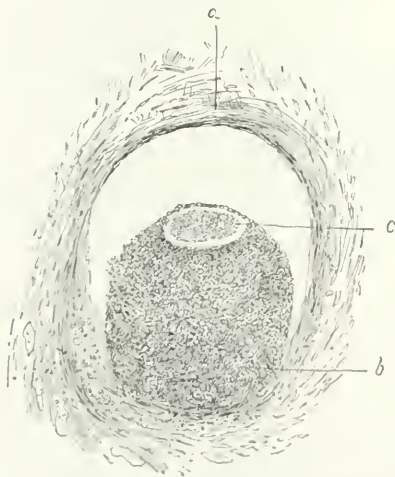


FIG. 512.—Hemorrhage into the semicircular canal (Politzer); a, section of the osseous semicircular canal; b, extravasated blood; c, membranous canal.

In regard to the inflammatory changes taking place in the labyrinth, the writer is inclined to believe that a classification according to the ideas expressed by Gruber is most reasonable and scientific, and would do much to dissipate the confusion now existing in most textbooks on the subject of diseases of the internal ear. *The inflammations affecting the labyrinth are, therefore, divided into: (1) hyperplastic (labyrinthitis hyperplastica) and (2) exudative (labyrinthitis exudativa).* In the former we may have hypertrophy of the auditory nerve stem, due to infiltration and proliferation of the neurilemma (Politzer); deposits of calcareous salts or of

amyloid bodies in and about the nerve; hyperostosis of the petrous bone narrowing the labyrinthine cavities; thickening of the periosteum; increased quantity of the perilymph and endolymph (Steinbrügge); infiltration with small cells and hyperplasia of the connective tissue between the membranous and osseous labyrinth (Moos); a similar condition affecting the membranous labyrinth (Moos); development of osseous tissue from chronic inflammation of the labyrinthine periosteum; excessive epithelial growth on the inner side of the membranous labyrinth in chronic inflammation (Politzer); chronic endarteritis; depositions of concretions of phosphate of lime and of corpora amylacea within the labyrinth. *In the exudative form of inflammation* we have intense hyperemia which may produce a serous saturation of the structures of the labyrinth; an infiltration with small lymphoid cells (Moos) or round cells (Schwabach); a hemorrhagic exudation, as from a pachymeningitis hemorrhagica (Moos); a purulent inflammation, due either to the direct propagation of pus from neighboring structures, or by way of the blood-vessels or by the lymph-spaces (Politzer), or by dehiscences in the bony wall between the superior semicircular canal and the cerebral cavity (J. Dunn), or to infection by the immigration of micro-organisms (Steinbrügge).

These inflammatory processes produce various alterations of the anatomical elements of the labyrinth: the effect of the invasion by micro-organisms is manifested by a mycotic fatty degeneration of the endothelium of the blood-vessels, causing coagulation and thrombosis and colloid degeneration of the labyrinthine tissues (Moos); injury of the acoustic nerve apparatus by hemorrhages or mycotic degeneration—the axis cylinders resisting longest (Moos); stasis and thrombosis of the periosteal blood-vessels (Steinbrügge); rapid destruction of the connective-tissue elements; destruction of the osseous tissue through entrance of the micro-organisms into the periosteum, the bone-corpuscles, and the blood-vessels of the Haversian canals. In addition, the poisonous products of metabolism, the toxalbumins, probably play an important part (Moos). The micro-organisms (streptococcus, staphylococcus and Fränkel's diplococcus of pneumonia (Schwabach) gain entrance to the labyrinth through the aqueducts, the periosteal blood-vessels and, probably, also along the sheath of the auditory nerve, as does the pus. In the beginning, the perilymphatic cavity is almost exclusively the seat of the disease, which later extends to the endolymphatic cavity (Habermann). The micro-organisms seem to collect and to develop their greatest working power in the most dependent parts of the labyrinth (Habermann). The inferior portions of the cochlea are, therefore, most affected (Politzer); Steinbrügge, however, thinks the proneness to location in this region is rather due to the propagation of the affection from the cranial cavity.

As a result of the inflammation of the labyrinth, the nerve fibers, cells, and ganglia (see Figs. 514, 519) are destroyed or atrophied from pressure, their place being taken by newly formed connective tissue, or left vacant, thus forming a system of lacunae corresponding in arrangement to the normal nerve distribution of the part (Moos, Scheibe, Steinbrügge); the membranous labyrinth may be totally destroyed, likewise the structures of the labyrinthine windows, with displacement of the stapes (Habermann); coagulation necrosis of the labyrinthine ligaments may be produced, with consequent collapse of the membranous semicircular canals (Moos); the osseous capsule may be more or less destroyed. If the quantity or virulence of the infection be great, there may be absence of all tendency to reactive inflammation and the production of new formations (Moos).

Should reactive inflammation be established, it results in the production of newly formed granulation- (Habermann) (Fig. 513), connective (Moos,

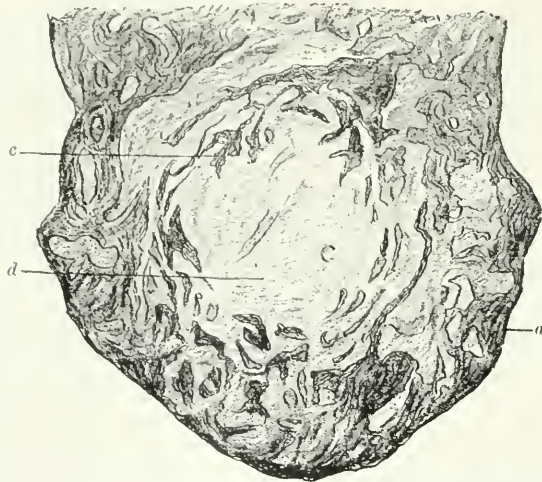


FIG. 513.—Section of semicircular canal of a boy dead from cerebro-spinal meningitis of seven weeks' duration (Habermann). Canal is filled with granulation-tissue (*d*), and in its periphery (*c*) the bone (*a*) is eroded.

Scheibe), fibrous (Gradenigo), or osseous (Toynbee) tissue; these new formations at times going so far as to produce complete obliteration (Fig. 514)

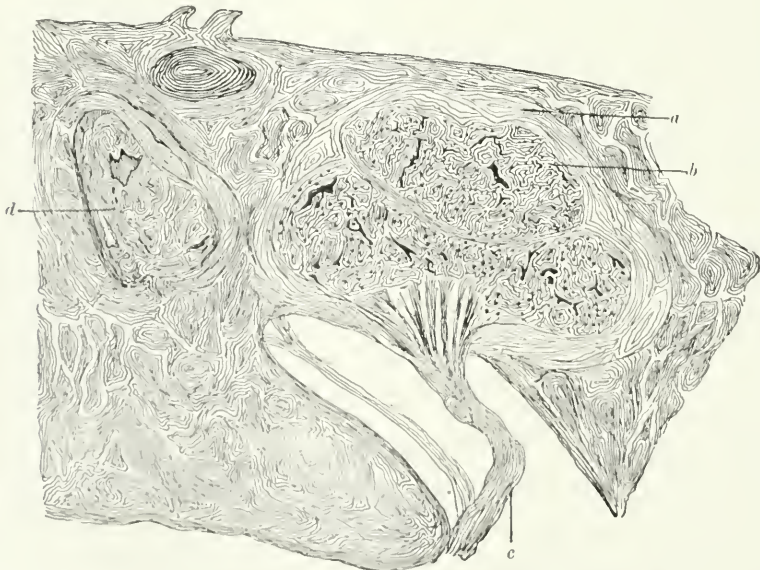

FIG. 514.—Section through the cochlea of a deaf-mute (Politzer): *a*, intact capsule; *b*, cavity of cochlea entirely filled with newly formed osseous tissue; *c*, auditory nerve, whose fibers continue only a short distance into the newly formed osseous mass; *d*, vestibule, narrowed by the hyperplastic process to a small angular space lined with roundish epithelial cells.

of the labyrinthine cavities (Politzer), of the foramina cribrosa, of the aqueducts (Scheibe), and of the oval and round windows (Toynbee). Ossification



proceeds from the remnants of periosteum (Fig. 515) and from the newly formed connective and fibrous tissues.

**Acoustic Nerve.**—Among the pathological alterations of the acoustic nerve apparatus we will first take up changes in the stem of the auditory nerve. Hyperemia and ecchymosis may exist (Politzer); deposition of corpora amylacea or concretions of phosphate of lime; fatty degeneration

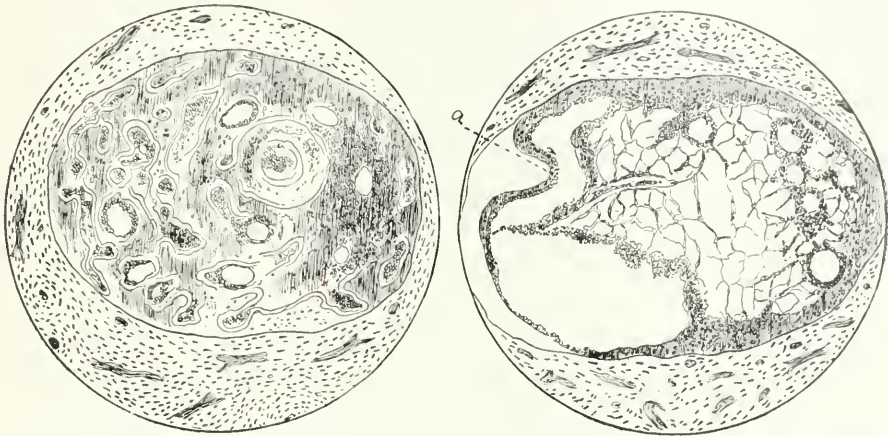


FIG. 515.—Sections of the semicircular canals of a boy dead of hydrocephalus internus (Steinbrügge). The canals are filled with connective and osseous tissue. The ossification is more advanced on the right at (a), beginning from detached periosteum.

(Politzer); gray degeneration (Wernicke); atrophy; leukemic small-celled infiltration (Alt); purulent infiltration (Heller); embedding of the nerve in meningeal exudation (Schwartz). Tumors, principally sarcoma, fibroma, and so-called neuroma, may invade the internal auditory canal (Fig. 516), exerting pressure with consecutive atrophy or even solution of continuity (Politzer). The auditory nerve is more frequently the seat of morbid growths

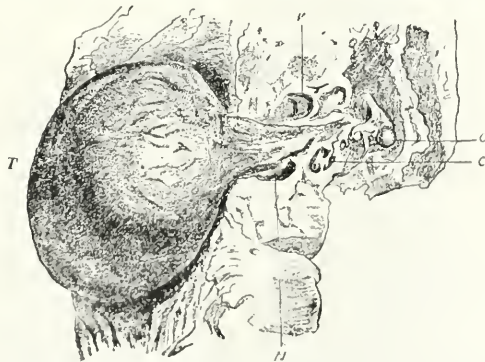


FIG. 516.—Spindle-celled sarcoma of the auditory nerve (Politzer): O, tympanic cavity with malleus and incus; V, vestibule; C, cochlea; T, tumor of the acoustic nerve; N, its extension into the auditory meatus.

than any other cerebral nerve (Virchow). The changes most likely to occur in the region of the acoustic nerve origin in the medulla are due to thickening and purulent inflammation of the ependyma of the fourth ventricle and softening of the floor (Knapp); effusion into the fourth ventricle, either serous (Stuart), aqueous (Jackson), sero-purulent (Armstrong and Clarke), or



purulent (Ames); tumors in or about the fourth ventricle. Disease of the first and second convolutions of the left temporal lobe also interfere with audition (Wernicke), the cortical center for hearing probably being located in this region. Of course, any pathological condition along the course of the cerebral acoustic nerve-fibers also induces disturbances of function. Increased intracranial pressure may cause secondarily increased labyrinthine pressure with depression of Reissner's membrane (Steinbrügge) and bulging outward of the membrane of the round window (Moos). Many cases, however, of increased intracranial pressure, as in chronic hydrocephalus, show no such change in labyrinthine pressure nor any impairment of the function of hearing (Pomeroy).

**Etiology.**—Anemia or oligemia of the labyrinth has been noted in connection with general anemia (Miot and Herek), with continued fevers (Roosa), with gestation and parturition (Pomeroy), with aneurism of the basilar and atheroma of the internal auditory artery (Miot and Herek), with changes in the middle ear exerting pressure upon the labyrinthine structures through the round and oval windows (Pomeroy).

Hyperemia of the labyrinth occurs in all conditions producing congestion of the head (Hartmann); in conditions exerting pressure on the venous channels of the brain and consequent obstruction to the return flow of blood from the ear (Politzer), on the vessels of the internal auditory canal (Politzer), or exerting pressure on the large veins of the neck (Schwartz); in disturbances of the circulation originating in the heart, lungs (Schwartz), or kidneys; in prolonged exposure to sharp sounds (Roosa); in the gouty or rheumatic diathesis. Any hyperemia of the labyrinth occurring in connection with inflammation of the external or middle ear must certainly be considered, since Eichler's recent anatomical confirmation of Schwartz's clinical observations, as the result of a reflex action through the sympathetic upon the vaso-motor nervous system of the labyrinth, rather than a direct influence through anastomoses. Eichler found that the vascular supply of the labyrinth was entirely distinct from that of the surrounding tissues, and that the connection between the vessels of the tympanum and those of the labyrinth, which Politzer maintains, does not exist. Schwartz had long ago held that even in the very highest degrees of inflammation of the tympanum it is only exceptionally that a simultaneous hyperemia is met with in the labyrinth. It is a matter of observation that in chronic middle-ear suppuration with granulomata and polypi the functional tests show no impairment of function of any importance in the sound-perceiving apparatus.

Hemorrhages and ecchymoses are prone to happen in all conditions producing hyperemia of the labyrinthine structures; in the infectious diseases causing changes in the vascular walls; in pachymeningitis hæmorrhagica (Moos); in leukemia (Steinbrügge); in typhoid fever (Barelay); in nephritis, gout, and rheumatism; in fracture or concussion of the skull; in diabetes; sometimes in embolism of the arteria auditiva interna (Gruber).

Atrophy and degeneration of the acoustic nerve apparatus may be caused by syphilis; by any labyrinthine inflammation of sufficient gravity to interfere with nutrition; by changes in chronic otitis media exerting long-continued pressure on the labyrinth and thus producing anemia, which, if continued for a sufficient time, will result in nutritive changes of the nature of atrophy (Pomeroy)—and these secondary nerve affections may remain although the tympanic disease disappears (Gruber); by acute hydrocephalus internus, leading to softening and shrivelling of the nuclei of the auditory nerve (Politzer); by fetal ependymitis (Meyer) doing the same; in chronic

hydrocephalus, tumors of the brain and the nerve from pressure (Politzer); gray degeneration and atrophy in tabes dorsalis (Pierrot, Wernicke, Habermann); in old age by calcareous deposits (Böttcher) and corpora amylacea (Politzer); by hemorrhage; by nephritis and influenza (Gradenigo); by contraction of the basilar artery (Politzer); by apoplectic and inflammatory processes involving the floor of the fourth ventricle (Politzer); by professional concussion of sound (Roosa); by purulent inflammation of the ependyma (Politzer); by purulent inflammation of the stem of the auditory nerve from a similar condition of the meninges (Politzer); by emboli and embolic softening along the acoustic nerve tracts (Politzer). Among the nerves of sense, the auditory is the most "impressionable"—that is, its function is more frequently impaired by general diseases and by chemical changes in the blood in infectious diseases (Politzer). Affections of the auditory nerve attack, in the majority of cases, both organs of hearing. It is probable that degenerative processes involving one auditory nerve will in time pass over to the other. The view that atrophy of the auditory nerve can take place purely from inaction, as in ankylosis of the stapes, has not yet been corroborated by experience (Politzer); in fact, the results of post-mortem examinations point the other way. The changes which occur in presbycusis and otitis media sclerosa seem to be due to a coincident trophic disturbance similar to that in the middle ear rather than to any atrophy from disuse (Alderton). Central atrophy depends almost without exception upon cerebral disease, whilst the peripheral is most often a consequence of disorders of the auditory organ itself (Gruber). The occurrence of the disturbances of hearing in these processes depends less upon the extent than upon the seat of the pathological accumulation (Politzer).

**Hyperplastic inflammation** (labyrinthitis hyperplastica) may occur in syphilis, which is causative in most of the forms of this affection; in the first stages of exudative inflammation of the labyrinth due to infectious diseases, and the inflammatory process may advance no further (Moos); in gout and rheumatism; in rachitis; in typhoid fever and leukemia and in old age.

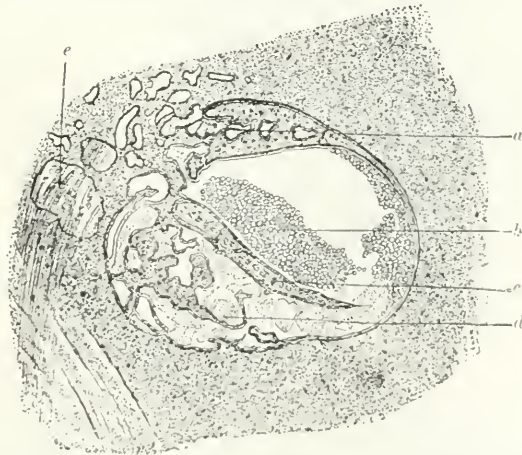


FIG. 517.—Section of the basal coil of the cochlea, from a deaf man who died of leukocythemia: *a*, osseous growth on the median wall of the scala tympani; *b*, leukocythemic plaques in the scala tympani; *c*, lamina spiralis; *d*, connective tissue and osseous growth in the scala vestibuli; *e*, atrophic ganglion cells in Rosenthal's canal (Politzer).

**Exudative inflammation** (labyrinthitis exudativa) may be caused by obstruction in the internal auditory meatus to the outflow of blood from the

labyrinth (Politzer); by typhoid fever (Barclay); leukemia (see Fig. 517) (Politzer); epidemic cerebro-spinal, hemorrhagic, pachy- and simple meningitis (Heller, Moos, Politzer); syphilis, tuberculosis, measles, diphtheria, scarlatina, scarlatinal diphtheria, mumps, variola; by an extension from an otitis media purulenta of long standing (Bezold). This form of inflammation occurs more frequently in children than in adults, because of the more frequent occurrence in children of the acute exanthemata, etc. Further, the anastomotic connections between the middle ear and the labyrinth on the one hand, and between the labyrinth and the cranial cavity on the other, are more numerous in children than in adults; and further, because in the child's ear through the aqueducts there is a freer communication between the labyrinthine fluid and the cerebro-spinal cavity than in the adult (Politzer).

**Symptomatology.**—**Functional Reactions in General.**—Before taking up the departures from the normal reactions to functional tests in diseases of the sound-perceiving apparatus it is necessary to devote some attention to the normal decline in hearing evidenced in advancing age. Zwaardemaker has tabulated the average responses for the upper-tone limit at the different periods of life about as follows:

|                                                                             |      |
|-----------------------------------------------------------------------------|------|
| Galton's whistle (see Fig. 472) is heard under 10 years at the mark . . . . | 1.22 |
| “ “ “ is heard from 20 to 30 “ “ “ . . . .                                  | 1.39 |
| “ “ “ “ 40 to 50 “ “ “ . . . .                                              | 2.23 |
| “ “ “ “ over 60 “ “ “ . . . .                                               | 3.03 |

A presbycusis (hearing of old age) may, however, be considered as normal

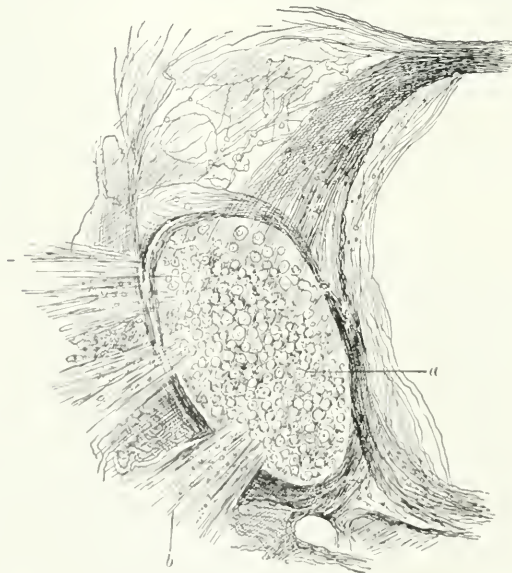


FIG. 518.—Section of Rosenthal's canal and the spiral ganglion (normal), showing—*a*, ganglion-cells in Rosenthal's canal; *b*, nerve-fibers of the cochlear branch entering into the ganglion (Politzer).

which is not lower than Galton 4.8 (Zwaardemaker). The lower-tone limit is elevated to about the same extent in old age (N. J. Cuperns). In old age the B.-C. (bone-conduction) does not alone experience a reduction, but sinks proportionately with the lessening of the hearing distance, the A.-C. (air-conduction), etc. (Bezold).



In diseases of the sound-perceiving apparatus, the *upper-tone limit*, obtained by means of the Galton whistle, is *lowered*—i. e. the highest notes elicited by the whistle being denoted by one or fractions of one, and the lower notes by multiples of one and their fractions; as the obturator is withdrawn the note deepens or lowers at the same time that the indicator or graduated

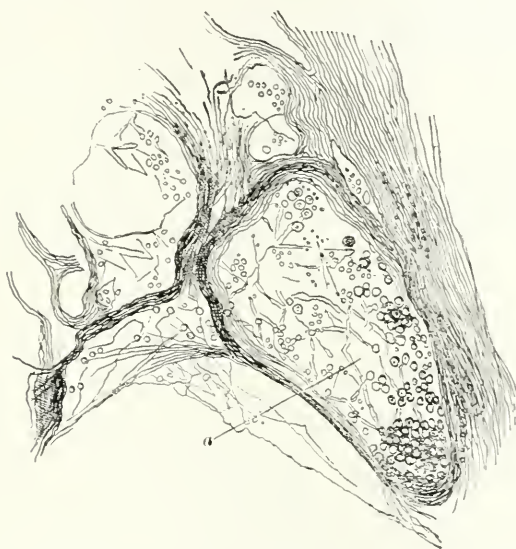

FIG. 519.—Section through Rosenthal's canal of a boy dead of acute encephalitis, who became suddenly deaf five years previously, showing marked atrophy of nerve-cells and fibers; a, Rosenthal's canal (Politzer).

scale shows higher and higher numbers, and, therefore, a higher number on the scale, as 4.8, indicates a much lower note than a lower number, as 1.22. The *lower-tone limit* by A.-C. (air-conduction), as obtained by a clamped tuning-fork vibrating from 26 to 64 double vibrations in the second, is *impaired very little or not at all*. The *absolute duration* of B.-C. (bone-conduction), Schwabach's test, is *shortened or abolished* for all or for certain tones. A.-C. > B.-C. (air-conduction is better than bone-conduction), both in *intensity and in duration* throughout the musical scale, Rinné's test. If the disease is unilateral, the vibrating tuning-fork C, placed in contact with the vertex, midway between the ears, should be heard in the unaffected ear, Weber's test; or in the better-hearing ear if the disease is bilateral. This test is not so reliable as those previously described. In labyrinthine disease the patients hear the deeper tones of speech very well, while the higher tones are no longer perceived (O. Wolf). It is well in testing with the whisper or speech to remember O. Wolf's division of the voice-sounds into—

1. The deep, like R and V;
2. The middle, like the explosives B, K, and T;
3. The high and strong, like S, Sh, and G; and the high and weak, like F, L, N, and H (which are excluded as dependent on other tones—tone-borrowing).

Wolf devotes particular attention to the consonants. Bezold employs the names of numbers as test-words, as these are familiar to both children and adults. Equal intensity of sound can be obtained by using the reserve



air left after a forced inspiration followed by a normal expiration (J. E. Sheppard). To test the hearing for speech thoroughly, it is quite sufficient in most cases, after testing a few words, to note the distance for those words perceived with the greatest difficulty (Lucæ).

*Disturbances of equilibrium are apt to be observed in any process producing irritation of the nerve-endings in the vestibule, the semicircular canals, or in the stem and origin of the auditory nerve.* In testing for disturbances of equilibrium, it is well first to determine the static (the body at rest) equilibrium and then the dynamic (the body in motion) equilibrium. The author tests the former by means of the apparatus shown in Plate 12, consisting essentially of a movable inclined plane, after the method of v. Stein. A person with normal powers of equilibrium should be able to maintain his erect position until the board reaches an inclination of  $35^{\circ}$  to  $40^{\circ}$  to the horizontal when facing toward the apex of the angle—*anterior inclination*. *Posterior inclination*, with the back turned toward the apex, varies from  $20^{\circ}$  to  $30^{\circ}$ ; *lateral inclination*, with the side toward the apex, from  $37^{\circ}$  to  $38^{\circ}$ . In patients with labyrinthine disease, giving rise to vertigo, etc., the angle measures  $20^{\circ}$  or less by anterior inclination, etc., and this is much decreased when the eyes are closed. The static equilibrium is also tested with the eyes open and shut, with the legs close together, while standing on the toes, and while standing on one leg. A healthy person can stand in these positions for some time, with slight balancing, while the eyes are closed; but a person with imperfect powers of equilibrium immediately begins to show disturbances of these powers. The dynamic equilibrium is tested by walking forward and backward on a level, by turning on the vertical axis of the body to the right or left with legs together, and, finally, by turning about on one leg alone. The last movement is the most difficult, but a healthy person can go through these various motions with little if any trouble; whereas aural patients with disturbance of the powers of equilibrium find it more or less difficult or impossible, and their movements are attended by great weariness.

Given these reactions, the inference is well-founded that we have to do with an affection of the sound-perceiving apparatus. Still other tests have been devised by Bing, Brenner, Gradenigo, Gelle, and others; but the above have been more universally tried, are sufficient for the purposes of diagnosis, and are more reliable.

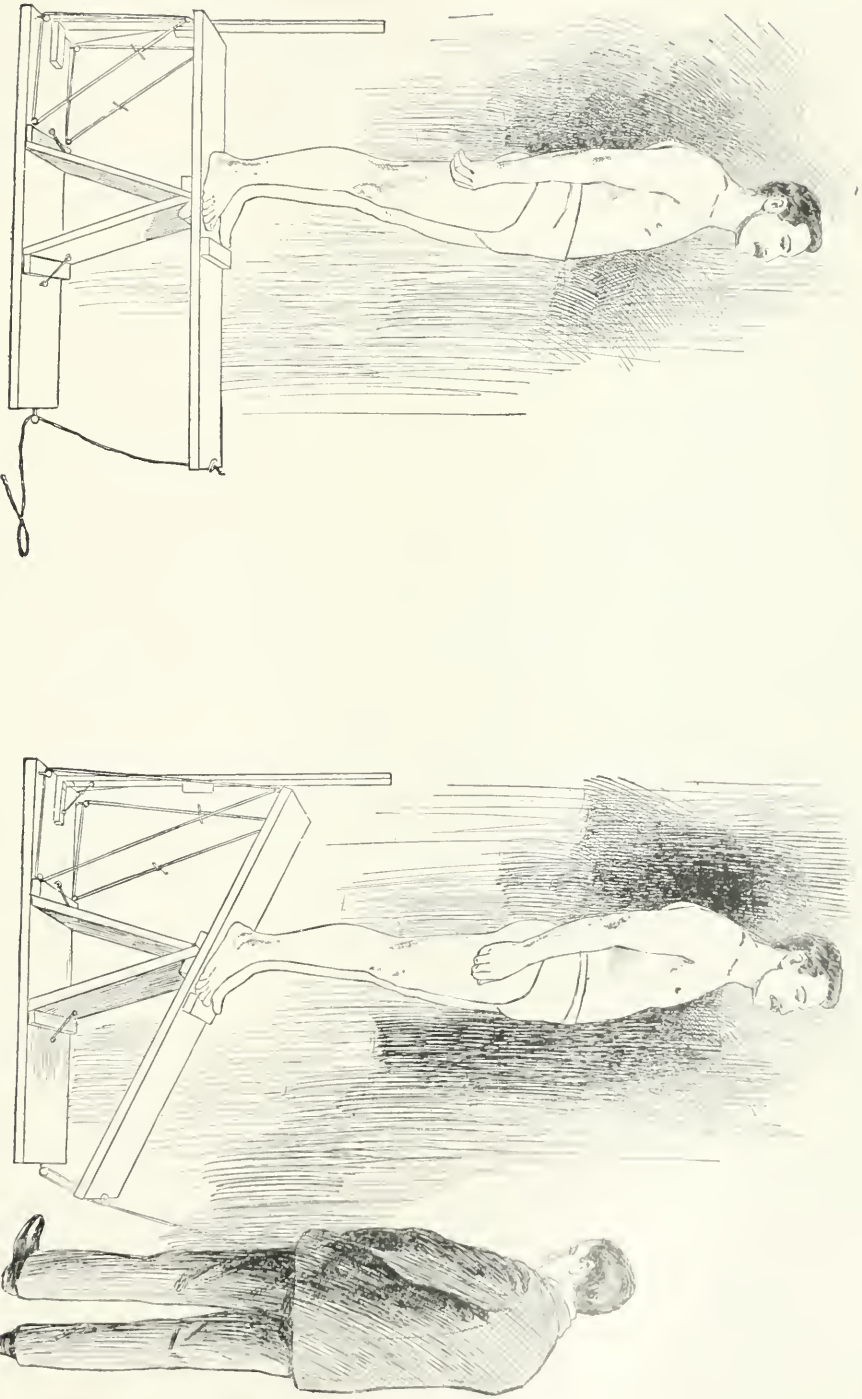
The symptoms of affections of the sound-perceiving apparatus are more particularly described as follows:

**Anemia.**—There is usually some dulness of hearing, which is manifested either as a slowness of perception only, or as a real impairment of the hearing power. The impairment in the hearing ability follows along the line of the test-responses as given above, especially, however, being noticeable in the curtailment of the duration of B.-C. Annoying tinnitus of a low pitch is commonly present. The patient may be subject to occasional attacks of vertigo, and usually is the victim of general anemia.

**Hyperemia.**—There is very little if any impairment of the hearing power, and there may be present hyperesthesia of the nerve to certain sounds. Often there is a feeling of fulness and distention in the ears or in the head, with dulness of intellect or even giddiness or vertigo at times. With this is usually associated a high-pitched tinnitus. The functional tests show a limited involvement of the sound-perceiving apparatus. Paresthesiæ are likely to be complained of.

**Hemorrhage** is usually immediately followed by marked vertigo, aggravated on closure of the eyes, with possible falling or unconsciousness (the

PLATE 12.



The author's static goniometer, consisting of a plane acting on the principle of a lever, the fulcrum being in the middle. The resistance at one end is obtained by solid rubber cords passing through pulleys, and the power at the other end by friction on a cotton cord passing through a pulley on the base-board. An upright at the resistance end is graduated in degrees corresponding to the angle that the inclined board makes with the base-board. The apparatus is made so as to be easily taken apart and stowed in small compass. A toe-rest to prevent slipping of the feet on the smooth board is placed, just so far in front of the fulcrum as to bring the center of gravity of the patient about 2 to 3 inches behind the fulcrum. The apparatus is made of common pine boardings.



latter is rather rare) unless the hemorrhage is confined to the cochlea, in which case vertigo is absent (Gradenigo). With or immediately following this occur nausea or vomiting, severe tinnitus (in some cases preceding the attack), occasionally profuse perspiration, and impairment of the hearing up to complete deafness. The symptoms thus given constitute what was formerly generally designated as Ménière's disease, and is the only condition to which that name should be given. Amelioration of these symptoms takes place in a short time, the vertigo, hardness of hearing, and tinnitus continuing longest. The hardness of hearing rarely disappears entirely, and the tinnitus is likely to persist, although diminished in intensity. There is always danger of a repetition of the hemorrhage. The functional tests give varying responses according to the locality and the extent of the hemorrhage, but always confirm a diagnosis of involvement of the sound-perceiving apparatus.

The symptoms of embolism and thrombosis are presumably similar to those of hemorrhage, and serous effusion can give the same more fleetingly (Gruber).

**Labyrinthitis Hyperplastica.**—The most marked form of this inflammation is seen in connection with syphilis, usually as a late manifestation in the acquired, or around puberty in the hereditary, and gives rise to deafness, appearing gradually or suddenly, subject to periods of quiescence and exacerbation; also to loud aural tinnitus. Vertiginous attacks and disturbances of equilibrium are usually slight unless the exudative form of inflammation is induced. It is likely to be accompanied by very violent headache (Charazac), often nocturnal (Pomeroy) when due to syphilis. Both ears are usually affected. The sudden deafness coming on with serous saturation or lymphoid infiltration may disappear almost completely; but usually the hyperplastic formations are causative of a certain amount of permanent deafness. The functional tests leave no doubt as to the seat of the trouble in the sound-perceiving apparatus.

**Labyrinthitis exudativa** in its most acute form comes on very suddenly with perhaps a rigor; with fever, nausea, or vomiting very commonly; with profound deafness, marked derangement of co-ordination; at times, stupor or delirium (although usually the mind is clear); intense tinnitus and vertigo, and, in some cases, pain. This very acute form occurs with epidemic cerebrospinal meningitis (Votolini described this form of inflammation as a primary inflammation, but there is not much doubt that it is an affection secondary to a more or less localized meningitis), with the acute infectious diseases (measles, scarlet fever, diphtheria, etc.) or epidemic parotitis, etc. Most of the symptoms abate or disappear in a few days to a few weeks, but the staggering gait and deafness are more persistent—the latter rarely improving to any great extent. Functionally, the upper-tone limit is greatly lowered; B.-C. markedly reduced throughout or destroyed for part or all of the musical scale; A.-C. > B.-C.; the power of equilibrium much impaired. The less acute forms of exudative inflammation of the labyrinth give rise to vertigo (unless confined to the cochlea), to sudden loss of hearing power, intense tinnitus, lowering of the upper-tone limit, with B.-C. reduced or absent, A.-C. = B.-C., and to disturbances of equilibrium.

In affection of the nerve-trunk the most prominent symptom is impairment of hearing. There are also present tinnitus, vertigo, staggering gait, and excessive functional exhaustibility (Gradenigo). Usually unilateral, it may be bilateral, as in tabes dorsalis. Hardness of hearing is usually most pronounced for the tuning-forks of middle register (Gradenigo), perception for high and low notes being fairly well preserved. B.-C. is very much impaired.



Word-deafness (sensory aphasia) furnishes the most reliable sign of involvement of the *cortical area*, usually of the left first temporal convolution. The function of both ears is usually impaired; tinnitus is more commonly absent; B.-C. is reduced in duration (see page 779).

Concussion of the head may provoke symptoms indicating an involvement of the sound-perceiving apparatus even up to complete deafness, and this latter may be induced without any recognizable changes being necessarily found in the labyrinth on post-mortem examination (Gruber). The symptoms usually present are diminution of hearing, tinnitus, vertigo, headache, unconsciousness, pain occasionally, occasionally acoustic hyperesthesia or alteration in pitch of certain tones, etc., one or all. These symptoms have been explained as due to shock to the acoustic nerve (Buck), basilar inflammation resulting from a blow (Buck), or hemorrhage at the point of origin of the acoustic nerve (Moos).

Fractures of the petrous bone, involving the labyrinth, are accompanied by hemorrhage from the meatus, or if the tympanic membrane is not ruptured, the blood may pass through the tympanum and the Eustachian tube into the throat (Buck); serous-looking discharge in considerable quantity; very pronounced subjective noises; disturbances of equilibrium and vertiginous symptoms; facial paralysis in 55 per cent. of the cases (Schmidt). In both concussion and fracture the functional tests of involvement of the sound-perceiving apparatus are present.

Neurotic disturbances of the sound-perceiving apparatus, which may be unassociated with pathological anatomical alterations, are by no means uncommon, and are described below.

Acoustic neurasthenia has as symptoms impairment of hearing, varying from mere slowness (acoustic torpor or lassitude) to considerable deafness, especially marked under any prolonged strain or confusion of sound, mental anxiety, or extreme physical fatigue (Poli), and improving rapidly after rest. Tinnitus may or may not be present, and is increased by fatigue; paresthesiæ are common, with great fluctuation of the ability to hear; the upper-tone limit is not apt to be impaired; but the duration of B.-C. is lowered throughout the musical scale, and there is great functional exhaustibility of the acoustic nerve. Either one or both ears may be involved, though usually both. The patients are generally neurasthenic, and any circumstance which aggravates this condition is the cause of marked decrease in the hearing (Gelle). This condition is frequently associated with that following.

Acoustic hysteria is usually associated with great deafness, which appears suddenly and is not subject to the fluctuations noticeable in neurasthenia; it is the same throughout the continuance of the attack. Vertigo is never present (Rohrer), and tinnitus is not frequent; one or both ears may be affected or the attack may pass from one ear to the other; paresthesiæ or anesthesia of the external auditory canal and the tympanic membrane may be present (Würdemann); functional tests are apt to be contradictory, the most constant being lowering of the upper-tone limit.

Hyperacusis is an overexcitable condition of the acoustic nerve, sometimes even painful, occurring generally periodically in connection with great nervous or mental excitement, with neuralgia, or after partaking of stimulants (Politzer). It also occurs in the incipency of inflammatory affections of the ear.

Paracusis consists in the false perception of the pitch of a sound. *Paracusis loci* is the inability to tell the direction from which the sound comes, and depends upon the difference in the acuteness of perception of the two

ears. As our judgment of the direction of sound depends upon binaural hearing, in unilateral deafness the apparent source of the sound will be projected in the direction of the normal-hearing ear (Politzer).

**Diplacusis** is a form of paracusis in which a single tone is heard double; either each ear perceives the tone differently and it seems doubled (*D. binauricularis*—Knapp), or a double perception of a single tone is got by one ear (*D. monauricularis*): the two tones differ from each other in time (*D. echoica*) or in interval (*D. harmonica* or *disharmonica*—H. Daae).

“**Nervous tinnitus**” (Politzer) may exist as a pure neurosis without difficulty of hearing. It is observed as an irritable condition of the nerve in convalescence from severe febrile affections; in connection with sexual excesses, intemperance, overfatigue of the auditory nerve, and extreme mental disturbance. It may continue indefinitely, the hearing remaining unimpaired.

**Hallucinations of hearing** may occur rarely in ear-diseases without a changed condition in the brain (Politzer).

**Color-hearing** is a term employed to define that phenomenon by which certain tones always excite in some people the sensation of color.

**Deaf-mutism.**—One of the most important results of labyrinthitis is the production of deaf-mutism. In the United States there were about 38,200 deaf-mutes to every 100,000 inhabitants (v. Tröltzsch), but this proportion is apparently diminishing. They belong, to a great extent, by birth to those classes of society which are least favorably situated economically as well as socially (H. Mygind). In the majority, the deaf-mutism develops before the end of the third year (Robertson), but may develop as late as the eighth year (Lemeke). The pathological seat of the causative process is, almost without exception, in the labyrinth (H. Mygind). In connection with the labyrinth, the middle ear is surprisingly often found to be affected, only exceptionally as regards lack of formation, but almost regularly by violent inflammation, generally of a purulent nature (H. Mygind). Deaf-mutism occurs more frequently in the male sex (v. Tröltzsch). More than half the cases are due to acquired deafness (H. Mygind), and epidemic diseases are probably most often the cause of the deafness (H. Mygind). Bezold is probably nearly right in his statement that about 43 per cent. are totally deaf, and it is the general opinion that among these the acquired are greater in number than the congenital (Hartmann). There is noticeably a very frequent occurrence of partial defects in the musical scale, in which sometimes the upper and sometimes the lower limits of tone are absent; sometimes single or multiple gaps or islands are found which show no perception at all (Bezold). Only about 8.4 per cent. have hearing power sufficient for intercourse with other people (Lemeke). Disturbances of equilibrium (static or dynamic) are present in 50 per cent. (A. Bruck), and those showing normal equilibrium are also much more apt to have normal speech (L. W. Stern). Heredity exerts a great influence, especially in those families in which there are many cases of hardness of hearing, but direct transmission is absent, as Mygind found that not a single child of deaf-mute parents was itself deaf and dumb. Consanguineous marriages are only causative when joined to hereditary and other influences (as constitutional disease)—(L. Blau). Deaf-mutism is especially apt to occur in those families in which many children have been born in rapid succession (H. Mygind). Gillespie has drawn attention to the frequency of goiter in deaf-mutism; and Lemeke, of affections of the naso-pharyngeal tract, especially adenoid vegetations. The bodily growth keeps pace with that of normal persons, but there is defective brain development (Lemeke); as a rule, however, they are endowed with organic, mental, and normal sensitive-

ness but little inferior to the normal (Ottolenghi). They do not exhibit a higher mortality than normal individuals living under the same circumstances (H. Mygind), but they are especially prone to lung-diseases. Nearly half of all deaf-mutes over 20 years of age are obliged to fall back on the help of others for their maintenance (H. Mygind). Marriages contracted by deaf-mutes exhibit a very small degree of fertility (H. Mygind).

**Diagnosis.**—The diagnosis has been almost sufficiently indicated in the symptomatology, but there are a few points that it seems well to emphasize.

In any case of hardness of hearing the first thing to be determined is whether the lesion is located in the sound-conducting or in the sound-perceiving apparatus. The antagonistic reactions to the functional tests may be tabulated as follows :

*Diseases of the Sound-conducting Apparatus.*

Upper-tone limit very little, if any, lowered.

Lower-tone limit by A.-C. elevated.

Absolute duration of perception of B.-C. increased throughout the musical scale.

B.-C. > A.-C. both in intensity and duration in the lowest part of the musical scale, and ascending with the gravity of the disease (Rinné).

Weber's test heard in the diseased or the harder hearing ear.

Deeper tones of speech not heard; higher tones well heard.

*Diseases of the Sound-perceiving Apparatus.*

Upper-tone limit noticeably lowered.

Lower-tone limit by A.-C. not elevated.

Absolute duration of perception of B.-C. diminished or abolished throughout all or in parts of the musical scale.

A.-C > B.-C. both in intensity and duration throughout the musical scale (+ Rinné).

Weber's test heard in the normal- or better-hearing ear.

Deeper tones of speech well heard; higher tones not heard.

In order to bring these differing reactions more graphically before the eye, the author has arranged them below in the *schema* originally devised by himself, first giving the normal reaction in the healthy ear for comparison—the numerals representing the duration of perception in seconds, the Rinné showing whether the respective forks are heard louder by A.-C. or B.-C. at the initial point.

In marked disease of the sound-conducting apparatus the reaction will be approximately as below :

| A.-C.          | A.-C. | A.-C.           | A.-C.            | A.-C.            | A.-C.           | Rinné.                        | B.-C.          | B.-C. | B.-C.                      | B.-C.           | B.-C.            | Equal           |
|----------------|-------|-----------------|------------------|------------------|-----------------|-------------------------------|----------------|-------|----------------------------|-----------------|------------------|-----------------|
| 22             | 25    | 15              | 33               | 32               | 22              | Schwabach }<br>B.-C.<br>A.-C. | 0              | 8     | 8                          | 13              | 15               | 13              |
| 12             | 13    | 7½              | 13               | 13               | 14              |                               | 14             | 14    | 11                         | 17              | 16               | 14              |
| C <sup>i</sup> | C     | C <sup>ii</sup> | C <sup>iii</sup> | C <sup>iii</sup> | C <sup>iv</sup> | Tuning-fork.                  | C <sup>i</sup> | C     | C <sup>i</sup>             | C <sup>ii</sup> | C <sup>iii</sup> | C <sup>iv</sup> |
| Galton 1 5/10  |       |                 | Weber =          |                  |                 |                               | Galton 1 2     |       | Weber in the affected ear. |                 |                  |                 |

Average normal ear.

Average case of otitis media purulenta recurrens.

<sup>1</sup> It will be noticed that the upper-tone limit is slightly impaired in the scheme; this is in keeping with the author's findings as described in the article "The Upper-tone Limit in the Normal and Diseased Ear."

In disease of the sound-perceiving apparatus the following reactions will serve as a type :

|                |       |                |                                  |                  |                 |                            |
|----------------|-------|----------------|----------------------------------|------------------|-----------------|----------------------------|
| A.-C.          | A.-C. | A.-C.          | A.-C.                            | A.-C.            | A.-C.           | Rinné.                     |
| 12             | 17    | 18             | 21                               | 15               | 10              | Schwabach { A.-C.<br>B.-C. |
| 4              | 6     | 7              | 6                                | 4                | 2               |                            |
| C <sup>I</sup> | C     | C <sup>I</sup> | C <sup>II</sup>                  | C <sup>III</sup> | C <sup>IV</sup> | Tuning-fork.               |
| Galton 2.7     |       |                | Weber in the better-hearing ear. |                  |                 |                            |

Average case of otitis interna.

In cases in which there is an affection of both the sound-conducting and sound-perceiving apparatus, both upper- and lower-tone limits are contracted, the duration of B.-C. is impaired, B.-C. is better than A.-C. (—Rinné) for the lower forks, while A.-C. is better than B.-C. (+Rinné) for the higher forks, and both the higher and deeper tones of speech are imperfectly heard. The degree in which one or the other apparatus is responsible for the hardness of hearing is indicated by the closeness of the resemblance of the results of the functional tests to the reactions given by the one or the other type of disease.

In the matter of locating the lesion in any particular portion of the sound-perceiving apparatus much has yet to be learned, but the following deductions seem to be well established as the result of post-mortem examinations of cases clinically observed before death : word-deafness points to involvement of the cortical areas ; lower- and upper-tone limits fairly well preserved with deafness for forks of middle register and greatly impaired B.-C. indicate involvement of the nerve-stem (Gradenigo) ; disturbances of equilibrium may occur in the course of any pathological process causing irritation of the terminal filaments in the vestibule or ampullæ, of the nerve-fibers in the auditory nerve-stem (Kreidl), or of the central origin of the nerve (Hillairet) ; pathological processes involving the cochlea alone do not induce vertigo (Gradenigo) ; the cochlea is the only part specialized for the perception of sound, as the retina is for light, and its total destruction is followed by total deafness ; it is probable that the lower notes are perceived at the cupola, and the higher notes at the base.

In attempting to make a diagnosis these deductions should be borne in mind while studying the results of the functional testing, remembering always, however, that it is often impossible to determine whether the disease is in the labyrinth, nerve-trunk, or central course (Politzer).

In fracture of the petrous bone, the escape of cerebro-spinal fluid is not essential (Gruber), and no certain conclusions with respect to the anatomical situation, gravity, or the subsequent behavior of the fracture can be drawn from the external appearances in the ear and from the functional disturbances (Schmidt). In most cases both the internal and middle ear are affected together (Schmidt). Fracture may occur without loss of hearing (J. E. Shepard) if the labyrinth is not involved in the fracture line.

The diplacuses are, in the author's experience, usually due to affections of the middle ear, as in a case recently observed of diplacusic echoica coming on during the acme of an attack of otitis media subacuta.

The neuroses are recognized by their symptoms and the peculiar constitutional condition of the patient.



Bearing in mind the above few remarks in connection with those on symptomatology, the diagnosis, according to our present knowledge, should not offer insuperable obstacles to the conscientious observer.

**Prognosis.**—The prognosis is always hopeful in those cases in which there has been no destruction of the anatomical elements, as in anemia, neurasthenia, etc.; always unfavorable in those cases in which such destruction has taken place. The condition remaining after a trial of treatment of moderate duration is apt to be the condition that will remain permanently, except in the case of hemorrhage, where repeated attacks will tend to further impairment of hearing.

Amelioration may and usually does take place in the other symptoms, such as vertigo; but the hearing improves only so far as the anatomical elements develop recuperative power, and when that power is exhausted, improvement ceases.

**Treatment.**—The treatment of anemia of the labyrinth is in most cases practically that of the treatment of general anemia, as in the anemia and oligemia following gestation and parturition. In the local anemia due to aneurysm or atheroma very little can be done; when due to pressure brought on by changes in the middle ear, operative interference to relieve that pressure, if possible, should be undertaken.

Hyperemia, if acute, should be met by local blood-letting, purgation, and rest at the same time that the diet is limited and stimulants interdicted. The causative agency should always be searched for and corrected as far as possible on general lines. Regulation of the diet and bowels, curtailment or denial of stimulants, and correct ordering of the care of the body and method of life are always indicated and produce the best results.

Hemorrhages into the labyrinth should be treated, until the acute symptoms subside and absorption begins, by complete bodily rest, local blood-letting, purgation, hot foot-baths, limitation of diet, and abstinence from the use of all stimulants, alcohol, tobacco, etc. Later, comparative rest and abstention from mental or physical work, with the regulation of the diet and bowels, will do more to favor absorption than the administration of drugs. Should this method of treatment be found impracticable, or conjointly with it, iodid of potassium in gradually increasing doses has given the best results in the author's hands. Pilocarpin has been strongly advocated by some authors, given either by the mouth or hypodermatically, beginning with one-eighth of a grain two or three times daily and working up until the physiological effect is obtained, when the patient is held to that dosage for a shorter or longer time.

In the hyperplastic form of labyrinthitis, regulation of diet and digestion, of the bowels, and denial of stimulants, counter-irritation over the mastoid, and attempts to provoke derivation and, most important, the attempted removal of the cause. Resolution may be encouraged by the administration of iodid of potassium or of pilocarpin, if these are not contra-indicated by the condition causing the lesion or by the state of health of the patient.

During the acute stage of the exudative form of labyrinthitis as much should be done as possible to decrease the intensity of the attack and to limit the extension of the process. This in most cases amounts to very little. Rest in bed is imperative, limitation of the diet, cardiac sedatives, diaphoretics, regulation of the bowels, and derivatives not contra-indicated by the general condition. After the acute symptoms have subsided, resolution is to be encouraged by the continuance of rest, light but nourishing diet, the regulation of the excretory organs, and the administration of those remedies

known to have an effect on the pathological deposits and new formations, such as the iodid of potash, mercury, pilocarpin, etc.

The regeneration of the affected nerve-elements may be encouraged by the administration of the various nerve-stimulants and nerve-foods, such as strychnia, phosphorus, etc.

The principal treatment for concussion and fracture is rest and the meeting of symptoms as they arise.

The treatment of acoustic neurasthenia is, of course, that of the general neurasthenic condition. The general health should be improved by all the means at our command. The author has found that the feeling of well-being produced by the administration of gelsemium is a very important aid in inducing the patient to attempt and to adhere to those regulations necessary to the attainment of this much hoped-for improvement; it should be administered in the form of the fluid extract. Strychnia has produced only a temporary improvement in the author's hands. The general health must be improved if any permanent betterment is to be attained, and gelsemium has the power of stimulating the ambition of the neurasthenic to the extent of accomplishing the tasks necessarily set for this purpose.

Hysteria requires the administration of those remedies—pharmaceutical, psychical, and physical—usually recommended for use in the general condition.

The various other neuroses, reflex and otherwise, are to be treated from the standpoint of the cause.

It will be noticed that the subject of the treatment of affections of the sound-perceiving apparatus by means of electricity, phono-massage, and various other more or less imperfectly tried remedies has not been touched upon by the writer. The reason for this lies in the fact that the advantage to be derived from these remedies has been much doubted by very many competent otologists who have given them fair trial, and that certain disadvantages in their use have been discovered in some conditions. Further attention needs to be devoted to them as remedial agencies.

The treatment of deaf-mutism consists in the removal of any curable pathological conditions found to exist in the sound-conducting apparatus and the improvement of what hearing power still remains in the sound-perceiving apparatus. Chronic suppuration of the middle ear is especially prevalent among those mute from acquired deafness, and should receive competent attention to prevent fatal results. Urbantsehitsch has recommended systematic acoustic instruction by the pronunciation of vowels, consonants, single words, and sentences; the instruction to be given for a short time two or three times daily. Politzer is of the opinion that this may be the means of effecting a modulation in speech, but that the hearing cannot be affected thereby, because it has generally been lost through processes which have run their course and have left behind irreparable anatomical changes.

# OPERATIONS.

By J. ORNE GREEN, A. M., M. D.,

OF BOSTON, MASS.

## OPERATIONS ON THE AURICLE.

**Auricular appendages** are composed either of fat or cartilage covered with skin (Fig. 520). Their removal for cosmetic effect by an elliptical incision is usually simple. If they are cartilaginous, the cartilage often extends inward quite deeply, but the removal of the whole is unnecessary; it is sufficient to cut off the cartilage just below the level of the surrounding surface and suture the skin.

**Coloboma of the lobule** may be congenital or acquired, the latter usually caused by heavy ear-rings, which have slowly cut their way out. The operation for both varieties is practically the same (Fig. 521). Cut a strip of skin from *a* to the lower edge of the lobule and turn it down; from the same point, *a*, freshen the edges as far as *b* by removing a thin strip;

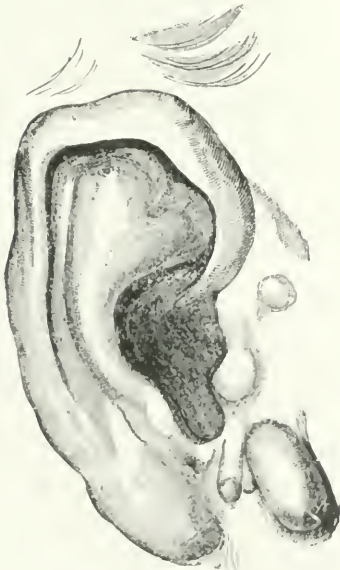

FIG. 520.—Polyotia of auricular appendages, consisting of the nipple-like outgrowths in front of the ear (v. Ammon).

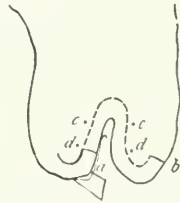

FIG. 521.—Operation for coloboma of lobule.



FIG. 522.—Snellen's clamp for bloodless operation on the lids or lobule.

suture the lobule at *c* and *d* by transfixing sutures, then suture *a* to *b* by fine sutures, and the skin at any gaping spots also by fine sutures. The results

in the acquired fissures are almost perfect; but in the congenital variety are not so good, as the edges of these fissures are apt to be somewhat atrophied. Hemorrhage during the operation can be wholly avoided by enclosing the lobule in a Snellen's clamp (Fig. 522).

**Fissures of the auricle**, either congenital or the result of traumatism, may be corrected in the same manner as those of the lobule.

**Macrotia**, or abnormally large auricle, has been improved by Schwartze in the following way: An elliptical piece of the cartilage was removed from the fossa of the helix, and then a triangular piece from the helix well into the concha; the edges were then united by deep sutures.

**Projecting Auricle.**—To tie down an auricle which is protruding from the head make two concave incisions 5 cm. long behind the ear, one on the mastoid 1 cm. backward, and one on the auricle 1 cm. forward, with the concavities facing each other, the cuts uniting above and below at acute angles. Dissect off this skin, loosen the remaining skin at the edges for 0.5 cm., unite the edge by sutures, press firmly into position by iodoform gauze, and bandage the auricle firmly against the skull.<sup>1</sup>

Grooving or excising a segment of the cartilage in the fossa of the helix is needful in some cases, as in the previous operation.

**Defects of the auricle** can rarely be benefited, because the defect is usually too great to be improved by plastic surgery. In exceptional cases, however, a fairly well-formed auricle is simply adherent to the skull and can be dissected off; a flap of skin can then be inserted behind and a considerable gain in appearance thus obtained.

**Congenital fistula**, a remnant of the fetal first branchial cleft, only requires surgical interference when the secretion is so abundant as to be a serious inconvenience, when there is retention and the formation of a large cyst, or when the fistula becomes infected and suppurates. In such cases the only effectual course is to dissect out the entire epithelial lining of the tract, which usually extends quite deeply, one-half inch or more. In two cases which I operated upon the removal of the deepest portion of the fistula exposed the capsular ligament of the temporo-maxillary articulation.

**Wounds of the auricle** usually heal wonderfully well, even if deep in the cartilage. Wounds at the orifice of the meatus, if granulating, are liable to cause stenosis or atresia, which must be guarded against by packing, cauterization, removal of granulations, or by grafting of skin.

**Fibroma of the lobule**, ear-ring tumor or keloid, requires complete removal by taking out a triangular piece of the lobule; any portion of the new growth left will cause a recurrence of the tumor. Pass a narrow-bladed knife through the lobule in healthy tissue above the middle of the tumor and incise through the base of the lobule in healthy tissue; do the same on the opposite side and bring the parts together by deep sutures. The operation is practically the same as that for coloboma, except in the care necessary to excise all of the growth; and if it is possible to get a narrow flap of healthy skin and insert it on the edge of the lobule, as described above for coloboma, the disfiguring notch in the contour of the lobule will be avoided.

**Atheromatous, dermoid, and serous cysts** require the removal of the entire cyst-wall by dissection.

**Angioma.**—The treatment must vary according to the size of the growth: if small it can be dissected off and the skin sutured over the wound, or it may be destroyed by the thermocautery or by electropuncture. Large growths involving the whole thickness of the auricle may require am-

<sup>1</sup> Gruber: *Monatsschrift für Ohrenheilkunde*, Feb., 1896.



putation of the portion of auricle involved. Occasionally the whole auricle is involved in a mass of large tortuous blood-vessels which communicate freely with enlarged and irregular arteries arising from the carotid. In these amputation by slow dissection, ligating the vessels as they are cut, is our only resource; and ligation of the common carotid artery must precede the amputation. After removal of the auricle the deeper tortuous veins can be dissected out. Then, as in every wound involving the orifice of the meatus, an attempt should be made to turn a flap of skin into the meatus to prevent atresia from granulation-tissue.

**Epithelial Carcinoma.**—Our only resource is early extirpation by excision; if small, excise the growth with the whole thickness of the cartilage; if large, amputation of the entire auricle is necessary, and, if the tissues within the orifice of the meatus are involved, the entire cartilaginous meatus should be removed with the auricle. Any infiltrated glands should be dissected out. If the orifice of the meatus is involved, a plastic operation should supply a surface of skin, at least on one side, to prevent atresia.

Some cases do well, and I have followed such for several years without there being any recurrence; in other cases there is a rapid return, either in the cicatrix or in the meatus, which is usually fatal in a few months from involvement of the deeper ear and brain or of the parotid region. A recurrent growth, small and isolated, justifies a second operation; but a rapid recurrence in the form of a diffuse infiltration, usually in front of the tragus, is, in my opinion, beyond surgical relief.

#### OPERATIONS ON THE MEATUS.

**Congenital atresia** is usually associated with malformation of the auricle, and in most cases also with malformation of the middle and inner ears from imperfect development. This internal malformation renders surgical interference inadvisable except in the rare, simplest forms where the closure is merely by a thin layer of skin and where an exploratory puncture shows there is no fibrous or osseous closure further in. The skin can then be excised by a circular incision as near the periphery as possible, or quartered by two cross-cuts and the triangular flaps excised with curved seissors. By either method great difficulty is experienced in maintaining the opening, which can only be done by keeping a tube, metallic or rubber, in the passage until the skin has united over the wound, or else by a plastic operation inserting skin from the concha or tragus. Secondary contraction may occur unless combated long after apparent healing.

**Acquired atresia** is the result of granulation-tissue within the meatus, which, uniting across the passage, has fused into a connected mass, undergone fibrous organization, and been covered with epidermis. A successful operation here depends very much on the same conditions spoken of under congenital atresia, except that there is no question of malformation of the middle and inner ears. In many of these cases the occluding membrane is thin,  $\frac{1}{32}$  to  $\frac{1}{16}$  of an inch in thickness; but occasionally the entire meatus is converted into a dense fibrous tissue. If the membrane is thin, the same operation described for congenital atresia holds good; but where a considerable portion of the meatus is occluded by fibrous tissue, I do not believe any operation will succeed in making a permanent opening.

**Carcinoma** of the meatus is usually of the epithelial variety and an extension of the same disease from the auricle. If it involves only the cartilaginous meatus it can be removed together with the auricle (see Carcinoma

of the auricle); if it involves the osseous meatus, however, an operation is, in my opinion, unjustifiable, as it cannot be successful and is liable to set up increased activity in the morbid growth. Varieties of carcinoma of the meatus other than epithelial are extensions of the disease from neighboring parts, usually from the parotid gland.

**Granulations**, inflammatory growths of granulation-tissue, are usually an expression of some other trouble—deep-seated inflammation and often caries; but their removal is demanded to give exit to pus or to get at the deeper disease. If pedunculated they can be cut off with a No. 30 or 33 copper wire in a Wilde's snare, or removed by evulsion with forceps or curetted away. Cocain in 10 per cent. solution is useful both for local anesthesia and to diminish the bleeding. After the removal the underlying disease requires its appropriate treatment; and until this is cured the possibility of recurrence is not excluded.

**Exostoses.**—Their removal is demanded only when they close the meatus, thus producing serious impairment of hearing, or when there is suppuration of the deeper structures and the growth prevents the evacuation of pus.

If distinctly pedunculated, it may be possible to separate them by placing a small osteotome against the pedicle and fracturing this by a sharp blow from a mallet, then removing the growth with forceps. If not pedunculated, the growth can be best reached by deflecting the auricle and cartilaginous meatus forward. This is done by beginning at the extreme upper anterior edge of the auricle and carrying an incision  $\frac{1}{2}$  cm. from the auricle behind, around, and down to the lower wall of the meatus through the skin; then dissecting off the auricle without the periosteum until the meatus is reached, when the periosteum is incised close to the meatus above and behind and separated together with the cartilaginous meatus from the bone until the exostosis is reached. This can then be thoroughly exposed by drawing the separated auricle and meatus forward with a long flat hook. The growth can now be removed by chisels and mallet or by burrs on a surgical engine. Strict asepsis is, of course, necessary. After removal the periosteum should be carefully replaced together with the cartilaginous meatus, the auricle stitched into position, a light packing of dry iodoform gauze placed in the meatus to retain the periosteum firmly against the bone, and an aseptic dressing applied over the whole ear and mastoid. The frequency of dressings must depend upon the condition of the ear: with suppuration, daily dressings are necessary.

**Hyperostosis**, a general hyperplasia of the bone, is particularly liable to occur with chronic suppurations of the tympanum; and if the hyperostosis closes the meatus an operation may be a vital indication to prevent retention of pus.

In such cases two methods are applicable. One is to drill through the growth in the meatus with a surgical engine and enlarge the opening by burrs. This has been done with success: but the opening thus obtained is a small one which, becoming covered with granulations, is kept open with difficulty; and, as the hyperplastic process in the bone will probably continue, a renewed closure is likely to occur even when the seat of operation has healed well.

The other method is to do a full tympano-mastoid exenteration (see page 796), removing all the hyperostosis on the posterior wall. This has the advantage of making a large meatus, of enabling one to treat the underlying tympanic disease, if there is one, as is usually the case, and is much more likely to put a stop to further hyperplasia of the bone.

**Exostosis Cartilagineæ.**—Still a third form of osseous growth is occasionally found in the meatus, apparently congenital and probably developed from a remnant of fetal cartilage. To the American Otological Society in July, 1893 and 1894, I reported four cases of osseous growth, three on the mastoid wall of the meatus and one apparently arising from the tympanum; they differed from ordinary exostoses in being covered with cartilage and in lying free or but slightly attached to the cavities of the surrounding bone. They were removed by exposing them by displacement of the auricle forward and then extracting them with forceps, without any cutting of the bone. A full description and discussion of them can be found in the *Transactions*, 1893 and 1894.

**Foreign bodies** can, in most cases, be removed by syringing, and this should be tried in all cases; instrumental interference is unjustifiable except when syringing fails, either from the body being firmly impacted or becoming impacted by swelling from moisture. In these exceptional cases the ingenuity of the surgeon is sometimes taxed to the utmost to adapt his instrument to the peculiarities of the foreign body and its position in the meatus. *In children and nervous adults a general anæsthetic is often required*, especially if the meatus is irritated from previous injurious manipulations.

Angular toothed forceps are adapted to bits of wood, grass, or similar objects. The wire loop of a snare can sometimes be passed around a pebble, and it can thus be gradually rolled out. A small sharp hook is very useful for peas and beans; a blunt hook for beads.

These are perhaps the most common instruments; but in a difficult case the surgeon's armamentarium can scarcely be too large. Occasionally a foreign body is so firmly impacted in the deeper meatus or tympanum that it cannot be displaced by any instrument through the meatus, either through lack of space to exert sufficient force, or through the body's having been forced beyond the narrowest part of the meatus and then having swollen, or through its having been impacted within the tympanum. In such cases the auricle and cartilaginous meatus should be displaced, as already described under exostoses; free access is thus gained to both osseous meatus and tympanum, and instruments adapted to the body can now be used with success. By this method I have successfully removed impacted glass, a tooth, and several flattened bullets from the tympanum, and swollen vegetable substances from the deeper canal, which it was physically impossible to have got out through the cartilaginous meatus.

#### OPERATIONS ON THE TYMPANUM.

**Paracentesis.**—Good illumination by means of a reflector and speculum is necessary. Asepsis in regard to meatus, auricle, hands, and instruments should be practised. The pain of the operation is very variable; if the drum membrane is bulging extremely from the pressure of secretion, its sensitiveness is often so reduced that but little pain is felt; if, on the contrary, it is very much thickened by infiltration, the pain is often severe. The natural sensitiveness varies also in different parts, being least in the lower half of the membrane and greatest in the posterior superior quadrant just behind the short process. The operation is so rapidly performed that narcosis is often unnecessary; but with children, with the timid, or where the drum membrane is much infiltrated, primary etherization is desirable.

The object to be attained is a cut through the drum membrane, in length from one-quarter to one-half of its diameter, and made in such a direction that



both the radial and circular fibers of the membrana propria shall be incised, thereby insuring a slightly gaping wound from the contraction of both sets of fibers, facilitating drainage. The chief difficulties of the operation are (1) the judging of the distance, as only monocular vision can be used, and (2) getting the incision long enough, allowance not being made for the inclination of the membrane. The first can be overcome by keeping the point of the knife in slight motion as it is passed down the meatus, when, as the point touches the membrane, its motion is arrested and the puncture is immediately made by a slight thrust. The second is obviated by continuing to pass the knife slightly inward as the cut is made downward. Before withdrawing the knife the edges of the wound should be pressed apart to prevent their adhering with the slight bleeding which ensues.

Although various instruments with and without guards have been proposed, nothing in my opinion is so simple and good as the original paracentesis-needle of Schwartze, a small lance-shaped knife, the shank of which is 5 cm. long, bent at an angle of 50 degrees and inserted in a handle 10 cm. long. For enlarging an existing perforation or an insufficient puncture the blunt-pointed, slightly curved dilatation-knife of Schwartze cannot be improved.

The point of election for the operation will depend upon the object sought to be accomplished. The most common object is evacuation of secretion, and for this, if the drum membrane is greatly bulging, the cut should be made through the most prominent projection; if, however, there is no very conspicuous bulging it should be through the posterior lower quadrant, beginning a little above the umbo, midway between that and the periphery, and continued slightly obliquely downward to the lower periphery; this secures the most thorough evacuation and drainage. In paracentesis of the upper posterior quadrant, which is never advisable except with a bulging at that point, the risk of injuring the ossicles, especially the articulation of the incus and stapes, requires that the operation be done with great caution against too deep a thrust into the tympanum. A paracentesis of the anterior half of the membrane is never advisable except where there is a distinct bladder-like protrusion of the membrane at that situation, which is extremely rare; an opening at this point evacuates very insufficiently the secretion collecting posterior to the opening. When the drum membrane is much infiltrated it may be advisable in exceptional cases to make a cross-cut, thus giving a triangular flap, which, being pressed back, will keep the opening patent for a longer time.

The tympanum having been thus opened, if the secretion is thin and under any degree of pressure, it will evacuate itself freely; and if the Eustachian tube be open, slight inflation by Valsalva's method will complete the evacuation, and the air will pass out without râles, with the characteristic perforation-whistle. If the secretion is thick and adhesive or if the Eustachian tube is closed, it may be necessary to use the catheter, through which injections of warm sodium-chlorid solution ( $\frac{1}{4}$  of 1 per cent.), boric-acid solution (5 per cent.), or some other mild and warm antiseptic solution may be used. My own practice varies with the case. In otitis media acuta with a thin bloody serum I content myself with following the paracentesis by simple drainage by means of a wick of corrosive-sublimate cotton, without inflation of any kind; with a simple acute effusion without congestion and with marked retraction of the drum membrane due to closure of the Eustachian tube (hydrops. ex vacuo), I use moderate inflation—most commonly by the catheter, because the force of the inflation with this is so completely under the control of the surgeon—although with children or timid persons Politzer's inflation may be necessary. In chronic catarrhal cases where the secretion is thick, often jelly-like and adhesive, injections by the catheter are frequently necessary to soften and wash out the masses, and aspiration from the meatus by means of Siegle's speculum will sometimes assist the evacuation; but care should be used to avoid any



extreme congestion from the suction. In acute suppurations I avoid inflations at first; and if the secretion is too abundant and thick to be absorbed by a short wick, use hot syringing, especially if there is much pain.

Although paracentesis is most frequently used for evacuation of serum, mucus, and pus from the tympanum (and in all of these conditions is indispensable, and in the case of the last often life-saving), it is also occasionally useful for enabling us to get into the tympanum for the purpose of (1) dividing *synechie*, (2) removing intratympanic polypi, (3) relieving anomalies in tension of the drum membrane.

To get at *synechie* a short incision should be made as near their attachment as possible and the adhesions divided by passing a curved or right-angled knife through the opening. For *intratympanic polypi* a large opening, often with an extended cross-cut, is necessary—its situation dependent on the seat of the polypus. *Anomalies in tension* may be either increased or diminished tension. For the former, incision of the posterior fold as proposed by Lucae requires that the fold should be pierced close to the periphery directly behind the short process and the cut continued downward through the whole fold; although injury of the *chorda tympani* may result, it is of absolutely no importance. For diminished tension numerous small incisions in the most relaxed portion of the membrane have been advised with the object of increasing the tension by the resulting cicatrices. Neither of these operations for tension have, however, received general approval, as they but imperfectly relieve a single one of several pathological conditions which produce the deafness.

**Tenotomy of the tensor tympani muscle** for the relief of deafness and subjective noises produced by sclerosis or adhesive processes in the tympanum is of slight, if any, value. In my own hands it proved so worthless that I gave it up years ago. It can only relieve the retracted condition of the drum membrane; while we now know that the important pathological changes are on the inner wall, especially about the base of the stapes, and that these cannot be influenced by the operation. Almost the same thing can be said of *tenotomy of the stapedius* muscle; in a few exceptional cases I have seen a certain degree of relief to subjective noises and vertigo by this operation, where the stapedius was greatly thickened by cicatricial tissue resulting from previous suppurations and where the condition could be diagnosed by direct inspection through a large perforation of the drum membrane.

Tenotomy of the tensor is performed best in the posterior superior quadrant by incising the membrane parallel with the manubrium, just behind and a little below the short process; the tenotome is then inserted through the opening toward the tympanic roof and with its edge forward until the head of the malleus is felt; it is then rotated forward until it engages the tendon of the muscle, which can be severed with a slight sawing motion. As the tendon is cut through it is felt to yield, and the manubrium with the drum membrane will be felt and seen to move outward more freely than before. By far the best tenotome is Schwartz's.

**Tenotomy of the stapedius** can be done with any small straight knife or with a paracentesis-needle when the stapes lies low and is exposed through a large perforation.

**Excision of Parts or the Whole of the Conducting Mechanism.**—These operations should be carefully divided into—

- (1) Excisions for the relief of deafness otherwise incurable.
- (2) Excisions for existing tympanic suppurations.

Under the first head the operations are undertaken with the object of removing parts of the conducting apparatus which have become so immovable by disease that they prevent vibrations from reaching the auditory nerve. The diseases producing this immobility are (*a*) adhesive inflammations (thickenings, calcifications, adhesions), the result of previous tympanic suppurations and catarrhs; (*b*) the obscure pathological process known as sclerosis, the important characteristics of which are changes on the inner (labyrinthine) wall of the tympanum and about the niche and foot-plate of the stapes.

It is impossible here to give the full history of the various operations which have been proposed; they can be briefly summarized as follows: excision of the tympanic membrane and malleus; of the incus; of the long process of the incus; of the tympanic membrane, malleus, and incus; of the stapes; of the tympanic membrane, malleus, incus, and stapes.

The methods of operating will be considered later, as they are the same whether done for deafness or for suppurations, except that in the former, with a healthy drum membrane, the strictest asepticism is absolutely necessary.

In regard to the operations for deafness, I think it can be said that in neither the adhesive nor the sclerotic diseases have the results equalled the expectations of their originators or received general recognition by otologists. In adhesive inflammations occasionally fair and even good results are obtained (see page 738); but only in a small proportion of cases as yet, and the indications for or against the operation are not established. In sclerosis any degree of success is so rare and the failures so many that for my own part I have given up all varieties of the operation for this disease.

With our present pathological knowledge only two of the operations for deafness are worthy of consideration:

(1) Excision of the tympanic membrane, malleus, and incus, leaving the stapes in position.

(2) Excision of the tympanic membrane, malleus, incus, and stapes. Which to adopt must depend upon the condition of the individual case. If the rigidity exists in the malleus and incus and, after their removal, the stapes is found by the probe to be freely movable, it should be left in position; if, however, it is immovably fixed and not to be released by the separation of adhesions of the crura to the niche, the only hope of success is in removal of this bone also.

For **tympanic suppurations**, removal of parts of the conducting mechanism is merely fulfilling the well-recognized surgical laws of removing obstructions to the thorough evacuation of pus so as to get surgical cleanliness and remove diseased bone (microbic foci) which keeps up the infection. It is especially indicated where the suppuration is in the epitympanum or attic; for the head of the malleus, the incus and stapes, the tensor tympani and stapedius muscles, the ossicular ligaments and many folds of mucous membrane are crowded into or below this narrow space; and a suppuration of the mucous membrane, which covers all of these structures, with its resulting swelling, often so interferes with free drainage that recovery is absolutely impossible without an evisceration of the cavity. In addition to this, the retention of pus is very apt to produce caries of the ossicles or of the petrous bone, which keeps up the suppuration. For both pus-retention and ossicular caries the operation is indicated and successful in a large proportion of cases. In performing it the whole of the existing drum membrane, together with the malleus and incus, should be removed; for any of these being removed the others become useless and merely act as obstructions

to cleanliness; while in cases of the ossicles, pathological statistics show that both ossicles are usually diseased, but the incus more extensively than the malleus.

The different steps of the *operation* are as follows: (1) Separation of the drumhead by incision around its periphery as near the tympanic ring as possible.

(2) Tenotomy of the tensor tympani muscle by passing a Schwartz's tenotome over the tendon and dividing it, as already described on page 788. After severing the tendon the knife should be passed downward along the inner edge of the manubrium in order to separate any adhesions which are tying that bone down.

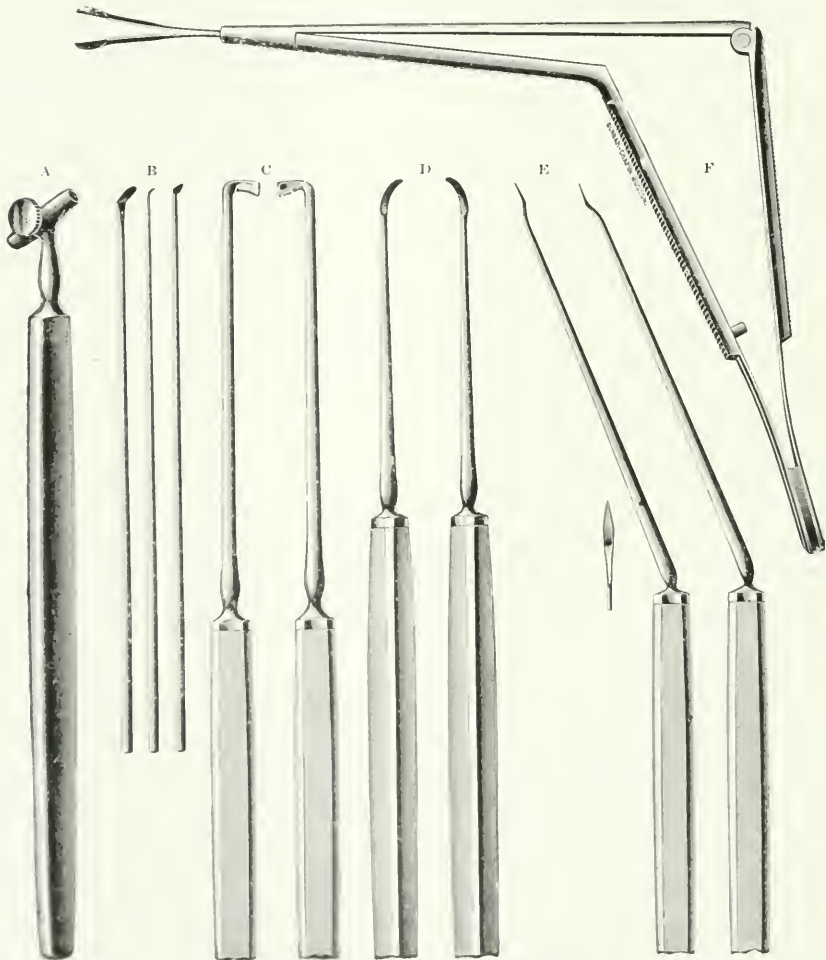


FIG. 523.—Instruments for intratympanic operations; A, adjustable handle; B, angled knives; C, Ludwig's incus-hooks; D, dilatation-knives; E, synecchia-knives; F, Sexton's forceps.

(3) Disarticulation of the incudo-stapedial joint by incising it by short cuts with a small sharp-pointed knife set at nearly a right angle with its shank—the incisions being made in the plane of the joint, perpendicular to the axis of the stapes. If the stapes is situated low in the tympanum, the joint can



be seen; if high, the disarticulation must be done by feeling. A free movement of the long process of the incus proves the success of the disarticulation.

(4) Removal of the hammer by seizing it in strong forceps at or near the short process, carrying it slightly inward to bring the neck out from its insertion in the Rivinian notch, and then bringing the bone downward into the meatus and withdrawing it together with the drum membrane. Occasionally the incus comes away with the hammer, but usually it remains; if its long process is visible, it can be seized with forceps and withdrawn; if it is not seen, it must be brought down into view by an incus-hook, as described below (Fig. 523) in regard to carious ossicles, and then withdrawn.

(5) Separation of adhesions about the crura of the stapes, if any, can be accomplished by any small sharp-pointed knife or by a paracentesis-needle.

(6) Removal of the stapes, if that be desirable, is accomplished by inserting a small, blunt steel hook between the crura and drawing the bone out gently. Unless the foot-plate is ankylosed this can be done readily; but with ankylosis the crura fracture and removal of the foot-plate is then impossible.

The whole operation can be done under cocain with scarcely any pain if the patient is steady; but each successive portion of tissue requires to be cocainized by a pledget of cotton on an applicator. In an intact drum membrane the first puncture must necessarily cause pain, but from that puncture the saturated cotton-point inserted in the opening will thoroughly anesthetize about one-eighth of an inch of tissue; the cut can then be continued that distance and then another application of cocain made. Solutions of 5 per cent. are sufficiently strong. Absolute immobility of the head is required, and in a nervous patient general anesthesia is necessary.

In the operation for suppuration certain modifications may be necessary. In these suppurative cases there is often much granulation-tissue which bleeds freely, masses of inspissated pus and cholesteatomatous material, and the ossicles are often reduced to mere fragments, with calcifications fixing them so that considerable force is required for their removal. The most common spot for caries in the ossicles is the long process of the incus, which in 60 cases of my own had produced a natural disarticulation in 75 per cent., thus doing away with the operative disarticulation. With mere fragments of ossicles adherent by calcification, the Ludwig's incus-hooks are often necessary; and in removal of the incus, which is often reduced to a portion of the body only, these instruments I consider indispensable and prefer them to anything I have yet seen (Fig. 523). The malleus and tympanic membrane having been removed, the incus-hook should be passed into the anterior superior portion of the epitympanum, with its concave surface backward; it should then be swept backward so as to engage the body of the incus and bring it down into the meatus, whence it can be withdrawn by forceps. With a broad and deep attic several sweeps of the hook may be necessary in different portions of the cavity before the incus is dislodged, and in sweeping along the medial (labyrinthine) wall the position of the Fallopian canal should be borne in mind and but slight force used at this point; any twitching of the facial nerve is a signal of danger. Occasionally the incus is not brought into view by the backward sweep, but can be found by reversing the process and sweeping from behind forward. After removing the incus, the cavity should be thoroughly cleansed of cholesteatomatous masses, inspissated pus, and granulations by the Ludwig hooks, by snare and forceps. Bleeding can be greatly reduced by the use of cocain, and before beginning the operation I always inject the cavity with a 5 per cent. solution. In the



operation for suppuration I have generally found etherization necessary, as the tissues are inflamed. The after-treatment consists of cleansing with the tympanic syringe and the use of antiseptics applied directly to the tympanum: a saturated solution of boric acid in absolute alcohol for granulations, simple boric-acid powder for a slight serous discharge, and a solution of carbolic acid in glycerin (1:25) for simple suppuration.

**Polypi and granulations** should be carefully distinguished from sarcomata or epitheliomata. Their removal is required because they keep up the inflammation of the parts to which they are attached, and because, if large, they cause retention of pus. Whatever their attachment, whether on meatus, tympanic membrane, ossicles, or tympanum, they must be got rid of before the inflammation can subside. They are almost without exception inflammatory granulation-tissue, soft or firm according to the amount of fibrous tissue which they contain; occasionally they contain cysts and exceptionally assume a teleangiectatic character from excessive development of blood-vessels. They usually are pedunculated, but occasionally are broad-based; and they vary in size from a pin's head to one inch or more long. They are the result of inflammation of the underlying tissue, often of a simple suppuration, often of a caries of the bone.

The choice of methods for removing them must depend upon their size, shape, character, and attachment. Small soft granulations can be destroyed by caustics, preferably argentic nitrate fused on a probe, or shrivelled by alcohol; but in most cases immediate removal is the quickest, surest, and least painful method. This can be accomplished with snares, forceps, or curettes.

Small pedunculated granulations can be seized and removed by evulsion with appropriate forceps if their situation admits of it; small broad-based ones, if soft, can be crushed by the same means; if firm and their attachment admits of it, they can be removed with a small curette. In either variety where evulsion is undesirable, as in attachment to the ossicles or drum membrane, a delicate snare will cut them off. Pedunculated granulations in the *epitympanum* or *aditus* can often be swept down and removed with the Ludwig incus-hook.

Large polypi attached to the walls of the meatus can also be removed with forceps by evulsion, but only exceptionally can their attachment be made out with such certainty as to justify this method; in almost all of these cases the snare is the only appropriate instrument.

The snare can be used either as an evulsor or as an *éraseur*, according to whether the wire is drawn against a cross-bar at the end of the instrument or completely into the tube in the absence of a cross-bar. The canula of the snare should be small and delicate for small granulations attached to delicate parts; much larger and heavier for large, especially for fibrous polypi. The size and quality of the wire should be adapted to the work also; for small growths on the tympanic membrane or ossicles I prefer a soft, malleable copper wire, even as small as No. 36; for large growths copper wire, No. 28 or 30; occasionally for large fibrous growths steel piano-wire, No. 2, is necessary. The malleable copper wire seems to adapt itself to the base of the growth better than a stiffer material, and I prefer it in almost all cases. The loop of wire, being made a little larger than the growth, is passed around it, bearing in mind the anatomical peculiarities at its attachment; the loop is then tightened or drawn into the tube and the tumor removed. Evulsion is to be preferred as more thorough where it is not liable to tear away important parts; where it is liable to do this the *éraseur* action is to be used. With

large polypi it is often difficult to pass the loop completely down to the base. As much as possible is removed at the first insertion and the remainder by subsequent insertions. Except with very nervous persons general anesthesia is unnecessary, thorough cocainizing with a 10 per cent. solution being sufficient.

The subsequent treatment consists in destroying all remnants of the growth and getting the seat of it healed. If caries exists, the only course is to get rid of the process, for without this the growth is certain to recur, and the object of removing the polypus is to enable us to get at the caries. Without caries the remnants should be disposed of by cauterization or by shrivelling; for the former I confine myself almost entirely to argentic nitrate fused on a probe, applied superficially in case of a small remnant of a soft growth, or bored directly into the growth if the remnant is large and firm. For shrivelling, alcohol (95 per cent.) and glycerite of carbolic acid (1:25) are very useful, applied either by instillation, by injection through a tympanic syringe, or by painting.

**Mastoid operations** are required for two pathological conditions: (1) pus in the pneumatic cavities of the mastoid, the retained products of suppuration of the mucous membrane lining the cells (empyema); (2) different varieties of otitis, including suppuration of the diploë, inflammation of the cortical substance, caries, and necrosis. They are of two kinds: (*a*) opening of the mastoid antrum (Schwartz's operation); (*b*) cleaning out the whole interior of both mastoid and tympanum, a tympano-mastoid exenteration (Schwartz-Stacke or Schwartz-Zaufal operation).

The **antrum operation** consists in opening the antrum through the external mastoid cortex, and in so doing exposing the whole interior of the mastoid so as to remove all diseased tissue, whether osseous or soft. The antrum is the objective point to be reached, for it is the only constant cavity within the mastoid; the rest of the bone may be, instead of pneumatic, as usually described, diploëic or sclerosed. There is no method of determining beforehand the condition of the interior of the bone; a large prominent mastoid is more likely to be pneumatic than a small, depressed, ill-developed one; the bone in a dolichocephalic skull is more likely to be well developed and pneumatic than in a brachycephalic skull. It is equally impossible to foretell whether we shall find empyema, otitis, or osteomyelitis; the opening of the bone finally settles the question. Osteosclerosis can be excluded in acute mastoiditis resulting from acute tympanic suppurations, unless the mastoid has been inflamed from some previous disease; it is unlikely in a mastoiditis which has shown symptoms of extension outward as subperiosteal abscess or extension downward into the neck; it can be strongly suspected in chronic, long-continued tympanic suppurations.

Certain irregularities of formation may be found in any mastoid, apparently regardless of its perfect or imperfect development.

(1) The roof of the antrum, which forms the floor of the middle fossa of the skull, may vary as much as 2 cm. up or down; the linea temporalis marks the line of this roof fairly well externally, and measurements on large numbers of skulls show that the floor of the middle fossa is never 1 cm. below the linea temporalis. A safe rule, then, to avoid opening the middle fossa is to keep 1 cm. below the linea temporalis, but as this linea is sometimes imperfectly developed, another rule is to make the upper edge of our opening 3 mm. below an imaginary line drawn horizontally backward from the upper edge of the meatus, which is well marked by the *spina supra-meatum*.

(2) The outward curving of the sigmoid groove which carries the lateral sinus varies very much; it may project even to the external cortex, and such a possibility must always be borne in mind, and possible wounding of the lateral sinus guarded against by the use of chisel and mallet worked slowly and carefully, and by the omission of all boring instruments, like trephine or drill.

(3) The extent of cancellated structure varies; it sometimes extends far backward and far inward; and as in osteomyelitis especially, the removal of nearly all cancellated structure is desirable, the possibility of this peculiarity should not be forgotten.

The floor of the antrum, roughly stated, is on a level with the upper wall of the meatus, and the cavity itself is from  $\frac{1}{4}$  to  $\frac{1}{2}$  inch back of the superior posterior edge of the tympanic ring.

**Method of Opening the Antrum.**—Expose the mastoid by an incision through the periosteum 1 cm. behind the attachment of the auricle, beginning 1 cm. above the linea temporalis and extending the cut down nearly to the tip of the process. Separate the periosteum forward so as to expose the *suprameatal spine*, and backward so as to expose the surface of the mastoid. From the spine draw an imaginary horizontal line backward (Fig. 524), and

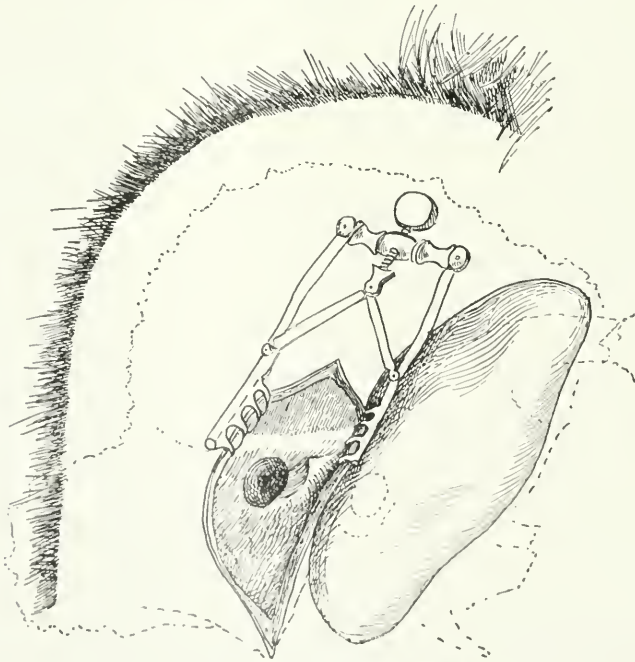


Fig. 524.—Operation for opening the antrum: external wound stretched by Allport's retractor, and bone opened behind suprameatal spine.

begin the upper edge of the opening 3 mm. below this line and about 1 cm. back from the posterior edge of the meatus, removing the cortex by thin chips with a gouge and mallet. The seat of election is usually marked by a flat and slightly depressed surface. The cortex of the bone varies in thickness from a thin shell to 1 cm.; remove it by thin chips over a surface 7 to 10 mm. in diameter, taking care to work parallel with the meatus, or, if anything, a little more forward and upward. As soon as the cortex is cut through,



examine with a probe ; there may be *large pneumatic cavities*, in which case feel for landmarks, upward for the roof of the mastoid to define the floor of the middle fossa, backward and inward to define the posterior fossa. Now break down all the partition-walls between the cells with a curette till the antrum is reached at a depth of not over 15 mm. ( $\frac{1}{2}$  inch) from the outer anterior edge of the surface opening ; clear out the involved interior of the mastoid with curettes, removing the walls of the cells, granulations, pus, and detritus, douche gently with corrosive sublimate (1:5000), pack with iodoform gauze, and bandage.

In other cases on opening the cortex the interior is found to be *partly or wholly diploëtic* ; more careful work is then necessary, and the diploë should be removed straight inward, parallel with the meatus, to the depth of 6 to 9 mm. ( $\frac{1}{4}$  to  $\frac{3}{8}$  inch), and then it is necessary to work slightly forward, inward, and upward to reach the antrum ; but never go beyond 15 mm. ( $\frac{1}{2}$  inch) from the external surface at the seat of election for fear of wounding the facial nerve or posterior semicircular canal. Having opened the antrum, the whole diploë of the mastoid should be removed with curettes, then cleanse, pack, and dress.

In still other cases no pneumatic or diploëtic structure is found ; the deeper the opening is carried the harder the bone becomes—*osteosclerosis*. These are by far the most difficult operations ; one gets no guide from the probe as in the other varieties of bone, and the greatest care is necessary to keep the proper direction of the opening. The bone should be removed in small chips, the opening carried straight in, parallel to the meatus, to the depth of 5 to 8 mm. ( $\frac{1}{5}$  to  $\frac{3}{8}$  inch), and then continued upward and slightly forward not deeper than 15 mm. ( $\frac{1}{2}$  inch) from the external surface. Often after going through sclerosed bone for 7 to 14 mm. ( $\frac{1}{4}$  to  $\frac{1}{2}$  inch) diploë is met ; this should be removed by curettes as thoroughly as possible ; then cleanse and pack.

It is the exception to find the pathological condition as clearly defined as is here given ; *caries* is very apt to complicate ; and if during the operation carious bone is found, it should be thoroughly removed, care being taken to avoid wounding the dura mater, the facial nerve, and the labyrinth. Not infrequently the roof of the mastoid next the cerebrum is carious, also the inner posterior wall next the lateral sinus and cerebellum ; these carious spots should be removed by a curette, the dura being pushed back from the bone. Narrow gauze strips can be carried into any crevice to stay the bleeding, and cleanse for thorough inspection. At any stage of any operation the removal of a small chip of bone may expose a gray shining membrane, which is a signal of danger ; it may be cholesteatoma, pyogenic membrane, or dura, and must be examined carefully before proceeding. Extensive caries may require enlargement of the whole original opening.

The only cases which are exceptions to the above general rules of operating are those in which there has been *extension* of the internal suppuration *through a carious fistula of the cortex*—outward through the external cortex, forward through the anterior cortex, or downward into the neck through the mastoid floor. With *extension outward*, incise the periosteum as in the regular operation, expose the fistula and follow this in, clearing away all softened bone, and within the mastoid be guided by the existing conditions as described above. With *extension forward*, after the first incision expose the posterior wall of the osseous meatus by pushing the periosteum forward, and the fistula can be seen and followed. With *extension downward*, fistulæ are to be looked for in the base of the mastoid ; this can be done by deflecting the periosteum



from the posterior aspect of the mastoid tip and then passing a bent probe or director beneath the periosteum along the digastric fossa which constitutes the base of the mastoid. Having thus found the fistula, remove the outer surface of the tip, exposing the interior of the bone together with the fistula, and cleanse as in the other varieties.

These fistulae are always to be suspected and carefully looked for when the external tissues are edematous and swollen; they are almost certain to exist whenever any pus is found between the periosteum and the bone; with extension outward the edema begins on the external surface; with extension forward, on the posterior wall of the meatus; with extension downward, beneath the mastoid in the neck, early assuming the characteristics of a cellulitis, which may form an abscess anywhere in the neck beneath the deep fascia and burrow extensively, even into the pleura. Next to the extensions to the brain these inflammations in the neck are the most serious complications of mastoiditis, sometimes requiring deep dissections of the neck, even to the vertebræ, in order to evacuate the pus.

With extensions toward the brain upward, inward, and backward, the tympano-mastoid exenteration is usually necessary.

The **tympano-mastoid exenteration** is well described by the name; it is an evisceration of the interior of the bone by making the mastoid, antrum, tympanum, epitympanum, and meatus one large cavity with perfectly smooth and healthy walls, by removing the external cortex of the mastoid, its entire cancellated structure, the posterior osseous meatus-wall, the tympanic membrane, the malleus and incus, and the outer wall of the epitympanum. It is indicated for simple caries of the bone which cannot be reached by the ordinary antrum operation—*i. e.*, caries of the tympanum, epitympanum, aditus and extensive caries of the mastoid, and also for cholesteatoma of the mastoid and tympanum. The variations in formation of the bone, the low-lying roof, the outward curvature of the lateral sinus, the extensive cancellated structure, are of as much importance to the surgeon in this as in the antrum operation. The same may be said of the measurements given in speaking of the antrum operation. In addition, in this operation the danger of wounding the facial nerve is much increased; and the course of the Fallopian canal and its relations to the floor of the aditus and to the posterior osseous meatus should be continually in mind, as well as the relations of the external semi-circular canal.

There are two methods of getting at the antrum and aditus: one advocated by Schwartze, Zaufal, and their followers, who open from behind forward; the other advocated by Stacke, who opens from in front backward. The former extirpate the posterior superior membranous lining of the osseous meatus; the latter saves it to make a flap for covering the exposed bone.

The former operation is divided into seven steps:

- (1) Exposure of the operative field;
- (2) Extirpation of the posterior and superior lining of the osseous meatus;
- (3) Exposure of the antrum by chiselling away the mastoid and posterior osseous meatus;
- (4) Removal of the pars epitympanica;
- (5) Exenteration of the tympanum and mastoid;
- (6) Stitching and bandaging;
- (7) After-treatment.

For the first step incise over the middle of the mastoid from 2 cm. above the linea temporalis to 2 cm. below the tip, and from the upper end of this

cut make a horizontal incision forward for 3 to 4 cm. and backward also for 3 to 4 cm. From these cuts expose the entire mastoid by making a skin-periosteal flap forward to the meatus and the same backward. Secondly, separate the cartilaginous from the osseous meatus on its posterior and superior circumference, then incise the skin of the upper anterior wall of the osseous meatus from the tympanic ring outward; parallel with and opposite this make a similar incision along the posterior lower wall of the meatus; separate from the bone all of the skin included between these incisions on the upper wall from without inward and remove it with scissors, thus thoroughly exposing the upper and posterior walls of the meatus. Thirdly, enter the antrum as already described in the antrum operation, and then remove the wedge between this opening and the tympanum by chisels, or else chisel away the bone at once from the antrum surface (place of election for the antrum opening) forward into the osseous meatus, without first entering the antrum, going deeper and deeper until mastoid, antrum, aditus, tympanum, and meatus are united by a deep groove in the bone (Fig. 525). Check all bleeding, and the tympanic membrane or its remnants are now visible. Fourthly, separate any portions of

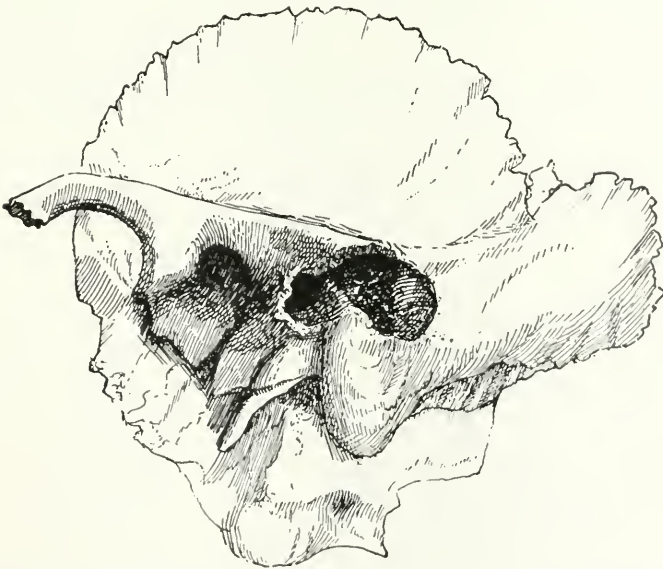

FIG. 525.—Tympano mastoid exenteration (soft parts not shown). The wall of the sigmoid sulcus is seen in the back of the mastoid opening, and the ridge of the bone protecting the facial is preserved between this and the meatus. If the mastoid is diseased, its whole external cortex should be removed to the very tip.

the drum membrane which exist at the tympanic ring and remove them together with the malleus by forceps; disarticulate the incus from the stapes and remove it by forceps (see Operation for Carious Ossicles, page 791); it is usually buried in swollen mucous membrane and granulations. Now push the mucous membrane of the epitympanum inward and remove the whole floor of that cavity by gouge and mallet and curette till the roof of the epitympanum passes without any ridge into the upper wall of the meatus (Fig. 526). Fifthly, clean out all the cavities, removing all cancellated structure, all prominences and ridges, making every part smooth, beginning with the mastoid, then respectively antrum, epitympanum, roof of tympanum and its walls. Examine every portion of the remaining walls for caries with a

right-angled probe, especially the posterior wall of the antrum and its lower inner corner next the lateral sinus; and, if anything suspicious is found, remove it, even if it exposes the dura. Wipe dry with pledgets of

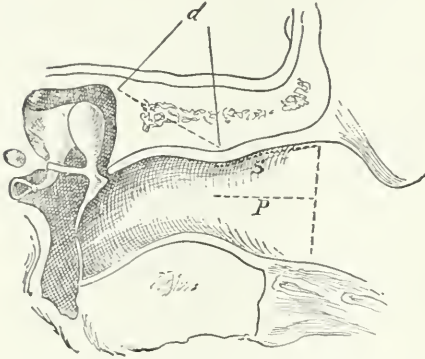


FIG 526.—Section of tympanum and canal, showing by dotted line at (d) the wedge of bone removed to open the attic.

gauze, taking care to remove all bits of bone. Finally, split the cartilaginous meatus from near the concha throughout its length along its posterior wall, thus making two triangular flaps (Fig. 526). Sixthly, suture the horizontal wounds and 2 to 3 cm. of the upper part of the perpendicular wound, laying the skin-periosteal flap carefully against the bone; suture the corners of the meatus-flaps above and below into the skin so as to stretch them up and down, and then pack the tympanum and antrum with iodoform gauze from the meatus, and similarly fill the mastoid from the wound; add an aseptic dressing and bandage.

Seventhly, the after-treatment requires the most careful personal attention of the surgeon. The healing must take place, not by the cavities filling with granulations, but by granulation of the entire surface merely, which must then become covered by a firm, dry epidermis. The two chief points are to keep the wound aseptic and to keep down redundant granulation-tissue, which can only be done by keeping the whole cavity packed firmly with iodoform or sterile gauze, every little crevice receiving attention. If granulations become prominent, they must be removed by the snare, by argentic nitrate, or by the galvano-cautery.

The details of Stacke's operation are as follows:<sup>1</sup> Make a curved incision at the insertion of the auricle or close to it from the temporal region to 1 cm. below the tip of the mastoid through the skin and subcutaneous tissue only. Dissect off the soft parts above the *linea temporalis* outside of the temporal fascia and draw them downward. From the *linea temporalis* downward extend the first cut through the periosteum and along the *linea*, make a cross-cut forward through the periosteum, thus making a triangular flap of periosteum, which is then raised by a raspatory as far as the edge of the osseous meatus; then with a narrow elevator raise the membranous meatus from the bone deeply into the osseous meatus till the whole posterior and upper osseous meatus is visible by drawing the parts forward. The whole mastoid should then be exposed by pushing its periosteum backward, if necessary making a cross-cut. If a fistula or discolored cortex exists, follow this into the antrum; then remove the posterior wall of the meatus and epitympanum.

If no fistula exists, with a small curved scalpel cut the posterior and upper membranous meatus as near the tympanic ring as possible, and draw this, together with the loosened auricle, forward by a blunt hook. After checking bleeding, the *membrana tympani* is visible; and the whole membranous meatus is retained to cover the bone.

The next stage is the exenteration of the tympanum by removing the drum membrane or its remnants, together with the malleus. Then place a gouge, bent slightly backward (Fig. 527), some millimeters above the free edge of the epitympanum and separate the bone by short light blows with a

<sup>1</sup> *Die operative Freilegung der Mittelohrräume*, Tübingen, 1897.



mallet, measuring the depth of the epitympanum with a bent probe, and continue removing the bone till the roof of the epitympanum is smooth and continuous with the upper wall of the meatus. The incus is now seen and removed.

Next pass a probe along the tegmen tympani into the *aditus* and with a small gouge, bent backward, remove the posterior superior meatus-wall into the




FIG. 527.—Stacke's gouge for removing the canal wall

*aditus* until the probe freely enters the antrum and a good orientation of every part is obtained. Instead of the probe, Stacke uses a protector, as he calls it. The external cortex and lateral portion of the posterior meatus-wall is now removed in large pieces by the chisel, the position and size of the antrum being known, and the antrum changed from a fistulous cavity into a narrow trough, which passes smoothly into the upper and lower meatus-walls without corners or sinuses. Medialwards the so-called spur between the antrum and tympanum must be smoothed, the now visible facial prominence forming the lower limit, which it is impossible to touch without endangering the facial nerve. From the height of this prominence the spur must be sloped off till it entirely disappears laterally in the lower meatus-wall. Here a minute

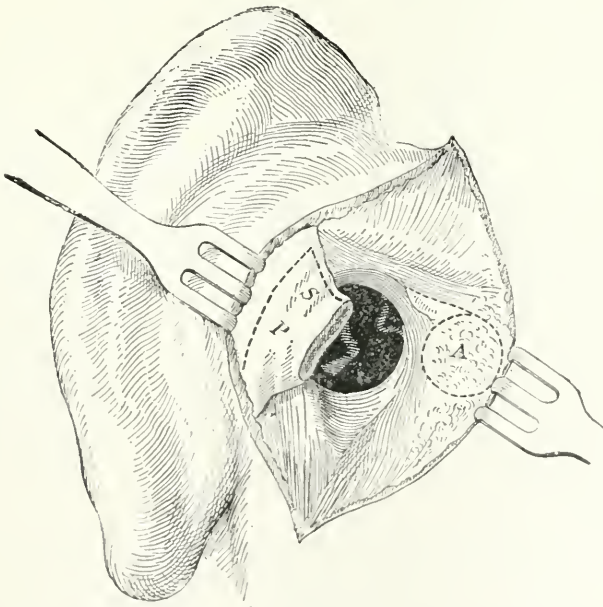


FIG. 528.—Auricle and cartilaginous canal turned forward for Stacke-Schwartz operation—the dotted lines at *A* showing the bone removed, and at *P, S*, the flaps to be transplanted into the gap (Vulpian) The writer makes but one flap without cutting at *P*, as do most operators.

artery of the bone is often encountered; and bleeding from it can be best checked by rubbing its orifice with a blunt instrument. All pathological products can now be removed under inspection, working carefully in the tympanum to avoid the stapes. The hypotympanum, as it is called by Kretschmann, only remains, and, except with curies of the tympanic floor,



it is unnecessary to remove it; the danger to the facial nerve is very great here. With cholesteatoma, after removing everything macroscopically pathological, Stacke grinds down the bone with burrs on an electromotor engine to remove any pathological masses in the Haversian canals. Lastly, if the cells of the mastoid toward the tip are involved, they should be cleaned out.

Finally, the last stage of the operation is to make a flap from the membranous meatus to cover the bone as far as possible. This is done by making a horizontal cut parallel with the axis of the meatus and along the middle of its upper wall from close to the concha to its inner end; perpendicular to this, close to the concha, make a second cut downward and backward so as to make a rectangular flap (Fig. 528). Now tampon tympanum, epitympanum, and aditus with small pieces of gauze, and then through the meatus tampon this rectangular flap to cover the bone between the meatus-wall and the floor of the antrum. The upper part of the wound is sutured into position and an aseptic dressing applied.

The final result by either method of operating is the same; the mastoid, antrum, aditus, tympanum, epitympanum, and meatus are turned into one large, continuous cavity with smooth walls which must become covered with a dry, firm epidermis. This epidermis can only grow from other epidermis which must extend inward from the external edges or be transplanted into the cavity. This transplantation can be by Thiersch grafts after the bone has become covered with small, firm granulations, and also by turning into the cavity a flap of skin taken from the outside; the latter implies a permanent opening behind the auricle. There is necessarily a large surface of exposed bone from the operation, and the more this can be covered at the time the quicker the healing and the less the risk of caries; and the more epidermis there is in the cavity the more rapidly will epidermization of the whole take place. Various methods of covering the bone and obtaining epidermis have been proposed. One is in the first exposure of the mastoid to cut down to the tip in front, then around the tip and upward at the posterior edge of the mastoid, then dissect up the skin alone and turn it upward for one flap; next dissect up the entire periosteum of the mastoid from above and turn it down for a second flap, so that after completion of the operation these flaps can be tamponed over the bone. Another is to turn in a flap of skin taken from the neck; while still another is to dissect up the skin behind the mastoid, to take from this place as large a flap of periosteum as is desirable to turn in, and then replace the skin against the bone, where it soon adheres. I have practised the first two methods with satisfaction. The last I have never used; it has the disadvantage of not supplying any of the desired epidermis.

Although the operation for cholesteatoma is the same as for caries, the surface affected by the growth requires special treatment; not only the whole investing membrane, if any, should be thoroughly curetted away, but the surface of the underlying bone should be as thoroughly curetted as its position admits to remove any growth in the Haversian canals. Zaufal advocates cauterizing it with a Paquelin cautery; Stacke uses an electromotor engine instead of the curette.

The after-treatment of the cavity is tedious, lasting from three to six months; the tamponing must be kept up till epidermization has covered the greater part of the cavity; it cannot be omitted till at least one of any two opposing surfaces are skin-covered. When, however, epidermization is well advanced, the omission of the tampons and exposure to the air will hasten

the cure. Aristol and dermatol in powder are important aids to epidermization and to protect the young epidermis from maceration.

The tympano-mastoid exenteration, whatever method of performing it experience may finally determine to be best, seems to me destined to take an important position not only in the surgery of chronic otorrheas, but also in the surgery of the otitic brain-diseases.

The **otitic brain-diseases** are :

- (1) Pachymeningitis externa purulenta, with extradural abscess ;
- (2) Leptomeningitis purulenta, or arachnitis ;
- (3) Phlebitis and thrombosis of the sinuses and of the jugular ;
- (4) Abscess of the brain, or encephalitis.

The brain-disease is due to infection of the brain from the infected ear, the infectious material reaching the brain through disease of the bone next the dura, through the natural communications which lead from the ear to the inside of the cranium, or through some of the tissue-connections, blood-vessels, or connective-tissue fibrils, which pass into and through the bone from both tympanum and dura. If the extension takes place through the roof of the temporal, the brain-disease is in the cerebrum ; if through the inner wall, the brain-disease is in the cerebellum.

The following table of otitic diseases from Körner<sup>1</sup> has a most important bearing on the surgery of these diseases :

|                         | Total. | Bone diseased to dura. | Bone diseased, but not to dura. | Bone healthy.       |
|-------------------------|--------|------------------------|---------------------------------|---------------------|
| Sinus diseases . . . .  | 39     | 32 = 82 per cent.      | 3 = 7.7 per cent.               | 4 = 10 per cent.    |
| Brain-abscesses . . . . | 40     | 37 = 92 "              | 1 = 2.5 "                       | 2 = 5 "             |
| Meningitides . . . .    | 30     | 17 = 57 "              | 4 = 13.3 "                      | 9 = 30 "            |
|                         | 109    | 86 = 79 per cent.      | 8 = 7.3 per cent.               | 15 = 13.7 per cent. |

The tympano-mastoid exenteration, with modification for circumstances, in many cases is the best operation for these intracranial diseases ; for as the ear is the original pus-focus, still active and still infecting, it should be the first point to attack. This is the only operation which exposes at once the entire roof of the antrum, aditus, and tympanum, and also the inner wall of the mastoid, thus allowing a thorough exploration of most of the spots whence transmission of infection to the brain occurs. It also allows the most perfect drainage by evacuating the pus at its most dependent position. In many cases, moreover, while we may feel confident of the existence of intracranial disease, we are unable to define its nature exactly ; in other cases, while reasonably certain of our diagnosis of the brain-trouble, we cannot be sure of its exact location ; again, in a very considerable proportion of cases the surgeon first sees the patient when the brain-disease is so active that time is more important than an accurate diagnosis. In all of these classes of cases a thorough exposure of the interior of the bone is the primary step for diagnosis, localization, and treatment ; in this sense the operation on the bone is often exploratory. If any justification of this course is necessary, it is seen in the fact, shown in the table above, that in 79 per cent. of all otitic brain-diseases the bone is diseased directly upon the dura, and the operation on the bone means following the disease inward. I would emphasize this necessity of operating early in intracranial disease without waiting for an accurate diagnosis ; for in a large number of cases the full complex of symptoms

<sup>1</sup> *Die Otitische Erkrankungen des Hirns, der Hirnhäute und der Blutleiter*, Frankfurt, 1894.

necessary for a perfect localized diagnosis only appears a few hours before death.

Having performed the tympano-mastoid exenteration in a case showing brain-symptoms, disease of the bone next the brain should be sought by a careful examination of the whole superior and interior walls of the cavity. The diseased bone may be only a point not larger than the end of a probe; if found, it should be removed with curettes, and the opening enlarged by curettes or rongeurs.

With pachymeningitis externa (extradural abscess), pus is immediately evacuated and the dura cleansed. If the disease is in the middle fossa the only complications are arachnitis and brain-abscess; a fistula through the dura renders one or the other probable, and such a fistula should then be sought; if not found, the opening in the bone should be enlarged so far as the anatomical situation will allow, thorough drainage established by wicks of sterile gauze, and the wound dressed often enough to keep it free from collections of pus, usually daily. The dura becomes covered with granulations which adhere to the edges of the bone, and finally is covered by epidermization of the cavity.

**Sinus-thrombosis.**—If, however, the pachymeningitis is in the cerebellar fossa, besides the possibility of arachnitis and brain-abscess, phlebitis of the lateral sinus should be looked for, as it is a very common complication. It can usually be recognized by feeling the cord of a thrombus; but in case of doubt the sinus can be explored by aspiration, when we get purulent serum if the thrombus is broken down at the point of puncture, no fluid of any kind if the thrombus is firm, and venous blood if there is no thrombus. If thrombosis exists, the sinus should be exposed from its upper to its lower curve by removing the bone with curettes, rongeurs, or an engine, laid open freely, and the thrombus withdrawn both from behind and from below so far as it is broken down, and the vein cleansed. Hemorrhage from removal of the thrombus has never been reported, I believe; should it occur, it can be checked by a tampon of iodoform gauze. Before opening the sinus, however, the internal jugular had better be ligated to prevent displacement of thrombi and general infection; but the dangers of a prolonged operation or infiltration of the neck from a gravitation-abscess through the base of the mastoid, or from periphlebitis, may render this ligation inadvisable or impossible.

The following table from Körner is certainly in favor of the ligation:

*Operations on the Lateral Sinus:*

|                                                            | Cured.              | Died.               | Total. |
|------------------------------------------------------------|---------------------|---------------------|--------|
| With ligation of jugular . . . . .                         | 26 = 63.4 per cent. | 15 = 36.6 per cent. | 41     |
| Without ligation of jugular . . . . .                      | 16 = 42 per cent.   | 22 = 58 per cent.   | 38     |
|                                                            | 42 per cent.        | 37 per cent.        | 79     |
|                                                            | Cured.              | Died.               | Total. |
| Ligation before evacuation of sinus.                       | 19 = 68 per cent.   | 9 = 32 per cent.    | 28     |
| Ligation after " "                                         | 6 = 60 per cent.    | 4 = 40 per cent.    | 10     |
| Ligation without " "                                       | 1 = 50 per cent.    | 1 = 50 per cent.    | 2      |
| Ligation between beginning and end of evacuation . . . . . | 0                   | 1                   | 1      |
|                                                            |                     |                     | 41     |

*Cause of Death of Above 37 Cases :*

|                                         |    |
|-----------------------------------------|----|
| Pyemia with lung-abscesses . . . . .    | 12 |
| Pyemia without lung-abscesses . . . . . | 5  |
| Leptomeningitis . . . . .               | 11 |
| Leptomeningitis and pyemia . . . . .    | 3  |
| Brain-abscess . . . . .                 | 2  |
| Shock . . . . .                         | 1  |
| Not determined . . . . .                | 3  |
|                                         | 37 |

If a fistula through the dura is found, arachnitis or brain-abscess is probable; to distinguish which is present is often impossible. If the former, the case is hopeless; if the latter, there is a possibility of cure. If the fistula is toward the cerebrum, the dura should be exposed over an extended surface, if possible, as large as 3 cm. in diameter, by cutting away, if necessary, the *linea temporalis*; if toward the cerebellum, by cutting away the posterior portion of the mastoid. The dura should then be opened by a crucial incision, and if the abscess has reached the surface, as is often the case, pus is immediately evacuated and the abscess can be freely opened. If only a small fistula is seen in the brain-tissue, or if no fistula is seen, the brain must be explored with a director. How deep this exploration can be carried without injuring specially important parts is of great consequence. These special parts are the anterior, inferior, and posterior horns, the lenticular nucleus, and the inner capsule; these can be avoided by confining the exploration to  $2\frac{1}{2}$  cm. (1 inch)<sup>1</sup> perpendicularly inward from the surface of the dura and 4 cm. ( $1\frac{1}{2}$  inches) at an angle of 45 degrees with the surface; from the base of the brain upward the exploration can be carried to any distance, provided it is kept outside of  $2\frac{1}{2}$  cm. from the lateral surface.<sup>2</sup>

Exploration having proved the presence of an abscess, the exploratory puncture should be enlarged by tearing, the abscess thoroughly evacuated, drained by gauze wicks, and subsequent drainage provided for in the dressing.

In case of doubtful diagnosis or localization, this plan of following the disease inward by a tympano-mastoid exenteration or some modification of it is often best in my opinion; but it has its distinct limitations due (1) to the condition of the bone, (2) to the abscess lying beyond reach from the ear. Under the first we may have such a bony sclerosis or such a low roof and projecting Fallopian prominence or such an outward and forward curvature of the sigmoid groove as to forbid an opening sufficiently large for the brain-operation. Under the second are the very exceptional abscesses in the frontal or occipital lobes, abscesses in the upper convolution of the temporal lobe, and some abscesses of the cerebellum.

If the condition of the bone forbids the opening through the ear, bearing in mind the statistics which show that the chances are 80 in 100 the brain-disease is directly connected with the bone, any exploration should be close to the bone. To get at the mastoid and tympanic roof the skull may be opened at a point  $\frac{1}{2}$  cm. horizontally backward from a point 2 cm. above the upper edge of the osseous meatus, the dura opened and explorations made as already described. To get at the inner surface of the mastoid the posterior portion of that bone can be removed till the dura is fully exposed for at least 2 cm. behind the lateral sinus; explorations can then be made in the cerebellum in any direction to the depth of 3.5 cm. inside the lateral sinus. Another method of exposing the cerebellum, where the mastoid is so heavy or sclerosed as to make the above operation inadvisable, is to strike a basal line from the

<sup>1</sup> Hansberg: *Archives of Otology*, Jan., 1895.

<sup>2</sup> Measurements for an adult brain



inferior osseous edge of the orbit to the occipital protuberance, and to open the skull on this line 5 to 7 cm. back from the edge of the osseous meatus, just below the superior curved line of the occipital bone.

Abscesses beyond reach from the ear can only be diagnosed by a complete complex of localizing symptoms; where such a diagnosis can be made, the skull must be opened over the seat of this abscess. To reach the upper or first temporal convolution, enter the skull 2 cm. back from a point 3 to 3.5 cm. above the upper edge of the osseous meatus; to get at frontal or occipital abscesses, open over their seat as determined by previous localizing symptoms; for them no rules can be given.

I would here utter a caution about the dangers of the trephine, at least on the squamous portion of the bone, which varies very much in thickness in different parts, and the trephine may easily enter the brain at one part of its circumference some time before it has penetrated the bone in another part. In my opinion the only proper instruments are chisel and mallet, round burrs for thinning the inner cortex, and rongeurs to enlarge the first opening made.

Hesitation should always be felt in regard to opening the dura; it is justified only by the existence of a fistula in it or by urgent symptoms pointing to the encephalon, exclusive of arachnitis. Explorations can be carried to the dura with very little risk; it is a fibrous membrane not easily infected; but its incision exposes the arachnoid and pia, which are extremely sensitive to infection, and prolapse of the brain is very apt to follow withdrawal of the support afforded by the dura.

Where the ear cavities are not opened primarily, they must receive attention after the brain-operation, or at a subsequent operation it should never be forgotten that they are the original cause of the brain-disease.

THE NOSE AND THROAT.



# NOSE AND THROAT.

## ANATOMY OF THE UPPER AIR-PASSAGES, INCLUDING HISTOLOGY AND EMBRYOLOGY.

BY HARRISON ALLEN, M. D., LL. D., AND ARTHUR A. BLISS, A. M., M. D.,  
OF PHILADELPHIA.

### EMBRYOLOGY OF THE NOSE, PHARYNX, LARYNX, AND TRACHEA.

BY DR. ARTHUR AMES BLISS.

**The Nose.**—The development of the nose begins about the fourth week of fetal life.

On either side of the fore-brain the epiblast becomes thickened, and in the center of the *olfactory area* thus formed a depression appears, the *olfactory depression*. This assumes a pyriform shape, the larger opening external, the smaller extending backward as a groove toward the buccal invagination, where, very early, appear the rudiments of Jacobson's organ.

The rudimentary base of the nose, the *fronto-nasal process*, appears in the median line at the lower margin of the fore-brain (Fig. 529). A depression exists in the center of this process, and on either side of the depression are the *mesial nasal processes*, their bases being united to the fronto-nasal process, while their free margins terminate in tubercles—the *globular processes*. These eventually approach one another until they unite in the median

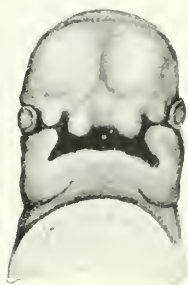

FIG. 529.—Head of human embryo, showing above the oral cavity the fronto-nasal and mesial nasal processes (H18).

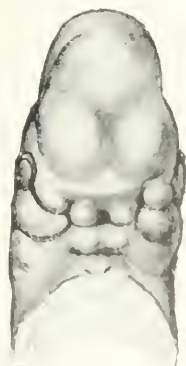

FIG. 530.—Head of an embryo, showing the development of the lateral nasal processes (H18).

line and form the intermaxillary process and middle portion of the upper lip. A depressed surface is left between them, and from this is formed the



lower part of the nasal septum. During this development the globular processes extend backward, also bordering the space which will become eventually the roof of the mouth (Fig. 530). This backward extension constitutes the nasal laminae, by the development of which the nasal septum is completed. Two processes, the *lateral nasal processes*, with bases attached to the fore-brain on either side, external to the fronto-nasal process, grow forward around the olfactory depressions, unite in the median line, and form the *alae nasi*.

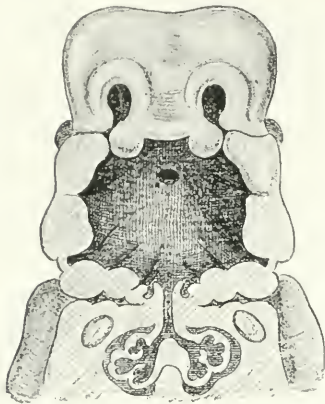


FIG. 531.—Head of embryo, partly sectioned to show the beginning palatal processes growing inward (Hlis).

In their development they meet the *maxillary processes*, also growing forward to the median line, and between the maxillary processes and the lateral nasal processes is found a groove on either side of the head, extending from the eye to the nose—the *lacrymal groove*. The maxillary processes as they approach one another come in contact and unite with the free ends of the globular processes, a junction which, together with the *intermaxillary process*, forms the lip and upper jaw, thus making the division between the anterior part of the nasal passage and the buccal cavity (Fig. 531). Posterior to this now closed anterior part, the olfactory depressions still open into the mouth; but from the outer sides of these depressions processes are thrown out (Fig. 531) which develop into the turbinal bodies, while gradually the

developing palatine processes of the superior maxilla, outgrowths from the embryonic maxillary processes, approach the lower part of the nasal septum, and unite with it and with one another to form the roof of the mouth and floor of the nose. The nares and buccal cavity are thus separated from one another (Fig. 532), except in the extreme posterior part of the nasal passages, where, in the naso-pharynx, is found the free opening from the nares to the oro-pharynx.

#### The Mouth, Pharynx, Larynx, and Trachea.

—In the process of evolution of the embryo from the blastoderm the three embryonic layers gradually enfold three distinct cavities, called the fore-gut, the hind-gut, and, between them, a space which long remains in free communication with the yolk-sack. The cephalic portion of the embryo is bent at a right angle around the anterior part of the fore-gut. Below, the latter is bounded by the heart. A thin epithelial membrane separates the fore-gut from the involution of the epiblast which forms the buccal cavity, or *stomodaeum*. This deepens, projecting upward into the angle between the fore- and mid-brains, where the pituitary body is formed; the epithelial septum between the buccal cavity and the fore-gut disappears; and the process of development already described in treating of the growth of the nose completes the formation of the face and mouth. The anterior part of the fore-gut, the area of the pharynx, enlarges, and the hypoblastic layer throws out four projections on either side in order from above downward. Opposite these outgrowths the epiblastic layer projects inward, and four clefts

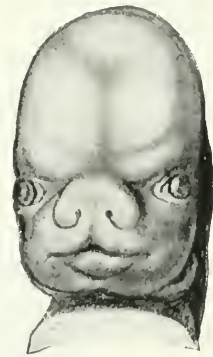


FIG. 532.—Head of embryo, showing the completed union of the constituents of the nose and lip (Hlis and Quain).

Opposite these outgrowths the epiblastic layer projects inward, and four clefts

in the pharyngeal wall are thus formed, the *cephalic visceral clefts*. About them the pharyngeal wall thickens into five curved ridges, the *cephalic visceral arches*. A forked elevation termed the *furcula* separates the second and third visceral arches (Fig. 533). A groove passes through its center, and immediately in front of this, in the receding angle between the two arms of the second arch, a tubercle projects, the *tubercle impar* (see Fig. 533). The second and third arches coalesce at their receding angles to form one mass with four projecting arms. The latter grow forward into a V-shaped projection, enclosing the tubercle impar and uniting into one mass to form the tongue. The epiglottis is developed from the furcula, and from it also develop the ary-epiglottic folds and arytenoid cartilages. The groove seen in its center extends to the entrance of the larynx.

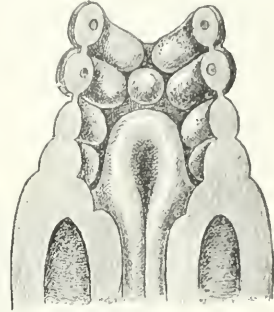


FIG. 533.—Posterior aspect of the visceral arches as seen from the interior of the pharynx (HIS).

Of the visceral clefts the first, called the *hyo-mandibular cleft*, is an important element in the formation of the Eustachian tube and middle ear. The median base of the branchial rudiments gradually separates from the esophagus, serving as a partition-wall between the latter and the larynx and trachea.

#### ANATOMY OF THE NASO-PHARYNX, PHARYNX, LARYNX, AND TRACHEA.

**The Pharynx.**—The pharynx is the common entrance to the respiratory and digestive tracts. For purposes of description and, also, clinically, it may be divided into three distinct areas—the naso- or rhino-pharynx, the oro-pharynx, and the laryngo-pharynx (Fig. 536).

The *rhino-pharynx* lies immediately posterior to the nasal chambers or posterior nares. It is slightly quadrilateral in shape, its transverse diameter measuring about one and three-eighths inches, while its antero-posterior and vertical diameters are about three-quarters of an inch.

In front it is bounded by the two oval openings of the posterior nares, with the rear margin of the vomer in the median line (see Figs. 535 and 562). This margin is thin below, but widens into two lateral arms or wings above, where the vomer is attached to the body of the sphenoid bone. The upper surface of the naso-pharynx or vault is formed by the basilar process of the occipital bone and a portion of the body of the sphenoid bone (see Fig. 434). On either side it is flanked by the pharyngeal openings of the Eustachian tubes (see Figs. 451, 562). Its floor is formed by the soft palate and by the opening into the oro-pharynx.

The mouths of the Eustachian tubes present prominent projections on either side of the naso-pharynx, formed mainly from the cartilage of the tube. The orifice of each tube lies about on a plane with the posterior margin of the vomer. Its exact position varies in different subjects. A well-defined ridge of cartilage roofs the tube and forms its posterior lip. The ridge is less prominent in front than above and behind the Eustachian opening. It is not seen below the orifice. The mucous membrane of the naso-pharynx forms a distinct fold where it is reflected over the posterior lip of the tube and passes thence to the pharynx. Luschka terms this fold the *plica salpingo-pharyngea*. A similar fold, less marked however, extends from the anterior lip of the tube to the soft palate, termed by Luschka the

*plica salpingo-palatina*. A crescent-shaped depression is seen immediately behind the posterior lip of the Eustachian opening—the *fossa of Rosenmüller*. It is of considerable clinical importance, as it is a valuable guide in the introduction of a catheter into the Eustachian opening. The Eustachian openings, closed during a state of rest, are opened by the contractions of the *tensor* and *levator palati* muscles. The tensor muscle, termed also the *spheno-*

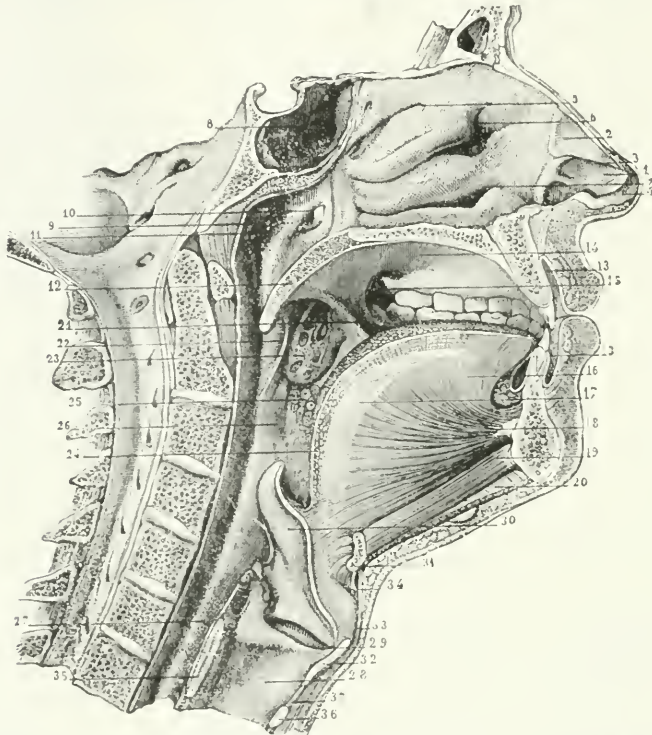


FIG. 534.—Sagittal section of the head and neck, showing the upper air-passages, beginning at the nostril (1), including the superior (5), middle (6), and inferior (7) nasal meatus beneath the corresponding turbinals, the sphenoid sinus (8), the Eustachian tube (10), the rhino-pharynx and Rosenmüller's fossa (11) above the soft palate (12), the oro-pharynx (26), and fauces (22), and the laryngo-pharynx (27). The trachea is not shown below the cavity of the larynx (28) with its ventricle (29) bordered by the vocal cord below and the ventricular band above. The relation of the epiglottis (30) to the larynx below it and the hyoid bone (31) in front is well shown; but the tongue (17) really fills the mouth normally and lies in contact with the soft and hard palate (14), the uvula (21) reaching to the epiglottis, as the mouth is not properly a part of the air-passages (Leidy).

*salpingo-staphylinus*, or dilator muscle, arises from the scaphoid fossa and base of the internal pterygoid plate of the sphenoid bone, and from the front of the entire cartilaginous portion of the Eustachian tube. Its fibers pass downward, winding around the hamular process of the sphenoid bone, and are inserted in the soft palate. Its contraction dilates the tube by drawing the anterior margin of its cartilage and the membranous front wall downward and forward (see Fig. 450). The *levator palati* muscle arises from the petrous portion of the temporal bone and from the cartilaginous part of the Eustachian tube. Its fibers are inserted by a broad tendon into the median line of the soft palate (Fig. 535). Its function is to lift the lower wall of the Eustachian tube, which tends to separate the lateral walls and open the tube. The *palato-pharyngeus* muscle, described later, is also partially attached to the cartilaginous part of the Eustachian tube. It acts as an aid to the levator palati muscle.



The covering of the naso-pharynx consists of mucous membrane richly supplied with mucous glands and having a covering of columnar ciliated epithelium. Beneath the mucous membrane lies a dense fibrous aponeurosis, which is the upper part of the general pharyngeal aponeurosis. It is firmly attached to the basilar process of the occipital bone and to the petrous portion of the temporal bone.

In certain subjects suffering from sclerotic or atrophic rhinitis, a well-defined ridge is seen to project from the posterior and lateral walls of the naso-pharynx about at the level of the free margin of the soft palate. Acting with the palate, when the latter is raised, this ridge becomes very prom-

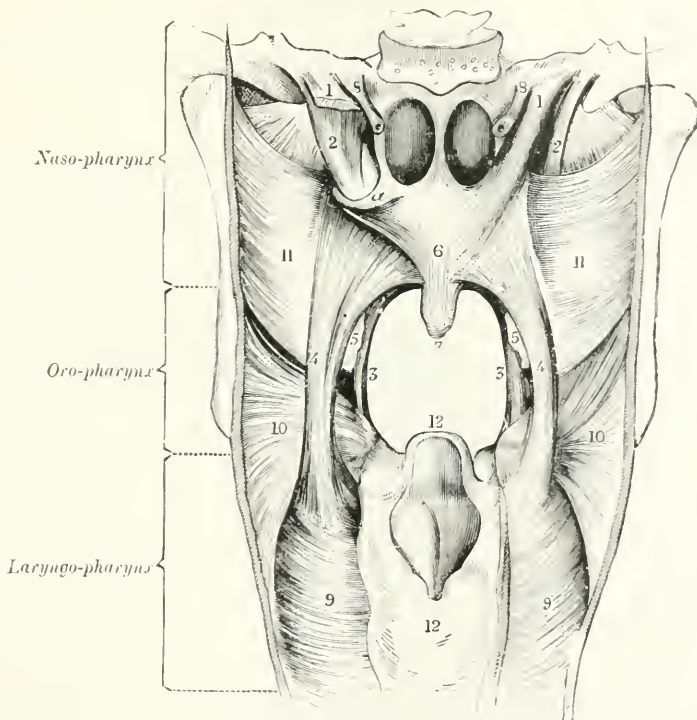


FIG. 535.—Pharynx from behind, showing its muscles. The levator palati (1) is seen to arise beneath the Eustachian tube (8), to be inserted into the velum, as is the tensor (2) after hooking around the hamulus at *a*. The palato-glossus (3) and the palato-pharyngeus (4) form the anterior and posterior pillars enclosing the tonsils (5), and the azygos (6) passes down upon the uvula (7). The inferior (9), middle (10), and superior (11) constrictors of the pharynx are shown partially, and the posterior nares, the oral cavity (normally filled by the tongue), and the larynx (12) (Brown).

inent, "Passavant's cushion," and helps to close the opening from the naso- to the oro-pharynx, as strings pucker up and close the mouth of a purse.

Its existence often interferes with the escape of secretions downward from the naso-pharynx, and thus causes their retention and crust-formation at this point. This ridge is caused by the prominence of the contracting upper fibers of the superior constrictor muscle of the pharynx as they pass downward and backward along the free superior margin of the muscle from its wide attachment above to the median line of the pharyngeal aponeurosis.

The lymphoid structure in the naso-pharynx is of great clinical importance. This tissue is a part of "the lymphoid ring" of the pharynx. It is located in the center of the superior and posterior walls of the naso-



pharynx, and spreads laterally on either side to the recesses above the lips of the Eustachian openings and even into the fosse of Rosenmüller. Normally, it is about one-fourth of an inch in thickness, and should not cause occlusion of the naso-pharyngeal space or pressure upon the Eustachian opening. In structure it is a collection of lymph-follicles, or adenoid tissue, held together in a loose fibrous network of connective tissue and covered with mucous membrane having columnar ciliated epithelium. In rather rare instances an opening is observed leading to a closed sac in the center of the mass, termed the *bursa pharyngea*. Its very existence as a normal structure has been questioned by many writers. When present it is doubtless an abnormal phase of development (see page 949).

The **blood-supply** of the naso-pharynx comes through the ascending pharyngeal artery, a branch of the external carotid; through the ascending palatine, a branch of the facial; and through the sphenopalatine, a branch of the internal maxillary (see Fig. 549).

The *veins* pass into the internal jugular vein.

The *nerve-supply* comes from the superior maxillary nerve (second branch of the fifth nerve) and from the pneumogastric and glosso-pharyngeal nerves.

The **Oro-pharynx and Laryngo-pharynx**.—The *oro-pharynx* may be said to extend downward from the projection on the posterior wall of the pharynx caused by the tubercle on the anterior arch of the first cervical vertebra. An imaginary line from this point to the base of the uvula serves as a dividing-line between the naso- and oro-pharynx (Fig. 534). We shall refer to the oro- and laryngo-pharynx as the pharynx proper. It is quadrilateral in shape, its antero-posterior diameter being much more narrow than its transverse. Its anterior wall extends from the base of the uvula and the free margin of the soft palate downward across the oral cavity to the posterior extremity of the greater horn of the hyoid bone. Its posterior wall extends from the tuberosity on the anterior arch of the first cervical vertebra to the orifice of the esophagus. Its lateral walls are in relation with the common and internal carotid arteries, the internal jugular vein, the sympathetic nerve, and the eighth and ninth cranial nerves.

In general structure the pharynx is a musculo-membranous sac consisting of three layers, an inner mucous membrane, a middle fibrous layer, and an outer layer of muscular tissue.

The *mucous membrane* of the pharynx is thin, and in the naso- and oro-pharynx adheres closely to the fibrous layer beneath it. Like the mucous covering of the alimentary tract in general its epithelial layer consists of squamous cells. As the pharyngeal vault is approached the epithelium changes more and more to the type found in the respiratory tract, and, in the purely respiratory tract of the naso-pharynx, it becomes columnar and ciliated. Two varieties of glands are found in the pharyngeal mucous membrane. One, the ordinary muciparous gland, exists in greatest number in the oro-pharynx and upon the soft palate. The glands of the second variety lie deeper in the mucous membrane and belong to the lymphoid type. These ductless follicles are scattered irregularly throughout the mucous membrane, but exist in greatest number along the lateral surfaces of the pharyngeal wall, lying closely behind the so-called posterior faucial pillars.

The *fibrous layer of the pharynx*, or pharyngeal aponeurosis, external to the mucous membrane is, in the upper pharyngeal region, very dense in structure; but in the laryngo-pharynx it becomes thinner, until it is scarcely to be traced at the entrance of the esophagus. In the naso-pharynx it adheres closely to the basilar process of the occipital (Fig. 536).

The *muscular coat of the pharynx*, its third and deepest layer, consists of three flat *constrictor* muscles, so arranged as to form a sheath around the posterior and lateral walls.

The *superior constrictor muscle* arises from the lower portion of the margin of the internal pterygoid plate and from its lamular process, from the portion of the palate-bone adjacent and from the reflected tendon of the tensor palati muscle, from the pterygo-maxillary ligament, from the alveolar process of the superior maxilla above the posterior extremity of the mylo-hyoid ridge,

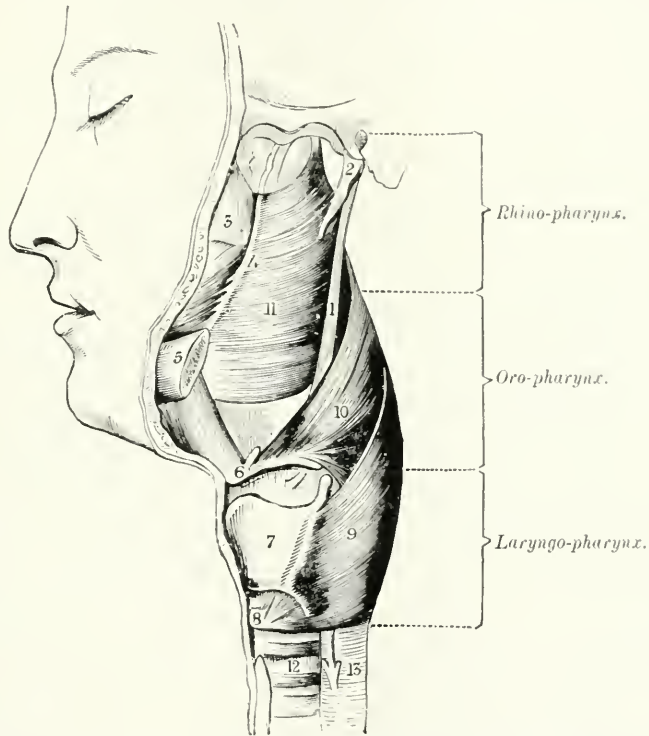


FIG. 536.—Lateral view of the pharynx, larynx, and esophagus, showing the superior (11), middle (10), and inferior (9) constrictors, arising from the pterygo-maxillary ligament (4), the hyoid bone (6), and the larynx (7), respectively, to pass back to the posterior raphé. The arrangement of the fibers clearly suggests the action of the superior constrictor in closing off the rhino-pharynx before deglutition through the action of the lower constrictors.

and from the sides of the tongue, where a few fibers of the superior constrictor are in connection with the genio-hyoglossus muscle. From this very widely-distributed attachment the fibers of the main body of the muscle curve backward to be attached to the raphé in the median line of the pharyngeal aponeurosis. The superior fibers curve backward and upward, blending with the fibrous aponeurosis which covers the pharyngeal vault, and is attached to the pharyngeal spine of the occipital bone. The projecting ledge caused by the free upper margin of this muscle, already mentioned, assists in closing the naso- from the oro-pharynx, and is of clinical importance in some cases of atrophic rhinitis. The superior constrictor is quadrilateral in form, and its fibers are thinner than are those of the middle and inferior constrictors. Its inferior fibers are partially overlapped by the upper fibers of the middle constrictor.

The *middle constrictor*, arising from the greater and lesser horns of the hyoid bone and from the stylo-hyoid ligament, is a fan-shaped muscle, its fibers passing up, back, and down to the median raphé.

The *inferior constrictor*, the largest of the three, arises from the thyroid and cricoid cartilages, its attachment to the thyroid being at the inferior cornua and along the oblique lines on the sides of the ala and on the surfaces immediately behind these lines, almost as far as the posterior borders. From the cricoid cartilage it arises in the interval between the crico-thyroid muscles in front and the facet for the crico-thyroid articulation behind. The fibers pass backward and slightly upward, and are attached to the raphé in the median line of the pharyngeal aponeurosis, the ascending fibers overlapping the lower fibers of the middle constrictor, while the lower fibers blend with the circular muscular fibers of the esophagus. Beneath the constrictor muscles are found the *longus colli* and the *rectus capitis anticus muscles*, with the cervical vertebræ beyond.

The three constrictor muscles are the chief elements in the formation of the muscular layer of the pharynx. Certain other muscles, however, contribute to the formation of this muscular coat, and are classified among the muscles of the pharynx. These are the *stylo-pharyngeus*, the *palato-glossus*, the *palato-pharyngeus*, and the *stylo-hyoid*.

The *stylo-pharyngeus* (see Figs. 535, 536) is a long, narrow, muscular band, round and cord-like above, where it arises from the inner side and base of the styloid process, but flattened and widened as it descends by the side of the pharynx, passing between the superior and middle constrictors. Most of its fibers terminate beneath the mucous membrane of the pharyngeal wall, some merging with fibers of the constrictor muscles. Other fibers descend farther and are inserted into the thyroid cartilage on its posterior border.

The *palato-pharyngeus* muscle (see Figs. 534, 535) is a broad thin band, widening as it descends, apparently from the base of the uvula, and passes down and back, to be lost in the lateral pharyngeal walls. It forms with the covering mucosa the "posterior pillar of the fauces." Its superior origin is by two fasciculi in the soft palate, joining their fellows of the opposite side in the median line. It is inserted with the stylo-pharyngeus into the posterior border of the thyroid cartilage. A few of its fibers spread along the sides of the pharynx and cross the latter to join, in the median line, those from the opposite side.

The *palato-glossus muscle* (see Figs. 534, 535) forms the so-called "anterior pillar of the fauces." It is a narrow fibrous band, narrower and thinner than the palato-pharyngeus muscle, or "posterior pillar." Its upper attachment is the anterior surface of the soft palate. It passes in front of the tonsil downward, forward, and outward, and is inserted into the sides and back of the tongue.

**Blood-supply of the Pharynx.—Arteries.**—The ascending pharyngeal arteries, branches of the external carotid, supply the constrictor muscles and the mucous membrane. They may be of abnormal size, not rarely so large as to cause a distinct pulsation on one or both sides of the pharynx, just behind the posterior faucial pillars.

The Vidian and descending palatine arteries, branches from the internal maxillary artery, also supply the pharyngeal tissues, as do branches from the facial, the tonsillar, and ascending palatine arteries.

**Veins.**—A thick network of veins is found in the fibrous layer of the pharynx, forming the pharyngeal plexus in the posterior and lateral walls. From these the blood is led by the pharyngeal vein into the internal jugular.

*Lymphatics.*—The lymph-vessels follow the course of the pharyngeal plexus and veins and enter the chain of lymphatic glands along the sheath of the carotid, terminating on the right side in the right ductus lymphaticus; on the left in the thoracic duct.

*Nerves.*—The sensory nerves of the pharynx come from the glosso-pharyngeal. The motor nerves are derived from the glosso-pharyngeal and pneumogastric. These, with the sympathetic, unite to form the pharyngeal plexus.

*Lymphoid Structure of the Pharynx.*—Reference has been made already to the ductless follicles in the pharyngeal mucous membrane and to their special seats of location on the lateral and postero-lateral walls of the pharynx.

At certain points in the pharynx are found conglomerate masses of lymphoid tissue, forming a continuous "lymphoid ring" around the entrance to the alimentary and respiratory tracts.

The upper segment of this ring is formed by the adenoid tissue of the naso-pharynx, or "pharyngeal tonsil," already described; the lateral segments are formed by the "faucial tonsils," and the lower segment by the lymphoid tissue found at the base of the tongue, "the lingual tonsil." The *faucial tonsils* are small oval or almond-shaped masses of lymphoid tissue, placed within the somewhat triangular space between the palato-pharyngeal and the palato-glossal muscles. In the normal condition they are about three-quarters of an inch in vertical length by one-third of an inch in breadth. Even within normal limits, however, there is great variation in size. The free surface of each faucial tonsil is marked by numerous round or slit-like openings, arranged in two or more parallel columns, or more irregularly, which lead down into invaginations of the surface called crypts. This peculiar structure is claimed by Retterer to be the result of an ingrowing of the epiblastic membrane into the hypoblast. The epithelial elements are thus forced into a lymphoid mass, and the latter grows around the invaginations or into their walls, breaking up their outline into small, lateral pockets. The diverticula, as Harrison Allen terms the lymph-follicles, are thus in the faucial tonsils arranged in groups which occasionally sink below the general surface of the mass, thus forming the crypts.

The *lingual tonsil* occupies the base of the tongue, being placed between this and the epiglottis. It is a smooth, soft, even mass of lymph-follicles, the diverticula of which, as Allen states, are single and not in groups.

The covering of both the faucial and lingual tonsils consists of the pharyngeal mucous membrane. In many instances, however, this is underlaid by bands of fibrous tissue which more or less fully encapsulate the lymphoid masses.

The faucial tonsil is in rather close relation with the internal and external carotid arteries, the internal jugular vein, and the pneumogastric nerve. These structures, however, pass through the posterior portion of the pharyngo-maxillary interspace, while the faucial tonsil occupies the anterior part of this space; thus they are safely beyond the reach of any cutting instruments which are used with skill and care in operations upon the tonsils.

The *blood-supply* of the faucial tonsil comes from the facial artery by the tonsillar and ascending palatine; from the lingual artery by the dorsalis lingue; from the external carotid by the ascending pharyngeal; and from the internal maxillary by the descending palatine branch. The most important artery is the tonsillar, springing from the facial artery. It is a small vessel in children, but in adults is of more important size. It is not apt to be wounded during cutting operations upon the tonsils, unless such procedures involve the base of these masses.



The *veins* center into a plexus, named the tonsillar plexus. The nerves are from the fifth nerve and the glosso-pharyngeal nerve.

**The Larynx.**—The larynx forms the entrance to the respiratory tract and is, at the same time, the organ for the formation of the voice. Its function of voice-production depends largely upon the vocal cords, and the general structure of the larynx is designed to protect these and to give attachment to the muscles controlling their movements.

**The Cartilages.**—The framework of the larynx (Fig. 537) consists of the thyroid, the cricoid, and the two arytenoid cartilages, composed of true cartilage; and of the two corniculæ laryngis (cartilages of Santorini), the two cuneiform cartilages (cartilages of Wisberg), and the epiglottis, all fibro-cartilaginous in structure. Above the larynx, and at the base of the tongue, which is attached to it, lies the hyoid bone (Figs. 537, 538). The hyoid bone (from the Greek *υ*-shaped), besides its important relation to the tongue and its function in serving to stretch the pharynx in its lateral diameter, serves also to give a point of fixation above to the larynx. It consists of a central body with two greater and two lesser cornua. The body is quadrilateral in form, convex on its anterior surface, concave posteriorly. It supports the two lesser cornua which project upward and backward from its superior and lateral margins. From these lateral margins beneath the lesser cornua extend backward the greater cornua, completing the half-circle. From the hyoid bone muscles and ligaments pass to the epiglottis and to the thyroid cartilages, uniting it with these structures.

The *thyroid cartilage* (Fig. 537) (from the Greek, a shield) consists of two curved quadrilateral plates, converging anteriorly to meet in the median line, and forming a projecting angle somewhat like the prow of a ship. This angle is a prominent feature in the neck (see Fig. 534), especially in the adult male (the "Adam's apple"), standing boldly outward beneath the integument, from which occasionally it is separated by a bursa. The upper margin of each side, or *ala*, of the thyroid curves downward at this point of junction, forming the thyroid notch, resembling the spout of a pitcher; and backward each descends slightly to rise abruptly at the posterior limit into a long process, pointing upward, called the superior cornu (Fig. 538). The prominent anterior angle of the thyroid is slightly concave below the thyroid notch. The lower border of each ala curves backward and generally downward and forms the lesser cornu. The posterior, free borders of the thyroid, which are rounded and thick, thus terminate, above in the greater, below in the lesser, cornua. An oblique ridge passes downward and forward across the outer surface of each ala of the thyroid, starting from a tubercle near the base of the superior cornu, and gives attachment to the sterno-thyroid and thyro-hyoid muscles. Back of this ridge, and including the surface to the posterior margin of each ala, is the long narrow area of attachment of the inferior constrictor muscle of the pharynx, while to the center of the posterior margin is attached the stylo-pharyngeus muscle.

The inner surface of each ala is concave, and covered in the upper and posterior portions with mucous membrane. In the receding angle anteriorly, where the two alæ unite immediately below the thyroid notch, the thyro-epiglottic ligament forms the attachment of the epiglottis, and just below this, on either side, are the anterior points of attachment for the ventricular bands, or false vocal cords (Fig. 539). The true vocal cords, together with the thyro-arytenoid muscles, have their anterior points of attachment immediately beneath these in the lower third of this receding angle. The lower margins of the thyroid cartilage, in their anterior and lateral aspects,

give attachment to the crico-thyroid membrane and to the crico-thyroid muscle.

The *crioid cartilage* (from the Greek, a ring) lies immediately below the

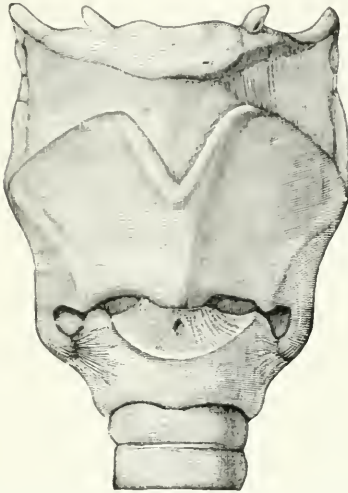


FIG. 537.—Larynx, showing the thyroid and cricoid cartilages, with the trachea below and the hyoid bone above, with the connecting membranes (Leidy).

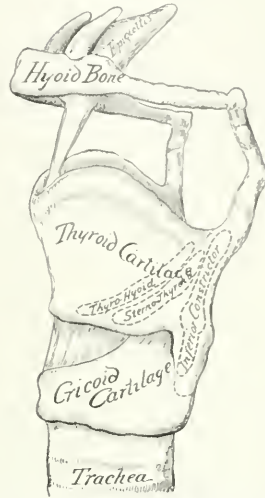


FIG. 538.—Lateral view of larynx in its relation to the hyoid bone and trachea.

thyroid (Figs. 537, 538, 540). Its anterior half is small, narrow, rounded, and convex in shape. Its superior margin rises as it extends backward,

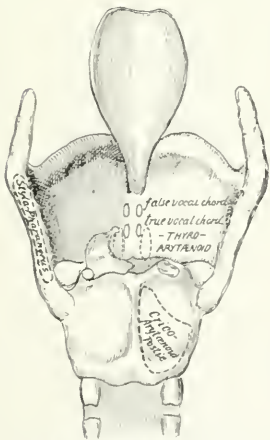


FIG. 539.—Inner aspect of larynx from behind, showing insertions of epiglottis, true and false cords, and of the intrinsic muscles.

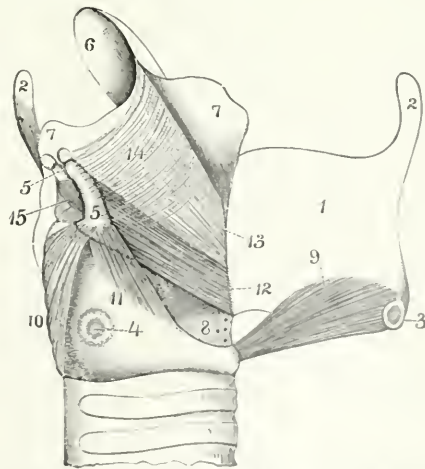


FIG. 540.—Larynx dissected to show the muscles: the crico-thyroid (9) inserted on the inner aspect of the ala to the articulation (3); the posterior crico-arytenoid (10) inserted at the base of the arytenoid (5), behind the lateral crico-arytenoid (11); the thyro-arytenoid (12) just below the position of the vocal cord; the thyro-epiglottic (13) and aryteno-epiglottic (14) fibers between the lamina of the ary-epiglottic fold; and the arytenoid (15) between the arytenoid cartilages (Leidy).

causing the cartilage to broaden toward its posterior portion, which is almost thrice as broad, in a vertical direction, as is the anterior; while it is at the

same time greatly increased in thickness. On the outer lateral surface of this posterior "seal" portion of the ring are facets, one on either side, for articulation with the lesser cornua of the thyroid cartilage. On its upper surface in this posterior half are two facets, their long diameters transverse, for articulation with the arytenoid cartilages. In the median line of the broad posterior border of the cricoid is a vertical ridge for the attachment of the esophagus, with broad points of attachment on either side for the posterior crico-arytenoid muscles. The outer surface of the cricoid anteriorly gives attachment to the crico-thyroid ligament and to the crico-thyroid muscle and to the lateral crico-arytenoid muscle.

The cricoid forms the back of the larynx, as well as its lower portion, and is the base upon which the other cartilages of the larynx rest.

The *arytenoid cartilages* ( $\delta$ , a pitcher) (Fig. 539) are two pyramidal cartilages which articulate with the upper margin of the thick posterior portion of the cricoid. They might be called the cartilages of the vocal cords, as the vocal cords, together with all the muscles controlling their movements (with the exception of the crico-thyroid), are attached to the arytenoids. They present three surfaces, a base, and an apex for study. The inner surface of each cartilage, covered with mucous membrane, is smooth, flat, somewhat triangular in shape, for apposition to the corresponding side of its fellow. The anterior surface is convex and gives attachment to the ventricular bands and the thyro-arytenoid muscle. The posterior surface is concave and triangular in shape and gives attachment to part of the arytenoid muscle. The base is concave for articulation with the corresponding convex facet on the cricoid, and is marked by two projections or processes terminating its external and anterior angles. The longer of these is the anterior, called the *vocal process*, as to it the vocal cord is attached. The rounded external process is named the *muscular process*, and upon it are inserted the posterior and the lateral crico-arytenoid muscles. The apices of the arytenoids are pointed and curve backward and inward. Each apex is crowned by a small nodule of cartilage, serving to lengthen it slightly, called the *cornicula laryngis*, or cartilage of Santorini. To these nodules are attached the aryteno-epiglottidean folds, in which, close to the outer side of each cartilage, are embedded the two small cartilages of Wrisberg, the cuneiform cartilages. They are sesamoid in character and vary greatly in size in different individuals. Two sets of sesamoid cartilages are also found occasionally, the posterior and anterior sesamoid cartilages. When present, the posterior sesamoids lie between the apices of the arytenoids and the cartilages of Santorini; the anterior are found in the extreme anterior end of the vocal cords, being attached to the receding angle of the thyroid cartilage.

The *epiglottis* (see Figs. 538 and 539), named from its position above the glottis, is the cover of the larynx. It is an oblong, leaf-shaped plate of fibro-cartilage, its upper border rounded, its lower somewhat pointed and attached by a long thyro-epiglottic ligament to the receding angle of the thyroid cartilage immediately below the thyroid notch. The mucous membrane covering the anterior surface toward the base of the tongue is reflected to the sides and base of the cartilage in two folds, the *glosso-epiglottic ligaments*. The anterior surface curves forward slightly toward the tongue, but the position varies greatly in different subjects. The posterior surface, transversely concave but vertically rather convex, faces somewhat downward over the laryngeal entrance and is covered with mucous membrane, which at its base is thickened by the presence of adenoid tissue into a smooth, slightly prominent elevation termed the *cushion of the epiglottis*. Its free margin is rounded, or, especially



in children, is narrowed into a curve, with the concavity downward, rendering, when in this form, a view of the interior of the larynx somewhat difficult, as the epiglottis is apt then to be more depressed than when this upper margin is broad and flattened. The epiglottis is also connected with the body of the hyoid bone on the posterior surface of the latter by a ligamentous or elastic band, the *hyo-epiglottic ligament*. The aryteno-epiglottic folds are attached to the sides of the epiglottis. Numerous pits, or depressions, are found in the body of the cartilage of the epiglottis, in which lie small mucous glands. The epiglottis being freely movable varies in position during respiration and deglutition. During respiration it maintains a somewhat vertical direction, its free margin being curved toward the base of the tongue. In the act of deglutition, however, as the larynx rises, the epiglottis is carried upward against the base of the tongue and its free margin is greatly depressed, so as to serve as a cover to the entrance of the larynx.

**Ligaments of the Larynx.**—The thyroid cartilage is bound to the hyoid bone by three ligaments, the two *lateral thyro-hyoid ligaments*, narrow, rounded bands of fibro-elastic tissue, attached to the extremities of the superior cornua of the thyroid cartilage and extending upward to the greater cornua of the hyoid bone; also, the *thyro-hyoid membrane*, a broad, fibro-elastic membrane, attached below to the upper border of the thyroid cartilage, and above to the posterior face of the body of the hyoid bone. The superior laryngeal nerve and vessels pass through the median line of this membrane.

The thyroid and cricoid cartilages are bound together by three ligaments, the *crico-thyroid membrane* and two *capsular ligaments* (see Fig. 537). The crico-thyroid membrane, triangular in shape, passes from the superior margin of the cricoid cartilage in the median line and from both sides anteriorly, and is inserted in the lower border of the anterior part of the thyroid cartilage. Thick in the center, it becomes thinner on either side, and these lateral portions are joined at their insertion with the insertion of the true vocal cords. In the median line the crico-thyroid membrane lies directly beneath the skin, and thus offers a ready means for effecting an artificial opening into the larynx. At this point the membrane is crossed by an anastomosis of the two small crico-thyroid arteries. It is covered on its inner surface with mucous membrane. The lateral portions of the crico-thyroid membrane are covered by the crico-thyroid muscle and the lateral crico-arytenoid muscles.

The capsular ligaments between the cricoid and thyroid cartilages bind the inferior or short processes of the thyroid to the cricoid cartilage at their points of articulation.

The arytenoid cartilages are held to the cricoid cartilage by loose *capsular ligaments*, also posteriorly by the small *posterior crico-arytenoid ligaments*.

The epiglottis is bound to the hyoid bone by two ligamentous bands which extend from the sides of the cartilage, near its apex, the *hyo-epiglottic ligaments*, and to the thyroid cartilage by the *thyro-epiglottic* ligament already described.

The *median glosso-epiglottic* folds of mucous membrane unite the epiglottis to the base of the tongue.

*Interior of the Larynx* (Fig. 541).—The general shape of the laryngeal opening is triangular with the base posterior. Looking from above into the larynx the free margin of the epiglottis is first seen, a curving surface which varies in the degree of its curvature in different subjects. Beneath, and posterior to the inner face of the epiglottis, appear the apices of the arytenoid cartilages, the small cartilages of Santorini at the apex of each, the smooth rounded swelling on the outer side of both arytenoids, paler than the red of



the general mucous covering, showing the location of the cartilages of Wisberg. These are seen to lie each in the body of a broad prominent fold, which passes in a half-circle framing the sides of the laryngeal opening, one on each side, from the arytenoid cartilages upward to the side of the epiglottis. These are the aryteno-epiglottic folds. Below the level of the apices of the arytenoid cartilages, two bands, covered, like the tissue already named, with mucous membrane, pass from the arytenoids forward to the receding angle of the thyroid cartilage, terminating there beneath the attachment of the epiglottis. These are the *ventricular bands*, or *false vocal cords*. They are also named the superior thyro-arytenoid ligaments.

Beneath these ventricular bands, and appearing to edge their free border, although in reality below them, are seen two white bands which pass forward from the anterior angles, or vocal processes, of the arytenoid cartilages to the receding angle of the thyroid cartilage. These are the *true vocal cords*. Between the free margins of the vocal cords is an open space of triangular shape with the base posterior, which varies in width as the cords approach or recede from each other. This is the glottis, or *rima glottidis*, and through this space can be seen the anterior surface of the trachea ridged by its rings perhaps down to the bifurcation into the bronchi. Between the arytenoids, at about the level of the vocal cords, is a point of considerable clinical importance, the space between the arytenoids, or *the interarytenoid space*.

A free space exists between the ventricular bands and the vocal cords. This space is found to follow the under surface of the ventricular bands, extending laterally and upward between the ventricular bands and the alæ of the thyroid cartilage on either side, and to terminate anteriorly in a blind pouch. The space is called the ventricle of the larynx, and the pouch named

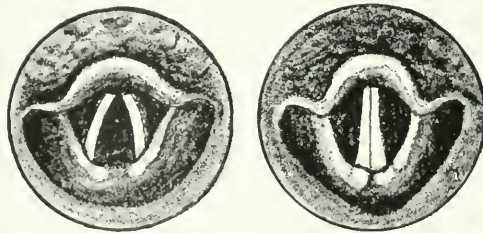


FIG. 541.—The laryngoscopic image in deep inspiration and in phonation.

the saccus laryngis (Fig. 542). This entire area is lined with mucous membrane richly supplied with mucous glands.

The chink of the glottis varies in extent according to age and sex. In the adult male its length is about seven-eighths of an inch. In the female it is smaller. When fully dilated this triangular-shaped opening at its base posteriorly is about one-half of an inch in width. At the posterior attachment of the vocal cords will be seen usually a slight indentation of a whiter color than that of the main body of the cords. This point is the extremity of the vocal process of the arytenoids. It is of some clinical interest, as these points have at times been mistaken for ulcerations or cicatrices on this portion of the vocal cords.

The free margins of the vocal cords mark the most narrow portion of the larynx. Below these the subglottic space widens, assuming the general form of the circle formed by the cricoid cartilage, at first somewhat oval in the lateral diameter, soon changing to circular as the trachea is approached. Thus a section of the entire larynx would roughly resemble an hour-glass form,

widening above and below, with a constriction in the center at the location of the vocal cords (see Fig. 548).

**Muscles of the Larynx.**—The muscles of the larynx are the posterior crico-arytenoids, the lateral crico-arytenoids, the inter-arytenoid or arytenoid, which act as the abducting and adducting muscles of the vocal cords; the thyro-arytenoids and crico-thyroid, whose function it is to regulate the tension of the vocal cords; the thyro-epiglottic, aryteno-epiglottic, superior and inferior, supplying some power of movement to the epiglottis; the thyro-hyoid and sterno-hyoid, which serve as muscles of fixation for the larynx.

The *posterior crico-arytenoid* arises from the posterior surface of the cricoid cartilage, on either side of the median line (Fig. 539). Its fibers pass

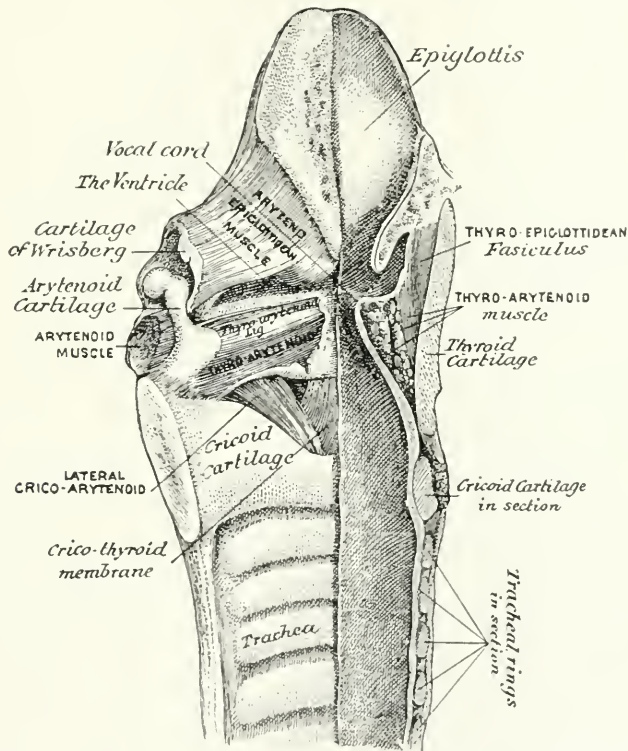


FIG. 542.—Interior of larynx, showing on the right the parts in median section, and on the left a dissection of this half, with the muscles and cartilages exposed (Allen).

upward and outward and are attached to the muscular process of the arytenoid cartilage (Fig. 540, 5). With point of fixation on the cricoid, this muscle, by contracting, rotates the arytenoid cartilage outward by drawing its muscular process backward. The two vocal processes of the arytenoid cartilages are thus drawn away from the median line outward, and the vocal cords are separated (see Fig. 665).

The *lateral crico-arytenoid* muscles (see Fig. 540) arise, one on either side, from the upper margin of the lateral part of the cricoid cartilage. The fibers of each muscle pass upward and backward and are inserted in the muscular processes of the arytenoid cartilages at a point just anterior to the insertion of the posterior crico-arytenoid muscles. The action of the lateral crico-

arytenoid muscles, being fixed at their cricoid attachments, is to adduct the vocal cords by drawing forward the muscular processes of the arytenoid cartilages, thus approximating the vocal processes of these cartilages (Fig. 665).

The *arytenoid muscle* is a single, square-shaped muscle with two sets of fibers, the transverse and oblique. The transverse fibers, which are the deeper, are attached to the posterior surface and outer margin of one arytenoid muscle and pass transversely across to be inserted into the corresponding part of the other arytenoid cartilage (see Fig. 540, 15). The more superficial oblique fibers consist of two thin muscular slips which pass from the base of one arytenoid cartilage to the apex of the other. In some instances fibers from the oblique bands pass around the outer sides of the two cartilages and blend with the fibers of the thyro-arytenoid or the aryteno-epiglottic muscles. The action of the arytenoid muscle is to bring the bases of the arytenoid cartilages together, thus completing the closure of the chink of the glottis. Contraction of the lateral crico-arytenoids alone leaves a small triangular opening between the cords at the interarytenoid space. This opening is closed by the contraction of the arytenoid muscle (Figs. 540 and 541). The *thyro-arytenoid* muscles lie parallel to and slightly below the vocal cords along either side of the larynx (Fig. 540). The muscles arise, one from either side of the receding angle of the thyroid cartilage, to the outer side of the insertions of the vocal cords. Passing outward and backward the fibers are inserted into the bases and anterior surfaces of the arytenoid cartilages and into the external surfaces of the vocal processes (see Fig. 542). Each thyro-arytenoid muscle is divided into two quite distinct portions, internal and external. The internal portion follows the vocal cord closely, some of its fibers, indeed, appearing to pass into the structure of the cord. The external portion passes backward along the outer side of the sacculus laryngis, and has a broad attachment to the external surface and outer side of the arytenoid cartilage. With point of fixation at the receding angle of the thyroid cartilage, the thyro-arytenoid muscles draw the arytenoid cartilages forward. The vocal cords are thus shortened and relaxed. The internal portion of this muscle, however, has an apparently contradictory action, for, by its attachment to the vocal cords, its contractions approximate the free margins of the cords and regulate their tension. This function is of importance in the production of the high notes in the singing voice. The external portion of the muscle, besides its action in shortening the cords, has also the power of compressing the sacculus laryngis. A superior thyro-arytenoid muscle is sometimes described (Santorini, Luschka, Schrötter), which is viewed by some authorities as a distinct muscle. Its origin is from the receding angle of the thyroid cartilage, immediately above the origin of the thyro-arytenoid muscle. It is attached to the muscular process of the arytenoid cartilage, some fibers passing downward to the cricoid cartilage or to the crico-thyroid membrane. It is quite probable that these muscular fibers, instead of forming a distinct muscle, constitute a series of oblique fibers which are, in reality, a part of the complex thyro-arytenoid muscle.

The *crico-thyroid muscle* arises from the anterior and lateral portions of the cricoid cartilages (see Fig. 540, 9). The fibers divide into two bundles, the more anterior pass directly upward and slightly backward and are inserted into the inner portion of the lower margin of the thyroid cartilage. The more posterior fibers pass upward and backward and are attached to the thyroid cartilage at the base of the inferior cornu. The action of this muscle is to render the vocal cords tense by increasing their length, either by



drawing the thyroid cartilage downward toward the cricoid, thus stretching the vocal cords and increasing their tension, or, with the thyroid cartilage as the fixed point, to draw the cricoid cartilage upward and backward, which movement, it is claimed by the advocates of this method, will elongate and increase the tension of the vocal cords. The action of this muscle is a question which is still in dispute, and we feel that it has not yet been definitely decided.

**Blood-supply of the Larynx.**—The arterial supply of the larynx comes by the superior and inferior thyroid arteries.

The *superior thyroid* is a branch of the external carotid. It divides before entering the larynx into two branches, the superior laryngeal and the inferior laryngeal, the latter called also the crico-thyroid artery.

The *inferior thyroid artery*, one of the branches of the thyroid axis, supplies the muscles and mucous membrane of the posterior part of the larynx by means of its laryngeal branch, or posterior laryngeal artery.

**Veins.**—The laryngeal veins correspond in their courses to those of the arteries. They unite into three veins, the superior, middle, and inferior thyroid veins, which in turn enter the internal jugular vein.

**Lymphatics.**—The lymphatic vessels of the larynx collect from a thick network of vessels in the laryngeal mucous membrane into two trunks, one above the ventricle of the larynx and one below the cricoid cartilage. These trunks empty into the deep cervical lymphatic glands.

**Nerves of the Larynx.**—The larynx derives its nerve-supply from the pneumogastric nerve. The superior laryngeal branch of this nerve is the general nerve of sensation for the mucous membrane of the larynx, and is the motor nerve for the crico-thyroid muscle and for the arytenoid muscle, the latter being supplied also by the recurrent laryngeal nerve.

The recurrent laryngeal nerve is the general motor nerve of the larynx.

The *superior laryngeal nerve* arises in the inferior ganglion of the pneumogastric. It passes downward along the sides of the pharynx to the superior margin of the thyroid cartilage. Here it divides into an external and an internal branch. The external branch of the superior laryngeal nerve passes downward beneath the sterno-cleido-mastoid muscle to supply the crico-thyroid muscle. The internal branch pierces the thyro-hyoid membrane and supplies all the mucous membrane of the interior of the larynx, as well as the base of the tongue, with sensory filaments. It sends filaments to the arytenoid muscle, and anastomoses with the recurrent laryngeal nerve.

The *recurrent laryngeal nerve*, sometimes named the inferior laryngeal nerve, is also a branch of the pneumogastric. On the right side of the body this nerve leaves the pneumogastric at about the level and in front of the right subclavian artery. Passing around this artery from before backward it ascends to the side of the trachea, posterior to the common carotid and inferior thyroid arteries. In winding about the subclavian artery the recurrent laryngeal nerve on the right side comes in very near relation to the apex of the right lung.

On the left side of the body the recurrent laryngeal nerve leaves the pneumogastric in front of the arch of the aorta. It passes around the aortic arch from before backward at the side of the ductus arteriosus, and passes upward to the side of the trachea. Both right and left recurrent laryngeal nerves pass upward in the groove between the trachea and esophagus. They pass beneath the lower border of the inferior constrictor muscles of the pharynx, gaining entrance to the larynx just posterior to the articulation between the inferior cornua of the thyroid cartilage and the cricoid cartilage.



They supply all the muscles of the larynx with motor filaments, with the exception of the crico-thyroid muscle. There is anastomosis between the recurrent laryngeal and superior laryngeal nerves.

The relations of the recurrent laryngeal nerve—on the right side with the apex of the lung and with the subclavian artery; on the left side with the arch of the aorta—are of great clinical importance, as paralyzes of the laryngeal muscles may result from pressure against the recurrent laryngeal nerve by aneurysm of the vessels named, at the point of passage of the nerve around them, or, on the right side, by irritation from the inflammatory conditions in the apex of the right lung. The motor fibers of the recurrent laryngeal nerve are supposed to be derived from the spinal accessory nerve. Russell of London<sup>1</sup> has investigated the nerve-supply of the abducting and adducting muscles of the larynx and feels warranted in “the conclusion that the muscles closing and opening the glottis are respectively supplied by different bundles of nerve-fibers, preserving an independent course from center to periphery, the abductors being situated on the tracheal side and the adductors on the external side of the nerve.” This theory still requires more general observation, as does also that of Onodi, quoted by Bosworth, that the laryngeal muscles receive a supply of motor fibers from the spinal cord, by way of the spinal ganglia of the sympathetic system, extending as low as the lower cervical and first dorsal spinal ganglia, the course of the fibers being direct from the spinal cord to the first thoracic ganglion; then through the communicating branch between this ganglion and the last cervical ganglion; and from this latter directly to the recurrent laryngeal nerve. The advantage of having a double motor nerve-supply for the muscles of the larynx is quite obvious.

**The Mucous Membrane of the Larynx.**—The laryngeal mucous membrane is continuous with the lining membrane of the pharynx and trachea. Its epithelial covering is generally of the squamous variety. Over the lower or posterior surface of the epiglottis it is columnar and ciliated. This is also true of the mucous membrane extending below the ventricular bands, which is continuous with and corresponds to that of the trachea. The vocal cords, however, are covered with squamous epithelium. The mucous membrane is rather loosely attached to the submucosa over the anterior surface of the epiglottis, on the posterior surface of the arytenoids, on the aryteno-epiglottic folds, and in the ventricle of the larynx. This fact accounts for the rapid development of edema of these parts in very severe inflammatory processes.

The larynx contains an abundant amount of lymphoid tissue, especially at the border of the epiglottis and in the aryteno-epiglottic folds, the arytenoids, the interarytenoid space, and the ventricles of the larynx.

**The Trachea.**—The trachea extends from the lower margin of the cricoid cartilage to the bronchial tubes, a distance in the adult of about four and one-half inches. It is a cylindrical tube flattened posteriorly where it lies in contact with the esophagus. It is a membranous tube partially surrounded by incomplete rings of cartilage. It extends from the fifth cervical to the third dorsal vertebra, where it divides into the two bronchi. Its transverse diameter varies from three-fourths of an inch to an inch. Internally it is lined with mucous membrane covered with columnar ciliated epithelium and richly supplied with lymphoid tissue and mucous glands.

The trachea is surrounded and partly covered by important structures. The common carotid and inferior thyroid arteries lie on either side of it, together with the recurrent laryngeal nerve. Crossing it on a level with the

<sup>1</sup> *Brit. Med. Journ.*, June 18, 1892; *Annual of the Univ. Med. Sciences*, vol. xiv. P. 3, 1893.

second and third tracheal rings lies the isthmus of the thyroid gland in a sheath formed by two layers of the deep cervical fascia. The lobes of the thyroid gland lie on either side of the trachea and larynx from the isthmus to the thyroid cartilage. Below the isthmus and immediately over the trachea is a network of veins, the intrathyroid plexus.

On either side of the trachea, in the superficial fascia of the neck, lie the two anterior jugular veins, at about two-fifths of an inch from the median line. These veins communicate by a transverse trunk which crosses in front of the trachea immediately above the sternum. Of the arteries, the crico-thyroid must be recalled crossing the crico-thyroid membrane. An anomalous vessel, the *arteria thyroidea ima*, is found in rather rare instances running up the front of the trachea from the arch of the aorta. The innominate artery, crossing the trachea at the level of the episternal notch, sometimes crosses higher up within the field of a low operation for tracheotomy. In very rare instances both common carotids spring from the innominate artery. In such cases the left common carotid crosses in front of the trachea to reach the left side of the neck. In all operations for tracheotomy the relation of the trachea to these important structures lying about it, and this possible anomalies, must be borne in mind.

---

## THE CLINICAL ANATOMY OF THE NASAL CHAMBERS.<sup>1</sup>

BY HARRISON ALLEN, M. D.

Correct impressions of the localities in which morbid processes occur in the nasal chambers, as well as the means resorted to for their relief, demand, to a degree perhaps greater than in other parts of the economy, an intimate acquaintance with the structure and relations of the component parts.

The peripheral olfactory apparatus must be conceived as a special membrane covering the nasal aspects of the lateral masses (Figs. 543, 545), these uniting with the cribriform plate and the perpendicular plate to form the ethmoid bone. Each lateral mass is comparable to the eyeball or to the petrous portion of the temporal bone, in the meaning of the term that it is devised to protect an organ of special sense. The conditions under which the act of smelling is efficient demand the act of breathing to be also efficient: hence, each lateral mass is a part of a system of bones which is in free communication with the outer air. The bones are named as follows: the vomer, the ethmoid bone, the sphenoid bone, the nasal bones, the superior maxille, the palatal, the inferior turbinated, and the lacrymal bones.

The ethmoid bone, the vomer, and the sphenoid bone belong to the brain case, since they are developed with those structures which enter into the composition of the base of the skull. The nasal bones and the incisorial intermaxillary portions of the superior maxille are developed in pairs from the fronto-nasal process of the embryo. The remaining parts also arise in pairs, but at the sides of the skull, and (excepting the lacrymal) extend inward to join the median structures. All of these, with the exception of the ethmoid and inferior turbinated bones, have relations distinct from those pertaining to the nasal chamber. The communication of the nasal chamber with the ethmoid cells, the frontal, the maxillary, and the sphenoid

<sup>1</sup> Through the untimely death of the author, this section failed to receive his final revision and personal choice of illustrations [Ed.].

sinuses add greatly to the intricacy of the region. The os planum is often perforated at more than one point in advanced disease of the ethmoid cells, as is the floor of the orbit in disease of the maxillary sinuses. While both of these systems are accessory to the nasal chambers (Fig. 548), their clinical relations therewith are important.

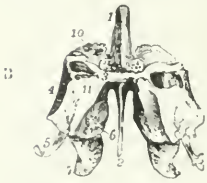
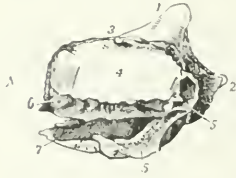

FIG. 513.—Back and side view of the ethmoid bone, showing in B the lateral masses on either side of the vertical septal plate (2), with which they are united by the cribriform plate (3) at the base of the crista (1). Between the nasal meatus and the orbital plate (4) are the cells, the closure of many completed by the frontal and other bones articulating with the ethmoid and projecting downward are the superior (6) and middle (7) turbinates and the uncinate process (5) (Allen).

The nasal chamber is conveniently divided into three parts by planes, the initial lines of which are started at the transverse sutures of the floor.

The anterior part lies in front of the maxillo-premaxillary suture: the vertical transverse section defining it will answer to the interior (vestibule) of the external nose (nearly).

The middle part lies between the maxillo-premaxillary suture and the maxillo-palatal suture: the plane defining it, beginning in front at the *ductus ad nasum*, will embrace the lateral mass of the ethmoid bone (nearly).

The third part lies back of the maxillo-palatal suture and includes the vertical plate of the palatal bone with the end of the middle turbinal: the plane defining it is sharply limited by the anterior border of the vertical plate of the palatal bone. The third part is continuous with the internal pterygoid plate in the meso-ptyergoid fossa.

It may be observed that the inferior turbinated bone has no morphological value and is ignored in the definitions of the planes.

The variations in the nasal chamber are numerous, and it is not assumed here that the regions above named are uniform. They are available, however, since they are based on function and are true in the great majority of examples of crania. Among the exceptions to some statements may be mentioned the following: the floor of the nose in advance of the maxillo-premaxillary suture is sometimes so shortened as to yield a plane which would not contain all or nearly all the interior of the external nose. The middle turbinated bone sometimes projects forward beyond the line of the *ductus ad nasum* into the anterior third.

The anterior third is in reality a canal of entrance to the olfactory surfaces, and the posterior third is in a less exact sense a canal-like passage of exit. The part last named is the same at different periods of life and in all animals; while that of the anterior passage is exceedingly variable, both in ages of the individual and in groups of animals.

Each nasal chamber is bounded by the roof, the floor, the outer, and the inner, or septal, walls.

**The Roof.**—The roof of the nasal chamber is confined to the under-surfaces of the nasal bones in advance of the frontal, a small, unimportant, and variable surface of the bone last named; the cribriform plate of the ethmoid bone; and, at the extreme posterior part, a portion of the body of the sphenoid bone. The cribriform plate is an exceedingly vulnerable part of the roof. Many examples are on record of wounds penetrating it; and its position at the top of the cleft, between the septum and the middle turbinated bone, as the parts are seen when inspected by the anterior rhinoscopy, must be borne in mind in all intranasal procedures.

**The Floor.**—The floor of the nasal chamber on either side of the incisor crest is elevated in proportion as the crest itself is developed (Fig. 546); when

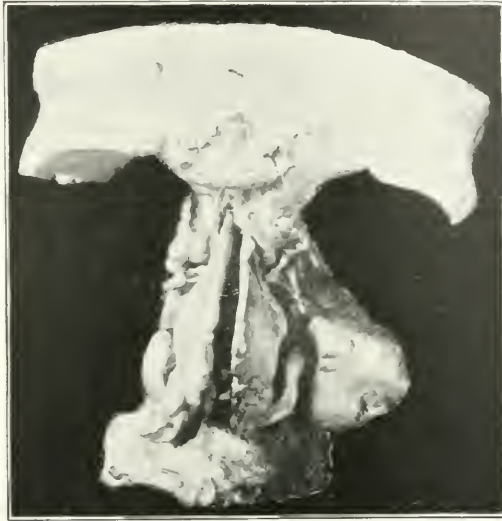

FIG. 544.—Metal cast of the upper air-passages and oral cavity, showing the maxillary sinus on the right, asymmetrical frontal sinuses above, with the delicate infundibulum and the anterior ethmoid cells. (Randall).

the crest is absent, or of moderate proportion, the floor of the vestibule is on the same level as that of the horizontal plate of the maxilla. On the whole, it is disposed to incline downward slightly from before backward. An abrupt fall or “break” in the inclination is sometimes demonstrated at the

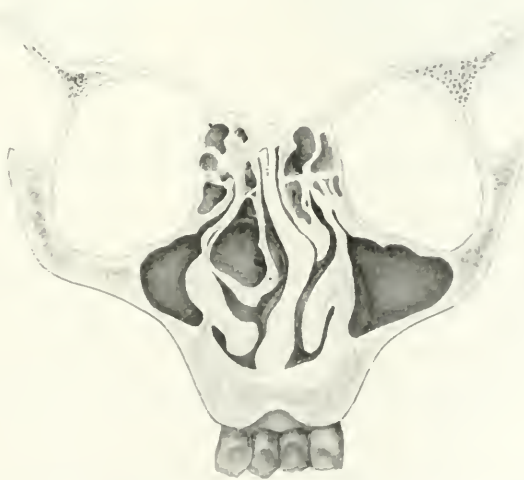


FIG. 545.—Transverse section of the nasal chambers, showing marked asymmetry, the bulbous left middle turbinate bone apparently deflecting the septum to the right and narrowing the maxillary sinus (from Zuckerkandl).

point where the incisorial portion of the floor ends and the maxillary portion begins (Fig. 546). It is of importance to detect the change of level, for secretions may accumulate in the angle and by undergoing decomposition resist



efforts to correct the causes of fetor. The mucous membrane in the recess may be ulcerated and the lesion escape observation. Straight plugs, tubes, or cannule cannot be carried conveniently to the floor of the passage at a level below that of the incisorial portion.

**The Outer Wall.**—The outer wall of the nasal chamber embraces the superior, middle, and inferior turbinated bones and the unciniate process. On the lateral mass of the ethmoid bone is defined the superior meatus; between the middle and the inferior turbinated bone is the middle meatus; and between the inferior turbinated bone and the floor of the nose the inferior meatus.

**The Middle Turbinated Bone.**—The middle turbinated bone, while understood to be but a process of the ethmoid bone, is clinically defined as though it were a separate element. It presents many variations, and their study becomes a matter of the first importance. The bone, as seen foreshortened in the living subject, relates less to the outer wall of the nose than is described in the manuals of anatomy. It might be compared to a stalactite

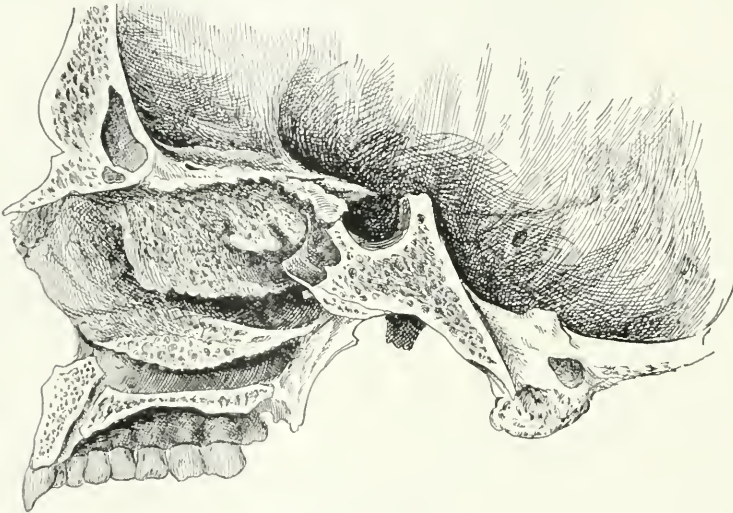


FIG. 546.—Sagittal section of the skull, showing the bony outer wall of the nasal chambers, with the turbinated bones and the rise of the floor in front at the incisorial foramen.

hanging near the roof of an irregular cavern. It may be laminar, without increased width of the free lower border, which is variously deflected; it may have a moderate amount of inflation and appear in sections pyriform in outline, thus constituting perhaps the average condition; or, as is often found in females, it may be enormously inflated so as to exhibit in sections a veritable globose contour (Fig. 545). Infrequently the inflation is not confined to the pendant portion, but extends into the anterior portion of the pedicle as well, where it may even involve the adjoining ascending process of the maxilla.

The size of the middle turbinate varies, quite apart from its shape. As a rule, the bone answers to the lower limit of the perpendicular plate of the ethmoid bone where it joins the vomer; while it rarely extends below this line, it often falls short of it. One of the most interesting variations in the ethmoid bone arises from the arrest of development after an attack of scarlet fever. The lateral mass remains stunted and is lodged high up in the chamber. When otitis persists, as is often the case, the proximity of these masses

to the cribriform plate should lead the practitioner to conduct all local treatment with due care. It is quite true that small ethmoid bones are sometimes examples of arrest of development from fundamental causes, and probably in some degree correlated with defects in the normal rate of evolution of the brain. For we must not overlook the harmony known to exist between the size of the olfactory surfaces, at least of the ethmoid bone, and the functions they subserve in extending the distribution of the special nerves over a peripheral organ.

The middle turbinate is composed of a straight or globose anterior part and a deeply concave posterior part, the concavity being directed outward. The concave part (conch) can be explored from in front and subjected to treatment, for it is often the seat of retained secretion and granulation-tissue. The median and anterior surfaces of the bone are less coarsely marked than is the inferior turbinate, although it may be provided anteriorly with numbers of small spicules. In the infant the anterior end is always thin, compressed, and parallel to the perpendicular plate, although the free lower end is deflected either inward or outward, more commonly in the direction first named. In all ages the bone inclines downward and backward to a degree greater than is seen in the inferior turbinate (see Fig. 546).

**The Inferior Turbinate Bone.**—The inferior turbinated bone is attached to the maxilla and palate-bone so as to form a bond of union between these structures. It extends the length of the nasal chamber—the extreme front border just back of the anterior nasal aperture being in some examples free. The bone is marked by numerous coarse depressions, grooves, and rugosities. It is concave on its outer surface and convex or straight on its inner. Seen in the living subject the anterior end presents a rounded, almost cherry-shaped mass, often with scarcely a suggestion of the position of the inferior meatus, although this region can be carefully outlined by the aid of the probe; the inner (median) surface of this part of the inferior turbinated bone is, as a rule, sharply convex and, indeed, is the most rounded of any part of the surface. Not infrequently it or its covering forms in diseased states septal apposition, if not actually false union or synechia. In my opinion the disturbing factor in the formation of this union is not septal but turbinal, and the reduction of the turbinal is of greater use than the disturbance of the septum. Directly back of the point of septal apposition the convexity of the bone in great part disappears. The inferior turbinate is often of considerable height—a variation never seen in like degree in cabinet crania. In cleft palate the free inferior border tends to grow down to a deeper plane than is normal.

**The Middle Meatus and the Uncinate Process.**—Above the middle turbinated bone lies the middle meatus, sharply defined both from in front and behind. The most conspicuous structure seen in the skull in this region is the uncinatè process of the ethmoid bone. Usually this process lies parallel to the anterior part of the lateral mass, but it often projects at right angles to the plane of these cells, from which in the living subject it is often difficult to separate it. The process may be mistaken for the middle turbinate. In text-books the usual account of the process is to state that it narrows the opening from the maxillary sinus into the middle meatus. This it certainly does; but its more important clinical connection is to the cells with which indeed it is in true morphological relation. In some instances the process is deeply concave on its anterior surface, and its median border is turned sharply forward. When the lateral masses are moderately developed the process makes no impression upon the eye in the living subject, and is imper-

fectly discerned even in the skull; but when the process is at right angles to the outer wall the anterior ethmoid cells (Fig. 547) are always large, and as a rule, constitute a single, rounded, cherry-like mass (*bullæ ethmoidalis*). Thus, when the right-angled position of the process is detected, the observer may conclude that the enlarged cells lie directly behind it. It is the relation existing between the uncinate process and the anterior ethmoidal cells and the ascending process of the maxilla that makes this part of the nasal chamber of importance in studying the relations existing between lachrymal and nasal disease. Directly within the middle meatus is sometimes seen the opening into the maxillary sinus, and within the inferior meatus that of the lachrymal canal.

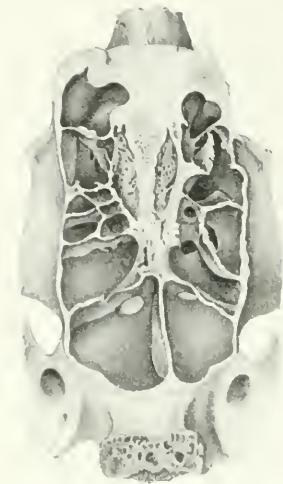

FIG. 547.—Horizontal section passing above the cribriform plates and showing the ethmoid, sphenoid, and frontal sinuses with their openings toward the nares (*Zuckerkanal*).

**The Inner, or Septal Wall.**—The word “septum” implies that the two chambers are being studied together and that the septum is a partition. In this essay the septum is assumed in the main to yield the inner wall of each chamber (Fig. 544). The septum is composed of a bony and a cartilaginous part. The anterior third (about) of the bony septum is notched; the upper border of the notch is defined by the perpendicular plate of the ethmoid bone, the lower border of the vomer and incisor crest of the maxilla. The notch is occupied by the triangular cartilage, which appears to be unfortunately named—according to the studies of Freeman, it is of a quadrilateral figure. The bony inner wall of the nasal chamber is composed of the perpendicular plate of the ethmoid bone, the vomer in front of its alæ, the incisor crest, the anterior nasal spine, and that much of the horizontal plate of the superior maxilla which ascends to form a crest. The incisor crest, the spine, and the process last named differ from the perpendicular plate and the vomer in being composed of symmetrical parts, and, in common with all such structures, present variations according to the manner in which the right and left constituents unite. This statement is particularly applicable to the incisor crest and the nasal spine, which present innumerable variations—no two specimens being alike. The nasal spine is developed before the crest, and is not simply the anterior end of this elevation, as is usually stated. The crest is always rudimentary in young subjects, and, indeed, is often absent, although the spine may be prominent. Although divided into right and left parts in adults, not infrequently the crest remains in its juvenile condition throughout life. As a rule, it is well developed and has a disposition not to extend backward beyond the incisive foramen. The vomer, passing forward as a single straight plate deeply grooved for the accommodation of the triangular cartilage, will have its relation to the crest undisturbed so long as the structure last named is of moderate development; but if it be more than usually high the union is not harmonious. Hence arises the thickening of the septum at this place and the disposition to deflection either to the right or left—in most cases the latter. The height of the incisor crest is often so great as to cause the septum to be myielding in the region answering to the height of the inferior turbinated bone. If a high crest is also carried well to the outer wall of the nose it creates an exceedingly narrow passage within the vestibule.



The perpendicular plate of the ethmoid bone may project forward beyond the maxillæ and downward so far as greatly to narrow the size of the septal notch. It may constitute, when malplaced, an important factor in nasal obstruction. The prognosis should always be guarded when the plate is so disposed.

Sharply defined projections from the septum are called "spurs." As a rule, they are ledges of varying degrees of development. The most common of the "spurs" is on the upper vomerine border, either where it forms the lower boundary of the triangular notch, or where it is joined by the perpendicular plate of the ethmoid bone. But a spur is often found high up and back on the septum, and may occupy in great part the middle meatus.

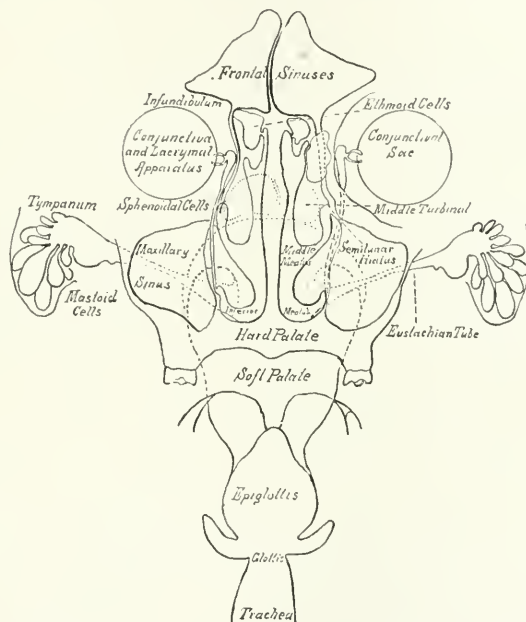


FIG. 548.—Scheme of upper air-passages based upon metal corrosion casts.

**Asymmetry** of the nasal chambers is generally acquired and is often the result of injury. Errors in growth and development may arise, however, in the nasal chambers as elsewhere in the economy. Asymmetries of the group last named are in great measure products of civilization. Ethnological cabinets furnish material for study less valuable than that obtained from the dissecting room or observed in our patients. Inflammatory or other obstructive conditions, even when temporary in character, may cause narrowing of the passages. Whatever may be the etiology of these confessedly obscure variations, the fact remains that one chamber, commonly the left, is the smaller, and that the septum inclines away more or less from the median line. A summary of the above statement is here given: Deviation of the septum from a straight line is associated with a high incisor crest; and when this is well established, the vomer tending to grow forward when there is no space in front to permit it so to do, it is deflected from the straight line; or if it enters into the compass of the triangular notch, it is itself abruptly turned to the left.

Far back in the nasal chamber, at a place answering to the union between the perpendicular plate of the ethmoid and the vomer, an irregular ridge can



often be felt in making digital examinations. The ridge is more common on the left than on the right side, and is of varying degrees of hardness. Often it can be pressed away by the finger; but more commonly it will not yield unless sawed or drilled.

The degree of consistence of the septum and turbinated bones is subject to variation. The former may be thin and porous or thick and eburnated. No sign is accepted by which the state of the bone can be determined by inspection. Large bones projecting well into the chambers may yield to slight interference, while small bones may be exceedingly resistant. The application of these facts to practice are of importance. A thin, yielding septum may be the cause of failure in attempting to arrest hemorrhage by plugging the chambers. A marked deviation can sometimes be corrected by the finger to almost the degree desired; while if the parts be thick and firm nothing will yield until they are attacked vigorously by the aid of instruments.

**The Nasal Apertures.**—The apertures of each nasal chamber are two in number, the anterior and the posterior. The anterior is the nostril and the posterior is the choana. The nasal chamber is examined by reflected light thrown through the nostril, or by a mirror carried into the naso-pharynx, which reflects the view as seen at the choanæ. When the skull is examined, the anterior nasal aperture takes the place of both the nostrils; and the mid-region of the base of the skull, of the naso-pharynx. If it is accepted that the nostril is an aperture, the term cannot be used as a synonym for "nasal chamber," as is sometimes done by clinical writers. The term "naris" is discarded.

The *anterior nasal aperture* is defined by the maxilla and the nasal bones, and is exceedingly variable when a series of all races of men is examined. But in clinical studies—excluding those conducted on the negro—the opening is pyriform, with the base of the figure downward, and presents two trenchant asymmetrical borders which are raised above the level of the floor of the nose. The entire figure has been compared to the heart on the playing card. Welcker happily likens it to the figure of the European elm (*Ulmus montanus*), from the fact that the lower border of one of the chambers (commonly the left) is below the level of the other. The conjoined incisor crests of the maxillæ often appear at the aperture. The perpendicular plate of the ethmoid bone, infrequently here seen, may even project beyond its plane, thus in reality converting the anterior nasal aperture into two apertures.

The *choana*, or *posterior nasal aperture*, is bounded inferiorly by the posterior margin of the palatal bone. The lateral margin answers to the anterior border of the internal pterygoid plate. It would be difficult to define the upper margin were it not for the presence of a group of minute bone-spicules which receive no name in anatomy, so far as I am aware, which, nevertheless, are exceedingly useful in defining the plane of each choana. The inner margin is the septum, but this is not a reliable guide to the base of the choana, since the posterior margin of the vomer often lies well forward on the crest between the palate-bones. I have called this phase of the nasal septum "recedent," to distinguish it from that form where the base comes sharply up to the base of the posterior nasal spine. In subjects that exhibit the recedent form, the vomer will allow the posterior ends of the inferior turbinals to approach, although they do not touch—the mucous membrane over both bones remaining normal. Care should be taken in such conditions not to confound these masses with hypertrophy of the posterior ends of the turbinal bodies.

The region of the choanæ, after all is said, is not of importance. In

practice the choanae in reality include the *meso-ptyergoid fossa*, or, as I have ventured to call it, the *posterula*, or back porch to the nasal chamber. This is a single region into which the choanae debouch. It contains the ale of the vomer and all of the inner surface of the internal pterygoid plates. The finger introduced into the naso-pharynx is received into the posterula, and the pterygoid surfaces are clearly defined at the sides. In rare instances these may be thickened, retaining the infantile form, and may aid other conditions in tending to reduce beyond normal limits the posterior apertures of the chambers.

**The Nasal Mucous Membrane and its Blood-vessels.**—The mucous membrane lining the nasal chambers is of three kinds: first, the olfactory membrane, which is limited (nearly) to the ethmoid bone on the inner aspect of each lateral mass and the opposed surfaces of the perpendicular plate; second, the highly vasular and partially erectile structures (turbinal bodies) covering the inferior turbinated bones; third, the generalized membranes which line the other bones and the walls of the accessory sinuses.

The property of cocain in constricting small blood-vessels is used with advantage in studying the anatomy of the nasal chambers in the living subject. The contrast in the shapes of the inferior turbinal body before and after an application of a 10 per cent. solution of cocain is such as to give the observer an accurate impression of the extent of the erectile mucous membrane covering it. The cushion surfaces of the bodies with contour convex before the cocain is applied disappear, and in their places are noted a membrane bound down to the bone, to whose irregularity it conforms. We speak of a turbinated bone and a turbinal body—the latter phrase to express the

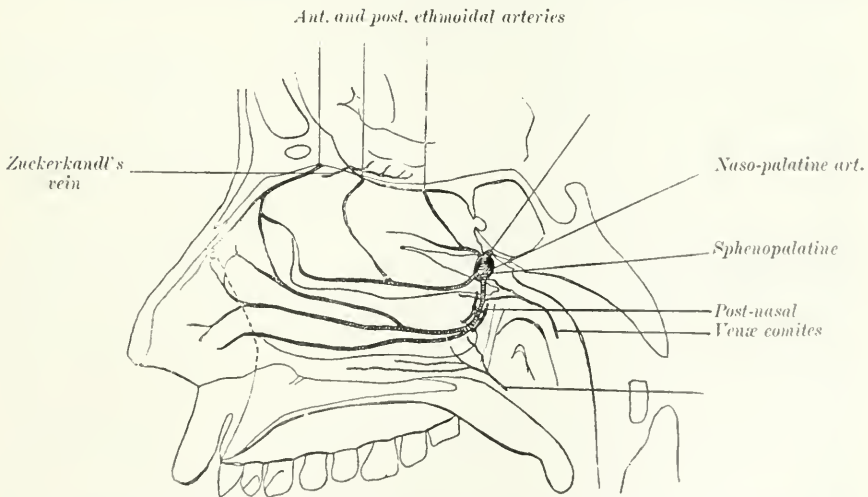


FIG. 549.—Vessels of the lateral wall of the nose, showing direct cerebral communication through Zuckerkandl's vein (Zarniko).

fact that the body is an erectile membrane which has a shape in a measure distinct from the skeletal surfaces with which it is closely incorporated.

As a rule, incisions into the turbinal body are followed by moderate bleeding, which ceases spontaneously. Occasionally wounds over the middle turbinal bleed more freely, which in order to staunch require interference by pressure or use of astringents. The mucous membrane on the outer wall and in the sinuses is uniformly indisposed to bleed so as to demand interfer-

ence. It is far different with the septum. Here the cartilaginous portion, where it joins the incisor crest, is exceptionally vascular. A caruncular swelling is often found at this point, which should be carefully avoided in making incisions for minor surgical procedures. A second point from which hemorrhage is apt to occur is over the triangular cartilage itself. This is never from an incision, but is commonly from abrasions, and is therefore the region from which blood often springs in non-surgical epistaxis. The seat of hemorrhage is found at a point just beyond the tip of the triangular notch. Hemorrhage occurring from wounds reaching the submucous tissues is far different from the foregoing. Two distinct locations are here noted—namely, the septum along the line of the vomer at any part, which answers to the positions of the deep septal blood-vessels; and the posterior third of the outer wall, where it receives the arteries and veins which pass through the sphenopalatine foramen (Fig. 549).

The bones of the nasal chamber are remarkable for being in whole or in part covered with mucous membrane, and are supplied largely with its blood-vessels. The muco-periosteum is a valuable term in describing such a membrane, for it fixes the mind upon the analogy between such a membrane and the periosteum. If the comparison between the two membranes is precise, then the study of the nasal chambers as part of the great skeletal group of bones, being as exact in pathology as in anatomy, relegates many of the morbid conditions of the chamber to phases of periosteitis and osteitis.

**The Nerves.**—The nerves that must be recalled in surgical treatment of the nasal chamber are unimportant. The operations on the nasal septum will sometimes cause numbness of the incisor and canine teeth to be complained of for a few days after operation.

**Asymmetry and Narrowing of the Nasal Chambers.**—It has been stated on page 831 that the nasal chambers are often asymmetrical—the asymmetry being caused by deviation of the nasal septum, usually to the left side, and that such deviation is acquired either as a direct result of traumatism or of disease. The chambers, however, may be unequal in size, even when the septum remains straight. Such a relation is due to fundamental causes, and will be found, like all these conditions, to correlate with other peculiarities in the economy. An important element in prognosis is here to be considered, for a congenitally narrowed or occluded chamber can never be made entirely efficient. Sometimes the posterior portion only of the chamber exhibits asymmetry. This is due to a defect in the development of the sphenoid bone, the body of which does not normally expand; thus the pterygoid processes are kept too close together, the palatal bones, as well, remain in an infantile condition, and in time the choanae are even inadequate for the accommodation of the posterior ends of the turbinals. If an operation be proposed for deviation of the septum or other causes of obstruction in the anterior portion of a chamber of a subject where the posterior portion remains undeveloped, a statement of the results to be expected should be guarded, since the narrowing at the choanae and posternula may in itself maintain obstruction. In these cases the choanae are always small and oval; the internal pterygoid processes are convex, and the turbinals are thick and pressed together against the septum. Cases have been observed characterized by retention of all these parts in an embryonic condition, with resultant atresia. Even when the choanal plane is normal, narrowing may occur at the posterior third of the chamber; thus converting each posterior portion into a passage, which might be compared to a funnel laid on its side and with its neck directed forward.

# PHYSIOLOGY OF THE UPPER AIR-PASSAGES.

BY WALTER J. FREEMAN, M. D.,  
OF PHILADELPHIA.

THE study of the physiology of the nose, throat, and larynx is of the greatest practical importance, for it is only by an intimate knowledge of their functions in health that we are able correctly to appreciate the significance of pathological conditions. At times, indeed, when insurmountable difficulties prevent thorough physical examination, we must fall back upon our knowledge of the normal functions of the parts, such as breathing, swallowing, phonation, etc., to obtain a correct diagnosis.

## NOSE.

The old idea of the nose as simply an organ of olfaction has given place to an appreciation of the influence it exerts upon the whole economy, not only by its vital functions of warming, moistening, and filtering the inspired air, but also by its acting as a protective organ to prevent the admission of harmful substances in inhalation.

**Functions of the Nose.**—*Respiration.*—(1) Passage-way for air in breathing; (2) warming, moistening, and filtering the inspired air.

*Olfaction.*—(1) Perception of odors in inspiration; (2) perception of flavors in expiration.

*Phonation.*—(1) Resonance; (2) production of overtones.

*Protection.*—(1) By sensation; (2) by olfaction.

*Ventilation.*—(1) Of the ears; (2) of the accessory sinuses.

**Respiration.**—(1) We notice from the dryness of the throat in mouth-breathing that this is not the passage-way intended by nature for the air in inspiration, and we realize that normal respiration should take place through the nose, and that mouth-breathing is a pathological condition giving rise to many injurious results.

Paulsen has proved that the air in respiration takes a very different course from that formerly supposed to be the case.

Instead of flowing back along the inferior meatus, the air passes directly upward from the nostril to the superior meatus, whence it falls by a gentle curve toward the choana.<sup>1</sup> This shows the old arbitrary division of the nose into a lower respiratory and an upper olfactory portion to be, physiologically at least, incorrect. It seems curious that the inferior meatus should thus be avoided by the inspiratory currents, for the inferior turbinals contain the largest amount of vascular tissue. It must be remembered, however, that nowhere in the nose is the air at rest, and as the air in the inferior meatus is

<sup>1</sup> One can readily be convinced that the stated course of the air is the true one by examining the nose of a person who has inhaled finely divided magnesium. The powder will be found adhering to the anterior end of the middle turbinal and as far up the olfactory cleft as one can see, while the inferior meatus and turbinal remain almost entirely free (Fig. 551). Hence the common appearance of dust and crusts on the anterior ends of the middle turbinals.



more sluggish, it has received more heat, and when drawn into the current

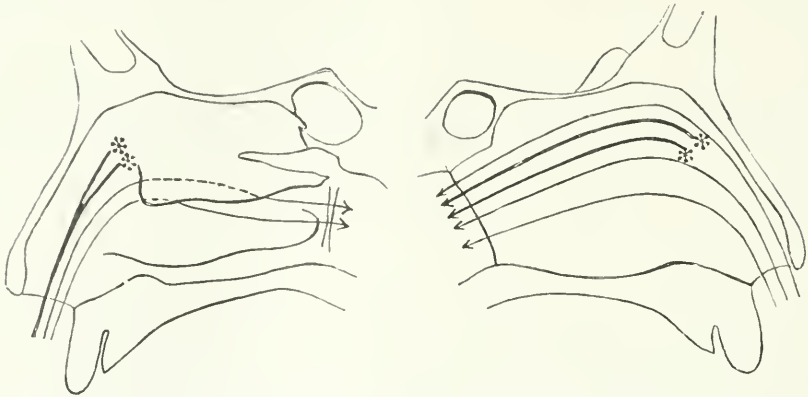


FIG. 550.—Diagram showing the course of principal and auxiliary currents of air in normal respiration.<sup>1</sup>

raises its temperature more quickly.<sup>2</sup> The main currents of air pass into the naso-pharynx at the highest portion of the choanal arches, and an enlargement of the pharyngeal tonsil, encroaching even slightly upon these openings, impedes respiration much more than does swelling of the ends of the inferior turbinals, blocking to a marked degree the lower portion of the choane (compare Fig. 560).

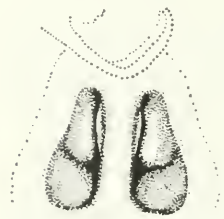

FIG. 551.—Anterior nares, showing white deposit of inspired magnesium-powder upon the septum and middle turbinals only.

The course of the air in expiration is nearly the same as in inspiration, except that it is directed higher up—*i. e.*, through the posterior part of the superior meatus, a point that we shall soon see is of importance in detecting flavors.

(2) Within the nose the shelf-like arrangement of the turbinated bones gives increased extent of surface to the vascular membrane with which they are covered. The interior of the nose is completely lined with mucous membrane, that covering the inferior turbinals, the lower portion of the middle, and the posterior ends of the middle and superior turbinals, containing vast systems of blood-vessels, which are the chief source of the heat and moisture supplied to the air in inspiration. These blood-sinuses are surrounded by involuntary muscular fibers, and, although they are commonly so called, they are not, correctly speaking, true erectile bodies, which consist of large irregular spaces lined with pavement epithelium. This muscular tissue is under the control of the sympathetic system, which reaches the interior of the nose by way of the sphenopalatine ganglion, and derives its influence from the cerebro-spinal system. It is known that there are vaso-dilators as well as vaso-constrictors, and their centers probably lie in the floor of the fourth ventricle.<sup>3</sup> The dilatation and contraction of the sinuses caused by these nerves are constantly going on, and are physiological actions of great importance. The object is the regulation of the amount of blood in the turbinals, and hence the proper warming and moistening of the inspired air. The mechanism is, indeed, a delicate one which is able to supply the requisite amount of heat

<sup>1</sup> Zarniko: *Die Krankheiten der Nase*, etc., p. 38. Later observers have not only confirmed this, but have found that the air takes a still higher course.

<sup>2</sup> Zarniko, p. 40.

<sup>3</sup> Chapman: *Human Physiology*, p. 732.

and moisture under all the varying changes of temperature and humidity to which animal life is subjected. Thus we notice that when the temperature is cold, the turbinals swell and the passages become more closed. This indicates that the vascular tissue has become filled, and that a large amount of warm blood is being brought into contact with the impeded current of inspired air, raising its temperature to a higher degree. While the swelling of the turbinals is frequently accompanied by increased secretion, this is not necessarily the case, for we may have the one independent of the other. Were it otherwise, in cold weather we should normally have excessive secretion, a condition, however, which, although frequently met with, is due to abnormal sensitiveness of the nasal mucous membrane to contact with cold air. We know that at 32° F. air, to be saturated, requires but 2.1 gr. of water to the cubic foot. Thus the tissues of the nose would be called upon for very little moisture in cold weather did they not, in raising the temperature of the inspired air, also raise its saturation point, which goes to illustrate the nice balance which must normally exist. According to Aschenbrandt and Kayser, the inspired air receives from 20° to 40° of heat,<sup>1</sup> and becomes saturated, or nearly so,<sup>2</sup> in its passage through the nose. This renders it suitable for the interchange of oxygen and carbonic acid gas in the lungs, a simple action of osmosis which takes place most perfectly when with warm fluid on one side of a membrane there is warm, moist air on the other.

To supply the large amount of water necessary to moisten the inspired air, Bosworth has calculated that about a pint should be secreted by the nose, and this is obtained from the sinus-tissue of the turbinals, together with the tears and the secretion of the muciparous glands.

The function of the nose in filtering the inspired air is practically perfect, for Tyndall has demonstrated that the expired air is free from germs. This takes place, first by action of the vibrissæ, the hairs of the vestibules, which hinder the entrance of large particles, and next by the adherence of smaller particles to the moist surfaces of the intricate passages of the nose and naso-pharynx. When in large amount, or when the nose is too roomy, or pathological conditions interfere with this normal filtering process, particles may reach the lower respiratory tract. While the mucus is an important agent in arresting the dust, the cilia are in no less degree active in cleansing the surfaces. The ciliary wave in the nose is toward the naso-pharynx, that in the naso-pharynx toward the mouth, while that in the lower respiratory tract is upward, so that foreign particles are carried toward the mouth and thus removed, either by expectoration, or, more physiologically, by swallowing. The activity of the cilia depends very much upon the quality of the mucus with which the membranes are covered; for in certain states, when there is much viscidness, it is known that their action is much hindered. This gives rise to a feeling of stuffiness, so great at times that patients with fossæ so open that one is able to see the vault through both sides, complain that the nose is obstructed. We see, therefore, the vital functions exercised by the intranasal mucous membrane; and a correct knowledge of its physiological functions should teach us as far as possible to avoid cauterization or destruc-

<sup>1</sup> To determine the amount of heat thus imparted to the inspired air, Bloch has formulated the following rule: The amount of heat is equal to five-ninths the difference between the body-temperature and that of the external air. Taking, for example, the temperature of the air at 32° F. and that of the body at 98.5° F., we have five-ninths of  $98.5^{\circ} - 32^{\circ}$ , or about 37°. Consequently the temperature has been raised from 32° to nearly 69° F. in its short passage through the nose.

<sup>2</sup> Bloch is probably correct in the experiment showing that the inspired air is only two-thirds saturated, for we notice an uncomfortable feeling in breathing completely saturated air.

tion of this tissue, and to remove instead septal overgrowths or to correct deformities of the septum which interfere with respiration.

**Olfaction.**—(1) As a function for yielding pleasure and for serving as a means of information and protection, olfaction has been held in far too low estimation. In man this sense receives very little attention, partly because of the protected position which the organ of smell occupies, thus greatly diminishing its liability to injury, and the consequent infrequency of disorders of olfaction, but more especially because of the almost universal lack of development and training. It is probable that in the course of evolution, devolution of this sense has taken place, and that in primitive man it was much more highly developed. Indeed, in certain cases we find the sense so acute that its possibilities seem almost incredible.<sup>1</sup> The increase in size and number of the turbinals would seem to have an important bearing on the sense of olfaction, as furnishing greater extent of surface for distribution of olfactory nerves. While the presence of a fourth or even a fifth turbinal is probably due to a persistence of the sagittal furrows found in the embryo, the fact that a fourth turbinal is present in certain negro tribes in whom olfaction is very acute seems to point toward the lessening of the function in civilized man as due to lack of development of the organ of olfaction.<sup>2</sup> Not only has there been an apparent degeneration of the sense, but directly bearing upon this, also a decrease in size of the olfactory lobes and the fields of distribution of the nerves.<sup>3</sup> Thus while most writers claim that the terminal filaments are distributed to the middle as well as the superior turbinal and the region of the septum opposite, Schultze's investigations, confirmed by von Brunn's careful measurements, have proved that the olfactory epithelium does not reach the lower edge of the *superior* turbinal by  $7\frac{1}{2}$  mm., and that the whole olfactory surface, divided nearly equally between the turbinal and the septum, has an extent of but 257 sq. mm., although this is increased slightly by scattered islands of olfactory cells. The olfactory organ, then, is placed in the remotest region of the nose; and it is, therefore, only by an appreciation of the direction of the air-currents in respiration that we are able to understand how it can be acted upon at all by odoriferous particles.

In order that we may detect odors, certain conditions are essential. The perceptive structures must be normal, nasal respiration must be unhindered, and the surface must be moist.<sup>4</sup> The external nose and the power of sniffing<sup>5</sup> are also necessary in order that the current of air may be properly directed into the superior meatus. Then again, that the odor of substances may be perceived, they must be either in a gaseous state or in a state of fine subdivision and capable of absorption. Whether the odoriferous substances cause olfaction by their specific weight, by their power to absorb heat (Tyndall) by their chemical properties, or by their specific action on the

<sup>1</sup> The sense of smell is far more acute in the lower races of man than in the higher, to whatever extent in the latter it may have been developed. Thus Arabs are said to smell fire thirty miles away (Chapman, p. 764).

<sup>2</sup> Fisher and Penzold have found that in man  $\frac{1}{23700000}$  mg. of sulphur-alcohol (over ten times more powerful than musk) to one liter of air was the utmost limit in which odor could be detected. The ability, however, with which animals are able to follow a trail shows that their sense of olfaction is much more acute than that of man (Gaulle: *Heymann's Handbuch der Laryngologie und Rhinologie*, vol. iii. p. 196).

<sup>3</sup> The olfactory bulbs and nerves are best developed in animals in which the sense of smell is most acute. The olfactory region is most developed in the dog (Chapman, p. 764).

<sup>4</sup> Whether moisture is necessary because it protects the epithelium, or whether it has a more specific action in transmitting the sensation, we do not know; but olfaction is markedly hindered if membranes are dry, although not interfered with even if secretion is excessive.

<sup>5</sup> Anosmia may be due to facial paralysis, the power of sniffing being lost. It may also be caused by loss of the external nose, being restored when the nose is replaced by operation.

pigment cells<sup>1</sup> of the olfactory region, can probably never be stated definitely. It is a matter of speculation and theorizing at present, and many ideas as to its mode of action have been advanced. It seems probable that the theory that olfaction depends upon the chemical composition (Haycraft) and molecular weight of the substance will finally be generally accepted.

(2) The greater part of the sensation that we designate as taste is, in reality, olfaction<sup>2</sup>—that is, olfaction during expiration. The term taste should, strictly speaking, be limited to perception of sweet, sour, bitter, and salt, the only sensations detected by the nerves of gustation; but so narrow an interpretation cannot be adhered to as yet. One can readily be convinced of the truth of this statement by holding the nose while drinking or eating, for thus the currents of air are unable to pass through the nose, and all flavors and odors are unperceived. Also in cases of imperforate choana, although the organs of olfaction are normal and the nasal fosse otherwise free, the senses of smell and taste are both in abeyance because of the absence of both inspiratory and expiratory currents through the nose. It is in the experience of everyone that severe coryza will likewise rob a person not only of smell, but in a great part also of taste. The great delicacy of the sense of taste seems to be due to the course of the air in expiration, as it passes higher in the nose and thus more powerfully affects the olfactory region.

**Phonation.**—(1) Resonance being an increase in the volume of sound, the voice gains its strength and character by the reverberation of the air contained in the nasal passages and accessory sinuses. The hard palate must be looked upon as a sounding-board and as a decided factor in transmitting the vibrations to the chambers above. We can, then, understand the reason why growths that obstruct the nasal cavities destroy the character of the voice, not only by preventing the passage of air through the nostrils, but by interfering with vibration. While the accessory sinuses have been variously stated to be intended to lighten the skull, to act as sources of warm air and as reservoirs for mucus to moisten the nose, and for use in olfaction, these functions are of little or no weight in comparison with the important part they play as resonating chambers. Even the frontal sinuses seem to have influence in this direction; for the native Australian negroes, who have no frontal cavities, have voices singularly lacking in resonance, a peculiarity said to be due to this malformation. The explanation of the musical voice of the African negro, so contrasted with the unsympathetic tones of the American Indian, seems to lie in the greater size of the antra in the former race.

(2) The nose and naso-pharynx are also necessary, as Helmholtz has shown, for the production of overtones, which give character and increased richness and volume to the voice.

**Protection.**—(1) We have already spoken of the protection afforded by the nose in removing from the inspired air foreign particles which would otherwise penetrate to the delicate pulmonary alveola. But the nose serves also by its sensitiveness to touch to prevent injurious substances from gaining admittance, or by calling forth reflex action, such as sneezing, to cause their

<sup>1</sup> Darwin states that animals with darker pigment in this region have more acute sense of smell. The dark-complexioned races are also known to have the olfactory sense more highly developed. Hutchinson reports the case of a negro who turned white and subsequently lost the sense of smell. Ogle reports that white herbivorous animals are more apt to be poisoned by eating poisonous plants than those with darker pigment (Bosworth).

<sup>2</sup> Ogle reports two persons both of whom by a blow on the head lost the sense of olfaction, yet the true sense of taste was preserved. No difference could be detected by them between boiled onions and apples or port and Burgundy wines; of the wines, the first seemed like sweetened water and the other like dilute vinegar (Zwaardemaker: *Die Physiologie des Geruchs*, p. 9).



expulsion. For these purposes we have an abundant supply of both sympathetic and sensory nerves distributed to the interior of the nose. The trigeminus is the great sensitive nerve of the nose, and transmits the impressions received through both its ophthalmic and superior maxillary branches. Thus the entrance of irritating substances first gives rise to a cessation of breathing, followed by a forcible expiration to remove the offending material. This is usually accompanied by a free flow of mucus due to the irritation of the trigeminus and sympathetic, the former exciting an abundance of clear, non-viscid secretion, and the latter a scanty, but very viscid, flow.

(2) The importance of olfaction in protecting the organism against injurious air and food is seldom appreciated, although its function in enabling certain animals, such as the carnivora, to track their prey and procure food, and others, such as the deer or rabbit, ill-protected by nature for self-preservation, to avoid danger, is universally recognized.

**Ventilation.**—(1) The part played by the nose in the function of ventilating the middle ears can best be understood by observing the interference which takes place when nasal respiration is obstructed. We know from the Toynebee experiment—that of swallowing while the nostrils are closed—that the air within the tympani is rarefied and the membranes become retracted. Grave consequences frequently arise from the persistence of the malposition of the tympanic membranes thus taking place in cases of hypertrophied turbinals, deformities of the nasal septum, etc., which obstruct the free passage of the air through the nose, and therefore interfere with ventilation through the Eustachian tubes.

(2) A somewhat similar action takes place in the accessory sinuses, although the effects cannot be directly observed and do not usually give rise to such serious results. According to the experiment of Braune and Clausen, while the pressure in the nose in breathing is equal to from 7 to 10 mm. of water, in the act of *sniffing* the vacuum formed in the superior maxillary sinus is equal to a negative pressure of 780 mm. of water. This explains Randall's observation, that by sniffing one may readily produce hemorrhage from the lining membrane of these cavities, especially when they are acutely congested.

#### NASO-PHARYNX.

The naso-pharynx possesses no special sense, but the location here of the pharyngeal tonsil and numerous muciparous glands, whose functions are those of protecting and lubricating the throat, makes it of great importance. It serves also as a resonating chamber of great value for the voice, and contains muscles by whose action the tympanic cavities are ventilated.

While the pharyngeal tonsil *per se* is too often considered an abnormal growth, and its function as a germinating center for leukocytes is overlooked, its enlargement interferes so markedly with the vital processes of free nasal breathing and normal ventilation of the ears that its physiological functions should not weigh against such important considerations when damage is threatened by its presence. It has been said that the function of the pharyngeal tonsil as a source of lubricating secretion for the pharynx is of no importance, judging from the atrophic processes which affect it in adult life. Granting that this pathological condition is widespread, so that the most familiar picture is that of absence or of great reduction in size, it is nevertheless my experience that only those throats can be looked upon as normal in which all the tonsils, although small, are present and in good condition. So, also, in the nose, the sclerotic condition of the turbinals in late adult life,

termed senile atrophy, is looked upon as the natural accompaniment of age because of the frequency of its occurrence, in apparent forgetfulness of normal though rare cases, where the turbinals are as large and smooth as in youth.

Sensation in the naso-pharynx is supplied not only by the trigeminal and glosso-pharyngeal nerves, but also by the superior laryngeal. From this fact arise many erroneous impressions in patients, who refer to the region of the larynx sensations arising in the naso-pharynx.<sup>1</sup>

The ventilation of the ears is brought about by the action of the palatal muscles. While the velum hangs relaxed, the openings of the Eustachian tubes are nearly vertical slits; but in the act of swallowing they open and become somewhat triangular in shape, allowing the free entrance of air. During "empty" swallowing this is even more pronounced, for the soft palate then ascends to its utmost limits, and in this manner the regular physiological ventilation is constantly provided for.

#### MOUTH.

Among the many functions of the mouth, want of space will permit only a brief reference to certain ones bearing directly upon our subject. Besides those concerned in deglutition, the mouth has a most important influence on articulation, the consonants and many of the vowels being formed by the movement of the lips and tongue. It also acts as a speaking-trumpet to throw the concentrated and amplified sounds in definite directions. By means of the special sense supplied by the glosso-pharyngeal and lingual nerves we are able to distinguish only the sensations of salt, sour, bitter, and sweet. These impressions are conveyed to the centers of taste in the brain through the fibers of the chorda tympani from the anterior two-thirds of the tongue, and through the glosso-pharyngeal nerves from the posterior third.

While the nerves of special sense of the nose and mouth contribute much to our pleasure in eating and stimulate the powers of salivary secretion and digestion, our enjoyment is due also to the consistency and other characteristics of the food which act upon the nerves of general sensibility. The glosso-pharyngeal and lingual are also nerves of general sensation, and like the trigeminal in the nose act as guards against injurious substances. The intensity of the sensation of taste depends upon the "solubility and concentration of the substance and upon the degree of force with which it is rubbed in, as in tasting."

#### THROAT.

Limiting the term throat to the oro-pharynx, we find its physiology of much importance, for here are located anatomical structures connected with the nose, mouth, and larynx, making their functions interdependent, so that the physiology of the pharynx is really that of the related parts.

Among the many physiological functions which find their expression here are the voluntary ones of articulation and sucking. Deglutition and retching are for the most part involuntary and occur reflexly. The pharynx has important influence in articulation, especially in modulation of the voice, as in singing. In sucking, the base of the tongue is drawn downward and outward, and thus creates a vacuum, breathing in the meanwhile being carried on through the nose, between the acts of sucking and swallowing. The vital importance of maintaining free nasal respiration during infancy should be too well recognized to need further comment.

<sup>1</sup> One must be on his guard against following implicitly the assertions of the patient as to the seat of sensation. Many a foreign body in the tonsil has been sought for in vain in the larynx through following blindly the patient's opinion of its supposed location.

While deglutition is at the beginning a voluntary act, when once started it becomes involuntary. It is brought about reflexly by stimulation of the nerves of the pharynx, which happens normally by the presence of food, etc., or pathologically by any sensation of foreign substance in the throat. Thus, among other things, any abnormal dryness of the pharyngeal mucous membrane, or enlargement of the lingual tonsil, or thickened secretion hanging in the throat may give rise to the ineffectual or "empty" swallowing which so often causes great distress. In swallowing normally, the action begins at the tip of the tongue, which is pressed against the roof of the mouth, the other sections following in order, the substance to be swallowed being thus forced backward into the pharynx. The anterior pillars of the fauces then come together, and, with the arched tongue, shut off the return to the mouth. Then the superior constrictors contract, forming an elevation (Passavant's cushion) across the posterior pharyngeal wall, which, meeting the elevated soft palate, shuts off the entrance to the naso-pharynx. In paralysis of the velum, as after diphtheria, or in destruction or cleavage of the soft palate, the closure is incomplete, so that fluids and even solids regurgitate into the vault and even through the nose. In hypertrophy of the pharyngeal tonsil, which hinders the full elevation of the velum, and in adhesion between the tonsils and the anterior pillars, which prevents the soft palate from ascending, the same insufficiency occurs. Following the contraction of the superior constrictors, the middle and inferior constrictors<sup>1</sup> of the pharynx act involuntarily and reflexly and force the object downward. At the moment of swallowing, the larynx is drawn upward and forward under the tongue, and the epiglottis is thus usually<sup>2</sup> forced over the laryngeal opening.

In retching, which precedes vomiting, there is contraction of the lateral walls of the pharynx so that they may meet in the median line. The center for vomiting<sup>3</sup> being near that of respiration in the medulla, practical use may be made of this knowledge in preventing vomiting during examination of the throat. By noticing this premonitory contraction of the fauces and directing the patient to breathe deeply and quickly, the tendency to retching may very frequently be stopped and the examination completed.

#### TONSILS.

While the physiology of these structures will be treated more fully in the section allotted to them, it seems desirable to emphasize here the important part they play as protective organs. It is now recognized that all the lymphatic tissue, whether in the form of simple collections of lymphatic cells scattered throughout the nose, Eustachian tubes or pharynx, or collected into prominent groups, as in the naso-pharynx, fauces, or at the base of the tongue, are germinating centers for leukocytes. That absorption is a special function of the tonsils, as asserted by some, is probably a mistake; for although made up of lymphatic tissue, they are not in direct connection with the general lymphatic system. Their peculiarly irregular surface favors the catching and retention of substances, and absorption can of course take place as easily here as through any mucous membrane.

<sup>1</sup> Meltzer has experimentally shown that the middle and inferior constrictors are not absolutely necessary even for the deglutition of solids (Einthoven: Heymann, vol. ii, p. 58).

<sup>2</sup> It has been shown that the epiglottis does not even normally always close the opening of the larynx (Schmidt: *Die Krankheiten der oberen Luftwege*, p. 45).

<sup>3</sup> It is not necessary to have any irritation of the fauces to bring about the action of retching, as there are fibers connecting the vomiting-center with the convulsions. The simple thought, by translation, may act upon the center, and, as we often see, may cause gagging merely at the sight of the examining instrument (Laudois: *Physiologie des Menschen*, p. 295).

## SOFT PALATE AND UVULA.

We have spoken of the elevation of the soft palate in deglutition. As its elevation prevents the escape of food into the naso-pharynx in swallowing, so its elevation prevents, and its relaxation permits, the passage of waves of sound through the nose, and thus its action is of great importance in speaking. Particularly is this action of importance in singing, for the naso-pharynx and nose are especially concerned in the production of overtones, which give fulness and character to the voice.

Too little attention has been given to the physiological functions of the uvula. While it is generally recognized that it assists in more securely stopping the entrance to the naso-pharynx when the soft palate is elevated, I regard its most important function as that of acting on the edge of the velum like a weight on a drop-curtain. In all the shades of tone the uvula is of great influence in causing the edge of the velum to fall more quickly, overcoming the tendency for its moist surface to adhere to that of the posterior pharyngeal wall. The rapidity of the actions of the soft palate in singing or speaking can scarcely be appreciated until one has observed its movement directly, as in patients after the removal of the superior maxilla. That this function exists and is of practical importance can be readily recognized from the change in voice produced by too long or too heavy an uvula.

## LARYNX.

The two important physiological functions of the larynx are those of protection of the delicate structures below and of voice-formation. In addition, it has the function of regulating the amount of air in breathing, which is done reflexly, the glottis widening with each inspiration.

Of these, by far the most important to the whole economy is the function of protection. The contact of anything irritating with the sensitive structures guarding the larynx immediately causes them to contract, thus preventing its entrance; or, if it has gained admission, the sudden escape of air through the glottis tends to carry with it the offending substance, and the action is accompanied by a harsh sound (cough), due to the rough vibrations of the vocal cords. It is not only solid particles which thus call into action the protective function of the larynx, but also certain gases, such as ammonia and chlorine, called irrespirable gases; and even strong wind, whether warm or cold, act in a somewhat similar manner.

The larynx produces sound by throwing the column of expiratory and inspiratory air into vibration as it passes over the approximated edges of the vocal cords. This would give rise to sound of very limited nature, but it is so modified by the force of the current (volume), by the size of the opening (pitch), and by the influence of the surrounding cavities (quality), that the voice may become the most perfect of musical instruments. The action of the larynx is not like that of a pipe in the production of tone, for in order to give the low note, Do (64 vibrations), it would have to be some 8 feet long; neither is its action like that of a stringed instrument, for it would necessitate a cord many feet in length to produce this low note.<sup>1</sup> Its action closely resembles that of the hautboy, in which the sound is produced by a combination of pipe with a vibrating reed. The knowledge of this fact is made use of after laryngectomy by employing a reed in the artificial larynx to enable the patient to talk.

<sup>1</sup> Chapman, p. 846.



# GENERAL ETIOLOGY AND PATHOLOGY OF DISEASES OF THE UPPER RESPIRATORY TRACT.

BY J. H. BRYAN, M. D.,

OF WASHINGTON, D. C.

DISEASES of the upper respiratory tract—that term for the purpose of this article being confined to the naso-pharyngo-laryngeal region—may be either local conditions or local manifestations of some general disease, and they are as varied as are the tissues which go to make up these complex organs. Thus we may have any known pathological condition of the mucous membrane, cartilages, bones, blood-vessels, or glandular tissue.

In an article devoted to the consideration of the general etiology, pathology, and symptomatology of diseases of the upper respiratory tract, it will be possible to give only a general idea of some of the more common conditions met with in this region.

Of all the tissues composing this tract, the mucous membrane is the one most frequently affected, and it is subject to three forms of inflammation, viz., the catarrhal, the croupous, and the diphtheritic.

**Catarrhal inflammations** affect adults as well as children, and they are the most common affections we have to deal with. They have been recognized from the earliest times; early writings showing the familiarity of the ancients with these affections and their influence on the general health. These inflammations have become more frequent and have increased in severity during the present century, owing to the complex conditions of modern civilization, which has no doubt developed new influences which operate to produce these severe conditions.

They have a widespread distribution over the earth's surface, and are more frequently met with in cold than in warm climates, and in high than in low latitudes. In the temperate zone, according to Seitz,<sup>1</sup> they are most frequently observed between the isotherms of 18° and 4°; although there is no region absolutely exempt. In a study of the etiology of these affections it is desirable to know the superficial contour as well as the geological character of the region before the full influence of the humidity and the temperature and barometric changes can be estimated. Changeable temperature has a great influence in the production of these affections; therefore they are more prevalent in the spring, when the temperature and winds are more variable, than in the fall.

The causes of catarrhal inflammations are both exciting and predisposing. Among the exciting causes may be mentioned a sudden exposure to cold when the body is scantily clad, thus giving rise to the phenomenon of "catching cold." There are several theories as to the process of catching

<sup>1</sup> *Catarrh and Influenza*, 1865, p. 85.

cold. The theory of Rosenthal is that the cold acting upon the surface of the body excites the arterioles to contraction, by which the blood is driven from the surface to the internal organs including the mucous membranes, and there acts as an irritant, exciting an inflammation. This theory is based upon the faulty assumption that a part is inflamed because it receives more blood, whereas it really receives more blood because it is inflamed.

The theory of Seitz is that inflammations resulting from catching cold are the result of removing heat to an undue extent from the external surface of the body, this sudden removal causing some functional disturbance of the body by which a morbid process is set up. Neither of these theories explain satisfactorily the phenomena that take place. Bosworth<sup>1</sup> is more nearly correct when he states that the action of cold upon the body is probably upon those nutritive changes which are constantly going on within the body, and by which animal heat is produced. Any interference with this heat production results in a morbid process which, in a mucous membrane, shows itself in the form of an inflammation.

A much more potent factor in the production of catarrhal inflammations than simple exposure to a low temperature is the degree of the relative humidity of the atmosphere. Probably the most frequent cause of this form of inflammation to-day is the influenza, an infectious disease which appears in epidemic form, rapidly spreading from place to place. It is of microbial origin, and bacteriologists have succeeded in isolating the specific germ which causes it. The local conditions of this affection differ in no wise from a simple catarrhal inflammation, except in the degree of the inflammatory process.

Aside from the effects of the changes of temperature, the inhalation of irritating vapors and finely divided mechanical irritants is an important factor in the production of these conditions. Such irritants are particularly noticeable in our large manufacturing cities, where the atmosphere is heavily laden with smoke and gases produced by the large factories, as well as with particles of dust which come from the pulverizing of asphalt in our modern pavements. These substances being constantly inhaled produce more or less irritation, which eventually results in a low form of inflammation. A more limited number of cases arise from some systemic or organic influence or from some functional disturbance; and a few cases may depend upon some structural defects in the parts themselves. Prominent among the predisposing causes from within the organism are gastro-intestinal disturbances arising from errors in diet or over-indulgence of the appetite. It is a matter of common occurrence that a defective digestive process and imperfect assimilation exert their harmful effects in the production of reflected irritation in the upper air-passages. This frequency is noticed in children under the third and fourth year, in whom attacks of indigestion so readily occur, and who show a great degree of reflex sensitiveness. Aside from the so-called reflex disturbances, the gastro-intestinal disorders are frequently the direct source of inflammation of the upper respiratory tract. Chronic pharyngitis, one of the most universally distributed diseases of this region, has probably for its most common origin disturbances of the stomach. Dr. T. R. French,<sup>2</sup> who has recently made a very interesting contribution to the study of this subject, states that in all cases of chronic pharyngitis there is some disorder of the stomach. In conjunction with Dr. C. S. Fisher he examined the throats of 23 patients whose stomach-contents had been examined after a test-meal, and in all of these patients there was found some form of stomach disorder asso-

<sup>1</sup> *Diseases of the Nose and Naso-pharynx*, p. 58.

<sup>2</sup> *N. Y. Med. Journ.*, Sept. 12, 1896.

ciated with a pharyngeal catarrh. It is not only the pharynx and nasopharynx, but also the nose and larynx that may be affected by such conditions. Ariza, cited by Moreau Brown,<sup>1</sup> mentions three forms of laryngeal disturbances that result from gastric affections :

(1) Laryngeal hyperesthesia, where the patients complain of a burning sensation and pain in the larynx, but where the fauces and larynx are perfectly normal.

(2) A condition in which the vocal cords and surrounding parts are both hyperemic and painful, varying in intensity according to the severity of the gastric disorder.

(3) A reflex paralysis dependent upon gastro-intestinal disturbance.

Then there are apt to be acute attacks frequently occurring in the neurasthenic, and accompanied by more than ordinarily profuse serous discharge.

Aside from the dyscrasia, such as syphilitic and tubercular diatheses, which render the mucous membrane peculiarly liable to take on inflammatory action, there are other constitutional affections which play a very important rôle in the production of diseases of the upper respiratory tract, such as gout and rheumatism. There are certain conditions of the throat in which the pain is out of all proportion to the amount of local disturbance observed ; and it is in such cases that gout or rheumatism will in the majority of instances be found to be the exciting cause. While my own experience leads me to believe that the association of certain forms of tonsillitis and rheumatism is something more than accidental, I consider the question to be still unsettled. If the researches of Henry L. Wagner<sup>2</sup> and others who claim to have found the same microbe in tonsillitis and in the blood in rheumatism are confirmed, it will go a long way in clearing up this much-mooted relationship of tonsillitis to rheumatism. There are certain forms of rhinitis, especially the hyperesthetic variety, either associated with asthma or not, which are frequently observed in overfed and plethoric subjects, and which have for their causation a surecharching of the system with uric acid.

Prominent among the causes of catarrhal inflammations of the pharynx, larynx, and trachea may be mentioned the pernicious habit of mouth-breathing resulting from some morbid condition within the nose, or to hypertrophy of the lymphoid tissue in the vault of the naso-pharynx. The cold, unfiltered, and unmoistened air passing over the pharynx into the larynx and trachea affords a great disposition to catarrhal inflammations of these organs.

The strong influence of many modes and habits of life in the production of these affections is obvious, among which may be mentioned a sedentary life in a close vitiated atmosphere, and the custom of overheating the houses so frequently observed in this country, thereby rendering the subject sensitive to the changes in the weather.

Numerous micro-organisms find an excellent culture-soil in the oropharyngeal tract, some of which are harmless, while others are pathogenic in character and are the source of the infectious and contagious affections, such as diphtheria, scarlet fever, whooping-cough, and phlegmonous inflammations that are met with in this region. Lennox Browne<sup>3</sup> further subdivides these micro-organisms into a third group, which are innocuous so long as the subject enjoys perfect health, but so soon as this is depressed or there is any abrasion of the mucous membrane systemic infection takes place, with sometimes serious results. In this later group may be classed the leptothrix buccalis, the pneumococcus, and the diplococcus, all of which are frequently

<sup>1</sup> *N. Y. Med. Journ.*, Aug. 29, 1896.

<sup>2</sup> *Trans. Amer. Laryn. Assoc.*, 1894.

<sup>3</sup> *Diseases of the Throat*, 3d Ed., p. 161.

found in the healthy mouth and throat. To these may be added the staphylococcus albus and aureus and the streptococcus pyogenes.

The nose, on the other hand, does not offer such a fertile soil for the growth of these micro-organisms as does the oro-pharynx, for according to the researches of St. Clair Thomson<sup>1</sup> and Hewlett, who have recently investigated this subject, it may be stated that the occurrence of micro-organisms on the Schneiderian membrane is so infrequent that their presence must be regarded as quite exceptional. This is borne out by our clinical experience, for infectious diseases of the nose are much less frequent than in any other part of the upper respiratory tract. Paget<sup>2</sup> has confirmed the above results, and finds the nasal cavities in the normal state free from microbes except at the anterior part and vestibule. He concludes that the asepsis of the nasal cavities is due to the structure of the canal, to the ciliated epithelium, and to the germicidal quality of the mucus, which he finds is absolute for the anthrax bacillus, very marked for the Klebs-Löffler bacillus, and less so for the staphylococcus and streptococcus organisms. This explains why operations in this region show a certain degree of immunity from infection.

**Pathology.**—While the pathology of ordinary catarrhal inflammations is comparatively simple, there are certain conditions which are much more difficult to understand. Among them may be mentioned hypertrophy of the lymphoid tissue in the vault of the pharynx, hypertrophy of the turbinal bodies, and deformities of the septum, resulting either from eelchondroses, exostoses, or deflections. In order to comprehend fully the pathology of inflammations of the upper respiratory tract, it is necessary to understand the pathology of inflammations in general. They may be said to result either from the action of micro-organisms, or from an irritant of which cold is the most common example. The impression produced by cold upon the vaso-constrictor nerves stimulates them to contract the capillaries of the skin, the result of which is a diminution of the blood-supply to the periphery and a reflex to the internal organs including the mucous membranes. If these organs are in a state of health no harm will result. In those cases, however, where there is a deviation from the normal and the internal resistance is not sufficient to maintain the equilibrium, the capillaries dilate at the weakest point from overpressure. This is the condition of hyperemia or the first stage of inflammation. If now the cause is removed and the paralyzing effect on the vessels overcome, the hyperemia may subside and recovery occur. If, however, the cause should continue to operate, or the paralyzing effect on the blood-vessels cannot be overcome, the case passes on to the second and third stages of inflammation. The increased rapidity of the circulation, which is the first effect of the dilatation, is soon followed by a slowing of the blood-current; the leucocytes begin to seek the periphery of the stream, which adds to its stagnation; while the pressure from behind continuing, a transudation of the fluid constituents of the blood through the walls of the vessels takes place, and is thrown out on the surface of the membrane. This exudate varies in quality, according to the intensity of the inflammation, from a thin serous to a thick mucous discharge—this constituting the second stage of inflammation. If the inflammatory action increases and the leucocytes form a part of the exudate, we have the third, or suppurative, stage.

In acute inflammations the quantity of mucus is largely increased over that of the normal flow; but in the chronic processes the apparent increase may be, as Bosworth<sup>3</sup> suggests, a diminution, owing to the fact that the normal

<sup>1</sup> *Medico-chir. Trans.*, vol. lxxviii.

<sup>2</sup> *Journal of Laryngology*, Nov., 1896.

<sup>3</sup> *Op. cit.*, p. 101.



secretion of serum which serves to dilute the mucus in health, and which disappears by evaporation without being noticed by the patient, is diminished when the membrane is inflamed, leaving behind a thick mucous discharge which soon makes itself evident.

**Croupous and Diphtheritic Inflammation.**—The other forms of inflammation met with in mucous membranes are the diphtheritic and croupous. In both of these affections, the exudate, instead of being fluid as in the catarrhal variety, is characterized by a membranous deposit. Occasionally we meet with conditions characterized by pseudo-membranous deposits caused by irritants, non-microbic in character, such as steam, ammonia, and chlorine.

Until within recent years the two diseases known as croup and diphtheria have been considered as separate and distinct affections; but since the advances made in bacteriological research there is a tendency to consider them as one and the same affection. Clinically, they are similar only in the sense that both are characterized by the formation of a membranous deposit. True croup lacks many of the constitutional symptoms of diphtheria, such as the high temperature, septic infection, and the frequent serious sequelae of the latter affection. The confusion of these two affections has been caused by finding the Klebs-Löffler bacillus, the cause of diphtheria, in the croupous deposit. When we consider that this bacillus is frequently found in the throats of patients who are not suffering from diphtheria, we are forced to the conclusion that their presence in the croupous deposit is either accidental, or, as Moritz Schmidt<sup>1</sup> suggests, these two affections may bear the same relation to each other as do tuberculosis and lupus of the skin.

**Nasal Obstruction.**—Thus far we have considered the pathology of simple inflammations of the mucous lining of the upper respiratory tract. There are other conditions, however, whose pathology is not so readily explained. In order to understand the so-called obstructive affections of this region, it will be necessary to make some reference to the physics of the nose and its relation to the rest of the respiratory tract. Without encroaching too much upon the domain of physiology, it will only be necessary to refer to the nose as a respiratory organ, the significance of which has only within recent years been fully appreciated; one of its principal and most important functions being to heat and moisten the external air on its way to the lungs. When from any cause this function is interfered with, mouth-breathing results with all its accompanying evils. The disturbances which mouth-breathing produce are the more serious the younger the subject and the longer the existence of the interference with the free passage of air through the nose. The conditions which give rise to interference with free nasal respiration are obstructive in character, and they may result from congenital or acquired closure of the nostrils; from paralysis of the *alae nasi*; from hypertrophy of the inferior turbinal bodies, or of the lymphoid tissue in the vault of the pharynx; from ecchondrosis, exostosis, or deflections of the septum; from polypi and granulation tissue, resulting from suppurative inflammations of the accessory sinuses; or from foreign bodies. The effect of these nasal obstructions on the rest of the respiratory tract is to render the subject prone to attacks of pharyngitis, laryngitis, and tracheitis, which when once established are liable to become chronic.

In obstructions resulting from hypertrophy of the inferior turbinal bodies there is generally an antecedent chronic rhinitis, producing a congestion and swelling of the erectile tissue sufficient to produce a temporary stenosis of the nasal chamber. Among other causes for nasal stenosis may

<sup>1</sup> *Die Krankheiten der oberen Luftwege*, p. 369.

be mentioned the constant inhaling of irritating vapors, which causes a chronic congestion and swelling of the parts. Bosworth,<sup>1</sup> on the other hand, believes that these cases in the majority of instances are dependent upon septal deformity, either as a deflection or projecting spurs, tracing the origin of these etiological factors back to infancy, when the child received a blow on the nose sufficient to produce the deformity. There is no doubt that septal deformities, either in the shape of deflections or projecting spurs, are in a large number of cases associated with hypertrophy of the inferior turbinals, although they are not always present. Wherever these stenoses are situated, the atmospheric pressure behind the obstruction has become diminished, and in consequence a chronic congestion is produced.<sup>2</sup> This, of course, means an increased nutrition of the body with a resulting hypertrophy, in which there is an increase of all the tissues which go to make up these bodies, viz., the epithelial and fibro-elastic layer, and the submucous tissue containing the racemose glands and venous sinuses. The degree of hypertrophy varies, in some cases being very slight, not causing sufficient obstruction to the respiration to attract the attention of the patient; while in other instances the increase in size is sufficient to block up the nasal chambers and occasionally to project backward, presenting tumefied masses in the naso-pharyngeal space.

Septal deformities may be either deflections or in the form of *ecchondroses* or *exostoses*. They may originate either as a result of traumatism or from an inflammation of the mucous membrane. Traumatism in early youth or infancy plays no doubt a most important part in the production of these deformities, but I believe it is by no means the frequent cause that is so generally assumed. It may happen that these injuries in infancy are readily overlooked or forgotten; but when they do not occur until later in life, an injury sufficient to produce a marked bending of the septum is not apt to pass entirely out of the memory. These conditions have their beginning in the infancy or early life of the subject. When such a person is exposed to cold a catarrhal inflammation of the lining membrane of the nose sets in, with a resulting nasal stenosis. This, of course, acts in the same manner as in hypertrophic rhinitis by producing a rarefaction of the air posterior to the stenosis, with a resulting hyperemia which eventually becomes chronic. The consequence is an increased nutrition of the parts with, in the case of the cartilaginous portion of the septum, a production of cartilage-cells beneath the mucous membrane. This production of cells continues as long as the irritation lasts, and there is a distinct projection from the septum into the nasal chamber known as an *ecchondrosis*. The same process holds true for the vomer, when the projecting process or tumor is composed of bone, and is known as an *exostosis*. They may exist either alone or the one may be continuous with the other, and they generally have their starting at the sutural junction between the triangular cartilage and the vomer. Occasionally we find them without any deflection of the septum, but in the majority of cases there is some decided bending to the side corresponding to the *ecchondrosis* or the *exostosis*. Syphilis is also, in my experience, a common cause in the production of these conditions.

The deformities resulting from deflection of the septum are not so readily explained. It is occasionally congenital, and in many cases it results from traumatism, but this is not so common an etiological factor as to explain this very frequently occurring deformity. Inflammations explain the process of

<sup>1</sup> *Op. cit.*, p. 125.

<sup>2</sup> [Despite the authorities supporting this view, it seems overdrawn.—Ed.]

bending in a few cases by the weakening of the septum, the atmospheric pressure being greater on one side than on the other at some period of the process causes it to bend in the direction of the least resistance. In most instances it is the result of a physiological process—the septum being fixed between two unyielding planes, bends to one side or the other in order to make room for its increased growth.

**Adenoid Hypertrophy.**—Situated in the naso-pharynx, pharynx-wall, and at the base of the tongue there is a certain ring of tissue, similar in structure but differing from the neighboring tissues of the upper respiratory tract, which plays a very important part in the pathology of the diseases of this region. While all the lymphoid tissue forming this ring has a striking similarity in structure, there is a decided difference as regards its life-history when diseased, in that the tissue in the naso-pharynx shows a tendency to atrophy at puberty, while that in the fauces and lingual region may continue into adult life; indeed, the lymphoid tissue at the base of the tongue is rarely diseased until after puberty. This brings us to the consideration of the next and probably the most important form of obstructive disturbance met with in the upper respiratory tract, and that is hypertrophy of the lymphoid tissue in the vault of the pharynx. This affection has been variously described as enlargement of the third tonsil and adenoid vegetations. It has been recognized for many years, but it was left to the late Prof. Wilhelm Meyer<sup>1</sup> to point out the frequency of its occurrence and its clinical importance. It is essentially a disease of childhood, occurring occasionally at the earliest periods of life. While it shows a tendency to disappear at puberty, it is frequently observed in adults. Although this affection cannot properly be said to be due to heredity, it is nevertheless observed as occurring very frequently in families with the so-called lymphatic temperament. Several members of the same family may be afflicted in the same manner, all showing a tendency to hypertrophy also of the faucial and the lingual tonsils.

Climate has a very decided influence in the production of this condition, it being much more frequently observed in cold, damp countries than in those where the atmosphere is warm and dry.

Probably the most frequent cause of the hypertrophy of this tissue is frequent and neglected attacks of catarrhal inflammations of the nose and naso-pharynx. The lymphoid tissue becoming once inflamed, shows a tendency to continue and become chronic through the same agencies that produce hypertrophy of the inferior turbinal bodies, with which it is very frequently associated. Among the other exciting causes may be mentioned diphtheria and the exanthemata.

The stenosis resulting from an acute catarrhal rhinitis, or from that due to one of the previously mentioned obstructive nasal disorders, may be sufficient to excite a hyperemia and swelling of the post-nasal lymphoid tissue by rarefying the air in the naso-pharyngeal space. This congestion resulting from lessening of the atmospheric pressure in this region causes an increased nutrition of the tissue with a consequent hypertrophy of its constituent elements.

**In the faucial lymphoid tissue** there are several distinct pathological conditions recognized, viz., the acute inflammations, which may involve only the mucous covering of the gland or extend into the follicles, giving rise to the crupous or follicular variety; or the whole gland may be involved, and, going on to the suppurative stage, result in abscess of the tonsil or peritonsillar tissue. In the chronic form we recognize the hypertrophic variety,

<sup>1</sup> *Hospitals Tidende*, Copenhagen, Nov., 1868.



and, according to the classification of Bosworth, the hyperplastic, which is in reality an advanced stage of the hypertrophic form.

The eroupous variety is a simple inflammation of the follicles that go to make up the gland, infectious in character, and manifested by a thick deposit making its appearance at the mouths of the crypts, and occasionally spreading out as a membrane on the surface of the gland. This exudate is soft and easily wiped away from the tonsil, when it can be seen exuding from the mouths of the follicles. In the hypertrophic variety of tonsillitis there is an increase in all the tissues that constitute this gland. The follicles occasionally become overdistended with secretion, giving rise to a constant fetid discharge from the gland. In the hyperplastic variety there is an increase in the connective-tissue elements, with a gradual destruction of the lymphoid tissue proper. In these cases the gland becomes hard and fibrous in character.

The lingual tonsil situated at the base of the tongue is liable to be affected by any of the pathological conditions mentioned as affecting the other lymphoid glands; but it is much more rarely affected. It is essentially a disease of adult life, and may have for its origin any of the infectious diseases; but it is more frequently associated with some form of gastric disturbance.

#### SYMPTOMATOLOGY.

Many of the diseases affecting the naso-pharyngo-laryngeal tract have symptoms which are common to one or more of them, and in a general way they may be either subjective or objective—the former relating to the disturbance of functions of the organs affected, while the latter are such as can be seen by the observer only.

**Obstruction to nasal respiration**, resulting in mouth-breathing, is one of the most prominent symptoms among nasal disturbances, as previously set forth.

Occasionally the patient will be found to insist that he has perfect nasal respiration, especially when the intranasal obstruction is not sufficient to make a very decided impression on him, but careful questioning will generally elicit the further information that he awakens in the morning with the mouth open and dry, and that there is snoring during sleep. This symptom is probably more frequently noticed in children who are also very restless during sleep, frequently awakening and calling for water to moisten their parched throats. When the mouth-breathing has existed for some time most decided changes are noticed, not only in the soft parts, but also in the bony frame-work of the mouth and chest, which are more severe the younger the individual. The features are relaxed and assume a well-recognized indolent and stupid expression.

Disturbances of speech, such as stuttering and imperfect articulation, are also frequently observed.

Headache is a common symptom noticed in many forms of intranasal disturbances, especially when resulting from the pressure on the soft parts of bony or cartilaginous projections from the septum, from pressure due to swelling of the middle turbinals, and in inflammatory conditions of the accessory sinuses.

Loss of memory and lack of mental application to the extent of being unable to concentrate the attention upon any one subject are symptoms frequently observed in these nasal and post-nasal disturbances. It is especially noticeable in children suffering from hypertrophy of the post-nasal lymphoid tissue. These little subjects frequently get the reputation unjustly of being



stupid, when their mental inactivity is entirely due to some form of nasal obstruction. This is the condition described by Guye of Amsterdam as aprosexia.

Nocturnal enuresis is a symptom so frequently associated with nasal obstruction in children, especially that resulting from lymphoid hypertrophy, that its concurrence can scarcely be called accidental. Grönbech,<sup>1</sup> cited by Schech, out of 192 cases of hypertrophy of the post-nasal lymphoid tissue, found enuresis 24 times. Twelve of these cases were cured after operation.

**The Palate and Teeth.**—A brief reference in this place may be made in connection with mouth-breathing to the changes in the arch of the hard palate, which in the very young becomes altered, assuming an acute bow or V-shape. This deformity results from a combined pressure of the buccal muscles exerted on both sides and a column of air constantly striking the hard palate. Körner distinguishes between the alterations of the upper jaw of children who have suffered from nasal stenosis before the shedding of the deciduous teeth, and those which result from nasal stenosis during the change of teeth. In the first instance there occurs generally the cupola-shaped elevation of the palate; the alveolar border which naturally forms a semi-circle assumes the form of an ellipse; but there is no change in the position of the teeth. If the nasal stenosis exists at the time of the change of the teeth, then the lateral alveolar borders are approximated while the anterior border is pushed forward, and the high arch of the palate increases until it encroaches upon the cavities above. The teeth in these cases assume a very irregular shape.

**Diseases of the ear** frequently accompany nasal and post-nasal disorders, and vary from a simple occlusion of the Eustachian tube, resulting from an acute rhinitis, to a severe suppuration of the middle ear, with all its dangerous sequels. Children suffering from hypertrophy of the post-nasal lymphoid tissue frequently exhibit various degrees of deafness, varying according to the size of the growth from a slight diminution of the hearing to almost complete deafness.

**Loss of smell**, varying from a slight impairment to a complete loss of the function, known as anosmia, may accompany almost any form of intranasal disturbance involving the upper part of the nose; but it is most frequently associated with development of polypi and other inflammatory conditions of the ethmoid bone. In many cases where there is a loss of smell there will also be observed some disturbance in the function of taste. While the taste may not be absolutely lost, it will often be found very much diminished for the perception of flavors.

**Voice.**—The influence of nasal diseases is frequently observed on the voice, the obstructive affections of the nose and naso-pharynx modifying its tone and rendering articulate speech thick or muffled and difficult to understand. These defects are occasionally observed in parietic conditions of the soft palate which so often accompany disorders of the nose and naso-pharynx, giving the voice a nasal character, so that it is difficult at times to distinguish it from that due to nasal stenosis. The pronunciation of certain consonants under these conditions is considerably modified; for example, *d* sounds like *n*, and *b* is similar to *m*, while the sound of *g* is very difficult to make. It frequently becomes a nice point to decide whether the cause of these speech-defects lies within the nose, naso-pharynx, or is of central origin.

In laryngeal affections the voice may be natural in speaking and altered only in singing, breaking in the passage from the lower to the higher regis-

<sup>1</sup> *Sitzungsberichte des Aerztlichen Vereins, Munich.*

ters. It may be hoarse or uncertain, being natural at times and husky at others, or it may be entirely absent as in aphonia. The respiration may be seriously embarrassed both in nasal and laryngeal affections. In the former it may be obstructed by either acute swelling or hypertrophy of the turbinal bodies, hypertrophy of the post-nasal lymphoid tissue, deformities of the septum, or by new formations within the nasal cavities, such as polypi.

**Respiration.**—In laryngeal affections the respiration may be more or less embarrassed, hurried, or retarded, according to the nature of the affection. It is often accompanied by a loud noise which may be either stridulous or stertorous in character—the former generally accompanying inspiration, when it indicates some laryngeal obstruction resulting from new formations or foreign bodies, spasm of the laryngeal muscles, false membranous deposits, or paralysis of the abductor muscles of the vocal cords; while stertorous breathing more frequently accompanies expiration and is associated with general paralytic conditions.

**Cough** is a common symptom of diseases of the larynx, varying in character according to the location and intensity of the inflammation from a simple hacking cough or clearing of the throat to one that is hoarse, barking, or metallic in sound. It may occur in paroxysms and is frequently suffocative. Cough is also a not infrequent symptom of diseases of the nose and naso-pharynx, when it is said to be reflex in character, and due to some pressure on the sensitive nerve filaments in these regions or to an undue irritability of certain sensitive areas, as in the auditory canal, which when irritated give rise to an annoying form of paroxysmal cough.

**Deglutition** in diseases of the upper respiratory tract may be either difficult, a condition known as dysphagia; painful, odonphagia; or at times impossible, aphagia.

While dysphagia is not a symptom very common to nasal affections, it nevertheless occurs occasionally in those cases where there is a decided enfeeblement of the soft palate resulting from nasal and post-nasal inflammations. It is much more frequently observed in those cases in which the pharynx and larynx are involved, especially where there is obstruction in the fauces, pharynx, or esophagus, or where there is any ulceration or destruction of the velum, either with or without an enfeeblement of the nervo-muscular control of the constrictor muscles of the pharynx. It frequently happens in such cases that the food passes into the nares. Occasionally also, when the epiglottis is either ulcerated or destroyed through the action of syphilis or tuberculosis, the food has a tendency to pass into the larynx until the parts so adapt themselves as to enable it to follow the natural channel into the esophagus.

Odonphagia is associated with nearly all the acute inflammatory affections of the pharynx, particularly tonsillar inflammations, and also with many of the chronic conditions of the larynx, such as tubercular laryngitis, especially when the epiglottis is involved; or when this organ is the seat of malignant disease.

Aphagia is generally present when the larynx or the pharyngo-laryngeal tract are the seat of malignant disease, and results either from the act of swallowing being so painful that the patient refuses to swallow, or the obstruction is so marked that it cannot be overcome.

Under the heading of objective symptoms or those revealed to the physician by the various methods of examination, may be mentioned a change in the color, form, position, and secretion of the parts studied.

The color may be increased or diminished according to the nature of the

disease, being increased in all affections of an inflammatory nature, the intensity varying in degree according to whether the parts are the seat of an acute, subacute, or chronic inflammation. It is frequently diminished in those cases where there is general anemia or a marked depression of the heart's action.

It may be altered when the patient is suffering from such general conditions as jaundice, when the membrane assumes a decidedly yellow hue, or from tuberculosis in its early stages, when the membrane frequently presents a grayish appearance.

The form may be changed by an increase of tissue, as in the hypertrophic form of inflammation so often noticed in the nasal and naso-pharyngeal cavities, or by a decrease of tissue, such as is observed in atrophic rhinitis. In the larynx the lining membrane may be the seat of a serous, purulent, tubercular, syphilitic, or malignant infiltration, sufficient at times to encroach upon and diminish the caliber of the glottis to a marked degree. The size and shape of the glottis may be changed by the several positions assumed by the vocal cords in the various paralyses of the intrinsic muscles of the larynx. The position of the nose may be altered by any morbid growth springing from within the nasal cavity, but otherwise it is rarely changed. The larynx, however, is very frequently displaced from its normal position by such extralaryngeal affections as bronchocele, cancer, or enlarged glands of the neck; while contraction of the cicatricial tissue resulting from syphilitic ulceration in many instances disturbs the normal relation of the parts within the cavity.

# METHODS OF EXAMINATION AND DIAGNOSIS IN AFFECTIONS OF THE NOSE AND THROAT.

BY JOHN W. FARLOW, M. D.,

OF BOSTON, MASS.

BEFORE proceeding to the examination of the interior of the nose and throat, it is always of importance to look critically at the face and neck of the patient and also to try to get as much preliminary information as possible by external palpation. This often furnishes valuable clues and hints which are quite likely to be overlooked if they are left until after the internal examination. Look at the region of the frontal sinuses and see if there is any prominence or tenderness on either side; look at the conjunctivæ; feel of the nasal bones with reference to depression or abnormalities of any kind. The degree of mobility of the cartilaginous septum and the presence of deviations and large perforations can be felt by the fingers on the outside.

The *alæ nasi* should also be tested as to their strength or flaccidity. The folds and creases about the nose are often indications of muscular action which has for its object the opening of the nostril by drawing the ala away from the obstructing septum. Notice whether the mouth is habitually closed, the shape of its aperture, the dryness of the lips, whether the teeth or jaws overlap. Always feel for enlarged glands of the neck both in front of and behind the sterno-mastoid muscle. The neck should be thoroughly relaxed, otherwise the glands are not easily reached.

Inform yourself as to the condition of the ears, especially as regards the existence of suppuration. The hyoid bone and the thyroid and cricoid cartilages are to be examined and any enlargement of the thyroid gland noted. Move the larynx from side to side to test its mobility and the amount of creaking on the prevertebral structures and also to see if there is any tenderness. The finger placed lightly on the crico-thyroid membrane detects the narrowing of the crico-thyroid space when the pitch of an emitted note is raised.

According to Gerhard<sup>1</sup>, very important deductions can be drawn as to paralysis of the larynx by external palpation alone; but it is not my purpose here to do more than point out the advantages of a thorough external examination as a matter of routine practice before beginning internal examination.

As regards the latter, the nose should always be examined first, then the mouth and post-nasal space, and lastly the larynx.

## EXAMINATION OF THE NARES.

For illuminating the nose and throat we have at our disposal diffused daylight, sunlight, candle, oil-lamp, gas, the Welsbach burner, electric light, oxyhydrogen light, and perhaps acetylene gas. Ordinary daylight is not strong enough for the nose or post-nasal space, and is too uncertain and

*Archiv für Laryngol.*, vol. ii. p. 281.



variable. Sunlight has the merit of bringing out in their natural colors the various structures examined, but it also has many drawbacks. Its change of position, intervening clouds, and various obstructions on the earth render it very unreliable. With the concave head-mirror the rays are easily brought to a focus, and a burn may result unless we are careful to keep the illuminated area beyond the focal distance. In order to change the direction of the rays and make them more horizontal and thus better adapted for reflection by the head-mirror it is well to have them caught by a plane mirror at the window, which will reflect them at any required angle to the head-mirror. The power of the sun's rays is so great that, in spite of many drawbacks, it certainly illuminates and brings out most vividly the various tissues under examination.

The electric light is used either as a small lamp attached to the head or as a lamp fastened to the wall or table, and the rays are reflected by the head-mirror. The head-lamps have always seemed to me to be heavy and cumbersome and to have no special advantage. In the other form of lamp the light is often not bright enough and the film casts a disturbing shadow.

I have seen the oxyhydrogen light in some European clinics, but it is bulky, expensive, and not easily managed. It is used as a direct illuminant and not reflected by a head-mirror, and we shall see particularly as we examine the nose, that it is very essential to focus the light quickly at varying depths, and that in so small a space the axis of vision and of illumination should be the same and a head-mirror is indispensable.

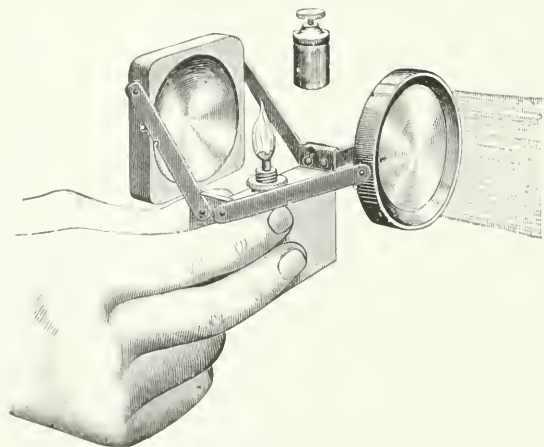


FIG. 552.—Folding lamp for laryngoscopy, ophthalmoscopy, and other uses.

An oil-lamp with a bright flame, such as the Rochester burner, or even the ordinary student's lamp, is to be recommended where there is no gas, the principal objection being the heat; but for everyday work nothing has proved itself so well suited for our purpose as gas with the Argand burner. Gas has also an advantage over the electric light in that with it we can warm our mirrors and instruments, fuse medicines upon probes, etc. The Welsbach burner gives a very brilliant light, and it is unfortunate that it is so fragile, especially when used with adjustable fixtures. The light from acetylene gas is very powerful, and objects illuminated by it look more as they do by day light than when ordinary gas is used, but it is hardly yet available.

One of the best fixtures for gas is the adjustable arm-bracket attached

firmly to the wall. This can be raised or lowered and moved in any direction. Where the light is to be on a table at a distance from the wall a movable gas-lamp with an adjustable arm is excellent. A very good little portable lamp, very compact, easily carried, and well adapted for use at the bedside is the one figured (Fig. 552).

It is advisable to have a dark chimney with a bull's-eye condenser to concentrate the light and make it more powerful, and I have found the Mackenzie condenser very satisfactory (see Fig. 553). The room need not be

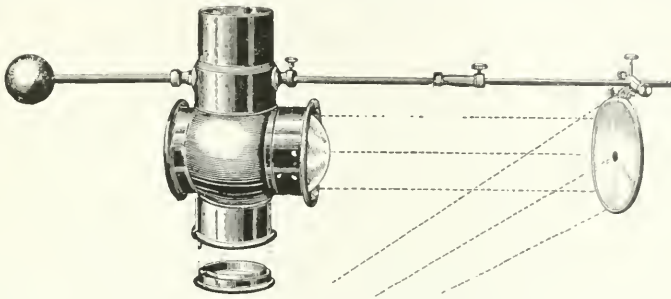


FIG. 553.—Shade and condenser.

dark, but no strong light should shine on the patient's face. He should sit in a wooden chair with a fairly straight high back without arms. For operation, a head-rest can be attached to the back, against which the head can be pressed. Women sometimes like to have a small cushion behind the shoulders or back of the head, especially if the examination is at all prolonged. The clothing about the neck should be loose, and there should always be a handkerchief in the hand and nothing else. The use of instruments is so likely to cause a flow of mucus, sneezing, gagging, etc., that a handkerchief may be needed suddenly at any moment. The hands should be in the lap, and the arm should not rest on the table, because this forces up one shoulder and makes the examination harder. The position should be an easy, natural one and without any tendency to rigidity of the neck.

The light should be on the right of the patient, on a level and about on a line with his mouth, and far enough away from the head so that the heat is not annoying—about nine inches—and when not actually in use had better be turned down. On the left hand, at a convenient height, should be some form of spittoon. The doctor sits directly opposite the patient on a light, but firm stool, with his knees outside those of the patient.

I have already spoken briefly of what we should look for externally. Notice the size and shape of the nostrils, see if the fleshy septum is directly under the cartilaginous septum, or if the latter projects anteriorly into one or the other nostril. Look for dilated capillaries where the septum presses against the skin, for cracks, fissures, skin eruptions. Try the strength of the alæ and see if there is a tendency for them to collapse or fall in and block the nose by a valve-like action.

In testing the patency of the nostrils place the finger under the opening in such a way as not to displace the parts. The sound made by the expelled air shows more or less accurately the amount of obstruction in the nose. If an oily liquid is blown into one nostril by a vaseline atomizer it should come out of the other in nearly equal volume if both nostrils and the post-nasal space are free, but obstructions in or behind the nose diminish the amount of the escaping vapor in proportion to the degree of obstruction. If a piece

of finely frayed-out absorbent cotton is held lightly in front of each nostril the amount of motion imparted to the cotton by the air as it comes out of the nose will show to a certain extent the perviousness of the nose. This method is often of use to demonstrate that, for instance, in the case of a child asleep with mouth wide open, most of the air goes through the nose and very little through the mouth. Hold the cotton in front of the mouth and then near the nostrils, and the movement of the cotton may be much less by the air from the mouth than from the nose, even when the post-nasal space is much blocked and the mouth is wide open. This is a very forcible way of showing to parents that the mouth is not doing the work of the nose.

A graphic idea of the perviousness of the nostrils can be obtained by holding a cold glass mirror horizontally under the nostrils on a level with the upper lip and noting the size and shape of the moisture which condenses on the glass on exhaling through the nose. The length of time that it requires for the moisture to disappear is also a factor in determining the degree of obstruction, the vapor from the narrow side disappearing first.

The sense of smell is tested in a general way by holding to the nostrils various volatile substances of different strengths as regards their odor and noting how they are perceived by the patient. For more accurate measurement, an instrument devised by Zwaardemaker and called an olfactometer can be used. This consists of a glass tube *C* (see Fig. 554), whose bent end

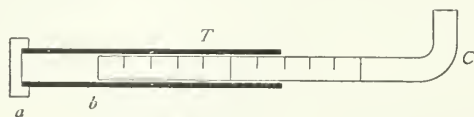


FIG. 554.—Zwaardemaker's olfactometer.

fits into the nostril. This slides in a cylinder *T*, which is made of the odorous substance or is impregnated with it. When the tube *C* is pushed to the end of the tube *T*, the inspired air contains no vapor, but the more the tube *C* is drawn out of the tube *T*, the more the inspired air will be exposed to the inner side of *T*, which is odorous. The distance to which *C* has to be drawn out before the odor is perceived, and which is indicated by the scale marked on the glass, gives the measure of the acuteness of smell. Tubes impregnated with different volatile substances are used, and the temperature of the air should be borne in mind, as the warmer the air the more volatile the substance. The perception of an irritation of the nasal mucous membrane by vapors, such as ammonia, or powders, should not be confounded with the sense of smell.

For illuminating the interior of the nose it is necessary to have a concave mirror to concentrate the light and project it in any required direction. The early mirrors were larger than many of those now in use, but possessed no advantages from their size. One with a diameter of  $3\frac{1}{2}$  inches is large enough, and the lighter it is the better. Thin glass and an aluminum back diminish the weight. A large open eye-hole gives a much better view than a small one. The head-band should be firm but not elastic. The Schrötter band with the two knobs to rest on the nose causes an unpleasant feeling of weight and pressure, and to my mind is much inferior to the simpler ones which have a padded piece to rest on the forehead over the eye. One that gives a firm support, is light, and can be folded together and over the mirror, making it safely portable, is to be preferred. An open wire band to go over

the vertex and take support under the occiput is thought by some to cause less heat and fatigue than the solid bands. The perforated hard-rubber band, shaped to the head, made by Pfau of Berlin, has the advantage of being clean, and the weight of the mirror is distributed over the whole circumference of the head. The ordinary band absorbs the perspiration and in warm weather can become foul and irritate the skin.

The mirror is usually worn over the right eye, although some prefer it over the left, claiming that it thus protects the examiner's eyes better from the glare of the lamp. It can be attached to a rod fastened to the lamp, and its weight is then entirely removed from the head (see Fig. 553). This is not a good arrangement for examining the nose, because it is necessary to move the patient's head up and down and in various directions, and the opening of the nose is so small that a slight movement of the head throws the light away from the nose and the position of the mirror has to be changed constantly by the hand. For the tonsils and pharynx and also for the larynx, when the latter is easy to see, it is more useful, because slight movements of the patient's head do not remove the light from the throat.

The nasal specula most commonly used are those of the bivalve, duck-bill, and the open wire type, with their various modifications. The open wire specula have certain disadvantages; they do not hold the hairs out of the

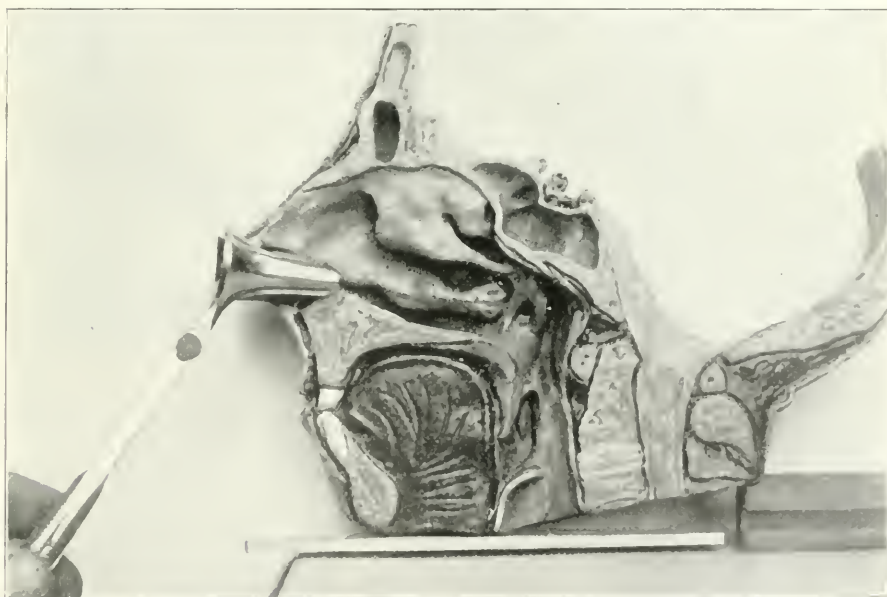


FIG. 555.—Hartmann's bivalve speculum as held for the study of the inferior turbinal and meatus (in a cast of the opened nasal chamber).

way, they have almost no reflecting surfaces, and they cut into the nose. Some of them, Bosworth's, for example (one of the best), are self-retaining in certain cases, and are useful as retractors in operating in the front of the nose, but are not so well adapted for examining the middle and posterior parts.

The duck-bill specula, of which Duplay's is one of the most generally used, are light, have good reflecting surfaces, thus lighting up well the deeper portions of the nostrils, hold the alae and the hairs well out of the way, and do not cut into the nose. They do not allow the passage of large instruments



through them, and in some cases are not well adapted for operations, but for examinations they are excellent.

Of bivalve specula there are many varieties. I have always considered that Hartmann's (Fig. 555) answered its purpose very well. A firm even expansion of the nasal orifice can be made with it, and it has good reflecting surfaces and allows the passage and manipulation of good-sized instruments. The blades are sometimes made too thick.

As a simple retractor of the ala a bent hairpin can be used and can be held in place by a tape fastened to it and then tied around the head. A nasal probe is indispensable for exploring the cavities and estimating the density and mobility of the various structures. It should be long enough to reach the posterior pharyngeal wall easily through the nose and fairly stiff. I have used with satisfaction one like Fig. 556. It is five inches long from the tip

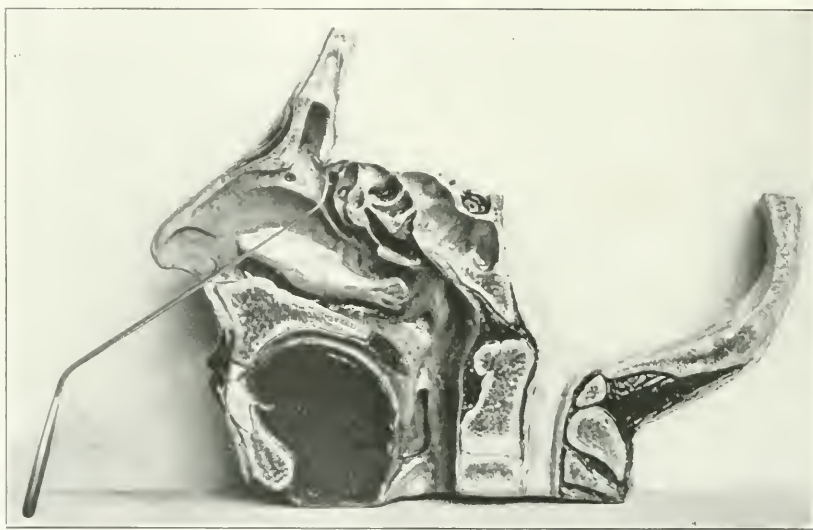


FIG. 556.—Nasal probe inserted into semilunar hiatus and infundibulum of a cast of the dissected nasal chambers.

to where it bends downward at the handle. All instruments should be warm and used very gently.

In order to get better access to the interior of the nose its tip should be lifted up by the finger so as to get a view over the anterior projection of the floor of the nose. The speculum is introduced closed, one blade resting against the septum and the other against the ala, and gradually opened. The anterior septum should be looked at while the speculum is being put in, otherwise the blade may cover small cracks, vessels, or ulcers. Students often overlook small perforations for this very reason. The thin mucous membrane of the septum can be made to bleed very easily by pressure of the end of the speculum, a thing to be carefully avoided.

When the patient's head is straight (see Fig. 555) the most prominent object on the outer wall of the nostril is the red rounded end of the inferior turbinal body, underneath which is the inferior meatus. The opening of the tear-passage into this meatus is not seen, being concealed by the turbinal. We should be able to follow this body along to near its middle and sometimes even to its posterior end, and may even see a portion of the posterior pharyngeal wall. By getting the patient to say *K*, we not infrequently see the soft

palate lifted, and if the turbinal is very small, we may see the Eustachian eminence; and the act of swallowing shows the mouth of the tube brought nearer the median line and more into view.

The turbinal is subject to great variations in size from vaso-motor influences, as well as from hypertrophy and atrophy of its tissues. Sometimes it is so large as to fill the whole anterior part of the nostril, and a mere touching with the probe may cause it to diminish perceptibly. Spraying also may have the same effect. We must distinguish between a true and an apparent hypertrophy. The former is quite firm to the probe and does not diminish appreciably in size under the influence of cocaine. The turbinal may also be very small, in which case the inferior meatus is usually large and the posterior pharyngeal wall may be plainly seen. It is important to determine whether this smallness is natural or due to an atrophy. If normal, the membrane over it will have the normal color and moisture, and the rest of the nose will be found in good condition. If atrophic, the membrane will be a dull, lusterless red, perhaps rather dry, and there may be crusts or muco-purulent secretions over it or in the rest of the nose. The posterior end of the turbinal is liable to great swelling, which can be determined by the probe from the front, or often better by posterior rhinoscopy, as we shall see.

The head should now be tipped farther back, which brings into view the middle meatus, the usual seat of polypi and the place where the openings of the antrum, frontal sinus, and ethmoid cells are found. Above this is the middle turbinal body, which begins farther back than the inferior, is less rounded in shape, and with its mucous membrane more closely adherent to the bone. It is not seen to such an extent as the inferior, as a general rule, and great hypertrophy of the latter or deviations of the septum may conceal it altogether. If the head is tipped still farther back, we can see the roof of the nose and the olfactory fissure; but the superior turbinal is not visible. The upper regions of the nose are narrow and sensitive, and the probe should be carefully used. As the olfactory nerve is distributed on the upper part of the septum and over the superior and middle turbinates we should notice whether there are any obstructions which would prevent the air from having free access to these important regions and also whether the membrane in which the nerve is distributed is normal or atrophic or covered with crusts or abnormal secretions.

Foreign bodies are usually in the inferior meatus and cause a purulent or even bloody discharge. A unilateral discharge, especially in a child, should always awaken a suspicion of a foreign body, and with the probe we are able to feel and locate it. Necrosis may also cause a bloody, purulent discharge with the characteristic odor, and should be carefully hunted for with the probe, in the upper part of the nose particularly.

On the inner side of the nostril is the septum, made up of the anterior or cartilaginous septum, the perpendicular plate of the ethmoid and the vomer. It is very uncommon to find the septum straight, dividing the nose into two equal nostrils. The cartilage is very frequently bent so as to encroach upon one nostril, or it may have a sigmoid deviation which occludes both nares. Thickenings in the shape of ridges and spurs are common. These may press against the turbinates in such a way as to make it very difficult or even impossible to see far into the nose.

To determine the thickness of the septum we can introduce the little finger into each nostril and estimate the amount of intervening cartilage; or we can make use of the septometer, such as Seiler's, whose scale gives an

accurate measure of the thickness of the structures between the ends of the blades.

If the light is thrown into one nostril, especially if it is sunlight, the color of the septum when viewed through the other nostril is much lighter where the septum is thin than in its thickened portions. A probe bent at the end when slid along a ridge or spur will show when the posterior edge has been reached.

The anterior vulnerable septal cartilage is the usual seat of epistaxis, and here we should look for dilated vessels, ulcers, and perforations.

The normal secretion of the nose is clear mucus, more copious in cold weather than in summer. The character and seat of the secretions of the nose should be carefully noted before they are removed by spray, swab, or forceps. Occasionally we meet a case where there is a very profuse and annoying flow of clear mucus which hinders our examination. A small dose of atropin about four hours before the visit serves to check this. Our great resource for obtaining a better view of the interior of the nose is cocain. This causes the turbinals to diminish in size; the amount of blood in the mucous membrane is lessened. This is of special value in hypertrophic conditions where, without it, we could see only the anterior part of the inferior turbinal. The nose should be carefully dried with cotton and a small quantity of a weak solution, say 4 per cent., placed against the tissues which it is desired to diminish in size. This is much wiser than spraying the solution indiscriminately into the nose. When the anterior obstruction is diminished, another application can be made farther in. The nose should be first examined as thoroughly as possible without the cocain; for this, while rendering the deeper structures visible, blanches the tissues and so changes their aspect that we might be entirely misled unless we knew the condition before the cocain was applied.

Yet, even with the help of cocain, we shall find some nostrils so narrow and tortuous and the external orifice so small and even pointing downward that we can get but a very imperfect view of the interior.

#### ACCESSORY CAVITIES.

Within the last few years the accessory cavities have begun to attract the attention they deserve. The antrum, frontal sinus, and anterior ethmoidal cells open into the middle meatus (see Fig. 556); the posterior ethmoidal cells and the sphenoidal sinus open into the superior meatus. If a discharge of pus is seen in the upper part of the nasal chamber, when not due to necrosis or a foreign body, it probably comes from one of these cavities. In early life they are very imperfectly developed; but in later life, especially since the epidemics of influenza, their diseases are seen to be not uncommon.

The largest and most frequently affected cavity is the maxillary antrum, which has its outlet at the top and empties into the middle meatus by an opening which is usually concealed by the middle turbinal, under which pus from the antrum makes its appearance. If this pus is thoroughly removed and the head bent forward and downward, with the side of the face corresponding to the suspected antrum uppermost, pus will thus more readily run out of the natural opening and can be seen under the middle turbinal when the patient again sits upright.

Transillumination often gives a certain amount of information as to whether the pus is located in the antrum, and should always be tried before making an exploratory puncture. Unless the room can be made absolutely

dark, it is well to use a piece of black cloth, such as photographers use in focussing, or a black rubber sheet which can cover the heads of examiner and patient, and when tightly held under the chin shuts out effectually every ray of light. A small electric light (Heryng's is good, but there are a number of others) is placed in the mouth above the tongue and the lips are tightly closed. All tooth-plates should be removed. When the electric light is turned on, the healthy antrum should allow the light to pass through it and show a crescentic bright area under the eye, and sometimes the pupil is lighted up (see Plate 14). The patient should also have the subjective sensation of light in the eye with the eyes closed. In case the antrum is filled with pus or any opaque substance, this area and sensation of light are entirely wanting. This method is often of great value as corroborative evidence; but too much reliance should not be placed on it, because there are cases in which the face fails to be lighted up when the antrum is empty, even when the bony walls are not abnormally thick. But I think we may safely say that where there is a discharge of pus under the middle turbinal and that side of the face remains absolutely dark without sensation of light in the eye, while the other side is brightly illuminated with sensation of light, the chances are very greatly in favor of our having to deal with empyema of the antrum (see page 970).

To make sure that the antrum is the part affected we can wash it out in various ways. A hollow cannula, such as Hartmann's, can be passed along under the middle turbinal till it comes to the neighborhood of the natural

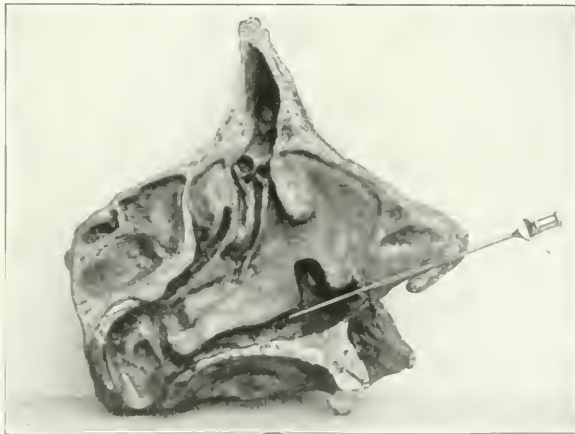


FIG. 557.—Hajek's straight cannula inserted for puncture of the antrum-wall in the inferior meatus (in a cast of the nasal chamber, dissected to show the lachrymal duct, the infundibulum, etc.).

opening and then turned outward, and it can sometimes be felt to enter the opening. A syringe attached to the cannula may be used to suck the pus out, or warm water may be forced in, and the stringy flocculent pus which appears shows its antral origin.

In case the opening is not found, it is possible to perforate the outer wall of the middle meatus with a trocar and wash out through this artificial opening, the pus escaping through the natural opening or one or more accessory openings which may exist. Care should be taken not to puncture too deep for fear of entering the orbit. Cocain should be used for these manipulations, both to produce anesthesia and also to cause a shrinking of the tissues and gain room. It may be necessary to remove the anterior end



of the middle turbinate to gain greater freedom for the cannula. Pieces of polyp and granulations, if present, should also be removed.

I have preferred to make the exploratory puncture in the outer wall of the inferior meatus, about the middle third, where the bone is usually thin. For this the curved trocar, such as Krause's or Myles's can be used, or the straight hollow needle of Hajek (see Fig. 557). This is passed along under the inferior turbinate to the proper spot, and is then pointed outward and pushed through the bone into the antrum, when the washing out follows, as above described. If a tooth has recently been extracted, the alveolar socket may be so thin that a cannula can be passed easily through it into the antrum. The alveolar process can be perforated through the socket of the bicuspids or molars or between the roots of the teeth. These latter places, as well as the canine fossa, are generally chosen in carrying out treatment rather than for simple diagnostic purpose.

In case we find that the pus in the middle meatus does not come from the antrum, we should look to the frontal sinus and the anterior ethmoidal cells. The former is reached through the infundibulum by a small hollow sound or cannula (see Fig. 556). This is often difficult, and it may be necessary to remove the anterior end of the middle turbinate. If pus is brought away on the sound when it enters the infundibulum, or if washing out the cavity through the cannula shows pus, the frontal sinus is presumably the seat of disease, as it may be when the antrum is filled by its discharge.

We can also make use of transillumination by covering the electric lamp with a thick piece of rubber open at the end so as to throw the light in one direction only. The rubber is placed against the roof of the orbit, not too near the thick orbital ridge (see Plate 14), and pressed upward, inward, and backward. The healthy sinus may thus be lighted up and show an illumination over quite an area. In case one side is light and the other not, it will give us an intimation that the dark sinus may contain pus. But the frontal sinus is so irregular in contour and size that we must not lay too much stress on this mode of examination.

The anterior ethmoidal cells are entered by passing the probe upward between the middle turbinal and the outer wall into the hiatus semilunaris (see Fig. 556). The opening is near that of the frontal sinus, and the end of the probe should be bent at a right angle.

The opening of the sphenoidal sinus can sometimes be seen when the turbinals are very much atrophied. The anterior wall is usually about seven centimeters from the anterior nasal spine. A probe passed along the anterior part of the floor of the nose upward and backward between the septum and the middle turbinal, crossing the latter a little posterior to its center, should reach the anterior wall of the sinus (see Fig. 555).

#### EXAMINATION OF THE PHARYNX.

The lips, cheeks, teeth, palate, tongue, and floor of the mouth should be carefully examined for ulcers, cicatrices, fissures, swellings, ranula, tongue-tie, etc.

For the tonsils, pharynx, and post-nasal space a tongue-depressor is necessary. It is possible to get something of a look at the fauces by pressing down the tongue with a spoon, pencil, paper-cutter, the patient's finger, or even without any instrument, the patient saying "Ah!" during a deep inspiration, but no thorough examination can be thus made. The depressor of Türk is one of the oldest and has the advantage of resting at the corner

of the mouth and is easily held by the patient when the examiner desires to use both hands in examining or operating.

The narrow-bladed depressor of Fränkel is much used and holds down the center of the tongue well and takes up but little room in the mouth. But I have found the sides of the tongue likely to be raised on either side of the instrument, shutting off the sides of the throat and the base of the




FIG. 558.—The author's tongue-depressor.

tonsils from view. It has not seemed to me to take a sufficiently strong hold on enough of the tongue to keep it steady and out of the way. I prefer a broader, thin blade with a fenestrum, somewhat concave from side to side and also from front to back. About an inch in width at its widest part and from 3–3½ inches in length gives a blade which keeps the sides as well as the center of the tongue out of the way (Fig. 558).

In open wire depressors the tongue is very apt to protrude between the wires and obstruct the view; and folding depressors, although portable and convenient, are not always stiff enough.

The proper use of the tongue-depressor is of great importance and is the key to a correct examination of the throat and post-nasal space. The patient should be told to open the mouth, but not too wide, and to keep the tongue inside the mouth, its tip against the lower front teeth. He should then say "Ah!" in a natural voice without contracting the throat. When he has said this several times the tongue-depressor is taken in the hand and carried over the tongue till the end of the blade is well over the dorsum where the tongue begins to curve downward, and while "Ah!" is being spoken the instrument presses downward and pulls forward the base of the tongue. If the handle is held between the thumb and forefinger, the middle finger placed under the chin acts as a fulcrum and the third and little fingers pull the handle upward and consequently help to depress the tongue still more. With the tongue, chin, and depressor thus firmly held, the patient's head can be moved up or down or sideways, and is well under the control of the examiner (Fig. 559).



FIG. 559.—Tongue-depressor in position for examining the fauces, with finger under the chin.

There are, however, many cases where this is a very difficult undertaking. A short, thick, muscular tongue requires considerable force to make it lie down; a strong but steady pressure should be used. Some patients have such irritable throats that they gag even before the tongue-depressor

touches the tongue. Great patience is needed and many trials. It is sometimes well to endeavor to turn the patient's attention from what you are trying to do by getting him to say "Ah!" several times in a loud tone while you try the depressor. Immediately after a meal there is a greater tendency to gagging than when the stomach is nearly empty, and the visit should be timed accordingly. If there is secretion on the posterior pharyngeal wall, it should be removed, because it tends to cause gagging when the tongue is held. The nose and post-nasal space should be freed from secretions, as free nasal respiration makes it easier to have the tongue held. The gagging of the alcoholic may be almost impossible to overcome, and in such cases it is well to try a few doses of bromid. Pieces of ice held in the mouth diminish the irritability.

In case we find our patient still unable to allow a satisfactory view of the throat we can generally succeed by painting the posterior pharyngeal wall with a 5 per cent. solution of cocaine. The unpleasant sensation of suffocation and of a foreign body impossible to dislodge soon disappears, and the patient should be told of this. A fairly stiff probe is of great use in examining the tonsils. If passed between the anterior pillar and the tonsil, it shows the presence or absence of adhesions. It should be passed into the crypts to determine whether they contain cheesy secretions or tonsilliths. A dull wire curette is valuable for searching under the anterior pillar and in any deep depressions in or about the tonsil. The probe can also pull the tonsil from its bed and render it more visible and bring out more clearly the size of its attachment to the side of the throat. During gagging the tonsils are everted, approach the median line, and appear much larger than they really are, consequently they should be examined while at rest and in their natural position. If one fore-finger is placed under the angle of the jaw and the other in the mouth against the tonsil or soft palate, we can determine the density of the tonsil, whether it contains a hard concretion or a cyst, and also the presence of fluctuation.

#### POST-NASAL SPACE.

For the post-nasal space we make use of the rhinoscopic mirror, which should have a size corresponding to the distance between the soft palate and the pharynx-wall and also between the uvula and the tonsil. The common size is about half-an-inch in diameter, but for children, especially where the tonsils are large, one-half the size is large enough. In some cases where there is plenty of room and the parts not sensitive, we are able to use a laryngoscopic mirror. The usual angle of the mirror to the shank is about  $105^{\circ}$ , but mirrors are also made with a joint by means of which any desired angle can be obtained. The head should be held a little forward. After warming the mirror, to avoid condensation of moisture, it should be held like a pencil, the reflecting surface upward and passed parallel to the surface of the tongue until the uvula is reached. It should then be turned diagonally and passed between the uvula and the tonsil, usually to the right of the uvula and then behind and below the soft palate, with the reflecting surface facing upward and forward. The patient should be directed to breathe through the nose and try to say "en" with a strong nasal tone.

The view obtained is of a part only of the post-nasal space at a time, and the mirror has to be turned in order to see the different parts in succession. It is very important to have the base of the tongue well pulled forward so as to have plenty of room for this manipulation of the mirror. The landmark

for which we look is the back of the vomer, which is of a yellowish gray color, broader at the top than lower down. The middle turbinal is generally more prominent than the inferior, whose lower half and the inferior meatus are often not visible. These structures are lighter colored, more gray, than their anterior ends. High up we may see on one or both sides the small superior turbinals which are not visible through the anterior nares. The mirror has to be turned considerably toward the sides in order to see the Eustachian prominences with their yellowish, crater-like openings, over the edge of which a small red vessel is often seen. Behind the prominences are

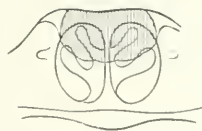

FIG. 560.—Adenoid hypertrophy as seen from the front, showing its true relation.

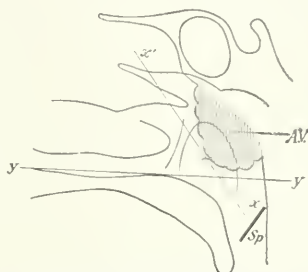

FIG. 561.—The same growth apparently far less dependent, as seen by posterior rhinoscopy (Zarniko).

the fossæ of Rosenmüller, perhaps irregular at the bottom, or there may be bands of adhesion stretching across to the prominences. The pharyngeal vault should be dome-shaped and is often irregular. In the center we may find a cleft, the median recess, whose depth can be told by passing into it behind the palate a suitably curved probe, which can also give information as to the density and extent of any thickened tissues at the vault. The mirror

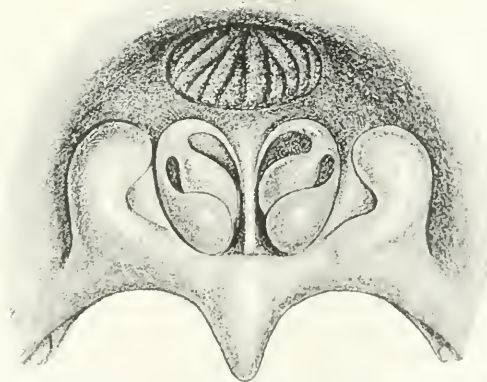


FIG. 562.—Post-rhinoscopic view of the septum, choanae, Eustachian tube-mouths, soft palate, and pharynx-vault (after Heymann).

alone sometimes gives an inadequate idea of the amount of hypertrophy at the vault, as will be readily seen by looking at Figs. 560 and 561.

We will suppose that there is a growth which reaches down to the lower border of the inferior turbinal. When looked at through the anterior nares we see the growth hanging down as far as the inferior meatus, represented by the dotted line. The rhinoscopic mirror, however, seems to indicate that its



lower margin is on a level with the superior meatus, and is consequently of much less extent than it really is. In such a case it is well to hold the mirror more horizontal and look at the posterior end of the growth, if that is possible, when we may find that it hangs down farther than we had first supposed. But a much better way is to make use of digital exploration, as we often have to do when no post-nasal examination is possible. The examiner stands at the side of the sitting patient with his arm around the patient's head, and in the case of a child it is well to press the cheek in between the teeth, which serves to keep the mouth open and also prevents the biting of the examiner's finger. A metal finger is often used as protection against the sharp lower teeth, or a mouth-gag may be employed.

The forefinger of the doctor's hand, the palmar side up, is then passed along the side of the mouth to the tonsillar region and then behind the soft palate, being very careful not to carry the uvula or palate with it. The elbow is well depressed and carried in front of the patient and the finger feels for the septum, turbinates, Eustachian eminences, the vault, and can thus estimate very accurately the amount and character of any obstructions, whether central, near the choanae, how much of each posterior naris is covered, and whether the growths are on the posterior wall. The examination should be short but thorough, and may be unsatisfactory unless the child is firmly held. It should follow and not precede other methods of examination, because the child has usually had all the examination he will submit to when the finger has once been behind the palate.

Still another way of seeing the post-nasal space is advocated by Katzenstein of Berlin,<sup>1</sup> who calls it autoscopic. The patient lies on his back with the head hanging down as far as possible. The mouth is then opened and the tongue drawn forward, as in laryngoscopy. A palate-retractor, resembling an eyelid-retractor, is then placed behind the uvula, and by slowly and gradually increasing the force used the palate is drawn so far forward and downward that we are able to see the posterior pharyngeal wall, the vault, the Eustachian eminences and openings, the plica salpingo-palatina, the plica salpingo-pharyngea, and the fossa of Rosenmüller. The septum, turbinates, and choanae are not visible. Post-nasal tumors and adenoid hypertrophy can be seen and operated on in this way without a mirror, and the catheter can be placed directly in the Eustachian tube without having to pass it through the nose. Strong illumination is necessary here, as in all examinations of the post-nasal space.

The obstacles to rhinoscopic examination are many. The tonsils may be so large as to prevent the introduction of even the smallest mirror. A very broad uvula may interfere, in which case we can hold it to one side or lift it by a palate-retractor. The distance between the soft palate and the pharynx may be so small that there is no room for the mirror. By using a little cocaine on the back of the palate we may be able to pull it forward by the palate-hook and gain space enough for a small glass.

Where the fauces are of sufficient size the attempt to pass the mirror behind the palate often causes the latter to be drawn back against the pharynx-wall, even when the mirror has not touched the tongue, uvula, or pharynx. The mere presence of the mirror, whether by interfering with the passage of the air or by acting on the mind, is enough to excite movements of the palate. A very small mirror may be tolerated when a large one is not. I have sometimes succeeded by passing the tongue-depressor on the side of the tongue instead of in the center and pushing the tongue over

<sup>1</sup> *Arch. f. Laryngol.*, Band v. p. 283.

to the other side. Thus room enough is gained near the tonsil for a small glass, and the patient does not have so much the feeling that the tongue is being held down.

I have already spoken of the need and value of a weak solution of cocaine in the pharynx, and it is also well to paint a little on the back of the palate.

A good many self-retaining palate-retractors have been devised to hold refractory palates out of the way, and that of White is probably as good as any. One end goes behind the soft palate and the anterior branches are placed on the outer side of the lip, one on either side of the nose. I have found, however, that cases that needed them generally did not tolerate them; and when they were well borne that they were not necessary. The palate may be held forward by tapes or rubber-bands passed through the nose, drawn down behind the palate and out of the mouth, and tied over the upper lip. This method is more commonly used in operating than in examining.

### LARYNX.

The lingual tonsil and the glosso-epiglottic fossa are not well seen by using the tongue-depressor, although it is occasionally possible to pull the tongue sufficiently away from the epiglottis to get a view of part of the region. But we succeed so much better with the laryngoscopic mirror that this examination is generally combined with that of the larynx. The forefinger passed all around the base of the tongue gives a very good idea of the amount of tissue present, its character, whether inflammation or suppuration are present, and can often detect foreign bodies which find here a convenient lodging place.

For looking at the larynx the usual method is to have the patient's head held well back and the extended tongue held between the thumb and forefinger of the examiner. This lifts the whole larynx. Care must be taken not to pull the tongue too hard, especially when it is sore or the teeth sharp and rough. For a mirror we use a glass about an inch in diameter, although if the fauces are small or the tonsils large, and usually in children, we have to choose a smaller size. On the other hand, in adults we can sometimes use one much larger, and with one the size of a silver dollar I have obtained a very satisfactory view. The shank should be quite stiff, and I have been surprised to find so many slender and flexible ones in the market. Those sold in students' sets are often too flimsy for actual use. A stiff, firm handle, shank, and mirror are much more easily borne by the patient. The mirror figured (Fig. 563) is one that I have found excellent.

The glass should be warmed over the lamp and the metal back tested against the ball of the thumb to insure its not being too hot. The handle is then taken between the extended fingers and thumb. The mirror is introduced with the glass side down, above and parallel to the dorsum of the tongue, but without touching the latter. The patient is directed to say "Ah!" and as he does so the base of the tongue is lowered and the soft palate is raised. The mirror is placed under the uvula, which it carries backward and upward, and the glass is pointed downward at an angle of about 45°. This is the position for looking into the larynx; but it is well before this to look at the base of the tongue. For this purpose we hold the mirror nearly horizontal and near the posterior edge of the hard palate. We can thus look directly down on the base of the tongue, or if we carry the mirror back to the uvula we must slant it farther forward than as if to look

into the larynx. We should note the region of the circumvallate papillæ and the glosso-epiglottic fossa, which should normally be free and rather smooth. If hypertrophy of the lingual tonsil is present, we see red, rounded, raised masses filling the whole or a part of the space or even crowding upon the epiglottis, or we may find it acutely swollen, with yellow or white spots on the surface, or false membrane or ulceration. A smooth atrophy in this region is thought by some to be characteristic of syphilis.

Coursing over the base of the tongue in adults we may see large, dilated, or varicose vessels, looking not unlike rivers in the atlas.

After having examined the region anterior to the epiglottis, we place our mirror to look into the larynx, as spoken of above. The epiglottis is now

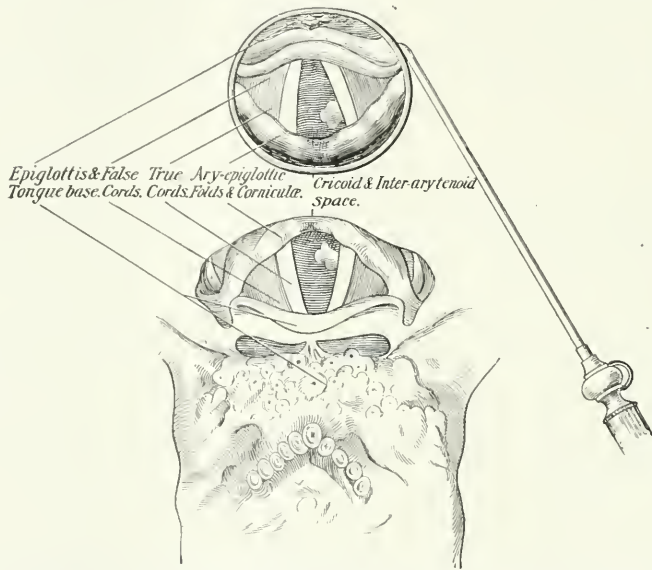


FIG. 563.—Schematic view of tongue-base, epiglottis, arytenoids, and ary-epiglottic folds, ventricular bands and vocal cords, with the laryngoscopic reflection. A polyp shows below the left cord (after Schröter).

the great obstacle and the patient should be told to say "Ah!" or what is still better, to take a number of deep breaths and say "ch!" during the inspiration. This serves to lift the epiglottis. If not successful at first, we are generally rewarded after a number of trials by seeing it gradually lift. We may at need spray a little cocain into the larynx or paint the posterior surface of the epiglottis and hook it forward with a bent probe, the patient holding the tongue.

The epiglottis varies greatly in shape and position. It is usually of a reddish-yellow color, and its free edge is thin. It may be erect or pendulous, hanging completely over the larynx, or in any position between these extremes. In children it is generally bent more backward than in adults. It may be rounded, incurved in the center of its free edge, omega-shaped, its edge turned over, etc. It is sometimes not symmetrical, and may not be in the median line. The mucous membrane is much more closely adherent to the posterior surface than to the anterior, so that swellings, edema, or cysts are more often found on the latter. Low down on the posterior surface we see the projection called the cushion (see Fig. 511), which is at times quite marked. Extending downward from either side of the epiglottis

toward the median line and the posterior part of the larynx we see what are called the ary-epiglottic folds, which are narrow near the epiglottis and become wider as they descend. The two rounded projections on either side of the median line are the small cartilages of Santorini and Wrisberg, and below them are the arytenoid cartilages, whose form is not definitely seen. These structures are covered with a reddish membrane in health. Between the arytenoids is the interarytenoid space, where hypertrophies of various kinds are likely to occur.

The vocal cords are the pearly-white bands which stretch across from their anterior commissure at the inner angle of the thyroid cartilage to the vocal processes of the arytenoids posteriorly. In respiration the posterior ends separate, leaving a V-shaped aperture, but in phonation they lie parallel to and nearly or quite in contact with each other. Just above the cords is a dark space, the opening of the ventricle, more plainly seen when the larynx is thin and relaxed. Just above and outside the mouths of ventricles are the ventricular bands or false cords, which are of a red color.

Below the true cords we see a little of the inner side of the cricoid cartilage, and farther down a number of transverse white bands, the rings of the trachea, and consequently the anterior wall; and occasionally we can even

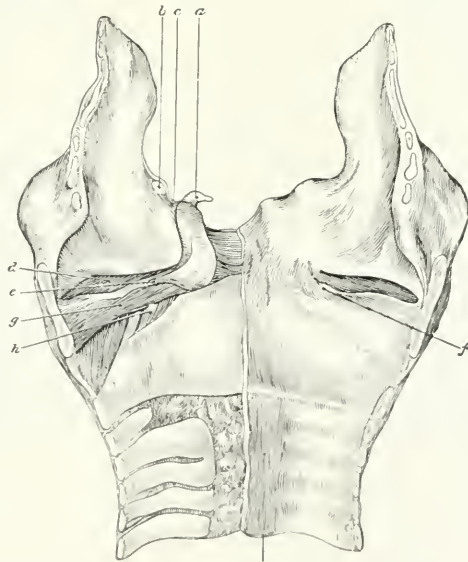


FIG. 564.—Larynx opened from the front and partially dissected on the left showing the anatomical relations of the cords, *c, f*, ventricles, *d*, corniculae *a*, and epiglottis (schrötter).

see the bifurcation of the trachea and the opening of the bronchi. Outside of the ary-epiglottic folds are the pyriform sinuses; and the cornua of the thyroid cartilage may sometimes be seen as whitish elevations in their floor.

In the mirror these laryngeal structures look as if spread out in one plane; but study of the excised larynx (Fig. 564) shows very forcibly what should be borne in mind while using the mirror—that they are on very different planes, and that from the top of the middle of the ary-epiglottic fold down to the top of the vocal cord is about an inch. It is of great service to study a model or a larynx removed from the body as a preliminary to using the mirror.



The objects looked at in the mirror are seen as if inverted; that is, the anterior commissure of the cords is at the top of the mirror and apparently points backward, whereas the arytenoids are on the lower side of the mirror and seem to be anterior. The figure (Fig. 563) will illustrate my meaning. In using the probe to touch the different parts of the larynx it is necessary to bear this inversion in mind, and it is well to practise on a model. It has seemed to me that students have more difficulty in passing the probe backward against the anterior face of the interarytenoid space than forward toward the anterior commissure when trying on the excised larynx.

There are many difficulties in the way of obtaining a good view of the larynx. A short, thick tongue, perhaps even tongue-tied, may be almost impossible to hold with the fingers or may fill up so much of the mouth as to leave very little room for the mirror and the light. We may then find it better to use the tongue-depressor and draw the tongue forward with it so as to make room at its base for the mirror. If the throat is very irritable we can spray cocaine into the larynx or paint the pharynx or use pieces of ice.

In children the epiglottis is often bent over the larynx in respiration, and the glottis is difficult to see. To overcome this the long, curved tongue-depressor of Moutt Bleyer can be used, which goes behind the tip of the epiglottis, lifts it and also the whole larynx to some extent, or the tongue-depressor of Es-cat may be tried. Its branched ends are placed behind the sides of the epiglottis in the pyriform fossa, and so pull forward and upward the epiglottis as to open up the entrance to the larynx, and a view can be obtained with the mirror. A mouth-gag may be necessary.

In the ordinary examination with the head thrown well back the face of the mirror is so turned as to show the anterior wall of the trachea. If the head is bent well forward while the patient is standing and the examiner, kneeling in front of the patient, holds the mirror well up against the uvula, a very different view is obtained. Instead of the anterior part of the larynx and trachea we see the posterior wall, sometimes even as far as the bifurcation. This is the method of Killian, and is valuable for looking at the posterior part of the larynx, the posterior ends of the cords and underneath their surface. It is not always easy to carry out, as the position of the examiner is not a comfortable one. The saliva runs out of the mouth into the doctor's hand and up his sleeve, so that it is well to have the patient expectorate before we use the mirror. The light does not come in a suitable direction, and the head-mirror is usually beyond its focal distance from the throat-mirror. If the examiner wears glasses they may also be an obstacle from the unusual position of the head. But in spite of these difficulties the view of the posterior part of the larynx and trachea is often very striking and gives information not to be obtained by the ordinary method.

The larynx can also be viewed by transillumination in a dark room. The electric lamp, such as is used for the frontal sinus, is placed against the front of the neck in the neighborhood of the cricoid cartilage. The tongue is held and the mirror passed as in ordinary examinations, only no light is thrown in through the mouth. The larynx is seen in the mirror to be illuminated by a light which traverses the tissues of the neck and gives a yellowish-red look to the parts quite different from the usual examination. It was hoped that this method would be of great service in determining abnormal densities of the different tissues traversed by the rays of light, but it is not much used for that purpose at present.

PLATE 13.

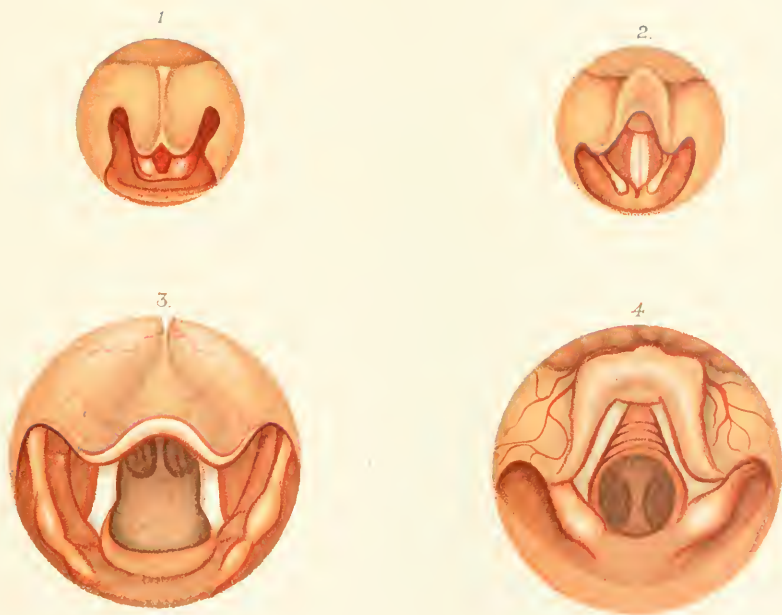


FIG. 1.—Larynx of a child in quiet breathing, nearly covered by the epiglottis.

FIG. 2.—The same during phonation, with the epiglottis raised and the cords in apposition.

FIG. 3.—Adult larynx and trachea to the bifurcation in deep inspiration, showing the back wall by Killian's method, with the chin low and the head inclined forward.

FIG. 4.—Usual view of the normal larynx and front wall of the trachea to the bifurcation (from Krieg's Atlas, with slight modification).



## AUTOSCOPY.

Under this name Kirstein has reverted to the oldest method of examining the larynx. No throat-mirror is used, but the base of the tongue and the epiglottis are drawn very much forward by a specially-constructed tongue-depressor, and the examiner looks directly down into the throat illuminated by an electric lamp or by light reflected from a head-mirror and sees the posterior part of the larynx, the arytenoids, perhaps the posterior half of the cords, and the posterior part of the trachea. The patient should have a yielding tongue and neck to give good results. He should be seated, the upper part of the body thrown forward and the head tilted slightly backward. The physician stands in front, and places the depressor as far back as possible on the tongue with firm pressure downward and forward on its root, whereby a deep groove is formed, allowing the rays of light to fall in line with the laryngo-tracheal axis.

According to Kirstein, in about one-fourth of all adults the whole larynx

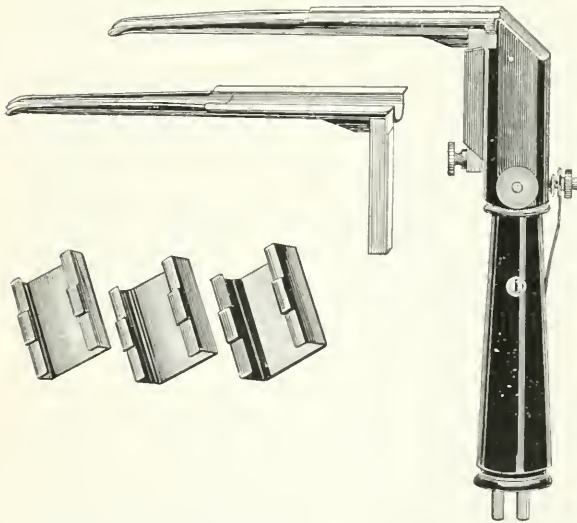


FIG. 565.—Kirstein's laryngoscope with electric light attachment and interchangeable depressor (Thorner).



FIG. 566.—Position of neck and head during examination with the electric autoscope (Thorner).

and trachea can be thus conveniently examined, except that the extreme apex of the anterior commissure can be seen in but one-tenth of all cases. About one-half of all people can be fairly well examined, so that the posterior region of the larynx, including sometimes a more or less extensive portion of the trachea, is exposed to view. This method, he claims, is applicable to children under anesthesia, and sometimes without anesthesia. This needs corroboration, and the method is in no sense a substitute for ordinary examination with the mirror, which gives us in most cases all needed information.

## THE RÖNTGEN RAYS.

The X-ray has served to locate foreign bodies in the air-passages and esophagus. The nose and upper throat are so accessible by our present means of illumination that it is not of the same help to the laryngologist as to the general surgeon.



## THERAPEUSIS AND PROGNOSIS.

BY GEO. A. LELAND, A. M., M. D.,

OF BOSTON, MASS.

**General Therapeusis.**—Treatment in the diseases of the upper passages may be divided into general and local, the former of which may first be considered. And it may be premised that these regions are not to be considered as separate from the rest of the body, but as a part of it, and not only influencing it but being influenced by it—the corollary of which is that they are not always to be subjected to local treatment alone, but that the general diseases and conditions of the body are to be taken into account. For it will frequently be found that general treatment is far more efficacious in the removal of some of the manifestations of disease in the upper air-passages than local treatment, which is so often, in these days of enthusiastic specialism, given the most prominent, if not the only, place in the thoughts of some so-called laryngologists. An early recognition of these conditions may often save the patient from much discomfort and expense, and the physician from no little anxiety and apprehension. For many local manifestations of general disease are only aggravated by local treatment—*e. g.*, an acute gouty pharyngitis, late syphilitic tumefactions of the tonsils, the first swelling of late syphilis in the nose, the laryngeal papillomata which precede malignant disease, and so on.

Aside from the exanthemata (including typhoid fever) with their characteristic throat manifestations, which will doubtless be discussed in their proper articles, there are some common, every-day conditions which cause much discomfort and no little alarm. One of the most common of these is rheumatism, where there is very little to be seen. The faucial and pharyngeal mucosa shows but slight redness, often in small areas, variable in their locations, more or less early in the day. The history, not only of the individual, but of the family near and remote, assists in the diagnosis. The lithemic diathesis perhaps shows frequent manifestations not only in him, but in various members of his family, even in several generations. In such a throat it is not rational to suppose that the local exhibition of the usual sprays or pigments will produce more than a very transient amelioration, and may, especially the latter, produce only discomfort; this, however, may yet serve a purpose by making the throat seem so much worse that when the irritation subsides the patient considers himself better. It is here that general remedies directed to the diathesis are to be employed. The correction of ailments of the *prima via*, such as gastro-intestinal catarrh, and regulation of the bowels; the exhibition of the lithic solvents, such as the various salts of potash and lithia, the salicylates and salicylic acid (always, however, using these last either not at all or with great caution where there is a tendency to deafness from middle-ear or labyrinthine lesions), piperazin, etc.; the regulation of diet, especially as to the ingestion of foods containing uric acid, and the xanthin

group, notably red meats and tea and coffee according to Haig,<sup>1</sup> urging the importance of drinking large quantities of pure water (the English rule being 3 to 5 pints daily)—these among other measures may be mentioned. The solvent action of some of the alkaline tablets, dissolved slowly in the mouth and followed by a copious draught of water, is often of local service, notably those prepared from the Ems Springs by evaporation, and known as the Ems pastilles.

It is notable that in his discussion of general therapy for disease of the upper air-passages, Dr. Phillip Schech devotes a page and a half to the mention and recommendation of mineral waters.<sup>2</sup>

A peculiar manifestation of the lithemic diathesis, and a very distressing one, is the dry mouth and throat rarely complained of by the aged. The salivary and mucous secretions are nearly if not quite absent; the tongue is dry and parched and at times painfully cracked; deglutition is almost impossible. The urine will show almost no color, very light specific gravity, and very small amounts of uric acid and especially of urea. Here some of the measures above noted, assisted at the onset and perhaps longer by minute doses of pilocarpin muriate or nitrate, will produce wonderfully satisfactory results, while the whole gamut of local applications may be tried in vain.

Another form, perhaps, of lithemic diathesis, or at any rate of mal-assimilation, is the thick throat associated with obesity. The faucial appearances here are those of a very narrow space behind the velum, the surface of which is thrown into rugæ by gagging and phonation, thus almost entirely closing the passage. This thickening can most probably not be gotten rid of by local applications without danger of producing too great reaction, and later even cicatrices, which may leave the throat in a worse condition than before. Treatment should be directed to the general condition; to the digestion, both gastric and intestinal; to the action of the liver and the kidneys. And it is possible that we may hope from the study of glandular therapy to find that some of these cases are due to a greater or less degree of Basedow's disease, as was well shown in the report of a case of "myxedema of the throat" by Dr. Farlow, in the last "Transactions of the American Laryngological Association."

In the writer's experience some cases of submucous thickening of the throat have apparently been much benefitted by the exhibition of thyroid extract. Of course, in cases of thickened hypertrophic pharyngitis a local cause may be found in improper nasal respiration, which, as will be referred to in its proper place, can be corrected.

Closely allied with these rheumatic diatheses is the gouty; and it will be found of great value to recognize its acute or chronic manifestations. In its acute form we find a crimson-red, thick, shiny mucous membrane of the pharynx and fauces, where the characteristic feature is the extremely acute pain, much aggravated by swallowing, which seems much more than the manifestations call for. It would be hopeless to use sprays except for slight and transient benefit, and the usual pigments would only produce extreme discomfort for a longer or shorter time. It will be found in the history of such a patient that he has perhaps had some gout before in other and more usual locations, and that he has remedies which he is accustomed to use; and these will doubtless produce a much more satisfactory cure of his throat than other means. And so also in the chronic gouty throat or in the throat convalescing from the acute stage, which has lost its shiny reddened appearance

<sup>1</sup> *Uric Acid in the Causation of Disease*, A. Haig, 1896.

<sup>2</sup> *Die Krankheiten des Kehlkopfes und der Luftröhre*, 1897, pp. 50 and 51.

and has become flabby and pale with a muco-purulent, viscid, sticky secretion, remedies directed to the diathesis are much more efficacious than those for local application, except so far as they are beneficial as cleansing agents. In all these conditions allied to the lithemic diathesis it is necessary to pay a great deal of attention to the diet; and here a general physician who has a thorough mastery of the physiology and pathology of digestion, or the throat specialist who adds this also to his specialty, will have greater success than he who simply treats locally.

There is another condition described as neuralgia of the throat where there is a great complaint of painful sensations both at rest and upon movement, especially probably in the latter part of the day, and the pain is of a sharp and lancinating quality; here local applications are absolutely contra-indicated, since they generally produce an aggravation of the discomfort. It will be found that the patient is anemic or neurasthenic and that general treatment is much more serviceable than local. Here, however, it may be said as applying to this condition, as well as to those which have been before mentioned, that where the symptoms are especially referred to any one part, the patient feels much better to be doing something; and while not much is to be expected from local treatment *per se*, some simple gargle may be prescribed as a placebo.

Another painful condition of the throat is to be found in hardworked individuals, especially professional men. It is not infrequent that overworked physicians, clergymen, teachers, and even lawyers have a painful condition of the throat come on at the end of the day: this is simply a condition of muscular and nervous fatigue, in which local applications are of little benefit, but where rest, and tonics like *nux vomica*, are very efficacious. It is not infrequent to have an overworked physician drop into the office late in the day complaining of just this fatigue of the throat, and it is with great satisfaction that we can assure him that there is no alarming malady threatening. Public speakers doubtless have this trouble much aggravated by an improper use of the voice, and the so-called "ministers' sore-throat" is often but the result of the American method of talking back in the throat with indistinct articulation—swallowing of the words, as the Germans call it. Correction of bad habits, with attention to the general condition of the patient, will here give the best results. Some of the lozenges may be of assistance to reduce hyperemia or to induce moisture when there is a sense of dryness, but they are merely palliative; the underlying cause must be sought out and abolished.

In this place may be mentioned a peculiar condition of the pharyngeal mucosa characterized by thickening, pale pinkish color, sluggish scanty secretion, and obstinacy under treatment, which, on the exhibition of iodids and perhaps mercurials, will seem to be due to a latent taint of specific disease, although the history is doubtful or absolutely negative and there are no other lesions to be discovered in ordinary examination. This is not very common, but should always be borne in mind; and it will be found that this treatment does not always have to be used as a *last* resort. The pathology of this condition has probably not been thoroughly worked up; but it may be said in general, judging from clinical observation, to be a submucous infiltration with more or less involvement of the superficial lymphatic structures which have a rather pale and asthenic appearance. These may easily break down in a superficial loss of substance with a grayish base; not the usual appearance of a mucous patch, but more nearly that of a superficial abrasion from rough treatment, a scraping off of the surface, as it were. It may not be true that



these appearances are always due to specific disease; but it has happened to the writer to have them clear up so kindly under the iodid of potash or syrup of hydriodic acid, perhaps assisted by biniodid of mercury, and afterward to find an obscure history of infection, that it does not seem to be a condition of great rarity. Of course, where there are the characteristic lesions of secondary or later stages, the ordinary remedies, both general and local, will be exhibited without question.

There is one other condition which seems to claim a place here, and that is an affection of the throat where there is an even blush diffused over the fauces and pharynx and even the mouth, of more or less intense redness; sometimes the tongue will be fiery red, with none of the usual coating, an appearance which is shared by the interior of the mouth and throat to a less degree. Arsenical poisoning must here be borne in mind, especially if it is found that the patient is better away from his ordinary dwelling, as in vacation time, or that he has the usually ravenous appetite, with perhaps the malaise of this condition. Perhaps he is given to the deleterious habit of putting things into the mouth, as in one case which came under the writer's observation, where in reading a book the patient tore off the corner of each page after finishing it and put it into his mouth. With this throat it is well to institute the usual investigation to find out the source of the poison, including the examination of the urine, to see if it is present in the system, or to clear up at least that possibility. General treatment only can here be indicated.

The various forms of paralysis come under this general head, among which may be mentioned paresis of the palate in greater or less degree in post-diphtheritic paralysis, or in the early stages of tabes dorsalis; the laryngeal crises in later stages of this last distressing disease; or vagus paralysis on one side in aneurysm of the arch, or of the innominate, or from pressure of mediastinal glands, etc.

There are doubtless other states of the system which have their manifestations prominently in the throat, but those mentioned are the most prominent which have come under the writer's observation. Figures are not at hand and probably have not been collected to enable us to judge of the proportion of such cases; but it is doubtless true that a very large percentage are much better treated by general measures than by local treatment alone, and it is also obvious that general treatment is only assisted by the local in their management.

Before leaving the general part of the subject, it may be well in this place to note certain hygienic measures which may offer suggestions in preventive therapeutics or preventive medicine, in which such vast strides have been made toward the comfort of humanity in our modern times. An ounce of prophylaxis may be worth a pound of surgical or pharmaceutical interference.

In general, it may be asserted that nothing is more conducive to the maintenance of a proper condition of the mucous membranes of the upper air-passages than the avoidance of colds; for to colds may be attributed the beginning of most of the common inflammatory states of these membranes. Their initial congestions are due principally to three causes: 1, a sluggish skin; 2, a state of the blood best called lithemia in our present knowledge of the subject; and 3, to the action of atmospheric micro-organisms and dust.

1. If the skin is active—*i. e.*, if, after being chilled, it will again take up its quantum of blood on returning to warm surroundings—the internal con-



gestion, called cold, will not remain. To keep the skin active is one of the problems in the prophylaxis of catarrh. This raises the question of clothing, bathing, ventilation, and heating.

The clothing should be adapted to the weather; and in a changeable climate like that of New England and the Atlantic coast, also of the Southern shore of the Great Lakes, should be of such material that sudden chills may be avoided. The layer next the skin should be such that it will conduct the perspiration, both sensible and insensible, into the next layer, so that the skin may not be in a damp envelope. To this end cotton should be avoided because it does not hold the body-heat if dry, and when wet with perspiration allows rapid evaporation and so chilling of the surface. Wool is almost universally recommended because it retains heat: it is, however, irritating to sensitive skins, and, having the property of absorbing moisture slowly, also gives it off slowly. Hence the skin is damp before the moisture is absorbed and enclosed in a damp envelope afterward, which may keep up evaporation and abstraction of body-heat for a long time, until the garment has become dry again. This would be an advantage to the laboring man who is constantly manufacturing heat; but is a disadvantage to those who have long periods of rest between those of exercise. The material, however, which seems theoretically to answer the purpose best is a new one now bidding for public favor, viz., a linen mesh. This is smooth, unirritating and absorbent; it carries the moisture from the skin, and quickly drying, maintains a layer of warm air next the surface of the body. It remains to be seen whether its advantages will enable it to win recognition against the popular prejudice in favor of wool.

In general it may be said that clothing for the house should not be too heavy, but that sufficient addition should be made on going out in wintry weather. The fashion of wearing furs, except in the most rigorous weather, is doubtless conducive to dampness of the skin and should be avoided. Woollen outer garments are much more to be recommended than the heavy impervious pelts through which there can be no ventilation; like the rubber boot, the latter tend to keep the skin in a bath of perspiration, which is destructive of its activity and allows the rapid loss of heat on their removal.

*Bathing*, both for its stimulating and cleansing purposes, is rightly considered not only a prophylactic but a therapeutic measure of great service in the treatment of catarrh of the upper air-passages. Rosenberg<sup>1</sup> recommends daily cool baths, and it is well known that they who take the cool morning dip are less troubled with colds; doubtless because the vaso-motor system is toned up to better control of the vascular supply of the nose.

Little need be said on this subject except to caution that the skin should never be left in a slightly moist state after a bath. Hence, the cold or hot bath is much better than the tepid one which is not stimulating enough to produce a reaction. As a therapeutic measure the very hot bath (103° to 108° F.), used within the first forty-eight hours of a cold, followed by a cold dash (60° to 80° F.), and this followed by vigorous friction till the skin is perfectly dry and of a pink color, is one of the best means which can be suggested to break up a cold. The hot soak should be continued fifteen to twenty minutes; the cooling off from two to ten minutes; and after the drying of the skin the bed-clothing should not be heavier than usual.

In this connection may be mentioned that *hyperidrosis pedis* with its accompanying cold feet is a prolific cause of catarrh, not only of the hyper-

<sup>1</sup> *Die Krankheiten des Mundhohle, des Rachens, und des Kehlkopfes*, Berlin, 1893, p. 84.

trophic, but of the atrophic variety—as mentioned by Kretschmann, quoted by Jacobson.<sup>1</sup> This author recommends very stimulating treatment for the feet, and states that cure may be brought about even in atrophic rhinitis without local treatment.

The necessity, therefore, of keeping the feet warm and dry is obvious. Foot-wear in cases of catarrh should be as carefully attended to as possible: in the damp winter and spring weather the ordinary leather sole, especially of ladies' shoes, is probably never thick enough to keep dampness from the sole of the foot, and should always be supplemented by rubber.

Shampooing the head is also sometimes a cause of obstinate inflammatory conditions, most often, perhaps, because of insufficient drying, which allows of chilling of the surface by evaporation and hence congesting of the interior. This may take place even in some cases where drying is properly done. It is a question whether the long hair of our lady patients can be dried so as not to work evil in some catarrhal cases. At all events, the evil is sufficient to make the practice always a subject of inquiry.

*Ventilation.*—This is a matter of no small importance, especially as regards that of the chamber at night in the winter season. The popular craze for fresh air during sleep is often carried too far. To live in a room artificially heated to 70° to 80° F. during the day, and then to retire with the windows open, so as to be practically out of doors with uncovered head when the body-resistance is reduced in sleep, would seem to be wholly irrational. The sunless, chill night-air, blowing in steady draughts or only in gentle gusts upon the unprotected head, must do much injury in catarrhal cases, and should be strenuously avoided. The night-caps of our grandparents, relegated to the past with their unheated chambers situated remote from the warm living-rooms, would still be useful articles of night-clothing for those who must sleep with open windows.

*Heating.*—In our northern climates this should receive careful attention from the throat specialist. The physiological functions of the nose in respect of the supplying of moisture to the inspired air should point out to us the cause of much of the engorgement and hypertrophy of the interior of the nose and throat which manifest themselves in winter colds. The air below the freezing-point is deprived of much of its moisture: brought into our houses and raised to 70° or 80° F., or drawn in as breath and raised to 98° F., it must take up its quota of moisture. Hence, a more or less increased function of the mucous coverings of the turbinals—and in mouth-breathers, of the throat—which results in an obstructive engorgement or in chronic inflammatory thickening. These evils may be avoided by proper saturation of the indoor atmosphere with moisture—much more important when the heating is by steam or hot water. It is obvious then that cauterization of such engorged noses may be productive of evil, and painting of such hyperemic throats with astringents only a source of discomfort and not of cure; and that both may be more rationally treated by proper attention to indoor atmospheric conditions. Here the hygrometer comes to be a much more important instrument of observation than the thermometer. And it may be said that houses are much more comfortably heated when this instrument registers 65° to 80° than when below 50° F.

2. *State of the Blood.*—It often happens that patients complain of colds which they say come on without cause—*i. e.*, without known exposure or carelessness in dress, etc. This may often be due to a lithemic condition, as lately pointed out by Dr. L. Duncan Buckley. A cold may thus be, as

<sup>1</sup> *Lehrbuch der Ohrenheilkunde*, 1893, p. 435.

it were, a uric-acid explosion. On investigation it may be found to follow the ingestion of a heavy meal, or of a quantity of malt liquors, or of tea or coffee—which Haig<sup>1</sup> has shown to contain large quantities of the xanthin group—or to neglect of proper exercise or bathing.

Buckley's method of cure has been found in certain cases to be very efficacious, and is as follows: Twenty grains of bicarbonate of soda are given every one-quarter hour for four doses; if there is not sufficient relief after waiting two hours, the same series is repeated. The five-grain soda-mint tablets are a convenient means of administration.

3. **Atmospheric Micro-organisms and Dust.**—Probably the presence of colds in a large part of the community at any one time, so as to seem like an epidemic, is due to this cause. The prevalence of epidemics of influenza, of hay-fever, of diphtheria, or tonsillitis is often accompanied by great frequency of colds, or at least of irritable states of the upper mucous membranes. At other times, when the graver forms are not so pronounced as to show evidence of the above-named diseases, colds may be the lesser expression of their influence.

The mechanically and chemically irritant effects of atmospheric dust are a prolific cause of inflamed mucous membranes. Hence during the windy months in our cities it is often almost universal to see cases of inflamed noses and throats due solely to surface irritation. Certain classes of the community also are frequent sufferers from this state of the mucous lining of their upper air-passages—among which may be mentioned gentlemen who assume personal care of their furnaces, teachers who make much use of the blackboard, workers in dusty shops, and tinsmiths and plumbers who inhale the acid fumes inseparable from soldering. For these people some of the various nasal respirators are of service to clear the inhaled air (or even a small tuft of absorbent cotton introduced into the orifice of each nostril), and bland or protective sprays may be frequently used with advantage to cleanse the irritated surface. Scheeh and others recommend that sufferers from bacteria-laden or dust-laden atmospheres in larynx or nose be removed from the city into the cleaner air of the country or the woods.

**Mouth-breathing.**—This is a habit which should be interdicted *in toto* from the very earliest moment of life; and it is the duty of every physician to impress upon the young (or old) mother that nasal respiration must be insisted upon at the outset with every infant. The parts are so small that if the nose is deprived of its proper air-currents, the engorgement of the parts soon closes it. The accoucheur attends to the funis, the bowels, and even the eyes of the infant, but habitually omits to call attention to the importance of nasal respiration. It is not improbable that this may be one factor in the early occurrence of obstructive nasal engorgement which results in adenoid vegetation.

**Diet.**—This must usually be left to the family physician; but at times even the throat specialist may find it convenient to interfere. When the trouble is due to the lithemic state and its congeners, as mentioned above, it may be necessary to proscribe sweets and starches in some cases, or nitrogenous foods in others; highly spiced foods may keep up a congestion of the fauces and pharynx. Alcoholic beverages probably act in two ways, as local irritants and as vaso-motor dilators. To avoid the first effect, the stronger liquors should be diluted; to obviate the second, excessive use should be prohibited. In the writer's experience the most uniformly reddened and thickened mucous membranes of all visible parts of the upper air-tract above

<sup>1</sup> *Loc. cit.*



the bifurcation of the trachea was in a man who complained not of pain but only of some discomfort, who confessed to habitually having taken about fifty drinks of whiskey *per diem* for several years; miscellaneous libations of the vinous and malt liquors were not counted.

Tobacco undoubtedly exercises more or less of an irritating effect on the mucous membranes, especially when, as Rosenberg<sup>1</sup> even finds it well to say, the smoke is blown through the nose. The inhalation of cigarettes probably is the worst form of the use of tobacco; but there is a vast difference in the irritating effect of tobaccos. Those which contain saltpeter in appreciable amounts, whether natural to the leaf or introduced in the curing, should be avoided by patients whose throats are irritable, or by those whose tongues or lips show a tendency to leukoplakia. The presence of the nitrate of potash is easily seen when the fire causes a flashing as it progresses down the leaf and leaves minute white dots of the hydrated carbonate of potash on the ash. This drug is probably introduced to carry the fire in moist tobaccos—such as plug and cigarettes, as well as in some cigars designed to be used “green,” and is chosen because it has no objectionable flavor, but only adds a pungency to the smoke. But in the decomposition by combustion, nitric acid is given off to be added to the smoke, which can but be irritating to the mucous surfaces with which it comes in contact.

**Rest.**—Schech lays great stress on the importance of rest in inflammatory and ulcerative conditions, especially when, in the vocation of the patient, use of the voice is necessary. He even goes so far as to send the patient away to a quiet place or resort, according to the severity of his condition.

Use of the voice should be interdicted in inflammatory states of pharynx and fauces, and especially of the larynx; and in the former the use of some drug, as belladonna or atropia, to diminish the secretion and so diminish the necessity of swallowing, may be of service. In cases of singers' nodes (pachydermia tuberosa), both acute and chronic, absolute rest of the voice is the most efficient method of treatment, and should be insisted upon also with any other mode. *Per contra*, in paralytic affections, especially those depending on the hysteric or neurotic state, diphtheritic paralysis, etc., exercise should be employed rather than rest—according to the same author.<sup>1</sup>

After this somewhat lengthily but, it is to be hoped, useful consideration of the general therapeutics and hygiene of the subject, we come to that of the local manipulative treatment, which too often assumes a greater importance than it really deserves. And at the outset it is well to lay down a principle that whatever is to be done should be done with strict attention to the physiological function of the parts—that their efficiency should be by no means impaired, but facilitated.

**Local Treatment.**—In local treatment there are employed various means and procedures, as follows:

**Gargles.**—It is a universal custom to prescribe gargles for almost every affection of the throat, but it is obvious that in laryngeal and naso-pharyngeal affections they are, as a rule, wholly useless unless a method is employed which requires a great deal of practice for its proper performance. It is possible by half swallowing the fluid to reach the top of the larynx, and by suddenly throwing the head forward in its ejection to wash the naso-pharynx, as elucidated by Swain and others; but in the most common use of the gargle it probably does not reach back of the posterior pillars of the fauces. “Made-up” gargles have deservedly fallen into disrepute, and, although tannin and some other astringents are sometimes used in acute congestions,

<sup>1</sup> *Loc. cit.*



they are of doubtful value. Astringent and stimulating remedies must necessarily be irritating, and, therefore, in painful and inflammatory states are apt to aggravate rather than cure.

Gargles are of more value, probably, because of their temperature than of their composition. The most useful gargle is, in the writer's opinion, hot water, to which may be added simple substances such as bicarbonate of soda or borax, or even salt, which have cleansing and stimulating or soothing properties and are easy of access. In the inflammatory states the extremes of heat and cold are of greatest value, and in such affections as acute inflammation of the fauces or tonsils, probably extreme heat as a gargle, or better, as advocated by Smith of Cleveland, pressed upon the inflamed area in the form of a large tampon soaked in hot water, has much antiphlogistic power. The universal use of chlorate of potash as a gargle is probably of most value as a placebo.

**Sprays.**—The forcible and voluminous spray recommended by Mackenzie is doubtless of great value as a cleansing agent and should be used warm in the nose: the solution should be of the strength of two-thirds of one per cent. of alkali (as Dobell's or Seiler's solution) to give a bland, unirritating wash for the nasal mucous membranes. It should be a rule that no liquids which cause smarting should be used in the nose; and that liquids should be used principally when there is secretion to be washed away. The nose is made for air and not for water; and it is probable that much evil is produced by the routine employment of sprays and washes on the Schneiderian membrane. In inflammatory states soothing sprays may be used, such as those exhibited in an oily menstruum; but even these are suspected of doing evil after long-continued use, since they tend to cause a feeling of dryness and discomfort, probably affecting the secreting power of the mucous membrane unfavorably. In sluggish states of the secretion, or in atrophic states, stimulating sprays may be employed, such as those containing iodine or alcohol in various proportions. Rectified spirit is used by Miller of Edinburgh in cases of polypi, and by Creswell Baber in hypertrophic rhinitis (McBride).<sup>1</sup>

Cold sprays should not be used, lest by producing a hyperemia they may produce a chronic engorgement. The spray-apparatus most highly to be recommended is that which has a nasal tip in the shape of an acorn or cone, which should be introduced only into the orifice of the naris, pointing backward parallel with the septum, the fluid being propelled by a force of not more than ten to fifteen pounds pressure, lest the mucosa of the turbinates and septum be abraded. The straight-pointed tips often sold for nasal use are to be avoided, except in the hand of the physician, since the tender mucous surface of the septum anteriorly near the columella may be so wounded by contact that an eroding ulcer may be started and kept up. It is not infrequent to see an area a centimeter in diameter, with a crust more or less bloody, under which is an ulcer of the septum which will produce a perforation if allowed to continue. This may also be brought about by improper use of the handkerchief or finger-nail, as well as by the end of the spray-tube; hence, the acorn- or cone-shaped tip is the one which should be used by the patient himself in his own nostril, the shaft being held parallel to the median line.

An atomizer which forces considerable fluid should be selected, since the use of the finest sprays is usually most inefficient and tedious. Sprays may be used with greater force in the fauces; but the turned-up tip for the naso-pharynx is of doubtful value, since its contact with the mucous membrane of the throat may often produce irritation. Sprays used in the larynx

<sup>1</sup> *Diseases of Throat, Nose, and Ear, 1892.*

for cleansing or soothing purposes are of great value in the hands of the physician, and if used during phonation probably can be made to reach all supraglottic parts of the larynx; and with a forcible stream, perhaps under pressure of twenty pounds or more, with a spray-tube capable of delivering a large volume, the interior of the trachea can sometimes be cleansed, during deep inspiration, of the inspissated secretion of a dry inflammation of its membrane. In the larynx at first but a small amount of the fluid should be sprayed in quickly, lest the patient be embarrassed by unpleasant spasm and cough. Vapors formed by very fine comminution of fluids are of doubtful value in the upper air-passages, since only an exceedingly small amount of the medicament can come into contact with the membranes, especially if coated with secretion; and it is hardly possible that such mild applications can be of much service, since it is the function of mucous membranes to throw off all foreign substances. Thus, in all these uses of sprays it is well to bear in mind that the solution should be of sufficient strength to accomplish its object before the mucous secretion can wash it away, except where cleansing only is desired, when this eliminating property of the membrane is more or less in abeyance.

The use of the nascent chlorid-of-ammonium vapor caused by the union of the fumes of strong hydrochloric acid and ammonia water by means of an apparatus devised by Vercker, Lewin, or Kerr is doubtless of considerable value: the way in which it acts is probably not yet determined, but the membranes assume a more normal condition after being well bathed with its white dense cloud.

**Douches.**—Douches are of great value when properly used, but are liable to be exceedingly dangerous. The introduction of a solid stream of water by whatever means is antagonized perhaps overmuch by aurists, because of the liability to force the fluid into the middle ear. There is no doubt, however, that intelligent patients may be able, under explicit directions and by experience, to so use the douche that it may be of greatest value, especially in cases of atrophic rhinitis or other less offensive purulent conditions. The very hot douche may be of use in its poultice action to reduce inflammations in the nose which cause such inflammatory states of the accessory sinuses, as recommended by Bosworth; but the rule should be laid down that the douche should always be introduced through the narrower nostril and that the act of swallowing should not be performed during the passage of the stream; and after its use that the fluid should be hawked away from the naso-pharynx before blowing the nose; and, of course, that the Politzer air-douche should not be used until a considerable time has elapsed. It is probable, however, that after the membranes have been soaked by the use of the douche, the patient may be more susceptible to cold in going out into the open air in the colder weather. The solutions to be used in the douche are usually those, such as Dobell's and Seiler's, which have alkaline and antiseptic properties. They should be of such strength as not to produce smarting or tingling of the membranes and should be at the body temperature or higher; about two-thirds of one per cent. is the proper strength. The small elevation of the reservoir is important; the bottom of the reservoir should not be over six or eight inches above the orifice of the nose. The patient should also be cautioned never to use the douche carelessly or in haste; for one lapse might destroy the middle ear for life.

The external application of cold and heat is often serviceable in inflammatory states of the nose or of the throat. After injury an extreme cellulitis may be kept under by cold compresses on the nose. Acute tonsillitis may

be aborted by holding an ice-bag behind and under the angle of the jaw. Acute laryngitis, even to the extent of inflammatory edema, may also be aborted or kept under by the ice-bag or by Leiter's coil (cold) around the front of the neck. The application of heat to the tonsils and throat, in the form of the poultice or coil, is often very grateful to the patient, and requires no comment.

**Powders.**—The use of these agents in the nose is not physiological, because of its function to get rid of foreign bodies by sneezing, hypersecretion, and the action of the ciliated epithelia. Hence, the general use of snuffs because they "clear the head" is calculated to entail congestion and hypernutrition, especially in the common form of catarrh of which patients complain, which is generally that of a slight hypertrophy or engorgement; they should be forbidden, since they tend to increase the evil. Bland antiseptic powders, however, can often be used to advantage after operations or in cases where there is superficial loss of substance in the nose, or even where only the cilia seem to be absent. Such substances as iodoform, dermatol, aristol, and their congeners, which have become so numerous of late, may be of value in these cases, either pure or diluted with starch or bismuth or even compound stearate of zinc. It must be borne in mind, however, that, as in the ear, an insoluble powder sometimes hinders the proliferation of the mucous membrane to cover a defect. In these cases, therefore, insoluble powders should not be used; but they should be of such material that by the heat and moisture of the nose they will be melted into an oil or syrup.

The use of powders in the larynx probably does not in most cases compensate for the discomfort which they cause; but the antiseptic powders and those having a specific action, such as iodoform and its congeners, are valuable in ulcerative conditions of this organ.

The best powder-blower for the nose is one manufactured by the Davidson Co., known as No. 192.

**Pigments.**—The name of these substances is legion—and is continually being added to—but the one substance which has lasted through many periods of antagonism, and which is now probably the most universally used, especially in Germany, is the solution of nitrate of silver in various strengths; this has a slightly astringent, strongly antiseptic, and somewhat stimulating action. It can be applied—except in the nose—to all the parts of the upper mucous membranes. It is best applied to the naso-pharynx and larynx in strength from 2 to 8 per cent.; and may be used even to 12 per cent. in the larynx and on the tonsils. It is best, of course, to begin with mild solutions and work up. It is to be borne in mind that the nitrate of silver sometimes produces ceruleanism; and the writer has seen at least one case where a deep-brown pigmentation of the membranes and a dull coloration of the skin was attributed to the use of nitrate of silver in the throat; fortunately these cases are of extreme rarity.

Where an astringent effect is sought for, as in pharyngitis, solutions of tannin, 60 grs. to the oz. of glycerin; of the subsulphate of iron, 40 grs. to the oz. of water; of sulphate of zinc, 10 to 30 grs. to the oz. of water (also used as a spray), may be mentioned among others as of considerable value. It is probable that the use of astringents in the nose, such as tannin or iron, even in their strong solutions, are productive of more discomfort to the patient than of benefit to his condition; much better results may be obtained by the use of caustics.

As stimulating pigments may be mentioned tincture of iodine from 10 to 50 per cent. in glycerin, which may be of value in various states of the



pharynx characterized by sluggish secretion. Some have recommended a saturated solution of iodoform in ether in such conditions. The pigment selected should be applied by a brush; various kinds are recommended, but probably the most efficacious is that made by twisting a pledget of cotton on the roughened end of a metallic applicator. In all manufactured brushes there is the element of uncleanness, and the shoulder of the part containing the hair is apt to injure the membrane with which it comes in contact. In Germany a form of forceps, such as Baginsky's, is frequently used to hold the saturated pledget of cotton; but they are unwieldy and have no advantages over the cotton firmly wound upon a roughened stilet. One of the great disadvantages of the brush is that the hairs, one or all, may be left in the throat of the patient. This can never occur with a cotton applicator properly made.

**Tampons.**—In atrophic rhinitis the Gottstein tampon, either dry or saturated with a stimulating solution, has been very much advocated. It produces its effect by extreme irritation, which brings on a hyperemia and, therefore, greater nourishment of the parts. The principle is doubtless correct. The small pledget of cotton or tampon soaked with a 4 to 10 per cent. solution of cocain (to which has been added 4 or 5 grs. of resorcin to the oz.—which not only preserves the fluid but seems to prevent constitutional effects) and accurately applied to the atrophied turbinals is also of great value in these states. The first effect of the cocain is to exsanguinate the parts; the second is to paralyze the vessels and so to induce a passive hyperemia which lasts a considerable length of time and increases the nourishment of the parts without the disagreeable effect of the Gottstein tampon.

**Cocain.**—To this drug the rhinologist is indebted for the opening of his whole field; but on account of its secondary action and its constitutional effects its use should be restricted to diagnostic purposes. It should not be prescribed for the patient's personal use, and may be said to have no therapeutic value except in cases of atrophic rhinitis, as mentioned above. When, however, in the later stages of tuberculosis, or of malignant disease of the larynx, deglutition becomes excruciatingly painful, it may be used to enable the patient to eat with more comfort and so keep up his nourishment. The formation of the cocain habit, which is doubtless one of the worst of the drug-habits, must always be borne in mind, although fortunately it does not seem to be very common among patients.

In the first congestion of a cold it may be of use to establish nasal respiration; but if the result is not permanent after one or two trials its use should not be continued. It is without doubt true that the continued use of cocain produces a state of engorgement and hypertrophy which is most intractable. The great advantage of cocain in producing anemia and shrinking of the nasal structures—as well as anesthesia—does not seem to be shared by the new drug lately brought to notice, eucain. The fact that the latter produces engorgement and hyperemia will probably prevent its coming into general use in the nose. Menthol has a mildly anesthetic action—*e. g.*, in 5 to 10 per cent. solutions in oily menstrua, and may be useful in some cases of painful deglutition, but cannot take the place of cocain.

**Lozenges and Troches.**—Certain substances are with advantage put into this form: the drug makes a solution or mixture with the saliva and accomplishes the object desired. For stimulating purposes, when the throat feels rough and uncomfortable, the various combinations of chlorid of ammonium are very useful; among these may be commended those made after the formula of the London Throat Hospital Pharmacopeia, with black-currant paste; and those compounded with cubebæ and licorice or with guaiacum, made by



various pharmaceutical chemists, may be mentioned. Antisepsis is by this method often carried out most efficiently in cases of foul mouth or lacunar tonsillitis, or even in mild cases of streptococcus or diphtheritic throats by use of tablets of the bichlorid of mercury  $\frac{1}{1000}$  to  $\frac{1}{200}$  gr., as made by Fraser, Wyeth, and others. Tablets of these strengths are not disagreeable to the taste, and should be dissolved in the mouth every one to four hours, thus converting the saliva into an antiseptic solution of more or less strength. In acute tonsillitis may be recommended here the small tablet, made by Fraser and others, called "tonsillitis tablets," containing aconite and belladonna to influence the circulation, and the red iodid of mercury as an antiseptic; probably this iodid of mercury is more powerfully antiseptic than the bichlorid, and  $\frac{1}{100}$  gr. in each tablet is not too much to be given every two to four hours. In mild inflammatory conditions where there is considerable annoying irritation of the fauces, the tablets of "red gum" or other astringent drugs may be used with advantage. After the irritation produced by smoking, chlorid of ammonium and red gum have been often given to advantage.

The almost universal remedy in this form is chlorate of potash, which, given in all states of the throat, is almost as often given erroneously. This drug is supposed to be taken into the circulation and eliminated by the salivary glands and mucous glands of the fauces and pharynx; it therefore increases the activity of the blood-supply of these regions, and hence should not be given in acute inflammatory states. In cases, however, of dry pharyngitis, where there is more or less lack of secretion—the chronic inflammatory thickening producing an engorgement and, therefore, sluggish action—this drug generally finds its rational therapeutic use.

It may here be mentioned that some drugs seem to have a specific action on the membranes of the upper air-passages: for example, the iodids increase their circulation and glandular action; belladonna diminishes their secretion, and may be used when, as in an early coryza, it is desirable to stop the mucous flow. Quinin, arsenic, nux vomica, and other tonics are of value in those cases of engorgement of the nasal mucous membranes where the vaso-motor system seems to have lost its tone. Iodids seem also to increase the secretion of the larynx and trachea, so that they may be given where an expectorant effect is desirable.

Massage is recommended, notably by some German authors. In atrophic rhinitis a stroking or vibratory massage has been recommended (by M. Braun) and much claimed for it; but Rosenberg<sup>1</sup> considers it of doubtful value, although some good effects have been observed. A probe-tipped applicator is wound with cotton which is saturated with a solution of tincture of iodin in glycerin, 1 part to 4 or 8, or in an ointment containing iodin, and applied to the membrane in this manner. The object here is an increased blood-supply, as in the case of the tampon. Laker recommends a similar procedure in dry laryngitis. In paralysis, muscle-weakness, and neuralgia, massage is recommended by M. Schmidt and others.

Electricity is doubtless of greater value in these conditions, either used as the faradic, induced vibratory current, or as the interrupted constant galvanic current. Electricity may be used, by means of the double electrode of v. Ziemssen, on the muscles of the velum palati, fauces, or in the larynx; or more comfortably by the ordinary single electrode, the kathode (N) being placed on the area to be treated, and the anode (P) by a sponge electrode at the outside of the throat or back of the neck. In diphtheritic paralysis, in

<sup>1</sup> *Loc. cit.*, p. 87.

the weak muscular action of the late persisting puerile voice, in the fatigued larynx of singers, especially after a cold, these procedures are of great value, the strength of the current being regulated by the sensations of the patient. Faradization of the whole larynx may also be accomplished by pressing a small electrode deep at each side of the larynx, or by placing the negative pole in front of it and the positive pole at the back of the neck. This procedure is of much service in atonic states characterized by weak voice, caused by cold, overuse, or vocal strain, and similar conditions.

The combination of massage and electricity to the outside of the larynx is often very useful. This is accomplished by clamping the negative pole to the right hand or wrist of the operator, so that the current will flow through the fingers, and placing the positive pole at the back of the neck, as before mentioned.

**Caustics.**—In the use of these destructive agents the greatest caution is to be advocated, since they are to be used principally in the nose and larynx. It is very easy to remove by their means redundant tissue; it is not so easy to remove just enough and still preserve the functions of the parts. It should be the rule to do a little less than enough rather than a little more, since it is easy to burn more, but not to restore that which has been too zealously destroyed.

In the nose first was used glacial acetic and fuming nitric acids, but being liquid, their action was difficult to control and they have deservedly been relegated to the past. Next comes chromic acid, which could be fused on a metallic applicator and drawn in lines along the turbinal bodies. Its disagreeable odor, its active deliquescence and too powerful action, causing a deep wound and a troublesome slough and slow healing, have been disadvantages which have led to its disuse. It is, however, the best agent to close the little bleeding vessels in the septal ulcers before mentioned, which are the frequent cause of epistaxis.

The best acids for caustic action are without doubt the monochloroacetic and the trichloroacetic acids. These act practically in the same way to produce condensation (Bosworth) of the tissues subjacent to the area of their application, the former having a little more powerful effect than the latter. These acids come in crystals and can be readily fused on the applicator; or, being slowly deliquescent, the thick liquid can be taken up on a probe very finely wound with cotton (the excess being shaken off), and this will have almost the same caustic value as the former method and is easier of preparation. These acids have the great advantage that the slough becomes hygroscopic and remains on the site of the application as a protective covering, like a piece of wet chamois skin, leaving a smooth surface on removal. After the effect of the cocain has subsided, there is apt to be some pain; but it is not lasting, and is far less than after the use of chromic and glacial acetic acids.

The most efficient and most accurately controllable agent in this class is the galvano-cautery; and now it is the most reliable, since the rheostat has been perfected and the Edison street current can be brought to our hand, enabling us to discard the ever troublesome and expensive battery.

This powerful agent should not be used on turbinals presenting a transient engorgement from atmospheric irritation or vaso-motor relaxation, but only upon those showing true hypertrophy; the distinction is made manifest by cocain. If the whole turbinal shrinks down to a minimum, it is not hypertrophy; but if some remains, especially if it is pale, flabby, and less easily compressible, then it is a true hypertrophy and will permit the use of these agents. The galvano-cautery tip can be used in two ways in these

cases: the point being heated to a cherry-red color, a line can be drawn on the lower edge, and on one or two parts of the face of the third turbinals or along the middle, or one or both sides of the second or middle turbinals; or one or more lines may be drawn along that swelling of the septum so often occurring over the suture between the ethmoid plate and the triangular carti-




FIG. 567.—Rheostat or commutator for adapting the street current to cauterize use.

lage. Some have decried the cauterization of the second turbinal, fearing meningitis by extension of inflammation or other evils. But this fear is probably not well grounded unless the operation were done where there was so much swelling in the lower parts of the nose as to make drainage poor or *nil*. For this reason the lower parts of the nose should be treated first, and after healing has taken place it will be safe to treat the upper parts.

This "lining" of the surface of the intranasal swellings, however, causes much destruction of the ciliated epithelium and of the glandular layer under this; healing is then sometimes rather tedious, and there is danger of *synechie* if the lumen is narrow. Hence, it is at times better to puncture the anterior part of the swelling and to carry the heated point backward as far as is necessary in the cavernous layer parallel to the outer surface. For this purpose the platinum part of the point may be made longer than usual, say three-fourths of an inch in length. In this way only a small round point of the surface is



FIG. 568.—Cautery-point.

destroyed and healing is more rapid. A flow of blood is apt to follow the extraction of the point, but can be controlled by withdrawing it slowly and then sealing the aperture with the still glowing point. A white heat is not hemostatic.

The best handle is that of Schech, and he has also probably brought the points to the greatest perfection as to their form. If the copper part of the electrode is too small, it will get disagreeably hot before the operation is finished; this adds much to the nervous apprehension of the patient if it is felt. The copper part should, therefore, be large enough to keep the platinum heated without itself getting hot. This principle is carried out in points made by the Edison Company.

The use of the galvano-cautery on hypertrophied tonsils is advocated by many. In the opinion of the writer, however, it is irrational and dangerous. The inflamed tonsil (especially in the lacunal variety) is large because of



morbid processes and products in the crypts. Unless the electric point is carried to the bottom of these crypts and the whole of the interior treated, some of the *materies morbi* is left after the adhesive inflammation has sealed the outer part of the lumen (there is the same objection to the ordinary amputation with the guillotine); and if it is carried to the bottom it comes too near the capsule and the large vessels lying just to the outside. Enucleation or dissection (as first advocated by Hoffman and elucidated by the writer, *Boston Medical and Surgical Journal*, Oct. 12 and 19, 1893) seems much more rational. Moreover, the galvano-caustic method of reduction requires several sittings, and thus keeps the throats of most patients in a state of painful inflammation longer than does dissection, which may need but one or two sittings.

The use of the galvano-cautery or of other caustics is fortunately not often required in the larynx, but may be indicated in some cases of tumefactions. For example, lactic acid (40 per cent. to 100 per cent.) has been very highly praised in tubercular nodules and ulcers; and nitrate of silver, fused on Schrötter's concealed applicator, in papillomata or pachydermia among others. But the use of the galvano-cautery for singers' nodes (pachydermia tuberosa) as advocated is, in most cases, entirely uncalled for, since absolute rest will cause their disappearance in a very few weeks, with much less danger to the delicate edges of the vocal cords.

#### PROGNOSIS.

The question is often asked of the specialist, "Can my catarrh be cured?" or "Can it be cured permanently?" The first of these questions can generally be answered in the affirmative, except in some very bad cases of atrophic nasal catarrh or of destructive specific ozena; and the second also in the affirmative, as truly as in any other affections of the mucous membranes. Recurrences are to be expected or to be guarded against in most ills to which human flesh is heir, except perhaps death or those which can be permanently shut out by surgical measures, such as enucleation of an eye, or amputation of a limb, or removal of the appendix vermiformis: then why not a recurrence of catarrhal conditions to be brought on by the same means as previous attacks? But it is altogether probable that if all contacts are abolished in the nose by removal of extraneous growths and by reduction of abnormal swellings of normal structures without destroying the functions of the parts, so as to establish the habit of nose-breathing; if purulent cavities are drained and allowed to heal, whether of the accessory sinuses or other sources of pus emptying into the nose; if caries or necrosis of hard or soft parts can be stopped and their products removed so as to be no longer the source of irritation as foreign bodies; if bad habits are corrected and the daily life brought into rational physiological channels; if troublesome or deleterious dyscrasia and diatheses can be eliminated or held in abeyance—then probably the symptoms of catarrh can be abolished. So that in most cases the patient may be promised that he can be cured or, if not cured, made so much better that he will consider himself cured, till by his own carelessness or misfortune causes operate to induce a new manifestation of his trouble.

These same questions are almost always asked by anxious parents when hyperplasia of the pharyngeal tonsil has been discovered in their children. It seems to the writer that an affirmative answer can always be given, provided the nares are unobstructed and the habit of nasal respiration is imme-



diately established. No statistics are at hand; but it is probably true that habit and hypertrophic nasal obstruction are the great factors operative in cases of recurrence. *Per contra*, given an obstructed nose and adenoid vegetations, it is often safe to give the prognosis that the latter may wholly disappear or cease from troubling, provided they are not too old and hard, if the former is restored to normal caliber and mouth-breathing stopped. This desirable result has been attained in the practice of the writer more than once; and the cases of recurrence which have formerly come under his observation were in children with obstructed noses or whose parents did not insist on nasal respiration.

In closing this article, a word as to the danger of too much or too radical surgical interference in the upper air-passages deserves a place. Destruction of tissue in the nose should be limited to the hard parts as much as possible. It is a great mistake to remove the lower turbinals except for necrosis, although much of their covering may be redundant. The posterior ends may be amputated, the middle and anterior ends may be prodded and scored with the cautery and any excrescences removed, but not enough to shrivel them into cicatricial masses without function. The whole body even may be bent downward and outward on its attachment like a hinge, but it is protested that it should not be destroyed nor removed. Atrophic rhinitis, dry, crusty, malodorous catarrh, pharyngitis sicca, and chronic inflammation of the surfaces lower down threaten the victim of such mistaken zeal, if not immediately, surely in the near future. The middle turbinal is functionally less important and may even be removed with less danger of future evil when it suffers edematous mucous degeneration (so-called) or caries, or becomes cystic and enlarged, causing painful disturbance of the fifth nerve by pressure. 'Twere better to reduce its size by the various means suggested, but even then its ability to keep its surface clean should not be impaired.

It is significant, as Chapell and others have shown, that even by ordinary operations in the nose in certain individuals reflex neurosis may be set up, producing exaggerated nervous symptoms especially as to the nose itself, inability to apply the mind, and even melancholic depression. Perhaps in no branch of surgery, then, is there more need of caution than in this region.

It is obvious also that the mucous membrane of the naso-pharynx should not be removed with the pharyngeal tonsil, nor the pillars of the fauces with the faucial tonsil, nor in the larynx should the delicate edges of the vocal cords be injured, nor other part wounded so that cicatricial bands may impair its shape or movements. In fine, in all this region of the upper air-passages, the operator should have ever in mind the inflexible rule that if he cannot reach the perfection of his ideals, he certainly must make the patient no worse in any particular.

# ACUTE AFFECTIONS OF THE NOSE.

BY WILLIAM E. CASSELBERRY, M. D.,

OF CHICAGO, ILL.

**Acute Rhinitis.**—Acute rhinitis, *or coryza*, colloquially termed “cold in the head,” is an acute inflammation of the mucous membrane and submucous tissues of the nasal cavities, the naso-pharynx being usually likewise involved, at least to some degree. It not infrequently affects the ears, *via* the Eustachian tubes, and is prone to extend to the pharynx, larynx, and bronchioles. This sequence may on occasion be reversed, the rhinitis following an initial inflammation in the lower respiratory tract; or the whole surface may become inflamed at one time. Also, the maxillary, frontal, and sphenoid sinuses and the ethmoid cells, being cavities immediately contiguous to the nasal chambers proper, can rarely wholly escape; and at times one or more of them may present, as a complication, an acute sinusitis far more grave than the original rhinitis.

**Etiology.**—While local inflammation is the salient feature of an acute “cold in the head,” there is reason to believe that a fundamental disorder of the nerve-centers leading to vaso-motor paresis is associated therewith. Reasoning from analogy and from pathology and clinical history, one must regard acute suppurative rhinitis as an infection by pathogenic micro-organisms, although germs specific to this particular form of suppuration have not as yet been identified. However, certain local and constitutional conditions seem to favor infection, and the latter ensues finally under the influence of vascular disturbance which has been excited by some sort of exposure.

1. Chronic hypertrophic rhinitis, obstructive deformities of the septum, and adenoid vegetations probably, by maintaining local congestion and stenosis, favor recurrent attacks of acute rhinitis.

2. Extreme bodily fatigue or nervous exhaustion, the physical lassitude engendered by excesses, and the tuberculous and syphilitic dyscrasie render the individual more vulnerable upon exposure. The habit of hot bathing, especially previous to going out in cold weather, is a prolific underlying source of rhinitis. These, as well as the custom by many of wearing too heavy apparel and living in overheated apartments, seem to exert a softening influence upon the bodily surface, lessening its resistance to draughts and climatic inequalities.

3. In the presence of such local or constitutional predisposing conditions, acute rhinitis follows certain exposures with such regularity and precision that one must infer a causal relationship to exist between chilling of the body and rhinitis. A draught between the shoulders, permitting the feet or other parts of the body to become cold and damp, exposure to bleak winds, as in driving in an open vehicle, or too rapid checking of the perspiration, causes through the intervention of the vaso-motor nervous system a sudden turgescence of the nasal vessels, especially of the turbinal bodies. In the majority

of instances this congestion is but transitory, passing off in a few hours and followed merely by increased secretion; but in other instances it does not subside, but augments in violence, and is followed in twelve to twenty-four hours by a muco-purulent and then almost a purulent discharge. This congestion of the nasal vessels occasioned by thus "taking cold" seemingly favors a microbial invasion of the mucous membrane by impairing in some manner its power of resistance.

Extreme heat of weather, especially when accompanied by enervating dust-laden winds and acting upon individuals in a state of fatigue, is capable of exciting a form of acute rhinitis colloquially termed "heat-cold." In like manner a much overheated sitting apartment or assembly hall, or a journey in a superheated railroad car can have a similar result. In fact, a "cold" results quite as frequently from getting too hot as from being too cold.

Again, the subjects of supersensitive nasal mucous membranes may suffer from pronounced nasal irritation when exposed to the inhalations of various atmospheric impurities—*e. g.* the dust of railroad travel, the smoke and fumes of large cities, particularly when combined with fog, as is often the case in London and Chicago, different kinds of pollen, and even the aroma from horses. Asthmatic symptoms occasionally supervene upon this variety of nasal irritation, and the whole picture differs somewhat from that of an ordinary acute rhinitis, partaking more of the condition which in its typical form is known as "hay-fever" or vaso-motor rhinitis.

Instances are not wanting of direct infection of one person by the discharges of another—an accident which is apt to happen among children by the use of handkerchiefs in common. Suppurative rhinitis in infants is also attributable to direct infection from the vaginal discharge during birth, and this infection may be of a gonorrhœal nature. Acute bleborrhœa is another term applied to suppurative rhinitis with profuse secretion. The infecting agent may be the gonococcus or other pyogenic micro-organisms.

Rhinitis is one of the salient manifestations of genuine influenza; it is an initial symptom of measles; and quasi-rhinitis is a prominent characteristic of iodism, and to a less extent of cinchonism. It is apt to occur during pregnancy and is then aggravated by the passive venous congestion which is incidental to that state.

**Symptoms.**—A sense of stuffiness in the nostrils, with sneezing, burning, and dryness, together with malaise and a slight febrile reaction, is succeeded in a few hours by an acrid watery discharge, which later leads to a free muco-purulent secretion. A simultaneous congestion of the frontal sinuses will occasion headache; but this does not argue pressure by accumulated muco-purulent secretion within these cavities, for actual empyema of the frontal sinuses is rare. Much discomfort results from the partial or complete occlusion of the nares, especially at night, the patient necessarily breathing in part through the mouth, which occasions dryness of the throat and a sense of dyspnea; small children will actually struggle for breath and even suffer attacks of laryngismus stridulus excited in consequence. The sense of smell is obtunded or for the time suspended, and that part of taste which is dependent on the olfactory sense is impaired. A symptom which becomes a serious inconvenience to public speakers and singers is alteration in the quality of the voice, which acquires a guttural and so-called "nasal tone" because of limitation of the resonance-space by intranasal swelling. The anterior nares become red, sensitive, and excoriated.

On inspection by means of a nasal speculum and reflected light the mucous membrane appears of a darker red color than usual and the turbinal

bodies swollen. At times, however, especially at the second stage—that of profuse serous discharge—the turbinal bodies of now one and then the other side may appear collapsed. At the third stage quantities of muco-purulent secretion will be observed. Posteriorly the conditions and aspects are similar.

**Diagnosis.**—From erysipelas, acute rhinitis is distinguished by the gravity of the former affection and the erysipelatous hue which will gradually extend over the lip and nose externally. The nasal irritation from a foreign body is unilateral; that of measles is indistinguishable from simple acute rhinitis until the cutaneous eruption appears; that of iodism will be associated with cutaneous papules and will promptly cease on withdrawal of the drug. Hay-fever occurs in August and September; the patient will perhaps have a history of previous attacks, and in any event the sneezing, burning, post-nasal and lachrymal irritation endure without diminution or change for a period much in excess of simple acute rhinitis.

**Prognosis.**—Simple acute rhinitis, uncomplicated by serious implication of the collateral sinuses or of the ear, will spontaneously terminate in recovery in from five to fourteen days. Nevertheless treatment should not be neglected, for it will certainly lessen the severity and duration of the disease and tend to prevent complications or a transition into chronic nasal catarrh.

**Treatment.**—Sufferers should receive the benefit both of immediate treatment and of wise prophylaxis. At the time of an attack many remedies are of real service; but a multiplicity of recommendations is confusing and tends to lessen confidence in any one line of treatment. I will therefore describe simply my own methods of dealing with these cases.

If it is sought to abort the disorder, a single average-sized dose of Dover's powder or of morphin or codein is given at bedtime, also a laxative if needed. The morphin may be combined with atropin to advantage, as in the customary hypodermic tablet—*e. g.*, morphin sulphate, gr.  $\frac{1}{6}$ , and atropin sulphate, gr.  $\frac{1}{120}$ . The patient is especially well covered in bed, outside air is excluded, and the temperature of the apartment maintained during the night at 60° to 70° F. This will usually result in a slight excess of secretion from the skin, but no effort is made to produce profuse perspiration. If a decided sudorific effect be desired, a sort of "Turkish bath" may be extemporized previous to retiring by seating the patient, enveloped in a blanket, upon a chair beneath which a small lamp is caused to burn. In the morning on rising three ounces of Rubinat saline water should be taken, provided a laxative has not been administered the night before. If convenient, as in the case of many ladies, confinement to the house for a day or two will insure a prompt recovery.

Quinin has acquired notoriety among laymen as an abortifacient agent; but it is unreliable, and seems even at times to aggravate the condition. Cocain, in the form of a spray, only exceptionally succeeds in actually aborting the disease, although it affords temporary relief; and one is also disappointed in the alleged effects of antipyrin similarly used for the same purpose.

During the course of the affection I have most frequently prescribed prepared "rhinitis-tablets" (Dr. Lincoln's formula, one-half strength), one every two hours, which are composed as follows:

|    |                       |                   |          |
|----|-----------------------|-------------------|----------|
| R. | Ext. belladonnæ fld., | gr. $\frac{1}{8}$ | .008;    |
|    | Camphore,             | gr. $\frac{1}{4}$ | .016;    |
|    | Quinina sulph.,       | gr. $\frac{1}{4}$ | .016.—M. |

although other remedies—*e. g.*, aconite, potassium bromid, strychnin, or codein—may be indicated at particular stages; aconite and potassium



bromid early when there is fever, and strychnin later to stimulate the parietic vaso-motor system. Codein or morphin conjoined with atropin in small doses is serviceable when there is a harassing cough; and even for the rhinitis itself during the first few days it would be an excellent remedy if it were not for well-known objections to its continuous or general use.

Local treatment is of the utmost importance, and the following mixtures render satisfactory service by atomization:

*Spray No. 1.*

|    |                     |                |        |
|----|---------------------|----------------|--------|
| R. | Menthol,            | gr. j          | .065 ; |
|    | Ol. eucalypti,      | ℥ ij           | .2 ;   |
|    | Ol. gaultheriæ,     | ℥ ij           | .2 ;   |
|    | Sodii bicarbonatis, | gr. xv         | 1. ;   |
|    | Sodii boratis,      | gr. xv         | 1. ;   |
|    | Glycerini,          | ʒ ij           | 12. ;  |
|    | Aquæ,               | q. s. ad., ʒ j | 32.—M. |

Sig.—Dilute, adding one teaspoonful of medicine to one ounce of warm water for use as a spray.

*Spray No. 2.*

|    |                             |                |        |
|----|-----------------------------|----------------|--------|
| R. | Menthol,                    | gr. j          | .065 ; |
|    | Ol. pini pumilionis,        | ℥ v            | .35 ;  |
|    | Ol. gaultheriæ,             | ℥ ij           | .2 ;   |
|    | Ol. eucalypti,              | ℥ ij           | .2 ;   |
|    | “Benzoinol,”                | ʒ ss           | 15. ;  |
|    | “Oil vaselin,” <sup>1</sup> | q. s. ad., ʒ j | 32.—M. |

Sig.—Use with a double-bulb (Davidson) atomizer, either alone or following the use of Spray No. 1.

In office practice it is quite customary to spray first with a  $\frac{1}{2}$  per cent. solution of cocain, followed in five minutes by Spray No. 1, and this in turn by the emollient Spray No. 2.

At home either Spray No. 1 or Spray No. 2 or both may be used every three hours or according to convenience.

To Spray No. 1 can be added a minute quantity of cocain hydrochlorate equal to  $\frac{1}{8}$  per cent. when diluted; but then care must be observed not to use the spray with greater frequency than every two or three hours, as the too frequent use of even diluted solutions of cocain in the nose results in a reactionary turgescence of the conchæ and, in susceptible individuals, in systemic disorder of the nervous system and irregularity of the heart's action. In fact, one should avoid as far as possible prescribing or placing cocain in the hands of patients; for the sensations engendered by its nasal use, together with the cerebral stimulation by absorption through the nasal mucous membrane, are so enticing as to tempt the patient not only to too frequent and profuse use of the substance for the time being, but also to the formation of a chronic cocain habit.

For young children, who are often terrified by spraying, may be substituted a small syringe or an ordinary medicine-dropper used as a syringe, with which to project gently either of these spray solutions through the nostrils. All solutions for nasal use should be somewhat warm.

Of the many vapor inhalations I would mention camphorated steam as a domestic remedy of power. It is conveniently used by placing a pint of

<sup>1</sup> By “oil vaselin” is meant the yellow opalescent oil free from kerosene odor.

steaming hot water in a glass fruit-jar and adding two drachms of spirit of camphor: a funnel, preferably of glass, is then inverted to cover the mouth of the jar, and the rising steam is inhaled through the nostrils as it escapes from the small end of the funnel. So used, especially during the evening for a half hour, it conduces to a comfortable night's rest and facilitates recovery. The inhalation of steam through a sponge wrung out of hot water is another domestic expedient. The vapor from a few drops of a mixture of equal parts of spirit of ammonia, carbolic acid, and cologne, inhaled from cotton stuffed into a paper cornucopia, conduces to the comfort of the sufferer, as do pocket-inhalers which contain menthol or its combinations.

When intumescence of the turbinal bodies continues to be annoying beyond the usual period of actual acute inflammation, immediate relief will be afforded by two skilfully-made electro-cauterizations after the manner much in vogue for chronic hypertrophic rhinitis.

**Prophylaxis.**—Those who are exposed to climatic inequalities, and who would at the same time escape recurrent attacks of acute rhinitis, should seek in their mode of life to conserve and increase a natural resistance. To this end, no hygienic detail is of greater importance than the habit of cold bathing immediately on rising in the morning. The bath may be of the plunge, shower, or wet-towel variety, with the water at a temperature of 50° to 56° F., taken in a reasonably warm room and followed by friction with a linen crash towel, and this by brief calisthenic exercises. Patients who have a fancied repugnance to cold water are directed to commence by simply rubbing the whole surface of the body quickly with a wet crash towel. The cold bath invigorates the vaso-motor nervous system, accustoms the cutaneous surface to changes of temperature, and generally augments the bodily tone. This "hardening process," to get the best effect, should be supplemented by regular and persistent open-air exercise in all kinds of weather. When properly clad even delicate patients may safely be discouraged from omitting their outings simply because it rains, snows, or blows. To remain indoors because of trifling inclemency in the weather means at certain seasons an uninterrupted confinement to hot and ill-ventilated rooms for days at a time, with all the softening effects that such a mode of life invokes.

As to clothing, it is a golden rule to keep comfortable, avoiding an excess of raiment even more assiduously than a deficiency; and changing even to the underwear as frequently as required by variations of temperature. For instance, on a sultry late November day it is certainly less hazardous to rechange to lighter wear than to endure the general relaxation incidental to being overclad. Even in winter, extra-thick underwear is undesirable for those who live chiefly indoors, a light grade of good woollen material, supplemented by varying grades of outer clothing and overcoats, being best. For spring and fall a still lighter article either of good merino or wool, and for midsummer balbriggan or even gauze, is suitable for the ordinarily robust individual. Chest-protectors are abominations, and neck-mufflers are permissible only on extreme exposure. Ordinarily leather will not keep out moisture; and wet or even damp feet in cold weather, endured for hours without opportunity to change, is a prolific cause of "colds." A protective overshoe, as low as will answer the purpose and removed on passing indoors, is therefore a necessity.

Living apartments and offices should not be heated beyond 70° to 72° F., and means should be provided for reasonable ventilation and for imparting to hot air a degree of humidity; however, when the other conditions above

mentioned are complied with, the baneful effects of oftentimes uncontrollable superheating become much less manifest.

Finally those individuals who are predisposed to acute rhinitis by reason of adenoid vegetations, chronic hypertrophy of the turbinal bodies, obstructive deformities of the septum, or nasal polypi, should have such affections remedied by accepted methods, supplementing this treatment by observance of the laws of hygiene.

**Membranous Rhinitis.**—Membranous rhinitis, also termed croupous rhinitis and rhinitis fibrinosa, is an acute inflammation of the nasal passages accompanied by a whitish membranous exudate which covers the whole or parts of the inflamed mucosa. A membranous exudate frequently forms in consequence of chemical or electro-cauterization of the turbinal bodies; but this condition differs essentially from genuine membranous rhinitis. The exudate is thick, gray-white in color, confined to the immediate vicinity of the cauterized site, which it overlaps somewhat, shading off to a thin edge a little distance from the center of the most intense inflammatory action. If this pseudo-membrane be forcibly detached on the second day, it redevelops; if allowed to remain it becomes incorporated with the eschar produced by the cautery, and the whole will separate spontaneously like an eschar about the fifth day. There is no evidence that such a membranous exudate results otherwise than from a regenerative type of inflammation following the application of an intense and destructive irritant. Contaminating micro-organisms are found; but to them cannot be attributed the initial pathogenic rôle. It is of importance chiefly as an object lesson, serving to remind one that all membranous exudates are not to be ascribed to a single cause, and that, however ubiquitous the Klebs-Löffler bacillus may be, there are yet other agencies capable of producing an inflammation of the membranous type.

As in the throat, so also in the nose, an exudate like that of membranous rhinitis proper can doubtless ensue from infection by any one of several species of pathogenic micro-organisms; in many of the cases only staphylococci and streptococci have been found; while in others of identical clinical course Klebs-Löffler diphtheria bacilli have been demonstrated—albeit oftentimes sparse in numbers, of questionable virulence, or mixed with other microbes. Of twenty-two cases which were subjected by Edmund Meyer<sup>1</sup> to both microscopic and bacteriologic investigation with animal experiments, in thirteen virulent diphtheria bacilli were present, and in nine there were streptococci of little virulence and the staphylococcus pyogenes albus and aureus. The clinical course in both series of cases was essentially the same.

It is true that the disease which has acquired the name of membranous rhinitis, even when the diphtheria bacillus is associated therewith, differs radically in symptomatology from typical nasal diphtheria. Its manifestations are chiefly local, it is not accompanied by constitutional symptoms other than those of a "cold in the head," and it shows but little disposition to extend to the throat. Hence in those cases in which the Klebs-Löffler bacillus has been reported, it has sometimes been suggested that this in reality might be the pseudo-diphtheria bacillus of Hoffmann, which is little virulent, but which morphologically, studied only by the microscope, is quite similar to the diphtheria bacillus. As is now well-known, the pseudo-bacillus is viewed by Escherich as an independent organism, but by Roux and Yersin as an attenuated form of the Klebs-Löffler bacillus. Again, since diphtheria bacilli are occasionally present in healthy throats, and as their detection alone, unaccompanied by the usual symptoms, hardly suffices for a diagnosis of diph-

<sup>1</sup> *Archiv f. Laryngologie, etc.*, Vierter Band, Heft 2, S. 253.

theria, so also in the nose the presence of a few such bacilli does not render it certain that they constitute the responsible cause of the membranous rhinitis. In this connection, Dr. W. H. Gross,<sup>1</sup> of the Children's Hospital of Boston, presents valuable corroborative evidence. Weekly culture examinations were made from the normal throats and noses of 300 children, the Klebs-Löffler bacillus being found in 8 per cent. of the cases. Of this number the nose was the habitat in 65 per cent. and the throat in 35 per cent. In none of these did clinical diphtheria develop.

However, since in Edmund Meyer's thirteen cases all the Klebs-Löffler bacilli were found to be virulent, it is impossible to escape the conclusion that these cases at least were of diphtheritic origin, and that there are conditions not yet definitely known, pertaining to the resistance of the individual or to the degree of virulence and number of the micro-organisms, which determine a wide variation from the usual clinical picture of nasal diphtheria. Until these conditions are better understood such cases will be found classed under the designation "membranous rhinitis;" although it is expected that in the immediate future the general term "diphtheria" will have appropriated most of them for its own.

**Etiology.**—From an etiologic point of view one may therefore divide so-called membranous rhinitis into two types: diphtheritic and non-diphtheritic. Corroborative evidence of the identity of the diphtheritic type of membranous rhinitis with true diphtheria is occasionally obtainable in a definite history of exposure to infection while in attendance upon diphtheria patients.

*Case I.*—Miss ——, a trained nurse, applied for treatment at St. Luke's Hospital, complaining of obstruction of the left nostril, which she had at first attributed to a "cold." The inflammation had commenced while she was nursing a diphtheria patient, and she had been under the treatment of her patient's physician for about eight days. During that time the passage was occluded by a white membranous exudate, pieces of which were detached by forceps and subjected to bacteriological examination, disclosing Klebs-Löffler bacilli. On personal examination at the end of the eighth day the vestibule of the nose and the upper lip were found tumefied and incrustated by an excoriating discharge, while the septum and anterior part of the inferior turbinal body were still covered by a thin whitish exudate. On account of the swelling it was impossible to determine the exact extent of the exudate; but none was visible by posterior rhinoscopic examination. A culture taken at this time again disclosed Klebs-Löffler bacilli mingled with cocci. The right nostril, while somewhat inflamed, presented no exudate. The patient had not complained of any constitutional symptoms whatever, but appeared worn-out and anemic; she had continued her nursing duties to the end and left the hospital the same day to rest at her own home.

*Case II.*—Dr. S——, a young physician, was interne at the Children's Free Hospital of Detroit during an epidemic of diphtheria. A few days after the cessation of this continuous exposure he noticed an inflammation in the left nostril, which progressed to the point of total occlusion by swelling and a white exudate, with an excoriating discharge. He stated that this exudate had been so plentiful that shreds could readily be detached. He was examined about the seventh day, at which time the membrane consisted of a mere film covering an excoriated surface which embraced the vestibule, the cartilaginous septum, and the anterior part of the external nasal wall, extending backward not exceeding three centimeters. A culture was taken and examined by Dr. Gehrman, of the Chicago Health Department, in conjunction with his assistant and the patient himself, who reported the presence of Klebs-Löffler bacilli. There were no constitutional symptoms, and convalescence was complete in three weeks.

It is thus seen that a liability to the dissemination of diphtheria lurks in the diphtheritic type of membranous rhinitis; it doubtless escapes medical observation and treatment many times, being regarded by the parents of the affected children simply as a "cold," while in reality, from etiologic and pathologic standpoints, it is veritable diphtheria, differing only in degree

<sup>1</sup> *University Medical Magazine*, Oct., 1896; *Medicine*, Nov., 1896.



rather than in kind. Nevertheless, one is not justified in assuming all cases of membranous rhinitis to be diphtheritic, for in many the most careful search has disclosed only cocci. The crucial test lies in the microscopic examination of a culture, which should be deemed imperative in every case.

**Pathology.**—The structure of the pseudo-membrane is similar to that which occurs elsewhere in diphtheria. Microscopically, it is composed of proliferated epithelial cells in a fibrinous network.

**Symptoms.**—The symptoms are much the same for both types of the disease, and are ushered in by dryness and fulness of the nostrils with persistent tickling; later there is a free discharge, watery at first, but becoming thick and tenacious. By the third day an exudate will have formed, which, if torn away by forceps, leaves bleeding points and soon re-forms. The fibrinous deposit may occur in one or both nostrils and may embrace any or all parts of the passages, extending a variable distance backward. It rarely embraces the throat, although it may do so; or rather in these instances it seems to originate in conjunction with acute infectious pseudo-membranous inflammation of the faucial and post-nasal tonsils. Much discomfort ensues from the total occlusion of one or both nostrils and from the excoriation and tumefaction of the anterior nares, the external nose and upper lip being at times so red and swollen as to suggest erysipelas. In fact, it is likely that the micro-organism of erysipelas may be one of those capable of producing membranous rhinitis. These conditions are well exemplified in

*Case III.*—Dr. D—— had been exposed by attendance upon a case of scarlet fever with membranous deposit in the pharynx. He was taken ill with the characteristic symptoms of acute infectious pseudo-membranous tonsillitis. Within the right nostril was observed a distinct exudate covering the vestibule, cartilaginous septum, inferior turbinal body, and other parts as far as one could see. It differed from the ideal diphtheritic deposit, being thinner and semi-transparent, and had more the aspect of epithelial debris; but was evidently not merely such. The nose externally was swollen and of a decidedly erysipelatous hue, the redness being confined, however, and not extending above the bridge of the nose.

**Diagnosis.**—This will depend upon attention to the salient features already described; if seen late, after the characteristic appearances have subsided, it might be mistaken for simple rhinitis which had led to excoriation of the vestibule or for secondary syphilis. Erysipelas should be kept in mind.

**Prognosis.**—The disease has endured usually for about three weeks; nor has this period varied in consequence of treatment, although the comfort of the patient is conserved by remedial measures.

**Treatment.**—For the diphtheritic type of membranous rhinitis antitoxin should be injected, provided the condition assumes a degree of gravity. One would expect this to ameliorate the condition and shorten the duration of the disease.

For the non-diphtheritic type the tincture of the chlorid of iron internally best meets the indications. Locally a variety of medicaments have been used; often, however, with disappointing results. Cocain in 2 per cent. to 4 per cent. solution fails to exert its customary degree of retraction; but wisely employed, especially by means of cotton tampons, it affords relief and is serviceable preceding the application of other remedies. In my own cases, following the cocain I have applied satisfactorily by tampons this lotion:

|    |               |        |        |
|----|---------------|--------|--------|
| R. | Resorcin,     | gr. xv | 1.;    |
|    | Ol. amygdalæ, | ʒiij   | 12.;   |
|    | Glycerine,    | ʒiij   | 8.;    |
|    | Alcohol,      | ʒiij   | 10.—M. |

For its destructive effects upon the membrane a weak solution of one of the iron preparations has been commended. Löffler's solution, appropriately diluted for nasal use, might be substituted. It is composed as follows: Menthol, 10 gm.; toluene, q. s. ad., 36 c.c.; creolin, 2 c.c.; iron chlorid solution, 4 c.c.; alcohol, q. s. ad., 100 c.c. Medicaments which smart and irritate the nostrils for any length of time had better be avoided or their strength reduced. For his own use an alkaline and antiseptic spray conduces to the comfort of the patient—*e. g.*:

|                     |                   |         |
|---------------------|-------------------|---------|
| R. Menthol,         | gr. $\frac{1}{3}$ | .22 ;   |
| Ol. eucalypti,      | gr. xv            | 1. ;    |
| Ol. gaultheriæ,     | gr. xv            | 1. ;    |
| Sodii bicarbonatis, | ʒj                | 4. ;    |
| Sodii boratis,      | ʒj                | 4. ;    |
| Glycerini,          | f ʒiiss           | 45. ;   |
| Aquæ,               | q. s. ad., f ʒiv  | 120.—M. |

Sig.—To be diluted by adding one to three teaspoonfuls of medicine to an ounce of water for a spray.

**Abscess of the Nasal Septum.**—The condition which for the sake of simplicity in nomenclature is designated “abscess of the septum” only occasionally presents the typical characteristics of acute circumscribed suppuration. When caused by traumatism, the first stage may be an effusion of blood beneath the muco-perichondrium of the cartilaginous septum, which is termed “hematoma of the septum.” In time the blood degenerates, perhaps becomes infected by pyogenic micro-organisms, and changes to a brownish-

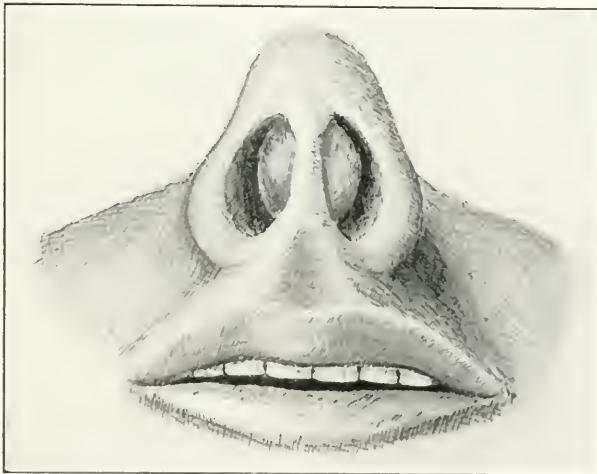


FIG. 569.—Abscess of the septum, protruding bilaterally.

yellow fluid, which when evacuated appears neither like blood nor typical pus. In this state it has been called “cold abscess.” Again, when it originates without traumatism and runs an acute course, with pain, fever, and obstructive swelling, terminating in ideal suppuration, it has been spoken of as “acute perichondritis.” Jurasz<sup>1</sup> has described a form in which the contained fluid is at first serous, termed serous perichondritis. Some sort of abscess is the culminating stage of all these conditions (see page 1117).

<sup>1</sup> *Journal of Laryngology, etc.*, Nov., 1896, p. 266.

Although it might be possible for the bony portions to be affected, the usual seat of the disease is the cartilaginous part of the septum, and it may be either unilateral or bilateral.

**Etiology.**—The most frequent cause is believed to be traumatism—*e. g.* blows or falls upon the nose; yet in many cases it is impossible to establish this relationship. Slight contusions, readily forgotten, can determine a hematoma of the septum. This may run an insidious course, endure for days or weeks, and undergo spontaneous absorption, having been little noticed; but in other instances the blood changes to sanguinolent pus and the cartilage itself disintegrates, the abscess-contents being retained by the bulging muco-perichondrium. Pyogenic micro-organisms could excite suppuration in these and also in so-called idiopathic cases by gaining an entrance through the excoriations which are frequent on these surfaces. The disease may occur also during the course of typhoid fever or small-pox; and Schech<sup>1</sup> calls attention to the frequency with which facial erysipelas proceeds from abrasions upon the septum, and infers that abscess of the septum can be caused by infection by the streptococcus erysipelatus. In many cases still it is quite impossible to assign any definite cause. This was true in the following case, which is a typical example of the variety termed cold abscess:

*Case I.*—Master G—, aged sixteen years, while away from home at school, began to suffer from nasal obstruction, which he attributed to an acute exacerbation of his customary "catarrh." No history of traumatism could be elicited, the disease having seemingly commenced as a cold and continued several weeks before it received serious consideration. But nasal obstruction and swelling within and without the nose gradually grew so serious that he was sent home, where he was confined to bed, supposed to be suffering from asthma. On examination the diagnosis was at once apparent, for from each side of the septum bulged a fluctuating tumor which completely blocked both nostrils. The enveloping mucosa was unbroken, somewhat inflamed, and the nose generally reddened and edematous. A brownish-yellow liquid was withdrawn by a hypodermic syringe, and this was followed by a free incision toward the base of one side and gentle curetting of the cavity. The central portion of cartilage had liquefied; but it redeveloped from the muco-perichondrium and perfect recovery ensued.

**Symptoms.**—In case of the transition of a hematoma into an abscess, the disease may manifest itself either quite insidiously or the suppurative change may ensue quickly and be associated with sneezing, general nasal irritation, and slight fever. In either event the salient symptom ultimately complained of will be obstruction to nasal respiration, together with the discomforts of mouth-breathing.

When the abscess arises in the form and in consequence of acute perichondritis, it is ushered in during a few days by symptoms indicating a high degree of inflammation—*e. g.* chill, pronounced fever, swelling and redness of the whole organ. Spontaneous rupture is more apt to occur quickly in this than in the former type, although it may be much delayed after the subsidence of the inflammatory symptoms, leaving again nasal obstruction as the salient symptom.

*Case II.* exemplifies the latter type. Mr. —, aged twenty-six years, thought he had contracted a severe "cold in the head," the condition commencing with chilly sensations, followed by headache, fever, local sensitiveness, and redness extending to the bridge of the nose. These symptoms gradually subsided, but were replaced by nasal obstruction and what he now supposed was chronic nasal catarrh. The examination was not made till the third week, when a fluctuating tumor was observed to bulge from each side of the septum. Typical pus was evacuated by an incision and the cavity curetted. The destroyed central part of the cartilage ultimately redeveloped without deformity. He positively denied the least probability of traumatism as a cause.

<sup>1</sup> *Die Krankheiten der Mundhöhle, des Rachens und der Nase*, 5. Aufl., 1896, S. 298.

**Diagnosis.**—By simple inspection with the head tilted backward the semicircular tumor may be seen bulging from one or both sides of the septum (Fig. 569). Palpation by a probe will cause deep pitting or even fluctuation, and aspiration by a hypodermic needle will provide a sample of the contents. It may thus be readily distinguished from polypus, for which it is most commonly mistaken by novices, which occurs but rarely in this situation; and also from syphilitic gumma, which commonly develops at just this spot. I have seen one case of gumma, in which the central part had liquefied before the occurrence of superficial ulceration, in which the diagnosis would have been impossible had not other syphilitic signs been present.

**Prognosis.**—If recognized reasonably early and the abscess evacuated, the prognosis is very good. Notwithstanding complete liquefaction of the cartilage itself, if the muco-perichondrium be preserved another cartilaginous septum will develop, and this usually without deformity. However, if the disease be unrecognized or if the inflammatory action extend to the antero-superior border of the septum, the line of junction of the septum with the lateral cartilages and nasal bones, softening and depression of these, which constitute the dorsum of the nose, will result. Apart from this "saddle-back" deformity or in conjunction with it, perforation of the septum can also ensue.

**Treatment.**—When the initial stage is a hematoma, cold applications would be suitable. In any event, as soon as pus is present a rather free incision should be made low down on one side and the contents expressed. This should be reopened daily with a probe until the cavity has been effaced. It is probably not necessary to eurette, wash out, or pack the cavity with gauze, although one or all of these may seem desirable at times.

**Abscess and Furuncle of the Nasal Wing.**—Furunculosis of the wing of the nose is of frequent occurrence and results commonly from infection or irritation in or about the hair-follicles, as from pulling out hairs. The boil is usually quite small, scarcely more than a "pimple," but is accompanied by an amount of tenderness, swelling, and redness of the nasal appendage quite disproportionate to its size. It points inside the wing of the nose in a position difficult of observation even with a nasal speculum, but it can be exposed to view in a small rhinoscopic mirror held just within the vestibule. It should be punctured as soon as suppuration is evident, as this will abbreviate materially the incidental discomfort.

Genuine abscess occurs, but much more rarely, in the same situation, and may be ascribed to similar causes. I have observed but few cases; in one of them, however, the abscess had attained the size of a hickory-nut, with large swelling and total occlusion of the nostril. Laudable pus was evacuated by an incision made from within.

L. Wroblewski<sup>1</sup> mentions having seen and operated upon several cases of abscess of the wing of the nose occasioned by the bacillus anthrax benignus.

**Erysipelas of the Nose.**—Too little attention has been drawn to the fact that so-called idiopathic facial erysipelas quite commonly originates within the nose.

**Etiology.**—The cause here, as elsewhere, is an infection by the streptococcus erysipelatus, a micro-organism specific to erysipelas, which gains entrance through fissures and excoriations which frequently affect the anterior nares and the cartilaginous septum as well as more rarely the deeper surfaces of the nasal fosse. Otherwise trifling intranasal operations may furnish the responsible gap, and it is even possible, although not proven, that infection

<sup>1</sup> *Archiv für Laryngologie und Rhinologie*, ii [or Zweiter], Band, 1895, S. 297.



may occur through an unbroken surface. Certain persons are predisposed to infection on the slightest provocation.

**Symptoms.**—The affection commences like an acute rhinitis of unusual severity. The temperature runs high, there is total occlusion of the nostrils, a profuse excoriating muco-purulent secretion, swelling with erysipelatous redness of the nasal appendage, and later an extension of the erysipelatous dermatitis to a variable distance over the face. In like manner it may extend posteriorly to the naso-pharynx and pharynx or involve the collateral sinuses of the nose—a combination which may present the gravest aspects. On inspection the nasal mucosa appears of a dusky-red color, or it may be covered by a thin milky exudate.

**Treatment.**—By way of prophylaxis, especially with those who have a history of previous attacks, excoriations and fissures should receive adequate attention to secure prompt healing; all operative measures not strictly necessary should be avoided and others made with thorough antiseptic precautions.

During the attack, for internal administration, the classical remedy for erysipelas, tincture of the chlorid of iron in doses of ten minims and upward, has not been successfully superseded. Locally, for intranasal use, sprays Nos. 1 and 2, formulæ for which are given in the section on acute rhinitis, serve a useful purpose; and as a topical application for the excoriated anterior nares and inflamed skin surfaces, the resorcin mixture detailed in the section on membranous rhinitis can be commended.

**Epistaxis—Nose-bleed.**—Epistaxis (*epi staxo*, to flow drop by drop) is a hemorrhage from the nose, and varies in degree from a trifling inconvenience to an occurrence which involves grave danger to life.

**Etiology, Pathology, and Varieties.**—1. *Idiopathic.*—Even when apparently spontaneous, a slight traumatism as in picking the nose or using a handkerchief roughly may be the exciting cause. The bleeding point can be anywhere in the nasal fossæ; but in 90 per cent. of the cases by actual count<sup>1</sup> it is found just within the nostril on the cartilaginous septum. This structure is richly supplied with blood by the anterior artery of the septum, a branch of the superior maxillary, and in copious hemorrhages it may be the artery of the septum itself or some of its twigs which have been opened. The vessels are poorly protected by a thin mucosa, and the spot is much subject to erosion, ulceration, and incrustation. With vessels thus ready to break at any moment, a variety of local and constitutional conditions serve to excite bleeding.

It is a well-known symptom of typhoid, malarial, and pneumonic fevers. It is liable to ensue upon violent exercise or to accompany "rush of blood to the head," from whatever cause, especially in plethoric individuals and in persons affected with passive congestion of the venous system from organic disease of the heart, liver, or kidneys, and during pregnancy. It follows large doses of quinin. It is of course a symptom in ulcerative syphilitic disease, in angioma or "bleeding polypus of the septum," in sarcoma, carcinoma, and other nasal neoplasms. In elderly persons, if recurrent and without other cause, it indicates an ominous degeneration of the vessels. This I have observed in the case of an aged gentleman who had bled profusely in spite of remedies and through the packings for three days, when careful examination by reflected light and with rapid swabbing disclosed a spurting artery of the septum, which was instantly sealed by electro-cauterization.

*Vicarious epistaxis* is a substitution of nasal hemorrhage for the natural menstrual flow, and occurs at times of acute suppression of the menstrual function or of its difficult establishment about the age of puberty and during

<sup>1</sup> Chiari and Baumgarten, cited by Bosworth: *Diseases of the Nose and Throat*, vol. i. p. 312.

the menopause. Doubtless in these cases, also, there is a weakness or erosion of the vessels of the septum, which are unable to withstand the hyperemia of the head which results during perversion of menstruation. The menstrual molimen, including the congestive headache, is relieved by the vicarious epistaxis, which within reasonable limits may be regarded as beneficial rather than detrimental. In one case cited by Fränkel,<sup>1</sup> however, the recurrent nasal flow was so profuse that a fatal termination ensued.

2. *Traumatic*.—Hemorrhage following fractures and other intranasal accidents, while profuse for a short time, commonly ceases spontaneously. If persistent in spite of packing, it indicates an injury to neighboring parts. Serious bleeding has occasionally resulted from otherwise trifling intranasal operations—*e. g.* removal of spurs from the septum, cauterization of the conchæ, etc., so that means to cope with this contingency should be provided and operations possibly declined on persons from whom a bleeding history is elicited.

**Symptoms.**—Only the premonitory symptoms of those subject to habitual epistaxis require special mention. Patients complain of vertigo, tinnitus, temporal throbbing, a sense of cerebral pressure and headache, while the cheeks are flushed and the conjunctivæ injected. They are gratified at the bleeding for the relief which it brings.

**Diagnosis.**—In the absence of actual hemorrhage only a careful search and palpation with a probe, at the risk of exciting bleeding, will disclose the responsible vessels.

**Treatment.**—Most attacks cease spontaneously inside of half an hour. Simple expedients are: the superficial plugging of the nostril with cotton, pressure of the nasal wing against the septum, the insertion of a finger into the bleeding nostril, ice applied to the side of the nose and held in the mouth, the application of ice in small pieces within the nostrils, ice to the back of the neck and along the spine for its reflex action, the injection of hot water, 120° F., or spraying of hot vaselin into the nose,<sup>2</sup> damming of the blood into the general venous system by constriction of the extremities near the trunk by straps or handkerchiefs, and the administration internally of a mixture of gallic acid, antipyrin, and fluid extract of ergot.

Spraying the nostril by strong astringent solutions of tannic acid, iron, or alum is seldom effective and is objectionable on account of the irritation produced, although the insufflation of powdered matico is generally commended. A better and really effective spray is composed of 4 per cent. solution of cocain in 2 per cent. solution of antipyrin, materials which act as powerful vessel-constrictors. After spraying, a pledget of cotton soaked in peroxid of hydrogen may be introduced well into the nostril, the pressure from the liberated gas in all directions assisting in the formation of a clot.

Really serious cases are prone to resist all of these measures, and then one must either locate the bleeding vessel by rapid swabbing and cauterize it by electricity, chromic acid, or nitrate of silver, named in the order of desirability, or, in case the hemorrhage is too profuse to permit of this procedure, or if for other reasons it cannot be accomplished, one should pack the nasal fossa from front to back with 10 per cent. moist iodoform gauze. This is best done by a slight modification of the plan first proposed by Dr. E. Fletcher Ingals.<sup>3</sup> Two strips of double-thickness gauze, each two feet in length and a full inch in width, are prepared, and near the distal end of each (the end first

<sup>1</sup> *Ziemssen's Cyclopedia*, vol. iv. p. 152.

<sup>2</sup> Frank M. Rumbold: *The Laryngoscope*, 1896.

<sup>3</sup> E. Fletcher Ingals: *Diseases of the Chest, Throat, and Nasal Cavities*, p. 550

to be inserted) a strong thread is tied. The first strip is passed through the inferior meatus to the naso-pharynx, fold after fold being pushed in until the lower channel is full. The second strip is passed in like manner well into the middle meatus, and traction is then made on the threads in order firmly to pack the gauze at the rear end, the surplus of gauze in front is cut off and the threads anchored to a padded stick across the nostril. In narrow nostrils there may be room to manipulate but one strip of gauze, and this will then suffice. The point is that the gauze shall be placed as far backward as the naso-pharynx and not merely stuck in front.

Plugging the posterior nares is a common resort for obstinate epistaxis; but it is liable to provoke inflammation of the middle ear, mastoiditis, and brain complications. I have seen a patient's life placed in jeopardy thereby, and am firmly of the opinion that posterior plugging should be avoided whenever possible. A substitute is found in the above-described method of packing the nose from in front, which will suffice for all cases of strictly nasal hemorrhage.

When, however, the bleeding is from the naso-pharynx itself, as from the removal of "adenoids" or tumors or from operations on the posterior ends of the turbinated bodies, it may be necessary to plug posteriorly.

A wad of iodoform gauze, adapted in size either to fit well into the choana or to fill in part the naso-pharynx, according to the location of the bleeding point, is tied across the middle by strong double silk thread. A soft catheter is passed through the nose, and to its end, picked from the pharynx by forceps, one double thread is tied, and the plug, assisted by a finger around the velum, is thus drawn into the naso-pharynx. These threads are best anchored to a small padded stick across the anterior nares. The other string ends, or one of them, is maintained through the mouth as "a leader" by which to detach the plug. The posterior packing should not remain longer than twenty-four to thirty-six hours without removal. A still less septic plug and one perfectly soft and globular can be prepared, as suggested to me by Dr. Ethan A. Gray, by making it double, as it were, one layer inside the other, the strings being sutured around the inner kernel and both layers being covered by thin rubber cloth. Thus I have saved the life of one patient who required packing for a period of five weeks.

NOTE.—Other acute diseases of the nose, primary and secondary syphilis, nasal diphtheria, acute sinusitis of the maxillary, frontal, ethmoid, or sphenoid cavities, and traumatism will be considered in the respective chapters devoted to these conditions as a whole.

## CHRONIC AFFECTIONS OF THE NOSE.

BY MORRIS J. ASCH, M. D.,

OF NEW YORK CITY.

CHRONIC hypertrophic rhinitis is a condition of the nasal passages characterized by hypertrophy of the mucous membrane covering the turbinal bodies, by enlargement of the bodies themselves, and by outgrowths from the septum or floor of the nose, which may result from local or constitutional causes.

**Etiology.**—Chronic hypertrophic rhinitis may follow repeated attacks of acute rhinitis, whether they result from exposure, unhygienic surroundings, or from unhealthy occupations. Printers and workers in chemicals or in trades where dust abounds are particularly liable to the affection, as the particles thus inhaled aggravate, if they do not cause, it; while, in addition, there is the class of workmen exposed to both climatic changes and dust—such as dock-laborers and workers in saw-mills—who are frequent sufferers from the disease.

The condition is not of rapid development, but comes on gradually, attention being called to it by the resulting inconvenience. Some are peculiarly liable by reason of temperament, especially neurotic individuals. Constitutional causes are gout and defective nutrition. Lithemic patients are prone to this affection along with other diseases of the throat and nose met with in gouty subjects. Broken-down constitutions, whether resulting from syphilis, or from defective nutrition following acute disease, or any depressing cause—such as insufficient nourishment and poor surroundings—are easy victims of chronic rhinitis. Leukemia, malaria, and serofula are all factors in its causation, but although chronic hypertrophic rhinitis occurs mainly in those of poor constitution, yet in persons otherwise healthy an acute catarrh may, under external influences, become chronic and give rise to the pathological changes peculiar to this disease. It has been observed as the result of grip, and is said to occur sometimes after medication with iodin and mercury. Irritation caused by obstruction of the nasal passage, deviation, spurs, or by the “narrow nose” of Störek, may produce chronic hypertrophic rhinitis, or by causing a passive hyperemia aggravate it when resulting from any constitutional cause.

**Pathology.**—The prominent condition in chronic hypertrophic rhinitis is hypertrophy of the turbinal bodies and of the mucous membrane covering them. This membrane is richly supplied with blood-vessels, and especially veins. It is elastic, and therefore erectile, and forms with the submucous layer true corpora cavernosa, which fill or collapse according as they are supplied with or emptied of blood. When the walls of the venous canals become thickened through hypertrophy and lose their elasticity, the enlargement becomes permanent. Wingrave<sup>1</sup> says that the condition is not a mere hyper-

<sup>1</sup>*Journ. of Laryngol.*, 1894.



trophy of the structure, but consists of a true degeneration and infiltration of the walls of these vascular spaces; the walls gradually losing their power of active recoil, the vessels become more and more distended and a permanent enlargement, which is in fact a varix, ensues.

In the first stage of the disease the turbinal borders are greatly enlarged and the mucous covering soft and sodden, yielding without elasticity to the pressure of a probe. There is a decided cellular infiltration of the epithelium and subepithelial tissue, especially about the glands and vessels.

The epithelial cells are increased in number, the upper layers becoming flattened or cuboidal, while the ciliated cells are preserved only to a slight extent. The venous channels are distended in the deeper portions. After a time the swelling of the mucous membrane becomes more marked and there is a change from diffuse infiltration to a circumscribed thickening. The appearance of the parts now indicates a fibrous change, and the surface of the turbinals may become irregular from want of uniformity in the swelling.

The inferior turbinal is the part usually enlarged, especially in its posterior extremity. The anterior extremity is also frequently affected, while it is very rare to find enlargement only of the middle portions. These circumscribed infiltrations sometimes appear as true growths of varying color—sometimes purple, indicating great vascularity—sometimes whitish because of preponderating connective tissue and thickening of the epithelium.

The surface is frequently smooth, as in ordinary nasal mucous membrane; at other times papillary hyperplasia is so strongly developed as to give rise to a mulberry-like appearance. Not infrequently myxomatous changes occur, especially at the anterior extremity of the inferior turbinals, while papillary degeneration is most frequently observed in the posterior hypertrophies. Later on we find cartilaginous and bony outgrowth from the septum and floor of the nose, which by obstruction to respiration and by pressure act injuriously.

Posteriorly the ends of the inferior turbinals, when enlarged, are usually dark red, although sometimes white in color, with a surface varying in appearance, sometimes smooth and rounded, but often rough, irregular, and mulberry-like, and occasionally they protrude into the naso-pharynx so as to interfere with the functions of the Eustachian tubes. The middle turbinals are also the seat of these hypertrophies, as is also the floor of the nose and the sides of the septum. The pharyngeal tonsil will often be found enlarged.

Later in the disease all these morbid conditions become more marked. The hypertrophied tissue becomes more dense; and in addition to the turbinal enlargements we have ecchondroses from the septum and exostoses from the anterior nasal spine of the superior maxillary bone.

The middle turbinals show a hard, resisting surface, filling the whole meatus, tightly pressed against the septum; although frequently the mucous membrane covering them becomes the seat of a myxomatous degeneration, giving rise to masses which, from their soft and gelatinous appearance, may be mistaken for polypi.

On the posterior portion of the septum there are thick cushion-like swellings of the same color as the surrounding mucous membrane, and from the floor of the nose and from the posterior extremity of the inferior turbinals appear firm elastic hypertrophies, usually light in color, either smooth or papillated, although when their surface is rough they are frequently of a darker hue. When the hypertrophies appear on the septum they are often symmetrical in both nostrils. The vault of the pharynx and the larynx are usually involved in the last stage of the affection.

**Symptoms.**—In the first stage of the disease the symptoms are those of ordinary catarrh. The secretion in most cases is thick and scanty, containing large quantities of mucus. It is muco-purulent, and on account of its toughness dries most readily and appears as odorless yellow and yellowish-green crusts on the walls of the nasal cavity and at its entrance. In rare cases the secretion is free, thin, and serous, as in acute catarrh.

The principal symptom, however, and the one most complained of, is that of more or less nasal obstruction, the degree varying with the size of the swelling and the character and quantity of the secretion. Accompanying this is the discomfort produced by the accumulation of secretion in the naso-pharynx, where it either dries and is hawked out with difficulty, or is expectorated or swallowed. There is fulness of the head, especially in the frontal region and over the eyes, frequently followed by severe migraine; in addition there is a sense of dryness of the tongue and throat, which is almost continuous. The secretion of mucus in the throat is abundant in the mornings, and frequently the patient vomits in the effort to be rid of it.

A common fact noticed is the filling of the hypertrophied turbinal with blood by gravitation. It frequently happens that when a patient lies on the side the corresponding hypertrophied part will be distended, while bending the head forward will cause occlusion of both sides; a reversal of position will favor the return of the blood and the restoration of function of the part.

Mouth-breathing, with all its attendant evils, is a prominent feature of the disease, and a nasal twang to the voice is a common accompaniment. The sense of smell is affected, and frequently complete anosmia results, in which case the sense of taste is also impaired. As a result of the attempt to clear the nose of adherent secretion, small hemorrhages occur; and the frequent use of the handkerchief often gives rise to painful eczemas at the nasal orifices.

When the middle turbinals are involved, frequent and severe frontal headaches occur, the result of pressure on the nasal branch of the fifth pair. Pharyngitis, laryngitis, and bronchitis are also present as the result of the nasal lesion. Most common, however, as the result of the obstruction of the nasal passage we find affections of the ear. Chronic catarrh of the middle ear and of the Eustachian tubes are frequent sequelæ, while tinnitus and vertigo also occur.

The eyes also suffer as a result of hypertrophic catarrh. Conjunctivitis is not uncommon. In asthenopia with headache, where correction of refraction has not cured, the cause has often been found to be in an enlarged middle turbinal body, the removal of which relieved all the symptoms.

Among other symptoms due to hypertrophic rhinitis are reflex neuroses; not very common, it is true, but still sufficiently so to warrant our examining the nasal cavities for their probable cause. Hay fever is often relieved by the removal of hypertrophied tissue on the inferior or middle turbinated bodies. Schech speaks of a nervous catarrh of similar origin where a thin, clear, and extremely profuse secretion makes its appearance suddenly and at intervals, associated with diminution or loss of smell, obstruction of the nose, and violent sneezing. These attacks last several hours, and are most frequent at the menstrual periods. Vaso-motor disturbances are not uncommon. Reddening and swelling of the face and conjunctiva often appear on the slightest irritation, and disappear as suddenly, leaving no trace.

Asthma is the most common of the reflex disturbances in hypertrophic rhinitis. It usually comes on during sleep, and may be, as suggested by Schech, the direct consequence of irritation of the vagus—the result of dis-

eased nasal mucous membrane. Too much stress, he thinks, has been laid on the part the spongy tissue plays in the origin of nocturnal asthma, though it certainly is a factor in its production.

Other reflex symptoms that have been observed are aphonia, laryngeal spasm, and supra-orbital and facial neuralgias. Spasmodic cough is not infrequently found to be the result of intranasal pressure, and I have often relieved a cough of long standing by removal of the hypertrophied turbinal body.

It has been my experience that asthma and hay fever, when they can be referred to the nose, depend upon the hypertrophy of the inferior turbinals; while neuralgias and headaches were as invariably the result of pressure of the middle turbinal on the septum. Epileptic attacks and vertigo may be also included among the affections induced by this disease. It will be seen, then, that the results of a diseased condition of the intranasal regions may produce complications far beyond the local trouble in sight; and bearing this in mind, the ophthalmic or aural surgeon of to-day can scarcely be said to have made a thorough examination of a patient when the nasal cavities have not been included. It is very certain that the presence of spurs, hypertrophies, and deviations play a very considerable part in the production of catarrhal troubles both of the eye and ear. Affection of the lachrymal ducts, keratitis, purulent dacryocystitis, and impaired vision, together with all the distressing symptoms that belong to mouth-breathing, as anxiety at night, disturbed sleep, dryness of the pharynx, larynx, and trachea, with sometimes resulting inflammation, disordered digestion, and mental dulness, all these may follow the condition of the nostrils.

Externally we may have eczema of the nostrils, the result of irritation, sycosis from the constant maceration of the upper lip, pustules, erysipelas, and redness at the tip of the nose from engorgement, the swollen spongy tissue preventing a return of the blood.

When we examine a patient we find appearances varying with the stage of the disease. In its first stage the nostril is more or less occluded anteriorly by an enlarged inferior turbinal body, which is either red or normal in color. The enlargement is spongy and elastic, and, although usually occupying the anterior extremity of the inferior turbinal, it may also be found to involve the middle, causing it to press against the septum. Hypertrophy of the inferior turbinal can be temporarily reduced by pressure with a flat probe, the enlarged sinuses emptying, but immediately filling again. This rapid resumption of shape tends to distinguish the hypertrophic from the chronic form of rhinitis where pressure by a probe simply displaces a certain amount of infiltration.

Cocain in from 2 to 5 per cent. solution has the same effect in rapidly contracting the spongy tissue, but does not entirely dissipate its tumefaction. Those swellings that disappear entirely under cocain belong to simple chronic rhinitis, and not to the hypertrophic variety.

**Diagnosis.**—There should be no difficulty in making a diagnosis of this affection. The only disease with which it might be confused is nasal polypus, but the use of the sound and of cocain should easily differentiate the two conditions. An important point when making the diagnosis is to ascertain whether the hypertrophy is primary or due to a constitutional cause, such as syphilis, as this has an important bearing on the prognosis and treatment.

The **prognosis** is good if there are no complications.

**Treatment.**—In the first stage of the disease the treatment should be mild, attention paid to hygienic surroundings, the nasal passage protected



from vitiated atmosphere, and in some cases removal to another climate recommended. Excess of any kind must be prohibited, and any constitutional vice which might be a factor in producing the disease is to be sought for and eradicated, if possible.

It is astonishing how much good can be done in the first stage of the disease simply by attention to the ordinary laws of health. The local treatment must be unirritating. At first only the simplest remedies should be used, by means of the spray or irrigation, by the nasal douche, the nasal douche-cup, and insufflation of appropriate solutions through the anterior nasal passage into the pharynx. The spray, many formulæ for which are in constant use, should be applied, if the application be made by the patient himself, by means of the hand-ball atomizer such as is usually sold in the shops, provided with a blunt nozzle to prevent injury to the nostril. When the spray is used by the physician in his office, compressed air is usually the motive power, contained in a cylinder filled by means of a hand-pump, although the pumping may be done by means of water-power or an electric motor.<sup>1</sup>

While I am accustomed to use the spray in the treatment of chronic rhinitis, I do not look upon it as a curative measure, except in very slight and recent cases, when the clearing away of secretion gives the affected mucous membrane an opportunity to regain its normal condition. I do find the spray very useful, however, when the pressure is raised to forty pounds, to wash away crusts from the posterior nares and especially from the vault of the pharynx—so much so that I have never had occasion to use a posterior nasal syringe for the purpose. In atrophic cases of long standing, where the secretion is very adherent, I have sometimes made use of dry cotton, wrapped on an applicator bent at a right angle, to remove it, but usually the force of the spray is sufficient. If the force of the spray is increased gradually there is no discomfort, nor is any injury inflicted either in the nostrils or the Eustachian tube. A very slight stain of blood may follow the application, but there is no epistaxis nor any consequence to alarm the patient.

The solution used in the atomizer varies rather with the fancy of the operator than with the exigency of the case, for any detergent alkaline fluid may be used. Normal salt solution, boric acid gr. x to ʒj aq., Dobell's solution with the addition of listerin, or a combination with thymol-menthol and eucalyptol as in Seiler's tablets, are all in frequent use. Sajous recommends a solution of bicarbonate of soda and borax, ʒā gr. viij; ext. fluid. pini canadensis, ℥ xv; glycerin, ʒij; aquæ ad, ʒiv. Alum 1 or 2 grains to aq. ʒj is used; but in common with the salts of zinc and lead is said to produce anosmia.

Of more importance than sprays in their curative properties are applications made locally to the affected membrane. Nitrate of silver is probably the most efficient of all the simple applications; it can be applied in strengths of two to ten grains to the ounce, but should never exceed this. It must be used with regularity, as an occasional application of it is of no advantage.

<sup>1</sup> In my clinic at the New York Eye and Ear Infirmary, where sprays are largely used as cleansers in all cases of nasal disease, every table at which a surgeon is seated is supplied with a rubber tube which connects with an atomizer by means of a bayonet-joint. The compressed air is forced into a large cylinder in the basement of the institution by means of an air-compressing engine driven by steam, which is in constant action during the service of the clinic. A safety-valve on the cylinder, usually set at forty pounds, prevents the pressure ever rising beyond this point. The cylinder connects by means of an iron tube with the clinic-room, where it is distributed to each of the tables at which patients are treated. In consequence of the distance traversed by the tubes some of the pressure is lost before reaching the operator, so that the spray is usually made at a pressure of about thirty pounds, which is the strength I find most convenient, but which can be still further modified by the cut-off regulating the spray.



Störck objects to its use in consequence of the stains it sometimes produces on the exterior of the nose, and of the disagreeable sensation resulting. It should never be used as a spray, but applied carefully with a piece of lint wound on the extremity of a fine nasal applicator there should be no external mark, and any disagreeable sensation resulting can easily be relieved by the snuffing up of a little salt water. There is a possibility that a pocket handkerchief used just after the application may be stained. This can be guarded against by giving the patient a Japanese paper handkerchief to use for a little time after the treatment. Iodin and glycerin made according to the following formula: Iodini, gr. vj; iodidi potassii., gr. xij; glycerinae, aque,  $\bar{a}\bar{a}$   $\bar{5}\bar{j}$ , is an application of great value.

Krieg recommends soziodal of soda and menthol in lanolin and vaselin: Sodii soziodal, menthol,  $\bar{a}\bar{7}$  gr. xv; lanolin,  $\bar{5}\bar{s}s$ ; vaselin,  $\bar{5}\bar{j}$ , to be used as an ointment. Resorcin in 10 per cent. solution has been recommended as an efficient application, and a host of other astringent and alterative substances which too often fail to accomplish the good result promised. Powders are used by some writers, insufflated into the nostril, but they more frequently clog the passages and produce irritation than bring relief. They are to be used, if at all, when the discharge is profuse. Camphor, tannin, bismuth, iodoform, subnitrate of bismuth, and borax, all have been used in this way, either snuffed up into the nose or blown in by an insufflator. I am inclined to believe that more harm than good is produced by this method of nasal medication, except when there happens to be an ulcerated surface, which is not likely to occur in the affection we are discussing.

Occasionally in hypertrophic rhinitis, when it happens that the obstruction is located at the anterior extremity of the inferior turbinal, and is soft, the patient suffers great inconvenience at night from his inability to breathe through the nostrils. In such cases I have found that great relief can be given by the introduction of a vulcanized rubber nasal tube, such as I use after the operation for deviated septum, which should be just large enough to remain in the nostril when inserted. This gives rise to no irritation, and enables the patient to sleep in comfort. It is not intended to bring about a cure of the hypertrophy by pressure, but merely to serve as a palliative during the temporary nocturnal swelling that occurs so frequently in this disease.

When we find the hypertrophic process to be so far advanced that ordinary treatment is of no avail, we must have recourse to measures calculated to cure by removing a sufficient quantity of the redundant tissue, and by means of the resulting cicatrix insure its permanent reduction. To do this we use caustics, acids, the galvano-cautery, the snare, either with the cold wire or galvano-caustic loop, and, in case of posterior enlargement, curettes or ring-knives. The caustic acids are used only when the hypertrophy is anterior and is soft. Those in most general use are the chromic and monochloroacetic acids. When the use of an acid has been decided on, the nostril is well washed out with a modified Dobell's solution, dried with absorbent cotton, and if the patient is sensitive it is anesthetized with a solution of cocain varying from 2 to 8 per cent. in strength, according to his susceptibility. It frequently happens that the weaker solution is quite sufficient to deaden sensation, and it is certainly safer to use it in cases where only a brief time will be taken up in any operative proceeding, in view of the toxic effects not infrequently observed after its intranasal use.

The cocain should be applied by means of a pledget of absorbent cotton, allowed to remain in contact with the affected turbinal for about five min-

utes; it is then removed and the part dried. The chromic acid is applied by means of a fine probe wrapped with cotton-wool, which is moistened and dipped in the acid, so as to permit but a small quantity to adhere. This is pressed firmly against the turbinal for a few seconds, taking care not to affect too large a surface. The acid remaining is neutralized by an alkaline solution. After a little while cicatrization with contraction follows, but the process must be repeated several times before any appreciable improvement is noticed. An interval of a week at least should intervene before an application of the acid is repeated.

The acetic acid is to be used with the same precaution and in the same manner as the chromic acid, except that an aluminum applicator with a pocket to hold the dry acid is used. In the advanced stage of anterior hypertrophy, when the fibrous change has become marked, the more powerful agency of the galvano-cautery must be invoked. The various forms of batteries and the methods of heating the cautery-knife having been mentioned elsewhere, it only remains to describe the technique of its application. The nostril having been anesthetized with cocaine, the margins of the nostril are protected by a speculum—Duplay's or a large aural speculum answering the purpose very well—otherwise they are likely to be burned. The electrode should not be large, a small knife answering every purpose. It should be heated to a cherry red, and a linear incision of the required length made through the mucous membrane. It is very important that the knife should be heated to the proper temperature; a lower degree of heat than the cherry red will give rise to severe pain, while with a white heat profuse hemorrhage may ensue. Care must also be taken not to burn the septum, otherwise the resulting inflammation may cause synechiae to form. After the cauterization the parts are to be sprayed with Dobell's solution or with liquid vaselin, repeated daily for a week, at which time another cauterization may be performed. Several applications of the galvano-cautery are usually required to produce any appreciable result.

The resulting inflammation is slight, and usually there are no uncomfortable sequences if the application has been carefully and judiciously made; yet there are cases on record where serious results have followed either a too extended and deep cauterization or when it had been made too freely to the posterior extremity of the turbinal; for it must be laid down as an axiom that this procedure can only be safely applied to the anterior hypertrophies. Störek<sup>1</sup> protests strongly against the indiscriminate use of the galvano-cautery, while believing it to be the best means of application. He complains that it is used too frequently, and especially by inexperienced men who do not know when and how galvano-cautery is to be done, who burn away the mucous membrane in all directions, from which eventual recovery never occurs. On the contrary, there results a still worse condition of the mucous membrane, which becoming adherent to the opposite side, causes synechiae and often complete occlusion. Where a patient has only had chronic nasal catarrh, he now has an occlusion of his nose that makes his life unhappy. No application of the galvano-cautery should be made except to parts clearly in the field of vision. He is so strongly impressed with the abuse of this method of treatment that he declares that if it were possible to forbid the use of the remedy by police regulation, he would be the first who would vote for it.

If the galvano-cautery is ever applied to the posterior extremity of the inferior turbinal body, it should only be by means of a guarded electrode in the hands of an experienced operator; and even then there is danger of

<sup>1</sup> *Diseases of Nose, Throat, and Larynx*, Vienna, 1895.

inflammation of the Eustachian tube with resulting purulent otitis. Erysipelas, conjunctivitis, meningitis, and septicemia are complications that have followed too bold a use of the galvano-cautery.

*Electrolysis* has been recommended by some authors; but the uncertainty of its results and the slowness of the method have prevented its being used extensively.

When the hypertrophied tissues are too extensive to be removed by caustics, or when they are soft and pendulous or circumscribed, we resort to surgical means for their removal—forceps, the ring-knife, or the snare being used.

In this country the ring-knife is rarely employed, although in England Wingrave and in Germany Störek approve its use. Wingrave, in a communication made to the British Medical Association at Bristol in 1894, reports over 200 cases of turbinal varix treated in this way, and as the result recommends the use of the ring-knife of Carnalt Jones.

In hypertrophies of the middle turbinal body it not infrequently happens that the part cannot be satisfactorily encircled by the wire-loop; in such cases strong forceps, such as are figured elsewhere, are used to remove the superfluous tissue and relieve the obstruction. But by far the most satisfactory method for the removal of intranasal growth is the cold wire snare, used in the instrument devised by the late Dr. Jarvis, or one of its many modifications. This method is preferable for several reasons. It is easily applied and can be used in the narrow passages of the nose, which would be impassable to anything larger than the wire; the inflammatory reaction which follows its use is less intense and less lasting than that following the cautery; there is less danger of infection, and if proper care be taken there is less danger of hemorrhage; but in order to insure this it is necessary that the section be made slowly, from twenty minutes to half an hour being occupied in the removal of a large hypertrophy. If this precaution is not taken serious hemorrhage may result, especially when cocain has been used as a local anesthetic, for this not only prevents sensation, but masks the bleeding by the temporary contraction it produces. While it may be said that cocain should be used in all cases, still it has the disadvantage of rendering the operation much more difficult in those cases where the enlargement is principally of the soft tissue, especially in the posterior portion of the inferior turbinals, for it so contracts the tissues that it is almost impossible to encircle them in the loop.

I am in the habit in operating by this method of using the Jarvis snare, with a modification in the manner of fastening the wire. In place of the pins around which the wire is wound, in order to hold it, on the original instrument, there is at the end of the movable cannula a steel clamp with its inner surface finely grooved, and which is governed by a screw. The ends of the loop of wire pass between the surfaces of the clamp and are retained in position by a screw working on a male screw passing through the lower clamp. This arrangement has the great advantage that a small loop can be passed into the narrowed nostril and enlarged at the will of the operator. When the loop has been sufficiently enlarged—and sometimes it is necessary to make it larger than the turbinal in order to permit of its encircling the projecting extremity—it is drawn upon until it is felt that it has the hypertrophy in its grasp. The clamp is then tightened and the loop gradually drawn in by the screw provided for that purpose.

The advantage of fastening the wire by means of the clamp over pins or any method that fixes the ends of the wire is, that if by any chance the cannula should have been screwed down to its fullest extent without cutting



through the growth, by simply loosening the clamp the cannula can be run along the wire to its original position, and, the clamp being refastened, the tightening of the loop is begun anew. This maneuver is very useful and has served me more than once in difficult cases. When the anterior extremity of the inferior turbinal is to be removed, cocaine may be used if the patient is unwilling to bear the slight amount of suffering entailed by the operation, although it renders the operation more difficult. As before remarked, the loop must be tightened very gradually, or profuse and even serious hemorrhage may occur.

When the posterior extremity of the turbinal is to be removed the operation becomes much more difficult. The location of the swelling makes it more difficult to grasp and the prolonged manipulation is harder to bear. It is not possible to give any detailed instruction as to the method of operating. Each operator, as a rule, has a method of his own, being governed by his own peculiar facility. Some, by a special knack of giving direction to the wire, are able to easily encircle the mass. Others put the loop which has been passed through the nostril in place by means of a finger introduced into the naso-pharynx, while others guide it into position by means of the rhinoscopic mirror. Whatever method is used, two objects must be carefully looked out for—viz., prevention of hemorrhage and avoidance of infection. To insure this it is necessary, after the operation has been performed in the cautious manner advised above, to use antiseptics. Aristol or dermatol blown into the nostril answers the purpose very well. A pledget of corrosive-sublimate gauze is then inserted and removed in twenty-four hours, after which it need not be replaced; but the wound must be sprayed with a modified Dobell's solution, consisting of the ordinary Dobell's with the addition of ten grains each of thymol, eucalyptol, and menthol to the pint, and afterward insufflated with the antiseptic powder every day until cicatrization is complete.

When the operation has been performed too quickly and hemorrhage follows, cold or astringents should be applied, or the nose may be sprayed with peroxid of hydrogen or a solution of antipyrin. If these means fail to stay the bleeding, it will be necessary to plug the nostril. This I do in the following manner: I take a wad of antiseptic cotton the size of a two-draehm vial or larger, according to the size of the nostril, and tie a silk ligature to its center; this is forced into the nostril so as to close its posterior opening, leaving the end of the ligature projecting beyond the nostril. On top of this, antiseptic cotton is packed until the nostril is filled and the hemorrhage checked. The end of the ligature is then cut to the proper length and fastened to the cheek alongside of the ala of the nose with a bit of adhesive plaster. If this fails to prove effective, the packing must be taken out and replaced in the same manner. This method has always stood me in good stead, and I have never had to use any other means to restrain bleeding, even when very alarming. The packing must be left in place forty-eight hours. If removed before that time the bleeding is likely to recur, and occasionally even then, in which case it must be replaced as before. If, however, there should be no return of bleeding, the nostril should be cleansed with a *very gentle* spray, an antiseptic powder insufflated, and the case treated as where there has been no complication.

When instead of the cold wire the galvanic loop is used, the same precaution as to slow section and antiseptics after the operation must be observed. If the wire is heated to a white heat and the section made rapidly, hemorrhage will inevitably ensue. It sometimes happens in a narrow nose that the portion of the turbinal removed by the snare is too large to pass the external



orifice; in such cases it falls backward into the pharynx and is expectorated through the mouth, or, as occasionally occurs, is swallowed by the astonished patient.

In addition to hypertrophy of the extremities of the inferior turbinal, other enlargements demand treatment: myxomatous degeneration of the mucous membrane of the middle turbinal, hypertrophies of the floor of the nose, and thickening of the posterior portion of the septum. Each one of these must be treated according to the nature of the hypertrophy and its location. The polypoid thickening of the middle turbinal is best removed by snare, although in careful hands the contact of the galvano-cautery will accomplish a good result. For hypertrophy of the floor of the nose when cartilaginous or osseous the electro-trephine is best suited; when soft the galvano-cautery must be used. The swellings on the posterior portion of the septum are more difficult to manage. They should only be subjected to surgical interference when they add to the obstruction of the posterior nasal passage. They are usually soft, and under the guidance of the rhinoscope can be touched with the galvano-cautery. There is not, to my mind, the same risk in its use here as when applied to the posterior extremity of the inferior turbinal, for the orifice of the Eustachian tube is less likely to be injured and there are no important structures in the immediate vicinity. When the nasal passage permits, a small electro-trephine may be introduced and the projection shaved away: but it is only rarely that this can be done satisfactorily.

Before using surgical measures of any kind, however, it is well to give a trial to local applications of the iodine and iodid of potash solution, which in some comparatively recent cases will cause the hypertrophy to disappear.

Some writers divide the treatment of chronic hypertrophic rhinitis according to the early or late stage of the disease, but in whatever stage the disease comes under treatment, the rule is always to use the mildest method that will accomplish the desired result. Only when local applications fail to reduce the enlarged structure should recourse be had to surgical measures, and then only that surgical method should be employed that will do least harm to the surrounding healthy tissue. Cases have far too frequently occurred where the discomfort of the patient resulting from too radical an operation has brought about annoyance exceeding that of the original disease.

Attention must be paid to proper hygienic measures. The same rules are to be observed as in patients suffering from simple chronic rhinitis. Exercise in the open air, bathing and friction of the skin are particularly to be insisted upon. The whole body should be vigorously rubbed every morning on rising with a horse-hair glove or a dry coarse towel and then exposed to the air for some minutes. Cold plunge-baths are not to be advised, but the patients, if not too susceptible, may use cold sponging.

Local hygienic measures consist in removing the patient from an irritating or dust-laden atmosphere, or in cases where a person's trade or profession makes this impossible, a respirator may be worn or the irritating air be prevented from entering the nostril by a thin wad of Angora wool inserted just within the vestibule, as proposed by Dr. J. Solis-Cohen.<sup>1</sup>

The constitutional measures to be employed depend on the condition producing the disease. When the gouty diathesis is prominent, suitable means must be taken to antagonize it. So with syphilis, malaria, anemia, neurasthenia, etc. No specific medication is indicated, only such remedies should be administered as are called for by the condition of each patient.

<sup>1</sup> *Diseases of the Throat and Nose.*

## DEVIATION OF THE NASAL SEPTUM.

Deviation of the nasal septum is one of the most prominent causes of chronic disease of the nose, carrying with it maladies of the accessory sinuses, troubles of audition, and various nervous affections classed as reflex, such as asthma, chorea, and headaches. It is not to be confounded with the simple thickenings of the mucous membrane over the vomer and cartilaginous septum which frequently cause stenosis; but consists in a decided bending of the triangular cartilage of the nose to either side, nearly always accompanied by a corresponding alteration in the shape of the vomer and invariably by a redundant amount of material in the cartilage itself, which may be so great in some cases as entirely to occlude the nostril, and by interfering with proper drainage and respiration cause the varied inconveniences which call attention to the malformation. The character of the deformity varies in different cases. There are five varieties of deviation to be observed. There may be—

*First.* Simple deviation of the cartilaginous septum to either side where there is a simple rounded convexity on one side and concavity on the other, with little or no thickening of the mucous membrane.

*Second.* Deviation of the cartilaginous septum in the same manner, accompanied by corresponding deviation of the anterior portion of the vomer.

*Third.* Sigmoid deviation where the cartilage is bent in an "S" shape, with a convexity at its superior and inferior portion in one nostril, and convex at the middle portion in the other, making a sharp longitudinal ridge running posteriorly.

*Fourth.* The deviation may be angular.

*Fifth.* It may be vertical, in which case the cartilaginous septum is alone involved. In nearly all cases, though not invariably, the deviation is toward the left. Sex seems to have some influence, as more cases are observed in males than in females.

**Etiology.**—There are several causes of deviation of the septum. Delavan<sup>1</sup> divides them into predisposing and exciting; he considers diathesis and racial characteristics as the most important of the predisposing causes, and believes that persons suffering from the strumous, syphilitic, tubercular, or rachitic diatheses are most liable. This view of its diathetic origin is hardly borne out in the cases that have fallen under my observation, where the majority of them seemed to be free from any constitutional taint. As regards the influence of race, deviated septa are much more common among the civilized than the savage races. This is attributed to the greater admixture of types occurring in civilized countries as the result of immigration, while the rarer occurrence of deviation among the less civilized races is due to the purity of the race. Races with aquiline noses are more apt to have deviated septa, except the American Indians, who are singularly free from the deformity.

Exciting causes may be imperfect or unequal development of the plate of the vomer, the result of malnutrition or inflammation.

Obstruction of the anterior part of one naris is considered by Collier<sup>2</sup> to be a factor in the production of the deformity by producing rarefaction posteriorly, the resulting pressure causing deviation on that side.

Deflections of the septum are usually observed in adults or adolescents, but cases have been observed in my clinic at the New York Eye and Ear Infirmary whose age did not exceed four years. Traumatism is an occasional cause of deflection, but the cases due to this cause, unaccompanied by fracture

<sup>1</sup> *Trans. Amer. Laryng. Assn.*, 1887.

<sup>2</sup> *Journ. of Laryng. and Rhinology*, vol. v. p. 91.

of the nasal bones, are so rare that it can hardly be considered as an important factor in the causation of the deformity. A very important cause is the defective development of the bony septum. The vomer consists in its early stages of two laminae enclosing a plate of cartilage which forms the cartilaginous septum; these laminae do not coalesce until after puberty, consequently unequal development of one of these laminae would push the other out of line and cause a corresponding deviation. This unequal development in different directions gives rise to the various forms of deviation observed.

Local malnutrition is, according to Inguis,<sup>1</sup> an important factor in the production of deflection. Jarvis regards the high-arched palate as a cause of deflection, the septum being crowded upward by the hard palate until it yields to the pressure brought to bear on it, the cause of the palatal deformity being explained on the theory of atmospheric pressure, occlusion of the nasal passages creating in them through inspiration a partial vacuum, disturbing the equilibrium of pressure upon the upper and lower aspects of the roof of the mouth. This inequality of atmospheric pressure, exerted during infancy and early growth of the child, gives rise to the permanent deformity of the hard palate, thus interfering with the normal development of the septum, in turn further disturbed by the disturbance of respiration.

The bony ridges found along the line of suture of the septum with the superior maxillary bone are due probably to primary injury, aggravated afterward by hypernutrition. They can scarcely be classed as deviations, though considered so by many authors who have treated of the subject.

Roe,<sup>2</sup> in a paper on the etiology of deviations of the nasal septum, considers that heredity plays an important part as a predisposing cause, not only by the dyscrasias which may be transmitted, but also by the blending of different races, bringing about an infinite variation in the conformation of the osseous and cartilaginous structures; and that trauma, nasal obstruction, and unequal growth of the component parts of the vomer are the most frequent exciting causes.

**Symptoms.**—Attention is usually called to the existence of the deformity by the functional troubles which give rise in many cases to serious inconvenience. Obstructed respiration is the most noticeable annoyance, thereby causing mouth-breathing with its accompanying inconveniences, nasal voice and post-nasal catarrh. Mackenzie<sup>3</sup> reports a case where the most troublesome symptom was epistaxis caused by erosion of the outer wall of the nose; but the great majority of patients who have come under my observation have complained of the impeded respiration caused by the obstructed nostril, and have sought relief on this account only.

Severe headaches are often caused by a deviated septum, when a deviation in the upper portion of the septum presses on the middle turbinal body, while asthma and affections of the larynx are not infrequent results. A very common symptom is the nasal voice which is nearly always present in well-marked cases. Cases have been seen by me where chronic headache and asthma were present and were relieved on restoration of the respiratory function of the occluded side. When there is considerable deviation the nose is often twisted to one side, but frequently there is only a slight twist of the tip.

**Diagnosis.**—The diagnosis of the affection is very easy and can be made even on a very superficial observation. Examining the nostrils anteriorly there is found a bulging of the cartilaginous septum into one side, either entirely or partially occluding it. On the opposite side there is a correspond-

<sup>1</sup> *Trans. Amer. Laryng. Assn.*, 1882.

<sup>2</sup> *Trans. Amer. Laryng. Assn.*, 1896.

<sup>3</sup> *Diseases of Throat and Nose*, vol. ii. p. 426.



ing enlargement of the nasal cavity, frequently filled by a hypertrophied inferior turbinal body. This is so frequent a condition as almost to be constant. The septum itself is rarely increased in thickness when there is deviation; but it often happens that the septum is thickened to such a degree as to cause obstruction, and unless attention has been called to the condition an error in diagnosis might easily be made. Inexperienced observers have mistaken a deviated septum for a myxoma, which should easily be recognized by its mobility, softness, and pale color. Whatever the form of the deviation, the symptoms are the same; they do not differ whether it be sigmoid, vertical, or a simple curved bending. It is not always possible to ascertain by anterior rhinoscopy whether the cartilaginous deviation is continuous with the bony septum; but if the case permits it, posterior rhinoscopy will reveal its existence, if present.

Practically, the coexistent deformity of the bony septum is of no importance, as the correction of the deformity in the cartilaginous portion will almost invariably restore the function of the nose and permit respiration.

**Treatment.**—Treatment of deviation of the septum is necessarily surgical; all palliative methods are useless, and simply waste the time of the surgeon and exhaust the patience of the invalid. Pressure, digital and instrumental, the use of metallic sounds, or of laminaria for gradual dilatation, are methods which have all been tried and relinquished—the irritation caused by them more than equalling the discomfort produced by the original trouble, while the results are negative.

Several methods have been devised for the correction of the deformity; they vary largely in method and principle, and most of them, because complicated in their technique, have given way to simpler processes.

Dieffenbach, as early as 1845, excised the projecting portion of the deflected cartilage with a knife. Huyler dissected up the mucous membrane from the prominent portion of the septum and removed the redundant cartilage with scissors. Adams, in 1875, proposed to correct the deformity by means of the forceps which are known by his name. He fractured the septum with them, retaining it in its proper place afterward by means of ivory plugs or steel plates adjusted by screws.

Ingals proposed an oblique incision through the convexity of the septum, then, having detached the mucous membrane from the cartilage, he excised a V-shaped piece, bringing the parts together by suture and holding them in place by tampons.

Glasgow, in 1881, presented to the American Laryngological Association the method of Steele, which consists in making a stellate incision over the deviation, through the mucous membrane and cartilage; the septum is then crowded back and an ivory plug inserted, which is worn until the cure is complete.

Jarvis, in 1882, proposed the removal of the projecting portion of the cartilage by means of the needle and snare. He pierces the base of the projection with a transfixion-needle until the point appears, a wire loop of a snare is passed over the projecting point, and the engaged portion is severed.

Roberts of Philadelphia uses pins to hold the septum in place after having corrected the deformity. He makes an incision through the septum along the line of convexity; then pushes a long steel pin through the septal cartilage of the normal nostril a short distance above and in front of the incision. Pressing the end of the nose and septum into proper position, he brings the head of the pin close to the anterior part of the septum, causing the part lying in the obstructed nostril to lie across the incision and adapt



itself lengthwise along the surface of the septum beyond. The pin is then pushed in to the head and its point deeply embedded in the soft tissues of the septum and upper and posterior part of the obstructed nostril.

Roe, in 1891, devised a fenestrated forceps for rectifying the deformity by pressure after having partially incised the cartilage by means of a modified Steele's forceps with which he cuts through the cartilage and mucous membrane of one side only, leaving the mucous membrane of the other side intact. As the incision must be made over the convex portion of the deviation, it necessarily follows that in aggravated cases it will not be possible to introduce the instrument in order to make the incision.

Watson of Philadelphia proposed a bevelled incision along the crest of the deviation through the cartilage, but not through the mucous membrane of the opposite side; the upper portion is then pressed over toward the other side until it hooks itself onto the lower and is thus held in place. The projecting base that is left can then, or after healing, be removed by the saw.

The method that I prefer and with which I have had the most satisfactory results is one presented by me at the meeting of the American Laryngological Association in 1890. It has been performed by myself and colleagues very many times and has been uniformly successful. The principle is the same as that of other operations—viz., the destroying of the resiliency of the septum, but the technique of the operation differs, and in that lies the secret of its success. The operation has been slightly modified by me since I proposed it, but in its important features it remains the same. It consists in making a crucial incision through the cartilaginous septum, breaking down by the finger or forceps the bases of the segment thus formed, and the insertion of a hollow splint. The rapidity and simplicity of the operation commend it, for it can be completed in a very few minutes, even in complicated cases. The instruments I employ in the operation are:

*First.* A pair of strong cartilage-scissors, one blade blunt and narrow for introduction into the obstructed nostril, the other, the cutting blade, of a



FIG. 570.—Straight scissors.

curved wedge-shape (Fig. 570), the slanks of both blades being curved outward so as to admit of closing without interfering with the column; the han-




FIG. 571.—Angular scissors.

dles being of steel and curved like those of a dental forceps. I sometimes use a scissors with blades bent at a right angle with which to make the horizontal cut, but it is not indispensable (Fig. 571).

*Second.* A curved elevator for breaking up any adhesions that may exist between the septum and turbinal body.

*Third.* An Adams's forceps or one with stout parallel blades, as in Fig. 572.




FIG. 572.—Compressing forceps.

*Fourth.* A hollow vulcanite splint of oval form and of a size according to the nature of the case. I formerly used a triangular tin splint, cut to adapt itself to the cartilage and held in place by a tampon of antiseptic gauze, but the discomfort experienced from the packed nostril and the danger of sepsis led me to devise the hollow splint (Fig. 573), which is thoroughly effective and by permitting the passage of air is more satisfactory to the patient. This splint is a tube of hard rubber of a proper shape to enter the nostril and hold the



FIG. 573.—Asch's hollow splint.



FIG. 574.—Mayer's hollow splint.

replaced septum in its new position. The splint as originally devised by me was rounded on its external surface—with perforations—which serve to retain it in place (Fig. 573). Dr. Emil Mayer of New York modified it by making it more oval in its caliber and consequently flatter on the sides (Fig. 574) and also larger. The splint slips up under the tip of the nose and is easily retained in its position. There have been other modifications proposed, but I am in the habit of using one or the other of these two, as the shape or size of the nostril may indicate. Both splints are made in various sizes.

The mode of performing the operation is as follows :

Before etherizing, the nostrils are sprayed out with an antiseptic solution. I am accustomed to use Dobell's solution with the addition of a few drops of thymol and eucalyptol. The patient then having been etherized and the head drawn over the edge of the operating-table so as to permit the blood to flow into the naso-pharynx, the steel elevator is introduced into the obstructed nostril and any adhesions which may exist between the septum and the turbinal body are broken up. When a deviation is the result of traumatism or complicated by it, these adhesions are sometimes bony and require a good deal of force to divide them; in such cases I find a convex gouge to be of service. The blunt end of the scissors is then introduced into the obstructed nostril and the cutting blade into the other end. An incision is made in a horizontal direction across the greatest convexity of the deviation. The scissors are then removed and reintroduced and a vertical incision made at right angles to and across the center of the horizontal one, forming a crucial incision as near as possible over the most prominent portion of the deviation. The finger is then introduced into the *obstructed* nostril, and with it the seg-

ments made by the incision are pushed into the opposite one until they are broken at their base and the resiliency of the septum destroyed.

On this point depends the success of the operation, for unless the fracture of these segments is assured, the resiliency of the cartilage will not be overcome and the operation will fail. The septum is then straightened with forceps, and the hemorrhage, which in many cases is quite brisk, is checked by a spray of ice-cold Dobell's solution. A hollow splint of a size and shape suited to the case is then introduced into the affected nostril, a smaller one into the other, and the operation is completed. The splint in the patent nostril is introduced merely to assist in preventing bleeding, and is removed in twenty-four hours, as the one in the contracted nostril suffices to hold the septum in position. This splint is removed on the second day after the operation, cleansed thoroughly and replaced, after which it is taken out, cleansed and replaced every day for at least five weeks, by which time the healing of the septum in its modified position should be complete. After the fourth day it will be easy for the patient himself to remove and replace the splint, reporting to the surgeon once or twice a week for observation until there is no further use for its application.

It sometimes happens that the lower segment of the cartilage projects into the nostril. Nearly always this projection is absorbed if left to time, but it can easily be removed by the electro-trephine or the galvano-cautery. Perforation following the operation is so rare as not to be considered as a probable sequence. The few cases which I have seen where it occurred were due to cachexia and to unskillful performance of the operation. It will not suffice, however, to make the incision, insert the splint, and let the wound take care of itself in order to get a successful result. The patient must be seen every day for the first week, and at least twice a week after that until cured.

The operation is equally effective, whatever may be the character of the deviation; whether simple convexity, sigmoid, or vertical, the same procedure will apply to all, merely taking care that the incision be made with reference to the shape of the deformity.

Other operations for the deformity consist of the removal of the prominent portion of the convexity by saws, chisels, or burrs operated by the electro-motor; but these methods are only available where there is much thickening of the septum and when the permeability of the nostril can be attained without the risk of perforation. It sometimes happens that the thickening of the septum is so great as to permit of this being done, but this condition is rare.

Thoroughly unsurgical is the method of Blandin, in which, by means of a punch, a circular piece is removed from the most prominent part of the deviation—a procedure which does not cure the deformity, but simply allows the air to pass out from the unobstructed nostril into the occluded one, while it substitutes one deformity for another, and there ensues a permanent ulceration with its attendant hemorrhage and crusts.

Cauteries and electrolysis have been used to remedy deviations of the septum, but as in the case of the saw these methods can only avail where the thickened septum is the cause of the obstruction.

Stoker and Hubert advise the use of laminaria bougies and of tampons, but it may be said with certainty that all such measures barely palliate. They cause irritation and produce conditions as unfavorable as the disease they are employed to cure.

A long experience has shown me that it is unwise to treat deviations of the septum otherwise than radically. In no other way can the discomfort produced by it be alleviated and the respiratory functions of the nose restored.

# DISEASES OF THE TONSILS, PALATE, AND PHARYNX.

BY JAMES EDWARD NEWCOMB, M. D.,

OF NEW YORK CITY.

## DISEASES OF THE TONSILS.

**General Considerations.**—A proper understanding of the relations of the various tonsils to each other is obtained by regarding them all as segments of the so-called tonsillar ring—that is, the circular continuity of lymphoid tissue, starting in the naso-pharynx and extending on each side to the lips of the Eustachian tubes, thence to the posterior surface of the soft palate, to the space between the faucial pillars (forming in the latter region the faucial tonsils), and finally uniting in the so-called fourth or lingual tonsil at the base of the tongue.

The faucial tonsils are limited above by the approximation of the faucial pillars, but extend a variable distance below. They may be said to lie in the anterior part of the pharyngo-maxillary “interspace”—that is, a space between the lateral wall of the pharynx, the internal pterygoid plate, and the upper cervical vertebrae—lying almost directly back from the pharyngo-palatine arch. This “interspace” is filled with connective tissue. Behind it are both carotid arteries, the internal,  $1\frac{1}{2}$  cm., and the external 2 cm. distant from its lateral periphery. In healthy throats at rest the tonsils do not protrude beyond the level of the pillars.

**Structure.**—A tonsil, says Harrison Allen, is an association of diverticula developed from the epithelial layer of the mucosa, in the walls of which are grouped muciparous glands and lymph-follicles. The various tonsillar deposits vary only in the arrangement of these diverticula. In the lingual tonsil they are single; but in the pharyngeal and faucial, compound. In the latter the arrangement is such as to render especially noticeable the depressions—crypts or lacunæ (not follicles)—upon the surface. Soft in infancy, they become harder as age advances, partly from the growth of connective tissue and partly from a cortical hardening due to the constant impact of food. They begin to atrophy at middle life. Their more detailed anatomy and their physiology are elsewhere discussed. It may only be said here that a rarefaction of the epithelium is constantly going on at the surface even in health, and still more in disease; so that at times and in places this epithelial layer is only one or two cells thick. Hodynpyl has shown that the intact epithelium practically prevents any absorption whatever, but that its removal affords free access of infectious material to the lymph-channels: yet this claim must be modified in view of Goodale's recent experiments.<sup>1</sup> Various micro-

<sup>1</sup> *Trans. Amer. Laryng. Soc.*, 1898.



organisms may effect a breach through this thinned epithelial layer. Hence the frequency with which the tonsils serve as the channel of entrance of various disease-poisons to the system.

Finally, it is to be borne in mind that the pathological processes affect all the tonsils alike, and that variations in local symptoms are mainly due to locality.

#### ACUTE TONSILLAR INFLAMMATIONS.

This group includes the acute catarrhal, lacunar (wrongly called follicular), croupous, parenchymatous, and suppurative varieties. The catarrhal form rarely occurs apart from an acute catarrhal pharyngitis, under which heading it will be considered. The suppurative form, or quinsy, is really a peri- rather than an intratonsillar affection.

**Acute lacunar tonsillitis** is often associated with the parenchymatous variety, into which it frequently runs. It consists of an inflammation chiefly manifested by a filling of the crypts with whitish plugs of inflammatory exudation, together with a general congestion of surrounding parts, associated with a constitutional febrile reaction.

**Causes.**—Perhaps the most frequently assigned cause is exposure to cold. But at the outset it must be premised that in the light of our present views on pathology exposure to cold has very little significance as a causative factor in this class of diseases: it probably acts but indirectly and means only lessened resistance to morbid action. All sorts of micro-organisms are constantly present in the throat, the harmful influence of which is nullified by a sound condition of the organism. Exposure to cold, by temporarily lowering the resisting power of the tissues, allows the pathogenic germs to exert their effect.

A disordered gastro-intestinal canal is found in many instances, particularly in patients subject to the so-called bilious attacks. Causative factors are also found in the rheumatic and gouty diatheses. In regard to rheumatism, its frequency as a cause has, in the opinion of the writer, been greatly exaggerated. His records of 586 cases of various forms of tonsillitis and pharyngitis show 154 presenting evidences of rheumatic tendency, or 26.2 per cent.; while 432, or 73.8 per cent., presented no such evidences. These figures differ from those of Haig Brown, out of whose 119 cases 64, or 54 per cent., had some rheumatic tendency. Fowler believes that 80 per cent. of all cases of rheumatism have had previous sore throats; but the line of argument followed by him does not seem convincing with reference to the point at issue. Hope denies that the tonsils are a selective area for the rheumatic poison which, he says, attacks sero-fibrous rather than muco-fibrous structures, such as the tonsils really are. He even regards it as rare to meet with examples of recurring angina in those who carry recent or unmistakable evidences of a rheumatic attack.

Chronic enlargements of the tonsils naturally invite recurring inflammations. Suppressed menstruation seems to be a factor in some cases. Entrance of foreign bodies, sudden changes in atmospheric conditions, and exposure to odors from defective drainage are also causative factors. The latter may be regarded as a type of a wide range of septic influences. Hospital attendants frequently suffer from this affection.

Fränkel and Lennox Browne find intranasal operations to be a frequent excitant of this form of tonsillitis. It seems to follow the use of the galvano-cautery rather than that of cutting instruments. The reason assigned is that for a time after the cauterization the filtering function of the nares is held in

abeyance, and that some of the bacteria found in the nose are stimulated into an abnormal virulence.

**Pathology.**—Either one or both organs may be affected. They are swollen and reddened, while the surrounding tissues become more or less edematous. This edema is frequently marked in the soft palate and uvula, the latter often being deviated to one side. The mouths of the lacunæ are filled with whitish plugs composed of dead epithelium, leukocytes, and various micro-organisms. Sometimes more or less thick tenacious mucus is so evenly spread over the walls of the lacunæ as to suggest a false membrane, but it can be easily brushed off, leaving no bleeding surface, and it does not contain fibrin.

As to bacteriological findings, both staphylococci and streptococci are present. Fränkel believes the latter to be the pathogenetic cause. Meyer found in 53 cases, 14 with staphylococci (generally staphylococcus aureus), 24 with a mixture of the two, and 15 with streptococci, in pure culture. A diplococcus resembling (and perhaps identical with) that of pneumonia has also been met with. The varying proportion of these two micro-organisms causes no appreciable variation in the clinical features of the disease. Meyer's researches show that the secretion from non-inflamed tonsils ordinarily contains a coccus very analogous to the streptococcus pyogenes, a small growth often arranged in pairs, staphylococci, and leptothrix growths.

**Acute Parenchymatous Tonsillitis.**—Very frequently the foregoing condition is present without any marked enlargement of the tonsil; but often the organ becomes greatly increased in size from the exudation of inflammatory products into its substance, so that we have a combination of the lacunar and parenchymatous forms; or, again, the organ may be greatly swollen while the mouths of the crypts are clear.

**Symptoms.**—The symptoms in both forms are essentially the same. The local manifestations may either precede or follow the general. The latter assume the type of an acute infectious disease. There is more or less chilliness, followed by fever of rapid rise ( $104^{\circ}$  F.), with corresponding changes in pulse and respiration, headache, constipation, thirst, anorexia, general malaise, and bodily pains, with an amount of prostration out of all proportion to the apparent severity of the local lesion. The worst cases show clammy sweats, restlessness, insomnia, and even delirium. The local manifestations begin with pricking or tingling sensations referable to the throat, soon changing to a continuous pain. It becomes increasingly difficult, especially in the parenchymatous variety, to open the mouth; the glands of the neck become swollen and painful, the pain radiating to the ears. Partial bluntness of hearing, taste, and smell is not uncommon. A sense of suffocation (occasionally a real danger thereof) results from the glandular swelling. The throat is constantly filled with a thick, tenacious mucus, attempts at swallowing which (or also talking) greatly increase the patient's distress. The tongue is coated and the breath offensive. Deglutition is often agonizingly painful, and fluids sometimes regurgitate through the nose. Persistence of the fever sometimes brings out a rash of an erythematous type.

**Differential Diagnosis.**—Scarlatinal throats sometimes present lacunar inflammation, but here the disease is usually ushered in with vomiting; and the appearance of the rash within twenty-four hours settles the question. Also, the facial congestion is generally much more extensive, while the actual swelling of the parts is much less. The appearance of the tongue also helps us.

In primary specific sore throat the lesion generally appears in symmetrical areas on both sides. The congestion is of a duller red hue; pain is slight and fever generally absent. In fact, it is rather from the simple catarrhal than the lacunar form of tonsillitis that this condition has to be separated.

From diphtheria the diagnosis is not always easy. We now recognize bacteriologically a lacunar diphtheria—that is, a true diphtheria with the exudate confined to the walls of the lacunæ. To the eye and in its clinical features it resembles precisely the lacunar form of acute tonsillitis. The culture-medium alone will enable us to decide. Many instances of reported contagion in lacunar tonsillitis have doubtless been truly diphtheritic. It may be said that in diphtheria the exudate occurs in large patches, is generally of a grayish hue, and of a more ragged appearance. A bleeding surface after removal is no proof of true diphtheria, but only of a croupous inflammation—that is, exudation with degeneration of tissue. Moreover, here the constitutional symptoms come on more slowly and the temperature rarely rises so high; indeed, may be even subnormal.

*Course.*—The disease lasts from one to fourteen days, averaging four or five. It may leave the tonsils chronically enlarged, or before subsiding go on to a quinsy. A few cases have resulted fatally, but the prognosis is regularly good.

*Treatment.*—If cases are seen at the very outset, the disease can sometimes be aborted by painting the tonsils with strong solutions of cocain, with pure guaiacol, or with silver nitrate (15 per cent. solution). A mercurial purge followed by a saline should be administered, and small and frequent doses of aconite, belladonna, or opium should be given. The writer has used with success the familiar “tonsillitis tablet” composed of—

|                       |                          |
|-----------------------|--------------------------|
| R. Tr. aconit.,       | ℥ $\frac{1}{5}$ ;        |
| Tr. bryoniæ,          | ℥ $\frac{1}{10}$ ;       |
| Tr. belladonnæ,       | ℥ $\frac{1}{10}$ ;       |
| Red iodid of mercury, | gr. $\frac{1}{100}$ .—M. |

Of these, one may be taken hourly for three hours, and one every two hours thereafter. At the outset, cold compresses may be applied to the neck; while if the case goes on to full development, hot applications will afford greater relief. Frequent gargling with a hot solution of bicarbonate of soda in water will remove the clogging mucus.

Most cases, however, are well advanced when they come under medical care, and of remedies proposed in this and later stages there is no end. Guaiac given in the form of lozenges or dram doses of the ammoniated tincture has long enjoyed a reputation in curing this condition; but it is uncertain in effect and very disagreeable in taste. For some years the writer has had the best results with salol, given in hourly doses of five grains in mucilaginous suspension (not tablets) flavored with some essential oil. He has found that in a series of 81 consecutive cases, watched with reference to this fact, the pain was relieved on an average in fifteen hours. Allowing for sleep, not more than ninety grains are taken in the twenty-four hours, and this daily dosage is perfectly safe unless there be definite kidney-trouble. In a few cases of the above series the urine assumed a darkish color. Salicin has been credited (if continued for a week or more after the subsidence of the active symptoms) with the power of preventing subsequent persisting hypertrophy. Other drugs of value are sodium sal-



icylate, antipyrin, and the muriated tincture of iron. The latter sometimes proves surprisingly efficacious after one has used in vain some of the newer and much-praised remedies. The self-limited nature of the affection must be borne in mind when estimating the value of any remedy. Scarifications, incisions, or punctures are not recommended in this form of tonsillitis. Occasionally relief follows the digging out of the crypts with a small sharp scoop.

It is well to isolate every case of sore throat, although the direct contagious nature of lacunar tonsillitis is still a matter of dispute.

**Acute Croupous Tonsillitis.**—By the term “croupous” is here meant an exudative inflammation leading to the degeneration or death of tissue. The change may involve the epithelial covering only, or may extend through the entire mucosa with swelling of the surrounding tissues. The exuded fluid, rich in fibrino-plastic material, coagulates on the surface of the mucosa, forming the false membrane.

**Causes.**—This variety frequently occurs as a complication of the exanthemata and various infectious diseases. It is seen occasionally in the later stages of renal trouble and of the wasting maladies. In one sense it may be said that the special form due to the Löffler bacillus is the lesion of diphtheria, but that is not what is meant by the title above used. It may also occur as a primary affection from almost any of the causes mentioned under the lacunar form.

**Pathology.**—We find here the typical false membrane from the coagulation of the exuded *liquor sanguinis*, rich in fibrino-plastic material, and from the emigration of leukocytes. Fibrin is thereby formed on the mucosa entangling the leukocytes, now appearing as pus-cells in its meshes. Subsequent coagulation-necrosis leaves either superficial erosions or ulcers of varying depth. Bacteriologically the staphylococcus and streptococcus are the most common excitant organisms. Some classifications would include the pseudo-bacillus of Löffler. It is not yet proven that a simple streptococcal sore throat is necessarily contagious in the popular acceptance of the word.

**Symptoms.**—These are in a general way the same as those of lacunar tonsillitis, although generally of a greater severity. The tonsil may be but little swollen and the exudate limited to its convexity. The swelling of the cervical glands is generally noticeable, as is also the prostration.

**Diagnosis.**—The disease most nearly resembling simple croupous tonsillitis is diphtheria. Here, again, it is asserted with much emphasis that culture-tests alone can decide in doubtful cases. The local appearance may, in the light of each practitioner's experience, incline him to this or that view, but bacteriology alone can settle the question. The disease generally runs from six to eight days, often leaving the patient very weak and anemic. Recovery is the regular rule.

**Treatment.**—The measures outlined for the treatment of the lacunar form may be tried; but in the majority of cases it is better to rely on a constitutional tonic-treatment and keep the mouth as thoroughly disinfected as possible. A 1:3000 bichlorid mouth-wash is as efficient as any, and when the membrane begins to come away, hydrogen dioxide solutions (equal parts freshly mixed with lime-water) may be employed.

**Acute Circumtonsillar Inflammation.**—It has been customary to speak of this disease as a suppurative tonsillitis or quinsy. The former is objectionable in that it implies that the tissue of the tonsil proper suppurates, while the truth is that this change takes place in the vast majority of cases in the connective tissue surrounding the tonsil, especially in front of and above it.



**Causes.**—These are the same as those of the varieties of inflammation previously described. Any case beginning as lacunar or parenchymatous may go on to suppuration. The latter may follow a specific affection of the organ, as in the case reported by J. H. Bryan.

**Pathology.**—We have here a pure phlegmon of the circumtonsillar cellular tissue. The tonsil may be pushed inward from the pressure of the inflammatory products and appear enlarged where it really is not. Occasionally the suppurative process actually invades the tonsillar substance. The abscess is more apt to point in the upper part of the anterior pillar or just above it; less frequently lower down in the posterior pillar. Occasionally the pus burrows its way to the bottom of one of the tonsillar crypts, through which it may be seen oozing to the surface.

**Symptoms.**—These are of much the same character as before given, and are generally of a severe type. If the suppuration is secondary to one of the other forms, the pus-formation may engraft upon the preceding symptoms a distinct additional rigor, with high fever and profuse sweating. The swelling in the fauces becomes extreme. The whole side of the pharynx becomes enlarged, tense, and brawny. The soft palate is pushed forward and a tumor may be felt in the neck. It is often impossible for the patient to open the mouth at all, even to admit a tongue-depressor. Swallowing is also often impossible. The uvula becomes edematous and obstructs free respiration. If left to itself and only one tonsil is attacked, the disease generally runs its course in a week, by which time the abscess will have burst. Recovery is prompt. The involvement of the other tonsil means another period of misery. A serious, though fortunately a rare, complication is edema of the glottis. The bursting of the abscess during sleep may cause some of the pus to be swallowed and the patient may awake choking. No fatal cases from this cause alone are personally known to the writer, but one or two are on record.

**Treatment.**—This is at the outset the same as for the lacunar and parenchymatous forms. If pus-formation is apparently brewing, hot sponges to the neck and the vapor from hops in boiling water are grateful to the patient. Alkaline washes help to keep the mouth clear from thick mucus. Early incision is advocated. It is permissible as soon as there is any fullness about or protrusion of the faucial pillar, and should be followed up by flushing the mouth out with hot water. Where we suspect pus the blade of the scalpel should be passed in at least half an inch, held horizontally, and the direction of the incision should be from without inward toward the median line. Deep-seated pus is in this way frequently evacuated where more superficial puncture would be useless. In other words, our aim is the general one to get rid of the pus as soon as it is formed, and we treat the abscess on general surgical principles. Internal remedies are useless after pus has once formed. The syringing of the pus-cavity with a long curved tube attached to a syringe full of antiseptic solution has in some cases apparently hastened convalescence.

**The Lingual Tonsil.**—The fourth, or lingual, tonsil is situated between the circumvallate papillae and the anterior surface of the epiglottis. It resembles the faucial bodies in structure, except in that the arrangement of the diverticula of its epithelial layer is single, while in the faucial bodies it is compound. Concerning physiology and pathology, the same general remarks apply to both regions.

Simplicity of classification is furthered by saying that we may have here the simple catarrhal, the lacunar and parenchymatous, and the circumton-

sillar varieties, as previously outlined. The list of causes and the nature of the lesions are identically the same. Ruault states that poisoned saliva from dental caries has a special effect on the lingual tonsil.

The general symptoms are those already described under the faucial tonsillar inflammations. The local symptoms vary somewhat from the faucial type, and this variation is due to the different area affected. Thus, the feeling as of a foreign body in the throat is especially prominent. Cough is frequently referred to the larynx, while the pain is especially referred to the root of the tongue.

In the lacunar type of the disease the constitutional symptoms are apt to be more severe than in the corresponding inflammation of the faucial bodies. The epiglottis may become swollen and even the structures around the glottic opening, thus causing dyspnea, which is at times alarming and sometimes demands operative relief. The initial pain is frequently referred to the hyoid region.

The circumtonsillar or suppurative form (lingual quinsy) is less common than in the fauces, owing to the scanty amount of connective tissue at the root of the tongue. The special point of importance is the recognition of the precise malady with which we have to do. The mirror and the finger should both be used as aids to diagnosis. Incision of a fluctuating area is preferably made with the galvano-cautery. It is worth remembering that these cases are sometimes ushered in by an attack of edema of the glottis. Spontaneous evacuation of the abscess during sleep, especially if it discharges posteriorly, introduces an element of great danger. Cases of chronic abscess and of retention-cysts in this region are on record.

The various forms are often overlooked because the physician contents himself with simply using the tongue-depressor, a procedure which does not bring the area of the lingual tonsil into view. The laryngeal mirror will reveal the lacunæ choked up with inflammatory plugs and show the enlargement of the tonsil as a whole, either as a median single mass or as bilateral masses separated by a furrow. Palpation with the finger will reveal the existence of fluctuation when pus has formed.

The treatment of these various forms of lingual tonsillitis is identical with that of the corresponding forms of the faucial affections. As local applications we may use tannin and morphin, glycerite of boro-glycerin, weak cocain solutions, and menthol in olive oil or alboline (gr. xv-5j). During the acute stages the vapor of boiling water poured on hops is gratefully borne, and convalescence may be hastened by swabbing with diluted perchlorid of iron (one part to eight or ten of water). The worst cases of this variety may suggest Ludwig's angina.

**Acute Ulcerative Tonsillitis.**—Under this heading Moure has recently called attention to a sub-variety of lacunar tonsillitis characterized by the presence of large ulcers which closely resemble syphilitic lesions. The tonsils present, more frequently on their mesial aspects, grayish patches covered with a cheesy coating of some thickness, but easily removed and leaving a mammillated surface. The borders of the ulcer are clean cut but not particularly swollen. The remainder of the organ may or may not be enlarged.

These ulcers may be single or multiple, without any tendency to coalesce. They may follow one another on the same tonsil, so that the organ may at one time exhibit different stages of the lesion. The process seems to start as an acute inflammation in the crypts. The gross appearance is compared by Moure to that of a cauterized tonsil from which the slough is about to separate (Fig. 575).

No special cause for this sub-variety has as yet been proven. The disease seems to attack by preference young adults, and to be more prevalent in the spring and fall.

**Symptoms.**—These correspond to an extremely mild form of the ordinary lacunar disease. The cervical glands are rarely affected.

**Treatment.**—The ulcers should be thoroughly cleansed with zinc-chlorid solution (1:30) containing a little cocain, and then a bromid gargle in glyce-

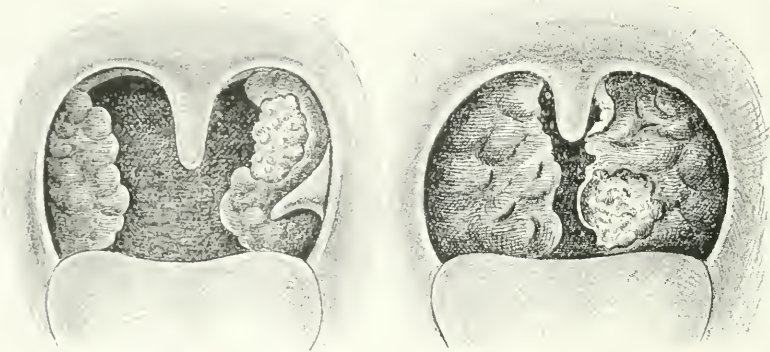


FIG. 575.—Acute ulcerative tonsillitis (Moure).

rin and water should follow. All pharyngeal irritants should be avoided. Initial curetting of the affected area has been done with success.

The writer has seen but one case which he would place under this heading. In this instance the left tonsil of an Italian, about thirty-five years old, presented a crateriform ulcer corresponding to the description above given. Doubtless certain cases of this nature have been regarded as ulcerating gummata. The gumma, however, is generally near the periphery of the tonsil, so that the neighboring parts are rapidly invaded. Moreover, the edges of the specific ulcer are generally surrounded by an angry red zone which is wanting in the lacunar ulceration.

#### CHRONIC TONSILLAR INFLAMMATIONS.

Modern pathological views enable us to distinguish the same varieties of chronic as of acute tonsillar inflammations. The chronic catarrhal form is really one element of a chronic pharyngitis, under which heading it is referred to. The existence of a chronic croupous form is a matter of some doubt. A special variety attended with an exudate due to the bacillus coli communis is referred to later in this article.

**Chronic Lacunar Tonsillitis.**—**Pathology.**—In this condition the tonsils are but little if at all enlarged, but the crypts become filled from time to time with cheesy masses. This seems to result from the narrowing or bridging over of the crypt-orifices, either by inflammatory processes or by a sort of villous ingrowth (Sokolowski) of the epithelium into the lacunæ. Retention of crypt-contents leads to dilatation, irritation, and inflammation. The plugs thus retained are composed of epithelial debris, leukocytes, fatty granules, cholesterolin, and various mycotic elements. They frequently emit a very offensive odor.

**Symptoms.**—The symptoms of the condition are faucial irritability



(tickling, burning, feeling as of foreign body), with pain radiating toward the ears, and increased on swallowing. The breath is fetid and the tongue frequently coated. Singing and smoking aggravate the symptoms. The expulsion of the plugs is followed by relief. The patients are frequently very much worried about themselves.

Inspection does not always reveal the condition. The probe must be used and the crypts explored. According to Gumpert, two sites must be closely scrutinized: (1) the upper extremity of the tonsil, between the pillars—the so-called epitonsillar fossa; and (2) the middle of the tonsil, directly behind the anterior pillar. The condition is frequently overlooked, and the faucial dysesthesia is referred to dilated lingual veins, enlarged pharyngeal follicles, hysteria, etc. Meanwhile, the patient gets no better.

**Treatment.**—The crypts should all be cleared out by some spud-like instrument or scoop and then slit up thoroughly. The bared areas should then be vigorously rubbed with a strong solution of iodine and potassic iodid, of each ʒjss to water ʒj. This generally effects a permanent cure.

**Chronic Tonsillitis Due to the Bacillus Coli Communis.**—Recent French writers have insisted that there exists a form of chronic tonsillitis due to the bacillus coli communis, and with a definite clinical course. Its characteristics are:

1. Its chronic course, beginning, it is true, with a brief stage of acute inflammation.

2. Its extreme persistence, since none of the therapeutic measures habitually directed against anginas are able to modify it. In one case only excision of the tonsil sufficed to remove it.

3. The slight intensity of the local subjective symptoms, no pain in the throat, no dryness or hypersecretion; at times a slight difficulty in swallowing when the exudate becomes confluent.

4. A notable deterioration out of all proportion to the local condition, and generally manifested in digestive disorders. These features are clearly of tonsillar origin, as they lessen after the clearing out of the crypts, but return upon the reappearance of the exudate.

5. The characteristic appearance of the tonsillar exudate—viz., a dull-white color, semisoft consistence, punctiform masses emerging from the crypts, but not, as a rule, encroaching upon the intercryptic surface, the mucosa covering which presents only a slight redness. Occasionally the masses coalesce, suggesting a pseudo-membrane, slightly adherent but removable without leaving a bleeding-surface, resistant, and not disintegrating when placed in water.

6. The integrity of the peritonsillar and pharyngeal regions.

7. The absence of glandular enlargements.

Bacteriologically, the exudate shows a pure culture of the bacterium coli commune, not only on the surface but in sections of the tonsillar tissue. The micro-organism differs from that isolated from the intestine in certain minor culture-reactions.

The authors, moreover, declare that this germ is frequently found in healthy human mouths, and express the belief that this form of tonsillitis is frequently overlooked. The most common condition with which it might be confounded is the ordinary leptothrix mycosis. But in the latter the exudate is generally hard and horny, is removed with difficulty, and under the microscope reveals its characteristic mycelial threads and spores.

**Chronic Parenchymatous Tonsillitis.**—This is one of the most common affections with which we have to do. It may occur as the result



of preceding acute attacks; or it may be seen so early in life that it is impossible to say just when it began. It is regularly found in strumous children and in those living under bad hygienic surroundings. It may, however, occur in grown people without any dyscrasia and in those comfortably housed and fed.

**Pathology.**—The entire tonsil is enlarged (one or both) and of varying consistency. In the child or in very recent cases in the young adult it feels more or less pulpy, while in the older cases it is distinctly hard. Under the microscope it is seen that the lymphoid elements have undergone a true hyperplasia and that more or less connective tissue has developed. This may be seen even by the naked eye as irregular trabeculae running through the mass, and by their contractile tendency hardening the latter (Fig. 576).

Not infrequently we find that the anterior pillar of the fauces appears as a broad and thick fibrous band, which completely envelops the anterior half of the tonsil; and by a process, apparently of contraction, has pressed and rotated the latter backward, so that whatever remains of its free surface presents toward the posterior wall of the pharynx. Adhesion to the posterior faucial pillar may also occur.

This connective-tissue development bears on the question of possible hemorrhage after tonsillotomy. It leads to a canalization of the blood-vessels, so that after section their mouths are held open and they cannot retract within their sheaths. The organ may feel soft at the surface but be quite hard at the plane of the section. Its general state constantly invites fresh inflammatory attacks. The crypts become clogged up, and the waste

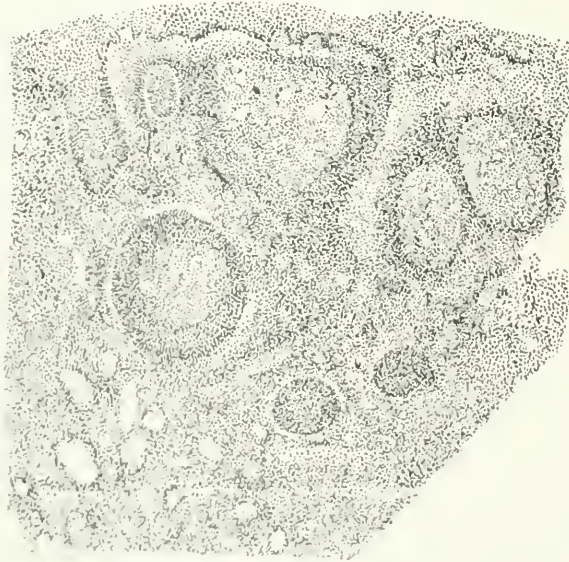


FIG. 576.—Hypertrophy of the faucial tonsil (Seifert and Kahn)

products accumulating behind these plugs lead to renewed inflammation. Removal of a layer of surface-tissue corresponding to the depth of these crypts will often give surprising relief to the constant series of outbreaks, although, of course, such a plan of treatment is to be condemned as not being sufficiently thorough.

**Symptoms.**—Enlarged tonsils are in a sense foreign bodies and give rise to symptoms accordingly. All functions of the surrounding parts are more or less hindered. An enlarged pharyngeal tonsil (so-called "adenoid vegetations") may coexist with enlarged faucial tonsils; and it is difficult to determine to which of the two areas of diseased tissue a given symptom is to be referred. The voice is thick, the patient speaking as if the mouth was partially full, and some of the normal nasal resonance of phonation is lacking. Breathing is somewhat interfered with, although in adults true dyspnea is rare. In children, however, the oro-pharynx seems to be encroached upon, so that a slow carbonic-acid accumulation in the system takes place. Snoring and mouth-breathing may occur. The need of oxygen finally becomes so great that the child, if asleep, will wake up suddenly, presenting the familiar "night-terrors." The senses of taste, smell, and hearing are more or less blunted, and there may be actual aural inflammation. The enlarged tonsils, moreover, interfere mechanically with the actions of the delicate muscles which govern the functions of the Eustachian tubes.

Children with enlarged tonsils are apt to suffer from defects of chest-development and general physique. They will sometimes improve with marvellous rapidity after the pharynx is cleared out. Doubtless many chest-deformities referred to enlarged tonsils should be referred along with the latter to some underlying diathesis. The breath is offensive, the stomach frequently disturbed, and the bowels disordered. The inspired air passing over the diseased crypts containing cheesy plugs of decayed epithelia, fermenting mucus, and particles of food, the child is constantly inhaling a vitiated atmosphere. Nocturnal enuresis is sometimes present.

**Diagnosis.**—Even a casual inspection of the fauces will reveal the enlarged masses, which the act of gagging throws out still more prominently into view.

**Treatment.**—The condition offers no hope of improvement if left to itself. It is true that the tonsils will atrophy in later years, but by this time irreparable damage may have been done in various directions. If the tonsils are large enough to cause any of the foregoing symptoms, they should be removed. The only question is as to preference of methods in such removal.

In children tonsillotomy with some approved instrument is preferable (for operation, see page 1205), and it is the writer's experience that a more satisfactory removal can be accomplished without anesthesia than with it.

Where the tonsils are large but flat and non-projecting it is difficult, if not impossible, to engage any considerable portion of them within the ring of the guillotine. Under these circumstances we may employ ignipuncture (see below) or the method of Ruault—"traitement par morcellement." He has devised a tonsil punch-forceps, by which pieces of the tonsillar substance may be bitten off. This instrument will engage in the tonsillar tissue if the surface of the latter is at all uneven. If it is smooth, the crypts should first be scraped out, adhesions to the faucial pillars broken down with a palate-hook, and the tonsillar surface incised with a small blade set at a right angle to the axis of its shaft. In this way bits of tissue are presented to the punch-forceps for removal. After bleeding has ceased, the raw surface should be vigorously rubbed with a cotton-carrier dipped in a solution of iodine 1 part, potassium iodide 1 part, water 8 parts. A smart stinging sensation ensues, which passes off in twenty minutes. Secondary retraction of the stump greatly increases the amount of reduction in size.

In older patients the use of the guillotine is somewhat hazardous, owing

to the liability to hemorrhage. We may use here either the cold-wire or galvano-cautery snare—the latter being the one more frequently employed. The cold snare can be used with a stiff wire which can be accurately adjusted. It can be tightened slowly and hemorrhage thereby avoided. It is extremely painful, and owing to the time its use requires, the latter necessitates in children a general anæsthetic. In adults the cold snare can be used under cocaine.

The hot snare (galvano-cautery loop) has the advantage of being practically a bloodless operation. The wire should be of irido-platinum, which is much stiffer than pure platinum wire, while retaining also all of the latter's advantages. It is somewhat difficult to adjust the loop and hold it in position until the current can be turned on, unless the tonsillar mass to be removed is of considerable size. It is therefore often of service to make on the posterior aspect of the tonsil a groove either with a bent electrode or with the concavity of the loop itself. In this way the latter will hold and not slip off when it is tightened. The current should be turned on and off alternately, the snare being tightened in the meantime, the latter part of the cautery-section being slowly made.

It is not necessary to remove the entire tonsil. A thick slough will eventually come away, causing a still further shrinkage of the tonsil. It has been said that entire removal of the latter leaves an annoying dryness of the mouth, but this has not been the personal experience of the writer.

Where the shape or disposition of the tonsillar structures is such as to necessitate removal by piecemeal or gradually, we have in addition to the method of Ruault that of ignipuncture. This can be made practically painless by injecting one or two drops of a 5 per cent. cocaine solution under those areas selected for operation. The cautery-tip should be inserted deeply into a crypt, the current then turned on, and the tip be made to burn its way diagonally outward. Eight or ten such punctures can be made at each sitting. The throat is quite sore for a day or two, and it is better to attack only one tonsil at a time. Ice-water gargles and antiseptic mouth-washes can be used *ad interim*. There is a great variation in the rapidity of shrinkage after such treatment—some tonsils rapidly melting away, as it were, while others require repeated sittings. Care should be taken to avoid burning the faucial pillars, for the minute cicatrices thus formed are apt to become neuralgic foci on every slight cold in the throat.

Of course, neither the cautery-snare nor -tip should be used without a rheostat. It must be remembered that contact with moist tissues quickly abstracts heat from the wire, and allowance must be made accordingly.

**Chronic Inflammation of the Lingual Tonsil.**—For all practical purposes only the parenchymatous variety need be mentioned. One case (perhaps others) has been recorded of chronic encysted abscess in this situation.

The affection has been commonly regarded as more frequent in women about middle life and with a history of previous menstrual disorders than in men. Out of 17,566 cases of throat-trouble, Lennox Browne found varicose veins at the base of the tongue associated with hypertrophy of the lingual tonsil in 1866, or 10.6 per cent. Again, in 1547 cases, 438, or 28.3 per cent. Of this latter group, however, only 31 per cent. were in women, while 69 per cent. were in men. Of his private cases, 99 per cent. were voice-users.

In any event the affection is one belonging to the period of middle life, and this is a point worthy of note, because at this age atrophy of all the tonsillar structures is generally present. Hickman has recorded the case of a child



dying of asphyxia a few hours after birth, supposedly from a congenital glottic tumor, but the autopsy revealed an enormous hypertrophy of the normal tissue on the posterior part of the tongue.

Other causes are those in general of the various forms of chronic tonsillar inflammation, including especially all forms of irritant ingesta.

**Pathology.**—The enlarged lymphoid mass may be situated in the middle line, or there may be a mass on each side with a deep furrow between. The growths often project sufficiently to infringe upon the edges of the epiglottis and even to compress the latter (the so-called “incarceration of the epiglottis”). Minutely examined, we find nodular elevations which exhibit a

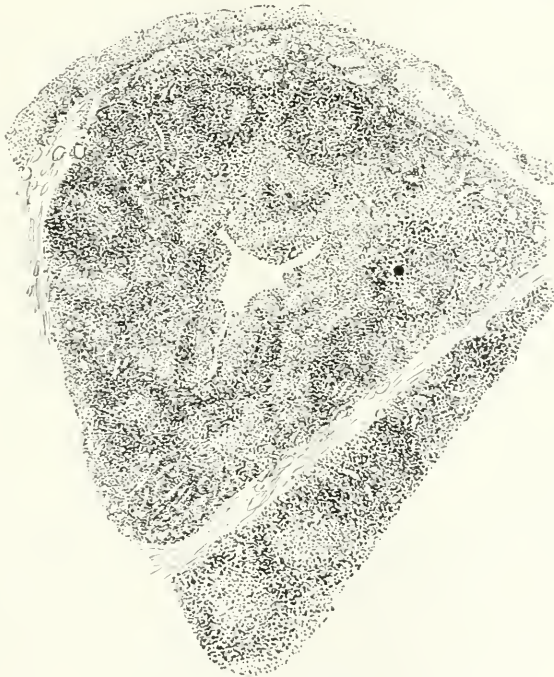

FIG. 577.—Hypertrophy of the lingual tonsil (Seifert and Kahn).

well-marked umbilication. This latter is a central crypt due to a depression of the stratified epithelium. Such crypts are sometimes lined with ciliated epithelium. In minor cases the enlargement may consist almost entirely of an epithelial hyperplasia, which is hard and wart-like rather than soft like the typical lymphoid overgrowth (Fig. 577). The lymphatic channels from this region pass directly backward, and after coursing through the deep lingual glands join the deep cervical glands in the neighborhood of the bifurcation of the common carotid artery.

**Symptoms.**—The principal symptom is pharyngeal dysesthesia, manifested in a great variety of ways. There may be every intervening grade between a slight tickling and a sharp stinging pain. At other times there is a sensation as if the throat was grasped from the outside and forcibly compressed, or there may be the sensation as of a foreign body stuck in the tissues, with a constant desire to clear the throat.

Manifold varieties of reflex or direct neuroses are often present. The purity and vigor of the singing voice become impaired; esophageal spasm is



frequently evoked, and the condition of the lingual tonsil should never be overlooked in searching for the cause of *globus hystericus*. Asthmatic attacks are not uncommon. The patients are, as a rule, extremely neurotic, and women especially are apt to fear that these pharyngeal disturbances are the forerunners of cancer.

**Treatment.**—The condition is not a serious one, and the annoyance it causes is out of all proportion to its real pathological importance. But patients have a just grievance and have a right to demand relief. This does not come without interference. Outside of the cessation of any vicious practice in eating, drinking, voice-use, etc., the end to be sought is the reduction in size of the offending mass.

If necessary, a previous application of cocaine should be made before any manipulative measures are attempted. If the masses are large enough to engage in the ring of the tonsillotome (especially the Mackenzie instrument, curved to correspond with the curve of the tongue), the latter may be used to remove them. We may also use the cold-wire snare in a curved cannula, employing transfixion-needles to insure engagement of the snare in the tissue. The ordinary curved uvulotomy scissors will answer in some cases, or we have also at our disposal the hot snare.

When the growth is diffused, some sort of caustic must be employed. Nitrate of silver is useless because its action is too superficial. Chlorid-of-zinc solutions, caustic pyrozone, and chromic acid are at our disposal. Perhaps the cauterizing agent most frequently employed is the galvanocautery tip at a dull-red heat, five or six punctures being made at each sitting. Caustics should not be recklessly used in this situation, for the formation of too much cicatricial tissue at this point may eventually aggravate the very condition we hope to relieve. More important than this, however, is the fact that too much irritation might start a neoplastic formation liable to assume a malignant character.

Hemorrhage after any cutting operation here is usually slight. Swelling is for a time very painful. Ice-pellets should be freely used. All hot drinks, spices, condiments, and coarse foods should be avoided for a day or two.

In the use of caustics special care must be taken to avoid injuring the epiglottis, which is apt to react severely to very slight trauma.

#### LINGUAL VARIX.

Apart from the enlargement of the lingual tonsil, the veins in this situation may become tortuous and dilated, assuming a varicose condition. To this have been given the names of lingual varix, hemorrhoids of the tongue, etc. As to the local physical condition, it is practically identical with that in rectal hemorrhoids.

**Causes.**—The affection is rare before the twentieth year, and far more common about middle life. It most frequently occurs in patients with torpid liver and those who suffer from chronic dyspepsia associated with constipation and piles. It may be present in almost any chronic visceral affection obstructing free venous return, and occasionally seems to be one of the local manifestations of a general tendency to vaso-motor neuroses.

**Pathology.**—The veins are entangled and appear as a network of dark-red or reddish-blue streaks or bands, with here and there local dilatations; or there may be actual nodosities, small ampullæ in which the blood-current stagnates.

**Symptoms.**—The symptoms are the same as those of simple enlarge-

ment, with the important addition that from time to time small hemorrhages may occur. These, while rare, generally give great alarm to the patient, as he is apt to regard them as the forerunner of lung-trouble.

**Treatment.**—The digestive apparatus and bowels should be regulated and any dietetic errors corrected. The vessels are best obliterated by the galvano-cautery tip at a dull-red heat and under the general precautions already noted.

#### CHRONIC ENCYSTED TONSILLAR ABSCESS.

Among the causes of tonsillar enlargement may be mentioned the occurrence of chronic encysted abscess. This condition has been carefully studied by Peyrissac, who has analyzed ten cases. Some presented a hard condition of the organ, suggesting a fibroma. They are to be regarded as similar in their mode of origin to the ordinary cold abscess, although they have no tubercular element. Bacteriologically, they have no characteristics other than those of abscesses in general, and do not seem to have any relation to a special diathesis.

An intermittent purulent discharge may suggest the nature and underlying cause of the tonsillar enlargement. The contents of the abscess-cavity may be grumous or syrupy in consistency. The pus-cells show marked fatty and granular degeneration, and are rich in cholesterolin-crystals. The lining wall is apparently of a low grade of connective tissue, organized from the surrounding tonsillar parenchyma.

The **treatment** is not attended with any particular difficulty.

#### POLYPOID HYPERTROPHY OF THE TONSIL.

Apart from hypertrophy of the tonsil as a whole, we may have a localized enlargement giving rise in a lesser degree to the same symptoms as general hypertrophy and remediable by the same measures, especially the snare. In these adjunct masses there is generally an excessive development of connective tissue, resembling at times an actual sclerosis.

Such growths arise from one of three possible sources :

1. They may be accessory-tonsils.
2. There may be an elongation at the site of implantation of one or several lobules of a multilobular and hypertrophied tonsil.
3. The entire tonsil may become pedunculated.

#### CALCULI OF THE TONSIL.

Not infrequently small stone-like bodies, tonsilloliths, as they are called, are found in the tonsil or are discharged from its surface. They vary in size from a pin's-head to a pea, and a few very large ones have been reported. Their composition, as determined by Langier, is: calcium phosphate, 50; calcium carbonate, 12.5; mucus, 12.5; water, 25 per cent. The constant occurrence therein of cholesterolin is a disputed point. It certainly has been found in some instances, as have also magnesium salts. The starting-point of formation may be a minute foreign body; but is generally a mass of retained secretion in the crypts. Various micro-organisms have been found embedded in these calculi.

The **symptoms** are those of a foreign body, sometimes causing tonsillar enlargement. Palpation and the exploring-needle will render the diagnosis certain.

**Treatment** consists in incising the tissue over the calculus, scooping the latter out and cauterizing its bed.

#### FOREIGN BODIES IN THE TONSIL.

These are generally either chicken- or fish-bones, pins, hairs, or bristles from a tooth-brush. Occasionally the entire foreign body becomes embedded in the tissue, but generally a portion projects and can be seen or felt. In case inspection reveals nothing we must always palpate. Removal by forceps is generally easy enough.

That large class of cases must not be forgotten in which the body has been swallowed but has left a slight lesion, causing much pharyngeal discomfort. This dysesthesia can be relieved by a mild cocain-spray. Even then it is difficult to persuade patients of the groundlessness of their fears.

#### XEROSTOMIA (DRY MOUTH).

This condition was first described in 1868 by J. Hutchinson who gave it the name it bears. Since that time some twenty-five cases have been recorded. The most prominent feature in all has been a persistent and extreme dryness of the buccal mucosa. The dryness may begin in the eyes and nose, extending thence to the pharynx and trachea. The teeth are apt to crumble. All the cases thus far reported have been in women.

The nature of the disease is unknown. It shows no constant lesion. In one or two instances the parotid glands have been enlarged, but the ducts have remained pervious. Many of the cases have presented coincident trophic changes in other parts of the body, suggesting the central origin of the affection.

All local or constitutional remedies have thus far proven useless. Pilocarpin and potassium iodid seem to exert no effect on the condition.

#### DISEASES OF THE EPIGLOTTIS.

It is unusual for the epiglottis to be the seat of primary inflammatory affections. It is generally secondarily involved, as in lupus, tuberculosis, and syphilis, in which it presents the lesions characteristic of these respective affections. It shares, so far as its mucous covering is concerned, in the various catarrhal conditions of the pharynx and larynx. In enlargement of the lingual tonsil the latter sometimes compresses the edges of the epiglottis, giving rise to the so-called "incarceration" of the latter. The epiglottis itself frequently responds to this irritation by growing larger, but this increase in size will disappear when the tonsil is properly removed.

The organ in health may be curved, angular, pendulous, or folded. Its edges may be smooth, serrated, or crenated. The under surface is always of a redder hue than the upper.

Concerning its function, we are still in considerable ignorance. It undoubtedly does help to protect the larynx from the entrance of food; but we know, both from animal experimentation and from the results of disease, that absence of the organ is not incompatible with easy deglutition. It has also been regarded as a "sounding-board," reflecting the vocal sound-wave to the pharynx, where it is in part articulated. If it is destroyed, the voice is less distinct, and if its edges are irregular and jagged, the voice may be rough and harsh.

The specific affections of the epiglottis are elsewhere considered. We have here to treat of simple enlargement.

**Enlargement of the Epiglottis.**—This is a pure hyperchondrosis, with more or less thickening of the mucosa covering it.

The causes are the same in general as those which lead to the production of chronic pharyngeal catarrhs.

**Symptoms.**—It is difficult to separate the symptoms of an enlarged epiglottis from those which may be referred to an enlarged lingual tonsil or a varicose condition of the lingual veins. We find here the same pharyngeal dysæsthesia, pain in varying degree, irritative cough, empty swallowing, sensation as of a foreign body, vocal impairment, and gastric irritability. During acute exacerbations of catarrhal states painful swallowing is perhaps the most disturbing feature.

Rice has described a form of epiglottic inflammation caused by a natural size of the organ sufficient to bring it into contact with surrounding parts. The organ is abnormally hard throughout. In such cases the least exciting cause, as talking, singing, eating, going out into the cool air, change of body posture, etc., may cause an attack of coughing, or at least render the voice temporarily incompetent for any vocal effort.

**Treatment.**—This is in a general way that of the catarrhal condition always found in these cases, including, of course, the removal of all sources of irritation. Such measures, if faithfully carried out, will often reduce an enlarged epiglottis to its normal size. Astringent applications alone are of but little value. Cocain and oily sprays are but palliative, and their continued use is objectionable. The employment of the galvano-cautery generally provokes severe inflammatory reaction. Rice advises trimming off about one-eighth of an inch from the margins of the cartilage where they impinge upon the pharyngeal walls, using for this purpose long-handled curved seissors. Reaction is but moderate and hemorrhage is not excessive. He specially cautions against the removal of more than a narrow ribbon of tissue. Price Brown has used the galvano-cautery in one case where the epiglottis was long and narrow, but with its tip turned up into a horizontal position. No evil results followed.

#### DISEASES OF THE UVULA.

The anatomy of the uvula is elsewhere described. Concerning its physiology we are still uncertain, for the various functions assigned to it do not seem to suffer by its removal.

**Malformations.**—We can do no better than quote the statistics of C. Berens, who found in 3000 throats, 84 cases of abnormality in shape—viz.: hypertrophy, 11; pendulous, 2; fish-tailed shape, 39; attached to other parts, 2; deeply cleft, 14; worm-like shreds, 8; completely separate, 2; supernumerary, 4; also absent, 2.

**Acute Uvulitis.**—This is generally seen in connection with acute pharyngitis and tonsillitis, but may occur independently. It may arise from trauma (including excessive vocal effort), septic absorption, and occasionally after ignipuncture of the tonsils. The uvula becomes swollen and œdematous. It may even bleed, and one or two cases have been reported in which there was a hemorrhage into the substance of the uvula itself.

**Symptoms.**—These are (1) general, in the form of a slight febrile reaction; and (2) local, as dysphagia, pain, a feeling that the throat is filled up, rarely dyspnea. There is generally slight dry cough, thick voice, and general pharyngeal discomfort.



**Treatment.**—The uvula should be punctured freely with a finely pointed bistoury, especially when the edema is marked. Demulcent washes, hot alkaline gargles, etc., may then be used, followed later by an astringent preparation, as:

R. Tr. kino,  
 Tr. catechu co.,  
 Glycerit., acidi tannici,                   āā ʒj.—M.  
 S.—Teaspoonful in one-half glass cold water for gargle.

**Chronic Uvulitis.**—This is generally secondary to chronic catarrhal conditions of surrounding parts and cured by the treatment of the latter. It is an essential part also of elongated uvula, to be next considered.

**Enlarged Uvula.**—This condition is present in varying degree in nearly all patients who are subject to frequent sore throats of any kind, and especially in those who indulge in forced and unregulated vocal effort.

**Pathology.**—The enlargement may be a general thickening or merely an elongation. The latter may be merely a prolapse of the mucous membrane upon the muscular substance, or may be a true hypertrophy of the entire organ with downward extension, so that the tip rests on the dorsum of the tongue. There is always more or less paresis of the soft palate.

**Symptoms.**—The amount of disturbance produced by this condition varies greatly in different patients. Some with very long uvulae make no complaint whatever. Generally there is more or less tickling, coughing, retching, and even vomiting. These may be excited by the sudden change from one temperature to another, by diffused cold to the skin (as in bathing), or when fatigued. In the worse cases there may be nocturnal glottic spasm, the uvula being most relaxed during sleep. The constant coughing sometimes causes rupture of the superficial vessels of the lower pharyngeal mucosa, and the patients bring up an occasional tinge of blood in the gelatinous pellets they expel. All these symptoms sometimes lead the sufferer to believe that he has serious lung-disease, but a removal of the offending tissue quickly reassures him. To vocalists an enlarged uvula is a serious menace. The voice becomes easily fatigued, loses its range, strength, and clearness, and frequently becomes tremulous.

In examining these cases the parts must be relaxed and nasal respiration maintained, else the soft palate will be drawn up and a wrong perspective of the parts be presented.

**Treatment.**—In those cases where the mucosa is merely edematous and prolapsed on the muscle, simple astringent troches and mouth-washes may suffice. If, however, their use for a reasonable length of time does not effect the requisite shortening of the organ, or if there is a true hypertrophy with elongation of the muscle, a portion of the latter should be removed. (For Uvulotomy, see page 1208.)

The normal organ averages in the adult about three-eighths of an inch in length, and when the mouth is closed should hang free in the fauces without touching the tongue. It must not be forgotten that the frequent hawking caused by enlarged uvula tends mechanically to aggravate still further the condition.

#### DISEASES OF THE PHARYNX.

The pharynx is a fibro-muscular funnel-shaped tube, extending from the under surface of the basilar process of the occipital to a point about opposite

to the sixth cervical vertebra and on a level with the cricoid cartilage below. The upper part of the tube is expanded into a dome, imperfect in front, and likened to a "carriage-hood with the front window half-way down." At its sides are the common and internal carotid arteries.

Above, it communicates anteriorly with the posterior nares, laterally with the Eustachian tubes, in the middle with the mouth, and below with the larynx and esophagus. It has a strong fibrous investment, with a series of muscular constrictors and a mucous lining continuous with that of the surrounding cavities.

The epithelial lining is of the columnar ciliated variety in the dome and as low down as the floor of the nose; below it assumes the squamous type. It has a rich glandular supply, the acinous variety being generally distributed, less abundantly, however, in the vault; while the lymphoid deposits (not true glands) are massed about the orifices of the Eustachian tubes and in the dome, forming in the latter the third, pharyngeal, or Luschka's, tonsil.

In any consideration of pharyngeal maladies, two facts should be borne in mind. One is inherent in its structure and the other in its function. Being a combination of mucous membrane, muscle, and fibrous aponeurosis, it is naturally subject to the general run of acute inflammatory conditions; but it also bears the brunt of many outbreaks due to the gouty and rheumatic diatheses.

Moreover, the pharynx is a food- as well as an air-conduit. It has thus a relation to the digestive as well as to the respiratory tract; and disturbances of either may be caused by pharyngeal disturbances, or may even cause them. The existence of a serofulous taint acts in the same direction.

**Acute Catarrhal Pharyngitis.**—This is an acute exudative inflammation of the mucous lining of the pharynx. This cavity is a veritable breeding-place for all sorts of micro-organisms, and yet in a condition of health they are harmless. Exposure to cold really means lessened resistance of the tissues to germ-vitality and germ-entrance into the substance of the membrane. The excessive use of alcohol and tobacco, the ingestion of irritant food, the presence of foreign bodies, etc., are accountable for many attacks. Gouty and rheumatic poisons frequently expend themselves upon this area. Another frequent exciting cause is a disordered state of the stomach and a torpid liver, especially that group of symptoms collectively known as a "bilious attack."

As predisposing causes we may have a bad general environment, poor ventilation, improper clothing, the breathing of noxious gases, and occupations of a sedentary character. The disease is more prevalent during the damp seasons of spring and fall, affecting especially those exposed to sudden temperature-changes. All ages suffer from it.

**Pathology.**—The affection is the simple type of acute exudative inflammation occurring in a mucous membrane, with its stages of congestion, swelling, dryness, and later increased secretion. It may be confined to various areas, as the post-pharyngeal wall, the palatal folds, the fauces, or may affect the entire cavity. Pretty generally the covering of the tonsils is involved, and we really have an acute catarrhal tonsillitis as well as pharyngitis. The mucosa may be shining and smooth or of a granular appearance.

**Symptoms.**—In a simple case there is generally a very mild constitutional febrile reaction. Locally, we have pain of various degrees of intensity, painful swallowing, irritative cough, with a constant desire to clear the throat. Viscid mucus is expectorated, sometimes in pellets and occasionally blood-streaked. Smell, taste, and even hearing may be impaired—the latter

especially when the attack is engrafted upon an old tonsillar enlargement. The attack may pass off into "a cold in the head."

The prognosis is always good, the inflammation rarely extending to the deeper structures.

**Treatment.**—At the outset a mercurial and saline should be given, followed by aconite and belladonna in small but frequent and alternating doses. Pellets of ice are grateful, and in the milder cases relief may come from the free use of some astringent lozenge, such as the krameria or red-gum troches. Weak cocaine solutions may be sparingly sprayed on to relieve pain, but a graduated atomizer should always be employed, so as to register the amount of the drug used. Menthol in albolene (gr. xv- $\bar{5}$ j) is often just as efficacious. For this and similar purposes the "pyrozone-atomizer" may be employed.

In the diathetic cases, guaiac, salicylates, colchicum, and syrup of iodid of iron find their proper application. Iced compresses may be used externally. An edematous uvula or palate should be freely punctured. Food should be soft and non-irritating.

A simple tonic is often advisable after the subsidence of the acute symptoms. For the excessive secretion some form of astringent gargle is generally employed. A good formula is that given on page 938.

It has become fashionable in certain circles to decry the use of gargles on the ground that the fluid comes in contact with only a very small part of the affected area, never passing, as ordinarily used, beyond the anterior faucial pillars. The ideal method of gargling is that known as the "Von Tröltzsch" plan. The patient sits, or better lies down, with the head thrown back. He takes a mouthful of the gargle and begins the movement of swallowing without letting the liquid go down his throat. He next throws the head suddenly forward, when part of the fluid will go up into the naso-pharynx and find its exit through the nostrils, while the rest escapes through the mouth.

It is obvious that but few patients can thus juggle with their swallowing-apparatus. Moreover, the method is painful at any time, and therefore practically inadmissible in many acute inflammatory states. As a matter of fact, however, Swain has demonstrated that by this method fluid may be brought in contact with the outer or extralaryngeal surface of the epiglottis, the ary-epiglottic ligament, the arytenoid cartilages, and the posterior commissure of the larynx, as well as with the upper surfaces. In the later stages of acute catarrhal pharyngitis mild antiseptic troches or mouth-washes may be of service. To avoid a repetition of the attacks proper foot-wear and woollen underclothing should be worn. The neck and upper chest should be drenched night and morning with cold water and briskly rubbed with a coarse towel.

**Chronic Catarrhal Pharyngitis.**—Under this heading are to be considered the chronic catarrhal condition of the membrane as a whole, and also that distinct affection of its lymphoid elements known as "follicular pharyngitis." A localized variety of the latter is known as pharyngitis lateralis.

**Simple Chronic Catarrhal Pharyngitis.**—In this form the lesion is generally confined to the pharyngeal mucosa proper. The uvula, palate, and faucial pillars usually escape. The tonsils, however, are frequently enlarged.

Quite a difference of opinion exists as to the cause of this affection. The majority of writers would seem to regard it either as a result of repeated acute catarrhal processes, as in the case of mucous membranes generally, or as a disease set up by some of the long-acting causes named below. Bosworth emphatically states his conviction that "chronic pharyngitis is in no



instance the result of repeated attacks of acute inflammation; but, on the contrary, the chronic process sets in first, whereupon its clinical history is marked by repeated attacks of acute catarrhal sore throat." According to his view, the condition is generally secondary to a chronic gastritis, especially that form due to alcohol.

A frequent cause is the inhalation of all sorts of irritants, including tobacco-smoke. Here again we tread on disputed ground, some claiming that the nicotin and irritating salts of the smoke will set up a pharyngitis *ab initio*, and others that they merely aggravate a pre-existing condition. Some cases seem to arise from the extension of a naso-pharyngeal process or to be aggravated by the constant hawking and straining of the pharyngeal muscles.

Finally it must not be forgotten that the pharyngeal mucosa is bathed by all the air inspired through the nose. Hence, if this air is not (owing to intranasal abnormalities) properly strained, moistened, and warmed, it will act as an irritant. Particularly is this the case if nasal obstruction is sufficient to cause mouth-breathing.

**Pathology.**—We have here to deal with a proliferative inflammation occurring in a mucous membrane. The blood-vessels take no share in the process, which consists in the formation of a low grade of connective tissue in the deeper layers. The mucous glands, which are here scanty, are not much affected. The secretion is apparently increased and abnormally viscid. The lymphoid elements are not involved. In some of the older cases enlarged veins may course over the surface.

**Symptoms.**—As the affection is so frequently associated with gastric disorders, the symptoms of the latter are very much in evidence in the form of flatulency, gagging, nausea, and even vomiting. Combined with these is a continuous smarting feeling in the pharynx, with special discomfort in swallowing spiced foods or hot drinks. A coexisting naso-pharyngitis aggravates all symptoms. The whole mucous lining of the pharynx is excessively irritable. It is often impossible at the first sitting to make a satisfactory examination. Particularly is this the case in institution patients, with their usual excesses in malt-liquors and inferior tobacco. The mucosa is of a dark-red, beefy color, which rarely extends forward beyond the posterior faucial pillars. The breath is sour and offensive, while the tongue is more or less coated.

**Treatment.**—In many cases the pharynx itself is best left alone for awhile and attention directed toward the removal of vicious practices in eating and drinking. If irritability of the mucosa prevents proper examination, weak cocain applications may be made, or the patient may be put under the influence of the bromids, using also a strong solution of the latter for a gargle. Alcohol and tobacco must be cut off entirely, and tea and coffee during treatment. The bowels should be regulated with salines and cholagogues. An alkali with a bitter may be given after meals. Greasy foods, pastries, etc., fall under the ban. But little fluid should be taken at meals, so as to ensure the proper mastication of the food.

These procedures will alone cure many cases of chronic catarrhal pharyngitis. If, however, local discomfort persists after the stomach is regulated, we may make local applications to the pharyngeal mucosa. Silver nitrate (gr. xv- $\bar{3}$ j) or the zinc salts (except the chlorid) in the same strength may be used. These remedies are exactly as good as the host of new ones recently placed on the market. Nothing is gained in the care of these common maladies by running after strange therapeutic gods.

A valuable menstruum for many topical agents is the new oleo-stearate



of zinc, a union of stearate of zinc with benzoated albolene. It forms a viscid whitish mixture, not disagreeable to the taste. It can be used as a vehicle for the ordinary run of topical agents.

**Chronic Follicular Pharyngitis.**—In this affection the brunt of the pathological process falls upon the lymphoid structures which lie in the deeper layers of the mucosa. This change is of the greater clinical importance in that the process seems to involve in some way not entirely clear the sensory nerve-filaments of the area, giving rise to symptoms causing great discomfort.

**Causes.**—Over and above all there lies a diathesis to which has been given the name of "lymphatism." It is a tendency of all lymphoid structures at an early period of life to take on an overgrowth. With the earlier writers this tendency figures under the category of scrofula. At the present time we are disposed to admit the affinity, though not the identity, of the two.

The lymphatic overgrowth beginning in childhood affects more or less all the lymphoid deposits in the naso-pharynx and pharynx. The evidences of disease in the former of these two regions greatly predominate, so that not until later years do the troubles referable to the follicular ailment in the pharynx distinctly show themselves. Bad hygienic general environment predisposes to this form of catarrh; but there is no reason to believe that it has any relation to rheumatism or gout.

**Pathology.**—The follicular enlargement is a distinct process from the beginning, and probably is never a passing over from the simple catarrhal process described in the previous section. It may be accompanied by a simple surface-catarrh. It may be diffused over the surface of the pharynx, which assumes a granular appearance (granular pharyngitis), or may localize itself at the sides, just behind the posterior faucial pillars.

To these ridges or bead-chain-like deposits Schmidt has given the name of "pharyngitis lateralis." These ridges occasionally become adherent to the pillars, so that their union appears as large cords on either side.

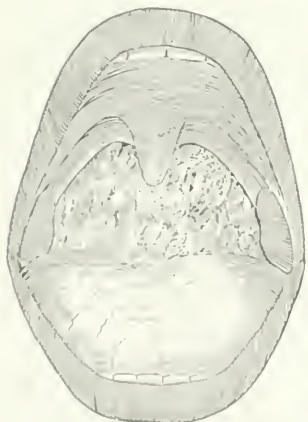

FIG. 578. Chronic follicular pharyngitis (Cohen).

The affection of the follicles seems to be most pronounced near the mouths of the muciparous glands. The process is really one of hyperplasia, a true increase in the number of lymphoid elements, especially about the efferent channels of the lymph-nodes. This hyperplasia may be diffused throughout the deeper as well as the superficial lymphatic structure of the mucosa, causing a thickening thereof, or it may be localized as blunt masses projecting a little from the surface. At first these masses are soft, but in later years they grow smaller and harder and may even disappear, leaving no symptom; but their persistence in later years is the legacy of the changes during the time of "lymphatism" (Fig. 579).

**Symptoms.**—As the most prominent we note pharyngeal dysæsthesia, due first to the unusually rich nerve-supply of the pharyngeal mucosa, and second to the fact already noted that the nerve-filaments are involved in the nodal changes. We may have all grades of sensation, from a mere discomfort to an actual pain. On account of this neurotic element it has been claimed that the disease is more common among women, but we have not so found it.

Overuse of the voice aggravates the discomfort. Painful swallowing is often felt. It has been suggested that the circulation through the follicles is increased and that attendant pressure-changes cause a true neuralgia.

The secretion is not, as a rule, increased in amount. Sometimes the follicles seem to lie on a bed of whitish connective tissue and the whole area looks very dry (pharyngitis sicca). The voice is husky, probably from a reflex influence upon the phonatory muscles. A dry nervous cough is often present.

The uvula may be elongated, especially when an accompanying nasopharyngitis produces much hawking. So, also, the faucial and lingual

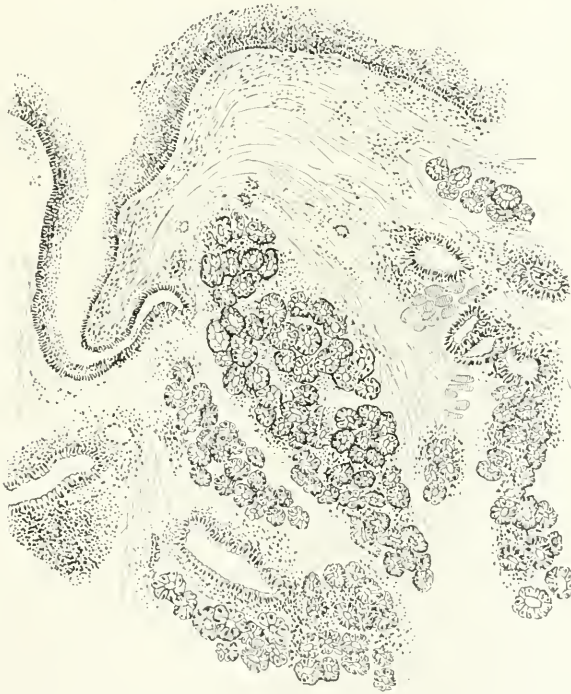

FIG. 579.—Pharyngitis granulosa (Seifert and Kahn).

tonsils may be enlarged. Frequently the enlarged veins are seen coursing over the pharyngeal wall, but they are not distinctive of this condition. The disease may continue indefinitely, although without any extension to neighboring parts. There is no conclusive evidence that it predisposes to phthisis.

**Treatment.**—As to general measures, we may refer to the treatment of the simple catarrhal form. The local treatment consists in the removal or destruction of the diseased follicles.

Of destructive agents we have chromic and trichloroacetic acids, and the galvano-cautery at a bright cherry-red heat. Six or eight follicles may be treated at each sitting. A drop of 5 per cent. cocain solution injected at their bases through a curved needle will render the cauterization painless. E. Mayer cures these diseased surfaces, and has devised a special instrument for this purpose and obtains excellent results. An antiseptic mouth-wash should be used after cauterization.

In pharyngitis lateralis the same plans may be followed. Several sittings are required, and the reaction after the cautery is more severe in this situation than on the post-pharyngeal wall.

**Hemorrhage from the Pharynx.**—A brief note should be made concerning hemorrhages from the pharynx. These may be due to two different classes of causes: (1) Changes in the blood, and possibly in some cases in the blood-vessels, which permit the escape of the blood in various parts of the body—*e. g.*, purpura, hemophilia, leukemia, pernicious anemia, etc. (2) Ulcerations of various kinds, suppuration, trauma, the so-called "hemorrhagic laryngitis," and perhaps varicose veins. The latter source has been alluded to under "lingual varix."

Pharyngeal hemorrhages from the causes enumerated under the first of the foregoing divisions are rare. Under the second we may include cancerous ulcerations and also laryngitis sicca where the formation of crusts and their subsequent dislodgement may cause erosion of superficial vessels.

Tubercular ulceration of the larynx rarely, if ever, causes local bleeding, although the larynx may retain blood coming from the lungs or bronchi.

Where patients come to the physician with the history of having raised a little blood, the lungs are naturally first examined, and if there are neither signs nor symptoms of pulmonary trouble, the bleeding is referred to the throat and apt to be regarded as of slight moment. Such reasoning is fallacious. True pharyngeal hemorrhages are extremely rare, and their existence should never be predicated unless a clot or a bleeding-point can actually be seen upon the mucous membrane of the pharynx. In the greater majority of all these cases the blood comes from some part of the respiratory tract below the glottis—*i. e.*, signifies lung-trouble, whether there are any other signs or symptoms to correspond with it or not.

Of course, the mouth and gums must be carefully searched in this class of cases. So, also, allowance must be made for the existence of valvular cardiac trouble and pulmonary hyperemia. In some cases the blood escapes by diapedesis rather than by actual rupture of vessels.

It must be borne in mind that the intimate anatomical and physiological relations of the pharynx with the larynx and parts below permit blood effused in one situation to quickly deposit itself in another. Hence we must be cautious in our deductions as to the actual source of the bleeding. Moreover, blood effused high up in the tract may get into the lungs and so predispose to tubercular invasion.

Finally, we must be on our guard against malingerers who, for their own various purposes, can produce pharyngeal hemorrhage with the greatest readiness.

**Pharyngo-mycosis.**—Under this title are properly included all mycotic growths occurring in this situation. Among the parasites most frequently found here are the *oidium albicans*, *actinomyces*, *aspergillus fumigatus*, *baeillus fasciculatus*, and the growth causing that rare affection *nigrities lingue* or black-tongue. By common clinical consent, however, the term, unless qualified, is restricted to cases of *leptothrix* growth. This form was first described by Fränkel in 1873.

**Causes.**—As predisposing causes we have preceding inflammations, especially of the tonsils, and carious teeth. It frequently follows acute tonsillitis, and has doubtless been often mistaken for a chronic lacunar affection. The exciting cause, or rather the essence of the disease, is the growth of the *leptothrix*-threads.

**Pathology.**—The deposits occur most frequently on the faucial and

lingual tonsils, but they are occasionally seen on the pharyngeal tonsil, less frequently on the soft palate, post-pharyngeal wall, glosso-epiglottic folds, and larynx. J. Wright found them in one instance upon the inferior turbinal body. They appear as patches apparently embedded in the tonsillar crypts and projecting above the surface. They are generally hard and horny, being removed with great difficulty. They may exist as isolated areas of varying size or they may be connected by threads extending from one to another and interlacing like the tendrils of running vines.

If a bit of deposit is removed, teased in glycerin, and examined with a low-power objective, we note a mass of epithelia (an accidental feature) surrounded by irregular granules, in which are embedded the rod-like cells of various species of the leptothrix-fungus (belonging to the group of schizomycetes). These rods or mycelial threads generally occur in links, and sometimes curl up at their ends into fine hair-like filaments. Other rods appear colorless, but with sharp, dark borders, the centers seeming to be full of granular matter. The loose granules are in some instances the spores of the growth. Methyl-blue staining will bring out alternating colored and uncolored segments on the threads; while Lugol's solution gives with them the characteristic starch-reaction.

This fungus has never been cultivated outside of living bodies. Leptothrix-threads of various species inhabit every healthy mouth. The presence of tartar on the teeth, an altered reaction of buccal secretion, and a disordered digestion all seem to promote their growth. There is no proof that the gouty or rheumatic states predispose to them. They are found in rhinoliths, tonsillar concretions, and vesical calculi; in the secretion of tracheal ozena, fetid bronchitis, and pulmonary gangrene; on the coating of the tongue in low fevers, in the lachrymal duct, intestine, vagina, and feces. Most of the cases of mycosis reported have been in young women. In any situation the growth may precipitate lime-salts from fluids holding them in solution.

A somewhat novel view of the nature of this affection is that advanced by Siebenmann, who contends that Fränkel's benign tonsillar mycosis, with its formation of solid horny matter, should be taken from the category of mycoses and put in that of hyperkeratoses of the mucosa. As a product of a less complete keratosis should be regarded the less complete epithelial keratosis which is found in all tonsils, and which is an excellent medium for the development of the organisms of decomposition. The collection of incompletely keratosed epithelium is therefore a constant menace to the surrounding tissues, analogous to cholesteatoma of the middle ear. Siebenmann would drop the name "pharyngo-mycosis" and substitute therefor "lacunar hyperkeratosis."

**Symptoms.**—These consist of constant irritation in the fauces and a pricking or a pasty feeling, with mild cough and difficulty in swallowing. In one case submaxillary glandular enlargement was noted. Schech has found fever with general malaise, weakness, and anorexia preceding the local deposits. The tonsils themselves may be a little red and swollen. Semon has seen the soft palate and uvula congested, the latter being also very edematous.

**Course.**—The deposits come and go sometimes regardless of treatment. There is no danger in the affection. It is of more pathological interest than of clinical importance.

**Treatment.**—All functional disorders should be corrected; the teeth must be put in good condition. In one of the writer's cases the deposits



permanently disappeared as soon as this was done. Sweets must be cut off from the diet. A change of climate will alone cure some cases.

As to topical measures, nearly every caustic and antiseptic in the pharmacopœia has been recommended—*e. g.*, solutions of zinc chlorid, balsam of Peru in alcohol, iodin and carbolic acid in glycerin, salicylic acid in alcohol, borax, bichlorid, chromic acid, silver nitrate, and pyrozone. Smoking is reported to have cured one case, and an instance in the writer's experience lends some color to this view. Nicotin solutions, however, should *not* be applied. Some of the larger deposits may be torn away with forceps. The favorite measure is the galvano-cautery tip carried to the base of each deposit. Tonsillotomy may be done if the organ is large enough to engage in the guillotine. Internally, salol and the alkalies have been used.

**Herpes of the Fauces.**—This is one of the rare diseases. Obviously, different clinicians have had different conditions in mind in their use of this term. Else how can we account for the fact that of two prominent writers, one has seen only 12 cases in a lifetime, while the other reports over 100 cases in six years?

The disease consists in the occurrence on the uvula, soft palate, tongue, and inside of the cheeks of small blisters, resembling somewhat the customary herpetic patches seen on the skin. The tonsils and epiglottis may also be invaded, while the posterior pharyngeal wall regularly escapes. The affection may be unilateral or bilateral. It occurs more frequently in children, in those constitutionally delicate, and in neurotic young women. It is especially prevalent during diphtheritic outbreaks, in damp climates, and during the colder months. Many of the patients are distinctly anemic.

**Pathology.**—In the initial stages small distended vesicles are seen with a surrounding zone of inflamed mucosa. These occur singly or in patches. They may disappear by absorption, leaving no trace; or may burst, leaving shallow circular ulcers. The vesicular stage is a brief one, for the epithelial covering of the patch is so delicate that it cannot hold the fluid which collects beneath it except for a very short time. Still, again, the patches may coalesce, forming a large bulla, which after discharging its contents becomes covered with a membranous deposit, suggesting diphtheria. Bosworth records three cases where the eruption assumed the form of herpes iris—*i. e.*, "small rings of minute papules enclosing a patch of healthy membrane." He regards the process as a localized inflammation of the papille of the subepithelial layer of the mucosa originating principally in the terminal filaments of the nerves.

**Symptoms.**—These consist of a moderate febrile reaction and a burning feeling in the fauces, increased by deglutition. Occasionally there is a severe itching about the parts. The pain may radiate to the ears, nose, and even to the larynx. A similar rash may appear coincidentally on the lips, thus assisting in the diagnosis. The fauces show a circular arrangement of the eruption, at times papular, or vesicular, or even pustular, with the later history above described.

**Cause.**—The duration is about a week, and patients always recover; but the mucous membrane may be left predisposed to infection. Successive crops of eruption occasionally prolong the disease.

**Treatment.**—All neurotic and anemic states must be corrected, for these cases frequently relapse. At the outset sedative and demulcent mouth-washes are indicated. Morphiu and carbolic acid in glycerin may be applied to the painful areas. Potassium chlorate is useless, and may even increase the local discomfort. Mild caustics may prevent the spreading of the patches.

## DISEASES OF THE NASO-PHARYNX.

Under this heading are considered acute and chronic post-nasal catarrh and enlargement of the pharyngeal tonsil, including lymphoid hypertrophy in the vault of the pharynx, the so-called "adenoids." Other naso-pharyngeal affections are dealt with elsewhere in this work.

**Acute Naso-pharyngitis: Acute Post-nasal Catarrh.**—This affection is essentially an acute exudative inflammation of the mucosa lining the naso-pharyngeal space. It is frequently associated with an acute rhinitis, or rather both lesions occur in that condition known as a "cold in the head;" but it is possible for either to occur separately.

**Causes.**—Exposure to cold and damp plays the chief exciting rôle. Here also should be borne in mind what has already been said regarding such exposure as related to temporary impairment of tissue-vitality. As occurring in very young patients, we generally find acute naso-pharyngitis associated with more or less enlargement of the pharyngeal tonsil, which in turn may have resulted from repeated attacks of acute rhinitis. The abuse of alcohol and tobacco, exposure to dust-laden air, noxious vapors, and various septic influences are all contributing causes. The relation of any particular diathesis to the acute form of the disease cannot be regarded as proven. Disease of the nasal mucosa is regularly present, and is regarded by some as the most frequent excitant cause.

**Pathology.**—As already suggested, the process here is the typical one of acute exudative inflammation, with its successive stages of congestion, dryness, swelling, and hypersecretion. The follicles are reddened and enlarged and bathed first in mucus and later in muco-pus.

**Symptoms.**—Cases are ushered in with a very mild febrile reaction, general malaise, and anorexia. The fever rarely rises to 101° F., and yet the patient is miserable out of all proportion to this temperature. There is a dry, smarting feeling in the back part of the throat, with painful swallowing. Owing to the close anatomical relation between the mucosa and the bony vault, this stage of dryness from arrested secretion is apt to be prolonged. The gastro-enteric tract is often in a torpid, sluggish condition, and we have coated tongue, nausea, or even vomiting and constipation.

From this stage the condition passes into that of hypersecretion, which generally affords some relief to the local discomfort. The discharge is at first whitish and mucous in character; but later becomes yellowish and of a muco-purulent consistency. It trickles down from behind the soft palate and is expectorated, or in very young patients swallowed; some of it may be blown out through the anterior nares. Such a muco-purulent flow increases the tendency to gagging and nausea. This secretion is viscid, tenacious, and glairy. After a varying period of these symptoms—from two to ten days—there ensues a third stage characterized by progressive improvement in all symptoms.

During the course of the attack the dry sensation in the naso-pharynx may amount to an actual pain, and suggests by its radiation a facial neuralgia. There may be a stiffness of the cervical muscles, as in muscular rheumatism. The voice may be of a nasal character, and a short irritative cough is not uncommon. During the stage of hypersecretion the lining of the Eustachian tube may swell, causing occlusion and more or less deafness.

Although the affection is quite distressing to patients, it is essentially mild, and if the nares are free does not extend to parts below. If, however,

they are obstructed and the air is not properly warmed, moistened, and filtered, the pharynx proper may suffer in consequence.

**Treatment.**—This should first be directed toward the gastro-intestinal tract, for a restoration of the latter to activity may abort an attack. A mercurial followed by a saline should be given immediately. An initial full dose of quinin and Dover's powder with a hot bath and other diaphoretic measures are often of greatest service. For the headache and general malaise the coal-tar products—phenacetin, ammonol, lactophenin, etc.—in five-grain doses every hour, are valuable. Bosworth advocates aconitia in  $\frac{1}{500}$ -grain doses every hour or two until the pharyngeal pain abates.

For local relief cocain may first be used to deplete the vessels and allay pain. The amount of the drug employed must be carefully restricted. After free secretion is established, the naso-pharynx should be irrigated three or four times daily by any of the methods in common use. The writer prefers a small rubber catheter with a large number of very fine perforations at the distal end, while its proximal end is attached to a rubber bulb. This is filled by suction in the usual manner and then passed along the floor of each nostril until the perforated end is in the naso-pharynx. Gentle pressure on the bulb will discharge a series of fine currents, which will bathe the entire cavity without injury to the Eustachian cushions, but effectually removing all secretion. The solutions to be used should be rather more than lukewarm. They may be made up of glyco-thymoline, boro-lyptol, listerine, etc., one teaspoonful to three ounces of water. A cheaper and yet efficient solution is one teaspoonful to the pint of water of a powder composed of equal parts of chlorid, biborate, and bicarbonate of sodium.

After the second stage is passed, applications may be made on the post-nasal cotton-carrier of silver nitrate (gr. xx- $\bar{5}$ j), or Mandl's solution: iodine, gr. v; potassium iodid, gr. xv; acid carbolic, ℥ ij; glycerin,  $\bar{5}$ j. If much tissue-hypertrophy remains in the vault, the galvano-cautery or cauterizing acids are indicated. The use of a palate-hook greatly facilitates the necessary manipulations.

**Chronic Naso-pharyngitis: Chronic Post-nasal Catarrh.**—By this term is signified a condition characterized by the excessive discharge from the naso-pharynx of a secretion altered in quality as well as quantity. It may cling to the site of production or diffuse itself more or less over the surrounding structures. Its discharge is generally effected by a characteristic nasal sercratus or hawking.

This disease is common in all lands, and affects especially dwellers near large bodies of water and in damp climates. It is especially common in America, and is sometimes spoken of by English and Continental writers as "American catarrh." It appears in every grade of severity, from a mere annoyance, scarcely noticeable, to a condition which renders the patient himself thoroughly miserable and disgusting to others.

**Causes.**—Many cases in adults are doubtless referable to neglected disease of the pharyngeal tonsil occurring in earlier years. In childhood all inflammations are prone to invade lymphoid structures. Such a tendency is often aggravated by some intercurrent infantile disease, especially the exanthemata. The various diatheses act through this intermediate lymphatic involvement. The use of tobacco and alcohol are to be considered as exciting causes, the former perhaps only aggravating a pre-existing disease; while the latter primarily affects the stomach, between which and the pharynx there exists, as we have seen, an intimate relation.

In regard to the effect of cold alone, as an excitant of the acute form

which later subsides into the chronic, Bosworth strenuously insists that the chronic form precedes, and that cold produces exacerbations into an acute or subacute stage. Modern rhinology, however, assigns the most important rôle among the causative factors to the condition of the nasal chambers. The recognition of their true function has been the great advance in this field of medicine. They should be examined in every case of post-nasal catarrh. If they are diseased, some naso-pharyngeal lesion can be safely predicated. The normal secretion from the glands of the latter region is thin, clear, and bland. If, however, owing to intranasal disease, it is constantly fanned by a current of air which is cool, dry, and dusty, its proper elaboration will be interfered with. Cell-desquamation in the naso-pharynx is unduly stimulated. A thick, stringy, dust-laden mucus appears, very tenacious and removed with difficulty. If the disease progresses, crust-formation finally results.

**Pathology.**—In addition to the excessive cell-desquamation and abnormal secretion there is more or less diffuse hyperplasia of the lymphoid elements of this region. A noteworthy impulse was given in 1885 to the discussion of this question by the publication of Tornwaldt's monograph on the "Significance of the Pharyngeal Bursa." He assigned as a frequent cause of chronic post-nasal catarrh a diseased condition of this bursa. It may be the seat of chronic catarrhal inflammation or may be cystic, with a closure of the outlet. To such a condition, also, Tornwaldt referred a host

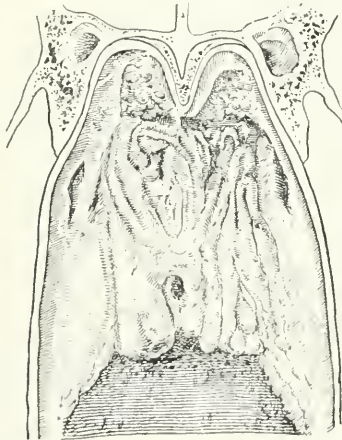


FIG. 580.—Pharyngeal vault, showing median and lateral folds; also, orifice of bursa (Luschka).

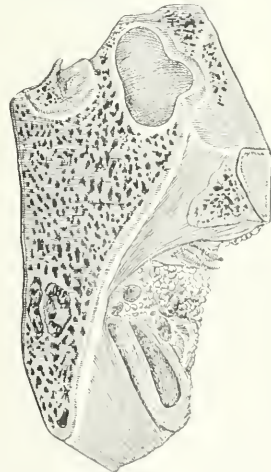


FIG. 581.—Pharyngeal bursa (Luschka).

of reflex symptoms in various parts of the upper air-tract. His views gained some adherents, but are now regarded as too extreme. He considers the bursa as a normal anatomical structure, but Schwabach, after examining over thirty different specimens, denied the statement that the bursa was a special anatomical formation. It should rather be regarded as an integral portion of the pharyngeal tonsil, sharing in common with the latter all pathological changes (Figs. 580, 581).

The heads examined by Schwabach showed in the vault of the pharynx a series of irregular clefts of varying depth forming intervening ridges of variable breadth. The older the child the less distinct was this cleft-formation. The median cleft was the most persistent. The bursa, he asserts, is



nothing but a remnant of this median cleft. Partial or complete agglutination of its edges forms a blind pocket or pouch, extremely favorable to the retention of mucus, which, under such circumstances, tends to become purulent, and a cyst results. Such inclusion-cysts are uncommon. Their epithelial lining is the same as that of the surrounding area. The columnar type here predominates, shading off into the squamous as we pass down the pharyngeal wall; but at times even in the vault the latter type prevails, owing to irritating secretions or the attrition of inflamed surfaces.

Examination of tissue removed from such cases shows first of all an epithelial layer with a range in structure from columnar ciliated to squamous cells. Underneath are lymph-nodes embedded in a mass of lymphoid tissue, which in turn presents trabeculae of scanty connective tissue. The usual cryptic depressions appear on the surface (Figs. 582, 583).

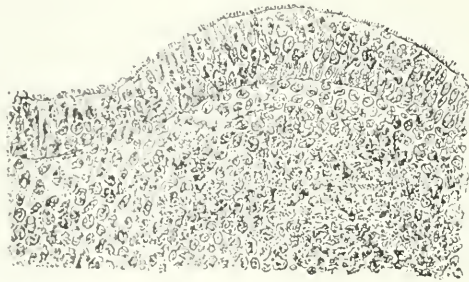


FIG. 582.—Lymph-follicle from naso-pharynx (altered from Zarniko).

Bosworth has pointed out the difficulty of recognizing the relation between the local pathological change and its most annoying symptom—viz., increased secretion. There is no increase of the ordinary muciparous follicles, and the increased secretion must therefore come from the surfaces of the clefts and ridges, which take on a functional activity not unlike that of a mucous gland. The mucus being itself abnormal, further irritation is caused, and thus the vicious circle is perpetuated.

**Symptoms.**—The most prominent symptom is the discharge of a profuse, viscid, yellowish secretion. It may adhere to the surface of the mucous membrane or flow down the posterior wall and be removed by frequent hawking. There is often the sensation of a pendant drop just behind the soft palate. We must suppose that this secretion is perfectly fluid as it appears at the mouths of the glandular ducts, and that its inspissation results from the abnormal environment it there meets. Its consistency varies from time to time. In those cases where there is an inclusion of the median cleft the discharge is more apt to be fluid. The cavity apparently fills slowly and then becomes a source of sufficient irritation to provoke hawking and lead to an evacuation of the bursal contents. During the day the natural activity of the pharyngeal muscles keeps the discharge from clogging up; but on waking in the morning the accumulation of the night-hours begins to be dislodged, causing gagging, nausea, and even vomiting. During the damp weather and at the sea-level the severity of the foregoing conditions is generally increased.

Does this form of catarrh predispose to affections of the lower air-tract—the larynx, trachea, and bronchi? This question has often been discussed. Probably none of the detached mucus ever goes down the windpipe. It

glides along the post-pharyngeal wall into the esophagus. It is not, therefore, the carrier of contagion to the laryngeal mucosa. Patients who suffer synchronously from naso-pharyngeal and laryngeal catarrh are probably the victims of abnormal intranasal conditions. The correction of the latter is the only rational treatment of the twofold catarrhal malady.

Of reflex symptoms, we may cite asthma and headache. The middle-ear catarrh sometimes seen in naso-pharyngeal cases is probably due to intranasal trouble, causing improper ventilation of the pharyngeal vault and middle ear. It may at times be due to direct propagation of disease of the vault along the lining of the Eustachian tubes.

**Diagnosis.**—In the examination of a given case we must first ascertain whether we have to do with a post-nasal catarrh pure and simple or with one complicated by other morbid states.

In an uncomplicated case the small mirror will enable us to recognize either the broad diffuse hypertrophy of the mucosa or the enlarged "bursa." The latter appears as a cleft of varying depth with lateral rounded lips, making a picture which a French writer calls with greater realism than modesty the "vulva of the naso-pharynx." An accumulation of discharge here may result from syphilitic changes; but other evidences of the latter trouble will make the diagnosis easy.

It is difficult at times to eliminate as factors of the discharge the inflammation of the sphenoidal or post-ethmoidal sinuses. When the patient reclines the discharge from these cavities may trickle back into the naso-pharynx, and its appearance there simulates bursal disease. A careful examination made during the day, after previously cleansing the region, will generally determine whether or not serious trouble exists.

**Course.**—Patients have generally suffered, in a mild degree at least, for many years before coming under professional care. As a rule, the longer they have complained the more quickly they seem to think they can be cured. Most of them *can* be cured if they will follow up treatment long enough, but at the outset a full statement of the continued care necessary should be laid before them.

**Treatment.**—Any underlying diathesis which may be found will suggest its own appropriate remedy. Special attention must be paid to bathing, clothing, foot-wear, and general hygiene. Alcohol must be cut off in all its forms. At the outset tobacco must be given up, but later a mild cigar may be taken after dinner.

In regard to diet, no special rule can be laid down. More often the stomach-condition, if annoying, is the effect and not the cause of the naso-pharyngeal trouble. A cure of the latter will often remove the former.

As to local treatment, the number of remedies is legion. One is probably as good as another if thoroughly applied. Naso-pharyngeal cleanliness is the foundation-stone of all successful care of these cases. From two to four times daily the vault should be cleansed with some one of the solutions named in a preceding section (boro-lyptol, glyco-thymoline, pyrozone, listerine, etc.), all in the proportion of one to two teaspoonfuls in four ounces of water. Available also are the old-fashioned Dobell's solution or the alkaline powder (equal parts of salt, borax, and baking soda: of the mixture, one teaspoonful to the pint of lukewarm water).

These washes may be snuffed up from the hand or used in the nasal douche-cup or familiar "feeding-cup" of the sick-room. Ordinary atomizers spraying through the anterior nares are useless. The diseased surface must be laved with a certain volume of alkaline or antiseptic solution at body-

temperature, so that all the adherent secretion may be floated up. Of course, too forcible manipulation of any kind should be avoided.

After the parts are thoroughly cleansed, some alterative application may be made on the cotton-carrier, such as the glycerite of tannic acid, or of boro-glycerin or a solution of iodin gr. v, potassium iodid gr. xv, carbolic acid ℥ ij and glycerin ʒj; silver nitrate gr. xxx-ʒj; glacial acetic and lactic acids in varying strengths. All have their advocates. Such applications should be made three times weekly.

The nasal douche with the usual reservoir and long tube has not been advocated, as the writer is convinced that but few patients are sufficiently skilful in its management to render its use entirely safe. The douche-cup will suffice for every case if it is faithfully and persistently used. It can do no harm if of a proper shape and size. In office-practice, the long, hard-rubber syringe with curved tip will answer every purpose. An elaborate air-spray apparatus is in no wise necessary.

If the disease be more pronounced it will be necessary to actually destroy or remove the diseased tissue. For this purpose we have chromic acid and the galvano-cautery. With the latter the bursa can be thoroughly eradicated. Small currettes and some of the varieties of post-nasal forceps are also available. The use of the palate-retractor and post-nasal mirror are necessary for accurate manipulation of these instruments, use of which should be preceded by cocain on the cotton-carrier in 20 per cent. solution.

**Lymphoid Hypertrophy in the Pharyngeal Vault.**—This is the familiar condition variously known as hypertrophy of the third, pharyngeal or Luschka's tonsil, adenoid vegetations, etc. It was first described by Czernak in 1860, but he did not appreciate its clinical importance as we understand it to-day. It remained for the late Wilhelm Meyer of Copenhagen to accurately portray the affection. So thorough and complete was his exposition of the subject, that no one has been able to add anything essentially new to his now classical paper which appeared in 1870.

It is unfortunate that the term "adenoids" has come into such common use. It is in this connection anatomically incorrect. It was formerly supposed that the hypertrophy was made up of true glandular tissue, hence adenoid in structure; but this tissue contains no true secreting glands. Its folds and fissures may at times take on, so far as the elaboration of mucus is concerned, a secreting function.

**Causes.**—The condition may be congenital. Scrofula, syphilis, and tuberculosis all predispose to it. It seems hereditary in some families, but the existence of several cases in the same family may easily be referable to the same diathesis or to exposure to the same unsanitary surroundings. No race or climate is exempt from the disease. The majority of cases are seen in children from four to ten, although no age is exempt. Both sexes are equally affected. An underlying factor exists in the tendency of children to "lymphatism," which has been described in a previous section. The ebb of the lymphatic tide comes about the time of puberty, when there is a tendency of the lymphoid structures to atrophy.

Associated lesions of the malady are hypertrophic rhinitis and especially enlarged faucial tonsils. In a few cases the nasal mucosa may be distinctly atrophic.

**Pathology.**—The lymphoid masses are variously arranged in the nasopharynx. Occasionally they are pendant from the vault; but more frequently they are irregularly distributed, running forward to the edges of or even into the choanae, filling the fosse of Rosenmüller, encroaching upon the



Eustachian orifices, and extending a variable distance downward upon the posterior and lateral pharyngeal walls (Fig. 582).

Under the microscope, the tissue is seen to be covered with stratified columnar epithelium, more or less deprived of its cilia. The surface is deeply furrowed, giving the mass a lobulated appearance. The bulk is made up of lymphoid cells with a scanty blood-supply. These cells are arranged in the usual "node" form, with internodal areas sparsely supplied with a low grade of connective tissue which, however, has a fairly abundant blood-supply (see Fig. 583).

These lymph-nodes resemble in every respect the solitary follicles of the intestine, and have the same relation to the lymphatic system. The lymph-vessels rim near the bottom of the folds into which the surface is thrown. The blood-vessels are for the most part atypical in structure. Those which are at the bases of the masses—*i. e.* nearest to normal tissue—may, however, show a more typical structure. The amount of connective tissue present does not bear any necessary relation to the age of the patient. As a rule, the masses are softer in young children and harder in adults.

It must be remembered that this lymphatic formation is merely an over-

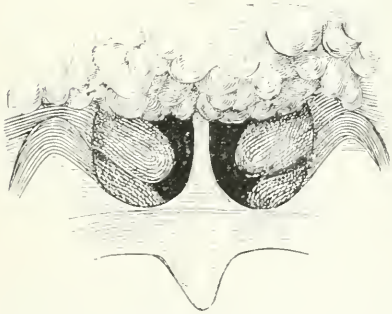

Fig. 583.—Lymphoid hypertrophy in the naso-pharyngeal vault.

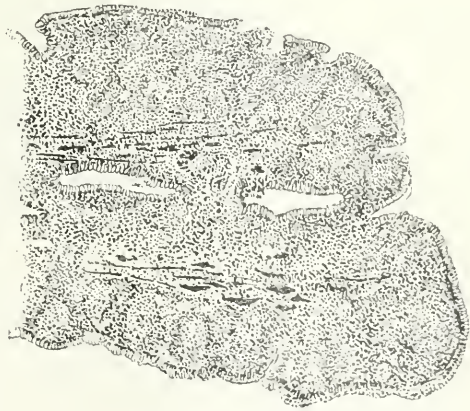

Fig. 584.—Section through lymphoid growth (altered from Zarniko).

growth of a normal histological element of the mucosa in this situation. It is not an adventitious deposit. Therefore, those who speak of complete removal use a term which, strictly speaking, is not correct, for absolutely complete removal would mean a removal of the mucosa itself.

The relative preponderance of the cellular elements gives to the growths their soft jelly-like consistency, and the furrowed surface likens the feel to the examining finger to that (to use the customary simile) of "a bag full of earth-worms."

It must not be forgotten that in adults also the lymphoid hypertrophy is found; but, as previously noted, the consistency of the deposits is firmer and they are aggregated in the middle of the vault, at the site of the so-called third or pharyngeal tonsil. The condition is really a hypertrophy of the latter structure (see Fig. 562).

Small cysts are occasionally found in the masses.

As compared with enlargements of other segments of the tonsillar ring, the principal difference here is the small amount of connective tissue. The



growths are largely protected from those irritative influences which predispose to connective-tissue formation.

**Symptoms.**—Patients are brought to the physician with the statement that the nose is more or less stuffed up and at times discharges muco-pus. The children breathe through their mouths and snore at night. The voice has a peculiar “dead” quality or lack of resonance. The expression is stupid and the mental condition seemingly often below par. Deafness is not uncommon, and in marked cases an offensive aural discharge exists. Cough may occur and occasionally spasmodic breathing. Other possible features are nose-bleed, night-terrors, nocturnal enuresis, aprosexia, and a broadening of the bridge of the nose.

Night-sweats, chest-deformities, abnormal formation of the facial and palatal bones, defective development, and many other allied conditions have

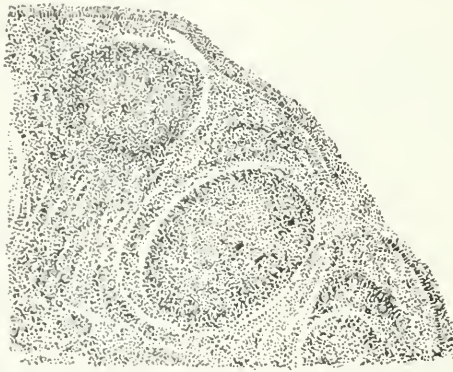

FIG. 585.—Hypertrophy of the pharyngeal tonsil (Seifert and Kahn).

been directly attributed to lymphoid vegetations in the vault. Many of them are doubtless more properly referable to the underlying dyscrasia of which the vegetations are but a single expression.

Let us analyze the foregoing symptoms somewhat in detail.

The profuse nasal discharge is the result (as previously stated) not of an inflammation of the true acinous glands, but of the surfaces of the folds and clefts of the growths. The tissue is so soft and pulpy that it breaks down under the examining finger, which upon its withdrawal is covered with blood, and this latter fact alone evidences an abnormal naso-pharynx. The mouth-breathing comes from the greater or less obstruction to the passage of air through the posterior nares, through the pharynx, and thence to the lungs. The snoring ensues upon the relaxation of the soft palate, always present and naturally accentuated during sleep.

The voice-tone arises from the interference of the growths with the excursions of the sound-waves transmitted upward from the larynx. The “sounding-board” function of the pharynx is impaired. “Spring,” “ninety-nine,” etc. are pronounced “sprig,” “nīdy-nīd.” Deafness and aural discharges are sequences of rarefaction of air in the naso-pharynx, hyperemia of the lining of the Eustachian tubes and middle ear, and retracted drum-heads. There may be eventual ankylosis of the ossicles with atrophy of the tympanic membrane. Sometimes a true catarrhal inflammation is set up, changing to a purulent form.

Cough is referable to pharyngeal irritation, either from mouth-breathing or from the impact of secretion detached from the vault. Night-terrors,

sense of choking, enuresis, etc., are all due to the overloading of the blood with carbonic-acid gas and the resulting nervous explosion. Grönbech found enuresis in 13 per cent. of 192 cases, with a large proportion of cures of this special symptom after removal of the vegetations. He admits a general predisposition to enuresis. Otherwise, he says, we would find it more frequently in hypertrophy than we do.

The term "aproxexia" (from a Greek derivation meaning literally "not to hold toward or to") was suggested by Guye of Amsterdam as a proper designation for the inability which many of these children manifest to concentrate their attention upon any one thing. It probably arises from a sluggish lymph-circulation at the base of the brain, which in turn affects the functional integrity of the higher centers. Retzius and Axel-Key have demonstrated the close anatomical relations between the lymph-channels of the naso-pharynx and those at the base of the brain.

Harrison Allen has called attention to a condition which he calls "adenoid disease." The obstruction is here due to a congenitally narrowed naso-pharynx. It does not excite mischief by reason of its influence on either respiration or acute catarrh, but affects directly general nutrition, and in the opinion of the author quoted is allied to acromegaly and myxedema.

Several authors report cases of torticollis coexisting with but cured by the removal of the lymphoid vegetations, and the same is true as regards epileptic seizures.

**Diagnosis.**—Many of these cases can be recognized at sight, the peculiar facies and open mouth at once suggesting the nature of the trouble. In tractable children the small mirror enables us to actually see the deposits. In intractable ones the forefinger of the right hand can easily be slipped up behind the soft palate and the situation of the masses accurately located. Another test (not diagnostic of this particular condition, however) is the throwing of a warm antiseptic or oily spray through one anterior naris. If the nose and naso-pharynx are clear, the fluid will escape from the other nostril with practically undiminished force.

It is, of course, possible for these vegetations to be of a sarcomatous, syphilitic, or tubercular nature, so far as their pathological structure is concerned; but unless other and visible evidences of these respective diseases are present, our diagnosis will probably fall short of this degree of refinement. Such cases have come to light mainly from the microscopic examination of the tissue removed.

**Prognosis.**—Parents always inquire if vegetations will do any permanent injury if left alone. Most emphatically they will. The worst cases with their train of symptoms, called in general "catarrh," will have attracted the parents' attention, and they will consent to operative removal of the offending tissue. In the less marked cases they may regard an operation as unnecessary; but it must be pointed out to them that even if there seems to be no immediate danger, there is great danger of permanent damage to the organs of hearing and of the perpetuation of an intractable post-nasal catarrh after puberty. Immediate dangers are the increased liability to any contagion which may surround the child, diseases from impaired vitality of the upper air-tract, defective mental and physical development, deformities in the jaws, and defective dental development.

On the other hand, there is no operative procedure in the whole domain of this branch of medicine attended by happier results than is that for the removal of lymphoid hypertrophy from the vault of the pharynx. The child is physically almost born again. Dull intellects brighten, deaf ears

are un-stopped, phonation becomes clear and distinct, mouth-breathing disappears. In short, the child is a new creature.

Does such tissue recur after removal? The general answer has been in the negative, provided that the operation has been thorough. F. E. Hopkins, who has investigated this question, believes that recurrence may happen even after the most thorough removal. This possibility of recurrence is not surprising when we remember that the lymphoid elements in this situation are not mere surface-deposits. They normally infiltrate all the layers of the mucosa down to the periosteum. Literally, complete removal of all lymphoid elements would therefore leave bare bone.

**Treatment.**—The existence of any underlying diathesis must be sought out and remedied. For general tonics cod-liver oil and syrup of the iodid of iron have no superiors. The latter should supplement every operative procedure. Customary directions should be given in regard to bathing, clothing, foot-wear, diet, etc. Especially should it be insisted upon that the child shall sleep in a room directly open to outside air.

Little value resides in topical sprays and applications. They may afford temporary relief, but it is only temporary. Caustic acids and the galvanocautery have their advocates as destructive agents, but such measures are difficult to follow out in children. By exclusion, therefore, the question of treatment practically narrows itself down to the removal of the vegetations by some cutting or scraping method.

In children over twelve and in adults, cocain-anesthesia will suffice. In younger patients we have the choice between ether, chloroform, nitrous oxid, and ethyl bromid. If ether is used, only the primary degree of anesthesia need be induced.

Of instruments we have the finger-nail or the steel nail to be worn over the forefinger, various curettes and forceps almost without number. These are figured and all operative details described under Operations.

# ATROPHIC RHINITIS.

BY W. PEYRE PORCHER, M. D.,

OF CHARLESTON, S. C.

**Synonyms.**—Rhinitis sicca and cirrhotica ; Coryza fetida ; Ozena, etc.

In atrophic rhinitis, as in atrophy of other organs, atrophic degeneration of the glandular and muscular structures is found in one form or another, whether the disease occurs in the young or the old, in the plethoric or the anemic. Microscopical research amply substantiates this fact, as shown by the investigations of Fränkel, Gottstein, Krause, Hartmann, Bosworth, and others. Owing to the various phases which it presents, it has been divided by authors into several varieties—namely, mucous or simple dry rhinitis, muco-purulent or atrophic rhinitis, and ozena ; but the typical form of non-ulcerative atrophic rhinitis, attended by the formation and retention of crusts in the nasal fossæ, is distinctive, and is characterized by a horrible stench, which once inhaled can never be forgotten.

The odor from syphilitic necrosed bone resembles it in some degree and is quite as objectionable ; but the fetor of atrophic rhinitis has more of a musty, graveyard odor, and produces a sensation which is unlike anything else to which it can be compared. It is generally admitted that syphilis is not always a factor in the etiology of typical non-ulcerative atrophic rhinitis ; but syphilitic ulceration with caries always results in atrophic degeneration of the nasal mucosa, and in the majority of instances the disease will be found combined either with syphilis, struma, or tuberculosis.

The odor varies greatly in intensity in different individuals, as well as the crust-formation, even to the complete absence of one or the other symptom ; but where the fetor is marked it may safely be depended on that retained secretion will be found in some fosse or in the accessory sinuses ; and where the amount of crust-formation is very great and long retained, the fetor will usually be proportionately intense. I speak of typical non-ulcerative atrophic rhinitis because one of the most common fallacies is that the disease is always accompanied by ulceration. There is never any ulceration except when a crust has been allowed to remain so long that a raw surface is left beneath it, or where the septum is excoriated by frequent picking with the finger-nail, or as a result of syphilitic or tubercular degeneration. It occasionally happens that atrophic degeneration occurs without crusts or odor ; but these cases are by no means of frequent occurrence.

Atrophic rhinitis is found so much oftener in the female than in the male that it has been held by some to be purely a woman's disease, as it develops frequently at the age of puberty and is thought to be uncommon after the menopause. This has not been the experience of the writer, however, as many of the worst cases which have come under my care have been in old women who have long passed the menopause ; and it has occurred quite as frequently in men as in women. Just when the disease begins or what is the immediate cause, has always been difficult to determine from the



history; as in most, if not all, cases the patients are unaware of its existence until it has become so well established and has made such inroads that it can no longer be overlooked, either by themselves or their friends. It may be found at any age from extreme youth to old age; but in the former case it is very difficult to differentiate it from the syphilitic manifestations with which it is so often combined or on which it is superinduced. The poorly nourished or those whose hygienic surroundings are very bad are the most common subjects of the disease, because of the repeated catarrhal attacks to which they are liable and the prolonged purulent discharges in which these attacks result.

**Symptoms.**—A typical case of atrophic rhinitis has been described as follows: The patient complains of great, often almost choking, dryness in the throat, of accumulation of mucous crusts, particularly in the vault of the pharynx, and of loss of the sense of smell; an intolerable sickening odor may or may not be present in greater or less degree. On inspection the mucous membrane is found to be dry and shiny, and the turbinals nearly or entirely destroyed by atrophy. The nasal chambers are greatly enlarged, so that the pharyngeal wall can be plainly seen by anterior rhinoscopy. The surface of the turbinals is often rough and irregular from unequal degenerations; and intense congestion from crust-irritation is generally present. By posterior rhinoscopy the pharyngeal glandular tissue is found to be almost totally destroyed, and the vault and nasal fossæ are blocked by crusts, often intensely offensive, which may be either dry or soft and mucous in character, and often completely occlude the Eustachian tubes and posterior nares. The lower pharynx presents a most peculiar and typical appearance. The posterior wall is dry, often puckered from lack of moisture, and intensely congested. The posterior half-arches appear drawn much nearer together than in their normal condition, and on pressure with the probe, the pharyngeal mucous membrane is found to be practically resting on the bodies of the vertebrae. Deeply congested and frequently abraded tissues are found on examination with the laryngoscope, and the trachea and bronchi are often also diseased.

The foul breath forms, of course, the most obtrusive symptom. Owing to the atrophy of the nerve-filaments in the olfactory region, where the degeneration generally begins, there is complete anosmia, so that the patients are entirely unconscious of the stench which they exhale; but they gradually learn to shun people. Their presence, however, is often only too apparent, even when they are at a distance, unless they are in the open air or the ventilation of the apartment is unusually good.

The trouble is generally attributed by the patients to gastritis, or the complaint is made that they never have occasion to blow the nose from one week to another. When they do, however, a large crust is generally expelled. This gives great relief to the sufferer and lessens the odor for a short time; but it recurs with full intensity as soon as the crusts re-form, and becomes more penetrating the longer they are allowed to remain. The color of the crusts varies from brown to green and yellow, and they are sometimes even black on the outside. They are generally hard in the middle, but become softer in consistency as they approach the outside edges.

The eyes and ears are often involved. The mouths of the Eustachian tubes are large and patulous, and not infrequently acute suppurations of the middle ear, accompanied by very severe pain, are caused by small particles of mucus which have been inhaled or driven in by the forcible use of the anterior or posterior nasal douche. When the abscess is complicated with or

dependent upon a syphilitic diathesis, there may be a complete absence of pain, and this forms a means of differential diagnosis between an abscess due alone to atrophic disease and that dependent upon the syphilitic diathesis. Bosworth maintains "that in a given number of cases of grave impairment of hearing the number due to hypertrophic disease outnumber those due to atrophic disease in far greater proportions than the comparative frequency of the two diseases." This is a most rational conclusion for many reasons, but especially because every tendency of hypertrophic rhinitis is to occlude the Eustachian tubes, whereas in the atrophic forms the tubes are open and patulous. Tinnitus and many other intractable forms of ear-disease are sometimes distinctly traceable to this disease. Many affections of the eyes may accompany or result from atrophic degeneration of the nose, notably phlyctenular keratitis and conjunctivitis.

Atrophic rhinitis frequently dates from one or other of the exanthemata, scarlet fever, measles, or diphtheria, or more commonly from a series of bad colds in the head. There is a certain facial expression that is almost typical of sufferers from *ozena*—the low flat nose with the large open nostrils. In old subjects the nose generally appears to be almost sunken in the face. There is a peculiar dry appearance about the vestibule and anterior naris. There is a complete absence of vibrissæ, with widely distended alæ, as though the patient was suffering from want of breath. This must unquestionably be caused by the large plugs of mucus, in which a small hole is often found, on which, unless they resort to mouth-breathing, the patients must depend for their supply of air until the plug is removed. So tightly do these crusts become impacted in the nares that their pressure may contribute to cause the abnormal roominess found in the nose, the turbinals are pressed widely apart, there is a complete collapse of the erectile tissue, and in some cases the mouths of the Eustachian tubes and the posterior pharyngeal wall can be inspected by anterior rhinoscopy. The mucous membrane is conspicuously pale, except around the margins of ulcerations or in localized spots of inflammation. In the incipiency of the disease the mucous membrane will generally be covered with a thick, glairy, white secretion, which constitutes a most aggravating source of annoyance both to the patient and to the practitioner. The patient keeps up an incessant coughing, hawking, and clearing of the throat in the effort to get rid of it, and the physician finds it almost impossible to free the throat and nose, even with the most persistent washing and swabbing out with antiseptic solutions, etc. It is the belief of the writer that many patients have succumbed to this disease before the diagnosis was ever clearly established. The continuous cough and irritation so lowers the vitality of the patient that death supervenes directly or is superinduced upon some intercurrent malady.

Epistaxis not infrequently occurs as a result of erosions caused by dry incrustations on the septum and elsewhere. These erosions may be so small that the point from which the hemorrhage proceeds can only with difficulty be detected. The hemorrhage may also be produced by a perforation through the septum, due to incessant picking of the nose in the effort to get rid of the crust-formation. Hoarseness is often present and the vocal function is always impaired. In the later stages of the disease the crusts break up, and small particles being inhaled set up violent spasms and incessant and aggravating cough. These small particles are often seen lying upon the vocal cords or other parts of the laryngeal interior, and there can be no question that their presence often results in the most intractable laryngeal and pulmonary inflammation.

**Etiology.**—Many theories have been advanced as to the etiology of this disease. Mackenzie says: "That atrophic rhinitis always appears as a sequel of a pre-existing catarrhal inflammation is rendered highly probable from a number of clinical and pathological facts. If the clinical history be accurately taken, it will point to pre-existing catarrhal process. As has been indicated above, the rapidity with which the hypertrophie passes into the atrophic form of rhinitis is proportionate in all probability to the possession of some constitutional taint, such as congenital or acquired syphilis."

Dr. Bosworth says that "a purulent rhinitis in childhood is a catarrhal process in the first year and a catarrhal process always; and that it consists essentially in an increased secretion of mucus in the earlier stages, together with rapid desquamation of epithelial cells, which, running its course as a purulent disease in from five to ten years, develops finally into what is known as atrophic rhinitis. The disease, in fact, is the first stage of so-called dry catarrh or ozena." The theory that a purulent inflammation of the accessory cavities is the cause of atrophic rhinitis was advanced many years ago by Michel, and sphenoidal and ethmoidal involvement is common.

A hypertrophied mucous membrane may be found in one nostril with atrophic degeneration in the other; but that does not prove that either condition is dependent upon the other.

One of the interesting theories of the etiology of atrophic rhinitis is that of Löwenberg, who attributed it to micro-organisms.

Auché and Brindel<sup>1</sup> contribute a paper to the bacteriology of atrophic rhinitis which confirms the observations of many previous students. They examined twenty cases, and their results are summed up as follows:

"1. The diplobacillus of Löwenberg has been demonstrated in all the cases of atrophic rhinitis with or without ozena in course of evolution. It was not found in old atrophic coryzas which had apparently been cured. It is not the pathogenic agent of ozena.

"2. The pseudo-diphtheria-bacillus was found eighteen times out of twenty observations of atrophic coryza in course of evolution. It was met with twice in four patients affected with old atrophic rhinitis which had been much ameliorated. It is not the causative agent of ozena. It is very probably only a saprophyte developed in the nasal chambers of patients affected with atrophic coryza, on account of changes in the secretions of the mucosa.

"3. The little bacillus of Pes and Gradenigo was only found in cases of ozena (crusts), and only in the proportion of three to twenty.

"4. Electrolysis produced no effect upon the microbial flora of our patients."

Arslan,<sup>2</sup> after the bacteriological examination of 24 cases, arrived at results which are equally negative so far as concerns the discovery of an organism which could be regarded as the causative agent of the malady, but he is disposed to be rather optimistic in his views as to the efficacy of the serum-treatment of ozena. He treated a number of cases with diphtheria-antitoxin, but an analysis of all his cases does not seem to me to warrant the hope that in the serum we shall find a satisfactory curative agent for this distressing malady.

Although Gradenigo has recanted his first favorable opinion of the method and there have been other discouraging reports, there seems to be considerable interest abroad among rhinologists in the outcome of experience with the method. Moline<sup>3</sup> reports having cured three cases of advanced ozenic atrophic rhinitis by the repeated injections of 10 cc. of Roux's diphtheria-antitoxin. He reserves his decision as to the value of the method for fuller experience, and he suggests that the curative properties may reside in ordinary horse-serum. Compaired sums up his experience with the serum-treatment of ozena as follows:

"1. At present this procedure is one which furnishes the most positive results in the treatment of ozena.

<sup>1</sup> *Revue hebdomadaire de laryngologie*, etc., No. 41, 1897; Wright, *N. Y. Med. Journal*, June 4, 1898.

<sup>2</sup> *Archivio italiano di otologia*, vol. vi, fasc. 1, 2, 3

<sup>3</sup> *Annales des Maladies de l'Oreille*, etc., April, 1897.

"2. The result is shown subjectively by the disappearance of the fetor after the second or third injection of 5 or 6 cc. of serum recently obtained and employed according to all the aseptic and antiseptic rules; and objectively by the absence of dryness in the nasal fossæ with diminution of the crusts and the increase of the nasal secretion.

"3. Objectively, a change in the color of the mucosa is noted, becoming redder, moist at times, and slightly congested and hyperæmic.

"4. The crusts are less hard, dry, and extensive, and become more fluid, according as the number and dose of the injections increase.

"5. The quantity of 10 cc. proposed by Gradenigo is not free from danger, and this is so even as to weaker doses. For this reason it is necessary to use the injections in gradually increasing doses with great care.

"6. The treatment in question offers many inconveniences and dangers, but, on the other hand, it furnishes very positive results; therefore it is proper that the study of the method should be carefully pursued."

Notwithstanding the above statement, until a micro-organism is constantly demonstrated in the superficial layers of the atrophied mucous membrane and it is shown that inoculations produce the disease, we must be satisfied with believing that micro-organisms are responsible only for the characteristic odor of the altered secretions of atrophic rhinitis, in which they find a suitable medium for their growth. It is probable, from what has thus far been reported, that several microbes are capable of producing the odor when growing in the secretions.

Purulent inflammation originating in any of the accessory sinuses or resulting from a simple acute inflammation may likewise result in atrophic degeneration, with more or less complete destruction of the muciparous glands and follicles. The effect of pus on the epithelial and glandular structures, especially in the nose, need not be dilated on here; but it has been a well-observed fact that atrophic degeneration generally begins upon the middle turbinal bodies, and it has also been noted that scabs which become incrustated there and elsewhere almost always contain some particles of pus incarcerated on the under surface of them. Of course, it may be said here that atrophy may result from the simple non-use of any organ, without the presence of any inflammation, simple or purulent, to produce it. Paradoxical as it may appear, it is nevertheless true that the nares of habitual mouth-breathers or those to whom the nose is little more than an ornament of the face, instead of becoming larger from atrophy of the mucosa, become narrower and more occluded, almost as though a hypertrophic instead of an atrophic process had been established; so that it cannot be said that atrophic degeneration is in any case due to simple non-use of the organ—first, because of the fact above cited, and second, because the worst cases of atrophic rhinitis are generally found in those who live in workshops where they breathe the most foul air, sooty emanations, etc.

Atrophic rhinitis occurs quite often at a very early age. Large green crusts forming complete casts of the nose have been found in children of seven years and younger. In these cases the etiological factors of hypertrophy, dust-inhalation, etc., may be entirely excluded. This was notably the case in a child of six or seven years of age that was brought to the writer. There was no specific taint in this case, and hence there could be but one cause to which the disease could possibly be attributed—namely, a prolonged rhinitis resulting from an acute attack which had been left to run on until the nasal mucosa was almost entirely destroyed.

Polypi, malignant growths, etc., have been cited as a cause of ozena. Hereditary abnormal patency of the nostrils has also been advanced as one of the causes of ozena, because of the inability of the patient to free the nostrils of accumulated mucus. This is too hypothetical to be relied on;



but there is no doubt that the fetor is due to decomposition and fermentative products, because when the nostrils are cleansed in the proper manner there is an almost complete absence of fetor for many hours afterward. The theory that atrophic degeneration is nothing but a secondary stage of the hypertrophic variety has been refuted time and again by many of the most careful clinical observers, because it affords no explanation of the ozena of early childhood; and the dry rhinitis of later life is not always preceded by hypertrophy, and hypertrophy does not always terminate in atrophy. The theory of Michel that the disease is due solely to purulent discharges flowing from one or other of the accessory sinuses met with much favor for some time; but this also has been refuted, because in some instances the accessory sinuses were not found to be involved or any discharge flowing from them.

**Diagnosis.**—In regard to diagnosis, there should be no difficulty, as the intense fetor at once makes itself known, and in the cases where this symptom is reduced to a minimum the large roomy nostril, together with the characteristic physiognomy, at once proclaims the nature of the malady. I cannot agree with the authors who make separate subdivisions of simple vascular collapse of the turbinals, mucous or simple dry rhinitis, ozena, etc. I am inclined to believe rather that these will be found to be only different stages of the same disease. This also applies to ulcerations which are found in some so-called non-syphilitic cases and not in others.

The ulcerations will generally be found in those cases in which there has been not only an entire neglect of treatment, but in which the patients have had no relief from the sources of irritation which originally started the disease, and in which the crusts have been retained so long that the mucous membrane has broken down and left the tissues abraded.

The crusts in lupus vulgaris may be mistaken for those of atrophic rhinitis, but lupus generally attacks the outside of the nose as well as the inside; and when the inside is alone involved the crusts adhere so closely that they cannot be removed without hemorrhages and the fetor is never so intense as it is in ozena. In ordinary cases of atrophic rhinitis the crust will be found lining the mucous membrane of both nares. It may completely fill the nasal chamber, being perforated in places for the air to pass through; and when blown out it will show a complete cast of the interior.

In syphilitic ulceration the ravages of the disease are far more general than in lupus and the sequestrum rapidly forms, which, together with the history of the case and the peculiar fetor, may make the diagnosis very clear. The presence of rhinoliths can only be determined with the aid of the rhinoscope and the probe. Tubercular ulceration may be mistaken for ozena, especially in the incipiency of the disease; but here again we must rely on the history, the general appearance of the patient, and the microscopical examination.

**Pathology.**—Opinions vary so much in regard to the pathology of atrophic rhinitis in accordance with the various theories of the etiology of the disease, that it is difficult to arrive at any definite conclusion in regard to it. It is generally admitted that it is similar to that of atrophic degeneration in any other organ—*i. e.*, a gradual wasting away of the different layers of mucous membrane and the conversion of their individual elements into fibrous connective tissue. The walls of the erectile spaces are converted into dense fibrous bands, which in contracting obliterate the erectile cavities. This fibrous degeneration may be confined to the deeper layer and the epithelial layer be intact; or the epithelial layer may be destroyed, while the deeper layers are less involved. The limits of this article make it impossible to go

into the minute microscopical appearances of this condition; but this can be found in any of the text-books on the subject.

**Prognosis.**—It is beyond question that this disease is one of the most intractable to deal with in the whole field of medicine, and from the very nature of the case it is held by a very large number of most eminent authorities to be incurable. There are still a large number, however, as will be seen later, who believe that the mucous membrane can be so changed by judicious use of stimulants, antiseptics, constitutional treatment, etc., that a virtual cure is brought about; and in the light of the most recent investigations it is the opinion of the writer that this latter conclusion will be found to be correct.

**Treatment.**—It is apparent, then, as has been stated by some writers, that atrophic rhinitis is not a disease *per se*, but is the result of any inflammation, acute or chronic, specific or non-specific, whether excited by exposure to cold or continuous inhalation of irritating dust, vapors, etc., which ends in a purulent discharge, and which may or may not involve the accessory sinuses, but is sufficiently prolonged to wash away the epithelium and destroy the nasal mucosa. If this is true, what measures should best be instituted for the relief of the patient, and what hope have we that the formation of seals may be stopped?

In response to an article by the writer, this subject was very fully discussed at the meeting of the American Laryngological Association in 1896, and again it was made the special subject of discussion at the annual meeting in 1897, and a great many varieties of treatment were suggested. The following *résumé* of remarks will give some idea of most advanced views of the treatment of this disease (see also page 885):

Dr. C. C. Rice expressed his belief that the disease was intimately dependent upon some constitutional taint or unhealthy occupation or manner of living. He therefore urged the necessity of giving patients out-of-door work with good hygienic and sanitary surroundings. He recommended a combination of 75 per cent. compound stearate of zinc with boric acid and 25 per cent. compound stearate of zinc with alum. This powder should not be used after the discharge has been stopped and congestion controlled, as it is too drying. In the markedly congestive forms of atrophic rhinitis seen in immoderate cigarette smokers and alcoholic drinkers this powder is a valuable one. It goes without saying that we should not promise any benefit from any form of treatment unless excessive smoking and drinking are given up.

Dr. Wright recommended mild stimulation with a weak solution of thymol.

Dr. Delavan concurred with Dr. Wright, and recommended electricity for the same reason.

Dr. Vanderpoel had used diphtheria-antitoxin based on the similarity between the Klebs-Löffler bacilli of diphtheria and those found in atrophic rhinitis, and in one case there was no return of the crusts which the patient had had before the attack of diphtheria.

Dr. Logan laid stress on the necessity of establishing free drainage from the accessory sinuses, so as to stop the continual discharge of pus over the middle and upper turbinals.

Dr. Casselberry advised that patients should select the warmer, moist, and salubrious climate of the Southern seashore rather than the dry regions of the West.

Dr. Mackenzie recommended weak solutions of bichlorid of mercury rather than strong antiseptics. A form of stimulation in the shape of mas-

sage has been strongly recommended by Laker of Vienna. Massage may be applied to the nose either by the aid of an electrical vibrator or simply by titillating the parts with a probe armed with a pledget of cotton.

The Germans and Italians recommend bichlorid of mercury strongly on the assumption that the disease is due to the presence of bacteria. Koch and Löwenberg claim great benefit from a solution of 1:2000 or 1:4000, applied with a spray or brush. Cardonne of Naples and Maramo also advocate the same treatment. Bellanti has used the diphtheria-antitoxin with great benefit in ozena; and other observers have used the same treatment, but not with uniformly good results.

Dr. George Stoker of London warmly recommends the use of oxygen-gas in this affection and chronic aural suppuration. The nose or ear is first thoroughly cleansed with warm water and the gas is then applied from four to six hours daily, with intervals of one half hour. The efficacy of this plan of treatment is beyond question where free outlet is given to all pus-cavities and free ingress of oxygen is allowed.

Where a specific element is present mercury should be pushed to the extent of moderate salivation. A patient recently under the care of the writer became severely salivated, with the result that the formation of crusts as well as the severe headaches which had occurred daily before the treatment has ceased entirely and the patient considers himself cured. He has experienced no ill effects whatsoever from the salivation, and denies absolutely any venereal infection; nevertheless, the atrophic condition has undoubtedly been materially benefited. He used locally also a spray, as follows:  $\mathcal{R}$ . Glycerin pur.,  $\bar{5}\bar{i}$ ; sodii bibor.,  $\bar{5}v$ ; aquæ destillatæ,  $\bar{5}j$ . The nose was thoroughly sprayed with this solution three times a day. The use of the galvanic current applied locally, first recommended by Shurly of Detroit and afterward by Delavan and Hartmann, has produced excellent results.

A great many drugs have been used for their irritating and stimulating effects. Among these may be mentioned iodoform, iodol, aristol, salicylic acid, camphor, iodin, perchlorid of iron, tannin, alum, opium, 25 per cent. trichloroacetic acid, etc. The writer has used with much success a solution of iodin, glycerin, and potassium iodid applied on a cotton pledget high up in the vault of the nose. This produces a very profuse discharge of mucus, which washes away the crusts and after a time appears to prevent their formation.

The use of caustics, the electric cautery, chromic acid, etc., should never be indulged in because of their injurious effect on an already attenuated membrane. Almost every drug in the *Materia Medica* has been tried in one way or another to cure this disease, and they have been given up because they proved either entirely valueless or only palliative. Dioxid of hydrogen was at one time highly extolled, but has been abandoned because it leaves the mucous membrane as dry as ever. Oily solutions in combination with various drugs act as excellent stimulants and protectives, but do not accomplish much in the way of cure.

In conclusion, the writer would suggest the following plan of procedure: A rigid examination should first be made to determine if there is any discharge of pus from the accessory sinuses, any sign or possibility of specific taint, any history of tubercular or diphtheritic disease, and the general hygienic and sanitary surroundings of the patient should be carefully investigated. Should a pus discharge be found from any of the accessory sinuses, free outlet should be given to it and the sinus should be carefully washed out with hydrogen dioxid and dusted with some antiseptic powder. If in any case there is the

least likelihood of a specific complication, mercury and opium with mercurial inunction should be pushed until mild salivation is produced. It has been the experience of the writer that the combination of mercury and opium has a much more rapid and satisfactory effect than iodid of potash,<sup>1</sup> even when given in very large doses. The patient should be ordered to keep the nose thoroughly cleansed always with Seiler's solution or a spray of glycerin and biborate of soda or some other mild stimulant used three times a day. If the patient has had diphtheria or the crusts still persist, diphtheria-antitoxin may be administered and a solution of bichlorid of mercury (1:2000) be sprayed daily. The patient should be directed to live out of doors as much as possible, and his general health should be built up with tonics, cod-liver oil, etc.

The limits of this article entirely forbid further elaboration of this subject. Suffice it to say that the best results will be obtained when the patient is instructed how to maintain thorough cleansing so as to promote adequate nasal respiration, as well as the healing of all ulcerations, proper drainage, and the restoration of the normal mucous lining membrane as far as possible. He should have plenty of fresh air and sunshine, as well as absolutely hygienic surroundings. In some instances a visit to the seashore or some mineral springs will exert a marked influence for the better. J. N. Mackenzie advises that "as little liquid nourishment should be taken as is compatible with the comfort of the individual."

The ingestion of large quantities of liquids is to be deprecated, as well as alcoholic beverages of any kind, unless taken in great moderation. Healthy out-door exercise, combined with the observance of the ordinary rules of health, will generally so moderate the worst features of the disease as to render the patient comparatively comfortable, if not entirely relieved.

<sup>1</sup> In syphilitic cases ulceration and sequestrum-formation may be furthered by the mercurial, when the iodid will give as prompt and lasting cure without such loss of substance.



# DISEASES OF THE ACCESSORY SINUSES OF THE NOSE.

By ROBERT CUNNINGHAM MYLES, M. D.,

OF NEW YORK CITY.

THE accessory sinuses of the nose are cavities in the bones of the head and face that connect with the nasal fossæ by one or more narrow apertures. There are three bilateral single sinuses—the antra of Highmore, or maxillary sinuses, the frontal sinuses, the sphenoidal sinuses, and two bilateral groups of sinuses, the anterior and posterior ethmoidal sinuses.

## ANATOMY.

The maxillary sinuses are situated on both sides of the face, between the orbits and upper teeth (see Fig. 545); their average measurements are about 27 millimeters through the center, both vertically and antero-posteriorly. They have an oblong or fissure-like opening into the middle meatus of the nose, about

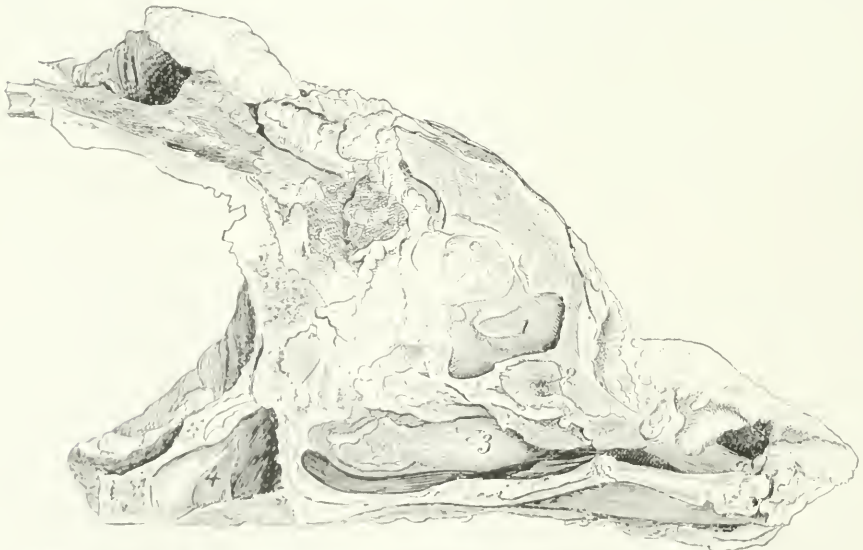

FIG. 186. Horizontal section through the nasal cavities from above: 1, cavity of antrum of Highmore; 2, nasolacrimal duct; 3, middle turbinal; 4, sphenoid cell. (See also Plate 10.)

its middle third. Accessory openings posterior to the hiatus are common. Occasionally the roots of the molars project like small cones from the floor of the sinus, and frequently there are partitions and membranous bands, one-fourth to one-half an inch high, dividing the floor and walls into compart-

ments. These are often regarded by observers as pathological formations, but I believe that they are normal. The walls of the canine fossæ and the inner or nasal wall, from one-third of an inch above the floor, are very thin, excepting that part which gives an attachment to the inferior turbinated bone. Fluids of low specific gravity will sometimes flow from the frontal sinus, down through the infundibulum, into the antrum of Highmore. This is important, as it shows that the antrum may serve as a pus-reservoir for the inflammatory products from the frontal sinus or anterior ethmoidal cells. The ethmoidal cells are situated between the nasal process of the superior maxillary and lacrymal bones and the frontal sinus in front; the sphenoid and palate bones behind; the sphenoid, cribriform plate, and frontal bones above; and the os planum, lacrymal, sphenoid, and superior maxillary bones on the outer side. The inner side is bounded by the space from

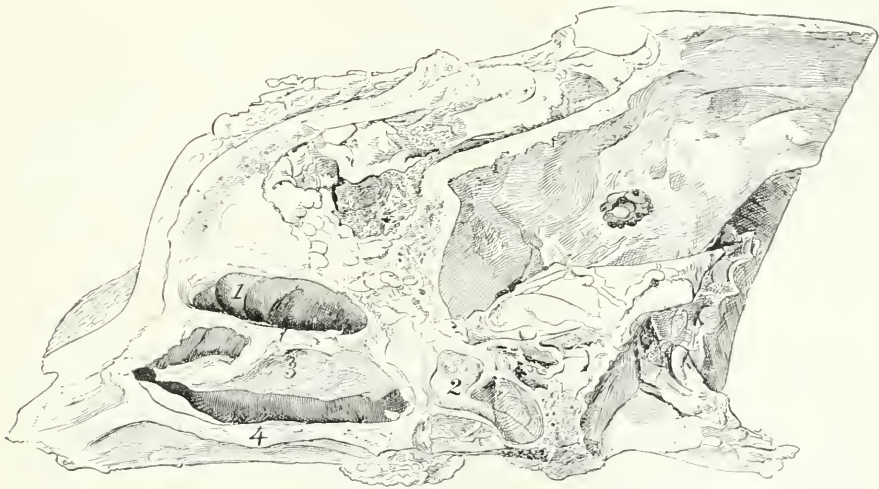

FIG. 557.—Horizontal section through the nasal cavities: 1, cavity of antrum of Highmore; 2, sphenoid cell; 3, inferior turbinal; 4, septum.

the cribriform plate to the middle third of the middle meatus in front and to the attachment of the middle turbinated bone behind. (Fig. 543 shows the ethmoidal cells partially exposed.) They are separated by an unbroken partition into anterior and posterior cells. Sometimes the anterior cells communicate with the infundibulum or frontal sinus direct. The anterior cells drain by an opening in the median wall of the ethmoidal bulla, and frequently by another opening into the superior meatus. The sphenoidal cells are best described as being in the body of the sphenoid bone; they are separated from the posterior ethmoidal cells by a common wall, and discharge their contents through an opening in the upper anterior wall. (Fig. 548 shows right and left cells as they cross the median line.) The frontal sinuses are situated in the frontal bone, above the inner canthus of each eye. Their walls are made up by the frontal bone, excepting a part of the floor, which is formed by the ethmoidal cells and the projecting portion of the nasal process of the superior maxilla (see Fig. 547). These cavities are irregular in size: in the average sinus the perpendicular and transverse diameters are about one inch in their longest axis. The central antero-posterior diameter measures about three-eighths to one-fourth inch; it is not uncommon to find one large and one very small cell in the same head. The large cells usually extend toward

the temporal region, from one to three millimeters beyond the orbital notch, and they discharge their secretion through an irregular tortuous canal, the infundibulum. They are divided by a bony wall, which is rarely central and occasionally perforated (see Figs. 544 and 548).

#### PHYSIOLOGY.

Although the physiology of these cells is not definitely settled, an analysis of their function points to the conclusion that they are intended to supply warm air and moisture for respiratory purposes, and also probably to act as resonators for modifying certain qualities of the voice. When we consider that about 400 cubic inches of air are inhaled per minute, which should be warmed to a temperature as near 98.5° F. as possible, and that this same air should be charged with vapor nearly to the point of saturation, I cannot conceive of a more satisfactory arrangement than these cells afford. During respiration the apertures, including the naso-lachrymal ducts, have a tendency to dilate, while during expiration they partially close. At the beginning of inspiration, the partial vacuum produced takes a part of the latent air from within the cells, and the velocity of the inspired current further draws from them. Toward the end of the inspiratory act, new air enters the cells to fill the partial vacuum, aided by the natural law by which warm air is displaced by cold. On expiration, the *vis à tergo* pressure partially closes the cells. The to-and-fro currents of air constantly draw the tenacious mucus from the cells, overcoming the adverse conditions of small openings and the laws of gravity.

#### EMPHYEMA OF THE MAXILLARY SINUS.

**Etiology.**—Distinguished specialists have written a great deal within the past few years concerning the cause of pyogenic conditions within the antrum of Highmore; and they are about equally divided on the question whether disease of the nose or the teeth is the more frequent causal factor of disease. My own experience in the chronic cases is that the teeth and nose are about equally responsible for the purulent condition. Many of my worst cases were caused by fillings placed in teeth with very large cavities where the nerves were either exposed or dead. Suppuration had evidently occurred in the root-end; the pus had discharged itself, with little resistance, through the thin bone lying between the top of the alveolus and the floor of the antrum, and from that time the tooth had not given the patient any pain nor the dentist any concern. But the patient had been trying nearly all of the patent catarrh-remedies, and had been treated by different specialists for nasal and post-nasal catarrh. A few cases seemed to be caused by alveolar periostitis, caries, and necrosis, which had been originally started by a decaying tooth. The majority of the cases of nasal origin began with polypoid degeneration. In some of my patients their septa were so far deflected in the upper middle region that the middle turbinal bodies were pressed firmly against the hiatus; the secretions had been retained under putrefactive and fermentative conditions, and had produced chronic inflammations of the membranes and bones, and probably necrotic areas. Influenza, la grippe, or acute inflammations of almost every kind appear to produce empyema when the swelling is so great as to close the normal opening, especially by pressing the upper and inner valve-like lip of the hiatus outward against the semilunar partition. Atrophic rhinitis, syphilis, tuberculosis, tumors, and foreign bodies occasionally cause suppuration in the antrum.

**Symptoms.**—In cases of acute empyema with complete occlusion the pain is extremely severe, and there is a feeling as though the antrum would rupture from the intense pressure. In four of my suppurative cases with complete stenosis the pain ceased immediately after the evacuation of the pus. In those instances where the acute and subacute catarrhal process either occurred simultaneously with nasal cold or extended into the antrum by continuity there was a slight fulness and a sensation of stuffiness in the region beneath the eye, together with a thick muco-purulent discharge into the middle meatus beneath the bulla, which usually stopped within from three to six weeks. The chronic cases all had the symptoms of so-called post-nasal catarrh, and in the majority of them the mucus and pus were discharged also through the anterior nares. Certain patients complained of the fluid running downward over the upper lip whenever the head was inclined forward; others complained of asthma, tubal stenosis, tinnitus aurium, and impairment of hearing, which were relieved after an operation or by irrigation of the antrum. In my series of cases pain was the most irregular and deceptive symptom of all. Frequently it was entirely absent; at other times it would occur in either the frontal, maxillary, temporal, or occipital regions, or in two or more of them.

**Pathology.**—I have classified the usual pathological conditions under eight subdivisions, as follows, representing the pathological states approximately as I have observed them in my cases:

I. Acute catarrhal, suppurative, and infectious sinusitis, without complete stenosis of the normal outlet.

II. Acute catarrhal, suppurative, and infectious sinusitis, with complete occlusion of the normal outlet.

III. Subacute and chronic catarrhal and suppurative sinusitis, with moderately obstructed opening, with or without decayed puro-mucoid débris.

IV. Polypoid degeneration.

V. Alveolar periostitis and periodontitis, attended by suppuration, caries, necrosis, or other pathological changes at the root-end.

VI. Atrophic rhinitis.

VII. Tumors and foreign bodies.

VIII. Syphilis.

Acute cases without stenosis are very common. The mucous membrane of the nose and cavity is usually congested at first, and then it begins to swell, and continues to do so until it is several times its normal thickness. At this stage it usually throws out a thick muco-purulent secretion; the discharge gradually ceases within from three to six weeks, and the membrane is left a trifle thicker, having undergone slight hyperplasia. In the completely stenosed cases, where neither nature nor surgery relieves them, necrosis of the soft tissues usually occurs, and occasionally the bone is involved in the same process.

In the subacute and chronic catarrhal and suppurative cases, where the opening is moderately obstructed, the mucus frequently becomes partially inspissated and forms a lump, which enlarges by accretion and acts as a foreign agent, causing a bacterial development. The corroding by-products of this frequently destroy the surfaces of the mucosa and start small ulcerated areas, which, if not cured, extend in time to the periosteum, and often to the bone itself.

Polypoid degeneration extends from the ethmoid, or has its origin upon the antrum-membrane. In its early stages this peculiar condition may be classed as watery edema. If it occurs on the lateral or upper walls of the

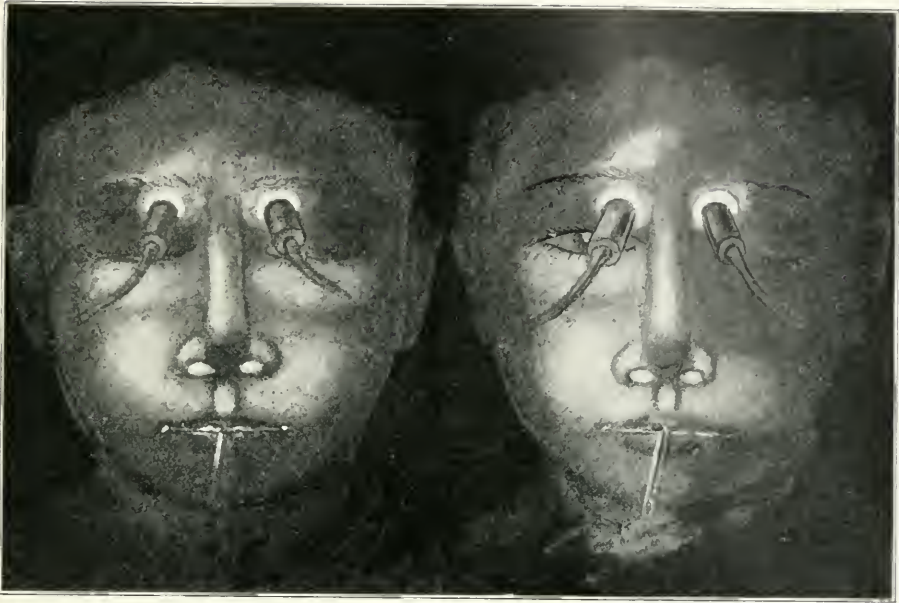


cavity, and remains more or less flat or mammillated, there is a possibility of its returning to its normal state under favorable conditions; but if it once becomes pedunculated it seems to lose this power of self-restoration. Caries, necrosis, and burrowing periostitis in the molar or bicuspid roots frequently extend through the floor of the bone and burrow in a fistulous manner beneath the periosteum, elevating it and frequently leaving the entire membranous floor floating in muco-purulent matter. A rupture may take place through this membrane at a distance from the injured bone and discharge itself into the nose. The membrane becomes very thick and granular, and debris from the mucus, pus, and bone degenerates in the cavity. The atrophic process, which is the consequence, in my opinion, of suppurative rhinitis in early childhood, invades the antrum, frequently destroys the epithelium and the serous glands of the membranes, and leaves a sclerosed membrane which secretes a semipurulent matter; this, in turn, degenerates in the warm cell and issues through the normal opening into the nose, where it is formed into crusts by the inspired air.

Tumors, especially sarcomata, may form in the antrum and simulate empyema. Syphilis usually attacks the antrum-walls by the formation of gummata; while at rare intervals the germs of scarlet fever, measles, tuberculosis, and diphtheria invade the antrum, as do aspergilli and other fungi.


**Diagnosis.**—A unilateral pus-discharge from the nasal cavity is by far the most suspicious symptom of empyema of the maxillary sinus. On rare occasions this unilateral pus- or muco-pus-discharge is only made manifest posteriorly. On the other hand, polypoid degeneration, which, in my experience, is next in frequency to the irritation caused by decaying teeth in causing antrum-trouble, is usually bilateral. The classical symptoms as laid down in the older books are usually wanting, save in the acute stenosed cases. The frequency and urgency of diseases of the antrum have led us to abandon the consideration of a great deal of the circumstantial evidence upon which formerly so much stress was laid, and we make small delay in trying to obtain positive evidence at once. This is usually secured first by inspection of the middle meatus. If pus is detected beneath the bulla ethmoidalis under the middle turbinal body and the hiatus semilunaris, we know that one of the three cavities is diseased—the anterior ethmoidal cells, the frontal sinus, or the antrum of Highmore. After cocaine has been applied to the membrane and pus is found, a cotton-applicator should be used to wipe it away, and, if pus then exudes from beneath the middle turbinal body and on the lateral side of the bulla ethmoidalis, it of course comes from the anterior ethmoidal cells. If, after wiping it away and placing the patient on a lounge, with the top of his head near the floor, pus comes from the hiatus, the evidence is almost positive that its source is the antrum. In those cases in which the pus is liquid in character it will flow readily into the nose and will have a more or less offensive odor. If, however, the pus is very thick and much intermixed with mucus, it will sometimes merely protrude through the opening. In the frontal sinus cases I have usually been able to detect the pus at the very uppermost anterior part of the hiatus. Usually it is well, even after the pus discharges with the head in a downward position, to introduce a curved irrigation-tube into the hiatus, and inject warm water into the cavity; if this is successfully done, we are almost invariably rewarded with the evidence of pus in the returned fluid. In those obscure forms of latent empyema, the first evidences of their existence is usually shown by the electric light (Plate 14). Although this procedure is not infallible, it is of great value in the hands of one who knows how to employ it. A pus-discharge

PLATE 14.



I.

II.



III.

IV.

FIG. I.—Transillumination of both maxillary antra by electric light in mouth, and of both frontal sinuses by lights under the orbital margin.

FIG. II.—Failure of transillumination of antrum and frontal sinus on the left, while both are lighted, and the pupil also, on the right.

FIG. III.—Failure of illumination complete for frontal and maxillary sinuses of both sides.

FIG. IV.—Only the right maxillary antrum is illuminated, while both frontals remain dark.



on one side, with a dark umbra beneath the corresponding eye, is almost conclusive evidence; yet, to make assurance doubly sure, I nearly always remove some of the pus from the antrum, either through the natural opening with the silver irrigation-tube or by means of the trocar and cannula passed through the antrum-wall in the middle meatus, just below and posterior to the hiatus.

In a few of my cases even these tests failed to demonstrate positively the pathological state within. They were cases in which the antrum was full of polyps, and in most of them there was a thick, tenacious mucus with occasional hardened lumps. The irrigation-fluid simply passed over the polyps. Puncture through the bone of the canine fossa or through the alveolus of the tooth has always seemed to me too serious a procedure to be justified for merely diagnostic purposes. The small trocar and cannula (Fig. 588) passed through the middle meatus, below the posterior end of the hiatus,



FIG. 588.—Curved trocar and cannula for entering the maxillary antrum.

where there is either very little or no bone, causes but little pain and apparently no after-disturbance. Tenderness on pressure and dulness of percussion may occur from periosteal irritation or may be due to the smallness of the antrum; but they have little significance, except as they may concur with a train of symptoms, to make the diagnosis by exclusion.

**Prognosis.**—Diseases of these sinuses rarely cause death directly; but they frequently make life miserable. The dangerous cases of antrum-trouble which I have seen have been those in which the orbital plate was broken through by the intense pressure of the confined gases and fluids; and a few cases are reported in which the pus, burrowing through the orbit and ethmoid, has extended to the brain. In nearly all of the acute and subacute cases resolution takes place within a few weeks. If a case has existed over a year with a history of constant muco-purulent discharge, disclosing, when the cavity is opened, carious and necrotic bone, with destruction of a considerable area of the mucosa, the prognosis in regard to an early cure is unfavorable, as it usually takes several months or a year or two for the tissue to regain, even approximately, its former state. I have found cases of necrosis of the septa of the superior maxillary bone and general polypoid degeneration of the mucous membrane of the cavity the most obstinate in treatment and unfavorable in prognosis.

**Treatment.**—The best procedure in treating these cases will be determined by the pathological state and by the history of each case. Acute and subacute cases, not of dental or polypoid origin, can usually be readily cured by restoring the nasal mucous cavities to their normal state, and by irrigation of the sinus through the natural openings. In cases of dental origin the offending tooth should be removed; and, in those of recent date, the tissues should be let alone for a few weeks in order that they may have an opportunity to resume their normal condition, the causal factor of disease having been removed. If the trouble has existed for more than six or ten months and there is a decided odor from the antrum, with evident carious and necrotic trouble at the root-end, I advise immediate penetration by making an opening, about 5 or 6 mm. in diameter, through the alveolus-floor. Irrigation



with disinfectants should be passed through with the regulation tubes and syringes. If the internal walls appear on probing or curetting to be in an extremely degenerated state, with serious carious and necrotic conditions of the bone, I think that the safest and most effective operation under these circumstances consists in a large opening into the antrum through the canine fossa and the anterior lower border of the malar ridge.<sup>1</sup> This

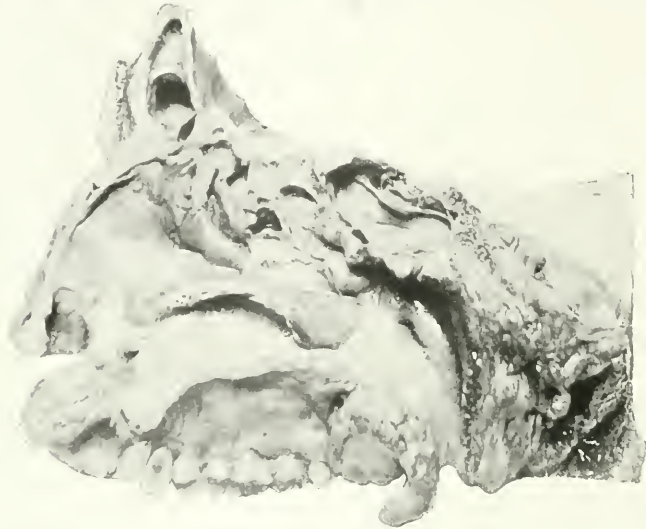


FIG. 589.—Removal of anterior two-thirds of inferior turbinal to gain access to the antrum through the outer nasal wall.

opening should be from 10 to 15 mm. in diameter; the cavity should be carefully curetted, and in certain cases a counter-opening (Fig. 589), at least 8 to 10 mm. in diameter, should be made through the inferior meatus-wall into the nose. I have operated by cutting off the inferior turbinal and trephining through the inferior meatal wall, and have



FIG. 590.—Drainage-tubes for antrum.

also cut into the lower border of the hiatus in the middle meatus. The cases in which I did this were so extensively and seriously diseased that I did not get as good a result as I had anticipated, chiefly because I could not curette the walls through this intranasal perforation. The after-treatment should consist of aseptic and antiseptic irrigations, and in certain cases keeping the canal open by means of rubber (Fig. 590) or silver tubes, with occasional careful curettage of the necrotic and granular surfaces and the insufflation of boric acid and of iodoform in certain cases where there is frequent accumulation of foul-smelling pus. I have found the injection of a drachm and a half of liquid alboline, containing 3 to 10 grains of iodoform, left in the cavity, to afford marked and decided relief.

CLASS I.—The cases of *acute nature without stenosis* are very common, and usually last from three to six weeks. They come on after the manner of an ordinary cold in the head, followed within a few days by very disagreeable feelings of fulness, oppression, and dulness; in some cases a certain amount of headache exists, or toothache, and a dull feeling is present in the ears. This stage is relieved by a copious flow of muco-pus. During the

<sup>1</sup> [The operator must be prepared for severe hemorrhage in rare cases.—E.D.]

course of these cases the ordinary treatment for a severe cold is the best. Most individuals who are subject to this condition have from two to four attacks during the year. The rational treatment is one of prophylaxis, which consists mainly in reducing and removing the intumescent and abnormal tissues within the nose, which should be done during the intervals of the attacks.

**CLASS II.**—*Acute Catarrhal, Suppurative, and Infectious Sinusitis with Stenosis.*—These cases, besides requiring the ordinary treatment, demand the evacuation of the retained secretion at once. A limited amount of a saturated solution of cocain should be applied to the parts around the natural opening, and a persistent effort should be made to enter the cell with a tube, or, failing in this, penetration with trocar and cannula should be made, and the cavity should be carefully aspirated and irrigated. As soon as its patency is restored the patient recovers rapidly. These cases call for the same treatment during the intervals as that described for Class I.

**CLASS III.**—*Subacute and Chronic Catarrhal and Suppurative Sinusitis, with Moderately Obstructing Stenosis, Thickened Mucosa, with or without Retained Decaying Puro-mucoid Débris.*—This class of cases is the most fruitful source of post-nasal catarrh, and is rather difficult to diagnose accurately. The symptoms rarely indicate the latent pathological condition sufficiently to warrant the operative procedures necessary for a proper diagnosis or treatment. In these cases attempts should be made to irrigate through the natural openings. In certain cases removal of the anterior end of the middle turbinal facilitates this procedure, and frequently we are rewarded with a cure or decided relief. It is taken for granted that in all classes of cases any abnormal intranasal conditions should be rectified. When these cases resist the irrigation-treatment and are of sufficient importance, a counter-opening should be made in the cell-walls and proper curettage and drainage should be carried out.

Mrs. C., aged thirty. Acute empyema; sent for me to visit her. Complained of great pain and fulness which came on with a cold in the left jaw, which was swollen and tender. The hiatus was closed by tumefaction of all the tissues near the part. After applying cocain-crystals, I washed out the antrum through the natural opening; muco-pus flowed out with the boric-acid solution; immediate relief from the severe pain followed, and the patient gradually recovered.

Miss L., aged twenty-six, had been suffering for several days from severe pain and oppression in the right side of the face, with a sensation as though the face and orbital cavity would burst. Her septum was deflected with an echondrosis; the turbinals were much swollen, and transillumination produced an umbra under the right eye. I reduced the intumescent tissues with cocain, and found the tissues about the right hiatus swollen and papillomatous in appearance. On introducing one of the smallest silver tubes the confined pus escaped with the irrigating fluid, which gave her immediate relief. I removed by snare a fungating papillary growth, about three millimeters in diameter, from the internal margin of the hiatus. After several irrigations at three days' intervals the cavity gradually returned to a normal condition.

Mr. A. W., aged fourteen, consulted me in May, 1892. Complained of (in his own words) "Very bad discharge from nose for the last four or five years, which consists of pure matter. Sometimes there is a buzzing noise in the head on waking in the morning. A bad smell from the nose." There had been a muco-purulent discharge with unpleasant odor, mostly from the right side, for the past three or four years.

Rhinoscopic examination showed the septum deflected to the left with an ascending oblique echondrosis. The septum was deflected to the right superiorly, pressing the middle turbinal body outward; pus mixed with mucus was issuing from the right hiatus. He had excessive hypertrophy of all the turbinal tissues, and also of the third and faucial tonsils. The electric light produced a light spot beneath the left eye and an umbra beneath the right. I reduced the hypertrophy of the turbinals with the electric cauter and chromic acid, and irrigated the right antrum through the natural opening two or three times a week for a few months.

The patient gradually improved, pus ceased to flow, and the electric light produced the light spot beneath both eyes.

CLASS IV.—*Polypoid Degeneration*.—This class furnishes by far the majority of the operative cases. Woakes, Bosworth, Casselberry, and others have well described them and their treatment. Large counter-openings, packing, careful and repeated curetting, good drainage, and irrigation are the essentials for successful treatment.

CLASS V.—*Odontic Periostitis and Periodontitis, Sometimes Terminating in Caries and Necrosis*.—It is universally conceded that the offending tooth in this class of cases should be removed, and, if the case be of long standing, the cavity should be opened, carefully curetted, and dressed. Formerly, following the advice of many dentists and surgeons in these extensively necrosed cases, after the tooth had been extracted, I drilled upward through the socket; but the after-history of many of such cases has caused me to regret it. The principal objectionable features are: the distance through the bone to the floor of the antrum; the dense thick tissue of the gum; the difficulty experienced in curetting, the long walls of the opening preventing the proper play of the handle of the curette; the easy entrance of food into the antrum, and the necessity of plugging the tube, when one is worn for drainage, while eating. I take it for granted that every one would prefer the lower anterior border of the malar ridge for penetration in all cases where the first molar tooth has been absent for some time. The most serious obstacle which I have met with is the decided objection of the patient to losing a tooth.

In nearly all extensively diseased cases, where some other operation was performed in place of the one through the malar ridge, the patient and myself have both had cause to regret it. On the other hand, a great many of the worst types of cases have done well when the operation was properly made through the point of election. The surgeon has complete subsequent control of the antrum, and can keep it open and curette it at any time without inconvenience to himself and with very little pain or annoyance to the patient. The canine fossa, where the bone is very thin, is the next point of preference; the main disadvantages are its distance up under the cheek and the elevation of the opening above the floor of the antrum. The history of the following cases presents some of the difficult problems of this class of cases.

Mr. C. H., aged twenty-five. Presented for treatment, 1891. There was a history of long-continued catarrhal discharge from the nostrils, anteriorly and posteriorly, much greater on the right than on the left, and a most unpleasant odor in the expired breath. The nostrils were very disagreeably stenosed, the right more than the left. The secretions were muco-purulent, excessive in the mornings, at times decidedly creamy in color and consistency, and leaving more or less of a permanent yellowish stain on the handkerchief. The objective symptoms were a moderately deflected septum, hypertrophy and passive dilation of turbinal tissues, which I reduced with electric cautery and chromic acid. On certain mornings there was a stream of muco-purulent matter issuing from the posterior end of the right hiatus semilunaris, and continuing its course, on the upper surface of the inferior turbinal body, to the naso-pharynx, and not, as usual, passing over the inferior turbinal toward the floor of the nostril. After reducing the general hypertrophy, I diagnosed empyema by placing the electric light in the mouth, showing a very dark shadow over the right antrum and bright spot under the left eye; and besides the corroborating evidence of pus discharged from ostium maxillaris, I passed a curved needle through the antrum-wall in the inferior meatus after Mikulicz's method and found pus in considerable quantity. Irrigation of the antrum through the hiatus gave similar results. He had splendid teeth, but on close inspection the right second molar was pale white in color and appeared as though the nerves were dead. This tooth had been filled with an amalgam four years



previously and had given no disturbance since. I proposed removal of the tooth and trephining, but he refused an operation in which he would lose a tooth. Subsequently I sent him to a dentist, who removed the filling and found some purulent secretion and offensive gas in the palatine root; he treated it for some time with the hope of arresting the trouble above, but without avail, and the patient finally consented to have the operation performed. Under gas Drs. Bradley and Dixon removed the tooth and I trephined a space about 6 millimeters in diameter through the socket. The antrum was full of the most offensive pus and gas it has ever been my ill-luck to detect. I curetted from the cavity a great deal of granulation-tissue and some carious bone, and after irrigating the cavity with an antiseptic solution, packed it with iodoform-gauze, which remained in for a few days. Subsequently I packed it once a week, and there was very little pus or odor when I removed the gauze. He improved steadily for a few months, wearing a gold tube fitted to a special plate, and irrigated the cavity regularly; then the hole gradually closed, and all of the old-time unfavorable symptoms reappeared. I then removed a part of the external wall of the antrum and found extensive granulations and carious bone, which were carefully curetted. He wore the rubber tube for a long time, and when I saw him last was in a very good condition, the irrigation bringing away daily only a small lump of mucus about as large as a pea.

This is a typical case due to the filling of a tooth before the pathological state in the root had been relieved.

The results in the cases where I have penetrated through the walls of the meatus have not been so satisfactory as those reported by Grant and other European writers. I have noticed that many cases under thorough and careful curetting ultimately did better than those which were extensively or over-curetted, or those in which the curette was used too moderately. I have found the greatest benefit from recuretting, at intervals of about one month, until all bare bone is covered and granulation-tissue cicatrized.

CLASS VI.—*Atrophic Rhinitis*.—The bacilli of atrophic rhinitis frequently find a permanent home in the sinuses. Robertson of Newcastle-on-the-Tyne and Grünwald have done some original and efficient work in this class of cases. I have found two kinds of cases apparently caused by this affection: one in which the semi-solid putrid débris is confined in the cavity and remains a causal factor in keeping up the condition, and the other in which the tissues have undergone degenerative changes. Irrigations will frequently relieve the first; curetting and drainage are generally necessary to restore the latter.

CLASS VII.—*Tumors*.—Tumors occasionally develop in these cavities. Early diagnosis is of the greatest importance, for it frequently enables the surgeon to save the patient's life by timely removal, and rescues him from a condition of intense pain and distress. Among the benign tumors mucocoeles and osteomata are the most important.

Among the malignant tumors, sarcoma (spindle- and round-celled) and osteosarcoma are the most common. The prompt removal of the superior maxilla in a patient of Dr. Wyeth's and mine has apparently cured him of an otherwise fatal disease.

The patient was sent to me in February, 1894, by Dr. Wyeth for my opinion concerning the right antrum of Highmore. He had been troubled with a diseased tooth, pain in the right upper jaw, and with an extremely unpleasant discharge for two years. A diseased tooth had been extracted. In August, 1892, a local dentist opened the antrum, but the pain continued. In September, 1893, Dr. Wyeth (the patient being under ether) opened and curetted the antrum through the tooth-socket, but little relief from the discharge was experienced. In January, 1894, Dr. Wyeth recuretted the antrum, but the unfavorable symptoms continued.

In passing the curette over the antrum I noticed a thick and peculiar lining on the antrum-walls, which produced very much the same sensation as one experiences when scraping a raw potato. I expressed my opinion that it was a malignant neoplasm, and, upon Dr. Wyeth's suggestion, a specimen was sent to Dr. Prudden, who reported that it was a large-celled sarcoma. In March, 1894, Dr. Wyeth removed the superior maxillary



bone, with part of the pterygoid plate. The patient recovered from the operation, and seems to be doing very well with an artificial jaw, and continues in the practice of his profession as a lawyer. There remains one unfortunate result: the continuance of a constant sweetish and extremely disagreeable taste in the mouth. There is a little muco-pus issuing at the point where the section of the naso-lachrymal duct was made. I saw the patient in the summer of 1896, and there was no recurrence.

CLASS VIII.—*Syphilis*.—Gummata frequently develop in the nasal walls of the antrum. I had recently under observation three cases of gumma of the internal wall of the antrum of Highmore. They did well under iodid of potassium and occasional scraping of the necrosed bone.

An illustrative case, Mrs. S., aged fifty, applied to me in 1894. She was suffering from such severe pains in the left side of her head that she had only slept a few minutes at a time for several nights and days. I removed a degenerated gummatus internal wall of the antrum; found the cavity extensively diseased and full of putrid secretion and tissue-débris. Besides local measures I gave her iodid of potassium; controlled the pain for a few days with morphia. She improved rapidly, and in two months was apparently well.

#### DISEASES OF THE ETHMOIDAL CELLS.

The large number of the ethmoidal cells and the peculiar latency of their affections make it difficult to determine the extent of their pathological conditions and to adopt a successful line of treatment. These cells, in my experience, are oftener diseased than any of the other cavities. Polypoid degeneration is their most frequent affection. The bacteria of grippe and influenza invade these cavities and produce alarming and distressing symptoms. In the young suppurative rhinitis nearly always terminates in atrophic rhinitis, and is a frequent cause of chronic ethmoidal empyema.

**Etiology.**—Woakes and Thudicum have probably done more than any others to inaugurate active methods of treatment of these cavities. The mucosa of the ethmoid bone seems to have a peculiar proneness to watery infiltration, which if not relieved will terminate in a polypoid state. This condition seems to affect all of the tissues, including the periosteum and the bone, and it ultimately renders the bones soft and brittle. Occasionally the septum, or an exostotic or eochondrotic growth protruding therefrom, so presses into the ethmoid or middle turbinated body as to close the natural openings, and degeneration takes place as a consequence. In a few cases inflammatory and necrotic processes extend from the antrum to the ethmoid. In others the process extends from the frontal sinus. Cysts occasionally form in one of the cells and extend backward and forward, breaking down the intercellular walls, and finally make their appearance above the inner canthus of the eye, where the bone is probably thinnest.

Again, acute catarrhal inflammation of the Schneiderian membrane is frequently attended by an edema which continues so long that it obstructs the respective openings of the cells for several days. This causes putrefaction of the retained secretions; they in turn irritate or destroy the mucous lining of the cells; and pus either discharges through the normal outlet or forces its way by pressing through it (?) or through an artificial opening. If the pressure has been sufficient to produce necrosis, and if the drainage has not been free, we have as a result chronic thickening with pus-production, or watery edema or polypoid changes. Syphilis at times will form gummatus tumors, which in breaking down present the appearances of polypoid degeneration. Osteomata and malignant tumors in this region are occasionally the cause of considerable pain and a discharge of broken-down tissue-products.

**Symptoms.**—The most common symptoms of ethmoid disease are muco-purulent discharges through the rhino-pharynx and through the anterior nares, with dull and deep-seated pain around the orbit, frontal region, or in the temporal and occipital regions. In chronic cases the pain is largely dependent upon the retention of the secretions and the amount of periosteal disease. The chronic cases with free drainage usually complain of muco-pus in the pharynx, larynx, and bronchi. Acute cases with stenosis complain of profound oppressive pain and fulness throughout the post-orbital, frontal, and temporal regions, and usually show some mental dulness—the patients complaining of a disinclination to mental activity. In cases of mucocele the symptoms are often very obscure. The pain in the ethmoid region and behind the eye is rather constant and severe; and the nasal walls of the ethmoid rarely bulge or protrude sufficiently to awaken our suspicions, although ultimately the orbital plate, just above the inner canthus of the eye, gives away and protrudes.

**Diagnosis.**—In cases of acute inflammation and stenosis of the ethmoidal cells the diagnosis is extremely difficult, save when it is inferred from the intense subjective symptoms. The subjective symptoms are usually those of acute and infectious rhinitis; rarely, indeed, do we have sufficient evidence to warrant us in penetrating into one of these cells when a condition of acute empyema exists. Frequently in cases of grippe the patient implores the physician to cut into the cells to relieve the distressing and almost unbearable symptoms of pressure. In chronic cases with discharge the diagnosis is not difficult; but in cases where abnormal conditions obstruct the view there is some difficulty in distinguishing between empyema of the anterior ethmoidal cells, of the frontal sinus, and of the antrum of Highmore. In those cases where the muco-purulent discharge flows from the septal side of the bulla ethmoidalis, the evidence that there is empyema of the anterior ethmoidal cells cannot be disputed. Pus in the superior meatus can mean only one of three things—posterior ethmoidal, or sphenoidal trouble, or subperiosteal bone-disease. Pus issuing from the posterior ethmoidal cells must pass over the posterior end of the middle turbinal body; and when the source is the sphenoidal cell it usually passes behind the tip and over the posterior upper border of the choana. Occasionally sneezing or forced blowing of the nostril forces muco-pus into the upper chambers. In such cases wiping the mucus away and awaiting its reappearance will decide. The posterior rhinoscopic mirror is most valuable in demonstrating muco-purulent secretions in the superior meatus. The degree to which the pathological state has extended can be determined by the objective appearances, especially by the character of the pus, muco-pus, and the edematous, polypoid, and sclerosed states. I have been able to confirm my suspicions on many occasions when the irrigation-tube had been passed into the natural opening. The probe will convey an idea of the diseased state of the membrane, but it is frequently deceptive concerning the bone. The periosteum and mucous membrane of these bones is very thin, and frequently the probe feels as if it was on bare or exposed bone when it is in a fairly normal state. This has led many of our best writers into controversy on the diagnosis of diseases of this region.

**Treatment.**—Although we have done much in the treatment of ethmoidal disease, many questions in regard to the best methods are yet to be settled. The ethmoid is really the home of nasal polypi; the majority of the serious cases are the cause or consequence of polypi, and are etiological features in the deeper degenerative changes of tissue and bone. All pedunculated polypi should be removed by the wire snare, and I have found the Bos-

worth snare by far the best for this purpose. In a few cases it is well to pull out the polypi after the wire has been well tightened around the pedicle; on the other hand, it is sometimes better to cut through the pedicle and afterward destroy the small polypi that grow around the base. The profound symptoms of pain, shock, and hemorrhage that follow tearing away great sections of the mucous membrane and bone by traction on the snare should contraindicate its indiscreet use. After the practise of these methods in my cases I have never observed the recurrence of polypi in the space of the pedicle; yet I have noticed little polypi growing around the parts, and that their growth continues, being favored by the absence of the larger ones; these should be removed by some excisor-forceps. I have found Jarvis's to be the best. In nearly all serious ethmoidal cases the question of removing a part or all of the middle turbinal body should be carefully considered, and as it is necessary in most cases, it is well to decide this question early. I do not believe in the method of tearing this bone away with forceps, as advocated by some earlier writers, because the membranous tissues that pass through the cribriform plate

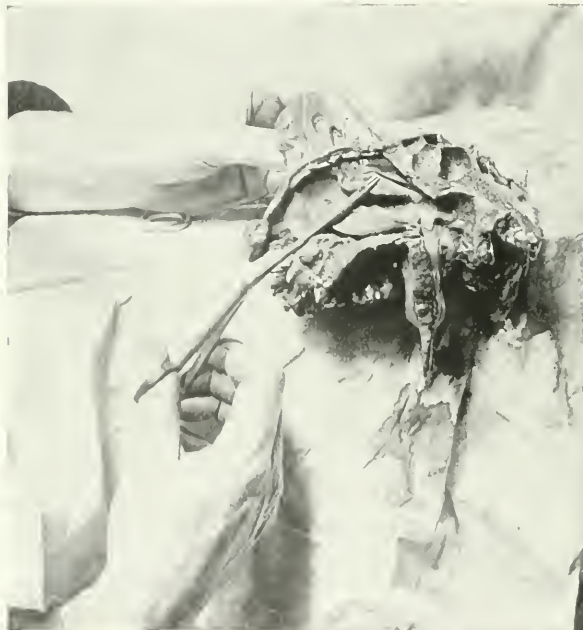

FIG. 591.—Dividing the middle turbinal before sawing off the posterior half to gain free access to the sphenoid sinus.

with the olfactory nerve, and extend downward over the middle turbinated bone, are quite tough, and sometimes they are torn loose from the bone up to the plate instead of breaking off where the middle turbinated body joins the ethmoidal bone. In my experience I have found the most feasible procedure to be that of making a section with nasal clippers or scissors through the middle of the bone. The Bosworth wire snare with small cannula will remove the anterior and posterior sections readily and effectively, with little disturbance to the membranes of the parts above. Deflected septa, narrow nostrils, and hemorrhage are the chief difficulties to be overcome. The floors of these cells can be penetrated with shoulder-protected drills and trephines with very little danger to the neighboring parts. The antero-posterior nasal

excisor-forceps, a cut of which I present, has been extremely valuable for enlarging these openings and for removing the floors of the cells. The patient rarely experiences disagreeable results, save in the cases where the cancellated parts of the ethmoid bone have been cut into. The small malleable curettes are extremely valuable in removing pus, polyps, and granulation-tissue. When the holes are large enough the cells usually drain so well that it is necessary to irrigate them at stated intervals only. When the process

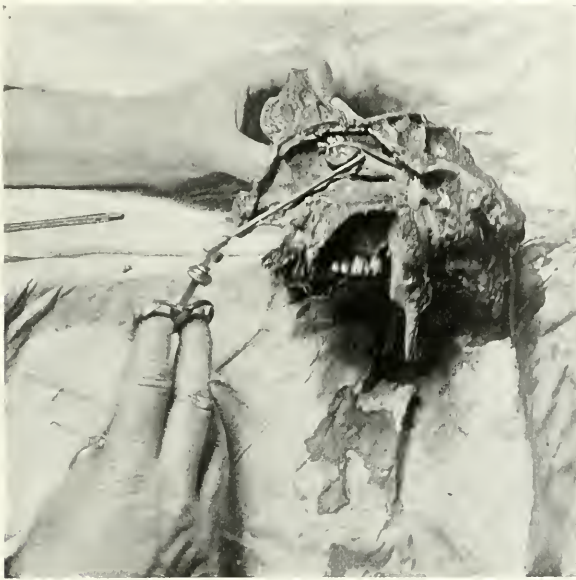

FIG. 592.—Bosworth's snare in position for making the section of the middle turbinal (author's specimen).

extends far up into the little cells above the orbital cavity, or in some of the recesses under the cranium, the results of treatment are not so satisfactory. I have found that it is advantageous to freely spray the nose two or three times a day with a preparation of liquid alboline 4 oz., carbolic acid, eucalyptol, and menthol,  $\bar{a}\bar{a}$  10 grains; this is usually very soothing and beneficial. In the suppurative cases I use the nasal douche, 1 quart of warm water, 1 teaspoonful of salt,  $\frac{1}{2}$  drachm of carbolic acid, applied by a fountain-syringe through the narrower nostril; with occasional insufflations of boric acid, aristol, and iodoform. Bosworth reports most remarkable results from drilling into these cavities with an ordinary burr and breaking down the intracellular walls; and I believe that he accomplishes this entirely by the sense of touch and appreciation of distances and directions from the anterior nares.

As to results, regarded from the standpoint of the subjective symptoms, about three-fourths of my ethmoidal cases are apparently well; but on inspecting them, in the majority of cases, a small quantity of pus and mucopus can be seen either in the nose or issuing from the natural or artificial openings. This increases in winter, and is very much diminished in the summer time.

#### DISEASES OF THE FRONTAL SINUSES.

The frontal sinuses develop about the age of puberty, and apparently are the extension of the ethmoid cells into the frontal bone. They are much



more frequently diseased than is generally suspected, and many supra-orbital headaches are due to trouble in these cavities. Improved methods of inspecting the region of the opening of the infundibulum and the use of silver irrigation-tubes have thrown a great deal of light upon their pathology, and have led to procedures that have indisputably relieved the morbid conditions.

**Etiology.**—Polypoid or myxomatous degeneration has been the cause of the diseased conditions in the majority of the cases that have come under my observation. Of nine frontal sinuses which I have opened externally, seven had polypi within the cavity and one had fronto-ethmoid necrosis. I have seen a great many cases with polypi in the region of the infundibulum, and evidently extending up into the frontal sinus, which were operated upon per nasi and carefully treated. These cases have improved under drainage, but did not seem to get entirely well. I have had one case of osteoma. I have seen a few cases of syphilitic invasion resulting in necrosis. Parasites sometimes invade this cavity, especially in the southern parts of the American continent, as by the screw-worm or larva of the *comptosmia masecllaria*, cases of which have been so well reported by Sir Morell Mackenzie.

**Symptoms.**—Pain above the eyes and through the frontal bone is the almost constant subjective symptom of frontal-sinus disease; this is frequently made worse by bending the head forward and downward. In cases of complete stenosis of the infundibulum the pain is very great, and the symptoms of oppression and suffering are profound. In the chronic cases, where the nose is not occluded by deflection or hypertrophy, mucus-pus can be seen at the very uppermost end of the lower lip of the hiatus semilunaris, rather anterior to the bulla ethmoidalis.

**Diagnosis.**—The diagnosis can frequently be inferred from the constant pain, tenderness, and discharge in the region of the middle meatus, but the only infallible test is the demonstration that pus really comes from the cavity. The silver irrigation-tube is by far the most valuable and reliable means of attaining this evidence; although I think that we are justified in operating when the subjective symptoms indicate frontal sinus trouble and when the objective conditions demonstrate that there is pus in the infundibulum and the anterior cells. Tenderness to deep pressure, dulness on percussion, and failure of transillumination (see Plate 14) furnish auxiliary evidence.

**Prognosis.**—The prognosis, as regards the relief of the pain and the excessive discharge, is very good indeed if we secure and maintain good drainage from the cavity; but in many cases life is jeopardized on account of the opposition on the part of the patient to an external operation.

**Treatment.**—In acute cases with complete stenosis of the infundibulum the region of the nasal opening of the infundibulum should be




FIG. 593.—Irrigation-tube.

thoroughly cocaineized and an attempt made to enter the infundibulum with a silver irrigation-tube—a cut of which is shown in Fig. 593. In several cases I have succeeded in dislodging the gas and pus and in equalizing the external and internal atmospheric pressure. It may not be necessary to enter the frontal sinus in all the cases, as the relief seems to be secured

after the manner of that produced by the Eustachian catheter in tympanic troubles. The following case illustrates a brilliant result obtained by this method.

The patient sent for me; I found him almost in a state of collapse and in great agony. He had been suffering for several days with intense pain, together with a full feeling in the right frontal sinus. I sprayed the nostril with cocain and applied it on cotton. The hiatus and infundibulum were very much swollen; the middle turbinal body was moderately so. I passed a tube into the infundibulum and injected gently but firmly a borated solution; a gush of pus and offensive gas followed, with immediate cessation of the severe symptoms. The muco-purulent discharge continued for a few weeks, but the patient recovered completely.

When relief of the retained pus cannot be secured through the nose, and when the subjective symptoms are profound, an external opening should be made without delay by making an incision extending from the center line of the forehead and on a level with and through the eyebrow, or above it, outward to within two millimeters of the supra-orbital notch. A small hole, 6 or 8 millimeters in diameter, should be chiselled through the bone (Fig. 544), the cavity carefully cleansed and inspected, and afterward a probe or bougie should be passed through the obstructed infundibulum into the nose. If deemed expedient, one of the silver retention-tubes can be kept in and the external wound closed. Subsequent irrigation can be easily carried out through the tube in the nose.

The two chief considerations in the treatment of the chronic cases are: First, the removal of the pathological tissues and their products. Second, the securing and maintenance of proper fronto-nasal drainage.

On account of the irregularity in the size of the frontal sinus and infundibulum, the procedure that would be successful in one case would not be so in another with the same pathological conditions. The selection of a place for making the incision and chiselling through the bone is a very important one, and the more I operate the more I am convinced that a small opening should be made just above the supra-orbital ridge, close to the median line; it should then be extended upward and outward for a sufficient distance to make an aperture about 8 to 10 millimeters in diameter. The direction of the chiselling will be determined by the position of the dividing wall of the sinuses. If none of the ridge is removed we have very little resulting depression; and the great advantage is secured of being able to trephine, chisel, and inspect the floor of the sinus, the infundibulum, and the anterior ethmoidal cells, through which, in my opinion, it is absolutely necessary to make a free drainway into the nose. In the other operation which I have performed quite frequently, and which seems best in cases where the wound is intended to be left open and packed for any length of time, it is very difficult to chisel, trephine, and properly enlarge the infundibulum through the hole in this below the supra-orbital ridge-space; although in a few cases I have removed the anterior wall down to the nasal process of the superior maxillary bone and succeeded in making a partially satisfactory and permanent opening into the nose (Fig. 594). Lue has evidently grasped the most practical idea that has yet been presented—that is, to close the external wound at once after having made a large opening through the fronto-nasal canal and inserted a large silver drainage-tube. The after-treatment of these cases consists of irrigating the cavity through the tube for three or four weeks, and then until the discharges cease, continuing the irrigation through the patulous canal which had been created by the tube.

In seven cases with severe and prolonged disease of the frontal sinus I opened nine of the sinuses. One of the sinuses was obliterated by packing

for nine months, but there was a resulting depression. The patient is entirely relieved of the original symptoms. In one of the polypoid cases the frontal sinus was opened by the infra-orbital-ridge method, packed and everted; the necrosed bone was scraped, and this cicatrized over. The patient made a complete recovery, and the sinus has been well since the closure of the external wound. In another case of fronto-ethmoidal abscess the anterior wall of the ethmoidal cells was drilled and chiselled away: almost all of the nasal process of the superior maxillary was removed, the

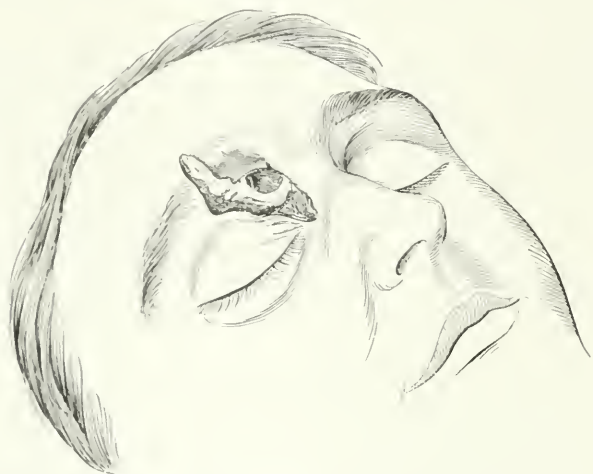

FIG. 594.—Operation beneath the supra-orbital ridge, before upper section has been stitched: intended for external drainage (author's specimen).

cavity was scraped, irrigated, and drained with a tube, and the sinus seems to have been in good condition ever since. Some of the cases were troubled with acute swelling and retention, and the scar-tissue was re-incised with immediate relief. Three of the cases operated upon by the same method remained in apparently good condition up to six months or one year; but in each one of them, on two or three occasions, extreme pain occurred, with swelling in the sinus; the infundibulum seemed to be closed, this being the result of acute cold. Silver tubes were introduced through the infundibuli and the accumulation of degenerating mucus and pus dislodged. The patients improved at once, and subsequent irrigation brought away only clear fluid. At times these patients discharge a mucus from these cavities, which seems to be of a catarrhal and transitory nature.

#### DISEASES OF THE SPHENOIDAL CELLS.

**Etiology.**—Acute inflammations of the sphenoidal cells accompany or are consequent upon acute rhinitis, especially in cases due to infection. Polypi are frequently the cause of chronic disease within the cell. Syphilis commonly affects the cell-wall with a gummatous deposit. Ethmoidal mucocele will occasionally break through the dividing wall. Tumors occasionally develop in or extend into the cavities.

**Symptoms.**—The subjective symptoms of acute inflammations of the sphenoidal sinuses are headache and a full, heavy feeling over and behind the eyes. In the cases of chronic suppuration, the subjective symptoms are deep-seated pains in the orbital, temporal, and occipital regions, feelings of depres-

sion and oppression, discharge of pus or muco-pus over the anterior surface of the sphenoidal cell at the posterior extremity of the middle turbinal body, and disturbances of the field of vision. The objective symptoms are hyperplastic edema of the nasal mucosa covering the cell, discharge of pus, muco-pus, polypi, and pharyngitis sicca, due to destruction of the epithelium by the pus, which flows constantly over the post-pharyngeal wall.

**Pathology.**—The osseous modification and changes in the vitality of the bone occur in those sphenoidal cases in which the mucosa has undergone polypoid degeneration, the bone becoming brittle and losing much of its cohesive quality. In neglected syphilitic cases, necrosis of the bone or soft tissues always follows the gummatous process. The chronic suppurative cases with stenosis of the normal opening are usually protracted by the irritating qualities of the degenerating products.

**Diagnosis.**—The diagnosis is comparatively easy in those cases where the nasal fosse are not seriously obstructed by septum deflections and the throat is tolerant enough to permit posterior rhinoscopy. The obstruction in many cases is the posterior end of the middle turbinal body; its early removal will facilitate matters greatly. Under favorable conditions the pus can be seen flowing from the normal opening, which is situated above the superior turbinal body in the uppermost part of the anterior sphenoidal wall. An irrigation-tube passed through the opening will confirm the provisional diagnosis.

**Prognosis.**—Since surgeons have adopted the method of making a large opening of 8 to 10 millimeters in diameter into this sinus, the prognosis is much more favorable.

**Treatment of Chronic Empyema.**—The treatment of chronic empyema is essentially surgical. Much annoyance and delay in the favorable progress of these cases will be avoided by removing the posterior half of the middle turbinal body as a first step in the operation, as it almost always lies in the direct line of the operative field. In my experience the most simple and satisfactory procedure for the removal of the middle turbinal body is carried out by cutting into its middle section with the nasal clippers (Fig. 592), placing the wire of the Bosworth snare in the cut and over the posterior end, and by firm traction removing the whole posterior half. In

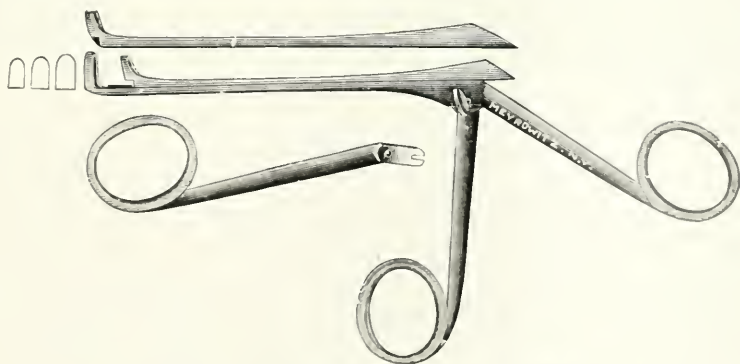


FIG. 595.—Rongeur for opening sphenoid sinuses, etc

certain cases a long and rather small silver probe can be passed through the normal opening of the sinus, and this can be followed with some form of gouge or curette. Usually it is best to enter the sinus about  $\frac{1}{4}$  to  $\frac{1}{2}$  inch



below the normal opening, and about 3 or 4 millimeters externally to the septum. The wall is usually thin at this spot, and the only objection is the probability of wounding the naso-palatine nerve and the sphenopalatine artery, which traverse the bone near this region. After the opening has been made, it is well to pass in one of the smallest size antero-posterior nasal clippers (Fig. 595), and cut out the wall upward and laterally; the instrument cuts after the manner of a rongeur forceps. When the blood is wiped away the sinus can be easily observed and the pathological state rather definitely determined. In my experience polyps have been found in the majority of the cases. It is well to curette them away very gently and carefully, for any tearing of the upper walls might bring on intracranial trouble. I have noticed diseased conditions rapidly improve under simple drainage and careful attention. The tendency of all these openings, even when large enough to admit the little finger, is to close, and it is very remarkable with what rapidity they become occluded. They then require a second excision of the contracting membrane. The syphilitic have given me more trouble than the polypoid cases, because of extension of the necrosis into the body of the sphenoid bone. Tumors occur sometimes in the sphenoid; but they usually originate in the fibrous tissues of the rhino-pharynx or in sarcomatous degenerations of the ethmoid, and extend through the wall into the cell. Certain types of infectious or septic rhinitis invade this cavity and produce a diseased state of the mucosa, which in turn generates a putrid product, and this product acts as a perpetual nidus for new re-infecting material. Proper opening of the sinus and curettage, followed by antiseptic irrigation, usually cures the case or affords decided relief.

**Sphenoidal Cases.**—In two of my sphenoidal cases the symptoms were so severe that death was anticipated. The anterior walls were punctured, and after breaking through with a gouge the antero-posterior clippers were used to enlarge the opening. The cavities were curetted, and the patients improved at once and steadily. These openings gradually closed, and at the end of six or eight months had to be re-excised; this brought about immediate relief from the severe symptoms which had returned. I noticed in the latter cutting of the bone that it had become much harder than it was originally. One syphilitic case, which is under observation at the present time, is apparently well in a subjective sense, save for a certain amount of post-nasal catarrh; and I can detect dead bone, which extends from the rostrum of the vomer into the sphenoid. I have been gradually removing this necrosed bone at intervals with a drill which excavates laterally.

# ACUTE AFFECTIONS OF THE LARYNX AND TRACHEA.

By WILLIAM E. HOPKINS, M. D.,

OF SAN FRANCISCO, CAL.

## ACUTE CATARRHAL LARYNGITIS.

GUERSANT first clearly described the simple form of this disease. The disease-process consists of a very mild non-dangerous inflammation of the mucous membrane of the larynx, not absolutely confined to any age, but usually occurring in adults, and may run on to a chronic condition.

**Etiology.**—It may be primary or secondary, idiopathic or the result of some direct and known irritation. Its principal causation is the process known as "catching cold," grafted upon an already slight and possibly chronic hyperemia or congestion of the lining membrane of the larynx. Occurring primarily in the larynx, this disease is extremely rare. Indeed, Bosworth considers it as invariably secondary to an inflammation in some other portion of the upper respiratory tract. The irritation caused by inhaling air not properly warmed and moistened or filled with particles of dust; irritating vapors, such as chlorin, bromin, sulphur, ammonia, tobacco-smoke, etc., predispose to chronic change; and the stimulus of cold produces the acute condition. In early life, frequent attacks of tonsillitis, pharyngitis, and the hypertrophy of the pharyngeal tonsil predispose to attacks of this disease; while in later life some chronic process in the nose or naso-pharynx is frequently found. On account of the greater exposure, it occurs most frequently in men.

**Pathology.**—The changes in this disease are entirely similar to those occurring in acute catarrhal inflammations of all mucous membranes. There is at first dilatation with engorgement of the blood-vessels and arrest of secretion from the muciparous glands; later there follows a serous and mucous hypersecretion. The greatest swelling is found where the membrane is most lax—at the arytenoid commissure and subglottic region.

**Symptoms.**—Changes in the voice are chiefly noted. It may be hoarse, dulled, or entirely lost; phonation may be slightly painful and labored; there may be slight dryness, roughness, or tenderness of the throat, accompanied by a tickling sensation. The cough, when present, is dry, harsh, and painful. Except in young children there is rarely any interference with respiration.

**Diagnosis.**—Changes in the voice and the metallic cough will indicate the seat of disease. The laryngoscope will reveal in mild cases the enlarged blood-vessels scattered over the mucous membrane, and especially noticeable on the cords, commissure, and ventricular bands; in severe cases the membrane may be pink or deep red in color, and there may be small localized hemorrhages. When swelling is noticeable the function of the cords may be interfered with, resulting in aphonia. Infiltration of the muscles inter-

feres with proper adduction. The rise in temperature is very slight, rarely exceeding 100° F.

The disease runs a course lasting from five to ten days and ends in resolution. It is of importance chiefly to singers and public speakers.

**Treatment.**—The whole upper air-tract should be considered in treating this disease. In the early stages direct local applications should, perhaps, be avoided. The inhalation of steam, medicated with the oil of pine, compound tincture of benzoin or the oil of eucalyptus, with the wet pack locally, should be sufficient. The use of oil-sprays is of unquestioned service. Later in the disease we may try the direct application of astringents, such as nitrate of silver (1 to 2 per cent. solutions), menthol, or some preparation of tannin or iron. To relieve the cough a mild dose of codein may be prescribed. The exhibition of large doses of the muriate of ammonia (30 to 40 grains) will, at times, very rapidly control the disease.

#### ACUTE CATARRHAL LARYNGITIS IN CHILDREN.

It has been found that in childhood the mucous membrane of the larynx possesses a greater number of vessels and lymphatics than later in life, and that the tissues are less resistant and more relaxed. In consequence, there are some differences, from a clinical point of view, in the disease as occurring in childhood. When the disease develops in early life, certain characteristic features are noticeable in relation to the anatomical region attacked. According as the mucous membrane in the region above or below the vocal cords is the seat of the disease, it naturally follows that we may divide the disease for clinical study into supraglottic and subglottic laryngitis. We may meet either of these conditions up to about fourteen years, although a very large percentage of the cases will be encountered before the fourth year.

**Acute Supraglottic Laryngitis.**—This runs a course very similar to that of the simple catarrhal laryngitis of adults, and may be considered as identical with it. There is, indeed, somewhat greater tenderness over the upper part of the larynx, and in very rare cases there may be very slight dyspnea. There is the usual morbid predisposing cause to be found in the naso-pharyngeal region, and the common exciting cause of exposure and "taking cold." Its course is short, rarely lasting more than ten days. It is very mild in character and resolves naturally. It may be necessary to differentiate it from a slight croupous laryngitis. This may be done by observing the suddenness of the onset of the latter disease and its steadily progressive course.

**Subglottic Laryngitis; False Croup; Millar's Asthma; Laryngitis Stridulosa.**—The entire surface of the larynx is more or less involved in this form of inflammation, but the intensity of the process is much greater in the tissues below the vocal cords. The mucous and submucous connective tissue becomes infiltrated and swollen, leading to more or less dyspnea.

**Etiology.**—There seems to be a constitutional tendency to this disease. Heredity seems to be associated with it. Several children in the same family or families closely related will suffer from repeated attacks. Strumous children are predisposed to it, and those with an abnormally large and active lymphatic system. Gerhardt insists that the chief predisposing cause will be found above, in enlarged tonsils or other obstructions in the air-passages. While this may undoubtedly influence any disease of the larynx, no close causative connection can be found associated with this particular form of

laryngitis. The exciting cause is practically the same as in the previous class.

According to Sappey (*Anatomic Descriptive*, 1868, vol. ii. p. 869), the very abundant lymphatic supply found in this region in children explains the marked and at times extreme swelling found in the acute stage of the disease. The pathological condition is more or less stenosis from the crowding forward of the congested and inflamed mucous membrane by the engorged lymphatics.

**Symptoms.**—There will be some prodromal symptoms sufficiently severe to indicate marked systemic disturbance—the general feeling of malaise, severe or slight headache, the accelerated action of the heart, and the temperature increased to 100° or 101° F. The voice, at first hoarse, rapidly becomes shrill and metallic, and phonation may be very painful. A croupy cough sets in early, and is of a harsh, dry, barking nature. Even after phonation is entirely suspended this cough retains its characteristic sound, proving quite conclusively that it is produced by the dry, swollen tissues below the cords. This process is similar to inflammations of other mucous membranes, and after a period of variable length, usually two or three days, the mucous secretion is resumed, the cough becomes softer and less irritating, and there is some little frothy expectoration. During the day the symptoms are invariably less severe, while at night exacerbations occur that have a seemingly alarming import. The child, somewhat relieved by the restful day, falls into a calm and easy sleep. This may continue several hours, when he suddenly awakens in a violent and agonizing struggle for breath. The face is flushed, the lips purple, the nails blue, and every muscle tense and contracted—all of the characteristic symptoms of marked dyspnea. These serious symptoms may continue for half an hour or longer; finally the child succeeds in coughing up a quantity of inspissated mucus and the attack subsides. A period of relief and rest will follow for a few hours, when the child again wakens in a similar paroxysm. These exacerbations occur only at night and separated by periods of complete remission of dyspnea. Usually there will be from four to eight of these violent seizures during the progress of the disease. The question of muscular spasm is a mooted point. That true spasm of the laryngeal muscles is a prominent factor in these seizures is asserted by Rilliet and Berthez,<sup>1</sup> D'Espine and Picot,<sup>2</sup> J. Lewis Smith,<sup>3</sup> and Gottstein;<sup>4</sup> while Bosworth,<sup>5</sup> Rauchfuss,<sup>6</sup> and Dehio claim that muscular spasm plays no important part, and if it occur is purely incidental. Probably the principal cause is the swelling, which is greatly increased by the presence of the dried mucus acting as an irritant foreign body; it is also probable that the same irritation produces a certain amount of spasm of the laryngeal muscles.

There is a persistence of more or less difficulty of breathing throughout the attack, but only at night do the paroxysms become sufficiently severe to occasion distress. During the remissions a slight inspiratory murmur, higher in pitch, will be heard. On succeeding nights the paroxysm will recur at about the same hour as the first, although, as a rule, with diminished severity.

**Diagnosis.**—Though difficult and often impossible, an effort should be made to examine the parts with the laryngoscopic mirror. When a view is secured the mucous membrane appears inflamed and engorged, while protruding between the vocal cords will be seen the rounded swollen masses of the subglottic tissues. These are of a deeper red than the cords and the tissues above. Differentiation must be made between this condition and mem-

<sup>1</sup> *Maladies des Enfants*, 1853, p. 351.

<sup>2</sup> *Maladies de l'Enfance*, 1884, p. 612.

<sup>3</sup> *Diseases of Children*, Phila., 1890, p. 646.

<sup>4</sup> *Die Krank. des Kehlkopfes*, 1892, p. 80.

<sup>5</sup> *Nose and Throat*, p. 504.

<sup>6</sup> *Handbueh der Kinder-Krankheiten*, 1878, p. 116.



branous croup, diphtheria, foreign bodies, and perichondritis. In both membranous croup and diphtheria there is much greater systemic disturbance; the temperature ranges higher, the cough is less marked and not so severe, the disease is progressive, and is not characterized by nocturnal exacerbations with almost complete remissions; also the false membrane can generally be seen *in situ* or attached to surrounding tissues. A foreign body may give rise to many of the symptoms of acute subglottic laryngitis; but the history, together with an examination by means of either the mirror or the index finger, will generally clear up the diagnosis. Perichondritis of the cricoid cartilage is more difficult to exclude; but with the aid of the laryngoscope the irregular nodulated swellings, generally unilateral, can be seen and easily recognized.

The disease runs a course of from six to twelve days, and, as a rule, is not dangerous, a fatal termination being very rare.

**Treatment.**—The general health of the patient should be considered. The strumous, lymphatic child, subject to attacks of croup, should be toned up with syrup of the iodid of iron and cod-liver oil. The passages above should be looked after with care and relieved if found in an unhealthy condition. During an attack the child should be confined in a warm and moisture-saturated atmosphere; the bowels should be acted on by repeated small doses of calomel; while internally the ammonias and small doses of an opiate should be administered to stimulate the secretion of mucus and to allay the irritating and exhausting cough. During the acute paroxysms at night every effort should be made to soften and expel the dried mucus and to moisten and soothe the dry, irritable, and inflamed mucous membrane. With this end in view we may use a hot bath, steam-inhalations, or hot fomentations, and these failing, excite free emesis by tickling the fauces with the finger or a brush, or by administering an emetic, such as ipecac. If the attack is extremely severe or there is dangerous dyspnea, inhalations of ether or amyl nitrite may be given, the O'Dwyer tube introduced, or the trachea may be opened.

#### ACUTE PHLEGMONOUS OR EDEMATOUS LARYNGITIS.

Much confusion in classification is encountered in the literature of this disease. Cohen<sup>1</sup> describes edema and acute, chronic, infraglottic, and hemorrhagic edematous laryngitis; while the different forms of the disease are divided by Mackenzie<sup>2</sup> into typical, contiguous, and consecutive edematous laryngitis. Ziemssen<sup>3</sup> recognizes only one form, laryngitis phlegmonosa; while Gottstein<sup>4</sup> and Schrötter<sup>5</sup> describe acute and chronic submucous laryngitis and acute and chronic edematous laryngitis. Browne<sup>6</sup> acknowledges only acute and chronic inflammation of the submucous tissues.

The presence or absence of high temperature and other acute inflammatory symptoms renders this disease clearly divisible into two general forms—acute phlegmonous laryngitis and simple edematous laryngitis. The occurrence of either form is rare, the latter especially so.

**Acute Phlegmonous Laryngitis.**—This is an acute inflammation of the laryngeal mucous membrane, to which is added edema due to serous effusion. The edema here follows the characteristic course of inflammatory

<sup>1</sup> *Diseases of the Throat and Nasal Passages*, 2d. Ed., 1879.

<sup>2</sup> *Diseases of the Throat and Nose*, American Ed., vol. i. p. 277.

<sup>3</sup> *Cyclopædia of Medicine*, American Ed., vol. vii. p. 791.

<sup>4</sup> *Die Krankheiten des Kehlkopfes*, 1888.      <sup>5</sup> *Vorlesungen über den Krankh. de. Kehlk.*, 1887.

<sup>6</sup> *The Throat and Nose and their Diseases*, 3d. Ed., 1890.

edema in other tissues and exhibits the different stages of serous, sero-purulent, and purulent edema.

**Etiology.**—In addition to cold, the usually assigned cause, there is undoubtedly exposure to some septic infection. Such an authority as Mackenzie states that he never encountered a case except of septic origin. Virehow considers it a true erysipelas of the larynx. It is indeed usually found among hospital physicians and nurses, undoubtedly the most exposed class of people. It is very rare as a primary condition, being found generally secondary to quinsy, abscess of the neck, follicular pharyngitis, and tonsillitis, or complicating an attack of typhoid, typhus, variola, or diphtheria. It may develop at any age, but is usually found between twenty and forty.

The same morbid changes are found as in inflammatory edema of mucous membranes elsewhere. There is first vascular engorgement followed by serous effusion, the swelling being most marked where the membrane is most relaxed—that is, in the aryepiglottic folds, ventricular bands, and the epiglottis posteriorly. At first serous, the effusion gradually becomes purulent.

**Symptoms.**—A slight chill accompanied by a corresponding rise of temperature is rapidly followed by decided impairment or loss of voice, with dyspnea and stridulous breathing. The condition is progressive, the dyspnea developing within twelve hours, growing steadily worse for twenty-four to thirty-six hours, when it reaches its maximum. There is pain and soreness on pressure or swallowing, and cough is not often present.

**Diagnosis.**—This disease can only be confounded with the presence of a foreign body or an attack of simple edema. The history of the case and the use of the mirror should prevent mistakes. You will see the red, tense, and glossy membrane with three rounded swollen masses of tissue above the small triangular opening of the glottis.

**Prognosis.**—This is a disease of rapid development. It runs a short course of four or five days, the extent and severity of the symptoms varying largely. If at the end of thirty-six hours the dyspnea has not become dangerous, the case will spontaneously resolve. Until this time, however, it should be closely watched, as symptoms sufficiently alarming to demand surgical interference may occur at any moment.

**Treatment** is at first the use of the ice-bag or Leiter coil to the larynx, with local depletion (leeches) externally, and free and frequent scarification of the swollen, inflamed mucous membrane within. The atmosphere should be warm and saturated with moisture, and only such drugs as will stimulate secretion should be administered. When serious symptoms develop so suddenly as to prevent tracheotomy, the introduction of a small laryngeal catheter is advised by Macewen.

### EDEMA OF THE LARYNX.

Under this name is considered that morbid condition which presents a simple edema of the mucous membrane of the larynx, without inflammation, and which is certainly secondary to a more serious general condition.

**Etiology.**—Some morbid change in the kidneys, heart, or liver, an obstruction to the return circulation in the neck, a vaso-motor paresis, or any general or local condition which tends to produce dropsical effusion may be the cause of this disease. There is an escape of normal healthy serum into the submucous tissues, producing general swelling of the parts and

noticeable tumefaction in the relaxed portions of the mucous membrane, the aryepiglottic folds on each side, and the epiglottis in front and above.

**Symptoms.**—The onset is sudden. There will be loss of voice, with great difficulty in breathing, inspiration being more difficult than expiration. There is little pain, soreness, or cough.

The **diagnosis** is easily made by the history of the case and laryngoscopic examination.

The **prognosis** is always grave. Death from the laryngeal stenosis is liable to occur and very quickly; but even should this be controlled, the general condition is almost invariably of an organic nature and incurable.

**Treatment.**—Efforts should be made to control, at least temporarily, the systemic cause. Free diaphoresis or catharsis is indicated, while local puncturing of the swollen tissues freely should be frequently done. This not availing, resort should be had to tracheotomy.

### CROUPOUS LARYNGITIS.

**Synonyms.**—Croup; Membranous laryngitis.

It would hardly prove profitable to enter into the active discussion that has been carried on for many years past regarding the unity or duality of croup and diphtheria. Perhaps the weight of modern evidence tends to the belief that croupous laryngitis is a local affection with some general disturbance; while diphtheria is a general systemic disease with local expression. It is not yet demonstrated, but largely a matter of opinion gained from personal observation and experience. The literature on the subject is most confusing. Statistics in general are not to be depended on, and even mortality statistics are unreliable owing to frequently varying opinion. While there are many points of similarity, there are also enough elements of distinction to warrant the consideration of croupous laryngitis as a disease distinct from diphtheria.

**Etiology.**—That there is at least some similar or analogous causative element in this disease to diphtheria cannot be denied. In diphtheria proper its distinctive germ can generally be detected; while although the germ of non-diphtheritic croup has not yet been separated, the possibility and probability of its future discovery had not been abandoned. It is likely that a germ finds lodgement in the pharynx, tonsils, or larynx, which excites an inflammatory process with certain well-marked and peculiar characteristics. The disease may commence above in the pharynx or fauces, progress downward, and attack the laryngeal mucous membrane secondarily. It is selective, and age and susceptibility play important parts. True croupous laryngitis is practically unknown in adult life, while it is most common between the ages of one and nine years, rapidly diminishing in frequency from this time on.

**Pathology.**—The membrane consists essentially of two layers—a superficial, consisting of the epithelium that has proliferated and undergone mucoid degeneration, and a deeper, composed of fibrinous strata, with numerous leucocytes scattered throughout its layers.

**Symptoms.**—At first there is generally slight catarrh, with some rise of temperature and a general feeling of languor; there may or may not have been a chill. Loss of appetite and persistent thirst accompany painful deglutition. The pulse is full and the skin hot and dry. After a few hours there is slight hoarseness, and later a short, dry, shrill cough; the voice becomes more impaired and assumes a whispering character. Then interfer-

ence with respiration appears and there is some laryngeal stridor. The mucous membrane is bright red, and may show some patches of false membrane. These symptoms usually occupy the first twenty-four to forty-eight hours of the disease and are followed by attacks of dyspnea. The voice is lost, the face is red and anxious, there is a hoarse, stifled cough, with little or no expectoration. The attacks at first last but a few moments and subside, although the stridor remains. The pulse increases in rapidity and is irregular. The attacks of dyspnea become more and more frequent until they are practically constant, with no remissions and occasional aggravation of the symptoms. From time to time pieces of the membrane are coughed up. The struggle for breath becomes each moment more painful and exhausting, and finally death supervenes from suffocation.

**Diagnosis.**—True croup must be differentiated from acute catarrhal laryngitis of severe form and from diphtheria. In the former there is absence of the membrane, frequent cough, the attacks come on only at night, and there are absolute and prolonged periods of rest with complete absence of dyspnea.

For the differentiation from diphtheria, see the article on that disease.

**Prognosis.**—This is a most serious disease; death may occur at any time from dyspnea.

**Treatment.**—This should be both local and constitutional. Internally the preparations of mercury should be administered. They can be given in frequent and increased doses. The salts of iron, notably the tincture, are most valuable. Locally ice may be used in the form of the pack, and small lumps may be swallowed. Sprays of lactic acid and persulphate of iron are also valuable. The chief danger to be guarded against is suffocation; so everything should be in readiness for the performance of intubation or tracheotomy, and interference when demanded should not be delayed. An expert in both operations will generally select the former procedure as being simpler, more rapid and less dangerous in itself, knowing that should intubation fail, the trachea can then be opened.

### DIPHTHERIA.<sup>1</sup>

This is an acute infectious disease having local manifestations in the upper air-passages.

It has been known and studied from the earliest times, but no absolute evidence as to its causation was produced until 1868, when Oertel made the announcement of the presence of a micrococcus in the exudate that is characteristic of this disease alone. This view was confirmed by many other investigators, notably Recklinghausen, Prudden, and Wood and Formad, who carried on many elaborate culture-experiments; but until the announcement by Klebs and Löffler of the definite microscopic characters of the bacillus which is peculiar to this morbid process, the discussion was not set at rest.

**Etiology.**—A diphtheritic attack is undoubtedly precipitated by a deposit of the Klebs-Löffler bacillus upon the faucial or laryngeal mucosa. There, finding a favorable culture-medium, it sets up its peculiar inflammatory process; and as the result of the life-functions of the bacilli there is generated a ptomain that, absorbed by the capillaries, enters the general circulation and produces the constitutional symptoms. This theory, first advanced by Cheyne, was subsequently confirmed by Brieger and Fränkel, who injected in rabbits the filtrate of the diphtheritic membrane, entirely

<sup>1</sup> See page 1010. The different standpoints of the two writers seem to justify duplication.



separated from the bacilli, and reproduced the general disease, but without the local laryngeal manifestations.

A very large majority of cases occur in childhood, and at least seventy-five per cent. prior to the age of ten years. Cold and damp climates and the periods of the year when these conditions prevail undoubtedly predispose to the disease. All catarrhal processes, enlarged tonsils, the presence of adenoid growths or diseased nasal fosse render one more liable to the infection. Absence of sanitary surroundings is an important element, the disease having undoubtedly a filth-origin and the bacillus thriving best in the neighborhood of sewers, street-cuttings, turned earth, and locations shut off from sunlight. Diphtheria is both contagious and infectious; it may attack individuals, it may develop only in a limited community from some special local origin, or it may be epidemic and spread over a very wide area; but wherever and whenever it makes its appearance, it is without doubt due to the presence of its own specific organism.

It may be carried in clothes, in letters, or in the furnishings of railway-carriages; while drinking-water and milk are favorable transportation-mediums. It is a disease common to the lower animals, and a pet animal will often convey it to its owner. There is no question as to the vitality of this germ, but its activity must be somewhat restricted. It will be found redeveloping in hospital-wards years after their abandonment and thorough disinfection; but the area of its activity must be limited when you realize that all cities and large towns are the best breeding-places for the bacillus, and yet the number of cases occurring each year represents but about one to every thousand of population. The danger of breath-transmission is small, the secretions retaining the bacilli; yet small particles may be thrown out by coughing or sneezing, and these deposited on some mucous surface will serve to propagate the disease.

**Pathology.**—The bacillus, finding lodgement on the mucous membrane, reproduces itself with great rapidity. It forces its way into and through the epithelial layers into the mucosa, causing inflammation of that membrane. There is dilatation of the blood-vessels, exudation of serum, and escape of the leucocytes. The epithelial cells proliferate, and uniting with the fibrin, which coagulates on exposure to the air, form the false membrane. Thus will be seen a pathological process identical with croupous inflammation, except for the presence of a specific organism (Bosworth). The inflammatory process is so energetic, the fibrinous bands contract so rapidly, that necrosis of the false membrane, as well as of the superficial layers of the true mucosa, will take place, and sloughs will form and be thrown off, leaving the raw and bleeding surface exposed. The membrane quickly re-forms on these spaces or resolution takes place. In mild cases the false membrane is very thin and superficial and penetrates to very little depth; while in malignant cases the entire mucous membrane may be infiltrated. As a rule, the exudate first appears on the tonsils or faucial arch. It may extend into the nasal spaces but, as a rule, it passes downward, involving the pharynx, larynx, trachea, and even extending into the bronchi. When in the lower air-passages, the false membrane assumes more the croupous form, penetrating but slightly into the mucous tissue. Some of the organs show slight changes; the kidneys and liver may be somewhat enlarged and minute hemorrhages may be found; while in the brain and spinal cord minute extravasations of blood are found scattered throughout their tissue.

**Symptoms.**—In direct contagion the period of incubation is very short, not more than thirty-six hours; where the infection is conveyed, it may be

much longer, varying from three to ten days. Experimental inoculation may develop the disease in twelve hours. In a typical attack of the disease you will have the false membrane not only involving the tonsils and fauces, but penetrating the larynx, and in addition the serious constitutional disturbance caused by the toxic absorption. There may be the general prodromal symptoms of malaise, restlessness, and loss of appetite. Sometimes there is vomiting and great nervous excitement, even convulsions. The direct onset of the disease is marked by a chill or chilly sensation, followed by mild febrile disturbance, dry, flushed skin, headache, and scanty, highly colored urine. The mental processes are unusually dulled, and the patient often lies in a half-stupid condition. The febrile reaction is not severe, the temperature rarely rising above 102° F. The heart's action is weak and rapid. Accompanying these symptoms there will be dryness of the throat, some pain and difficulty in swallowing, and soreness and tenderness in the tissues of the neck. At the end of twelve hours, if the throat is examined, thin circumscribed patches of whitish or pearl-colored membrane will be seen on the tonsils or fauces; and at the end of twenty-four hours these patches will have completely covered the tonsils and assumed the characteristic yellowish and velvety appearance. The mucous membrane is intensely injected and somewhat discolored. Within three days a purulent or muco-purulent discharge sets in, the membrane continues to spread, the edges become ragged, and sloughing begins. If the membrane progresses upward, the soft palate swells, the uvula becomes edematous, and the nasal passages become occluded by a mass of membrane and muco-purulent secretions; the tongue becomes dry and brown; the breath fetid from the necrotic membrane and decomposition of the secretions. About this time the serious symptoms of laryngeal involvement will appear. There will be another rise in temperature, the voice changes, and the development of dyspnea, as shown by increased inspiratory effort, the subclavicular depression, and the fixation of the chest-muscles. The laryngeal obstruction is due to the narrowing of the passage by the exudation, and perhaps in part by muscular paresis. In the larynx the membrane is more characteristic of the croupous deposit, except in spots (Prudden) where it invades the mucous tissue. If life be prolonged for two or three days the membrane may become separated, and at times a membranous cast of the trachea will be thrown off. Resolution may take place as in the upper part of the pharynx, or similarly there may be a fresh exudate. This may be considered as a description of a case of moderate severity. In the simpler forms there may be very slight systemic disturbances; and the false membrane, if any, thin, almost transparent, and consisting of a few scattered patches. In the malignant form the attack will be characterized by profound symptoms of toxic absorption. The usual features of blood-poisoning will be noticed; and indeed, in a case of this class, the vital powers will apparently be overcome almost from the onset by the virulence of the poison. Convulsions or low, muttering delirium may be constant; there will be absence of tendon-reflex; rapid, feeble, and irregular pulse, or a condition of semi-coma.

**Diagnosis.**—It is chiefly necessary to make the distinction between this disease and membranous croup. In the early stages this may be attended with some difficulty. The croupous membrane is thin, of a whitish color, with a glazed, shining surface, and can be easily wiped away without irritating the surface beneath; the diphtheritic membrane is thicker, has a soft, velvety appearance, a yellowish-brown color, and is so adherent to the mucous tissue that its removal is not easy, and will leave a raw and bleeding surface

beneath. Later in the diphtheritic process there will be fetor, a profuse muco-purulent discharge, and the dirty bluish-black, ragged, necrotic membrane. The croupous membrane undergoes no change until the end; it continues clean and white, and has no mucous or purulent discharge. In recent times the true scientific method for determining the presence of the diphtheritic process has been followed. Knowing with what rapidity the Klebs-Löffler bacillus multiplies, a small portion of the exudate is transferred from the throat to a properly prepared culture-tube partly filled with peptone, bouillon, or blood-serum. In twenty-four hours colonies of the bacilli will form that can be recognized by the naked eye, and the bacilli can be demonstrated under the microscope. This plan, so simple, safe and certain, is being rapidly adopted by the entire profession; and most of the large cities employ a competent bacteriologist, a large part of whose duty it is to make these investigations.

**Prognosis.**—Diphtheria is rightly regarded as one of the most fatal of diseases. The mortality-rate is large, and there are many complications and sequelæ. Until very recently the mortality-rate varied from 40 to 60 per cent. Under the influence of the treatment by antitoxin this has fallen to from 12 to 20 per cent. Two causes are active in producing a fatal termination, the asphyxia secondary to laryngeal stenosis and the overwhelming of the nerve-centers and organs by the blood-poison. The toxic effects may be marked in the mildest form of the disease as well as in the most virulent. There may be much interference with the cardiac function, due to the action of the poison on the nervous centers controlling it, or there may be instant cessation of the heart's action, due to the overwhelming effect of the poison upon the heart-muscle itself. Among the most important complications and sequelæ may be noted albuminuria, bronchitis, changes in the abdominal viscera, purulent inflammation of the middle ear, and paralysis of the various muscles.

**Treatment.**—The two points to be kept in mind in the treatment of diphtheria are to prevent the spread of the local process and to control the systemic effects of the ptomain-poison. In consequence, there should be systematic local and constitutional treatment. Innumerable preparations have been used locally, and among them may be mentioned solutions of bichlorid of mercury, even as strong as 1 part to 500 (Sternberg), carbolic acid from 5 to 30 per cent. (Ranlin), lactic acid from 30 to 50 per cent. (Bosworth), the persulphate or perchlorid of iron (Bosworth), the nitrate of silver 5 to 10 per cent. (Trousseau), hydrochloric acid, nitrate of mercury, chlorid of zinc, bromin (15 per cent.), solution of pancreatin, trypsin, and other digestive ferments, the officinal aq. calcis, the peroxid of hydrogen by spray and inhalation—all of these applications have their advantages, and each its special and ardent advocates. The application should be made only under good illumination and with the greatest care. The object of various local applications is to destroy the pathogenic organism by direct action; in consequence, they should be applied directly to and around the margins of the membranous deposits. Internal medication is indicated to combat the effects of the poison by sustaining the resisting powers of the system. The preparations of alcohol are undoubtedly best for this purpose, and whiskey and brandy should be freely and frequently administered. The tincture of iron in large doses is most important, while such drugs as digitalis, strophanthus, carbonate of ammonia, and musk, especially support the heart's action. The mercurial treatment is strongly advocated by eminent and experienced observers, the mild chlorid, the corrosive chlorid, and the cyanid each

having its supporters. Various antiseptic sprays have been found extremely useful, and will come in contact with diseased tissues beyond the reach of direct applications. The constant use of steam, both in the atmosphere and by inhalation, prevents the dissemination of the germs, keeps the surface of the tissues moist, and enables the gangrenous membrane to separate more readily. The recent introduction of antitoxin in the treatment of diphtheria marks an important advance. It is too early as yet to decide upon the ultimate value of this method. It is claimed, however, that the mortality has been so greatly reduced by its use as to remove the fear heretofore felt for this dread disease.

After every effort has been made, every method tried, a very large proportion of cases will still show that the laryngeal stenosis is progressing, and without surgical interference there is imminent danger of suffocation. We may then choose between opening the air-passages or introducing an intralaryngeal tube. The individual experience of the operator will decide which method to follow: either may be relied upon to give temporary relief; but the progressive advancement of the disease will overcome, at times, every effort made (see page 1029).

#### LARYNGISMUS STRIDULUS.

**Synonym.**—Spasm of the glottis.

This condition is more a symptom than a disease. It is a spasmodic closing of the glottis, purely neurotic in its character.

**Etiology.**—It may occur at any age, but is most frequently found in children, especially if they are ill-nourished or rachitic. The spasm is usually brought on by something that nervously unbalances the child—loud talking, coughing, teasing, irritating, or perhaps a drop of water or milk finding its way into the larynx during feeding.

**Symptoms.**—There are two or three labored efforts at inspiration, followed by total cessation of breathing. This may pass in a moment and respiration be resumed. The spasm may continue, the glottis never relax, and death at once supervene. There may be but one attack, or there may be several before the fatal issue; and there may be general systemic convulsions. There is no recognized pathological change whatever. The disease is instantly understood even by the inexperienced.

**Treatment.**—Sudden shock, slapping the sides and back, dashing cold water on the naked body and face, the application of strong ammonia or amyl nitrite to the nose, or forcing a catheter or intubation-tube past the obstruction in the larynx.

#### ACUTE PERICHONDritis.

Acute inflammations of the perichondrium of the laryngeal cartilages are occasionally met with.

**Etiology.**—The cause may be idiopathic, or the disease may follow typhoid, typhus, diphtheria, pneumonia, or any of the exanthemata. Syphilis is a very prevalent cause. The pathology is the same as that of a perichondritis in any location. Increased vascularity, followed by swelling, effusion, and pus-formation, separating the perichondrium from the cartilage.

**Symptoms.**—There is usually some systemic disturbance, a feeling of malaise, chill, etc., followed by a slight rise of temperature, with a sense of fulness in the larynx, soreness, pain on swallowing, slight dyspnea, and more or less loss of phonation. The local symptoms depend largely upon the extent of inflammation and the particular cartilages involved.



When the cricoid cartilage is the seat of the trouble dyspnea and loss of phonation are the principal symptoms. There may be cough. In affection of the arytenoid there is some slight dyspnea and impairment of voice; but interference with deglutition is the principal symptom.

When the thyroid is involved it is usually unilateral, and interference with phonation is the principal symptom. The voice is never entirely lost, but becomes very hoarse. There may be a purulent discharge through a fistula in the neck.

**Diagnosis.**—This is often made with very great difficulty. Careful and thoughtful consideration, with frequent examinations with the laryngoscope, will enable one to detect the diseased cartilage or exclude the diseases simulating it. These are croupous laryngitis and acute catarrhal laryngitis.

**Prognosis.**—There may result necrosis of the cartilage, with fistulous passages to the surface. There is final resolution usually, with some permanent voice-changes. There is little real danger to life.

**Treatment** should be the administration of mercury and iodid of potassium, and surgical measures may be called for from time to time to curette or scarify the tissues internally or to open pus-sacs or fistulous passages.

#### HEMORRHAGIC LARYNGITIS.

Hemorrhages into the larynx, or the so-called hemorrhagic laryngitis, is an extremely rare condition, unless secondary to ulcerative processes such as are found in syphilitic or cancerous diseases. Türk cites a case as occurring from syphilitic ulceration and Mackenzie describes it as one of the symptoms of acute laryngitis. The only point of practical importance is to determine whether the bleeding is from the larynx or the bronchial tubes; as in the former case it is of little consequence, while in the latter it is an indication of probable tubercular changes.

#### ACUTE CATARRHAL TRACHEITIS.

The development of an acute inflammatory process localized solely in the trachea is indeed of very rare occurrence. That this structure takes part in every severe inflammation that involves the larynx and fauces above and the bronchial tubes below may be expected, both from its direct connection and similarity of structure. That acute catarrhal tracheitis does occur, however, alone and idiopathically, is undoubtedly true; and it runs a course parallel to and of the same character and intensity as diseases of like nature in the tissues above and below. It is almost invariably of a catarrhal form, and is followed very rapidly by an extension of the disease to the larynx and bronchi.

**Etiology.**—The causation when it develops independently is the same as in the neighboring structures. There is the usual predisposition dependent upon chronic changes in the mucous tissues above, and exposure serves to light up the process. It is in reality almost always an extension downward of a laryngeal catarrh that has itself extended from above. In youth it is generally consequent upon an acute rhinitis; while in later life it is secondary to a bronchial catarrh. It may occur at any age; and, like other inflammations of the air-tract, it is found most frequently in the male, dependent, no doubt, upon their greater exposure to the exciting causes—*i. e.*, sudden climatic changes, wet clothing, draughts, and dust.

**Pathology.**—In the early stage there is the usual vascular injection and

turgescence and some slight swelling from serous exudation. The surface will be dry and glazed. Later, when mucus secretion is resumed, the swelling subsides and resolution follows.

**Symptoms.**—A dry, irritating cough, caused by the air-current passing over an inflamed surface, and a constant tickling sensation causing a continuous effort at clearing the throat, but totally devoid of expectoration. Ordinarily there is no dyspnea, as the trachea will allow of great encroachment on the caliber of its lumen without interfering with the normal air-current; but in very severe cases there may be slight dyspnea. As the disease runs its course the irritating cough gradually subsides and expectoration increases. This is greater in quantity than in catarrhal laryngitis and much less than in bronchitis. If the stethoscope is applied to the trachea there will be heard in the early stage a harsh, dry, inspiratory sound, and later on an abundance of large moist râles.

**Diagnosis.**—An acute respiratory disease with cough and expectoration, but without dyspnea or aphonia, must involve either the trachea or bronchi. The stethoscope will exclude the latter region, and if a tracheoscopic examination is made the mirror will quickly show the highly injected, dark-red, inflamed mucous membrane.

**Treatment.**—The local application of the wet compress or counter-irritation with a tampon. The inhalation of vapors saturated with benzoin, eucalyptus, or some of the essential oils. A mild expectorant-mixture containing ammonia may be given.

# CHRONIC INFLAMMATORY DISEASES OF THE LARYNX.

BY C. E. DE M. SAJOUS, M. D.,

OF PHILADELPHIA.

## CHRONIC LARYNGITIS.

As here understood, the term chronic laryngitis simply means a condition of the larynx brought about by chronic inflammation affecting either the superficial or deep tissues of this organ, and involving either a restricted portion or the totality of the parts concerned. Syphilis and tuberculosis of the larynx, sometimes termed "syphilitic" and "tubercular" laryngitis, are considered elsewhere in this volume.

**Etiology.**—In the vast majority of cases, chronic laryngitis represents but an anatomical subdivision of a chronic inflammatory disorder involving the respiratory tract, the nasal cavities—anterior or posterior—the pharynx, the tonsils—post-nasal, pharyngeal or lingual—the trachea, and the bronchi, representing as many foci. Indeed, chronic laryngitis *per se*, involving no other portion of the respiratory surfaces, is rarely met with, except in persons such as singers, clergymen, public speakers, officers, hucksters, etc., who are called upon to use their voices excessively and vigorously. Occupations such as those involving arduous labor in a dusty or smoky atmosphere are also capable of inducing a chronic inflammation of the larynx, but in these, likewise, the vocal organ is but a part of the area involved, the nose, nasopharynx, and pharynx being also kept inflamed through contact with the extraneous irritants. Gastric and hepatic disturbances, especially those caused by the abuse of alcoholic drinks, are frequent causes of chronic laryngitis, as evidenced by the hoarseness of drunkards and the laryngoscopic image presented by the larynx in such cases. Here again, however, the glottic turgescence and hyperemia but represent what might be seen along the entire mucous surfaces—the active manifestation of a general vascular engorgement.

Four prominent subdivisions of the general causative factors will best serve to clearly define the limits wherein each line of remedial measures will find its most effective application. Starting with the source of congestion most benign in giving rise to local manifestations, we have—first, contact of the mucous surfaces of the larynx with a dust-, smoke-, or fume-laden atmosphere capable of eliciting a marked hyperemia of the parts. In this class may be included smokers who indulge their habit immoderately and who spend much of their time in the vitiated atmosphere of bar-rooms, smoking-cars, etc. In these cases the mucous membrane of the entire mucous tract is, as it were, bathed in fresh smoke with each inspiration, the respiratory act thus serving to maintain the contact between the irritant and the mucous surfaces. The constitutional effect of tobacco—nicotism—enters

but slightly in the causation of local congestion. The local irritation produced is further aggravated in smokers who expectorate freely, the main factor in the causation of the congestion being an abnormal dryness. In individuals who make it a practice to inhale smoke deeply, a whistling r le resembling that observed in mild asthma is frequently heard. Singers, public speakers, etc. often suffer from hoarseness after a long railroad trip, during which their organs of phonation and respiration have been exposed to the drying and irritating influence of smoke and dust. Workers in tobacco, weavers, mill-hands, etc., may be included in this category of cases. That deficient lubrication of the upper respiratory tract plays an important part in these cases is shown by the thirst which attends them. Alcoholism is thus sometimes engendered, the alcoholic beverages tending in turn to aggravate the trouble.

The second class of causes, and one which, as already stated, furnishes by far the greatest number of cases of chronic laryngitis, is represented by all disorders of the nasal cavities, anterior and posterior, which interfere with their normal physiological functions. To allow the ingress of a sufficient quantity of air, to warm the latter and rid it of its irritating particles or noxious micro-organisms, are functions which, interfered with, promptly give rise, directly and indirectly, to morbid processes in the regions which they were intended to protect. Chronic catarrhal affections, stenotic or atrophic, septal deviations or tumors, by compromising the lumen of the upper respiratory passages and reducing or arresting the outpour of nasal mucus, by limiting the powers of the ciliated epithelium, transform parts which formerly acted as guards above the larynx into centers of morbid changes. These may exert their influence directly by continuity of tissue and the irritating action of muco-purulent secretions which find their way into the larynx; indirectly, by imposing more or less mouth-breathing—dusty, unwarmed, and perhaps septic air thus coming into direct contact with the laryngeal mucous membrane.

The third class includes the various visceral or diathetic disorders frequently overlooked as causative agents. In a large proportion of these cases the larynx but furnishes the most salient evidence of a general hyperemia of the mucous membranes. This hyperemia may be incident upon some disorder compromising the functions of the vascular system, either by causing on the one hand changes in the elements of the blood itself, or by offering a mechanical impediment to its circulation, especially in the capillaries, the result of a localized engorgement. The liver is the organ of predilection in this particular, the hepatic engorgement being in turn frequently secondary to a gastric disorder. Such cases commonly suffer also from hemorrhoids. As to diatheses, it is quite certain that in gouty subjects general treatment calculated to antagonize the effects of the dyscrasia acts promptly when local treatment will utterly fail. As regards syphilis, a chronic laryngitis occurring in an infected individual will be materially benefited and frequently cured by a course of iodid of potassium after all topical measures have proven futile. Again, cod-liver oil and iodin will do more to cure chronic laryngitis in lymphatic children than any direct medication. All these undeniable facts point to the influence of general affections upon laryngeal tissues—a point too frequently overlooked (see also page 875).

In excessive professional use of the larynx, coupled with faulty methods of tone-production, we have the fourth variety, and the most pernicious etiological factor as regards local anatomical changes. A peculiar feature of these cases is that they do not always present active symptoms, baritones



and basses frequently showing laryngoscopically every evidence of active inflammation—intense redness of the vocal bands, marked thickening of the margins of the glottis, etc.—without suffering from the least hoarseness to attract attention to the vocal organ. These cases point to the effects of overuse—namely, a localized engorgement of the superficial blood-vessels caused by intense and prolonged muscular contraction. The vessels beneath the surface being, as it were, supported by surrounding tissues, the superficial capillaries bear the brunt of the undue blood-pressure, owing to the absence of resistance afforded by their location, and become inordinately and permanently dilated. Years are doubtless required to produce this varicose condition in the average case, but an undue effort at a time when a singer is not in his usual good health may in an instant cause a vascular dilatation presenting the same redness, but attended by all the phenomena of an acute inflammation, the precursor of a tedious chronic catarrhal disorder susceptible to frequent exacerbations.

Chronic inflammatory disorders of the larynx are more frequently observed in men than in women, because they are more exposed to the etiological factors outlined than the latter. Smoking and drinking are prolific indirect causes, as stated, and these habits are most generally indulged in by the male sex. Chronic laryngitis can occur at all ages.

**Symptoms.**—Impairment of the voice is naturally the most prominent symptom—one but little, if at all, influenced by the nature of the primary cause of the laryngeal disorder. A sensation of rawness or tickling gives rise to the desire of hemming or hawking—a voluntary effort to rid the larynx of a supposed offending mass of mucus. The hoarseness may not be continuous, but occur only after the voice has been used for a short time. In some cases the voice is at first quite veiled or hoarse, and after a few words or sentences have been spoken it becomes temporarily clear. The vocal disability, however, is sometimes shown by a feeling of local fatigue, heat, and constriction. In singers all these symptoms may be present simultaneously, the least effort at singing increasing the trouble. The voice is usually lowered in pitch. Complete aphonia occasionally occurs. Pain is an occasional symptom, denoting the probability of rheumatic diathesis. Cough provoked by the sensation of itching already alluded to is present in the majority of cases and is occasionally spasmodic. The expectoration is scanty, however, unless tracheal or bronchial trouble is also present.

The laryngoscopic appearances vary considerably and are proportionate to the degree of active inflammation. The evidences of local hyperemia are nevertheless always present, and vary from a slight arborescent and light pink tinge, suggestive of congestion, to a bright red hue, indicative of violent inflammation. The epiglottis is also congested, enlarged vessels coming over its posterior surface, while the aryteno-epiglottic folds appear thickened, the tumefaction involving the entire larynx in marked cases. The general redness, however, is not so marked as in some cases of acute laryngitis. The vocal bands are also more or less congested; the congestion may either be limited to a small portion of their surface or involve their entire area. Small masses of stringy cream-like mucus are frequently to be seen forming films when the glottis is opened.

In some cases the vocal bands appear relaxed and their thickened edges do not seem to come accurately together, an elliptical opening being occasionally observed between them. This want of parallelism is due to muscular paresis (see Plate 15), affecting usually but one side. Shallow abrasions of the epithelial covering are occasionally met with, especially in the interaryte-

noid space. Deeper ulcerations, sometimes leading to perichondritis, have been observed by various clinicians.

In some cases the secretion, besides being muco-purulent or purulent, is prone to adhere firmly to the mucous surfaces and to become partly desiccated in this situation. The dry crusts formed, by impeding the free passage of air, give rise to more or less dyspnea. Laryngoscopically examined, the larynx appears red and dry, with greenish crusts closely adhering to parts adjoining the vocal cords either above or below. Owing to the appearance of dryness, a special name, *laryngitis sicca*, is frequently given this disorder. The breath expired from the mouth is usually very fetid, hence another name, *ozena laryngis*, given it by observers who considered the disease as invariably associated with atrophic catarrh of the naso-pharynx. It is probably a rare manifestation of chronic laryngitis, but it appears to me one possessing an insufficient number of known characteristics to warrant for it a special position in our nomenclature.

Hemorrhage of the larynx sometimes occurs in the course of chronic laryngitis in connection with severe cough and copious expectoration. In a case related by Michael Pleskoff the expectoration had been bloody on several occasions. Laryngoscopy revealed the ordinary diffuse redness of the vocal bands common to chronic laryngeal catarrh; but in the region of the left vocal process, near the ventricle, there was an elongated, submucous, circumscribed bloody patch, which covered half the breadth of the vocal band, and which was evidently due to rupture of a blood-vessel. The treatment instituted consisted solely in suppression of the voice, and gradual absorption of the effused blood took place with its disappearance in three weeks.<sup>1</sup> Another marked case was recently reported by Compaired.<sup>2</sup>

The infraglottic space is frequently involved in the inflammatory process, and the mucous membrane of its walls sometimes projects slightly beyond the margins of the glottis, especially when the vocal bands are abraded. In the so-called laryngitis sicca this region is one of predilection for the formation of crusts.

**Pathology.**--Whatever the primary causative factor, the main pathological feature of these cases is dilatation of the vascular supply, the vessels of the bands reaching in some cases, as already stated, a condition of varicosity. The chronic character of the disease is mainly due to paresis of the vascular walls and to the hyperplastic character of the chronic inflammatory process.

In mild cases it is probable that there is merely deficient lubrication, especially when an atrophic rhino-pharyngitis represents the primary cause, hyperesthesia of the surface taking an active part in the production of the subjective symptoms.

**Prognosis.**--Marked cases of chronic laryngitis seldom tend toward recovery. In cases in which the disorder is due to irritation by inhaled irritating substances, the continued use of the voice and the inhalation of dust and smoke attending everyday life are as many conditions tending to keep up the trouble, if not to aggravate it. These sufferers are seldom willing or perhaps able to give up an occupation in order to counteract a disease the symptoms of which do not involve marked suffering or danger to life. This is especially the case in patients in whom the voice is not a source of livelihood, as it is in singers, speakers, etc. In the great majority of these cases, therefore, the chances of recovery are to a degree compromised by circumstances beyond the physician's control. When they are within his control, the prog-

<sup>1</sup> *Münchener med. Woch.*, Dec. 4, 1888.

<sup>2</sup> *Annales des Maladies de l'Oreille*, etc., May, 1896.

nosis is at once modified, appropriate treatment and a judicious change of occupation leading to recovery in many uncomplicated cases.

Cases of chronic laryngitis in which the primary causative agent is represented by some disorder of the naso-pharyngeal tract generally respond promptly to measures capable of favorably influencing the morbid process. The prognosis of these cases, therefore, depends upon that of the primary disease. The same can be said of cases in which visceral or diathetic disorder plays an active rôle as an etiological factor. Hepatic torpidity added to gastric insufficiency are with difficulty overcome, and a chronic laryngitis due to these conditions, while yielding to judiciously directed measures, frequently reappears with much greater suddenness than it departed.

The prognosis of chronic laryngitis in singers is often a question of great moment, a brilliant career being frequently at stake. Fortunately, advanced laryngeal therapeutics enable us to satisfactorily treat even the worst of these cases, provided our instructions are properly carried out.

Another question of importance is the possibility of complications during the active inflammatory process, and particularly the likelihood of a simply chronic laryngitis being transformed into benign or malignant growths or into tuberculosis of the larynx. As to benign growths it is undeniable, judging from clinical evidence. Still the proportion of benign neoplasms as compared to that of cases of marked chronic laryngitis is so small that the presence of a concomitant dyscrasia capable of manifesting itself when hyperemia is prolonged beyond a certain limit can but suggest itself. The same might be said of malignant growths until we are better acquainted with their pathology. As regards tuberculosis of the larynx, no case so far reported warrants the assertion that a catarrhal inflammation can at any time give rise to a local tubercular process. Indeed, a careful clinical study of the subject has led me to conclude that tuberculosis of the larynx is primarily due to precisely an opposite condition, local adynamia, and that what benefit topical applications afford in the treatment of "tubercular laryngitis," so-called, is in a measure due to the local stimulation produced.

**Treatment.**—To properly treat chronic laryngitis the predominating etiological factor of each case must be clearly determined. The local application of astringents to the larynx in a patient in whom a disordered digestive system plays the leading part can but finally prove ineffectual; the relief obtained is soon attended by a return of the symptoms. To treat the larynx alone when a nasal disorder is also present is as futile, unless the laryngeal inflammation be a mere exacerbation of a latent catarrhal process that is soon to yield of its own accord. In other words, to merely treat the larynx without seeking for the primary cause, proximal or remote, is to court defeat or to accept time as an ally in the great majority of cases. In this disease, probably as much as in any other that could be named, the removal of the active cause is the most important feature of the treatment; the application of topical remedies playing a secondary—although important—rôle in hastening the successful issue. Briefly, in cases due mainly to continued irritation of the larynx and adnexa by such extraneous elements as dust, smoke-fumes, etc., a change of habit or occupation should be enjoined; when the laryngeal disease is due to a morbid process of the nose, naso-pharynx, pharynx, etc., this morbid process should be corrected; when a gouty or rheumatic diathesis, a gastric or hepatic affection, etc., is at the bottom of the trouble, general treatment of the condition is all-important; when in singers, speakers, etc., the organs of phonation are improperly and excessively used, the paramount indication to insure success is to correct the



errors. The prognosis of the case depends mainly upon the perfection with which all these indications can be carried out.

The topical measures vary but little, whatever the primary cause of the local trouble, and common to all forms is the maintenance of cleanliness, not only of the larynx itself, but of the naso-pharyngeal cavity as well. For this purpose, a drachm of bicarbonate of soda dissolved in a pint of lukewarm water serves an admirable purpose. A few tablespoonfuls of this solution being placed in an atomizer, the pharynx and larynx are freely sprayed at short intervals during two or three minutes. The balance of the solution is then employed to cleanse the naso-pharyngeal cavities, the palm of the hand being used as a dipper from which the liquid is inhaled. The patient should do this morning and evening and on reaching home from work, if his occupation happens to be one capable of causing irritation of the mucous tract. After using the warm detergent spray, the patient should employ in the same manner a solution of resorein, 5 grains to the ounce.

To obtain contraction of the superficial blood-vessels, local applications of active astringents must be made. The most satisfactory of these is still nitrate of silver, employed in solutions varying from 10 to 60 grains to the ounce. When erosions are present the latter solution should be preferred and applied after slightly anesthetizing the laryngeal surface to prevent spasmodic contraction. A small pledget of cotton should be used, and after being adjusted in the grasp of the forceps and dipped in the solution it should be lightly squeezed between the folds of a towel to prevent dripping. When another remedy is preferred, a solution of sulphate of copper, 30 grains to the ounce, may be employed. In cases uncomplicated by erosions, etc., weaker solutions of nitrate of silver or a 10-grain solution of tannin in glycerin applied every other day, besides the measures to be carried out at home by the patient, usually suffice to bring about recovery, provided the original cause has been properly treated. Important in this connection, especially when treating people who use their voices professionally, is always to include the infraglottic region, the portion immediately below the vocal bands, in the remedial measures adopted. A peculiarity of the mucous membrane of this region is to form creases or longitudinal folds when the bands are not in extreme adduction. Upon the integrity of this crease-forming quality greatly depends the character of the voice. In the treatment of singers, local applications including the infraglottic space and calculated to reduce congestion and irregular traction upon the edges of the vocal bands will be found to control much more readily a case of hoarseness due to an acute, subacute, or chronic disorder than when the same application is limited to the upper laryngeal cavity. As soon as the regular formation of creases is interfered with, the tension upon the vocal bands becomes excessive or irregular, and there is added to the catarrhal or other anomalous local conditions present one of even greater mechanical moment.

These cases are frequently characterized by what might be termed a subacute exacerbation. The benzoate of sodium, 5 grains every three hours, usually suffices to arrest this intercurrent trouble. If the attack is a sharp one, the patient should remain at home and inhale every hour the steam of a mixture of two teaspoonfuls of the compound tincture of benzoin and a pint of boiling water. The vessel containing the water should be covered with a towel folded into the shape of a cone; into the upper opening of this cone the patient introduces his nose, mouth, and chin to better confine the benzoin-laden steam inhaled and prevent too rapid a dissipation of the heat.

In cases of long standing the superficial blood-vessels are sometimes



permanently dilated to twice their normal caliber and are increased in length in proportion. Astringents here are useless. The only measure likely to procure a return of the voice is to cauterize the varicose vessels of the surface of the vocal bands. Chronic acid is the best agent for the purpose. After thorough anesthetization with a strong solution of cocain, the acid, fused by heat to the end of a covered probe, is applied to one of the bands while the patient in his effort to make a sound brings the bands in apposition, and thus renders accidental cauterization of their edges impossible. An abrasion the size of a small pea is the result, and this spot, after healing, is distinctly whiter than the surrounding parts. The applications are to be renewed every few days, each band being treated alternately, until all the areas of superficial congestion have been destroyed.

Kranse<sup>1</sup> of Berlin, in stubborn cases occurring in singers, recommends a method considerably employed in the United States many years ago—*i. e.*, minute longitudinal incisions made with a lancet-shaped laryngeal scarificator into the hyperplastic tissues of the bands. The bleeding is slight, and rapid improvement ensues. In the same class of cases Massei of Naples recommends spraying with a 2 per cent. solution of lactic acid, used frequently, eight to ten times daily. Hygienic measures and tonics form important adjuvants.

In mild chronic laryngitis frequently attending an overworked professional vocalist, an exacerbation of the local trouble is often due, as already stated, to deficiency in the lubrication of the vocal bands. This condition is successfully combated by the administration every two hours of 10 grains of ammonium chlorid in a tumblerful of water, and the topical use of warm sprays of a saturated solution of potassium chlorid at the same intervals. The doses are so managed that the last one should be taken at least about three hours before a performance. This avoids exposure during the subsequent stage of perspiration. A lozenge containing one grain of the ammonium chlorid taken between acts is of benefit in some instances, mainly owing to its effect upon the pharynx.

Of importance in these cases is the question of rest. This is always indicated, especially in female voices, a fine voice being always endangered when it is used during a more or less grave local disorder. Our recommendation should be framed accordingly, taking the severity of the local trouble as our guide as regards the duration of the resting period and its degree. Unfortunately, rest is rarely possible in professional singers, and as long as a vestige of voice remains they insist upon a continuance of their work. What are we to do in these cases? Without doubt the most advantageous plan to all concerned is frankly to disclose to the patient the dangers incurred; to recommend abandonment of rehearsals; limitation to the smallest degree possible of the part to be sung or spoken; to transpose, when possible, all high notes, or, if this is not possible, to shorten the chest-register a couple of notes, thus changing to the head-tones without having to throw upon the larynx the strain of the two highest notes of the chest-register; in other words, to limit as much as practicable the work of the vocal apparatus.

Besides the local measures recommended, these cases require special efforts to overcome the muscular fatigue entering for a great share in the subjective symptoms. Strychnia,  $\frac{1}{60}$  of a grain every three hours, and electricity are usually effective. The faradic current is most effectively employed in the following manner, which introduces water as a conductor for the current, thus avoiding the local irritation caused by contact with the electrode, and

<sup>1</sup> *Berliner klin. Woch.*, April 16, 1894.

doing away with all gagging: The patient having taken what is usually called a mouthful of water—in reality, about an ounce—is told to throw his head backward and to open his mouth. The first movement of deglutition causes the water to fill the pharyngeal cavity. Light being thrown in, a Mackenzie laryngeal electrode is introduced and simply immersed in the water, the external electrode, thoroughly wetted to secure penetration through the skin, being placed over the thyroid. The circuit being then closed by pressing the button of the Mackenzie electrode, the current is allowed to flow as long as the patient can hold his breath. The mouth-electrode being then taken out, he can, either by closing his mouth and bowing his head forward, bring the water forward and take a few breaths through the nose, then renew the first movement, throwing the head backward, etc., or take another mouthful of water, after ridding himself of the first. The oftener the sittings—which should last at least fifteen minutes—are renewed, the better; the patient may even be taught the procedure, and he can then treat himself twice or three times daily at home.

When there is a tendency to the formation of crusts, as in “laryngitis sicca,” the benzoin-and-steam inhalations are very effective. Iodid of potassium, five grains in a glass of water after each meal, has given me the best results. Local applications of a 30-grain solution of nitrate of silver usually prevent a return of the trouble.

#### NODULAR LARYNGITIS, OR CHORDITIS TUBEROSA.

**Etiology.**—This is a disorder of the mucous membrane of the vocal bands, consisting in the development of small nodules on the surface or edge of the latter as a result of chronic laryngitis. The use of the voice while an inflammatory process is present in the larynx, a faulty method of singing, friction of the free edge of one band against that of the other where the voice is considerably used, are the main primary factors to which this disease is attributed. It is almost always observed in singers and public speakers, and more frequently in sopranos and tenors than in baritones and basses. According to Moure,<sup>1</sup> this affection is frequently met with in children from seven to ten years of age.

**Symptoms.**—The most prominent symptom is hoarseness, or an irregular production of the voice, characterized by the escape of air simultaneously with the emission of sound. In some cases there is aphonia when the normal vocal effort is made in speaking, while sound is emitted during vigorous enunciation. In others, again, complete aphonia exists. There is usually no dyspnea, and in fact no evidence of local trouble other than the mild chronic laryngitis which is usually present in such cases.

The nodules may be situated upon either band. In the few cases I have had occasion to treat they were situated on the free edge of the left band—a mere coincidence, doubtless. In one case there was evident irritation of the same spot on the other band, caused by the friction of the nodule. In this manner secondary nodules are thought to be produced, as they are frequently symmetrically located. The growths are usually the size of a pin-head; in one of my cases, however, the growth had reached at least four times that size. The nodules are usually pinkish-gray, an areola of red, from which arborescent venules sometimes project, surrounding the base. They are said to sometimes disappear spontaneously or to become changed into laryngeal growths of another variety.

<sup>1</sup> *Revue de Laryngologie*, Feb. 8, 1896.

**Pathology.**—The nodules are the result of inflammatory action. The hyperplasia, at first limited to the epithelium, finally implicates the tissues beneath, the changes consisting mainly in cellular-tissue hypertrophy. The epithelial elements are also largely increased.

**Treatment.**—I am inclined to believe that the nodules reported as removed by the local application of strong solutions of nitrate of silver or of iodine were not really nodules, but merely ampullæ or tortuous blood-vessels, such as those occasionally observed in chronic laryngitis of old standing. In *bona fide* cases, the only measures found of real service in my cases were chromic-acid crystals, the silver nitrate in its solid form, and the galvano-cautery. Either of the former two agents may be fused upon the end of a protected probe and applied to the nodules after anesthetizing the laryngeal surfaces. Of the remedies mentioned, chromic acid has served the best purpose, applied in the manner described in the section on chronic catarrhal laryngitis. Nitrate of silver and the galvano-cautery leave a scar-like tissue which might ultimately compromise a fine voice.

#### PACHYDERMIA OF THE LARYNX.

Although this affection is not always considered as a morbid entity, its pathological features are nevertheless such as to warrant its classification among the special complications of chronic laryngitis.

**Etiology.**—Pachydermia of the larynx is a disease consisting of symmetrically elongated swellings of oval shape, most frequently observed near the posterior extremities of the vocal bands, especially the region of the vocal processes. It occurs especially as a result of the chronic laryngitis observed in persons addicted to the excessive use of alcohol and tobacco, and is sometimes ascribed to tuberculosis and syphilis. Judging from the cases so far observed, it occurs most frequently in men between thirty and forty-five years of age.

**Pathology.**—In a series of fifteen larynges affected with pachydermia examined microscopically, Habermann<sup>1</sup> found connective-tissue changes in the mucosa and submucosa of the vocal cords and ventricular bands, extending occasionally into the thyro-arytenoid muscle involved (Fig. 596). In some spots, especially the vocal processes and the posterior wall (the inter-arytenoid space), individual papillæ had developed into papilloma-like growths. The cup-like prominences due, as thought by B. Fränkel, to pressure exercised by the vocal processes upon one another during phonation, were present in the majority of cases, the central depression corresponding to the point of the hyaline process. Connective-tissue strands radiated in all directions from the surface of the papillæ. The erosions and ulcers found occurred most frequently on the vocal processes, about equally on each side, less often on the free border of the vocal bands. Nothing was found to indicate that these ulcerations were due to either tuberculosis or syphilis. The association of pachydermia and ulceration with diseases which cause general congestion, pulmonary emphysema, cirrhosis of the liver, etc., was, however, confirmed.

**Symptoms.**—The symptoms vary according to the situation of the local thickening, but as a rule the disease runs its course unattended by any great degree of discomfort. The first symptom—huskiness—is usually ascribed to a cold, and is accompanied by frequent desire to clear the throat, owing to a sensation resembling that caused by the presence of a foreign body. Slight

<sup>1</sup> *Zeitschrift für Heilkunde*, Bd. xvi., 1895, and *Journal of Laryngology*, Oct., 1896.

dyspnea is sometimes experienced; this is perhaps due to the diminished abduction observed in these cases.

Examined laryngoscopically, the larynx appears more or less congested according to the intensity of the catarrhal process that may be present. In some cases the laryngeal surfaces, except the sites, of the growths, appear normal. On the vocal bands, however, and almost always over the vocal processes, two pink or red swellings, one on each side, and sometimes involving the posterior wall of the larynx, may be seen. One of these growths is much larger than the opposite one. In a case seen by Dundas Grant the larger

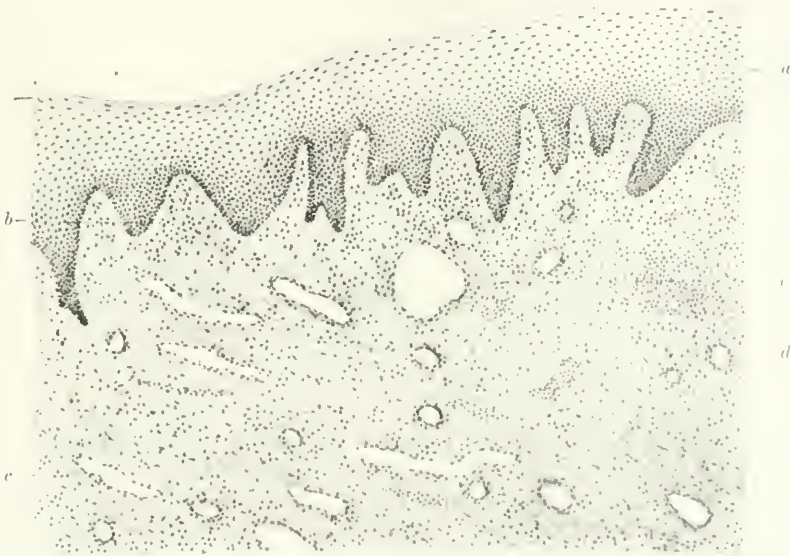


FIG. 596.—Section of mucosa, showing pachydermia of the larynx. The hypertrophied papillae *b* are covered with greatly thickened epithelium (*a*), and the infiltrated submucosa (*d*) shows gaping vascular channels (*c*) (Seifert and Kahn).

tumor had reached the size of a shirt-button. The smaller thickening on the opposite side shows an excavation or depression at its apex, precisely where the growth of the other side comes in contact with it during approximation of the vocal bands. This cup-like depression, as already stated, is due to the pressure exerted by the tumor of the one side upon the corresponding tumor of the other. There may be but one excrescence, however, and indentation of the opposite be formed at the expense of the tissues of the vocal band proper.

**Prognosis.**—The prognosis of this affection mainly rests upon the possibility of transformation from a benign to a malignant growth. Klebs<sup>1</sup> considers pachydermia laryngitis as a possible primary stage of cancer; but this view has not been generally sustained, and the prevailing opinion is that degeneration into malignancy is not to be feared. Chondritis and perichondritis, however, have been observed; but as a rule the affection is considered a benign one, offering no special danger to life. As regards the voice, permanent impairment is likely unless the case be seen and properly treated in its early stages.

**Treatment.**—The measures recommended for the treatment of nodular laryngitis are probably the best to adopt, especially the local application of

<sup>1</sup> *Deutsche med. Woch.*, p. 537, 1890.



chronic acid. The internal administration of iodid of potassium has been found beneficial in some cases owing to the frequent association of the disease with syphilis. The local measures indicated for the treatment of chronic laryngitis may also prove of value. A spray of a 3 per cent. solution of chlorid of sodium has been especially recommended.

Removal with forceps followed by local cauterization has been advocated by Gougenheim; while Moll states that he has obtained prompt results from electrolysis, a double needle and a current of 5 milliamperes being employed.

#### CHRONIC SUBGLOTTIC LARYNGITIS.

**Etiology.**—This is a rare form of chronic laryngitis in which the brunt of the inflammatory process is located in the tissues beneath the vocal bands, giving rise in this situation to more or less rapid hypertrophic changes. The nature of this disease has remained obscure owing to its rarity, but it is thought to be associated with the so-called serofulous habit, syphilis, tuberculosis, and rhino-scleroma. According to Gordon Holmes,<sup>1</sup> the causes of this disease are nearly always well defined. Exposure to wet and cold, straining efforts of the voice, and excessive indulgence in spirituous liquors are, in his opinion, almost exclusively the sources of the disease. It is also allied to certain occupations in which the vocal organ is used with vigor. Of 47 cases seen, 30 were males. Reports of cases seen by other authors would indicate, however, that the disease occurs more frequently in females than in males. It occasionally presents itself as a complication of typhoid fever.<sup>2</sup>

**Pathology.**—An analysis of the microscopical examinations reported by Wedl,<sup>3</sup> Sokolowski,<sup>4</sup> and Kuttner<sup>5</sup> tends to show that the disease consists mainly of a chronic cell-proliferation, not only in the mucous and submucous cellular tissue, but also in the underlying muscular layer, the epithelial lining sinking into the submucous tissue in various places. This process progressing insidiously, a dense indurated mass is gradually developed, which occasionally includes the edges of the vocal bands and the neighboring tissues. It would seem that besides a dyscrasia, lymphatism, syphilis, etc., the disease requires some exciting organism, especially the typho-bacillus and that of rhino-scleroma, for its development. No bacillus special to the disease has as yet been found.

**Symptoms.**—The earliest symptom is hoarseness, which is generally attributed to a cold. The voice is muffled and labored, and is sometimes completely lost. This complete aphonia is more likely to occur in females than in males. The patient sometimes experiences a sensation of weight in the throat, due probably to the impediment offered by the more or less solidified subglottic tissues to the movement of the vocal bands. Pain is seldom experienced, but there is often a sensation of pricking that causes the patient to frequently "hem" to clear his larynx of a small mass of mucus which may have collected over the diseased area. Such a patient, who may perhaps experience a slight difficulty in breathing during exertion, may all at once, without the least warning, become the prey of intense dyspnea, and pass away unless immediate relief be at hand, the subjective manifestations being such as to suggest other disorders, cardiac or vascular, as the cause of death.

<sup>1</sup> *Lancet*, November 15, 1884, p. 867.

<sup>2</sup> A. Sokolowski, *Archiv für Laryngologie*, Bd. ii, H. 1, 1894.

<sup>3</sup> Wedl, in *Turek's Klinik der Krankheiten des Kehlkopfes*, p. 203, 1866.

<sup>4</sup> Sokolowski, *Op. cit.*

<sup>5</sup> Kuttner, *Archiv für Laryngologie*.

Several such cases have been reported; others have been saved by timely tracheotomy. The subglottic enlargement on each side can usually be seen laryngoscopically, especially when the vocal bands are abducted, appearing as more or less rounded bulging masses varying from the dull, variegated pink tint of catarrhal hyperemia to the vivid red hue of active inflammation. In acute attacks the latter color prevails and the glottic lumen is almost occluded. When edema is a prominent factor of the case, the grayish-white color of the projecting mass suggests the presence of polypi such as those found in the nasal cavities.

**Prognosis.**—As may be surmised, the prognosis of such a case is not encouraging, tracheotomy or laryngotomy becoming obligatory. Even then the patient frequently perishes from gradually increasing debility unless an intercurrent disease such as pneumonia should carry him off. It is probable, however, that, discovered early, the trouble might be arrested by antagonizing any condition, occupation, overuse of the voice, etc., capable of inciting local trouble, or by counteracting the pathogenic influence of any dyscrasia that may be present.

**Treatment.**—Change of climate, to avoid acute exacerbations so frequently caused by damp cold, is indicated, with cessation of vocal effort and any other occupation or habit acting as exciting cause. Gordon Holmes,<sup>1</sup> who has obtained some cures, states that relief may be obtained from the use of cold spray inhalations, of solutions of perchlorid of iron, sulphate of copper, etc., between paroxysms, but that during the exacerbations warm soothing inhalations, impregnated with opium, conium, or stramonium, are preferable. Local applications by the attending physician of a solution of perchlorid of iron—two drams to the ounce of water—directly to the hypertrophied region are of value in mild cases. In advanced cases strong solutions of nitrate of silver are recommended. Cauterization of the parts with the galvano-cautery has been highly recommended by Voltolini; while Mackenzie advised scarification. Sokolowski recommends laryngofissure and thorough extirpation of the hypertrophied tissues.

#### CHRONIC TRACHEAL AFFECTIONS.

Unless of a neoplasm, the trachea may be said never to be independently the seat of a chronic affection, merely sharing in those which extend into it from the larynx above or from the bronchi below. Separate discussion is therefore needless.

<sup>1</sup> *Loc. cit.*, p. 868.

## DIPHTHERIA OF THE AIR-PASSAGES.

BY J. H. MCCOLLOM, M. D.,

OF BOSTON, MASS.

**Definition.**—The term diphtheria, derived from the Greek word *διφθεζρα*, meaning skin or leather, should be applied only to those cases of sore throat in which a membrane is found, and in which a culture taken from this membrane or near it shows the presence of the bacilli of diphtheria, or in those cases in which there is a profuse nasal discharge, a culture from which shows the presence of these organisms. In cases of laryngeal stenosis, although no membrane is visible and the cultures are negative, the existence of this membrane has been proved by autopsies and by the fact that membrane has been coughed up. The term membranous croup is a misnomer and is a relic of past ages. No such disease, as distinguished from diphtheria, exists, and the term should be erased from the nomenclature. Laryngeal stenosis in children in the vast majority of instances is caused by the presence of a membrane which is the result of the growth of the bacilli of diphtheria. Streptococci may cause the appearance of a membrane in the air-passages, but this membrane is not sufficiently thick and tough to impede the respiration.

**History.**—It is generally supposed that diphtheria is a disease of modern times, but Arctæus, a Greek physician of Cappadocia, wrote a description of a disease similar to diphtheria in 111 A. D. In the sixteenth century the disease was prevalent to a greater or less extent, according to written statements of the physicians of that time. In 1821 Bretonneau wrote the first full and elaborate account of the disease. After that time until 1847 diphtheria did not seem to attract much attention among the physicians of the Continent. In 1847 an outbreak of diphtheria occurred in England, which was traced to its origin at Boulogne and was known as the “Boulogne sore throat.” Since that time diphtheria has been more generally recognized and more carefully studied; and for this reason, although the disease is somewhat more prevalent at the present time than formerly, yet the apparent increase is due in a measure to its better recognition.

Diphtheria was first recognized in Boston, Massachusetts, in 1859, in which year there were 19 deaths from this cause reported. From what is known of the disease to-day, it seems reasonable to suppose that if 19 deaths from a so-called new disease were reported, there must have been many cases of the same disease that were not recognized. The following year there was only one death from this cause reported in Boston. Since that time the death-returns have shown a gradual increase in the number of deaths. In 1863 and 1864, in Boston, with a population of 186,526, there were 353 and 287 deaths, respectively. From 1865 to 1874 there were very few deaths from diphtheria. In 1875 the number of deaths from this disease increased to an alarming extent. In 1881 there was quite a severe epidemic of this disease in this city, the deaths for that period numbering 802, giving a rate

per 1000 of the living of 2.178. Since 1881 the number of deaths from diphtheria has varied from 285 to 878 each year. The number of cases reported in 1894 was 3019, with 878 deaths, making the death-rate from this disease per 1000 of the living for 1894, 1.803, while that of 1893 was 1.145. The most marked increase in the cases of diphtheria in 1894, as compared

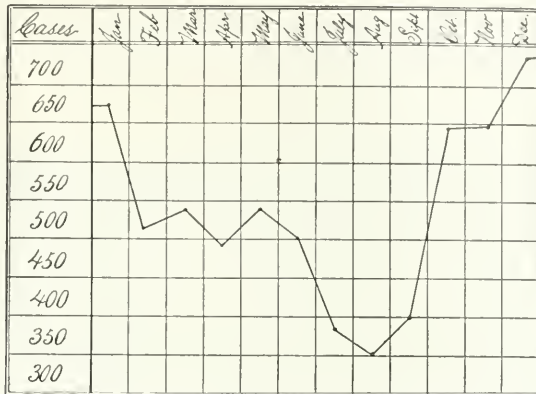


FIG. 597.—Chart of the total number of cases of diphtheria in Boston, by months, for five years.

with 1893, occurred in the last six months of the year. The ratio of deaths per 1000 for 1895 was 1.173, and that for 1896 was 0.980.

In England the increase of the mortality from diphtheria has been much more marked in the larger towns than in the rural districts. In London this has been more particularly noticeable.

**Etiology.**—The discovery by Klebs of the bacillus of diphtheria in 1883 and the investigations by Löffler a year later, placed the etiology of diphtheria upon a scientific basis. The result of these researches shows conclusively that diphtheria is distinctly a contagious disease; that it never originates spontaneously; that it is a local disease; and that the constitutional symptoms are due not to the presence of the organism in the blood, but to the toxin caused by the growth of the bacillus.

It is now generally conceded that imperfect drainage and unsanitary conditions should not be considered important factors in increasing the frequency of this disease. Twenty years ago diphtheria was considered to be a filth-disease, but careful investigation of the course of epidemics in various cities and towns has shown conclusively that diphtheria is no more prevalent where unsanitary conditions exist than where the general sanitation is good.

The influence of mild cases of diphtheria in the public schools has a marked effect on the prevalence of the disease. The accompanying chart, which gives the number of cases of diphtheria reported in Boston, Massachusetts, by months, for five years, shows that when the schools are in session the number of cases is much greater than during vacation-time, in the months of July and August.

Cows may have diphtheria, and when suffering from the disease may be a source of infection. Klein, in a report to the Local Government Board of London, traced an epidemic of the disease to milk from cows that gave unmistakable evidence of being ill of diphtheria. Small areas of false membrane were found on the teats of these cows. Cultures made from these lesions contained the diphtheria-bacillus. Cats fed on the milk from these



cows contracted diphtheria. While there is no positive evidence that the milk in the udder contained the germ of the disease, there is every reason to believe that the milk was contaminated by the hands of the milkers.

One factor in the spread of diphtheria is the existence of this disease in cats and dogs. Diphtheria manifests itself in cats and dogs, not by the presence of marked membrane in the throat, but by the condition of the lungs simulating pneumonia. The animal has a peculiar strident cough, has anorexia, and loses flesh rapidly. If children are allowed to play with animals suffering from this disease, they may contract it from them.

The area of infection of diphtheria is not as great as that of scarlet fever, but that it is a distinctly contagious disease must be admitted. The discharge from the nose and the secretions from the mouth may be the carriers of the contagium, hence the importance of burning or disinfecting all articles soiled by these discharges. Kissing frequently conveys the germs of the disease from one person to another.

**Morbid Anatomy.**—Diphtheria must be considered a local disease at the outset; and the symptoms that occur later are the result of the toxin caused by the growth of the bacilli. The growth of these organisms causes the formation of false membrane, which, according to Weigert, as stated by Councilman,<sup>1</sup> is due to a necrosis of the epithelial surfaces. The exudation from the vessels beneath coming in contact with the necrosed tissue coagulates and forms fibrin. Wagner<sup>1</sup> says the presence of the membrane is due to hyperemia and inflammation of the tissues beneath, and that there is a fibrinous metamorphosis of the epithelial cells. Heubner<sup>1</sup> found that in the beginning of the disease membrane was formed in the most superficial layers of the epithelial cells and gradually extended to the deeper ones. The appearance of the membrane during the first twelve hours, as compared with its appearance forty-eight hours later, is explained by this view of Heubner. The membrane in diphtheria is generally of a grayish-white color, and, as a rule, cannot be easily detached; but this is not universally the case, as frequently it is white, and appears only in small circumscribed patches easily detached. The membrane sometimes early in the disease assumes a gangrenous appearance, which is an omen of very grave import. Nasal diphtheria is characterized by a profuse nasal discharge, and it is the exception that any membrane can be detected without a rhinoscopic examination. Diphtheria of the eye, often caused by the transmission of the germs of the disease from the nose, is of frequent occurrence. There is great swelling of the lids, intense congestion of the conjunctivæ, and frequently, but not always, the formation of a false membrane. Frequently the pharyngeal inflammation extends through the Eustachian tube and causes an inflammation of the middle ear. The membrane may extend into the larynx, giving rise to marked dyspnea. Below the vocal cords the membrane is not very firmly attached to the subjacent tissues and is frequently coughed up. Fig. 598 represents membranous casts of the trachea coughed up by a patient ill with diphtheria. Casts of the right and left bronchi can be clearly seen.

Membrane may extend into the various ramifications of the bronchi. The heart may be of a grayish-yellow color, and when death occurs late in the disease, may show evidences of fatty degeneration. The kidneys, as a rule, are enlarged; and on section the cortex is found swollen and the region of the convoluted tubes opaque. When death occurs late in the disease, during apparent convalescence, there are no characteristic macroscopic lesions found, as a rule, at the autopsy. Microscopical examination, however, of

<sup>1</sup> *Boston Medical and Surgical Journal*, cxxxiii., 10, p. 231.

the nerves shows in the majority of instances marked degeneration of the nerve-tissue.

**Prophylaxis.**—The importance of isolating every case of doubtful sore throat cannot be overestimated, and it is also equally important to isolate every child who has a profuse nasal discharge, until the diagnosis can be definitely made by means of a bacteriological examination. It is a trite saying, but nevertheless true, that mild cases of contagious disease are much more dangerous to the public health than the severer ones. The writer has investigated quite a number of outbreaks of diphtheria which could be definitely traced to mild cases of the disease, cases so mild that no physician

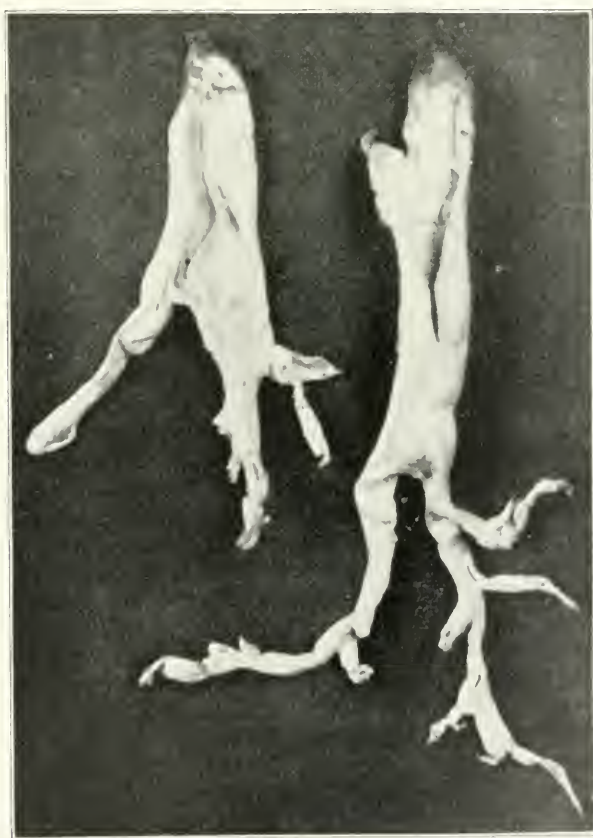


FIG. 598.—Casts of the trachea and bronchi.

saw them. Too much emphasis cannot be laid upon the danger of permitting children with profuse nasal discharges, loaded with the bacilli of diphtheria, to mingle with others. The careful medical inspection of schools, in order that children suffering from mild attacks of diphtheria may be isolated at their homes, is a very important factor in prophylaxis. When a patient is taken ill with diphtheria, he should be placed in an upper room of the house. All hangings, stuffed furniture, and carpets should be removed from the sick-room. If possible, only one person should attend upon the patient, and she should wear cotton gowns, which should be frequently changed and disinfected. All discharges from the patient should be disinfected by corrosive

sublimate, 1 part to 500, or by a solution of carbolic acid, 1 part to 20. No handkerchiefs should be used, but in place of them pieces of old cotton-cloth should be employed to receive the discharges from the nose and mouth. These pieces of cloth should be burned. All utensils should be sterilized in boiling water or by washing with a solution of corrosive sublimate, care being taken, however, to thoroughly wash them after the immersion in corrosive sublimate. The room should be well ventilated and, if possible, should have a sunny exposure. An abundance of sunlight in the room of a patient is of very great importance. The germicidal properties of sunlight have been very clearly demonstrated by v. Es-march. In his experiments he proved conclusively that the bacilli of diphtheria in culture-tubes and on cloth were destroyed in from four to five hours. Pure air and plenty of sunlight are Nature's most effective germicides. Burning sulphur in a room where a patient is ill is a most reprehensible practice. It not only fails to do any good, but is a source of very great annoyance to the patient and nurse. The nurse should always carefully disinfect her hands with corrosive sublimate after any manipulations of the patient, and it is well to frequently wash the mouth with Dobell's solution, 1 part to 3. The physician, when making his visit, should wear a cotton gown, and should be particularly careful to wash his hands in a solution of corrosive sublimate after his visit. Careful attention to these various details diminishes the chance of spreading the disease.

After the recovery or death of the patient, the mattresses and blankets should be sterilized by superheated steam. The floors and woodwork should be washed with a solution of corrosive sublimate, 1 part to 500. The walls of the room, if painted, should be washed in a similar manner. If papered, the paper should be removed. The ceiling should be whitened or tinted. All washable materials should be boiled for an hour. Books and toys had better be burned, as there is no way of disinfecting these articles properly. The experiments of Koch in 1888 proved conclusively that sulphurous acid gas, in the manner in which it was usually employed, was useless and that this method of disinfection was misleading. It has been shown in the laboratory that various micro-organisms exposed under a bell-glass to the fumes of sulphurous acid gas for twenty-four hours have been destroyed, yet this is no proof that sulphurous acid gas is an efficient disinfectant for apartments. The conditions in the rooms of a house are entirely different from those under a bell-glass. It is impossible to make a room in a house airtight, and for this reason sulphurous acid gas cannot be considered a reliable disinfectant in these cases. For the purpose of investigating the true germicidal value of sulphurous-acid-gas disinfection, a few experiments were made by the writer. Six test-tubes, containing each about 10 c.c. of the water from the tap, colored slightly with rosolic acid and plugged in the usual way, were exposed to the fumes of sulphurous acid gas for six hours in a room where there had been a case of diphtheria. The cotton plugs from three of the tubes were removed just before the room was closed and replaced as soon as the room was entered. It was found that the color of the rosolic acid was discharged by the sulphurous acid gas in all of them, proving that the gas had penetrated into the interior of the tubes. Cultures on gelatin-plates made from all these tubes showed a growth of the common organisms found in drinking-water. The number of colonies, however, that developed in the gelatin-plates was not so great as that which developed in the plates used for the control-experiment. In the second experiment six test-tubes—one of which contained a pure culture of the diphtheria-bacillus on cotton cloth; a second, containing a pure culture of the spirillum of Asiatic cholera pre-



pared in a similar manner; a third, a culture of the diphtheria-bacillus in bouillon; a fourth tube, containing a culture in bouillon of the spirillum of Asiatic cholera, of the diphtheria-bacillus, and of the bacillus pyocyaneus; a fifth tube, containing a pure culture of the diphtheria bacillus on blood-serum, and a sixth tube, containing the water from the tap—were used. These tubes, plugged in the usual way and the contents colored slightly with rosolic acid, were exposed to sulphurous acid gas for six hours in the presence of moisture. As in the previous experiment, the plugs were removed from three of the tubes. The color was found to be discharged from the rosolic acid in all of them. Cultures made from these tubes were found to contain all the organisms with which the initial tubes had been inoculated, with one exception, that of the tube in which there were three organisms. In this tube the spirillum of Asiatic cholera was not found. The growth was not very abundant in the inoculations made from these tubes. It therefore seems evident from this limited investigation that, while sulphurous acid gas may possibly inhibit the growth of pathogenic organisms, it certainly does not destroy them. Chlorin gas, when evolved in the presence of steam, is one of the most efficient disinfectants, but the objection to it is the fact that it ruins all metal with which it comes in contact. Fischer has proved by his experiments that if the spores of the anthrax-bacillus were exposed in moist air to chlorin gas they were destroyed after an exposure for one hour. The disinfectant known as electrozone, which is made by the decomposition of sea-water with a current of electricity, contains a large proportion of chlorin with a small quantity of iodine and bromine. Recent experiments prove that this agent possesses powerful antiseptic and germicidal properties. There can be no doubt regarding its deodorizing powers.

Steam under pressure is now considered to be the only proper method of disinfecting mattresses, wearing-apparel, and carpets. It is important to take the precaution of removing all leather and horn buttons, as these materials will not stand the high temperature. There are various forms of steam disinfecting apparatuses manufactured abroad, and those made in this country are modelled on the same plan. Geneste and Herscher of Paris manufacture a stationary and a movable apparatus. The stationary one consists of a large iron cylinder capable of sustaining a pressure of twenty pounds to the square inch. At each end of the cylinder, which is placed in a horizontal position, are cast-iron heads moving on hinges and adapted with screw bolts, so that they can be tightly closed. A tight partition-wall separates the ends, so that there can be no communication between the room where the infected articles are put in and that from which the disinfected articles are removed. At the bottom is a coil of closed steam-pipes for the purpose of heating the interior of the cylinder; at the top is a set of perforated pipes for introducing steam. An appliance for exhausting the air to increase the penetrating power of the superheated steam is attached to the apparatus. The movable one, the principle of which is the same as that of the stationary, is mounted on wheels and weighs about as much as a fire-engine. The steam is generated by a fire-box at the lower part of the cylinder. Henneberg of Berlin manufactures a similar movable apparatus, which has some slight improvements over that of Geneste and Herscher. These movable disinfecting cylinders can be used with great advantage in sparsely-settled districts, but are not adapted for use in a thickly-settled locality. Numerous experiments show conclusively that a temperature of about  $212^{\circ}$  F. for one hour will destroy all micro-organisms, and, therefore, where heat



can be properly applied without injury to the articles, it is the very best method of disinfection. In disinfecting by heat in one of these steam-cylinders it is important to raise the temperature to 250°, which means a steam-pressure of fifteen pounds to the square inch, for an hour, in order that the heat may penetrate into the interior of mattresses and rolls of blankets. The best method of disinfecting upholstered furniture is an open question. The only available method of accomplishing this end is by immersion in boiling naphtha for two or three hours. Although there are no reliable bacteriological experiments on this point, yet as most of the coal-oil products are disinfectants of greater or less value, and as it has been definitely settled that the thermal death-point of many organisms is about 160° F., it seems reasonable to suppose that this method of disinfection for these articles is of practical use. The vapor of formaldehyd, judging from the results of the experiments of Vaillard and Lemoine, is a germicide of some value. The apparatus required is inexpensive and its use not difficult. More extended experiments, however, are necessary before the efficacy of this mode of disinfection can be absolutely accepted.

**Symptomatology.**—The period of incubation of diphtheria is from two to three days. The disease is ushered in by a slight chill and a general feeling of malaise. In children the onset in certain instances may commence

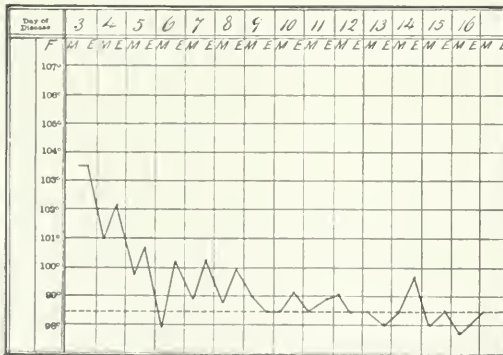


FIG. 599.—Temperature-chart in diphtheria without antitoxin.

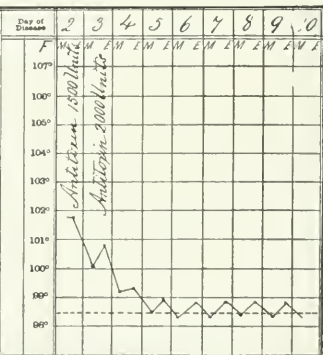


FIG. 600.—Temperature-chart in diphtheria with antitoxin.

with a slight convulsion. There is a feeling of pain and soreness in the throat; dysphagia is not a prominent symptom at the commencement of the attack. There is a peculiar dark-red appearance of the mucous membrane of the mouth which is characteristic of the disease, and, although not always seen, yet it is sufficiently common to be classed as one of the symptoms. At the end of twelve to twenty-four hours a small patch of membrane of a grayish or dirty-white color appears. This membrane may extend very rapidly, so that in the course of twenty-four hours the tonsils and uvula may be covered by it. Sometimes the membrane becomes gangrenous and there is an extremely disagreeable fetid odor from the patient. At this stage a profuse nasal discharge may appear; and if the membrane extends and the patient becomes septic, spots of ecchymosis appear on various parts of the body. These spots of ecchymosis are of very grave import. Few cases in which these symptoms appear recover. The difficulty of swallowing now increases; the patient is in a listless condition or may be delirious. Delirium of an active type is not a common symptom in diphtheria, although it sometimes occurs. An eruption resembling scarlet fever may appear in the

later stages. Hemorrhages may occur from the nose and mouth. The temperature, as a rule, is not much elevated, but in certain instances, on the second or third day of the attack, may rise to 104° F. The accompanying charts (Figs. 599, 600) give the temperature in diphtheria without antitoxin and with antitoxin. In some instances the temperature may be subnormal. A subnormal temperature is greater cause for anxiety than a moderately elevated one. The pulse is rapid and weak and does not always bear any relation to the temperature. Sometimes the pulse is very slow; and when this occurs it is an indication of the profound impression of the toxin of diphtheria upon the nervous centers. There is anorexia and, frequently, nausea and vomiting. Diarrhea is frequent, but it is not a constant symptom. In the laryngeal cases it is the exception rather than the rule that any membrane is visible in the mouth. There is marked stenosis of the larynx, characterized by a cyanotic hue of the face and by marked retraction just below the xiphoid cartilage. Supraclavicular retraction is also a prominent symptom, more marked in older children and young adults. The patient is restless, is constantly opening his mouth in the vain attempt to get air into the lungs. In adults retraction of the thoracic walls is not a very marked symptom. Attacks of dyspnea may occur very suddenly in the course of a mild attack of the disease. A peculiar harsh, brassy cough is a symptom of very frequent occurrence in laryngeal diphtheria. These attacks of suffocation are sometimes relieved by the expulsion of large pieces of membrane.

In the acute stage of diphtheria death is caused by either laryngeal stenosis or by the toxin generated from the growth of the bacilli. In the later stages of the disease or during convalescence a fatal issue is due to the action of the toxin on the nervous centers. Pneumonia and broncho-pneumonia are very frequent complications in the course of diphtheria. A streptococcal infection, abscess of the cervical glands, and a purulent inflammation of the joints may occur. Inflammation of the middle ear not infrequently is observed. In the later stages or during apparent convalescence paralysis very frequently appears. Palatal paralysis is frequently seen, characterized by a nasal voice and by the passage of fluids through the nose during the act of swallowing. This form of paralysis may be so marked that there is inability to swallow a sufficient amount of food, and the patient is in danger of dying from inanition. Ocular paralysis also frequently occurs, characterized by inability to read, dilated pupil, and also in certain instances by double vision. There may also be a general paralysis, in which the patient lies in a listless state in bed, unable to raise his head or to move his arms and legs beyond a limited extent. There is sometimes a peripheral neuritis, in which the pain and discomfort are very marked. Paralysis of the pneumogastric nerve, characterized by obstinate vomiting and failure of the action of the heart, is a frequent cause of death during apparent convalescence from the disease.

**Diagnosis.**—The discovery of the bacillus of diphtheria by Klebs, in 1883, and the further study of this organism by Löffler, have given us a ready method of diagnosis by the aid of bacteriology. Much has been said regarding laboratory diphtheria and clinical diphtheria: clinicians having claimed that, in certain cases where the membrane in the fauces had the characteristic appearance of a diphtheritic membrane, the bacteriologists failed to detect the specific organism of the disease. As a matter of fact, from personal study of something over 3000 cases of diphtheria, both clinically and bacteriologically, it seems to me that the failure to detect the organism has occurred so seldom that it does not invalidate the accuracy of a bacteriological diagnosis. If the cultures are taken properly, if the culture-medium

is in a suitable condition, and if the staining is done *secundum artem*, the failure to detect the organism very rarely occurs. A very great source of error is the fact that when taking the culture the swab or the platinum needle is rubbed over the surface of the membrane in the very position where the organisms are most likely to die. The edge and, if possible, the under surface of the diphtheritic membrane are the proper places from which to take the cultures. It is also well to take a second culture from the secretions of the mouth. In nasal diphtheria where no membrane is visible, the profuse secretion from the nose is invariably found to be loaded with the bacilli. A second source of error is the use of an antiseptic gargle a short time before the culture is taken. Practical experience has shown that when this is done the bacilli of diphtheria are not, as a rule, found in the culture-medium, although other organisms, such as cocci and streptococci, may be present.

The organism that causes diphtheria, not only in human beings but in the lower animals, is a small bacillus, straight or slightly curved, with rounded

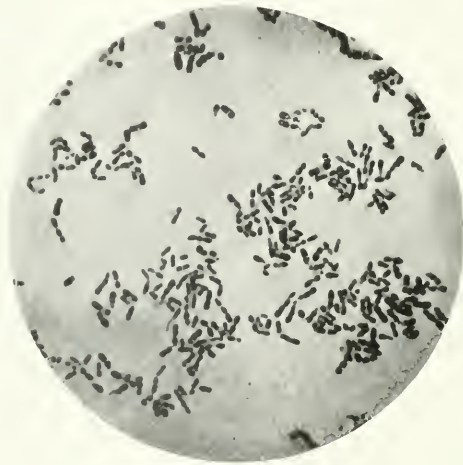


FIG. 601.—Bacillus diphtheriae, from a culture upon blood-serum;  $\times 1000$  (Fränkel and Pfeiffer).

ends, having a diameter of  $0.5$  to  $0.8\mu$  and from  $2.5$  to  $3\mu$  in length (Fig. 601); or, in other words, the length of this organism is about one-half that of the diameter of a red blood-corpuscle. This organism requires a peculiar stain, which is known as Löffler's methylene-blue, consisting of a saturated alcoholic solution of methylene-blue (30 c.c.), and of a watery solution of caustic potash, 1 part to 10,000 (100 c.c.). Hunt's differential stain is of great assistance in doubtful cases. This stain is composed of a watery solution of methylene-blue, a 10 per cent. watery solution of tannic acid, and a dilute watery solution of methyl-orange as a counter-stain. When the bacillus of diphtheria is stained by this method the pole-granules are brought out with great distinctness, while the body of the organism is of a light greenish-yellow color. So far as is known, no other organism presents this peculiar appearance when stained in this way. The bacillus of diphtheria is an aerobic, non-motile, non-liquefying organism. It does not form spores, which has an important bearing on the subject of disinfection. Although this organism grows on all the usual culture-media, the growth is more characteristic on Löffler's mixture, which is composed of 3 parts of blood-serum and 1 part of bouillon containing 1 per cent. of peptone, 1 per cent. of grape-sugar, and one-half of 1 per cent.



of sodium chlorid. On this culture-medium, at the temperature of the blood, the growth is very abundant, so that at the end of twenty-four hours small, round, elevated colonies of a grayish-white color and dry appearance will be seen. In laryngeal cases of diphtheria where no membrane is seen, cultures from the mouth invariably give a negative result. If the case requires operation, cultures from the intubation-tube or from the tracheotomy-tube, as a rule, show the presence of the bacillus. The fact that in these laryngeal cases a negative result is obtained, has led many to throw discredit upon this method of diagnosis; but a consideration of the anatomy of the parts must lead one to the conclusion that we should not expect to find the organism in these cases, for the false membrane is situated so far down in the larynx that it is impossible to reach it. Another point of interest that has been proved by clinical experience is the fact that these laryngeal cases, unless associated with nasal diphtheria, are not particularly infectious.

The statement has been made that diphtheria-bacilli may be found in the throats of healthy individuals who have been exposed to diphtheria; and while this is true in certain instances, it is so rare that very little weight should be given to it. The result of the examination of the throats of thirty nurses on duty in the diphtheria-wards of the South Department of the Boston City Hospital proved the presence of this organism in only one instance. The existence of an organism resembling the bacillus of diphtheria found in healthy throats, and known as the pseudo-diphtheria-bacillus, has been used as an argument against the accuracy of this method of diagnosis; but this organism is so seldom found that it is not a very important factor. It has also cultural peculiarities which assist in its differentiation from the true diphtheria-bacillus. Abbott has made a bacteriological study of 53 cases of simple sore throat, and in only 4 of these was a bacillus found which resembled that of diphtheria. The examination of cultures from 130 non-diphtheritic throats, made by the writer, showed that the existence of this bacillus was not sufficiently frequent to be an element of error in bacteriological diagnosis. In the cultures from these 130 throats, bacilli of many varieties were found; but in no instance was an organism seen that with care would be likely to be mistaken for the bacillus of diphtheria.

The bacilli of diphtheria may be present a long time after recovery, and when this occurs the individual must be considered a source of danger, unless it has been shown by repeated experiments on guinea-pigs that the organisms are non-virulent. The length of time that the bacillus continues after the disappearance of the membrane varies in each case. Instances are reported in which positive cultures were obtained sixty days after the disappearance of the membrane. The organism remains much longer, as a rule, in nasal cases. The average length of time is about ten days, as proved by an analysis of 1972 cases treated at the South Department of the Boston City Hospital.

**Prognosis.**—Diphtheria must be considered an extremely fatal disease, the percentage of mortality in severe epidemics being as high as 50. In Boston, from 1878 to 1894, the highest death-rate of cases reported to the board of health in any one year was 35.7 per cent.; the lowest death-rate for any one year was 26.44 per cent., with an average of 30.7 per cent. As these figures are based on 24,813 cases, the fatality of the disease is evident. The prognosis, even in mild cases, must always be guarded. When there is extensive membrane, profuse nasal discharge, and marked septic odor, the prospect of recovery is very slight. A gangrenous membrane is cause for an unfavorable prognosis. The laryngeal cases that come to operation, in certain instances succumb to broncho-pneumonia; in others, death



is caused by extension of the membrane into the bronchi; the prognosis, therefore, in these cases, must be doubtful. The paralysis that occurs as a late symptom, if the muscles of respiration are not affected, generally ends in recovery. Failure of the action of the heart, characterized by a slow pulse, is a very grave omen; few cases of this nature recover. Degeneration of the pneumogastric nerve, characterized by persistent vomiting, irregular respiration, and a slow and irregular pulse, renders death certain. Spots of ecchymosis are very unfavorable symptoms, and epistaxis is of the gravest import. Sepsis, both in the operative and non-operative cases, is the forerunner of death. After apparent convalescence has commenced, the liability to failure of the action of the heart must be considered. Convalescence is always slow and tedious in the severer cases.

**Treatment.**—As diphtheria is a depressing disease, alcoholic stimulation should be commenced at the outset. The quantity of alcohol that a young child will take with positive benefit in a severe attack is surprisingly large. Whiskey or brandy must be given. It is well to commence in severe cases, in a child from one to two years of age, with a dose of from one to two drams every four hours, watching carefully the effect on the pulse and on the general condition. Digitalis should also be administered in appropriate doses early in the disease. Strychnia may be given in the later stages if there are indications of commencing heart-failure. When there is a great collection of mucus in the air-passages, atropia sometimes proves to be of great benefit. In cases of collapse the use of nitro-glycerin sometimes gives marked relief. Mercuric chlorid in small doses has been given apparently with advantage in a certain number of cases.

Antitoxin, however, is the most important agent in the treatment of diphtheria, and must be administered early in the disease. The healing-serum has been in general use some three years, and the results obtained from it are as favorable to-day as they were when the attention of medical men was first called to it. The animals that are to furnish antitoxin are rendered immune, so that the diphtheria-toxin has no effect on them. The toxin is prepared by cultivating virulent diphtheria-bacilli in bouillon for one month at a temperature of 37° C., or 98.5° F., so that the poison may accumulate. Before commencing to prepare the toxin the virulence of the diphtheria-bacilli must be tested by its effect on guinea-pigs. A procedure requiring less time has been advocated by MM. Roux and Yersin. This method consists in growing the cultures in a current of moist air. It must be borne in mind that in the preparation of antitoxin the bacilli of diphtheria are not used; but the toxin caused by their growth, the specific poison caused by them, is used. Toxin thus prepared should be of such virulence that one-tenth of a cubic centimeter should kill a guinea-pig weighing 500 grams in from twenty-four to forty-eight hours. Fränkel first rendered guinea-pigs immune to diphtheria by injecting pure cultures of the diphtheria-bacillus which had been sterilized at 70° C. Since then Behring has recommended a mixture of toxin and Gram's solution of potassic iodid.

Burger and Wasserman arrived at satisfactory results by growing a culture of the diphtheria-bacillus in a bouillon made from the thymus gland. This culture had been exposed to a temperature of from 65° to 70° C., during a quarter of an hour. The method which has given the best results is that used by Roux and Vaillard in their researches on tetanus. This consists of the addition of three parts of Gram's solution—consisting of iodine one part, potassic iodid two parts, and water 300 parts—to one part of the toxin. The injection is to be repeated after a few days, and either the dose

of the mixture must be increased or the proportion of Gram's solution diminished. A little later the toxin can be given pure. It is sometimes necessary to omit the injection for a time if the animal is losing in weight.

Dogs have been rendered immune to diphtheria by many experimenters, among the number Bardach and Aronson. Sheep and goats are quite sensitive to the action of the diphtheritic poison. The immunization of milk-animals, such as cows and goats, is of particular interest from the fact that the milk of these animals has a certain antitoxic power. Of all the animals capable of furnishing great quantities of the antidiphtheritic serum, the horse is the most easily rendered immune. He bears the toxin much better than any of the animals to which allusion has just been made. By injecting gradually increasing doses of the toxin at various intervals the horse, in two months and twenty days, is rendered immune—that is, he can receive from 200 to 300 c.c., according to his weight, of toxin of definite strength without disturbance. The serum from this animal has a certain protective power, which must be determined by experiments on guinea-pigs before it is ready for use.

The curative action of antitoxin has not been satisfactorily explained; but it appears from numerous experiments that this agent does not destroy the toxin, but that its remedial power is due to stimulation or some other special action on the tissue-cells. If, however, the cells have become so damaged by the action of the toxin of diphtheria that they cannot respond to the stimulation of the antitoxin, the remedy fails to accomplish good. This is a powerful argument in favor of the early administration of the healing-serum. The remedial power of antitoxin is also restricted to a certain degree by its inability to combat the streptococous infection, bronchopneumonia, and other complications referable to secondary infection. In some of the experiments made for testing the action of antitoxin, diphtheria was caused in female guinea-pigs by rubbing pure cultures of the diphtheria-bacillus on the excoriated surface of the vulvæ. In these cases the pigs recovered if the serum was injected before the inoculation, otherwise they died. A membrane was formed at the point of inoculation, but there was very little constitutional disturbance. After the second day the false membrane became detached and repair of the mucous surface commenced. In these experiments the protected animals received one five-thousandth part of their weight of the serum. Other experiments were those in which guinea-pigs were inoculated in the fauces with pure cultures of the diphtheria-bacilli. Guinea-pigs inoculated in this way died in three days if not protected by the serum.

In February of 1894, after the beneficial effects of antitoxin on animals had been proved, as the preceding brief *résumé* shows, the treatment of diphtheria by this method was commenced in the Children's Hospital in Paris. During the years from 1890 to 1893, inclusive, in this hospital 3971 cases of diphtheria were treated, with a death-rate of 51.71 per cent. From February to July 24, 1894, 448 cases were treated by antitoxin, with a death-rate of 24 per cent., a diminution of more than one-half. It should be said that all the cases treated by this method were extremely severe in their nature. It must also be borne in mind that in many of the cases there was in addition to the diphtheria-infection a streptococous infection which, as has been shown, has a nullifying effect on the benefit of the antitoxin. The effect on the local lesions in the throat was similar to that observed in the experiments on guinea-pigs.

It has been claimed by the opponents of antitoxin that diphtheria has of

late years assumed a less virulent type, and that many cases are now recognized by a bacteriological examination which were not so classed a few years ago. Baginsky, director of the Emperor and Empress Frederick Children's Hospital of Berlin, states emphatically that it is untrue that since the introduction of the serum-treatment diphtheria has assumed a less virulent type. On the other hand, he says the most malignant forms have been treated by him successfully with the healing-serum. He says for the six months ending June, 1896, the percentage of mortality (excluding moribund cases) was 8.22, as compared with a mortality of 40 to 50 per cent. a few years ago. Baginsky also states that between March 15, 1894, and March 15, 1895, the death-rate in his service in cases treated by antitoxin was 15.6 per cent., and that during the time when the supply of serum gave out in the months of August and September, in the same hospital, the death-rate rose to 48.4 per cent. It has been noticed by many observers that during the warmer months diphtheria, as a rule, does not assume so virulent a type as during the colder months; and the fact, therefore, that in the former period, when antitoxin was not used, the death-rate was nearly three times as great as when it was used, seems to be a sufficient answer to the statement that antitoxin statistics are unreliable because based on mild forms of the disease. Korte says that there was an increase from 33.1 per cent. when the serum was used to 53.8 per cent. when it was not used. Gaughofer noticed an increase from 12.7 per cent. with serum to 53.2 per cent. without. Heim found that the mortality rose to 65.6 per cent. without serum as compared with 22 per cent. with serum. In an epidemic at Trieste the fatality rose to 50 per cent. when the supply of serum failed, as compared with 18.7 per cent. when it was used. As these statistics are based upon cases occurring in the same epidemics, the argument that antitoxin-statistics are unreliable because based upon the mild forms of diphtheria is untenable.

In the Boston City Hospital, from February, 1891, to February, 1894, when antitoxin was not used, there were 1062 cases of diphtheria treated, with 493 deaths, giving a percentage of 46. As this embraces a period of three years, the type of the disease might change considerably. In the South Department of the Boston City Hospital, for a period of thirteen months, from September, 1895, to October, 1896, there were 1972 cases treated with antitoxin, and of these 1706 were discharged well, 266 died, giving a percentage of mortality of 13.4. If the deaths of the 70 patients who were admitted in a moribund condition are eliminated, it would bring the death-rate down to 10.3 per cent.

Mackenzie gives the death-rate in cases of laryngeal stenosis without operation as 90 per cent. Although these cases are not stated to be diphtheria, yet it is safe to conclude, in the light of our present knowledge, that nearly all of them must have been diphtheria. Of 260 cases of diphtheria with marked laryngeal stenosis treated with antitoxin at the South Department of the Boston City Hospital, 60 were relieved of this symptom without operation; two died. The cause of death in one case was broncho-pneumonia, and in the other cardiac failure. In addition to the use of antitoxin, some of these cases were placed under steam- and others had calomel-fumigation. While these measures relieved temporarily the urgency of the symptoms, the permanent relief was due to antitoxin, judging by the experience in pre-antitoxin days. In cases of intubation, antitoxin has been of very great benefit. Waxham, of Chicago, in his monograph on intubation, states that of 150 cases collated by him, previous to the use of antitoxin, the percentage of recoveries was 27.33. O'Dwyer, of New York,



the originator of intubation, reports in the *Medical Record* of October 29, 1887, 50 cases with 12 recoveries, giving a percentage of 24. As these cases occurred in private practice, it is reasonable to suppose that the operation was performed early, a condition that does not always occur in hospital practice, because patients are sent to a hospital as a last resort. In the Boston City Hospital, for the year ending January 31, 1895, there were 89 intubations and 74 deaths, giving a percentage of recoveries of 16.8. These cases did not have antitoxin. In the South Department, for the thirteen months ending October, 1896, there were 200 intubations where antitoxin was administered, with a percentage of recoveries of 46.5. If the percentage of recoveries in cases occurring in private practice where antitoxin was not used is compared with that of hospital cases at the South Department where antitoxin was used, it will be seen that the percentage of recoveries in the hospital cases is considerably larger than that occurring in private practice. If hospital cases before the days of antitoxin are compared with hospital cases after the use of this agent, it will be seen that the percentage of recoveries has been increased from 16.8 to 46.5. In intubation cases the use of antitoxin has shortened the length of time that it is necessary to wear the tube.

The question of conferring immunity on individuals who have been exposed to diphtheria, by injection of antitoxin, is a very interesting and important one. The results thus far obtained seem to prove that an attack of the disease may be prevented by the early administration of the healing serum. In an outbreak of diphtheria occurring in institutions, the immunization of all persons exposed to the disease should be strongly advocated. The time that immunity can be conferred is short, being about thirty days. A small dose, 200 to 300 units, is required.

**Injurious Effects of Antitoxin.**—Eruptions of various kinds following the use of antitoxin have been observed. These eruptions can be classified as urticaria, erythema, a papular eruption, and an ecchymotic eruption, which must be distinguished from the spots of ecchymosis occurring as an early symptom in severe cases of diphtheria; a punctiform eruption resembling scarlet fever, and an eruption resembling that of measles. The first four eruptions are sufficiently characteristic not to present any very great difficulties in diagnosis; but the last two so closely resemble eruptions of scarlet fever and measles that the most careful examination is required to make a definite diagnosis, and in some instances it is absolutely impossible.

In the scarlatinal form of eruption, the absence of vomiting, a normal temperature, no hardness of the palms of the hands or the tips of the fingers, the fact that the papillae of the tongue are not enlarged, and the absence of any eruption in the throat, are the cardinal points on which the differential diagnosis must be made. In the measles-like eruption the diagnosis must be based upon its transient character; that there is no rise in temperature; that the eruption appears first on the extremities; that there is no coryza; that there is no cough; no eruption in the mouth; no eruption behind the ears. In a small number of cases joint-pains, resembling articular rheumatism, have been noticed. These joint-pains, although a source of considerable discomfort to the patient, have not been sufficient to cause any great amount of anxiety and have been followed by no serious results. In a very few instances abscesses have occurred after the injection of antitoxin; but the number is so small that it is hardly worthy of consideration, being no greater than would follow a large number of subcutaneous injections of morphia. It has been stated that albuminuria is caused by the use of antitoxin, but the observers who have made these statements have lost sight of the fact that



albuminuria very frequently occurs in the course of diphtheria; and they also have not appreciated the well-recognized fact that the toxin of diphtheria may cause albuminuria, as is proved by the condition of the kidneys of guinea-pigs that have died from injections of pure cultures of the diphtheria-bacilli. Of the 1972 patients treated with antitoxin at the South Department of the Boston City Hospital, 674, or 34.1 per cent., had albuminuria, which proves that antitoxin does not increase the frequency of albuminuria, as this is not as large a percentage as occurs in cases not treated with antitoxin. In 173 cases the urine was examined before and after the administration of antitoxin. Of these 173 cases, it was found that in 99 instances albumin was absent both before and after the administration of antitoxin, which was without doubt due to the fact that the healing serum was administered before the diphtheritic membrane had increased sufficiently to generate toxin enough to cause albuminuria. In 33 cases the albumin was about the same, in 25 the albumin was diminished, which seems a sufficient answer to the claim that antitoxin causes albuminuria. In 16 cases the albumin was increased, but not to a sufficient extent to cause any special anxiety. Antitoxin has no influence on the later symptoms of diphtheria caused by the action of the toxin, such as paralysis, cardiac failure, and nerve-degeneration, but it does have a marked effect in preventing the formation of toxin and the consequent appearance of these symptoms. In Pepper's "Theory and Practice of Medicine," published in 1893, the percentage of post-diphtheritic paralysis in a large number of cases is given as 40. In the Homerton Hospital, England, of 1071 cases treated without antitoxin, paralysis occurred 125 times, giving a percentage of 11.6. Of the 1972 cases treated with antitoxin at the South Department of the Boston City Hospital, paralysis occurred in about 115 instances, 5.8 per cent. The conclusion, therefore, that antitoxin does not cause paralysis, as has been asserted, is justifiable.

In conclusion, then, it can be confidently asserted that antitoxin is a remedial agent of great value in the treatment of diphtheria; that its use does not cause albuminuria; that it does not predispose to paralysis, and that the eruptions and the joint-pains that sometimes follow its administration are not of sufficient importance to preclude its use.

The dose of antitoxin has been variously stated by different observers. The quantity must depend upon the number of antitoxin-units that the specimen used contains. As an initial dose, from 2000 to 3000 units, depending upon the age of the patient, should be given. If there is not a marked improvement in the appearance of the throat and in the general condition of the patient at the end of eight hours, a second dose should be given. If at the end of twenty-four hours the membrane has not commenced to roll up at the edges, if the swelling of the cervical glands is not diminished, if there is a profuse nasal discharge with a septic odor, a third dose should be given, and in certain cases a fourth, or even a fifth, dose may be required.<sup>1</sup>

The method employed by Behring and Ehrlich in testing the strength is the one now in general use in Germany. In the *Boston Medical and Surgical Journal* of December 17, 1896, Behring's method of testing the serum is thus described:

"Diphtheria-toxin is injected subcutaneously into a series of guinea-pigs

<sup>1</sup> Experience has much increased the concentrated potency of the serum while proving its innocuousness; and it is recognized that poor results in the past were often due to the timid and tardy use of inadequate doses. Better results are, therefore, to be hoped for.

to determine accurately the smallest quantity of toxin which is fatal to the guinea-pig. When this has been determined the toxin becomes the test-toxin. A given quantity of serum to be standardized is mixed with ten times the minimum fatal dose of the test-toxin and injected subcutaneously into guinea-pigs of nearly the same weight as those used in standardizing the toxin. If no local edema nor infiltration appears, if, in other words, the guinea-pig is completely protected, the quantity of serum used contains one-tenth of an antitoxin-unit. This is best illustrated by an example, the test-toxin has been standardized and found of such strength that 0.039 c.c. is the minimum fatal dose. The serum to be tested is diluted with sterile normal salt solution until 1 c.c. contains  $0.0016\frac{2}{3}$  c.c. of serum. The serum and 0.39 c.c. of toxin are mixed and injected subcutaneously. If the guinea-pig remains permanently well and shows no edema at the place of injection,  $0.0016\frac{2}{3}$  c.c. contains at least one-tenth of an antitoxin-unit. One c.c. would contain at least 60 units—that is, enough serum to completely protect 600 guinea-pigs from ten times the fatal dose of toxin. The antitoxic unit may thus be defined as being contained in ten times that quantity of any given serum which is required to neutralize ten times the minimum fatal dose of diphtheria-toxin when mixed with the latter and injected subcutaneously into a guinea-pig.”

Prof. H. C. Ernst employs the following method in testing the antitoxin which he prepares. This method is described by him as follows:

“A normal toxin is one of such a strength that .1 c.c. injected subcutaneously in a guinea-pig weighing 500 grams kills the animal in forty-eight hours; in other words, kills 5000 times its weight of guinea-pig. We call a normal antitoxin a serum of such a strength that .1 c.c. injected at the same time subcutaneously in a 500-gram guinea-pig with 1 c.c. (ten times the fatal dose) of normal toxin produces no effect; in other words, protects 50,000 times its weight of guinea-pig, and is, therefore, of a strength of 1 to 50,000. This is a serum that for practical purposes is marked “dose 10 c.c.,” or approximately sufficient to protect 100 pounds. When we find the serum tested in the same way of a strength of 1 to 100,000 or over, we mark it “dose 5 c.c.,” an amount approximately sufficient to protect the same weight.”

Many places have been selected for the site of the injection—the outer aspect of the thigh, the abdomen, the back, and the upper part of the thorax near the posterior axillary line. After trying these different places, experience has shown that the last-mentioned situation is the most desirable, because here the tissues are lax, there is no danger of entering a vein, and the patient can lie on the back or on one side without bringing any pressure on the inoculated place. If an abscess forms there is no danger of burrowing of pus, as might be the case in the thigh and back. The technique of the injection is as follows: The parts are thoroughly sterilized by washing with a solution of corrosive sublimate; a portion of the skin is pinched up and the needle plunged deeply into the subcutaneous cellular tissue, the antitoxin is then slowly injected. The puncture made by the needle is sealed by sterilized gauze and collodion. It is very important that the needle and syringe should be carefully sterilized by boiling. It is advisable to pour the antitoxin through sterilized gauze into the barrel of the syringe, rather than to attempt to draw it through the needle.

There are many different kinds of syringes in the market. Williams's syringe, which has an asbestos packing and is made of glass, is the one in use at the hospital, and it has proved to be well adapted for its purpose.

Lüer's syringe, which has a ground-glass piston accurately fitted, is a very satisfactory instrument. Koch's syringe is a very good instrument to use.

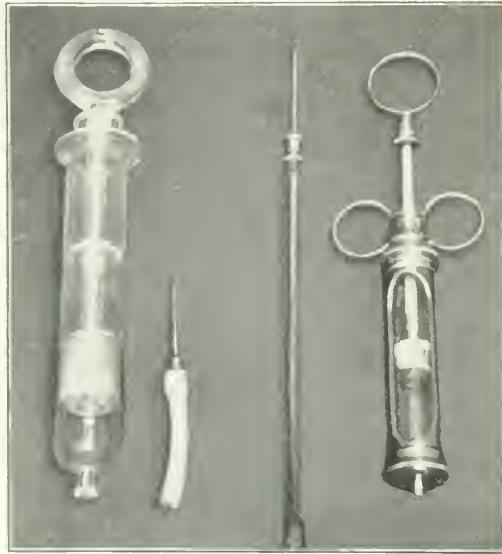

FIG. 602.—Antitoxin-syringes.

In selecting a syringe, it is well to choose one that has the needle connected with the barrel by rubber tubing. It makes very little difference

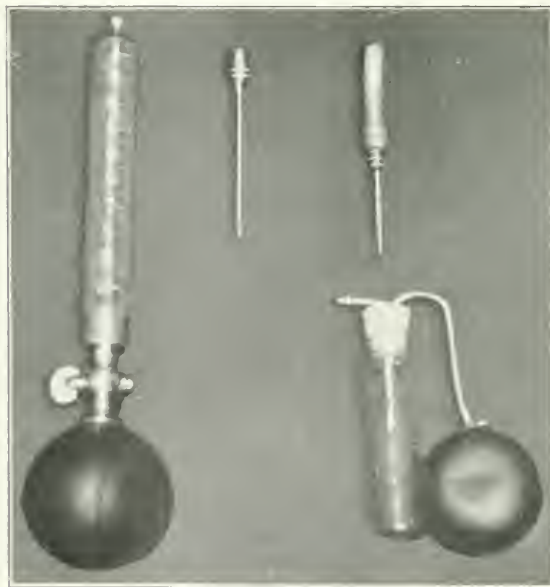

FIG. 603.—Antitoxin-syringes.

what kind of a syringe is used if the different parts are made of materials that can be sterilized by heat without injury. A comparatively small needle

should always be used. Figs. 602 and 603 represent the two syringes in general use.

In the treatment of moderate laryngeal stenosis occurring in diphtheria, recourse may be had to the inhalation of steam. A tent can be made over the bed and the steam generated in the ordinary croup-kettle. In hospitals a special apparatus for this purpose is connected with the steam-supply. Medicated steam sometimes seems to afford relief. The following mixture, in the proportion of one ounce to a pint of water, may be used with advantage in the croup-kettle :

|    |                       |             |         |
|----|-----------------------|-------------|---------|
| R. | Olei eucalypti,       | Apothecary. | Metric. |
|    | Acidi carbolici liq., | ℥j          | 30      |
|    | Olei terebinthinae,   | ℥j          | 30      |
|    |                       | ℥viiij      | 240.—M. |

Only a moderate amount of steam is required. The debilitating effect of a continued steam-bath is very great, and this is always to be avoided in the treatment of diphtheria. The air in the canopy must be simply saturated with steam, not oversaturated, as is frequently the case. The sublimation

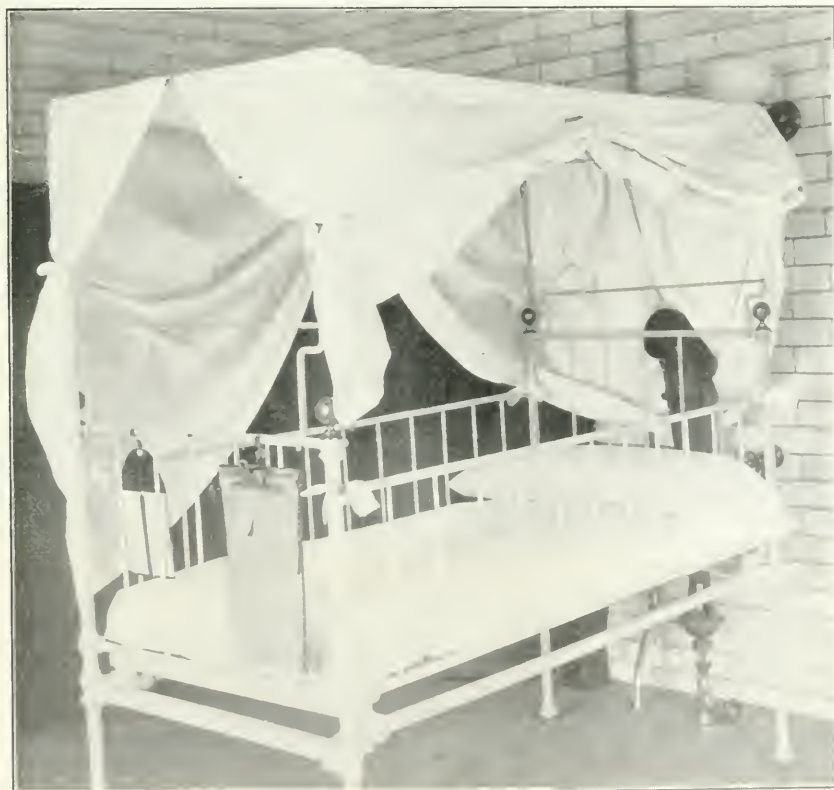

FIG. 601.—Steam-tent with sides raised, Boston City Hospital, South Department

of calomel often gives relief. A small alcohol-lamp, surrounded by wire gauze or perforated tin, with a pan on the top for the reception of the calomel, is the apparatus used. Five to ten grains of calomel are placed in the pan, and the quantity is repeated every thirty minutes for two or three times.



depending on the urgency of the symptoms. Care must be taken, however, not to continue this treatment for too long a time, as there is danger of causing salivation. Small doses of the syrup of ipecae, in addition to the measures just described, sometimes prove of benefit. Emesis, however, must not be caused.

Caustic applications to the throat have been advised, but their use is of doubtful advantage. The less the throat of a patient ill with diphtheria is irritated, the better. The experiments of Roux and Yersin show that the bacilli of diphtheria do not, as a rule, grow on sound mucous membrane, and, therefore, when the epithelium is removed by caustics and irritants, a fertile soil is prepared for the growth of these organisms. Irrigation with hot normal salt solution, or with a solution of mercuric chlorid, 1 part to

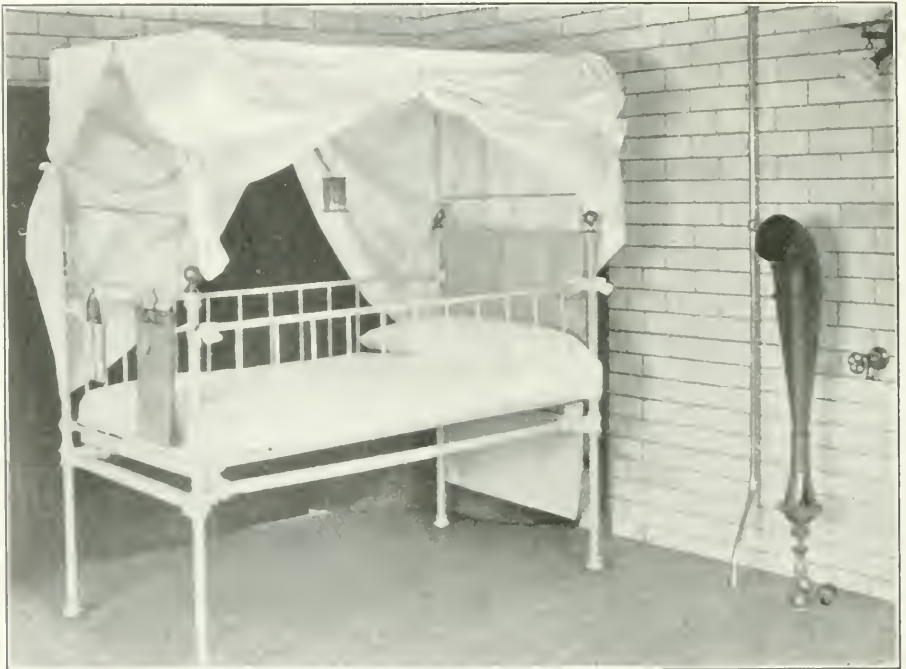

FIG. 695.—Apparatus for eulomel-sublimation, Boston City Hospital, South Department.

8000, or with a weak solution of chlorinated soda, every four hours, frequently gives much relief to the patient. This irrigation can be given by means of the fountain-syringe, with the patient either in the horizontal or vertical position. In nasal diphtheria the douche is of great advantage. By the irrigation all the loose membrane is removed, contributing much to the relief of the patient.

When there is marked dysphagia, spraying the throat with a 2 to 4 per cent. solution of cocain, a short time before food and stimulants are administered, is often of marked benefit, enabling the patient to take his treatment with a certain degree of comfort.

Painting the throat with a mixture of salicylic acid, twenty grains to the ounce of glycerin, is sometimes of advantage. The application of hydrogen-dioxid is sometimes beneficial. If there is much membrane, a strong solu-

tion is required. The application should be made with a mop. The nose can be sprayed with weak solutions of one, two, or five volumes.

In order to cause the disappearance of the bacilli after the membrane has disappeared, many things have been tried, but the results have not been very satisfactory. Spraying the throat with lemon-juice or with a 5 per cent. solution of antipyrin, or with a weak solution of mercuric chlorid, or with a ten-volume solution of hydrogen-dioxid, can be tried.

In laryngeal stenosis, characterized by great restlessness, a marked cyanotic hue, distinct clavicular and sternal retraction, operative interference is demanded. The choice lies between intubation and tracheotomy. O'Dwyer's tubes for intubation are in general use in this country. The apparatus consists of five tubes, suitable for children from one year to twelve years of age; the gag, the introducer, the extractor, and a scale indicating the tube to be used for a particular age. These tubes are plated with gold. The upper end of the tube has a head that rests on the ventricular bands and prevents the tube from slipping into the trachea; in the middle there is

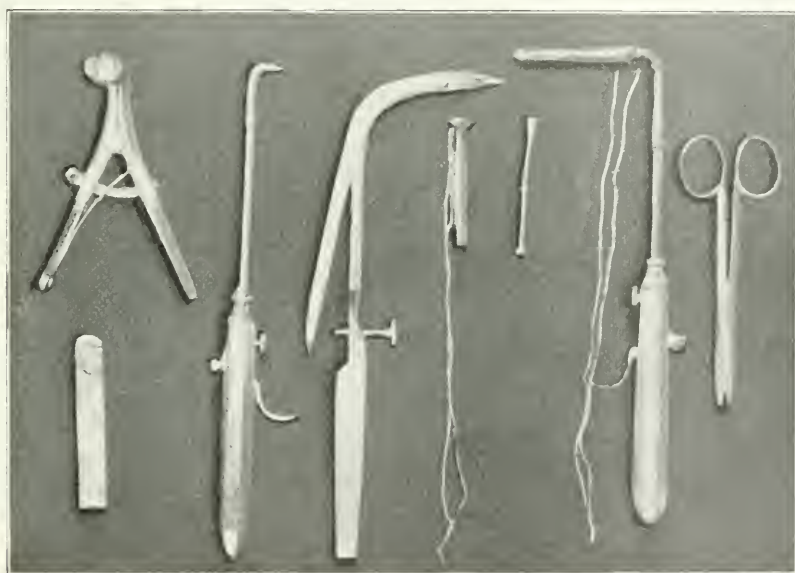


FIG. 606.—Showing the scale, the gag, the introducer, the extractor, a tube, the obturator, and the introducer with a tube attached.

a fusiform enlargement by which the tube is retained in the larynx. On the right side of the head is a small hole for the reception of a loop of silk. This loop of silk is to prevent the swallowing of the tube, if the first attempt at intubation is not successful. Each tube is fitted with an obturator, which is screwed to the introducer. The introducer consists of a handle and a shank; on the handle is a button, by pushing which the jaws at the end of the shank are pressed forward and the obturator disengaged from the tube. The extractor, which is curved, has at the distal end jaws which are opened by pressing on the lever in the handle.

Fig. 606 shows a tube attached to the introducer ready for use, a detached tube, the extractor, scissors for cutting the silk, the gag, and the scale.

Intubation is performed in the following manner: The patient is wrapped firmly in a blanket, so that he cannot move his arms, and then placed in a

horizontal position, with the head slightly raised. The mouth is held open by the gag, with its jaws resting on the molar teeth. Care must be taken not to have the cheek injured by the gag, and special care must be taken to prevent its slipping. The head must be steadied by the assistant who holds the gag. The operator takes the introducer in the right hand, with the index-finger around the hook on the under surface of the handle; the loop of silk passing over his little finger and his thumb resting on the button on the upper surface of the handle. The index-finger of the left hand is then passed down to the epiglottis, which is hooked forward; the tube is passed into the mouth, with the handle well down on the chest of the patient; when the epiglottis is reached by the point of the tube, the handle should be given an abrupt turn, so as to bring the tube into a vertical position. As soon as the tube is well in the larynx the button on the handle should be pushed forward, disengaging the obturator, which must now be removed, and the tube pushed into position by the index-finger. The loop of silk is passed



FIG. 607.—Intubation.

about the ear and the gag removed. If the tube is in the larynx, the patient will immediately commence to cough with a peculiar sound, which to be appreciated must be heard. If the breathing becomes easier; if the cyanotic hue disappears; if the retraction of the thoracic walls diminishes; if the loop of silk does not shorten, one may rest assured that the tube is in the larynx. After becoming satisfied that the operation has been properly performed, the gag is inserted a second time, the index-finger placed on the head of the tube, and one strand of the silk loop cut so that it can be removed. Remember that the finger of the operator must be a continuation of the posterior wall of the larynx; remember to make the abrupt turn; remember that no force must be used. If the tube is in the esophagus, no cough will be heard; there will be no relief in the breathing; the silk loop will commence to shorten as the tube passes down the esophagus. In certain instances intubation does not give relief, and tracheotomy must be done. If the tube becomes clogged by membrane, as is sometimes the case, it must be immedi-

ately removed. The first steps of an extraction are similar to those of an introduction. The extractor is passed into the lumen of the tube and the lever on the handle pressed so as to open the jaws, and the tube extracted by a reverse of the movements in introduction. Sometimes there is considerable difficulty in extraction, but by patience and gentleness the end can be accomplished. If the child coughs up and swallows the tube, the accident may cause considerable annoyance to the physician, yet it is not of serious import, for experience has shown that the tube is passed by the rectum in from twenty-four to forty-eight hours, without causing discomfort. No definite rule can be given regarding the length of time that the patient should wear the tube. It is well to remove it at the end of the third or fourth day, but it is frequently necessary to immediately re-insert it. In some instances three or four extractions and introductions may be required. The most favorable cases are those in which the child coughs up the tube at the end of the third day and does not require re-intubation.

The operation of tracheotomy is fully described in the article on Operations and in works on surgery.

In regard to the relative merits of tracheotomy and intubation, a few words may be said. It seems to me that intubation, in the majority of cases, is the better operation: First, because there is comparatively little shock; second, because there is no open wound to become infected; third, because the air in intubation enters the lungs through the natural channels, thereby diminishing the chance of broncho-pneumonia; and, lastly, because recovery is much more rapid after intubation than after tracheotomy, there being no granulating wound to heal. In adult life, tracheotomy is, perhaps, the better operation. Bourdillat gives the following statistics of recoveries after tracheotomy, by years: Under two years, 3 per cent.; between two and two and one-half years, 12 per cent.; two and one-half to three and one-half, 17 per cent.; three and one-half to four and one-half, 30 per cent.; four and one-half to five and one-half, 35 per cent.; over five years of age, 39.5 per cent.

Waxham, in his collation of 1072 cases of intubation, gives as the percentages of recoveries after intubation, by years, as follows: Under two years, 15.62 per cent.; between two and three years, 19.46 per cent.; between three and four years, 30 per cent.; between four and five years, 32.65 per cent.; between five and six years, 33.92 per cent.; over six years, 43.33 per cent. It will be seen, therefore, that under two years of age the percentage of recoveries after intubation was five times as great as after tracheotomy; and that in only one instance was the percentage of recoveries higher after tracheotomy than after intubation, and then the increase was very slight.

It has been claimed that an intubed child could not take sufficient nourishment, that he suffered from the lack of liquids, and to obviate this condition of things various measures have been suggested, such as rectal alimentation, the use of soft solids for food, and by what is known as the Casselberry method of feeding, which consists in placing the child on its back and lowering the head, so that the pharynx is on a lower plane than the larynx. When the child is placed in this position he can take a certain amount of food with comparative comfort. Nasal feeding, however, is by far the best method of introducing food into the stomach of an intubed child. It is not a painful procedure; it is not specially difficult to perform, and one has the satisfaction of knowing just how much food, how much stimulation, and what drugs are introduced. After the second or third introduction of the tube, as a rule, the child does not struggle and does not exhibit any indication of discomfort. The apparatus



tus in use at the hospital consists of a soft rubber catheter, in which is inserted a short glass tube, which in turn is attached to a rubber tube, and the rubber tube is connected with a glass funnel. The catheter having been well lubricated is slowly and carefully, without any force, passed through the anterior naris down into the esophagus. The funnel is elevated and about two ounces of water are poured into it, and then the requisite amount of milk, stimulants, and whatever drug may be deemed advisable to administer, followed by an ounce or two of water. The catheter is then removed quickly but gently. If the catheter is removed slowly its passage may cause vomiting, therefore it is important to remove it quickly. The condition of intubed



FIG. 608.—Apparatus for nasal feeding.

children fed in this way is very gratifying as compared with those fed in any other way. Nasal feeding is also of very great advantage in cases of post-diphtheritic palatal paralysis, and there is no doubt that lives have been saved by adopting this procedure when it was impossible for the child to take food in the natural way. Many cases might be cited in which death might have resulted either from inanition or from pneumonia caused by the introduction of food into the air-passages, if this method of feeding had not been used.

In diphtheria of the eye, the chief reliance must be placed on antitoxin, which should be administered heroically. The pupil must be dilated with atropia. The eye should be irrigated every two hours with a 2 to 4 per cent. solution of boric acid. In some instances the following ointment has seemed to be of use:

|    |                    |             |        |
|----|--------------------|-------------|--------|
| R. | Hydr. iodid rub.,  | Apothecary. | Metric |
|    | Cocaine muriatis,  | gr. j       | .065   |
|    | Atropie sulphatis, | gr. iv      | .260   |
|    | Petrolati,         | ʒj          | .260   |
|    |                    | ʒj          | 30.—M. |

A portion of this ointment the size of a small pea should be put in the eye every eight hours. The treatment of the later effects of diphtheria on the eye belongs rather to the province of the oculist than to that of the general practitioner. The action of antitoxin on the diphtheritic process in the eye is very marked, and the results following its use are very gratifying. The greatest attention should be given to keeping the eye clean. If only one eye is affected, the other must be protected with a watch-glass. It must be borne in mind that the object of treatment is to prevent the extension of the membrane and to cause its early disappearance; therefore all irritation of the conjunctiva is to be avoided. A patch of membrane that in the throat would not be of importance, in the eye might cause blindness.

The administration of food in the treatment of diphtheria must receive careful attention. Milk is the best article of diet, and should be given in quantities as large as the patient can be induced to take. Soups and broths may also be given. Soft solids are frequently grateful to the patient. In the later stages of the disease, cod-liver oil and iron should be given. Paralysis can be treated with strychnia, massage, and electricity. In the treatment of diphtheria, care must be taken not to exhaust the strength of the patient by over-zealous attempts to induce him to take food. The practice of giving food and drugs to a patient ill with an exhausting disease, every ten or fifteen minutes, is productive of much harm, and, therefore, cannot be too strongly censured.

# TUBERCULOSIS OF THE AIR-PASSAGES.

BY E. L. SHURLY, M. D.,

OF DETROIT, MICH.

## LARYNGEAL TUBERCULOSIS.

TUBERCULOSIS of the larynx consists of an ulcerative inflammatory process depending upon the presence and alterations of tubercular material in the soft tissues of the larynx. This material may appear as granular or nodular deposits, or as a more or less diffuse infiltration. There are two typical forms usually described: (a) An acute, inflammatory affection, described by Isambert and Friedländer as "acute tuberculous sore throat;" and by other observers as localized laryngeal tuberculosis. (b) A chronic process characterized more by infiltration and softening than by inflammation of the tissues. The former class has been by many authors considered a primary laryngeal affection, in the belief that the morbid process may originate and possibly remain in the larynx. Professional opinion, however, has been divided upon this point on account of the very frequent or almost constant implication of the lungs; although in rare instances, according to J. Solis-Cohen, no lesions have been found upon post-mortem examination in other organs of the body. The more chronic form is often denominated "secondary," because usually occurring subsequently to tuberculous disease of the lungs or other organs of the body. Between these two types there are many gradations according to the constitutional and local physical peculiarities—which also variously modify the course and character of the disease.

**Etiology.**—According to the consensus of professional opinion at the present time, the essential cause of laryngeal tuberculosis or laryngeal phthisis in all of its phases (as, indeed, of all other forms of tuberculosis) is the invasion of the tissues by the tubercle-bacillus of Koch; and to the action of this micro-organism is ascribed the whole pathogenesis of the disease. Although the numerous well-known and carefully-accepted laboratory experiments, besides other faithful work of reliable bacteriologists on this subject, leave little doubt concerning the accuracy of this doctrine, yet it does not supply to the clinician an adequate explanation of all the etiological or clinical features of this sometimes complex disease. While various vagaries in the vitality and growth of this micro-organism are sought to be demonstrated in the field of pathological histology in explanation of the diverse clinical effects ascribed to its presence, there still remains the knowledge of its notable failure to infect the larynx, except in from about 10 per cent. to 40 per cent. (according to various authors) of the cases of pulmonary phthisis, where certainly the conditions would seem exceedingly favorable.

The mode of invasion is supposed to be either from without through abrasions of the mucous membrane (exogenetic), or from within through the lymph- or blood-channels (endogenetic). J. Solis-Cohen believes that the

invasion is from without, and infers that generally "an acute laryngitis with some desquamation of epithelium affords an inlet to the germ." But if this were so, almost every case of pulmonary tuberculosis would be accompanied by laryngeal infection for obvious reasons; and, moreover, the laryngeal disease would be apt to occur anywhere about the structure, instead of (as we observe) in selected places; while the constant application of infected sputum to a continual succession of abrasions would prove an infallible method of infection. The comparative immunity of the larynx has been accounted for in two ways. One is that tubercle-bacilli are slow in developing and need not only a *suitable nidus* but *quiescence*, conditions which the larynx, from its exposed situation and constant movement in respiration, phonation, and coughing, does not afford; and the other is, that the abrasions of the mucous membrane of the larynx are so quickly protected, either by exudate or granulations—each of which is known to be if not quite bactericidal, at least very resistant—that a proper foothold, so to speak, for the micro-organism can only with difficulty be obtained. As to the first explanation we may remark that when the laryngeal membranes are in the least degree swollen, there must be numerous abrasions from friction of the parts, for according to Rice and Hodgkinson there is continual friction between the ventricular bands, the walls of the ventricles, and the vocal cords. Regarding the question of a resting-place, there is probably no place more attractive to micro-organisms for *quiescence* than the laryngeal ventricles, where even particles of dust will remain, when mixed with leukocytes or secretion, perhaps for days, and where (being rich in lymphatic tissue) the region would furnish abundant pabulum for the growth of tubercle-bacilli. Yet it is immune.

Concerning the second explanation there is little to be said, except that the defensive effects of the reparative process in this situation are probably no more active and effectual than in similar tissues in other localities.

A few years ago Dr. Gibbes and myself scarified the pharynx and epiglottis of several healthy monkeys and applied thereto sputum from tuberculous patients, without producing in any instance local tuberculosis. We also scarified in like manner the pharynx and epiglottis (and possibly the membrane covering the arytenoids) of two monkeys suffering from pulmonary tuberculosis, without the production of local infection. In this connection I might relate that a patient of mine suffering from pulmonary tuberculosis accidentally suffered from the lodgement of a piece of chicken-bone in the pyriform sinus of the larynx. In his effort and that of others to dislodge the foreign body the pharynx was considerably wounded, as was also the aryepiglottic fold and the covering of the arytenoid and supra-arytenoid cartilages. It was with some difficulty that I was able to remove the bone, owing to the impaction of some of its spiculae beneath the surface of the mucous membrane. As he came from a distance, considerable time had elapsed (about ten hours) between the period of the accident and the period at which I saw him, and in consequence there was considerable tumefaction of the region. I fully expected a development of secondary laryngeal tuberculosis on account of this accident, but no such phenomenon occurred. The man lived about eighteen months after this accident and was under my observation more or less of the time, but never presented any tubercular lesion of the larynx or pharynx that could be detected by the laryngoscope or by the observation of subjective symptoms. I regret to say that no post-mortem examination of the case could be obtained in order to verify microscopically this assumption. Therefore, it would seem that the moderate degree of invulnerability of the larynx to tuberculosis, or the invasion



and ravages of the tubercle-bacilli, if you please, must depend for explanation upon some other hypothesis or facts than can be ascribed to either the latent or oblique behavior of the tubercle-bacillus, or to the mere abrasion of the laryngeal mucous membrane under the circumstances usually set forth. While I would not unjustly underestimate the property of latency so generally recognized as belonging to tubercle-bacilli (Bollinger has shown that tubercle-bacilli may remain latent in bronchial glands for twenty years without losing their vitality<sup>1</sup>), nor the modifying effects upon their growth of "tissue-reactions," yet I believe with Unterberger not only that the rôle of the tubercle-bacilli in spreading disease is overstated, but that the independent powers ascribed to them have also been overestimated.

Neither will the addition of the "tubercular tendency" ("congenital tendency") serve to supply completely the missing etiological link, because there are so many cases of chronic laryngeal catarrh observed in persons who possess the tubercular tendency who go through life without becoming subjects of laryngeal tuberculosis; while on the other hand, in a considerable number of cases of tubercular disease, no tubercular or "scrofulous" family history, nor event of exposure to other cases, nor history of previous severe disease can be elicited. The accession of this disease, therefore, must await some definite bio-chemical or nutritional alteration of the part, of a more or less local character, before its particular pathogenesis can be established. Undoubtedly, as Cohen says, "it is not improbable that certain bacillary elements exist normally in the tissues of the healthy individual, which under certain conditions undergo conversion into tubercle-bacilli."

Gibbes, Mittendorf, and others describe forms of tubercular tissue differing in histological characters from one another. The second author indeed asserts, upon the basis of numerous bacteriological and histological examinations, that tubercular tissue, called technically "crude" or "healthy," is very frequently devoid of tubercle-bacilli.

Regarding the so-called secondary variety there can be no doubt that the toxic agent arrives at the larynx through the lymph-channels, and depends for its local development upon the continuous and enduring alteration of the cellular elements either created or maintained by the lympho-cellular metabolism which belongs to the general disease, whether the tubercle-bacilli or some specifically depraved cellular or protoplasmic elements be regarded as the initial ferment or not. In the light of recent investigation upon the nature and powers of the various proteids of the animal body in health, as well as in disease, it is, of course, very difficult to understand the early steps in the development of *any* general disease of an infectious or septic character; especially as the exact relation of the microphytic ferments to the various proteids upon which they are supposed to operate has not yet been definitely settled.

"The effect on the body-cells of the presence and growth of tubercle-bacilli varies considerably and depends upon the *number* and *virulence* of the germs present, the *character* of the tissue in which they lodge, and the *vulnerability* of the *individual*" (Prudden and Delafield).

Ever since Virchow pointed out the wonderfully independent and specialized functions of the cellular elements of the body, both physiology and pathology have made important progress; but as yet the real mutations, both in health and disease, of these incessantly working components have escaped positive or complete detection. Their exact source and manner of regeneration are as yet unknown, as well as the definite chemical composition of all

<sup>1</sup> *Brit. Med. Journ.*, Oct. 17, 1896, p. 64.

their various protoplasmic contents; while their relation to, and influence upon, the body-fluids, such as blood and lymph, are still to a great extent subjects of speculation. Hence, until further progress is made in this direction, we shall be unable to say whether chemical changes in *them* precede or follow the presence and operation of bacteria; in other words, whether toxins or bacteria constitute the initiation of morbid processes, and whether the defensive or immunizing agency resides altogether in the mobile or fluid tissue (blood and lymph), or partially or essentially in the formed tissues and secretions of an apparatus or organ.

Of predisposing causes of the so-called inflammatory varieties, the most striking are undoubtedly frequent attacks of acute and chronic laryngitis. Consequently such cases show much variation in their course, according to the circumstances of the previous disease and the amount and extent of local inflammation of the larynx. The local disturbance, of course, is very much aggravated if accompanied by miliary tuberculosis (in which event it is apt to be very rapid and extensive); also if connected early with pulmonary lesions of even limited area, such as localized broncho-pneumonitis (Cohen) or broncho-pulmonitis. But with the latter class of cases the march of the local disease is usually slower and milder.

Tuberculosis of the pharynx or tongue may in rare cases extend to the larynx. The larynx may also become infected from tuberculosis of the tonsils, which it is said (Hans Ruge) occurs much more frequently than is supposed, and is difficult to demonstrate clinically because ulceration is so often absent. An extension to the larynx from the cervical lymphatic glands may occur—although, perhaps, not frequently—also from tuberculous caries of the teeth. Schatz has reported cases of tuberculous caries of the teeth with involvement of the cervical glands where tubercle-bacilli were found in the cavities of the teeth, while their floors showed microscopically granular tissue containing giant cells.

Constitutional syphilis and the excessive use of alcohol are common determining factors in the origin of laryngeal tuberculosis. Indeed, the former disease may occur concurrently with it.

Inordinate and improper use of the voice is also a common predisposing factor.

*Age.*—Laryngeal phthisis is generally observed in persons between the ages of eighteen and thirty-five years. It may occur, however, in infancy or childhood (Cohen, Beverly Robinson, Bosworth), or rarely in old age (Bosworth) as a primary affection.

*Sex.*—Males are more liable than females to suffer from the disease; a fact so striking in relation to the occupation and domestic or social history of the two sexes in general, that one is led to place even additional emphasis upon the exogenetic over the hemogenetic or endogenetic sources of the morbid process.

*Occupation.*—Vocations requiring the use of the voice in the open air (peddlers, etc.), exposure to noxious or dust-laden air, or frequently alternating variations of temperature, or confinement in close rooms, offices, or shops are predisposing causes.

**Pathological Anatomy.**—The earliest appearances in the so-called inflammatory varieties are those of hyperemia. The capillaries are enlarged and more or less stuffed with blood-corpuscles (Gibbes). Into the surrounding tissue there is soon effused an abundance of leukocytes and small round cells, while the mucous glands are swollen with serum and the same cellular products, so that their acini become either obliterated or distorted by press-

ure. Here and there, after the disease has progressed, may be seen tubercular granula in the stroma without necrosis (Delafield and Prudden), either coalescent or more or less discrete; and distinct nodular formations of granula, perhaps with reticulated surroundings, may supervene as a result of productive inflammation or tissue-reaction. There become manifest in places attempts at organization instead of necrosis, or *vice versá*; the latter process, however, finally occurs from the subsequent obliteration of vascular supply through turgescence of lymph-channels and capillaries. According to Wright, productive inflammation and the formation of depraved granulation-tissue are apt to precede the necrosis in most instances. The mucous glands, which at first are excited to yield extra secretion, are soon compressed from without or invaded by infiltration products. The productive inflammation may lead to the formation of a granulation-tissue, which in spots will endure for quite a time; but the majority of such patches ultimately break down—ulcerate. Giant cells may not be found in the granulation-tissue in some cases; and, excepting in the undoubted "miliary" forms, where extensive ulceration or caseation rapidly supervenes, tubercle-bacilli may also be absent.

When the morbid process is localized, the surrounding tissue shows an active formation of connective and fibrous tissue with increasing vascularization—Nature's attempt undoubtedly to throw out a barrier. The zone of tissue nearest the seat of disease is well filled with small round cells and leukocytes in rather compact order. The pathological process is, as a rule, at first confined to the subepithelial layers, but soon involves the submucosa or even the deeper tissues. When softening occurs it is usually from below toward the surface, resulting in ulceration. The confinement of the caseation products, so as to produce what may be termed abscess, but rarely occurs; although after solution has taken place more or less pus, together with mucus, may be seen in the tissues as well as upon the surface. The epithelial layers of the mucous membrane suffer greatly and are entirely changed in their histological characters, both as to shape and dimensions.

In the infiltration form (see Fig. 613) there is a state of anemia, the capillaries are not increased either in number or caliber, but the lymph-channels are enlarged and filled; the mucous glands are also filled with serum and lymphoid cells, which form the basis of the so-called tubercle-granula, as well as round cells, which also fill the interacinous spaces. The epithelial layers are thinned and uneven from distention—perhaps more marked in the arytenoid region and epiglottis, where distention may be greater. At or near the sites of ulceration the epithelial layers are either lost or merged into one heterogeneous layer. Softening may quickly occur and the tissue break down rapidly to the surface of the perichondrium, even involving that structure; although it is apt to be checked by attempts at repair through the formation of granulation-tissue. The detritus from the ulcers usually shows an abundance of tubercle-bacilli, pus, mucus, altered epithelial cells, and epithelioid bodies.

The regions usually first affected are the arytenoids, posterior wall, ary-epiglottic folds, and the epiglottis, although the ventricular and vocal bands may be simultaneously involved. The ulterior ravages of the disease, if the patient lives long enough, may include any of the cartilages of the larynx (see Fig. 615).

**Symptoms.**—The early local symptoms are usually such as belong to persistent chronic laryngeal catarrh, and are of slow accession, unless, of course, the type of the disease be acute or it be a concomitant of general miliary tuberculosis. These symptoms consist of more or less hoarseness,

sense of uneasiness or dryness referred to the larynx, varying degrees of tenderness, and short, hacking, laryngeal cough. As the disease progresses there is soon added more or less pain in deglutition (odynophagia), and still later difficulty of deglutition (dysphagia) and painful and difficult phonation (dysphonia), or extinction of the voice (aphonia).

The severity of these clinical signs varies greatly, of course, according to the extent, progress, and seat of the morbid process; since, for instance, limited and unabraded infiltration or nodules, as a rule, give rise to less pain than more extensive and ulcerated lesions. Lesions of the epiglottis and arytenoids produce pain and embarrassment of deglutition much earlier than those situated at the aryepiglottic folds, vocal bands, or posterior wall of the larynx. Considerable infiltration of the interarytenoid region may exist without giving rise to much discomfort. The degree of suffering experienced will be according to the amount of ulceration and swelling of the larynx and the involvement of the neighboring lymphatic tissue, and may reach such a condition that the patient will dread to swallow, cough, or speak. We sometimes meet with odd cases, however, which show a comparatively anomalous degree of insensibility of the parts throughout the whole course of the process. These cases are usually secondary to pulmonary tuberculosis.

In the type of cases characterized by extensive infiltration and anemia of the tissues, the local subjective symptoms are less marked—excepting, perhaps, dysphonia or aphonia—owing undoubtedly to the lesser degree of inflammation present. The sensibility of the laryngeal tissues may be somewhat obtunded in many of these cases. There is, however, a marked degree of embarrassment of the vocal function and often mechanical obstruction to respiration. In any case, when the vocal bands escape implication, the change in the voice is of a less decided and progressive character.

If the pharynx be involved the distress and pain in deglutition is aggravated—the pain extending to the ears and perhaps to the face and teeth. Patients often complain of a sharp pain over the pectoral region of the chest, on the side corresponding to the most affected side of the larynx. This is probably due to the connection of the short thoracic nerve with the laryngeal through the central sensory centers.

The cough is often of a peculiar stridulous or rattling character, and when causing much pain is repressed as much as possible by the patient. The amount of expectoration varies greatly, according to whether there is much softening or ulceration of the tissues going on; but after the first stages there is usually considerable expectoration of mucus and saliva—often mixed with more or less pus and streaked with blood. A certain degree of immobility of the larynx, as a whole, is usually observed, which may be due to infiltration of the lymphatic glands in the neighborhood of the muscles or through the unconscious effort of the patient to escape the pain attending its movement. The suffering of a patient with extensive ulceration of the laryngeal structures is excruciating, and toward the last, even the act of breathing, as well as speaking and swallowing, may amount to torture.

The constitutional disturbance in the acute varieties takes place early, so that even before the appearance of marked laryngeal disease—debility, slight emaciation, more or less insomnia, limited anorexia, hyperpyrexia, a rapid pulse, and frequency of respiration may be observed. Indeed, so insidious is the attack sometimes that the serious import of the hemming, hacking, and throat-uneasiness, coupled with poor appetite, restless nights, debility, etc., may go unrecognized for quite a while, especially when, as is often the case, the complexion and display of personal ambition of the patient seem to



remain unchanged. I have known several cases of this sort in whom ambitious tyros have mutilated the turbinals in the belief that these unoffending adnexa were obstructing respiration and otherwise preventing the well-being of the patient.

In one such case brought to me for consultation after severe sanguinary surgical attacks had been made upon the turbinals and nasal septum, there were no subjective symptoms of laryngeal disease worth noting; and yet laryngoscopic examination showed a considerable infiltration of the left arytenoid region with corresponding infiltration at the apex of the left lung.

Another case worth alluding to briefly was that of a young girl of eighteen years, of ruddy complexion and plump appearance, who had been complaining for about two months of debility, slight dyspepsia, anorexia, and a very moderate hacking cough with soreness of throat, and whose voice was but very slightly altered. Examination showed slight swelling of the arytenoid region and very slight evidences of condensation at the upper right lung. Further infiltration and ulceration of the larynx rapidly supervened, and she died four months after. Such cases are also treated sometimes as "malaria!"

The anemic, diffuse, infiltrating type of the disease is usually preceded for a considerable time by constitutional symptoms of unmistakable signifi-

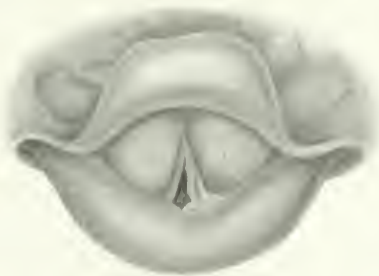

FIG. 609.—Red, infiltrated larynx with ventricular bands swollen almost into contact, hiding the right cord and most of the left, the base of which is covered by a nodule on the arytenoid (Grünwald).

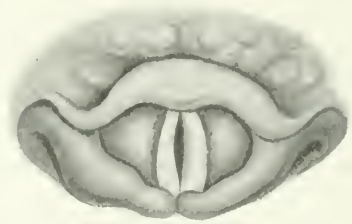


FIG. 610.—Early tuberculous nodules of the epiglottis and arytenoids with a pale right cord and an injected margin of the left (Grünwald).

cance, although exceptionally these cases may have been long preceded by symptoms of pharyngo-laryngeal catarrh only, without showing much systemic disturbance. As before remarked, there are many gradations of severity giving rise to corresponding modifications in the symptomatology. But too much confidence must not be placed in the apparent mildness of the symptoms as a basis for prognosis.

Besides, a large number of these cases show exacerbations and remissions which greatly alter both the subjective and objective symptoms from time to time. As a rule, however, when a patient exhibits persistent alterations of voice, with cough and other symptoms relating to the larynx, together with nocturnal elevation of temperature, frequent pulse, and otherwise unaccountable debility and malnutrition, the actual advent of laryngeal phthisis may be suspected, whether the physical signs elicited from an examination of the chest are corroborative or not.

In a large proportion of cases, especially if advanced, the tubercle-bacilli may be found in the sputum; but early in the disease, especially when more or less localized, this micro-organism will very often not be found, however carefully the search may be made.

**Objective Symptoms.**—The laryngoscopic appearances belonging to laryngeal phthisis or tuberculosis may, for purposes of description, be presented in five groups. The first (see Fig. 609) includes those cases which resemble chronic laryngeal catarrh somewhat, and are characterized by more or less diffuse hyperemia, inflammation, and swelling of the mucous membrane. The intensity of the hyperemia and swelling, however, is generally confined to either the base of the arytenoid bodies and interarytenoid space, the epiglottis, or, exceptionally, to the aryepiglottic folds, ventricular and vocal bands. The latter, however, are not affected to so great an extent by tumefaction, on account of their anatomical character. The tumefaction is not at all evenly distributed, but preponderates in one region or another. The more acute as well as localized varieties show this appearance very soon, and small roundish ulcers appear sometimes over the vocal cords near the posterior vocal processes first, or upon the epiglottis or toward the bases of the arytenoids very soon. They may be many in number or only two or three.

The second group of cases is marked also by hyperemia (see Fig. 610), but more localized; and the tumefaction may affect either the epiglottis or

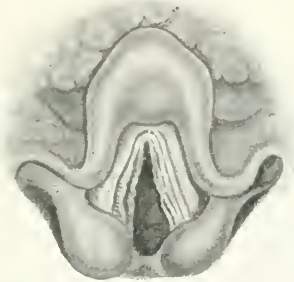

FIG. 611.—Infiltrated larynx with injected ventricular bands, the left cord nodular and the right apparently divided by an ulcer along its entire margin. Pyri-form tubercular swelling of the arytenoids (Grünwald).

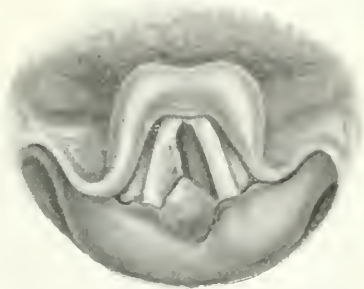

FIG. 612.—Tuberculous infiltration with tumor-formation between the pyriform arytenoids and on the right cord (Grünwald).

the arytenoids, generally the latter region particularly. These parts appear as pyriform or “club-shaped” swellings of brownish-red color, with the deeper tint toward the base. The vocal bands are usually a grayish- or brownish-white. The infiltration of the tissues may not be extensive, at first affecting mostly the arytenoids and aryepiglottic folds. The tumefaction gives to the parts in the laryngoscopic image a rather tense, smooth appearance, of a yellowish-red or salmon color, until ulceration supervenes, when the color may grow even paler, with reddish blotches. The epiglottis may be the part most affected in such cases, and is never so intensely colored as adjacent parts.

The third group (see Fig. 612) comprises those cases which are slow and attended with exacerbations and remissions. The color of the mucous membrane varies from a salmon to a dark red or brick red, while the tumefaction presents itself in rugæ, folds, or projections (tumors). One or the other arytenoid body is more or less fixed in position and usually bounded by ragged or papilla-like projections. The vocal bands are thickened, roughened on their edges or surface, and of a dirty-gray or brown color. Many vegetations simulating papillomata may jut out from around the base of one or the other arytenoid body, or from the interarytenoid space, the epiglottis, or the vocal bands. The edges of the latter may appear notched, either from actual

ulceration or from the effects of former ulceration, granulation, or cicatrization of the same.

The fourth group includes cases of diffuse tubercular inflammation (see Fig. 613). The mucous membrane appears in the image pale, bloodless,

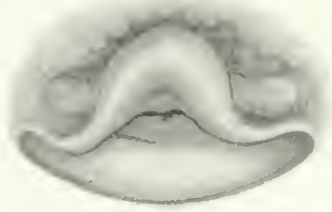


FIG. 613.—Diffuse infiltration of the posterior wall of the larynx, hiding all configuration of the arytenoids and the subjacent structures (Grünwald).

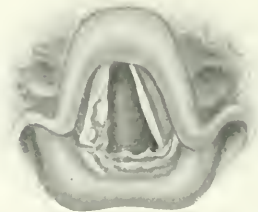

FIG. 614.—Pale larynx with swollen and roughened posterior wall and cicatricial changes about the left vocal cord, while destruction is still advancing on the right (Grünwald).

swollen, and glistening. The tumefaction varies in degree and extent, and like other forms it may be more marked at the arytenoid bodies, which will then show the "clubbed" appearance, or at the epiglottis, which will then

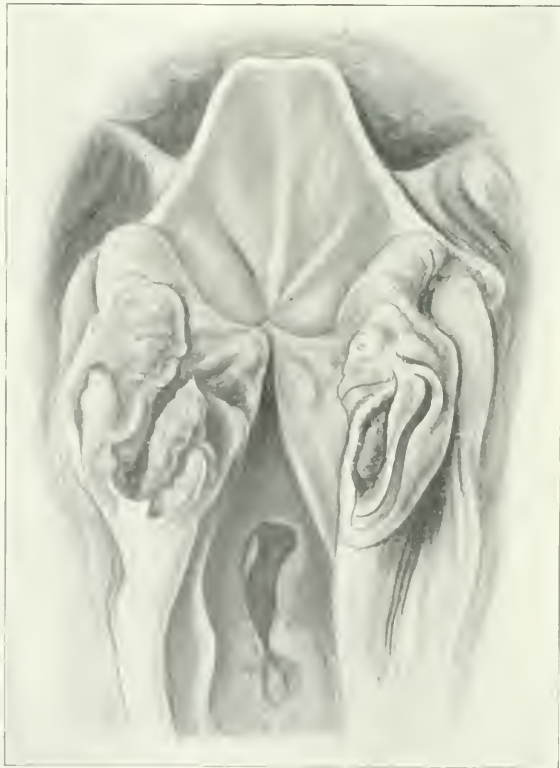

FIG. 615.—Larynx opened from behind, showing necrosis of the cricoid with ossified sequestrum and marked tubercular infiltration of adjacent structures. The ulcerated tracheotomy-opening is conspicuous below (Grünwald).

show the "turban-like" appearance (see Figs. 613, 614). The swelling may be so great as to give the appearance of edema, and may entirely obscure the

view of the interior of the larynx. The ulcerations are likewise small, and may be numerous, close together, or scattered; they are roundish or lenticular in shape until the deeper structures become involved, when they assume various shapes with ragged edges. When situated on the edge of the epiglottis, that appendix appears as if gnawed or "worm-eaten."

Group five (see Fig. 615) shows the results of extensive ravages in the advanced stages of the disease. After the destructive process has reached the deeper parts, such as the submucous connective tissue, perichondrium, or even the cartilages themselves, necrosis of the cricoid, arytenoid, or thyroid cartilage may be present. The ulceration in such an event is irregularly serpentine, deep, and extensive, with borders surrounded by granulations and scar-tissue, while the floors consist of sloughing dark-gray or greenish masses, more or less bathed with pus and sputum. The intervening mucous membrane is thickened and irregular in contour, of dark color, and in patches consists of little more than granulation-tissue.

There are, of course, gradations between these types of local disease, which give varying and sometimes quite anomalous pictures. For instance, the hyperemia, swelling, or ulceration may be limited to just one arytenoid body, or one aryepiglottic fold, or one side of the epiglottis; or the infection may be almost confined to one side of the larynx, especially when the process

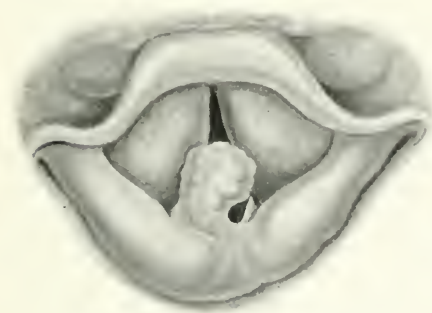

FIG. 616.—Tuberculous tumor-formation on the posterior wall with pale rigid infiltration of the ventricular bands and edematous swelling of the arytenoids (Grünwald).

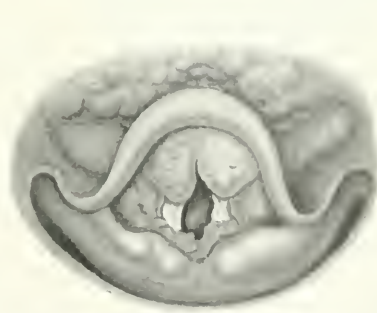

FIG. 617.—Hard raspberry masses of tuberculous infiltration without ulceration, almost filling the larynx (Grünwald).

first takes place in the deeper tissues; while in other cases there may be the appearance of considerable inflammation or hyperemia of one part, with an anemic infiltrated appearance of another part. There are also great variations in the distribution of the ulcerations. They may be confined to the laryngeal surface of the epiglottis or its very edge; or the posterior wall may be the seat of undetected ulcerations. It is therefore advisable in many cases to resort to Killian's method of examining this wall (see page 872) in order to ascertain its condition. There may be only two or three ulcers visible, and those situated on the vocal bands only; or, on the other hand, small ulcers may be scattered over the epiglottis, ventricular bands, arytenoid bodies, or vocal bands respectively, as if sprinkled into the vestibule of the larynx. Necrosis and ulceration of the tissues will surely take place more or less extensively in the natural course of events. But either under appropriate treatment or spontaneously, in the cases of slower march, a retrogression and healing of ulceration may occur. When this event transpires, granulation and cicatrization with their attendant contraction will mark the retrogression of the disease. The cicatricial tissue is not nearly so abundant as in syphilis or



lupus, because the patient does not usually live long enough to recover from extensive destruction of the tissues in tuberculosis. Yet there may be enough found to cause at least uncomfortable if not dangerous interference with respiration from stenosis or enough to produce troublesome aphonia. The vegetative proliferations also may become threatening, requiring removal, for sometimes they amount to tumors of considerable size (Figs. 616, 617). These vegetations are sometimes ejected spontaneously (J. Solis-Cohen). Again, the function of the larynx may be compromised by hypertrophied (reparative) tissue (superior and inferior hypertrophy) organized in folds or ridges (as seen in Fig. 618), or the action of the vocal bands may be impaired by adhesions. When ulceration begins the parts are usually freely bathed with mucus-pus, which is more or less adherent to the roughened surfaces, and shows usually in the image as partially desiccated or coagulated clumps, or as stringy bands or threads. The interarytenoid space is nearly always so covered; while the posterior wall of the larynx, as well as the walls of the trachea, may be plastered with clumps of sputum.

**Diagnosis.**—Laryngeal tuberculosis is often difficult to differentiate from chronic laryngeal catarrh, syphilis, lupus, and sometimes certain forms of epithelioma; and, as Scheech says, may baffle differentiation in some instances. When a clear and satisfactory history of the patient can be obtained, the difficulties are very much lessened, if not removed. There are numerous instances on record of a mixture of these diseases taking place; as, for instance, syphilis becoming implanted upon a subject suffering from laryngeal tuberculosis (see Fig. 622), in which case the difficulty of diagnosis is great. It is often confounded with ordinary hypertrophy of the laryngeal mucous membrane accompanying chronic catarrhal laryngitis or syphilitic laryngitis. Syphilis of the larynx, however, is usually preceded not only by its own peculiar clinical history, but by the occurrence of the local disease somewhere in the upper structures of the throat, such as the soft palate, pharynx, tonsils, or the nasal septum. This is especially true of the tertiary form, which shows preferably in the soft palate; whereas the lesions of laryngeal tuberculosis usually begin and remain in the larynx; but in the advanced stages the local appearance of this affection frequently simulates tertiary syphilis, lupus, or epithelioma. In secondary syphilis the ulcers are of a somewhat different character—being deeper, kidney-shaped, or irregular, with sharp-cut, everted edges, but they may be situated, as in laryngeal phthisis, on the epiglottis or aryepiglottic folds, vocal or ventricular bands. The tumefaction of the surrounding tissues is generally much less than in tuberculosis, and the inflammatory areola about the ulceration is usually present and characteristic. The parts are generally less painful than in laryngeal tuberculosis. In tuberculosis the ulcers are commonly shallow, of lenticular shape, with smoother edges, and with less disposition to immediate sloughing than syphilis. Syphilitic ulceration is attended with less tumefaction, and is in preference located on the epiglottis or vocal cords; whereas tubercular ulceration usually appears first in the region of the arytenoid cartilages or interarytenoid space, and is attended with tumefaction.<sup>1</sup> The grayish or yellowish tubercular spots sometimes described by authors as visible just beneath the surface of the mucous membrane (miliary deposits) are very rarely observed, although sometimes a mottled appearance does accompany the early stages of tubercular infiltration. In lupus, while the nodular growth is not as plain as if occurring on the skin (see Lupus, page

<sup>1</sup>The rough rule, "anterior lesions are syphilitic; posterior, tuberculous," often holds good.

1060), yet the papillomatous or granular appearance is well enough marked. Its course is very slow, and after softening has taken place the ulcerations soon coalesce to form a few discrete plaques, the everted, red, granular, ragged or papular edges of which are characteristic. Outside of these spots may be seen zones of thickened papillomatous membrane of varying hues of red. Besides, the parts are not painful to the touch, nor is there much pain in swallowing. Pyrexia is usually absent, and during remission the cicatricial tissue is prominently visible. In the so-called secondary form of tubercular laryngitis (Fig. 618), the peculiar paleness of the mucous membrane, with characteristic swelling of the arytenoid bodies, known as the "clubbed appearance," will serve, when present, to settle the diagnosis at once, even without the presence of pulmonary symptoms.

Epithelioma usually invades the larynx from the lateral wall of the pharynx, the tongue, or the esophagus, very rarely occurring as a primary affection in the larynx unless preceded by some benign neoplasm or lupus. It is of slow growth and without much constitutional disturbance. When it does occur in the larynx it is usually in the deeper regions of the organ, and will be found as a mass of tissue raised above the surface of the mucous membrane. It will be of a very deep-red color, of velvety contour, with fissured and sinuous channels bordered or filled by sloughs coursing through the mass here and there. It presents no definitely bordered ulceration, but irregular pockets, and readily bleeds upon being touched. It conveys the idea of an excrescence from the first.

The cervical glands are usually very early enlarged and hard. Sarcomatous tumors of the larynx are more rare than the myxo-sarcomatous. Their growth is rapid and presents the smooth appearance and contour of a vascular tumor or polyp. The growth is prone to bleed upon the slightest provocation, and does not present a lobulated appearance nor any of the characteristic ulcerative details of either syphilis or laryngeal tuberculosis. It appears as if independent of the surrounding tissues—not blended with them. Besides, there are no constitutional signs presented, at least for a time, if we except the cachexia.

Glanders and leprosy sometimes simulate, in their local manifestations and appearance, laryngeal tuberculosis; but the history of the case and the preceding lesions of the skin or lymphatic glands in leprosy, and of the nose or mouth in glanders, will serve to distinguish these affections from each other. In the advanced stages, when the destruction of tissue has been considerable and perichondritis or cicatrization has been concomitant, it is often very difficult, from appearances alone, to distinguish syphilis or lupus from laryngeal tuberculosis; especially is this true of the former affection. Yet, generally by an exploration of the chest, taken together with the clinical history of the case, one may clear up all doubt.

**Prognosis and Course.**—The prognosis is always grave. The form described as acute tuberculous laryngitis, or inflammatory tuberculous laryngitis (tubercular infiltration), offers practically no hope, because it is merely a local manifestation of a general miliary tuberculosis which may possibly be affecting any or all of the glandular organs of the body. This form of general infection sometimes attacks persons in apparently robust health,

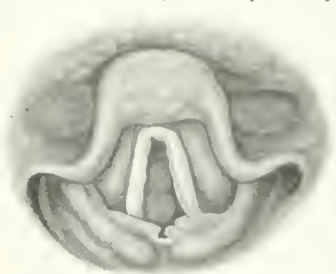

FIG. 618.—Nodular, lupus-like infiltration of the epiglottis, true and false cords, forming small tumor-masses on the arytenoids, and causing total aphonia (Grünwald).

whom one would think from their appearance would be able to resist, for a time at least, any sort of general infection or sepsis. In such persons, however, its course may be, and indeed usually is, as rapid as with those appearing more delicate. The larynx soon presents evidences of great inflammation, and its tissues soon break down. We meet with cases, however, which might properly be classified as acute, in which the disease becomes limited and retrogresses for a time, even though there may be well-marked physical signs of involvement of the lungs. I have met with several such cases which, contrary to expectation, have remained passive for a long time. In the more chronic forms, manifested by pale, anemic mucous membranes, the disease usually runs a slower course, but is almost always fatal. These cases are frequently accompanied by systemic infection of the bronchial lymph-nodes or spleen. Such cases may run an inactive course, however, usually unaccompanied by either the intense odonphagia or dysphonia of other forms; yet the voice is nearly always more or less impaired. The limited forms of the disease usually respond to appropriate treatment and regimen, and, excepting for exacerbations of acute laryngitis—the result of attacks of influenza, etc.—may be kept more or less passive for years, if not permanently checked.

**Treatment.**—The treatment of this affection is generally classified as general and local. The general treatment may be considered as *climatic*, *hygienic*, *specific*, and *symptomatic*; and the *local* treatment may be discussed under the following captions—local medication by inhalation, sprays, or insufflations, and surgical treatment.

The influence of climate in modifying all of the tuberculous diseases is well known and need not be discussed at length. However, in no form of phthisis is it more disappointing than in that of *active* laryngeal tuberculosis. Usually a warm moist climate is the most beneficial to the majority of cases, provided it is not too enervating, such as a tropical or subtropical one. The dry warm climates, such as those of Arizona, New Mexico, and some parts of California, do not seem to suit many of these cases, perhaps on account of the dryness of the air, for in many instances the laryngeal symptoms seem to grow worse after entering such localities. When a dusty or windy feature is characteristic of the climate of the locality, the discomfort and distress is sure to be increased (Ingalls). With regard to altitude, it may be pointed out as a rule that only a moderate elevation is well tolerated by many subjects. A large majority of those who dwell above 3000 feet are apt to suffer extra distress, if not exacerbations of inflammation of the larynx; this is especially true of the well-marked inflammatory cases. There are, however, many exceptions, especially when the local lesion is in a primitive state, or when much infiltration or ulceration is present. Strange as it may seem, cases showing but little involvement of the lung are not as much relieved as those in which there is notable involvement of the lungs, such as commencing softening or excavation. A cold dry climate with plenty of sunshine has been found even more generally beneficial than a highly-elevated dry or dusty one. Sometimes, however, when the cold is very intense, the laryngeal mucous membrane seems to be irritated thereby, especially if there be much hyperemia. In short, according to experience, a windy, dusty locality is not suitable for cases of laryngeal phthisis, except when there is more or less ulceration of the larynx or caseation of the lungs going on. A moist warm climate or ocean-voyages would therefore seem preferable as a rule. Of course, it will be understood that the individual and the individual circumstances may furnish valid exceptions to any rule.



The hygienic treatment consists for the most part in proper clothing, not too frequent bathing, and the administration of nourishing but digestible food; out-door life as far as possible during the day, with a cool (but not too cold) sleeping-apartment. Patients with this disease should be very careful about exposure to coal-gas for any length of time. The use of tobacco, either chewing or smoking, ought to be prohibited, also the too frequent use of cold and hot drinks in close alternation, such as ice-water and hot tea or coffee at meal-times. The full quota of sleep each twenty-four hours should be obtained. Patients should be enjoined to spare the voice as much as possible in conversation; singing and public speaking ought to be prohibited. I have known several instances where patients in the early stages of laryngeal phthisis, presenting certainly good prospects for at least temporary recovery, have been thrown into almost a fatal exacerbation by the strenuous use of the voice. One of these cases, I may briefly state, was that of a clergyman who was making an apparently good recovery. He had been away for some months from his duties and had returned to his residence in a district containing a great many friends among the congregations of several churches where he was well known. About the time of his return there was considerable church activity and public agitation on special moral questions concerning the district in question. As he had been a popular and efficient pulpit-orator, lecturer, and worker, he was persuaded to take an active part in these events. After making three prolonged and rather vehement orations in three adjacent towns during a period of a week or so, he contracted a violent inflammation of the larynx, which renewed the exudation into the tissues, and ulceration—affecting permanently the integrity of the larynx and necessitating his immediate removal to the South, where he expired in about nine months. A similar effect occurred in the case of a prominent lawyer who was a patient of mine and whose case bade fair to end in recovery. He was induced to return from a needed sojourn in the West Indies (where he was sent) to take part in some important cases that he had been engaged for, and after finishing this task a severe inflammation of the larynx with extreme tubercular infiltration followed. Many other like instances could be given to show the necessity of rest—as absolute as may be—in the management of laryngeal phthisis.

The specific treatment of laryngeal tuberculosis has not yet arrived at the perfection which we would wish. A great many agents have been brought forward from time to time which have undoubtedly been attended by a modicum of good results; but owing to numerous failures they have been gradually put aside. The seekers of truth in this field of discovery are numerous, however, and we may with reason hope that—guided by past failures and partial successes—the right series of therapeutic measures may yet be reached. Among the more modern agents of supposed specific value may be mentioned creosote, guaiacum, tuberculin and its various modifications, dog-serum, horse-serum—plain and tuberculinized—nuclein, chlorid of gold and sodium, cantharidid of potassium, chlorin water with chlorid of sodium, oil of cloves, cinnamon and other essential oils, chlorid of zinc, the formates, iodin, etc. There are many cases on record of moderate and even brilliant results following the use of each of these agents, both in laryngeal and pulmonary tuberculosis; but, as said above, the effects have been short of general utility. I am led to the conviction, from my own experience with these several agents, that they are perhaps less useful in a specific sense in laryngeal tuberculosis than in pulmonary tuberculosis. These agents have all been used in the general belief, of course, that all cases of laryngeal



tuberculosis were simply the expression of a general infection. But undoubtedly some of the cases reported to have been cured have been aggravated forms of ordinary chronic inflammation of the larynx; while some may have been cases of chronic laryngitis complicated by syphilis. I have myself been deluded once in a while by such erroneous diagnoses, and undoubtedly others have met with the same misfortune. These remedies have been used both hypodermatically and *per os*. While the hypodermatic use of such remedial agents is manifestly more desirable, the attendant pain and difficulty of properly carrying out this plan of medication render its general adoption of doubtful practicability, especially in private practice.

I am still of the opinion that among these agents *iodin, when conjoined with some proteid substance*, furnishes the best results so far as specific medication is concerned. It seems to make some difference in the ulterior effects whether the drug is administered in connection with iodid of potassium, glycerin, and water, without some *proteid* material or not, for I have found repeatedly in the same patient that the administration of the drug, either hypodermatically or by the mouth, in a mixture with *sterilized bouillon* will produce more lasting benefit than when given otherwise; so that we have adopted the habit in hospital practice of administering it in bouillon or milk. It may also be given advantageously in combination with glycerin and extract of malt. I have also used creosote and guaiacol in the same way with apparently better effects than when given alone; and we may therefore be pardoned for the suggestion that perhaps the majority of remedies administered for constitutional effects—if there are no chemical contra-indications—would be more efficacious when so combined. Whether a chemical combination actually takes place between these agents and some unknown proteid of the animal fluid used, I am unable to say; but possibly at some future time this point may be satisfactorily demonstrated. Guaiacol and oil of cloves are both very useful when administered in an emulsion, in suitable doses, three or four times daily, or (sometimes a better way) in very small doses repeated every hour for a certain number of times, according to the tolerance of the patient. The former agent as “benzozol” has given very good results. In the more chronic cases characterized by anemia of the mucous membrane, phosphorus administered in solution with olive oil in capsule is highly beneficial. This combination may be found on the market in the form of capsules containing from one one-hundredth to one-thirtieth of a grain of phosphorus in 10 or 15 minims of oil. It should be administered always just after food has been taken, and if irritation of the stomach, urticarious eruption, or aphrodisiac effects follow its use, the dose must be materially modified or the administration of the drug stopped. Arsenic, especially the arsenate of iron, chlorid of gold and sodium, salicin, and strychnin are very valuable tonic agents. Strychnin and salicin are among the most useful agents for general effects. When there is much hyperpyrexia, salol or sodium salicylate may be substituted for salicin. For the temporary repression of temperature, acetanilid, or aconite, or judicious bathing may be resorted to. The somewhat prevalent practice of combining either of these agents with other things—sometimes not synergistic—is certainly a bad one! Of course, this criticism does not apply to mixtures containing sedatives, such as codein or hyoseyanus. But, as a rule, it is preferable to administer all drugs designed for temporary effect, *alone*. The use of alcoholic beverages in this disease is fraught with perplexity: for while in many instances alcohol in one form or another is indicated, yet the condition of the

throat may be such as to prohibit it, either on account of the local pain attending its deglutition, or on account of its decided and directly deleterious effects upon the diseased larynx. It will be found better generally to select the malt beverages and preparations, rather than the spirituous. The administration of a little rectified spirit with milk, however, will be found useful when large draughts of whiskey, brandy, rum, etc., cannot be consumed without distress or evil effects.

The *symptomatic* treatment of laryngeal tuberculosis can scarcely be formulated, and will depend upon a variety of circumstances which will indicate the agents to be selected for each individual case in order to allay cough, pain, hyperpyrexia, diarrhœa, mental perturbation, etc. As laryngeal tuberculosis when advanced is perhaps one of the most painful affections to which flesh is heir, the practitioner may be sorely taxed to meet the constant demand for relief without incurring other mischief. However, opium and its salts, for internal medication in such cases, still retain their popularity—codein, morphin, or the powdered drug seems best. Cough may be mitigated by the milder anodynes, such as codein, tincture of opium, hydrochlorate of cocain, hydrate of chloral, etc., together with the various expectorants and balsams (see Formulary). Care should be taken that syrups are not used too freely, lest nausea, vomiting, and anorexia be favored. Chlorid of ammonia and other chlorids may cause severe pain when the mucous membrane is ulcerated, otherwise they may be used. Sleep may be secured by the administration of sulfonal, trional, chloral, the bromids, or some preparation of opium, alone or in combination with one of the other anodynes mentioned.

The *local* treatment consists of inhalations of gases or medicated air, sprays, and powders. Inhalations of medicated air are of little permanent benefit excepting in the early stages, or when there is an unusual amount of salivary or other expectoration. There are a number of suitable inhalers in the market, from which volatile substances may be inhaled either with or without the aid of hot water. A simple instrument may be made of tin, with a perforated receptacle at its distal end for containing a piece of sponge, upon which may be dropped preparations of creosote, carbolic acid, menthol, camphor, creolin, tinct. benzoin, tinct. myrrh, etc., combined with chloroform, ether, alcohol, or spirits of ammonia. These agents may also be dropped into hot water contained in a hot-water inhaler. These instruments can be used by the patient several times a day, with sometimes very good effect in the early stages of disease. When, however, this form of inhalation increases the sensation of "dryness," "stiffness," or pain referred to the throat, they should be discontinued. A preferable method of inhalation

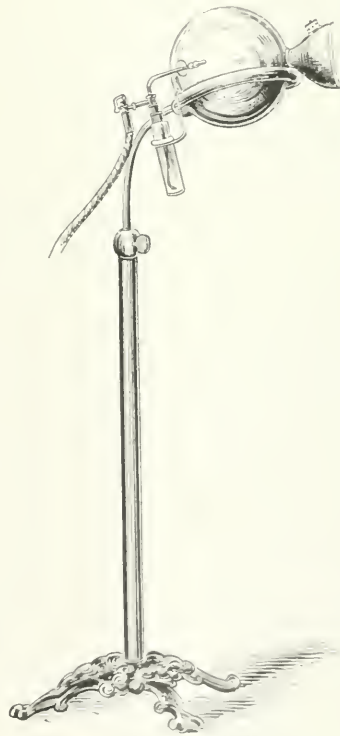


FIG. 619.—Globe inhaler

in general is accomplished by spraying the medicament into the throat from either a steam or a hand-ball atomizer. The spray may be projected directly into the throat, or it may be projected (especially if it be oleaginous) into a globe inhaler (see Fig. 619), from which it can then be inhaled through a face-shield which will completely enclose the nose and mouth. This is a much more thorough method of local treatment in laryngeal phthisis, especially when the agent is in the form of an oleaginous solution. All such agents as creosote, camphor, menthol, carbolic acid, guaiacol, creolin, phenol, oil of eucalyptus, etc. may be dissolved in a pure fluid petrolatum or olive oil and projected into the inhaler, whence they can be carried into the larynx by the ordinary process of respiration. Although this means of local medication may fail in many instances of producing radical change, it, nevertheless, affords a very practical and efficient method of relief. The watery solutions are best used by spraying directly, as near as possible, upon the parts. In this manner there may be used with tolerable efficiency solutions of formate of soda, bichlorate of soda, alum, boric acid, carbolic acid, cocaine, morphin, hydrochlorate of coniin, tannic acid, sulphate of iron, sulphate of zinc, nitrate of silver, chlorid of zinc, etc. These chemicals may be used in varying quantities according to the requirements of the case (see Formulary). *Insufflations* of powders upon the larynx, although of great value, especially when ulceration has taken place, are sometimes not well tolerated on account of the desiccation of the secretions or the prolonged and distressing paroxysms of cough which they produce. Among the agents most useful as insufflations in laryngeal tuberculosis may be mentioned iodoform, iodoform with boric acid or bismuth, naphthalin, aristol, euphorin, boric acid, tannic acid, ammon. citrate of iron and potassium, stearate of zinc or alum, subnitrate or tannate of bismuth, morphin with gum acacia, etc. The insufflations should always be preceded by a thorough spraying of the parts with some detergent solution, such as bichlorate of soda or phosphate of soda; and care should be taken that the amount of powder propelled upon the larynx is not too great, otherwise distressing spasm and cough may supervene, lasting a considerable length of time and producing not only extra congestion and irritation of the parts, but, perhaps, vomiting and exhaustion. It is often desirable to apply directly with a brush or pledget of cotton certain medicaments, in the form of pigments, to ulcerations. This may be done preferably by using the Wagner laryngeal brush or a pledget of absorbent cotton, either held by forceps or wound around the roughened end of a probe or applicator. In this way strong solutions of nitrate of silver, chloroacetic acid, lactic acid, carbolic acid, chlorid of iron, chlorid of zinc, formaldehyd, creosote, formate of sodium, etc., may be carried to the part.

The range of surgical measures for the relief of this disease is necessarily limited. The papillomatous excrescences which sometimes accompany progressive ulceration may have to be removed by evulsion, snaring, or escharotics. Especially is this the case when such protuberances occur about the vocal cords or ventricular bands, and by their presence obstruct respiration or produce great mechanical irritation of contiguous parts. A few years ago Dr. Heryng adopted and promulgated the plan of thoroughly curetting tuberculous ulcers and afterward applying to the surface so abraded lactic acid in the proportion of 20, 30, or 50 per cent. solutions, or stronger, according to effects. This met with considerable favor for the treatment of some cases. There is no doubt that it may be a very efficient and practicable measure in cases of isolated ulcerations in the upper part of the larynx; but for a large proportion of cases of laryngeal tuberculosis presenting no limited

lesions, but a simultaneous breaking down of many spots separated from each other, this plan of treatment will necessarily be limited in its application. Besides this, many times the lesions will be found out of reach. Then, too, there are individuals in whom, for some reason, these parts are too physically sensitive for interference of that sort, even under the influence of cocaine, without exciting a general disturbance which is not easily allayed. This was my experience in two favorable cases, when I was obliged to desist after early manipulation. The application of lactic acid without the curettement is generally well borne and efficient. Scarification of the larynx in the chronic form is a measure of relief which is not practised, perhaps, as often as it ought to be. The writer called attention to this plan of relieving the tension of the parts some twelve years ago; and many practitioners who have adopted the plan have reported good results from it. It ought not, however, to be indiscriminately adopted, because the objection urged against the practice, that it opened up the deeper tissues to probably further infection, holds good in many instances. However, as ulceration in any event is inevitable, especially after great infiltration, it will be found that the anticipation of nature's step in this direction by scarification will greatly modify the subsequent necrosis of the tissues, and at the same time enable the practitioner to meet the prospective condition by more thorough medication. I would therefore still advise in some cases of inordinate effusion—even though it be not considered edematous—a reasonable amount of scarification over the tumefied parts, whether it be the arytenoid cartilages, interarytenoid space, ary-epiglottic folds, or epiglottis.

Hypodermatic injections of creosote or other agents into the laryngeal mucous membrane have been in my hands very disappointing.

It must be confessed that local treatment in many cases is of little value, excepting for the palliation of pain and other phases of distress, mainly, perhaps, because the lesions are more or less out of reach and too deep in the mucous membrane. On the other hand, in some of the slower-going cases, characterized by limitation and accessibility of the lesion, a judicious local treatment constitutes our principal means of assisting nature to resist the progress of the disease. We must agree with Gleitsman that, theoretically, the thorough removal by surgical means of the diseased tissues and the induction of a healthy reparative process is the ideal desideratum; but, unfortunately, there are as yet no practical ways of successfully carrying out such laudable aims. So we are still, as it were, obliged to drift along empirically, without any exact principles of therapy to follow in the management of this disease. It will, therefore, be impossible to lay down any rules for the application of this, that, or the other agent or preparation; and the question of the selection of topical medication must be left to the skill and experience of the practitioner. It may be added, however, in conclusion, that of all agents for general use, perhaps none surpasses iodoform, aristol, resorcin, fannogen, or mercury protochlorid, used either by insufflation or in solution or in mixture with petrolatum oil. Next in value, especially when ulceration has begun, may be ranked lactic, chloracetic, and carbolic acids; and after these, chlorin water, sodium formate, silver nitrate, zinc chlorid, mercury bichlorid and biniodid, creosote, and oil of eucalyptus. The inhalation from a face-shield inhaler of 1 ounce of solution of mercuric chlorid (1 : 3000), immediately followed by an inhalation of from 2 to 4 ounces of a solution of (1 to 2 per cent.) iodoform in petrolatum oil, will oftentimes prove highly beneficial to a large number of cases. The inhalation of chlorin water combined with a solution of salt in water is also very efficient when it does



not cause much pain or coughing. Usually from  $\frac{1}{2}$  to 1 ounce of each (mixed) is as much as ought to be given at a sance.

One of the leading therapeutic indications is toward the assuagement of pain and laryngeal distress. For such purposes we must resort preferably to the local application of either cocain, coniin hydrochlorate, bromoform, morphin formamidid, atropin, aconitin, chloroform, menthol, ethyl-bromid, creolin, or similar agents. These substances are best used in the form of spray or pigment, excepting ethyl-bromid and chloroform, which are volatile (see Formulary).

In cases where much soreness is generated from a more or less continued muscular action of the pharyngo-laryngeal muscles, coniin hydrochlorate, menthol, or ice (held in the mouth until melted) will be found beneficial. For promoting an antagonistic effect against the burning and rawness often complained of, either aconitin, atropin, or hyoscin will be found useful in addition to other treatment.

Cocain hydrochlorate or morphin alone, or in combination with either iodoform, aristol, naphthalin, or carbolic acid, will be found to be the "sheet anchors" for the relief of pain. The frequent cleansing of the throat with sprays containing peroxid of hydrogen, borie or carbolic acid, when well borne, is a good practice and one which greatly promotes the comfort of the patient, to say the least. The formulæ for the use of these several agents are appended.

#### FORMULARY.

##### *Sprays.*—

- (1) Zinc chlorid, 1-3%; (2) Zinc sulphate, 1-4%; (3) Mercuric biniodid, 0.2%, and Potassium iodid, 4%—in glycerin and water.
- (4) Sodium formate, 2-3%; (5) Coniin hydrochlorate, 0.2%; (6) Mercuric bichlorid, 0.2%, and Hydrogen dioxide, 16%—in water.
- (7) Alumol, 2%, and Cocain hydrochlorate, 1%—in peppermint-water.
- (8) Oil of eucalyptus, 3%; (9) Menthol, 1%, and Camphor, 1%; (10) Creolin, 1.5%, and Alcohol, 0.2-0.5%—in liquid petrolatum.

##### *Pigments.*—

- (11) Iodin, 0.4%, and Potassium iodid, 1%; (12) Formaldehyd, 10%; (13) Pyoktanin (blue), 2%, and Acacia, 2%—in water.
- (14) Hyoscin hydrobromate, 2%; (15) Aconitin, 0.2%; (16) Morphin sulphate, 1%, and Antifebrin, 2%—in glycerin and water.
- (17) Lactic acid, 20-40%, in water. (18) Carbolic acid, 12.5%, in glycerin.

##### *Insufflations.*—

- (19) Tannic acid, 6%; Powdered starch, 19%; and Bismuth subnitrate, 75%. (20) Resorein, 50%, and Powdered starch, 50%.
- (21) Aristol, 50%, and Powdered starch, 50%. (22) Silver nitrate, 1-2%, and Tale powder, 98-99%. (23) Tannic acid, 3%; Cannabin tannate, 7%; Bismuth subnitrate, 45%; and Powdered starch, 45%. (24) Silver nitrate, 3%; Acacia powder, 32%; and Bismuth subnitrate, 65%. (25) Armenian bole, 25%. Sugar, 25%; and Sodium biborate, 50%. (26) Morphin sulphate, 0.3%; Mild mercuric chlorid, 20%; Sugar, 40%; and Bismuth subnitrate, 40%. (27) Morphin sulphate, 3%, and Iodoform, 97%. (28) Iodoform, 11%; Borie acid, 34%; Naphthalin, 55%; and Oil of Bergamot, a sufficient quantity.

##### *Internal Medication.*—

- (29) Compound solution of Iodin (Lugol's solution), 15 cc., and Glycerin, 15 cc. Ten drops in milk every four hours.
- (30) Syrup of ferrous iodid, 30 cc., and Compound syrup of the hypophosphites, 30 cc. Teaspoonful three times a day.
- (31) Salicin, 4 gm.; Calcium hypophosphite, 6 gm.; Whiskey, 150 cc.; and Fluid extract of Malt, 210 cc. Two to four teaspoonfuls three times a day.
- (32) Sodium salicylate, 412 gm.; Cinnamon-water, 120 cc.; and Water, 120 cc. Two teaspoonfuls three times a day.
- (33) Powdered bone, 8-12 gm.; Glycerin, 30 cc.; and Cinnamon-water, 90 cc. Teaspoonful three times a day.

**TUBERCULOSIS OF THE NASAL PASSAGES AND THE PHARYNX.**

**The Nasal Passages.**—Tuberculosis confined to the nasal passages exclusively or primarily occurring there is extremely rare (Cohen, Bosworth, Chiari, Hajek, Risdél, Kafeman, Schäffler). The disease is more often observed in connection with pulmonary phthisis of an advanced stage, or, according to Kafeman, in cases of latent tuberculosis. This author states that the reported cases of primary tuberculosis of the nose, pharynx, or larynx, without pre-existing tuberculosis or latent foci elsewhere, should be received with a great deal of skepticism. Authoritative statistics derived from autopsies are cited in support of this statement.

The more common site for the development of the disease is in the region of the cartilaginous septum of the nose, although Chiari observed that in his six cases other parts as well as the septum were affected; in one the maxillary sinus being involved. Kaschier distinguishes a form of the disease which particularly affects the bony framework. Lermoyez cites cases of the occurrence of tuberculous vegetations at the vault of the pharynx. There are a few cases on record in which tuberculosis of the naso-pharynx seemed to follow operations for the removal of adenoid vegetations in patients who were previously free from either tubercular disease or hereditary tendency. A few such cases have been reported by Kafeman and others, one or two of which were followed by tubercular meningitis. It is sought to account for the occurrence of this latter class of cases upon the supposition that the wound of the operation offered an opportunity for the entrance of tubercle-bacilli, carried there either by inspired air, food, the instruments or finger of the operator. Some writers believe that in all such cases either the bacilli or some tubercular formation is already present in the glandular tissue. I have never observed a case of primary nasal tuberculosis, although having seen several cases occurring in the course of advanced pulmonary phthisis. Cases have been reported in which the disease began in the form of a few papilloma-like prolongations from the mucous membrane at intervals along the septum—tubercular tumors, as it were. These cases are notable for their slow march. The lesions oftener occur just at the vestibule of the nose.

**Etiology.**—The majority of observers believe that the only cause of the disease in this situation, as elsewhere, is the implantation of tubercle-bacilli, and that these micro-organisms may be conveyed to the part either from without by contact of sputum during acts of coughing or vomiting; by means of the finger, as in picking the nose; by the inspiration of bacilli-laden air; or from within through conveyance from some remote focus by either the blood or lymph (Kafeman, Chiari). The well-known ubiquity of the tubercle-bacillus and the frequency of catarrhal affections of the nose entailing abrasions, etc., are relied upon in explanation of these modes of origin. Chiari believes that the infection generally takes place by the inoculation of some abrasion or fissure of the epithelium with tubercle-bacilli conveyed there by the finger. Although adopting the idea of primal bacillary infection, he nevertheless states that he found tubercle-bacilli in four only of his six cases. Kafeman, who published two interesting cases of so-called primary nasal tuberculosis, and who likewise believes in the bacillary origin of all tubercular disease, found no tubercle-bacilli in either of his cases, but in one of them some stray specimens of the Langhans bacillus. This author attributes the malady in his cases to a probable infection through abrasions of the mucous membrane by bacilli-laden air, as

neither of his subjects were tubercular nor of a tubercular tendency. The signal immunity of the nasal passages from tuberculous disease, when so constantly exposed to abrasion and invasion by tubercle-bacilli, has been a subject of much perplexing speculation. Lately, however, experimental researches of the bacteriology of the nasal passages have led to some conclusions which may account for the hitherto-observed immunity mentioned. Clausen found that the nasal passages of rabbits were apt to contain quantities of pyogenic bacteria. Von Besser, Fernier, Lermoyez, and others found that the human nasal passages, pharynx, and larynx contained numerous bacteria, such as the diplococcus pneumoniae, streptococcus pyogenes aureus, tubercle-bacillus, etc.; while St. Clair Thomson, Hewitt, and others found that healthy nasal passages were bacteria-free. Fernier and Bretschreiber also, making similar investigations with varying results, concluded that the nasal passages were only quasi-aseptic. The conclusions of Thomsen and Hewitt were to the effect that the normal secretions of the nasal passages and throat were bactericidal, and hence neutralized immediately the virulence of any superimposed micro-organisms. From all these observations, and from the negative results of clinical experience, it is fair to infer that perhaps some of these cases of so-called primary nasal tuberculosis were really of doubtful character. Those observers (Störck, Thost, Heryng) who really believe that fissures or abrasions of the mucous membrane invite the origin and development of the disease, confess that there must be some particular change in the cell-life of the part in order to consummate the establishment of the malady. Strauss has found that the nasal passages and pharynx of healthy persons who spend much time in the presence of phthisical patients, or in rooms where phthisical patients are confined, contain large numbers of tubercle-bacilli. The question as to the power of tubercle-bacilli to penetrate sound epithelial tissue is yet an unsettled one. A further discussion on the etiology of this subject will be found in the section on Tuberculous Laryngitis.

**Symptomatology.**—The early symptoms consist, for the most part, of a mild coryza and frequent attempts at sneezing, with a sensation of fulness and uneasiness within the nasal passages. The discharge, which is at first of a mucous character, gradually becomes more serous or muco-purulent, but is not apt to be very profuse. After a while the nasal passages become more or less plugged with exfoliating crusts, which accumulate just inside of the nostril and cause considerable itching, burning, and other irritation. There is rarely much odor to the discharge, such as we meet with in ozæna. There may be slight swelling of the skin of the nose, redness and marked soreness. Very little pain is complained of, however, unless the internal parts be touched. The disease is usually confined to the mucous membrane covering the cartilaginous septum, although after a time ulceration of the turbinals may be observed. The ulcerations are usually small, with red rims, and discrete, although in places there may be confluence of them, and they are not disposed to heal. Slow-growing perforation of the cartilaginous septum is sure to take place, and in some cases this may be the first symptom to excite the alarm of the patient. The perforation gradually extends, by a molecular dissolution of the edges, until nearly the whole of the triangular cartilage disappears. When the disease takes an exacerbation, as sometimes occurs, its extension may become quite rapid, covering more or less of the whole line of the septum and even extending to the pharynx. The local symptoms in this event are, of course, very much aggravated. In all cases pain, coryza, and lachrymation may make the patient very miserable,

aside from more or less constitutional disturbance. If the lungs or other organs are also the seat of the tubercular process, the constitutional symptoms of septicemia are very much aggravated. Tubercular meningitis is to be expected as a termination of cases of true nasal tuberculosis. In the form of the disease characterized by tuberculous tumors, the surrounding tissues are slow to take on reactionary disturbance, for the ulceration is slow and confined to the little neoplastic formations. It has been observed, also, that the general disturbance is much less in these cases, and that the cartilaginous structures escape destruction for a longer time. Perichondritis and periostitis, with necrosis, may be expected, however, in severe or neglected cases; but, as a rule, except for the destruction of the septal cartilage, the ulceration usually confines its ravages to the mucous membrane.

**The Pharynx.**—Primary tuberculosis of the pharyngeal mucous membrane is very rare, but does occur, and may be tolerably latent for a time. It is frequently more or less mixed with syphilitic disease or laryngeal phthisis, and often coexists with these affections or carcinoma (Baumgarten, M. Schmidt). In my own practice I have never met with an instance which was not connected with either a syphilitic taint or with laryngeal or pulmonary phthisis. Two notable examples which came under my observation were preceded in the one case by secondary, and in the other by tertiary, syphilis. Kafeman states that there are two forms of pharyngeal tuberculosis, one a miliary, and the other a papular or tumor, form. Cases of the former class are characterized by the development in many places of small miliary tubercles, and in the latter by the formation of one or two patches only—generally upon the lateral walls and posterior surface of the velum palati. The nasopharynx does not seem to participate very often in the disease, but the base and tip of the tongue and the oral cavity are more likely to do so. The ulcers are small, surrounded by a narrow red, raised rim. As the disease advances they may coalesce and excavate more or less beneath the edges of the mucous membrane, giving the edges a raised, worm-eaten, or irregular appearance later on. In some cases considerable infiltration takes place, so that the mucous membrane in the neighborhood or all over the pharynx (if it be the miliary form) appears edematous. The pharyngeal wall suffers, and the velum palati is also very apt to participate, in which case the uvula is edematous and very tender. The shapes of the ulcerations vary, but are usually oval, more or less elongated, and covered with muco-pus, either soft or partially desiccated. When situated upon the posterior wall, which is exceptional, the surface presents a cleaner and rawer appearance. Deglutition is always very painful—the patient shrinking from swallowing very hot, very cold, or salty food. In some instances the deglutition of the saliva is very painful. In advanced cases the cervical glands are more or less swollen and tender, as are also the muscles of the neck. The patient presents an anxious expression of countenance, is pallid, and emaciates rapidly after the disease has progressed for some time, owing to the difficulty of obtaining sufficient nourishment. When the tongue is involved, the parts especially affected are the tip, sides, and base. Ulcerous cracks and fissures, more or less surrounded by small papillæ, are characteristic. The organ is always very sensitive. In these cases, even if confined to the pharyngeal cavity, the tonsils are apt to be involved. Indeed, the tonsils are said by Strassman, Denochowsky, Dieulafoy, and others to be extremely liable to tuberculous disease. The first-named observer found the tonsils tuberculous in 13 out of 21 autopsies made upon tuberculous subjects, and Denochowsky, in each of 15 autopsies of similar subjects, found the tonsils tuberculous. Dieulafoy



injected parts of extirpated tuberculous tonsils into 61 animals, 13 per cent. of which contracted general tuberculosis. Cornil, on the other hand, examined 70 cases, and found giant cells in 4 only; while Virchow has declared that tonsillar tuberculosis is very rare. It is also said that the tubercular process in these glands takes place primarily in the deeper tissues—the lower endothelial lining of the follicles or crypts and lymph-spaces—and that ulceration does not readily follow. For this reason the surface indications are therefore wanting and the disease may escape notice. The conclusions of some observers seem to indicate that these glands are common seats of latent tuberculosis. Nevertheless, the theory that a very favorable lodgement for tubercle-bacilli is offered by the crypts of the tonsils, and also that the surface-manifestation of the disease may be infrequent owing to deep infection, would seem to offer to a practical mind an inadequate explanation of the infrequency of the visible manifestations of tonsillar tuberculosis. Again, why should the advent of tubercle-bacilli into the deeper structures of the tonsil through the blood-vessels and lymph-channels, instead of from without inward, be a selected mode of infection? The only explanation worthy of acceptance would be that perhaps an antitoxic character belonging to the secretions of the tonsil is sufficient to render the surface immune to the action of tubercle-bacilli—that is, supposing that the bacilli are the only cause of the tonsillar disease. It will be remembered that St. Clair Thomson and others have shown that the nasal and buccal secretions are probably strongly bactericidal; and, if this be a fact, therein may lie the explanation of the frequent escape of these glands, as well as the upper air-tract generally, from tubercular disease.

The **diagnosis** of nasal and pharyngeal tuberculosis is not always very easy. Syphilitic inflammation of the nasal septum, lupus, and sarcoma may easily be mistaken for tuberculosis. Indeed, lupus and syphilis are often much alike in their local characteristics, as well as tuberculosis and lupus. In syphilis, besides the history of the case, it will be found that the whole nasal septum is very much infiltrated, and that the disease is taking a more rapid course. When ulceration has taken place in syphilitic disease there is breaking down of larger areas, which may subsequently coalesce, although at first remaining quite distinct. The character of the ulceration is not particularly distinctive, for we may have in either disease a serpiginous, ragged, undermined sort of ulceration with raised red edges. In pure syphilitic affections of the septum, where the disease is confined to the triangular cartilage, the differential diagnosis is quite difficult in the absence of supporting clinical history. Nevertheless, a microscopical examination may serve to determine the diagnosis, although it will not be safe to rest always upon the discovery of the tubercle-bacilli alone, for these micro-organisms may be always present to a greater or less extent in the nasal secretion, even in cases which are not really tuberculous, as shown by the researches of Strauss and others. From lupus, tuberculosis may be distinguished by the much slower course of the former affection and the presence of lupous disease of the skin just external to the nose, or somewhere about the face, and the absence of any great amount of surrounding infiltration and constitutional disturbance. Then, too, the presence of the characteristic small, pointed, pinkish granulations will serve to distinguish lupus. The lupous exulceration is inclined to heal and leave its characteristic scar-tissue, while the tuberculous is not. The age of the patient also may serve to strengthen the differential diagnosis, for lupus of the nose, as a rule, attacks

the young or the very old; while tuberculosis of the upper air-tract is very rare under fourteen years of age (Demme, Bollinger).

From sarcoma, tuberculosis may be distinguished in the course of the disease by the absence of a distinct tumor, which is soft to the touch, of red color, of considerable size, and showing a disposition to rapidly enlarge from its point of attachment outward. The sarcomatous growth bleeds easily. Sarcoma can only be mistaken for the so-called tubercular tumors which sometimes appear in the nose. But the latter are usually small and multiple; while sarcoma, as a rule, is confined to one or two points.

The **prognosis** of tuberculous disease of the nose or pharynx is certainly very grave, although if the disease be recognized early the prospects of the patient are not so bad, because in this situation, if there be little or no general infection, there is an opportunity of entirely eradicating the morbid process.

The **treatment** for the disease in either of these situations should be chiefly local and surgical. No time should be lost in removing, as far as possible, the diseased masses, either with the curette or the galvano-cautery, wherever they may be situated within reach. After this has been done a vigorous local treatment, consisting of the application of antiseptics, such as formaldehyd, formate of sodium, carbolic acid, resorcin, iodoform, chlorin water, or guaiacol, must be adopted. The last agent is reported by E. Fränkel and H. Bergeat to be highly useful in lupus. It is also efficient in local tuberculosis. The thorough removal of the disease, as suggested above, will be found in all cases the most efficient method of treatment. Besides local measures, great benefit will be obtained from the internal administration of iodin, chlorid of gold and sodium, arsenic, and phosphorus. Climatic changes are not as markedly beneficial as when the larynx and pulmonary organs are involved, although any regimen and hygienic measure which will promote the health of the individual will, of course, be beneficial. No attempt to repair the edges of the perforation of the septum after the disease process has become checked—by such methods as scarification, trimming of the edges, or cauterization—will prove efficient. It will be found far better to simply promote the covering of the edges of the perforation, however extensive it may be, by emollient applications.

#### LUPUS OF THE AIR-PASSAGES.

**Lupus vulgaris**, the variety with which we are mainly concerned—as is well-known—is particularly a disease of the external skin. It appears insidiously, as a rule, and slowly extending in that apparatus, terminates in a process of exulceration. It is also not infrequently met with upon the mucous membrane, which in many respects is histologically analogous to the external skin. Indeed, some observers believe that the mucous membranes are more often affected first in lupus of the face. One of the most frequent sites for the development of lupus vulgaris is at the angle of the nose, the mouth, the eye, or somewhere in the neighborhood of an external opening of the body. While some dermatologists assert that any portion of the skin is liable to its attack, others assert, upon an apparently equal basis of facts, that certain covered portions of the skin are invulnerable. It has been asserted, as a rule, that lupus vulgaris always primarily occurs upon the skin and affects the mucous membrane afterward. However the rule may be, there are instances enough on record of the primary invasion of the mucous membrane to constitute at least marked exceptions. It is stated

that there are many instances of lupous disease of the lining membrane of the nasal chambers, which run for a long time without being discovered, where no dermatic involvement ever took place. The point of origin of lupus of the nasal cavity is most frequently in the mucous membrane covering the cartilaginous septum. From this point it may gradually spread intranasally along the septum or extranasally to the vestibule of the nose and the skin. Sometimes the pharynx is involved secondarily from a focus on the nasal septum.

**Etiology.**—The principal etiological factor in lupus of the nose, as elsewhere, is supposed to be the tubercle-bacillus. However, as this question will be fully discussed under the caption of Lupous Laryngitis, it need not detain us here.

**Symptomatology.**—The objective symptoms of lupus are usually very mild, rendered so by its well-known tendency toward a chronic course. The first symptoms may be unaccountable sneezing and slight coryza, although the discharge is not apt to be profuse except in the first stages of the disease. After the histological changes incident to the first stages of the disease have become developed, the breaking down or ulceration begins to take place in small spots, and then there will be more or less formation of yellowish or brownish crusts with slight ichorous or serous discharge. The appearance of the spot is not so characteristic as when the skin is affected. In the nose the infiltration is quite insignificant, and does not present that peculiar brownish granular appearance until after ulceration has taken place. When this has happened, lines or valleys with bacon-colored bases may be seen, interrupted and surrounded here and there by little pinkish-red granules, all of which are more or less covered with scales or crusts somewhat adherent. As said before, perforation soon takes place, and gradually enlarges as the disease advances. The course of the lupous ulceration does not differ from that of other ulcerations, advancing by infiltration and subsequent breaking down, but its trail is covered by the formation of characteristic scar-tissue, which is, however, much more delicate and less characteristic here, as in other mucous membrane, than upon the skin. I have never seen a case of nasal lupus in which the adjacent skin was not involved. The destruction of the skin and consequent contraction of cicatricial tissue necessarily produce more or less deformity of the nose. Lupus vulgaris is inclined to stop before the osseous tissue, confining its ravages to the softer parts. Exceptionally, however, especially in syphilitic cases, bone as well as cartilage proves no barrier to its advance. In such cases, the destruction of the tissues being greater, the deformity is also proportionately greater.

The prognosis is quite favorable, although the disease can rarely be checked without the production of more or less destruction of the nasal septum, with at least permanent perforation. A sort of eczematous eruption is apt to persist even after the recovery from the lupoid ulceration, which is a matter of considerable annoyance to the patient and very difficult to overcome.

**Lupus of the pharynx** is much more rare than lupus of the nasal passages, and although appearing without any relationship whatever to syphilis, is, nevertheless, more often found in syphilitic subjects. It is stated by many authors that lupus is a disease which is found in tuberculous subjects or those of tuberculous tendency; indeed, as will be seen subsequently, many authors regard the two diseases as identical. This question, however, is still a practically unsettled one, and need not detain us here. The portion of the pharynx more often attacked is the soft palate, and of



this the buccal, more frequently than the pharyngeal, surface. Next in order of frequency of occurrence may be mentioned the lateral wall of the pharynx, or rather the faucial arches, especially at their junction with the velum palati. In the cases of lupus of the pharynx which have fallen under my observation, the soft palate or the faucial folds have been the primary seat of the disease in all but one instance. The course of the ulceration in this situation is usually very mild, and leads to no more constitutional disturbance than when situated upon mucous membranes elsewhere, excepting as it interferes more or less with proper deglutition. In such instances the loss of body-weight and consequent development of general physical weakness is progressively marked during the period of ulceration. After cicatrization takes place, however, these difficulties disappear and the nutrition of the patient soon assumes a normal condition. In a case which has been under my treatment the ulceration and destruction of tissue was considerable for a time, and as deglutition grew extremely painful, the patient, in consequence of lack of food, became very weak. This case occurred in a woman whose family were free, as far as could be ascertained, of any tuberculous tendency, but who had suffered two years previously from a severe attack of small-pox—indeed, the skin all over the body presenting the marks or pits of the disease. We were unable to trace, however, any causal relation between the eruption of lupus and the variola; neither could there be traced in this case any syphilitic taint after the most thorough investigation into the life-history of both the patient and the patient's husband. I have ascertained of no instance on record of lupus of the nasopharynx.

The prognosis of lupus in these situations is favorable unless the disease circumvents the tonsil or some other hidden place where adequate local treatment cannot be pursued.

**Treatment.**—The local treatment should be a vigorous one, consisting of thorough excision or evulsion of the morbid tissues. For this purpose curettement and the galvano-cautery offer the most suitable means. After this has been done, persistent local application of resorein, iodoform, sodium formate, guaiacol, or carbolic acid, or escharotics, such as zinc chlorid, chromic acid, etc. The general treatment by iodine, iodid of potassium, and arsenic will prove very efficacious, especially the former. In the case of lupus affecting the soft palate or pharynx so as to interfere with proper deglutition, 4 per cent. solution of cocain should be freely applied to the diseased parts just before a meal is taken, and the meal should be such as to contain the most nutritious constituents of alimentation. Out-door life and proper hygienic surroundings will add material benefits to any course of treatment.

Notwithstanding the fact that the tubercle-bacillus is so often absent in many specimens of lupous tissue, yet the majority of writers persist in ascribing the essential cause of the disease to the tubercle-bacillus of Koch, although the same observers note the discovery of the bacillus of Lustgarten as well. To account for the diverse clinical behavior of lupus, as compared with so-called tubercular affections of other tissues, Councilman believes that the quality of the bacillus and the resistance or definite reactionary characteristics of the tissue invaded are quite sufficient, holding, for instance, that the histological peculiarities of the skin will resist the development of the tubercle-bacilli in its tissues, and thus give rise to the slow and heterogeneous clinical phenomena observed in lupus.



## LUPOUS LARYNGITIS.

Lupous laryngitis is a chronic inflammation of the mucous membrane, characterized by the formation of small nodules or tubercles in the deeper tissue—the submucosa. These nodules disappear either by resolution, exfoliation, or ulceration, leaving a peculiar cicatricial tissue. There are several varieties of lupus described by dermatologists, chief of which is lupus vulgaris—the variety usually found affecting mucous membranes. Lupus erythematosus has received its name from Cazenave on account of its healing with the formation of scar-tissue similar to lupus vulgaris. Many modern dermatologists and pathologists, however, think that it should not be classed with lupus vulgaris, because no tubercle-bacilli have been found in the tissue-formation of its eruptions. Unna, for instance, suggests that it be called *seborrhea congestiva*, and not classed with the tubercular affections. Besnier of Paris and some others argue that it is a tuberculous affection, and should therefore retain its present name. Leloir also believes that it is tuberculosis, and capable of reproducing itself by inoculation. The disease commonly attacks, and is confined to, the skin; but when the site is in the neighborhood of any of the orifices—such as the nares, mouth, ears, vagina, or rectum—it is apt to extend and involve the contiguous mucous membrane. Exceptionally, however, it affects the mucous membrane *primarily*, in which case the nasal or buccal mucous membrane, or that of the soft palate, pharynx, larynx, conjunctive, rectum, or vagina, may be the part affected. Leloir's statistics show (Morrow) that out of a total of 312 cases of lupus, mucous membranes were involved 109 times—the mucous membrane *secondarily*—yet primary lupus of the nose, a more common type than formerly supposed, may escape notice. Neisser concludes that lupus of the face is generally caused by extension from adjoining mucous tracts, especially from that of the nose. The internal mucous membranes, such as the gastric, intestinal, or bronchial, are not subject to invasion, although a case is reported where the process was observed on the mucous membrane of the trachea.

Primary lupous laryngitis is quite rare, many laryngologists of large experience not having seen a case, while others have seen but very few cases each. Among these, Bosworth mentions having seen but one, M. Mackenzie two, Lefferts four, and Rice three. As the invasion is insidious and very chronic, and the signs of the same very obscure, many observers believe (as also of the nasal mucous membrane) that the disease occurs in the larynx oftener than is supposed—especially as it generally attacks the young, who do not come under observation as readily as older persons. Among these observers, R. De la Sota y Lastra and Rice make this suggestion. The epiglottis is generally the part attacked, according to Chiari and Richl.

**Symptoms.**—The constitutional disturbance incident to this affection is practically slight, unless the disease is so situated or so advanced as to interfere with the functions of deglutition or respiration, or unless some complication attended by unusual inflammatory or septic processes in the neighboring glands or tissues supervene. Such complications are rare, however, until the disease has run a very long and aggravated course; for there is usually but little tendency to general infection of any sort, although Leloir and others say that it may produce partial or general infection. Hoarseness and a sense of dryness or thickening referred to the throat, with slight dysphonia or dyspnea, are among the early and, it may be said, persistent symptoms. There is little or no pain complained of unless the disease is advanced and extensive, or ulceration with an unusual amount of inflammation has taken

place, when more or less difficulty of swallowing may occur, although not even then very much. When there is much swelling, attention is required in order to prevent the ingress of particles of food into the larynx during the act of deglutition. The temperature rarely rises until the disease is quite advanced and complicated, and then perhaps only to 99° F. The local appearances are usually less marked on mucous membranes than on the skin. Michelson has shown that it is almost impossible to trace accurately the limits which separate the lupous tissue from the mucosa, because it is only in the cicatrices that we find the characteristic lupous nodule when the mucous membrane is the seat of disease.

The laryngeal face of the epiglottis is usually first affected, and presents a slightly swollen hyperemic condition with a few papular projections like granulations, which afterward break down into an ulcerated patch (see Fig. 618). In some cases the free border of the epiglottis appears whitish or gray, thickened and studded here and there with dark-red papillomatous patches. After a while the laryngeal vestibule becomes altered in shape from the infiltration, etc. The thickened and misshapen mucous membrane presents irregularly circular folds or rugæ, appearing similar to a slightly prolapsed and puckered membrane, and is studded here and there with grayish glistening fissures and dark-red papules, which in turn may be coalesced to form a patch. These places are not very painful to the touch nor during swallowing. At a later stage these spots become softened and soon show evidences of slow, dry ulceration bounded by ragged edges or a slightly reddened granular areola. According to Leloir and contrary to Baumgarten, suppuration of the lupous patch is not an essential characteristic, and when present is due to the combined action of the agents of suppuration (streptococci) and the bacillus of Koch. If the seat of the disease be the border of the epiglottis, it may appear as if worm-eaten (Lastra). Even now the swelling and hyperemia of the surrounding parts may be quite insignificant; for the infiltration seems undulatory and very chronic, so that the general condition of the patient may remain good in every particular. The progress of the disease is so slow that it may cover a number of years, and then may terminate in pulmonary or meningeal tuberculous or epithelioma (Morrow), although not necessarily, for many observers have never known a cure in a tuberculous subject (Bosworth). At the same time, the local process during this period is subject to great variations of exacerbation and quiescence. This is true of lupus affecting mucous membranes as well as the skin.

A retrogression is marked mainly by a gradual healing of the ulceration, with the formation of a thin, bluish-gray, glistening cicatrix, somewhat more moist and duller, however, than the lupous scar-tissue of the skin, and surrounded by zones of thickened, rough, dark mucous membrane. Then after a period of quiescence more or less prolonged (which in some cases leads one to the conclusion that a cure has been effected) there is a recrudescence, which at the time may not be accounted for by any event in the domestic or clinical history of the patient. It will now be observed that two or more foci of papillary swelling with inflammation are starting from about the periphery of the old lesion. These may perhaps go through a more rapid or aggravated course of softening, tumefaction, and ulceration, etc., and may be accompanied by more infiltration of the surrounding tissue than at the former period. Indeed, some cases present a greater severity of local action at each successive exacerbation, so that the ulceration and inflammation may become somewhat alarming, while the ulceration perhaps assumes the serpiginous form spoken of by some writers. This event is quite dangerous when affect-

ing the larynx, and apt to be extensive in its ravages, simulating to a certain degree lupus exulcerans (lupus exedens) of the skin. Besides this, the corresponding cicatrices from such an amount of destruction leave troublesome and sometimes vicious deformities, which may endanger life through interference with the laryngeal or esophageal openings (stenosis).

**Etiology.**—Lupus was formerly regarded as related to scrofula, or cancer—if not really cancerous—by the older authors, mainly on account of the observation of cases becoming cancerous. It was also considered a sequence of syphilis. Ricord held that it was an inherited manifestation of tertiary syphilis. Kaposi, however, says positively that syphilis in a parent has no connection with lupus in the children; moreover, Hebra and Kaposi have found recent syphilis and lupus in the same individual. The latter (syphilitic) view is to some extent prevalent nowadays. Again, it has been considered a serofulous disease; but as so-called scrofula is generally considered to be of tuberculous nature, or practically a form of tuberculosis, this view would coincide with the opinion now prevailing that lupus is a *local chronic tuberculosis!* Some authorities have believed, and do yet, that lupus vulgaris, especially in the skin, belongs to the serofuloderms; that it is essentially a serofulous disease! Kaposi and others combat this idea, and say in effect that scrofula is entirely absent in many cases of lupus. Indeed, it is now so classed by the majority of modern dermatologists and pathologists, and may be found in the category with tuberculosis verrucosa cutis, serofuloderma (tuberculosis of the subcutaneous tissue), tuberculosis cutis, etc.

The tubercular nature of lupus was suspected for years before the discovery of the tubercle-bacilli of Koch, on account of the histological analogies between the several affections as persistently pointed out by Friedländer and others; but the hematogenetic origin of lupus was not assailed until the discovery of the tubercle-bacilli in lupous tissue (lupoma) by Demme, Koch, and afterward by others, when all doubt seemed to be swept from the minds of the majority, and the tubercle-bacilli (as in other tubercular disease) became the recognized cause of lupus vulgaris. Moreover, these views have been strengthened from time to time by experimental and other observations apparently showing the inoculability and infectiousness of lupous tissue, for J. Jadassohn, Leloir, and others have cited instances of the production of lupus by inoculation, and they regard every case of lupus vulgaris as due to inoculation with the tubercle-bacillus, thus denying the so-called hematogenous development of the disease as promulgated by Baumgarten. Koch, Leloir, and others claim to have demonstrated this by the transmittal to guinea-pigs and rabbits of tuberculosis by inoculation with lupous tissue-cultures. The starting-point is probably the entrance into the skin or mucous membrane of the tubercle-bacilli in one of the following ways: 1, indirect inoculation from without; 2, indirect inoculation by continuity from deep tuberculous foci; 3, inoculation by way of lymphatics or the veins passing through a tubercular focus more or less remote; 4, infection of hematogenic origin; 5, infection by inheritance.

Methods 1 and 2 are probably the most frequent. However, there are no instances, I believe, where lupus has been a result of contact (contagion) of one lupous patient with another, nor where the inoculation of bacilli into the skin experimentally has produced lupus. Kaposi and other European dermatologists, and Dühring in this country, are rather skeptical as to the identity of lupus with tuberculous affections. Kaposi says: "Nevertheless, the attempted demonstration of the identity of scrofula,



tuberculosis, and lupus has not yet proven such identity. Cases of 'inoculating tuberculosis' are reported in constantly increasing numbers, but it seems to be regarded as immaterial that years may have elapsed between the assumed 'inoculation' and the occurrence of the tuberculosis of the skin. No experimental proof has been offered, however, that characteristic lupus vulgaris can be produced by inoculation of tubercle-bacilli." Drs. Morison and Symington<sup>1</sup> examined the tissue from twenty lupous cases without finding the tubercle-bacilli, and M. Cornil examined the skin of eleven lupous patients, and found only one tubercle-bacillus. Dr. Hennege Gibbes believes lupus a tubercular affection, but says that the bacilli are sometimes not found in the lupous tissue. Kaposi and others deny the infectiousness and heredity of lupus; but cases have been recorded where a parent of a patient suffered from lupus, and an instance where several brothers and sisters of another patient suffered from lupus. Leloir again says that diversity in the phenomena of the several varieties may be accounted for by the mode and seat of the inoculation (inoculation from within outward or from without inward); the deposit of the virus in parts more or less vascular; the greater or lesser virulence of the virus inoculated, and different degrees of reaction of the tissues. All authorities agree that it is a disease of early life. According to Leloir it begins generally in infancy, and may produce partial or general infection of the system. Concerning the exciting causes of lupus, especially as regards the mucous membrane, there seems to be a paucity of positive information. Syphilis and eczema of the nose, and fistulae leading to the site of tuberculous disease, are cited as having induced the formation of lupus in a few cases; but mechanical or chemical injuries are not spoken of as probable causes of the disease in mucous membranes, unless we accept the theory of those who believe in the direct or indirect inoculation with tubercle-bacilli, and who think that a previous abrasion is necessary for the introduction of the germ. Leloir's classification of the varieties, all varieties which he believes are tubercular, is as follows:

(a) True lupus, non-exedens and exedens.

(b) Atypical varieties of lupus: 1, lupus vulgaris calloide; 2, lupus vulgaris myxomatosis; 3, lupus vulgaris sclerosis and demi-sclerosis; 4, lupus vulgaris erythematoid.

(c) Scrofulo-tuberculosis, gummata-dermatic and hypodermatic.

(d) Ulcerative tuberculosis: 1, secondary; 2, primary.

(e) Mixed tegumentary tuberculosis resulting from a combination of two or more of these varieties.

A review of the conflicting literature upon the etiology of lupus from a clinical standpoint might lead to the following considerations:

(A) If lupus is due to the presence of the tubercle-bacilli, and therefore of the same pathological nature as the other so-called local tuberculous diseases, how can its peculiar clinical course, which is much at variance with that of other of the tubercular affections, be accounted for? Is there in the histological, biological, or chemical constituents of either the skin or mucous membranes at the orifices of the body any special antidotal property, in the form of either serum, cell, proteid, ferment, secretion, or tissue, which will so effectually resist the development or growth of tubercle-bacilli or the extension of their accompanying toxins as almost to nullify their hitherto-accepted destructive tendencies?

(B) What, also, is the reason that the implantation of tubercle-bacilli in the mucous membrane of the larynx in one instance produces a slow-

<sup>1</sup> *Journ. Cut. and Gen.-Ur. Dis.*, vol. ix. p. 268.



going, practically non-infectious local disease (lupus); while in another instance the same micro-organism rapidly develops, extends, and thereby sets up a destructive local disease and a fatal general infection?

I confess that all the explanations with which I am familiar touching these points are inadequate to explain these clinical anomalies. The histological resisting character of the skin or its temperature and movements is urged by some observers in explanation of the very chronic and innocuous course of this disease. The paucity of the tubercle-bacilli and their encapsulation—contributing to render them latent—is stated by Unna. Lastra, however, seeks to account for the incongruities observed by the supposition that the bacilli or their accompanying toxins may be attenuated, and in substantiating this view he reasons by analogy, and ingeniously cites the effects of attenuated doses of chemical agents on the system as compared with larger quantities or more concentrated qualities of the same, thus assuming that the cytogenesis or mitosis of a part depends upon the dosage. According to Unna, the smallest number of tubercle-bacilli are able to stimulate productive inflammation, the formation of giant cells, and serofibrinous exudation; but be that as it may, could we, under even these conditions of attenuation, expect any such pathological process in the mucous membrane of the larynx, a part whose susceptibility to tubercle-bacilli and tuberculous toxins are continually alleged as a matter of fact? Either we have not yet fully learned the morphology of the tubercle-bacillus, or we must look upon the doctrine as a fiction that it (tubercle-bacillus) is independently the cause of lupus of the larynx. There is no use of taking up space by theorizing, but it seems certain from the clinical history and pathological anatomy of lupus vulgaris of the larynx that its etiology depends essentially in some way upon a perverted or aberrant (karyokinesis—catogenesis—or nutations) process of regeneration of the constructed or formed tissues of the part, or that the bacillus of lupus, instead of being identical with the real tubercle-bacillus of *ordinary tuberculosis*, is perhaps more closely allied to the bacillus of Fisch, which is found in rhinoscleroma.

**Age.**—All authorities agree that lupus is a disease of early life, although there are instances on record of its occurrence at an advanced age.

**Sex.**—The female sex seems to be more susceptible than the male. Of 79 cases collated by Bosworth, 51 were females and 18 males. Other statistics on this point coincide.

**Heredity.**—There have been differences of opinion regarding the hereditary transmission of lupus, but unquestionably the instances of such transmission are rare.

**Inoculability.**—I think the majority of dermatologists believe that the disease is inoculable, either directly or indirectly; but as that question has been dealt with in the discussion of the etiology, there is nothing to be added here, excepting to recite the oft-quoted verdict of the territorial jury—viz., "*not proven.*"

**Traumatism** has been cited as a predisposing cause of the disease in the skin, and, by those who accept the doctrine of inoculability of the disease, is believed to be an important etiological factor.

**Pathology.**—According to Prudden and Delafield, lupus consists in the presence of "small multiple nodules of new-formed tissue, somewhat resembling granulation-tissue, in the cutis mucosa or submucosa. By the formation of new nodules and a more diffuse cellular infiltration of the tissue between them, the lesion tends to spread, and by the confluence of the infiltrated portions a dense and more or less extensive area of nodular infiltration may be

formed. There may be an excessive production and exfoliation of epidermis over the infiltrated area, or an ulceration of the new tissue."

In the clinical group of diseases called lupus there are other forms of lesion which are not caused by the tubercle-bacilli.

Unna lays great stress upon the part played by the large so-called plasma-cells of Waldeyer, and thinks the giant cells are of secondary formation. He also points out that the tubercle-bacilli are encapsulated in the giant cells, and therefore become latent. Jadassohn thinks the plasma-cells are not of any particular importance in lupus, because occurring in other inflammatory processes.

Kaposi says that the pathology of the disease relating to the skin does not differ essentially from that affecting the mucous membrane.

In all instances of tuberculosis we find the tubercle the product of the tubercle-bacilli—a nodule of so-called granulation-tissue, composed histologically of small round cells, deeply stained by coloring-agents, together with larger cells possessing a clear nucleus that have been called epithelioid cells, and large cellular elements, with peripherally arranged nuclei and homogeneous center, the Langhans giant cells. These cells are enclosed between the meshes of connective tissue, and are characterized in distinction from normal cells by their instability. Sooner or later a modification begins in the nodule. Its center becomes necrotic—*i. e.*, the cell-protoplasm is coagulated, the nuclei lose their power of responding to staining-agents, the intercellular substance also takes part in the degeneration, and there results a coagulation-necrosis in the Weigert sense—a condition that has been called cheesy degeneration.

**Diagnosis.**—Lupus of the larynx may simulate tuberculosis, syphilis, epithelioma, rhinoscleroma, or chronic glanders. According to Neisser (Morrow), the chief diagnostic points of lupus are the beginning in childhood and its very chronic course. If the lupus laryngis be secondary to the same disease of the skin or an extension from it to fauces and larynx, then the diagnosis may be easily made out. But when the larynx is primarily affected the task may be a more difficult one, at least in some of its stages.

The general clinical history, showing an absence of constitutional disturbances of any moment, will serve to distinguish it from laryngeal phthisis, and from syphilis by lack of the history belonging to the latter disease. On inspection, the absence of much inflammation, the dry, negative, un-suppurating appearance of the ulceration, limited in situation and not clearly defined, with rather coarse granulated edges, will usually serve to differentiate it from the sharply-cut suppurating ulcers of syphilis surrounded with highly-colored and tolerably well-marked areola, and from the shallow roundish lenticular ulcers on a pale and swollen mucous membrane which distinguish from syphilis and tuberculosis this disease. When ulceration is active the local appearances might lead to some confusion, but in such cases the clinical history, as well as the characteristics of the local formation, will remove perplexity. Syphilitic ulceration of the nose often resembles lupus, and diagnosis in such cases may have to be suspended to await developments.

Rhinoscleroma usually begins first on the skin of the nose. Its ulceration is flat and soon covered by a stiff crust. There is usually no softening nor ulceration, nor very much contraction, and no such melting away, so to speak, of the tissues as in lupus.

Epithelioma can only be mistaken for lupus when it is of local origin in the larynx, which is not often. When so occurring it is generally situated at first either upon the epiglottis or in a laryngeal ventricle. It may be seen as a more or less reddish growth of uneven although unbroken surface and

to stand out from the tissues. When breaking down it presents sinuous slough-patches or pockets and granulations, but no cicatricial tissue.

**Treatment.**—The treatment should be both constitutional and local. The systemic treatment should be upon the tonic and so-called alterative plan. The subjects of lupus more often than otherwise show the effects of privation or malnutrition. Therefore, a generous diet, out-door life, and suitable clothing, together with such tonics as salicin, quinin, Fowler's solution of arsenic, tincture of the chlorid of iron, etc., should be administered.

Arsenic in one form or another has been considered highly beneficial for the last century. Indeed, it has been deemed by some as almost a specific for lupus. It certainly is one of the most useful remedies in vogue. Iodin and iodid of iron are also of great value, especially if combined with the syrup of the hypophosphites. In my limited experience the use of arsenical preparations and iodin, either hypodermatically or by the mouth, has given the best general results. Iodid of arsenic and Fowler's solution are the favorite preparations. Cod-liver oil and malt-preparations may also be taken with benefit. When there is a cachectic sallow appearance with tendency to lymphadenitis, phosphorus in oil should be given three times a day.

The chief indication for local treatment is the removal of the offending tissue. This has always been the desideratum. The older practitioners sought to accomplish this elimination by means of powerful caustics, such as caustic soda, caustic potassa, arsenious and nitric acids, chlorid of zinc, etc. More recently the dermatologists have resorted to either the knife or curette for the speedy removal of lupous tissue. This surgical plan has also been adopted in cases of lupus of the mucous membranes, but according to Bosworth with the effect of aggravating the disease. Undoubtedly, when so situated that the diseased tissues can be wholly cut away at once, such an operation would be performed.

The use of the galvano-cautery ought in many cases to supersede other escharotic treatment, although strong solutions of chlorid of zinc or lactic acid are very satisfactory in their effects. The case which I have cited was treated locally, mainly by occasional applications of lactic acid followed by daily applications of a spray of a strong solution of resorein. Pyoktamin, topically applied as Bougard's paste or injected into the parts by the hypodermatic syringe, is reported as being efficient. I have used a solution of iodin in this manner, but could not see that the effects were more striking than when introduced elsewhere under the skin. The application of balsam of Peru has been reported as giving good results. There is danger of producing edematous or phlegmonous inflammation of the larynx by rough treatment; for that reason it is obvious that the same thorough treatment as applied to the skin would be inadmissible for application to the larynx. For routine local treatment it will be found that resorein or iodoform, or both, in conjunction with the careful use of the galvano-cautery, lactic or chromic acids, will constitute the most efficient and safest treatment for this disease.

The use of tuberculin and tuberculoceidin seems to have been abandoned.

#### LEPROSY OF THE AIR-PASSAGES.

Leprosy often involves the mucous membranes in the course of the general affection, and its lesions might be confused with the others here considered; but it is probably always secondary to the cutaneous manifestations of the disease, which should make clear the diagnosis, and is too rare to demand discussion here.

# SYPHILIS OF THE AIR-PASSAGES.

BY WILLIAM C. GLASGOW, M. D.,

OF ST. LOUIS, MO.

---

NEXT to the skin, the respiratory tract furnishes the most frequent manifestations of syphilis. Owing to the slight disturbance caused by the initial and secondary lesions, these are often overlooked; and the latest stage, from its greater destruction of tissue and its marked disturbances, has been placed in greater prominence as a factor in the disease. The initial lesion here has been considered by many to be only a possible contingency; and they are apt to ascribe the infection to a hidden chancre of the genitals. The observation of men of large experience has proven, however, that syphilis may be "insontia;" that occurrence of the extra-genital chancre is not rare; and that its possibility must be considered in all cases where the initial lesion is not plainly apparent. The secondary lesions of the upper air-passages are always more or less evident. To differentiate them from similar conditions due to other causes is not always easy; and in some cases a positive diagnosis can be made only through the presence of the well-known lesions of the skin. Tertiary lesions are usually marked and distinctive, and in only a small percentage of cases can there be any doubt. According to anatomical classification, syphilis of the air-passages may be divided into diseases of the nose, diseases of the pharynx, diseases of the larynx, diseases of the trachea, and diseases of the lungs.

## SYPHILIS OF THE NOSE.

Primary syphilis of the nose is acknowledged by all authorities to be very rare. When we consider the uncleanly habits of certain people, and the frequent interchange of handkerchiefs and towels among the members of the family, by which means infection can be so readily carried, and also the frequency of abrasions at the entrance of the nostrils, we are surprised that it does not occur more frequently. Buckley, from an analysis of 9058 cases of extra-genital syphilis, gives 95 cases occurring in the nasal cavity. In his personal experience he has found one case occurring in 113 cases of extra-genital syphilis. He thus describes the symptoms of this case: "There was great swelling of the left nostril, which stood open and was covered internally with a dry crust, and on the margin there was an ulcerated surface free from crust. The passage of the nose was red and uneven from small nodular masses." There was no history of a preceding syphilis, and the lesion was suspected to be a chancre, rather than a later manifestation of the disease. Under the mixed treatment, and calamine and zinc ointment applied to the lesion, there was great improvement with healing of the ulcer. Secondary syphilis appeared later, confirming the diagnosis. The infection in this case seems to have come from the use of an infected towel. The most frequent site of primary lesions in the nose is the cartilaginous



septum, and the infection is usually carried by the finger-nail. In some cases the surgeon is responsible through the use of unclean instruments. Several cases are recorded of infection by the Eustachian catheter. Bosworth describes a case of Moure: "The ulcer presented a large granular mass which bled easily upon touch, and which not only produced notable stenosis, but also pressed upon the ala of the nose to such an extent as to produce a marked deformity." In a case of Watson, the base of the chancre presented the appearance of a hard cartilaginous tumor with an ulcerated surface which bled easily upon touch, and projected so far into the nostril as to produce a marked stenosis.

An indolent swelling of the submaxillary glands is constant at this stage, and the constitutional disturbances of early syphilis are often witnessed. Erythema or a subacute rhinitis is the one pronounced symptom of the secondary stage. If mucous patches occur, they must be exceedingly rare. The "snuffles" of the new-born child is one of the frequent symptoms of congenital syphilis.

Syphilitic rhinitis differs in appearance in no way from an ordinary rhinitis. The diagnosis can be made with certainty only when the lesions of the skin show the recognized eruptions of syphilis. Its duration, however, is longer than a simple catarrhal rhinitis; and this chronicity and resistance to treatment add to its suspicious character.

The third stage of syphilis shows the most marked manifestations in the nose, causing ulcerations, superficial and deep, and gummata. Gummatus deposit may occur in any portion of the nose. The most frequent site is the septum and the floor of the cavity. It is most commonly limited in extent, forming a tumor as large as, or larger than, a pea. In some cases, however, the infiltration is more extended. It commences most frequently in the submucous tissues, extending both to the surface and the deeper tissues. It may continue for months with an unbroken surface; but sooner or later degeneration occurs, and ulcerations, either superficial or deep, result. The periosteum or perichondrium becomes involved, and later there is necrosis of the bony structures. The septum is a frequent site of ulceration, especially the junction of the cartilaginous with the bony septum. Perforation of the septum is a common result. Many consider a perforation of the septum to be an evidence of syphilis; but experience shows that the perforation may be due to the breaking down of a tubercular infiltration or may be the result of any constant and repeated irritation of the septum. Where the bony septum is involved, the existence of syphilis is unquestionable. Next to the septum, gummata are seen most frequently in the floor of the nasal cavity. The mucous membrane and the submucous tissues, with the underlying bone, are involved, and perforation of the hard palate occurs. Frequently gummata are found in other portions of the nasal cavity, producing necrosis of the bones and great development of fibroid tissue. The deformity resulting from the destruction of the bony frame-work of the nose and the shrinking of the fibroid tissue produces the typical saddle-nose which is characteristic of syphilis.

The **symptom** of the early stage of nasal syphilis is a profuse secretion. It can hardly be distinguished from that of a catarrhal rhinitis, except that it is more obstinate and resists ordinary treatment. When it occurs in the new-born it is probably syphilitic. In the later stage there is a great tendency to the formation of crust with a mucopurulent secretion; the peculiar fetor of dry or syphilitic caries is unmistakable. With the formation of the gummata there is more or less obstruction of the nostrils through

edematous swelling. When degeneration takes place beneath the mucous membrane, or when perichondritis exists, there is always more or less pain until the pus reaches the surface.

### SYPHILITIC LESIONS OF THE PHARYNX.

Lesions of the pharynx occur in some form in the majority of cases of syphilis. The chancre or primary infiltration is more common than is ordinarily believed, and it is often overlooked owing to the insufficient illumination of the pharynx during examination. Excluding primary lesions of the lips and tongue, we find the tonsils to be the most frequent site, and, next to this, the soft palate. Contrary to the usual belief, infection in these cases has taken place most frequently through the use of pipes, eating-utensils, and public drinking-cups. The use of the last seems to be the most common source of infection. We can well imagine that the use of a cup by one having mucous patches on the lips would carry the infective material to the next one who used it. Unelean practices are responsible for only a limited number of cases. Referring to Table 3, published by Buckley, we find 307 cases of chancre of the tonsil among 9058 cases of syphilis. Schadek, among 68 cases of extra-genital chancres found in the fauces, locates 34 on the tonsil.

Chancre of the tonsil presents the appearance of an indurated ulcer of the organ, which may be limited in extent or involve a large surface (compare Fig. 575). The ulceration is superficial, but may be small, with its base covered with dirty-gray secretion. The indurated condition of the periphery declares the diagnosis, which will soon be confirmed by the glandular swellings and the lesions of the skin. In some cases the symptoms of the chancre are so slight as to escape notice; in others they are marked. Pain may be very prominent, either confined to the pharynx or radiating to the ear. The submaxillary glands become swollen, but their suppuration is rare.

Erythema of the fauces is frequent. We find a circumscribed redness of the mucous membrane involving the soft palate, the pillars of the fauces, or the tonsil. The color is a coppery-red, and it is sharply limited to certain areas. Frequently it is confined to one side, with a well-marked line of demarcation in the median line and in the line between the hard and soft palates. Occasionally we find patches of congestion on the two sides, with the median line free—the so-called “Dutch garden symmetry” (Hutchinson). This condition usually coincides with the early skin-lesions of syphilis, and is often overlooked, as it rarely gives any special symptoms. Erythematous patches may be present in the naso-pharynx, giving rise to catarrhal symptoms. We occasionally see in those who have passed through the secondary stage, perhaps years afterward, the occurrence of a subacute angina, which will yield only to the specific treatment. In a case of the writer, an angina which had been under treatment for a long time by several physicians yielded at once to a mixed treatment, and the redness entirely disappeared. With the cessation of treatment owing to an attack of grippe, the angina returned, and permanently disappeared only after a prolonged specific course.

Mucous patches are of frequent occurrence in secondary syphilis. They are found on the pillars of the palate, the tonsil, and other parts of the buccal cavity. They are usually circumscribed in extent, presenting small patches of a mother-of-pearl color. As a rule, they are level with the surface of the mucous membrane, and are brought into greater prominence through the congestion of the surrounding tissues. They present somewhat the appear-

ance of the mucous membrane after the surface has been touched with nitrate of silver. In a certain number of cases we find the patch thickened and somewhat raised above the surface, resembling in a certain degree the patches of diphtheria. They have a tendency to remain unchanged over long periods, unless modified by treatment. Occasionally we see the infiltrated patches presenting ulcerations and erosions. These are superficial in character and have a tendency to extend at the periphery. Secondary lesions appear from six months to two years after infection.

Tertiary syphilis of the pharynx is strictly the result of a gummatous infiltration of the tissues, the mucous membrane, the submucous tissues, or the bones. Manifold in its pictures, modern medicine ascribes all these conditions to degeneration of the gummatous infiltration. More or less rapid ulceration, with great destruction of tissue and the development of a cirrhotic contractile tissue, is the usual sequel. Gummatous tumors may be confined to limited areas, or the deposit may be extensive. Unless checked by treatment, they may break down rapidly, giving rise to ulceration, which in the beginning may be small and may occur at several points. If unchecked, it is prone to extend, producing great destruction of tissue. The ulcer may be round or irregular, and is surrounded by a red areola. It has sharply defined edges, and its base shows feeble granulation-tissue exuding secretions composed largely of pus and broken-down epithelium. The posterior pharyngeal wall is a frequent site of the gummatous infiltration and extensive ulceration. Superficial ulcers frequently occur in the upper part of the pharynx, and are hidden from view unless discovered through a rhinoscopic examination. When the ulcers extend deeply into the tissues, they may involve the periosteum with a subsequent caries of the bone.

The posterior surface of the palate is a common site of a softening gumma. The destructive process may be very rapid, and perforation of the palate is quickly established; unless checked, the eroding process may continue until more or less of the palate is destroyed. The dependence of the ulceration upon the gummatous deposit is strikingly shown in some of these perforations of the soft palate, where we see large areas destroyed, with normal strings of tissue remaining between the perforations. Ulcers of the tonsil are not usually as large as those of the palate; they are more longitudinal, and show less tendency to extend. Several ulcers may be seen at the same time on the tonsil with sound intermediate tissue. The deep perforating ulcer has occasionally produced erosion of a blood-vessel with hemorrhage. Gummatous tumors occur on the posterior pharyngeal wall and the hard palate, where they show little tendency to soften. They appear as hard, firm, rounded tumors covered with mucous membrane. They may be quite large and present the appearance of a fibroma or a sarcoma. A case of the writer presented a gummatous tumor of the tonsil, as large as a small hen's egg, largely blocking up the fauces. In some of these cases the diagnosis is difficult, and can only be affirmed after a microscopical examination or the test of treatment.

Another result of gummatous infiltration is seen in the development of contraction and scar-tissue. A great and varied distortion of the pharynx is the result, and membranous folds are formed which cause great inconvenience and distress. Adhesion of the soft palate to the posterior pharyngeal wall, often complete, or with a small opening, is not uncommon. A membranous adhesion between the lower pharynx and the root of the tongue, largely closing the larynx and esophagus, has several times been observed. Such a case came under my observation a few years ago. The opening was



large enough to allow free respiration, but great difficulty was experienced in swallowing. Adhesions between the soft palate and the palatine folds are of frequent occurrence. They are usually unilateral.

Symptoms of secondary syphilis of the pharynx may differ but slightly from those of an ordinary catarrhal pharyngitis. There may be a sensation of dryness of the membrane, and more or less pain on swallowing. The secretions are usually increased. The glands of the neck are swollen; but this may also result from other causes. The occurrence of the tertiary stage gives rise to more prominent symptoms. The pain of swallowing may become so intense as almost to preclude the taking of food. It may radiate to the ears and assume the form of a neuralgia. The secretions are greatly increased, and become purulent and ropy. When the palate is involved either through infiltration or ulceration, we find a disturbance of the speech, and fluids are often regurgitated into the nasal cavities.

### SYPHILITIC LESIONS OF THE LARYNX.

The larynx becomes involved in a large number of cases of syphilis. The disease may be in the milder forms, and be overlooked, or in the most destructive, which cannot escape notice. Authorities are greatly at variance as to its frequency, laryngologists meeting a larger percentage of cases than the dermatologists. In a large number of cases laryngeal syphilis appears secondary to syphilis of the pharynx. It has, however, been frequently observed independently, often occurring many years after the initial lesions. It may occur in varied forms from two months to fifteen years after infection. Primary syphilis of the larynx is almost unknown, although it has been reported. Secondary syphilis has been observed as early as the second month—the usual time is from six months to three years after the infection. It assumes the forms of an erythema, mucous patches, and erosions.

Erythema or syphilitic catarrh is an early and most constant lesion. It resembles so closely an ordinary catarrhal laryngitis that in many cases it is impossible to make a differential diagnosis unless it is accompanied by the skin-lesions. Even in such cases the occurrence of laryngeal hyperemia may be an accidental condition of ordinary catarrhal laryngitis in a syphilitic subject. The true nature of the lesion can be determined only by the result of treatment. In certain typical cases the color of the membrane is of a deeper red than that of an ordinary catarrhal hyperemia. It is more persistent, and there is usually a greater swelling of the membrane. In other cases it is found confined to limited areas. Mucous patches are not frequent. They have been reported as occurring on the under surface of the epiglottidean folds, the true and the false cords. They are similar in appearance to the mucous patches of the pharynx. They seem to be the origin of the erosions which are often seen in the larynx. Occasionally they present the appearance of condylomata.

Symptoms of the second stage are obscure, and will depend upon the area affected. When the vocal cords are concerned, the symptoms resemble those of a catarrhal laryngitis; the voice may become rough and hoarse. If the arytenoid cartilages or the interarytenoid fold are involved, the patient may have an irritative or tickling cough and clearing of the throat. The tertiary lesions of the larynx appear from the third year of infection on to an indefinite period. Cases are on record in which the laryngeal affection has arisen twenty years after the primary lesion. It assumes the form of a gummatous infiltration or tumor; and when softening occurs there is ulceration, and the



gummatous infiltration will present the appearance of a thickened, infiltrated area. This may extend through the submucous tissue, involving the perichondrium, while the mucous membrane of the affected area may be normal or reddened. The epiglottis is the most frequent site of the infiltration (Fig. 620), but it is also seen on the true cords, false cords, and the ary-epiglottidean folds. The epiglottis may be changed into a swollen, deformed organ, and the

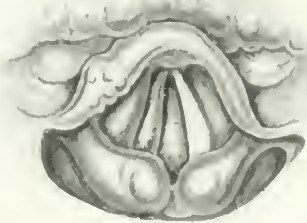

FIG. 620.—Fresh gumma on the epiglottis and syphilitic infiltration of the right true vocal cord and ventricular band (Grünwald).

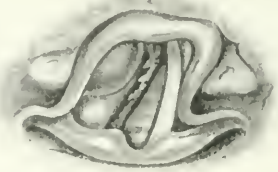

FIG. 621.—Tertiary syphilitic deposits in the right cord and ventricular band with gumma of the adjacent part of the epiglottis (Grünwald).

ary-epiglottidean folds become large and prominent: the swollen false cords may largely fill the glottic opening. Gummatous tumors are simply circumscribed areas of infiltration which develop into the form of a tumor (Fig. 621). They occur in all parts of the larynx, and may be single or multiple. The tendency of the gummatous formation is to soften, and when this occurs the destructive process is very rapid. It burrows deeply in the tissues, producing a deep, excavated ulcer, with destruction of the underlying cartilage. The epiglottis may be partially eroded or completely destroyed through the necrotic process. The crico-arytenoid joint and both the true and false cords may be involved in the same process. The collateral edema and swelling may be so great as to occlude the glottis. The deep ulcer of syphilis has a certain characteristic appearance: the edges are sharply defined, and the base is covered with gray secretion. In form it is irregular and it is surrounded by infiltrated tissue. The superficial ulceration is not so characteristic. It may have an extensive surface, and has a great resemblance to a tubercular ulceration.

The differential diagnosis between a syphilitic ulcer of the late stage and the tubercular will often be difficult and at times impossible, without the consideration of other signs and symptoms of the disease; this will especially be the case where a mixed infection is present (Fig. 622). The syphilitic ulcer has sharp, better-defined edges; it is apt to be single, and presents the appearance of an excavated area with a reddened, thickened surrounding. The tissue about a tubercular ulcer shows an anemic color. A common sequence of the ulceration will

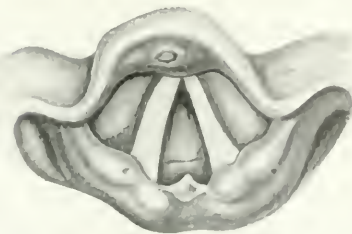


FIG. 622.—Tubercular outgrowth in the intra-arytenoid space and tertiary syphilitic infiltration and ulcer of the epiglottis (Grünwald).

be found in the development of the contractile scar-tissue, which produces great distortion of the laryngeal structures and which remains permanently, giving in after years positive evidence of the disease. Adventitious membranes may be formed between the cords, largely closing the glottis.

## SYPHILIS OF THE TRACHEA.

Syphilis of the trachea assumes the form of erythema in the early, and gummatous infiltration in the later stage; it is frequently consecutive to the disease in the larynx. Erythema of the trachea can be discovered only through the use of the laryngeal mirror. There are no symptoms, unless there be irritating cough. The gummatous ulcer can occasionally be seen in the mirror, if it occurs on the portion of the trachea which can be illuminated. It is more frequently entirely overlooked, and is suspected only when the development of stenotic symptoms shows the presence of contractile scar-tissue. It may be multiple, and invade large areas of the trachea, and it may be superficial or deep. The deep ulcer may break down the cartilage and form a connection with the adjacent organs. Contractile adhesions may result, largely occluding the lumen of the trachea. In a case of the writer the upper portion of the trachea was almost entirely closed by adhesions; the patient survived fourteen years after a low tracheotomy.

## SYPHILITIC LESIONS OF THE LUNGS.

That syphilitic lesions of the bronchi and lungs occur has been proven by post-mortem examinations, but the diagnosis in most cases is extremely difficult, if not impossible, during life. Post-mortem specimens have shown the presence of the gummatous infiltration, and this has been found broken down, forming cavities. Syphilitic phthisis can only be suspected when it occurs in a person subject to syphilis, and even then a possibility of a mixed infection must be considered. The physical signs and symptoms are similar to those occurring in many cases of ordinary phthisis, and it resembles those cases which have been justly termed a local tuberculosis of the lungs. The general symptoms are slight, and emaciation is not so marked as in tubercular phthisis. The physical signs will show a local infiltration confined to single portions of the lungs. We may have the moist râles and bronchial breathing with dulness, if a perceptible area has been infiltrated: the cavity signs will be present where an abscess has emptied into a bronchus. The iodid-of-potash test will be the leading element in the diagnosis.

## TREATMENT.

The treatment of syphilis of the respiratory tract follows the rules of the treatment of general syphilis, with the addition of such local treatment as may be needed in individual cases. The accepted rule of giving the mercurials in the early stage and the iodids in the later will be generally followed. The experience of the writer has shown, however, the greater value of the so-called "mixed treatment" in almost all stages of the disease. The fresh solution of a combination of corrosive sublimate, gr.  $\frac{1}{12}$ , and iodid of potassium, gr. x, has given quicker and better results than the use of the same drugs in pill form, as biniodid or protiodid of mercury. In addition, when it is necessary to check ulcerative action or to promote the absorption of gummatous infiltration, the iodids must be given in larger and increasing doses. Occasionally a course of mercurial inunction will develop the power of the iodids when the response to treatment is not satisfactory. In all cases where there has been a development of syphilitic anemia a course of tonics will be indicated; and we should have decided benefit from the use of iron, manganese, strychnia, and cod-liver oil.

The local treatment, although secondary, will be essential in most cases of nasal and throat syphilis. The thorough cleansing of the surface by means of the spray or syringe, using an antiseptic and alkaline solution, will favor resolution and will prepare the way for the proper application of such local remedies as may be indicated. In nasal syphilis such local treatment is all-important. The dead bone should be removed, if this can be done without violence, and the ulceration touched with nitrate of silver. In the pharynx and larynx the application of compound solution of iodine will hasten the resolution of the gummatous infiltration; and acid nitrate of mercury or nitrate of silver will tend to bring about the healing of the ulceration. In ulcers of the larynx the insufflation of aristol or iodoform with morphia will be grateful and useful. The cicatricial contractions, with the resulting stenosis in both the pharynx and the larynx, will be troublesome and obstinate. The results of surgical treatment of these conditions have been most unsatisfactory—division of the adhesions and membranous formations by either the knife or the cautery being almost always followed by a re-growth of the divided structures. Gradual dilatation has given the best results. No surgical interference is justifiable until the disease has become quiescent.

# NEOPLASMS OF THE UPPER AIR-PASSAGES.

BY JONATHAN WRIGHT, M. D.,

OF BROOKLYN, N. Y.

As introductory to the subject, I translate from the interesting and valuable work of Prof. Moritz Schmidt, the initial page of his chapter on "New Growths of the Upper Air-Passages:"

"In order to give some idea of the frequency of neoplasms in the upper air-passages, I will make a résumé of those observed by me in the last ten years. These occurred among a total number of 32,997 patients, and were as follows:

## In the nose :

- a.* Mucous polypi, 757 (462 men; 295 women).
- b.* Fibroma, 2 (men).
- c.* Papilloma, 6 (3 men; 3 women).
- d.* Lymphoma, 2 (women).
- e.* Lympho-sarcoma, 2 (women).
- f.* Cyst, 1 (man).
- g.* Sarcoma, 6 (1 man; 5 women).
- h.* Carcinoma, 5 (3 men; 2 women).

## In the naso-pharynx :

- a.* Fibroma, 13 (7 men; 6 women).
- b.* Cysts, 101 (60 men; 41 women).
- c.* Angio-sarcoma, 1 (man).
- d.* Sarcoma, 1 (man).

## In the oro-pharynx :

- a.* Fibroma, 3 (1 man; 2 women).
- b.* Papilloma, 40 (29 men; 11 women). In reality the figures should be higher, since from the slight interest in these growths, careful account of them was not kept.
- c.* Cyst, 1 (man).
- d.* Tonsillar polypi, 5 (3 men; 2 women).
- e.* Sarcoma, 2 (1 man; 1 woman).
- f.* Carcinoma, 16 (15 men; 1 woman).

## In the larynx :

- a.* Fibroma, 256 (178 men; 78 women).
- b.* Papilloma, 46 (31 men; 15 women).
- c.* Singers' nodes, 109 (56 men; 53 women).
- d.* Lipoma, 1 (man).
- e.* Myxoma, 3 (men). In recent years they are not especially mentioned. Weigert regards them as edematous fibrous polypi. They are included under (*a*).
- f.* Fibro-myxoma, 1 (man).
- g.* Tubercular tumors, 36 (14 men; 22 women).
- h.* Cyst, 8 (2 men; 6 women).
- i.* Sarcoma, 3 (men).
- k.* Carcinoma, 75 (61 men; 14 women).

## In the trachea :

- a.* Carcinoma, 2 (1 man; 1 woman)."



## NASAL NEOPLASMS.

Neoplasms of the nose and throat, of inflammatory origin, are met with very frequently. At a glance it may be seen in Schmidt's tables how markedly the mucous polypi preponderate over all other nasal growths. The same may be observed in the larynx, under the heads of fibroma and singers' nodes. True tumors, especially those of benign origin, are excessively rare. Much confusion has arisen from the mistaken conceptions of laryngologists in regard to the pathological character of these growths. Much of this has resulted from the exceedingly unsatisfactory theories of the pathogenesis of tumors in general. It is doubtless true that there are many neoplasms which to all histological appearances are true tumors, which yet depend on the over-nutrition of inflammatory processes for their origin. It is not the province of the writer to attempt here the task of drawing a satisfactory line of division between true tumors and the neoplasms of inflammation.

**Edematous polypi** of the nasal mucous membrane belong to the latter category. They are usually called myxomata, which in some degree they resemble, both microscopically and macroscopically; but they are in the vast majority of the cases, in the nose, the result of a chronic inflammation; and hence, serous infiltration being their most marked characteristic, they are better called edematous polypi. It should be remembered that the word polypus refers simply to their pedunculated form. Exactly the same histological condition is found in the nasal mucous membrane in a sessile form.

**Histology.**—The epithelium resembles that of the surrounding mucous membrane—*i. e.*, columnar ciliated cells in the upper part of the nasal chambers and non-ciliated below; flat cells in the lower pharynx and larynx. This epithelium may undergo metamorphoses from the attrition of surfaces or other irritation, such as the flowing of pus from the ethmoidal sinuses, so that the cilia may be lost from the columnar cells and the latter become more or less flattened, resembling the squamous type. The layers may become thickened either uniformly or digitations may form, dipping into the stroma at irregular intervals. The epithelium may, on the other hand, be entirely unchanged.

*The stroma* is separated by the effused serum into bundles, leaving spaces between. The size of these spaces or meshes and the quantity of the stromafibers differ greatly—apparently according to the degree and the age of the process.

*The fluid* contains some mucin and fibrin. When coagulated in the hardening processes of histological technic, the fibrin, unless broken up into granules, may be easily mistaken for connective-tissue fibers. Round cells of varying diameters are entangled in the meshes of the stroma and in the fibrin. These and connective tissue are found most abundantly in the region of the blood-vessels (Fig. 623) and glands, if they exist.

*Glands* are usually scanty. If present at all, they are usually found in or near the pedicle. From being barely visible, they are frequently dilated so as to form cysts of a size occupying almost the whole of a large pedunculated polypus (Fig. 624). They are found also in the sessile forms.

*Blood-vessels* are also scanty and capillary in size, being found most abundantly just under the epithelium, forming a delicate red tracery visible to the naked eye.

*Nerves* have been demonstrated in the stroma.

*The pedicle*, when it exists, is made up of the firmer unseparated stroma of the mucous membrane.

**Etiology.**—The so-called “polypoid degeneration,” although histologically the same, is more conveniently considered under the head of chronic rhinitis, where, indeed, both forms pathologically belong.

Both forms are the result of chronic inflammation of the nasal mucosa. There may or may not have been previous symptoms of this rhinitis, but evidently the effusion of serum into the tissues is caused by some vascular

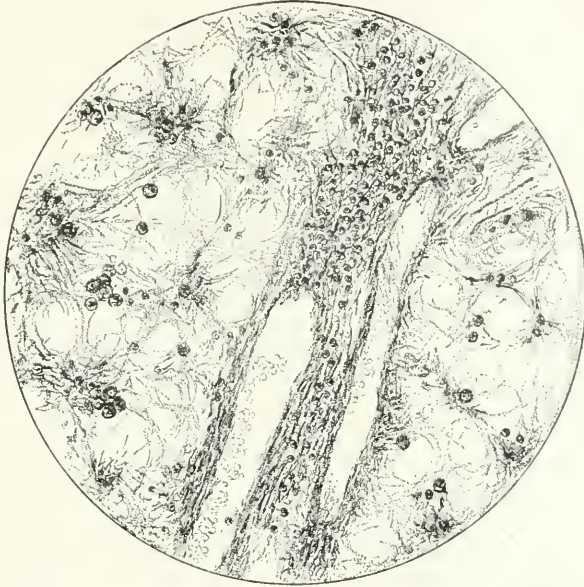

FIG. 623.—Stroma, round cells, and blood-vessels of an edematous nasal polyp.

change which is as yet imperfectly understood. We may conjecture from anatomical reasons,<sup>1</sup> which it is not necessary to detail here, that there is some interference with the efferent blood-current as well as with the walls of the capillaries themselves. Chronic hypertrophic rhinitis rarely occurs in children; therefore these growths are more common in adults than before

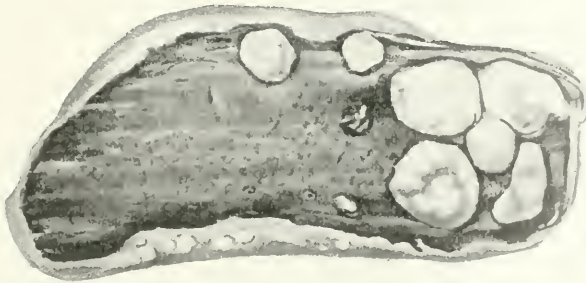


FIG. 624.—Cysts in a polyp.

twenty. They have, however, been reported at all ages, and even congenital cases have been observed. They are more common in men than in women. Out of 200 cases, according to Morell Mackenzie,<sup>2</sup> 123 occurred in men.

<sup>1</sup> “A Consideration of the Vascular Mechanism of the Nasal Mucous Membrane,” etc., *Amer. Journ. Med. Sci.*, May, 1895.

<sup>2</sup> *Diseases of the Throat and Nose.*

**Situation.**—A nasal edematous polypus has its origin in the vast majority of cases from the mucous membrane covering the middle turbinated bone or from that part of the ethmoid near the hiatus semilunaris. Edematous polypi may be found, however, at any point within the nasal chambers. At the posterior end of the turbinal bodies and on the septum we usually find the sessile form combined with dilatation of blood-vessels; rarely, pedunculated growths are found in these localities. The size of the polypi varies greatly—from that of a pin's head, sprinkled over the mucous membrane of the middle turbinated bone, to enormous dimensions. I extracted one from the nostril of a man with symptoms extending over twenty years, which presented externally and projected posteriorly into the pharynx. It had filled one nostril completely, and had pushed the cartilaginous and bony septum so far to the other side as to cause complete occlusion. It was folded on itself, so that when it lay straightened out on the table it measured nearly 5 inches in its long diameter, and in some places was more than  $1\frac{1}{2}$  inches thick. Its pedicle was comparatively small. The pressure which it had exerted had resulted in the atrophy of the internal structures of the nose to such an extent that the enormous cavity left after extraction had smooth walls. I can find no record of any as large as this; but several have been reported that approximated it in proportions. They rarely exist separately, but when complete nasal obstruction exists there are usually multiple growths. Occasionally they fill the ethmoid cells, causing absorption of their bony walls, and once or twice I have seen distortion of the bridge of the nose. The edematous process, by pressure or the extension of the inflammation, frequently causes caries or disintegration of the ethmoidal bony tissues, and this has been called by Woakes<sup>1</sup> "necrosing ethmoiditis." On this account the masses removed frequently have spicula of bone embedded in them. The bone has been described by some writers as newly formed. This is probably a mistake.

**Symptoms.**—These depend largely upon the size and number of the polypi and the extent of the edematous process. Nasal obstruction may be complete on both sides, giving rise to great discomfort, or one or more polypi may exist in the nose for years without signs. A flapping valve-like action on respiratory efforts may be appreciated by the patient or even heard by the examiner.

Headaches are very common, and this is especially the case when the polypi have their bases of attachment high up, or if they invade the accessory sinuses.

A watery discharge from the nose frequently exists, causing excoriation of the margins of the nostrils and redness of the skin of the nose. This may be accentuated to an erysipelatous flush over the nasal regions.

Various complications—ethmoiditis, frontal, maxillary, or sphenoidal sinus-troubles—may be present; the patient frequently suffers from catarrhal deafness. All symptoms are aggravated by cold, damp weather.

**Examination** shows masses of varying extent blocking the nasal chambers or hanging down from above. They have the appearance of the pulp of a grape, and are frequently traversed by a delicate tracery of red capillaries. The color may be pink or of a dusky-red hue. Rarely, in large nasal chambers, the attachments may be seen along the borders of the middle turbinal, but usually the masses themselves preclude any attempts at inspection of the upper region of the nose, and it is impossible in the majority of cases even to ascertain with a probe the exact point of insertion. There may be

<sup>1</sup> *Nasal Polypus.*



great tenderness, but usually the fosse are tolerant of examination. With a rhinoscopic mirror the masses may be seen projecting into the naso-pharynx. They may be confined to one side, but usually exist to an unequal degree on both.

**Treatment.**—Modern rhinology has practically abandoned all methods of removal but that by the nasal snare.

It is frequently desirable, and occasionally possible, to remove the anterior end or lower border of the middle turbinated bone in order more surely to reach their place of origin. This has been especially urged by Dr. Casselberry,<sup>1</sup> who has devised an instrument for that purpose. Various other instruments have been used, such as rongeur forceps, snares, drills and trephines. It is an operation which the writer has frequently found impossible to do satisfactorily. When disease of the ethmoid cells and of the middle turbinated bone coexist with the polypi, as happens in a large proportion of cases, it is well to remove as much of the bony walls as can be included in the snare or nipped off with rongeurs, care being taken not to encroach upon structures lying too close to the cribriform plate of the ethmoid. When, however, extensive bone-involvement coexists, the treatment of that becomes the chief aim and the extraction of polypi merely incidental.

It is said that edematous polypi tend to recur. When a polypus is severed at its base, it is doubtful if another appears in the same locality. When the middle of the mass is cut through by the wire, that portion left behind will sometimes shrivel up, but usually it will grow again to nearly its former size. Apparent recurrence comes from the pathological fact that large areas of mucous membrane in the middle meatus are edematous and send forth new buds and projections as fast as room is made below for them. An attempt should therefore always be made to eurette this surface or cauterize it thoroughly. The cauterizer, however, should never be used unless a view can be had of the field of operation. Most frequently the bases of these growths are out of sight. The eurette in skilful hands is then of service. As may be readily understood, no certain assurance can ever be given after any operation or series of operations, however thorough, that further polypi may not subsequently develop; and the patient should be cautioned to present himself after a lapse of several months for a careful inspection of the nasal chambers. Not infrequently it will then be seen that recurrence has not taken place, but that more or less atrophy of the mucosa has supervened. The question of the degeneration of nasal polypi into sarcoma has been much discussed. It is impossible to deny that this does sometimes take place, but many of the cases so reported are open to well-grounded suspicion of having been sarcomatous from the first, as many malignant growths present an edematous appearance.

**Vascular Neoplasms of the Septum.**—These are very frequently called angiomas, but they usually have exactly the same structure as do the hypertrophies of the posterior border of the inferior turbinal bodies, and are evidently dilatations of new and old blood-vessels in the mucous membrane of this locality. Many cases reported as angiomas are apparently sarcomatous or fibromatous growths, in which vascular dilatation is a marked feature. This is especially true of growths occurring elsewhere than on the septum or in the erectile tissue of the turbinal bodies. Such are many of the growths reported in Roe's tables, in the *Transactions of the American Laryngological Association*, 1885.

In the *Archiv für Laryngologie*, Bd. 1, there is a symposium of reports

<sup>1</sup> *Trans. Amer. Laryng. Assn.*, 1894.



of vascular tumors of the septum: 13 were reported, and 5 cases may be selected from Roe's tables as undoubtedly benign vascular neoplasms; I have sections of 2 other growths, making altogether 20.

Some of these doubtless are true angiomata—*i. e.*, made up of newly formed and dilated vascular channels; but it is impossible to separate them from the vascular growths which are entirely made up of an hypertrophy of one or more of the elements of the normal mucous membrane combined with marked vascular changes. The fibrous elements may predominate or the lymphoid layer may be greatly proliferated; but more frequently there is an unequal and irregular increase of all the elements of the mucous membrane. The surface-epithelium is usually proliferated, and frequently the cells are altered in shape. In other words, marked vascularity is a characteristic of all septal neoplasms.

Growths of similar structure in the erectile tissue of the turbinal bodies—the “turbinal varix” of English writers—will not be considered here, as they are usually included under the head of hypertrophic rhinitis.

**Symptoms.**—Nasal obstruction on the affected side may have existed for many years. Hemorrhage from the nostril frequently occurs, and may be dangerously abundant. The growth does not erode the neighboring tissues, although it may completely fill the lumen of the naris. Some of the cases reported have been of rapid growth, and yet apparently benign.

**Examination** shows a rounded growth with a somewhat irregular surface of a bright-red or dark-purple appearance. It may be abraded in places, and when probed bleed easily. It is more or less movable, according to its size and the thickness of its pedicle. It is usually attached to the anterior part of the septum.

**Prognosis.**—If the growth is shown to have no malignant elements, the prognosis is good. Removal is comparatively easy, and recurrence is very exceptional.

**Treatment.**—The galvano-cautery snare, armed with an irido-platinum-wire loop, is the instrument of choice. Jarvis's original snare may be used and the steel-wire loop slowly tightened, sometimes using several hours in the process. A rapid cutting-operation is pretty sure to be followed by severe hemorrhage, and this may occur after any operation with the wire, however slow. For slight oozing the galvano-cautery is sometimes efficacious. Firm packing with strips of iodoform or borated gauze should be employed in obstinate cases, and pressure exerted against the ala from the outside, since the site of the growth is usually far enough forward for this simple procedure to avail.

**Fibroma.**—While it occasionally occurs in and about the naso-pharynx, fibroma springing from the nasal structures is exceedingly rare.

One reported by Dr. Charles H. Knight<sup>1</sup> I had the privilege of examining microscopically (Fig. 625). It was a smooth movable growth, attached to the posterior end of the middle turbinal body, and was darker in color than the average edematous polyp. Microscopically it was seen to be covered by columnar epithelium, and was made up exclusively of homogeneous bundles of curling elastic fibers. Its removal by the cold snare was easily performed and produced no hemorrhage. There was no recurrence. A number of cases have been collected from literature by Bosworth,<sup>2</sup> Casselberry and others; but a perusal of the reports leaves one in considerable doubt as to the accuracy of the histological diagnosis or of their intranasal origin. Even the case referred to here as of undoubted histological character and spring-

<sup>1</sup> *Manhattan Hospital Reports*, Jan., 1895.

<sup>2</sup> Bosworth: *Dis. of Nose and Throat*.

ing from an intranasal structure, might be more conveniently considered under the heading of naso-pharyngeal growths.<sup>1</sup>

**Fibroma Papillare or Papilloma.**—Ten or a dozen undoubted cases, and probably a few more, have been reported, but some confusion exists as to their identity; the same name having been given by Hopman<sup>2</sup> and many of the Germans to the papillary hypertrophies of the nasal mucous membrane, which occur so frequently in the regions of erectile cavernous tissue. True papilloma is made up of epithelial cells supported by a delicate framework of new connective tissue, rising on the surface as papille and dipping into the underlying stroma as digitations. They grow principally by the proliferation of epithelial structure. They occur in the nose, either as soft pedunculated masses or as hard warts on the anterior portions of the septum. The soft growths also occur on the floor of the nose and on the anterior portions of the external wall. So constantly is this the rule in those cases which have been examined and properly classified, that any papillary growth seen to be springing from other localities or reported without microscopical proof as having been found elsewhere in the nose, may be regarded as probably not a papillary fibroma. Exactly such a growth as figured in Zuckerkandl's "Anatomy of the Nasal Fosse"—springing from the middle of the under surface of the inferior turbinal—I once examined and found to be a papillary hypertrophy.<sup>3</sup>

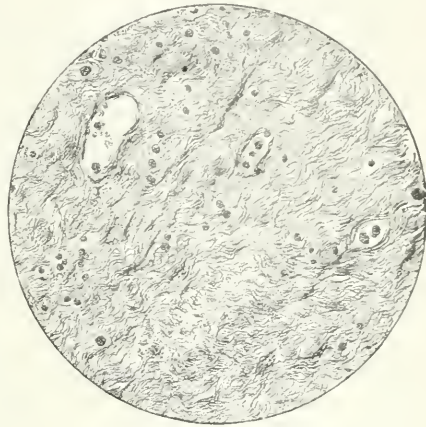


FIG. 625.—C. H. Knight's case of nasal fibroma.

True papillomata of the septum have been observed at all ages. I have examined one for Dr. Arrowsmith of Brooklyn coming from the nasal fossa of a child of five, and Santi has reported one in a man of eighty-four. Sex seems to have no influence.

They are usually of slow growth and painless, but sometimes bleed easily. They cause nasal obstruction and have a valve-like action on the respired air, as in the case of the ordinary polyp. They have a vascular fungous look and are freely movable. Hemorrhage on removal may be abundant, but is easily controlled. They do not tend to recur.

<sup>1</sup> Bosworth, by saying that all naso-pharyngeal fibromata spring from the basilar process of the occipital or the body of the sphenoid bone, excludes all of those whose origin is in the immediate vicinity, just within the choanae. These he evidently includes among the nasal growths, since he refers to 41 cases in literature, most of which seem to have had all the characteristics of the naso-pharyngeal growth and some probably sprang in reality from behind the choanae, forming secondary attachments within the nose. Mackenzie, on the other hand, gives a more liberal interpretation to the term naso-pharyngeal fibroma, and includes those which spring from the immediate vicinity of the naso-pharynx and present the same or nearly the same clinical features. Thus it comes that he is able to report but one case of his own of nasal fibroma and to refer to very few in literature. The case of Dr. Knight sprang from the posterior end of the middle turbinal body and projected into the naso-pharynx. So that nearly all true fibromata have their origin on or in the immediate vicinity of the roof of the naso-pharynx; and absolutely none occur in the anterior part of the nasal fossa. This is exactly what we should expect, when we remember that the fibrous sheet at the roof of the pharynx spreads out laterally upon the pterygoid plates, and anteriorly for some little distance along the roof of the nose, and on the vomer and posterior surfaces of the upper turbinated bones.

<sup>2</sup> Virchow's *Archiv*, 93, 1883, p. 213.

<sup>3</sup> *N. Y. Med. Journal*, Oct. 13, 1894 (Dr. Richard's case).

The following references will be found to include nearly all the reports of true papillomata up to August, 1896, though some of these are of doubtful character :

- Michel: *Krankheiten der Nasenhöhle* (Translated by Shurly, p. 72).  
 Zuckerkandl: *Anatomie der Nasenhöhle*, 1882, p. 70.  
 Aysagner: *Annales des Maladies de l'Oreille*, Nov. 1885, p. 335.  
 Butlin: *St. Bartholomew's Hospital Reports*, 1885, p. 150.  
 Verneuil: *Bull. et Men. de la Société de Chirurgie de Paris*, No. 12, 1886, p. 658.  
 Solis-Cohen: *Revue de Laryngologie*, 1889, p. 151.  
 Cozzolino: *Revista Clinica et Terapeutica*, No. 2, Feb., 1887, p. 75.  
 Mulhall: *Trans. Amer. Laryng. Assn.*, 1890.  
 Santi: *The Lancet*, Dec. 8, 1894.  
 Wright: *Trans. Amer. Laryng. Assn.*, 1895.  
 Mackenzie (G. Hunter): *Lancet*, Aug. 15, 1896.

**Treatment.**—Removal by the snare can usually be accomplished without much hemorrhage. As the growths are situated in the anterior part of the nose, bleeding, if it occurs, may be easily controlled.

**Bony cysts** of the nose are of moderately rare occurrence. They are found in the anterior end of the middle turbinated bone, and may contain only air or a yellow viscid fluid or pus.

**Pathology.**—The middle turbinated bone is considerably enlarged anteriorly, and is covered by hypertrophied and usually edematous mucous membrane. Edematous polypi are frequent complications.

**Microscopical examination** of the bony wall must be made after decalcification. Sections are then cut, and it will be seen that the cyst-cavity, which may be as large as a cherry, is lined by a scanty stroma without glands or many blood-vessels and by columnar ciliated epithelium. The

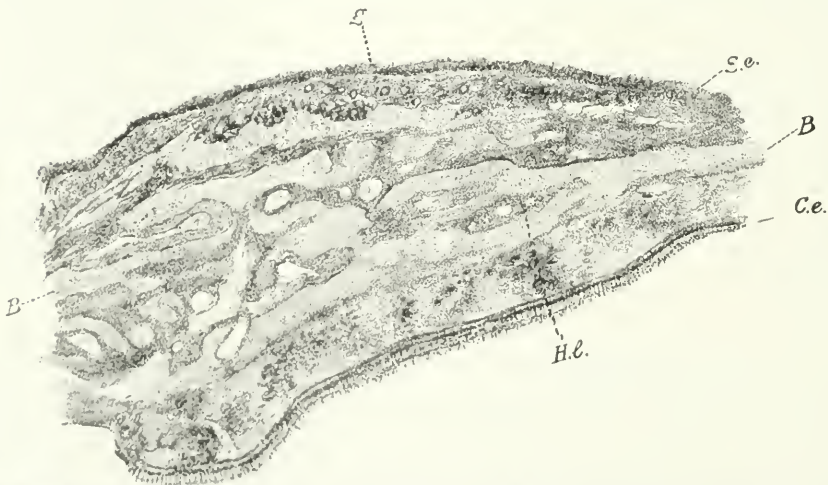


FIG. 626.—Section of bony cyst: *B*, bone; *H.l.*, Howship's lacunae with new connective tissue and blood-vessels; *C.e.*, ciliated epithelial lining of cyst-cavity; *S.e.*, surface epithelium; *g.*, glands.

bony tissue itself is seen to be in a condition of hyperplastic and rarefying inflammation, with the formation of new bone-tissue and the absorption of old and new bone. This is carried on by means of osteoblasts and osteoclasts and the formation of Howship lacunae. There are lakes, or rather gulfs and bays, of new connective tissue, which nourish the peculiar cuboidal cells which line their shore, and which have the power of secreting and



absorbing bone-salts. Figs. 626, 627, from a section of a specimen sent me by Dr. Butts of New York City, show this process, which is essentially the same as the physiological process of bone-growth.

**Occurrence.**—The condition is almost wholly confined to women after puberty and before old age. We see here, as well as in atrophic rhinitis and

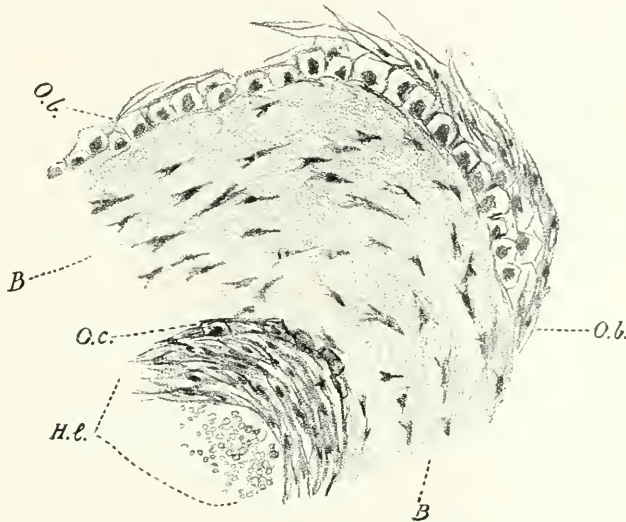


FIG. 627.—Section of bony wall of cyst, showing a Howship lacuna with its marginal osteoclasts (*O.c.*) below, and the osteoblasts (*O.b.*) on the convexity of the bony lamella.

naso-pharyngeal fibroma, the marked influence of sex on morbid processes in the nose. I am not aware that these cysts have been reported as existing in any other locality in the nose than at the anterior end of the middle turbinated bone.

**Symptoms.**—Pain with frequent exacerbations is the prominent symptom in these cases. Nasal obstruction also exists, but may not be complete: at times it is the only symptom present. As the patient nearly always has edematous polypi in the same nostril, the symptoms depend somewhat on that condition. These symptoms have usually extended over many years.

**Examination** after removal of projecting polypi shows a rounded resisting mass at the anterior end of the middle turbinated bone, a part of which it forms, pressing firmly against the septum and sometimes causing a marked deviation of it. The feeling imparted to a probe conclusively shows that the mass is made up of bone.

**Etiology.**—From what has preceded, the inference is pretty clear that we have here a pathological condition which is the result of chronic inflammation. This, beginning in the mucosa, results in the formation of edematous polypi, as explained under that heading. The inflammatory process is in time transmitted to the underlying periosteum and bone, and we have then the condition of hypernutrition which causes the growth of the bony structure. This we should expect to result in the porous formation observed in other hyperplastic bone-processes, and this we frequently see in dried specimens of the middle turbinated. Since there is mucous membrane lining the walls of these cysts provided with columnar ciliated epithelium, we must presume that communication has existed at some time with the external sur-



face. The demonstration of the proliferative bone-formation in the walls of these cysts shows pretty clearly the method of development into large spaces of what were originally small cavities. Their communication with the ethmoidal labyrinth may have closed before the end of embryonic development, or it may have existed prior to inflammatory changes and have been closed by them, or the communication may still exist. Dr. T. Passmore Berens of New York was kind enough to show me a dry specimen of cystic enlargement of the anterior end of the middle turbinated bone, in which the communication was wide and direct.

**Treatment.**—The steel-wire snare may be used to remove these bony outgrowths. If they are too resistant or too firmly wedged against the septum to allow the use of this instrument, a perforation may be made into the cavity with a dental burr or trephine and the bony walls then removed piecemeal with rongeur forceps. Hemorrhage may be considerable, and there may be considerable inflammatory reaction. When, as frequently happens, there are carious bone and edematous polypi, curetting must also be employed.

#### LITERATURE OF BONY CYSTS OF THE NOSE.

- Zuckerkaudl: *Norm. and Path. Anatomie der Nasenhöhle*, 1893, vol. i. p. 63.  
 Stieda: "Inaug. Dissertation," Rostock, 1895.  
 Glasmacher: *Berlin, klin. Woch.*, No. 36.  
 Beyer: *Internat. Centralt. f. Laryngologie*, etc., vol. ii., No. 5, p. 237.  
 Schaller: *Erfahrungen in der Rhin. und Laryng.*, Wiesbaden, 1885.  
 McBride: "Diseases of Throat, Nose, and Ear," original report, *Edinburgh Med. Journ.*, Dec., 1888, p. 304.  
 Schmiegelow: *Revue de Laryngologie*, etc., No. 10, 1890.  
 B. Fränkel: *Berl. klin. Woch.*, No. 22, p. 498, 1890.  
 P. Hegeman: *Ibid.*  
 Chas. H. Knight: *Trans. Amer. Laryng. Assn.*, 1891; *N. Y. Med. Journ.*, Mar. 19, 1892.  
 Stieda: *Archiv f. Laryng. und Rhin.*, Bd. 3, No. 3, 1895.  
 Wagner: *Rev. de Laryngol.*, etc., No. 22, 1895.  
 Castañeda: *Archivos Latinos de Rinología*, Sept. and Oct., 1895.  
 Macdonald: *Lancet*, June 20, 1891.  
 Zwillinger: *Wiener klin. Woch.*, No. 19, 1891.  
 Wright: *N. Y. Medical Journal*, June 27, 1896.

**Cysts of the nasal mucous membrane**, sometimes called **cystomata**, are occasionally reported. They are always, I believe, of glandular origin, resulting from the excessive dilatation of glands in edematous polypi or tissue.

**Osteoma** and **chondroma** have both been reported as new growths in the nose. They are of exceeding rarity, and are not to be confounded with the very common exostoses and echondroses of the septum.

As has been intimated, true tumors—*i. e.*, circumscribed neoplasms not due to inflammation—are rare in the nose, and in my experience such benign tumors are much more rare than malignant growths. It is exceedingly difficult, however, to gain any idea of this from rhinological literature, as all sorts of inflammatory phenomena are classified as tumors. The writer does not speak of true myxoma of the nose, because out of many hundred sections of 50 or 60 specimens of mucous polypi examined microscopically, and many more nasal neoplasms seen and operated on clinically, he has never observed a nasal growth that was plainly a true myxoma. There is hardly a case reported in literature, in which the diagnosis is not open to grave criticism from the data given or from insufficiency of data. Nevertheless, it is probable that such true tumors do occasionally grow in the nose.

## MALIGNANT TUMORS OF THE NOSE.

**Adenoma** is said to be a benign growth; but it is so frequently combined with carcinomatous or sarcomatous elements, and it is said, even when pure, to degenerate so frequently into malignancy, that its occurrence in any structure is to be looked upon with suspicion as to its benign character. Pure adenoma (Fig. 628) in the nose is almost unknown, although hypertrophy of

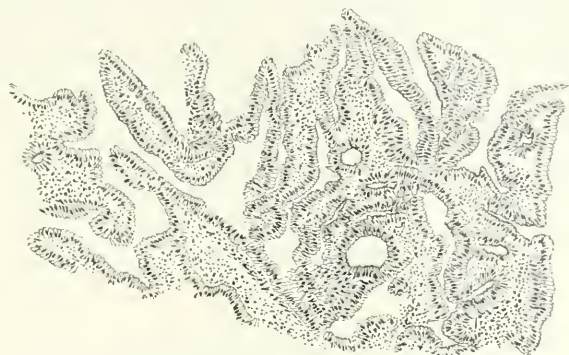

FIG. 628.—Adenoma of the nose.

the glandular structures of the mucosa is occasionally seen carried to such an extent that the question of its inflammatory origin may well be raised. A typical adenoma is made up of epithelial cells so arranged as to form convolutions and tubules more or less resembling gland-structure. Indeed, it usually springs from the glandular cells of various organs. There is very scanty connective tissue, round cells, and blood-vessels. I have in my possession sections of a nasal tumor, in portions of which, at least, pure adenomatous structure may be observed. The case was under the care of Dr. Thomas J. Harris, at the Manhattan Eye and Ear Hospital, and to him I am indebted for the following history:

"The patient, Mr. C., is seventy-five years old, and has been under my care some eighteen months. When he first came to the hospital in November, 1893, he was a most pitiful object. There was total occlusion of the nares, with muco-pus constantly dripping from them. They were filled with masses of tumors presenting all the appearances of the common gelatinous polypi. By snare and curette in a number of operations I removed everything, making a diagnosis (from repeated recurrences) of myxo-sarcoma. For nearly a year, with occasional gentle curetting, the nares remained clear. His appetite returned and he pronounced himself cured. In November, 1894, exophthalmos (left eye) appeared with constant pain. I then supposed that the ethmoid sinuses had been invaded, but on account of his age determined to attempt no operation. The nose still remained comparatively free. Some two weeks ago the mass which I sent you suddenly appeared. This I removed with the cold snare, and considerable hemorrhage followed. The macroscopical appearances of the tissue had long since changed, and it now shows much necrosis. Its malignancy has certainly very much increased in the eighteen months in which I have observed the case."

This patient, Dr. Harris informed me, lived until the following summer (1895). The greater part of the sections of the mass were taken up with convolutions and involutions of glandular epithelium. The layers of epithelium were never more than two or three deep, and were supported by a framework of new connective tissue.

In the portion of the growth sent me, from which the section shown in Fig. 628 was made, I am unable to find any plainly sarcomatous tissue; but there are extensive areas of round and spindle-cells which, although they

more closely resemble the granulation-tissue of inflammation, may be of a sarcomatous nature. Moreover, the clinical history plainly shows that the growth, at least in its later stages, was of a malignant character. By a coincidence, such as so strangely and so often occurs in clinical work, a similar instance of an adenoma—this time, however, plainly showing sarcomatous tissue—came under Dr. Harris's observation shortly after the first case.

Dr. Bosworth says that he has been able to find in literature the reports of only a very few cases, and even in these there is a reasonable doubt as to the unmixed character of the growth. Not only does it have on the one hand a puzzling resemblance and a close relation to glandular hypertrophy, but, on the other hand, it is frequently combined with epitheliomatous appearances—the so-called tubular or adeno-carcinoma.

**Papillary Epithelioma (Zottenkrebs).**—Closely allied to adenoma, if not identical with it, is a rare nasal growth which Billroth,<sup>1</sup> who reported 2 cases, called "Zottenkrebs." Michel,<sup>2</sup> Hopman,<sup>3</sup> Zarniko,<sup>4</sup> and Kieselbach<sup>5</sup> have each reported a case.

The last named called it a papillary epithelioma. It is a benign growth, as a rule, and resembles a papilloma. In Fig. 629 will be seen the drawing

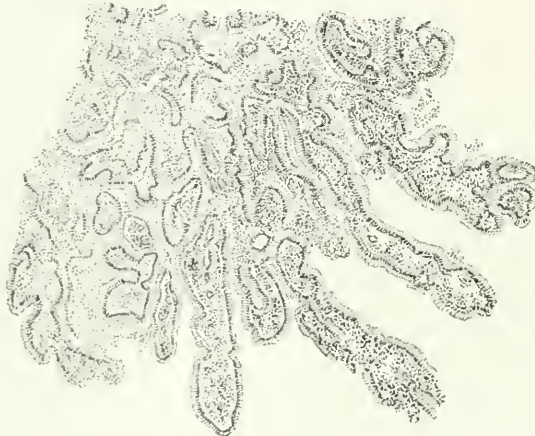

FIG. 629.—Papillary epithelioma of the nose.

of a slide sent me by Dr. Hinkel of Buffalo. It came from a tumor which occurred on the middle turbinal of a woman. It will be seen that it is made up of convolutions and involutions of columnar epithelium supported by a framework of fibrous tissue infiltrated with round cells. It forms a villous surface like a papilloma, but differs from it in that the layers of epithelial cells are not thickened and do not dip into the stroma. There is no infiltration of tissues nor concentric epithelial nest-formation in the tissues, as in cancer. In one of Billroth's cases it had existed for eleven years, and in Kieselbach's case he had removed successive portions of the growth for a period of six years. In the cases of Zarniko, Kieselbach, and Hinkel<sup>6</sup> it has been reported as occurring on the middle turbinal. In Zarniko's case it was combined with edematous growths.

From the history of Verneuil's case, which I have placed among the

<sup>1</sup> *Ueber den Bau der Schleimpolyp.*

<sup>3</sup> *Virchow's Archiv*, Bd. 93, p. 234.

<sup>5</sup> *Virchow's Archiv*, Bd. 132, p. 371.

<sup>2</sup> *Die Krankheiten der Nasenhöhle*, etc.

<sup>4</sup> *Virchow's Archiv*, Bd. 128, p. 132.

<sup>6</sup> Hinkel, *Trans. Amer. Laryng. Assn.*, 1898.



papillomata because it was so reported, we may conjecture that it was possibly also of this nature. Otherwise it is a unique case of papilloma.

**Sarcoma**, in my experience, is the most common tumor of the nasal fossæ, if we exclude those benign neoplasms which are the result of the various forms of chronic inflammation or directly connected with them. This, however, I am aware, does not coincide with the statements of those who have had larger experience and perhaps wider fields of observation. The discrepancy, as intimated above, is evidently, however, one of pathological nomenclature.

This is not the place for an extended description of the histology of sarcoma, which in the nose presents no characteristics to distinguish it from sarcoma elsewhere in the body. Dr. Bosworth<sup>1</sup> has given abstracts of the histories of 41 patients with sarcoma of the nose.

Newman, in his excellent monograph on "Malignant Disease of the Nose and Throat," gives the history of 3 cases of sarcoma and 2 of carcinoma of the nose, as well as a complete bibliography of the subject. His table of ages at which sarcoma occurs is given as follows:

|                          |    |           |
|--------------------------|----|-----------|
| Below 10 years . . . . . | 6  | per cent. |
| 10 to 20 . . . . .       | 19 | "         |
| 20 " 30 . . . . .        | 8  | "         |
| 30 " 40 . . . . .        | 9  | "         |
| 40 " 50 . . . . .        | 39 | "         |
| 50 " 60 . . . . .        | 8  | "         |
| 60 " 70 . . . . .        | 9  | "         |
| Above 70 . . . . .       | 2  | "         |

I have in my collection microscopical sections of two specimens sent me by Dr. Thomas J. Harris of New York—one of adeno-sarcoma, the other of angio-sarcoma (Fig. 631), also a specimen of endothelial sarcoma (Fig.

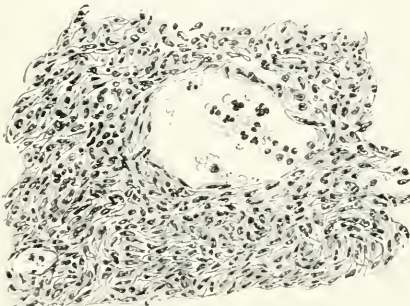


FIG. 630.—Endothelial sarcoma of the septum.

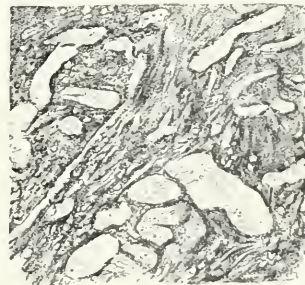


FIG. 631.—Angio-sarcoma of the septum.

630), from Dr. F. W. Hopkins of Springfield, Mass., and one of alveolar sarcoma, from Dr. W. P. Brandegee of New York. Gouguenheim and Hilary,<sup>2</sup> Dansac,<sup>3</sup> and Katzenstein<sup>4</sup> have reported 5 others. This makes 53 cases in all, from which certain facts are apparent.

It is difficult to ascertain what form of sarcoma has been most frequently observed in the nose, as the nomenclature in the reports varies so. All forms seem to have been noted, the round-celled variety perhaps more frequently.

As to age, 15 of them were between forty and fifty, 11 were over fifty,

<sup>1</sup> *Diseases of the Nose and Throat.*

<sup>2</sup> *Annales des Maladies de l'Oreille*, 1893.

<sup>3</sup> *Ibid.*, 1893.

<sup>4</sup> *Ibid.*, 1891.



and 17 were under forty years of age. Of those in whom sex was mentioned, 29 were women, 24 were men. The right side of the nose was affected 15 times and the left side 9 times.

**Etiology.**—This is entirely unknown. Too many people have chronic rhinitis to permit us to state that nasal catarrh is a predisposing factor. Injury is too infrequent an incident in the clinical history to allow us to look on it as an exciting cause. It occurs most frequently in middle life, when, as a rule, over-nutrition of cell-life has ceased and before degeneration-changes have set in.

It may be well again to say that convincing evidence of sarcomatous degeneration in benign tumors or in inflammatory neoplasms of the nose is lacking. None of the cases of such asserted malignant transformation are free from the reproach of insufficient observation or incomplete examination. Surface appearances and the early clinical history are not criteria of histological structure. The possibility of such transformation, however, cannot be denied.

**Symptoms.**—Unremittent and increasing unilateral nasal obstruction, accompanied often by repeated epistaxis, is the initial sign of malignant nasal disease. The patient soon complains of pain, referred to the brow or temple. At first a watery, then a sanious muco-purulent, discharge comes from one or both nostrils. Photophobia and epiphora on the affected side are usually present, and there may be affection of the vision from pressure on the optic nerve. The general health is at first but slightly affected. As the tumor grows, pain and loss of appetite, sleepless nights, frequent epistaxis, the nauseous odor and the mental distress cause rapid loss of strength and flesh, making an unmistakable picture of human misery. Exophthalmos, the widening of the bridge of the nose (the so-called "frog-face"), edema and discoloration of the face are the external evidences of the disease.

**Examination** at an early stage may reveal implantation of the growth at any point in the nasal chambers. It may be a smooth, somewhat resilient growth; but it is usually, especially in the later stages, a friable fungous mass, bleeding easily when touched. Portions of it are apt to be edematous, and it may have every appearance of the ordinary nasal polyp, but the color is apt to be darker. It is evidently more vascular, and it may not be at the usual site of origin of the ordinary polypus. The growth soon reaches such a size that it is impossible to make out its origin. The nasal cavity is filled, and it encroaches upon and fills the naso-pharynx. It may grow into the antrum. It soon projects from the nostril anteriorly. It may grow upward, absorbing the cribriform plate and causing death; or it may grow downward, pushing down the soft palate or eroding the bony nasal floor. Cervical glands at the angle of the jaw are usually not involved until a late stage of the disease, when the diagnosis is tolerably clear.

**Diagnosis.**—The patient usually does not present himself until it is perfectly evident that we have a malignant growth to deal with, but some cases have been reported as seen in their earliest stages. Its vascularity or its lack of transparency, its unusual implantation, its proneness to considerable hemorrhage, or its appearing as a single growth, may arouse suspicion that it is not an ordinary edematous polypus. Its prompt extirpation and microscopic examination should follow. If the microscope should reveal the appearances of a round-celled sarcoma, the clinical observer must not unreservedly accept the diagnosis, however skilled a microscopist may have made it. The vigorous administration of the iodid of potash combined with mercury may disprove the most positive assertion of the pathologist and the most careful

diagnosis of the clinician. The other forms of sarcoma, however, do not so much resemble the granulation-tissue of syphilis or tuberculosis. From the vascular growths of the septum, the so-called bleeding polypi or angiomata, sarcoma is to be distinguished by its more rapid growth and by its greater friability and tendency to bleed on slight provocation. A sarcoma of the septum in its early stages may, however, closely resemble these vascular growths both in structure and general appearance.

Prognosis depends largely on the character of the elements, the situation, involvement of parts, rapidity of growth, and the promptness with which the character of the trouble is recognized and the proper treatment instituted. Mingled with fibrous, vascular, or glandular hyperplasia, prompt and thorough eradication may result in cure, or at least in indefinitely putting off recurrence. Frequent recurrences do not necessarily make the case hopeless. It should be carefully watched and new growths promptly and thoroughly removed. When situated in the upper part of the nose it may easily have involved intricate and vital structures, rendering complete removal impossible. Wherever it may be attached, no operation should be attempted that does not hold out a chance of complete removal. Any incomplete operative measures will only accelerate the growth and render the patient's doom more certain.

**Treatment.**<sup>1</sup>—When the growth is circumscribed or has a pedicle, removal by the hot or cold snare and subsequent curetting of its base may be efficient. Application of caustics, cauterization, or electrolysis should be avoided. An external operation may hold out prospects of thorough removal which internal operations do not: if so, this heroic treatment should be promptly adopted.

**Carcinoma of the nose** is of rare occurrence. Many of the cases referred to by Bosworth are apparently not substantiated by a microscopical diagnosis. Seifert and Kahn picture one in their histological atlas, and Dr. Beaman Douglas has lately reported one in the *N. Y. Medical Record*, Aug. 8, 1896. The symptoms do not differ materially from those of sarcoma, from which it must be diagnosed by means of the microscope.

The prognosis is entirely bad. Operation does not lengthen life nor, as a rule, alleviate suffering.

## TUMORS OF THE SINUSES.

**Benign neoplasms of the maxillary sinus** are: *Bony cysts*, which occur in connection with the roots of the teeth. *Edematous polypi*,<sup>2</sup> which occur occasionally as the result of purulent inflammation, but are also frequently found at autopsy, having given no sign during life.

**Cysts of the mucous membrane** are also seen very frequently post-mortem. Rarely they fill the whole antrum, as in a case reported by Dr. Chas. H. Knight.<sup>3</sup>

The suggestion was made many years ago and adopted by Virchow<sup>4</sup> that the cases of the so-called hydrops of the antrum of Highmore were probably of this nature. The cysts are, as in the nose, of glandular origin.

<sup>1</sup> Coley's method of treatment by erysipelatoous streptococcus-serum is credited with some success in otherwise hopeless selected cases, especially of spindle-celled sarcoma, wherever situated.

<sup>2</sup> Zuckerkandl, *Normale und Pathologische Anatomie*; Heyman, *Virchow's Archiv*, Bd. exliiii., Heft 1; Fränkel, *Archiv für Laryngologie*, Bd. iii., Heft 3; Dmochowski, *Ibid.*

<sup>3</sup> *Trans. Amer. Laryng. Assn.*, 1895.

<sup>4</sup> *Die Geschwülste*, Bd. i., p. 244.

**Osteoma**, apart from the very common exostoses, is occasionally noted post-mortem.

De Roaldes has reported a remarkable case of compound follicular odontoma of the antrum.<sup>1</sup>

**Malignant Neoplasms of the Antrum.**—Sarcoma has frequently been reported as primary in the antrum, and Schmidt makes the statement that carcinoma is not an infrequent occurrence. While I have seen several cases of sarcoma which presumably began in the antrum, I have never seen a carcinoma, and I am familiar with only one report in general literature.<sup>2</sup> This case is so well authenticated and the history so well reported by Dr. Reinhard,<sup>3</sup> that an abstract of some of the points may be useful to the rhinologist as illustrating the course of malignant disease in this locality. The patient was a man of sixty-five. For five years he had suffered from left-sided nasal obstruction, and for one year from unilateral nasal suppuration and radiating pain in the left side of the face, with loss of flesh and strength. The anterior molar tooth of the upper jaw having become carious, the patient had it removed, and this was followed by the discharge of foul-smelling pus through the alveolus into the mouth. The left side of the face became somewhat swollen, and the alveolar opening into the antrum became larger. On using a probe it was evident that it did not move freely in the antrum, but was engaged in some soft substance. Fluid syringed in the opening came out of the hiatus semilunaris much more quickly than in simple empyema of the antrum. There were no glandular enlargements and no eye-symptoms; the patient receiving no benefit from constant irrigation of the antrum, a snare was introduced through the alveolar opening and some of the tissue removed. A polyp was also removed from that side. Microscopical examination showed the antral growth to be carcinomatous, and that the nasal polyp was a hypertrophy of the nasal mucosa. On account of the severe pain, excision of the jaw and extirpation of the growth, which was more extensive than expected, was performed, with at least temporary relief from all symptoms. The patient was discharged five months later with no recurrence. A similar case has been reported by Dr. Wendell Phillips.<sup>4</sup> I have had the privilege of seeing the patient and examining the specimen.

This illustrates how a malignant growth may set up an empyema of the antrum, which may be taken for the sole and primary trouble. It also shows that the excision of the jaw may be indicated and successfully performed for temporary relief of the symptoms, which in this case and in all such cases are unendurable if the operation, however severe and dangerous, holds out any hope of relief. Death on the operating-table may perhaps be considered the most successful outcome for the patient.

**The neoplasms of the ethmoidal sinuses** may be considered as having been treated of under the head of nasal neoplasms. Nearly all the edematous polypi spring from the mucosa of this region, and they may infiltrate the ethmoidal cells to such an extent as to simulate malignant growths by causing external deformity. The malignant growths of the ethmoid are inoperable, and prove rapidly fatal by extension to the cerebral cavity.

**Neoplasms of the Frontal Sinuses.**—Osteomata sometimes occur

<sup>1</sup> *Trans. Amer. Laryng. Assn.*, 1894.

<sup>2</sup> Vernouil also reported a case of epithelioma of the left maxillary sinus in the *Bull. de la Société de Chirurgie de Paris*, 1886, p. 658.

<sup>3</sup> "Ein Fall Von Primärem Epithelial Carcinom der Oberkieferhöhle," *Archiv f. Laryngologie*, Bd. ii., p. 230.

<sup>4</sup> *Journ. of Laryngology*, July, 1898.

in the frontal sinuses, and usually give rise to no symptoms. Schmidt<sup>1</sup> says that occurring in the nose they usually start from the mucosa of the frontal sinus, and the same is true of many orbital exostoses. Cysts of the mucous membrane are rare, but even dermoid cysts have been noted in the frontal sinuses and in the anterior parts of the nose.

Edematous polypi and especially edematous swelling of the mucous membrane are found in connection with empyema of the sinus, and occasionally without pus-formation, as a complication of a similar condition in the nasal mucosa.

**Sphenoid Sinus.**—Similar pathological conditions as to neoplasms are reported by Zuckerkandl as having been found in the sphenoidal sinus, but the diseases of these cavities have not as yet been sufficiently studied to make a consideration of their neoplasms profitable here.

#### TUMORS OF THE NASO-PHARYNX.

**Naso-pharyngeal Fibroma.**—Naso-pharyngeal fibroma is a tumor which, in many respects, presents peculiar characteristics. It is histologically a benign growth, but owing to its situation gives rise to symptoms which, if unrelieved, are almost certain to result in death; and it demands operative treatment which the most skilled rhinologist and the most daring surgeon are sometimes unable to afford with success.

It occurs almost exclusively in males between ten and twenty-five years of age. So marked is this influence of age, that not a few cases are recorded of spontaneous recession of the growth after this period, affording in this respect a marked resemblance to another naso-pharyngeal growth—viz., lymphoid hypertrophy or adenoid vegetations.

It is fortunately tolerably rare, and it falls to the lot of very few rhinologists to have seen more than two or three instances. Situated at the base of the brain and at the junction of the air- and food-paths, almost at the center of the skull, endowed with the faculty of unlimited growth, pressing upon and absorbing even bony structure, its early recognition and its prompt and vigorous treatment are of vital importance to the patient and of great difficulty to the surgeon.

It springs from the dense fibrous tissue and periosteum which cover the under surface of the basilar process of the occipital bone and the body of the sphenoid. This fibrous tissue extends to some extent laterally down to the pterygoid plate of the sphenoid and perpendicular plate of the palate-bone, as well as on to the posterior ends of the upper turbinated bones and the vomer. From these situations, also, fibroma occasionally takes its origin. From whatever source it springs, it may contract adhesions with contiguous structures by inflammatory processes.

**Histology.**—Its structure is dense, being made up almost entirely of white fibrous tissue, between the fibers of which may be seen in places areas of round and spindle-cells, which remind one of sarcoma.

**Etiology.**—Its more or less sharp limitation to the age of adolescence and the male sex would seem to point to some connection with the cranial development, which is so marked during this period; but it is not an unknown affection in the female or before or after the period of ten to twenty-five, which includes the great majority of cases.<sup>2</sup>

<sup>1</sup> *Die Krankheiten der Oberen Luftwege*, 1894, p. 506.

<sup>2</sup> See the chapters devoted to it in the works of Morell Mackenzie, Bosworth, and Greville-Macdonald, and Lincoln's classical papers, *Trans. Amer. Laryng. Assn.*, 1879 and 1882; *N. Y. Med. Journ.*, May 26, 1894, p. 653.



**Symptoms.**—The initial symptoms are apt to be those of post-nasal catarrh, accompanied by repeated and at times grave epistaxis. The evidences of post-nasal obstruction soon supervene—the dead voice and thick speech and difficulty in respiration. Deafness, more or less marked, is present. A peculiar condition of somnolence has been noted in many cases, the patient being often overtaken by sudden and irresistible drowsiness. Possibly this may be akin in its etiology to the aprosexia from which some adenoid cases suffer. Later, pain and a muco-purulent discharge may be present. Pressure on the neighboring parts results in external deformity—the separation of the maxillary bones and the exophthalmos—producing the hideous aspect known as “frog-face.” Growth downward forms a hindrance to deglutition; while occasionally, though rarely, upward growth through the foramen lacerum medium or by absorption of the bone may cause cerebral symptoms and death. According to Greville Macdonald,<sup>1</sup> vomiting is sometimes a distressing symptom.

**Examination** with the post-nasal mirror shows a smooth rounded mass of a color varying from pink to dark purple. Varicose blood-vessels may be seen on the surface. It may project into the nasal fosse and be seen by anterior inspection. It may grow through the speno-maxillary fissure and be felt under the zygoma. When of moderate size its base of implantation may be seen; but usually it fills the post-nasal space, and so frequently has contracted adhesions to neighboring parts that its origin cannot be distinctly made out. It usually has a broad base, but it sometimes has a small one, being pedunculated and freely movable. This may be appreciated by a probe through the nasal fosse or by the finger behind the palate. To the finger it has a firm elastic feeling. Considerable care and gentleness must be exercised in these maneuvers, as alarming hemorrhage is apt to occur.

**Diagnosis.**—The chief difficulty in diagnosis is to distinguish it from sarcoma. The age and sex of the patient, the place of origin, and to some extent the firm consistence of the tumor, may serve to establish its nature; but frequently the microscope must serve as the final arbiter.

**Prognosis.**—Naso-pharyngeal fibroma is a grave disease at best, but it is rendered still more so when it has progressed so far as to render an external or preliminary operation necessary. Left to itself, it usually results in a suffering death; although some cases are related where spontaneous cure has taken place. When occurring near the end of the period of liability, they have been observed to retrocede and even to slough away. This, however, should never be expected or waited for if operative procedures hold out any hope of successful removal. The favorable cases are those which present themselves with a pedunculated growth, and in whom the whole nasopharynx is not filled with it; and if I may be allowed to make the remark, their chances are considerably better if at this stage they fall into the hands of a skilled rhinologist rather than into those of a general practitioner who does not at once recognize the character and gravity of the case, or of a general surgeon who is disposed to recommend at once an external operation.

**Treatment.**—Several methods of procedure may be adopted. When the whole or a part of the growth can be included in the loop, the irido-platinum wire of a galvano-cautery snare should be used. Sometimes the difficulties of the technic are so great that it may be necessary to abandon this and make the attempt with the steel wire of a cold snare, occupying several hours in completing the removal. Subsequent cauterization of the stump

<sup>1</sup> *Diseases of the Throat and Nose.*

of the growth is usually recommended, but its utility is open to some doubt. Unfortunately there are a number of cases where this operation with the snare is impossible. The shape and broad attachment of the tumor is such at times that a wire cannot be made to encircle the growth. Electrolysis should then be tried, more with the hope of diminishing the size of the mass or altering its shape to such an extent that the snare-operation is practicable. It is sometimes only possible to remove it piecemeal. Hemorrhage does not occur with the hot snare, and is not uncontrollable with the cold wire. Tamponing the post-nasal space may be necessary, and firm pressure may be made with curved instruments against the stump.

Recurrence is frequent, and a number of operations may be necessary. If the growth can be kept in check until the period of immunity is reached, the recurrence may be finally prevented, and even retrocession in the growth may be expected. The other methods of treatment are injection of various substances into the growth. Lactic acid has been recently used by Ingals<sup>1</sup> with great success. The galvano-cautery electrode may also be used to advantage at times, but usually as an adjuvant to more thorough methods of removal. Finally, as a last resort, the patient may be submitted to the risk of an external operation. An operation for a naso-pharyngeal growth which cannot be removed by intranasal maneuvers is necessarily one of the gravest and most dangerous which the general surgeon can undertake; and statistics of the results both in intranasal operations and in the preliminary external operations seem to warrant the preference of the best authorities for the former, while the latter procedure should be resorted to only when all other methods have been demonstrated to be absolutely of no avail.

**Fibro-mucous polypi** are described by various writers as partaking partly of the character of the pure fibroma and partly of that of the edematous polypus within the nose. These growths are evidently fibromata of sluggish growth which have become edematous. Such growths usually have their origin partly, at least, within the nose. They do not bleed, nor do they tend by their pressure to invade other regions and absorb adjacent structures. They are usually pedunculated, and their removal is not attended with any great difficulties. They seem to be regarded as of rare occurrence; but it is probable that their comparatively trivial character has led to less frequent reports than of the more formidable fibromata. They are said by Bosworth to occur more frequently in females.

The **symptoms** are those of post-nasal obstruction and irritation.

**Examination** shows that the growth is paler in color and has a softer consistency and a smaller pedicle than the true fibroma. It is more movable.

**Treatment** is correspondingly easier, it being usually possible to remove it with the cold snare introduced through the nose or to twist it from its attachment with forceps or fingers from the mouth. It shows little or no tendency to recurrence.

**Enchondroma.**—Bosworth reports from literature only 2 cases of enchondroma of the naso-pharynx. Nasal obstruction, with headaches and some external deformity from pressure, were noted.

**Hairy Pharyngeal Polypi.**—Reports of ten of these curious growths have been collected by Conitzer,<sup>2</sup> who contributed to the number a case of his own. They contained not only hairs and their follicles, but also the other normal constituent parts of the skin. Most of them also contained cartilage. They were pedunculated tumors, attached usually to the posterior surface of the soft palate and more frequently to the left of the median line, but some

<sup>1</sup> *N. Y. Med. Journ.*, Sept. 19, 1896.

<sup>2</sup> *Deut. med. Woch.*, No. 51, 1892.

in the vault and posterior wall of the pharynx. They were presumably all congenital. A similar growth was reported by Wagner,<sup>1</sup> in 1884, who called it a *dermoid cyst*. It is not included in Conitzer's table.

Under the head of *Teratomata*, a number of similar cases are referred to by Lemox Browne, in Burnett's *System of Diseases of the Ear, Nose, and Throat*, vol. ii. p. 726; and he speaks of them as occurring also in the middle and lower pharynx.

**Sarcoma of the Naso-pharynx.**—Sarcoma is an occasional occurrence in the naso-pharynx. Bosworth,<sup>2</sup> in 1892, had collected from literature 18 cases, and added the complete history of a remarkable case of his own. Fourteen of these cases were in males and 5 in females. Their ages ran as follows:

|                    |   |                    |   |
|--------------------|---|--------------------|---|
| 1 to 10 . . . . .  | 2 | 30 to 40 . . . . . | 2 |
| 10 to 20 . . . . . | 5 | 40 to 50 . . . . . | 7 |
| 20 to 30 . . . . . | 3 |                    |   |

We see here, as in sarcoma of the nose, that from forty to fifty is the decade of life furnishing the largest number of cases.

It is hardly necessary to repeat here the history of the symptoms of naso-pharyngeal fibroma, which those of sarcoma so closely resemble; but it is more profitable to point out some differential points. In the first place, we do not expect fibroma after twenty-five years of age, but younger than this the growth in question may be either sarcoma or fibroma. The symptoms have usually run a more rapid course in sarcoma, and on examination it will be seen there has been a correspondingly rapid growth in the tumor. Epistaxis, while as frequent, is not apt to be as copious as in fibroma. Ulceration of the surface appears earlier. In Bosworth's case and in one other there was a general diffusion of the growth over the pharynx. Under the microscope the appearances are usually characteristic enough; but even here the diagnosis of sarcoma, especially when of the round-celled variety, is in some cases extremely difficult. Many cases of undoubted fibroma present in places histological appearances almost identical with round-celled sarcoma.

The **prognosis** is almost uniformly bad, although Bosworth's case recovered after piecemeal removal with the snare, and Warren's cases were all well or nearly so after external operation. This is so unusual as to raise some doubt as to the diagnosis, although well certified to in Bosworth's case.

**Treatment.**—Fortunately the treatment does not hinge on a differential diagnosis between fibroma and sarcoma. Prompt and thorough removal by intranasal procedure, if possible, is indicated in both cases. In Bosworth's case this was done piecemeal with the cold snare, and although the mucous membrane was extensively infiltrated, complete success was attained and the growth had not recurred after seven years. While encapsulated or circumscribed sarcomata may be thoroughly removed by means of the snare, it is difficult to conceive how a new growth, with malignant potentialities widely infiltrating the tissues, can be so thoroughly removed by means of a snare,

<sup>1</sup> *Diseases of the Throat and Nose*.

<sup>2</sup> Since then cases have been reported by Thomas, Bennett, Delie, Lange, McIntyre, Cohen, Práge, Robertson, Iwanicki, Logan and Scheineman, and a case is reported by the U. S. Surgeon-General's Office, references to all of which will be found in the *Centralblatt für Laryngologie*, from 1887 to 1895 inclusive. In addition to these, cases have been reported by Zematski (*Sajon's Annual*, 1895, vol. iv., D 49), Delavan (*Journal of Laryngology*, 1894, p. 360), and Warren (3 cases, "Surgical Pathology"). I know of 2 other cases, which have not as yet been reported.

which necessarily only removes surface-protuberances, as to destroy its power of growth; yet the microscopical diagnosis in the case is indisputable, so far as the skill of the examiners is concerned.

The treatment by external excision is so frequently fatal and ineffectual that the question of its advisability is in many cases doubtful.

**Carcinoma.**—Carcinoma of the naso-pharynx is of much rarer occurrence. Bosworth having had one case himself, has collected from literature the records<sup>1</sup> of 5 others. In only one of the latter, however, does there seem to have been a microscopical examination. I have a microscopical section of another case which was reported by the late Dr. Sidney Allan Fox<sup>2</sup> of Brooklyn. An abstract of the history of this case may be of value here.

The patient was a man forty years old. Family history was good and the patient had always enjoyed good health. A year previous to his coming under observation he was much exposed to wet and cold weather. This was followed by sharp pain in the ear, partial deafness, and a feeling as if his own voice was very loud. His general strength began to fail somewhat, and his nervous system to deteriorate. Six months later he began to be troubled very much with headache, especially in the daytime. He was also troubled with the earache above mentioned, with deafness and with obstruction of the posterior nares. When he came under observation his appetite was poor; he was unable to sleep at night because of an inability to breathe through the nose and the constant annoyance of mucus dropping in the throat. His hearing was defective and he was diploic. The odor from the naso-pharynx was fetid in character. Anterior rhinoscopy showed nothing, but posteriorly the naso-pharynx was seen to be filled by a cauliflower-like growth. The lateral walls of the pharynx, as well as its posterior wall, were matted with the growth, as were also the choanae and the spaces about the Eustachian orifices. *There was no evidence of external or internal glandular involvement.* Microscopical examination showed it to be an epithelioma.

A preliminary operation (Annamdale) was done by Dr. Fowler, and as much as possible of the growth removed. It rapidly grew again, and the patient died two months later. Autopsy showed that the growth had perforated the base of the skull, involved the brain, and had extended into the left orbit, possibly also the right.

As was said in speaking of the treatment of nasal sarcoma, the best hope that can be held out to the patient in advising such a surgical operation is that he may not survive it. Life can doubtless be prolonged more by cleansing and cautious removal of obstructing protrusions of the growth with the cold snare than by any radical operations.

#### BENIGN NEOPLASMS OF THE FAUCES, TONSILS, AND ORO-PHARYNX.

By the oro-pharynx we mean that portion of the anatomical pharynx which, we may say roughly, can be seen by direct vision in its whole extent—*i. e.*, from the level of the hard palate to the level of the arytenoid summits. Below this point the region belongs to the digestive, and not to the respiratory, system.

**Papilloma** of the soft palate, and especially of the uvula, is the most common of all true tumors of the nose and throat. They vary from the size

<sup>1</sup> Ferri, *Archivi di Otologia*, 1893, p. 40, has reported a case, and McBride another, *Diseases of the Throat, Nose, and Ear*, p. 322.

<sup>2</sup> *N. Y. Medical Journ.*, March 8, 1890. The editor has specimens, from a case of Politzer, involving the Eustachian tube.



of a pin's head to that of a cherry, though the majority of them are not larger than a pea. They are more frequently found on the anterior than on the posterior surface. They are attached frequently to the free edge of the soft palate and faucial pillars. They are of the same structure as true papilloma, or fibroma papillare, elsewhere. The normal epithelium lining the oropharynx, made up of pavement-cells, is exposed to attrition by the passage of food and the rubbing of opposing mucous surfaces. Probably it is to this, rather than to the change in the type of epithelium which takes place behind and above the soft palate, that we are to ascribe the frequency of these growths. Jurazs<sup>1</sup> speaks of having seen 14 cases in his clinics, of which 10 were between twenty and thirty, and all between nineteen and forty-four years of age. Eleven of them were men.

**Symptoms.**—They usually give rise to no symptoms, but are frequently seen in examining the pharynx, either as sessile warts on the mucous membrane or as pedunculated growths hanging from the tip of the uvula or the edge of the palate. Sometimes they cause tickling and coughing; but this seems to depend quite as much on the idiosyncrasy of the patient and the hyperesthesia of the mucous membrane as upon the size and shape of the growth.

The **diagnosis** is easily made from the gross appearances, and because it is by far the most common of all growths in this locality; but occasionally the best of observers is deceived. A notable instance of this was in a case reported by Dr. Leferts,<sup>2</sup> in 1889, as a typical papilloma in a girl of sixteen. He made no microscopical examination.<sup>3</sup> The growth recurred after removal, and was again removed by Dr. Simpson<sup>4</sup> and reported by him, after microscopical examination, as an instance in which a benign neoplasm had degenerated into a sarcoma. It seems very evident that the growth was malignant from the first. Lennox Browne relates<sup>5</sup> a similar mistake as occurring in the practice of Morell Mackenzie; so that, however great the probability, the microscope must complete the evidence.

**Prognosis.**—They are benign growths and, as a rule, of no significance.

**Treatment.**—When large enough to cause symptoms or give the patient any alarm, they may be cut off with a pair of uvula-scissors.

**Fibroma.**—Bosworth refers to 7 cases in the tonsils and 7 in the oropharynx. Leferts<sup>6</sup> has reported a case. They are benign growths and easily removed.

**Angioma.**—Phillips has reported a case,<sup>7</sup> Bosworth refers to 2 others, and Flatau to another.<sup>8</sup>

**Lipomata** have been reported by Farlow<sup>9</sup> and Schmidt.

**Adenoma.**—Nasier reports a case.<sup>10</sup> He refers to 2 cases by Hutchinson.<sup>11</sup>

**Cysts of the Mucous Membrane.**—I have observed one case in a middle-aged woman who complained that something had been growing in her throat for the last eighteen months. A small round tumor, a little larger than a pea, was seen growing at the base of the right posterior faucial pillar. It was smooth and sessile. It gave no evidence of its presence until the

<sup>1</sup> *Die Krankheiten der Oberen Luftwege*, 1891.

<sup>2</sup> *Trans. Amer. Laryng. Assn.*, 1889.

<sup>3</sup> This case is quoted by Bosworth, and accepted as a papilloma, in his book published just after Dr. Leferts's report and before Dr. Simpson's.

<sup>4</sup> *Trans. Amer. Laryng. Assn.*, 1893.

<sup>5</sup> Burnett's *System of the Diseases of the Ear, Nose, and Throat*, vol. ii, p. 724.

<sup>6</sup> *Loc. cit.*

<sup>7</sup> *N. Y. Medical Record*, March 12, 1887, p. 293.

<sup>8</sup> *Nasen, Rachen und Kehlkopf Krankheiten*, p. 331.

<sup>9</sup> *Trans. Amer. Laryng. Assn.*, 1895.

<sup>10</sup> *Rev. Mensuelle de Laryngologie*, No. 11, 1887, p. 618.

<sup>11</sup> *Lancet*, May 22, 1886, p. 973.

patient, who had a family history of cancer, noticed it. Fig. 632 shows a section of the walls, which are fibrous and lined on both sides with squamous epithelium similar to that of the surrounding mucous membrane. There were no glands and no lymphoid tissue. Its fluid contents escaped in the

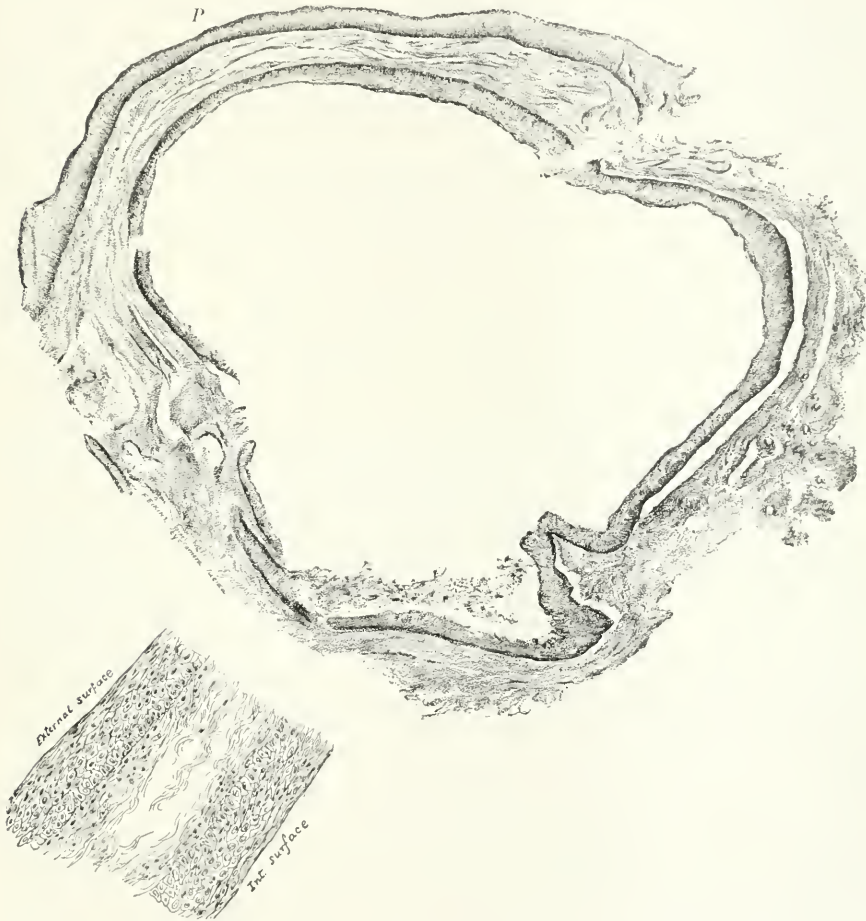


FIG. 632.—Oro-pharyngeal cyst: P, point from which high-power drawing is taken.

removal. It was probably an inclusion-cyst, having its origin in some acute inflammatory condition of the mucosa.

It will be noted in Schmidt's table that he mentions one cyst of the oro-pharynx, but gives no further details.

There is a growth connected with the tonsils which is occasionally seen in the throat—usually but wrongly called a *supernumerary tonsil*. Its formation seems to be brought about by a fibrous growth shutting off a portion of the lymphoid tissue of a hypertrophied tonsil. The fibrous tissue is gradually lengthened into a pedicle. Such a growth I have examined microscopically for Dr. W. F. Dudley of Brooklyn. These growths, as well, indeed, as many others of the oro-pharynx, may by the length of their pedicle cause alarming dyspnea or interfere markedly with deglutition.

## MALIGNANT TUMORS OF THE FAUCES.

There seems to be a certain practical line of division between malignant disease of the contiguous structures of the soft palate, tonsils, and oro-pharynx, due, doubtless, to difference in anatomical structure, physiological function and pathogenic influences. This makes it seem desirable to consider them separately.

On looking over Schmidt's tables we see that more *carcinomata* were observed in the oro-pharynx and larynx than all other growths combined, if we rule out papillomata and the inflammatory growths, the so-called laryngeal fibromata and tubercular tumors. It will also be seen that it is very much more frequent in men than in women—at a ratio of 15 to 1 for the pharynx. This same influence of sex is discernible in the reports of 30 cases of carcinoma of the fauces collected by Bosworth. Only one was in a woman. Bosworth comments on this as a curious coincidence. The chances are very great, however, that there is hidden behind the fact an etiological significance of which we can at present form no surmise. The cases that I have observed and know of personally have all been in men. We can hardly suppose that the greater exposure of men in their occupation to irritative causes would entirely account for this.

**Sarcoma of the Soft Palate.**—A few cases have been reported, Bosworth, in 1892, collecting 20. It is much more frequent in males (13 to 4), and occurs as often in patients over forty years of age as in younger ones.

All forms have been noted, with no especial preponderance of any one.

**Symptoms.**—It is usually of slow growth and does not tend to ulcerate quickly. It frequently gives rise to no symptoms until it has existed some time. Interference with deglutition and the thick sound of the voice may be the first symptoms complained of. Pain, however, may be prominent from the first, and this is especially so if ulceration has occurred, in which case excessive salivation and foulness of the breath add to the discomfort of the patient. The general health deteriorates. As a rule, glandular involvement in the neck does not occur until the growth has invaded other structures. Hemorrhage is not reported as an incident in the course of the disease.

The tumor is usually circumscribed—a round, smooth growth covered by mucous membrane and enclosed in a capsule, or it may be more diffuse and nodulated. It may spring from any part of the soft palate and spread over its whole extent, but does not show a marked tendency at first to invade contiguous structures.

The duration of the disease varies from six months to several years. Sometimes it has apparently existed for years in a quiescent condition.

**Diagnosis.**—The same caution should be observed in excluding a syphilitic growth by the administration of large doses of the iodid of potash. This should be especially borne in mind when the microscope reveals rounded structure.

It is easily distinguished from tuberculosis, which almost never occurs without manifestations elsewhere. From fibroma it cannot be surely distinguished without a histological examination. The rarity of fibroma in this situation, and the slowness of its growth, its firmness of consistence, and the lack of pain in the history will tend to exclude it.

The prognosis is always grave; but not a few cases have been reported in which many years had elapsed without any recurrence after thorough operation. Much will depend on the rapidity of growth and involvement

of neighboring structures. Those cases are particularly favorable which are seen early.

**Treatment.**—Incision of the mucous membrane may enable the operator to shell out an encapsulated growth; but usually the field of operation should include healthy tissue, and suspicious areas should be thoroughly burned out with the thermo-cautery. No radical operation should be undertaken unless with hope of the complete extirpation of the growth. Without such hope, removals of projecting and obstructing portions with the snare (from time to time) may be advisable. The use of a cleansing mouth-wash, such as the ordinary Dobell solution or the peroxid of hydrogen, will tend to relieve the fœtor. Weak solutions of cocain or a 10 per cent. spray of antipyrin help to assuage the pain when violent. The liberal use of opiates is indicated in these hopeless cases.

**Carcinoma of the soft palate**, although somewhat more frequent than sarcoma, is still a very rare growth. Bosworth has collected the reports of 30 cases up to 1889. In looking over Semon's *Centralblatt für Laryngologie* for the years since then, I can find a reference to only one case.<sup>1</sup> We see at once what a marked contrast this forms to the frequency of epithelioma of the tongue; while the benign epithelial growth—papilloma—is so frequently seen on the soft palate and so rarely on the tongue.

Among Bosworth's cases is one of twenty-five and another of twenty-seven years of age; but forty to fifty shows a slightly larger number (5) than any other decade.

Of the 31 cases, including Katzenstein's, all but one were in men, affording a more striking example even than sarcoma of the greater frequency of malignant growths of the throat in men. Owing to insufficient microscopical reports, it is impossible to ascertain what form of carcinoma is most frequent.

It occurs as a rapidly growing infiltrating neoplasm with a fungous or irregular surface. Ulceration occurs early in its course.

**Symptoms.**—Pain radiating in various directions is usually the prominent symptom, but is not always present at first. Stiffness of the palate is complained of in some cases. Notwithstanding these symptoms, the growth has usually advanced so rapidly that, when it comes under observation, considerable infiltration of the soft palate and ulceration have already taken place. The ulceration is characteristic as of cancer elsewhere. The underlying infiltration raises the floor of the ulcer, while the surrounding fibroid border is not sharp-cut, but rounded. The floor of the ulceration may be covered with whitish secretion or may be fairly clean and pink-looking; but it is always irregular and nodular. Hemorrhage frequently occurs and the general health rapidly deteriorates. Foul-smelling secretions from the ulcer and lancinating pains destroy the appetite and render the patient's life miserable. Glandular enlargement is sometimes absent even in late stages of the disease, and is usually not present until the disease has spread to contiguous structures. This, however, it rapidly does, involving the base of the tongue, the lateral pharyngeal wall, and the hard palate; but, as Bosworth remarks, they usually die even before this takes place.

The prognosis is entirely hopeless.

The diagnosis from sarcoma has been sufficiently indicated by the previous remarks. The microscope must, of course, be the final arbiter between the two. As between cancer and syphilis, the microscope is a perfectly satisfactory means of diagnosis and should always be promptly employed. Carcinoma rarely resembles papilloma in this situation. The infiltration is marked.

<sup>1</sup> Katzenstein, *Berl. klin. Woch.*, No. 9, 1892.



Treatment.—Occasionally a radical operation may be advisable; but usually this holds out to the patient no hope even of diminishing suffering. Cleansing and disinfecting washes and opium include the palliative indications.

**Sarcoma of the Tonsils.**—Gray,<sup>1</sup> in reporting a case, gives a list of 18 other reports of sarcoma found in literature. I have been able to find trustworthy accounts of 13 other cases<sup>2</sup> since then. Others have been reported; but either the reports are not accessible to me or satisfactory data are not given. Indeed, Bosworth in his book has collected 45 cases, and others have been reported since then. Of the 32 cases which I have studied, the following facts are apparent. As lympho-sarcoma and round-celled sarcoma are synonyms in the reports, we find that all the cases but 5 come under that one head, showing pretty conclusively that the growths, as a rule, spring from the lymphoid, and not from the fibrous, elements of the tonsil, even at an age when the lymphoid activity has sunk into insignificance.

|                 |            |     |         |
|-----------------|------------|-----|---------|
| From 50 to 60   | there were | 9   | cases.  |
| “ 60 to 70      | “ “        | 8   | “       |
| Over 70         | “ “        | 4   | “       |
| From 10 to 20   | “ “        | 3   | “       |
| “ 30 to 40      | “ “        | 2   | “       |
| “ 20 to 30      | “          | was | 1 case. |
| “ 40 to 50      | “ “        | 1   | “       |
| Younger than 10 | “ “        | 1   | “       |

From this analysis we see that more than half the cases occurred in persons over fifty years of age. With the exception of one case of six years, the 3 youngest cases were seventeen years old. Therefore we see that this lymphoid growth almost always occurs in the pharynx at an age when benign lymphoid hypertrophies (enlarged tonsils) are unknown to begin. Sex seems to have no influence (13 to 17); and there seems to be no marked preponderance on either side of the throat.

**Symptoms.**—The onset of the symptoms frequently resembles an attack of tonsillitis. Instead of entirely subsiding, some swelling and tenderness are left behind. This may remain stationary for a few weeks; but gradually the size of the tonsil increases, the surrounding tissue of the pillars of the fauces and the soft palate and uvula become reddened and edematous. The pain increases, as a rule, although in some cases it is never a prominent symptom. Ulceration occurs much earlier than is usual in sarcoma. Glandular involvement is also more frequent and comes on earlier. Hemorrhage is an occasional symptom. The general health becomes seriously affected after a few months; the sense of taste and smell are soon lost; foul discharge and odor are present. The growth may extend backward and downward, interfering with deglutition and respiration.

**Prognosis.**—The disease usually goes to a fatal termination within a year, and sometimes in a few months. Round-celled sarcoma in any situation has a most unfavorable prognosis, but in the tonsil it is especially rapid and fatal. One of Newman's cases lived five years after the operation and died of a

<sup>1</sup> *Amer. Journ. of Medical Science*, February, 1889, p. 154.

<sup>2</sup> MacCoy, *Phila. Med. News*, Feb. 2, 1889; Mygind, *Journ. of Laryng.*, Aug. 1890, p. 301; Cheever, *N. Y. Med. Record*, May 25, 1889; Wolfenden, *Journ. of Laryng.*, Oct., 1889; Schönborn, *Centralblatt für Laryng.*, vol. v.; Lediard, *Journ. of Laryng.*, 1890, p. 17; Homans, *Journ. of Laryng.*, 1891, p. 428; Cohen, *Phila. Med. News*, Jan. 27, 1894; Wagner, *N. Y. Med. Record*, Feb. 3, 1894; Watson, *N. Y. Med. Journ.*, Nov. 10, 1894, p. 584; Newman, *Malignant Growths of the Throat and Nose* (2); Mikulicz, *Atlas der Krankheiten der Mund und Rachenhöhle*.

recurrence in the other tonsil: this was a spindle-celled sarcoma. Weinlechner's case (quoted by Bosworth), another spindle-celled sarcoma, was injected with iodoform and ether and the common carotid artery was tied after the case had been pronounced hopeless by Billroth: the case entirely recovered. Another case, which was called a lympho-adenoma, lived two and a half years after operation, and still another lived seven years. In reading the literature it seems that the chance of a favorable prognosis is proportionate to the chance of mistake in diagnosis; and the suspicion arises that the microscope or our understanding of the pathology of sarcoma is at fault.

**Diagnosis.**—What has been said of tertiary syphilis, in connection with the diagnosis of sarcoma elsewhere, applies with equal force to tonsillar growths. The growths are so rare that differential diagnosis between sarcoma and carcinoma can only be settled by the microscope, because no one's experience is wide enough to trust to the "clinical sense" which is of value in so many cases. Iodid of potash and the microscope should be our chief aids.

**Treatment.**—Owing to the hope, though a forlorn one, which has been realized in a few cases, thorough extirpation should be undertaken where it is a possibility. The necessity of an external incision for the removal of diseased glands, as well as for the complete removal of the growth, is frequently evident. Otherwise, palliative measures are to be adopted as mentioned above.

**Carcinoma of the tonsils** is of more frequent occurrence than sarcoma. About 100 cases may be found in literature.<sup>1</sup>

It has been reported in a case as young as seventeen (Bryant) and as old as eighty-two. Sarcoma, however, has not only been reported at a younger age (six), but also in a woman of eighty-nine. The average age of carcinoma, according to Bosworth, is fifty-two and one-half years. It occurs much more frequently in males.

Calculating from the figures given by Bosworth, it occurs in the tonsils about once in 2000 cases of carcinoma of all parts.

**Symptoms.**—A careful study fails to note any essential difference between the subjective symptoms of sarcoma and those of carcinoma of the tonsils. The duration also seems to be about the same—from a few months to a year and a half.

**Diagnosis.**—The appearance of the growth seems to vary a little from that of sarcoma. There is more apt to be ulceration with carcinoma. A fleshy pinkish mass, fungoid and rough, projects into the pharynx, sprouting from the swollen tonsils and the infiltrated mucous membrane around it. A sarcoma, on the other hand, usually shows a smooth projecting surface, and is less completely covered with ulceration or fungoid excrescences. However, as said before, the microscope must be the final arbiter, for nothing is so deceiving as the external configuration of tumors.

The prognosis is, of course, as bad as possible, although in one of Newman's cases operated upon by him, there was no recurrence at the end of two years, and in another case no recurrence at the end of five months.

**Treatment.**—It is hardly necessary to speak of treatment. The only treatment for cancer is the knife and at once, if there is any possibility of complete eradication of all the tissue. Palliative treatment has been mentioned above for sarcoma.

<sup>1</sup> Bosworth refers to about 85 cases. Newman has reported 8 other cases since Bosworth, and several others are referred to in literature since the publication of Newman's work.

**Sarcoma of the Oro-pharynx.**—Few authenticated cases have been reported. Dr. F. I. Knight<sup>1</sup> reported a case in 1879, and reviewed the reports which had been made, of pharyngeal growths, up to that time; but many of them were apparently not really sarcoma. Bosworth, in 1892, mentioned 14 or 15 cases. By referring to Semon's *Centralblatt für Laryngologie*, I find the following cases reported since 1886:

- Felix: *Monatsch. f. Ohren.*, 1894, p. 255.  
 2 cases, spindle-celled; pedunculated; removal successful.  
 Montaz: *Médecine Mod.*, Sept., 1894.  
 "Lymphadenoma;" eleven years old; death from suffocation.  
 Delmas and Carnieu: *Journ. de Méd. de Bordeaux*, No. 14, April 7, 1895.  
 Hoppe: *Die Maligne Geschwülste der Pharynx. Dissert.*, Berlin, 1892.  
 Katzenstein: *Berl. Laryng. Soc.*, May 20, 1892; in *Centralblatt für Laryngologie*, No. 9, 1892. Short notice, 2 cases in report.  
 Cheatham: *Amer. Practitioner and News*, Dec. 7, 1889.  
 Norton: *Med. Press and Circular*, May 22, 1889.  
 Felici: *Il Morgagni*, March, 1888 (mentioned by Bosworth).  
 Black: *Glasgow Med. Journ.*, Feb., 1886.

This makes a record of 25 or 30 cases altogether, and the list is tolerably complete.

We have seen how malignant a growth is sarcoma of the tonsils. When it occurs in the oro-pharynx this is far from being the case. In this locality the growth is very frequently pedunculated or has a small base of attachment. It grows more or less slowly and does not have a tendency to glandular involvement. It is more frequently of the spindle-celled variety, which is usually less virulent. They are reported as springing from the posterior pharyngeal wall or low down on the sides of the pharynx.

Their usual occurrence is after middle life, although we again see here an instance in a child of eleven years. It is here also more frequent in men.

**Symptoms.**—It usually gives rise to no symptoms until deglutition or respiration is interfered with, which occurs at an early date, however, owing to its situation and the common presence of a pedicle. It may cause cough by encroaching in its growth upon the arytenoid summits or folds. Dyspnea from this cause has been reported as severe and dangerous; and, in the case of the child reported by Montaz, death occurred from the impaction of a portion of the growth in the larynx. As to duration, it seems from the histories that the disease may extend over several years, although it is sometimes rapidly fatal.

**Prognosis.**—Of course, the usual termination is in death; but if the tumor is such in shape and situation as to allow of complete removal, there is a fair chance of no recurrence; and if it recurs, a second operation may be more successful.

**Treatment.**—When pedunculated and not too large, the growth may be removed with the galvano-cautery snare. When, however, it has a broad base of attachment, or when it is so large as to make such a manipulation of doubtful success, a lateral, or better a subhyoid, pharyngotomy may be done. One or two cases were operated on through the mouth after preliminary tracheotomy.

**Carcinoma of the Oro-pharynx.**—Below the tips of the arytenoid cartilages—*i. e.*, in the laryngo-pharynx—carcinoma, often of scirrhus nature, is a very frequent occurrence. Above this point, however, it is one of the rarest of growths (Fig. 633).

Bosworth refers to about 30 cases, although some of these had their origin

<sup>1</sup> *Trans. Amer. Laryng. Assn.*, 1879.

evidently in the laryngeal part of the pharynx. I have been able to find very few reports since then.

The variety is usually epitheliomatous or scirrhus. One case was reported as young as twenty; but pharyngeal carcinoma is no exception to the rule which obtains elsewhere as to age. The larger number of cases seem to have been in females, a contrast to what we have hitherto noted in neoplasms of the upper air-passages.

**Symptoms.**—Gradually increasing discomfort and pain in swallowing first attract the patient's attention. Extension of the growth to the larynx and esophagus causes dyspnea and increases the difficulty of deglutition. Involvement of the cervical glands occurs early, and deterioration of the general health rapidly ensues. There may or may not be any bleeding. The duration of the disease is from six to eighteen months.

**Prognosis** is of course bad, but some prolongation of life by early surgical interference may be expected in favorable cases.

**Treatment**, if radical, of course belongs to the general surgeon. Tracheotomy, feeding *per rectum*, and opium are the palliative measures that are indicated in some of the cases.

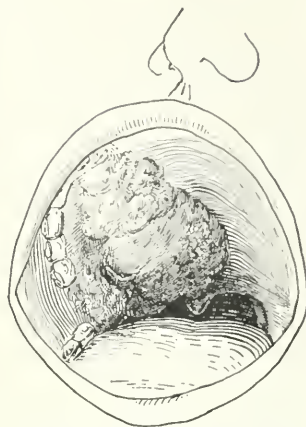

FIG. 633.—The author's case of epithelioma of the oro-pharynx in a man of sixty, springing from base of post-facial pillar. Began about five months before drawing was made.

### BENIGN NEOPLASMS OF THE LARYNX.

It is said by Moure,<sup>1</sup> quoting from Schwartz's tables of Fauvel's cases, that these growths occur in about 1 per cent. of the cases of laryngeal disease. Of late years chronic laryngeal disease, except the specific lesions of tuberculosis, syphilis, and cancer, seems almost to have disappeared from our nose- and throat-clinics in America. There is hardly any way of explaining this except by suggesting that the prompt and thorough treatment of nasal diseases, which all patients receive in this country, has produced this marked diminution of laryngeal disease.

It is my impression, however, that the proportion of benign growths to other affections of the larynx is rather more than 1 per cent. in New York City. Nevertheless, such are exceedingly rare, and very few of us see more than a very few cases each year in the public clinics. One has only to look at the works of Türk, Störk, Fauvel, and Mackenzie to realize that the early laryngologists saw a much larger number than occurs in the practice of any laryngologist to-day.

This may be graphically seen on referring to Semon's statistical tables<sup>2</sup> of his investigations, where Fauvel and Störk each say they had seen 600 cases of benign laryngeal growths, and others with "prerhinological" experience note very large numbers.

They are more common in men than in women. According to Mackenzie, out of 287 cases of benign laryngeal growths in his own practice and in that of others, 197 were males and 90 were females. They are most common in middle life, although some forms—as papilloma—are more frequent in chil-

<sup>1</sup> *Leçons sur les Maladies du Larynx*, p. 394.

<sup>2</sup> *Centralblatt für Laryngologie*, March, 1889.



dren. They are more common in those who make professional use of their voices. In children an attack of the measles has been frequently noted as the time at which the symptoms of papilloma began. Syphilis and tuberculosis produce their own neoplastic phenomena in the larynx, but have no appreciable influence in producing independent tumors.

Looking at Schmidt's tables, we again note the great preponderance of certain laryngeal growths. Fibroma, papilloma, singers' nodes, and tubercular tumors so far outnumber the other benign growths—lipoma, myxoma, and cysts—that the contrast is striking; while adenoma, chondroma, angioma, neuroma, with others which Gerhardt mentions,<sup>1</sup> have not been seen in his experience. This clinical fact alone, which is the common experience of all laryngologists, is strongly suggestive of the conclusion that, if they are not all of them results of chronic inflammation, the latter is a prominent factor in their etiology.

“**Singers' nodes**” are acknowledged by all to be the direct products of chronic inflammation. The name refers to their external appearance and the etiological factor in their occurrence. Their histological structure, while always giving evidence of inflammation, is not always the same. Occasionally the principal hyperplasia is in the epithelium, whose flat layers are thickened and supported by subjacent structure. More frequently there is marked increase in the lymphoid elements, raising up the epithelium into surface-protuberances; while in other cases the stroma is increased in volume, and frequently its fibers are separated by effused serum. Usually, however, there is a combination of these pathological changes with an increase of the vascularity of the parts. They are seen only upon the true cords, nearly always in their anterior thirds, either upon their superior surfaces or at their edges. They are sometimes bilateral at the edges, but of unequal size, having the appearance that one had been formed first and then affected by attrition the edge of the opposite cord. Occasionally it will be observed that the protuberance on one cord has made a little concavity at the edge of the opposite cord (see page 1105).

**Etiology.**—They occur chiefly among professional people who overuse their voices. This especially is the case in amateur singers. It is occasionally observed in news-boys and in choir-boys.<sup>2</sup>

**Symptoms.**—A young woman who has been singing a few months, or a vocalist from the music-halls who has been overstraining her voice, comes with the complaint of inability to produce certain notes or that a very little practice tires her larynx. Later in the course of the trouble there is complaint of occasional hoarseness and fatigue of the voice in ordinary conversation. The patient may be otherwise in perfect health.

**Examination** reveals one or both cords congested and rough at the edge or throughout the whole extent. It may be swollen and ecchymosed, and looks as if it had been bruised between two hard surfaces. A sessile growth from the size of a pin's head to that of a split pea may be seen on the anterior part of one or both cords, or there may be a number of these little protuberances scattered over their surfaces.

**Prognosis**, of course, relates entirely to the restoration of the voice, and this depends largely on whether the voice has broken down under use or abuse. It is doubtless true that in many of these cases the trouble at the bottom is really a natural structural weakness of the vocal organs. In

<sup>1</sup> “Kehlkopfgeschwülste,” Nothnagel's *Specielle Path. und Therapie*.

<sup>2</sup> Moure, “Laryngite Nodulaire des Enfants,” *Revue Hebdomadaire de Laryngologie*, Nos. 6, 7, 8, 1893.

others overuse of the voice has produced the trouble. The former cannot be corrected, and these patients cannot sing except in extreme moderation; but the ordinary voice may be entirely restored. Others, by proper care and treatment, may regain the singing-voice.

**Treatment.**—First, rest as absolute as possible must be insisted on for the larynx. The patient should not be allowed to talk more than necessity requires. The air-passages in the pharynx and nose must of course be put in order. Applications of nitrate of silver or sulphate of zinc (10 gr.— $\bar{z}$ j) should be made daily or three times a week. Usually after several weeks this will result in the subsidence of the neoplasm. If it is of large size and should persist, attempts at removal may be made. It is occasionally of such a size and shape that it may be seized with forceps or shaved off with the laryngeal guillotine or snare. The laryngeal bistoury, either protected or unprotected, cannot be too strongly condemned. The most disastrous wounds have been inflicted by it even in skilled hands.<sup>1</sup> The galvano-cautery electrode is usually to be preferred for operative procedures on these growths.

**Laryngeal Polypi.**—By this term we understand benign growths of the larynx, whatever their histological structure, which have more or less circumscribed bases of attachment. Their symptomatology and treatment are so nearly identical that these will be spoken of as a whole, following a brief account of the pathogenesis, histology, gross appearances, and occurrence of each.

**Edematous Polypi of the Larynx—the so-called Fibromata.**—As in the nose, where edematous hypertrophies of the mucous membrane are

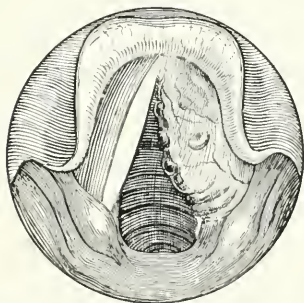


FIG. 634.—Angiodiapedema of larynx (from Krieg's Atlas).



FIG. 635.—Edematous fibroma of vocal cord.

often called myxomata, so in the larynx we find practically the same structure in growths, which until very recently have been almost universally called fibromata or fibro-myxomata.

In the nose these serum-soaked neoplasms are covered by a translucent columnar epithelium, and are scantily supplied with blood-vessels. In the larynx, on the other hand, they are covered by an opaque stratified pavement-epithelium. They are more exposed to bruising by the muscular movements of the vocal cords and the forcible air-currents in coughing and loud speaking, which produce extravasations of blood into the meshes of the separated stroma-fibers. These two circumstances give them either a solid white look or a dark-red appearance.

My own histological examinations as well as clinical experience lead me to believe that Chiari<sup>2</sup> is correct in stating that they are local hypertrophies

<sup>1</sup> See Schrötter's *Vorlesungen über die Krankheiten der Kehlkopfes*, 1892, p. 295.

<sup>2</sup> *Archiv für Laryngologie*, Bd. ii., Heft i.

of the vocal cords. Their structure closely resembles that of edematous nasal polypi. As has been stated, the surface-epithelium and the extravasated blood constitute the chief differences. There are also more blood-vessels, which are usually much dilated, making vascular channels across the loose stroma. Hyaline bodies are also frequently met with, and supposed to be due to the degeneration of the stroma-fibers (Fig. 635).

**Etiology.**—In studying their structure we see at once that they are the result of chronic inflammation, and therefore have the same cause as do the singers' nodes already referred to. As a matter of fact, their structure is identical with many of the latter growths, which may therefore be looked upon as early stages of laryngeal polypus. They are more common in men, and are seldom seen in children.

**Physical Appearances.**—They are smooth, rounded bodies, which may be sessile or may have a long pedicle. They may be red and congested or look pale and opaque. They usually have their attachment to the anterior part of the true cords, but may also spring from the ventricles or false cords, the subglottic space (see Fig. 563), or from the anterior commissure. They may be very small, in which case they are usually sessile (singers' nodes); or they may be so large as almost to fill the larynx, leaving surprisingly little room for respiration. When large they are commonly pedunculated, pear-shaped growths. They are usually single, but may have several lobules.

**Papilloma** is of such frequent occurrence in the larynx and is so closely allied to various manifestations of inflammation, such as pachydermia and the surface-phenomena of certain tubercular and syphilitic lesions, that we must presume that the local irritation of inflammation is an important element in its pathogenesis. Generically it has been classified by pathologists among the fibromata and called a papillary fibroma; but its chief characteristic is epithelial proliferation, and to be consistent with pathological laws it would seem that its name should rather be "benign epithelioma." According to Schmidt's tables, he met it in about 10 per cent. of his cases of laryngeal neoplasms. Schrötter<sup>1</sup> places its proportions at 18 per cent., while Moure<sup>2</sup> agrees with Bruns, Fauvel, Massei, Krishaber, and Elsberg in saying that it occurs in about 50 per cent., and Mackenzie puts the figure as high as 67 per cent. Schnitzler<sup>3</sup> says it is the most frequent of all laryngeal growths, especially in children; while in adults papilloma becomes less frequent and fibroma more common. This discrepancy probably depends on how many of the inflammatory nodules, already spoken of, are placed in the category of tumors. Its most frequent site of attachment is the vocal cords in their anterior third and at the anterior commissure, but it may occur everywhere in the larynx. A growth may have a long pedicle which allows its attachment beneath the cords, and yet the mass may present above them.

In *children* it presents certain features in diagnosis and treatment not observed at other periods of life nor in other growths. Congenital cases have been reported in which the child was aphonic from birth. In very young children laryngoscopical examination is usually unsatisfactory and always more or less incomplete. When the growths are situated in the upper part of the larynx they can sometimes be felt by the examining-finger. Hoarseness in a child, slowly increasing to aphonia and dyspnea, render the diagnosis exceedingly probable. Tracheotomy may then be indicated, in the course of which the diagnosis will be established. The growths are usually sessile and frequently disseminated. While Hooper<sup>4</sup> has succeeded in operating on

<sup>1</sup> *Vorlesungen über die Krankheiten des Kehlkopfes.*

<sup>2</sup> *Klinischer Atlas der Laryngologie.*

<sup>3</sup> *Leçons sur les Maladies du Larynx.*

<sup>4</sup> *International Clinics*, October, 1891.



children after tracheotomy, and even without it, by endo-laryngeal methods under ether, this is usually not practicable nor satisfactory. Tracheotomy should be performed, when indicated, for the dyspnea, and the tube left in for several months before thyrotomy is done, which may result in permanent loss of voice or serious impairment of it.

A large number of cases have been reported of spontaneous cure after tracheotomy, presumably due to the rest afforded the larynx. Thyrotomy may be done and the larynx thoroughly curetted and cauterized, but recurrence even then is common. Intubation has been tried in hope that the pressure of the tube would cause absorption of the growths, but not with satisfactory results.

**Physical Appearances.**—They may be single or multiple, with a long pedicle or broad-based. They may dot the surfaces of the cords as little buds or fill the whole cavity of the larynx with a fungus-looking mass, which may be pale or of a dark-red color. Their size, however, is not usually larger than a pea.

**Differential Diagnosis.**—There are certain conditions in the larynx which may give rise to a mistaken diagnosis of papilloma. The one which possesses most interest is *epithelioma*. As has been said, papilloma is itself a distinctly epithelial growth. Every laryngologist knows that occasionally a beginning cancer will present exactly the same appearance in the larynx as a papilloma. Indeed, there may be no carcinomatous elements in the surface-proliferations, and thus a microscopical examination of portions removed by endo-laryngeal procedure may be misleading. A papillary tumor occurring in the larynx under twenty-five is in all probability a benign growth. Occurring in a patient over fifty, who has had no previous laryngeal trouble, however benign in its appearance, it is always to be looked upon with suspicion. If it is pedunculated, and after existing several months the surrounding mucous membrane presents no appearance of infiltration nor zone of inflammation, it is presumably benign. Any limitation of movement in the excursion of the vocal cords is a suspicious circumstance, which if marked is almost pathognomonic of malignant disease. Recurrence after thorough removal in case of malignancy is apt to be accompanied by infiltration, while when benign this is not noted; but recurrence itself in a patient past middle life is not a favorable omen, although in children it is the rule in benign growths. Unless the piece removed for examination includes some of the tissue from which the growth springs, a negative microscopical examination is not conclusive. On the other

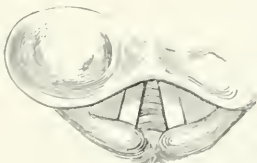


FIG. 636.—Cyst of larynx (from Mackenzie).

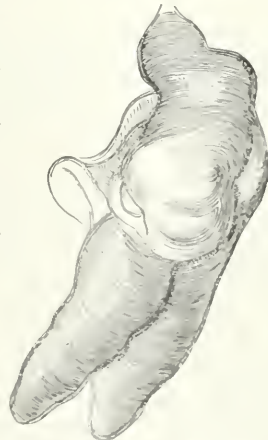

FIG. 637.—Lipoma of larynx (from Schrötter).

hand, even a surface-clipping may show the character of the growth; but frequently a concentric arrangement of epithelial cells leaves the examiner in doubt as to their significance. Under such circumstances time must be



allowed to watch the progress of the case, but it should be examined at frequent intervals by a competent diagnostician.

**Tuberculosis** of the larynx presents occasionally an appearance which to the novice closely resembles a papillomatous growth (see Figs. 612, 616, 617, 622). Papillary masses at the posterior commissure, or, less frequently, more anteriorly, may so project into the larynx as to hide underlying infiltration or ulceration. Examination of the chest or sputum may even be negative or the former doubtful. The position of the growth at the posterior commissure, its sessile character, the paleness of the larynx, the prominence of cough as a symptom, and the general history of the case, will usually allow the experienced laryngologist to make a diagnosis without the aid of pulmonary signs. Microscopical examination will frequently show tubercle-bacilli; but these may also be absent, and only the epithelial proliferation is to be noted.

**Cysts**<sup>1</sup> (Fig. 636), angioma<sup>2</sup> (Fig. 634), myxoma,<sup>3</sup> lipoma<sup>4</sup> (Fig. 637), chondroma,<sup>5</sup> adenoma,<sup>6</sup> lymphoma<sup>7</sup> (Fig. 638), and colloid growths are all occasionally met with in the larynx, while amyloid degeneration<sup>8</sup> has been noted in various tumors.

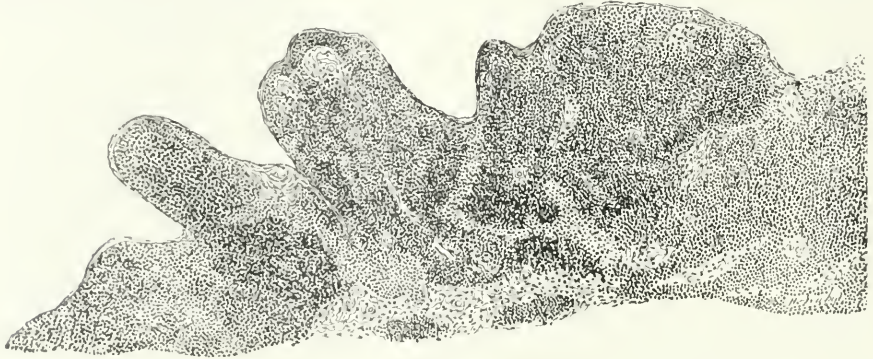


FIG. 638.—Papillary lymphoma of larynx.

**Symptoms of Benign Laryngeal Growths.**—In a general way it may be said that supraglottic tumors first produce cough, neoplasms of the vocal cords first give rise to hoarseness, and infraglottic growths to dyspnea; but it will be readily understood that no absolute rule can be laid down.

<sup>1</sup> Garel, *Centrabl. f. Laryng.*, iv., 147; *Lyon Méd.*, April 12, 1885; Richard Ubrich, *Dissertation*, Würzburg, 1887; Ledderhose, *Deutsch. Zeit. f. Chirurg.*, xxix., 4, 1889; Ref. *Centrabl. f. Laryng.*, vi., 255; Chiari, *Centrabl. f. Laryng.*, viii., 308; Thost, *Deutsch. med. Woch.*, 1891, No. 20, p. 686; Ingals, *N. Y. Med. Journ.*, Sept. 1, 1894, p. 260.

<sup>2</sup> Wolfenden, *Journ. of Laryng.*, 1888, p. 291; Glasgow, *Trans. Amer. Laryng. Assn.*, 1888, p. 146; Loomis, *N. Y. Med. Record*, April 5, 1896.

<sup>3</sup> I have sections of two specimens in my possession. The reports of myxoma are so confused with those of edematous growths that it is difficult to distinguish the true from the false. Bosworth refers to 12 or 15 cases.

<sup>4</sup> Farlow, *N. Y. Med. Journ.*, ii., p. 610, Nov. 16, 1895; Schrötter, *Vorlesungen über die Krankheiten des Kehlkopfes*, p. 271.

<sup>5</sup> Virchow, *Die Krankhaften Geschwülste*, i., p. 411; Bond, *British Medical Journ.*, May 6, 1893; Gerhardt, *Kehlkopfgeschwülste*; Nothnagel's *Spec. Path. and Therap.*

<sup>6</sup> It is doubtful whether these occur in the larynx, though Cornil and Ranvier (*Histologie Pathologique*, ii.) speak of a diffuse condition there which they call adenoma.

<sup>7</sup> The only reports, without general lymphomatosis, are Wolfenden and Martin's *Studies in Path. Anat.*, Fasc. 2, 26; Jonathan Wright's "Subglottic Neoplasms," *Journ. Amer. Med. Assn.*, Sept. 26, 1891.

<sup>8</sup> Martuscelli, *Archivi Italiani de Laryngologic*, Fasc. 3, 1896; Gerhardt, *loc. cit.*

Glottic spasms, aphonia, and apnea are the graver forms of the same clinical character. Pedunculated growths, by changing their position in relation to the glottis, frequently cause intermittency or exacerbation of these symptoms.

Benign tumors being usually of slow growth, the advent of dyspnea is not noted by the patient, except in the case of pedunculated growths, when it is intermittent or spasmodic, until very surprising encroachment has been made on the air-way. They so gradually become accustomed to interference with respiration that it is not noticed until some sharp attack of inflammation still further blocks the larynx and perhaps produces dangerous choking. The laryngoscope, of course, establishes a diagnosis which, until it is used, is mere surmise.

**Treatment.**—The treatment of benign laryngeal neoplasms consists in their removal from the larynx or their destruction *in situ*. The method and means employed will depend almost entirely upon the size, shape, and situation of the growth. Small sessile growths can best be destroyed by the galvano-cautery. The various forms of laryngeal forceps, snares, and guillotines are the endo-laryngeal instruments, among which selection must be made for the pedunculated or circumscribed growths. This selection will be largely a matter of the individual preference of the operator. Urgent dyspnea may necessitate immediate tracheotomy. In many cases the tumor may be so large that it is advisable to have tracheotomy-instruments at hand for immediate use, should the emergency of the moment require it during an endo-laryngeal attempt. Rarely, in subglottic or in broad-based hard growths, such as chondromata, a thyrotomy is necessary.

### MALIGNANT TUMORS OF THE LARYNX.

**Carcinoma of the Larynx.**—It is not intended here to treat of those cases of cancer which, originating elsewhere, have spread by continuity or metastasis to the larynx. Such are the malignant growths of the laryngopharynx and esophagus, and of the cervical glands.

In 1889 Semon<sup>1</sup> collected the statistics of laryngeal cancer in such numbers that from the facts given we are able to gather a better and more definite knowledge of malignant growths in the larynx than in any other part of the air-passages. This was due to the interest aroused in the tragic fate of the Emperor Frederiek of Germany, and to the unfortunate quarrels of his medical attendants.

Semon's tables show the reports of 107 observers, whose collective experience comprised 10,747 cases of benign growths and 1550 malignant tumors, a proportion of about 7 to 1. Since, as we shall see later, considerably less than 100 reports of laryngeal sarcoma could be collected in 1894 from literature, we may disregard these growths in estimating the relative frequency of carcinoma of the larynx.

As will be seen from his list, Schmidt had himself seen 75 cases. From Semon's tables we find that Störk had seen 100 in Vienna, Oertel 46 in Munich, Massei 39 in Naples, Fauvel 150 in Paris, Semon 56 in London, Cohen 100 in Philadelphia. These are figures given in some cases as estimated, and the number is proportionately larger owing to the numerous cases seen in consultation.

Gerhardt says carcinoma of the larynx is three times more common in men than in women. According to Schmidt's experience it is nearly four times as

<sup>1</sup> *Centralblatt für Laryngologie.*

frequent. Jurasz's own experience was 15 men, 1 woman. He quotes Baratonx's collected statistics as showing 88 per cent. in men.

Jurasz's cases showed it most frequent in the decade from 50 to 60. Gerhardt, quoting Kraus, gives the following table as to age.

|                    |     |
|--------------------|-----|
| 20 to 30 . . . . . | 4   |
| 30 to 40 . . . . . | 18  |
| 40 to 50 . . . . . | 49  |
| 50 to 60 . . . . . | 76  |
| 60 to 70 . . . . . | 30  |
| 70 to 80 . . . . . | 10  |
|                    | 187 |

Schrötter says he has seen it in a child of three and a half and in a girl of ten and a half years. It has been noted that it occurs more frequently in well-to-do people, and especially in those who use their voices constantly. Heredity seems to have a marked influence in some cases.

The site of growth in Jurasz's cases was as follows :

|                                               |    |
|-----------------------------------------------|----|
| Whole larynx . . . . .                        | 1  |
| Right side of larynx . . . . .                | 2  |
| Epiglottis of larynx . . . . .                | 3  |
| True cords, 1 right, 1 left, 2 both . . . . . | 4  |
| True cords and ventricular bands . . . . .    | 3  |
| Arytenoids and interarytenoid space . . . . . | 2  |
|                                               | 15 |

In Mackenzie's 53 cases, however, 28 sprang from the ventricular bands.

Bosworth, quoting from Gurlt, says that out of 11,131 cases of carcinoma it occurred in the larynx in 63 cases, as against 47 in the air-passages above it.

Epithelioma is the form usually observed, but encephaloid, adeno-carcinoma, and scirrhus have all been reported in the larynx. The medullary cancer is more frequently extrinsic and the scirrhus is very rare. Out of 68 cases collected by v. Ziemssen, 57 were epithelioma, 9 encephaloid, and 2 villous tumors; out of Mackenzie's 53 cases, 2 were scirrhus. The usual duration is about three years, but some cases of adeno-carcinoma<sup>1</sup> have lately been reported which lasted five or six years.

**Symptoms.**—Hoarseness is the first symptom, which usually comes on gradually and lasts for several months before any other symptom supervenes. The majority of the patients are in good general health. The hoarseness, after a longer or shorter time, is accompanied by dyspnea and cough; the former rapidly increases until tracheotomy is urgently indicated. Later in the disease glandular enlargements may be felt in the neck; but they are usually not present at first, although Fränkel reports cases in which the glandular involvement was the most marked feature of the case from the first. Dysphagia sooner or later occurs, and pain, worse at night, robs the patient of sleep. These symptoms are more marked and come on earlier when the ulcerated growth is on the posterior wall or the epiglottis and aryteno-epiglottic folds; but are late when the tumor is on the vocal cords or in the laryngeal ventricles.

The general health deteriorates, the appetite fails, and there is loss of flesh and strength.

Ulceration gives a peculiar and, Fränkel says, characteristic odor to the breath, which is identical with that from a pharyngeal carcinoma. In

<sup>1</sup> Sokolowski, *Archiv für Laryngologie*, Bd. i., heft 1; Krieg, *Ibid.*, Bd. i., heft 2.



a recent case of carcinoma of the pharynx, before I realized the source of the odor, the first impression I had of it was that the patient had been using a gargle of the solution of the chlorid of iron on a fetid surface.

Finally the growth becomes apparent to external palpation, perforating the laryngeal cartilages, which crackle under the finger on pressure. It may even perforate the skin and appear as a fungous mass externally. The last phases of the disease present a most pitiable aspect of human suffering. Tracheotomy has long since become necessary. Granulations block the tube and, growing below it, slowly suffocate the patient. Continual cough, inability to swallow, lancinating pains, and the foul odor make a picture which every laryngologist should have in mind in considering the treatment of the disease in its early stages. Pieces of necrosed cartilage are coughed out, or portions of the tumor may fall into the trachea and bronchi. Perforation of the esophagus frequently supervenes and food may penetrate the bronchial tubes. Hemorrhage is sometimes abundant, although blood is usually only mixed with the copious discharges from the throat. Perforation of the carotid may, however, end the case. Death may come thus, or from exhaustion, or from supervening pneumonia due to penetration of pieces of the growth or food and blood into the lungs—the so-called “Schluck Pneumonic.” Suffocation is, therefore, not the only termination of the disease, although it is a frequent one.

**Diagnosis.**—The *laryngoscopic appearances* of laryngeal cancer must be considered in connection with its differential diagnosis, so far as its initial stages are concerned. Its differentiation from papilloma has already been alluded to. In its incipient stages epithelioma frequently resembles the benign growth. At other times a flat, indolent ulcer on the vocal cord may be seen at the first laryngoscopic examination. When the edges are infiltrated and round we may suspect carcinoma, but sometimes this is not the appearance. The edges may be more or less flat and sharp-cut. Anti-syphilitic treatment in decisive doses of mercury and the iodid of potash must be given while a microscopical examination is being made. Tuberculosis must be thought of, and an examination of the lungs for physical signs, and of the sputum for bacilli, must be made.

When the growth occurs in the ventricles of the larynx, the problem is a much harder one to solve. We find a smooth swelling presenting above the cords. Being covered by mucous membrane it is impossible to remove a piece for examination. There is a limitation or entire abolition of movement of that side of the larynx. There is nothing to be done but to try to exclude a syphilitic gumma by the vigorous administration of the iodid of potash. Once I saw such a growth which was evidently tubercular. We must remember that cancer may coexist either with a syphilitic history or pulmonary phthisis. We must also remember that the administration of the iodid of potash may cause a sensible, although temporary, diminution in the size of a cancerous swelling. As Fränkel says, it seems as though the disease was simply catching its breath for a fresh start. The surface finally is involved and the diagnosis becomes evident.

The appearance of the growth, which in the early stages varies so, in the later stages is more uniform and characteristic. The ulcer of cancer then differs in no way from its appearance elsewhere. A fungous mass covered by grayish or whitish secretion fills the larynx more or less completely. The growth eats into the cartilages, causing the swelling characteristic of perichondritis. It has nearly always, even in the initial stages, burrowed more deeply into the underlying tissues than appears on the surface. It grows



upward over the top of the larynx, infiltrating the surrounding tissues and producing then marked glandular involvement.

Semon has pretty conclusively settled by his statistics the question of the degeneration of a benign into a malignant growth of the larynx. The exceeding rarity and doubtfulness of this occurrence was one of the assertions of pathologists which clinicians had been loath to accept. In only 45 out of the 10,747 cases reported did this seem possible; while as following upon endo-laryngeal operations it was only reported 33 times. Many of these reports render the opinions expressed extremely doubtful; so that excluding all but the certain cases, Semon's proportion is 1 to 1645 of malignant degeneration after endo-laryngeal operation. And after all, we may say that the proof is necessarily a *post hoc, ergo propter hoc* argument. We must allow the possibility of a benign tumor becoming malignant, although the strongest microscopical proof must be required to admit of its probability in any case.

The prognosis of laryngeal carcinoma is, of course, very bad; but the statistics hereafter quoted, it should be remembered, include many cases in which the growth was not confined to the "box of the larynx."

The same rule here holds good, as to the difference in the prognosis of those cases operated on early and those operated on late, as elsewhere in the body; although the cartilaginous walls shutting off the growth from surrounding tissues would seem theoretically to give the incipient cases an especially good prognosis. Without operation all cases die miserably.

**Treatment.**—Of late years the conviction has grown among laryngologists that every primary intrinsic carcinoma of the larynx in its early stages is a case for extra-laryngeal rather than endo-laryngeal operation. The diagnosis once made, the laryngologist should see *noli me tangere* written in the larynx of every case. No operator, however skilled, can ever be sure that he has removed the infiltrating cancer-cells. There is every reason to believe that cancer is a local disease, which, if disturbed by any operative procedure short of extirpation, is apt to spread rapidly beyond the reach of the knife. Fränkel and Moure both state their belief that the removal of pieces for histological examination does no harm, but that the wound usually heals over. The majority of observers, however, do not agree to this. Doubtless, ineffectual tampering with an already malignant though quiescent growth has, by its results, given rise to the opinion formerly held by some, that such procedures were the exciting cause of a malignant degeneration.

No rules for operation can be laid down that will apply to every case. In a general way it may be said that all cases which are confined to the interior of the larynx and in which there is no glandular involvement are cases for operation by laryngectomy or some of its modifications. Excision, according to Powers and White,<sup>1</sup> has been performed upwards of 300 times. From them I quote the following table, which gives at a glance a general report of the results attained:

#### 1. TOTAL EXCISION OF THE LARYNX.

|                                                                                                                        |     |
|------------------------------------------------------------------------------------------------------------------------|-----|
| Cases reported prior to January, 1892 . . . . .                                                                        | 180 |
| Died as result of operation . . . . .                                                                                  | 72  |
| Died in first year, 5 from recurrence . . . . .                                                                        | 8   |
| Recurred in first year, either dead or living when reported . . . . .                                                  | 51  |
| Recurred after 1 year (13 months 2, 2 years 2, 2 years 1 month, 2 years 7 months, 3 years 4 months, 9 years) . . . . . | 8   |
| Reported in first year, free . . . . .                                                                                 | 16  |
| Reported in second year, free . . . . .                                                                                | 11  |
| Reported in third year, free . . . . .                                                                                 | 3   |
| Reported after 3 years, free . . . . .                                                                                 | 11  |

<sup>1</sup> *Medical Record*, March 23, 1895.

2. PARTIAL EXCISION OF THE LARYNX.

|                                                                         |    |
|-------------------------------------------------------------------------|----|
| Cases reported prior to January, 1892 . . . . .                         | 77 |
| Died as result of operation (8 weeks) . . . . .                         | 26 |
| Died in first three years (3 from recurrence) . . . . .                 | 5  |
| Recurrence in first year, either dead or living when reported . . . . . | 17 |
| Recurrence after 1 year (13 months, 16 months, 17 months) . . . . .     | 3  |
| Reported in first year, free . . . . .                                  | 13 |
| Reported in second year, free . . . . .                                 | 4  |
| Reported in third year, free . . . . .                                  | 2  |
| Reported after 3 years, free . . . . .                                  | 7  |

After what has been said of the course of laryngeal cancer left to itself, it will be admitted that the many cases who died as a result of operation are not to be looked upon as necessarily an argument against the procedure; nor are the cases of complete recovery to be looked upon as unqualified successes. The loss of a larynx is a terrible mutilation of the human organism, and the after-life of the patient, with or without an artificial vocal apparatus, is not an enjoyable existence. Gussenbauer and Wolf have invented mechanisms which permit these patients to produce articulate speech; but many cases have been reported in whom some fold of tissue has been formed by nature to serve as a vibrating membrane in the production of sound and its modification by the lips and tongue into speech.

Cohen's well-known case of adeno-carcinoma, in which the larynx and upper part of the trachea being removed, the remaining tracheal orifice was stitched to the skin above the episternal notch, is still alive (November, 1896)—nearly five years after operation—and he speaks hoarsely, but distinctly, by means of swallowed air which he holds in a kind of a pouch in his pharynx and expels past some vibrating fold of mucous membrane in the neighborhood of the pillars of the fauces. He breathes without cannula through the cervical opening.

Excision of the larynx is an operation which, in fairness to the patient, should only be performed by a surgeon skilled in all the technic of modern surgical methods and equipped by previous surgical experience with the ability and presence of mind to meet grave and often unexpected problems which may arise during its performance. Cohen and especially Semon<sup>1</sup> are the laryngologists who have had the most gratifying results in these operations: but, as a rule, it is not a task to be undertaken by even the experienced laryngologist.

In many cases the tumor has spread, either by direct growth or by metastasis, beyond the larynx. The inclusion of these in the tables given is what makes the percentages of recurrence and death so high. In each case, as it is met, a decision as to a radical operation or a palliative treatment is to be decided on its merits and according to the wishes of the patient, when the conditions are explained to him. Tracheotomy for the passage of air is always indicated, and even gastrostomy for the introduction of food may be a means of prolonging a miserable existence.

**Sarcoma of the Larynx.**—Bergeat<sup>2</sup> has presented the most complete and exhaustive review of the reports of sarcoma of the larynx yet published. His list is as follows:

|                                                       |     |                                                     |    |
|-------------------------------------------------------|-----|-----------------------------------------------------|----|
| Laryngeal sarcoma, primary . . . . .                  | 85  | Tracheal and bronchial sarcoma, primary . . . . .   | 7  |
| Laryngeal sarcoma, secondary, by continuity . . . . . | 10  | Tracheal and bronchial sarcoma, secondary . . . . . | 9  |
| Laryngeal sarcoma, secondary, by metastasis . . . . . | 2   | in man . . . . .                                    | 9  |
| Doubtful . . . . .                                    | 17  | Tracheal and bronchial sarcoma, secondary . . . . . | 1  |
|                                                       |     | in animal (dog) . . . . .                           | 1  |
|                                                       | 114 |                                                     | 17 |

<sup>1</sup> Semon (*Lancet*, Dec. 15, 1891, *et seq.*), in a series of private cases, has attained the best results hitherto published. <sup>2</sup> *Monatsschrift für Ohrenheilkunde*, 1895, Nos. 8 and 12.

Reports of the following cases (not included in Bergéat's tables) are at hand :

Chappell,<sup>1</sup> female, aged 32, symptoms 4 years. Sarcoma (perithelioma) of epiglottis, very large, pedunculated, removed with hot snare; weight 360 grains; size  $4\frac{1}{2} \times 3\frac{5}{8}$  inches in circumference.

Thompson,<sup>2</sup> male, aged 35, blacksmith, symptoms 6 months, right side of larynx, laryngectomy.

Mackenzie says that he had seen only 5 cases of sarcoma of the larynx. As he had seen 53 cases of carcinoma, we have the ratio in his experience of about 1 to 10. Schmidt's proportion, it will be seen, is 3 to 75 or 1 to 25; while Bergéat quotes Gurlt as giving the general relative occurrence throughout the body as 1 to 13. Bosworth, quoting Gurlt, says that out of 848 sarcomata, the larynx was the seat of disease in only 1 case.

In Bergéat's tables, out of 66 cases of primary sarcoma, 48 were of the male sex and 18 female—in general, he says, sarcoma occurs in men 10 per cent. more frequently. It occurred in men almost twice as frequently (15) from 50 to 60 as in any other decade; the next in frequency (8) being from 40 to 50. The youngest was 7 years old; the oldest 81. In women it occurred from 21 to 53 inclusive, there being 5 each from 30 to 40 and from 40 to 50, and only 2 from 50 to 60. Curiously enough he notes its more frequent occurrence in people who came often in contact with horses.

In variety they were spindle-celled, 22; round-celled, 12; alveolar, 5 or 6; mixed, 4; giant-celled, 2 or 3; fibro-myxomatous, 1.

It had its origin most frequently on the vocal cords, but also occurred in almost every other locality. On the vocal cords and epiglottis the spindle-celled sarcoma was almost the exclusive form found. No instance is recorded in which the growth originated in the larynx and spread to the pharynx; the secondary invasion was always the other way. Erosion and perforation of cartilage were rarely observed. In spite of the numerous observers who have drawn attention to the lateness of glandular involvement in laryngeal carcinoma, Bergéat noted it in 15 per cent. of the cases of laryngeal sarcoma. This was especially marked with the round-celled and alveolar sarcomata. The course of these forms is frequently very rapid; but the duration of sarcoma of the larynx seems to vary greatly, the symptoms sometimes dating back only a few weeks and sometimes running back for several years; some of the cases having lived as long as 7, 8, and 10 years. Pain and dyspnea are not so prominent as in carcinoma, and ulceration is also not so usually observed. The general health is frequently not seriously affected; but there is the greatest variation in the severity of the symptoms.

Diagnosis from carcinoma is usually impossible without a microscopical examination. The same caution must be observed here as elsewhere in distinguishing small round-celled sarcomata from syphilitic and other granulomata. In summing up all the cases, as Bergéat has done, it is seen that the average course and clinical picture differ materially from those of carcinoma, and yet in any given case the differential diagnosis upon these alone is not satisfactory. Bergéat lays some stress on a striking yellow color which is sometimes observed in sarcoma, but never in carcinoma, on the slower growth, the later and more infrequent ulceration. Sarcoma is sometimes pedunculated. There are rarely any sharp-pointed projections, but they are usually round and broad.

Prognosis.—In a general way the prognosis after all methods of operating is better than in carcinoma, one case of total extirpation being well and

<sup>1</sup> *Laryngeal Neoplasms, case 2.*

<sup>2</sup> *The Medical News, Oct. 26, 1895.*

able to work after fifteen years; and in one case the duration was twenty-one years, during which many endo-laryngeal operations were performed. In the larynx, as elsewhere, there are many cases in which the diagnosis is a matter of considerable doubt, even with microscopical examination.

**Treatment.**—The same indications obtain as in carcinoma.

### NEOPLASMS OF THE TRACHEA.

Avellis<sup>1</sup> gives a résumé of the literature of benign tracheal growths. He refers to 17 reports, making with his own about 20 undoubted cases. A few have been reported since 1892.<sup>2</sup>

Many cases are reported of granulation-papillomata and polypi around tracheotomy-wounds, and a few cases are recorded of the projection of pieces of thyroid hypertrophies into the trachea. There are also some reports in which it seems evident that the growths really sprang wholly or principally from the subglottic portion of the larynx. The benign growths were usually papillomata or fibromata. An adenoma and a chondroma have also been noted; but we may be permitted to doubt the nature of these, since the former is so rare anywhere in the air-track and of such a doubtful nature when reported, and chondroma is apt to be confounded with ecchondrosis. Ecchondroses pure or partially ossified have often been noted *post mortem*.

Carcinoma of the trachea is so rare that when Cornil and Ranvier published their work in 1884 they denied<sup>3</sup> absolutely that it ever occurred there primarily. Nevertheless, several had been reported. Ten years later Pogrebinski<sup>4</sup> was able to give abstracts of 13 reports of carcinoma of the trachea, 3 of which he looked upon as doubtful, while 1 was known to have started in the esophagus. To this number he adds a case of his own, an epithelioma primary in the trachea. Many of these cases were of the encephaloid variety. There are a number of other cases reported in which the trachea was secondarily involved from growths in the esophagus and in the thyroid gland. Not included in this list is a doubtful case of Schmidt's and a genuine case described by Oestreich.<sup>5</sup> Another case is referred to in the *Centrabl. für Laryngol.*, viii. p. 396. We have seen that in Bergeat's tables but 7 cases of primary tracheal sarcoma are on record, thus refuting the statement of Koch,<sup>6</sup> that sarcoma is the more frequent malignant neoplasm.

The chief symptom is dyspnea, and when dyspnea occurs from a tracheal growth, that growth always dangerously occludes the air-way. In the upper part of the trachea always, and in the lower part usually, the laryngoscope will reveal the nature of the trouble. The physical characteristics of the growths differ in no way from similar neoplasms in the larynx. A low tracheotomy may gain time for a more extensive opening of the air-tube and extirpation of a benign growth. Many cases of death from it are on record; but endo-tracheal operations are usually impracticable. Malignant growths are almost uniformly unrelieved and fatal; although in Schmidt's case of epithelioma, diagnosed microscopically by Weigert, the patient was alive two years after operation. Dyspnea without other symptoms usually appears so late that in malignant cases the patients present themselves only when their condition is hopeless. Indeed, many of the reports are from the post-mortem table.

<sup>1</sup> *Monatsch. f. Ohrenheilk.*, etc., 1892, No. 7, p. 195.

<sup>2</sup> *Centrabl. f. Laryngologie*, 1892, viii. pp. 104-492; 1894, x. p. 100; 1895, xi. p. 134.

<sup>3</sup> Vol. ii. p. 65.

<sup>4</sup> *Revue de Laryngologie*, 1894, No. 12, p. 441.

<sup>5</sup> *Deutsch. med. Woch.*, 1895, p. 34.

<sup>6</sup> *Ann. des Maladies de l'Oreille*, etc., 1890, p. 682.



# INJURIES AND DEFORMITIES OF THE NOSE AND THROAT.

BY JOHN O. ROE, M. D.,  
OF ROCHESTER, N. Y.

INJURIES of the nose may be considered under the following heads: (1) contusions, wounds, and burns; (2) fractures of the bones and cartilages; and (3) dislocations of the bones and cartilages.

## CONTUSIONS, WOUNDS, AND BURNS OF THE NOSE.

**Contusions.**—Owing to the prominent and unprotected position of the nose, it is subject to frequent injuries. The most frequent of such injuries are contusions caused by falls or by blows inflicted upon the nose with the fist or any hard substance. There is, according to the amount of the impinging force, more or less hemorrhage from the nose, and ecchymosis at the point of injury. When the injury is confined to the upper part of the nose, it is followed by more extravasation of blood into the loose cellular tissues at the base of the nose and around the eyes, and also by much more swelling of the soft parts, than when the injury is confined to the end or lower part of the nose, owing to the firmness of the tissues in the latter region.

**Treatment.**—When the injury is comparatively slight it, as a rule, gives rise only to moderate epistaxis, from the rupture of the capillaries of the pituitary membrane (usually at the juncture of the bony with the cartilaginous portion of the septum), which generally stops spontaneously. Severe lesions, and sometimes even slight injuries, will be followed by profuse and persistent hemorrhage, owing to the great vascularity of the pituitary membrane, or to a hemorrhagic tendency, requiring the application of pressure, or cold externally, or tamponing of the nose. The simplest manner in which pressure can be applied is by grasping the nose firmly between the thumb and forefinger as close to the face as possible. In this manner hemorrhage from the anterior portion of the nose can be immediately arrested; and at the same time by holding the head forward, so as to allow the blood to gravitate into the dependent portion of the nose, a clot is formed, which will favor the arrest of hemorrhage in the deeper parts.

In severe injuries there may be an effusion of blood between the laminae of the septum, causing what is termed a bloody tumor, which if allowed to remain until decomposition takes place, will result in abscess of the septum (Fig. 639). This should be incised through the nostril and thoroughly evacuated, and the cavity irrigated with bichlorid solution, 1 : 5000. Gentle pressure should then be applied to each side of the septum by means of a clamp having the arms covered with gauze or aseptic cotton, so as to obliterate the cavity and maintain coaptation until healed.

**Wounds.**—Wounds of the nose may be divided into incised, lacerated,

and punctured wounds, according as they are produced by cutting, blunt or bruising, or pointed instruments. They may affect the soft parts alone; the soft parts and bones and cartilaginous framework; or the soft parts, hard parts, and pituitary membrane. They may also be so extensive as to involve the nasal fosse, the orbit, and the accessory sinuses of the nose, and even the cranial cavity.

(a) *Incised wounds* may vary from a slight cut of the skin to the complete severance of the organ. They may be vertical, transverse, or oblique.

Simple incised wounds of the skin are of importance only so far as they cause disfigurement. In case of vertical wounds the edges of the skin come together very readily and can be easily held in position by adhesive plaster or styptic collodion; whereas in transverse wounds there is more retraction of the parts, which necessitates the uniting of the edges of the skin with fine sutures. Special care must be exercised when the inferior portion and wings of the nose are involved, because the elasticity of the cartilages of the alæ tends to separate the parts, while the functional importance is great.

Transverse incised wounds, involving the deeper structure of the nose, may allow the end of the nose to drop down on the upper lip, held only by the septum and tissues at the base of the nose. In some instances a transverse incised wound may be so extensive as to pass through the nose, involving the deeper structure and the maxillary bones. Larrey reports a case in which with "un coup de sabre" the inferior half of the nose, the corresponding two sides of cheek and upper lip, and the two maxillary bones were divided clear to the palate. The parts were carefully sutured in place, with complete recovery in forty-five days.

In other cases the nose may hang by a slender pedicle or be completely severed. A number of cases are recorded in which the union took place when the nose was set on again after it had been severed for several hours. In Cagarlinge's<sup>1</sup> well-known case it was detached five and one-half hours, and in Garenot's case the severed end, which had been bitten off, was recovered from the sewer into which it had been thrown. It was cleansed with warm water, reapplied, and on the fourth day was quite firmly united. In all cases, even if a number of hours have elapsed since the accident took place, attempts should be made at the restoration of the part by carefully cleansing the detached parts with warm sterilized normal salt solution, and scarifying or scraping the raw surface to encourage its attachment.

Galin and Hoffäcker claim an advantage in waiting a short time before restoration of the severed end by reason of there being a complete arrest of hemorrhage. The surfaces can be thoroughly cleansed, and the danger of formation of blood-clots between the surfaces will thereby be avoided. In attaching the severed portion the soft parts, including the cartilaginous portion, should be carefully stitched together, and the interior of the nose should be tamponed with antiseptic gauze to protect the parts from the inside and to maintain the nostrils in their normal form. The union, as a rule, takes place slowly; the end may remain cold and pale for twelve hours or even two or three days, and therefore we must not be in haste to regard the operation as a failure.

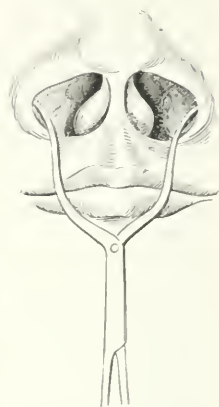


FIG. 639.—Abscess of the nasal septum, showing swelling on both sides.

<sup>1</sup> *Traité des Opérations de Chirurgie*, 1724, Chap. iii., Art. 2, Obs. 6.

(b) *Lacerated wounds* are usually produced by blunt instruments, falls on angular or rough surfaces, projectiles, etc. Wounds from blunt instruments are usually attended with a fracture or dislocation of the nasal bones.

In case of projectiles, where a bullet comes from a lateral direction, it usually passes through the nose, involving both walls; but in case of spent bullets they may penetrate only one wall of the nose and lodge in the meatus, the orbit, in an accessory sinus, or they may penetrate the brain. In some cases the wad of a gun may be forced into the wound with the bullet and remain there as a foreign substance. In one case reported by Legouest, the wad of a gun was found astride of the septum. The skin cicatrized after its introduction and the accident was forgotten. There was a continuous fetid discharge from the nose, and after four years the wad was discovered during a rhinoscopic examination and removed. The treatment of lacerated wounds of the nose requires especial care to render the parts aseptic and to coaptate the skin and maintain the normal contour of the nose, as far as possible.

(c) *Punctured wounds* are produced by sharp-pointed instruments. In some cases the instrument or foreign body may enter through the nasal fossae and penetrate the cranial cavity through the cribriform plate of the ethmoid bone, without external manifestation of the injury. Punctured wounds of the base of the nose are frequently followed by emphysema of the soft parts, owing to the looseness of the connective tissue in this region. This takes place most frequently when the penetrating wound of the nose communicates with the nasal cavity, and the emphysema is caused by the air being forced through this opening under the skin when the patient blows his nose, or during forcible expiration through the nose. It accordingly appears quickly, giving the sensation of a sharp, hot streak as the air is forced under the skin. It may be limited to the superior part of the nose, where the cellular tissue is quite loose, or it may extend to the eyelids, and sometimes to the neighboring portion of the face. Slender instruments, or such foreign bodies as knives, pencils, and the like, may penetrate the walls of the nose and break off, remaining in the wound.

**Treatment.**—Simple punctured wounds of the external nose, as a rule, require only ordinary antiseptic care. In complicated cases, however, in which the end of the instrument has broken off and remains as a foreign body, it must be extracted either through the wound, from the interior of the nose, or removed through an artificial opening, and the wound afterwards treated as an incised wound. Each case, however, must be treated according to the peculiarity of the conditions found. The emphysema of the face which sometimes accompanies punctured wounds of the nose usually subsides in a short time, although the disappearance can be hastened by poultices and compression.

**Burns and Scalds.**—Burns and scalds of the nose do not differ in their nature and treatment from burns and scalds of other portions of the body. They are of special significance only so far as the resulting cicatrices cause distortion of the organ and contraction of the nasal passages. It is therefore during the healing process of the burn or scald that we should give particular attention to prevent any such complication.

The contraction of the burn can be overcome in a great measure by resorting to skin-grafting before the wound is healed, thereby replacing the skin that has been destroyed and preventing the formation of cicatricial tissue, by which the edges of a wound are forcibly drawn together. Special care should be taken in this particular when the nasal orifices are involved. Ivory or vulcanite plugs or tubes should be inserted into the nostrils to keep

the nasal openings widely dilated, until all tendency to contraction of the tissues has passed. When, however, this contraction of the tissues has taken place and the nasal orifices have become greatly narrowed, the treatment to be adopted is described under the head of Stenosis of the Nasal Passages.

#### FRACTURES OF THE BONES AND CARTILAGES OF THE NOSE.

Fractures and dislocations of the nose may vary, according to the severity of the injury, from simple displacement of some one of the bones of the nose, without wounding the skin, to compound comminuted fracture of the bones, attended with more or less destruction and escape of the bony fragments, resulting in marked distortions and permanent disfigurement of the nose.

**Fractures of the bones of the nose** are comparatively rare when we consider the prominent and exposed position of the nose and the frequency with which bodily injuries occur. This is accounted for somewhat by the yielding condition of the cartilaginous portion of the nose, which more or less resists fracture, and the arched form of the osseous portion or bridge of the nose, which enables it to withstand a considerable amount of external force. The nose is also in many cases protected by the prominence of the frontal bone.

Fracture of the nose is more frequent in men than in women, and also more frequent in adults, owing to the cartilaginous and more yielding character of the parts in the young.

Fractures of the nose always result from force applied externally, oftenest in the form of blows or falls directly on the nose. They are usually attended with lesions of the integument, and are frequently associated with fractures of the nasal process of the superior maxilla, together with dislocation or fracture of the nasal septum. In severe injuries the osseous portion of the nasal septum, together with the nasal bones, has been driven backward into the brain.

Such injuries are usually attended with severe hemorrhage and escape of cerebral matter, with all the symptoms of fracture at the base of the cranium, and are generally fatal.

Fractures of the bones of the nose are almost always bilateral, unilateral fractures being rare. In some cases, when the force is applied entirely to one side, fracture of the bone on this side may be attended with dislocation of the bone on the opposite side, together with lateral dislocation of the nasal septum, as represented in Fig. 640.

Fractures of the nose may be divided into *simple*, *comminuted*, and *compound*. In simple fractures of the nose the line of the fracture may be vertical, oblique, or transverse, according to the direction of the blow. In vertical fractures one fragment may slide under the edge of the other, the latter protruding sufficiently to form a ridge readily felt by the finger. In oblique or transverse fractures the lower fragment is depressed; the upper fragment remains unbroken and, accordingly, maintains its normal position.

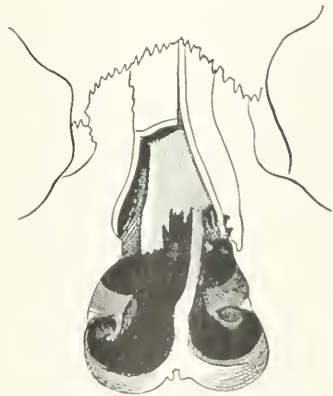

FIG. 640.—Fracture of the right nasal bone and displacement of the left, with lateral dislocation of the nasal septum.



In a comminuted fracture the fragments are more or less numerous, and in case it is compound they may escape through the wound and thereby be destroyed and lost. Simple fractures may exist without any resulting disfigurement; whereas comminuted or compound fractures may be followed by narrowing and obstruction of one or both nasal passages, and of one or both lachrymal ducts, causing lachrymal tumors and stylicidium.

The *lachrymal bones* may be fractured by a slight or very moderate blow, accompanied by discoloration of the eyelids; and sometimes emphysema of the cellular tissue of the orbit may take place, on blowing the nose, by the escape of air from the nostrils through the fractured edges of the bone.

**Diagnosis.**—The diagnosis of fractures of the nose in some cases is extremely simple, whereas in other cases it is attended with great difficulty. Simple fractures of the nose may exist without displacement of the fragments, the latter being held in place by the periosteum, the soft parts, and the mucous membrane. The line of the fracture can often be felt under the finger as a slight fissure. In other cases it is manifested only by pain in the seat of the injury. When there is displacement of the fragments the protruding edges of the fracture form a ridge, which is not only readily perceptible to the finger, but can be seen on inspection. In order to determine the extent of the fracture and the condition of the part, the examination should follow the injury as speedily as possible, for the swelling of the soft parts so quickly supervenes as to make the diagnosis very difficult.

Vertical fractures can be detected by the careful movement of the lateral fragments against the edges of the unbroken portion. In oblique or transverse fractures, since the lower fragment becomes depressed, the edge of the unbroken portion is prominent. Often, in making a rhinoscopic examination, the depressed portion of the bone can be seen projecting into the interior of the nose. In comminuted fractures the crepitation of the fragments is generally readily detected, but great care should be exercised when making the examination not to increase the displacement. In compound fractures the condition of the bony parts can be easily discovered by exploration with a probe through the wound. When the contused parts have become greatly swollen before the patient comes under observation, it is then usually necessary to wait until the inflammation and swelling have been reduced, before the exact condition of the part can be made out.

Two of the most prominent symptoms of fracture of the nose are epistaxis and emphysema of the tissues of the nose. Emphysema of the nose is indicative of rupture of the mucous membrane, through which opening air is forced into the tissues. It usually comes on rapidly when the patient blows his nose, as in the case of punctured wounds. It is generally limited to the region at the base of the nose; although it may extend to the periorbital cellular tissue (sometimes completely closing the eyes) and throughout the face. In exceptional cases it may involve the tissues of the neck. It is detected by crepitation, much as given by the edges of the broken bone. Epistaxis, which is almost always present, varies according to the extent of the injury, and may be very slight or very profuse, although it is never sufficient to endanger the life of the patient. It usually ceases spontaneously, although in severe cases tamponing the nose may be necessary to prevent weakening the patient from loss of blood. In these cases the presence of hemorrhagic exudates, which may accumulate between the hard and soft parts, should be recognized and evacuated to prevent purulent formations or septic infection and the breaking-down of the lacerated tissues.

In all cases of fracture of the nose the gravity of the case depends

entirely upon the brain-complication. The secondary complications which may follow these injuries are deformities of the nose, injury to the lachrymal apparatus, impairment of the sense of smell (either from occlusion of the nasal passages or injury to the olfactory nerve), and lack of resonance in the voice, owing to the contraction of the nasal passages.

**Treatment.**—In all cases of fracture of the nose the replacement of the fragments should be effected as speedily as possible, before swelling of the parts has supervened to prevent it; for when the swelling is extensive it is frequently necessary to wait until it subsides before the fragments can be replaced. This can usually be delayed for three or four days with perfect safety, although if the case is seen early, much of the swelling can be prevented by attention to antiseptic and antiphlogistic measures.

In case the fracture is a compound one, we should attend carefully to the wound of the skin (as in case of lacerated wounds of the nose) in order to prevent, as far as possible, disfigurement from resulting scars. Laceration of the mucous membrane should also receive attention and be rendered, as far as possible, aseptic.

In simple fractures the reduction is best accomplished with a smooth sound, placed in the interior of the nostril to raise the depressed fragments, and their coaptation is facilitated with the fingers on the outside of the nose. When no sound is at hand and the nasal passages are sufficiently large to admit the little finger, it can be very advantageously substituted. In some cases the fragments are best and most easily adjusted by means of a pair of smooth-blade forceps, one blade placed in the nostril and the other outside, according to the plan of Weber, care being exercised not to use too much pressure; and to avoid lacerating the tissue the blades can be covered with rubber or adhesive plaster. For this purpose Mollière uses forceps with ivory blades. When the septum has at the same time become fractured or dislocated, it also should be put in place.

When the fragments have been replaced, they must be held with some form of retentive appa-

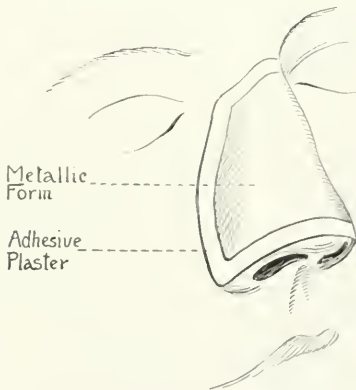


FIG. 641.—The author's metallic form.



FIG. 642.—Metallic form and adhesive plaster as applied.

ratus. If the skin is unbroken, a piece of rubber adhesive plaster, cut of the shape to completely cover the nose, has been found by the author to be one of the most important aids in rendering the exterior contour smooth and symmetrical. This is to be covered with a metallic form (Fig. 641), made

of a sheet of aluminum cut the requisite size and shape, so that when bent the internal contour is the same as the normal nose, and of sufficient size to rest lightly over the nasal border of the superior maxilla. Before this form is applied to the nose, I usually cover and line it with adhesive plaster, which materially assists in holding it in place. It is then adjusted to the nose and securely held in place with adhesive straps, as shown in Fig. 642.

Various other methods have been devised for maintaining the fractured nasal bones in place. Thus Malgaigne has used moulds of lead, which have the disadvantage of being heavy. Hamilton uses gutta-percha, but it is not readily adjusted to the desired shape of the nose. Weber employs strips of gutta-percha, maintained in place by plaster. Dumreicher employs successive collodion bandages, applied to the nose. Walsham uses a mask of leather, moulded to the face with braces controlled by screws, to maintain the bones in place. Adams has devised a nasal truss attached to a headband, which is buckled firmly around the head, with a padded arm controlled by screws resting against each side of the nose to hold it in position, as shown in Fig.

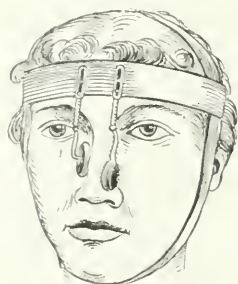

FIG. 643.—Adams's nasal truss.

643. None of these methods, however, has given me the satisfactory results obtained by the simple method which I have described.

Numerous internal supports have also been employed for holding these bones in position after the deformity has been corrected. Hamilton packs the nose with pledgets of lint, to each of which is attached a thread for ready extraction. Packard employs plugs of hard rubber, placed inside the nostril. These methods have their advantages since no one plug large enough to maintain the bones in place can be introduced through the nasal apertures. For the purpose of maintaining the vault of the nose, Mason, of Brooklyn, has devised a method of transfixing the nose with nickel or gold needles through the base, on a line with the maxillary junction. He then passes under the needles and over the nose a bandage of rubber. This is efficient to prevent spreading at the base of the nose, and at the same time to hold the nose snugly together and prevent depression of the vault. This is considered an exceedingly ingenious arrangement, and may be of service in some cases. After the parts have become solidified, at the end of seven or eight days, the needles are removed. Many discourage the employment of internal supports, because of the irritation which they cause. This objection is ill-founded, for the reason that the irritation is invariably due to the excessive amount of pressure employed. Very slight pressure only is required to maintain the parts in position, because they are naturally immovable and there is no muscular tension to cause their displacement, nor any other force when the nose is thoroughly protected by a uniform external support. The fragments can most easily be maintained in place by means of an elastic spring placed in the nostril, the tension of which is regulated by means of a screw on the outside, as shown in Fig. 644.

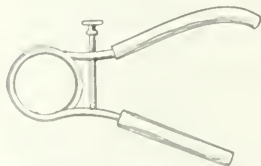


FIG. 644.—The author's intra-nasal spring.

Before the spring is inserted the interior of the nostril is carefully irrigated with an antiseptic solution and dusted with iodoform or some other strong antiseptic powder.

After the bones have been put into place a portion of iodoform-gauze is made into a roll that will just fit the upper portion of the nasal cavity, and

forced up into the vault sufficiently to hold the fragments in place in perfect coaptation with the external metallic mould that is placed on the outside of the nose. (In many cases, however, it is better to insert the internal support before the metallic form is applied.) Under this gauze is placed the upper arm of the spring, the lower arm resting on the floor of the nose. The spring should be made of the proper size and shape to fit the interior of the nose; while the tension exerted is regulated by a screw at the lower end of the spring. The pressure in these cases should be just sufficient to support the part without causing pain. The lower arm of the spring is covered with rubber tubing, to prevent irritation of the soft parts. By this method the lower respiratory passage remains unobstructed, so that nasal respiration is not materially interfered with. The interior of the nose also can be kept clean by frequent cleansing with an antiseptic wash, until the fragments are united and the nose is self-supporting.

In those cases in which the fractured bones are allowed to go unreplaced until firm union has taken place, re-fracture of the bones becomes necessary in order to restore them to their normal position. This operation will be described under deformities of the nose.

**Fracture of the Cartilages of the Nose.**—The lower portion of the nose is composed of two lower lateral shield-cartilages, united in the center. These shield-cartilages are connected with the nasal bones above by two upper lateral cartilages, which maintain the contour of the central portion of the dorsum of the nose, as shown in Fig. 645. In cases of moderate

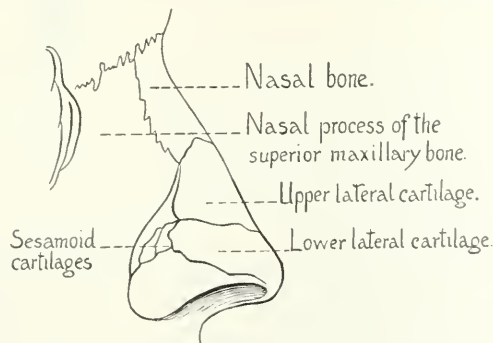


FIG. 645.—Profile view of the bony and cartilaginous constituents of the nose.

injuries to the nose these cartilages are rarely fractured; but when the injury is severe, particularly if inflicted by a more or less sharp body like the sharp edge of a board, fracture of the cartilages sometimes takes place. This is especially true of the upper lateral cartilages, which maintain the contour of the dorsum of the nose. Fracture of the shield-cartilage is readily detected by the resulting deformity and by the crepitation which can be elicited by careful manipulation; but fracture of the upper lateral cartilages is frequently so obscured by the attending swelling and inflammation that it is undetected, and only manifested by the resulting depression and deformity of the nose that follow after the inflammatory symptoms have subsided.

**Treatment.**—In many cases of fracture of the shield-cartilages the fragments are best held in place by means of the spring above described. When the fracture is in such a position that this cannot be readily maintained in place, a strip of vulcanite or celluloid can be moulded with heat and made to fit the nostril so as to maintain it in its normal position until the fragments



are united. Perforated cork-splints are also especially serviceable on account of their lightness and the readiness with which they can be fitted to the contour of the nostril. When these are not at hand the nostrils can be packed with antiseptic gauze, so as to maintain them in their proper form. It is advisable, however, to insert through the center an open tube for respiration (see Figs. 573, 574).

**Fractures of the Nasal Septum.**—The nasal septum being composed of three pieces, as shown in Fig. 646, and as each one of these pieces may be fractured independently, we therefore can divide fractures of the septum into three groups: as the fracture of the triangular cartilage, of the vomer, and of the perpendicular plate of the ethmoid.

The portion most frequently fractured is that of the triangular cartilage; it is always the result of traumatism. Fracture of the cartilage alone may

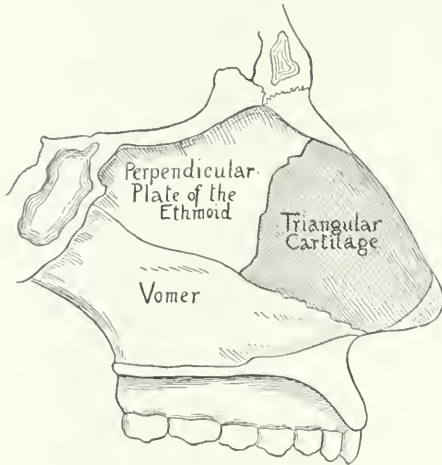


FIG. 646.—Bones and cartilage of nasal septum.

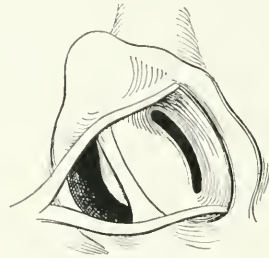


FIG. 647.—Dislocation of the triangular cartilage.

take place as an independent lesion or it may be associated with dislocation of the cartilage at its attachment with the vomer, as shown in Fig. 647. Fractures of the cartilage are also frequently associated with hematoma, which is bilateral; the bloody tumor filling both nostrils, communicating through the fissure in the septum. Separation of the cartilage may take place from displacement of the fragments, although they will more frequently be found overriding each other. The diagnosis of this accident is important, as the integrity of the nose depends on its recognition and proper treatment. When there is no displacement it can be recognized only by the attendant pain, the greater mobility of the structures associated with swelling of the soft parts, and the fissure can be found by exploration with a probe. The crepitus can be found by careful manipulation of the parts. Displacement of the fragments is manifested by depression of the end of the nose, which is distorted to one side, producing a double deformity. Sometimes the end of the nose is flattened on the face. When the fracture is compound it is accompanied by more or less epistaxis, and sometimes by subcutaneous emphysema.

Fracture of the vomer alone is a rare accident, and from its situation and position displacement of the fragments does not readily take place; the line of the fracture can, however, be detected by a careful exploration with a blunt-pointed probe, and on inspecting the nostril with the aid of a strong light it can sometimes be recognized by a hemorrhage-point.

Fracture of the perpendicular plate of the ethmoid is usually accompanied by comminuted fractures of the bones of the nose, although sub-

stances penetrating the nasal cavity have been known to fracture this bone alone. The cribriform plate may also be fractured and the foreign body at the same time enter the cranial cavity, the latter being always a very serious accident. When the fracture of the perpendicular plate exists alone it is usually at a point on a level with the vomer.

**Treatment.**—When there is displacement of the parts, they should be first put in place by means of a pair of forceps with flat parallel blades, one blade being inserted into each nostril, and by gentle pressure the bones can then be restored to their normal position, aided by gentle manipulations. When there is displacement of the fragments to one side it is frequently necessary to insert an internal support only on that side; and when there is laceration of the mucous membrane also on that side of the septum, the best form of support is made by winding sublimate cotton around a metallic plate from  $1\frac{1}{2}$  to 2 inches in length and of sufficient size to be inserted in the nostril, the nostril being first, however, irrigated with bichlorid solution, 1 : 5000, and dusted with iodoform. Other forms of support are frequently used for this purpose, as tubes made of hard rubber, of soft rubber, of cork, or of metal, each of which is excellent in cases to which it is adapted; but in cases where it is necessary to maintain the support only on one side, leaving the other nostril free for respiration, the cotton plug, having a metallic core to stiffen it for insertion, is preferable to all others. In cases in which it is necessary to maintain support on both sides a cotton plug can frequently be inserted in one nostril and a tube in the other.

#### DISLOCATIONS OF THE BONES AND CARTILAGES OF THE NOSE.

**Dislocation of the nasal bones** is an accident of comparatively infrequent occurrence, and always occurs as the result of blows against the nose, usually from a lateral direction. According to Marehant, dislocation of the nasal bones was recognized by Heister in 1770 and by Bell in 1796; but the first published example was by Bourguet in 1851, and later by Longuet in 1881. In Bourguet's case, a man, twenty-two years of age, was thrown against a sidewalk, striking on the left side of the nose. The upper third of the nose was deviated to the right, the lower end remaining normal. The elevation, which was a dislocation of the nasal bones, was reduced by introducing the ring-finger of the right hand into the nostril and exerting pressure on the outside, when the bone slipped into place and the dislocation did not recur. No deformity of the nose resulted.

A similar case recently came under my observation. A young lady, twenty-two years of age, was thrown from her carriage, striking on the right side of her face, injuring the nose quite severely. There was considerable swelling of the nose, but no crepitation and no fracture of the bones of the nose could be detected. The patient was very ill for a short time as a result of the accident, and it was feared that concussion of the brain had taken place. On her recovery, both nasal bones were found dislocated to the left and the nose was quite crooked; the right nasal bone was depressed, while the left nasal bone was thrown outward and upward, overriding the right, as shown in Fig. 640, forming a lump on that side. As the accident occurred four years before I saw her the deformity was permanent, but was corrected by me according to the methods that will be described in the section relating to deformities of the nose.

In another case, a little girl about five years old, while coasting, was thrown from her sled, striking her nose against the edge of an iron railing.

which drove the central portion of the nasal bones backward, dislocating them outward and leaving the nose in a flattened condition. Before surgical aid was secured the swelling of the nose so masked the injury that it was allowed to go uncared for. This resulted in a permanent flattening of the central portion of the nose and a bulging outward of the nasal bones.

Dislocation of the bones of the nose can readily be detected, *first*, by the deformity of the nose, and *secondly*, by the elevation of the dislocated edges, which can be felt as a ridge under the finger. The amount of dislocation varies usually with the amount of force exerted against the nose. There may be simple dislocation of one of the nasal bones, or all the various bones of the nose may be more or less dislocated to one side. In these cases the dislocation to one side is usually associated with fracture of the other, as shown in Fig. 640, against which the impinging force came. In some instances the cribriform plate of the ethmoid is fractured, and may be driven upward into the base of the brain.

**Treatment.**—The reduction of dislocations of the nasal bone is most easily accomplished by placing a smooth sound in the interior of the nose, and by gentle manipulation with the finger on the outside the bone can ordinarily be slipped into place. In some cases, especially if the nostril is large, the little finger can be passed into the nasal chamber and the depressed bones elevated, as in case of fracture of the nose. In this manner, with the thumb or finger on the outside of the nose, the dislocation can be reduced with great precision, as we are enabled by the sense of touch to detect the exact position of the bones. Usually there is no tendency for the dislocation to recur, owing to the lack of muscular tension on the part; but it is far better to apply a retentive apparatus to guard against such a possibility. This is best done by covering the whole of the nose with a piece of adhesive plaster, cut to fit, and by placing on the outside an aluminum form of the proper size and shape for the requirements of the nose, according to the plan described for the retention of fractured nasal bones. This is to be worn a short time, until the inflammation and swelling have subsided and the bones are firmly fixed in position.

**Dislocations of the cartilages of the nose** may be divided into dislocation of the external cartilages of the nose and dislocation of the internal or triangular cartilage forming the anterior portion of the septum.



FIG. 648.—Depression in the dorsum of the nose from dislocation of the upper lateral cartilage.

(a) *Dislocation of the external cartilages* of the nose usually takes place from blows inflicted on the dorsum of the nose. Owing to their elasticity and firm attachment the shield-cartilages are rarely dislocated, but the upper lateral cartilages filling the dorsum of the nose are more subject to injuries and more frequently dislocated. Owing to the smallness of these cartilages and the swelling which masks the injury the dislocation frequently passes unnoticed until it is recognized by the depression of the dorsum of the nose, after recovery from the depression of the dorsum of the nose, as shown in Fig. 648. This accident can be recognized and properly treated only directly after its occurrence and before swelling of the soft parts takes place, when the depression and the lack of support of the dorsum of the nose can be readily detected.

The cartilage can then be forced into place and held there by gauze packed into the interior of the nose at this point, supported by the spring



described on page 1122, Fig. 644, together with adhesive plaster applied to the exterior of the nose.

(b) *Dislocation of the triangular cartilage* of the septum is of frequent occurrence. It takes place most often in children as the result of a fall upon the nose. In older persons it may result from a fall, blows upon the nose, or various accidents. The dislocation most frequently found is that at the juncture of the triangular cartilage with the perpendicular plate of the ethmoid. It consists in the sliding backward of the cartilage to the side of the bone, giving the septum the appearance of being deflected to that side, as shown in Fig. 647. Since the posterior portion of the cartilage is thrown to one side, the anterior portion is naturally turned in the opposite direction, so that both nostrils are obstructed. There is often also dislocation of the lower border of the cartilage at its junction with the vomer, and also of the vomer at its juncture with the superior maxilla, projecting into the meatus on the side on which the dislocation takes place. This condition is readily detected by anterior rhinoscopic examination, and should be differentiated from cecchondrosis and other pathological conditions which frequently obstruct the nostrils. It is also readily seen that the convexity on one side is proportionate to the concavity on the opposite side. The perpendicular plate of the ethmoid is very often deflected to one side, together with the triangular cartilage; but its dislocation alone can only result from great external violence or from foreign bodies penetrating the nasal chamber.

**Treatment.**—This dislocation, if recent, can easily be put into place with the fingers, one finger being inserted in each nostril and the parts held there by a tampon placed in the nostril into which the dislocation took place. In other cases the dislocation may be reduced by the use of a smooth-bladed dressing-foreeps, or the blades of an ordinary foreeps covered with adhesive plaster to prevent wounding the soft parts. When the dislocation has become firmly fixed it can only be reduced by loosening the cartilage along its lower and posterior border. The parts are then forcibly put into position, and held there by a retentive apparatus. The success of the operation depends entirely upon the thoroughness with which the cartilage is loosened from its attachments, thereby preventing the tendency to return to its former position. In some cases it may be expedient to dissect out any redundant cartilage through a small incision made in the overlying tissue, reuniting the edges with fine sutures.

#### FOREIGN BODIES IN THE AIR-PASSAGES AND ESOPHAGUS.

**Foreign Bodies in the Nose.**—Foreign bodies found in the nose may be either animate or inanimate. They may be introduced from without or formed within the nose, as in the case of calcareous concretions termed rhinoliths.

*Animate foreign bodies*, such as leeches, flies, worms, etc., sometimes find their way into the nasal cavity; and other living creatures, such as maggots, may develop from the ova of flies deposited there; this more frequently occurs in tropical countries.

*Inanimate foreign bodies* may enter through the anterior nares, through the posterior nares, or through the walls of the nose.

Those that enter the anterior nares are chiefly such substances as beads, peas, stones, buttons, fruit-stones, pieces of wood, coins, and, in fact, nearly every substance that it is possible to crowd into the nostrils may sometimes



be found there. They are, however, usually introduced intentionally by mischievous children, lunatics, or hysterical women.

Substances that enter through the posterior nares are generally such as teeth, rings, fruit-stones, pieces of bone, etc., which have previously been swallowed and afterward expelled from the stomach and thrown forcibly into the nares during emesis. Substances, such as pieces of cotton and portions of sponges left after plugging the posterior nares, are sometimes found there acting as foreign bodies.

Foreign bodies that enter through the wall of the nose are usually spent bullets, fragments of stone from blasting, or of iron from the bursting of guns. Splinters of wood forced through the walls of the nose have been extracted from the nasal cavity.

**Symptoms.**—There is usually a more or less profuse sero-mucous discharge from the nose, or if ulceration has taken place the discharge becomes muco-purulent and bloody, and is more or less fetid. There is also more or less obstruction, according to the size of the body, and a swollen condition of the mucous membrane, sometimes attended by frequent attacks of sneezing and neuralgic pains of the face. In the case of peas, beans, etc., much pressure may be caused by the swelling of the body, and sometimes germination takes place.

Living bodies, such as maggots, termed in India "peenash," cause intense pain in the nose and frontal region, of a throbbing character, attended by a sensation of formication. There is swelling and edema of the face, eyelids, and palate, and epistaxis is usually present. Abscesses may form in the nose and destruction of bone may take place, leading to meningitis.

The **diagnosis** of foreign bodies in the nose is usually not difficult. If there is no history of the accident, which at best is unreliable, the occurrence of a unilateral fetid discharge from the nose should lead us to suspect the presence of a foreign body, especially in children. In adults it must be differentiated from syphilis and from disease of an accessory sinus, from which the discharge is almost always unilateral, and from sarcoma or carcinoma. If it is large and located in the anterior portion of the nose, a foreign body may be suspected by a bulging of the ala.

The question can ordinarily be very easily decided with the probe. In children a few whiffs of chloroform are advisable to quiet their fears; but in adults the use of cocain is all that is necessary, both for diagnosis and extraction.

The **treatment** of foreign bodies in the nose consists simply in their removal, although, as Mackenzie observes, there is no occasion for undue haste. Before this is attempted, therefore, their nature, situation, size, and fixedness should be determined.

Animate foreign bodies, such as insects and maggots, are best removed with chloroform. In fact, chloroform is the only effectual remedy. It should be diluted one-half with water, on account of the pain caused in using it full strength. It is then agitated and injected at once before the water and chloroform separate. This was discovered by Danzat, an apothecary's assistant in Mexico, in the year 1805. The vapor alone will sometimes cause a discharge of the maggots. If necessary to use it full strength, the dilution being ineffectual, general anesthesia should previously be produced with the vapor, as suggested by Mackenzie, to prevent the intense suffering.

Inanimate foreign bodies when lying somewhat loosely in the cavity are readily extracted with a pair of mouse-toothed forceps; but when more or less embedded in the tissues they should be carefully raised from their bed

by a suitably curved probe. Sometimes the use of sternutatories, a forcible blowing of the nose, or the use of Politzer's bag in the opposite nostril will cause the foreign body to be expelled. In some cases the method of Sajous will succeed where others have failed, which is by drawing a cotton or wool tampon through the nasal passage from behind.

When a foreign body is impacted in the nose it may be necessary to break it up by means of strong forceps, or by sawing it in two, or by drilling it.

When a foreign body is lodged in the posterior nares it can generally be forced down into the pharynx with a sound introduced through the nose, care being taken that it is not inhaled into the larynx or trachea, or swallowed.

**Rhinoliths, or Nasal Calculi.**—These consist in the deposition of the salts of the secretions of the nasal passages forming more or less solid bodies, usually having for their nucleus some foreign substance which has been introduced from without. Occasionally they form around some inspissated secretion, favored by a gouty diathesis. They enlarge slowly by accretion of the earthy salts to the surface, being composed mainly of phosphate of lime and magnesia, or chlorid of sodium, carbonate of lime, magnesium and sodium. They may attain considerable proportions, completely filling the nares, sometimes distending it like a foreign growth. From one patient I removed a rhinolith weighing 40 grains, having for its nucleus a small pledget of cotton. They are usually single, though in some cases there may be two or more. They are almost invariably unilateral. Their slowness of growth and the absence of history of the introduction of a foreign substance may cause them to remain undetected for a considerable period, the discharge, as in the case I have mentioned above, being regarded simply as catarrhal. The condition with which they might most easily be confounded is necrosis of the bones of the nose as a result of syphilis.

Their attending symptoms, diagnosis, and treatment are practically the same as that of an inorganic foreign body in the nose, with which they are to be classed.

**Foreign Bodies in the Larynx and Trachea.**—Foreign bodies entering the air-passages may be either fluid or solid. Fluid foreign bodies comprise articles of liquid food and drink, pus from a ruptured tonsillar, retropharyngeal, or aryteno-epiglottic abscess, blood entering during surgical operations or after an injury, and chyme or other vomited matter.

Solid foreign bodies comprise almost every conceivable substance that can possibly enter or pass through the larynx, and include both animate and inanimate bodies.

Among the most curious and interesting cases of animate bodies may be mentioned fish, held in the teeth during extraction of the hook, leeches entering while drinking water from pools or brooks, lumbricoids transferred from other parts of the body, flies inhaled while riding through them, and the epiglottis of a young woman which became impacted in the larynx while eating. The inanimate bodies that most frequently enter the air-passages are fruit-stones, pebbles, grains of corn, beans, coins, buttons, and the like.

The mode of entrance of foreign bodies may be either through the mouth, through the neck or chest-walls by fistulous openings, or from other portions of the body.

The entrance of substances into the air-passages through the mouth generally occurs during mastication and deglutition, while the person is laughing

or talking, or during sleep. Many cases of sudden death are reported where large pieces of meat or other substances have entered the larynx while eating, and caused immediate death from strangulation. Substances held in the

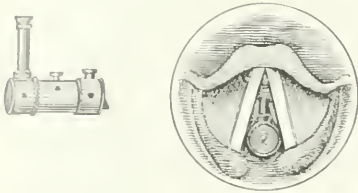


FIG. 649.—Toy locomotive in the larynx (Johnston).

mouths. One of the most interesting cases of this kind is reported by Johnston, where a toy locomotive was inhaled into the larynx of a child during sleep, requiring thyrotomy for its extraction (Fig. 649).

In adults one of the most frequent substances to enter the larynx is a tooth-plate which has not been removed before retiring. Schwetter reports a case where the patient was not aware of the accident until he missed his teeth in the morning. Corks held between the teeth during the administration of anesthetics, and sponges used about the mouth during operations, have been drawn into the larynx.

Substances entering through the neck or chest-walls are most frequently flying fragments from explosions, bullets, and other projectiles; and portions of ill-constructed tracheotomy-tubes, not properly cared for and allowed to corrode, may become detached and fall into the trachea.

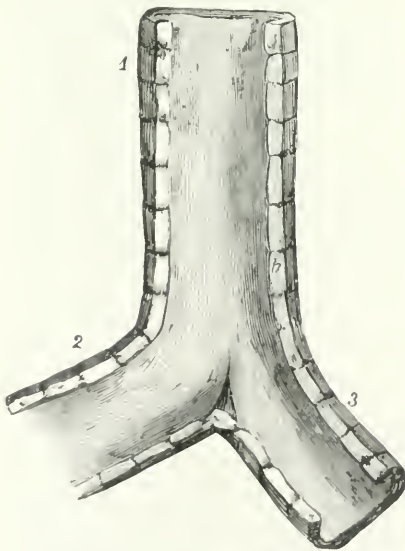


FIG. 650.—Bronchial septum; trachea and bronchial tubes laid open in front: 1, trachea; 2, right bronchial tube; 3, left bronchial tube; 4, bronchial septum, somewhat magnified to render it more conspicuous (Gross).

mouth are sometimes suddenly drawn into the larynx while laughing or during a fright, or during any condition which causes a sudden inspiration. Such substances as blown-gum darts, whistles, and the like are sometimes drawn into the larynx while the person is amusing himself with these substances. In some instances the substance becomes lodged in the pharynx during sleep. This occurs most often in children who go to sleep with toys, coins, buttons, etc., in their

Substances lodged in the esophagus may ulcerate through into the trachea or pass into it through fistulous openings. Bronchial glands have also ulcerated through into the trachea and acted as foreign bodies.

The location and position of a foreign body depends much upon its size and shape. Sharp, penetrating objects are frequently found sticking in the supraglottic portion of the larynx. Large alimentary substances or angular bodies are usually found in the larynx. Flat bodies, such as coins and buttons, are usually found in the ventricles of the larynx; while small, round, and heavy bodies commonly descend into the trachea. Small bodies that enter the bronchi usually enter the right one, since the bronchial septum is on the left side of the median line, as first

pointed out by Goodell of Dublin, as shown in Fig. 650. Of 98 cases collected by the writer, 58 were found to be in the right bronchus and 36 in the left. Of 156 cases, Bourdillet found that the foreign body was arrested in

the larynx 35, in the trachea 80, in the right bronchus 28, and in the left bronchus 15 times.

Substances lodged in the trachea change their position more often than those in the larynx. Sometimes they play up and down, as in the case reported by Glasgow, where a toy balloon, which had entered the trachea, moved up and down with each inspiration. Physical changes also take place in the foreign body. Mineral substances usually become more or less corroded. Corks, beans, grains of corn, and other dry substances absorb moisture and swell sometimes to double their original size, and in some instances seeds have been known to germinate in the air-passages.

The symptoms of foreign bodies in the larynx vary from complete and instantaneous suffocation, as in the case of an impaction of a mass of meat, to an almost complete absence of manifestations, as in the case of small or smooth, non-irritating substances.

The usual symptoms attending the lodgement of foreign bodies in the larynx are those of sudden choking, cough, and efforts at dislodging the substances. When the breathing is materially interfered with the patient often becomes excited and alarmed, and makes frantic efforts to obtain air. He grasps his throat, his eyes protrude, and his face becomes livid from the lack of oxygenation of the air.

Frequently these symptoms are occasioned only by the spasm of the larynx excited by the presence of the foreign body, and soon subside. In cases, however, due to mechanical obstruction, these symptoms continue until death ensues.

Small, sharp bodies, such as fish-bones, pins, needles, and the like, which usually penetrate the upper portion of the larynx, excite more or less cough and cause much discomfort on swallowing.

Substances lodged in the larynx, but lying in such a position as not to obstruct respiration, are attended with more or less hoarseness and coughing, as in the case of coins, and in some instances tooth-plates. These cause active symptoms only after congestion or inflammation has taken place.

Smooth, round bodies cause little irritation; while sharp or angular bodies cause inflammatory symptoms.

Foreign bodies finding their way into the trachea are usually manifested by a cough, dyspnea, and efforts at expulsion. If the dyspnea is continuous, it indicates that the foreign body has become impacted in the trachea or a bronchus; if intermittent, that it is movable in the trachea; if there is collapse of one lung, that it occupies one of the bronchi; or if there is interlobular emphysema of the lung, that there is laceration of some portion of the air-passages. Pain is almost always present, and may clearly indicate the location of the foreign body.

Sometimes the presence of the foreign body is manifested by frequent hemorrhages, emaciation, and all of the symptoms of phthisis, which cease on the expulsion or removal of the foreign body.

When a foreign body has been retained for a length of time, there is usually more or less fetor of the breath from decomposition of the foreign body or of the retained secretions. Frequently disease of the bronchi or pulmonary structure intervenes, and sometimes pericardial, mediastinal, or hepatic abscesses have resulted from ulceration and the extension of the inflammation to the surrounding structures.

The diagnosis of the case is greatly facilitated by the history of the accident. When there is no history, as in a case where the foreign body has entered during a period of unconsciousness, as in an epileptic seizure or



sleep, reliance must be placed upon the physical examination. A laryngoscopic examination can be usually made. In the case of a "Punch-and-Judy" whistle lodged in the lower part of the trachea of a boy eight years old, it was readily discovered by the author by the aid of the laryngoscopic mirror. When a laryngoscopic examination cannot be made the larynx can be explored with the finger; and when in the trachea, auscultation will frequently reveal the presence and location of the body—if a whistle, by a whistling sound, and if movable, by a "flapping noise" or Zwinger's "chattering bruit." When the air is excluded from one lung by reason of an obstruction of a bronchus, if it is in the right bronchus the lower lobe will be affected; while if in the left bronchus the entrance of air to the whole lung will be obstructed.

When the nature and location of the foreign body cannot readily be determined the X-rays should be employed, for they may not only locate the substance, but also materially assist in its extraction by showing its form and position.

Dyspnea caused by a foreign body lodged in a bronchus is sometimes mistaken for a foreign body in the trachea; and in a case where death was almost instantaneous from the blocking of the larynx, the death might be attributed to epilepsy or apoplexy.

The prognosis of foreign bodies in the trachea is always more or less serious. When death does not take place from suffocation serious inflammatory disturbance may arise, or there may be a sudden change of position of the foreign body, either in the larynx or trachea, which at any time may cause a fatal result. Small, smooth, non-irritating bodies rarely produce serious results, and are almost always expelled spontaneously; whereas sharp, angular or pointed bodies, even though suffocation be not imminent, should be removed as soon as possible.

The general consensus of opinion of surgeons is that no foreign bodies should be allowed to remain any length of time in the air-passages without the operation of bronchotomy. On the other hand, Weiss, from a collection of 1000 cases, mostly those reported to him privately, concludes that when the trachea and bronchus contain a foreign body, the patient will be more liable to recover if trusted to spontaneous expulsion. The statistics on this point are not of special value, for many patients die from suffocation who would have been saved by an operation, and many die after the operation when the foreign body might have been expelled spontaneously with recovery.

Substances entering the air-passages are usually expelled through the opening by which they entered, although in many instances, like bullets, heads of grain, etc., they have entered through the chest or the esophagus and have been expelled through the trachea. In other instances substances like heads of grain have entered through the larynx and trachea and were expelled through abscesses of the chest-wall.

**Treatment.**—The first and most important indication is the removal of the foreign body; but the method of removal will depend largely upon its nature and location.

Expulsion through the natural passages is facilitated by the use of a little chloroform to allay the excitability of the patient and the irritability of the parts occasioned by the presence of the foreign body. Among the natural aids are the various expulsive efforts, such as sneezing, coughing, vomiting; and by inversion, aided by percussion and circussion of the chest. The use of the sternutatories and emetics, tickling the nose with a feather to promote

sneezing, and of the throat to produce vomiting, have been employed from the earliest times. But little reliance, however, can be placed upon these methods.

In the case of movable bodies, such as coins, bullets, and similar weighty substances, inversion of the body will sometimes cause the immediate expulsion of the substance. The danger with which some regard this method from the impaction of the substance in the larynx is largely imaginary, for no case is reported where death has resulted. Of several methods of inversion the best is that described by Padley of Swansea: The patient is directed to sit on the elevated end of a bench, with his knees flexed over the end. He then lies backward on the inclined plane thus formed, and the coin drops into the mouth. Danger of spasm or impaction in the larynx is avoided by the ability of the patient to at once assume the upright position. The patient should inspire deeply and avoid speaking. A blow or slap on the chest will sometimes aid in the expulsion of a coin.

In the case of animate bodies lodged in the larynx, such as leeches and the like, they are best dislodged by swallowing turpentine or chlorid of sodium.

In some cases the introduction of an O'Dwyer tube is temporarily necessary to prevent suffocation from impaction or spasm of the larynx.

*Extraction through the Natural Passages.*—This should be done with the guidance of the laryngeal mirror; when this is not possible the instrument

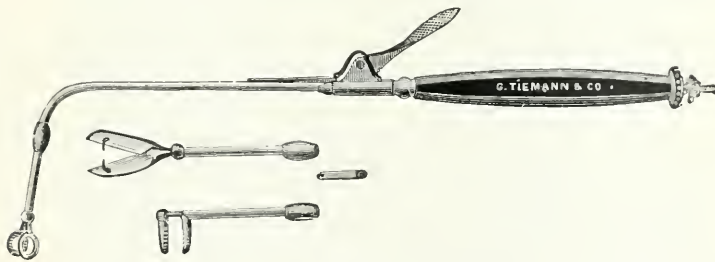


FIG. 651.—Mackenzie's tube-forceps.

can be guided with the index finger, as in the introduction of the O'Dwyer tube (see page 1030). When the foreign body occupies the supraglottic portion of the larynx, Cusco's lever blade-forceps or Mackenzie's angular forceps are

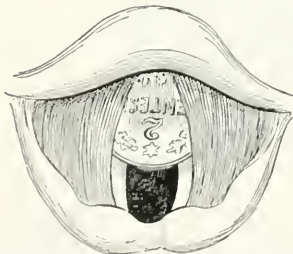


FIG. 652.—A coin in the laryngeal ventricle (Grazzi).

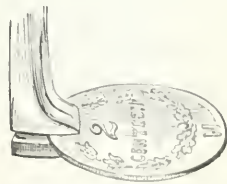

FIG. 653.—The same coin in the grasp of the instrument (Grazzi).

the most serviceable; but when in the subglottic portion of the larynx or in the trachea, Seiler's or Mackenzie's (Fig. 651) tube-forceps are the best. Mackenzie's tube-forceps with the blade having a lateral grasp are especially ser-

viable for the removal of coins impacted in the larynx. Fig. 652 represents the well-known case in which Grazzi removed from the larynx a two centesimi piece in this manner. Some rough or angular bodies lie between the vocal cords. It is not advisable to remove them through the larynx if there is danger of lacerating the larynx sufficiently to impair the voice permanently. Sometimes the removal can be accomplished only after the swelling has subsided under appropriate treatment.

When the foreign body is so located or impacted that it cannot be expelled or extracted through the natural passages, artificial openings must be resorted to. The various operations that are frequently called for are governed by the location of the foreign body; if in the larynx, thyrotomy or crico-thyroid laryngotomy, or if in the lower part of the larynx, laryngo-tracheotomy or tracheotomy; if in the trachea or bronchi, low tracheotomy.

When the trachea is opened the foreign body may be expelled either through the larynx or the tracheal opening, or it may be thrown up into the upper part of the trachea so as to be readily grasped with a pair of forceps. If the substance is in the larynx, it can now be more readily extracted, or it may be forced out of the larynx from below with a sound; or a piece of silk may be passed down from the mouth and a piece of sponge drawn up through the larynx from below.

Expulsion from the trachea is aided by turning on the face, inversion, succussion, and blowing into the trachea, or tickling it with a feather to excite cough.

The tracheal wound should be held widely open with suitable retractors such as Laborde's (Fig. 654), Golding-Bird's (Fig. 655), or Minor's retractor.

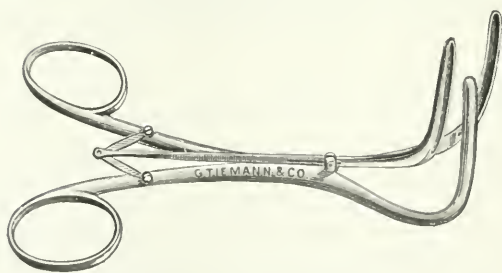


FIG. 654.—Laborde's dilator.

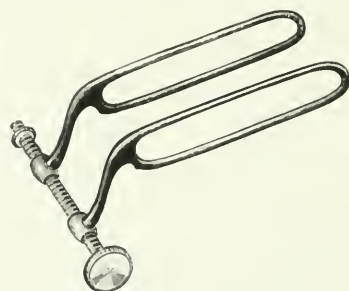


FIG. 655.—Golding-Bird's double retractor.

If the foreign body is not immediately expelled, Wythe's plan of stitching the edges of the tracheal wound to the integument is an excellent scheme

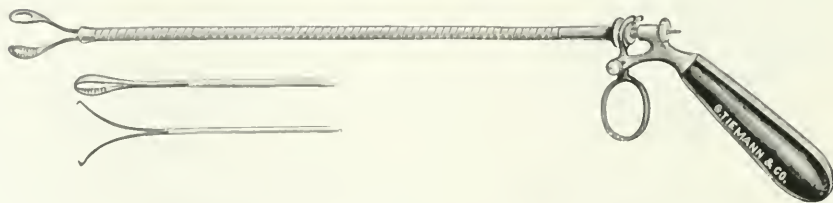


FIG. 656.—Roe's tracheal forceps, with flexible spiral tube.

to afford ready exit for the foreign body at any time. No tracheal cannula, of course, should be introduced. When the body is not expelled at once, it should be extracted by suitable instruments. Roe's tracheal forceps (Fig.

656). the stem being made of copper, so that it can be bent into any required position for reaching into a bronchus, is especially suitable. Gross's and Cohen's tracheal forceps are also serviceable instruments. Sometimes the position of the body can be ascertained by reflecting light, or tracheoscopy, and removed or dislodged with a hook made of a silver probe by bending up the end, and extracting with the aid of the finger.

Attempts at extraction should not be sufficiently prolonged to cause irritation of the part or exhaustion of the patient. We should rather wait for loosening and expulsion to take place. When this loosening does not take place and removal of the body must be effected, the operation of bronchotomy through the chest-walls, as suggested by Quénu and Figuera, or the plan of reaching the bronchi through an opening in the chest-wall from behind, by incising the third to sixth dorsal vertebrae, as proposed by Nesiloff, is to be considered.

**Foreign Bodies in the Pharynx and Esophagus.**—Foreign substances of almost every variety have been found in the pharynx and esoph-

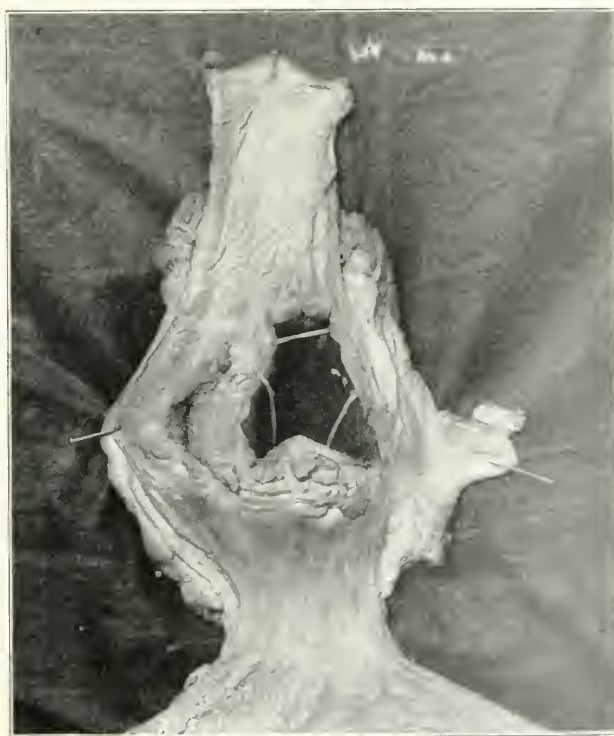

FIG. 657.—Tooth-plate lodged in a diverticulum in the esophagus for nearly two years. The patient insisted that the plate was in her esophagus, but exploration failed to detect it during life (silver).

agus. They may enter through the mouth or through the neck, as in the case of gunshot wounds, or the substance may be thrown up from the stomach and impacted in the esophagus.

Foreign bodies in the esophagus are usually arrested in the middle third where it is crossed by the left bronchus, or at the cardiac extremity, which is the narrowest portion of the tube.

Many pathological conditions favor the lodgement of foreign bodies in



the pharynx and esophagus, such as inflammatory affections, diseased conditions of the tongue, tonsils, pharynx, larynx, and esophagus, which interfere with deglutition and induce the sudden bolting of food in large quantities.

Substances carelessly placed in the mouth frequently become lodged in the throat, and during sleep tooth-plates and other substances often drop into the throat and become impacted in the esophagus; in some instances this takes place without the knowledge of the patient.

The **symptoms** attending the lodgement of foreign bodies in the pharynx and esophagus are usually dyspnea, laryngeal spasm, dysphagia, and pain in the region of the impaction.

Sometimes the dyspnea from the pressure of the foreign substance on the trachea is so great that it simulates the lodgement of a foreign body in the trachea or larynx. In nervous and excitable people the lodgement of such bodies in the throat or esophagus is sometimes purely imaginary, although all the symptoms of their presence are produced. In other instances foreign bodies have remained in the esophagus for years, entirely unsuspected, the disturbance caused by them being attributed to other causes. A pouch or diverticulum on one side of the esophagus will sometimes form for their lodgement, leaving the passage free, and sometimes they become encysted. Fig. 657 represents a tooth-plate lodged in a diverticulum in the esophagus for nearly two years. Its presence was suspected, but it could not be detected during life.

Sharp and slender substances, such as pins, needles, heads of grain, may pass through the walls of the esophagus, migrate to other parts, and emerge through an abscess. Foreign bodies, however, that remain for any length of time frequently produce the death of the patient or alarming conditions, such as edema of the larynx, abscesses, ulceration and stricture of the esophagus, perforation or rupture of the walls of the esophagus, penetration of the pericardium, the heart, the pleural cavity, larynx, and trachea, or caries of the vertebrae.

**Diagnosis.**—Foreign bodies lodged in the pharynx and upper part of the esophagus may be detected by inspection of the neck, if the substance is sufficiently large to give it a bulging appearance, by laryngoscopic examination, by palpation with the finger, and by exploration with sounds or by the X-rays.

In the lower part of the esophagus the foreign body can be detected with the sound and by auscultation of the esophagus over the back during deglutition, where a peculiar gurgling sound is heard at the location of the foreign body.

The esophagus can also be inspected by means of Mackenzie's esophagoscope, or it can be electrically illuminated by Mikulicz's esophagoscope. Duplay's resonator is especially serviceable for the detection of metallic substances. The sound, having a metallic tube, is attached to the hollow metallic cylinder, from which the sound is conducted to the ear. The striking of the metallic end of the bougie against the metallic substance is so magnified that the slightest touch can be detected.

**Treatment.**—Foreign bodies are removed from the pharynx and esophagus, first, through expulsion by natural means, as coughing, vomiting, and artificial digestion; second, by extraction by means of forceps, hooks, rings, and dilating probangs; third, by propulsion with the sponge-probang or by crushing the substance so that it will pass forward; fourth, by incision—by pharyngotomy or esophagotomy.

The employment of emetics is not only ill-advised but sometimes danger-

ous, owing to the liability of rupturing the esophagus or of lacerating it

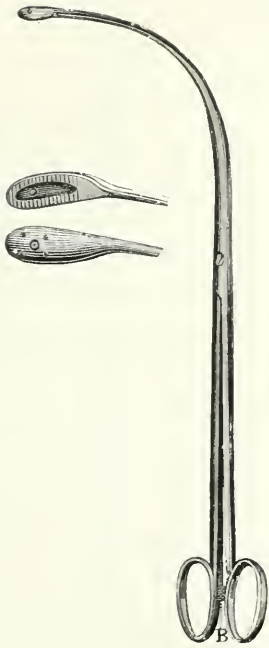


FIG. 658.—Fauvel's forceps, lateral grasp.

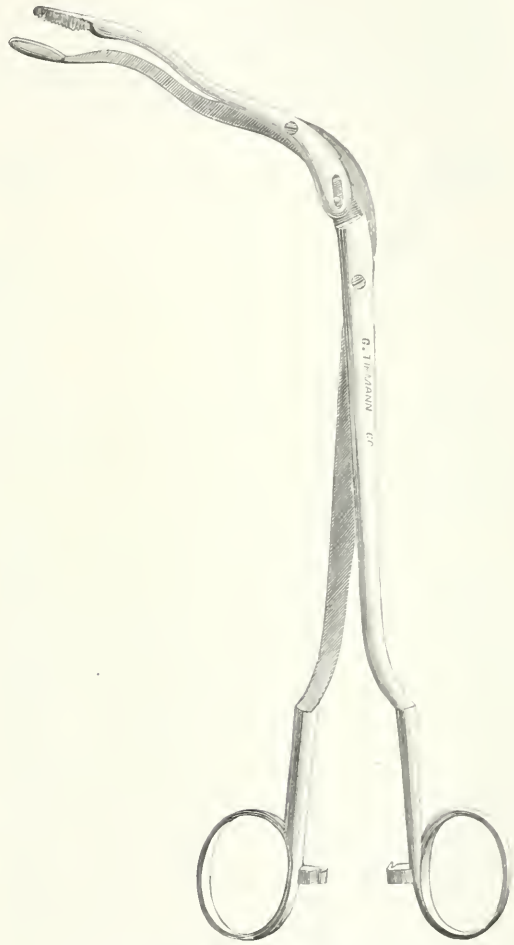


FIG. 659.—Fauvel's forceps, antero-posterior grasp.

during expulsion in case of sharp angular bodies. When small bodies are impacted it has been proposed that milk be ingested, and as soon as it has

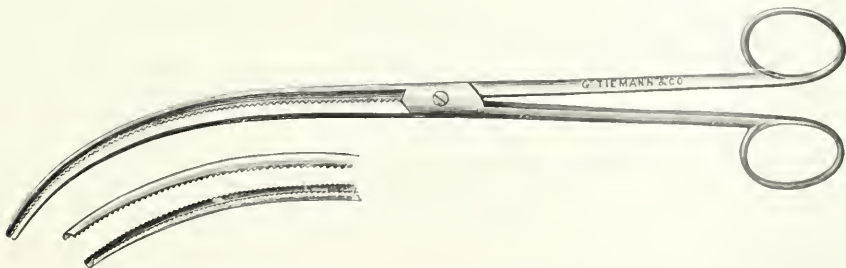


FIG. 660.—Bond's forceps (modified by author), with blades bevelled inward to avoid grasping mucous membrane, and to permit slender bodies readily to turn lengthwise.

had time to form a firm curd be ejected by the action of a prompt emetic, so

that it may sweep away the intruder. On the other hand, soft, bulky food, like oatmeal, may be swallowed in the endeavor to sweep on the foreign substance, and such food should always be freely given after tooth-plates and such bodies have entered the stomach.

For the removal of substances from the pharynx and upper part of the esophagus Fauvel's forceps (Fig. 658) and Bond's forceps (Fig. 660), as




FIG. 661.—Moe's gum-elastic forceps, with a tube so soft that it can follow the curves of the bronchi or esophagus.

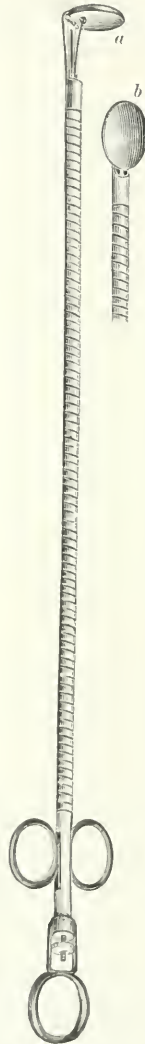


FIG. 662.—Roe's flexible spiral-lever extractor: *a*, lever opened after having been passed beyond the foreign body; *b*, closed during introduction or after the foreign body is grasped.

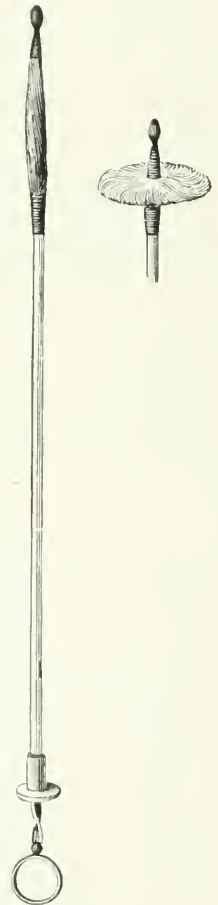


FIG. 663.—Gross's bristle probing, closed to pass the foreign body, and opened so as gently to sweep it upward in its withdrawal.

modified by the author, having a very narrow biting surface, are especially serviceable instruments. Moe's flexible-stem forceps (Fig. 661) are especially adapted for removing substances from the lower part of the esophagus.

Roe's flexible spiral-lever extractor (Fig. 662) and Graef's ring coin-

catcher are most useful for removing coins, metallic disks, and similar substances.

Gross's bristle umbrella probang (Fig. 663), inserted beyond the foreign body while closed and then expanded before withdrawal, is an excellent instrument for general use, and is adapted for the extraction of a variety of small substances, such as fish-bones, pins, and the like.

A great many different devices are often required for the removal of different substances, as Baud and Leroy devised passing drilled lead-balls over the string to dislodge fish-hooks and to protect the esophagus from the sharp ends during extraction.

In numerous instances similar ingenious devices have been resorted to for the extraction of different substances. In every case, however, great care should be taken not to irritate or lacerate or bruise the esophagus with the bite of the forceps or by the employment of too much force in extraction, lest serious inflammation be excited.

When a foreign body has become so firmly impacted in the pharynx or the upper part of the esophagus that it cannot be extracted *per vias naturales*, the operation of pharyngotomy or esophagotomy should be resorted to without delay. The rule laid down by Fisher is a safe one to follow—viz., in every case in which the foreign body cannot be removed within twenty-four hours after it has been impacted in the esophagus, external operations should be performed to obviate the danger of fatal internal complication.

**Injuries and deformities** of the pharynx and lower air-passages are not of frequent occurrence in forms that need special consideration here. Wounds, whether of cut-throat or other character, rather fall in the province of the general surgeon, except as inflicted by foreign bodies or laryngological surgery, when they concern the laryngologist largely as causes of severe and dangerous inflammation or edema. The latter condition sometimes ends fatally in the cachectic after the most trivial injuries, as in v. Ziemssen's case of a consumptive dying almost instantly after a prick of his ventricular band by a bit of inhaled tobacco-leaf. Scalds or other burns of the throat, most commonly from the swallowing of caustic substances, may also require a prompt opening of the air-passages in order to prevent suffocation, and prolonged antiphlogistic treatment to allay the inflammation excited, with ultimate operation to relieve the resulting stenosis.

Fracture of the larynx, generally of the exposed rostrum of the thyroid, as in cases reported by the author,<sup>1</sup> is occasionally seen, with not infrequently fatal result; while a cornu of the thyroid has at times been fractured by a blow or throttling pressure and dislocated inward, to be conspicuous in the supraglottic larynx-cavity.

Stenosis of the larynx from pachydermia, trauma, or syphilitic cicatrization may demand dilatation with the laryngeal catheter or such instruments as the author's forceps (see page 1209).

<sup>1</sup> *Ann. of Laryngol.*, April, 1881.



# NEUROSES OF THE UPPER AIR-PASSAGES.

BY JONATHAN WRIGHT, M. D.,

OF BROOKLYN, N. Y.

## SENSORY NEUROSES OF THE NOSE.

### DISTURBANCES OF OLFACTION.

**Anosmia.**—Absolute loss of smell from any cause is of rare occurrence. Great variation exists, both in normal and abnormal conditions of the nasal mucous membrane, in the intensity of olfactory impressions. Depending, as we must, almost exclusively upon the statements of the patients, their neurotic vagaries must always be taken into account in considering the etiology. Zwaardemaker and Schmidt<sup>1</sup> have divided the cases into the *respiratory* and the *essential*. By the *respiratory* we are to understand any condition which prevents the access of odor-laden air to the mucous membrane of the olfactory region. Such are, especially, nasal polypi, dryness of the mucous membrane and the formation of crusts upon it. Essential anosmia is due to actual lesions of the olfactory tract. There may be a chronic atrophic rhinitis or an acute inflammation of the olfactory mucous membrane, as in the case reported by Vergniaud.<sup>2</sup> The filaments given off from the olfactory bulb may be torn through by the jar of blows or falls on the occiput, as reported in several cases by Ogle, on whose paper,<sup>3</sup> in 1870, most of the literature is founded. There may be an actual olfactory neuritis, as in a case mentioned by Althaus.<sup>4</sup> Darwin, in his famous *Origin of Species*, drew attention to the fact that white sheep and pigs are poisoned by certain plants, while dark-colored ones are not. Ogle enlarges upon this fact, and quotes the case related by Hutchinson<sup>5</sup> of the negro who, on changing color by losing his dark pigment and becoming an albino, also lost his sense of smell. Ogle shows that it is highly probable that these phenomena depend upon the absence or loss of pigment in the olfactory mucous membrane. He states that the dark-skinned animals are enabled by their keen sense of smell to avoid the noxious plants; while the white animals, with pale Schneiderian membranes and feeble sense of smell, eat and are poisoned by them (see page 839). It is a fact easily observed that dogs, whose sense of smell is acute, have a deeply pigmented nasal mucosa. Syphilis of any part of the olfactory tract is said by Dana<sup>6</sup> to be the most frequent cause of essential anosmia. The last-named author also mentions several cases due to lesions of the olfactory bulbs and the cortical centers in the gyrus hippocampi and uncinatus. Cases are referred to by Mackenzie<sup>7</sup> in which

<sup>1</sup> *Die Krankheiten der Oberen Luftwege.*    <sup>2</sup> *Revue de Laryngologie*, etc., No. 17, Sept. 1, 1894.

<sup>3</sup> *Medico-Chirurg. Trans.*, 1870, liii. p. 263.

<sup>4</sup> *Lancet*, May 14 and 21, 1881.

<sup>5</sup> *Amer. Journ. of the Med. Sciences*, 1852, vol. xxiii. p. 146

<sup>6</sup> *N. Y. Med. Journ.*, Sept. 7, 1889.

<sup>7</sup> *Diseases of the Throat and Nose*, 1884.

there was congenital absence of the olfactory nerves and bulbs. Locomotor ataxia and cortical cerebral tumors and abscesses have been shown to be the causes of anosmia in some cases. In cases of paralysis it has generally been noted that the anosmia is unilateral and on the side of the lesion, there being no decussation of the olfactory tracts. We find various cases of anosmia reported as depending upon tobacco-poisoning (Parker), malaria (Raynaud)—when the anosmia was intermittent and cured by quinin—lead-poisoning (Grant), irritant substances, such as ether and snuff (Stricker), and astringent solution, such as alum (Wendt). Exceedingly foul smells (Althaus) or the prolonged smelling of any perfume, as in the case of the floum-tester mentioned by Wagner, may blunt the sense of smell, or the appreciation only of the accustomed odor. Anosmia may arise from reflex causes, such as elongation of the uvula (Lennox-Browne, Mackenzie), removal of the ovaries (Gottschalk), cauterization of the inferior turbinal bodies (Luc). Some doubtful cases are on record, ascribed to gout and rheumatism (Durrant, Mackenzie). In old age there may be a senile abatement of the acuteness or an entire loss of smell.

Notwithstanding this long array of causes, there is still another and perhaps a larger set of cases in which the most painstaking search fails to account for the anosmia. There are also many patients, who say they can smell nothing, in whom evidently the olfactory sense is unaffected or only slightly impaired.

Anosmia is frequently accompanied by loss of taste, but not always. Macdonald supposes that the posterior part of the olfactory tract is the region which governs the sense of taste. The essential qualities of taste, such as bitter and sweet, may be retained in anosmia, but the more delicate aroma of food is not appreciated. This is supposed to ascend through the nasopharynx to the olfactory region above the middle turbinated bone. Zwaardemaker has found that cocain powder mixed with starch and blown into the olfactory region will produce temporary anosmia. The latter author, in 1888, devised an instrument for measuring the olfactive powers of the nose, and called it an olfactometer (see Fig. 554). More recently<sup>1</sup> he has published a description of an improved, but more complicated, apparatus for the purpose. He recommends the use of valerianic acid in a solution 1 : 100,000, and various other unusual substances, among which he prefers vanillin 1 : 1000. For ordinary purposes the various essential oils, ether, vinegar, wood-alcohol, etc., in bottles, may be used to ascertain the olfactive condition of the patient.

The prognosis depends to a large extent upon the lesion, yet Mackenzie makes the statement that after anosmia has existed for two years we should hold out to the patient little hope of the restoration of the sense of smell. The principal exceptions to this rule are found in the respiratory cases of anosmia. Thus d'Agnanno restored the sense of smell in a case of anosmia from nasal polypi which had existed forty years; and White,<sup>2</sup> in two cases, one after twenty years and one after ten years, accomplished a cure. Occasionally the essential cases will recover; but, as a rule, it will be found that no treatment is efficacious, even the removal of the primary cause, because structural change has taken place in the olfactory tract itself.

**Treatment.**—Removal of the cause in the respiratory cases, the administration of quinin and strychnin in the neurotic, the discovery and correction of the cause in the reflex cases, are the indications for treatment. Some

<sup>1</sup> *Archiv f. Laryngologie*, Bd. iii., Heft ii., 1895.

<sup>2</sup> *Burnett's System of the Diseases of Ear, Nose, and Throat*, vol. ii. p. 94.

cases have recovered after the application of galvanism; and Mackenzie claims to have given relief in two cases by the insufflation of

|               |                                      |
|---------------|--------------------------------------|
| ℞. Strychnin, | gr. $\frac{1}{24}$ — $\frac{1}{2}$ ; |
| Starch,       | gr. ij —M.                           |

**Hyperosmia** seems common enough among highly neurotic women and men, but their complaints of certain odors would seem to be due more to their mental attitude and lack of self-control than to a really hyperesthetic state of the olfactory tract. It is occasionally noted in women at the time of menstruation. It differs from parosmia in being an exaggerated appreciation of one or more odors rather than a perversion of them.

Schmidt refers to some cases of morbid hyperosmia; while Scheel<sup>1</sup> speaks of a boy (James Mitchell) who, in the absence of his other senses, was able to recognize objects or individuals by their odor. The same is also related of Laura Bridgman.

**Parosmia**, or the perversion of smell, is said to be always either of cerebral or hysterical origin. It is, however, not uncommonly a more or less marked symptom of a bad coryza. This was especially noted during the late epidemic of the grippe. The odor of putrid flesh, fish, eggs, the smell of cooking meat, urine, petroleum, musk, burning hair, tar, pitch, phosphorus, garlic, or other indescribable and disgusting odors, are complained of. It is rather singular that in none of these cases has there been noted the occurrence of agreeable olfactory sensations. Mackenzie refers to cases in which the symptom was due to carcinoma of the frontal lobe of the brain, a glioma, gummata, or a fungous tumor of the cribriform plate. Althaus<sup>2</sup> relates a case in which parosmia was the beginning symptom of locomotor ataxia. There are many instances of it found among the insane, and it is occasionally reported in the aura of epilepsy. It is especially frequent in neurasthenia; and in women during pregnancy and at the menopause. A curious report by Sbreny states that, in a patient of his, cocaineization of the nasal mucous membrane repeatedly produced the sensation of a foul smell.

**Prognosis.**—In cases of cerebral origin the prognosis is bad, unless arising from a syphilitic lesion, where treatment may be of avail. In the insane and hysterical it depends on the general prognosis in the case. When dependent on local causes, as coryza, the prognosis is good.

**Treatment** depends on the etiology. Parosmia is a symptom.

The sense of smell has a more or less direct connection with the emotional life of man. Its connection with sexual excitement is a common phenomenon in animals. In the human race young women make use of artificial scents not only for their own gratification, but also to enhance their attractions for the other sex. Man being by nature the aggressive party, is less addicted to their use.

Goethe tells of Schiller keeping rotting apples in his writing desk, because in their atmosphere his poetic conceptions flowed more freely from his pen. In some individuals certain odors, or even the thought of them, produce headache, dizziness, faintness, or give rise to certain conditions. On the other hand, psychical influences may give rise to the subjective perception of odors.

“ And I swear, as I thought of her there, in that hour,  
And of how, after all, old things are best,  
That I smelt the smell of that jasmine flower  
Which she used to wear in her breast.

<sup>1</sup> *Krankheiten der Mundhöhle*, etc., f. 279.

<sup>2</sup> *Loc. cit.*

It smelt so faint, and it smelt so sweet,  
 It made me creep, and it made me cold;  
 Like the scent that steals from the crumbling sheet,  
 When a mummy is half unrolled."

#### DISTURBANCES OF SENSATION.

**Anesthesia; Hyperesthesia; Paresthesia.**—It is to be remembered that a small part of the anterior portion of the nasal chambers receives its sensory nerve-supply from the nasal branch of the ophthalmic division of the fifth or trigeminus nerve, and that the rest of the nose is supplied by the superior maxillary division, and the tongue and mouth by the inferior, with its gustatory branch; and that these three divisions unite at the Gasserian ganglion within the cranial cavity. It is probable that in many cases of cerebral hemorrhage, especially those in which there is facial anesthesia, the nasal mucous membrane, if examined, would be found anesthetic. The case mentioned by Althaus is the only one on record, so far as I know, where there was a peripheral paralysis of the fifth nerve. There were trophic changes in the mucous membrane of the eye, nose, and mouth; but the senses of smell and taste remained intact.

Hyperesthesia and hyperalgesia are so intimately connected with local lesions and reflex neuroses that they will be considered elsewhere.

Paresthesiæ of the nose may be the occasional symptoms of cerebral and nerve lesions; but hysteria here plays the most important part in the etiology. While it is not my plan to dwell long upon hysteria, I cannot refrain from giving the following account of a remarkable case which many American laryngologists will doubtless remember, as she has consulted a very large number of them.

The patient was a nervous woman of fifty, with a good family history. Fifteen years before she had received a blow with a parasol on the bridge of the nose: seven years ago she began to complain of nasal obstruction. Six years ago the menopause began. She has the appearance of a healthy woman, but she says that she suffers agony from frontal headache, pain within the nose, and nasal obstruction. Several years ago a surgeon removed a large piece from the nasal septum. From time to time since then several doctors, at her entreaty, have removed pieces. One rhinologist opened the frontal sinus and found it healthy. All these operations had given her only transient relief. She had other neurotic symptoms, upon which, however, she did not dwell. While giving me her history she drew from her pocket a bent-wire probe wound with cotton, and passing it dexterously into her nose, said she could feel that there was still something there, which she begged me to cut out. On inspection I found that the whole septum from the columna to the naso-pharynx had been removed, with the exception of a small ridge or blade of tissue along the floor of the nose. The middle turbinals met in the middle line, so that if there was any septum above them it could not be perceived. She assured me that this had been removed piecemeal by different doctors, and placing her probe upon the remaining stump, and moving it back and forth, she told me that if I did not take away that she would go to some one who would. I refused, and advised her to seek an alienist. She left my office in anger.

This may be said to be a case of "obsession" rather than of hysteria.

#### REFLEX NEUROSES OF THE NOSE.

I do not propose to enter into a discussion of the nature of a reflex neurosis further than to say that we commonly understand by it a process which consists of a nervous impulse starting at the peripheral termination of a sensitive nerve, carried through it to a sympathetic center, and from there carried back to its source or to a distant point, where it manifests itself in an excessive or disordered vaso-motor, sensory, or muscular activity. To account



for this disordered activity, we may suppose that the terminal nerve-filaments are diseased or subject to undue irritation by disease of their environment; or that there is disease of the nerve-trunks or their ganglia; or that there is a general excitability of the nervous organization of the individual. Pathology has as yet shed no new light on these possible sources of the trouble; and the clinical phenomena are so illusive that they have furnished only a multitude of bewildering hypotheses and theories. Since the rise of specialism in medicine, the devotee of each shrine has laid at the feet of his deity—the nose, the uterus, the stomach, the male urethra, or other isolated organs—as large a number of reflex neuroses as possible. It has therefore repeatedly happened that the same nervous phenomenon appears in many classifications; and the result has been bewildering and, to the candid observer, somewhat ridiculous.

Hay-fever, of late years, has been most frequently considered as belonging etiologically to the nose. Cases of epilepsy, melancholia, insomnia, neurasthenia, migraine, persistent hiccough, aprosexia, sneezing, and many other puzzling affections have appeared to some of the reporters to originate in the nose, chiefly because they have observed some ease coincident with nasal disease and abolished by treatment of it. But the same galaxy of phenomena has also been ascribed with equal right to other organs. Therefore logic teaches us that we are familiar only with the everchanging factor, and not with the central or constant one which we presume must exist.

**Hay-Fever.**—John N. Mackenzie,<sup>1</sup> in a historical study of the nasal reflexes, has shown that hay-fever and other nasal neuroses had been observed clinically from the earliest ages, but not classified in accordance with present knowledge and theories. At the beginning of this century, Heberden and Cullen had evidently observed the affection; but Bostock,<sup>2</sup> in 1819, was the first to describe it intelligently. Phoebus, Weyman, Beard, Blackley, Geddings, and others have made valuable contributions to the subject since then; but they devoted themselves to its clinical manifestations and its etiological dependence on extraneous influences rather than upon local nasal disease. Daly, in 1881, was the first to draw attention to the fact that a very large number of these patients had well-marked intranasal lesions. In this he was supported in this country by Roe,<sup>3</sup> Harrison Allen,<sup>4</sup> Sajous,<sup>5</sup> and abroad by Hack, Hertzog, and others. These gentlemen were disposed to look upon the general neurotic element as a minor factor or as a result of the local lesion. John N. Mackenzie,<sup>6</sup> in a remarkable series of articles, while giving local lesions their due consideration, has shown that the fundamental cause lies back of these in the abnormal excitability of the sympathetic nervous system. Bishop<sup>7</sup> has lately advanced the theory, with considerable force of argument, that hay-fever is due to the hyperacidity of the blood from the excess of uric acid; but it is too early yet to judge of the value of this suggestion.

Hay-fever is a term usually limited to manifestations of disturbance in the upper air-passages, which begin in May or June, and are then sometimes called "Rose-cold" or "June cold;" or it may begin shortly after the 1st of August and last until the advent of frost. The latter form is the one more commonly known as hay-fever, hay-asthma, rag-weed fever, autumnal catarrh, etc.

<sup>1</sup> *Trans. Am. Laryng. Assoc.*, 1887.      <sup>2</sup> *Medico-Chirurg. Trans.*, 1819, p. 161; 1828, p. 437.

<sup>3</sup> *V. Y. Med. Journ.*, May 12, 19, 1883; May 3, 10, 1884; *Trans. Am. Laryng. Assoc.*, 1884.

<sup>4</sup> *Am. Journ. Med. Sci.*, Jan., 1884.

<sup>5</sup> *Trans. Am. Laryng. Assoc.*, 1884.

<sup>6</sup> *Am. Journ. Med. Sci.*, April, 1884.

<sup>7</sup> *The Medical News*, Feb. 24, 1894.

**Symptoms.**—Its chief characteristics are those of a severe coryza in the early stages, which, instead of terminating in the third or resolving stage after ten days or two weeks, is indefinitely prolonged; or it may suddenly cease on an abrupt fall of temperature or the removal of the patient to another locality. Itching of the eyes and nose, alternating nasal obstruction, furious and long-continued fits of sneezing, lachrymation, photophobia, congestion of the conjunctivæ, frontal headache, more or less complete loss of taste and smell, an annoying cough, prostration and slight fever make these patients exceedingly uncomfortable, and for a considerable period render them unfit for any continuous occupation. Damp weather, east wind, dust, and the proximity of blooming vegetation increase the intensity of the symptoms. All degrees of severity are observed, from a very slight "cold in the head" to an illness which, for a part of the time, at least, may confine them to bed. The first of the periodical attacks is slight, and the severity increases with the recurring ones. The patients suffer much more in the morning hours than in the afternoon.

**Etiology.**—In this country the bloom of the rag-weed—*ambrosia artemisiæfolia*—is more often regarded by patients as the exciting cause of their attacks than any other plant; but the bloom of the cereals, dust, bright sunshine, and many other influences are used to explain the onset of the disease. The June cold or rose-cold, which presents the same clinical picture, but is certainly less frequent in this country than the autumnal form, has been supposed to be due to the pollen of the early flowers. It is probable that all floating particles of matter in the respired air have their effect upon the nasal mucous membranes of susceptible individuals. It occurs more frequently in the so-called temperate climates, being unusual in very warm or very cold regions. It is a very much more frequent occurrence in America and England than in other countries. Geddings, combining his cases with those of Weyman, says that it is more common in men than in women, in the proportion of 3 to 2. He gives the following table as to the age when the patients were first attacked:

|                    |           |
|--------------------|-----------|
| Under 10 . . . . . | 21 cases. |
| 10-20 . . . . .    | 28 "      |
| 20-30 . . . . .    | 38 "      |
| 30-40 . . . . .    | 19 "      |
| 40-50 . . . . .    | 16 "      |
| After 50 . . . . . | 3 "       |

In many cases heredity seems to play an important part, many members of the same family suffering from it. This is especially so in certain families of a neurotic type or distinguished by intellectual superiority.

The attack frequently comes on with great regularity as to the time of year. Sometimes the patient confidently expects it not only upon a certain day, but even at a certain time of day, although occasionally the attacks occur at any time of the year. Bosworth quotes Beard's statistics and his own, from which it appears that out of 278 cases beginning from May 1 to September 30, 186 cases began between August 10 and 31 inclusive, while the other cases were pretty evenly divided as to the date of beginning. The attacks in some of the cases run a shorter course, but the majority suffer until frost, and some seem never to be entirely free from the trouble. In Geddings's tables there is a marked preponderance among brainworkers—physicians, manufacturers, merchants, clergymen, and lawyers making up much more than half of the cases. It occurs much more frequently among neurotic people, although Roe denies this. A good many of Geddings's cases

are called "bilious." Most writers agree that the exciting extraneous cause seems most frequently to be the pollen of plants, since much the larger number of cases suffer only when the flowering plants shed their pollen, or in August and September, when the later grasses are in bloom. The experiments of Blackley and others point to the same conclusion; but it is also certain that other irritants in the respired air may act in the same way, since many of the cases suffer at irregular intervals throughout the year.

Notwithstanding many differences of opinion as to the relative importance of the factors in the etiology, those who have given the disease the most careful study agree that we must usually take into account:

1. Hyperexcitability of the sympathetic nervous system, which may or may not manifest itself by what we term a neurotic temperament.

2. Some local change in the nasal mucous membrane or its underlying cartilaginous and bony framework. This is most frequently found to consist of a real hyperplasia or a vascular dilatation of the erectile tissue or of an edematous (so-called polypoid) condition of the stroma, especially in the region of the middle turbinal. Combined with this, as pointed out by J. N. Mackenzie, we are able to find more or less localized areas of hyperesthesia in the posterior part of the nose. Spurs and deviations are more rarely a prominent local feature.

3. Some atmospheric condition (pollen, dust) which obtains principally either in the spring or the autumn.

Now, as a matter of fact, we not infrequently find cases in whom the neurosis of hay-fever is the only evidence of a neurotic temperament (Roe). We also often meet with cases that have no appreciable nasal lesion when not suffering from hay-fever (Mackenzie). Finally, as said above, many cases have the same manifestations at other seasons of the year or in localities where there is presumably neither dust nor pollen. The writer cannot escape the conviction that, in very many instances, but of course not in all, the local disease is the result, rather than the cause, of the neurosis. Excessive and long-continued vaso-motor disturbances lead to the demonstrable permanent damage of the fibro-muscular walls of the vessels and of the stroma of the erectile tissue of the nose. Low-grade inflammatory fibrous tissue takes the place of the elastic fibers of the normal stroma. It also encroaches upon, displaces, causes absorption of, and hinders the functional action of the smooth muscular tissue in the stroma and the walls of blood-vessels. Not only does it do this, but, as a consequence, the serous fluid thrown out from the vessels is finally, after repeated attacks, not absorbed, but remains as a permanent edematous infiltration of the stroma; and the cavernous spaces remain permanently dilated, owing to paresis of their walls, even after the vaso-motor storm has for the time passed away. This I have lately been able to observe in a young man who, after having had hay-fever for ten years to some extent, began to suffer more severely; and after the hay-fever season had passed this year, his nose remained more or less occluded. The mucous membrane of the whole nose was pale and edematous, in addition to the engorgement of the cavernous tissue, and reacted sluggishly to cocaine. By means of the snare, pieces were removed both from the inferior turbinal and from the region of the middle turbinal. Small polyp-buds, some as large as a pea, some as small as a pin's head, were seen in process of budding or protruding from the surface. Microscopically there was a difference in the specimens of tissue from the two regions. There were a large number of glands in the tissue from the inferior turbinals, which, except for their distension with serum, did not look materially altered from the normal; but

the stroma-fibers were evidently changing in character, and the smooth muscle-fibers, easily made out in the erectile regions when normal, were few and hard to find. In the middle turbinal region the structure was that usually found in the ordinary edematous polypus,<sup>1</sup> except that possibly the glands were not so much degenerated as usual. This and many other histological examinations simply tend to confirm the impression I have long received from cases clinically observed.

**Prognosis.**—Notwithstanding this, it is undeniably true that treatment directed to the local lesion, when it exists, results always in marked amelioration of the symptoms, and sometimes in a permanent cure. The cases with extensive nasal disease are the most favorable ones, for often when operated on they have apparently reached a stage when the neurosis is on a decline. Relieved of the peripheral irritation, perhaps originally brought about by the neurosis, nature so far overcomes the other etiological factors that the symptoms do not return at their next period. If the system becomes still further strengthened they may never recur; but after a few years many of these cases relapse. Another curious fact about these cases is that a shock to the nervous system, unconnected in any way with the treatment, may give temporary or lasting relief; as in the case mentioned by Dr. F. I. Knight, where a man, long a sufferer, broke his leg and the attacks ceased. He had also seen a case relieved by the mind cure. The case of Dr. J. N. Mackenzie has become famous, where an artificial rose produced a "rose-cold" in a sufferer from the affection, who, when disabused, was subsequently able to inhale the perfume of a real one.

**Treatment.**—From what has preceded, the indications for treatment seem pretty clear, although sometimes difficult to follow out. A careful inspection of the air-passages must be made, if possible, when the trouble is quiescent. All polypi, hypertrophies, spurs, and deviations in the nose must receive appropriate treatment, and all sensitive spots should be destroyed by the galvano-cautery. This should be done only by an experienced operator, and not by the tyro in rhinology, or innocent structure may be destroyed and annoying cicatrices and adhesions be left behind.

As for drugs, tonics of strychnin, quinin, and iron are indicated, and may be administered for weeks or months before the usual onset of the symptoms. Dr. Mackenzie's prescription is a pill—

|                     |                                       |
|---------------------|---------------------------------------|
| R. Zinci phosphid., | gr. $\frac{1}{16}$ ;                  |
| Quin. sulph.,       | gr. ij;                               |
| Ext. nucis vom.,    | gr. $\frac{1}{4}$ , before meals, and |
| Donovan's solution, | gtt. iij–v, after meals.              |

These patients must lead an out-door life, as free from mental strain as possible. Should all of these measures be found inefficacious, as often happens, there is nothing left for the patient but to seek refuge in stoic philosophy, or in distant localities, where experience teaches him that he is free from his trouble. This may be in the White Mountains of New Hampshire. "Of the various places mentioned within this territory, Bethlehem and Jefferson, Whitefield, White Mountain House, Fabian's Twin-Mountain House, Crawford House, Glen, Gorham, and Mount Washington may be regarded as entirely exempt" (Geddings).

Frequently immediate and entire relief is here experienced, and there is

<sup>1</sup> Wright, *N. Y. Med. Journ.*, Nov. 4, 1893. See p. 1076 in this work.



always great amelioration of the neurotic phenomena. The lake region of Maine, Lake Chautauqua in Western New York, Put-in-Bay on Lake Erie, Little Traverse Bay in Northern Michigan, Cresson in Pennsylvania, many parts of Canada, of California, and of Colorado are free from the disease, and give relief in many cases of hay-fever. Indeed, the seashore, the mountains—any change of locality—will relieve some patients; while nearly all are free from it during an ocean voyage.

**Spasmodic Asthma.**—Very shortly after the influence of the local nasal lesion was recognized and exaggerated in the etiology of hay-fever, interest was revived in a like causation of spasmodic asthma. To Voltolini is generally accredited the distinction of having in 1871 first drawn attention to the dependence of some cases of asthma upon nasal lesions, having cured a case by removing a polypus from the nose. This attracted a great deal of attention, and many papers were contributed to medical literature in confirmation of his observations; but the importance of nasal and pharyngeal disease as an etiological factor reached its climax in 1886, when Bosworth stated that in all the cases of asthma which he had seen there existed an intranasal lesion. In his book published in 1889 he repeated the statement. Out of 46 cases of asthma, 28 were cured and 12 improved by intranasal treatment, while only one was unimproved. He asserts that hay-fever or hay-asthma and perennial or bronchial asthma have the same etiology—*i. e.*, that the local exciting cause is always in the nose. He therefore calls the first vaso-motor rhinitis and the latter vaso-motor bronchitis. He subsequently reported 88 cases of asthma with intranasal lesion, of which 42 were cured (or nearly 52 per cent.), 33 improved, and 2 unimproved. This corresponds closely with the reports of Schmiegelow and Heyman. Bosworth's view of the etiology of asthma has been strongly combated by B. Robinson, Shurly, Ingals, J. N. Mackenzie, and others in the discussions which followed the reading of his papers. It is the belief of the writer that Dr. Bosworth has enunciated the proper theory in drawing close analogy between hay fever and asthma; but in saying that a local nasal lesion always enters into the chain of causes, he seems to have overshot the mark in each case. While the writer's experience is much less extended than Dr. Bosworth's, he certainly has seen cases in which no nasal lesion was present, and few cases of the trouble in which an entire and permanent cure resulted from intranasal operations on existing lesions. A rhinologist cannot from his own experience alone discuss this question intelligently, because the cases of asthma that seek him are those especially which have intranasal symptoms. We see this exemplified in the statement of Lublinski, who said that of 143 cases of asthma with nasal and pharyngeal lesions treated by operation, 27 (less than 20 per cent.) were cured and 13 improved. This experience was gained in a general medical clinic. Heyman, on the other hand, in a nose-and-throat clinic, saw 53 cases and cured 29 (more than 50 per cent.) and improved 14; 10 were unimproved. According to Schmiegelow's tables there were among 50 patients, 32 cured, 11 improved, and in 7 no result. Out of the 32 cases reported cured, there were recurrences in 17; and coincident with the return of the asthmatic attacks there was a recurrence of the nasal lesion. Schmiegelow says that the return of the asthma was caused by the recurrence of the nasal lesion. I have stated my reasons, in speaking of hay-fever, for believing that the neurosis is frequently the initial phenomenon, and the polyp or hypertrophy a secondary and resultant lesion. Schmiegelow's statistics show that his material was made up of 517 cases of chronic rhinitis, of which 40 had asthma (8 per cent.), and 139 cases of nasal polypi,

of which 31 had asthma (22 per cent.). These proportions certainly seem very high.

Brügelman distinguishes 5 kinds of asthma, according to their etiology: 1. Nasal asthma. 2. Intoxication-asthma (carbonic oxid). 3. Pharyngo-laryngeal asthma. 4. Bronchial asthma. 5. Neurasthenic asthma. Bollinger relates a case in which asthma apparently was caused by the presence of a rhinolith in the nasal chambers, and ceased after the expulsion of it. Roquer y Casadesus reports a case of asthma from an enlarged lingual tonsil cured by its abscission. Glasgow relates a curious instance in which a case of spasmodic asthma was cured by the accidental application of a 50 per cent. solution of carbolic acid to the larynx. From this and other experiences he believes that the larynx, as well as the nose and other organs, may be the starting-point of the reflex. We have already quoted the remark of Dr. F. I. Knight, that he had seen a case of hay-fever cured by the patient's breaking his leg. Cases have been brought forward to show the connection between various manifestations of neurosis of the skin, as urticaria, and circumscribed edema and asthma.

**Treatment.**—From this short review of the subject, whatever may be the reflex path from the nose to the bronchioles, whatever may be the proportion of the nasal reflex to other reflexes in the causation of asthma, it is clear that when lesions do exist in the upper air-passages, they should be thoroughly and carefully treated; but whether such lesions exist or not, the patient's other organs should be examined with care. Systemic dyscrasia, lithemia, gout, rheumatism, and the general neurotic tendencies must all be considered. The nose is only one wheel with many cogs in a complicated and mysterious mechanism.

An instance of the coincidence of marked naso-pharyngeal adenoids with severe asthmatic attacks which I treated several years ago, has taught me not to be too sure of the dependence of asthma on the nose for its origin. The patient was a young woman of considerable personal attractions, but with a most disagreeable "dead voice." She complained of violent attacks of asthma, somewhat dependent upon the climate and environment, and of constant nasal occlusion not dependent on either. The nose was narrow and the naso-pharyngeal vault filled with a mass of lymphoid tissue. I was cautious enough to make a guarded prognosis in regard to the asthma; but I was sure in my own mind that I would cure her of it. I removed the adenoids perfectly clean from the naso-pharynx, and incidentally had a copious secondary hemorrhage. She, of course, was greatly relieved of many symptoms, but not of her asthma; for, after a somewhat lengthy interval, it returned. I saw little chance of benefiting the nose, and refused further nasal treatment. She went for a long time to a very skillful colleague, who burned and cut the nasal mucous membrane. This was five years ago. Since then she has been married and has had a child, and although her general health has been fairly good, her asthma still troubles her at irregular intervals. A gynecologist has also tried his skill successfully on some sensitive spot, but she had a particularly bad time with the asthma last summer. Her nose is in as good a condition as possible.

To know the ultimate result of these nerve-shocking operations, one must compare the conditions of a long time before with those of a long time after them.

**Paroxysmal sneezing** may be claimed by the rhinologists as their reflex, since the physiological act usually receives its impulse from the nose. Sam Weller, it will be remembered, when asked by the footman if he took snuff, replied, "Not without sneezing"; but we must remember that bright sunshine, through the eyes, or erotic emotions, through the genital tract, may, in a physiological state, start the reflex. Lennox Browne reports a case of paroxysmal sneezing during pregnancy, beginning at the third month and lasting till term; while Herron reports a case from eye-strain. A case is

reported where manipulation of a diseased eye, preliminary to extirpation, caused violent sneezing in chloroform-anesthesia. The sneezing was only avoided by dropping cocaine in the eye.

Ringer and Morrell have gone over the literature of the subject and reported many cases; while Crickmay, Balfour-Graham, Hurley, Williams, and "F. R. C. S.," in a series of short notices, make various suggestions as to treatment.

Several years ago, a young woman applied at one of my clinics for relief from prolonged and frequently recurring attacks of sneezing. The middle turbinal on the left side was hypertrophied and pressed against the septum, and there was a large spur which occluded the nostril on the right side. As she complained of irritation in the left nostril, and palpation of the middle turbinal with the probe excited severe sneezing, the mucous membrane with some of the bony structure was removed. The operation was a rather severe one. She returned in about three months, saying that she had been entirely free of the trouble until the last few weeks, when it had begun again and was becoming as bad as ever. The spur was removed by trephine and saw from the other side. Both nostrils were now fairly free. The cautery was also used to reduce the vascularity of the inferior turbinal bodies. Another period of several months passed without any sneezing. It then began again and became worse than ever. She said that the paroxysms would sometimes last for an hour, and she would be so exhausted that she would have to take to her bed. She was apparently, but for her distressing trouble, in very fair general health. The paroxysms seemed to bear some relation to her catamenial periods, and I suggested that she should go to the gynecologist for an examination. She refused, and I did not see her again.

I remember a boy playmate, with congenital heart-trouble, it was said, who would be seized with uncontrollable fits of sneezing lasting many minutes. This would excite our hilarity to a high pitch. When his fit had left him he would join in the fun, and his paroxysm of laughing would also be prolonged and apparently uncontrollable. Another peculiarity about him was his liability to drop suddenly to sleep, even while standing. His mental capabilities were not limited, although rather below the average. Twenty years afterward I heard of him as alive and well; but I do not know whether his reflexes are still as active.

**Cough** has been repeatedly found dependent upon intranasal disease alone; although the usual extrapulmonary sites of the reflex (see page 709) are in the pharynx and larynx, set up by the various lesions of these regions.

**Glycosuria.**—Bayer<sup>1</sup> relates the history of a case in which nasal obstruction and post-nasal catarrh were accompanied by glycosuria, which disappeared on the relief of the intranasal condition.

Two years ago I operated on a boy of fifteen for an adhesion of the inferior turbinal to the bony septum throughout its entire length. The operations occupied three or four different sittings, with intervals of a week or ten days. He was previously in good health, except for the distress of nasal obstruction, which was increased by the presence of post-nasal adenoids. Large pieces of bone and mucous membrane and the lymphoid tissue from the naso-pharynx were removed. The boy bore the operations with great fortitude, and they were successfully and satisfactorily performed. For a month or six weeks he had to wear a gutta-percha plate in his nose to keep the bare bony surfaces apart. Before all the lymphoid tissue was removed from the pharynx he began to be languid and pale, and complained of frequent urination. Examination of the urine by his family physician, a distinguished and skilful man, revealed the presence of a small amount of sugar and that he was passing large amounts of urine daily. Local treatment was suspended, and he was put on tonics and sent to the country. After two or three weeks the sugar had disappeared; and after two or three months the urine came back to its normal amount and his general health was restored. I believe that here we had a glycosuria due to nervous depression from the shocks of repeated operations, which, while not very painful, were trying to the general nervous system.

**Salivation** is referred to by Bosworth as having been cured by intranasal treatment in two cases of elderly people. The list of neuroses occasionally ascribed to lesions of the nasal cavities includes esophageal spasm,

<sup>1</sup> *Revue de Laryngologie*, No. 19, Oct. 1, 1894.



hiccough,<sup>1</sup> spasmodic croup, aphonia, asthenopia, strabismus, blepharospasm,<sup>2</sup> migraine, chorea, epilepsy, vertigo, aprosexia, dyspepsia, exophthalmic goiter, acne, erythema of the skin, neurasthenia, and melancholia. This by no means exhausts the array of distant ills charged to the nose.

If the nose is such a fertile organ in the production of the misfortunes of its brother organs, it also has to bear troubles which are transmitted to it from the gastro-intestinal and the genito-urinary tracts, causing vaso-motor disturbances, post-nasal catarrh, epistaxis, and sneezing.

### SENSORY NEUROSES OF THE PHARYNX.

**Anesthesia** of the pharynx is occasionally observed in cerebral apoplexy, tumors, gummata, scleroses, general paralysis of the insane, etc., and in similar bulbar lesions. It is also present in a marked degree in extreme debility from anemia, phthisis, chorea, etc., and after epileptic convulsions. Certain drugs (chloral, bromids, cocain) produce it. Schmidt has noted unilateral anesthesia of the pharynx and larynx combined with anesthesia of the skin in a case after exposure to severe cold. McBride speaks of cases of carcinoma of the base of the skull in which there was hemi-anesthesia of the pharynx and larynx. Schech speaks of its occurring after influenza, and he refers to a report by Jurasz of its occurring after pneumonia. All these, however, are the exceptional causes of pharyngeal anesthesia. It usually presents itself as a sequel of diphtheria or as one of the manifestations of hysteria.

Besides these abnormal instances of the occurrence of anesthesia, we have a widely varying degree of sensitiveness of the pharynx in healthy individuals. Some patients bear surprising manipulations in their throats without evidence of pain or discomfort, although these great differences depend probably more upon differences in reflex excitability than in the real susceptibility to tactile or painful impressions. Women, as a rule, have more tolerant if not more anesthetic throats than men; and it has certainly been impressed upon me that neurotic people, those of nervous temperament, when once their first timidity is allayed, are more tolerant than others of the use of the laryngoscope.

**Hyperesthesia** is more common in men. They not only bear pain less stoically, but they evidently feel it much more than women. Fat persons of both sexes, but especially men, have more sensitive throats. Drinkers, especially of malt liquors, even when not excessive in their libations, are difficult subjects to examine or to operate on. The naso-pharynx is much more sensitive than the lower pharynx. Hyperesthesia is rarely a symptom of central lesions, but always accompanies local inflammations, such as pharyngitis or tonsillitis. The tongue is frequently hyperesthetic in spots. Careful inspection, if necessary with a magnifying glass, will usually disclose a swollen papilla. This will frequently give rise to great apprehension on the part of the patient that he has a beginning malignant growth.

All these hyperesthetic, as well as paresthetic, symptoms are observed in

<sup>1</sup> Abramson, *Journ. of Laryng.*, 1890, p. 216, reports two cases of hiccough, apparently dependent upon granular pharyngitis. These are the only cases that I can find in literature in which the origin of the reflex seemed to be in the respiratory tract. Indeed, the oro-pharynx may be considered as belonging to both the respiratory and the digestive tracts. Hiccough in severe forms is usually supposed to originate in the latter (Benedict, *Atlanta Med. Weekly*, Mar. 3, 1895).

<sup>2</sup> For the literature of ocular reflexes, see the full bibliography given by White (*Burnett's System*, etc., vol. ii. p. 129).



the habitual perusers of newspaper advertisements of quack nostrums and the execrable lueubrations of the imaginative reporters of the public press.

**Paresthesia.**—While the hyperesthesia and anesthesia of the pharynx are, as a rule, of little clinical interest, paresthesiæ are not only of exceedingly common occurrence, but very frequently baffle the skill of the diagnostician and disappoint the hopes of the operator. They are frequently due to tonsillar disease (not necessarily hypertrophy), to abrasions from the food or the foreign bodies in it, which leave no visible mark of injury to the mucous membrane as they pass over it; but they are, above all, more frequently observed at the time of the menopause in women, and in those who have slight or marked hyperplasia of the so-called lingual tonsil. Now it is an undeniable fact that many persons have a large amount of lymphoid material at the base of the tongue which rubs against the epiglottis and the side of the pharynx, who present no clinical manifestation of the condition; perhaps the larger number give no symptoms. We must therefore admit other and more important factors. These are supplied by the hyperexcitability of the sympathetic nervous system. An elongated uvula is a common cause of abnormal pharyngeal sensations, and its abscission affords the most satisfactory results of any operative treatment for the affection.

Granular pharyngitis of the posterior wall, so far as my observation goes, never by itself gives rise to any symptoms. It is, however, an irregular lymphoid hypertrophy of the mucous membrane, and when this extends to the lateral walls and invades the movable posterior pillars of the fauces it produces an attrition of surfaces, which frequently gives rise to the most marked of the symptoms under consideration. The "globus hystericus," the feeling of a hard, round body moving in the throat and an irresistible inclination, yet an inability, to swallow, is not infrequently seen at the menopause or in young women. I have seen it once in a young man. It is not necessarily an indication of hysteria. A feeling of cold or a burning heat is sometimes experienced by the patients: a feeling of a foreign body, a hair or a bone, a tickling or itching sensation is, however, the usual complaint. Occasionally this is so marked as to induce distressing cough and esophageal or laryngeal spasm. This is also to be sharply distinguished from hysterical manifestations. It is seen in neurotic states which nowadays we like to call neurasthenia. Rheumatic and gouty diatheses, and especially dyspepsia, are fertile sources of these neuroses. They may be due to nasal obstruction, and may accompany and aggravate cough from laryngeal or pulmonary disease.

**Treatment.**—Careful search must be made for local causes, and when found they must be removed. The crypts of the faucial tonsils must be destroyed by the galvano-cautery. If large enough to cause attrition of surfaces, the lingual tonsil must be reduced in size by the guillotine or cautery. I must confess to many disappointments in this treatment of the trouble. Applications to the base of the tongue of nitrate of silver—gr. x:ʒj—has been perhaps the most successful. This should be done twice or thrice a week. An astringent gargle—

|                 |        |
|-----------------|--------|
| ℞. Tr. kino,    |        |
| Tr. catechu,    |        |
| Glyc. tannin,   | āā ʒj; |
| Ol. gaultheriæ, | ʒj—    |

used with cold water, and half-swallowed and brought up with a gulp, so as to give the throat a course of gymnastics, will often benefit these patients.

This is a method of gargling urged by Swain, following v. Tröltzsch, and is really the only efficacious way. Hygienic and tonic treatment are indicated in the neurotic cases. Uvulotomy should always be performed when it is seen that the tip of the uvula rests, when relaxed, upon the epiglottis<sup>1</sup> or base of the tongue. Frequently its tip, formed exclusively of the mucous membrane, will be folded or curled up, at the time of the examination, in such a way that the use of a probe will alone disclose the condition. Lateral pharyngitis must be treated by cauterizing or cutting off irregularities of the surface. Usually, however, the mucous membrane in this situation is diffusely and uniformly infiltrated. The treatment of diseased faucial tonsils below, and of the pharyngeal tonsil or nasal obstruction above, will frequently cause this lateral pharyngeal infiltration or congestion to subside. Sometimes, however, it persists. Linear superficial cauterizations may be of benefit; but they always cause great dysphagia, and should be resorted to only after other treatment has been tried unsuccessfully. In middle-aged women it is well to explain to them the dependence of their symptoms upon the menopause, and tell them frankly not to expect much relief from local measures or medicines, but from time. Many will be satisfied, but some will seek advice elsewhere. A vigorous local treatment in these cases always results in disappointment to the patient and ultimate loss of prestige to the doctor. The patients are frequently importunate in their demands and obstinate in their belief of some pathological condition which exists only in their imagination.

**Neuralgia** of the pharynx is a Greek term for a pain in the throat for which the observer can find no visible or tangible explanation. It is sometimes called myalgia. I have frequently had patients complain of great dysphagia and give every evidence of suffering, in whom I could discover no pharyngeal lesion. These cases are seen more frequently in cold weather, when throat inflammations are rife. I am under the impression that in some of these cases at least we have a condition analogous to what is known as muscular rheumatism. Although there is constant pain, there is usually little tenderness to pressure unless it excites muscular contractions.

A saline purge and a gargle of bicarbonate of soda, one dram to a half ounce, in a glass of hot water, often gives some relief. The trouble usually passes off of itself in a few days. It is sometimes ascribed to a gouty or rheumatic diathesis. Morell Mackenzie refers to more chronic cases occurring in young women. Some of them suffered from anemia or chlorosis; but many were healthy and usually not hysterical. He recommends the local application of the tincture of aconite twice or thrice daily. Massei recommends the galvanic current.

#### MOTOR NEUROSES OF THE PHARYNX.

**Spasm.**—Tetanus, hydrophobia, tabes dorsalis, and hysteria are the usual causes of this rare affection. It is said to be occasionally seen in acute and chronic inflammations. Lennox Browne, in his paper<sup>2</sup> on pharyngeal tenesmus in 1891, seems to refer to cases which we are accustomed to include among the paresthesie, giving prominence as a cause to the lingual varices, about which we have read so much in English journals recently. Spasm of the pharynx has been reported by Bewley in a case of lesion of the fourth cerebral ventricle, in which there was apparently also a paralysis of the

<sup>1</sup> The uvula should not touch the laryngeal surface of the epiglottis (see legend of Fig. 534).

<sup>2</sup> *Archives de Laryngologie*, Feb., 1891.

esophagus. Seifert speaks of having seen clonic spasm of the soft palate with subjective tinnitus aurium in a case of hypertrophic rhinitis; while the same symptom was observed by Spencer in a case of cerebral tumor.

**Pharyngeal Paralysis.**—Diphtheria causes the majority of the paralyses of the palate and pharynx; but it is occasionally seen as a result of a simple acute inflammation, as mentioned by Jurasz, who also speaks of three cases in which the cause was unknown, one in which it was due to a bulbar paralysis, and one in which it followed cervical glandular swelling. I have seen one case<sup>1</sup> in which it was due to a syphilitic lesion, evidently of the floor of the fourth cerebral ventricle. It was unilateral and accompanied by lingual paralysis and atrophy and posticus laryngeal paralysis. I have also seen it in a fatal case of peripheral neuritis as the initial symptom of the involvement of the muscles of deglutition and respiration.

Besides the case of Jurasz, cases are referred to by Morell Mackenzie and others, which were reported before we depended upon bacteriology for our diagnosis, in which it was supposed to be caused by simple but severe angina. Bourges lately reported it after a case of membranous pharyngitis, in which bacteriological examination had not revealed the diphtheria-bacillus, and refers to its occasional occurrence after other diseases (typhus and pneumonia). He says it may be produced in animals by injection of streptococci and pneumococci toxins. I have also seen a case in which it was said the bacillus of Löffler could not be found. However, a negative bacteriological report is seldom conclusive. The symptoms are those of nasal speech and the regurgitation of food into the naso-pharynx. An examination shows the palate and pillars of the fauces relaxed and unable to respond to tickling with a probe. Mucosities may cover the posterior wall of the pharynx and cause the patient great annoyance. The prognosis is bad when due to central lesions, except in recent cases due to syphilis, when the vigorous administration of the iodid of potash may restore power to the muscles. Cases of peripheral pharyngeal paralysis nearly always get well of themselves. Strychnin and galvanism are the therapeutic measures employed; but I am not sure that they hasten matters at all, except that strychnin is an efficient tonic.

For a full account of the neuroses of the soft palate Rethi's excellent work<sup>2</sup> may be referred to.

#### NEUROSES OF THE LARYNX.

**Sensory Neuroses.**—Anesthesia of the larynx arises from the same causes as anesthesia of the pharynx, and is usually accompanied by it. Schnitzler speaks of it as occurring especially in anemia of the larynx.

**Hyperesthesia**, as in the pharynx, is usually present in the various forms of acute and chronic inflammation.

**Paresthesia** manifests itself usually by a tickling sensation, a feeling of a hair or other foreign substance in the larynx. It is commonly due to some abnormality of the laryngeal mucous membrane; but very frequently sensations are referred to the larynx by the patient, which have their origin in some slight lesion of the pharynx (Jurasz). All these sensory neuroses of the larynx are observed in hysteria.

**Neuralgia** of the larynx has been reported by Chapman in four cases as due to malaria, and cured by anti-malarial treatment; but from his

<sup>1</sup> *N. Y. Med. Journ.*, Sept. 28, 1889.

<sup>2</sup> *Motilität, Neurosen des weichen Gaumens, eine klinische Studie*, Vienna, 1893.

account of the cases the diagnosis seems to be a little uncertain. It is said also to be due occasionally to gout or rheumatism; but we may safely conjecture that in such cases it is really due to some slight involvement of the crico-arytenoid joint. One such case I have seen, when in a normal-appearing larynx pain was produced by pressure on the cricoid cartilage. In this case the exhibition of salol for a few days gave entire relief. Bosworth reports a case of his own in which, in a neurotic patient, severe pain in the larynx was due to an acute naso-pharyngitis. He refers to a report by Schnitzler of excruciating pain of the larynx and pharynx following an angina. Bosworth's case was cured by aconitin, gr.  $\frac{1}{50,000}$  and Schnitzler's by local applications of chloroform and morphin.

**Motor neuroses** of the larynx are to be divided into spasm (hyperkinesis), paralysis (hypokinesis), and incoördination of the laryngeal muscles. Space does not allow here of a consideration of the anatomical action and physiological function of the laryngeal muscles, nor of their innervation, nor, indeed, of a full review of the somewhat acrimonious discussion of the pathogenesis of the various motor neuroses, which for several years produced such a voluminous literature of the subject.

**Spasm** may affect any of the laryngeal muscles, and cases are occasionally reported in which there was spasmodic contraction of the abductors alone; but it is probable that this is always accompanied by, if not always the result of, paralysis of the adductors of the larynx.

Spasm of the adductors is sometimes divided into phonatory, deglutitory, and respiratory. Phonatory spasm is a rare affection in which the spasm of the adductors comes on only with attempts at phonation, preventing it, but not materially interfering with respiration. Deglutitory spasm of the laryngeal adductors is that form which supervenes whenever attempts are made to swallow, sometimes only fluid, sometimes only solid food, while in other cases the spasm is produced by *any* attempt at swallowing.

Usually by spasm of the larynx is understood the contraction of the adductors, producing a closure of the glottis which interferes more or less seriously with respiration. The most important and the most frequent of these cases present the well-known phenomena of spasmodic croup in children.

*Laryngismus stridulus* occurs most frequently in poorly nourished, if not always rachitic, children. The percentage of cases in which rachitis is an etiological factor is variously estimated by different authors from 50 to 90 per cent. Various theories have been advanced to account for the connection between the affections. Pressure on the medulla from softening of the cranial bones, or the presence of enlarged bronchial glands pressing upon or irritating the vagus or recurrent nerve, do not satisfactorily account for it. Heredity seems to have some influence. It is, however, not infrequently observed in apparently perfectly healthy children as the result of catching cold or disturbances of the stomach and bowels. Enlarged naso-pharyngeal and faucial tonsils occasionally seem to be the sole cause of attacks which differ in no way, except in severity, from those seen in rachitic children, and removal of the tonsils promptly relieves the symptoms. Occurring most frequently in male children from six months to three years of age, it is also seen both before and after this period. It usually occurs in the winter months, and the attacks come on more frequently at night.

**Symptoms.**—The little patient suddenly starts up from his sleep, gasping for breath, the face becomes livid, for many seconds respiration stops, and the child may become unconscious and death may at once ensue; but usually the



respiration begins again in gasps and gradually becomes normal. Cold sweat stands out on the face and the heart's action is much reduced. The whole attack may be over in a few minutes, or it may be prolonged and repeated several times in one night; and there is usually recurrence for several nights in succession.

**Treatment.**—The physician rarely gets to the patient in time to apply remedies, and the parents or attendants are usually too frightened to follow any directions that may have been given. The application of cloths wrung out of very hot water, or out of ice-water, to the anterior cervical region may shock the laryngeal muscles into good behavior for a time. A hypodermic injection of morphin, or the injection of a few drops of chloroform into the rectum, may cut short the attack. If possible, an efficient emetic may be given, as the yellow sulphate of mercury. The prophylactic treatment is proper hygiene, the administration of cod-liver oil, and the removal of lymphoid hypertrophies from the fauces and naso-pharynx.

Bosworth sharply differentiates the cases occurring in rachitic children from others. The death-rate is high among the former and low in the latter cases. He claims that in the latter cases we have a glottic or sub-glottic inflammation of the mucosa. This may be so, but the condition has been found post-mortem in the former cases; while the laryngoscope cannot, as a rule, be used to establish the diagnosis in any of the cases during life. The symptoms which give gravity to the affection are not inflammatory, but spasmodic. Sickly children cannot stand the sudden strain thrown on the lungs or heart by the spasm so well as robust children. I presume this is at the bottom of the apparent difference in the gravity of the cases.

**Laryngeal Spasm in Adults.**—While laryngeal spasm in children presents a fairly uniform clinical picture and is due apparently to a limited number of causes, the opposite holds true in adults. Notwithstanding its comparatively infrequent occurrence, we find cases reported as due to hysteria, to various local lesions of the nose and throat, to reflexes from other organs, and to lesions of the nerve-trunks and centers. It may occur at any time of the night or day or under various conditions of health and disease. It may be phonatory, deglutitory, or respiratory. The following remarkable case is reported for the first time, I believe, although it occurred many years ago in the New York Hospital.

The patient was an unmarried woman of thirty-two. Her father died of spinal meningitis. She had had a left pneumonia twice, inflammatory rheumatism, and some disturbances referable to her stomach, bowels, and kidneys. Since the last attack of pneumonia, five years previously, she had had a slight, persistent cough. Six years previously she had had a small tumor removed from some part of her throat, and after two years two more were removed. She knows nothing of their nature or situation. She had had at times some shortness of breath, but never any excessive dyspnea or aphonia until a few weeks before her admission. She had used morphin hypodermically for neuralgia, but was not an habitué. Four weeks ago she had caught cold, and since then the cough had been troublesome, and she had occasional dyspnea and aphonia. On the day of admission, after a hearty meal she had started for a walk feeling as well as usual; but soon experienced a feeling of constriction of the throat, and breathing became difficult. Being near the hospital she came directly there. She was restless and excited. Her breathing became more involved in spite of morphin by the mouth, inhalations of amyl nitrate and ether, and "faradization of the pneumogastric." She became unconscious three-quarters of an hour after admission; respiration was practically suspended. She was cyanosed, and her pupils contracted. Artificial respiration being of no avail, laryngo-tracheotomy was done. The introduction of the tube was not followed by any signs of tracheal irritation or spasm, but after a few moments respiration began. At first, it was only six to the minute. She remained unconscious for six hours, when the respiration having arisen to sixteen and being "Cheyne-Stokes" in character, she had a severe attack of coughing and became conscious. Fifteen ounces

of urine were drawn by catheter and found to be pale, 1008, albumen 2 per cent., no casts. For two weeks she suffered from sepsis due to a hypodermic abscess with sloughing. Her general condition finally became normal, except that she was hysterical in many ways. No pulmonary signs of importance were noted; but she had considerable gastric disturbance. The albumen soon disappeared from the urine. About four weeks after admission she had a very severe attack of coughing combined "apparently with bronchial spasm;" and for several weeks had such attacks lasting from thirty seconds to a minute, during which she struggled for air and became cyanotic. They would subside as suddenly as they came (hysterical?). After a time her condition improved and she had no more attacks. Dr. Lefferts examined her larynx and pronounced it absolutely normal. She was discharged from the hospital after the removal of the tracheotomy-tube.

Five or six years afterward this patient came under my observation for attacks of aphonia, evidently of hysterical origin. In the meantime she had no return of any laryngeal spasm.

I can offer no explanation of this case. Certainly we do not expect hysterical spasm to persist when the patient becomes unconscious and as near death as this young woman was; and yet hysteria was the salient feature in the laryngeal and other manifestations. Leo relates a case in which death ensued in a young man, which he thought was due to hysterical spasm of the larynx; although the history of the case leaves the reader in doubt as to the correctness of the diagnosis. Chaput reports a case of hysterical laryngeal spasm cured by tracheotomy; and Landgraf, one cured by catheterization of the trachea. All these cases were in men. Irwin relates a case where laryngeal spasm occurred in an adult, arising by reflex action from a bullet lodged in the arm. Removal of the ball cured the case. Foreign bodies in the nose, nasal tumors, gastric disturbances, irritation of the recurrent or vagus by tumors, are noted among the causes of respiratory laryngeal spasm. I have seen several cases in which an aneurysm of the arch of the aorta produced dyspnea, evidently rather by involvement of the recurrent causing laryngeal spasm than by pressure on the trachea or bronchi. Epilepsy, chorea, tetanus, and hydrophobia are the general nervous affections of which laryngeal spasm is the more or less constant accompaniment. As Gottstein remarks, it occasionally occurs in cases in which no explanation can be found.

Moire, in describing laryngeal spasm, divides the etiology into functional, directly irritative, peripheral, central, reflex, and associated with general affections. The form of laryngeal spasm we are most familiar with results from the impact of foreign bodies and local applications in the treatment of laryngeal affections.

**Symptoms.**—Long-drawn whistling inspirations and short expirations, with anxious face, drawn features, and cyanosed lips make an unmistakable picture of obstruction of the air-tube; while its sudden advent and intermittency indicate its spasmodic character. The obstruction is rarely so great as to completely stop the respiration, as in the cases narrated above. The attack may be a single one, or often repeated for days or months. The patients usually recover; but some of the diseases that give rise to it, as tetanus, hydrophobia, *tuberculosis dorsalis*, are in themselves fatal. It is not often possible to observe the larynx during one of these attacks. In the examinations that have been made there has been noted sometimes only closure of the true cords, but sometimes of the false cords, which hides the condition below.

**Treatment.**—Tracheotomy or intubation may be necessary to avoid immediate suffocation; but otherwise therapeutic measures must depend, as does the diagnosis, upon the cause of the affection.

**Nervous cough, or chorea of the larynx**, is an associated tonic spasm of the glottis and of the other respiratory muscles, resulting in a more or less rhythmical and continued cough or bark, which is only regularly absent during sleep. It has been most frequently noted in girls at the time or shortly after the advent of puberty; but it has also been noted before this period and at a more advanced age. In one case reported by Holden it occurred in a man of fifty-seven. F. I. Knight recorded a case in a woman of forty-two; other cases have been noted by Lefferts, Roe, Morgan, Schnitzler, Wheeler, Mandel, Porcher, Furundena-Labat, Tamburini, Kinnicut, Masucci, and Clark. Gottstein, Massei, Schmidt, and Schrötter have discussed the nature and etiology of the affection thoroughly in their works. Some cases seem to have been due to reflex causes; but since the majority of the cases as to age and sex are grouped around the period of the advent of puberty in women, we may conclude that the phenomenon is usually due to the nervous developments peculiar to that time. Hysteria, as usual at this period, is a prominent factor in some of the cases. These cases are usually reported under the head of laryngeal chorea; but it is exceedingly doubtful if it has any close relation to this affection, since very few of the cases were accompanied by any of the other choreic twitchings. The cases reported have excited the interest of physicians and the wondering curiosity of friends. Many have been known as "barking girls," and the incessant noise has rendered them a nuisance to their companions and made their own lives miserable. Fortunately, after a varying length of time the trouble disappears. The cough or bark may be repeated at intervals of a few seconds or minutes throughout the entire day or be only present for a short time, or there may be periods of days or weeks in which it is absent. It is always absent during sleep. On laryngoscopic examination the vocal cords are seen to be driven toward the median line, apparently by an uncontrollable spasm of the adductors. Knight states that in a case observed by him he could distinctly hear the click of the cords as they met. The air is driven out through the narrowing glottis by a corresponding contraction of the diaphragm, producing a short, sharp yelp or bark, terminating abruptly from the firm closure of the glottis. This is repeated at intervals varying from a few seconds to ten or fifteen minutes.

**Treatment.**—Local treatment is of little avail, and the bromids and narcotics have no curative value. The moral effect of authority, fright, galvanism, the mind-cure, faith-cure, or any of the other so-called hypnotic influences may suddenly terminate the neurosis. Of course, the general hygienic treatment by tonics, outdoor life, proper diet and sleep, and relief from any nervous strain, must all be insisted upon.

**Inco-ordination of the Laryngeal Muscles.**—(*Dysphonia* or *Aphonia Spastica*; *Aphthongia Laryngea* (Gottstein); *Phonatory Spasm*).—This is a curious laryngeal neurosis which has occasionally, although rarely, been noted. It seems to be in some cases a manifestation of hysteria; and in some cases has occurred from overfatigue of the larynx in preachers. Any attempt at phonation results in a more or less complete closure of the glottis, so that not a sound comes forth; and with it may be associated some respiratory spasm—that is, the adduction of the vocal cords lasts long enough to cause inspiratory dyspnea. In other cases there comes a high-pitched, shrill note from the larynx, possibly articulated, but not long sustained. A familiar example of this inco-ordination of the phonatory muscles is the changing voice of boys at puberty.

With the laryngoscope no abnormality is to be observed until the patient

attempts to phonate, when the vocal cords are seen to be firmly apposed in the median line.

*Functional inspiratory spasm* of the glottis is sometimes associated with the phonatory spasm, or it may exist without the trouble in phonation. When attacks of inspiratory dyspnea occur, it is seen on examination that the glottis is narrowed on expiration. The cords may be in apposition except at their posterior end, where there exists a three-cornered opening, from which we may suppose that the interarytenoideus muscle is not involved in the spasm. We may look upon these cases as evidences of perverse innervation—*i. e.*, the inspiratory impulse starts along its accustomed path to the abductors and is switched off to the adductors; but the cases have not been numerous enough to furnish data for study, and no theory satisfactorily explains them. Schmitzler first fully described the affection, and it has been discussed in the works of Schrötter, Gottstein, Moure, Bosworth, and Mackenzie; while cases have been reported by Onodi, Jendrassik, Jonquière, Meyer, Schmitzler, Landgraf, Sanctis, and others.

It occurs in adults, both men and women. In the latter it frequently depends upon hysteria, but in many cases no cause can be assigned. Mackenzie, Gottstein, Schrötter, and others have met with cases that have lasted for years without relief; but most of the hysterical cases have recovered.

**Treatment.**—Reflex causes must be sought for and remedied if they exist. The general health, if faulty, must be improved. Hysterical cases have been cured by suggestion, faradization, etc. Jonquière and Meyer cured some cases in hysterical women temporarily and others permanently by pressure on the ovaries.

Ataxia, nystagmus, and rhythmic movements of the vocal cords have been observed in tabes dorsalis, chorea, hysteria, cerebro-spinal meningitis, and paralysis agitans.

**Mogiphonia** is a term used by Fränkel to describe laryngeal phenomena induced by overuse or strain of the voice. It may be of a spastic form—phonatory spasm of the larynx—a tremulous form, or a paralytic form. The last-named has been noted by Fränkel and Bresgen in singers, preachers, and teachers. It is peculiar in that the voice may be used for other purposes, but phonation fails when they attempt to use the voice in the accustomed way—singing, preaching, teaching, etc. I do not find that others have used the term.

**Laryngeal Vertigo.**—Ictus laryngea, laryngeal epilepsy, laryngeal crises, laryngeal syncope, or lipothymia laryngea are synonyms for an affection which has not as yet been satisfactorily classified, although it has been recognized for twenty years. I have chosen the name laryngeal vertigo as a heading because that is the term under which most of the cases have been described in the English language, ictus laryngea being the name under which the affection is usually noted in other tongues. It is, however, neither a vertigo nor an epilepsy; since the cases reported have rarely suffered from the former and, except in two cases (Gray and Bianchi), have never presented any other manifestation of the latter. After a careful study of the reports it would seem that laryngeal syncope (lipothymia laryngea), the term used by Kurz, is the least objectionable. Laryngeal vertigo was first described in 1876 by Chareot, under that name. Since then there have been numerous reports in French and English, but there are few accounts of cases in German. Garel and Collet have given the best and most exhaustive description of it, reporting 23 cases of their own. With the exception of two or three



cases, all have been in men; and the majority of them were between forty and fifty years of age.

The patients feel a tickling in the larynx, cough once or twice, and become suddenly unconscious. This lasts for less than a minute, with quiet respirations and a feeble pulse, when they as suddenly regain consciousness and feel as well as ever—often laughing at the alarm the attack has excited in their companions. The face becomes flushed and congested at the beginning of the attack and is pale on recovering. There may be a single attack or a number of them at short intervals or at intervals of years. In some cases there has been evidence of bronchitis and emphysema or of an enlarged and fatty heart. Alcoholism, diabetes, and nephritis have been occasionally noted in these patients, but not frequently enough to make them of much importance in the consideration of the etiology. The patient may have had laryngeal irritation and cough for years, and only once an attack of syncope. He may cough only once slightly or many times violently before he becomes unconscious. Frequently he has been sitting quietly or the attack has come on in bed. At other times he has been walking or driving. In some cases there has been excessive bronchial secretion. Usually there has been no convulsive muscular action during the attack; but in some there has been twitching of various muscles. It is exceedingly probable, as urged by Garel and Collet, that these attacks often occur without the patients remembering them in their accounts, or without their being noted by their companions.

Various theories have been advanced to account for the attacks. Charcot supposed them analogous to Ménière's disease, the superior laryngeal nerve being involved in the intracranial irritation, instead of the auditory. Garel and Collet suppose it due to arterial anemia of the brain, there being an obstruction to the venous circulation and an insufficiency of arterial blood in the vessels due to a temporary weakening of the heart's action. This cardiac failure they suppose to be brought about by the involvement of the sympathetic nerves in the irritation of the superior laryngeal at the time of the cough. In only two cases was the attack observed by the reporter. Kurz found his patient in syncope; while Schadewaldt was looking at his case when one of the attacks began. This case subsequently died in one of the fits; but, as a rule, this has not been noted, nor does it appear necessarily to be an indication of disease of a vital organ. Gleitsmann's case had enlarged lingual glands, and the treatment of these abolished the attack. Adler attained the same result by clipping an elongated uvula, and Charcot by cauterizing a granular pharyngitis.

The cases are really more curious and interesting than instructive or important, since we are unable to classify them, and since they apparently are only exceptionally brought to the notice of the physician.

**Treatment.**—Local abnormalities must be sought for and removed, and the systemic diseases which may be present must receive their appropriate treatment. Drugs have no direct influence on the attacks.

**Laryngeal Paralysis (Hypokinesis).**—**Pathology and Etiology.**—Central paralysis of voluntary motion in the majority of cases is caused by some lesion of the cerebral cortex. Paralysis of involuntary motion in the majority of cases has its origin in the spinal cord or the medulla. Phonation is the product of voluntary, and respiration is the product of semi-involuntary, motion. Aphasia must be entirely separated from aphonia in the consideration of its etiology. Shortly after interest was first aroused in the location of areas of the origin of motor impulses in the cerebral cortex, Kruse, in 1884, showed that stimulation of the *gyrus prefrontalis* in animals

produced muscular movements of the larynx, palate, and pharynx. Thereupon Garel,<sup>1</sup> in 1886, reported a case of laryngeal paralysis in which autopsy showed a lesion of this area. Lewin had previously noted the occurrence of laryngeal paralysis in a case of hemiplegia; but Garel's was the first case that had come to autopsy in which a laryngoscopic examination had previously been made. In 1889 Semon and Horsley<sup>2</sup> published the results of their experiments on animals, by which Krause's statements were confirmed. They showed that the area was one of bilateral representation—*i. e.*, a stimulation of either side at the lower part of the *gyrus prefrontalis* would produce adduction of both vocal cords. They also showed that extirpation of one or both of these areas produced no laryngeal paralysis. These results have been confirmed by all observers with the exception of Massini, who claimed that faradization with weak currents produced movement of one side only of the larynx. Several observers have repeated Massini's experiments, with negative results. Garel and Dor later returned to the subject and reported further cases, and cited several from literature in which a cortical lesion was accompanied by laryngeal paralysis; but in none of these cases were they able to exclude a possible lesion of the pons, of the nerve-trunks, or of their peripheral distribution. Hunter Mackenzie's recent case is open to the same criticism. Semon and Horsley showed that the fibers from this cortical area passed through the *corona radiata* and internal capsule to the bulb. They showed also<sup>3</sup> that the respiratory cortical center in animals does not exactly correspond to the phonatory center, and that laryngeal movements were observed independent of thoracic movements of respiration. "Acceleration is obtained by exciting the precrucial gyrus; intensification, most commonly, from the region around the lower end of the crucial sulcus; and inspiration we have already localized in the cat just above the olfactory sulcus." The manifestation produced in a cat by stimulation of this area was persistent abduction of the vocal cords, while thoracic respiratory movements continued. As to phonation, they say that "there is in each cerebral hemisphere an area of bilateral representation of *adductor* movement of the vocal cords situated, in the monkey, just posterior to the lower end of the precentral sulcus at the base of the third frontal gyrus; and in the carnivora, in the precranial and neighboring gyri." The fibres from these run directly through the *corona radiata* to the internal capsule, where "the fibers which subserve the function of respiration are contained at first in the anterior limb and lower down, more especially in the region of the *genu*." "The fibers which subserve the function of phonation, and excitation of which produces adduction of the vocal cords, are, in the carnivora, grouped at, or just posterior to, the *genu*, and also, according to the level of the section, continued into the posterior limb. In the monkey they are concentrated as a small bundle in the posterior limb, among the fibers for the movement of the tongue and pharynx. From excitation of these fibers we have always obtained bilateral effects." They also described laryngeal respiration as represented in the medulla oblongata by an area in the upper part of the floor of the fourth ventricle. Here also unilateral stimulation produces bilateral effect, the prevailing movement being abduction; while adduction or phonatory movement (bilateral) is excited by irritation of the *ala cinerea* and the upper part of the *calamus scriptorius* at the lower border of the fourth ventricle. Irritation of one of the external borders of the restiform bodies produces unilateral adduction of the vocal cords. The authors, in conclusion,

<sup>1</sup> *Rev. de Laryngol.*, May, 1886, p. 248.

<sup>2</sup> *Brit. Med. Journ.*, Sept., 1886; Dec. 21, 1889.

<sup>3</sup> *Deutsch. Med. Woch.*, 1892, p. 672.

admit that they have indicated only the more prominent highways of nervous impulse, and that there may be other contributing paths.

Goltz, Onodi, and Klenipere have confirmed these statements, and shown that not only may these cortical centers be destroyed in animals without affecting the innervation of the larynx after the wound has healed, but they and others have proved that the whole of both cerebral hemispheres may be cut away with the cerebellum, leaving nothing but the pons, without affecting the movements of adduction or abduction in the larynx. These facts have been established by experimentation on animals. How far they are applicable to man it is impossible to say, although it is probable that owing to the larger evolution of the brain in man, especially that part of it having to do with speech, variations would be noted in important particulars from the lower animals. As a matter of fact, however, there has been no case reported in man of cortical lesion accompanied by laryngeal paralysis in which the possibility, and few in which the probability, of involvement of the nervous tract below could be excluded. We must, therefore, in view of the positive evidence in animals and the negative evidence in man, admit that Semon's declaration of the non-occurrence of cortical laryngeal paralysis in man is probably correct.

In 1873 Schieb and Schmidt, by experiments, apparently established the fact that the vagus gets the motor-filaments which supply the larynx from the upper filaments of the spinal accessory nerve. This view has obtained until lately, when Grabower and Grossman, by separate investigations, showed in 1890 that this was not the case, but that the motor innervation of the vagus was obtained through its lower filaments from the dorsal vagus nucleus in the lower part of the floor of the fourth cerebral ventricle. Darkschewitsch, in 1885, stated that the dorsal nuclei of the vagus and the spinal accessory nerves were coterminal, arising, therefore, from the same tract of gray matter. Grabower and Grossman in 1894, again separately, in a series of microscopic sections, have shown that the motor nucleus of the accessory and that of the vagus are not coterminal, but that the latter begins above where the former leaves off—in the medulla oblongata; and still more recently Grabower has reported a case which goes far, by clinical and pathological evidence, to establish the fact which he had previously announced from experimental and microscopic investigations. A bulbar lesion causing laryngeal paralysis we must, therefore, expect to involve the dorsal motor nucleus of the vagus nerve, which lies near the median furrow, at the lower part and beneath the floor of the fourth ventricle.

The anatomy, course, and distribution of the laryngeal nerves in general have been well understood for a long time; and space does not allow us to dilate upon well-known data. There are several points, however, upon which it is necessary to say a few words, as they have of late been the subject of important investigations. Notwithstanding the fact that Exner has shown that in certain animals the superior laryngeal nerve participates in the innervation of certain of the intrinsic laryngeal muscles, subsequent investigations show pretty clearly that this arrangement does not obtain in man; but that the external or smaller branch of the superior laryngeal nerve alone contains motor filaments, and these supply the crico-thyroid muscle only, the other branches of the superior laryngeal nerve being exclusively composed of sensory filaments (Onodi) which supply the laryngeal mucous membrane. Besides the nerve-supply derived from the superior laryngeal nerve, the crico-thyroid muscle has been shown by Exner, Onodi, and others to receive by means of a communicating branch (middle laryngeal nerve) motor impulses

from the pharyngeal branch of the pneumogastric. This has been a subject of considerable controversy; but in a later communication Exner has reasserted the fact. The other internal laryngeal muscles, adductors, abductors, and tensors are supplied by one nerve—the inferior or recurrent laryngeal nerve. The vagus, running from the jugular foramen with the blood-vessels, dips into the thoracic cavity and gives off the recurrent laryngeal, which winds around the arch of the aorta on the left and the subclavian artery on the right and returns to the larynx.

Rosenbach and Semon at about the same time (1880–1881) drew attention to the fact that in laryngeal paralysis the abductors are usually the first, and sometimes apparently the only, muscles to suffer as the result of central or nerve lesions. In hysterical aphonia, however, it is the adductors which are affected. Attention being drawn to this fact of the preponderance of abductor paralysis, great curiosity was excited as to the cause of this phenomenon. In 1884 Krause, by a number of experiments on animals, was convinced that this apparent paralysis of the abductors, resulting in the immobility of the vocal cords in the median line, was really due to a contracture of all the laryngeal muscles from irritation caused by pressure on the nerve-trunks or nerve-centers, or by their involvement in disease. This raised a point about which for many years much acrimonious discussion prevailed. Semon was the most persistent and the most successful of the opposers of this view; and his papers and references to the question have been voluminous and frequent. Although I was inclined at the time to believe that Krause's experiments had established his contention, and so expressed myself,<sup>1</sup> the weight of evidence has so preponderated against it in the last five or six years, that I cannot but admit that Semon's view is more nearly correct; yet, as the latter has said, one cannot deny that contracture occasionally is the cause of median position of the cords. Various explanations have been advanced to account for the greater proclivity of the abductors to loss of power. Although Mackenzie and Riegel had suggested the existence of separate filaments in the recurrent nerve supplying the different muscles, it remained for Onodi and Risien Russel to demonstrate the fact; but their position in the nerve, as suggested by Mackenzie and Riegel, could not account for the frequency of abductor paralysis. Hooper, in a valuable paper, showed that ether has a peripheral and differential effect upon the laryngeal muscles, the abductors being the first to suffer in their function. Jeanselme and Lermoyez showed that the abductors lose their contractility first post-mortem. Fränkel and Gad showed that freezing the recurrent nerve caused first a paralysis of the abductors. The experiments of Massini showed the same effect from application of chromic acid to the nerves. Mackenzie suggested that the greater exposure of the posterior crico-arytenoids to the passage of food and air made them more liable to injury, owing to their position. From these facts, it seems, as Semon says, that the greater proclivity of the abductors to the loss of power is probably due to the characteristics of the muscles themselves; but it must be confessed that the evidence in this regard is not complete.<sup>2</sup>

From what has preceded, it is not necessary to dwell long upon the causes of laryngeal paralyzes. We have seen that we may, in the present state of our knowledge, disregard the few cases that have been reported of lesions of the cerebral hemispheres. Various affections of the medulla oblongata not in-

<sup>1</sup> *N. Y. Med. Journ.*, Sept. 2, 1889; *Journ. Am. Med. Assn.*, Oct. 8, 1892.

<sup>2</sup> Grabower has, since the preparation of this chapter, adduced evidence to show that the greater vulnerability may be due to a difference in the method of termination of the nerve-fibers in the muscles (*Arch. f. Laryngologie*, Band v., Heft 1).



frequently produce laryngeal neuroses, together with other peripheral manifestations. Out of 122 cases of *tabes dorsalis* observed in Gerhardt's clinic, paralysis of the laryngeal muscles was observed in 17. Of these, 11 were of the posticus or abductor muscle of the glottis, 5 were bilateral, 4 upon the right hand, and 2 on the left. There were 3 cases of paralysis of all the muscles supplied by the recurrent—1 bilateral and 2 on the right side. Of the other 3 cases, there was 1 each of recurrent paralysis and of crico-thyroid (superior laryngeal), and once paralysis of the recurrent of one side and of the posticus muscle of the other. In 2 cases paralysis of the thyro-arytenoid was noticed. In 2 of the 122 cases ataxic movements of the vocal cords, and in 4 laryngeal crises, were observed. For a further account of laryngeal affection in *tabes dorsalis*, see the papers of Burger, Van Gieson,<sup>1</sup> and Dreyfuss.

Two cases of unilateral posticus paralysis have been observed in syringomyelia by Weintraud, and 1 by A. Schmidt. Paralysis and tremor of the vocal cords have been noted in multiple sclerosis by Lenbe, Bennett Lori, Collet, Spencer, Krzywicki, and others. In one of Collet's cases the lesion was in the cerebellum. Laryngeal paralysis is one of the symptoms caused by the progressive lesion of the gray nuclei of the bulb, which we call glosso-labio-pharyngeal paralysis, and is said to distinguish it from the pseudo-bulbar paralysis.

The lesions causing these symptoms are usually softening of the nervous matter caused by atheroma of the vertebral artery or its branches. As is readily understood, the sequel of symptoms varies somewhat, depending upon the vessel affected. Syphilis may set up similar changes in the blood-vessels; and the vigorous administration of iodid of potash may stop the progress of the disease, and to some extent restore function to the paralyzed vessels; but of course only a moderate degree of restoration is to be expected. Brain-tissue in this situation is not regenerated, although congestion and the pressure of inflammatory syphilitic products may be relieved. The small laryngeal muscles, when once atrophied, are not usually restored to function. Cases have been reported by Senator, Eisenlohr, Delavan, Wright,<sup>2</sup> Scheiber, and others.

Cases of bilateral laryngeal paralysis are rarely due to bulbar lesions; but, as will be seen by reference to the above instances, a number of cases of unilateral laryngeal paralysis have been found to be due to lesions of the medulla. This does not entirely correspond to the evidence, cited from Simon and Horsley's experiments, of the existence of a bilateral representation of laryngeal movements in the nuclei of the bulb in the lower animals. Evidently the last word has not been said concerning the central innervation of the larynx.

Tumors of the pons and medulla have been rarely reported as causing laryngeal paralysis. Gottstein reviews the subject and refers to the report of several cases of glioma and one case of aneurysm of the basilar artery by Ollivier d'Angers.

All the cases reported of laryngeal paralysis due to bulbar lesion have presented similar conditions in the regions supplied by the facial, acoustic, glosso-pharyngeal, spinal accessory, or other branches of the vagus nerve, according to the extent of the lesion.

Many cases of laryngeal paralysis have been reported due to the involvement of the trunks of the vagus or laryngeal nerves in tumors, traumatism, and other pathological conditions at the base of the skull. As these conditions may simultaneously involve the other nerves referred to, it is often a

<sup>1</sup> *The Journal of Nervous and Mental Disease*, July, 1896.

<sup>2</sup> *Loc. cit.*

matter of some difficulty to distinguish them from bulbar lesions. Such are the cases reported by Remak, McBride, and Türekk.

Lesions involving the trunk of the vagus on its way down the neck and of the recurrent as it winds around the great vessels in the thorax and travels back along the esophagus to the larynx, are the most fertile causes of laryngeal paralyses. Enlarged glands, traumatism from wounds and operations, goiters, aneurysms, tumors of the mediastinum, esophagus, and pharynx, pleurisy, and tuberculosis at the pulmonary apices, pericarditis, scoliosis of the cervical vertebra, have all been reported as causing paralysis of the abductors alone or of all the muscles supplied by the recurrent.

In aneurysm of the arch of the aorta, laryngeal paralysis may be the first, and for a long time the only, sign of dilatation of the vessel. Again, cases are not infrequently met with in which no cause can be assigned for the recurrent paralysis, and we are compelled to make a tentative diagnosis of simple neuritis.

We must suppose the rare instances of the paralysis of separate muscles to be due either to lesions of the nerve-twigs supplying them, or to involvement of the muscle-substance itself. As we have seen, paralysis of the abductors is said by Mackenzie to be due in some instances to their exposure to traumatism from the passage of boluses of food through the lower pharynx to the esophagus, or of cold drink. Several years ago I treated a case in which there was apparently a paralysis of the thyro-arytenoid muscles, with a paresis of the crico-thyroid and interarytenoid muscles on each side. Besides the elliptical opening in the glottis on adduction, the cords had the peculiar rounded outline described by Störek. This latter soon disappeared, but the laxness of the cords continued for some time. This condition supervened on the pharyngeal inflammation caused by swallowing carbolic acid. Besides in diphtheria, cases have been reported in, or as following, scarlatina, typhoid fever, influenza, measles, anemia, chlorosis, and psychical disturbances, cholera, trichiniasis, malaria, icterus, pneumonia, and poisoning from atropin, morphin,<sup>1</sup> arsenic, lead, and chronic alcoholism.

The very valuable recent paper by Heyman<sup>2</sup> comes too late to hand for a thorough analysis of the cases of toxic paralysis of the laryngeal muscles. His list of the poisonous agents includes lead, copper, antimony, phosphorus, arsenic, alcohol, atropin, morphin, and cocain.

In the same issue Lazarus reports paralysis of the abductors of the larynx in a case of gonorrhœa in which no other morbid influence was evident. Occurring in connection with these affections, the situation of the lesion has usually been unknown; although from the symptoms in some it was referred to the bulb and the nerves, as well as to their peripheral distribution.

Some cases of laryngeal paralysis due to reflex causes in the nose and elsewhere have already been alluded to in this work, and others are to be found in literature.

**Diagnosis and Symptoms.**—Before confining ourselves strictly to laryngeal manifestations, something must be said in regard to the phenomena which accompany laryngeal paralyses due to lesions of the medulla and the vagus nerve.

<sup>1</sup> Pneumonia and malaria (Schech) are included in the list of diseases, and atropin and morphin among the poisons which have caused laryngeal paralysis, but I can find no exact references to cases in the text-books of Sajous (p. 362, ed. 1889), Schech (*Die Krankheiten des Kehlkopfes*, etc., 1897), and Gerhardt.

<sup>2</sup> Fränkel's "*Archiv für Laryngol. und Rhinol.*," Band v., 1896.

In *lesions of the medulla oblongata* concomitant manifestations are almost always found elsewhere. The tongue may be paralyzed, atrophied, and protrude toward the affected side. There is usually a paralysis of the soft palate, causing nasal speech and the occasional regurgitation of food and drink into the nose. Difficulty in swallowing, from paresis of the pharyngeal muscles and anesthesia of the pharynx and larynx, may be present. There may be facial paralysis, deafness, and vertigo. Acceleration of the heart's action and of the respiration are of occasional occurrence. Sometimes the manifestations of bulbar disease are bilateral, in which case it is almost always the abductors alone which are affected; but usually, though not so frequently as in the other lesions, the laryngeal paralysis is unilateral. There is no well-authenticated case of paralysis of the adductors alone from any essential lesion. A few bulbar lesions have been reported by Jackson, Pronst, Senator, and Eisenlohr as causing bilateral laryngeal paralysis.

Many of these bulbar cases die, especially those in which there is a double laryngeal paralysis, from the extent of the disease in this region which presides over the most vital functions of the organism.

**Lesions of the Vagus Nerve.**—The involvement of other nerves in bulbar disease establishes the diagnosis, as a rule; but occasionally lesions at the base of the skull may simulate it by involving the trunks of several nerves besides the vagus. Such are the cases reported by McBride, and by Sehech, Bernhardt, and Nothmager.<sup>1</sup> Bäumlér, Johnson, McCall Anderson, and Whipman have published cases in which pressure upon one vagus has caused laryngeal paralysis of both sides. This Johnson explains by stating that as the vagus contains centripetal fibers the ensuing degeneration extends to the medulla and there by decussation involves the motor area of the other side. Such seemed to be the explanation of a fatal case of double abductor paralysis reported by the writer<sup>2</sup> in 1892. Krause's contention that the recurrent laryngeal nerve contains centripetal fibers has not been sustained.

**Paralysis of all the Muscles Supplied by the Recurrent Laryngeal Nerves.**—The vocal cord assumes the "cadaveric position," a term first used by v. Ziemssen, and since then generally adopted to denote a position half-way between the median line (phonatory position, adduction) and the lateral wall of the larynx (deep inspiration or extreme abduction). When the paralysis is complete and bilateral the voice is entirely extinguished, and it is only by a great effort of expiration that the lax vocal cords are thrown into vibration and a hollow, whispering note is produced. Forceful respiration causes the arytenoid cartilages to tip inward at their summits, which produces a stridulous sound. When there is no crico-thyroid paralysis, or only partial paralysis of some of the muscles, these symptoms are variously modified.

Bilateral paralysis of the recurrents is occasionally caused by the involvement of both recurrent nerves in cases of thyroid or esophageal cancer or aortic aneurysms, as noted by Mackenzie and others.

Unilateral paralysis at first causes entire aphonia, but after a time the unaffected cord will be seen to make more or less extensive excursions across the median line to meet its fellow, with the result of producing a more audible whisper or even some rough phonatory sounds. There is no dyspnea either in bilateral or unilateral recurrent paralysis when complete; or when partial, except in cases of bilateral abductor paralysis. Bilateral recurrent paralysis may at first be mistaken for the functional paralysis of the adductors in hysteria, but a more careful examination will show that the cords do

<sup>1</sup> Histories quoted by Gottstein, page 390.

<sup>2</sup> *Loc. cit.*

not move on forced inspiration; while in hysterical paralysis there are jerky movements of extreme abduction, or in some cases they may be immovable against the external laryngeal wall, leaving a much wider opening of the glottis than that left by the cadaveric position of the cords.

**Paralysis of the Abductors of the Larynx.**—When *bilateral*, both posterior crico-arytenoid muscles being completely paralyzed, the patient without immediate help dies from suffocation. It seems to me exceedingly probable that many sudden deaths from cerebral apoplexy might be explained in this way. The stertorous breathing in apoplectic coma lends probability to this suggestion.

The cases, however, in which bilateral paralysis has been observed laryngoscopically, have been those principally in which the disability came on gradually in one or both cords. The vocal cords are seen almost in apposition throughout their length. There may be, however, a narrow elliptic slit between them; while at the posterior commissure an isosceles triangle is formed on inspiration. This is due to the relaxation or, when present on both inspiration and phonation, to the paralysis of the interarytenoid muscle and the tensors of the vocal cords. Notwithstanding the great dyspnea in these cases, phonation is not materially interfered with, because the vocal cords are constantly in the phonatory position.

**Treatment.**—Tracheotomy in these cases is indicated to avoid impending suffocation. In my case and in others procrastination on the part of the patient resulted fatally. Where it becomes evident that the patient is liable to live a long time with a tracheotomy-tube, the question arises as to the excision of the vocal cords. This has been suggested by Hope and strongly condemned by Semon. It, of course, should only be done as secondary to tracheotomy, when it becomes evident that there is to be no recovery of function. The patient should have to choose between the extinction of voice and the necessity of wearing a tracheotomy-tube indefinitely. Judging from examples familiar to all laryngologists, we might expect some restoration of voice without vocal bands. So far as I know, this procedure has never been carried out in man, although adopted with advantage in horses as a cure for roaring. Division of one recurrent nerve has been done by Ruault in a case of bilateral abductor paralysis, in the hope that the cord would fall back to the cadaveric position; but this did not occur. Probably in all these cases, after a varying time, the adductors become atrophied from disuse as well as the abductors; but the arytenoid joint becomes stiffened also from disuse, and the cord is immovable.

**Unilateral abductor paralysis** is the most common of all the hypokinetic disturbances of the laryngeal muscles. When uncomplicated, it produces neither dyspnea nor dysphonia. It is not infrequently a surprising discovery in a routine laryngoscopic examination—giving, it may be, the first hint of a thoracic aneurysm, or possibly proving an unsolvable puzzle to the observer when he seeks its causation.

**Paralysis of the Adductors of the Vocal Cords** (*Crico-arytenoidi Laterales*).—*Bilateral*: This is the usual manifestation of hysteria in the larynx. It is distinguished by its sudden onset, as a rule, and by the fact that it occurs in a patient who nearly always presents some other sign of hysteria than the laryngeal one. Aphonia, occasionally the inability to whisper (apsithyria), the history of previous attacks which suddenly, from some trifling incident or from no assignable cause ceased, make the condition a tolerably easy one to recognize. Sometimes the patient is able to sing, but not to use a conversational tone; and various other phenomena which it is im-



possible to reconcile with the idea of an essential paralysis are helps in the diagnosis. Various theories have been advanced to account for the pathology of the affection. Thus Gerhardt supposes it to be of cerebral or nerve (vagus) origin because it is occasionally unilateral, and hence beyond the control of the will; but all theories to explain special phenomena in hysteria are of little value until an acceptable explanation with demonstrable material proof can be formulated to account for the general condition. The vocal cords are seen to be widely abducted, so that the glottis is constantly in the inspiratory position. Sometimes there seems to be a concomitant spasm of the abductors, so that the vocal cords disappear in the lateral larynx walls.

Paralysis of one lateral adductor has been noted by Mackenzie, Donaldson, Stewart, and others. Usually this rare affection is caused by hysteria or lead-poisoning. Some cases are recorded as due to reflex trouble in the nose. These cases have not been sufficiently studied to arrive at any conclusion in regard to differentiating between the functional cases (hysteria) and those probably due to some material lesion.

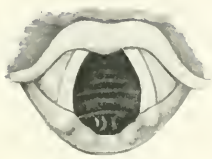**Paralysis of the arytenoideus**, the transverse or central adductor, usually occurs in connection with that of the other muscles, but is sometimes noted as occurring alone, when laryngoscopic examination shows that the vocal cords are in apposition throughout their anterior three-fourths on phonation, with a triangular space posteriorly. Aphonia is more or less complete.

While these cases usually occur in connection with hysteria, a number of cases have been reported where they seemed to result from acute or chronic catarrhal affections of the larynx. Proust and Tissier's monograph has the bibliography to 1890. Few, if any, cases have been since reported.

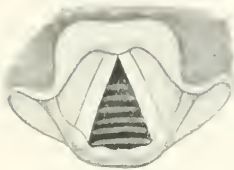**Paralysis of the Tensors and Adjusters of the Vocal Cords** (the external tensor—crico-thyroidens; the internal tensor—thyro-arytenoideus internus).—*Paralysis of the superior laryngeal nerve* supplying motor filaments to the crico-thyroid muscle and sensory filaments to the mucous membrane is a rare occurrence. Sometimes only the external or muscular branch seems involved, when it is said that the examining-finger will note the relaxation of the muscle by palpation of the crico-thyroid space. This has been caused by traumatism and operations, but more frequently results from diphtheria (v. Ziemszen). When resulting in total anesthesia of the larynx and of the epiglottis, great danger arises from the food and secretions entering the larynx. When this is accompanied by paralysis of the recurrent, the danger is still further increased. Mackenzie relates a case in which suppurative inflammation of the cervical glands caused paralysis, apparently of the superior laryngeal nerve alone; while Johnson reports a case following typhoid fever. According to the account given by Mackenzie, the vocal cords when adducted assumed at their line of junction a wavy appearance with a depression at the center. When only one cord is affected, it is seen at a lower level than the other side. Hoarseness and aphonia result.

Mackenzie, in his definition, says "Paralysis of the superior laryngeal nerve gives rise, when complete and bilateral, to anesthesia of the larynx and loss of power of the crico-thyroid, *thyro-epiglottic*, and *ary-epiglottic muscles*." He further says, "When these muscles are paralyzed the closure of the larynx during deglutition does not take place, the glottis remaining erect and against the root of the tongue." This is incomprehensible, as these latter muscles, so far as I have been able to gather from authorities (Gray, Quain, Onodi), are intimately associated with the arytenoideus muscle and supplied by the recurrent nerve; and so far as I remember my own observations of laryngeal paralysis, I have seen this position of the epiglottis in connection

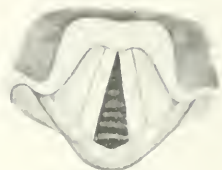PLATE 15.



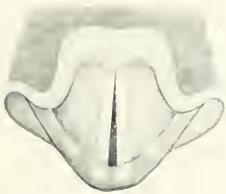1. Forced inspiration.



2. Quiet inspiration.



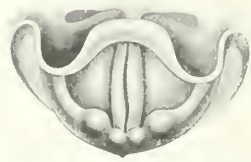
3. Relaxed or cadaveric position.



4. Moderate adduction.



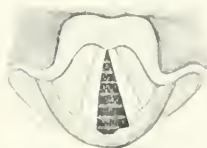5. Phonatory apposition.



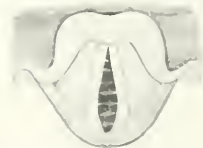6. Bilateral paralysis of external tensors (Mackenzie).



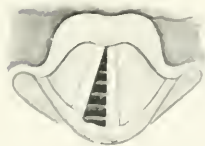7. Bilateral paralysis of internal thyro-arytenoids and arytenoid.



8. Paralysis of left posterior crico-arytenoid. Inspiration.



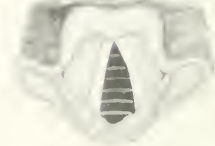9. Bilateral paralysis of lateral crico-arytenoids.



10. Left recurrent paralysis. Adduction.



11. Bilateral recurrent paralysis.



12. Left recurrent paralysis. Adduction.

Semi-schematic illustrations of the glottis in health and in disease.



with paralysis of other muscles supplied by the recurrent. The passage of food into the larynx in connection with superior laryngeal paralyses, I should suppose to depend more upon the anesthesia than upon the loss of power in these muscles, as intimated by him. This is a point to which I have been unable to find any reference in other authors, and I hesitate to make the criticism of an almost faultless text-book.

*Paralysis of the thyro-arytenoidei interni* muscles alone occurs frequently as the result of strain and local inflammation. It is seldom complete. An elliptical opening of varying transverse diameter is seen on adduction. Hoarseness or complete aphonia results. Usually rest and local applications after a few days restore the function of the cords; although Mackenzie reports a case in which it was paralyzed for three years, and cured in three weeks by faradization.

While laryngeal paralyses have been treated *seriatim* and separately, it must be understood that in the peripheral manifestation various combinations may exist which alter and complicate the laryngoscopic image, due to the influences of synergistic or antagonistic muscles.

An error in diagnosis may frequently arise in mistaking for paralysis the ankylosis of a crico-thyroid joint due to inflammation, or the inability or limitation in a vocal cord due to infiltration of the muscles or stroma by tubercular, syphilitic, or cancerous disease, or to the existence of fibrous cicatricial bands.

**Prognosis.**—We have only to consider the prognosis as it relates to the recovery of power in paralyzed muscles. Loss of function due to essential lesions is rapidly followed in the small laryngeal muscles by fatty degeneration and atrophy. Complete laryngeal paralysis from these causes, when it has existed for several months, is rarely recovered from, as pointed out by Elsberg<sup>1</sup> many years ago. Aside, therefore, from irreparable changes in the nerve-trunks and centers, peripheral changes soon render a cure of essential paralysis unlikely.

**Treatment.**—Indications must be met, as they arise, to preserve the patient's life by tracheotomy or intubation. In pareses or partial paralyses, and in functional paralyses faradization by an intralaryngeal electrode may be of advantage. Prompt removal of causes, such as pressure on nerves or inflammatory processes, may restore action to immobile muscles when the trouble has not resulted in too much degenerative change. The same may be said of central syphilitic lesions.

## HYSTERIA OF THE NOSE AND THROAT.

The manifestations of hysteria in the nose and throat, as elsewhere, are of such infinite variety and shade off so gradually into essential neuroses and so-called neurasthenia, that an orderly or complete account of them could not be given, if every case reported were reviewed and every case observed were reported.

Persistent or intermittent complaints of anosmia or parosmia are made by women in whose noses little can be observed that is abnormal. How to distinguish these cases from those in which there is essential disturbance of the olfactory apparatus is often a matter of great difficulty. When I see a neurotic woman with a nasal mucous membrane which is tolerably healthy, and yet who complains of anosmia persistently, so as to bring it to my

<sup>1</sup> *Phila. Med. Times*, July 30, 1881.



especial notice. I always think it is a case of hysteria; because true anosmia is usually complained of incidentally by patients who come for relief of other nasal symptoms. Reference has already been made to cases who complain of subjective sensations of obstruction or irritation in the nose. Here again it is difficult to separate the elements which are neurotic if not hysterical. While typical cases of hysteria differ entirely from typical cases of neurasthenia, there are so many on the border line between the two that one frequently hesitates as to their classification exclusively in either category.

Hysterical affections of the soft palate and pharynx are most frequently those of a sensory nature. Occasionally cases will be observed to simulate paralysis; but essential paralysis involves such a complex series of disturbances in deglutition, respiration, and speech, that flaws may be easily detected.

Hysterical aphonia has attracted more attention than any other manifestation of functional trouble in the larynx; yet we find simulation of almost every form of neurosis. Treupel<sup>1</sup> enumerates laryngeal spasm, nervous cough, inspiratory functional spasm of the glottis, phonatory functional spasm of the glottis, hysterical aphonia, and aphithyria, or hysterical mutism. All these have been mentioned in the preceding pages, and lack of space forbids any more extended notice of them. Local disease of trifling character in any part of the upper air-tract is frequently noted as a cause contributory to the general neurotic tendency. While it is usually observed in young women, it is by no means unknown in children or in people of advanced age, and is occasionally observed in men. Treupel's work deals exhaustively with the subject; and he asserts that all the laryngeal manifestations which have been observed in hysteria may, by practice in the healthy person, be reproduced at will. Of course, patients cannot be aware of the positions of the vocal cords taken in response to their impulses, but they can reproduce by their sensations states in which these phenomena occur. It is difficult, however, to explain all the laryngeal manifestations by this hypothesis. Laryngeal spasm persisting after loss of consciousness so that death ensues, is difficult to reconcile with the idea of exclusive control by the will.

**Treatment.**—Hysterical affections of the nose and throat can more frequently be cured by suggestion than by any other treatment. The methods of doing this are so various, and each one so often fails, that no one procedure can be considered of any exceptional value. Ostensible operations with forceps or cautery, or applications or mere examinations, accompanied by the confident statement of the operator as to its immediate efficiency, will frequently bring about a prompt disappearance of the local affection. These maneuvers will more frequently succeed in the unsophisticated patient on whom similar tricks have not been played before. Galvanism, that magical first cousin to charlatanry, is a potent device to bring about the desired impression on the patient. So far as my observation goes, all such phenomena are more frequently benefited, as to the local trouble, by individuals whose faith exceeds their scientific attainments, or whose effrontery supplants their scruples. However brilliant may be the immediate results of a deception, condoned by the ethics of Plato, it is only successful as concerning the immediate form of the neurosis, and does nothing for the general vice which lies behind, and is in no way a preventive of recurrence of the same trouble.

The treatment must be on the broad grounds of improving the general health and the moral tone of the individual, with an elimination of vicious influences—physical, social, and psychical.

<sup>1</sup> *Die Bewegungen-Störungen im Kehlkopf bei Hysterischen*, Jena, 1895; also *Berlin. Klin. Woch.*, No. 52, 1895. The former contains a very full bibliography of laryngeal hysteria.

# THE VOICE—ITS PRODUCTION AND HYGIENE.

BY G. HUDSON MAKUEN, M. D.,

OF PHILADELPHIA, PA.

VOICE may be defined as a moving column of breath set in vibration by its own impact with the vocal bands and reinforced by its diffusion through the various resonators into the surrounding atmosphere. According to this definition there are three important elements to be considered in relation to voice—namely, the moving column of breath, the vocal bands, and the resonators. We shall consider these elements in their order.

**The Moving Column of Breath.**—This column may be regarded as having the diaphragm for its base, and as being set in motion by the respiratory muscles. This motor process has been called the breathing of voice-production, and it differs from ordinary so-called natural breathing in that the one is active and voluntary, while the other is passive and automatic. Ordinary breathing is simply for the purpose of aerating the blood. The breathing of voice-production performs this function only incidentally, its main purpose being something far more complicated and difficult of execution. The large thoracic and abdominal muscles, some of them among the strongest in the body, must be controlled with precision and accuracy.

They work to a great extent in pairs, and of these pairs the one muscle opposes the other. For instance, the contraction of the diaphragm results in a protrusion of the abdominal walls (Fig. 664), and the strength of this protrusion depends upon the force of the contraction, which may be made very great. This outward motion of the abdominal walls is checked by the contraction of the abdominal muscles, which oppose in their action that of the diaphragm. In a similar way the costal muscles oppose each other, one set tending to elevate the ribs and the other to depress them. Thus the vocalist utilizes in breathing the principle of opposition of forces, by means of which perfect equilibrium of the various organs is maintained, and great strength becomes compatible with great delicacy of action.

Very little breath is required for the production of tone, and the function of the respiratory muscles is not so much to force breath out of the lungs, as to sustain and control the breath in the lungs and to give to the thorax a certain drum-like tension which is very essential to a resonant and well-balanced voice. Just as the drummer tightens his drum-strings,

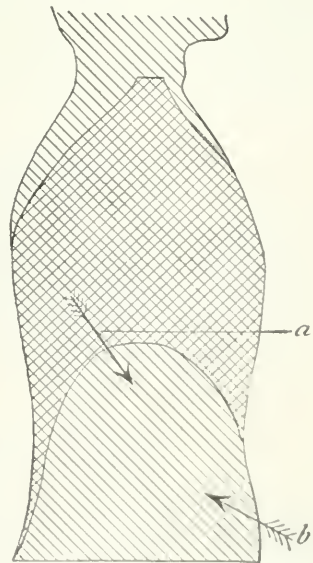


FIG. 661.—Schematic representation of the moving column of breath and the opposed action of the diaphragm (a) to the abdominal muscles (b).

so the vocalist contracts his thoracic and abdominal muscles. This may be best explained, perhaps, by describing the muscular action in the production of a single prolonged tone. There are two distinct processes: first, that of preparation, and second, that of actual tone-making. The preparatory process is similar to that which naturally takes place just prior to any other muscular act, as, lifting a weight or striking a blow. There is a slight inspiratory movement caused by the contraction of those muscles the function of which is to elevate the ribs. The diaphragm should have no part in this action, for its contraction depresses the ribs, and therefore it must be considered as an expiratory muscle. The second process, or that of production of tone, now follows, and consists, not, as many would have us suppose, in a complete relaxation of these inspiratory muscles, allowing the ribs to fall to their original position, but in a continuation of this tension and a simultaneous and stronger contraction of the expiratory muscles. The strength of this latter contraction should be proportionate to the strength of the desired tone and to the amount of breath which it requires.

Thus we have to deal with two distinct sets of muscles; one, the inspiratory, tending to elevate the ribs, and the other, the expiratory, tending to depress them. It is the nice adjustment of these opposing forces that gives to the thorax that degree of tension upon which the accuracy of breath-control and the consequent equilibrium and smoothness of the voice so much depend; and it is the education of these muscles which constitutes the first step in the cultivation of either the speaking or the singing voice. So far as possible, each muscle must be brought under perfect control and trained to respond promptly and accurately to an intelligent volition.

**The Vocal Bands** (Fig. 665).—These bands correspond to the strings of the violin. They are composed of small elastic threads of yellow fibrous tissue, and are from one-half to three-quarters of an inch in length, longer in the male than in the female, and situated in the larynx, or voice-box, so called because it encloses and protects these essential organs of voice (Fig. 542). The framework of this box is composed of cartilage, a material

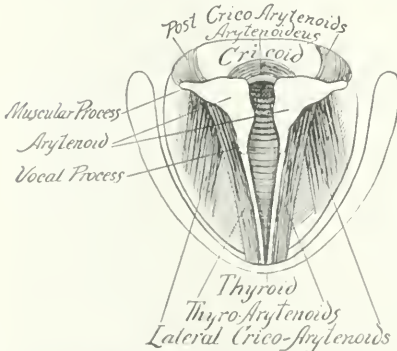


FIG. 665.—Diagram of the larynx, showing the vocal cords in relation to the arytenoids and the adductor, abductor, and tensor muscles.

more flexible than bone, yet more rigid than muscular or ligamentous tissue. These cartilages, nine in number—the thyroid, the cricoid, the two arytenoids, the two cornicula laryngis, the two cuneiform cartilages, and the epiglottis—articulate with one another by means of freely movable joints, and they are held together by numerous ligaments and controlled by still more numerous muscles. It is the motion imparted to the cartilages by these muscles which serves not only to place the vocal bands in the phonating position, but also to give them the necessary degree of length, weight, and tension. The arytenoid cartilages, to which the vocal bands are attached posteriorly, are freely movable at their points of articulation with the cricoid cartilage, and they are made to rock and revolve upon these points (Fig. 666) by means of various sets of muscles. The same principle of opposing forces applies here as in the management of the muscles controlling the column of breath. The contraction of one set of muscles tends to revolve

the cartilages in an inward direction, thus approximating the vocal bands; and the contraction of the opposing set tends to revolve them in an outward direction, retracting the bands and opening the glottis.

The *lateral crico-arytenoids* and the *arytenoid* combine in their action to close the glottis, and their opposing muscles, the posterior crico-arytenoids, tend to dilate the glottis; and it is by the nice adjustment of these forces that the vocal bands may be made to assume any position from that of close apposition to the sides of the larynx to that of close approximation in the median line, or even partial overlapping of the posterior edges, thus shortening the vibrating surface. When the vocal bands thus approach approximation, with only a narrow chink between the thin edges, their degree of tension is determined in the following manner: The thyroid cartilage, to which the vocal bands are attached anteriorly, is freely movable at its points of articulation with the cricoid, and its tilting forward upon the cricoid tends to remove it farther from the arytenoids (Fig. 666), and thus to make tense the vocal bands and also to elongate and attenuate them (Fig. 564). The forward tilting of the thyroid cartilage is accomplished in part by the *crico-thyroid muscle*, but chiefly by a muscle extrinsic to the larynx, the *sterno-thyroid*. The muscles opposing this downward and forward movement of the thyroid cartilage are the *thyro-hyoid* and *thyro-arytenoid* (intrinsic muscles) and the *stylo-hyoid* and *digastric* (extrinsic muscles). The importance of these extrinsic muscles of the larynx is not generally understood. In addition to controlling the degree of tension of the vocal bands, they serve to fix the larynx firmly against the cervical vertebræ during the emission of strong resonant tones.

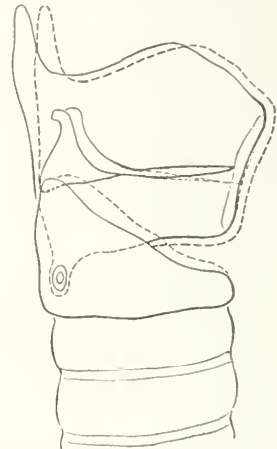


FIG. 666.—Diagram of the thyroid cartilage tilting upon the cricoid and stretching the vocal cords.

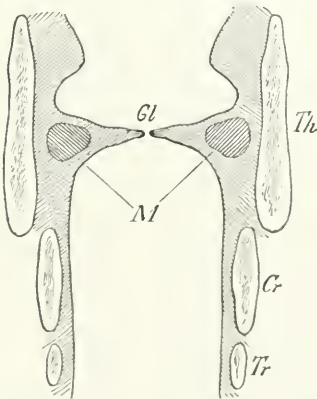


FIG. 667.—Section of the larynx at right angles to the vocal bands: *Gl*, glottis; *Th*, thyroid; *M*, thyro-arytenoid (Muecke).

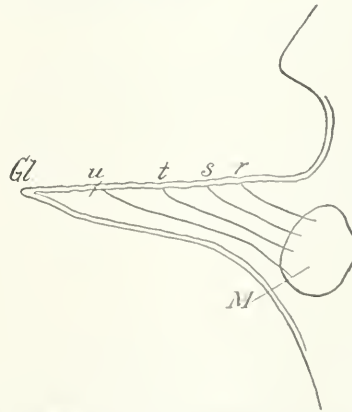


FIG. 668.—Schematic representation of the vocal band, showing the thyro-arytenoid muscle and "how it sends its fibers into the body of the band" (Muecke).

When this muscle is but slightly contracted the band may vibrate as far back as *r*; but when it is more and more contracted the extent of vibration is limited first to the point *s*, then to *t*, until finally, for the highest notes, only the part between *u* and the edge *Gl* is allowed to vibrate.

The *thyro-arytenoid* muscles also serve, by means of their intimate relation with the vocal bands, to limit the amount of their lateral vibrating surface and to adjust the lips of the glottis (Figs. 667, 668).



In the untutored larynx and throat these muscles are practically involuntary, and may perform their function very imperfectly; but in the process of the cultivation of the voice many of them may be brought under control of the will and thus trained to perform their function with greater efficiency. A laryngoscopic image of the larynx shows the vocal bands to be slightly separated posteriorly during ordinary breathing, and widely separated and flattened out against the sides of the larynx during deep breathing (Fig. 541). The extent of the separation depends upon the action of the abductor muscles, which turn the arytenoids outward. When the adductor muscles—those which turn the arytenoid cartilages inward—contract and the abductors relax, the bands come together in the median line and shut off all communication between the trachea and the pharynx. This always takes place immediately before the act of coughing or clearing the throat. But when the abductor muscles contract in conjunction with the adductors, the arytenoids become nicely poised upon their pivots, turning one way or the other by a minute fraction of an inch, as the vocal bands are required to be separated or approximated. It has been estimated that as slight a change as one-seventeen-thousandth of an inch is necessary to produce the wonderfully minute variations in pitch of which some of our noted singers are capable.

**The Resonators.**—Strictly speaking, the whole body is a resonator of the voice; and not only so, but the platform upon which the speaker or the singer stands, and the house in which that platform is built, are all in a certain sense resonators of the voice. The chief resonators, however, and those which contribute most to the individual characteristics of the voice and to its reinforcement, are the thorax, the trachea, the larynx, the pharynx, and the oral and nasal cavities with their contiguous structures.

The thorax, although not always so regarded, is one of the important resonant organs. The column of breath, resting as we have shown upon the diaphragm, receives vibrations from the vocal bands in the same way that the air above the bands receives vibrations; and when the ribs are slightly elevated and the muscles taut, the thorax becomes tensioned like a drum, and adds to the voice a peculiarly characteristic and pleasing quality.

The trachea is also an important resonator, and it is so constructed that the trained vocalist can increase or diminish its size both longitudinally and transversely, thus making it equivalent to a series of organ-pipes. It is for this reason, and because of the bellows-like function of the lungs, that the vocal mechanism is said to resemble that of the pipe-organ (see page 843).

The larynx itself probably has more to do with determining the quality of voice than any other part of the mechanism. Its size varies greatly in different individuals, and this variation is the chief cause of the wide differences in the qualities of voices. One illustration of this fact may be found in the marked change which takes place in the male voice at puberty. With the increase in size and density of the various parts of the larynx we have a sudden change in the quality of voice. The thin, childish treble grows into the heavy baritone or bass; and the transition stage is an important one, and should be treated with great care. Many a voice is injured irreparably by overwork at this period. Another illustration of the manner in which the size of the larynx determines the quality of voice is found in comparing the male and female larynges and voices. In almost exact proportion as the female voice is lighter and more flexible than the male voice, will the various parts of the female larynx be found to be lighter and more flexible than those of the male larynx. Of course, the differences in the other resonators contribute somewhat to these distinguishing characteristics, but the chief

cause exists in the laryngeal variations. The ventricles of the larynx—two depressions immediately above the vocal bands and parallel with them—and the ventricular bands situated immediately above the ventricles, influence the voice mainly by governing and directing the stream of vocalized breath after it leaves the glottis. The ventricles unite to form a little vestibule, the entrance to which is the chink of the glottis, or the space between the lips or edges of the vocal bands; and the exit is the space bounded by the corresponding thicker edges of the ventricular bands. During its entrance into the vestibule the breath is set in vibration or vocalized; this vocalized breath transmits its vibrations to the air already in the vestibule; and these vibrations are directed out through the ventricular exit into the upper larynx, the pharynx, and the mouth. The position of the larynx also has much influence on the voice. If it be held firmly fixed against the spine by the extrinsic muscles, the vocal resonance will be greatly increased. The entire spinal column may thus become a resonator of the voice.

We now come to a consideration of the pharynx as a vocal resonator. It is a funnel-shaped muscular bag with seven openings, and, like the mouth, it forms an important part of the alimentary canal, with the opening into the esophagus at its lower and posterior portion. The size and shape of the pharynx, however, and its general physical condition are important elements in the formation of voice. The posterior wall of the pharynx, a portion of which may be seen by direct inspection through the mouth, is well adapted

in its construction to gather the sound-waves as they are reflected from the epiglottis, and project them forward beneath the soft palate against the firm sounding-board formed by the hard palate and the teeth. Covering the solid, bony framework of the posterior wall of the pharynx we have the constrictor and palatopharyngeal muscles, which by their numerous contractions serve so to shape the reflecting surface that the vocalized breath may be directed toward any desired point. The training of these pharyngeal muscles forms a very important part of the work of the vocal teacher; and the care of the mucous membrane in this region is of the utmost importance to the voice. Inflammatory adhesions and thickenings act in various ways to injure the voice. They encroach upon the size of the pharyngeal space, they interfere with the free action of the muscles which have been mentioned, and they transmit to the larynx and trachea

their deleterious influence both by force of gravity and by continuity of structure. That the condition of the pharyngeal vault is an important factor in the resonance of the voice is shown by the marked change which takes place in the character of tone whenever this space is encroached upon by glandular or other hypertrophy. Adenoid vegetations, for instance, on account of their peculiar moist and spongy consistency, serve to damp the voice and destroy

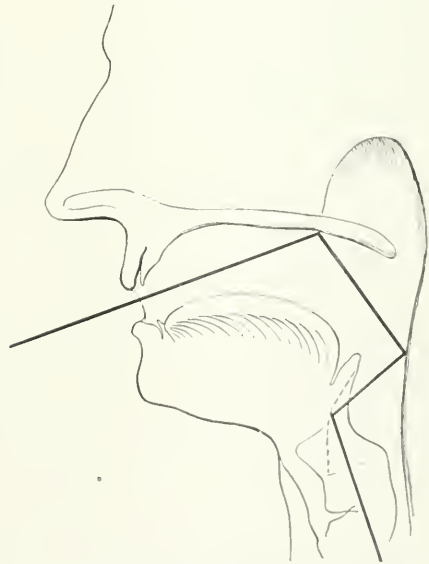


FIG. 669.—Diagram of the course of sound waves reflected from the epiglottis to the pharynx-wall, up to the palate, and thence out of the mouth.

the resonance that comes from this region. The posterior pharyngeal wall (Fig. 670) ascends vertically to a point about on a level with the floor of the

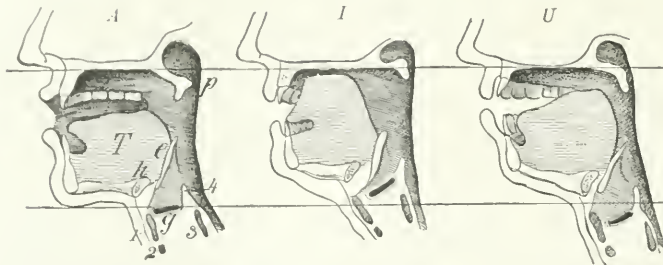


FIG. 670.—Section of the parts concerned in phonation, and the changes in their relations in sounding the vowels *A* (*ah*), *I* (*ee*), *U* (*oo*) (after Landois and Stirling): *T*, tongue; *p*, palate; *c*, epiglottis; *g*, glottis; *h*, hyoid bone; 1, thyroid; 2, 3, cricoid; 4, arytenoid cartilage.

nose, and then gradually inclines forward, making a graceful curve over to a point just above the choanae. The shape of this portion of the pharynx has been imitated in nearly all the artificial sounding-boards, whether constructed for the reflection of the voice or of the sounds of other musical instruments.

It is the function of the soft palate and the uvula to act as a kind of valve controlling the sound-waves and directing them either up through the pharyngeal vault into the nostrils when the palato-glossi muscles contract and diminish the size of the fauces, or out through the fauces into the mouth when the palato-pharyngei muscles contract and draw the palate back toward the pharyngeal wall, diminishing or cutting off entirely the passage-way to the post-nasal space. These to-and-fro and up-and-down movements of the soft palate during articulation are well demonstrated by a very ingenious instrument devised by the late Dr. Harrison Allen. It consists of a moderately stiff wire passed along the floor of the nostril until the distal end, which is slightly curved downward, rests upon the soft palate. The proximal end is placed against a revolving cylinder, and upon its prepared surface the up-and-down movements of the palate are accurately traced. This device furnishes a valuable aid to the study of an important part of the oral mechanism. The nasal chambers themselves and their communicating cavernous bones contribute much to the agreeable quality of the speaking voice, the nasal element being essential to the fullest and richest tones. For the sustained tones of the singing voice the palatal and pharyngeal muscles are tense, and the soft palate is held fixed against the pharyngeal wall, the sound-waves being directed entirely through the mouth. This tense condition of the palate is necessary in order that the palato-pharyngei and other extrinsic muscles of the larynx may perform their function. It is these variations in the size and shape of the vocal organs which determine the character or timbre of tone and distinguish one voice from another. There are no two voices alike, any more than there are two faces or two leaves on the trees alike. People are recognized by their voices as they are by their faces, and there are certain distinguishing characteristics in both which may not be changed. Not all voices may become great voices any more than all faces may become beautiful ones; but all voices may be improved by training, as all faces may be improved by care and cultivation.

Many of these resonators of the voice, such as the lips, the teeth, the tongue, the soft palate, the pharynx, and even the upper part of the larynx, may be regarded as belonging to an entirely different mechanism—viz., that

of articulation. We have considered the voice-producing organs; these are the speech-producing organs. The organs of voice manufacture the sound, and the organs of speech articulate it. The mechanism of articulation is as important as that of phonation to the singer as well as to the speaker; and these two mechanisms must work together in perfect harmony if we would have good speech and good song. The articulation of the singing voice differs in no respect from that of the speaking voice. It consists simply in the moulding of sounds into syllables and words which mean something to the ear, whether they be the sounds of speech or of song.

The palate is probably the most important organ of articulation. Fairly intelligible speech has been shown to be possible without a tongue, but the lips and teeth could more easily be dispensed with. Furthermore, the larynx and lungs are not absolutely indispensable to the production of tone, as has been proved by at least one person who can speak and even sing without any larynx and with the lungs entirely cut off from the pharyngeal and oral cavities. Not all persons, however, would learn to speak without a tongue or without a larynx. Indeed, most people speak badly enough who are not thus handicapped; and it is interesting to notice how slight a deviation from the normal in some of these organs will result in the most glaring defects of speech. All irregularities of the vocal and speech organs, whether acquired or congenital, should be corrected as early in life as possible, before the habits of speech are fully formed.

**The Hygiene of the Voice.**—The hygiene of the voice includes the hygiene of the whole physical organism, for there is scarcely any portion of the body which is not related directly or indirectly to the mechanism of the voice. Disease of any kind is reflected in the voice as clearly and as undeniably as in the face, and the cheerful ringing tones of exuberant health are known to us all. Therefore, whatever contributes to the well-being of the physical organism contributes also to the well-being of the voice.

It is a mooted question among specialists whether catarrh of the stomach is the cause of catarrh of the upper respiratory and vocal passages, or whether catarrh of these passages is the cause of catarrh of the stomach. This much we know, that the pharyngeal and oral cavities are continuations upward of the alimentary canal, and are lined with the same membrane; that the color and general condition of the tongue are clear indications of the condition of the stomach below. A coated tongue means a coated stomach, and, if I may use the expression, a coated voice. The care of the digestion, then, is of the first importance to the vocalist, both because of its direct influence upon the organs of voice and because of its indirect influence through the circulatory and nervous systems. Strong healthy nerves are essential to a good voice, and these nerves are dependent upon good blood properly circulating; and this, in turn, is dependent upon good digestion, and this upon good food thoroughly masticated. Articles of food affect the voice also by direct contact with the organs, and therefore highly-seasoned and stimulating food should be avoided. Tea, coffee, liquors, and the after-dinner cigar may injure the voice in the same way, and can be beneficial only when they offset these deleterious effects by assisting in the digestion of nourishing foods. No absolute rule can be laid down regulating the diet of individuals, for what is food for one is poison for another. Someone has well said that every man over forty years of age should be his own physician as far as diet is concerned, and I would place the age limit ten years earlier. The man who cares more for his stomach than for his voice will never make a great singer or a great speaker. The vocalist must eat to live, and not live only to eat;



and no little self-denial, in this and in other respects, is the price which must be paid for a well-preserved voice.

Madame Patti has said that a draught of air has always been the dread of her life. The cutaneous surface of the body should be classed among the organs of respiration. Indeed, it has been called the "outer lungs," on account of its absorbing and eliminating capacity. The skin should be kept active, therefore, by suitable exercise and judicious bathing. General exercise should never be carried to the point of fatigue, lest it result in the needless expenditure of that vital energy which is so necessary to the working of the vocal mechanism, and in the abnormal development of certain muscles, which prevents that harmonious action and nice adjustment and co-ordination so essential in the management of the vocal machinery. The matter of bathing should also receive careful attention. Many people bathe too much, and many more bathe too little. It should be remembered that the hot bath extracts heat from the body, and heat is only another word for energy. Only the very vigorous should take frequent hot baths, and they should be taken only upon retiring. The cool, daily plunge may be indulged in to advantage by many; but perhaps the cold hand- or sponge-bath, both morning and evening, is better for the average person. The feet, the upper chest, the neck, and the face should be hardened by frequent cold douches. These parts are the vulnerable ones in the singer and speaker.

As to the matter of dress, I am inclined to think that the less dress the better. As some one has said, "Man is not by nature a clothed animal." Whole races have been swept from the face of the earth, with not one left to tell the tale, because they were compelled by their conquerors to wear clothes. Heavy winter flannels, which may not be changed to suit the conditions of the moment, are positively contraindicated because they interfere with the breathing of the outer lungs. In other words, they interfere with the natural functions of the skin, throwing its work upon the mucous membrane or "inner skin," as it has been called. The natural result of this overwork of the mucous membrane is congestion, with all its deleterious effects upon the voice. We say we have "taken cold;" but "cold" does not express it any more than would "heat" or "indigestion," for either is probably a more frequent cause of the condition.

**Voice-training.**—This brings us to the training of the voice, which is, after all, the most practical part of our subject. "There are methods and methods," as some one has said, "and there is good in every one of them, but no one of them has a monopoly of the good."

Methods have their origin in the necessities of certain cases. We are too apt to reason in this way: My method eradicated my faults in vocalization and developed my voice to its present magnificent proportion; therefore it will eradicate your faults and develop your voice,—forgetting that no two of us are exactly alike, and that my faults are not necessarily your faults, nor is my voice your voice.

I do not believe, therefore, in so-called methods for the training of the voice, any more than I believe in iron-clad rules for the treatment of disease. Quinin is a good thing for malaria, but not every case of malaria may take quinin. The vocal teacher should use methods just as the skilled physician uses remedies. He should study the necessities of the case, he should make a thorough diagnosis, if you please, of the conditions as they exist, and then decide upon his plan of procedure, thus putting vocal training upon a scientific basis. This necessitates a thorough knowledge of the organs involved, and of their functions, both natural and special. The physical training of the

voice, reduced to its final essence, consists in the development and specializing of certain definite muscles. This, of course, can be carried to its highest perfection only when there is a corresponding psychical development. The one stimulates the other, and it is a question which takes precedence in the evolution of the singer or speaker. Written rules for the training of the voice are impracticable—one must have the living teacher, the choice of whom should be made with great care, for more harm than good is often done by bad teaching.

The ear is also an important factor in the training of the voice. It must be taught to stand guard over every tone, to become a fair and unprejudiced critic, exacting to the last degree. Defective hearing, therefore, is one of the greatest obstacles to vocal development. The man who cannot see his faults will rarely, if ever, eradicate them; and every man must perceive his vocal imperfections through the medium of the ear. Therefore the greatest care should be taken to preserve the functions of this organ. Acute inflammations of the ear should be promptly attended to by the skilled aurist; and at the first intimation of uneasiness in the ear, or beginning deafness, professional advice should be sought—for then, if ever, can the hearing be saved. An ounce of prevention at this time is worth a ton of cure later on. The cause of deafness is often traced to some catarrhal trouble in the nose or throat; and, fortunately, the vocalist generally discovers this trouble before the ear becomes seriously affected.

# OPERATIONS UPON THE AIR-PASSAGES.

BY JOHN O. ROE, M. D.,

OF ROCHESTER, N. Y.

## DEFORMITIES AND DEFECTS OF THE NOSE.

NASAL deformities are generally divided into idiopathic or congenital and traumatic or acquired. The former are usually regarded as mere accentuations of certain racial types; but no special deformity can be said to be governed merely by racial influences. Congenitally-deformed noses may, however, vary from a mere rudimentary knob to a very large and greatly distorted organ. Traumatic or acquired deformities sustain little or no relation to the natural conformation of the nose, and therefore may assume any form in which accident or disease happens to leave them.

From a surgical point of view, nasal deformities are to be divided into those in which the normal parts are present, but distorted from their natural position, and those in which there is a partial or complete absence of these parts. The first comprise those which affect the bony portion of the nose and those which affect the cartilaginous and soft parts.

Deformities of the bony portion may be subdivided into the *vertical*, in which the dorsal profile is distorted, being too convex or too concave, and the *lateral*, which, when viewed from the front, present abnormal contour, whereby the bony portion may be either spatulated or deflected. Deformities of the cartilaginous portion include excess or deficiency in the tissue of the *tip* of the nose, or its distortion from normal direction, and collapse or abnormal expansion of the *wings* of the nose.

## TREATMENT.

The treatment of nasal deformities differs in those in which the normal parts are present, but distorted from their natural position, and those in which there is a partial or complete absence of these parts.

In the former, treatment consists merely in restoring the parts to their normal position; whereas in the second class the deficiency must be supplied by tissues taken from some other part of the body, or by artificial or mechanical supports. In all cases, however, after securing or maintaining full respiratory patulency, the main cosmetic indication is to restore the symmetry of the nose. A nose which was originally proportionate to the face will, if deformed, appear very unsightly; while the same nose, although made one or two sizes smaller, will have a more or less handsome appearance if its different parts are perfectly symmetrical. So symmetry, and not size, is to be considered.

In the correction of deformities of mere displacement all operations should be done subcutaneously and without wounding the skin, in order to avoid scars which might be as unsightly as the original deformity. In some

instances fracturing of the nasal bones and of the septum also may be necessary in order to restore the parts to their normal position.

In all intranasal operations full asepsis of the instruments and hands is essential, and of the nasal vestibules, where the vibrissæ form a natural sieve to strain out all foreign matter from the inspired air. Mild antiseptic spraying and mopping of the accessible portions of the nasal chambers and nasopharynx should follow, and may be repeated after operation if clearly demanded; but rather better nasal results, with far less danger to the ear, have followed the abandonment of too much after-spraying and syringing.

**The Convex Vertical Deformity of the Bony Portion of the Nose.**—In correcting this deformity the skin is first raised from the deformed or projecting portion by incising within the nostril through to the under side of the skin. The opening is then enlarged sufficiently to admit the instrument required for the removing of the redundant tissue, which may be bone-scissors, rongeur forceps, a slender saw, or a chisel, according to the nature of the tissue to be removed. Care must be exercised not to remove too much of the redundant tissue, lest a depression more unsightly than the original deformity be left in the top of the nose. This accident more readily happens when the vault of the nasal passage extends all the way up into the projection, for the nasal chamber is very easily opened into on removing the projecting angular portion. After this redundant tissue has been removed, a gentle compress should be placed over the dorsum so as to maintain the integument coaptated against the nose, and worn from four to six days or until the skin has united to the tissue beneath.

**Concave Vertical and Spatulated Deformity.**—The operation consists in filling in the depressed and lowering the unduly prominent portions. As the depressed or saddle-back deformity, as it is termed, is usually the result of injury causing displacement of the tissues, it is not often that the nose can be made as large as it originally was; but it can be made symmetrical by filling in the low places with tissues taken from the elevated portions. This is done by raising the skin from the dorsum by incising from the inside of the nostril, as before, and, if the nose is flattened out, removing to the top of the nose the displaced tissue found at the sides, by making flaps and turning them upward. Bony ridges or projections are in this manner to be used by carefully sawing them off with a sharp slender saw. If the displacement of the tissue is into the nares, it can be utilized in the same manner by turning the flaps made from it up under the skin upon the dorsum of the nose.

When it is necessary to refracture and raise the depressed nasal bones, this is done according to a method which I have devised—by an incision, as before, sufficiently large to admit one blade of a pair of stout forceps, which is slipped under the skin raised from the nasal bone; while the other blade, covered with a rubber hood or adhesive plaster to avoid lacerating the mucous membrane, remains in the nasal passage. Sufficient force is then exercised to fracture the bone, assisted by slightly rotating or twisting the blades, when it can be raised to the desired position. The bone on the opposite side is then, if necessary, fractured in the same manner, and they are held in the desired position by an internal support, as described in the Treatment of Fractures of the Nose (page 1122). If the end of the nose still projects above the line of the central portion, it can be lowered, as later described.

Many plans for the making of a new nose, as will be presently described, have been used for correcting these minor defects. There is no advantage in nor necessity for performing external operations when we can work subcutaneous



ously to avoid wounding the skin and also utilize the normal tissues instead of resorting to mechanical supports for the correction of these deformities.

**Deflection of the Bones of the Nose.**—In correcting this deformity it is usually necessary to fracture the nasal bones, and on one side force the bone outward, on the other side inward. It may be also necessary to fracture the nasal septum, more or less, and to overcome the distortion of the cartilaginous portion. After fracturing the bones they should be held in the desired position, as in the treatment of fracture of the nasal bones. Great care must be exercised in the performance of these operations, and they are only to be undertaken under the most favorable conditions (see page 1119).

**Excessive or Deficient Development of the End of the Nose.**—The operation for *excess* (commonly termed pug-nose) consists in turning back the mucous membrane and, from the interior of the nostril, removing enough of the redundant tissue at the end to make the nose symmetrical and to bring the end down on a line with the dorsum. The mucous membrane is then replaced and supported by a light antiseptic compress in the interior of the nostril. Any associated expanded condition of the wings should be dealt with as will presently be described. After the operation the nose is to be held in the desired shape by the metallic form (Fig. 641), applied to the out-

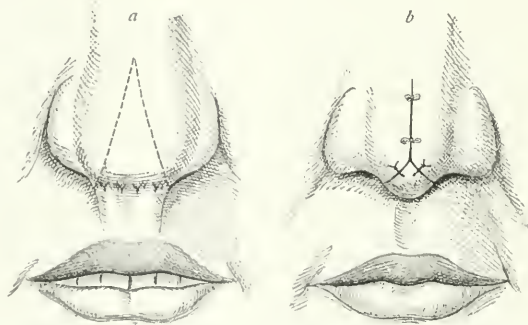


FIG. 671.—Operation for lengthening and narrowing the tip of the nose (Linhart).

side of the nose for several days, until healing in the exact position has taken place.

*Deficiency of the tip* is corrected by raising the skin and filling in the defect by means of plastic operation according to the conditions found. Where the frenum is short or defective, this can be rectified by taking flaps from the floor of the nose or upper lip. The upper portion of the tip can be filled in with tissue taken subcutaneously, in the form of flaps, from the sides of the nose and cheeks (see also Fig. 671).

Often a flattened condition of the end of the nose is associated with a lateral expansion of the alae, and is relieved by correcting the latter condition.

**Deviation of the Tip of the Nose from the Median Line.**—As this deformity is almost always associated with deviation, distortion, or dislocation of the triangular cartilage of the septum, it is usually necessary to straighten the septum, and in some cases this will be found to be all that is required to correct the deviation of the end of the nose.

This operation is performed by loosening the cartilage, and sometimes the columna also, along its junction with the superior maxilla, and making a vertical incision through the cartilage at the bend or point of deflection. The cartilage is then placed in position and held there with transfixion-pins or

splints or hollow plugs placed in one or both nostrils. Sometimes incisions are necessary to overcome the elasticity of the cartilage at other points. In most cases this is best done with a bistoury. With a finger in one nasal chamber we can determine when the cartilage has been completely incised from the other side without cutting through the mucous membrane beyond. By leaving the membrane intact on one side, it serves as an excellent splint to maintain the edges coaptated while healing. In some cases the end of the nose may appear to be deviated by reason of an excessive development or expansion of the shield cartilage on one side alone, the other side being straight and normal. Sometimes, when the lateral shield cartilages are deformed or distorted to one side, it is also necessary to freely incise them from the inside or loosen their attachment in order to overcome such elasticity as may tend to reproduce the deformity. The nose should then be held in place with a splint on the inside (Fig. 644) or a form on the outside, or sometimes by both, until it becomes fully fixed in the desired shape and position.

It is not infrequently the case that distortion of the end of the nose is associated with a deviation of the whole nose, in which cases it is necessary to combine the operations for correcting the deviation of both the osseous and cartilaginous portions of the nose.

**Collapse or Expansion of the Alæ.**—Correction of the deformities of the wings, whether collapsed or expanded, consists in carefully incising in several places from the inside the lower lateral and sometimes also the upper




FIG. 672.—Operation for reducing redundant tissue of the alæ (Linhart).

lateral or shield cartilages (see Fig. 645). It may be necessary in some cases of greatly expanded or inflated alæ to excise a V-shaped portion of the cartilage to permit of its being moulded to the desired shape. The parts are then to be placed in position by first inserting into the nostrils an internal support of the desired size and shape, consisting of a short tube of suitable material, and should be held there by an external shield until firmly fixed.

In case of expanded nostrils it will generally be necessary after the operation to apply only the external support or compress to maintain the parts in the desired position until the tissues become more fixed; whereas in the collapsed condition of the wings the external support is rarely necessary, the nostrils requiring simply to be expanded to their normal size and shape, and maintained in this position until the tendency to collapse is overcome.

Should the expansion of the alæ, however, be due to distention from an intranasal growth or foreign substance, the necessity for the removal of the growth or body is self-evident before the deformity of the nostrils can be overcome, and further intervention may be unnecessary (see also Fig. 672).

**Stenosis of the Nostril.**—The nostril or the vestibule of the nose may be so small upon one or both sides as greatly to impede proper respiration. This may be a congenital smallness or deficient development or an acquired lesion due to cicatrization after burns, lupus, or syphilitic ulceration. Acute inflammation of furuncular or other nature may temporarily close the nostril, but this would call only for evacuation of pus or similar obvious inter-

vention. For the simple stenosis, dilatation by frequently forcing in the lubricated finger may be sufficient, or the wearing of a tube for a time may be required. When the constriction cannot be thus easily overcome, divulsion may be necessary, care being taken to maintain the passage well dilated until after the parts have healed. Where loss of substance precludes success by these simple methods, plastic operation by flaps or skin-grafts will supply the deficiency.

The cutting away of a stenosis where the mucous membrane is already too limited in extent should not be attempted, for the reason that the surface will invariably grow together throughout the extent of the incision. In these cases it is best to raise the skin or mucous membrane from the contracted portion and remove the cicatricial connective tissue from beneath, then replace the parts and dilate the nostril to its fullest extent until healed, when they will remain in place, leaving the opening of the vestibule free.

#### PARTIAL OR COMPLETE ABSENCE OF THE NOSE.

There are two principal methods by which defects and deficiencies of the nose may be supplied or corrected, according to the condition of the case: by rhinoplasty, using only living tissues, and by internal artificial supports.

**Rhinoplasty** may be complete or partial. It is termed complete when the whole or the greater portion of the nose is supplied by tissue from some near or distant part; and incomplete when a small portion only is supplied.

(1) The Indian method, which takes the tissue from the forehead, was originated in Hindustan. It is serviceable only in supplying nasal defects in which there is a moderate loss of tissue; for when there is destruction of

the entire bony framework of the nose, sufficient material is not obtainable from the forehead to fill in the defect, and the transplanted tissue sooner or later drops through the large opening, and the nose sinks again to the level of the face.

In order to ascertain the size of the flap, a nose as desired is modeled of wax or plaster of Paris, and the portion that has been destroyed is outlined upon this model. Then by moulding a pattern of paper or thin leather over this model the exact size required is accurately determined, which should be made about one-third larger, in order to allow for the shrinkage of the tissues on healing. This pattern is then turned upward and spread out upon the forehead, the part corresponding to the lower portion of the nose uppermost, and outlined with ink or tincture of iodine to indicate the portion of the skin to be cut out. If the height of the forehead is not sufficient for the size of the flap, more

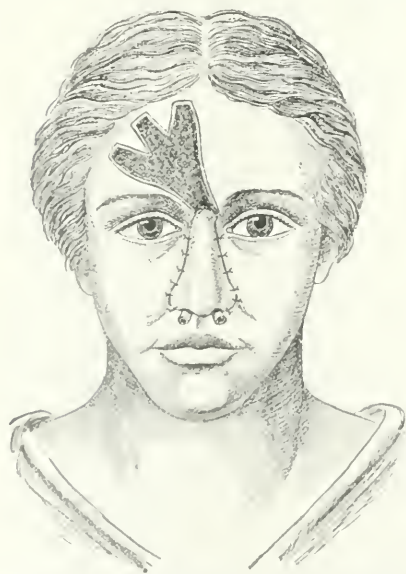


FIG. 673.—Rhinoplasty by the Indian method, with oblique flap and digitations for building the columna and alae (Malgaigne).

room can be obtained by cutting it out obliquely (as shown in Fig. 673), care being exercised not to cut too near the eyebrow, lest the latter be drawn up by the retraction of the scar. The flap should be cut out by a single

firm stroke of the knife, so as to afford an even, smooth edge. The flap is then raised and made to include the periosteum, or the anterior table of bone is included by chiselling it off, if desired, and the flap brought down and stitched into place by very fine gut, silk, or horsehair sutures.

In making this flap the pedicle should be sufficiently long to admit of being twisted upon itself, usually from left to right, so as not to compress the vessels, and wide enough to include plenty of nutrient vessels, especially the angular artery.

The low portion of the nose can be still further filled out by a flap taken from the root of the nose, made after the frontal flap has been cut out, so that all the skin of the bridge and root of the nose between the flap and the defect can be utilized. The width of this flap should be the same as the neck of the frontal flap, and left attached along the upper border of the opening. This supplementary flap is first stitched into the opening, the integument looking inward, after which the frontal flap is brought down over it and stitched into place.

Before these flaps are made the nose should be prepared for their reception by freshening the edges of the gap. Any cicatricial tissue that should be removed from the borders can be turned into the center, in the form of a flap, to assist in elevating the dorsum.

The twist in the pedicle usually forms an unsightly prominence, which can be obviated somewhat by cutting one side longer than the other, and afterward rectifying it by operation. The edges of the hole left in the skin of the forehead are then sutured together as closely as possible and any denuded space should receive a sprinkling of Thiersch grafts, so as to leave the least amount of disfigurement on healing. The coaptation of the edges is considerably facilitated by raising the skin for a considerable distance on either side so that it can be slid toward the center, care being exercised not to constrict the frontal flap. The new columna of the nose may be formed at the same time from a tongue from the forehead included with the flap, or from the upper lip, as will be described further on.

The after-treatment consists in maintaining the parts aseptic by light boric acid and bichlorid dressing very carefully applied. The dressing should not be changed oftener than required; and secondary hemorrhage should be guarded against by light pressure when it seems imminent. The flap may remain dark and edematous for some time, and finally unite most successfully. The swelling can sometimes be relieved by leeches or slight scarification.

A number of variations of this method have been practised by different surgeons, and nearly every operator has some modification peculiar to himself.

Verneuil made one incision along the median line of the depressed portion of the nose and two transversely at the base and tip respectively, and dissected up the two lateral flaps. He then raised an oblong flap of the requisite size from the middle of the forehead, leaving it adherent between the eyebrows by a pedicle, turned it directly downward, and stitched the two lateral flaps together over it; the skin of the flap lying inward, so that the raw surface came against the under surface of the lateral flaps.

(2) **The German and French Method.**—This consists in the formation of the nose from tissues taken from the side of the face. It was first proposed by Dieffenbach, and later modified by Nélaton, to avoid the frontal scar left after the Indian operation.

This operation consists in making a double flap, one from each side of



the nose, including a sufficient portion of the cheek, joined together by a common pedicle at the root of the nose. These flaps are then united in the center and carefully stitched together. A pattern of the desired form is made, so that the flaps are accurately cut in such a shape as to form the column of the nose and also sufficiently long for turning in to form a double edge to the nostrils (Fig. 674), which are kept open by hollow vulcanite tubes until the healing is complete and all tendency to cicatricial contraction is overcome.

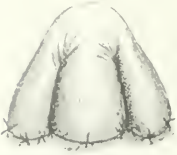


FIG. 674.—Formation of column and alae from the flap taken from above.

Nélaton modified this operation by making additional parallel flaps from the cheek just outside of the two primary lateral flaps; and these were brought to the center and stitched in place under the two primary flaps, which were then united along the median line of the nose.

When the tissue of the dorsum of the nose is gone and the septum is still in place, the latter can be utilized, as Mr. Bell and Nélaton suggest, and held in place by transfixing the septum and both the flaps at their outer lower edges with a straight needle. The wounds in the cheek may be partially closed by sutures, but are usually left to heal by granulation—the resulting depression adding to the relative prominence of the new nose.

(3) **The Italian or Tagliacotian Method.**—This was first practised by Branca of Sicily, by Bojani of Calabria, and Alexander Benedetti, professor of Anatomy at Padua, about the year 1495; but it was Tagliacozzi who, about the year 1587, so popularized the method by his skill and dexterity that it has since been known by his name. It consists in cutting from the biceps region of the arm a thick flap for the formation of the nose. Parallel incisions are made about four inches in length and of sufficient width to allow for the subsequent contraction on healing. This flap is raised except at the attached ends. A dressing is passed beneath to prevent reunion, and the wound, as practised by Tagliacozzi, was left open to granulate; by modern methods, however, the parts are maintained aseptic and the edges of the wound stitched together beneath the flap. At the end of about a week, when the flap has become sufficiently shrunken and hardened by exposure and covered with granulations, it is liberated at the upper portion, and then permitted to shrink still more for another week or two before it is attached to the face.

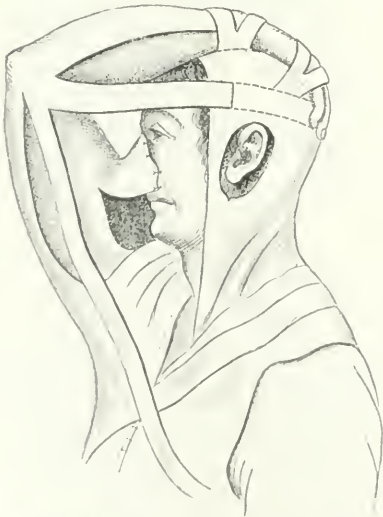

FIG. 675.—Italian method of rhinoplasty from the arm, which is immovably secured to the head until union of the flap has taken place. Linhart.

This usually requires about ten days, when the pedicle is severed and the arm released. This severed end of the flap is then carefully cut, shaped,

and stitched, so as to form a symmetrical end to the nose. Owing to the painful nature of this operation and the distressing position of the arm, it is not frequently resorted to.

Von Graefe made a flap with but one pedicle, and implanted it at once. This is inferior to the original plan, as it does not obviate the constrained position of the head and arm and lessens the chances of union, and is followed by much greater shrinkage of the nose after the operation. Warren of Boston took a flap from the anterior portion of the forearm, about two inches above the wrist, transplanting the flap at once, and in some cases succeeded in separating it on the fifth day.

**Partial rhinoplasty** consists in supplying minor defects of the different portions of the nose, usually of the alæ, of the tip and the columna, which have been destroyed by lupus, syphilis, by injuries, or by mutilations. While less extensive, these operations are often more important to the function of the nose than the complete rhinoplasty.

Each case requires a special study and oftentimes the greatest skill in order to adapt the operation to the conditions found.

**The Restoration of the Alæ.**—The alæ when destroyed may be formed from the same side of the nose, from the opposite or sound side, from the cheek, from the upper lip, or by the jumping process.

The lateral flap method of Denonvillier consists in dissecting a triangular flap from the sound tissues above the defect, which can be brought down on a line with the normal wing of the nose. The vertical incision is begun just above the end of the nose, leaving sufficient tissues to nourish a flap, and is carried up about half the length of the nose, as required, where a second incision is made obliquely downward to the upper and outer angle of the alæ.

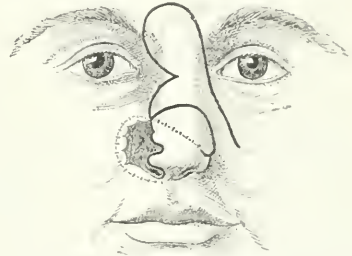


FIG. 676.—Partial rhinoplasty of alæ and columna by a flap from the bridge of the nose (Linhart).

The flap may be taken from the bridge of the nose (Fig. 676), from the opposite alæ, from the cheek, or from the lip, as the circumstances of the case dictate, and slid into place or carried across untouched surfaces by the jumping process.

**The Restoration of the Tip of the Nose.**—Mere shortness of the tip is best corrected by sliding down a  $\Lambda$ -shaped flap (Fig. 671). Keegan's operation consists in making a flap on each side of the bridge and base of the nose and extending the lateral incision downward to the upper border of the root of the nasal alæ. These flaps are dissected out from above downward, leaving the flaps attached at the lower border. These flaps are to be cut of the size necessary to fill the defect at the end of the nose when turned downward, sufficient allowance being made for contraction while healing.

A flap is then taken from the forehead in the usual manner, twisted and turned downward, and stitched into the place from which the other flaps have been removed. This is made sufficiently long to form the columna of the septum if lacking, the opening of the nostrils being maintained by hollow splints of the proper size and shape.

In Ollier's operation the incision is carried from a point near the center of the forehead to a point on a level with the lower border of the alæ. The skin only is dissected up from one side; while on the opposite side is included the periosteum, which underlies the upper portion of the flap, and the left

nasal bone, which is separated by means of a chisel. This entire flap then is carried downward sufficiently far to form the contour of the end of the nose and stitched there, the bony portions being secured with wire sutures. The space left by the removal is filled by a bony outgrowth developed from the periosteum, slid down from the forehead to cover the opening.

In some of these cases it is possible to supply the whole defect at one operation, but quite often secondary operations are necessary to form the columna and improve the opening of the nostrils.

**Restoration of the Columna of the Nose; Utilization of the Upper Lip.**—Many methods have been employed for the restoration of the columna. The Italian method, though not frequently employed, consists in taking a flap from the palmar surface of the hand and suturing it in place so as to form the column of the nose, the hand being held firmly in place until the flap has become united to the nose, which is similar to the Tagliacotian method of restoration of the nose. In Heuter's method the columna is formed from the skin covering the dorsum of the nose. The flap is cut out obliquely, to facilitate its rotation into position, and so cut that the rotation takes place at the tip of the nose, which renders it thicker at that point and thereby assists in elevating the tip of the nose. For the purpose of rendering the columna more rigid he recommends that the upper portion of the flap should include the periosteum covering the nasal bones, so that the formation of osseous tissue will afford a more rigid support.

*Wood's method* consists in making a flap from the central portion of the upper lip, between the cutaneous and the mucous surfaces, extending downward to, but not through, the vermilion borders of the lip. This flap is turned upward and covered by flaps taken from the cheek on either side.

*Dieffenbach's method* consists in making two vertical incisions through the entire thickness of the upper lip, thus making a tongue about one-fourth inch in width, which is entirely freed, except at its upper attachment. This is turned upward and united to the remains of the old columna and to the alæ by fine sutures. The mucous membrane of the lip, which looks outward in its new position, soon becomes skin on exposure to the air. The cut surfaces of the lip are then brought into apposition and united exactly as in the operation for harelip.

**Utilization of a Finger.**—The first to make use of the finger to supply the loss of a nose was Hardie of Manchester, England, in 1875, at the suggestion of his house-surgeon, Mr. Tyler, and it was next employed by Prof. Sabine of New York, in 1879.<sup>1</sup>

In 1893 the writer performed a similar operation on a lad of sixteen years of age, whose nose had been destroyed by hereditary syphilis, leaving a considerable aperture, around which the skin was very much wrinkled, since it had not been destroyed, but had lost its central support, which gave the lad a very repulsive appearance. The incision was made under the lower border of this wrinkled skin, which was dissected out for the insertion of the finger. The left ring-finger was prepared by removing the last phalanx, so as to do away with the nail, was denuded of its cuticle as far up as it was to be inserted beneath the skin, and the remaining portion was split in the center on the palmar side down to the bone. The tissues forming a double flap were turned outward and stitched to the edges of the skin of the nose after the insertion of the finger in the place prepared for it. The arm was then firmly held in place by plaster-of-Paris bandages, similar to the Tagliacotian method, until the union between the finger and nose had taken place, when

<sup>1</sup> *Illustrated Medicine and Surgery*, 1882, p. 37.

the finger was disarticulated at the knuckle. When the finger had become solidly united to the nose a portion of the bone of the finger was cut out, so as to leave sufficient redundant skin out of which to form the columna and the nostrils, the latter being kept open by hollow plugs.

The result was at first exceedingly satisfactory; but at the end of a year the nose had very materially diminished in size, due to a settling of the finger down through the aperture between the nasal bones, which was too wide to give it support.

This method would be exceedingly serviceable in some cases where the aperture was too small to permit the bone of the finger to drop through; but in cases where this aperture is too large, this method is far inferior to that of inserting mechanical supports beneath the collapsed tissues.

**The Employment of Artificial or Mechanical Supports.**—The use of artificial supports is required in those cases only in which the central cartilaginous or bony supporting frame is wanting, as is often the result of the ravages of syphilis. This method was first suggested by Letievant, who inserted beneath the skin of the depressed nose a supporting framework of aluminum. C. Martin improved upon this by substituting platinum. The device as used by Martin, which is the one most commonly employed, consists of a triangular piece of platinum, bent in the shape of the nose, the upper end of which rests on the nasal spine of the frontal bone, the lower wings being supported by two arms, one on either side, the ends of which are embedded in the superior maxilla (Fig. 677). The dimensions must, of course, correspond to the size of the nose to be supported.

The form is introduced by first performing the Rouge operation, in which the upper lip and nose are cut loose and turned up over the face so as to avoid wounding the skin, and also to gain direct access to the superior maxilla for drilling the holes in which to securely anchor the artificial bridge. The holes should be made in the inner side of the canine eminences, about on a level with the floor of the nose, care being taken not to enter the antrum. The location of the holes should be determined by the most careful measurements, in order to bring the artificial bridge in the median line of the face.

This apparatus has also been used by some for elevating the center of the nose in those cases of depression in which the bony framework is present. In these cases it invariably ends in failure, for it must necessarily be inserted between the skin and the osseous structure, leaving a closed space between the metallic bridge and the bone. No drainage is afforded, and sooner or later irritation is excited, the contained discharges decompose, and ulceration results. In the most favorable of these cases the device has been retained from one to five years, but in every case, sooner or later, some accident happens to the nose; or, on account of some complication, the artificial support must necessarily be removed, leaving the nose in a worse condition than

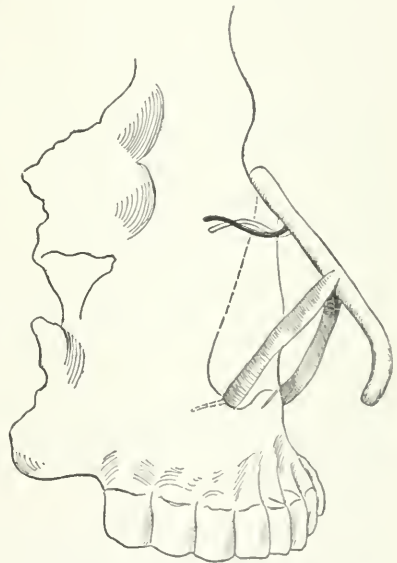


FIG. 677.—The Martin bridge as used by Weir (N. Y. Med. Jour., Oct. 22, 1892).



before. This method of support is only successful and only necessary in those cases in which the bony support is gone and where thorough drainage takes place into the nasal cavity, thereby reducing the irritation to a minimum.

In a case where the entire central support of the nose was gone, including the entire vomer, together with the nasal and lachrymal bones, the nose being completely flattened on the face, the writer inserted a support according to the method already described. The bridge was made of hard rubber, with arms made of a gold and platinum alloy. The arms constituted one piece, a band running over the form in a groove made for its reception and securely riveted to it. This made a much lighter bridge, quite as strong and less irritating than platinum, and exceedingly satisfactory. But whatever form of bridge is used, it should be prepared as far as possible beforehand, leaving only the position and width of the arms to be adjusted to the situation of the holes made in the jaw at the time of the operation.

It is important in these cases that the most thorough aseptic precautions be observed on inserting the bridge, and that the bridge be so inserted, so moulded, and so smooth as to prevent any friction or unequal pressure upon any of the soft parts; and it is also important that the supporting arms should be buried deeply in the maxilla, so that they are not easily displaced. Martin employed a bridge with attached arms for insertion in the maxilla to hold the bridge in place; but the plan of cutting the bridge and the supporting arms from one piece of metal when platinum is used, as suggested by Hopkins, is far better.

Before undertaking any operation for the restoration of the whole or any portion of the nose, we should ascertain if the disfigurement is the result of an injury or disease. If the latter, we should be certain that the disease, be it syphilis, lupus, etc., is completely arrested or cured. Also before deciding on the operation to be adopted, we must thoroughly investigate the condition of the different parts of the nose and also of the face in order to determine which region, the forehead, the cheeks and face, or the arm, will best supply the requisite tissue free from scars or disease and leave the least disfigurement.

In performing these operations the greatest care and skill are required to insure the best results. Each case requires the most careful study, for as Prof. Gross has well said: "For repair of these various defects some of the nicest processes of the art and science of surgery are required," . . . and that "if the operation is entered upon heedlessly or without due preparation of the part and system, failure will be almost certain."

#### DEFORMITIES OF THE NASAL SEPTUM.

Of the internal structures of the nose, the septum is the part most frequently deformed, presenting deviations from the median line, spurs, ridges, hyperplastic thickenings, and exostoses.

Deviation of the septum (see page 917) may affect the whole septum or some part of either the osseous or the cartilaginous portion. It is most frequently found in the cartilaginous portion, and next in point of frequency at the junction of the cartilaginous and osseous portions, while deviation of the posterior portion of the vomer is exceedingly rare. The division of deviations into osseous, cartilaginous, and osseo-cartilaginous, as suggested by Jarvis, is by far the most natural, and further attempts at classification are unnecessary. Thickening on one side of the septum is sometimes deep-

tive, giving the septum the appearance of being deviated to that side, when the plane of the other side may be perfect. Sometimes the septum is curved at different parts in such a way as to give it the shape of the letter S.

In some cases the deformity may consist in the septum being located to one side of the median line, although not deflected or curved, causing one meatus to be larger than the other.

Spurs, ridges, and hyperplastic thickenings may be found on any portion of the septum, although they are most frequently found located: First, along the line of junction of the vomer with the superior maxilla; secondly, along the line of junction of the anterior border of the vomer with the triangular cartilage and the lower posterior part of the perpendicular plate of the ethmoid; and thirdly, along the line of junction of the anterior border of the ethmoid with the triangular cartilage. They may be either unilateral or bilateral. Those located along the junction of the vomer, triangular cartilage, and superior maxillæ are more often bilateral than when elsewhere.

Deviations of the septum are very often associated with deformities of other portions of the nose, and also of the superior maxilla, and with a small high-arched hard palate, approaching a scoliosis of the whole face.

The **treatment** of the different deformities of the septum consists in the restoration of the parts to their normal condition. The importance of correcting these deformities, which almost always produce more or less nasal obstruction and reflex disturbance, can scarcely be overestimated.

The treatment is palliative or radical, the **palliative** measures consisting in the removal of such conditions as may have influenced an abnormal growth of the septum, such as the removal of adenoid growths, enlarged tonsils, or of any conditions which may interfere with the proper development of the nose during infancy and childhood, and the reduction of hyperplastic thickenings by medical measures.

The radical treatment may consist in forcing the septum into its proper position without the employment of cutting or fracturing instruments, by exerting pressure upon the convex side by the introduction into the nostril of plugs or tents, slowly forcing it over into place; these methods are, however, usually painful and unsatisfactory, and are not to be recommended.

The more surgical treatment consists in the forcible straightening of the septum. The methods employed, according to the conditions found, are: removal of the prominent portion of the deflection with knife, chisel, saw, scissors, drills, needle and snare, or punch; destruction of the prominence by caustics, electrolysis, or galvano-cautery; incising the septum with a knife or cutting-forceps, and restoring it to position by finger pressure, by the employment of pins, or of forceps having flat parallel blades; fracturing the septum by means of comminuting forceps.

Deviation of the septum is almost always associated with spurs, ridges, exostoses, etc., which have resulted from the same cause as that which caused the deviation, and these should be removed before the septum is corrected. If the spur or ridge is cartilaginous it is most easily removed with a cartilage-knife, although good authorities recommend its removal with the galvano-cautery, and some by the use of electrolysis, inserting both poles into the outgrowth at the same time.

Osseous outgrowths are most easily removed with a nasal saw or drill, or the bone-scissors or rongeur-forceps may be employed. H. Allen lifted the lip after Rouge's method and chiselled away exostoses of the floor. The drills may be burrs of various forms or the trophines devised by Curtis, and may be driven by the dentist's treadle-engine or an electro-motor. Good-

willie and others protect the soft parts with a shield which covers the outer side of the burr or trephine.

When the spur is associated with a marked thickening of the vomer on that side, the use of the trephine, as proposed by Wright, is to be recommended in some instances. A hole is made from the anterior to the posterior end of the deviation in such a manner that it goes as close to the mucous membrane on the other side as possible without perforating it. Into this resultant tunnel a slender saw is inserted, and the exostosis is removed by sawing upward and downward from this point (see Fig. 679).

The use of the snare and transfixion-needle for the removal of cartilaginous spurs is sometimes to be commended. The portion to be removed is transfixed with the needle, and the wire loop of the *érasneur* is then passed over the needle (see Fig. 680) and drawn up tightly, and the engaged portion cut through.

Caustics, electrolysis, and galvano-cautery are employed in some cases if the cartilaginous spurs are not large and other operative measures are rejected by the patient. Electrolysis in these cases is very warmly advocated by Casselberry.

**Forcible Correction by Forceps.**—The forceps most commonly used are those devised by Adams, illustrated in Fig. 572. The disadvantage of this instrument used alone is that it will simply force the septum to the median line without correcting the usual redundancy; it is mainly serviceable in the correction of osseous deformities, because in the cartilaginous portion it does not in any degree overcome the resiliency of the cartilage. In still ruder manner Hewetson's forceps press open the stenosed naris, crushing the weakest point. Browne claims that "the crushing of the turbinated bodies and bones, and fracture of the outer wall of the nose, which must take place in some instances, appear to give rise to no troublesome symptoms."

A number of modifications of Adams's forceps have been devised. Jurasz made them with detachable handles, so that the blades could be left *in situ*, held by means of screws, after the correction was made. Garrigou-Desarenès, to overcome the resiliency of the septum, had one blade convex and the other correspondingly concave, and tightened with a screw.

Hope of New York has devised a forceps to be used in connection with the Adams forceps in operating on the cartilaginous portion of the septum. One blade has a steel pin which is received into a corresponding opening in the other blade (see Fig. 678). The operation is then marked out with a line of punctures with this pin, which so weaken the cartilage that it is easily fractured. This instrument may be used in the thin portion of the bony septum.

For the purpose of incising the cartilage so as to overcome its resiliency Steele employed a stellate punch with radiating blades (see Fig. 678), and held the parts in place by means of plugs inserted into the previously obstructed nasal chamber. Asch accomplishes this with a pair of curved cartilage-scissors, similar to buttonhole-scissors (see page 918).

J. B. Roberts uses pins for holding the deflected portion in place after the resiliency of the septum is overcome with a knife. This same plan is also adopted by Watson, after having obliquely cut the septum along its greatest convexity and set it over in the center. The pin, which should be gold-plated to avoid corrosion, is inserted either through the dorsum of the nose or from the nostril so as to hold the flaps together, and the point is embedded in the floor below or the septum behind sufficiently to hold the pin in place until the parts are united.

Gleason makes a horseshoe incision through the lower side of the deflected portion and pushes the flap through the opening thus made. A dressing is inserted on the convex side of the septum to control bleeding and to hold it in place until the parts are united.

For the correction of the osseo-cartilaginous deviation, Fig. 678 represents a pair of fenestrated forceps devised by the author in 1891 for the purpose of fracturing the septum. One blade of the forceps is fenestrated, while

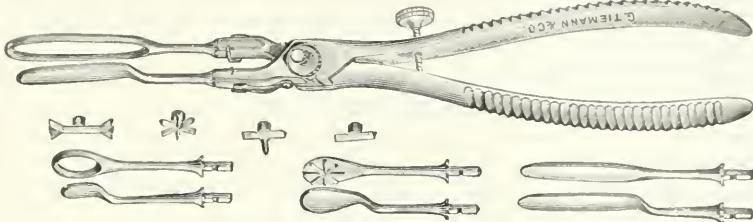


FIG. 678.—Roe's septum-forceps, with fenestrated blade for limited comminution, and interchangeable blades, making a Hope or Steele or Adams forceps as desired.

the other is made sufficiently narrow to fit loosely into the fenestrum of the opposite blade. The distance which the second blade passes through the fenestrum is regulated by a screw in the handle.

The fenestrated blade is inserted on the concave side of the septum, which is fractured sufficiently to overcome the resiliency. The advantage of these forceps is that fracture of the septum can be accomplished without wounding or lacerating the soft parts. The parts are then forced into the median line by a small nasal spatula, and a dressing is inserted on the convex side of the septum sufficient to hold it in the median line until it has become permanently fixed. These blades are detachable, and may be replaced by Adams's plane blade or by Hope's pin or Steele's stellate punches—the penetration of the latter being controlled by the screw so as to spare the farther mucous membrane, if desired.

The redundancy of tissue<sup>1</sup> which is frequently associated with the deviation requires removal to complete the procedure. Such projections may be removed in part before straightening, or at a subsequent operation; but it is still better to determine the extent of needed excision and to have this form a part of the main operation. Older operators were much afraid of perforating the septum, lest a permanent hole result; but with neat, clean operating there is little reason to fear any failure of the mucous membrane to unite unless there has been too much excision of tissue.

In all these cases the parts should be rendered aseptic by thoroughly cleansing them with a solution of bichlorid, 1 : 5000, both before and after the operation. The most aseptic and satisfactory form of dressing is a cotton plug, made by winding cotton over a small metal plate of sufficient size to fit the meatus. Before insertion iodoform is blown into the nostril with a powder-blower, and the plug dipped into a solution of bichlorid. If thorough aseptic precautions are taken it usually can be left for three or four days before removal. If further support is required the nostril should be re-irrigated, cocainized, and a fresh plug inserted.

Hollow splints made of hard rubber (Fig. 573) are employed by Asch and others, but they cause much more irritation, are less aseptic, and I have not found them so satisfactory as the cotton plugs.

<sup>1</sup> [It is too rarely recognized that hyperplastic redundancy is the usual cause of the deviation.—E.D.]



In nearly all cases if the operation is properly performed and all elasticity of the septum overcome, support to the septum is required for three to five days, until the provisional exudate is thrown out, which is ample to keep the fragments *in situ* and the septum in the median line without any return of the deflection.

#### DEFORMITIES OF THE TURBINATED BONES

are of not infrequent occurrence. Normally the turbinated bones project from the outer wall of the nasal chamber and turn downward and outward like a scroll, as shown in Fig. 679.

Instead of their normal bending downward and outward they are frequently twisted and distorted, projecting across the nares into contact with the septum.

Deformity of the inferior turbinated bone is frequently associated with hypertrophy of the turbinal body; while that of the middle turbinated bone

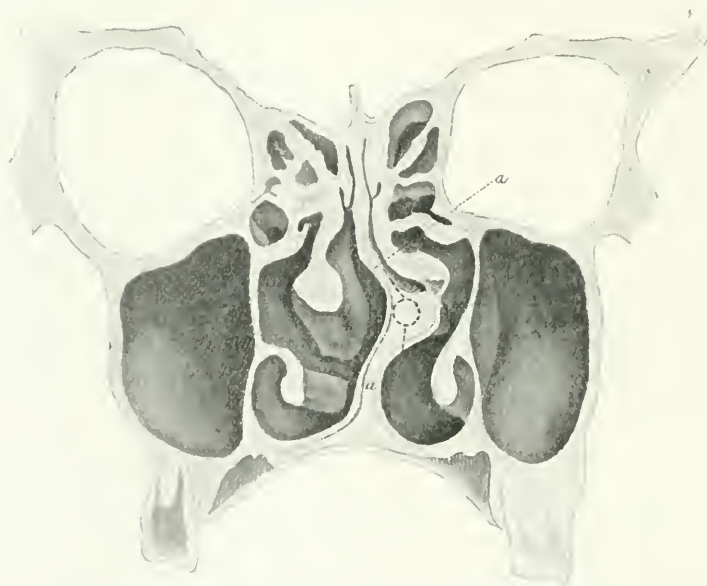

FIG. 679.—Transverse section of nasal chambers, antra and orbits, showing marked deviation and hyperplasia of the septum, with synchial attachment to the left middle turbinal. The dotted lines indicate Wright's method of drilling and sawing (Zuckermandl).

is associated with a marked thickening of the bone itself, which obstructs the passage and impinges firmly against the septum, or forces it over, as shown in Fig. 545, and is the cause of much irritation, frequent sneezing, and not infrequently persistent headaches.

In the case of the lower turbinated bones being distorted without hypertrophy of the soft parts, they can be fractured and bent backward, usually with a pair of nasal forceps. But the middle turbinated bone is best dealt with by sawing off the projecting portion and fracturing and forcing the remaining part backward against the outer wall of the nose with a small spatula, holding it in place by a light antiseptic cotton dressing until the bone becomes sufficiently fixed and the passage is permanently free.

**Reduction of Hypertrophy of the Erectile Tissue.**—The inferior turbinal bodies are more frequently found hypertrophied than any other por-

tion of the intranasal tissue, owing to the extreme vascularity of this tissue and its sensitiveness to atmospheric changes. The next in point of frequency is the middle turbinal, and third, the erectile tissue covering the posterior portion of the septum.

The principal methods employed for the removal or reduction of these hypertrophied tissues are cauterization with chemical means or the galvano-cautery, and removal with a snare or cutting instrument.

Where the hypertrophy is small, due mainly to thickening of the interstitial connective tissue, chromic acid fused on the end of a small flattened probe gives very satisfactory results. The part should be anesthetized with cocain and then thoroughly dried to prevent the acid from liquefying and running down on parts below. After the acid is applied the part should be dried with cotton and sprayed with an alkaline wash.

Trichloroacetic acid and strong lactic acid may be substituted, although less effective. The former is claimed to give a specially aseptic eschar.

In those cases in which the turbinal swelling is mainly of a vascular character, linear incisions with the galvano-cautery through the tissue down to the bone, so as to obliterate the deeper vessels, is far preferable to chemical caustics (see pages 888 and 910).

Delavan has suggested deep submucous incisions with a slender knife for severing and obliterating these vessels.

When there is a large amount of interstitial hypertrophy, as we find in chronic cases of nasal stenosis, the tissue is best removed with a Jarvis snare (Fig. 680), held in place, if necessary, by a transfixing pin.

When this tissue cannot be engaged by the snare it may be removed with nasal scissors. Care, however, should be exercised in every instance not to remove too much of the turbinal tissue, lest there result a dryness of the pharynx from lack of sufficient moisture imparted to the inspired air.

Hypertrophy of the vascular tissue on the septum is best destroyed with galvano-cautery used very cautiously. Masses occur also on the upper portion of the septum, caused by the irritation from contact of the turbinal. These when small in amount may be removed with chromic acid, or if large they can be cut away with a nasal knife. In operations in the nose there is little or no danger of the mucous membrane failing to cover the denuded part, even after the removal with the knife of quite an extensive portion; while if destroyed with the galvano-cautery, the mucous membrane is replaced with connective or cicatricial tissue. This is particularly the case in operations on the septum.

**Synechia of the nasal passages** may be congenital, but is most frequently found after disease or operation in the nose when the two opposite surfaces have been denuded at the same time, granulation-tissue shooting across and uniting the parts during the process of healing. Occasionally a spur grows across into contact and becomes attached to the turbinal, when a synchondrosis or synostosis may take place (Fig. 679). It has often proven a very obstinate condition to remove, for if the band is bodily cut away it

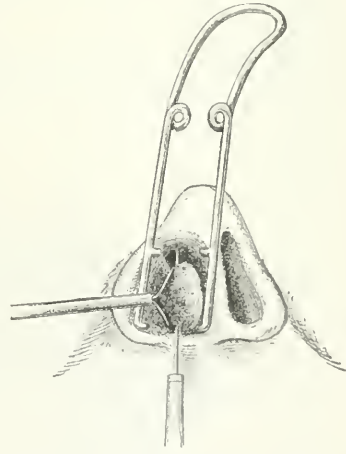


FIG. 680.—Hypertrophy of the anterior end of the right lower turbinal, transfixed by a Jarvis needle and encircled with a snare for excision.

will almost invariably reform. The best plan for preventing its return I have found to be in cauterizing one side only with the galvano-cautery, after cutting the band away, for the reason that cut and cauterized surfaces do not readily grow together. Previous treatment to shrink the tissues and separate the surfaces greatly facilitates operation and cure.

Any granulation-tissue that may shoot out can be touched with chromic acid. Another excellent plan is to wear a small metallic plate covered with asepticized cotton until the parts on the two sides are healed. This method is more troublesome and disagreeable to the patient than the other.

**Removal of Neoplasms.**—The operative methods of dealing with these formations vary as much as the structures themselves. *Myxomata*, or nasal polyps, are the most frequent (see page 1075). They may constitute simply small polypoid growths, very easily removed, or they may be multiplied like a bunch of grapes hanging from its parent stem, or they may constitute one huge growth, occupying the entire nasal chambers and extending into the accessory sinuses.

Various agents, as chlorid of zinc, iodin, carbolic acid, alcohol, have been recommended for local application or injection into the growth; but they are rarely effective and not advisable except when the polyps are exceedingly small.

Previous to the invention of Jarvis's snare these growths were usually removed by divulsion—grasping the polyp with a stout pair of forceps and

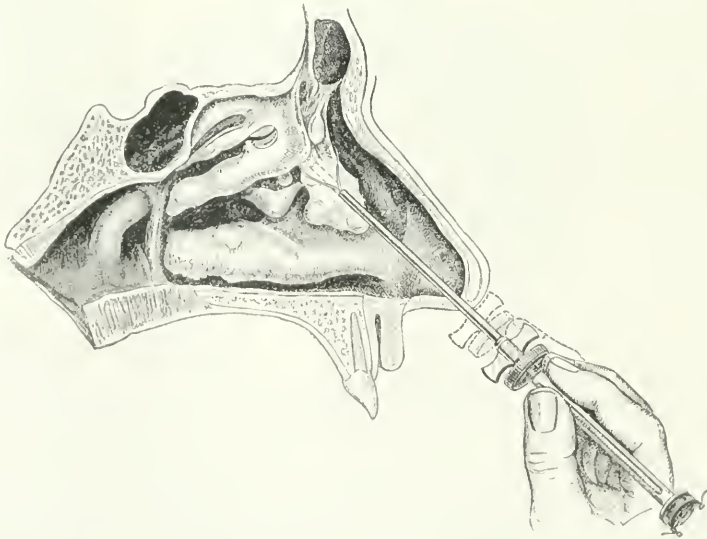


Fig. 681.—Polyp descending from the infundibulum engaged by the snare loop, which is tightened to secure it by pushing forward the cannula (after Zueckerkandl).

twisting it off. But with Jarvis's snare and the use of cocain these operations have been greatly improved. Fig. 681 represents the application of the snare to a polyp in the nose.

The snare, armed with a No. 5 piano-wire, is carefully introduced over the growth, then by a gentle forward-and-backward movement it is worked up as near the base of the growth as possible before tightening. This is best done by holding firmly with thumb and index-finger the outside tube to which the wire is attached while the cannula is forced forward by the middle finger

pressed against the nut. Escape of the growth is thus avoided; and after it is secured, the cutting is done by screwing down the nut as fast or as slow as seems best.

The return of the growth can often be prevented by cutting the pedicle with a slender knife, taking a portion of the periosteum or a scale of the bone with it.

In case the polyp involves the whole of a turbinated bone, it may be necessary for the eradication of the growth to remove the entire bone.

If the growths are small, I have found the interstitial injection of a saturated solution of bichromate of potash into the neck of the growths exceedingly effective in not only destroying them but preventing their return.

When the ethmoid cells are involved they require curettement in order to reach the deep portions of the growth.

After removal of the growth the parts should be kept clean with an antiseptic wash and carefully inspected. Any recurrence or small portion that escaped removal should be removed or destroyed. The patient, at frequent intervals, should return for an inspection, to insure against a return of the growth.

**Fibroma and Angioma.**—In the removal of myxomatous growths and nasal polypi very little hemorrhage is encountered; but in cases of the firmer and more vascular growths it is often profuse. This is best avoided by using the galvano-cautery loop or the cold-wire snare. In the use of the galvano-cautery loop care should be taken not to have the wire too hot. If brought to a dull-red heat only, it closes the vessels as it passes through the tissue; but if raised to white heat it cuts through quickly like a knife, and leaves the vessels open. In one case of angioma of the nose the writer removed a portion with the galvano-cautery loop which was followed by profuse hemorrhage, requiring plugging of the nose; whereas a very much larger portion of the same growth was removed very slowly with the cold-wire snare, and all hemorrhage was avoided.

The chief difficulty of removing from the nose large growths with the snare is in engaging the growth in the loop. This is most easily accomplished with a small flexible copper wire having a shot attached to one end and a stout silk thread to the other. The head of the patient is thrown backward and the shot end insinuated along the upper side of the growth. When the shot has reached the posterior wall the head of the patient is erected and the shot is slowly pushed down into the pharynx.

A similar one is passed through the lower meatus below the growth, when both wires are grasped with a pair of forceps and pulled out through the mouth. The copper wire is then removed and the ends of the thread tied together, when, with the aid of the finger behind the soft palate, the thread can be drawn up around the base of the growth. One end of the thread, preferably the upper end, is then attached to the steel or platinum wire with which we wish to encircle the growth and drawn round it and attached to the instrument for removal. In this manner some of the largest growths of the nasal passages may be removed with little risk of hemorrhage.

In some cases in which it is impossible to pass a loop around the growth, before recourse is had to the knife, electrolysis, best applied by the bipolar method, will sometimes be successful in arresting if not obliterating the growth. The bipolar needle should be plunged directly into the base of the tumor, and the current employed should be as strong as the patient can comfortably endure, cocain, of course, being first applied.

Enchondroma of the nose, as well as the septal enchondroses, can usually



be removed with a knife. In some cases it may be removed with the snare or with the galvano-cautery. Electrolysis has been commended, but seems to the writer a tedious and useless procedure when the outgrowth can be so quickly and effectively cut away.

**Osteomata** found in the nose are of two varieties, one being composed of cancellous and the other of ivory structure. They are usually located in the upper part of the nares, and may involve the accessory sinuses, often causing fetid discharges and pain from pressure. They are usually attacked with the saw or drill, the ivory variety being often removed only with the greatest difficulty, unless the point of attachment yields readily to the chisel or other instrument.

**Malignant growths** should, if possible, be totally extirpated, otherwise the partial removal tends to increase the rapidity of their growth. Partial removal may, however, in some cases be expedient. In sarcomatous growths the galvano-cautery loop will sometimes be successful in arresting the advance. A case of the kind was reported by Lincoln, in which the thorough removal of the growth with the galvanic snare caused the complete arrest of the growth for years.

In the case of carcinoma, it is only through complete extirpation of the growth that success is attained. The most radical and effective method of reaching the interior of the nasal chamber is that devised by Rouge of Lausanne, which consists in dissecting up the upper lip close to the superior maxilla, together with the whole soft structures of the nose, and turning them backward over the forehead, when the nasal chambers come plainly into view and become directly accessible for any operative procedure. Partial or total resection of the bony parts may be temporarily made, or the superior maxilla or other parts may have to be excised.

Coley reports many cases of sarcoma successfully treated with serum of streptococcus and bacillus prodigiosus. I have succeeded in destroying a sarcomatous growth with the injection of a saturated solution of bichromate of potash, already referred to in connection with polypoid growths.

#### EVACUATION OF ABSCESS OF THE NASAL CAVITY.

**Abscess of the septum** may result from an injury or other causes (see pages 899 and 1117).

The **treatment** consists in the evacuation of the pus by a free incision with a small nasal bistoury. The cavity should then be washed out with a bichlorid or hydrogen-dioxid solution injected into it. When the abscess is bilateral an incision is required in one side only, for the reason that the two sides almost invariably communicate. The cavity is then kept collapsed by pressure on each side by means of a suitable dressing placed in each nostril. This should be removed and the parts cleansed and dressed daily until cured.

This condition must not be mistaken for a hyperplasia on the septum or an eochondrosis of the cartilage. The question is quickly settled by exploration with a probe.

**Abscess of the turbinal body** sometimes occurs as the result of inflammation of the turbinated bone going on to necrosis. Sometimes these abscesses are chronic, and the discharge mistaken for that originating from an accessory sinus.

The **operation** consists in the free opening of the abscess and the removal of any necrotic bone that may be present, which is best done by a small burr run by an electric motor. The dead bone can be eradicated in this manner

without cutting away the turbinal, which should be removed only when entirely diseased.

#### BONY AND CICATRICIAL OCCLUSION OF THE POSTERIOR NARES.

Bony occlusion of the posterior nares is often congenital. In operating for its removal the size and extent should first be ascertained by the combined exploration of the anterior nares with a curved probe and with the finger in the posterior nares. When this is determined it should be removed with either a drill or bone-cutting forceps. Great care must be exercised, for the position of the bony formation frequently renders the operation extremely hazardous. In the case of a child that recently came under the care of the writer, the posterior nares were completely closed with a firm bony formation which had existed from birth. This was removed with a Curtis drill passed along the floor of the nose; when an opening had been made, one blade of a small right-angular bone-cutter was passed through and the bone chipped off until an opening of the requisite size had been made. Cicatricial tissue may close the opening secured, and must be removed as fast as it forms. Trichloroacetic acid has been praised as the cautery least apt to be followed by return of the occluding tissue.

**Stenosis of the naso-pharynx** due to the adherence of the soft palate to the pharynx may be congenital or it may be due to ulceration resulting from acute inflammation, as in diphtheria, from struma or tuberculosis; but is most commonly the result of syphilis, which in children may be hereditary, but in adults is usually acquired. The stenosis is rarely complete, there being nearly always a small opening between the two cavities. Complete stenosis in the case of a child recently came under my observation.

The readiness with which severed cicatricial adhesions reunite renders these operations extremely unsatisfactory; accordingly a great many devices have been resorted to to prevent reunion of the parts after having been separated, such as the insertion of rubber tubes, plates of hard rubber, metal rings, air-bags, and mechanical dilations. The most successful plan is that devised by Nichols, who with a curved needle passes a heavy silk thread through each side of the cicatricial tissue and ties it in the center. The knot is then slipped around back through one of the openings so as to be entirely out of the way, lying in the naso-pharynx, and is allowed to remain there until complete cicatrization has taken place around the thread in a manner similar to the treatment of web-fingers. The string is then removed, and by inserting an angular knife in one of the openings the adhesion between the two openings is cut away.

The best plan for keeping the cut surfaces apart until healed is by means of a small flat piece of hard rubber attached to and held in place by a string passed through each nostril and tied in front of the septum. In some cases daily dilatation of the parts is necessary to maintain the proper size of the opening, and in moderate stenosis only such dilatation may be necessary.

#### SURGICAL INTERVENTION IN DISEASE OF THE ACCESSORY SINUSES

has been dealt with earlier (page 966), and but few points need be here added.

**Maxillary Sinuses.**—The disease of the maxillary sinus most frequently necessitating surgical interference is empyema. There are five methods for gaining access to this cavity: (1) Through the natural opening;

(2) through a tooth-socket or alveolus; (3) through the canine fossæ or the canine eminence or the malar ridge; (4) through the inferior meatus; (5) through the hard palate.

Acute or subacute inflammation of the antrum can frequently be treated successfully through the natural opening, which in most cases is easily found with Hartmann's, or preferably with Myles's, silver tubes (Fig. 593). The second method, however, is the one most frequently resorted to, because it is the easiest and, as a rule, causes the least disturbance to the patient. In many cases the floor of the antrum is divided into separate compartments by septa. It is therefore important that the internal orifice of the opening through the alveolus should be wide enough to include and cut away any septa that may be present in order to afford free drainage. In many cases it is advisable to make the opening long and narrow and wider on the inside by separate insertions of the drill; or the two outer holes can be made a short distance from each other and the intervening space sawed out. By making an oblong opening in this way the food does not so readily enter, and in nearly every case a tube can be dispensed with. When a tube is required, Myles's soft-rubber tube (Fig. 590) is the best.

Some authors advise making a very small opening, which, in the experience of the writer, is unpractical, as it does not afford sufficient room for the exploration and free drainage of the cavity or the removal of growths, which are frequently found to be the exciting cause of the discharge. In case the premolar teeth are sound or a very large opening is necessary, it is best made through the canine fossa. In cases of growth in the antrum, it is frequently necessary to make a very large opening to permit free inspection of the interior and thorough removal of the growth.

The writer's method of opening the antrum through the canine fossa is first to incise and turn back the soft parts where the opening is to be made, then to drill a small hole near the lower side, which permits a preliminary exploration of the interior of the cavity with a probe to determine its size and shape. A slender saw is then introduced through this hole, and a circular button of bone of the desired size is sawed out of the anterior wall. It is usually desirable to make the opening sufficiently large to freely introduce the finger, which is a valuable aid for exploration. This large hole also affords ample space for the removal of growths or other diseased conditions and a ready access for treatment. This method of removing the bone with a saw I have found to be far superior to the use of the chisel commonly resorted to.<sup>1</sup>

When the outer bony wall of the nasal chamber is thin, an opening through it is easily made with a small curved trocar and cannula; but when this wall is firm, it is best made with a curved spiral drill attached to an electric motor. This method has often been found serviceable in recent cases, but it is not a route generally to be recommended, for the reason that the floor of the antrum is frequently much below the plane of the floor of the nose, and discharges from the nose will find their way into the antrum. It is also impossible through this opening to remove growths or to explore or properly treat the antrum when extensively diseased.

Opening through the hard palate is sometimes resorted to, and conditions may arise where it is the most advisable method, although generally it is not to be recommended, on account of the readiness with which food and other substances may be forced through the opening from the mouth.

**Disease of the Ethmoid Cells.**—Disease of the ethmoid cells is very often associated with nasal polyps, and in these cases the anterior ethmoid

[<sup>1</sup> Dr. Myles's opening further back is described on page 974.]

cells are most frequently affected; but when there is necrotic condition of the turbinated bone, the posterior ethmoid cells and also the sphenoid cavity are also very frequently involved. When unassociated with nasal polyps, the tissues covering the middle turbinated and ethmoid mass frequently have a boggy, doughy character and a pale color, resembling a polyp. In other instances the enlargement of the turbinal consists of a true connective-tissue hypertrophy, causing pressure on the septum and much reflex disturbance. In some cases the bone is denuded, which is very readily detected with a probe, and has been termed by Woakes "necrosing ethmoiditis." This condition is usually attended with purulent discharge, headache, supra-orbital and peri-orbital neuralgia, and sometimes the vision in the eye of that side is interfered with, or choked disk is found on ophthalmoscopic examination.

The only effective treatment is free opening of the cells and curettement of the diseased portion. In order to reach these cells, more or less of the turbinal body requires removal. A boggy hypertrophy of the middle turbinal bodies is best removed with a Jarvis snare, which is frequently employed for removing the turbinated bone; but for this purpose Myles's cutting-forceps is preferable, for the crushing of the bone by the snare is not desirable. Burrs and drills are employed by some. Bosworth employs a burr run by a hand motor, and depends largely upon the sense of touch with the instrument to locate the point for operation. This method, however, is hazardous, except for one thoroughly skilled in these operations. When the cells have been freely opened and sufficiently curetted to break down all the diseased cell-walls, the cavity should be thoroughly washed out with an antiseptic solution and packed with iodoform or sublimate gauze. This should be renewed as often as required, usually daily, and the healing process stimulated by mopping with a silver-nitrate solution, 30 grains to the ounce. If the purulent discharge continues, it indicates that all of the diseased cells have not been reached, or that the discharge comes from a neighboring sinus, which should be investigated.

**Disease of the Sphenoid Cavity.**—As already stated, disease of the sphenoid cavity is often associated with disease of the ethmoid cells and maxillary sinus, and is usually determined by tracing the source of the pus, aided by the use of the aspirating needle, or exploration with a probe. The opening in the cavity can sometimes be found by passing a probe directly backward along the lower border of the middle turbinal body, using that as a guide. Oftener it is higher and more lateral, so that the probe must curve outward and cross the posterior third of the turbinal (see Fig. 682). Empyema as in the maxillary sinus can also be determined by the effervescence on injecting into the cavity a small quantity of hydrogen dioxid. This cavity sometimes becomes the seat of polypoid or other growths and degenerated tissue, requiring curettement. In simple empyema the cavity should be washed out and medicated with a syringe having a long, slender nozzle.

Other diseased conditions frequently require a free opening of this cavity, which can be made by drilling through the anterior wall. This can safely be done by first ascertaining the distance of the anterior sphenoid wall from the end of the nose and marking the distance on the drill; then by allowing sufficient for the penetration of the wall of the cavity, we know exactly the distance beyond which the drill should not be passed. Ordinarily the entering of the drill into the cavity is at once perceived by the operator. When a sufficient opening has been made by the drill or the rongeur (see page 984), the growths or other diseased tissues are removed by curettement, the cavity is cleansed with an antiseptic solution and packed with iodoform or sublimate



gauze, as in the case of the ethmoid. Afterward the cavity requires frequent irrigation with a medicated solution until the parts are healed. After irrigation of the cavity the head should be held downward in such a position that the cavity will be entirely drained.

**Disease of the Frontal Sinuses.**—Disease of the frontal sinus is almost invariably associated with disease of the nasal cavity—most commonly polypoid growths or enlargement of the middle turbinal—obstructing the infundibulum. Empyema of the frontal sinus is most frequent, although it may be the seat of growths and degenerations. The disease of this cavity is indicated by the flow of pus from the upper portion of the semilunar hiatus, and by pain and tenderness to pressure over and around the eye.

The treatment of frontal-sinus disease is by drainage and injections of medicated solutions into the cavity. This can be reached by two routes: through the infundibulum or natural opening, or by an external incision through the bony wall. Through the infundibulum a slender silver catheter may be passed and the sinus irrigated and medicated, and in recent cases a cure is effected in a short time; but in chronic cases it must be reached through an incision in the outer wall. The incision should be made along the eyebrow, and the tissues raised and turned backward a short distance to give room for opening the bone. The cavity is best entered just above the supra-orbital ridge with a small drill run by electric motor, controlled by a foot-switch. Through this opening the cavity can be explored and its size and the relations of its walls ascertained. A larger drill can then be employed, or a button of bone taken out with a trephine, or the portion of the wall sawed out with a slender saw, as in opening the antrum. Luc adopts the plan of making a vertical incision from the root of the nose upward and so raising the soft parts that the opening through the bone is made under the flap just outside the median line, so that the two wounds will not come opposite each other. When the opening has been made, the cavity is curetted or dealt with according to the conditions found. A Bryan soft-rubber drainage-tube is then inserted through the natural opening into the nose, the flange on the head of the tube remaining in the cavity to keep the tube in place, and through this the cavity is irrigated and medicated from below. The external wound is then closed in the usual manner. It is important that the line of the incision, when horizontal, be made along the line of the eyebrow, so that the scar will be obscured by the hair.

#### TONSILLAR OBSTRUCTIONS IN THE NASO-PHARYNX AND FAUCES.

The most frequent obstructions in the naso-pharynx are adenoid growths or enlargements of the pharyngeal tonsil (see page 952), although nearly every known variety of growth is encountered in this region. A variety of methods is employed for the removal of these growths, as curettement, the use of cutting- or divulsion-forceps, scraping them out with the fingernail, or burning them away with galvano-cautery. These methods are applicable to the different conditions of the growth. When it is one rounded mass it is best removed with Löwenberg's postnasal adenoid forceps, having a posterior scooped projection, as shown in Fig. 682. When composed of independent vegetations scattered about the pharynx (Fig. 583), the simple ring-knife or Götstein's enrette may be chosen. When the mass is soft and spongy, it is very easily scraped away with the finger (Fig. 683) or with Darby's artificial fingernail-attachment. When it is firm and more or less pedunculated, it is often best removed with a postnasal snare curved to pass

up behind the soft palate. In children the use of a general anesthetic is always advisable unless there is some counterindication to its use. Chloroform or Schleich's mixture is the most satisfactory, and the operation as performed by the writer is as follows:

The child is anesthetized, a mouth-gag introduced—with its head slightly dependent. The tongue is then depressed and the chosen instrument introduced behind the palate and the growth removed. The child is then placed on the side, preferably the right, if the operator is right-handed, so as to allow the free escape of the blood without the danger of its being inspired into the larynx. The vault should then be digitally explored to determine if every part of the growth has been removed, which should be done before the operation can be considered completed. After the operation the vault of the

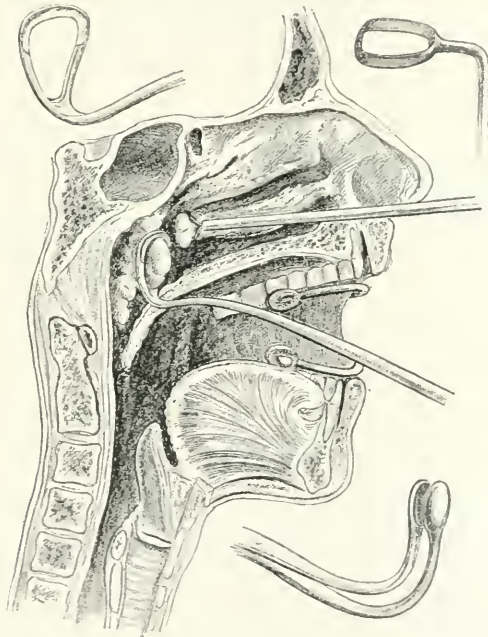


FIG. 682.—The Gottstein curette its blade shown also above to the left applied for the removal of the pharyngeal tonsil, the mouth being held open by a gag. A snare is also shown engaging a posterior turbinal hypertrophy through the naris. The Hartmann eurette is shown above and the Löwenberg forceps below, to the right.

pharynx can be irrigated with a postnasal syringe, using a bichlorid solution, 1 : 5000, for the purpose of removing blood and rendering the parts aseptic.

Further treatment than this is unnecessary, and often this can be dispensed with by thoroughly cleansing the parts with an alkaline solution used before the operation.

In operating on adults anesthesia, except by cocain, is rarely required. After the growth is removed the conditions that may have resulted from the presence of the growth, such as deafness and the imperfection of speech in children, must be properly dealt with.

Formerly the galvano-cautery was frequently employed in the removal of adenoid growths; but the danger of middle-ear complications attending its use in the postnasal space and the greater or less difficulty in its application, together with the superiority of other methods has caused it almost entirely to fall into disuse for this purpose.

Harrison Allen, Hooper, and others raise the child into a sitting posture for operation and incline it forward to let the blood flow from the mouth and nose. Allen using generally the alligator-forceps through the nose, guided by the finger in the pharynx, which is able also to squeeze out the softer masses as well as tear away the firmer. After the central mass has been removed, Hartmann's lateral-cutting curette (Fig. 682) may be used for the removal of any marginal portions remaining in Rosenmüller's fosse or elsewhere. When there is recurrence of the growth it is due to some portion of this

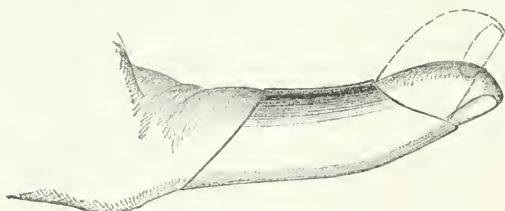

FIG. 683.—Metal finger-guard, serving also as mouth-gag during digital examination and erosion in the pharynx-vault. Its bevelled end can wedge open the teeth if set, and, while fully protecting, it permits sufficient motion.

lymphoid tissue which has escaped removal.<sup>1</sup> In exploring and operating with the finger a guard (Fig. 683) is useful, and can sometimes supersede a mouth-gag.

The **removal of the faucial tonsil** is called for in cases where it is enlarged sufficiently to project beyond the pillars of the fauces and cause obstruction or act as a foreign substance, or when the tonsil is not hypertrophied, but so diseased as to cause irritation of the fauces and more or less reflex disturbance. There are two principal methods for the reduction or removal of the tonsil—destruction by means of caustic substances and excision with cutting instruments.

The caustics employed are Vienna paste, chromic acid, nitric acid, nitrate of silver, chlorid of zinc, and the galvano-cautery.

Before the application of the caustic the tonsil should be anesthetized with cocain, or by the injection of Wilson's local anesthetic around the base of the structure. Where the Vienna paste is used, it is applied by mixing it with water to the consistency of a thick paste and rubbing it upon the tonsil with a small glass rod, care being taken that no paste be allowed to drop into the fauces.

Nitric acid is best applied with a very small pledget of cotton wound on the end of a probe, as may the saturated solutions of the other caustics; or crystals of chromic acid, silver nitrate, or chlorid of zinc may be picked up or fused on the end of a probe.

The galvano-cautery is most effectively employed by ignipuncture, using a slender-pointed electrode (Fig. 568), which is thrust into the tonsil at several different places, rather than burning away the tonsil *in toto*.

None of these processes is to be recommended, however, except as a substitute for the knife when its use is not permitted.

The only positively satisfactory and effective method is excision. This

<sup>1</sup> [While some recurrence is possible, that observed is generally due to the growth toward the free median space of adenoid tissue left at the sides. "Total removal" of lymphoid tissue, which commonly extends into the Eustachian tube, is neither safely possible nor desirable; but all that is obstructive or likely to become so should be removed, preferably by expression, since this destroys the smallest amount of mucous membrane.—Ed.]

may be done with a bistoury, with the tonsillotome, with the cold-wire snare, or with the galvano-cautery écraseur.

The bistoury employed should be slightly curved and have a blunt probe-point to prevent the wounding of the pillars of the fauces and to lessen the danger of cutting too deeply. The tonsil is removed by grasping it with a pair of forceps, dragging it from its base, and cutting off the diseased portion. In cases of flattened or lobulated tonsils the bistoury is a very practical instrument for the removal, especially in adults, although in many cases the writer gives preference to the cold-wire snare.

In children where the tonsils are found plump and rounded the tonsillotome of Mathieu or Mackenzie is very serviceable, although in these cases, also, the cold-wire snare is preferable.

In the use of the tonsillotome the patient is seated upright and the head held by the assistant. The tongue is depressed and the ring of the instrument is passed from below over the tonsil and well in behind it (Fig. 684).

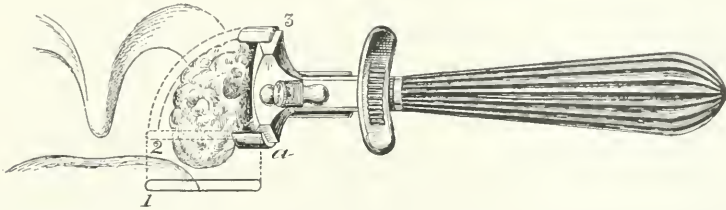


FIG. 684.—Diagram showing the method of applying the Mackenzie tonsillotome (after Howell).

The assistant presses with one finger on the outside of the neck directly over the tonsil, forcing it inward toward the fauces, so that it may the more fully enter the ring, and the guillotine-knife is then carried through the tissue, cutting off more than a surface slice.

Before the tonsils are excised they should be thoroughly liberated from the pillars of the fauces by a curved blunt instrument. This I regard as an exceedingly valuable procedure, as the tonsils are so frequently adherent to the pillars that unless liberated there is danger of cutting the enlarged blood-vessels of the pillar, which, if wounded, may bleed profusely or cause the alarming hemorrhages that occasionally follow tonsillotomy in adults.<sup>1</sup>

When portions of the diseased tonsil escape removal, it is frequently necessary to finish the operation by grasping these portions with vulsellum forceps and removing them with the cold-wire snare or bistoury.

In cases where hemorrhage is apprehended, the tonsil is best removed by means of the cold-wire snare or galvano-cautery écraseur, as in no instance has hemorrhage of any considerable extent followed the use of the cold snare.

The removal of the tonsils with the cold-wire snare or the galvano-cautery snare is done in the same manner as the removal with the tonsillotome, except that the tonsil is drawn outward with a pair of vulsellum forceps passed through the loop.

Lac of Paris and Farnham of Boston have devised punch-forceps for the removal of enlarged tonsils, which I have found in some cases serviceable, particularly in removing remnants of tonsils that have escaped excision. Bliss employs scissors to dissect away the entire structure and Pynchon does this with the galvano-cautery knife.

<sup>1</sup> J. Wright collected from literature some years ago 31 cases of bleeding after tonsillotomy—2 fatal; but this was out of a total of probably 100,000 operations.



In the removal with the galvanic snare allowance should be made in the adjustment of the loop for the portion of the tonsil that will slough away as a result of the burning.

In case of hemorrhage following excision of the tonsils the instrument always at hand and generally the most serviceable is the two large fingers of the hand corresponding to the side on which the operation is performed. The fingers are thrust into the tonsil, with the thumb pressing firmly on the outside of the neck. The writer has never seen a tonsillar hemorrhage that could not be controlled in this manner. In all ordinary cases the pressure for a short time will suffice for the complete arrest of the hemorrhage; but if there is a tendency to recur, pressure can be exerted in the same manner by Pendim's instrument.

With our present knowledge of tonsillotomy, the wounding of the deep blood-vessels of the fauces sufficiently to give rise to such alarming hemorrhages can only be justified or excused by an anomalous distribution of the arteries, which ought to be recognized beforehand by palpation or by their visible pulsation on careful inspection.

**Operations on the Lingual Tonsil.**—When the enlargement consists mostly in a vascular engorgement, the best method of reduction is with the curved galvano-cautery electrode having a slender point. By the aid of the laryngeal mirror the large vessels can be singled out and destroyed separately by burning deeply. On healing, the contraction of the tissues will cause obliteration of the intervening engorgement. For this purpose caustic agents are also used, such as chromic acid, nitric acid, and Vienna paste. These, however, are not to be advocated, as the use of them is painful and unnecessary.

Where the enlargement consists in hypertrophy of the interstitial connective tissue, it is best removed by excision. When the mass is more or less rounded and projecting, I have found the instrument devised by myself and termed a lingual tonsillotome, as represented in Fig. 685, exceedingly ser-

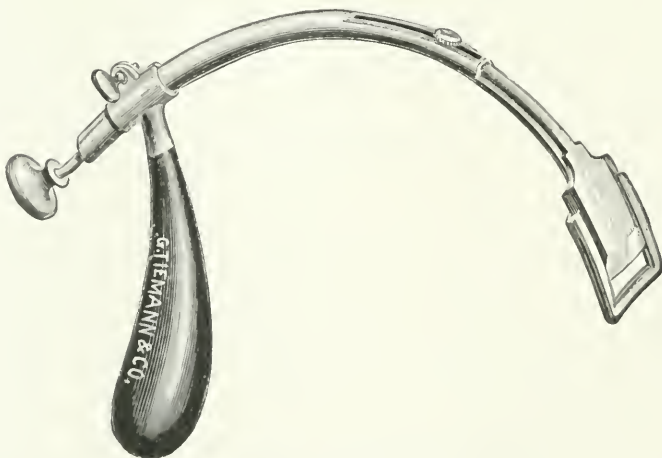


FIG. 685.—Dr. Roe's lingual tonsillotome.

viceable. The lower portion of the ring is caught under the lower edge of the growth between it and the epiglottis, and by pressing forward and downward the mass is forced through the opening, when the blade is shoved down and the whole mass severed, leaving a smooth surface.

In cases in which the hypertrophies are in the form of little lobules scattered about the base of the tongue, I have for a considerable time used the cold-wire snare having a curved stem to pass over the base of the tongue. But a small portion can, as a rule, be removed at a time, consequently a number of efforts are required to remove the entire mass. This method is, however, exceedingly satisfactory, causes little pain, and bleeding is rarely encountered.

In the removal of these growths it is important to adjust the instrument by aid of the laryngeal mirror, the tongue being drawn forward by the patient, in order to avoid injuring the epiglottis. Every portion of the growth should be removed, for if one or two small lobules remain behind, the irritation produced may be nearly as great as that caused by the whole mass.

#### EVACUATION OF FAUCIAL AND PHARYNGEAL ABSCESS.

Quinsy or peritonsillar abscess is rarely if ever a suppuration of tonsil-tissue, as it was formerly considered, although generally the result of phlegmonous inflammation from tonsillar infection. Scarification of the tonsil itself is in most cases as needless, therefore, as in retro-pharyngeal abscess. Fluctuation is to be sought by palpation, aided, if possible, by simultaneous ocular inspection, and incision should be made as soon as pus is detected or is clearly unavoidable. Harrison Allen probed carefully each tonsillar follicle, seeking a boggy point, and could often thus find and evacuate the first drops of pus, to the great shortening of the affection. The relief to the patient may be great even before pus is formed, while with the evacuation of the abscess most of the pain and distress of the condition is at an end. The thin region of pointing may perhaps be better recognized by touch than by sight, and pulsation is to be felt for, both as to its indication of the proximity of large arteries and because an aneurysm might be opened by mistake. The incision should be free, usually in or just inside of the anterior half-arch above the tonsil, entering the blade nearly half an inch and cutting horizontally in toward the median line; and vigorous use of the probe may be needed to fully enter and empty the flabby sac. Hot syringing with mild disinfecting solutions is usually advisable.

In the retro-pharyngeal abscess it is easier to evacuate the cavity; and lest it should deluge the air-passages and perhaps be drawn into the lungs, some open at its upper rather than at its most dependent portion. In these cases the possibility of extrinsic origin in adjacent lymph-gland, mastoid or vertebral suppuration must not be forgotten, and search should be duly made for any such condition. Where the retro-pharyngeal pointing is merely accidental and external operative intervention is needful, it may be better to drain outward without pharyngeal opening. In any of these cases the danger of wounding the large blood-vessels of the neck is much greater than in tonsillotomy.

#### UVULOTOMY.

It frequently happens that the uvula is cut away because it is the supposed cause of irritation which in reality originates from diseased conditions of other parts, and it is safe to affirm there is no organ in the body which is so often abused for fancied sins as the uvula.

It occasionally happens, however, that the uvula requires shortening, and for this purpose a variety of instruments have been devised: fenestrated

instruments similar to the tonsillotome, curved seissors with the ends coming together first so as to prevent its slipping away, and others having a pair of claws to seize the cut portion to prevent its falling into the larynx. Some advise the use of the snare, in order to avoid any danger of hemorrhage, which sometimes, although very rarely, occurs.

The simplest and, as I consider, the best method of removing the elongated portion of the uvula is to grasp the end with a pair of mouse-toothed forceps, pulling it gently forward, and with a pair of grape-vine seissors cut it on the slant so that the cut surface looks backward. This is important for two reasons, first, it prevents food from coming in contact with the cut surface, and it directs the mucus or fluids from the nasal space forward upon the base of the tongue, thereby preventing it from falling into the larynx.

In cutting the uvula particular care should be exercised not to cut it too short, allowance always being made for considerable contraction after healing to prevent its becoming shorter than its normal dimensions.

After uvulotomy some cases of hemorrhages have been reported. Morgan collected a number of such cases scattered through medical literature, and devised a clamp which can be applied to the end of the cut portion. This the writer has found in some cases exceedingly serviceable.

#### INTRALARYNGEAL OPERATIONS.

Papillomata and polypoid growths of the larynx are best removed by means of forceps, such as Mackenzie's (Fig. 686), guillotine, such as Stoerk's,

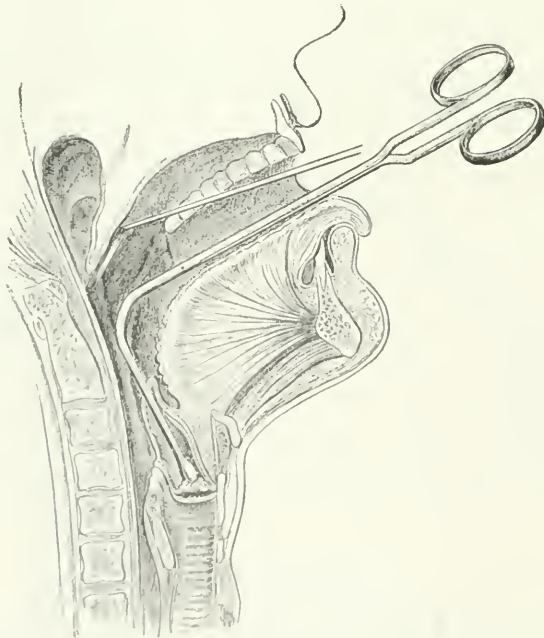


FIG. 686.—The Mackenzie lateral forceps in use to bite off a polyp of the right ventricle.

or rongeurs, such as Krause's. The choice of instrument depends much upon the form and seat of the growth and the facility of the operator.

The removal of foreign bodies is often a closely similar procedure, both

being guided, as a rule, by the mirror. The reversal of the image will confuse an inexperienced laryngologist, and the patient may need some drill to secure steadiness and the co-operation sometimes required; so some preliminary use of the probe is apt to be useful. Under cocain it is not commonly difficult to have the needful quiet for one or more attempts; but there is room for the exercise of the highest skill if prompt and full success is to be attained. Ample illumination is requisite, since much light will be cut off by the instrument, which is sometimes made with fenestrated jaws to lessen the obstruction to the view at the critical moment of seizing the object. Stock's tube-foreeps with its pistol-grip is a very serviceable instrument, offering the minimum of obstruction and irritation by reason of its well-planned curves. A guarded knife is sometimes employed, as for laryngeal scarifications, to cut off growths; and the use of the chemical or galvano-cautery has been elsewhere described (see page 1004). Preparations for a tracheotomy should often be made before intralaryngeal operations are undertaken, since dangerous dyspnea or actual suffocation might at any time supervene.<sup>1</sup>

Laryngeal stenosis can often be dilated from the mouth by the passage of a suitable catheter, by divulsion with instruments like the author's dilator

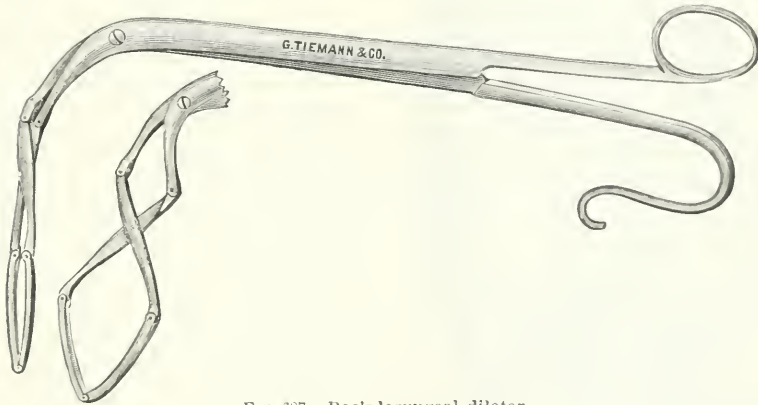


FIG. 687.—Roe's laryngeal dilator.

(Fig. 687), or by cutting and dilating, for which many instruments have been devised. (For Intubation by O'Dwyer's method, see page 1029.)

#### EXTERNAL OPERATIONS ON THE LOWER AIR-PASSAGES.

**Tracheotomy, Thyrotomy, and Pharyngotomy.**—External opening of the air-passages may be required for a number of conditions, chief among which is the prevention of suffocation by foreign body, false membrane, edema, abductor paralysis, or neoplasm. As a provision against the entry of blood into the lungs, it may be done preliminary to operations not otherwise requiring it; and its previous performance when the larynx is to be removed divides the shock of that operation and anchors the trachea to the external wound in a way that avoids some of the complications of the after-treatment. The need for it may be so sudden that little preparation is possible, and use must be made of whatever instruments are at hand—even a penknife having

<sup>1</sup>The multiplicity of carefully-designed instruments for operation within the larynx are evidence of how much may be attempted in this difficult field by the expert laryngologist. Yet even if it were possible here to refer in detail to these procedures, no written description could materially aid the practitioner in acquiring the dexterity by which success has been achieved. For detail as to the removal of foreign bodies, see page 1133.



been successfully employed in an emergency. Morell Mackenzie carried an emergency cannula, the split obturator of which contained a sterile knife ready for immediate use.

Where extreme limitation of time exists, penetration of the crico-thyroid membrane is usually indicated, for this structure is almost subcutaneous and generally devoid of vessels likely to cause troublesome hemorrhage. Additional space may be gained, if required, by cutting upward into the thyroid or downward through the cricoid; but without this a sufficient respiratory opening can be gained for the emergency, and more extensive operation in this region is at great risk of permanently impairing the voice.

Tracheotomy is generally to be preferred if a persistent opening and the wearing of a cannula is called for; and the opening may be made high or low, as the conditions of the case dictate. The presence of the thyroid gland and its vessels generally complicates the matter, and the fatness of the neck increases the annoyance caused by the tube, especially if the opening is low

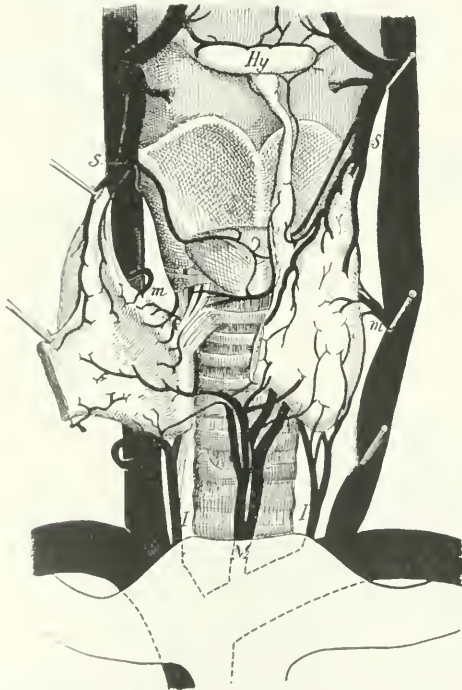

FIG. 688.—The trachea, larynx, and hyoid region, with the divided thyroid gland and the veins adjacent: the innominates are shown emptying into the cava and receiving the median (*M, I*) and inferior (*I, I*) thyroid veins; the superior (*S, S*) and middle (*m, m*) thyroid veins empty into the jugular (Farabouf).

down, where the trachea is deeper and remains of the thymus gland are present in the very young. Yet the low operation is generally preferred because the space above the isthmus of the thyroid is small; and it is a decided complication to have to secure this structure with double ligatures and divide it to make room (Fig. 688). The isthmus generally covers the second, third, and fourth tracheal rings, and a process may extend up to the hyoid. The simplest method of hasty tracheotomy is that of Durham, who lightly grasps the trachea between the thumb and finger, pressed down until both carotids are felt, and then dissects down upon it as it presses forward into the wound. The veins, engorged by the impeded respiration, are generally easily seen and pressed aside, and the trachea is quickly laid bare and opened, either directly or after fixing and lifting it with a tenaculum. By Bose's method the median skin-incision is crossed by

another at the level of the crico-thyroid membrane, laying this bare, and the undivided structures in front of the trachea are peeled down sufficiently to give access to it. As it is important to incise the trachea in the median line, great care should be taken to place the patient's neck and trunk straight, with the head drawn back over a rolling-pin or other firm support and immovably held there. In case of foreign body a retractor similar to a nasal speculum may be used to hold the trachea open, or a suture may be passed through each side of the tracheal wound and drawn upon whenever coughing promises to expel the obstructing object. Such threads are a very great

aid in placing the cannula in position at the first, and still more if it is to be replaced later after withdrawal for any cause; so Bosworth advises them as a rule. A portion of one or more rings may be resected in order to secure a gaping wound, and the margin of the tracheal and cutaneous wound on each side can be stitched together and a tube thus dispensed with.

Usually the operation can be performed with deliberate division of successive layers of the overlying tissues upon a grooved director, with all possible blunt dissecting, until the trachea is bared at the desired point and all bleeding vessels secured by compression or ligation. Then with a tenaculum a firm and central hold of the trachea is secured and the knife-point entered and the needful incision made upward and rather from within outward. Turning the knife-blade will separate the lips of the wound, while the fingertip above will hold wide the external wound and prevent blood from being drawn in with the first deep gasping inspiration. The cannula may now be slipped in along the finger, and its obturator, if used, promptly withdrawn as soon as it is in the trachea. The tube is then secured in place by tying the tapes attached to its neck-plate around the patient's neck; and the external wound, if large, may be narrowed or closed around the tube by sutures.

General anesthesia is often quite unnecessary, as the patient is sufficiently narcotized by the semi-asphyxiation. Chloroform is generally preferred because less irritating to the air-passages and less liable to cause vomiting, with its dangers. Much care must be given to secure due warmth and moisture of the air entering by this shortened route, for fear of pneumonia, which may supervene from this, as from inspired blood, and may rob the operation of its life-saving value. [Steam-soaked air may be needless or even harmful, but the room should be warm and certainly not too dry.] Artificial respiration may be required to start breathing [or to continue it if it should be interrupted after the first free inspiration, as will occasionally happen, as if from shock, on the free entrance of air]; and the patient may need judicious stimulation for hours or days in order to rescue him from the profound carbonic-acid poisoning which has taken place during the apnea. The inner tube must be removed and cleansed whenever impeded by mucus or false membrane, and a feather may be passed through the cannula and down into the bronchi to remove collections and to stimulate cough.

The operation may be exceedingly simple and easy, or may be, as characterized by Billroth, one of the most difficult in surgery. Three or four assistants are desirable, each of whom must give full attention to his own duty, although it be the simple part of maintaining the head and neck in exact position. Full illumination, best secured by the concave forehead-reflector, is essential to the most skilful work. There must be no flurry or clumsiness at the crucial moment of introducing the tube, for many an operation has failed at this point—serious damage being done to the tissues, bleeding reawakened, or false membrane pressed down and impacted. The Trousseau double tube with its quadrant-curve is theoretically inferior to the more right-angled and adjustable tube of Durham; but it is the one most often employed by Americans. A well-made soft-rubber tube can have ample lumen and be much more comfortable to the patient and less likely to cause sloughing from pressure. Fenestrated tubes may permit and even cause ingrowth of granulations, with troublesome resulting erosion; while such construction is needless since enough air generally passes around the cannula to furnish sufficient breath for phonation. Where bleeding is to be especially guarded against, Trendelenburg's or Gerster's dilatable tube may be used; but a tight-fitting single tube can serve the same temporary purpose, and

give place to one of better size at the close of the operation. Four sizes of tubes should be available, having an external diameter of ten, nine, seven, and five millimeters respectively.

The removal of the tracheotomy-tube after its purpose has been served may prove quite a troublesome matter, for the patient may have such severe dyspnea as to compel its reintroduction, and this may be difficult or even impossible through the narrowed wound, necessitating enlargement of it or resort to intubation. As the trouble may be largely hysterical, there is room for much tact in forestalling or overcoming it; and careful laryngoscopic examination should be made, if possible, before this removal is attempted, to make sure that the parts are in condition to resume their function.

Thyrotomy<sup>1</sup> or laryngo-fissure, often with preliminary tracheotomy, may be needed for the extirpation of broad-based growths or for foreign bodies impossible of removal by intralaryngeal methods. The cutaneous incision is to be made as for a high tracheotomy, from the hyoid bone to the cricoid ring; the rostrum of the thyroid is laid bare and divided centrally by gradually deepening cuts or by sawing if calcified. The mucous membrane should be exposed and all structures external to it divided and bleeding controlled before it is incised and the larynx opened, for very troublesome cough will be excited. The larynx-cavity should be entered from below under good illumination with the forehead-mirror, so that the vocal cords shall be seen and injury of them avoided. The purpose of the operation in extirpation of a growth or other step is to be then carried out after careful orientation, and the parts are brought together with all possible accuracy with silkworm-gut sutures, the skin-wound being separately stitched. The voice may be lost or permanently impaired by the operation, or not regained, as it sometimes might be, after consummate intralaryngeal work; yet if this latter is impracticable, the procedure is fully justified.

Subhyoid pharyngotomy may be needed to gain free access to the supra-glottic space or the entrance of the esophagus, and the opening may be made immediately below the hyoid bone or just above the thyroid cartilage. The incision is made at the chosen level and from one sterno-mastoid to the other, and carried down through the muscles until the thyro-hyoid membrane is freely exposed. This is entered laterally, and the epiglottis brought to view and drawn out of the wound after sufficient enlargement, when the region should be open to free access. If found requisite, the incision can be carried down along the sterno-mastoid as a lateral pharyngotomy or esophagotomy. Great fear was at one time entertained as to any injury or removal of the epiglottis; but numberless cut-throat injuries have demonstrated that it may be lost by injury as by disease with little serious result. Yet feeding should be by tube (see page 1032) or by rectum for several days after this operation.

**Extirpation and Resection of the Larynx.**—Malignant growths of the larynx rarely admit of thorough extirpation by endo-laryngeal methods, and as a speedily fatal result with great suffering is the only natural outlook, severe operative measures are justified in their removal. [When very limited, it may be feasible by laryngo-fissure to extirpate the growth with preservation of the structure and the voice; but partial or total excision is generally needful if thoroughness is to be secured. This last is a serious measure, demanding much surgical skill and resource, which is often best done by the

<sup>1</sup> [The facile laryngoscopic operator will employ it more rarely than one less expert, and seems a little apt to decry it as needless and unduly risking the voice; but skilfully done it ought to entail only legitimate risks, due rather to the condition calling for it than to the operation itself. —Ed.]



general surgeon rather than the laryngologist (see page 1113); yet many are better conversant with their cases than another can quickly become, and sufficiently versed in operative technic to make it well that they should direct if not perform the operation.]

Preliminary tracheotomy is generally advisable, and the patient may be allowed to recover fully and become habituated to the change before the graver intervention; although as performed by Perier and by Keen tracheotomy is not previously done. The larynx and upper portion of the trachea are sufficiently bared after free median incision and the grooved director passed behind the trachea, through the front of which a strong suture is passed just below the point selected as the lower limit of the excision. Traction upon this thread holds the trachea forward while it is cut across, and then draws it out of the wound; and a tightly fitting curved cannula is inserted and secured by tying the suture to a cleat upon it (Fig. 689). The anesthetic is transferred to this opening, while the larynx is lifted by a tenaculum and dissected up free from the esophagus and its upper attachments, and the excision completed according to the special requirements of the case. The trachea is stitched above the sternal notch into the wound,

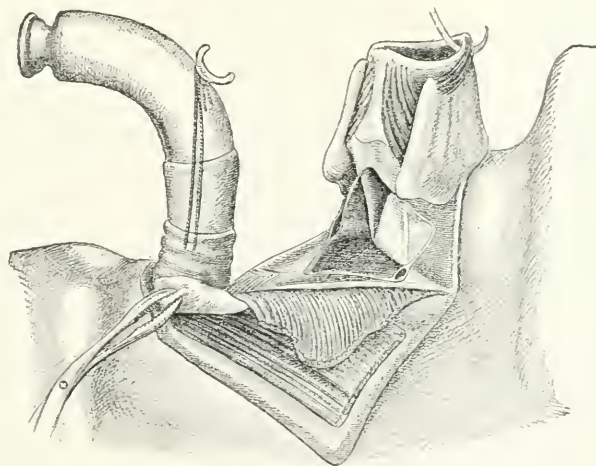


FIG. 689.—Extirpation of the larynx by Perier's method. The severed trachea is plugged with a tight cannula, and the larynx is lifted and dissected free from below.

which is completely closed elsewhere if possible, the cannula being retained or not as the case seems to require. An artificial larynx may be later employed, although some patients have been able to talk without it.

Partial resection—*e. g.*, excision of one side of the larynx, is regarded as a much less grave procedure, which Bosworth advises as a first step after exploration by laryngo-fissure, and if the growth appears limited to that side; while J. N. Mackenzie urges that the extirpation should be as total as of the breast, and should include all suspicious neighboring lymphatics.

In all these operations placing the patient in the Trendelenburg position may facilitate the procedure and greatly reduce its risks. Shock is to be met by full employment of injection or transfusion of warm neutral salt-solution; and in case of carbonic-acid intoxication, simultaneous venesection with free bleeding has been employed with apparent advantage.





# INDEX.

- ABDUCENS** nerve, paralysis of, 511, 513  
     paralysis, 511  
     spasm, 511  
**Abduction**, 157, 497, **503**  
     associated, 503  
     relation of adduction to, 157  
**Abductors of larynx**, paralysis of, 1167  
     of vocal cords, paralysis of, 1167  
**Aberration**, 107, 108, **230**  
     in skiascopy, 206  
     spherical, 88, 96  
**Ablepharia**, 241  
**Abscess**, chronic encysted tonsillar, 935  
     epidural, from tympanic inflammation, 756. See *Pachymeningitis externa*.  
     extradural, from tympanic inflammation, 756. See *Pachymeningitis externa*.  
     intradural, 758  
     of auricle, 655, 693  
     treatment, 693  
     of brain, 511  
     from ear disease, 761. See *Brain-abscess*.  
     of conjunctiva, 298  
     of cornea, 313  
     of eyelids, 242, 546  
     of lachrymal sac, 265, 267  
     of nasal septum, 899, 1116  
     diagnosis, 901  
     etiology, 900  
     evacuation of, 1198  
     prognosis, 801  
     symptoms, 900  
     treatment, 901  
     of nasal wing, 901  
     of orbit, 526, 528  
     operation for, 599  
     of sclera, 330  
     of turbinal body, evacuation of, 1198  
     pharyngeal, evacuation of, 1207  
     post-aural, 750  
     prelachrymal, 268  
     subdural, from tympanic inflammation, 758  
**Absence of nose**, operation for, 1184  
**Abstraction of blood** in acute otitis media, 721  
**Accessory sinuses of nose**, anatomy of, 966  
     diseases of, 966  
     optic-nerve lesions from affections of, 454  
**Accommodation**, **94**, **134**, 155  
     amplitude of, 136, 155  
     in emmetropia, 136  
**Accommodation**, amplitude of, in hyperopia, 137  
     in myopia, 137  
     effect of, on pupillary contraction, 148  
     Helmholtz's theory of, 131  
     involuntary, 216  
     mechanism of, 95  
     paralysis of, from ptomain-poisoning, 465  
     range of, 136  
     region of, 155  
     relation of, to refractive ophthalmoscopy, 200  
     relations of age to, 138  
     relative, 137, 155  
     relaxed, 213  
     spasm of, 213, 216  
     tone of, 184  
     Tscherning's theory of, 135  
     voluntary, 216  
**A. C. E. mixture**, 542  
**Acetamid** in chronic suppuration of middle ear, 689  
     in laryngeal tuberculosis, 1048  
**Acetic acid** in chronic nasopharyngitis, 952  
**Achromatopsia**, 457  
**Aconite**, 459  
     in acute catarrhal pharyngitis, 940  
     in acute rhinitis, 893  
     in laryngeal tuberculosis, 1018  
     tincture in acute otitis media, 720  
     in neuralgia of pharynx, 1153  
**Aconitia** in acute nasopharyngitis, 948  
**Acometer**, 668  
**Acoustic crest**, 618  
     hysteria, symptoms, 776  
     nerve, atrophy of, 769  
     degeneration of, 769  
     diseases of, pathology, 769  
     origin and distribution of, 621  
     neurasthenia, symptoms, 776  
     treatment, 781  
**Acromegaly**, 438  
**Actual cautery**, 252  
     application of, 567  
     in corneal ulcers, 315  
**Acuity of vision** of peripheral parts of retina, 168  
**Acute affections of larynx and trachea**, 985  
     of nose, 891  
     of tympanic cavity, 715  
     catarrhal laryngitis, 985. See *Laryngitis*.  
     catarrhal pharyngitis, 939. See *Pharyngitis*.

- Acute catarrhal tracheitis**, 996  
     circumtonsillar inflammation, 925  
     croupous tonsillitis, 925  
     edematous laryngitis, 988  
     lacunar tonsillitis, 922. See *Tonsillitis*.  
     mastoiditis interna, 749  
     myringitis, 713  
     naso-pharyngitis, 947  
     otitis media. See *Otitis media*.  
     parenchymatous tonsillitis, 923. See *Tonsillitis*.  
     perichondritis of larynx, 995  
     of septum, 899  
     phlegmonous laryngitis, 988  
     post-nasal catarrh, 947  
     purulent inflammation of middle ear, 660  
     rhinitis, 891. See *Rhinitis*.  
     sinusitis, 969, 972  
     supraglottic laryngitis, 986  
     tonsillar inflammations, 922  
     ulcerative tonsillitis, 927. See *Tonsillitis*.  
     uvulitis, 937  
**Adam's apple**, 816  
**Adams's nasal truss**, 1122  
     operation for deviated septum, 917  
     operation for shortening lid-border, 551  
     septum forceps, 1192  
**Addison's disease**, 330  
**Adduction**, 157, 497, **503**  
     associated, 503  
     relation of abduction to, 157  
**Adenoid growths**, removal of, 1202  
     hypertrophy, etiology, 850  
     examination for, 867  
     vegetations, 952. See *Lymphoid hypertrophy*.  
     otitis media from, 718  
**Adenoma of crumicle**, 304  
     of ciliary body, 490  
     of eyelids, 218  
     of lachrymal gland, 263  
     of larynx, 1108  
     of nose, 1085  
     of oro-pharynx, 1096  
     of trachea, 1115  
**Aditus ad antrum**, 628  
**Advancement**, 590  
     accidents and complications, 591  
     of capsule, 594  
     to correct faulty strabismus operations, 590  
**After-brain**, 19  
**After-cataract**, 389  
**After-images**, 498  
**Age** in etiology of ear-disease, 617

- Agnew's bident, 367  
 Air, index of refraction of, 92  
 Air-conduction, testing of, 669  
 Air-passages, catarrhal inflammation of, 844  
   croupous inflammation of, 848  
   diphtheritic inflammation of, 848  
   diseases of, symptomatology, 851  
   examination of, 855  
   leprosy of, 1066  
   lupus of, 1057. See *Lupus*.  
   operations upon, 1180  
   physiology of, 835  
   syphilis of, 1067  
   upper, affections of, prognosis, 859  
     anatomy, 844  
     diseases of, general therapeutics of, 874  
     local treatment, 881  
     gouty affections of, general therapeutics, 875  
     neoplasms of, 1075  
     neurosis of, 1140  
     rheumatic conditions of, treatment, 874  
 Ala nasi, abscess of, 901  
   retractor for, 860  
   of thyroid cartilage, 816  
 Alae nasi, collapse of, operation for, 1183  
   expansion of, operation for, 1183  
   restoration of defects of, 1187  
 Albinism, 351, 469, 520  
 Albolene in empyema of maxillary sinus, 972  
 Albuminuria, 390, 391, 416, 458  
 Albuminuric retinitis, 416. See *Retinitis, albuminuric*.  
 Alcohol, 441, 448, 459  
   as an antiseptic, 540, 541  
   in aspergillus of ear, 686  
   in diphtheria, 994, 1020  
   in laryngeal tuberculosis, 1048  
   sprays, 882  
 Alcohol-amblyopia, 460  
 Allantiasis, 465  
 Alum in atrophic rhinitis, 964  
   in chronic rhinitis, 909  
   in epistaxis, 903  
   spray in laryngeal tuberculosis, 1050  
 Amacrine cells, 74  
 Amaurosis, 472. See also *Amblyopia*.  
   from quinin, 463  
   partialis fugax, 483  
   traumatic, 360  
 Amblyopia, 457, 472. See also *Amaurosis*.  
   congenital, 457  
   exanopsia, 457, 504  
   from abuse of drugs, 459  
   from lead, 462  
   from loss of blood, 459  
   glycosuric, 458  
   hysterical, 466, 485  
   malarial, 459  
   of the visual field, 470  
   pretended, 466  
   reflex, 458  
 Amblyopia, toxic, 441, 448, 460, 477  
   etiology and pathology, 460  
   treatment, 462  
   traumatic, 360, 364  
   uremic, 458  
 American catarrh, 948  
 Ametrometer, 207  
 Ametropia, 212  
   axial, lengthening or shortening of eye in, 178, 201  
   frequency of, 213  
 Ammonia in catarrhal tracheitis, 997  
   in laryngismus stridulus, 995  
 Ammonium chlorid in chronic laryngitis, 1004  
 Ammoniol in acute naso-pharyngitis, 948  
 Amplitude of sound-waves, 635  
 Amyl nitrite in embolism of central retinal artery, 408  
   in laryngismus stridulus, 995  
   in subglottic laryngitis, 988  
 Amyloid degeneration of larynx, 1108  
   disease of conjunctiva, 296  
 Anyotrophic lateral sclerosis, 477  
 Anagnostakis-Hotz operation for entropion, 549  
 Anemia, 149, 246, 339, 352, 372, 399, 400, 421  
   of labyrinth, etiology, 770  
   pathology, 766  
   symptoms, 774  
   treatment, 780  
 Anesthesia, local, 542  
   general, 512  
   nasal, 1143  
   of larynx, 1154  
   of pharynx, 1151  
 Aneurism, 151, 406  
   of central artery of retina, 410  
 Angioid streaks in retina, 427  
 Angioma of auricle, 696  
   operation for, 783  
   of choroid, 493  
   of drumhead, 714  
   of eyelids, 248  
   of iris, 489  
   of larynx, 1108  
   of nose, removal of, 1197  
   of orbit, 531  
 Angle alpha, 96, 128, 129  
   beta, 96  
   gamma, 96, 128, 129  
   of incidence, 104, 105, 106  
   of refraction, 104, 105, 106  
   of strabismus, 505  
   visual, 138, 139  
 Angled knives for intratympanic operations, 790  
 Aniridia, 333  
   traumatic, 362  
 Anisocoria, 450  
 Anisometropia, 231  
   correction of, 232  
 Ankyloblepharon, 256, 563  
   congenital, 241  
 Ankylosis of foot-plate of stapes with oval window, 660  
 Ankylosis, stirrup-, 660  
 Annulus tympanicus, 622  
 Anomalies of ear-secretion, treatment, 684  
 Anophthalmos, 455, 523  
 Anosmia, 1140  
   in disease of upper air-passages, 852  
   prognosis, 1141  
   treatment, 1141  
 Anterior chamber, anomalies of, 343  
   development of, 27  
   foreign bodies in, 344  
   irrigation of, after cataract-extraction, 394  
   nasal aperture, 832  
   pillar of fauces, 814  
 Anthrax pustule of the eyelids, 242  
 Antipyrin, 449, 460  
   in acute rhinitis, 893  
   in acute tonsillitis, 925  
   in diphtheria, 1029  
   in epistaxis, 903  
   in sarcoma of soft palate, 1099  
 Antisepsis in ocular surgery, 539, 540, 541, 574  
 Antiseptics used in ophthalmic work, 540, 541  
 Antitragicus muscle, 636  
 Antitoxic unit, 1025  
 Antitoxin, diphtheria, dose of, 1024  
   injurious effects of, 1023  
   preparation of, 1020  
   site of injection, 1025  
   testing of, 1025  
   in diphtheria, 995, 1020  
   in diphtheria of conjunctiva, 286  
   in membranous rhinitis, 898  
 Antitoxin-syringe, 1025, 1026  
 Antrum, function of, 639  
   irregularities of formation of, 793  
   malignant neoplasms of, 1090  
 maxillary. See *Maxillary antrum*.  
   of Highmore, abscess of, 438  
   anatomy, 966  
   empyema of, 968  
   of mastoid, 632  
   opening of, 793  
   operation, 793  
   sarcoma of, 1090  
 Aortic insufficiency, 149  
 Aphagia, 853  
 Aphakia, 343, 395  
   congenital, 397  
   value of ophthalmometry in, 198  
 Aphakial hyperopia, 215  
 Aphonia, hysterical, 1170  
   in laryngeal tuberculosis, 1039  
   in nodular laryngitis, 1005  
   spastica, 1158  
 Aphthongia laryngea, 1158  
 Aproxia from nasal obstruction, 852  
   in condensing mastoiditis, 752  
   in lymphoid hypertrophy in pharynx, 955  
 Apsithyria, 1167

- Aqua calcis in diphtheria, 994  
chlorini, 280, 282, 285, 293, 549  
intraocular, injections of, 399
- Aqueduct, vestibular, 623  
of Sylvius, 19, 96
- Aqueous humor, 85, 87, 89  
index of refraction of, 89, 92
- Aquocapsulitis. See *Keratitis punctata*.
- Arachnitis from ear-disease, operation for, 801, 803
- Arachnoid sheath of optic nerve, 79
- Arcus senilis, 50, 326  
senilis lentis, 3-9
- Area Martegiani, 83  
olfactory, 807
- Argamblyopia, 457
- Argyll-Robertson symptom, 149, 150  
reversed, 150
- Argyll-Robertson's operation for senile ectropion, 531
- Argyria, conjunctival, 304
- Argyrosis, 304
- Aristol, 252  
in atrophic rhinitis, 964  
in chronic myringitis, 714  
in eczema of auricle, 693  
in inflammation of auditory canal, 705  
in injuries of drumhead, 713  
in laryngeal tuberculosis, 1050, 1051, 1052  
in polypi of auditory canal, 706  
in syphilis of air-passages, 1074  
in wounds of auditory canal, 708
- Arlt's operation for cicatricial ectropion, 552
- Arsenate of iron in laryngeal tuberculosis, 1048
- Arsenic, 460  
in affections of upper air-passages, 886  
in eczema of ear, 685  
in laryngeal tuberculosis, 1048  
in lupus laryngitis, 1068  
in lupus of pharynx, 1059  
in nasal and pharyngeal tuberculosis, 1057
- Arteria centralis retinae, 78  
thyroidea ima, 825
- Arterial pulsation in glaucoma, 374  
sclerosis, 420, 445
- Arteries, anterior ciliary, 86, 87  
ciliary, 86, 143  
long ciliary, 86  
of pharynx, 814  
palpebral, 36  
posterior ciliary, 86  
short ciliary, 86
- Artery, aberrant choroido-retinal, 190  
central retinal, 24, 86  
hyaloid, 24. See *Hyaloid artery*.
- Articulation, 841, 1176
- Artificial eye, introduction of, 599
- Artificial eye, operation for support of, 573  
larynx, 843  
ripening of cataract, 295
- Ary-epiglottic folds, development of, 809  
examination of, 871
- Arytenoid cartilages, 818  
development of, 809  
muscle, 822  
in voice-production, 1173
- Arytenoideus, paralysis of, 1168
- Asch's hollow splint, 919  
operation for deviated septum, 918
- Aspergillus fumigatus, 614d  
in corneal ulcers, 314
- Aspergillus-mycosis, 704  
pathology, 657  
treatment, 686
- Associated action of pupils, 148  
movements of eyes, 500
- Asthenopia, 409, 510  
from drugs, 466  
neurasthenic, 410, 485  
tarsal, 140  
toxic, 466
- Asthma in chronic hypertrophic rhinitis, 907, 908  
Millar's, 986  
spasmodic, 1148  
treatment, 1149
- Astigmatic eye, principal meridians of, 224  
eyes, vision of, 224  
pencil, distribution of rays and focal lines in, 127  
surfaces and pencils, 126
- Astigmatism, 50, 127, 212, 224, 327, 333, 352, 392, 409, 457  
after cataract-extraction, 396  
against the rule, 198, 226  
changes in cornea caused by, 226  
classification, 127  
combinations of lenses for correcting, 228  
compound, 127  
compound hyperopic, 227  
compound myopic, 227  
correction of, 227  
determined by trial lenses, 208  
following cataract-extraction, 226  
following iridectomy, 226  
from pterygium, 297  
from spasm of ciliary muscle, 365  
glasses for, 229  
hyperopic, 127  
irregular, 224, 231, 324  
skiascopy in, 207  
lenses for correction of, 128  
measured with ophthalmoscope, 200  
mixed, 127, 227  
myopic, 127  
nervous disturbances caused by, 226  
oblique, 227  
regular, 224  
determined by skiascopy, 206  
rule for determining amount of the, with ophthalmometer, 195
- Astigmatism, simple, 127  
simple hyperopic, 227  
simple myopic, 227  
symptoms, 226  
transitory, 415  
varieties, 226  
with the rule, 198, 226
- Astringents in chronic laryngitis, 1002, 1003
- Asymmetry of nasal chambers, 831, 834
- Atheroma, 391, 421
- Atmospheric micro-organisms in diseases of air-passages, 880
- Atomizer, 882
- Atresia of external auditory canal, 698  
of meatus, operation for, 784
- Atrium, 627
- Atrophic rhinitis, 957. See *Rhinitis sinu-sitis*, 970
- Atrophy of acoustic nerve, 769
- Atropin, 209  
in acute otitis media, 721  
in corneal ulcers, 280, 283, 315  
in diphtheria, 1020  
in iritis, 341
- Attic, 627  
inflammation of, 724
- Attollens auriculae, 636
- Attrahens auriculae, 636
- Auditory canal, 625  
desquamative inflammation of, 704  
external, atresia of, 698  
circumscribed inflammation of, 702  
doubling of, 699  
exostosis of, 706  
false membranes of, 707  
foreign bodies in, 708  
furuncle of, 702  
hyperostosis of, 706  
new growths of, 707  
polypi in, 705  
syphilis of, 707  
wounds of, 708  
otoscopic appearance of, 675  
unduly capacious, 699  
centers, 645  
meatus, external. See *Meatus external*.  
pathology, 655  
internal, development of, 621  
pit, 617  
sensation, perception and judgment, mechanism of, 644
- Aural fistula, congenital, 692  
polypi, pathology, 661
- Auricle, 625  
abscess of, 655, 693  
affections of, 691  
angioma of, operation for, 783  
congenital malformations of, 691  
cysts of, 655  
operations for, 783  
defects of, operation for, 783  
diphtheria of, 655  
eczema of, 655, 693



- Auricle, eczema of, treatment, 693  
 epithelial carcinoma of, 784  
 epithelioma of, 697  
 erysipelas of, 693  
 treatment, 685  
 fibroma of, 696  
 fissures of, operations for, 783  
 frost-bite of, 696  
 function of, 636  
 furunculosis of, treatment, 686  
 hematoma of, 655  
 herpes of, treatment, 685  
 herpes zoster of, 693  
 horny growths of, 697  
 hyperemia of, 654  
 pathology, 654  
 treatment, 685  
 intertrigo of, 654  
 keloids of, 655, 696  
 operation for, 789  
 lupus of, 695  
 treatment, 686  
 malignant growths of, 697  
 muscles of, 636  
 new-growths of, 696  
 operations on, 782  
 pathology of diseases of, 654  
 perichondritis of, 655, 694  
 phlegmonous inflammation of, 655  
 projecting, operation for, 783  
 syphilis of, 695  
 treatment, 686  
 wounds of, 697  
 treatment, 783
- Auricular appendages, removal of, 782
- Auscultation of middle ear, 679
- Auscultatory sound of the ear, 680
- Auto-ophthalmoscopy, 179
- Autopsy of larynx, 873
- Axial hyperopia, 215
- Myopia, 125, 222
- Axis, antero-posterior, of eye, 100
- average length of, 201  
 horizontal, of eye, 100  
 optic, 95, 128  
 visual, 96, 100
- BACILLUS coli communis, chronic tonsillitis from, 929
- diphtheria. See *Klebs-Löffler*.
- Klebs-Löffler*, 281, 284, 614a, 614b, 991, 1011, 1017
- Koch-Weeks', 614a
- lepra, 301, 614b
- ozena, 614d
- of diphtheria. See *Klebs-Löffler*.
- of influenza and ear-disease, 653
- of lepra, 301
- of Pes and Gradenigo in atrophic rhinitis, 960
- of tuberculosis, 392
- of Weeks, 276, 284, 614a
- of xerosis, 296
- Pfeiffer's capsulated, 614d
- pseudo-diphtheritic, 318, 614b, 1019
- pyocyanens, 614d
- pyogenes fetidus, 614d
- tubercle, 356, 614b, 1034
- Bacillus xerosis, 296, 614b
- Bacteria in corneal ulcers, 314, 614c
- in membranous rhinitis, 896
- in ocular diseases, 614a
- relation of, to ear-disease, 651
- Bacterium coli, 614d
- Balsam of Peru in lupous laryngitis, 1066
- in pharyngo-mycosis, 946
- Bandages, 541
- Bandaging in corneal ulcers, 316
- "Barking girls," 1158
- Basedow's disease, 534. See *Eryophthalmic goiter*.
- Basilar membrane, 619
- function of, 643
- Bathing and affections of upper air-passages, 878
- Baume tranquille in furuncle of auditory canal, 703
- Beat, 635
- Behring's diphtheria-antitoxin, 286
- Belladonna in acute catarrhal pharyngitis, 940
- in affections of upper air-passages, 886
- Benign neoplasms of larynx, 1103
- symptoms, 1108
- treatment, 1109
- Benzoate of sodium in chronic laryngitis, 1003
- Benzoin in tracheitis, 997
- tincture in acute catarrhal laryngitis, 986
- in chronic laryngitis, 1003
- vapor in chronic catarrh of middle ear, 733
- Benzoin-and-steam inhalations in laryngitis sicca, 1005
- Benzosol in laryngeal tuberculosis, 1048
- Beri-beri, 136
- Bezold's mastoiditis, 752
- Biborate of soda in laryngeal tuberculosis, 1050
- Bicarbonate of soda for impacted cerumen, 701
- in perforation of tympanic membrane, 688
- Bichlorid of mercury. See also *Mercuric chlorid*.
- in acute croupous tonsillitis, 925
- in atrophic rhinitis, 963, 964
- in chronic myringitis, 714
- in diphtheria, 991
- tablets, 886
- solution in acute otitis media, 722
- Bing's test, 672
- Bimiodid of mercury in syphilitic throat, 877
- Binocular blindness, test for feigned, 467
- field of vision, 167, 471
- fixation, 499
- field of, 502
- single vision, 156, 499
- field of, 502
- vision, 230, 499
- in anisometropia, 231
- Bismuth in chronic rhinitis, 910
- Bjerrum's test-objects for measuring field of vision, 163
- Blandin's operation for deviated septum, 920
- "Blanket," 618
- Blepharitis, 245, 258, 275, 286, 510, 613b
- etiology, 246
- from eye-strain, 214
- hypertrophic, 246
- pathology, 246
- pedicelosa, 247
- prognosis, 247
- simple, 245
- squamous, 245
- treatment, 247
- ulcerated, 245
- vaccine, 344
- Blepharo-adenitis, 245
- Blepharophimosis, 256
- congenital, 244
- Blepharoplasty, 555
- Blepharoptosis. See *Ptosis*.
- Blepharorrhaphy, 547
- Blepharospasm, 253, 306, 409
- clonic, 254
- from eye-strain, 214
- tonic, 254
- Blepharotomy, 547
- Bleyer's tongue-depressor, 872
- Blind spot, 66, 97, 169, 195, 470
- enlargement of, 447
- Blindness, feigned, 466
- influence of Röntgen rays on, 611
- tests for detecting feigned, 467
- unilateral reflex, 150
- Blood, state of, importance in affections of upper air-passages, 879
- Blood-staining of cornea, 326
- Blood-supply of faucial tonsil, 815
- of larynx, 823
- of naso-pharynx, 814
- of pharynx, 814
- Blood-tumor of the auricle, 655
- Blood-vessels of eyeball, 86
- of nasal mucous membrane, 833
- Blue-vision, 468
- Bond's forceps, 1137, 1138
- Bone caries in chronic suppuration of middle ear, 742
- Bone conduction, testing of, 669
- Bonnet's method of emucleation, 571
- Bony cysts of maxillary sinus, 1089
- of nose, 1082
- examination, 1083
- literature, 1084
- microscopical appearance, 1082
- treatment, 1084
- labyrinth, 620
- functions of, 640
- Borated alcohol in furunculosis of ear, 686
- Borax in chronic rhinitis, 910
- in pharyngo-mycosis, 946
- Boric acid in aspergillus mycosis, 686
- in chronic myringitis, 714
- rhinitis, 909

- Boric acid in chronic suppuration of middle ear, 689  
 in conjunctivitis, 275, 277, 280, 285, 287, 289, 293  
 in eczema of auricle, 693  
 in empyema of maxillary sinus, 972  
 in furunculosis of ear, 686  
 in inflammation of auditory canal, 704  
 in injury of drumhead, 713  
 in polypi of auditory canal, 706  
 in wounds of auditory canal, 708  
 insufflation of, in laryngeal tuberculosis, 1050, 1052  
 spray in laryngeal tuberculosis, 1050
- Boric powder in acute myringitis, 713
- Borolyptol in acute nasopharyngitis, 718  
 in chronic naso-pharyngitis, 951
- Bosworth's snare, 978, 979  
 speculum, 859
- Botulismus, 465
- Bougard's paste in lupous laryngitis, 1066
- Bougie, Eustachian, 682
- Bowman, membrane of, 51
- Bowman's lachrymal probes, 270  
 membrane, folding of, 326  
 operation for fistula of lachrymal gland, 596  
 operation of slitting canaliculus, 269
- Brachymetropia. See *Myopia*.
- Brain-abscess, 150  
 course, 762  
 termination, 762  
 from ear-disease, 761  
 operation for, 803  
 symptoms, 762
- Brain-diseases from diseases of ear, operations for, 801
- Brain-tumors, 150, 151, 520  
 a cause of optic-nerve atrophy, 444  
 a cause of optic neuritis, 435  
 mechanism by which they produce optic neuritis, 435
- Brain-vesicles. See *Cerebral vesicles*.
- Brandy in diphtheria, 994, 1020
- Breath, moving column of, 1171
- Breathing in voice-production, 1171
- Bridge-coloboma of iris, 332
- Bright's disease. See *Nephritis*.
- Bromid gargle in acute ulcerative tonsillitis, 928  
 of ethyl, 542  
 of potassium in acute inflammation of middle ear, 686  
 of sodium in acute inflammation of middle ear, 686
- Bromids in acute suppuration of middle ear, 688  
 in congestion of labyrinth, 690
- Bromin in diphtheria, 994
- Bromoform in laryngeal tuberculosis, 1052
- Bronchitis, 391
- Bronchocele, 391
- Bronchotomy for foreign bodies  
 in trachea, 1135
- Brücke's muscle, 131
- Buckley's method, 880
- Bulbar palsy, 150  
 paralysis, 445
- Bulla ethmoidalis, 830
- Buller's shield, 279, 285
- Bullous keratitis, 311
- Buphthalmos, 385
- Burchardt's dots, 140  
 international tests, 152
- Burns of nose, 1118
- Burnt alum in chronic suppuration of middle ear, 746
- Burow's operation for entropion, 551
- Bursa, pharyngeal, 812, 949
- CALCIFICATION of drumhead, 714
- Calculi, nasal, 1129  
 of tonsil, 935
- Calomel conjunctivitis, 295  
 in acute inflammation of middle ear, 686  
 in acute suppuration of middle ear, 689  
 in eczema of auricle, 693  
 in subglottic laryngitis, 988  
 in syphilis of auditory canal, 707  
 powder in syphilis of auricle, 686
- Calomel-sublimation in diphtheria, 1027
- Camera obscura, 88
- Camphor in atrophic rhinitis, 964  
 in chronic rhinitis, 910  
 spray in laryngeal tuberculosis, 1050  
 vapor in chronic catarrh of middle ear, 733
- Camphorated steam in acute rhinitis, 894
- Camphimeter, 163
- Canal, auditory, 625  
 hyaloid, 83  
 neural, 18  
 of Cloquet, 404. See *Hyaloid canal*.  
 of Petit, 85  
 of Schlemm, 55, 86, 87  
 of Stilling. See *Hyaloid canal*.
- Canaliculus, division of, 596  
 knife, 270  
 lachrymal. See *Lachrymal canaliculus*.
- Canalis remiens, 617  
 vestibular, 624
- Cantharid of potassium in laryngeal tuberculosis, 1047
- Canthotomy, 548  
 in gonorrhœal conjunctivitis, 281
- Canthus, inner, 31  
 outer, 31
- Capsular ligaments of larynx, 819
- Capsulary membrane, 23
- Capsule of lens, 80  
 of Tenon, 43  
 cheek ligaments of, 45  
 suspensory ligament of, 45
- Capsulo-pupillary membrane, 23
- Carbolic acid, 459  
 in corneal ulcers, 315  
 in diphtheria, 994  
 in lupus of pharynx, 1059  
 in nasal and pharyngeal tuberculosis, 1057  
 spray in laryngeal tuberculosis, 1050
- Carbolized oil in furunculosis of ear, 686
- Carbon disulphid, 459
- Carbonate of ammonia in diphtheria, 991
- Caruncle of eyelids, 242
- Carcinoma of caruncle, 304  
 of eyelids, 251  
 of lachrymal gland, 264  
 of larynx, 1109-1112  
 of meatus, operation for, 784  
 metastatic, of choroid, 493  
 of ciliary body, 491  
 of naso-pharynx, 1095  
 of nose, 1089  
 removal of, 1198  
 of optic nerve, 449  
 of oro-pharynx, 1102  
 prognosis, 1103  
 symptoms, 1103  
 treatment, 1103  
 of soft palate, 1099  
 treatment, 1100  
 of tonsils, 1101  
 of trachea, 1115  
 primary, of ciliary body, 490
- Cardinal points, 90, 92, 109  
 of a three-index system, 116  
 of human eye, 125  
 of optical surface, graphic method for locating, 113  
 of schematic eye, 92  
 properties of, 90
- Caries in acute mastoiditis interna, 751  
 of mastoid, 752  
 of orbit, 526
- Cartilage, arytenoid, 818  
 cricoid, 817  
 of Santorini, 818  
 thyroid, 816  
 triangular, 830
- Cartilages, emeiform, 816, 818  
 of larynx, 816  
 of nose, fracture of, 1123  
 of Santorini, 816  
 examination of, 871  
 of Wisberg, 816, 818  
 examination of, 871
- Caruncle, 31  
 adenoma of, 304  
 affections of, 304  
 carcinoma of, 304  
 chalky deposits in, 304  
 cysts of, 304  
 duplication of, 274  
 hypertrophy of, 294  
 papilloma of, 304  
 sarcoma of, 304  
 telangiectasia of, 304  
 trichosis of, 274
- Casselberry's method of feeding after intubation, 1031
- Cataract, 333, 385, 386, 404, 519  
 after, 389  
 after-treatment of operations for, 586

- Cataract, albuminuric, 390  
 anterior polar, 389  
 artificial ripening of, 395  
 black, 392  
 capsular, 390  
 capsulo-lenticular, 390  
 central lental, 390  
 combined extraction of, 582  
 complete, of young persons, 387  
 complicated, 388  
 concussion, 388  
 conditions influencing the result of operations on, 394  
 congenital, 387, 457  
 cortical, 388, 389  
 course, 393  
 development, 393  
 diabetic, 390  
 diagnosis, 393  
 discussion of, 395  
 entopic phenomena as a symptom of, 141  
 etiology, 391  
 extraction of, 347, 395, 580  
 in capsule, 582  
 immature, 394  
 monocular, 395  
 operation for, 580  
 with iridectomy, 582  
 following lightning-stroke, 392  
 fusiform, 390  
 glasses for, 396  
 glaucoma after extraction of, 578  
 glaucomatous, 377, 379  
 history, 386  
 hypermature, 392  
 immature, ripening operations for, 584  
 in chromatic asymmetry of iris, 147  
 incipient, 231, 392  
 from eye-strain, 214  
 inflammatory, 341  
 juvenile, 387  
 lamellar, 387  
 light field in, 394  
 linear extraction of, 395, 582  
 mask for, 586  
 methods of extracting, if vitreous escapes, 582  
 of opening capsule in extraction of, 581  
 mistakes and accidents, during extraction of, 582  
 Morgagnian, 392  
 naphthalin, 392  
 nuclear, 388, 389  
 operations for, 395, 579  
 pathology, 390  
 periods of development of, 392  
 posterior polar, 389, 426  
 process of ripening of, 393  
 prognosis, 393  
 punctate, 390  
 pyramidal, 389  
 raphanic, 392  
 relation of accommodative strain to the development of, 392  
 of acute and chronic diseases of eye to development of, 391
- Cataract, relation of heredity to development of, 391  
 of occupation to development of, 391  
 of sex to development of, 391  
 results after extraction of, 583  
 secondary, 389  
 operations for, 585  
 senile, 388  
 simple extraction of, 395, 580  
 soft, operation for, 582  
 special clinical forms of, 390  
 starvation-, 392  
 suction method of operating for, 395  
 symptoms, 392  
 traumatic, 347, 357, 384, 387, 392  
 operation for, 582  
 treatment, 394  
 varieties, 386  
 zonular, 387
- Catarrh, acute middle-ear, pathology, 659, 717  
 acute post-nasal, 947  
 American, 948  
 chronic post-nasal, 948  
 of middle ear, chronic, 726  
 sero-mucous, of the middle-ear, pathology, 659
- Catarrhal inflammation of upper air-passages, 844  
 etiology, 844  
 pathology, 847  
 laryngitis, acute, 985. See *Laryngitis*.  
 pharyngitis, acute, 939. See *Pharyngitis*.  
 chronic, 940. See *Pharyngitis*.  
 tracheitis, acute, 996
- Catheterization of the ear, 679  
 dangers of, 681  
 obstacles to, 680  
 substitutes for, 681, 733
- Catoptric test, 393
- Catoptrics, 102, 109
- Caustic potash for ceruminous masses in ear, 685, 700  
 in lupus of auricle, 686
- Caustics in air-passages, 887  
 in diphtheria, 1028
- Cauterization in chronic laryngitis, 1001  
 in epistaxis, 903
- Cautery in corneal ulcers, 315
- Cautery-points, 888
- Cavernoma of choroid, 493  
 of conjunctiva, 274, 390
- Cavernous sinus, thrombosis of, 529, 759  
 aneurysmal varix of, 534
- Cavity, drum, 626, 627  
 tubo-tympanic, 626
- Cellulitis of orbit, 527
- Center of optical surface, 109  
 of rotation, 96  
 optical, 117, 119, 120, 123  
 of a lens, 118
- Centered optical systems, 114
- Centers, auditory, 645, 776
- Central, 133  
 system of Bennett, 133
- Centrum ovale, hemorrhage into, 150
- Cephalic visceral arches, 809  
 clefts, 809
- Cerebellar ataxia in brain-abscess, 763  
 fossa, 623  
 tumors, 435
- Cerebellum, hemorrhage into, 150
- Cerebral abscess from ear-disease, 761  
 operation for, 803  
 origin of ear-disease, 652  
 peduncles, hemorrhage into, 150  
 softening, 150, 437, 445, 762  
 tumors in etiology of ear-disease, 648  
 vesicles, primary, 18  
 secondary, 19
- Cerebro-spinal meningitis, 339, 355  
 relation of, to ear-disease, 652  
 sclerosis, 151
- Cerebrum. See *Brain*.
- Cerumen, impacted, 699  
 etiology, 700  
 symptoms, 699  
 treatment, 684, 700
- Cervical ganglion, 97
- Chalazion, 249
- Chanere of eyelids, 247  
 of nose and throat, 1065
- Check ligaments, 45
- Cheesy pus in chronic suppuration of middle ear, 743
- Chemosis of conjunctiva, 298
- Cherry-red spot, 407
- Chiasm, optic, 438, 445, 478.  
 See also *Optic chiasm*.  
 diseases of, 480
- Chloracetic acid in laryngeal tuberculosis, 1050  
 in rodent ulcer, 252
- Chloral, 459
- Chlorate of potassium, 252, 886
- Chlorid of ammonium in affections of nose and throat, 885  
 in laryngeal tuberculosis, 1049  
 vapor, 883  
 of gold and sodium in laryngeal tuberculosis, 1047  
 in nasal and pharyngeal tuberculosis, 1057  
 of mercury in diphtheria, 994  
 of sodium in pachydermia of larynx, 1008  
 of zinc in chronic inflammation of lingual tonsil, 931  
 in diphtheria, 991  
 in laryngeal tuberculosis, 1047  
 in lypous laryngitis, 1066  
 spray in laryngeal tuberculosis, 1050
- Chlorinated soda in diphtheria, 1028
- Chlorin-gas in diphtheria-infection, 1015
- Chlorin-water in laryngeal tuberculosis, 1047, 1051  
 in nasal and pharyngeal tuberculosis, 1057



- Chloroform, 542  
 in acute otitis media, 721  
 in spasm of larynx, 1156
- Chloroma of lachrymal gland, 264
- Chlorosis, 410, 437
- Choana, 832
- Chocolate, 459
- Choked disk. See *Optic neuritis*.
- Cholera, 538
- Cholesteatoma of auditory canal, 704  
 of drumhead, 714  
 of ear, 753  
 of middle-ear, pathology, 661
- Chondroma of larynx, 1108  
 of nose, 1084  
 of trachea, 1115
- Chondromalacia of auricle, 694
- Chondritis tuberosa, 1005. See *Laryngitis, nodular*.
- Chorea, 406, 509, 511  
 color of iris in, 117  
 from eye-strain, 211  
 of larynx, 1158
- Chorio-capillaris, 58, 59, 189
- Chorio-retinitis, 457  
 striata, 428
- Choroid, 57, 301  
 angiona of, 493  
 atrophy of, 353  
 calcareous degeneration of, 357  
 capillary network of, 57  
 cavernoma of, 493  
 changes in, from eye-strain, 213  
 changes in, from myopia, 221  
 changes in visual field in diseases of, 475  
 circumpapillary coloboma of, 456  
 colloid degeneration of, 354  
 coloboma of, 192, 351, 457  
 congenital anomalies of, 351  
 contusion injuries of, 364  
 detachment of, 357, 364, 491  
 development of, 27  
 diseases of, 351  
 hemorrhage of, 364, 399, 428  
 hyperemia of, 352  
 lamina vitrea of, 59  
 layers of, 57  
 lymphatics of, 59  
 metastatic carcinoma of, 493  
 metastatic sarcoma of, 493  
 nerves of, 59  
 ossification of, 357  
 rupture of, 354, 357, 364, 392  
 sarcoma of, 491  
 senile areolar atrophy of, 354  
 solitary tubercle of, 356  
 stroma of, 58  
 tuberculosis of, 356  
 tumors of, 491
- Choroidal cleft, 22, 332, 333, 351  
 fissure, 26. See *Choroidal cleft*.  
 ring, 64, 184  
 stroma, 58
- Choroiditis, 189, 314, 352, 391, 396, 399, 403, 475  
 areolar, 353  
 central, 354  
 disseminated, 352, 426  
 etiology, 352
- Choroiditis, exudative, 352  
 from injuries, 354  
 guttate, 354  
 hemorrhagic, 351  
 metastatic, 355, 398  
 myopic, 354  
 pathological anatomy, 352  
 prognosis, 355  
 recent, 353  
 suppurative, 355, 356  
 symptoms, 353  
 syphilitic, 353  
 traumatic, 365  
 treatment, 355  
 unclassified forms, 354
- Choroido-retinal aberrant artery, 490
- Choroido-retinitis, 357, 387  
 sympathetic, 348  
 syphilitic, 419
- Chromatometer, 154
- Chromato-photo-optometer, 154
- Chromic acid, 887  
 in chronic follicular pharyngitis, 943  
 in chronic inflammation of lingual tonsil, 934  
 in chronic laryngitis, 1004  
 in chronic myringitis, 714  
 in chronic naso-pharyngitis, 952  
 in chronic rhinitis, 911  
 in condylomata of auditory canal, 707  
 in epistaxis, 903  
 in lupus of pharynx, 1059  
 in new growths of drumhead, 714  
 in nodular laryngitis, 1006  
 in pachydermia of larynx, 1008  
 in pharyngomycosis, 946  
 in polypi of auditory canal, 706
- Chromidrosis of eyelids, 259
- Chronic catarrh of middle ear, 726. See *Middle ear*.  
 catarrhal pharyngitis, 940. See *Pharyngitis*.  
 conjunctivitis. See *Conjunctivitis, chronic*.  
 encysted tonsillar abscess, 935  
 follicular pharyngitis, 942. See *Pharyngitis*.  
 hypertrophic rhinitis, 905  
 inflammation of lingual tonsil, 932  
 lacunar tonsillitis, 928. See *Tonsillitis*.  
 laryngitis, 998. See *Laryngitis*.  
 lingual tonsillitis, 932  
 mastoiditis interna, 754  
 myringitis, 713  
 naso-pharyngitis, 948. See *Naso-pharyngitis*.  
 non-suppurative inflammation of middle ear, 726  
 otorrhea, 660  
 parenchymatous tonsillitis, 929  
 post-nasal catarrh, 948  
 purulent inflammation of middle ear, 660  
 sinusitis, 973  
 subglottic laryngitis, 1008
- Chronic suppuration of middle ear, 739  
 tonsillar inflammations, 928  
 tonsillitis due to bacillus coli communis, 929  
 uvulitis, 938
- Chrysarobin, 295
- Cilia, 32  
 epilation of, 257  
 removal of, 544
- Ciliary arteries, 86  
 anterior, 86, 87  
 posterior, 86  
 body, 59, 84  
 adenoma of, 490  
 blood-vessels of, 61  
 contusion, injuries of, 364  
 cysts of, 491  
 diseases of, 344  
 injuries of, 346  
 metastatic carcinoma of, 491  
 myoma of, 490  
 myosarcoma of, 490  
 nerves of, 61, 490  
 penetrating wounds of, 347  
 primary carcinoma of, 490  
 sarcoma of, 491  
 tumors of, 490  
 border, scalping, 545  
 congestion, 143  
 glands, 86  
 margin, preparation of, for operations, 540, 574  
 muscle, 60, 95, 134  
 relation of, to accommodation, 95, 134  
 traumatic paralyses of, 360  
 traumatic spasm of, 360  
 nerves, 97  
 -nerve theory of sympathetic ophthalmitis, 349  
 neuralgia, 338  
 processes, 60, 95  
 development of, 28  
 ring, 59  
 staphyloma, 330  
 veins, 87  
 vessels, anterior, 113
- Cilio-retinal artery in relation to embolism of central artery of retina, 189, 408  
 vessels, 185, 490  
 in embolism, 408
- Cilium-forceps, 544
- Circulus venosus ciliaris. See *Schlemm's canal*.
- Circumtonsillar inflammation, acute, 925, 926
- Cisterna perilymphatica, 620
- Cleft eyelid, 241  
 of the lobule, 698
- Clinacteric, 319, 352, 420, 436
- Clouet, canal of. See *Hyaloid canal*.
- Coal-tar products, 459
- Cocain, 149, 210, 459, 542  
 and atropin in diffuse inflammation of auditory canal, 704  
 in furunculosis of auditory canal, 703  
 effect of, on corneal epithelium, 326  
 on paralytic myosis, 150  
 hydrochlorate in acute otitis media, 724



- Cocain in acute catarrhal pharyngitis, 940  
 in acute inflammation of middle ear, 687  
 in acute naso-pharyngitis, 945  
 in acute rhinitis, 895  
 in acute tonsillitis, 924  
 in acute ulcerative tonsillitis, 928  
 in chronic catarrhal pharyngitis, 941  
 in chronic inflammation of lingual tonsil, 934  
 in chronic rhinitis, 910  
 in corneal ulcers, 316  
 in diphtheria, 1028  
 in diseases of nose and throat, 885  
 in enlargement of epiglottis, 937  
 in examining nostrils, 862  
 in excision of conducting mechanism, 791  
 in herpes of auricle, 686  
 in lingual tonsillitis, 927  
 in membranous rhinitis, 898  
 in salpingitis, 723  
 spray in laryngeal tuberculosis, 1050
- Coccidia, 259
- Cochlea, 621  
 function of, 643
- Cochlear tube, 617
- Cocain in acute catarrhal laryngitis, 986  
 in acute rhinitis, 893  
 in laryngeal tuberculosis, 1049
- Cod-liver oil in chronic suppuration of middle ear, 746  
 in lupous laryngitis, 1066  
 in lymphoid hypertrophy, 956  
 in spasm of larynx, 1156
- Coffee, 459
- Colchicum in acute catarrhal pharyngitis, 940
- Cold applications in conjunctivitis, 280, 285
- Cold in acute suppuration of middle ear, 688  
 in etiology of catarrhal inflammations, 814  
 in the head, 891. See *Rhinitis, acute*.  
 wire snare, 912
- Colloid bodies of optic disk, 451
- growths of larynx, 1108
- Coloboma of choroid, 192, 351, 457  
 circumpapillary, of choroid, 456  
 of crystalline lens, 191, 397  
 of eyelid, operations for, 557  
 of iris, 191, 332, 469  
 of lobule, operation for, 782  
 of macula, 193, 351  
 of optic nerve, 191, 455, 457  
 of optic nerve-sheath, 455  
 pupillare. See *Left eyelid, traumatic*, 392
- Color of upper air-passages, alterations of, 853
- Color-blind, disposition of, 605
- Color-blindness, 190, 153, 451  
 methods of detecting, 603
- Color-field, 167
- Color-fields, reversal of, 486
- Color-hearing, 777
- Color-measurer, 154
- Color-perception, 98, 99
- Color-sectomas, 99
- Color-sensations, 169
- Color-sense, 153  
 in optic-nerve atrophy, 443  
 quantitative estimation of, 604  
 subnormal, 457  
 tests for, 153, 154, 155
- Color-vision, 141  
 standard of, in railway service, 605
- Colors, complementary, 99  
 congenital amblyopia for, 457  
 measurement of vision for, 153  
 mixed, 99  
 simple, 98  
 spectral, 98
- Columna of nose, restoration of, 1188
- Commotio retinae, 364, 414
- Commutor, 888
- Compressor lentis, 131
- Compsomyia mascellaria in frontal sinuses, 980
- Conch of middle turbinated bone, 829
- Concussion of the head, effect on labyrinth, 776
- Condensing mastoiditis, 751
- Condylomata of drumhead, 714
- Cone of light, 676
- Cone-visual cell, 70
- Cones, number of, 71  
 size of, in macula lutea, 139
- Congenital cataract. See *Cataract, congenital*.  
 conus, 194  
 fissure of lobule of ear, 692  
 fistula of ear, 692  
 operation for, 783  
 ptosis, 242, 254
- Conical cornea, 179, 222, 231, 328  
 keratoscopic appearances of, 328  
 operation for, 568  
 treatment, 328
- Conium, 254
- Conjugate, definition of, 124  
 deviation of eyes, 519  
 foci, 103, 108  
 relation of, to principal foci, 111  
 images, 111
- Conjunctiva, 30, 35  
 abscess of, 298  
 acute hemorrhage of, 278  
 amyloid disease of, 296  
 argyria of, 304  
 atrophy of, 291  
 benign tumors of, 300  
 blood-vessels of, 143  
 burns of, 358  
 cavernoma of, 271, 300  
 chemosis of, 298  
 cicatricial changes in, 296  
 cicatricial contraction of, 258  
 congenital anomalies of, 271  
 congenital tumors and cysts of, 300
- Conjunctiva, cylindroma of, 301  
 cysticercus cysts of, 301  
 cysts of, 293, 300  
 dermoid cysts of, 274  
 dermoid tumors of, 274  
 diseases of, 274  
 ecchymosis of, 298, 360  
 echinococcus cysts of, 301  
 eczema of, 286  
 emphysema of, 299  
 epithelioma of, 301  
 epithelium of, 36  
 essential atrophy of, 296  
 fibromata of, 293, 301  
 foreign bodies in, 368  
 gumma of, 300  
 herpes of, 287  
 horny granulations of, 293  
 hyperemia of, 274  
 hypertrophy of, 291  
 injuries of, from heat and chemicals, 358  
 lepra of, 302  
 lime burns of, 301  
 lipoma of, 274, 358  
 lithiasis of, 295  
 lupus erythematosus of, 302  
 lymph-follicles of, 35  
 lymphangiectasis of, 299  
 lymphomata of, 293  
 malignant tumors of, 301  
 mechanical injuries of, 359  
 myxoma of, 301  
 operations on, 561  
 osteoma of, 274, 301  
 papilloma of, 301  
 pemphigus of, 303  
 pigment-patches of, 274  
 polyp of, 547  
 preparation of, for operations, 510, 574  
 removal of foreign bodies from, 561  
 sarcoma of, 301  
 streptococcus-diphtheria of, 614  
 syphilis of, 300  
 telangiectatic patches of, 274  
 temperature of, 114  
 tuberculosis of, 302  
 tumors of, 300  
 wounds of, 359  
 xerosis of, 296, 318
- Conjunctival hemorrhage in nephritis, 298  
 veins, varix of, 248  
 vessels, anterior, 144  
 posterior, 143
- Conjunctivitis, 143, 249, 254, 256, 266, 275, 510  
 acute contagious, 276  
 catarrhal. See *Conjunctivitis, simple*.  
 chronic, 246, 294  
 cold applications in, 277  
 croupous, 283  
 diphtheritic, 258, 284, 285  
 diplo-bacillus, 614  
 epidemic catarrhal. See *Conjunctivitis, acute contagious*.  
 follicular, 289  
 from calomel, 295  
 from electricity, 468  
 from eye-strain, 214  
 from mydriatics, 295  
 from myotics, 295

- Conjunctivitis from Röntgen rays, 468  
 from stings of insects, 296  
 gonorrhœal, 266, 278, 279  
 granular. See *Trachoma*.  
 hemorrhagic catarrhal, 277  
 infectious, of animal origin, 614c  
 lachrymal, 291, 614b  
 lymphatic, 286  
 membranous, 283, 614b  
 muco-purulent, 276  
 neonatorum, 281, 282  
   antepartum, 281  
   corneal complications in, 282  
 Parinaud's, 614c  
 phlyctenular, 286, 287, 614b  
 pneumococcus, 275, 614a  
 purulent, 278  
   ulcers of cornea in, 316  
 simple, 275  
 tea-leaf, 278  
 traumatic, 275  
 toxic, 295  
 ulcers of cornea in gonorrhœal, 279  
   vernal, 287, 288  
 Consensual action of pupil, 148  
 Constrictor of pharynx, inferior, 814  
   middle, 814  
   superior, 814  
 Contorsion, 500  
 Contraction of pupil, 150  
 Contusions of nose, 1116  
 Coxus, 184, 192, 221  
   atrophic, 193  
   congenital, 194  
   underlying, 194  
 Convergence, 500  
   effect of, on pupillary contraction, 148  
   excess, 515  
   insufficiency, 517  
   movements of, 502  
   near-point, 503  
   nerve-center governing movements of, 502  
   paralysis, 517  
   power of, 161  
 Convergence-adduction, 503  
 Convergence-reaction of pupil, 148  
 Convulsions, 391, 409  
 Corectopia, 331  
 Corelysis, 343, 579  
 Corestenoma congenitum, 334  
 Cornea, 50, 89  
   abscess of, 313  
   anterior elastic lamina of, 51  
     epithelium of, 51  
     limiting membrane of, 51  
   arcuate fibers of, 52  
   blood-staining of, 326  
   blood-vessels of, 52  
   burns of, 358  
   cellular elements of, 52  
   changes in form of, caused by inflammation, 323  
   congenital opacities of, 329  
   staphyloma of, 329  
   conical, 328. See *Conical cornea*.  
   connective-tissue stroma of, 21  
 Cornea, contusions of, 359  
   creeping ulcer of, 313  
   curteting of, 567  
   curvature of, 196  
   diameter of, 146  
     in glaucoma, 376  
   dendritic ulcers of, 310  
   dermoid tumors of, 329  
   diseases of, 365  
   epithelioma of, 329  
   epithelium of, 21  
   erosions, of, 359  
   fibroma of, 329  
   fistula of, 321, 384  
   flattening of, 323  
   foreign bodies on, 368  
   form of, 50  
   geometrical figures in, 326  
   herpes of, 309  
   index of refraction of, 89, 92  
   infiltration of, with lymph, 326  
   inflammation of. See *Keratitis*.  
   injuries of, from heat and chemicals, 358  
   inspection of, 145  
   lepra of, 329  
   lime-burns of, 358  
   massage of, 322  
   mechanical injuries of, 359  
   micro-organisms in ulcers of, 311, 614c  
   morbid growths of, 329  
   nerves of, 52  
   non-inflammatory changes in form of, 327  
   opacities of, 322  
     due to metallic deposits, 326  
   operations upon, 566  
   panel-like opacities of, 326  
   papilloma of, 329  
   paracentesis of, 567, 578, 584  
   posterior elastic membrane of, 52  
   posterior endothelium of, 52  
   limiting membrane of, 52  
   powder-grains in, 368  
   primary transverse opacity of, 325  
   proper substance of, 51  
   radius of curvature of, 92  
   removal of foreign bodies from, 566  
   removal of powder-grains from, 567  
   results of inflammation of, 322  
   rodent ulcers of, 313  
   rupture of, 362  
   sarcoma of, 329  
   sensibility of, 146  
   serpiginous ulcer of, 311  
   staphyloma of, 323  
   structure of, 51  
   suppurative inflammations of. See *Keratitis, suppurative*.  
   tattooing of, 323, 568  
   transparent ulcer of, 309  
   transparent opacities of, 326  
   transplantation of, 323, 569  
   tuberculosis of, 318  
   ulcer of, 145, 245, 293, 313, 314, 315, 527  
     after tenotomy, 591  
     from gonorrhœal conjunctivitis, 279  
 Cornea, ulcer of, in small-pox, 317  
   vaccinal abscess of, 318  
   vertical meridian of, 197  
   wandering cells of, 52  
   width of, 145  
   wounds of, 568  
   wrinkling of, 324  
   zonular opacity of, 325  
 Corneal corpuscles, 52  
   loupe, 147  
   microscope, 147  
   reflection, size of, 196  
   reflex, 181  
   section during cataract-extraction, 580, 582  
 Corneo-scleral juncture. See *Sclero-corneal juncture*.  
 Cornicula laryngis, 816, 818  
 Cornu cutaneum, 248  
 Corpora geniculata, 479  
   quadrigemina, 149, 479  
 Corrosive sublimate in condylomata of auditory canal, 707  
 Corti, membrana tectoria of, 619  
 Corti's organ, function of, 644  
   rods, 619  
 Coryza, 891. See *Rhinitis, acute*.  
   fetida, 957  
 Couching, 395, 580  
 Cough, nasal, 1150  
   nervous, 1158  
 Counter-field, 110, 486  
 Couper's ophthalmoscope, 173  
 Crede's method of prophylaxis in conjunctivitis neonatorum, 282  
 Creolin in laryngeal tuberculosis, 1052  
   spray in laryngeal tuberculosis, 1050  
 Creosote in laryngeal tuberculosis, 1047, 1048  
   spray in laryngeal tuberculosis, 1050  
 Crescent, myopic, 221  
 Crest, acoustic, 618  
 Cribriform plate of ethmoid, 826  
 Cricio-arytenoid ligaments, 819  
   muscles, lateral, 821  
 Cricio-arytenoidea laterales, paralysis of, 1167  
 Cricio-arytenoids in voice-production, 1173  
 Cricoid cartilage, 817  
 Cricothyroid artery, 825  
   membrane, 819  
   muscle, 822  
   in voice-production, 1173  
 Critchett's operation for staphyloma, 571  
   of tenotomy, 587  
 Crossed cylinders, 229  
   lateral deviation, 157  
   paresis in brain abscess, 763  
 Croup, 990. See *Laryngitis, croupous*.  
   false, 986  
 Croupous conjunctivitis. See *Conjunctivitis, croupous*.  
   inflammation of upper air-passages, 848  
   laryngitis, 990  
   rhinitis, 896  
   tonsillitis, acute, 925

- Crus cerebri, 479  
 Crypto-glioma, 494  
 Cryptophthalmos, 241  
 Crystalline body, operations on, 571  
   lens. See *Lens, crystalline*.  
 Cuneiform cartilages, 816, 818  
 Curare, 460  
 Curettement in lupus of pharynx, 1059  
 Curetting in corneal ulcers, 315  
 Curvature-hyperopia, 215  
 Curvature-myopia, 222  
 Curves, study of, 103  
 Cushion of epiglottis, 818  
   Passavant's, 811  
 Cutaneous horns, 248  
 Cyanid of mercury in diphtheria, 995  
 Cyanuret of mercury, 540  
 Cyclic membrane, 345  
 Cyclitis, 114, 117, 215, **344**, 366, 396, 492, 494, 495  
   diagnosis, 345  
   etiology, 344  
   pathological anatomy, 345  
   plastic, 344  
   prognosis, 345  
   purulent, 345  
   serous, 344  
   symptoms, 344  
   traumatic, 344  
   treatment, 346  
   with capsulitis after cataract-extraction, 503  
 Cyclophoria. See *Insufficiency of oblique muscles*.  
 Cyclopia, 523  
 Cycloplegia, 511  
   traumatic, 360  
 Cylinder, crossed, 229  
 Cylinders, 126, 128  
   distortion of retinal images by, 230  
 Cylindrical lens, 207, 228  
   testing of, 210  
 Cylindroma of conjunctiva, 301  
   of lachrymal gland, 264  
 Cyst of lachrymal gland, 262  
 Cystectomy, 586  
 Cysticercus, 348, 428  
   cysts of conjunctiva, 301  
   in anterior chamber, 344  
   in vitreous, 402  
   of eyelids, 260  
   subretinal, 431  
 Cystoid cicatrix, 324, 353  
 Cystomata of nose, 1084  
 Cystotome, 580  
 Cysts, dermoid, of conjunctiva, 271  
   of auricle, 655  
   operations for, 783  
   of ear-canal, 304  
   of ciliary body, 491  
   of conjunctiva, 293, 300  
   of iris, 189  
   of larynx, 1108  
   of maxillary sinus, 1089  
   of nasal mucous membrane, 1084  
   of nose, bony, 1082  
   of orbit, 534  
   of oropharynx, 1096  
   of retina, 494  
   of DAAE's test for color-sense, 154  
   Dacryo-adenitis, acute, 261  
   chronic, 261  
   Dacryo-cystitis, 265, 295  
   acute, 267  
   chronic, 266  
   treatment, 268  
   Dacryoliths, 262, 263, 265  
   Dacryops, 262  
   Dabymple's sign, 535  
   Danger-signals in chronic suppuration of middle ear, 745  
   Darby's artificial finger-nail, 1202  
   Daturin, 209  
   David's spoon, 580  
   Day-blindness. See *Hemeralopia*.  
   Deaf-mutism, 777  
   treatment, 781  
   Deafness from otitis media, 716, 719  
   in acute affections of tympanic cavity, 716  
   in brain-abscess, 763  
   in chronic catarrh of middle ear, 729  
   operations for, 789  
   Defects of auricle, operation for, 783  
   Deflection of nasal bones, treatment, 1182  
   of nasal septum in etiology of nasal obstruction, 849  
   Deformities of nasal septum, operations for, 1190  
   of nose, operative treatment of, 1180  
   of turbinated bones, 1194  
   Degeneration of acoustic nerve, etiology, 770  
   Deglutition in diseases of upper air-passages, 853  
   Delirium in diphtheria, 1016  
   Demours's membrane, 52  
   Dench's tuning-fork, 669  
   Dendritic keratitis, 310  
   Dennett's test-types, 140  
   Denonvillier's method, 1187  
   Dental defects in cataract, 387  
   disease, 454  
   Deorsumversion, 501  
   Depression, olfactory, 807  
   Dermoid cyst of pharynx, 1094  
   of orbit, 534  
   of eyelids, 260  
   tumors of conjunctiva, 271, 300  
   Dermoids, lipomatous, 300  
   Descemet's membrane, 28, **52**, 55, 61, 336, 337  
   folding of, 326  
   perforation of, 311  
   Descemetitis. See *Keratitis, punctata*.  
   Dissection for soft cataracts, 584  
   Desquamated epithelium in chronic suppuration of middle ear, 743  
   Desquamative otitis, 753  
   Deviation-angle system of Jackson, 133  
   Deviation of nasal septum, 831, 915, 916  
   forcible correction by forceps, 1192  
   treatment, 917, 1191  
   Deviation of tip of nose, treatment, 1182  
   Deviations. See also *Strabismus, Heterophoria, Insufficiency, and Ocular muscles*.  
   associated parallel, 519  
   convergent, 515  
   divergent, 517  
   varieties of, 504  
   vertical, 518  
   De Wecker's method of advancement, 590  
   of capsule, 594  
   operation for staphyloma, 570  
   Dextrodruction, 502  
   Dextrotorsion, 502  
   Dextroversion, 500  
   Diabetes, 222, 339, 391, 394, 419, 421, 445, 458, 461, 511  
   insipidus, 419, 445  
   of ear, 685  
   Diachylon ointment, 244  
   Diellenbach's method of blepharoplasty, 556  
   operation of rhinoplasty, 1188  
   for deviated septum, 917  
   Diet in affections of upper air-passages, 880  
   in diphtheria, 1033  
   Diffusion-circles, 94  
   Digastric muscle in voice-production, 1173  
   Digitalis, 459  
   in diphtheria, 994, 1020  
   Dilatation of pupil, 149  
   cerebral origin of, 150  
   spinal origin of, 150  
   Dilatator pupillæ, 64, 96  
   Dilator center, 97  
   Dioptræ, the, 122, 123  
   Dioptric apparatus, 89  
   system, 100  
   Dioptries, 102, **109**  
   Diphtheria, 284, 436, 511, **991**, **1010**  
   -antitoxin, 286, **1020**  
   dose of, 1024  
   in atrophic rhinitis, 960, 963, 965  
   injurious effects of, 1023  
   preparation of, 1020  
   site of injection, 1025  
   testing of, 1025  
   bacillus of, 994, 1011, 1017.  
   See also *Klebs-Löffler bacillus*.  
   in membranous rhinitis, 896  
   diagnosis, 993, 1017  
   from membranous croup, 993  
   diet in, 1033  
   disinfection in, 1014, 1015  
   etiology of, 991, 1011  
   history, 1010  
   intubation in, 1029  
   morbid anatomy, 1012  
   nasal feeding in, 1031  
   of auricle, 655  
   of eye, 1032  
   otitis media from, 748  
   pathology, 992  
   prognosis, 994, 1019  
   prophylaxis, 1013  
   relation of, to ear-disease, 651  
   symptoms, 992, 1016  
   tracheotomy in, 1031  
   treatment, 994, 1020

- Diphtheritic conjunctivitis, 258. See *Conjunctivitis, diphtheritic*.  
inflammation of upper air-passages, 848
- Diploacsis, 777
- Diplo-bacillus, 614c  
conjunctivitis, 614c
- Diplococcus in oro-pharynx, 846  
in labyrinth, 767  
of Löwenberg in atrophic rhinitis, 960  
of pneumonia in ear-disease, 653  
pneumoniae, 614a
- Diplopia, 499, 509, 525  
a test for insufficiency of the ocular muscles, 156, 157  
monocular, in cataracts, 392  
region of, 157  
varieties, 500
- Direct method of ophthalmoscopy, 175  
measure of refraction by, 199  
reflex action of pupil, 148
- Discharge, aural, as a symptom, 667
- Dissection, 395, 584  
for secondary cataract, 585  
glaucoma after, 578, 586  
of cataract, 347
- Dislocation of nasal bones, 1125
- Dislocations of cartilages of nose, 1126
- Disseminated sclerosis, 151, 445, 447, 448, 520  
field of vision in, 167
- Dissonance, 636
- Distichiasis, 257  
congenital, 241
- Distortion, 500
- Divergence, 500  
movements of, 503
- Divergence-abduction, 503
- Divergence-insufficiency, 516
- Divergence-paralysis, 516
- Dobell's solution, 882, 883  
in chronic naso-pharyngitis, 951  
in chronic rhinitis, 909  
in sarcoma of soft palate, 1099
- Donder's schematic eye, 92
- Douches, 883
- Dover's powder in acute naso-pharyngitis, 948  
in acute rhinitis, 893
- Drainage of frontal sinuses, 980, 981  
of maxillary antrum, 972
- Dressings, 541
- Drum-cavity, 626, 627  
paracentesis of, 786
- Drumhead, 629  
acute primary inflammation of, 713  
angiona of, 714  
calcification of, 711  
cholesteatoma of, 714  
chronic inflammation of, 713  
condylomata of, 714  
development of, 622  
direct injuries of, 711  
epithelioma of, 714  
fibroma of, 714
- Drumhead, hemorrhage in, 711  
hyperemia of, 711  
infectious diseases of, 711  
injuries and diseases of, 711, 712, 713  
myxoma of, 714  
new growths of, 714  
polypi of, 714  
rupture of, 712  
small-pox of, 714  
syphilis of, 714
- Drusen, 451
- Dry heat in acute otitis media, 721  
mouth, 936
- Duboisin, 209
- Duct, endolymphatic, 617  
naso-lachrymal, 47
- Duplay's speculum, 859
- Dura, opening of, 801
- Dural sheath of optic nerve, 79
- Dust in affections of upper air-passages, 880  
"Dutch garden symmetry," 1069
- Dynamic strabismus, 156
- Dyschromatopsia, 458
- Dyscoria, 334
- Dysmenorrhea, 344
- Dysphagia, 853  
in diphtheria, 1016  
in laryngeal tuberculosis, 1039
- Dysphonia, 1158  
in laryngeal tuberculosis, 1039
- Dyspnea in acute phlegmonous laryngitis, 989  
in chronic subglottic laryngitis, 1008  
in croupous laryngitis, 991  
in lupous laryngitis, 1060  
in subglottic laryngitis, 987  
in tracheitis, 997
- EAR, abscess of, pathology, 655  
anatomy, 617  
anomalies of secretion of, treatment, 684  
aspergillus-mycosis of, 657  
treatment, 686  
auscultatory sounds of, 680  
blood-tumor of, pathology, 655  
catheterization of, 679  
cholesteatoma of, 753  
congenital fistula of, 692  
cysts of, 655  
diphtheria of, pathology, 655  
discharge from, 667  
diseases of, complications, 749  
eczema of, pathology, 654  
treatment, 685  
embryology of, 617  
examination of, 673  
external, affections of, 691  
anatomy, 625  
functional examination of, 668  
furunculosis of, treatment, 686  
herpes of, treatment, 685  
illumination of, 673  
inter-trigo of, treatment, 685  
keloids of, 655  
lupus of, treatment, 686
- Ear, menstruation from, 650  
middle, 626  
inflation of, with auscultation, 679  
ossicles of, 630  
osteology of, 620  
perichondritis of, 655  
physiology of, 634  
syphilis of, treatment, 686
- Earache, 715  
as a symptom, 667
- Ear-disease, etiology, 647  
cause, 668  
clinical history in, 665  
examination blank for, 683  
examination of patients, 665  
pathology, 654  
symptomatology and diagnosis, 665  
therapeutics, 684
- Ear-forceps, 674
- Ear-scoop, 674
- Ear-speculum, 673
- Ear-syringe, 674
- Eburnation, 751
- Echondrosis of trachea, 1115
- Echymosis of conjunctiva, 298, 360  
of eyelids, 371
- Echinococcus cysts of conjunctiva, 301  
of orbit, 531
- Echo, 634
- Ectoderm, 19, 20
- Ectopia lentis, 396
- Ectropia pupillae, 334
- Ectropion, 255, 258, 372, 526  
cicatrical, of upper lid, operations for, 553  
congenital, 241  
operations for, 551, 552  
organic, 258  
spasmodic, 258  
treatment, 258  
uveae, 378
- Eczema, 246, 275  
of auricle, 654, 693  
treatment, 693  
of conjunctiva, 286  
of ear, treatment, 685  
of eyelids, 241  
from eye-strain, 214  
seborrhœicum, 246
- Edema of larynx, 989, 990, 1139
- Edematous polypi of larynx, 1105  
of maxillary sinus, 1089  
of nose, 1076
- Egyptian ophthalmia, 294
- Electric ophthalmia, 468
- Electricity, 426  
in affections of upper air-passages, 886  
in atrophic rhinitis, 963  
in cataract, 391  
in chronic laryngitis, 1004  
in corneal opacities, 322  
in diseases of sound perceiving apparatus, 781  
in insufficiencies of ocular muscles, 520  
in optic-nerve atrophy, 449  
in vitreous opacities, 400
- Electro-cautery, 248  
in pterygium, 562
- Electrolysis, 248, 257, 564  
for removing cilia, 545



- Electrolysis in chronic rhinitis, 912  
 in deviation of septum, 920  
 in erectile tumors of orbit, 601  
 in fibroma of naso-pharynx, 1093  
 in lachrymal strictures, 271  
 in orbital angiomas, 531  
 in retinal detachment, 430  
 in trachoma, 564
- Electro-magnet, 369, 370
- Electrozone in diphtheria-disinfection, 1015
- Elephantiasis arabum, 252  
 lymphangiectodes, 252  
 telangiectodes, 252
- Embolism of central artery of retina, 406, 407, 421  
 relation of cilio-retinal artery to, 189
- Embryo, 17
- Embryology of the ear, 617
- Emmetropia, 212  
 amplitude of accommodation in, 136  
 determined by skiagraphy, 205
- Empyema of anterior mastoid cells with perforation, 752  
 of apex of mastoid with perforation into digastric fossa, 752  
 of mastoid, operation for, 793  
 of maxillary sinus, 968. See *Maxillary sinus, empyema of*.  
 operative treatment, 1199  
 of sphenoidal cells, treatment, 983
- Empyema, 409  
 of conjunctiva, 299  
 of eyelids, 371, 537  
 of orbit, 537
- Ems pastilles in rheumatic conditions of air-passages, 875
- Encanthis, 301
- Encephalocele, 533
- Enchondroma of eyelids, 248  
 of naso-pharynx, 1093  
 of nose, removal of, 1197  
 of orbit, 531  
 of sclera, 330
- Endocarditis, 421
- Endogenous infection, 355
- Endolymph, function of, 640
- Endolymphatic duct, 617
- Endothelioma of optic nerve, 449
- Enophthalmos, 170, 525, **538**
- Entoptic phenomena, 140  
 study of macula, 189
- Entropion, 257, 291, 293, 308  
 congenital, 241  
 operations for, 518  
 organic, 257  
 spasmodic, 257
- Enucleation, 384  
 complications after, 572  
 of an eyeball, 571  
 in panophthalmitis, 356
- Epencephalon, 19
- Ephidrosis of eyelids, 259
- Epicanthis, 241  
 operation for, 518
- Epidural abscess, 756. See *Pachymeningitis externa*.
- Epiglottis, 818  
 cushion of, 818  
 development of, 809  
 diseases of, 936  
 enlargement of, 937  
 examination of, 870  
 incarceration of, 933, 936
- Epilation, 544  
 of cilia, 257
- Epilepsy, 150, 151, 509, 511  
 from eye-strain, 244  
 influence of, on the ear, 649  
 laryngeal, 1159
- Epiphora, 264
- Episcleral congestion, transitory, 330  
 lymph-space, 87  
 vessels, 143
- Episcleritis, 329, 330  
 partialis fugax, 330
- Epistaxis, 902, 903  
 idiopathic, 902  
 traumatic, 903  
 vicarious, 902
- Epithelial carcinoma of auricle, operation for, 784  
 implantation tumors, 489
- Epithelioma. See *Carcinoma*.  
 contagious, 259  
 of auricle, 697  
 of conjunctiva, 301  
 of cornea, 329  
 of drumhead, 714  
 of nose, papillary, 1086  
 of sclera, 330
- Equilibrium, disturbances of, testing of, 774
- Ergot, 459  
 in congestion of labyrinth, 690  
 in epistaxis, 903
- Ergotism, 392
- Eruptions, antitoxins, 1023
- Erysipelas, 275, 444, 528  
 of auricle, 693  
 treatment, 685  
 of eyelids, 242  
 of nose, 901, 902
- Erythema of eyelids, 242
- Erythroptasia, 468
- Escar's tongue-depressor, 872
- Eserin in corneal ulcers, 280, 283, 316  
 in glaucoma, 384  
 in staphylococci, 324
- Esophagus, foreign bodies in, 1135, 1136
- Esophoria, 157, 161, 500, **515**  
 treatment, 520
- Esoptropia. See *Strabismus, convergent*.
- Essential atrophy of conjunctiva, 296  
 phthisis bulbi, 357
- Ether, 542  
 in subglottic laryngitis, 988
- Ethmoid bone, 825, 826  
 cells, disease of, operative treatment, 1200  
 disease, 976, 977  
 fistula, 602  
 mucocele of, 533  
 sinuses, 451  
 sinuses, neoplasms of, 1090
- Ethmoidal cells, anterior, examination of, 864  
 cysts of, 976  
 diseases of, 976  
 inflammation of, 977  
 polypi of, treatment, 977
- Ethmoiditis, necrosing, 1201
- Ethyl bromid in laryngeal tuberculosis, 1052
- Ethylenediamin, 465
- Eucaïn, 211, 595
- Eucain "A," 543
- Eucain "B," 543
- Eucalyptol in chronic catarrh of middle ear, 733
- Eucalyptus in trachetis, 997  
 oil in laryngeal tuberculosis, 1050, 1051
- Europhen in laryngeal tuberculosis, 1050, 1052
- Eustachian bougie, examination of ear with, 682  
 bougies in chronic catarrh, 734  
 catheter, inflation of ear with, 679  
 in salpingitis, 753  
 openings, 631, 809, 810  
 tube, 630  
 development of, 621  
 function of, 639  
 inflammation of, 723  
 isthmus of, 626  
 obstruction of, by chronic catarrh, 733, 734  
 pathology of, 663
- Eversbusch's method of making an eyelid, 555  
 operation for ptosis, 559
- Evisceration, 324  
 complications after, 573  
 of eyeball, 572  
 with insertion of artificial vitreous, 572
- Examination blank for ear-disease, 683
- Exanthematous eruptions of eyelids, 244
- Excision of ossicles in catarrh of middle ear, 737  
 in chronic suppuration of middle ear, 747  
 of sound-conducting apparatus, 788
- Exenteration, 572. See also *Evisceration*.  
 of orbit, 600  
 tympano-mastoid, 796
- Exophoria, 157, 500, **517**  
 in relation to full correction of hyperopia, 219  
 treatment, 520
- Exophthalmic goiter, 170, 255, 477, **534**
- Exophthalmos, 317, 525  
 cardiac, 531  
 pulsating, 531
- Exostoses cartilagineae of meatus, operation for, 786  
 of external auditory canal, 706  
 of meatus, operation for, 785  
 of orbit, 533
- Exotropia. See *Strabismus, divergent*.
- Exploratory tympanotomy, 737

- External auditory canal, affections of, 698  
 circumscribed inflammation of, 702  
 congenital atresia of, 698  
 diffuse inflammation of, 703  
 doubling of, 699  
 exostoses of, 706  
 false membranes of, 707  
 furuncle of, 702  
 hyperostosis of, 706
- ear, affections of, 691  
 anatomy, 625  
 function of, 636  
 rectus. *See Rectus, external.*
- Extirpation of larynx, 1212
- Extorsion, 197
- Extraction of cataract, 395, 580  
 after-treatment of, 586  
 combined, 5-2  
 disturbances of healing process after, 5-3  
 execution of operation of, 5-0  
 in capsule, 5-2  
 mistakes and accidents during operation of, 5-2  
 results of, 5-3  
 simple, 5-0  
 suppuration after, 5-3  
 various modifications of the operative procedure of, 5-1  
 with iridectomy, 5-2  
 of immature cataract, 394  
 of monocular cataract, 395
- Extradrural abscess, 756. *See Pachymeningitis externa.*
- Eye, a living camera, 88  
 anatomy of, 29  
 animal's, operation on, 611  
 antero-posterior axis of, 100, 201  
 cardinal points of schematic, 92  
 center of rotation of, 96  
 determination of position of opacities in media of, 179  
 development of, 17  
 development of fibrous and vascular coats of, 27  
 diphtheria of, 1032  
 direct inspection of, 112  
 examination of media of, 178  
 external examination of, 112  
 functional testing of, 112  
 general plan of examination of refraction of, 211  
 horizontal axis of, 100  
 human, cardinal points of, 125  
 hyperopic, 214  
 injuries of, 358  
 injuries of appendages of, 358  
 length of axis of emmetropic, 178  
 lengthening or shortening of, in axial ametropia, 201  
 methods of determining refraction of the, 196  
 movements of each, 498  
 muscles of. *See Ocular muscles.*  
 myopic, 219  
 opacities of media of, 183  
 operations on, 539  
 optical defects of, 95  
 position of, 170
- Eye, primary position of, 101  
 reduced, 93  
 refraction of, at different parts of retina, 200  
 rotation of, 100  
 schematic, 92  
 sympathetic affections of, 347
- Eye-ball, atrophy of, 315, 356  
 blood-vessels of, 86  
 contusion of, 360  
 dislocation of, 537  
 enucleation of, 571  
 fibrous tunic of, 50  
 foreign bodies in, 369  
 injuries of, from contusion, concussion, and compression, 360  
 lymphatics of, 87  
 macroscopical anatomy of, 48  
 microscopical anatomy of, 48  
 movements of, 100  
 nervous tunic of, 50, 65  
 ossification of, 318  
 penetrating wounds of, 367  
 principal diameters of, 49  
 refractive media of, 50  
 rupture of, 361  
 vascular tunic of, 50, 55
- Eye-balls, anomalies of movements of, 497
- Eye-brows, 260  
 cysts of, 260
- Eye-glasses, 239
- Eye-ground. *See Fundus.*
- Eyelashes. *See Cilia.*
- Eyelid, Eyelids, 30  
 abnormal shortness of, 246  
 abscess of, 242, 546  
 adenoma of, 245  
 angioma of, 248  
 anthrax pustule of, 242  
 blood-vessels of, 36  
 border, reconstruction of, 550  
 burn of, 372  
 carbuncle of, 242  
 carcinoma of, 251  
 chromidrosis of, 259  
 coloboma of, operation for, 557  
 congenital anomalies of, 241  
 contusions of, 372  
 cutaneous horns of, 248  
 cysticercus of, 260  
 dermoid cysts of, 269  
 development of, 28  
 diseases of, 241  
 ecchymosis of, 374  
 eczema of, 244  
 elephantiasis of, 252  
 emphysema of, 371, 537  
 enchondroma of, 248  
 epiphrosis of, 259  
 epithelioma of, invading orbit, 533  
 crsipelas of, 242  
 erythema of, 242  
 exanthematous eruptions of, 244  
 fibroma of, 248  
 furuncle of, 242  
 gumma of, 248  
 injuries of, 371  
 integument of, 32  
 lepra of, 252  
 lipoma of, 248  
 lupus of, invading orbit, 533  
 vulgaris of, 252  
 lymphatics of, 37
- Eyelid, Eyelids, method of everting, 443  
 milium of, 259  
 molluscum contagiosum of, 259  
 nerves of, 37  
 neuroma of, 248  
 nevus of, invading orbit, 533  
 operations for restoration of, 555  
 operations on, 514  
 papilloma of, 248  
 rare forms of carcinoma of, 252  
 replacement of lacerated, 557  
 rodent ulcer of, 251  
 sarcoma of, 250  
 sebaceous cysts of, 259  
 scorbrrhea of, 255  
 syphilis of, 247  
 third, 31  
 transplantation of cicatricial skin to replace integument of, 554  
 tumors and hypertrophies of, 248  
 ulcers of, 243  
 vaccinia of, 244  
 veins of, 37  
 wounds of, 372
- Eyes, associated movements of, 101, 500  
 associated parallel movements of, 500  
 astigmatic, 224  
 mobility of, 155  
 nervous mechanism governing associated parallel movements of, 502  
 secondary position of, 101
- Eye-speculum, 575
- Eye-strain, 213, 352
- FACE, examination of, in affections of nose and throat, 855
- Facial canal, 621, 755
- Facultative hyperopia, 215
- False croup, 986  
 membrane in diphtheria, 1012  
 membranes of internal auditory canal, 707  
 vocal cords, 816, 820
- Farlow's tongue-depressor, 865
- Far-point, 131, 155
- Far-sightedness. *See Hyperopia.*
- Fascia, oculi orbital, inflammation of, 529  
 orbitalis, 42
- Fascicular keratitis, 314
- Fauces, herpes of, 946  
 malignant tumors of, 1098
- Faucial abscess, evacuation of, 1207  
 lymphoid tissue, pathology of, 850  
 tonsils, 845, 924  
 pathology of, 850  
 removal of, 1204
- Fauvel's forceps, 1137, 1138
- Fenestra ovalis, function of, 610  
 rotunda, function of, 610
- Fetal cleft, 191
- Fibers of Gratiolet, 479  
 of Müller, 75  
 of Wernicke, 479

- Fibroma of auricle, 655, 696  
 of conjunctiva, 293, 301  
 of cornea, 329  
 of drumhead, 714  
 of eyelids, 248  
 of larynx, 1105  
 of lobule, operation for, 783  
 of middle ear, 661  
 of naso-pharynx, 1091, 1092  
 of nose, 1080  
   removal of, 1197  
 of optic nerve, 449, 530  
 of oro-pharynx, 1096  
 of sclera, 330  
 of soft palate, 1096  
 of trachea, 1115  
 papillare of nose, 1081
- Fibro-mucous polyp of naso-pharynx, 1093
- Field of binocular fixation, 502  
 of binocular single vision, 502  
 of fixation, 169, 498  
 of vision, 162, 470  
   absolute, 166  
   amblyopia of, 170  
   anomalies of, 172  
   binocular, 167, 471  
   changes in, in affections of optic nerve, 476  
     in diseases of choroid, 475  
     in diseases of retina, 473  
     due to optic hindrance, 473  
   contraction of, 472  
   effect of refraction on size of, 166  
   false projection of, 509  
   for colors, 167  
   in glaucoma, 379, 476  
   in optic-nerve atrophy, 446, 447  
   minimal, 166  
   relative, 166  
   size of, 165
- Fifth nerve. *See Trigemimus.*
- Filamentous keratitis, 311
- Filaria sanguinis hominis in anterior chamber, 341  
 in vitreous, 402
- Filtration-angle in glaucoma, 377
- Fissure, Glaserian, 625
- Fissures of auricle, operation for, 783
- Fistula, aural, 692  
 lachrymal, 268, 272  
 of ear, congenital, 692  
   operation for, 783  
 of lachrymal gland, 262
- Fixation, binocular, 499  
 contraction of field of, 499  
 field of, 169, 498  
 field of binocular, 502  
 line of, 96, 128
- Flaccid membrane, 628
- Flavors, perception of, 839
- "Flinder's section," 483
- Floor of nasal chamber, 827
- Fluid-brain, 19
- Fibrin, 115
- Focal distance, 92, 93  
   anterior, 90  
   posterior, 90  
   interval of Sturm, 225  
 in refraction of lens, 123  
 line, 824  
 planes, 91
- Focal points, 90, 92
- Foci, 105, 108  
   conjugate, 103, 108  
     relation of, to principal foci, 111  
   principal, 121  
   of surfaces measured from the surfaces, 114  
   of systems measured from principal points of systems, 114
- Foetus, 102, 124  
   first principal, 109, 110  
   principal, 114  
   second principal, 109, 110  
   virtual, of concave lens, 124
- Foerster's operation for ripening cataract, 584
- Folliculosis, 289, 292
- Fontana, spaces of, 28, 55, 86, 87, 377
- Foramen lacernum, 624
- Forceps, ear-, 674
- Fauvel's, 1137, 1138  
 for deviation of nasal septum, 1192  
 Garrigon-Desarenes, 1192  
 Mackenzie's tube-, 1143  
 Roe's tracheal, 1134
- Fore-brain, 19
- Fore-gut, 808
- Foreign bodies in auditory canal, 708  
 in cornea and conjunctiva, 368  
 in esophagus, 1135  
 in eyeball, 369  
 in larynx, 1129  
   and trachea, 1130-1132  
     removal of, 1209  
 in meatus, operation for, 786  
 in nose, 861, 1127, 1128  
 in pharynx, 1135  
 in tonsil, 936  
 in trachea, 1129
- Form of upper air-passages, alterations of, 854
- Formaldehyde, 272, 280, 293, 510  
 in corneal ulcers, 315  
 in laryngeal tuberculosis, 1050  
 in nasal and pharyngeal tuberculosis, 1057
- Formaldehyde-disinfection in diphtheria, 1016
- Formalin. *See Formaldehyde.*
- Formate of soda spray in laryngeal tuberculosis, 1050
- of sodium in nasal and pharyngeal tuberculosis, 1057
- Form-field, 166
- Forix conjunctiva, 35
- Fossa, cerebellar, 623  
 patellar, 80  
 posterior, 623  
 of Rosenmüller, 810
- Fourth ventricle, 19
- Fovea, 188  
   centralis, 66, 76  
     reflection from, 182  
 Foveal reflex, 67, 188, 406
- Fowler's solution in lupus laryngitis, 1066
- Fracture of bones of nose, 1119  
 treatment, 1121  
 of cartilages of nose, 1123  
 of lachrymal bones, 1120
- Fracture of larynx, 1139  
 of nasal septum, 1124  
 of petrous bone, 776  
 of triangular cartilage, 1124  
 of vomer, 1121
- Fränkel's diplococci in labyrinth, 767  
 tongue-depressor, 865
- Fränkel-Weichselbaum capsulated diplococcus, 614a
- Fricke's method of blepharoplasty, 556
- Fright, 149
- Frontal nerve, 37  
 disease, 980
- Frontal sinus, growths in, invading orbit, 533  
 operation for distention of, 602  
 sinuses, diseases of, 979  
   operative treatment, 602  
     drainage of, 980, 981  
     neoplasms of, 1090
- Fronto-nasal process, 807
- Frost-bite of auricle, 696
- Fruhjahr's cataract, 287
- Fundus, changes in, caused by eye-strain, 213  
 caused by myopia, 221  
 color of, 189  
 congenital-anomalies of, 189  
 differences of level in, 184  
 normal, 171, 184  
 physiological variations of, 189
- Fundus-details, 177
- Furcula, 809
- Furuncle of external auditory canal, 702  
 of eyelids, 242  
 of nasal wing, 901
- Furuncles of external meatus, pathology, 655
- Furunculosis of auricle, treatment of, 686
- GALLIC ACID in epistaxis, 903
- Galton's whistle, 669
- Galvanism, 310, 330. *See also Electricity.*
- Galyano-cantery, 509, 597, 887  
 in acute follicular pharyngitis, 913  
 in acute naso-pharyngitis, 918  
 in chronic naso-pharyngitis, 952  
 in chronic parenchymatous tonsillitis, 932  
 in chronic rhinitis, 911  
 in chronic subglottic laryngitis, 1009  
 in corneal ulcers, 567  
 in enlargement of epiglottis, 937  
 in fibroma of naso-pharynx, 1093  
 in lupus laryngitis, 1066  
 in lupus of pharynx, 1059  
 in neoplasms of nasal septum, 1080  
 in nodular laryngitis, 1066  
 in singers' nodes, 1105
- Ganglion, geniculate, 626, 627  
 retina, 67  
 spiral, 619, 620



- Gargles, 881  
 in acute catarrhal pharyngitis, 940
- Garrigou-Desarenes forceps, 1192
- Gasserian ganglion, corneal ulcers of, removal of, 317
- Gastric disturbance in etiology of catarrhal inflammation, 845
- Gelle's binaural synergy test, 672  
 test, 672
- Gelsemium, 251, 459  
 in acoustic neurasthenia, 781
- Geniculate ganglion, 626, 627
- German and French method of rhinoplasty, 1185
- Gerontoxon lentis, 389
- Gifford's reflex, 151
- Gland, lachrymal, 45
- Glands, ciliary, 86  
 of Moll, 33, 35
- Glaserian fissure, 625
- Glasgow's operation for deviated septum, 917
- Glass, index for, 110
- Glasses. See also *Spectacles*.  
 for astigmatism, 229  
 in hyperopia, 217, 218  
 in myopia, 222  
 mounting of, 234  
 period of adaptation of, 235
- Glaucoma, 143, 149, 226, 311, 357, 366, 373, 391, 396, 421, 428, 457, 492  
 absolute, 377  
 acute, 377, 378  
 after cataract-extraction, 578  
 after discission, 578, 586  
 anatomical conditions of, 377  
 chronic, 377  
 inflammatory, 379  
 complicated, 384  
 congenital, 385  
 congestive, 377, 379  
 danger of mydriatics in, 210  
 diagnosis, 381  
 from iritis, 341  
 differential diagnosis of simple, from optic-nerve atrophy, 382, 448  
 exciting causes, 376  
 field of vision in, 379-381  
 fulminant, 379  
 hemorrhagic, 384, 570  
 inflammatory, 375, 377, 381, 570  
 malignant, 383  
 non-inflammatory, 379  
 non-surgical treatment, 384  
 pathology, 376  
 pre-disposing causes, 375  
 primary, 374  
 relation of age, race, and sex to, 375  
 relation of refraction to, 375  
 secondary, 321, 341, 384  
 simple, 375, 376, 379, 382, 448, 570  
 subacute, 377, 379  
 treatment, 382  
 true forms of, 376  
 varieties, 374  
 visual field in, 476
- Glaucomatous degeneration, 378
- Glaucomatous excavation, 373  
 halo, 374  
 state, 378
- Glenoid cavity, 625
- Glioma endophytum, 494  
 exophytum, 494  
 of optic nerve, 449  
 of retina, 356, 398, 400, 494  
 diagnosis, 494  
 pathological anatomy, 495  
 prognosis, 495
- Globe inhaler, 1049
- Globular process, 807
- Glosso-epiglottic folds, median, 819  
 fossa, examination of, 869  
 ligaments, 818
- Glottis, 820  
 spasm of, 995
- Glycerite of boro-glycerin in lingual tonsillitis, 927  
 of tannic acid in chronic naso-pharyngitis, 952
- Glycosuria, nasal, 1150
- Glyeothymoline in acute naso-pharyngitis, 948  
 in chronic naso-pharyngitis, 951
- Goiter, exophthalmic, 534
- Golding-Bird's double retractor, 1134
- Gonococcus of Neisser, 278, 281, 314, 611a
- Gonorrhoea, 278, 339, 437
- Gonorrhoeal conjunctivitis, 266.  
 See *Conjunctivitis, gonorrhoeal*.  
 inoculations in pannus, 309  
 rheumatism, 279
- Göttstein's eurette, 1202, 1203
- Gout, 261, 319, 330, 339, 391, 399, 400, 421, 436  
 relation of, to ear-disease, 650
- Gouty affections of upper air-passages, general therapeutics of, 875
- Gradenigo's test, 672
- Graefe's cataract-knife, 576  
 equilibrium-test for ocular muscles, 157  
 operation of tenotomy, 587  
 sign, 535
- Granular conjunctivitis. See *Trachoma*.  
 lids. See *Trachoma*.  
 pharyngitis, 942
- Granulation growths in chronic suppuration of middle ear, 742
- Granulations of meatus, operation for, 785  
 of tympanum, removal of, 792
- Granuloma of conjunctiva, 301  
 of iris, 349, 489
- Grattage, 565
- Graves's disease. See *Exophthalmic goiter*.
- Gray degeneration of acoustic nerve, 769
- Green-blindness, 603
- Green's operation for entropion, 551
- Grippe. See *Influenza*.
- Greenouw's tests for light-sense, 168
- Gross's ear-scoop, 674  
 probang, 1138, 1139
- Grüening's operation for divergent strabismus, 589
- Guaiac in acute catarrhal pharyngitis, 940  
 in acute tonsillitis, 924
- Guaiacol in acute tonsillitis, 924  
 in laryngeal tuberculosis, 1048  
 in lupus of pharynx, 1059  
 in nasal and pharyngeal tuberculosis, 1057  
 spray in laryngeal tuberculosis, 1059
- Guaiacum in laryngeal tuberculosis, 1047
- Guillet's dots, 140
- Gumma of conjunctiva, 300  
 of eyelids, 248  
 of optic nerve, 450
- Gunn's dots, 106, 422
- Gymnastic exercises with prisms, 520
- HAAB'S electro-magnet, 370  
 reflex, 151
- Hematoma auris, 694  
 treatment, 695
- Hairy pharyngeal polyp, 1093
- Hajek's cannula, 863, 864
- Handle of malleus, fracture of, 712
- Hard cataract. See *Cataract, senile*.
- Harder's glands, 31
- Harlan's operation for cicatricial orbit, 600  
 for symblepharon, 563
- Harlan's test for feigned blindness, 467
- Harmonie, 635
- Hartmann's cannula, 863  
 combined probe and blunt hook, 674  
 ear-forceps, 674  
 speculum, 859, 860
- Hasner, valve of, 48
- Hay fever, 1144  
 in chronic hypertrophic rhinitis, 907, 908
- Headache, 226, 409, 510  
 from eye-strain, 214  
 in brain-abscess, 763  
 in chronic hypertrophic rhinitis, 907  
 in deviation of nasal septum, 916
- Hearing, defect of, as a symptom, 666  
 qualitative tests of, 669  
 quantitative tests of, 668
- Heart-disease, 420, 421
- Heat-cold, 892
- Heating in affections of upper air-passages, 879
- Helicis major, 637  
 minor, 637
- Helix, 625
- Helmholtz's formula, 113  
 ophthalmometer, 196  
 ophthalmoscope, 172  
 schematic eye, 92  
 theory of accommodation, 134  
 theory of color-perception, 99
- Hematemesis, 421



- Hematoma of septum, 899  
 Hemeralopia, 460, **469**  
 Hemi-achromatopia, 482  
 Hemianopia, 149, 170, **472**, **480**  
   heteronymous, 480  
   homonymous, 481  
   lateral, 481  
   monocular, 482  
   nasal, 480  
   significance of, 482  
   spurious, 448  
   temporal, 480  
   transient, 483  
   vertical, 482  
 Hemianopic pupillary inaction, 480  
 Hemianopsia. *See Hemianopia.*  
 homonymous, in brain-abscess, 763  
 Hemiparasia, 211  
 Hemophilia, 537  
 Hemophthalmia, 362  
 Hemorrhage after glaucoma operations, 383  
   from external meatus, 655  
   from pharynx, 914  
   in diphtheria, 1017  
   in drumhead, 711  
   in optic nerve-sheath, 453  
   into choroid, 364, 399, 428  
   into labyrinth, 663  
     etiology, 770  
     pathology, 766  
     symptoms, 744  
     treatment, 780  
   into optic nerve, 453  
   into orbit, 444, 537  
   into retina, 364, 417, 428, **420**  
     after cutaneous burns, 421  
     pathology of, 421  
   into vitreous, 401  
   subhyaloid, 421  
 Hemorrhagic laryngitis, 944, 996  
 Hereditary ataxia, 520  
   syphilitic, 339, 387  
 Heredity in etiology of ear-disease, 647  
 Hering's theory of color-perception, 100  
 Herpes auricularis, 655  
   conjunctive, 287  
   corneæ, 309  
   relapsing, 311  
   febrilis, 310  
   frontalis, 309  
   labialis, 310  
   of auricle, treatment, 655  
   of fauces, 946  
   zoster of auricle, 693  
   zoster ophthalmicus, 244  
 Herschel's prism, 158  
 Heterophoria, 161, **504**. *See also Insufficiency, Deviations, and Ocular muscles.*  
   etiological classification, 505  
   inertional, 510  
   reflex-disturbances from, 510  
   structural, 510  
 Heterophthalmos, 331  
 Heterotropia. *See Strabismus and Deviations.*  
 Hiatus Fallopii, 626  
 Hind gut, 808  
 Hippus, 151, **334**  
 Hoarseness in chronic subglottic laryngitis, 1008  
 Hoarseness in laryngeal tuberculosis, 1038  
   in lypous laryngitis, 1060  
   in nodular laryngitis, 1005  
 Holden's tests for light-sense, 168  
 Holmgren's method for color-blindness, 603  
   wools, 153  
 Holocain, 544  
 Homatropin, 209  
 Hommel's method of aural massage, 736  
 Homocentric rays, 89  
   refraction of, 90  
 Homonymous hemianopsia in brain-abscess, 763  
 Hook-cartilage, 630, 631  
 Hope's septum-forceps, 1192  
 Hordeolum, **243**, 546  
 Horner's muscle. *See Tensor tarsi.*  
 Horny growths of auricle, 697  
 Hot applications in conjunctivitis, 280  
   in corneal ulcers, 316  
   in iritis, 342  
   bath in subglottic laryngitis, 988  
   fomentations in subglottic laryngitis, 988  
   snare in chronic parenchymatous tonsillitis, 932  
 Hot-eye, 330  
 Hotz's method of transplanting cicatricial flap, 555  
   operation for reconstructing lid-border, 550  
 Hubbel's electro-magnet, 371  
 Humidity in etiology of catarhial inflammation, 845  
 Huskiness in pachydermia of larynx, 1006  
 Hutchinson's teeth, 319  
 Huyler's operation for deviated septum, 917  
 Hyaline bodies in optic disk, 451, 496  
 Hyalitis, 357, **398**, 410  
   asteroid, 399  
   punctata, 399  
   suppurative, 398  
 Hyaloid artery, 24, 403  
   persistent, 24, 190, **403**, 494  
   vestigial, remains of, 389, 404  
   canal, 24, 83  
   membrane, 28, **82**, 83, 84  
   vessels, 28  
 Hydrobromic acid in tinnitus, 738  
 Hydrocephalus, 436, 446, 455  
 Hydrochlorate of coniin in laryngeal tuberculosis, 1050  
 Hydrochloric acid in diphtheria, 994  
 Hydrogen dioxid in acute croupous tonsillitis, 925  
   in chronic suppuration of middle ear, 747  
   in diphtheria, 1028  
 Hydrophthalmos, **323**, 343, 570  
   anterior, 521  
   congenital, 385  
 Hydrops of intravaginal space, 434  
 Hygiene of the voice, 1177  
 Hyo-epiglottic ligaments, 819  
 Hyoid bone, 816  
 Hyomandibular cleft, 809  
 Hyosein, 209  
 Hyoseyamin, 209  
 Hyperacusis, 776  
 Hyperemia of acoustic nerve, 769  
   of auricle, pathology, 654  
     treatment, 685  
   of drumhead, 711  
   of labyrinth, etiology, 770  
     pathology, 766  
     symptoms, 774  
     treatment, 780  
 Hyperesophoria, 161  
 Hyperesthesia, nasal, 1143  
 Hyperopia of larynx, 1154  
   of pharynx, 1151  
 Hyperexophoria, 161  
 Hyperkeratosis, lacunar, 945  
 Hypermetropia. *See Hyperopia.*  
 Hyperopia, 170, 212, **214**, 333, 343, 394, 395, 457  
   absolute, 215  
   amplitude of accommodation in, 137  
   aphakial, 215  
   axial, 215  
   causes, 215  
   course, 215  
   curvature, 215  
   determined by trial lenses, 208  
   determined by skiascopy, 205  
   facultative, 215  
   full correction of, 217  
   index, 215  
   latent, 215  
   manifest, 215  
   measured with ophthalmoscope, 199  
   partial correction of, 218  
   symptoms, 216  
   total, 215  
   treatment, 217  
   varieties, 215  
 Hyperopic astigmatism, 128, 227  
 Hyperosmia, 1142  
 Hyperostosis of external auditory canal, 706  
   of meatus, operation for, 785  
 Hyperphoria, 161, 500, **518**  
   comitant, 518  
   left, 500  
   non-comitant, 518  
   prism-test for, 157  
   right, 500  
   treatment, 520  
 Hypertrophic rhinitis, chronic, 905  
 Hypertrophic tonsils, effect of, on ear, 748  
   galvano-cautery in, 888  
 Hypertrophy, adenoid, etiology of, 850  
   lymphoid, in pharyngeal vault, 952. *See Lymphoid hypertrophy.*  
   of tonsil, polypoid, 935  
   of turbinated bones, treatment, 1194  
   of vascular tissue of nasal septum, 1195  
 Hypertropia. *See Strabismus, circumvergent.*  
 Hyphema, 344, 362

- Hypokinesis of larynx, 1160  
 Hypopyon, 314, 335, 614b  
   in cyclitis, 345  
   in iritis, 336, 337, 338  
 Hypopyon-keratitis, 391  
 Hysteria, 151, 251, 259, 410, 466,  
   185, 511, 519  
   acoustic, 776  
   field of vision in, 167  
   influence of, on the ear, 649  
   of nose and throat, 1169  
   treatment, 1170  
   visual field in, 466  
 Hysterical aphonia, 1170
- Ice in acute catarrhal pharyngi-  
 titis, 910  
   in erupulous laryngitis, 991  
   in epistaxis, 903  
 Ice-bag in acute phlegmonous  
 laryngitis, 989  
 Ictus laryngea, 1159  
 Ideal points. See *Cardinal  
 points*.
- Idiopathic epistaxis, 902  
 Ignipuncture in chronic paren-  
 chymatous tonsillitis, 932  
 Illumination in ophthalmos-  
 copy, 179  
   minimum stimulus of, 153  
   oblique, 146  
   uses of, 146  
   of ear, 673  
 Image, 103  
   and object, 111, 112  
   magnification determined  
   by properties of principal  
   foci, 112  
   middle, 116, 120, 123  
   position and size of, 114  
   retinal, 89  
   in ametropia, 139  
   in emmetropia, 139  
   size of, 125  
 Image-forming optical instru-  
 ments, 103, 105  
 Images, conjugate, 111  
   formation of, in reduced eye,  
   94  
   on retina, 90  
   of Purkinje, 98, 135  
   real, 124  
   virtual, 124  
 Imbalance of ocular muscles.  
 See *Ocular muscles*.
- Impacted cerumen, 699  
 Incarceration of epiglottis, 933,  
 936  
 Incidence, angle of, 104, 105,  
 106  
 Incision of drum-membrane in  
 chronic catarrh of mid-  
 dle ear, 735  
   of vocal bands in chronic  
   laryngitis, 1004  
 Incisor crest, 827, 830  
 Inco-ordination of laryngeal  
 muscles, 1158  
 Incudo-stapedial joint, disartic-  
 ulation at, 790  
 Incus, 630  
   function of, 638  
 Index for air, 110  
   for glass, 110  
   of refraction, 105  
   of air, 92  
   of aqueous humor, 89, 92
- Index of refraction of cornea,  
 89, 92  
   of crystalline lens, 89, 92  
   of vitreous, 89, 92  
 Index-hyperopia, 215  
 Index-myopia, 222  
 Indian method of rhinoplasty,  
 1184  
 Indirect method of ophthalmos-  
 copy, 176  
   measurement of refraction  
   by, 201  
   reflex action of pupil, 148  
 Infectious diseases of drumhead,  
 714  
   relation of, to ear-disease,  
   650  
 Inferior constrictor of pharynx,  
 814  
   oblique. See *Oblique  
 rectus*, 39. See *Rectus*.
- Infiltration-anesthesia, 544  
 Inflammation of attic, 724  
   of auditory canal, circum-  
   scribed, 702  
   desquamative, 704  
   diffuse, 703  
   of drumhead, acute primary,  
   713  
   chronic, 713  
   of Eustachian tube, 723  
   of meninges from tympanic  
   inflammation, 756  
   of middle ear. See *Middle  
 ear, inflammation of*.  
   chronic non-suppurative,  
   726  
 Inflation of ear, Politzer's  
 method, 681  
   Valsalva's method, 681  
   of middle ear, 679  
 Influenza, 275, 339, 391, 436,  
 440, 511  
   and ear-disease, 653  
   middle-ear disease from, 718  
 Infra-auricular region, exam-  
 ination of, 672  
 Ingals's operation for deviated  
 septum, 917  
 Inhalations in laryngeal tuber-  
 culosis, 1049  
 Injuries in etiology of ear-dis-  
 eases, 648  
 Injury of drumhead, 711  
 Inner wall of nasal chamber,  
 830  
 Innominate artery, 825  
 Insanity, 151  
 Insects in auditory canal, 708,  
 710  
 Instruments, preparation of,  
 540  
 Insufficiencies of ocular mus-  
 cles, 254  
   etiological classification  
   of, 505  
   Stevens's classification of,  
   161  
   treatment, 520  
 Insufficiency of external recti,  
 157, 515  
   of internal recti, 157, 517  
   of oblique muscles, tests for,  
   159  
   of ocular muscles, 156  
   diplopia a test for, 156,  
   157
- Insufficiency of ocular muscles,  
 hysterical, 485  
   rod-test for, 160  
   screen-test for, 156  
   of vertical muscles, 518  
 Insufflations in laryngeal  
 tuberculosis, 1050, 1052  
 Interarytenoid space, 820  
   examination of, 871  
 Interference otoscope, 672  
 Intermaxillary process, 808  
 Internal auditory canal, pathol-  
 ogy, 664  
   ear, diseases of, treatment,  
   690  
   functions of, 640  
   syphilis of, treatment, 690  
 Internal rectus. See *Rectus*.
- Interstitial keratitis. See  
*Keratitis, interstitial*.
- Intertrigo of auricle, 654  
   treatment, 685  
   intorsion, 497  
 Intracranial complications of  
 mastoiditis, differential  
 diagnosis of, 764  
   of purulent otitis media,  
   755, 756  
   tumors. See *Brain tumors*.
- Intradural abscess from tym-  
 panic inflammation, 758  
 Intralaryngeal operations, 1208  
 Intra-ocular, injections, 399,  
 421  
   tension. See *Tension*.  
   hemorrhage from sudden  
   reduction of, 421  
   tumors, 384, 428, 489  
 Inratympanic operations in  
 chronic catarrh of middle  
 ear, 737  
 Instruments for, 790  
 Intra-vitreous injections, 400  
 Intubation in diphtheria, 1029  
 Iodid of mercury tablets, 886  
   of potassium in acute otitis  
   media, 722  
   in labyrinthitis exudativa,  
   781  
   in labyrinthitis hyper-  
   plastica, 780  
   in laryngeal perichondritis,  
   996  
   in laryngitis sicca, 1005  
   in lupus of pharynx, 1059  
   in pachydermia of larynx,  
   1008  
   in syphilitic throat, 877  
 Iodids in acute inflammation  
 of middle ear, 687  
   in affections of upper air-pass-  
   ages, 886  
   in eczema of ear, 685  
   in syphilis of internal ear,  
   690  
 Iodin and carbolic acid in  
 pharyngo-mycosis, 946  
   and glycerin in chronic  
   rhinitis, 910  
   in atrophic rhinitis, 964  
   in corneal ulcers, 315  
   in hypertrophy of inferior  
   turbinal, 914  
   in laryngeal tuberculosis,  
   1048  
   in lupous laryngitis, 1066  
   in lupus of pharynx, 1059

- Iodin in nasal and pharyngeal tuberculosis, 1057  
 injections in retinal detachment, 431  
 sprays, 882  
 vapor in chronic catarrh of middle ear, 733
- Iodoform, 280, 459, 541  
 gauze in epistaxis, 903, 904  
 in atrophic rhinitis, 964  
 in chronic rhinitis, 910  
 in corneal ulcers, 315  
 in empyema of maxillary sinus, 973  
 in injuries of drumhead, 713  
 in laryngeal tuberculosis, 1051, 1052  
 in lupus of pharynx, 1059  
 in nasal and pharyngeal tuberculosis, 1057  
 in syphilis of air-passages, 1074
- Iodoform-insufflation in laryngeal tuberculosis, 1050
- Iodol in atrophic rhinitis, 964
- Ipecac in diphtheria, 1028
- Iridectomy, 323, 324, 347, 366, 385, 395, 568, 575, 584  
 execution of the operation, 577  
 for removing tumors and foreign bodies from iris, 576  
 for secondary cataract, 586  
 in glaucoma, 382, 383, 576, 578  
 hemorrhage after, 421  
 in iris-prolapse, 576  
 in iritis, 343, 576  
 indications for, 575  
 methods of performing, for special morbid conditions, 578  
 optical, 395, 578  
 preliminary to cataract-extraction, 582
- Iridencleisis, 579
- Irid-remia, 333
- Irido-choroiditis, 324, 346, 384, 387, 391, 400  
 chronic serous, 346
- Irido-cyclitis, 311, 344, 391, 392, 611*b*. See also *Cyclitis*.  
 after cataract-extraction, 583  
 anterior, 376  
 plastic, 348, 356
- Irido-cystectomy, 579, 586
- Iridodesis, 347, 579
- Iridodialysis, 362, 363
- Iridodonesis, 334
- Iridoplegia, 150, 511  
 reflex, 150. See also *Argyll-Robertson symptom*.  
 traumatic, 369  
 unilateral reflex, 150
- Iridotomy, 579
- Iris, 61  
 angioma of, 489  
 anterior endothelium of, 62  
 anterior limiting membrane of, 63  
 anteversion of, 363  
 atrophy of, 148, 377  
 blood-vessels of, 64  
 cataract in chromatic asymmetry of, 147  
 chromatic asymmetry of, 147  
 chronic hyperemia of, 335  
 coloboma of, 191, 332, 469
- Iris, color of, 62, 147  
 in chorea, 147  
 congenital anomalies of, 331  
 contusion-injuries of, 362  
 cysts of, 489  
 pigment layer of the, 490  
 stroma of, 489  
 development of, 28  
 diseases of, 334  
 displacements of, 363  
 epithelial cysts of, 489  
 functions of, 96  
 granuloma of, 340, 489  
 hyperemia of, 334  
 inflammation of. See *Iritis*.  
 lacerations of, 362  
 lesion of nucleus of sphincter of, 149, 150  
 lymphatics of, 65  
 melanoma of, 490  
 mobility of, 148  
 motor disturbances of, 334  
 nerve-cells of, 65  
 nerves of, 65  
 operations in, 574  
 piebald, 147  
 pigment-layer of, 64  
 posterior limiting membrane of, 64  
 prolapse of, 315, 316, 576  
 after cataract-extraction, 583  
 radial lacerations of, 363  
 reactions of, 148, 149. See also *Pupil*.  
 retroflexion of, 363  
 rudimentary development of, 333  
 rupture of sphincter of, 363  
 ruptures of, 362  
 sarcoma of, 490  
 senile changes in, 334  
 serous cysts of, 489  
 sphincter of, 148  
 structure of, 62  
 traumatic spasm of, 360  
 tremulans, 334  
 tuberculosis of, 340  
 tumors of, 489  
 vascular stroma of, 63
- Iris-forceps, 577
- Iritis, 143, 147, 245, 321, 330, 332, 335, 381, 384, 391, 392, 396, 398  
 after cataract-extraction, 583  
 catamenialis, 339  
 chronic, 344  
 diagnosis, 340  
 divisions, 335  
 etiology, 338  
 from acute infectious diseases, 339  
 from staphylococci, 337  
 gonorrhoeal, 339  
 gouty, 339  
 gummatous, 337  
 objective symptoms, 336  
 papulosa, 337  
 parenchymatous, 336, 337  
 pathological anatomy, 340  
 periodic, 339  
 plastic, 336  
 prognosis, 341  
 purulent, 338  
 recurrent, 339  
 rheumatic, 339
- Iritis, serofulous, 339  
 serous, 327, 336, 337  
 simplex, 336. See *Iritis, plastic*.  
 spongy, 336  
 subjective symptoms, 338  
 sympathetic serous, 348  
 syphilitic, 338, 339  
 traumatic, 340, 343  
 treatment, 341  
 tuberculous, 339
- Iron in croupous laryngitis, 991  
 in eczema of ear, 685  
 in epistaxis, 903
- Irritation-mydriasis, 150
- Irritation-myosis, 150
- Isthmus of Eustachian tube, 626
- Italian method of rhinoplasty, 1186
- Itelberg's test, 672
- JACKSON'S ophthalmoscope, 173
- Jacob's ulcer. See *Rodent ulcer*.
- Jacobson's organ, development of, 807
- Jaeger's test-type, 137  
 types for accommodation, 155
- Jaesche-Arlt operation for entropion, 551
- Jarvis's operation for deviated septum, 917  
 snare, 1196  
 in hypertrophic rhinitis, 912
- Javal-Schiötz ophthalmometer. See also *Ophthalmometer*, 196
- Jennings's method for color-blindness, 604
- Jequirity in pannus, 309
- Johnson's operation for trachoma, 564
- Jugular veins, 825
- June cold, 1144
- Jurasz's septum-forceps, 1192
- KEEGAN'S operation, 1187
- Keoid of auricle, 655, 696
- Keratitis, 141, 245, 258, 266, 305  
 bullous, 311  
 recurrent form of, 311  
 dendritic, 310  
 e lagophthalmo, 317, 536  
 en bandelette, 341, 325  
 fascicular, 311  
 filamentous, 311  
 from schizomycetial infection, 611*d*  
 harvester's, 314  
 interstitial, 318  
 atypical forms of, 321  
 etiology, 319  
 pathology, 320  
 prognosis, 321  
 symptoms, 319  
 treatment, 321  
 vessel-formation in cornea after, 321  
 maculosa, 314  
 neuroparalytic, 317  
 nodosa, 327  
 nummular, 311  
 oyster-shuckers', 313  
 parenchymatous. See *Keratitis, interstitial*.  
 phlyctenular, 287. See *Keratitis, superficial*.

- Keratitis, punctata, 327, 336  
 ribbon-shaped, 325  
 sclerosing, 324  
 striped, 325  
 subepithelialis centralis, 311  
 superficial, 305  
   diagnosis and prognosis, 307  
   diet in, 307  
   etiology, 305  
   micro-organisms in, 306  
   pathology, 307  
   punctate, 311  
   symptoms, 306  
   treatment, 307  
 suppurative, 312, 313  
   etiology and pathology, 312  
 syphilitic, 318  
 vascular, 320  
 vesicular, 309, 311  
 with hypopyon, 313, 314
- Keratocoele, 316
- Keratoconus. See *Conical cornea*.
- Keratoglobus, 323, 385
- Keratomalacia, 296, 318
- Keratometer, 145, 146, 148
- Keratometry, 145. See *Ophthalmometry*.
- Keratoxyxis, 580
- Keratroscope, 145
- Keratosis obturans, 704
- Killian's method, 872
- Klebs-Löffler bacillus, 281, 283, 284, 614a, 848, 991, 1011, 1017  
   in membranous rhinitis, 896
- Knapp's method of blepharoplasty, 557  
 roller forceps, 561
- Koch's antitoxin-syringe, 1026
- Koch-Weeks bacillus, 276, 614a
- Kopiopia, hysterica, 185
- Krameria troches in acute catarrhal pharyngitis, 910
- Krause's glands, 252
- Krönlein's operation, 451, 601
- Kuhnt-Müller operation for shortening lid-border, 552
- Kyanopsia, 468
- LABORDE'S dilator, 1131
- Labyrinth, absence of, 765  
 anemia of, 766. See *Anemia of labyrinth*.  
 treatment, 780  
 bony, 620  
 bony and membranous, 621  
 deformities of, 765  
 hemorrhage into, 663, 766. See *Hemorrhage into labyrinth*.  
 treatment, 780  
 hyperemia of, 766. See *Hyperemia of labyrinth*.  
 micro-organisms of, 767  
 pathology, 663  
 syphilis of, pathology, 664
- Labyrinthitis, exudativa, etiology, 771  
 pathology, 766  
 symptoms, 775  
 treatment, 780  
 hyperplastica, etiology, 771  
 pathology, 766  
 symptoms, 775  
 treatment, 780
- Lachrymal apparatus, 45
- Lachrymal apparatus, diseases of, 261  
 diseases of drainage system of, 264  
 operations upon, 596
- bones, fracture of, 1120
- calculi, 262
- canaliculi, 16  
 atresia of, 261, 265  
 dacryoliths in, 265  
 foreign bodies in, 265  
 polypi in, 265
- canaliculus, double, 264  
 slitting of, 269
- conjunctivitis, 294
- disease dependent upon nasal catarrh, 272
- duct. See also *Nasal duct*.  
 blood-vessels of, 48  
 nerves of, 48  
 stenosis of, in newborn, 269
- fistula, 268, 272
- gland, 45  
 adenoma of, 263  
 adenocarcinoma of, 531  
 atrophy of, 263  
 carcinoma of, 264, 531  
 chloroma of, 264  
 cylindroma of, 264  
 cyst of, 262  
 development of, 29  
 diseases of, 261  
 dislocation of, 262  
 fistula of, 262  
 hypertrophy of, 263  
 lymphosarcoma of, 264  
 myxoma of, 263  
 myxosarcoma of, 263  
 operation for fistula of, 596  
 removal of, 270, 596  
 spontaneous dislocation of, 262  
 syphilis of, 263  
 traumatic dislocation of, 262  
 tumors of, 263
- groove, 808
- papille, 46
- passages, 46  
 anomalies of, 241  
 injuries of, 371  
 tuberculosis of, 269
- probes, 270  
 introduction of, 598
- puncta, atresia of, 264  
 congenital anomalies of, 264  
 double, 264  
 eversion of, 265  
 inversion of, 265  
 malpositions of, 264  
 treatment of, 265
- sac, 47  
 abscess of, 265, 267  
 destruction of, with catarrh, 270, 597  
 excision of, 597  
 inflammation of. See *Dacryocystitis*.  
 polypi of, 269  
 syphilis of, 269
- strictures. See *Nasal duct, strictures of*.
- Lachrymo-nasal duct, stricture of. See *Nasal duct, stricture of*.
- Lactation, prolonged, 394, 437
- Lactic acid, 889  
 in chronic laryngitis, 1001  
 in chronic naso-pharyngitis, 952  
 in croupous laryngitis, 991  
 in diphtheria, 994  
 in fibroma of naso-pharynx, 1093  
 in laryngeal tuberculosis, 1050  
 in lupous laryngitis, 1066
- Laetophenin in acute naso-pharyngitis, 945
- Lacunar hyperkeratosis, 945  
 tonsillitis, acute, 922, 928. See *Tonsillitis*.
- Lacus lacrymalis, 31
- Laevoduction, 502
- Laevotorsion, 502
- Laevoverision, 500
- Lagophthalmos, 255  
 congenital, 241  
 non paralytic, 255  
 paralytic, 255
- Lamina cribrosa, 79, 184  
 fusa, 51  
 spiral, 619  
 sprachoroidea, 57  
 vitrea, 59, 453
- Laminaria bougies in deviation of septum, 920
- Landolt's method of advancement, 593  
 method of blepharoplasty, 556
- Lantern-test for color-blindness, 604
- Laryngeal crises, 1159  
 epilepsy, 1159  
 muscles, neo-ordination of, 1158  
 nerves, 823  
 paralysis, 1160  
   diagnosis, 1165  
   etiology, 1160  
   pathology, 1160  
   prognosis, 1169  
   symptoms, 1165  
   treatment, 1169  
 polypi, 1105  
 stenosis, dilatation of, 1209  
 syncope, 1159  
 tuberculosis, 1034. See *Tuberculosis of larynx*.  
 vertigo, 1159
- Laryngismus stridulus, 995, 1155  
 treatment, 995  
 acute catarrhal, 985, 986
- Laryngitis, acute catarrhal, in children, 986  
 acute oedematous, 988  
 acute phlegmonous, 988, 989  
 acute supraglottic, 986  
 chronic, 998  
   etiology, 998  
   pathology, 1001  
   prognosis, 1001  
   symptoms, 1000  
   treatment, 1002  
 croupous, 990, 991  
 hemorrhagic, 996  
 lupous, 1060  
   diagnosis, 1065  
   etiology, 1062  
   pathology, 1064  
   symptoms, 1060  
   treatment, 1066



- Laryngitis, membranous, 990  
 nodular, 1005, 1006  
 phlegmonosa, 988  
 sicca, 1001  
 stridulosa, 986  
 subglottic, 1008  
   diagnosis, 987  
   etiology, 986, 1008, 1009  
   symptoms, 987  
   treatment, 988
- Laryngo-fissure, 1212
- Laryngo-pharynx, anatomy of, 812
- Laryngoscopy, 869
- Larynx, acute affections of, 985  
 acute perichondritis of, 995  
 adenoma of, 1108  
 amyloid degeneration of, 1108  
 anatomy of, 816  
 anesthesia of, 1151  
 angioma of, 1108  
 antoscopy of, 873  
 benign neoplasms of, 1103  
   symptoms, 1108  
   treatment, 1109  
 blood-supply of, 823  
 carcinoma of, 1109  
   diagnosis, 1111  
   prognosis, 1112  
   symptoms, 1110  
   treatment, 1112  
 cartilages of, 816  
 chondroma of, 1108  
 chorea of, 1158  
 cysts of, 1108  
 development of, 808  
 edema of, 989, 990  
 edematous polypi of, 1105  
 examination of, 869  
 extirpation of, 1212  
 fibromata of, 1105  
 foreign bodies in, 1129  
   removal of, 1133, 1209  
 fracture of, 1139  
 hyperesthesia of, 1154  
 interior of, 819  
 in voice-production, 1174  
 ligaments of, 819  
 lipoma of, 1108  
 lupus of, 1060. See *Laryngitis, lupus*.  
 lymphatics of, 823  
 lymphoma of, 1108  
 malignant tumors of, 1109  
 mucous membrane of, 824  
 muscles of, 821  
 myxoma of, 1108  
 nerves of, 823  
 neuralgia of, 1154  
 neuroses of, 1154  
 pachydermia of, 1006  
   etiology, 1006, 1007  
 papilloma of, 1106  
   differential diagnosis of, 1107  
   in children, 1106  
   physical appearances, 1107  
   removal of, 1208  
 paralysis of, 1160  
   abductors of, 1167  
   paresthesia of, 1154  
   physiology of, 843  
   resection of, 1213  
   sarcoma of, 1113, 1111, 1115  
   pain of, 1155  
   in adults, 1156  
   symptoms, 1155
- Larynx, spasm of, treatment, 1156  
 stenosis of, 1139  
 dilatation of, 1209  
 syphilis of, 1071  
   treatment, 1073  
 transillumination of, 872  
 tuberculosis of, 1031, 1108.  
   See *Tuberculosis of larynx*.  
   diagnosis, 1044  
   etiology, 1034  
   pathological anatomy, 1037  
   prognosis and course, 1045  
   symptoms, 1038  
   treatment, 1046  
 veins of, 823  
 ventricle of, 820
- Latent hyperopia, 215
- Lateral nasal processes, 808  
 ventricle, 191
- Lead, 411, 459
- Lead-amblyopia, 462
- Leeches, 355  
 in diffuse inflammation of external meatus, 686  
 in iritis, 312
- Leeching in acute otitis media, 721
- Leiter coil in acute phlegmonous laryngitis, 989
- Lemon-juice in diphtheria, 1029
- Lens, 122. See also *Leuses*.  
 binocular magnifying, 147  
 concavo-convex, 125  
 convexo-concave, 125  
 double concave, 125  
   convex, 125  
 focal length of, 123  
 location of optical center of, 210  
 optical center of, 118  
 periscopic, 228  
 physical relation of, to conjugate foci, 103  
 plano-concave, 125  
 plano-convex, 125  
 spherical, 207  
 strength of, 123  
 unit to estimate strength of, 123  
 virtual focus of a concave, 124  
 crystalline, 80, 89, 122  
   acquired dislocations of, 396  
   capsule of, 80, 81  
   coloboma of, 191, 397  
   congenital anomalies of, 397  
   dislocation of, 396  
   conicity of, 179  
   contusion of, 367  
   contusion-injuries of, 365  
   depression of, 580  
   development of, 22  
   of capsule of, 23  
   dissection of. See *Dissection*.  
   diseases of, 386  
   dislocation of, 366, 384, 396  
   into anterior chamber, 366, 396  
   into vitreous, 366, 396  
   under Tenon's capsule, 396  
 epithelium of anterior capsule of, 81
- Leuses, crystalline, fibers of, 81  
 increase in size of, 215  
 index of refraction of, 89, 92  
 operations on, 574, 579  
   on capsule of, 585  
   radius of curvature of anterior surface of, 92  
   of posterior surface of, 92  
 removal of, for cure of myopia, 224  
 rupture of capsule of, 365, 367  
 structure of, 81  
 subconjunctival dislocation of, 366, 396  
 subluxation of, 396  
 suspensory apparatus of, 83  
 ligament of, 80, 84, 85, 95  
 thickness of, 92  
 treatment of dislocations of, 396  
 vascular sheath of, 23, 494
- Lenses. See also *Glasses* and *Spectacles*.  
 cylindrical, 126, 128, 207, 228  
 forms of, 125  
 method of testing, 239  
 spectacle, 123, 236  
 spherical, 128  
 spherocylindrical, 228  
 systems for designating, 123  
 toric, 126  
 trial, 207  
 use of trial case of, 208
- Lenz-pit, 20
- Lenz-stars, 23, 82
- Lenz-vesicle, 20
- Lenticonus, 397
- Lepra bacillus, 301, 614b  
 of conjunctiva, 302  
 of cornea, 329  
 of eyelids, 252
- Leprosy, bacillus of, 614b  
 of air-passages, 1066
- Leptomeningitis, purulent, 758  
 operation for, 801, 802
- Leptothrix buccalis, 265  
 in oro-pharynx, 846  
 in pharynx, 944
- Leroy and Dubois ophthalmometer, 196
- Letter-blindness in brain-abscess, 763
- Lenkoma, 285, 322  
 adherent, 279, 322, 323
- Leuko-sarcoma of choroid, 493
- Levator palati, 631, 810  
 palpebrae, 33, 254  
 contraction of, in association with external pterygoid, 255  
 superioris, 41  
 veli palati muscle, 631, 810
- Ligament of Zinn, 39
- Ligament, suspensory, of crystalline lens, 84, 85, 95
- Ligaments, check, 45  
 of larynx, 819  
 palpebral, 33
- Ligamentum pectinatum iridis, 28, 55
- Light, 98, 102  
 decomposition of, by prism, 98  
 propagation of, 103

- Light, quantitative perception of, 152  
 wave-theory of, 102, 104  
 Light-difference, 153  
 Light-minimum, 153  
 Light-reflex of tympanic membrane, 676  
 Light-sense, 152  
 in optic-nerve atrophy, 443  
 of periphery of retina, 168  
 Lime-water in frost-bite of auricle, 696  
 Line of fixation, 96, 128  
 of regard. See *Line of fixation*.  
 of vision, 128. See *Visual axis*.  
 Linear extraction of cataract, 395, 582  
 Lingual quinsy, 927  
 tonsil, 815  
 chronic inflammation of, 932, 933, 934  
 examination of, 869  
 inflammations of, 926, 927  
 operations on, 1296  
 pathology, 850  
 varix of, 934. See *Lingual varix*.  
 tonsillitis, 926  
 chronic, 932  
 tonsillotome, Roe's, 1206  
 varix, 934, 935  
 Linseed oil in frost-bite of auricle, 696  
 Lipoma of auricle, 696  
 of conjunctiva, 274, 301  
 of eyelids, 248  
 of larynx, 1108  
 of orbit, 531  
 of oro-pharynx, 1096  
 Lipomatous dermoid of conjunctiva, 390  
 Lipothymia laryngea, 1159  
 Lippitudo, 245, 246  
 Listerine in acute naso-pharyngitis, 948  
 in chronic naso-pharyngitis, 951  
 in chronic rhinitis, 909  
 Listing, 90, 92, 93  
 schematic eye of, 122  
 Listing's reduced eye, 93  
 Lithemic diathesis in throat and nose, treatment of, 875  
 Lithiasis conjunctivæ, 295  
 Liver, diseases of, 121  
 Lobule, cleft of, 692, 698  
 coloboma of, operation for, 782  
 fibroma of, operation for, 783  
 Localization of sound, 616  
 Locomotor ataxia, 151, 147, 448  
 Löffler's bacillus, 614b. See also *Klebs-Löffler bacillus*.  
 in croupous tonsillitis, 925  
 culture-mixture, 1018  
 solution in membranous rhinitis, 899  
 Longus colli, 814  
 Loring's ophthalmoscope, 172  
 Loupe, corneal, 117  
 Löwenberg's diplococcus in atrophic rhinitis, 960  
 Lozenges, 885  
 Lucae's method of aural massage, 736  
 Ludwig's incus-books, 790, 791  
 Lüer's antitoxin syringe, 1026  
 Lungs, syphilis of, 1073  
 Lupous laryngitis, 1060. See *Laryngitis*.  
 Lupus, 243, 258  
 erythematous of conjunctiva, 302  
 of larynx, 1060  
 of auricle, 695  
 treatment of, 686  
 of larynx, 1060. See *Laryngitis, lupous*.  
 of nose, 1058  
 of pharynx, 1058, 1059  
 vulgaris, 252  
 of air-passages, 1057  
 of larynx, 1060  
 Luschka's tonsil, hypertrophy of, 952. See *Lymphoid hypertrophy*.  
 Lymph-sheaths of retinal vessels, 87  
 Lymph-space, episcleral, 87  
 subarachnoid, 79  
 subdural, 79  
 Lymph-tract, anterior, of eyeball, 87  
 posterior, of eyeball, 87  
 Lymphangiectasis conjunctivæ, 299  
 Lymphangioma of orbit, 530, 531  
 Lymphatics of eyeball, 87  
 Lymphatism, 942  
 Lymphoid hypertrophy in pharyngeal vault, 952  
 causes, 952  
 diagnosis, 955  
 pathology, 952  
 prognosis, 955  
 symptoms, 954  
 treatment, 956  
 ring of pharynx, 811, 815  
 Lymphoma of larynx, 1108  
 of orbit, 531  
 MACKENZIE'S condenser, 857  
 forceps, 1208  
 tube-forceps, 1133  
 Macrotia, operation for, 783  
 Macula, the, 188  
 coloboma of, 193, 351  
 lutea, 66, 76  
 size of cones in, 139, footnote.  
 symmetrical changes at, in infancy, 123  
 of cornea, 322  
 vascularization of, 188  
 Macular bundle, 75  
 halo, 182, 188  
 reflex, 188, 406  
 Madarosis, 241, 246  
 Maddox's obtuse-angled prism, 159  
 rod-test for insufficiency of ocular muscles, 160  
 Magnet for removing foreign bodies from cornea, 506  
 Magnifying lens, binocular, 117  
 Maier, sinus of, 46  
 Malar bone, necrosis of, 258  
 Malaria, 310, 339, 421, 436, 459  
 Male-fern, 459  
 Male-fern amblyopia, 466  
 Malignant growths of auricle, 697  
 neoplasms of antrum, 1090  
 pustule. See *Anthrax pustule*.  
 tumors of fauces, 1095  
 of larynx, 1108  
 of nose, 1085  
 treatment, 1089  
 Malingering, 466  
 tests for detecting, 467  
 Malleo-incudal fold, 632  
 space, 632  
 Malleus, 630  
 excision of, 791  
 function of, 638  
 Malleus-handle, fracture of, 712  
 Mandl's solution in acute naso-pharyngitis, 948  
 Mania, acute, 150, 572  
 after cataract-extraction, 586  
 Manifest hyperopia, 215  
 Manubrium of the malleus, 630  
 Marasmus, 392  
 Mariotte's blind-spot, 169, 470. See *Blind-spot*.  
 Marrow-sheath, retained. See *Medullated nerve-fibers*.  
 Martin's bridge, 1189  
 Massage in affections of upper air-passages, 886  
 in atrophic rhinitis, 964  
 in non-suppurative disease of middle ear, 689  
 in perichondritis of auricle, 695  
 of cornea, 322  
 of eyeball in cataract, 394  
 in embolism, 408  
 in glaucoma, 384  
 of ossicles in chronic catarrh of middle ear, 736  
 Mastoid, caries and necrosis of, 752  
 cells, anterior, empyema of, 752  
 function of, 639  
 emissary vein, 624  
 empyema of apex of, with perforation into digastric fossa, 752  
 neuritis, 751  
 operation on, through skull, 803  
 operations, 793  
 pathology of, 663  
 periostitis, 749  
 process, sclerosis of, in chronic suppuration of the middle ear, 741, 751, 803  
 region, examination of, 672  
 Mastoiditis, Bezold's, 752  
 condensing, 751  
 interna, acute, 749, 750, 751  
 chronic, 751  
 profunda, 749  
 purulent, differential diagnosis, 764  
 superficialis, 749  
 Mathieu's iris-forceps, 577  
 Maxillary antrum, examination of, 862  
 exploratory puncture of, 863  
 opening of, 1200  
 transillumination of, 862, 970, 972

- Maxillary processes, 808  
 sinns, 154  
 benign neoplasms of, 1089  
 bony cysts of, 1089  
 cysts of mucous membrane of, 1089  
 empyema of, 968  
 treatment, 971  
 growths in, invading orbit, 533  
 osteoma of, 1090  
 polyp of, 1089  
 polypoid degeneration of, 971  
 syphilis of, 976  
 tumors of, 975  
 sinuses, anatomy, 966  
 empyema of, operative treatment, 1199  
 physiology of, 968  
 Mayer's hollow splint, 919  
 Measles, 269, 275, 436  
 middle-ear disease from, 717  
 relation of, to ear-disease, 652  
 Meatus, atresia of, operation for, 784  
 carcinoma of, operation for, 784  
 exostoses cartilagineæ of, operation for, 786  
 exostoses of, operation for, 785  
 external auditory, pathology, 655  
 external, cholesteatoma of, 657  
 diffuse inflammation of, treatment of, 686  
 furuncles of, 655  
 hemorrhage from, 655  
 neoplasms of, 657  
 foreign bodies in, operations for, 786  
 granulations of, operation for, 785  
 hyperostosis of, operation for, 785  
 internal auditory, 621  
 of nose, middle, clinical anatomy of, 829  
 examination of, 861  
 operations on, 784  
 Mechanism of auditory sensation, perception, and judgment, 611  
 Media of the eye, 104  
 determination of position of opacities in, 179  
 examination of, 178  
 location of opacities in, 183  
 opacities of, 183  
 three, separated by two systems, study of, 115  
 Medulla oblongata, 97  
 Medullary plates, 17  
 Medullated nerve-fibers, 191, 195, 405, 438  
 Megalophthalmos, 524. See *Buphthalmos*.  
 Meibomian, 412, 468  
 Meibomian cyst, 546. See *Chalazion*.  
 glands, 29, 33, 34, 249, 252  
 chalky deposit in, 547  
 Melioria of iris, 190  
 Melanocarcinoma of choroid, 493  
 Membrana pupillaris, 301  
 tentorium of Corti, 619  
 Membrana tensa, 629  
 tympani secundaria, 620  
 Membrane, basilar, 619  
 flaccid, 628  
 hyaloid, 82, 83, 84  
 of Descemet, 28, 55  
 Reissner's, 619  
 reticular, 620  
 Ruysch's, 59  
 Shrapnell's, 628  
 tympanic, 629  
 physiology, 637  
 Membranous conjunctivitis, 283, 284, 614*b*. See *Conjunctivitis, membranous*.  
 labyrinth, function of, 649  
 laryngitis, 990  
 rhinitis, 896. See *Rhinitis*.  
 Ménière's disease, 775  
 Meningitis, 150, 151, 391, 436, 495, 528, 572  
 after evisceration, 356  
 after enucleation, 356  
 from tympanic inflammation, 756  
 Meningocele, 533  
 Meningo-encephalitis, 150  
 Meniscus, 125  
 Menopause. See *Climacteric*.  
 Menorrhagia, 421  
 Menstrual disturbances, 330, 352, 399, 420, 421, 436, 461  
 Menstruation, relation of, to ear-disease, 650  
 Menthol in acute catarrhal laryngitis, 986  
 pharyngitis, 940  
 in chronic catarrh of middle ear, 733  
 spray in laryngeal tuberculosis, 1050  
 Mercurials in syphilis of internal ear, 690  
 Mercuric bichlorid in conjunctivitis, 275, 277, 280, 285, 287, 293  
 chlorid in diphtheria, 1020, 1028  
 in laryngeal tuberculosis, 1051  
 in ocular antiseptics, 540  
 Mercury, 460  
 in atrophic rhinitis, 964  
 in croupous laryngitis, 991  
 in diphtheria, 991  
 in iritis, 342  
 in labyrinthitis exudativa, 781  
 in laryngeal perichondritis, 996  
 protochlorid in laryngeal tuberculosis, 1051  
 Meridians, principal, of astigmatic eye, 224  
 Mesial nasal process, 807  
 Mesoderm, 19  
 Meso-pterygoid fossa, 833  
 Metamorphopsia, 353, 364, 429  
 Metencephalon, 19  
 Meter-angle, the, 133  
 Meyner's fibers, 149, 180  
 Micrococcus lanceolatus, 614*a*  
 Pasteuri, 614*a*  
 Micro-organisms in acute lacunar tonsillitis, 923  
 in conjunctival affections, 275, 614*a*  
 Micro-organisms in corneal ulcers, 311, 614*c*  
 in labyrinth, 767  
 in membranous rhinitis, 896  
 in ocular diseases, 614*a*  
 in sympathetic ophthalmitis, 349  
 of oro-pharyngeal tract, 846  
 Microphthalmos, 241, 329, 387, 455, 457, 524  
 Micropsia, 412, 468  
 Microscope, corneal, 147  
 Microsporion-trachomatousum, 292  
 Microtia, 691  
 Mid-brain, 19  
 Middle constrictor of pharynx, 811  
 Middle ear. See also *Tympanum* and *Tympanic cavity*.  
 acute affections of, 715.  
 See also *Tympanic cavity*.  
 acute catarrh of, pathology of, 659  
 acute catarrhal inflammation of, 660  
 acute inflammation of, treatment of, 686  
 acute purulent inflammation of, 660  
 acute suppuration of, 660  
 treatment, 688  
 anatomy of, 626  
 auscultation of, 679  
 cholesteatoma of, 661  
 chronic catarrh of, 726  
 functional examination of, 731  
 operations in, 737  
 physical examination in, 730  
 treatment, 733  
 chronic non-suppurative disease of, treatment of, 689  
 chronic non-suppurative inflammation of, 726  
 chronic purulent inflammation of, 660  
 chronic suppuration of, 739  
 treatment, 689, 745  
 examination of, 678  
 fibroma of, 661  
 function of, 637  
 functions of appendages of, 639  
 inflation of, 679  
 mucopurulent inflammation of, 660  
 progressive non-suppurative disease of, treatment of, 690  
 proliferous inflammation of, pathology of, 659  
 sclerosis of, 727  
 suppurative inflammation of, with tuberculosis, 662  
 Migraine, 214  
 Military ophthalmia, 294  
 Miliium of eyelids, 259  
 Millar's asthma, 986  
 Mineral waters in rheumatic affections of air-passages, 875  
 Miner's nystagmus, 520  
 Minister's sore-throat, 876  
 Mires of ophthalmometer, 198

- Mirror, otoscopic, 673  
 Mirrors, 129  
 Mixed astigmatism, 127, 227  
   colors, 99  
 Modiolus, development of, 618  
 Moe's forceps, 1138  
 Mogoponia, 1159  
 Moist applications in acute  
   otitis media, 721  
 Moll. glands of, 33, 35  
 Molluscum contagiosum, 259  
 Monochloracetic acid, 887  
 Monocular vision from sup-  
   pression of image, 499  
 Monophthalmos, 523  
 Monoyer's test-types, 140  
 Morellement in chronic paren-  
   chymatous tonsillitis, 931  
 Morgagnian cataract, 392  
 Morgagni's globules, 390  
 Morphine and carbolic acid in  
   herpes of fauces, 946  
   formanilid in laryngeal  
   tuberculosis, 1052  
   in acute otitis media, 721  
   in acute rhinitis, 893  
   in laryngeal tuberculosis,  
   1049  
   in lingual tonsillitis, 927  
   in spasm of larynx, 1156  
   spray in laryngeal tubercu-  
   losis, 1050  
 Morton's ophthalmoscope, 173  
 Mouth, development of, 898  
   physiology of, 841  
 Mouth-breathing, general treat-  
   ment of, 880  
   in chronic hypertrophic  
   rhinitis, 907  
   in chronic parenchymatous  
   tonsillitis, 931  
   in etiology of catarrhal in-  
   flammation, 846  
   palate in, 852  
   symptoms, 851  
 Mucocele, 266  
   of ethmoid, 533  
 Muco-purulent inflammation of  
   middle ear, 669  
 Mucous membrane, nasal, 833  
 Mules's operation, 321, 572  
 Müller's fibers, 67, 71, 75  
   muscle, 41, 134. See *Palpe-  
   bral muscle*.  
   ring-muscle, 61  
 Multiple neuritis, 140  
   sclerosis, 177  
 Mumps, 261  
   and ear-disease, 653  
   of lachrymal gland, 262  
 Muriate of ammonia in acute  
   catarrhal laryngitis, 986  
 Muriated tincture of iron in  
   acute tonsillitis, 925  
   in chronic suppuration  
   of middle ear, 689  
 Muscæ volitantes, 400, 410  
 Muscle, ciliary, 60, 95, 134  
   external rectus, 39, 101  
   Horner's, 47  
   inferior oblique, 41, 101  
   inferior palpebral, 34  
   inferior rectus, 39, 101  
   internal rectus, 39, 101  
   levator palpebræ superioris,  
   41  
   levator palpebrarum, 254  
 Muscle Müller's ring-, 61  
   of Müller, 41  
   of Riolan, 35  
   orbicularis palpebrarum, 253  
   superior oblique, 41, 101  
   superior palpebral, 34  
   superior rectus, 39, 101  
   tensor choroidea, 60  
   tensor tarsi, 47  
 Muscles of larynx, 821  
 Muscles, ocular. See *Ocular  
   muscles*.  
   ocular actions of, 100, 101  
 Muscular process of arytenoid,  
   818  
 Musical sounds, 635  
 Musk in diphtheria, 994  
 Myalgia of pharynx, 1153  
 Mydriasis, 331. See also *Pupil,  
   dilatation of*.  
   irritation, 150  
   paralytic, 149, 150  
   traumatic, 360  
 Mydriatics, 149, 209  
   effect of, on paralytic myosis,  
   150  
   in determination of refraction  
   of eye, 210  
   in iritis, 342  
   sterilization of, 542  
   table of, 211  
   use of, 196  
 Myelitis, 440  
   ascending, 437  
 Myodesopsia, 400  
 Myoma of ciliary body, 490  
 Myopia, 170, 212, 219, 333, 343,  
   352, 354, 394, 395, 399  
   a symptom of diabetes, 222  
   amplitude of accommodation  
   in, 137  
   axial, 125, 222  
   causes, 219  
   complicated with glaucoma,  
   3-5  
   complications, 220  
   course, 222  
   curvature, 222  
   determined by skiascopy, 205  
   determined by trial-lenses,  
   208  
   factors active in production  
   of, 220  
   full correction of, 223  
   index, 222  
   malignant, 220, 428  
   measured with ophthalmol-  
   scope, 199  
   operative treatment, 224  
   ophthalmoscopic changes in,  
   221  
   partial correction of, 223  
   progressive, 220  
   removal of transparent lens  
   for relief of, 585  
   symptoms, 220  
   tendency of, 219  
   treatment, 222  
   varieties, 219  
 Myopic astigmatism, 127, 227  
   eyes, care of, 223  
 Myosarcoma of ciliary body, 490  
 Myosis, 150, 334. See also  
   *Pupil, contraction of*.  
   irritation, 150  
   paralytic, 150  
   spinal, 150  
 Myoties, 149  
   effect of, on paralytic myosis,  
   150  
   in glaucoma, 384  
 Myringitis acuta, 713  
   chronica, 713  
 Myxedema, 436  
   of throat, 875  
 Myxoma of conjunctiva, 361  
   of drumhead, 714  
   of lachrymal gland, 263  
   of larynx, 1108  
 Myxomata of nose, 1076. See  
   *Polypi, nasal*.  
   removal of, 1196  
 NAGEL'S meter-angle system,  
   133, 134  
 Naphthalin, 460  
   insufflation in laryngeal  
   tuberculosis, 1050  
 Naphthol-camphor in chronic  
   myringitis, 714  
 Nares, examination of, 855  
 Nasal anesthesia, 1143  
   apertures, 832  
   bones, deflection of, treat-  
   ment, 1182  
   calculi, 1129  
   catarrh, 272. See *Rhino-  
   pharynx, diseases of*.  
   chamber, apertures of, 832  
   nerves of, 831  
   septum of, 830  
   chambers, asymmetry of, 831,  
   834  
   variations in, 826  
   cough, 1150  
   duet, size of, 270  
   stricture of, 266, 268, 269,  
   270  
   feeding in diphtheria, 1031  
   glycosuria, 1150  
   hyperesthesia, 1143  
   lamina, 808  
   meatus, middle, clinical  
   anatomy of, 829  
   mucous membrane, 833  
   cysts of, 1084  
   neoplasms, 1076  
   obstruction, pathology of,  
   818, 851  
   paresthesia, 1113  
   passages, tuberculosis of, 1053  
   treatment, 1057  
   polypi, 1076  
   removal of, 1196  
   probe, 860  
   processes, 807, 808  
   salivation, 1150  
   septum, abscess of, 899, 1116.  
   See *Abscess*.  
   evacuation of, 1198  
   acute perichondritis of, 899  
   deformities of, operations  
   for, 1190  
   deviation of, 831, 915  
   treatment, 917, 1191  
   examination of, 861  
   fractures of, 1124  
   fractoma of, 899  
   papilloma of, 1081  
   removal of growths on,  
   1194  
   vascular neoplasms of, 1079,  
   1080  
   specula, 859



- Nasal spine, 830  
 synchia, removal of, 1195  
 tube in chronic rhinitis, 910  
 wing, abscess of, 904  
   deformity of, operation, 1183  
   tumor of, 901
- Naso-lachrymal duct, 47
- Naso-pharyngitis, acute, 947  
 treatment, 948  
 chronic, 948  
 treatment, 951
- Naso-pharynx, 809. See also *Rhinopharynx*.  
 carcinoma of, 1095  
 diseases of, 947  
 enchondroma of, 1093  
 examination of, in ear-disease, 678  
 fibroma of, 1091  
   treatment, 1092  
 fibro-mucous polypi of, 1093  
 lymphoid structure of, 811  
 physiology of, 810  
 removal of growths from, 1202  
 sarcoma of, 1094  
 stenosis of, treatment, 1199  
 tumors of, 1091
- Near-point, 134, 155  
 of convergence, 503
- Near-sightedness. See *Myopia*.
- Nebula of cornea, 322
- Necrosing ethmoiditis, 1201
- Necrosis of mastoid, 752  
 of orbit, 526
- Neoplasms of antrum, 1090  
 of ethmoid sinuses, 1090  
 of external meatus, pathology, 657  
 of frontal sinuses, 1090  
 of maxillary sinus, 1089  
 of nasal septum, 1079  
 of naso-pharynx, 1091  
 of nose, 1076  
   removal of, 1196  
 of sphenoid sinus, 1091  
 of trachea, 1115  
 of upper air-passages, 1075
- Nephritis, 14, 390, 394, 406, 416, 436, 437, 454, 458  
 relation of, to ear-disease, 619
- Nerve, acoustic, 621  
 frontal, 37  
 oculo-motor, 37, 97  
 optic. See *Optic nerve*.  
 supraorbital, 37  
 sympathetic, 97  
 third. See *Oculo-motor nerve*.
- Nerve-head. See *Optic disk*.
- Nerves, ciliary, 97
- Nerve of nasal chamber, 834
- Nervous cough, 1158  
 diseases, from eye-strain, 214  
 influence on ear-disease, 618  
 trinitus, 777
- Nasal canal, 18  
 groove, 47
- Neuralgia, 519  
 mastoid, 754  
 of larynx, 1154  
 of pharynx, 1153  
 of throat, treatment, 876
- Neurasthenia, 149, 154
- Neuritic, 776. See *Acoustic neurasthenia*.
- Neuritis, acute retrobulbar, 440  
 ascending, 435  
 chronic retrobulbar, 441  
 descending, 432, 434  
 fulminant retrobulbar, 440  
 interstitial, 434  
 medullary, 435  
 multiple, 450  
 optic. See *Optic neuritis*.  
 retrobulbar, 460, 477
- Neuro-epithelioma of retina, 495
- Neuro-epithelium of retina, 69
- Neuroglia, 75
- Neuroma of eyelids, 248  
 of optic nerve, 449
- Neuro-paralytic keratitis, 317
- Neuro-retinitis, 433, 436, 477, 527  
 from lead-poisoning, 437
- Neuroses of larynx, 1154  
 of upper air-passages, 1140
- Neurotic disturbances of sound-perceiving apparatus, 776
- Nexus of ciliary body, 490
- New growths of auricle, 696  
 of drumhead, 714  
 of external auditory canal, 707
- Nicol-prism, 154
- Nictitating membrane, 31
- Night-blindness. See *Nyctalopia*.
- Night-terrors in chronic parenchymatous tonsillitis, 931
- Nitrate of mercury in diphtheria, 994  
 of silver, 460  
 in abscess of auricle, 694  
 in acute catarrhal laryngitis, 986  
 in chronic inflammation of lingual tonsil, 934  
 in chronic laryngitis, 1003  
 in chronic myringitis, 714  
 in chronic rhinitis, 909  
 in chronic subglottic laryngitis, 1009  
 in chronic suppuration of middle ear, 689, 746  
 in condylomata of auditory canal, 707  
 in conjunctivitis, 277, 280  
 in corneal ulcers, 315  
 in diphtheria, 994  
 in eczema of auricle, 693  
 of ear, 685  
 in epistaxis, 903  
 in inflammation of auditory canal, 705  
 in lupus of auricle, 686  
 in new growths of drum-head, 714  
 in paresthesia of pharynx, 1152  
 in salpingitis, 723  
 in singers' nodes, 1105  
 solution, 884  
 spray in laryngeal tuberculosis, 1050
- Nitrite of amyl, 406, 408, 460
- Nitrobenzol, 460
- Nitroglycerin, 449  
 in diphtheria, 1020
- Nodal points, 90, 93, 114, 116, 119, 120, 121, 123  
 for different systems of surfaces, 123
- Noduli cornea, 311
- Noises, 635
- Normals, 103
- Nose, absence of, operation for, 1184  
 acute affections of, 891  
 adenoma of, 1085  
 and throat, general therapeutics of, 874  
 angioma of, removal of, 1197  
 bony cysts of, 1082. See *Bony cysts*.  
 burns of, 1118  
 carcinoma of, 1089  
   excision of, 1198  
 chondroma of, 1084  
 chronic affections of, 905  
 concave vertical deformity of, treatment, 1181  
 contusions of, 1116  
 convex vertical deformity of the bony portions of, treatment, 1181  
 cystomata of, 1084  
 deficiency of tip of, treatment, 1182  
 deflection of bones of, treatment, 1182  
 deformities of, operative treatment, 1180  
 deviation of tip of, treatment, 1182  
 dislocation of bones of, 1125  
 of cartilages of, 1126  
 edematous polypi of, 1076  
 embryology of, 807  
 enchondroma of, removal of, 1198  
 erysipelas of, 901  
 examination of, in ear-disease, 678  
 excess of tip of, treatment, 1182  
 removal of, 1197  
 fibroma of, 1080  
 fibroma papillare of, 1081  
 foreign bodies in, 1127  
 fracture of bones of, 1119  
   treatment, 1124  
   of cartilages of, 1123  
 functions of, 835  
 hysteria of, 1169  
 illumination of, 855, 858  
 lupus vulgaris of, 1057  
 malignant growths of, removal of, 1198  
 malignant tumors of, 1085  
   treatment, 1089  
 myxoma of, removal of, 1196  
 myxomata of, 1076  
 osteoma of, 1084  
   removal of, 1198  
 papillary epithelioma of, 1086  
 papilloma of, 1084  
 physiology of, 835  
 plastic surgery of, 1180  
 reflex neuroses of, 1143  
 restoration of columna of, 1188  
   of tip of, 1187  
 sarcoma of, 1087  
 scalds of, 1148  
 sensory disturbances of, 1140  
 syphilis of, 1067  
   treatment, 1073  
 wounds of, 1116, 1117, 1118
- Nose-bleed, 902. See *Epistaxis*.

- Nostril, 832  
 stenosis of, operation for, 1183
- Nostrils, expanded, operation for, 1183  
 testing of patency of, 857
- Noyes's method of advancement, 591  
 tracheoma-forceps, 564
- Nuclei, oculo-motor, 149  
 lesion in, 150
- Nuclein in tuberculosis of larynx, 1017
- Nucleus of sphincter of iris, lesion in, 150
- Nux vomica in affections of upper air-passages, 886  
 in exhaustion of throat, 876
- Nyctalopia, 296, 318, 353, 422, 425, 468  
 visual field in, 473
- Nystagmus, 352, 445, 447, 519  
 miner's, 520
- OBJECT and image, 111, 112
- Oblique illumination, 146, 393  
 examination of media by, 178  
 inferior, 41, 101, 497, 502  
 paralysis of, 511, 513  
 muscles, tests for insufficiency of, 159  
 superior, 41, 101, 497, 502  
 paralysis of, 511, 513
- Obliquus auricule muscle, 637
- Occlusion of posterior nares, operation for, 1199  
 of pupil, 337, 341, 343
- Occupations in etiology of ear-diseases, 648
- Ocular antiseptics, 539, 540, 541, 574  
 blood-vessels, rupture of, 362  
 deviations, comitant, 507  
 conversion of non-comitant into comitant, 508  
 differential diagnosis between comitant and non-comitant, 507  
 etiological classification of anomalies of, 505  
 non-comitant, 507  
 subjective symptoms, 508  
 treatment, 520  
 fissure. See *Choroidal cleft*.  
 mask for cataract dressing, 542
- muscles, 39  
 actions of, 11, 42, 100, 101  
 advancement in insufficiency of, 521  
 affections of individual, 510  
 associated antagonists, 501  
 associated paralysis of, 519  
 associated spasm of, 519  
 classification of anomalies of, 501  
 common tendons of, 39  
 diagnosis of affected, 514  
 diplopia a test for insufficiency of, 156, 157  
 distance of insertion of, from cornea, 40  
 etiology of anomalies of, 504  
 etiology of deviations of, 505
- Ocular muscles, general symptoms of anomalies of, 504  
 Graefe's equilibrium test for, 157  
 hysterical insufficiency of, 185  
 insufficiencies of, 156, 254  
 operations, 587  
 physiological action of, 497  
 reflex disturbances in insufficiencies of, 510  
 rod-test for insufficiency of, 160  
 scheme of double images in paralysis of, 513  
 screen-test for insufficiency of, 156  
 Stevens's classification of insufficiencies of, 161  
 tenotomy in insufficiency of, 521  
 testing with prisms, 156, 157  
 treatment of insufficiencies of, 520  
 varieties of anomalies of, 504
- Oculo-motor nerve, 37, 97  
 center, 150  
 effect of lesion of, on pupil, 149  
 paralysis of, 254, 511  
 nuclei, 149  
 lesion in, 150  
 paralysis, 511, 515  
 recurrent, 512
- Oculo-orbital fascia, inflammation of, 529
- Odontic periostitis, 974
- O'Dwyer's tubes, 1029
- Odynphagia, 853  
 in laryngeal tuberculosis, 1039
- Oil of cade in eczema of auricle, 693  
 of cloves in laryngeal tuberculosis, 1017  
 of eucalyptus in acute catarrhal laryngitis, 986  
 of pine in acute catarrhal laryngitis, 986
- Oleate of morphia in furunculosis of ear, 686
- Oleo-stearate of zinc in chronic catarrhal pharyngitis, 942
- Olfaction, disturbances of, 1140  
 physiology of, 838
- Olfactometer, 858, 1111
- Olfactory area, 807  
 depression, 807
- Ollier's operation, 1187
- Opacities in transparent media, location of, 183
- Operating masks, 612
- Operations, 539, 782, 1180
- Ophthalmia. See *Conjunctivitis neonatorum*. See *Conjunctivitis neonatorum*.  
 nodosa, 296  
 serofulons, 286
- Ophthalmic artery, aneurysm of, 534  
 migraine, recurrent, 512  
 operations on animals' eyes, 611
- Ophthalmitis, sympathetic. See *Sympathetic ophthalmitis*.
- Ophthalmodynamometer, 161
- Ophthalmio-lemnoscope, 154
- Ophthalmomalacia, 357
- Ophthalmometer, 115, 324, 328  
 as a chromatometer, 154  
 method of using, 197  
 of Helmholtz, 196  
 of Javal-Schiötz, 196  
 of Leroy and Dubois, 196
- Ophthalmometry, 196, 231
- Ophthalmoplegia, bilateral  
 transient, 512  
 externa, 511  
 from ptomain-poisoning, 465  
 interna, 511  
 progressive, 512  
 totalis, 511
- Ophthalmoscope, 171  
 measurement of refraction with, 199  
 optical principles of, 173  
 use of, 171
- Ophthalmoscopes for refraction, 173
- Ophthalmoscopy, 171, 196  
 direct method of, 175  
 illumination in, 179  
 indirect method of, 176  
 measure of refraction by direct method of, 199  
 by indirect method, 201  
 position of surgeon and patient in, 180  
 refractive, 199
- Opiates in acute myringitis, 713  
 in acute otitis media, 720  
 in acute suppuration of middle ear, 688
- Opium in atrophic rhinitis, 964  
 in laryngeal tuberculosis, 1049
- Optic atrophy. See *Optic nerve, atrophy of*.  
 axis, 95, 128  
 canal, hemorrhage into, 444  
 periostitis of, 441  
 centers, primary, 479  
 chiasm, 149  
 cup, 20, 21  
 disk, 66, 77, 184  
 anemia of, 442  
 atrophic excavation of, 187  
 bands of connective tissue on, 456  
 crescents at margin of, 193  
 crescents near, 221  
 cystic growth from, 191  
 distorted, 187, 193  
 dragged, 221  
 excavations in, 187  
 fibrous growth from, 191  
 glaucomatous excavation of, 187  
 hyaline bodies in, 451, 496  
 ischemia of, 442  
 physiological excavation of, 66, 78, 187  
 sarcoma of, 496  
 entrance. See *Optic disk*.  
 foramen, 30, 39  
 nerve, 79, 149  
 arachnoidal sheath of, 79  
 atrophy of, 149, 357, 382, 385, 394, 442, 477, 527  
 from blows on head, 111  
 from brain-tumor, 444

- Optic nerve, atrophy of, from  
 erysipelas, 441  
 from forceps delivery, 446  
 from hemorrhage, 445, 459  
 from injuries, 444  
 from lead, 462  
 from lightning-stroke, 446  
 from locomotor ataxia, 445  
 from pressure on chiasm, 445  
 from sinus disease, 454  
 from spinal disease, 445  
 from spinal injuries, 444  
 with excavation, 376  
 carcinoma of, 449  
 changes in, from eye-strain, 213  
 changes in visual field in diseases of, 476  
 coloboma of, 191, 455, 457  
 color-sense in atrophy of, 443  
 concussion of, 114  
 congenital anomalies of, 455  
 congenital atrophy of, 446  
 diseases of, 432  
 dural sheath of, 79  
 effect of loss of conducting power of, 149  
 embolic atrophy of, 443  
 endothelioma of, 449  
 fibroma of, 449, 530  
 glaucomatous excavation of, 373, 377, 381  
 glioma of, 449  
 gray atrophy of, 442, 446  
 gumma of, 450  
 hemorrhage into, 453  
 hyperemia of, 432  
 injury of, 537  
 lesions of, from affections of accessory sinuses, 454  
 light-sense in atrophy of, 443  
 lymph-clefts of, 87  
 neuritic atrophy of, 433, 443, 447  
 neuroma of, 449  
 physiological excavation of, 382  
 pial sheath of, 79  
 progressive atrophy of, 478  
 psammoma of, 449  
 removal of tumors of, 601  
 sarcoma of, 449  
 subarachnoidal spaces of, 87  
 subdural lymph-space of, 79  
 supravaginal space of, 87  
 theory of sympathetic ophthalmitis, 349  
 tuberculosis of, 450  
 tumors of, 449  
 tumors of intra-ocular end of, 496  
 visual field in atrophy of, 446, 447  
 nerve-sheath, coloboma of, 191, 455  
 hemorrhage into, 453  
 neuritis, 324, 392, 409, 418, 432, 458, 480, 525, 534  
 color sense in, 433  
 diagnosis, 438  
 etiology, 435
- Optic neuritis from carious teeth, 438  
 from gonorrhoea, 437  
 from hemorrhage, 459  
 from intranasal operations, 438  
 from lead, 463  
 from nephritis, 437  
 from physical exertion, 438  
 from severe hemorrhage, 437  
 from sinus disease, 454  
 from sun-stroke, 438  
 in brain-tumors, 435, 436  
 in deformities of skull, 436  
 in general diseases, 436  
 in glaucoma, 374, 377  
 in infectious diseases, 436  
 in intracranial diseases, 435, 436, 437  
 in meningitis, 436  
 in spinal diseases, 437  
 intra-ocular, 432  
 intra-uterine, 455  
 monocular, 436, 438  
 pathology, 434  
 prognosis, 438  
 second attack of, 436  
 simple, 432  
 spurious, 438  
 syphilitic, 437  
 theories of pathogenesis of, 435  
 treatment, 439  
 trephining for, 439  
 vision in, 433  
 visual field in, 433, 477  
 papilla. See *Optic disk*.  
 perineuritis, 435  
 stalk, 19  
 thalamus, 479  
 tract, diseases of, 481  
 tracts, 149  
 vesicles, 19, 20, 21  
 Optical center, 117, 119, 120, 123  
 of a lens, 118, 240  
 defects of eye, 95  
 instruments, image-forming, 103, 105  
 principles, general, 102  
 surface, 109  
 surfaces, combined systems of, 115  
 systems, centered, 114  
 Optico-ciliary neurotomy, 574  
 neurotomy, 384  
 Optics, geometrical, 103  
 physical, 103  
 physiological, 102  
 Optogram, 98  
 Optometer, 207  
 Optometry, 196  
 Ora serrata, 26, 65, 76, 84  
 Orbicularis palpebrarum, 33, 253  
 paralysis of, 317  
 Orbiculus gangliosis, 61, 65  
 Orbit, abscess of, 526, 528  
 acute cellulitis of, 527  
 acute parietal periostitis of, 526  
 angioma of, 531  
 blood-cysts of, 531  
 caries of, 526  
 cavernous angioma of, 531  
 cellulitis of, 527
- Orbit, chronic periostitis of, 526  
 congenital anomalies of, 523  
 contents of, 37  
 echinococcus of, 531  
 emphysema of, 537  
 enchondroma of, 531  
 erysipelatos cellulitis of, 527  
 exenteration of, 600  
 exostosis of, 533  
 fistula of, 602  
 foreign bodies in, 536  
 hemorrhage into, 444, 537  
 injuries and diseases of, 523, 536  
 lipoma of, 531  
 lupus of, 533  
 lymphangioma of, 531  
 lymphoma of, 531  
 medullary osteosarcoma of walls of, 534  
 necrosis of, 258, 526  
 operation for abscess of, 599  
 operations for cicatricial, 500  
 operations on, 599  
 osteoma of, 533  
 palpation of, 143  
 periostitis of, 525  
 phlegmon of, 527  
 pulsating angioma of, 534  
 removal of osteoma of, 601  
 removal of tumors of, 600  
 sarcoma of, 531, 532  
 sebaceous cysts of, 531  
 serous cysts of, 534  
 spontaneous hemorrhage into, 537  
 thickening of periosteum of, 532  
 tumor arising in cavities close to, 533  
 tumors arising from periosteum or bony walls of, 531  
 tumors arising in tissues of, 531  
 tumors of, 255, 529  
 Orbital cellulitis, 438, 444  
 fascia, 42  
 margins, injuries to bones of, 536  
 veins, thrombosis of, 365  
 Orbits, 29  
 axes of, 29  
 Organ of Corti, function of, 644  
 Oro-pharynx, adenoma of, 1096  
 anatomy of, 812  
 carcinoma of, 1102  
 cyst of, 1096  
 fibroma of, 1096  
 lipoma of, 1096  
 papilloma of, 1095  
 sarcoma of, 1102  
 Orthophoria, 161, 505  
 Orthoptic exercises, 521  
 Ossicles, excision of, 791  
 in chronic catarrh of middle ear, 737  
 functions of, 638  
 of the ear, 630  
 Ossiculotomy, 791  
 Osteitic pyemia with sinus-phlebitis, 761  
 Osteoma of conjunctiva, 274, 301  
 of maxillary sinus, 1080  
 of nose, 1084  
 removal of, 1198



- Osteoma of orbit, 533  
removal of, 601
- Osteo-phlebitis of temporal bone, 761
- Othematoma, 655, 694
- Otic vesicle, 617
- Otitic brain-diseases, operations for, 801
- Otitis, desquamative, 753  
externa diffusa, 703  
pathology, 656  
media acuta, 660, 715  
suppurativa seu perforativa, 660  
media, acuta, 715  
deafness in, 716, 719  
pain in, 711, 719  
treatment, 720  
media catarrhalis chronica, pathology, 659  
media catarrhalis sicca, 659  
purulent, intracranial complications of, 755  
sclerotica, 659  
serosa, pathology of, 659  
suppurativa seu perforativa chronica, 660  
operation for, 793
- Otoconia, functions of, 642
- Otoliths, 618, 642
- Otomycosis, 704  
pathology, 657  
treatment, 686, 704
- Otorrhea, chronic, 660
- Otoscope, 679
- Otoscopy, 673  
illumination in, 673  
instruments for, 673  
source of light in, 675  
technic of, 675
- Outer wall of nasal chamber, 828
- Oval window, 620
- Oxid of zinc in eczema of auricle, 693  
in erysipelas of auricle, 685  
in inflammation of auditory canal, 704  
in polypi of auditory canal, 706
- Oxycyanid of mercury, 540
- Oxygen-gas in atrophic rhinitis, 961
- Oyster-shuckers' keratitis, 313
- Ozena, 957  
laryngis, 1001
- PACHYDERMIA of larynx, 1006
- Pachymeningitis, 436, 441, 511  
externa from ear-disease, operation for, 801  
from tympanic inflammation, 756, 758  
relation of, to ear-disease, 648
- Pagenstecher's ointment. See *Yellow acid*.
- Palatine artery, 814
- Palatoglossus, 814
- Palatopharyngeus, 810, 814
- Palpebre. See *Eyelids*.
- Palpebral arteries, 36  
fascia, 34  
fissure, operations for enlarging, 547  
operations for shortening, 547  
ligaments, 33
- Palpebral muscles, 34
- Panas's operation for ptosis, 558
- Pancreatin in diphtheria, 994
- Pannus, 291, 293, 308
- Panophthalmitis, 279, 315, 330, 355, 356, 527, 528, 583, 594  
bacilli in, 614d
- Papillary epithelioma of nose, 1086
- Papillitis. See *Optic neuritis*.
- Papilloma of auricle, 696  
of caruncle, 304  
of conjunctiva, 301  
of cornea, 329  
of eyelids, 248  
of larynx, 1106  
removal of, 1208  
of nose, 1081  
of soft palate, 1095  
of trachea, 1115
- Papillo-macular bundle, 447, 478  
degeneration of, 460
- Parabolic glasses in conical cornea, 328
- Paracentesis of cornea, 324, 567, 578, 584  
in iritis, 313  
of drum-membrane, 786  
in acute otitis media, 722
- Paracondyloid outgrowth, 633
- Paracausis, 776  
loci, 776  
Willissii, 666
- Parallactic displacement, 373, 501
- Paralysis in diphtheria, 1017  
laryngeal, 1160  
of abductors of larynx, 1167  
of vocal cords, 1167  
of arytenoideus, 1168  
of external rectus, 511, 513  
of inferior oblique, 511, 513  
rectus, 511, 513  
of internal rectus, 511, 513  
of ocular muscles, method of diagnosing, 514, 515  
scheme of double images in, 512  
of oculo-motor, 254, 511, 515  
of superior laryngeal nerve, 1168  
of superior oblique, 511, 515  
of tensors and adjusters of vocal cords, 1168  
of throat, 877  
of thyro-arytenoidei interni, 1169  
pharyngeal, 1151  
progressive, of insane. See *Paracausis*.
- Paralytic mydriasis, 150  
myosis, 150
- Paramastoid outgrowth, 633
- Parasites in frontal sinuses, 980
- Parenchymatous tonsillitis, acute, 923  
chronic, 929
- Paresthesia, nasal, 1143  
of larynx, 1154  
of pharynx, 1152
- Parinaud's conjunctivitis, 614c
- Parosmia, 1142
- Paroxysmal sneezing, 1149
- Pars ciliaris iridica, 26  
retinae, 26, 60
- Pars iridica retinae, 61, 65  
optica retinae, 65
- Passavant's cushion, 811
- Pathogenic bacteria, relation of, to ear-disease, 654
- Pearly tumor of the drumhead, 714  
of external meatus, 657  
tumors, 459
- Pemphigus, 256  
of conjunctiva, 303
- Pencils, 105  
astigmatic, 126
- Perchlorid of iron in atrophic rhinitis, 964  
in chronic subglottic laryngitis, 1009  
in diphtheria, 994
- Perforation in acute mastoiditis interna, 751  
of tympanic membrane, 677  
treatment, 688
- Perichondritis, acute laryngeal, 995  
of auricle, 655, 694  
of larynx, acute, 995  
of nasal septum, acute, 899
- Perilymph, function of, 640
- Perimeter, 164, 499  
charts, 165  
prismatic, 163  
self-registering, 165
- Perineuritis, 441, 454  
distal, 447  
optic, 435
- Periodontitis, treatment, 974
- Periostitis, mastoid, 749  
odontic, treatment of, 974  
of orbit, 525
- Periotic region, examination of, 672
- Periscope lens, 228
- Peritomy, 309, 566
- Peritonsillar abscess, evacuation of, 1207
- Perivasculitis of retinal vessels, 421
- Potassium of potassium in conjunctivitis, 280
- Peroxid of hydrogen, 242, 277, 280  
in diphtheria, 994  
in epistaxis, 903  
in sarcoma of soft palate, 1099
- Perpendicular plate of ethmoid, 830, 831  
fracture of, 1124
- Persistent hyaloid artery, 190, 403  
pupillary membrane, 301
- Persulphate of iron in croupous laryngitis, 991  
in diphtheria, 994
- Pertussis and ear-disease, 649
- Pes and Gradenigo, bacillus of, in atrophic rhinitis, 960
- Petit, canal of, 85
- Petrosal groove, 626  
sinus, inferior, 624  
superior, 623
- Petrous bone, fractures of auditory, symptoms of, 776
- Pflüger's letters, 155
- Pharyngeal abscess, evacuation of, 1207  
aponeurosis, 812



- Pharyngeal arteries, 814  
 bursa, significance of, 812, 949  
 paralysis, 1154  
 polypi, hairy, 1093  
 tonsil, 815  
 enlargements of, removal of, 1202  
 function of, 840  
 vault, examination of, 867  
 lymphoid hypertrophy of, 952
- Pharyngitis, acute catarrhal, 939, 940  
 chronic catarrhal, 941  
 follicular, 942, 943  
 granular, 942  
 lateralis, 942  
 sicca, 943
- Pharyngo-maxillary interspace, 921
- Pharyngo-mycosis, 944, 945
- Pharyngotomy, 1209, 1212
- Pharynx, anatomy of, 809  
 anesthesia of, 1151  
 blood-supply of, 814  
 constrictors of, 813, 814  
 deformities of, 1139  
 dermoid cyst of, 1094  
 diseases of, 938  
 examination of, 864  
 in ear disease, 678  
 foreign bodies in, 1135  
 hemorrhage from, 944  
 hyperesthesia of, 1151  
 in voice-production, 1175  
 injuries of, 1139  
 lupus of, 1058  
 lymphatics of, 815  
 lymphoid structure of, 815  
 myalgia of, 1153  
 nerves of, 815  
 neuralgia of, 1153  
 paresthesia of, 1152  
 physiology of, 841  
 sensory neuroses of, 1151  
 spasm of, 1153  
 syphilis of, 1069  
 treatment, 1073  
 tuberculosis of, 1055  
 treatment, 1057
- Phenacetin in acute nasopharyngitis, 918
- Phenol spray in laryngeal tuberculosis, 1050
- Phlebolith of conjunctival veins, 248
- Phlegmon. *See Abscess.*
- Phlegmonous inflammation of the auricle, 655  
 laryngitis, acute, 988
- Phlyctena pallida, 287
- Phlyctenular conjunctivitis. *See Conjunctivitis, phlyctenular.*  
 keratitis. *See Keratitis, superficial.*  
 ulcer, 307
- Phlyctenule, 306
- Phonation, physiology of, 839
- Phonatory spasm, 1158
- Phonmassage in disease of sound-perceiving apparatus, 784
- Phorias. *See Insufficiency of ocular muscles.*
- Photometer, 501  
 Stevens's, 158
- Phosphenes, 430
- Phosphorus in nasal and pharyngeal tuberculosis, 1057
- Photometer, 152, 153, 605
- Phthiriasis, 247
- Phthisis bulbi, 356  
 essential, 357
- Physiological cup, 187  
 excavation, 78. *See Physiological cup.*  
 optics, 102  
 salt solution, 540, 1212
- Physiology of ear, 634  
 of upper air-passages, 835
- Pial sheath of optic nerve, 79
- Picric acid, 459
- Pigments, 884  
 in laryngeal tuberculosis, 1050, 1052
- Pillars of fauces, 814, 930, 1205
- Pilocarpin in chronic catarrh of middle ear, 738  
 in glaucoma, 384  
 in hemorrhage into labyrinth, 780  
 in labyrinthitis exudativa, 781  
 in labyrinthitis hyperplastica, 780  
 in vitreous opacities, 400  
 injections in retinal detachment, 430  
 muriate in rheumatic conditions of upper air-passages, 875  
 nitrate in rheumatic conditions of upper air-passages, 875  
 sweats in choroiditis, 355  
 in iritis, 342  
 in optic-nerve atrophy, 449
- Pince-nez, 239
- Pinguicula, 298
- Pin-hole disk, 179, 208
- Pink-eye, 276
- Pinna, 625
- Piperazin in rheumatic conditions of throat, 874
- Pit, auditory, 617
- Pitch, 635
- Pituitary body, 438
- Placido's disk, 145, 324, 328
- Planes, focal, 91  
 principal, 90, 116
- Plant-growth in ear, 657  
 treatment of, 686
- Plica salpingo-palatina, 810  
 salpingo-pharyngea, 809  
 senilunaris, 31, 35. *See also Semilunar membrane.*
- Plugging of posterior nares in epistaxis, 904
- Pneumatic cells of the petromastoid, 632, 750, 795
- Pneumococci in corneal ulcers, 314
- Pneumococcus, 614a  
 in conjunctivitis, 275, 281, 614a  
 in ear, 653  
 in oropharynx, 846
- Pneumonia, 436
- Points, 105  
 cardinal, 92, 109  
 of optical surface, graphic method for locating, 113
- Points, focal, 92  
 nodal, 90, 93, 114, 116, 119, 120, 121, 123  
 for different systems of surfaces, 123  
 principal, 90, 92, 93, 109, 110, 114, 116, 120, 123  
 for different systems of surfaces, 123
- Poltzer aecometer, 668
- Politzerization, 681  
 in acute otitis media, 721  
 in perforation of tympanic membrane, 688  
 in salpingitis, 723
- Poltzer's experiment, 678  
 method of inflation, 681
- Polycoria, 334
- Polyotia, 692
- Polypi, aural, 661  
 fibro-mucous, of naso-pharynx, 1093  
 hairy pharyngeal, 1093  
 in frontal sinuses, 980  
 nasal, 1076  
 removal of, 1196  
 of auditory canal, 705  
 of drumhead, 714  
 of larynx, 1105  
 removal of, 1208  
 of maxillary sinus, 1089  
 of trachea, 1115  
 of tympanum, excision of, 792
- Polypoid degeneration of maxillary sinus, 974  
 hypertrophy of tonsil, 935
- Polypus, aural, 661
- Pons, apoplexy of, 150
- Pooley-White operation for ripening cataract, 584
- Porus opticus. *See Optic disk.*
- Post-aural abscess, 750
- Post-auricular region, examination of, 672
- Posterior cranial fossa, 623  
 nares, occlusion of, operation for, 1199  
 nasal aperture, 832
- Posterula, 833
- Post-nasal catarrh, acute, 947  
 chronic, 948  
 space, autosecopy of, 868  
 examination of, 866
- Potassium bromid, 460  
 in acute rhinitis, 893  
 chlorid in chronic laryngitis, 1004
- Powder-blower, 884
- Powder-grains in cornea, 368
- Powders in the air-passages, 884
- Predisposition in etiology of ear-disease, 647
- Pregnancy, 391, 416
- Prelachrymal abscess, 268
- Presbycusis, 772
- Presbyopia, 137, 212, 213, 232  
 correction of, 233  
 effect of astigmatism on, 234  
 of hyperopia on, 233  
 of myopia on, 233  
 premature, in glaucoma, 381
- Pressions centripetals, 672
- Pressure-probe, 736
- Primary position, 498  
 of eyes, 101

- Prince's single-suture advancement, 592
- Principal foci, 121  
focus, 114  
first, 109, 110  
second, 109, 110  
meridians of astigmatic eye, 224  
plane, 114  
planes, 90, 116  
point, 109, 110  
points, 90, 92, 93, 114, 116, 120, 123  
for different systems of surfaces, 123
- Prism, 130  
apex of, 130  
base-apex line of, 130  
deviation produced by, 133  
notation, systems of, 134  
obtusely-angled, 159  
passage of light-rays through, 131  
plane, refraction of light in the principal section of, 130  
principal section of, 130  
refracting angle of, 133  
revolving, 158  
use, 132
- Prism-convergence, 157, 503
- Prism-diopter, 133  
scale of Prentice, 133
- Prism-divergence, 157, 503
- Prism-test for feigned blindness, 467
- Prismatic lens, testing of, 210
- Prisms, 207  
exercises with, in insufficiencies of ocular muscles, 520  
for insufficiencies of ocular muscles, 521  
numeration by angular deviation, 133  
numeration of, 133  
overcoming, 499  
testing ocular muscles with, 156, 157, 504
- Probe, nasal, 860  
pressure-, 736
- Process, fronto-nasal, 807  
globular, 807  
intermaxillary, 808  
styloid, 625
- Processes, lateral nasal, 808  
maxillary, 808  
mesial nasal, 807
- Progressive muscular atrophy, 150  
paralysis, 445, 477
- Projecting auricle, operation for, 783
- Prolapse of iris after cataract-extraction, 583  
treatment, 576
- Proptosis, 170
- Prosencephalon, 19
- Protection, function of larynx in, 813  
function of nose in, 839
- Prosthesis, in cicatricial orbit, 600  
oculi, 599
- Protozoa, parasitic, in trachoma, 292
- Prussak's pouch, 632
- Psammona of the optic nerve, 419
- Pseudo-diphtheria bacillus, 614b, 1019  
in acute croupous tonsillitis, 925  
in atrophic rhinitis, 960  
in membranous rhinitis, 896
- Pseudo-glioma, 400, 494
- Pseudo-isochromatic plates of Stilling, 604  
tests for color-sense, 145
- Pseudo-ptosis, 485
- Pterophthalmia, 215
- Pterygium, 297  
operations for, 561  
treatment, 298
- Ptomain-poisoning, visual disturbances from, 465
- Ptomains, 435, 459
- Ptosis, 254, 465, 565  
adiposa, operations for, 560  
congenital, 242, 254  
operations for, 557  
traumatic, 255
- Puerperal septicemia, 528  
state, 355, 437
- Pug-nose, operation for, 1182
- Pulsating exophthalmos, 531
- Pulsation of retinal arteries in optic neuritis, 433
- Pulse in diphtheria, 1017
- Punctum proximum. See *Near-point*.  
remotum. See *Far-point*.
- Pupil, 61, 96, 147  
abnormal reactions of, 149  
action of, to mydriatics, 149  
to myotics, 149  
actions of. See *Pupil-reactions*.  
associated action of, 148  
average diameter, 147  
cerebral cortical reflex of, 151  
cerebral origin of dilatation of, 150  
consensual action of, 148  
contraction of, 150  
convergence-reaction of, 148  
dilatation of, 149  
dilator of, 64, 96  
direct reflex action, 148  
diseases which cause dilatation of, 149  
eccentric position of, 334  
effect of accommodation on contraction of, 149  
effect of convergence on contraction of, 148  
effect of disease on, 149  
effect of irritation of sympathetic on, 150  
faulty, 334  
indirect reflex action of, 148  
in disease, 149  
influence of age on size of, 147  
influence of refraction on size of, 147  
measurement of, 148  
methods of testing reactions of, 148  
occlusion of, 337, 341, 343  
optical, 575, 578  
orbicularis action of, 151  
pain-reaction of, 149  
seclusion of, 337, 341, 344
- Pupil, skin-reflex of, 149  
special phenomena of, 151  
sphincter of, 64, 96  
spinal origin of dilatation of, 150  
varying in equality of, 151
- Pupil-reactions, 148, 149  
methods of testing, 148  
paradoxical, 151
- Pupil-reflex, centrifugal part of, 149  
centripetal part of, 149  
path of, 149
- Pupillary membrane, 23, 27, 390  
persistent, 21, 301
- Pupillometers, 148
- Pupils in hemianopia, 480
- Purkinje, images of, 98, 135
- Purkinje's figures, 144
- Purpura, 421
- Purpura hemorrhagica, 314
- Purulent leptomeningitis from tympanic inflammation, 758  
mastoiditis, differential diagnosis of, 764  
otitis media, intracranial complications of, 755
- Pyemia, 339, 355, 421, 528  
from ear-disease, 759
- Pyoktatin, injections of, in carcinoma, 252  
in lupous laryngitis, 1066
- Pyramid, 631
- Pyriiform sinuses, 871
- Pyrozone in chronic inflammation of lingual tonsil, 931  
in chronic naso-pharyngitis, 951  
in pharyngo-mycosis, 946
- QUALITATIVE tests of hearing, 669
- Quality of sound-tones, 635
- Quantitative tests of hearing, 668
- Quinin, 459  
in acute inflammation of middle ear, 687  
in acute naso-pharyngitis, 948  
in acute rhinitis, 893  
in affections of upper air-passages, 886  
in anosmia, 1144  
in auditory vertigo, 690  
in lupous laryngitis, 1066  
influence on the ear, 654
- Quinin-amaurosis, 463
- Quinin-amblyopia, temporary, 463
- Quinsy, 925. See *Circumtonsillar inflammation, acute*.  
evacuation of abscess of, 1207  
lingual, 927
- RABBIT'S conjunctiva, transplantation of, 563  
cornea, transplantation of, 323
- Rachitis, 387, 391  
and ear-disease, 650
- Radiant, 102
- Radii, 103, 105
- Radius, 104

- Radius of curvature of anterior surface of lens, 92  
 of cornea, 92  
 of posterior surface of lens, 92  
 of refracting surface, 106
- Railway service, standards of form and color-vision required in, 606
- Râles in the ear, 680
- Randall's ophthalmoscope, 173  
 test-types, 151
- Range of accommodation, 136
- Ray, 101  
 incident, 105  
 reflected, 105  
 refracted, 105
- Rays, 105  
 homocentric, 89
- Readjustment and resection.  
*See Advancement*, 590
- Real images, 124
- Recessus hypotympanicus, 628
- Reclination, 347
- Recti, insufficiency of external, 157, 515  
 insufficiency of internal, 157, 517  
 tenotomy of, 587, 589
- Rectus capitis anticus muscle, 811  
 external, 39, 101, 497, 502  
 paralysis of, 511, 513  
 inferior, 39, 101, 497, 502  
 paralysis of, 511, 513  
 internal, 39, 101, 497, 502  
 paralysis of, 511, 513  
 superior, 39, 101, 497, 502
- Recurrent fever, 421  
 laryngeal nerve, 823  
 paralysis of, 1166
- Red-blindness, 603
- Red-gum tablets, 886  
 troches in acute catarrhal pharyngitis, 910
- Reduced eye, 93  
 formation of images in, 94
- Red vision, 468
- Reflection, 103, 105, 109  
 angle of, 105  
 size of corneal, 196  
 total, 132
- Reflections during ophthalmoscopy, 181
- Reflex, foveal, 67  
 neuroses of nose, 1143
- Refracting angle of prism, 133  
 surface, radius of, 106  
 single, 93
- Refraction, 103, 105  
 abnormal, 212  
 angle of, 104, 105, 106  
 determination of, with trial lenses, 208, 209  
 index of, 105  
 measurement of, with ophthalmoscope, 199  
 mydriatics in determining, 210  
 normal, 212  
 objective methods for measurement of, 198  
 of eye at different parts of retina, 200  
 general plan of examining the, 211
- Refraction of eye, methods of determining, 196  
 of homocentric rays, 90  
 ophthalmoscopes, 173  
 progressive changes in, 214  
 static, 138, 139  
 subjective methods of testing, 207
- Refractive errors, 183
- Reissner's membrane, 619
- Rekoss's disk, 172
- Relapsing fever, 339, 398
- Relative accommodation, 137, 155
- Resection of larynx, 1213
- Reserve-air test of hearing, 669
- Resonance, 636
- Resonators of the voice, 1174
- Resorein in chronic rhinitis, 910  
 in laryngeal tuberculosis, 1051  
 in lupus of pharynx, 1059  
 in nasal and pharyngeal tuberculosis, 1057
- Respiration in disease of upper air-passages, 853  
 physiology of, 835
- Respiratory organs, relation of, to ear disease, 649  
 tract, upper. *See Air-passages, upper*.
- Rest in affections of upper air-passages, 881  
 in chronic laryngitis, 1004
- Reticular membrane, 620
- Retina, 65  
 acuity of vision of peripheral parts of, 168  
 anemia of, 406  
 anesthesia of, 410, 485  
 aneurism of central artery of, 410  
 angioid streaks in, 427  
 apoplexy of, 420  
 atrophy of, 515  
 bipolar nerve-cell, layer of, 72  
 blood-vessels of, 78  
 capillary hyperemia of, 408  
 central artery of, 78, 86  
 changes in, from eye-strain, 213  
 changes in visual field in diseases of, 473, 475  
 concussion-injuries of, 364  
 concussion of, 414  
 congenital peculiarities of, 405  
 congestion of, 409  
 cysticercus of, 431  
 cysts of, 494  
 derivation of essential nervous elements of, 222  
 detachment of, 222, 357, 377, 401, 428, 491  
 operations for relief of, 130  
 development of, 25  
 diseases of, 405  
 disturbances of pigment of, 405  
 edema of, 411, 414  
 elements of mammalian, 72  
 embolism of central artery of, 406, 421  
 excitability of, 98  
 external limiting membrane of, 75
- Retina, external plexiform layer of, 71  
 formation of images on, 90  
 functions of, 97  
 ganglion-cell-layer of, 74  
 glioma of, 356, 398, 400, 494  
 hemorrhage in, 364, 417, 420, 428, 534  
 from cutaneous burns, 421  
 hyperemia of, 408  
 image on, 89  
 inner nuclear layer of, 72  
 reticular layers of, 74  
 internal limiting membrane of, 75  
 plexiform layers of, 74  
 irritation of, 409  
 layer of rods and cones of, 69  
 layers of, 67  
 light-sense of periphery of, 168  
 lymphatics of, 79  
 macular bundle of, 75  
 nerve-epithelium of, 69  
 nerve-fiber layer of, 74  
 neuro-epithelioma of, 495  
 neuroglia of, 75  
 non-pigmented, atrophy of, 426  
 sclerosis of, 426  
 outer reticular layer of, 71  
 periphery of, 189  
 pigmentation of, from injury, 365  
 pigmented epithelium of, 25  
 sclerosis of. *See Retinitis, pigmentary*.  
 pigment-layer of, 67  
 pigment-striae in, 427  
 retained medullated nerve-fibers in, 194, 195  
 sclerosis of, 424  
 sensitiveness of, to colors, 99  
 spider-cells of, 75  
 sustentacular tissue of, 75  
 telangiectasia of vessels of, 410  
 thrombosis of central artery of, 408  
 vein of, 410, 421, 444  
 traumatic anesthesia of, 360  
 detachment of, 365  
 tumors of, 494  
 varicose veins of, 410  
 visual field in detachment of, 474
- Retinal artery, central, 24  
 epithelium, pigmented, 22  
 image, 89  
 in anisotropia, 139  
 in emmetropia, 139  
 size of, 125  
 images, distortion of, by cylinders, 230  
 vessels, entwined, 186  
 light reflex from, 182, 185  
 lymph-sheath of, 87
- Retinitis, 321, 410  
 albuminuric, 195, 416, 437, 458  
 induction of premature labor for relief of, 418  
 symptoms and pathology of, 416  
 visual field in, 474  
 atypical pigmentary, 426  
 central punctate, 422  
 relapsing, 414

- Retinitis, circinata, 422, 475  
 diabetic, 419, 475  
 diffuse, 411  
 embolic, 423  
 forms, 410  
 glycosuric, 419  
 hemorrhagic, 410, 415, 420  
 leukemic, 419  
 macular, 421  
 nephritic, 416  
 nyctalopia, 412, 469  
 of Bright's disease, 416  
 parenchymatous, 415  
 peripapillary, 411  
 perivascularis, 415  
 pigmentary, 385, 422  
   visual field in, 473  
 proliferans, 427  
 punctata albescens, 422  
 purulent, 423  
 renal, 416  
 serous, 411  
 simple, 411  
 solar, 422  
 striata, 428  
 suppurative, 423  
 sympathetic, 414  
 syphilitic, 413  
 unilateral albuminuric, 416  
   with exudative spots, 413
- Retino-choroiditis, 414, 422  
 syphilitic, 419, 426
- Retinoscopy. See *Skiascopy*.
- Retractor of ala nasi, 860
- Retrahens auriculæ, 636
- Retrolabular neuritis. *Neuritis, retrolabular*.
- Retropharyngeal abscess, evacuation of, 1207
- Rheostat, 887, 888
- Rheumatic diathesis, throat and nose in, 871, 875
- Rheumatism, 261, 319, 330, 436, 440, 461, 511  
 gonorrhœal, 279  
 iritis from, 339
- Rhinitis, 266  
 acute, 891  
   treatment, 893  
 atrophic, 957  
   treatment, 963  
 chronic hypertrophic, 965  
   treatment, 908  
 cirrhotica, 957  
 croupous, 896  
 fibrinosa, 896  
 membranous, 896  
   treatment, 898  
 sicca, 957  
 tablets for, 893
- Rhinoliths, 1129
- Rhino-pharynx, 809  
 dependence of lachrymal disease on affections of, 272  
 diseases of, 216, 409  
   in phlyctenular conjunctivitis, 286  
   in phlyctenular keratitis, 305
- Rhinoplasty, 1184  
 German and French method, 1185  
 Indian method, 1184  
 Italian method, 1186  
 partial, 1187  
 Tagliacotian method, 1186
- Rhinoscopic mirror, 866
- Rhinoscopy, 855
- Rhodopsin, 69
- Rice-powder in cezema of ear, 685
- Rima glottidis, 820
- Rinne's test, 670  
 in chronic catarrh of middle ear, 732
- Riolan, muscle of, 35
- Ripening operations for immature cataract, 584
- Risley's rotary prism, 158
- Rivianian segment, 628
- Roberts's operation for deviated septum, 917
- Rodent ulcer of cornea, 313  
 of eyelids, 251
- Rods and cones of retina, 69  
 number of, 71  
 of Corti, 619
- Rod-test for insufficiency of ocular muscles, 160
- Rod-visual cell, 69
- Rod's intranasal spring, 1122  
 laryngeal dilator, 1209  
 lingual tonsillotomy, 1206  
 metallic form for fractures of nose, 1121  
 spiral-lever extractor, 1138  
 tracheal forceps, 1134
- Rongeur for sphenoid sinuses, 983
- Röntgen rays, 369  
 location of foreign bodies in larynx by, 873  
 dangers of, 611  
 in ophthalmic surgery, 607  
 influence on blind eyes, 611  
 practical application of, 607
- Roof of nasal chamber, 826
- Rose-cold, 1144
- Rosenmüller's fossa, 810
- Rotation, center of, 96
- Round window, 620
- Rubinat water in acute rhinitis, 893
- Ruete's perforated mirror, 172
- Rupture of drumhead, 712
- Ruysch, membrane of, 59
- SACCULE, development of, 617, 618
- Sacculus laryngis, 820
- Saddle-bridge, 238
- Sacmisch's section, 315, 568
- Safety tube, 631
- Salicin in acute tonsillitis, 924  
 in laryngeal tuberculosis, 1048  
 in lupous laryngitis, 1066
- Salicylate of sodium in glaucoma, 384
- Salicylates in acute catarrhal pharyngitis, 949  
 in rheumatic conditions of throat, 874
- Salicylic acid, 459  
 in atrophic rhinitis, 964  
 in diphtheria, 1028  
 in cezema of auricle, 693  
 in pharyngo-mycosis, 946  
 in rheumatic diathesis, 874
- Saline cathartic in acute otitis media, 720  
 laxatives in acute suppuration of middle ear, 688
- Salivation, nasal, 1150
- Salol in acute tonsillitis, 924  
 in laryngeal tuberculosis, 1048  
 in pharyngo-mycosis, 946
- Salol-camphor in chronic myringitis, 714
- Salpingitis, 723
- Salt solution in chronic hypertrophic rhinitis, 909  
 in diphtheria, 1028  
 injection or transfusion of, 1213
- Santonin, 459
- Santorini, cartilage of, 816, 818
- Sarcoma, metastatic, of choroid, 493, footnote.  
 of antrum, 1090  
 of caruncle, 304  
 of choroid, 491  
 of ciliary body, 491  
 of conjunctiva, 304  
 of cornea, 329  
 of eyelids, 250  
 of iris, 490  
 of lachrymal gland, 264  
 of larynx, 1113  
 of naso-pharynx, 1094  
 of nose, 1087  
 of optic disk, 496  
 of optic nerve, 449  
 of orbit, 531, 532  
 of oropharynx, 1102  
 of sclera, 330  
 of soft palate, 1098  
 of tonsils, 1100
- Scala, tympanic, 619  
 vestibular, 619
- Scalds of nose, 1118
- Scarification in laryngeal tuberculosis, 1051
- Scarlattina, 269, 275, 436, 458, 528
- Scarlet fever, arrested ethmoid development in, 828  
 otitis media from, 717  
 relation of, to ear-disease, 651
- Schærch's cantery-handle, 888
- Schematic eye, 92  
 of Listing, 122
- Schlemm's canal, 55, 60, 61, 86, 87  
 in glaucoma, 376, 377
- Schmidt-Rimpler's method of measuring refraction, 201
- Schwabach's test, 670
- Schwartz's operation, 783, 793
- Schwartz's-stacke operation, 793, 796, 798
- Schwartz-Zaufal operation, 793, 796
- Schweigger's operation of resection of a rectus tendon, 591
- Sclera, 53  
 abscess of, 330  
 blood-vessels of, 54  
 development of, 27  
 diseases of, 329  
 enchondroma of, 330  
 epithelioma of, 330  
 fibroma of, 330  
 lymphatics of, 54  
 melanosis of, 330  
 nerves of, 54  
 osseous degeneration of, 330



- Sclera, perforation of, during tenotomy, 594  
 rupture of, 361  
 sarcoma of, 330  
 sulcus of, 49  
 tumors of, 330  
 Scleral corpuscles, 53  
 processes, 51  
 puncture in glaucoma, 383  
 ring, 66, 184  
 staphyloma, 361  
 wounds, operations for closing, 569  
 Scleritis, 144, 324  
 anterior, 330  
 deep, 330  
 gummatous, 330  
 Sclero-corneal juncture, the, 54  
 Scleronyxis, 580  
 Sclerophthalmia, 329  
 Sclerosing keratitis, 324  
 Sclerosis of mastoid process in chronic suppuration of the middle ear, 741, 751, 793  
 of middle ear, 727  
 Sclerotic. See *Sclera*.  
 Sclerotic-choroiditis, 330  
 Sclerotomy, 569, 570, 578  
 anterior, 385  
 in glaucoma, 383  
 posterior, 385, 570  
 Scopolamin, 209  
 Scorbutus, 537  
 Scotoma, 163, 169, 361, 410, 411, 422, 433, 451, 470, 472, 475, 486  
 absolute, 169, 472  
 central, 169, 440, 441, 445, 447, 448, 458, 466  
 flickering, 483  
 for colors, 169  
 in disseminated choroiditis, 475  
 in embolism of central artery of retina, 474  
 in glaucoma, 380  
 in medullary nerve-fibers, 476  
 negative, 169, 472  
 para-central, 169  
 peripheral, 169  
 physiological, 169  
 positive, 169, 472  
 relative, 169, 472  
 ring, 169  
 in syphilitic chorio-retinitis, 475  
 scintillans of Listing, 483  
 test-objects for, 169  
 Screen-test, 502, 504  
 for insufficiency of ocular muscles, 156  
 Screw-worm in frontal sinuses, 980  
 Serofulu, 243, 246, 261, 319, 330, 352, 387, 528  
 Serofulous ophthalmia, 286, 305  
 Scurvy, 421  
 Serratus, 628  
 development of, 622  
 Seasons in etiology of ear-disease, 617  
 of diphtheria, 1011  
 Sebaceous cysts of auricle, 696  
 of eyelid, 260  
 Sebaceous cysts of eyelids, 259  
 of orbit, 531  
 Seborrhea, 246  
 congestiva of larynx, 1060  
 nigricans, 259  
 of eyelids, 258  
 Seclusion of pupil, 337, 341, 343  
 Second sight, 222, 392  
 Secondary position, 498  
 Seiler's solution, 882, 883  
 Semicircular canals, 621  
 development of, 617  
 Semilunar membrane, affections of, 304  
 Septal deformities in etiology of nasal obstruction, 849  
 wall of nasal chamber, 830  
 Septic affections from suppuration of ear, 761  
 Septicæmia, 421  
 Septometer, 861  
 Septum, abscess of, 899. See *Abscess*.  
 hematoma of, 899  
 nasal, deviation of, 831. See *Nasal septum*.  
 orbitale, 31  
 vascular neoplasms of, 1079  
 Sero-mucous middle-ear catarrh, pathology of, 659  
 Serpiginous ulcer of cornea, 314  
 Serum-therapy, 286, 963, 1020  
 Sex in etiology of ear-disease, 617  
 Sexton's forceps, 790  
 Sexual organs, relation of, to ear-disease, 650  
 Shadow-test. See *Skiascopy*.  
 Shotted silk reflections, 182  
 Shrapnell's membrane, 628  
 appearance of, 676  
 Siegle's pneumatic speculum, 678  
 Sigmoid sulcus, 624  
 Silver nitrate in acute naso-pharyngitis, 948  
 in acute tonsillitis, 924  
 in chronic catarrh of Eustachian tube, 735  
 in chronic catarrhal pharyngitis, 941  
 in chronic naso-pharyngitis, 952  
 in nodular laryngitis, 1006  
 in pharyngo-mycosis, 946  
 Simple extraction of cataract, 395  
 Singers' nodes, 1104  
 Sinistroversion, 500  
 Sinus, inferior petrosal, 624  
 of Maier, 46  
 superior petrosal, 623  
 transverse, 624  
 Sinus-thrombosis from ear-disease, 759  
 operation for, 802  
 Sinusitis, premaxillary, acute, with stenosis, 969, 973  
 acute, without stenosis, 969, 972  
 chronic, 973  
 Skiagraphy. See *Röntgen rays*.  
 Skiascopy, 179, 196, 202, 230, 231  
 aberration in, 206  
 band-like appearance in, 206  
 Skiascopy in emmetropia, 205  
 in hyperopia, 205  
 in irregular astigmatism, 207  
 in regular astigmatism, 206  
 light area in, 204  
 in myopia, 205  
 point of reversal in, 203  
 practical application of, 205  
 with concave mirror, 203, 204  
 with plane mirror, 203  
 Skin, condition of, in affections of upper air-passages, 877  
 Skin-flap, grafting of, without pedicle, 533  
 Skin-grafting in atresia of external auditory canal, 698  
 Thiersch's method of, 533  
 Skin-grafts, 243, 372, 551  
 in symblepharon, 563  
 Skin-reflex of pupil, 149  
 Skull, opening of, in brain-disease from ear, 803, 804  
 Small-pox. See *Variola*.  
 of drumhead, 714  
 Smell, loss of, in diseases of upper air-passages, 852  
 sense of, 838  
 testing of, 858  
 Snake-venom, 459  
 Snare for intratympanic polypi, 792  
 galvano-cautery, in fibroma of naso-pharynx, 1092  
 in nasal polypi, 1079  
 in vascular neoplasms of nasal septum, 1080  
 Sneezing in lupus of nose, 1058  
 paroxysmal, 1149  
 Snell's law, 103, 105, 107, 130, 132  
 Snellen's clamp, 782  
 colored-letter test for feigned blindness, 467  
 operation for cataract, 559  
 for senile cataract, 551  
 of tenotomy, 588  
 test-types, 139, 140  
 types for accommodation, 155  
 Snow-blindness, 468  
 Snuffs, 884  
 Sodium formate in lupus of pharynx, 1059  
 salicylate in acute tonsillitis, 925  
 in laryngeal tuberculosis, 1048  
 Soft cataract. See *Cataract, congenital*.  
 palate, carcinoma of, 1099  
 fibroma of, 1096  
 in voice-production, 1176  
 papilloma of, 1095  
 physiology of, 843  
 sarcoma of, 1098  
 treatment, 1099  
 Sound, localization of, 646  
 Sound-collecting apparatus, 636  
 Sound-conducting apparatus, 637  
 excision of, 788  
 Sound-memory, 646  
 Sound-perceiving apparatus, diseases of, 765  
 diagnosis, 778  
 symptomatology, 772

- Sound-perceiving apparatus, treatment, 780  
morphology of, 765  
neurotic disturbances of, 776
- Sound-recording apparatus, 640
- Sound-waves, production and propagation of, 634
- Soziodal of soda in chronic rhinitis, 910
- Space of Tenon, 43, 54, 87
- Spaces of Fontana, 28, 55, 86, 87, 377
- Spasms of accommodation, 213, 216  
of glottis, 995  
of larynx, 1155  
in adults, 1156  
of ocular muscles, method of diagnosing, 514, 515  
of pharynx, 1153  
phonatory, 1158
- Spasmodic asthma, 1148
- Spectacle-frames, 238
- Spectacle-front, measurements for, 238
- Spectacle-lens, 236
- Spectacles and their adjustment, 236. See also *Glasses*.  
stenopaic, 231
- Spectral colors, 98
- Spectroscope, 154
- Specula, nasal, 859
- Speculum, ear-, 673  
Siegel's pneumatic, 678
- Sphenoid cavity, disease of, operative treatment, 1201
- Sphenoid sinus, 454  
neoplasms of, 1091
- Sphenoidal cells, 967  
chronic empyema of, treatment, 983  
diseases of, 982  
disease, 982  
fissure, 30, 39  
sinus, examination of, 864  
growths in, invading orbit, 533
- Spheno-maxillary fissure, 30
- Spheno - salpingo - staphylinus, 810
- Sphere, 126
- Spherical aberration, 88, 96, 230  
longitudinal, 108  
lens, 207  
testing of, 210  
lenses, 128
- Sphero-cylindrical lens, testing of, 210  
lenses, 228
- Sphincter of iris, 145  
lesion of nucleus of, 149  
rupture of, 363  
pupilla, 61, 96
- Spider-cells, 75
- Spinal cord, 97  
hyperemia of, 150  
myosis, 150
- Spiral ganglion, 619, 620  
lamina, 619
- Spleen, diseases of, 421
- Sponge-grafting in orbit, 573
- Spongioblasts, 74
- Sprague's paracentesis instrument, 722
- Spray-apparatus, 882
- Spraying in chronic laryngitis, 1003
- Sprays, 882  
In chronic hypertrophic rhinitis, 909  
in laryngeal tuberculosis, 1050, 1052
- Spring catarrh, 287
- Spurs of nasal septum, 831
- Squama, development of, 622
- Squint. See *Strabismus*.
- Stacke's gouge, 799  
operation, 796, 798
- Stapedius muscle, 631  
tenotomy of, 788
- Stapes, excision of, 791  
function of, 638  
liberation of, in chronic catarrh of middle ear, 737, 738
- Staphylococci, 283, 288  
in corneal ulcers, 314
- Staphylococcus albus in oropharynx, 847  
aureus, 337, 349  
in acute lacunar tonsillitis, 923  
in oro-pharynx, 847  
in labyrinth, 767  
pyogenes albus, 286, 614b  
aureus, 286, 614b  
citreus, 614b
- Staphyloma, 170, 384  
ciliary, 330  
congenital, of cornea, 329  
of cornea, 323, 343  
treatment, 374  
operations for, 570  
partial, 279  
posterior, 181, 192, 214, 221, 330, 354, 475  
scleral, 361
- Static refraction, 138, 139
- Steam in diphtheria, 995
- Steam-disinfection in diphtheria, 1015
- Steam-inhalation in diphtheria, 1027  
in subglottic laryngitis, 988
- Stearate of zinc in laryngeal tuberculosis, 1050  
with alum in atrophic rhinitis, 963  
with boric acid in atrophic rhinitis, 963
- Steele's septum-forceps, 1192
- Stellwag's sign, 535
- Stenopaic slit, 208, 329, 331  
spectacles, 231
- Stenosis of larynx, 1139  
dilatation of, 1209  
of naso-pharynx, treatment, 1199  
of nostril, operation for, 1183
- Stereoscopic exercises, 101  
vision, loss of, 510
- Sternothyroid muscle in voice-production, 1173
- Stevens's classification of insufficiencies of ocular muscles, 161  
operation of tendon-shortening, 593  
operation of tenotomy, 589  
phorometer, 158
- Stillicidium lacrymarum. See *Epiphora*.
- Stilling, canal of. See *Hyaloid canal*.
- Stilling's pseudo-isochromatic plates, 604
- Stirrup-ankylosis, 660
- Stomodeum, 808
- Strabismus, 170, 211, 457, 504  
advancement in, 521  
alternating, 505  
angle of, 505  
circumvergent, 505, 519  
constant, 504  
convergent, 500, 505, 515  
a symptom of hyperopia, 216  
deorsumvergent, 505, 519  
divergent, 500, 505, 517  
in myopia, 265  
dynamic, 156  
insertional, 510  
intermittent, 504  
measurement of, 504  
with perimeter, 505  
paralytic, 510  
spastic, 510  
structural, 510  
tenotomy in, 521  
treatment, 520  
vertical, 518
- Strabismus-hooks, 595
- Strabometry, 504
- Stratfield-Snellen's operation of grooving the cartilage, 550
- Streptococcus in the labyrinth, 767  
pyogenes, 283, 291, 295, 614b  
in corneal ulcers, 314, 614b  
in oro-pharynx, 847
- Streptococcus-diphtheria of the conjunctiva, 614c
- Streptococcus-serum in malignant disease of nose, 1089, note
- Streptothrix Försteri, 265
- Stria vascularis, 619
- Striped keratitis, 325
- Strophanthus in diphtheria, 994
- Stroscheim's disks, 513
- Struma. See *Scrofula*.
- Strychnin in acute rhinitis, 893  
in acoustic neurasthenia, 781  
in anosmia, 1144  
in chronic catarrh of middle ear, 738  
in chronic laryngitis, 1004  
in chronic suppuration of middle ear, 746  
in diphtheria, 1020  
in insufficiencies of ocular muscles, 520  
in laryngeal tuberculosis, 1048  
in optic-nerve atrophy, 149
- Sturm's focal interval, 225
- Stye. See *Hordeolum*.
- Styloid process, 625
- Stylo-pharyngeus, 844
- Subconjunctival hemorrhage, 594  
injections in choroiditis, 355  
in corneal ulcers, 315  
in iritis, 342  
of germicides, 566

- Subconjunctival injections of physiologic salt solution, 566
- Subglottic laryngitis, 986  
chronic, 1008
- Subhyaloid hemorrhage, 421
- Subhyoid pharyngotomy, 1212
- Sublimated alcohol in furunculosis of ear, 686  
solution in injuries of drum-head, 713
- Subnitrate of bismuth in chronic rhinitis, 910  
in eczema of auricle, 693  
in laryngeal tuberculosis, 1050
- Sucking, 841
- Suction method of operating for cataract, 395
- Sulcus, sigmoid, 624
- Sulphate of atropin in acute inflammation of middle ear, 687  
of copper in chronic laryngitis, 1033  
in chronic subglottic laryngitis, 1009  
of iron in laryngeal tuberculosis, 1050  
of zinc in laryngeal tuberculosis, 1050  
in singers' nodes, 1105
- Sulphid of calcium, 244
- Sulphocarbonate of zinc in perforation of tympanic membrane, 688
- Sulphuric acid in chronic suppuration of the middle ear, 629
- Sulphurous acid disinfection in diphtheria, 1014
- Sunstroke, 438
- Suppuration after cataract-extraction, 583  
of ear, septic affections from, 761  
of middle ear, treatment, 689
- Suppurative tonsillitis, 925
- Supra-auricular region, examination of, 672
- Supra-choroidal lymph-space, 57
- Supraglottic laryngitis, 986
- Supraorbital nerve, 37
- Surfaces, astigmatic, 126
- Sursunduction, 157. See also *Sursunvergenze*.
- Sursunvergenze, 157, 500, 503
- Sursunversion, 501
- Suspensory folds of drum-membrane, 628
- Sutures, 512
- Sycosis tarsi, 245
- Symphylarion, 256, 303, 359  
congenital, 241  
due to trachoma, 563  
operations for, 562
- Symmetrical changes at macula lutea in infancy, 423
- Sympathetic, cervical, effect of irritation of, on pupil, 150  
choroido-nitis, 348  
irido-exetitis, 348  
inflammation. See *Sympathetic ophthalmitis*.  
itis, 348  
irritation, 348  
nerve, 97
- Sympathetic ophthalmitis, 347, 366  
after cataract-extraction, 583  
caused by operations on eye, 347  
operations during, 351  
pathogenesis, 349  
prophylactic treatment, 350  
symptoms, 348  
treatment, 350  
papillo-retinitis, 348  
retinitis, 414  
vibration, 636
- Synchysis corporis vitrei, 401  
scintillans, 401
- Syncope, laryngeal, 1159
- Syndectomy, 566
- Synechia of nasal passages, removal of, 1195
- Synechia, 118, 315, 332  
anterior, 355  
detachment of, 579  
posterior, 336, 343  
detachment of, 579  
total posterior, 336, 343
- Synechia-knives, 790
- Synechiotomy, 579
- Synovitis of knee-joint in interstitial keratitis, 319
- Syphilides of conjunctiva, 300
- Syphilis, 243, 246, 261, 266, 310, 319, 352, 391, 399, 413, 414, 420, 427, 437, 461, 477, 511, 526  
iritis from, 338  
of air-passages, 1067  
of auricle, 695  
treatment, 686  
of conjunctiva, 300  
of drum-head, 714  
of external auditory canal, 707  
of eyelids, 247  
of internal ear, treatment, 690  
of labyrinth, pathology, 664  
of lachrymal glands, 263  
of lachrymal sac, 269  
of larynx, 1071  
treatment, 1073  
of lungs, 1073  
of maxillary sinus, 976  
of nose, 1067  
treatment, 1073  
of pharynx, 1069  
treatment, 1073  
of throat, general treatment, 876  
of trachea, 1073  
otitis media from, 718  
relation of, to ear-disease, 654
- Syringe, antitoxin, 1025, 1026  
ear, 674  
for impacted cerumen, 700
- Syringomyelia, 477
- System, centered optical, 114
- Systems, combined, of optical surfaces, 115
- TABES DORSALIS. See *Locomotor ataxia*.
- Tagliacotian method of rhinoplasty, 1186
- Tampons in atrophic rhinitis, 885, 964
- Tannic acid in epistaxis, 903  
in laryngeal tuberculosis, 1050, 1052
- Tannin in acute catarrhal laryngitis, 986  
in atrophic rhinitis, 964  
in chronic laryngitis, 1003  
in chronic rhinitis, 910  
in lingual tonsillitis, 927
- Tannogen in laryngeal tuberculosis, 1051
- Tapetum cellulorum, 59  
fibrosum, 59
- Tarsal asthenopia, 140  
cartilage. See *Tarsus*, glands. See *Meibomian*, tumor. See *Chalazion*.
- Tarsitis, 252  
syphilitic, 252
- Tarsorrhaphy, 536, 538, 547
- Tarsus, 33
- Tattooing of cornea, 323, 568
- Tea, 459
- Teale's operation for symblepharon, 562, 563
- Tectorial membrane, function of, 614
- Telangiectatic tumors of conjunctiva, 300
- Temperature in diphtheria, 1017
- Temporal bone, anatomy of, 622  
osteophlebitis of, 761
- Tenderness in brain-abscess, 763
- Tenon, capsule of, 43  
space of, 43, 54, 87
- Tenonitis, 529
- Tenon's capsule, hemorrhage into, 537  
after tenotomy, 594
- Tenotomy, accidents and complications of, 594  
complete, 587  
graduated, 589  
in insufficiencies of ocular muscles, 521  
of externus, 588  
of internus, 587  
of stapedius, 788  
of superior and inferior rectus, 589  
of tensor tympani muscle, 788  
partial, 589  
subconjunctival, 587
- Tension, 170, 373  
normal intraocular, 219  
symbols for, 170
- Tensor choroidea, 60, 134
- Tensor palati, 631, 810  
tarsi, 47  
tympani muscle, function of, 637  
tenotomy of, 788
- Tensors of vocal cords, paralysis of, 1168
- Test, Bing's, 672  
Gelle's, 672  
Rinné's, 670  
Schwabach's, 670  
Weber's, 670
- Test-card, 151
- Test-types, 151  
Dennett's, 140  
for illiterate, 152  
Jaeger's, 137  
Monoyer's, 140  
Randall's, 151

- Test-types, Snellen's 139, 140  
 Tests of hearing, 668  
 Tetanus, 572  
 Thalamecephalon, 19  
 Theobald's knife, 703  
 Iachrymal probes, 270  
 Therapeutics of ear-disease, 681  
 Thermocautery in lupus of auricle, 686  
 Thiersch grafts, 243, 372, **553**  
   in symblepharon, 563  
 Third nerve. See *Oculo-motor nerve*.  
   ventricle, 19  
 Thomson's ametro-meter, 207  
   method for color-blindness, 604  
   test for color-blindness, 151  
 Throat and nose, rheumatic conditions of, 874  
   examination of, 864  
   fatigue of, 876  
   hysteria of, 1169  
   neuralgia of, treatment, 876  
   paralysis of, 877  
   physiology of, 841  
   syphilis of, general treatment, 876  
 Thrombosis of brain-sinuses, 150, 436, 759, 801  
   of cavernous sinus, 529  
   of central artery of retina, 408  
   of central vein of retina, 421  
   of orbital veins, 355  
   of retinal veins, 410, 444  
   of umbilical veins, 355  
 Thymol in atrophic rhinitis, 963  
 Thyro-arytenoid ligaments, 820  
 Thyro-arytenoid muscles, 822  
   in voice-production, 1173  
 Thyro-arytenoidei interni, paralysis of, 1169  
 Thyro-epiglottic ligament, 819  
 Thyro-hyoid ligaments, lateral, 819  
   membrane, 819  
   muscle in voice-production, 1173  
 Thyroid arteries, 823  
   cartilage, 816  
 Thyrotomy, 1209, 1212  
 Timbre, 635  
 Tincture of chlorid of iron in chronic myringitis, 711  
   in diphtheria, 994  
   in erysipelas of nose, 902  
   in lupus laryngitis, 1066  
   in membranous rhinitis, 898  
   in new growths of drum-head, 714  
   of iodin in perichondritis of auricle, 695  
 Tinea tarsi, 245  
 Tinnitus as a symptom, 666  
   in acute otitis media, 749  
   in chronic catarrh of middle ear, 730  
   nervous, 777  
 Tip of nose, restoration of, 1187  
 Tobacco, 441, 448, 459  
   effect of, on the ear, 654  
   in affections of upper air-passages, 881  
 Tobacco-amblyopia, 460  
 Tongue-depressors, 864, 865  
 Tonometer, 170, 373  
 Tonsil, calculi of, 935  
 Tonsil, faucial, 815, 921  
   pathology of, 850  
   polypoid hypertrophy of, 935  
   removal of, 1202, 1204  
   foreign bodies in, 936  
   lingual, 815  
   operations on, 1206  
   pharyngeal, 815  
   supernumerary, 1097  
 Tonsillar abscess, chronic encysted, 935  
   inflammations, acute, 922  
   chronic, 928  
   ring, 921  
 Tonsillitis, acute croupous, 925  
   acute lacunar, 922  
   acute parenchymatous, 923  
   acute ulcerative, 927  
   chronic, due to bacillus coli communis, 929  
   chronic lacunar, 928  
   chronic lingual, 932  
   chronic parenchymatous, 929  
   lingual, 926  
   suppurative, 925  
 Tonsillitis-tablets, 886, 924  
 Tonsillotome, Roe's lingual, 1206  
 Tonsillotomy, 1204  
   in chronic inflammation of lingual tonsil, 934  
   in chronic parenchymatous tonsillitis, 931  
   in pharyngo-mycosis, 946  
 Tonsils, carcinoma of, 1101  
   diseases of, 921  
   hypertrophied, galvano-cautery in, 888  
   physiology of, 842  
   sarcoma of, 1100  
   structure of, 921  
 Toric lenses, 126  
 Torsion, inward, 497  
   of eye, 100  
 Torsion-diplopia, 500  
 Torsion-movement, 498, foot-note  
 Torus, 126  
 Total reflection, 132  
 Toxic conjunctivitis, 295  
 Toxicants and ear-disease, 654  
 Trachea, acute affections of, 985  
   anatomy of, 824  
   carcinoma of, 1115  
   chronic affections of, 1009  
   development of, 809  
   ectochondrosis of, 1115  
   fibroma of, 1115  
   foreign bodies in, 1129  
   in voice-production, 1174  
   neoplasms of, 1115  
   papilloma of, 1115  
   polypi of, 1115  
   syphilis of, 1073  
 Tracheitis, acute catarrhal, 996  
 Tracheotomy, 1209  
   in diphtheria, 1031  
 Trachoma, 257, 258, **289**, 308  
   acute, 290  
   chronic, 290  
   corneal complications in, 290, 291  
   description of stages of, 290  
   diagnosis, 292, 293  
 Trachoma, duration, 291  
   etiology, 292  
   excision of cul de sac for relief of, 565  
   follicular, 290  
   geographical distribution of, 292  
   operation of expression for, 564  
   operations for, 563  
   pathology, 292  
   prognosis, 293  
   racial distribution of, 292  
   treatment, 293  
 Trachoma-bodies, 290  
 Trachoma-coccus, 292, 644c  
 Trachoma-glands, 35  
 Traction-hook for foreign bodies in ear, 702  
 Tractus, 479  
 Tragicus muscle, 636  
 Traitement par morcellement, 931  
 Transillumination of larynx, 872  
   of maxillary antrum, 862  
 Transmitted light, examination of media by, 178  
 Transverse sinus, 624  
 Transversus muscle, 637  
 Traumatic epistaxis, 903  
 Trial-case, 207  
 Triangular cartilage, 830  
   fracture of, 1124  
 Trichiasis, 246, **257**, 293, 308  
   operations for, 518  
   treatment, 257  
 Trichloracetic acid, 887  
   in acute follicular pharyngitis, 943  
   in atrophic rhinitis, 961  
   in chronic myringitis, 714  
   in new growths of drum-head, 714  
 Trichlorid of iodine, 510  
 Trichosis of carnule, 271, 304  
 Trigemini nerve, 245, 254  
 Trochæ, 885  
 Trochlea of tensor tympani, 631  
 Trochlear nerve, paralysis of, 511, 513  
 Trochlearis. See *Oblique superior*.  
 Tropacocain, 543  
 Tropometer, 170  
 Trypsin in diphtheria, 994  
 Tscherning's theory of accommodation, 135  
 Tubal cell, 632  
 Tube, cochlear, 617  
 Tubercle-bacillus, 302, 356, 644b, 1034  
   in lupus laryngitis, 1062  
   in lupus of air-passages, 1059  
   in nasal passages, 1053  
 Tubercle impar, 809  
 Tuberculin in tuberculosis of larynx, 1047  
 Tuberculosis, 246, 319, 339  
   of choroid, 356  
   of conjunctiva, 302  
   of cornea, 318  
   of iris, 340  
   of lachrymal passages, 269  
   of larynx, 1034, 1108  
   diagnosis, 1044  
   etiology, 1034



- Tuberculosis of larynx, formula-  
 lary in 1052  
 pathological anatomy, 1037  
 predisposing causes, 1037  
 prognosis and course, 1045  
 symptoms, 1038  
 treatment, 1046  
 of nasal passages, 1053  
 treatment, 1057  
 of optic nerve, 450  
 of pharynx, 1055  
 treatment, 1057  
 relation of, to ear-disease, 653  
 with suppuration of middle  
 ear, 662
- Tubo-tympanic cavity, 626
- Tumor, intraocular, 170  
 of brain. See *Brain, tumor*  
*of.*
- Tumors, dermoid, of conjunc-  
 tiva, 274  
 intraocular, 318  
 of acoustic nerve, 769  
 of antrum, 1090  
 of brain. See *Brain-tumors.*  
 of cerebellum, 520  
 of ethmoid sinuses, 1090  
 of eyelids, 248  
 of frontal sinuses, 1090  
 of maxillary sinus, 975, 1089  
 of naso-pharynx, 1091  
 of nose, 1076  
 of optic nerve, 449  
 of orbit, 255  
 of trachea, 1115
- Tuning-fork, Dench's, 669
- Tuning-forks in testing hear-  
 ing, 669
- Turbinal bone, abscess of, evacu-  
 ation of, 1198  
 development of, 808  
 examination of, 860  
 varix, 1080
- Turbinals, hypertrophy of,  
 treatment, 912, 911
- Turbinated bones, clinical anat-  
 omy of, 828, 829  
 deformities of, operations  
 for, 1191  
 hypertrophy of, treatment,  
 1191
- Türk's tongue-depressor, 861
- Tympanic cavity, acute affec-  
 tions of, 715  
 deafness in, 716  
 pain in, 715  
 treatment, 720  
 pathology of, 659  
 inflammation, complications  
 of, 719  
 pachymeningitis externa  
 in, 756  
 membrane, 629. See also  
*Drumhead.*  
 changes in color of, 676  
 changes in position of, 676  
 examination of, 676  
 loss of substance of, 677  
 opacity of, 676  
 otoscopic appearances of,  
 676  
 pathology, 658  
 perforation of, treatment,  
 688  
 perforations of, 677  
 physiology of, 637  
 of, 619
- Tympanic suppuration, excision  
 of conducting mechanism  
 for, 789
- Tympano-mastoid exenteration,  
 796
- Tympanotomy, exploratory, 739
- Tympanum, 627. See *Tympanic*  
*cavity* and *Middle ear.*  
 granulations of, removal of,  
 792  
 opening of, through skull, 803  
 operations on, 786  
 instruments for, 790  
 polypi of, removal of, 792
- Typhoid fever, 339, 391, 436,  
 528  
 middle-ear disease from,  
 717  
 relation of, to ear-disease,  
 652
- Typhus fever, 339, 355, 436, 528
- Tyrrill's hook, 577
- ULCER of cornea, 145, 245, 279,  
 293, 313, 527, 614c. See  
 also *Cornea, ulcer of.*  
 in purulent conjunctivitis,  
 316  
 in small-pox, 317  
 micro-organisms in, 314  
 phlyctenular, 307  
 relation of micro-organisms  
 to transparent, 309  
 of eyelids, 243
- Ulcerative tonsillitis, acute, 927.  
 See *Tonsillitis.*
- Ulcers of cornea, 245, 313
- Umbilical veins, thromboses of,  
 355
- Umbo, 637
- Uncinate process of ethmoid,  
 underlying conus, 194
- Unilateral abductor paralysis,  
 1167
- Upper air-passages, anatomy of,  
 807  
 general etiology and pathol-  
 ogy of, 844  
 neoplasms of, 1075  
 physiology of, 835
- Uterine disease, 410
- Utricle, development of, 617,  
 618
- Uveal tract, 55
- Uveitis, anterior, 320  
 metastatic, 495
- Uvula, diseases of, 937  
 enlarged, 938  
 inflammation of, 937  
 in voice-production, 1176  
 malformations of, 937  
 physiology of, 843  
 papilloma of, 1095
- Uvulitis, 937
- Uvulotomy, 1207
- VACCINE blepharitis, 244
- Vagus nerve, lesions of, in  
 laryngeal paralysis, 11,  
 66
- Valsalva's method of inflation,  
 681
- Valve of Hasner, 48
- Vapors, 883
- Variola, 244, 269, 275, 339,  
 436
- Varix, lingual, 931
- Vascular neoplasm of nasal  
 septum, 1079  
 system, relation of, to ear-  
 disease, 649
- Vaselin in frost-bite of auricle,  
 696
- Vegetations, adenoid, 952. See  
*Lymphoid hypertrophy.*
- Vein, mastoid emissary, 624
- Veins, ciliary, 87  
 of pharynx, 814
- Vene vorticiosa, 58, 87
- Venous pulsation in glaucoma,  
 374
- Ventilation, function of nose  
 in, 840  
 in affections of upper air-  
 passages, 879
- Ventricle of larynx, 820
- Ventricular bands, 816, 820
- Vernal conjunctivitis. See *Con-*  
*junctivitis, vernal.*
- Verrucosities, 451
- Vertigo, 509  
 as a symptom of ear-disease,  
 667  
 in brain-abscess, 763  
 in chronic catarrh of middle  
 ear, 729  
 laryngeal, 1159
- Vesicle, lens, 20  
 optic, retinal layer of, 21  
 otic, 617  
 secondary optic, 20
- Vesicles, primary cerebral, 18,  
 19  
 secondary cerebral, 19
- Vestibular aqueduct, 623  
 scala, 619, 620
- Vicarious epistaxis, 902
- Vidian artery, 814
- Vienna mask, 612  
 method of enucleation, 571  
 paste, 597
- Virtual focus of concave lens,  
 124  
 images, 124
- Visceral arches, cephalic, 809  
 clefts, cephalic, 809
- Vision, absolute, field of, 166  
 amblyopia of field of, 470  
 anomalies of field of, 472  
 binocular, 230  
 field of, 167, 471  
 binocular single, 156, 499  
 changes in field of, due to op-  
 tic hindrance, 473  
 changes in field of, in affec-  
 tions of optic nerve, 476  
 changes in field of, in dis-  
 eases of choroid, 475  
 changes in field of, in dis-  
 eases of retina, 473  
 color-field of, 167  
 contraction of field of, 472  
 direct, 162  
 disturbances of, without oph-  
 thalmoscopic change, 457  
 effect of refraction on size of  
 field of, 166  
 false projection of field of,  
 509  
 field of, 162, 470  
 field of binocular single, 502  
 field of, in glaucoma, 379, 476  
 in optic-nerve atrophy, 446,  
 447

- Vision, formula for, 151  
 general physiology of, 88  
 indirect, 162  
 line of, 128  
 minimal field of, 166  
 monocular, from suppression of image, 499  
 of astigmatic eyes, 224  
 of colors, measurement of, 153  
 of peripheral parts of retina, 168  
 relative, field of, 166  
 size of field of, 165  
 standard required in railway service, 608  
 stereoscopic, loss of, 510  
 testing acuteness of, 151
- Visual acuity, 138  
 formula for, 140  
 methods of measuring, 140  
 angle, 138, 139  
 axis, 96, 100  
 cells, 25  
 field. See *Vision, field of*.  
 ganglia, primary, 479  
 line, 100  
 pathway, 478  
 purple, 66, 69, 88, 98  
 radiations, 479
- Vitiligoidea, 248
- Vitreous, 82, 89  
 artificial, 572  
 blood-vessel formation in, 402  
 body, development of, 28  
 cells of, 83  
 chamber, primitive, 21  
 cholesterolin-crystals in, 401  
 detachment of, 403  
 direct galvanization of, 401  
 diseases of, 391, 398  
 entozoa in, 402  
 fatty degeneration of, 403  
 fluidity of, 401  
 foreign bodies in, 369  
 hemorrhage into, 401  
 humor, transplantation of rabbits', 430  
 index of refraction of, 89, 92  
 inflammation of. See *Hypertitis*.  
 location of opacity in, by refraction of eye, 178, 201  
 membrane. See *Lamina vitrea*.  
 migratory leukocytes of, 83
- Vitreous, opacities in, 214, 222, 377, 399  
 spontaneous hemorrhage into, 401  
 spontaneous inflammation of, 398
- Vocal cords, examination of, 871  
 false, 816, 820  
 in voice-production, 1172  
 paralysis of abductors of, 1167  
 paralysis of tensors and adjustors of, 1168  
 true, 816, 820  
 processes of arytenoid, 818
- Voice, hygiene of, 1177  
 in chronic laryngitis, 1000  
 in laryngeal affections, 852  
 in nasal disease, 852  
 production and hygiene of, 1171
- Voice-formation, 843
- Voice-production, 1171  
 resonators in, 1174
- Voice-training, 1178
- Vomer, 825, 830  
 fracture of, 1124
- Von Hippel's operation for transplanting cornea, 569
- Von Tröltzsch plan for gargling, 940
- WARTS. See *Papilloma*.  
 Watered-silk reflections, 182
- Wave-length, 634
- Weber's canaliculus-knife, 270  
 test, 670  
 in chronic catarrh of middle ear, 732
- Weeks' bacillus, 276, 281, 614a
- Weiss's reflex, 182, 188
- Wernicke's symptom, 480
- Whiskey in diphtheria, 994, 1020
- White's palate-retractor, 869
- Whooping-cough, 436, 511  
 otitis media from, 718
- Wilder's operation for ptosis, 558
- Williams's antitoxin-syringe, 1025
- Wire snare in hypertrophic rhinitis, 912
- Wolfe's method of grafting a skin-flap without a pedicle, 553
- Wolffberg's test-pictures, 152
- Wood's operation for ptosis, 559
- Wood's operation, 1188
- Word-blindness in brain-abscess, 763
- Word-deafness, 776  
 in brain-abscess, 763
- Wounds of auricle, 697  
 treatment, 783  
 of external auditory canal, 708  
 of nose, 116  
 treatment, 1118
- Wrisberg's cartilage, 816, 818
- XANTHELASMA, 218
- Xanthoma, 218
- Xanthopsia, 468
- Xerophthalmia, 468
- Xerophthalmos. See *Xerosis*.
- Xerosis, 291  
 bacillus of, 296, 614b  
 conjunctiva, 296, 318
- Xerostomia, 936
- X-rays. See *Röntgen rays*.  
 location of foreign bodies in eye by, 607  
 location of foreign bodies in larynx by, 873
- YELLOW oxid of mercury in eczema of auricle, 693  
 in furuncle of external auditory canal, 703  
 ointment of, 247, 250, 307, 322  
 spots. See *Macula lutea*.
- Yellow-vision, 468
- ZINC chlorid in lupus of pharynx, 1059  
 solution in acute ulcerative tonsillitis, 928  
 salts in chronic catarrhal pharyngitis, 941
- Zinn, circle of, 54  
 zone of, 49, 80, 84, 85
- Zonula, rupture of, 365
- Zottenkrebs, 1086
- Zwaardemaker's olfactometer, 858
- Zygomatic process, development of, 622



CATALOGUE  
OF THE  
MEDICAL PUBLICATIONS

OF  
W. B. SAUNDERS & CO.,  
No. 925 WALNUT STREET, PHILADELPHIA.

Arranged Alphabetically and Classified under Subjects.

THE books advertised in this Catalogue as being *sold by subscription* are usually to be obtained from travelling solicitors, but they will be sent direct from the office of publication (charges of shipment prepaid) upon receipt of the prices given. All the other books advertised are commonly for sale by booksellers in all parts of the United States; but books will be sent to any address, carriage prepaid, on receipt of the published price.

Money may be sent at the risk of the publisher in either of the following ways: A post-office money order, an express money order, a bank check, and in a registered letter. Money sent in any other way is at the risk of the sender.

See pages 32, 33 for a List of Contents classified according to subjects.

---

---

## LATEST PUBLICATIONS.

- American Students' Medical Dictionary. See page 34.  
American Text-Book of Physiology—Second (Revised) Ed. Page 7.  
Friedrich and Curtis on Nose, Throat, and Ear. See page 34.  
Le Roy's Histology. See page 34.  
Ogden on the Urine. See page 34.  
Pyle's Personal Hygiene. See page 34.  
Salinger and Kalteyer's Modern Medicine. See page 34.  
Stoney's Surgical Technic for Nurses. See page 34.  
Hyde and Montgomery's Syphilis and Venereal Diseases—Revised and Enlarged Edition. See page 15.  
International Text-Book of Surgery. See page 15.  
Garrigues' Diseases of Women—Third (Revised) Edition. Page 13.  
American Text-Book of Dis. of Eye, Ear, Nose, and Throat. Page 5.  
Saunders' American Year-Book for 1900. See page 8.  
Levy and Klemperer's Clinical Bacteriology. See page 17.  
Scudder's Treatment of Fractures. See page 26.  
Senn's Tumors—Second Edition. See page 27.  
Beck on Fractures. See page 9.  
Watson's Handbook for Nurses. See page 31.  
Heisler's Embryology. See page 15.  
Nancrede's Principles of Surgery. See page 20.  
Jackson's Diseases of the Eye. See page 16.  
Kyle on the Nose and Throat. See page 17.  
Penrose's Diseases of Women—Third (Revised) Edition. Page 20.  
Warren's Surgical Pathology—Second (Revised) Edition. Page 31.  
Saunders' Medical Hand-Atlases. See pages 2, 3, 4.  
American Pocket Medical Dictionary—Third (Revised) Ed. Page 12.



# SAUNDERS'

## MEDICAL HAND-ATLASES.

---

THE series of books included under this title consists of authorized translations into English of the world-famous **Lehmann Medicinische Handatlanten**, which for **scientific accuracy, pictorial beauty, compactness, and cheapness** surpass any similar volumes ever published. Each volume contains from **50 to 100 colored plates**, executed by the most skilful German lithographers, besides numerous illustrations in the text. There is a full and appropriate **description of each plate**, and each book contains a condensed but adequate **outline of the subject** to which it is devoted.

One of the most valuable features of these atlases is that they offer a **ready and satisfactory substitute for clinical observation**. To those unable to attend important clinics these books will be absolutely indispensable.

In planning this series of books arrangements were made with the representative publishers in the chief medical centers of the world for the publication of translations of the atlases into different languages, the lithographic plates for all these editions being made in Germany, where work of this kind has been brought to the greatest perfection. The expense of making the plates being shared by the various publishers, the cost to each one was materially reduced. Thus by reason of their **universal translation** and reproduction, the publishers have been enabled to secure for these atlases the **best artistic and professional talent**, to produce them in the **most elegant style**, and yet to offer them at a **price heretofore unapproached in cheapness**. The success of the undertaking is demonstrated by the fact that the volumes have already appeared in **thirteen different languages**—German, English, French, Italian, Russian, Spanish, Japanese, Dutch, Danish, Swedish, Roumanian, Bohemian, and Hungarian.

In view of the striking success of these works, Mr. Saunders has contracted with the publisher of the original German edition for **one hundred thousand copies** of the atlases. In consideration of this enormous undertaking, the publisher has been enabled to prepare and furnish special additional colored plates, making the series even **handsomer and more complete** than was originally intended.

As an indication of the practical value of the atlases and of the favor with which they have been received, it should be noted that the **Medical Department of the U.S. Army** has adopted the "Atlas of Operative Surgery" as its standard, and has ordered the book in large quantities for distribution to the various regiments and army posts.

The same careful and competent **editorial supervision** has been secured in the English edition as in the originals, the translations being edited by the leading **American specialists** in the different subjects.

# SAUNDERS' MEDICAL HAND-ATLASES.

VOLUMES NOW READY.

## **Atlas and Epitome of Internal Medicine and Clinical Diagnosis.**

By DR. CHR. JAKOB, of Erlangen. Edited by AUGUSTUS A. ESHNER, M.D., Professor of Clinical Medicine, Philadelphia Polyclinic. With 68 colored plates, 64 text-illustrations, and 259 pages of text. Cloth, \$3.00 net.

"The charm of the book is its clearness, conciseness, and the accuracy and beauty of its illustrations. It deals with facts. It vividly illustrates those facts. It is a scientific work put together for ready reference."—*Brooklyn Medical Journal*.

## **Atlas of Legal Medicine.**

By DR. E. R. VON HOFMANN, of Vienna. Edited by FREDERICK PETERSON, M.D., Chief of Clinic, Nervous Dept., College of Physicians and Surgeons, New York. With 120 colored figures on 56 plates, and 193 beautiful half-tone illustrations. Cloth, \$3.50 net.

"Hofmann's 'Atlas of Legal Medicine' is a unique work. This immense field finds in this book a pictorial presentation that far excels anything with which we are familiar in any other work."—*Philadelphia Medical Journal*.

## **Atlas and Epitome of Diseases of the Larynx.**

By DR. L. GRUNWALD, of Munich. Edited by CHARLES P. GRAYSON, M.D., Physician-in-Charge, Throat and Nose Department, Hospital of the University of Pennsylvania. With 107 colored figures on 44 plates, 25 text-illustrations, and 103 pages of text. Cloth, \$2.50 net.

"Aided as it is by magnificently executed illustrations in color, it cannot fail of being of the greatest advantage to students, general practitioners, and expert laryngologists."—*St. Louis Medical and Surgical Journal*.

## **Atlas and Epitome of Operative Surgery.**

By DR. O. ZUCKERKANDL, of Vienna. Edited by J. CHALMERS DACOSTA, M.D., Professor of Practice of Surgery and Clinical Surgery, Jefferson Medical College, Philadelphia. With 24 colored plates, 217 text-illustrations, and 395 pages of text. Cloth, \$3.00 net.

"We know of no other work that combines such a wealth of beautiful illustrations with clearness and conciseness of language, that is so entirely abreast of the latest achievements, and so useful both for the beginner and for one who wishes to increase his knowledge of operative surgery."—*Munchener medicinische Wochenschrift*.

## **Atlas and Epitome of Syphilis and the Venereal Diseases.**

By PROF. DR. FRANZ MRACEK, of Vienna. Edited by L. BOLTON BANGS, M.D., Professor of Genito-Urinary Surgery, University and Bellevue Hospital Medical College, New York. With 71 colored plates, 16 black-and-white illustrations, and 122 pages of text. Cloth, \$3.50 net.

"A glance through the book is almost like actual attendance upon a famous clinic."—*Journal of the American Medical Association*.

## **Atlas and Epitome of External Diseases of the Eye.**

By DR. O. HAAB, of Zurich. Edited by G. E. DE SCHWEINITZ, M.D., Professor of Ophthalmology, Jefferson Medical College, Philadelphia. With 76 colored illustrations on 40 plates, and 228 pages of text. Cloth, \$3.00 net.

"It is always difficult to represent pathological appearances in colored plates, but this work seems to have overcome these difficulties, and the plates, with one or two exceptions, are absolutely satisfactory."—*Boston Medical and Surgical Journal*.

## **Atlas and Epitome of Skin Diseases.**

By PROF. DR. FRANZ MRACEK, of Vienna. Edited by HENRY W. STELWAGON, M.D., Clinical Professor of Dermatology, Jefferson Medical College, Philadelphia. With 63 colored plates, 39 half-tone illustrations, and 200 pages of text. Cloth, \$3.50 net.

"The importance of personal inspection of cases in the study of cutaneous diseases is readily appreciated, and next to the living subjects are pictures which will show the appearance of the disease under consideration. Altogether the work will be found of very great value to the general practitioner."—*Journal of the American Medical Association*.

## SAUNDERS' MEDICAL HAND-ATLASES.

### VOLUMES JUST ISSUED.

- Atlas and Epitome of Special Pathological Histology.** By DR. H. DÜRCK, of Munich. Edited by LUDVIG HEKTOEN, M. D., Professor of Pathology, Rush Medical College, Chicago. In Two Parts. Part I. *Just Ready*, including the Circulatory, Respiratory, and Gastro-intestinal Tract, with 120 colored figures on 62 plates and 158 pages of text. Price, \$3.00 net. Parts sold separately.
- Atlas and Epitome of Diseases Caused by Accidents.** By DR. ED. GOLEBIEWSKI, of Berlin. Translated and edited with additions by PEARCE BAILEY, M. D., Attending Physician to the Department of Corrections and to the Almshouse and Incurable Hospitals, New York. With 40 colored plates, 143 text-illustrations, and 600 pages of text.
- Atlas and Epitome of Gynecology.** By DR. O. SCHÄFFER, of Heidelberg. Edited by RICHARD C. NORRIS, A. M., M. D., Gynecologist to the Methodist Episcopal and the Philadelphia Hospitals; Surgeon-in-Charge of Preston Retreat, Philadelphia. With 90 colored plates, 65 text-illustrations, and 308 pages of text.

### IN PRESS FOR EARLY PUBLICATION.

- Atlas and Epitome of Obstetrical Diagnosis and Treatment.** By DR. O. SCHÄFFER, of Heidelberg. Edited by J. CLIFTON EDGAR, M. D., Professor of Obstetrics and Clinical Midwifery, Cornell University Medical School. 72 colored plates, numerous text-illustrations, and copious text.
- Atlas and Epitome of the Nervous System and its Diseases.** By PROF. DR. A. VON STRÜMPPELL, of Erlangen. Edited by EDWARD D. FISHER, M. D., Professor of Diseases of the Nervous System, University and Bellevue Hospital Medical College, New York. 83 plates and a copious text.
- Atlas and Epitome of General Pathological Histology.** With an Appendix on Pathohistological Technic. By DR. H. DÜRCK, of Munich. Edited by LUDVIG HEKTOEN, M. D., Professor of Pathology, Rush Medical College, Chicago. With 80 colored plates, numerous text-illustrations, and copious text.

### IN PREPARATION.

- Atlas and Epitome of Orthopedic Surgery.**  
**Atlas and Epitome of Operative Gynecology.**  
**Atlas and Epitome of Diseases of the Ear.**  
**Atlas and Epitome of General Surgery.**  
**Atlas and Epitome of Psychiatry.**  
**Atlas and Epitome of Normal Histology.**  
**Atlas and Epitome of Topographical Anatomy.**



THE AMERICAN TEXT-BOOK SERIES.

### AN AMERICAN TEXT-BOOK OF APPLIED THERAPEUTICS.

By 43 Distinguished Practitioners and Teachers. Edited by JAMES C. WILSON, M.D., Professor of the Practice of Medicine and of Clinical Medicine in the Jefferson Medical College, Philadelphia. One handsome imperial octavo volume of 1326 pages. Illustrated. Cloth, \$7.00 net; Sheep or Half Morocco, \$8.00 net. *Sold by Subscription.*

“As a work either for study or reference it will be of great value to the practitioner, as it is virtually an exposition of such clinical therapeutics as experience has taught to be of the most value. Taking it all in all, no recent publication on therapeutics can be compared with this one in practical value to the working physician.”—*Chicago Clinical Review.*

“The whole field of medicine has been well covered. The work is thoroughly practical, and while it is intended for practitioners and students, it is a better book for the general practitioner than for the student. The young practitioner especially will find it extremely suggestive and helpful.”—*The Indian Lancet.*

### AN AMERICAN TEXT-BOOK OF THE DISEASES OF CHILDREN. Second Edition, Revised.

By 65 Eminent Contributors. Edited by LOUIS STARR, M. D., Consulting Pediatricist to the Maternity Hospital, etc.; assisted by THOMPSON S. WESTCOTT, M. D., Attending Physician to the Dispensary for Diseases of Children, Hospital of the University of Pennsylvania. In one handsome imperial octavo volume of 1244 pages, profusely illustrated. Cloth, \$7.00 net; Sheep or Half Morocco, \$8.00 net. *Sold by Subscription.*

“This is far and away the best text-book on children’s diseases ever published in the English language, and is certainly the one which is best adapted to American readers. We congratulate the editor upon the result of his work, and heartily commend it to the attention of every student and practitioner.”—*American Journal of the Medical Sciences.*

### AN AMERICAN TEXT-BOOK OF DISEASES OF THE EYE, EAR, NOSE, AND THROAT.

By 58 Prominent Specialists. Edited by G. E. DE SCHWEINITZ, M. D., Professor of Ophthalmology in the Jefferson Medical College, Philadelphia; and B. ALEXANDER RANDALL, M. D., Professor of Diseases of the Ear in the University of Pennsylvania. Imperial octavo, 1251 pages; 766 illustrations, 59 of them in colors. Cloth, \$7.00 net; Sheep or Half Morocco, \$8.00 net. *Sold by Subscription.*

Illustrated Catalogue of the “American Text-Books” sent free upon application.



**AN AMERICAN TEXT-BOOK OF GENITO-URINARY AND SKIN DISEASES.**

By 47 Eminent Specialists and Teachers. Edited by L. BOLTON BANGS, M. D., Professor of Genito-Urinary Surgery, University and Bellevue Hospital Medical College, New York; and W. A. HARD-AWAY, M. D., Professor of Diseases of the Skin, Missouri Medical College. Imperial octavo volume of 1229 pages, with 300 engravings and 20 full-page colored plates. Cloth, \$7.00 net; Sheep or Half Morocco, \$8.00 net. *Sold by Subscription.*

"This volume is one of the best yet issued of the publisher's series of 'American Text-Books.' The list of contributors represents an extraordinary array of talent and extended experience. The book will easily take the place in comprehensiveness and value of the half dozen or more costly works on these subjects which have heretofore been necessary to a well-equipped library."—*New York Polyclinic.*

**AN AMERICAN TEXT-BOOK OF GYNECOLOGY, MEDICAL AND SURGICAL. Second Edition, Revised.**

By 10 of the Leading Gynecologists of America. Edited by J. M. BALDY, M. D., Professor of Gynecology in the Philadelphia Polyclinic, etc. Handsome imperial octavo volume of 718 pages, with 341 illustrations in the text, and 38 colored and half-tone plates. Cloth, \$6.00 net; Sheep or Half Morocco, \$7.00 net. *Sold by Subscription.*

"It is practical from beginning to end. Its descriptions of conditions, its recommendations for treatment, and above all the necessary technique of different operations, are clearly and admirably presented. . . . It is well up to the most advanced views of the day, and embodies all the essential points of advanced American gynecology. It is destined to make and hold a place in gynecological literature which will be peculiarly its own."—*Medical Record*, New York.

**AN AMERICAN TEXT-BOOK OF LEGAL MEDICINE AND TOXICOLOGY.**

Edited by FREDERICK PETERSON, M. D., Clinical Professor of Mental Diseases in the Woman's Medical College, New York; Chief of Clinic, Nervous Department, College of Physicians and Surgeons, New York; and WALTER S. HAINES, M. D., Professor of Chemistry, Pharmacy, and Toxicology in Rush Medical College, Chicago. *In Preparation.*

**AN AMERICAN TEXT-BOOK OF OBSTETRICS.**

By 15 Eminent American Obstetricians. Edited by RICHARD C. NORRIS, M. D.; Art Editor, ROBERT L. DICKINSON, M. D. One handsome imperial octavo volume of 1014 pages, with nearly 900 beautiful colored and half-tone illustrations. Cloth, \$7.00 net; Sheep or Half Morocco, \$8.00 net. *Sold by Subscription.*

"Permit me to say that your American Text-Book of Obstetrics is the most magnificent medical work that I have ever seen. I congratulate you and thank you for this superb work, which alone is sufficient to place you first in the ranks of medical publishers."—ALEXANDER J. C. SKENE, *Professor of Gynecology in the Long Island College Hospital, Brooklyn, N. Y.*

"This is the most sumptuously illustrated work on midwifery that has yet appeared. In the number, the excellence, and the beauty of production of the illustrations it far surpasses every other book upon the subject. This feature alone makes it a work which no medical library should omit to purchase."—*British Medical Journal.*

"As an authority, as a book of reference, as a 'working book' for the student or practitioner, we commend it because we believe there is no better."—*American Journal of the Medical Sciences.*

---

Illustrated Catalogue of the "American Text-Books" sent free upon application.

**AN AMERICAN TEXT-BOOK OF PATHOLOGY.**

Edited by LUDVIG HEKTOEN, M. D., Professor of General Pathology and of Morbid Anatomy in the University of Pennsylvania; and DAVID RIESMAN, M. D., Demonstrator of Pathological Histology in the University of Pennsylvania. *In preparation.*

**AN AMERICAN TEXT-BOOK OF PHYSIOLOGY.**

By 10 of the Leading Physiologists of America. Edited by WILLIAM H. HOWELL, PH. D., M. D., Professor of Physiology in the Johns Hopkins University, Baltimore, Md. Second edition, revised and enlarged, in two volumes.

"We can commend it most heartily, not only to all students of physiology, but to every physician and pathologist, as a valuable and comprehensive work of reference, written by men who are of eminent authority in their own special subjects."—*London Lancet.*

"To the practitioner of medicine and to the advanced student this volume constitutes, we believe, the best exposition of the present status of the science of physiology in the English language."—*American Journal of the Medical Sciences.*

**AN AMERICAN TEXT-BOOK OF SURGERY. Third Edition.**

By 11 Eminent Professors of Surgery. Edited by WILLIAM W. KEEN, M. D., LL. D., and J. WILLIAM WHITE, M. D., PH. D. Handsome imperial octavo volume of 1230 pages, with 496 wood-cuts in the text, and 37 colored and half-tone plates. Thoroughly revised and enlarged, with a section devoted to "The Use of the Röntgen Rays in Surgery." Cloth, \$7.00 net; Sheep or Half Morocco, \$8.00 net.

"Personally, I should not mind it being called **THE TEXT-BOOK** (instead of **A TEXT-BOOK**), for I know of no single volume which contains so readable and complete an account of the science and art of Surgery as this does."—EDMUND OWEN, F. R. C. S., *Member of the Board of Examiners of the Royal College of Surgeons, England.*

"If this text-book is a fair reflex of the present position of American surgery, we must admit it is of a very high order of merit, and that English surgeons will have to look very carefully to their laurels if they are to preserve a position in the van of surgical practice."—*London Lancet.*

**AN AMERICAN TEXT-BOOK OF THE THEORY AND PRACTICE OF MEDICINE.**

By 12 Distinguished American Practitioners. Edited by WILLIAM PEPPER, M. D., LL. D., Professor of the Theory and Practice of Medicine and of Clinical Medicine in the University of Pennsylvania. Two handsome imperial octavo volumes of about 1000 pages each. Illustrated. Prices per volume: Cloth, \$5.00 net; Sheep or Half Morocco, \$6.00 net. *Sold by Subscription.*

"I am quite sure it will commend itself both to practitioners and students of medicine, and become one of our most popular text-books."—ALFRED LOOMIS, M. D., LL. D., *Professor of Pathology and Practice of Medicine, University of the City of New York.*

"We reviewed the first volume of this work, and said: 'It is undoubtedly one of the best text-books on the practice of medicine which we possess.' A consideration of the second and last volume leads us to modify that verdict and to say that the completed work is in our opinion *the best* of its kind it has ever been our fortune to see."—*New York Medical Journal.*

---

Illustrated Catalogue of the "American Text-Books" sent free upon application.

**AN AMERICAN YEAR-BOOK OF MEDICINE AND SURGERY.**

A Yearly Digest of Scientific Progress and Authoritative Opinion in all branches of Medicine and Surgery, drawn from journals, monographs, and text-books of the leading American and Foreign authors and investigators. Arranged with critical editorial comments, by eminent American specialists, under the general editorial charge of GEORGE M. GOULD, M.D. Volumes for 1896, '97, '98, and '99. One imperial octavo volume of about 1200 pages. Cloth, \$6.50 net; Half Morocco, \$7.50 net. Year-Book of 1900 in two volumes—Vol. I., including *General Medicine*; Vol. II., *General Surgery*. Prices per volume: Cloth, \$3.00 net; Half Morocco, \$3.75 net. *Sold by Subscription.*

"It is difficult to know which to admire most—the research and industry of the distinguished band of experts whom Dr. Gould has enlisted in the service of the Year-Book, or the wealth and abundance of the contributions to every department of science that have been deemed worthy of analysis. . . . It is much more than a mere compilation of abstracts, for, as each section is entrusted to experienced and able contributors, the reader has the advantage of certain critical commentaries and expositions . . . proceeding from writers fully qualified to perform these tasks. . . . It is emphatically a book which should find a place in every medical library, and is in several respects more useful than the famous 'Jahrbücher' of Germany."—*London Lancet.*

**ABBOTT ON TRANSMISSIBLE DISEASES.**

**The Hygiene of Transmissible Diseases; their Causation, Modes of Dissemination, and Methods of Prevention.** By A. C. ABBOTT, M.D., Professor of Hygiene and Bacteriology, University of Pennsylvania; Director of the Laboratory of Hygiene. Octavo volume of 311 pages, containing a number of charts and maps, and numerous illustrations. Cloth, \$2.00 net.

**THE AMERICAN POCKET MEDICAL DICTIONARY.**

[See *Dorland's Pocket Dictionary*, page 12.]

**ANDERS' PRACTICE OF MEDICINE. Third Revised Edition.**

**A Text-Book of the Practice of Medicine.** By JAMES M. ANDERS, M.D., PH.D., LL.D., Professor of the Practice of Medicine and of Clinical Medicine, Medico-Chirurgical College, Philadelphia. In one handsome octavo volume of 1292 pages, fully illustrated. Cloth, \$5.50 net; Sheep or Half Morocco, \$6.50 net.

"It is an excellent book,—concise, comprehensive, thorough, and up to date. It is a credit to you; but, more than that, it is a credit to the profession of Philadelphia—to us." JAMES C. WILSON, *Professor of the Practice of Medicine and Clinical Medicine, Jefferson Medical College, Philadelphia.*

**ASHTON'S OBSTETRICS. Fourth Edition, Revised.**

**Essentials of Obstetrics.** By W. EASTERLY ASHTON, M.D., Professor of Gynecology in the Medico-Chirurgical College, Philadelphia. Crown octavo, 252 pages; 75 illustrations. Cloth, \$1.00 net; interleaved for notes, \$1.25 net.

[See *Saunders' Question-Compends*, page 23.]

"Embodies the whole subject in a nut-shell. We cordially recommend it to our readers."—*Chicago Medical Times.*

**BALL'S BACTERIOLOGY. Third Edition, Revised.**

**Essentials of Bacteriology ;** a Concise and Systematic Introduction to the Study of Micro-organisms. By M. V. BALL, M.D., Bacteriologist to St. Agnes' Hospital, Philadelphia, etc. Crown octavo, 218 pages ; 82 illustrations, some in colors, and 5 plates. Cloth, \$1.00 ; interleaved for notes, \$1.25.

[See *Saunders' Question-Compends*, page 23.]

"The student or practitioner can readily obtain a knowledge of the subject from a perusal of this book. The illustrations are clear and satisfactory."—*Medical Record*, New York.

**BASTIN'S BOTANY.**

**Laboratory Exercises in Botany.** By EDSON S. BASTIN, M.A., late Prof. of Materia Medica and Botany, Philadelphia College of Pharmacy. Octavo volume of 536 pages, with 87 plates. Cloth, \$2.00 net.

"It is unquestionably the best text-book on the subject that has yet appeared. The work is eminently a practical one. We regard the issuance of this book as an important event in the history of pharmaceutical teaching in this country, and predict for it an unqualified success."—*Alumni Report to the Philadelphia College of Pharmacy*.

**BECK ON FRACTURES.**

**Fractures.** By CARL BECK, M.D., Surgeon to St. Mark's Hospital and the New York German Poliklinik, etc. 225 pages, 170 illustrations. Cloth, \$ net.

**BECK'S SURGICAL ASEPSIS.**

**A Manual of Surgical Asepsis.** By CARL BECK, M.D., Surgeon to St. Mark's Hospital and the New York German Poliklinik, etc. 306 pages ; 65 text-illustrations, and 12 full-page plates. Cloth, \$1.25 net.

"An excellent exposition of the 'very latest' in the treatment of wounds as practised by leading German and American surgeons."—*Birmingham (Eng.) Medical Review*.

"This little volume can be recommended to any who are desirous of learning the details of asepsis in surgery, for it will serve as a trustworthy guide."—*London Lancet*.

**BOISLINIERE'S OBSTETRIC ACCIDENTS, EMERGENCIES, AND OPERATIONS.**

**Obstetric Accidents, Emergencies, and Operations.** By L. CH. BOISLINIERE, M.D., late Emeritus Professor of Obstetrics, St. Louis Medical College. 381 pages, handsomely illustrated. Cloth, \$2.00 net.

"A manual so useful to the student or the general practitioner has not been brought to our notice in a long time. The field embraced in the title is covered in a terse, interesting way."—*Yale Medical Journal*.

**BROCKWAY'S MEDICAL PHYSICS. Second Edition, Revised.**

**Essentials of Medical Physics.** By FRED J. BROCKWAY, M.D., Assistant Demonstrator of Anatomy in the College of Physicians and Surgeons, New York. Crown octavo, 330 pages ; 155 fine illustrations. Cloth, \$1.00 net ; interleaved for notes, \$1.25 net.

[See *Saunders' Question-Compends*, page 23.]

"We know of no manual that affords the medical student a better or more concise exposition of physics, and the book may be commended as a most satisfactory presentation of those essentials that are requisite in a course in medicine."—*New York Medical Journal*.



**BUTLER'S MATERIA MEDICA, THERAPEUTICS, AND PHARMACOLOGY. Third Edition, Revised.**

**A Text-Book of Materia Medica, Therapeutics, and Pharmacology.** By GEORGE F. BUTLER, PH.G., M.D., Professor of Materia Medica and of Clinical Medicine in the College of Physicians and Surgeons, Chicago; Professor of Materia Medica and Therapeutics, Northwestern University, Woman's Medical School, etc. Octavo, 874 pages, illustrated. Cloth, \$4.00 net; Sheep, \$5.00 net.

"Taken as a whole, the book may fairly be considered as one of the most satisfactory of any single-volume works on materia medica in the market."—*Journal of the American Medical Association.*

**CERNA ON THE NEWER REMEDIES. Second Edition, Revised.**

**Notes on the Newer Remedies, their Therapeutic Applications and Modes of Administration.** By DAVID CERNA, M.D., PH.D., formerly Demonstrator of and Lecturer on Experimental Therapeutics in the University of Pennsylvania; Demonstrator of Physiology in the Medical Department of the University of Texas. Rewritten and greatly enlarged. Post-octavo, 253 pages. Cloth, \$1.00 net.

"The appearance of this new edition of Dr. Cerna's very valuable work shows that it is properly appreciated. The book ought to be in the possession of every practising physician."—*New York Medical Journal.*

**CHAPIN ON INSANITY.**

**A Compendium of Insanity.** By JOHN B. CHAPIN, M.D., LL.D., Physician-in-Chief, Pennsylvania Hospital for the Insane; late Physician-Superintendent of the Willard State Hospital, New York; Honorary Member of the Medico-Psychological Society of Great Britain, of the Society of Mental Medicine of Belgium. 12mo, 234 pages, illustrated. Cloth, \$1.25 net.

"The practical parts of Dr. Chapin's book are what constitute its distinctive merit. We desire especially to call attention to the fact that on the subject of therapeutics of insanity the work is exceedingly valuable. It is not a made book, but a genuine condensed thesis, which has all the value of ripe opinion and all the charm of a vigorous and natural style."—*Philadelphia Medical Journal.*

**CHAPMAN'S MEDICAL JURISPRUDENCE AND TOXICOLOGY. Second Edition, Revised.**

**Medical Jurisprudence and Toxicology.** By HENRY C. CHAPMAN, M.D., Professor of Institutes of Medicine and Medical Jurisprudence in the Jefferson Medical College of Philadelphia. 254 pages, with 55 illustrations and 3 full-page plates in colors. Cloth, \$1.50 net.

"The best book of its class for the undergraduate that we know of."—*New York Medical Times.*

**CHURCH AND PETERSON'S NERVOUS AND MENTAL DISEASES. Second Edition.**

**Nervous and Mental Diseases.** By ARCHIBALD CHURCH, M.D., Professor of Clinical Neurology, Mental Diseases, and Medical Jurisprudence in the Northwestern University Medical School, Chicago; and FREDERICK PETERSON, M.D., Clinical Professor of Mental Diseases, Woman's Medical College, N. Y.; Chief of Clinic, Nervous Dept., College of Physicians and Surgeons, N. Y. Handsome octavo volume of 843 pages, profusely illustrated. Cloth, \$5.00 net; Half Morocco, \$6.00 net.

**CLARKSON'S HISTOLOGY.**

**A Text-Book of Histology, Descriptive and Practical.** By ARTHUR CLARKSON, M.B., C.M. Edin., formerly Demonstrator of Physiology in the Owen's College, Manchester; late Demonstrator of Physiology in Yorkshire College, Leeds. Large octavo, 554 pages; 22 engravings in the text, and 174 beautifully colored original illustrations. Cloth, strongly bound, \$4.00 net.

"The work must be considered a valuable addition to the list of available text-books, and is to be highly recommended."—*New York Medical Journal*.

"This is one of the best works for students we have ever noticed. We predict that the book will attain a well-deserved popularity among our students."—*Chicago Medical Recorder*.

**CLIMATOLOGY.**

**Transactions of the Eighth Annual Meeting of the American Climatological Association**, held in Washington, September 22-25, 1891. Forming a handsome octavo volume of 276 pages, uniform with remainder of series. (A limited quantity only.) Cloth, \$1.50.

**COHEN AND ESHNER'S DIAGNOSIS. Second Edition, Revised.**

**Essentials of Diagnosis.** By SOLOMON SOLIS-COHEN, M.D., Professor of Clinical Medicine and Applied Therapeutics in the Philadelphia Polyclinic; and AUGUSTUS A. ESHNER, M.D., Professor of Clinical Medicine in the Philadelphia Polyclinic. Post-octavo, 417 pages; 55 illustrations. Cloth, \$1.00 net.

[See *Saunders' Question-Compends*, page 23.]

"We can heartily commend the book to all those who contemplate purchasing a 'compend.' It is modern and complete, and will give more satisfaction than many other works which are perhaps too prolix as well as behind the times."—*Medical Review*, St. Louis.

**CORWIN'S PHYSICAL DIAGNOSIS. Third Edition, Revised.**

**Essentials of Physical Diagnosis of the Thorax.** By ARTHUR M. CORWIN, A.M., M.D., Demonstrator of Physical Diagnosis in Rush Medical College, Chicago; Attending Physician to Central Free Dispensary, Department of Rhinology, Laryngology, and Diseases of the Chest, Chicago. 219 pages, illustrated. Cloth, flexible covers, \$1.25 net.

"It is excellent. The student who shall use it as his guide to the careful study of physical exploration upon normal and abnormal subjects can scarcely fail to acquire a good working knowledge of the subject."—*Philadelphia Polyclinic*.

"A most excellent little work. It brightens the memory of the differential diagnostic signs, and it arranges orderly and in sequence the various objective phenomena to logical solution of a careful diagnosis."—*Journal of Nervous and Mental Diseases*.

**CRAGIN'S GYNÆCOLOGY. Fourth Edition, Revised.**

**Essentials of Gynæcology.** By EDWIN B. CRAGIN, M. D., Lecturer in Obstetrics, College of Physicians and Surgeons, New York. Crown octavo, 200 pages; 62 illustrations. Cloth, \$1.00 net; interleaved for notes, \$1.25 net.

[See *Saunders' Question-Compends*, page 23.]

"A handy volume, and a distinct improvement on students' compends in general. No author who was not himself a practical gynecologist could have consulted the student's needs so thoroughly as Dr. Cragin has done."—*Medical Record*, New York.

**CROOKSHANK'S BACTERIOLOGY. Fourth Edition, Revised.**

**A Text-Book of Bacteriology.** By EDGAR M. CROOKSHANK, M.B., Professor of Comparative Pathology and Bacteriology, King's College, London. Octavo volume of 700 pages, with 273 engravings and 22 original colored plates. Cloth, \$6.50 net; Half Morocco, \$7.50 net.

"To the student who wishes to obtain a good *résumé* of what has been done in bacteriology, or who wishes an accurate account of the various methods of research, the book may be recommended with confidence that he will find there what he requires."—*London Lancet*.

**DA COSTA'S SURGERY. Second Ed., Revised and Greatly Enlarged.**

**Modern Surgery, General and Operative.** By JOHN CHALMERS DACOSTA, M. D., Professor of Practice of Surgery and Clinical Surgery, Jefferson Medical College, Philadelphia; Surgeon to the Philadelphia Hospital, etc. Handsome octavo volume of 911 pages, profusely illustrated. Cloth, \$4.00 net; Half Morocco, \$5.00 net.

"We know of no small work on surgery in the English language which so well fulfils the requirements of the modern student."—*Medico-Chirurgical Journal*, Bristol, England.

**DE SCHWEINITZ ON DISEASES OF THE EYE. Third Edition, Revised.**

**Diseases of the Eye. A Handbook of Ophthalmic Practice.** By G. E. DE SCHWEINITZ, M.D., Professor of Ophthalmology in the Jefferson Medical College, Philadelphia, etc. Handsome royal octavo volume of 696 pages, with 256 fine illustrations and 2 chromo-lithographic plates. Cloth, \$4.00 net; Sheep or Half Morocco, \$5.00 net.

"A clearly written, comprehensive manual. One which we can commend to students as a reliable text-book, written with an evident knowledge of the wants of those entering upon the study of this special branch of medical science."—*British Medical Journal*.

"A work that will meet the requirements not only of the specialist, but of the general practitioner in a rare degree. I am satisfied that unusual success awaits it."—WILLIAM PEPPER, M.D., *Professor of the Theory and Practice of Medicine and Clinical Medicine, University of Pennsylvania*.

**DORLAND'S DICTIONARY. Third Edition, Revised.**

**The American Pocket Medical Dictionary.** Containing the Pronunciation and Definition of all the principal words and phrases, and a large number of useful tables. Edited by W. A. NEWMAN DORLAND, M. D., Assistant Demonstrator of Obstetrics, University of Pennsylvania; Fellow of the American Academy of Medicine. 518 pages; handsomely bound in full leather, limp, with gilt edges and patent index. Price, \$1.00 net; with thumb index, \$1.25 net.

**DORLAND'S OBSTETRICS.**

**A Manual of Obstetrics.** By W. A. NEWMAN DORLAND, M.D., Assistant Demonstrator of Obstetrics, University of Pennsylvania; Instructor in Gynecology in the Philadelphia Polyclinic. 760 pages; 163 illustrations in the text, and 6 full-page plates. Cloth, \$2.50 net.

"By far the best book on this subject that has ever come to our notice."—*American Medical Review*.

"It has rarely been our duty to review a book which has given us more pleasure in its perusal and more satisfaction in its criticism. It is a veritable encyclopedia of knowledge, a gold mine of practical, concise thoughts."—*American Medico-Surgical Bulletin*.

**FROTHINGHAM'S GUIDE FOR THE BACTERIOLOGIST.**

**Laboratory Guide for the Bacteriologist.** By LANGDON FROTHINGHAM, M.D.V., Assistant in Bacteriology and Veterinary Science, Sheffield Scientific School, Yale University. Illustrated. Cloth, 75 cts.

"It is a convenient and useful little work, and will more than repay the outlay necessary for its purchase in the saving of time which would otherwise be consumed in looking up the various points of technique so clearly and concisely laid down in its pages."—*American Medico-Surgical Bulletin*.

**GARRIGUES' DISEASES OF WOMEN. Third Edition, Revised.**

**Diseases of Women.** By HENRY J. GARRIGUES, A.M., M.D., Professor of Gynecology in the New York School of Clinical Medicine; Gynecologist to St. Mark's Hospital and to the German Dispensary, New York City, etc. Handsome octavo volume of 783 pages, illustrated by 367 engravings and colored plates. Cloth, \$4.00 net; Sheep or Half Morocco, \$5.00 net.

"One of the best text-books for students and practitioners which has been published in the English language; it is condensed, clear, and comprehensive. The profound learning and great clinical experience of the distinguished author find expression in this book in a most attractive and instructive form. Young practitioners to whom experienced consultants may not be available will find in this book invaluable counsel and help."—THAD. A. REAMY, M.D., LL.D., *Professor of Clinical Gynecology, Medical College of Ohio*.

**GLEASON'S DISEASES OF THE EAR. Second Edition, Revised.**

**Essentials of Diseases of the Ear.** By E. B. GLEASON, S.B., M.D., Clinical Professor of Otolaryngology, Medico-Chirurgical College, Philadelphia; Surgeon-in-Charge of the Nose, Throat, and Ear Department of the Northern Dispensary, Philadelphia. 208 pages, with 114 illustrations. Cloth, \$1.00 net; interleaved for notes, \$1.25 net.

[See *Saunders' Question-Compends*, page 23.]

"It is just the book to put into the hands of a student, and cannot fail to give him a useful introduction to ear-affections; while the style of question and answer which is adopted throughout the book is, we believe, the best method of impressing facts permanently on the mind."—*Liverpool Medico-Chirurgical Journal*.

**GOULD AND PYLE'S CURIOSITIES OF MEDICINE.**

**Anomalies and Curiosities of Medicine.** By GEORGE M. GOULD, M.D., and WALTER L. PYLE, M.D. An encyclopedic collection of rare and extraordinary cases and of the most striking instances of abnormality in all branches of Medicine and Surgery, derived from an exhaustive research of medical literature from its origin to the present day, abstracted, classified, annotated, and indexed. Handsome imperial octavo volume of 968 pages, with 295 engravings in the text, and 12 full-page plates.

**POPULAR EDITION: Cloth, \$3.00 net; Half Morocco, \$4.00 net.**

"One of the most valuable contributions ever made to medical literature. It is, so far as we know, absolutely unique, and every page is as fascinating as a novel. Not alone for the medical profession has this volume value: it will serve as a book of reference for all who are interested in general scientific, sociologic, or medico-legal topics."—*Brooklyn Medical Journal*.

"This is certainly a most remarkable and interesting volume. It stands alone among medical literature, an anomaly on anomalies, in that there is nothing like it elsewhere in medical literature. It is a book full of revelations from its first to its last page, and cannot but interest and sometimes almost horrify its readers."—*American Medico-Surgical Bulletin*.



**GRAFSTROM'S MECHANO-THERAPY.**

**A Text-Book of Mechano-Therapy (Massage and Medical Gymnastics).** By AXEL V. GRAFSTROM, B. SC., M. D., late Lieutenant in the Royal Swedish Army; late House Physician City Hospital, Blackwell's Island, New York. 12mo, 139 pages, illustrated. Cloth, \$1.00 net.

**GRIFFITH ON THE BABY. Second Edition, Revised.**

**The Care of the Baby.** By J. P. CROZER GRIFFITH, M.D., Clinical Professor of Diseases of Children, University of Pennsylvania; Physician to the Children's Hospital, Philadelphia, etc. 12mo, 404 pages, with 67 illustrations in the text, and 5 plates. Cloth, \$1.50 net.

"The best book for the use of the young mother with which we are acquainted. . . . There are very few general practitioners who could not read the book through with advantage."—*Archives of Pediatrics*.

"The whole book is characterized by rare good sense, and is evidently written by a master hand. It can be read with benefit not only by mothers but by medical students and by any practitioners who have not had large opportunities for observing children."—*American Journal of Obstetrics*.

**GRIFFITH'S WEIGHT CHART.**

**Infant's Weight Chart.** Designed by J. P. CROZER GRIFFITH, M.D., Clinical Professor of Diseases of Children in the University of Pennsylvania, etc. 25 charts in each pad. Per pad, 50 cents net.

**GROSS, SAMUEL D., AUTOBIOGRAPHY OF.**

**Autobiography of Samuel D. Gross, M. D.,** Emeritus Professor of Surgery in the Jefferson Medical College, Philadelphia, with Reminiscences of His Times and Contemporaries. Edited by his Sons, SAMUEL W. GROSS, M.D., LL.D., and A. HALLER GROSS, A.M. Preceded by a Memoir of Dr. Gross, by the late AUSTIN FLINT, M.D. Two handsome volumes, over 400 pages each, demy octavo, gilt tops, with Frontispiece on steel. Price per volume, \$2.50 net.

**HAMPTON'S NURSING. Second Edition, Revised and Enlarged.**

**Nursing: Its Principles and Practice.** By ISABEL ADAMS HAMPTON, Graduate of the New York Training School for Nurses attached to Bellevue Hospital; late Superintendent of Nurses and Principal of the Training School for Nurses, Johns Hopkins Hospital, Baltimore, Md. 12 mo, 512 pages, illustrated. Cloth, \$2.00 net.

"Seldom have we perused a book upon the subject that has given us so much pleasure as the one before us. We would strongly urge upon the members of our own profession the need of a book like this, for it will enable each of us to become a training school in himself."—*Ontario Medical Journal*.

**HARE'S PHYSIOLOGY. Fourth Edition, Revised.**

**Essentials of Physiology.** By H. A. HARE, M.D., Professor of Therapeutics and Materia Medica in the Jefferson Medical College of Philadelphia. Crown octavo, 239 pages. Cloth, \$1.00 net; interleaved for notes, \$1.25 net.

[See *Saunders' Question-Compends*, page 23.]

"The best condensation of physiological knowledge we have yet seen."—*Medical Record*, New York.

### HART'S DIET IN SICKNESS AND IN HEALTH.

**Diet in Sickness and in Health.** By MRS. ERNEST HART, formerly Student of the Faculty of Medicine of Paris and of the London School of Medicine for Women; with an INTRODUCTION by SIR HENRY THOMPSON, F.R.C.S., M.D., London. 220 pages. Cloth, \$1.50 net.

"We recommend it cordially to the attention of all practitioners; both to them and to their patients it may be of the greatest service."—*New York Medical Journal*.

### HAYNES' ANATOMY.

**A Manual of Anatomy.** By IRVING S. HAYNES, M.D., Adjunct Professor of Anatomy and Demonstrator of Anatomy, Medical Department of the New York University, etc. 680 pages, illustrated with 42 diagrams in the text, and 134 full-page half-tone illustrations from original photographs of the author's dissections. Cloth, \$2.50 net.

"This book is the work of a practical instructor—one who knows by experience the requirements of the average student, and is able to meet these requirements in a very satisfactory way. The book is one that can be commended."—*Medical Record*, New York.

### HEISLER'S EMBRYOLOGY.

**A Text-Book of Embryology.** By JOHN C. HEISLER, M.D., Professor of Anatomy in the Medico-Chirurgical College, Philadelphia. Octavo volume of 405 pages, handsomely illustrated. Cloth, \$2.50 net.

### HIRST'S OBSTETRICS. Second Edition.

**A Text-Book of Obstetrics.** By BARTON COOKE HIRST, M. D., Professor of Obstetrics in the University of Pennsylvania. Handsome octavo volume of 848 pages, with 618 illustrations, and 7 colored plates. Cloth, \$5.00 net; Sheep or Half Morocco, \$6.00 net.

"The illustrations are numerous and are works of art, many of them appearing for the first time. The arrangement of the subject-matter, the foot-notes, and index are beyond criticism. As a true model of what a modern text-book on obstetrics should be, we feel justified in affirming that Dr. Hirst's book is without a rival."—*New York Medical Record*.

### HYDE AND MONTGOMERY ON SYPHILIS AND THE VENEREAL DISEASES. Second Edition, Revised and Enlarged.

**Syphilis and the Venereal Diseases.** By JAMES NEVINS HYDE, M. D., Professor of Skin and Venereal Diseases, and FRANK H. MONTGOMERY, M. D., Lecturer on Dermatology and Genito-Urinary Diseases in Rush Medical College, Chicago, Ill. Octavo, nearly 600 pages, with 14 beautiful lithographic plates and numerous illustrations.

"We can commend this manual to the student as a help to him in his study of venereal diseases."—*Liverpool Medico-Chirurgical Journal*.

"The best student's manual which has appeared on the subject."—*St. Louis Medical and Surgical Journal*.

### INTERNATIONAL TEXT-BOOK OF SURGERY. In two volumes.

By American and British authors. Edited by J. COLLINS WARREN, M.D., LL.D., Professor of Surgery, Harvard Medical School, Boston; and A. PEARCE GOULD, M.S., F.R.C.S., Lecturer on Practical Surgery and Teacher of Operative Surgery, Middlesex Hospital Medical School, London, Eng. Vol. I. *General Surgery*.—Handsome octavo, 947 pages, with 458 beautiful illustrations and 9 lithographic plates. Vol. II. *Special or Regional Surgery*.—Handsome octavo, 1072 pages, with 471 beautiful illustrations and 8 lithographic plates. Prices per volume: Cloth, \$5.00 net; Half Morocco, \$6.00 net.

**JACKSON'S DISEASES OF THE EYE.**

**A Manual of Diseases of the Eye.** By EDWARD JACKSON, A.M., M.D., sometime Professor of Diseases of the Eye in the Philadelphia Polyclinic and College for Graduates in Medicine. 12mo volume of 535 pages, with 178 beautiful illustrations, mostly from drawings by the author. Cloth, \$2.50 net.

**JACKSON AND GLEASON'S DISEASES OF THE EYE, NOSE, AND THROAT. Second Edition, Revised.**

**Essentials of Refraction and Diseases of the Eye.** By EDWARD JACKSON, A.M., M.D., Professor of Diseases of the Eye in the Philadelphia Polyclinic and College for Graduates in Medicine; and—

**Essentials of Diseases of the Nose and Throat.** By E. BALDWIN GLEASON, M.D., Surgeon-in-Charge of the Nose, Throat, and Ear Department of the Northern Dispensary of Philadelphia. Two volumes in one. Crown octavo, 290 pages; 124 illustrations. Cloth, \$1.00 net; interleaved for notes, \$1.25 net.

[See *Saunders' Question-Compends*, page 22.]

"Of great value to the beginner in these branches. The authors are both capable men, and know what a student most needs."—*Medical Record*, New York.

**KEATING'S DICTIONARY. Second Edition, Revised.**

**A New Pronouncing Dictionary of Medicine, with Phonetic Pronunciation, Accentuation, Etymology, etc.** By JOHN M. KEATING, M.D., LL.D., Fellow of the College of Physicians of Philadelphia, and HENRY HAMILTON; with the collaboration of J. CHALMERS DACOSTA, M.D., and FREDERICK A. PACKARD, M.D. With an Appendix containing Tables of Bacilli, Micrococci, Leucomaines, Ptomaines, etc. One volume of over 800 pages. Prices, with Ready-Reference Index: Cloth, \$5.00 net; Sheep or Half Morocco, \$6.00 net. Without Patent Index: Cloth, \$4.00 net; Sheep or Half Morocco, \$5.00 net.

"I am much pleased with Keating's Dictionary, and shall take pleasure in recommending it to my classes."—HENRY M. LYMAN, M.D., *Professor of the Principles and Practice of Medicine, Rush Medical College, Chicago, Ill.*

**KEATING'S LIFE INSURANCE.**

**How to Examine for Life Insurance.** By JOHN M. KEATING, M.D., Fellow of the College of Physicians of Philadelphia; Vice-President of the American Pædiatric Society; Ex-President of the Association of Life Insurance Medical Directors. Royal octavo, 211 pages; with two large half-tone illustrations, and a plate prepared by Dr. McClellan from special dissections; also, numerous other illustrations. Cloth, \$2.00 net.

**KEEN'S OPERATION BLANK. Second Edition, Revised Form.**

**An Operation Blank, with Lists of Instruments, etc., Required in Various Operations.** Prepared by W. W. KEEN, M.D., LL.D., Professor of the Principles of Surgery in Jefferson Medical College, Philadelphia. Price per pad, blanks for fifty operations, 50 cents net.

### KEEN ON THE SURGERY OF TYPHOID FEVER.

#### **The Surgical Complications and Sequels of Typhoid Fever.**

By WM. W. KEEN, M.D., LL.D., Professor of the Principles of Surgery and of Clinical Surgery, Jefferson Medical College, Philadelphia; Corresponding Member of the Société de Chirurgie, Paris; Honorary Member of the Société Belge de Chirurgie, etc. Octavo volume of 386 pages, illustrated. Cloth, \$3.00 net.

"This is probably the first and only work in the English language that gives the reader a clear view of what typhoid fever really is, and what it does and can do to the human organism. This book should be in the possession of every medical man in America."—*American Medico-Surgical Bulletin*.

### KYLE ON THE NOSE AND THROAT.

**Diseases of the Nose and Throat.** By D. BRADEN KYLE, M.D., Clinical Professor of Laryngology and Rhinology, Jefferson Medical College, Philadelphia; Consulting Laryngologist, Rhinologist, and Otologist, St. Agnes' Hospital. Handsome octavo volume of about 630 pages, with over 150 illustrations and 6 lithographic plates. Price, Cloth, \$4.00 net; Half Morocco, \$5.00 net.

### LAINÉ'S TEMPERATURE CHART.

**Temperature Chart.** Prepared by D. T. LAINÉ, M.D. Size 8 x 13½ inches. A conveniently arranged Chart for recording Temperature, with columns for daily amounts of Urinary and Fecal Excretions, Food, Remarks, etc. On the back of each chart is given in full the method of Brand in the treatment of Typhoid Fever. Price, per pad of 25 charts, 50 cents net.

"To the busy practitioner this chart will be found of great value in fever cases, and especially for cases of typhoid."—*Indian Lancet*, Calcutta.

### LEVY AND KLEMPERER'S CLINICAL BACTERIOLOGY.

**The Elements of Clinical Bacteriology.** By DR. ERNST LEVY, Professor in the University of Strassburg, and FELIX KLEMPERER, Privat docent in the University of Strassburg. Translated and edited by AUGUSTUS A. ESHNER, M.D., Professor of Clinical Medicine in the Philadelphia Polyclinic. Octavo, 440 pages, fully illustrated. Cloth, \$2.50 net.

### LOCKWOOD'S PRACTICE OF MEDICINE.

**A Manual of the Practice of Medicine.** By GEORGE ROE LOCKWOOD, M.D., Professor of Practice in the Woman's Medical College of the New York Infirmary, etc. 935 pages, with 75 illustrations in the text, and 22 full-page plates. Cloth, \$2.50 net.

"Gives in a most concise manner the points essential to treatment usually enumerated in the most elaborate works."—*Massachusetts Medical Journal*.

### LONG'S SYLLABUS OF GYNECOLOGY.

**A Syllabus of Gynecology, arranged in Conformity with "An American Text-Book of Gynecology."** By J. W. LONG, M.D., Professor of Diseases of Women and Children, Medical College of Virginia, etc. Cloth, interleaved, \$1.00 net.

"The book is certainly an admirable *résumé* of what every gynecological student and practitioner should know, and will prove of value not only to those who have the 'American Text-Book of Gynecology,' but to others as well."—*Brooklyn Medical Journal*.



**MACDONALD'S SURGICAL DIAGNOSIS AND TREATMENT.**

**Surgical Diagnosis and Treatment.** By J. W. MACDONALD, M.D. Edin., F.R.C.S., Edin., Professor of the Practice of Surgery and of Clinical Surgery in Hamline University; Visiting Surgeon to St. Barnabas' Hospital, Minneapolis, etc. Handsome octavo volume of 800 pages, profusely illustrated. Cloth, \$5.00 net; Half Morocco, \$6.00 net.

"A thorough and complete work on surgical diagnosis and treatment, free from padding, full of valuable material, and in accord with the surgical teaching of the day."—*The Medical News, New York.*

"The work is brimful of just the kind of practical information that is useful alike to students and practitioners. It is a pleasure to commend the book because of its intrinsic value to the medical practitioner."—*Cincinnati Lancet-Clinic*

**MALLORY AND WRIGHT'S PATHOLOGICAL TECHNIQUE.**

**Pathological Technique.** A Practical Manual for Laboratory Work in Pathology, Bacteriology, and Morbid Anatomy, with chapters on Post-Mortem Technique and the Performance of Autopsies. By FRANK B. MALLORY, A.M., M.D., Assistant Professor of Pathology, Harvard University Medical School, Boston; and JAMES H. WRIGHT, A.M., M.D., Instructor in Pathology, Harvard University Medical School, Boston. Octavo volume of 396 pages, handsomely illustrated. Cloth, \$2.50 net.

"I have been looking forward to the publication of this book, and I am glad to say that I find it to be a most useful laboratory and post-mortem guide, full of practical information, and well up to date."—WILLIAM H. WELCH, *Professor of Pathology, Johns Hopkins University, Baltimore, Md.*

**MARTIN'S MINOR SURGERY, BANDAGING, AND VENEREAL DISEASES. Second Edition, Revised.**

**Essentials of Minor Surgery, Bandaging, and Venereal Diseases.** By EDWARD MARTIN, A.M., M.D., Clinical Professor of Genito-Urinary Diseases, University of Pennsylvania, etc. Crown octavo, 166 pages, with 78 illustrations. Cloth, \$1.00 net; interleaved for notes, \$1.25 net.

[See *Saunders' Question-Compends*, page 23.]

"A very practical and systematic study of the subjects, and shows the author's familiarity with the needs of students."—*Therapeutic Gazette.*

**MARTIN'S SURGERY. Seventh Edition, Revised.**

**Essentials of Surgery.** Containing also Venereal Diseases, Surgical Landmarks, Minor and Operative Surgery, and a complete description, with illustrations, of the Handkerchief and Roller Bandages. By EDWARD MARTIN, A.M., M.D., Clinical Professor of Genito-Urinary Diseases, University of Pennsylvania, etc. Crown octavo, 342 pages, illustrated. With an Appendix on the preparation of the materials used in Antiseptic Surgery, etc., and a chapter on Appendicitis. Cloth, \$1.00 net; interleaved for notes, \$1.25 net.

[See *Saunders' Question-Compends*, page 23.]

"Contains all necessary essentials of modern surgery in a comparatively small space. Its style is interesting, and its illustrations are admirable."—*Medical and Surgical Reporter.*

**McFARLAND'S PATHOGENIC BACTERIA. Second Edition, Revised and Greatly Enlarged.**

**Text-Book upon the Pathogenic Bacteria.** By JOSEPH McFARLAND, M. D., Professor of Pathology and Bacteriology in the Medico-Chirurgical College of Philadelphia, etc. Octavo volume of 497 pages, finely illustrated. Cloth, \$2.50 net.

"Dr. McFarland has treated the subject in a systematic manner, and has succeeded in presenting in a concise and readable form the essentials of bacteriology up to date. Altogether, the book is a satisfactory one, and I shall take pleasure in recommending it to the students of Trinity College."—H. B. ANDERSON, M. D., *Professor of Pathology and Bacteriology, Trinity Medical College, Toronto.*

**MEIGS ON FEEDING IN INFANCY.**

**Feeding in Early Infancy.** By ARTHUR V. MEIGS, M. D. Bound in limp cloth, flush edges, 25 cents net.

"This pamphlet is worth many times over its price to the physician. The author's experiments and conclusions are original, and have been the means of doing much good."—*Medical Bulletin.*

**MOORE'S ORTHOPEDIC SURGERY.**

**A Manual of Orthopedic Surgery.** By JAMES E. MOORE, M. D., Professor of Orthopedics and Adjunct Professor of Clinical Surgery, University of Minnesota, College of Medicine and Surgery. Octavo volume of 356 pages, handsomely illustrated. Cloth, \$2.50 net.

"A most attractive work. The illustrations and the care with which the book is adapted to the wants of the general practitioner and the student are worthy of great praise."—*Chicago Medical Recorder.*

"A very demonstrative work, every illustration of which conveys a lesson. The work is a most excellent and commendable one, which we can certainly endorse with pleasure."—*St. Louis Medical and Surgical Journal.*

**MORRIS'S MATERIA MEDICA AND THERAPEUTICS. Fifth Edition, Revised.**

**Essentials of Materia Medica, Therapeutics, and Prescription-Writing.** By HENRY MORRIS, M. D., late Demonstrator of Therapeutics, Jefferson Medical College, Philadelphia; Fellow of the College of Physicians, Philadelphia, etc. Crown octavo, 288 pages. Cloth, \$1.00 net; interleaved for notes, \$1.25 net.

[See *Saunders' Question-Compends*, page 22.]

"This work, already excellent in the old edition, has been largely improved by revision."—*American Practitioner and News.*

**MORRIS, WOLFF, AND POWELL'S PRACTICE OF MEDICINE. Third Edition, Revised.**

**Essentials of the Practice of Medicine.** By HENRY MORRIS, M. D., late Demonstrator of Therapeutics, Jefferson Medical College, Philadelphia; with an Appendix on the Clinical and Microscopic Examination of Urine, by LAWRENCE WOLFF, M. D., Demonstrator of Chemistry, Jefferson Medical College, Philadelphia. Enlarged by some 300 essential formulæ collected and arranged by WILLIAM M. POWELL, M. D. Post-octavo, 488 pages. Cloth, \$1.50 net.

[See *Saunders' Question-Compends*, page 22.]

"The teaching is sound, the presentation graphic; matter full as can be desired, and style attractive."—*American Practitioner and News.*

**MORTEN'S NURSE'S DICTIONARY.**

**Nurse's Dictionary of Medical Terms and Nursing Treatment.** Containing Definitions of the Principal Medical and Nursing Terms and Abbreviations; of the Instruments, Drugs, Diseases, Accidents, Treatments, Operations, Foods, Appliances, etc. encountered in the ward or in the sick-room. By HONNOR MORTEN, author of "How to Become a Nurse," etc. 16mo, 140 pages. Cloth, \$1.00 net.

"A handy, compact little volume, containing a large amount of general information, all of which is arranged in dictionary or encyclopedic form, thus facilitating quick reference. It is certainly of value to those for whose use it is published."—*Chicago Clinical Review.*

**NANCREDE'S ANATOMY. Sixth Edition, Thoroughly Revised.**

**Essentials of Anatomy**, including the Anatomy of the Viscera. By CHARLES B. NANCREDE, M.D., LL.D., Professor of Surgery and of Clinical Surgery in the University of Michigan, Ann Arbor. Crown octavo, 420 pages; 151 illustrations. Based upon *Gray's Anatomy*. Cloth, \$1.00 net; interleaved for notes, \$1.25 net.

[See *Saunders' Question-Compends*, page 23.]

"For self-quizzing and keeping fresh in mind the knowledge of anatomy gained at school, it would not be easy to speak of it in terms too favorable."—*American Practitioner.*

**NANCREDE'S ANATOMY AND DISSECTION. Fourth Edition.**

**Essentials of Anatomy and Manual of Practical Dissection.** By CHARLES B. NANCREDE, M.D., LL.D., Professor of Surgery and of Clinical Surgery, University of Michigan, Ann Arbor. Post-octavo; 500 pages, with full-page lithographic plates in colors, and nearly 200 illustrations. Extra Cloth (or Oilcloth for dissection-room), \$2.00 net.

"It may in many respects be considered an epitome of Gray's popular work on general anatomy, at the same time having some distinguishing characteristics of its own to commend it. The plates are of more than ordinary excellence, and are of especial value to students in their work in the dissecting room."—*Journal of the American Medical Association.*

**NANCREDE'S PRINCIPLES OF SURGERY.**

**Lectures on the Principles of Surgery.** By CHAS. B. NANCREDE, M.D., LL.D., Professor of Surgery and of Clinical Surgery, University of Michigan, Ann Arbor. Octavo volume of 398 pages, illustrated. Cloth, \$2.50 net.

**NORRIS'S SYLLABUS OF OBSTETRICS. Third Edition, Revised.**

**Syllabus of Obstetrical Lectures in the Medical Department of the University of Pennsylvania.** By RICHARD C. NORRIS, A.M., M.D., Demonstrator of Obstetrics, University of Pennsylvania. Crown octavo, 222 pages. Cloth, interleaved for notes, \$2.00 net.

**PENROSE'S DISEASES OF WOMEN. Third Edition, Revised.**

**A Text-Book of Diseases of Women.** By CHARLES B. PENROSE, M.D., PH.D., Formerly Professor of Gynecology in the University of Pennsylvania; Surgeon to the Gynecean Hospital, Philadelphia. Octavo volume of 531 pages, handsomely illustrated. Cloth, \$3.75 net.

"I shall value very highly the copy of Penrose's 'Diseases of Women' received. I have already recommended it to my class as **THE BEST** book."—HOWARD A. KELLY, *Professor of Gynecology and Obstetrics, Johns Hopkins University, Baltimore, Md.*

**POWELL'S DISEASES OF CHILDREN. Second Edition.**

**Essentials of Diseases of Children.** By WILLIAM M. POWELL, M.D., Attending Physician to the Mercer House for Invalid Women at Atlantic City, N. J.; late Physician to the Clinic for the Diseases of Children in the Hospital of the University of Pennsylvania. Crown octavo, 222 pages. Cloth, \$1.00 net; interleaved for notes, \$1.25 net.

[See *Saunders' Question-Compends*, page 21.]

"Contains the gist of all the best works in the department to which it relates."—*American Practitioner and News.*

**PRINGLE'S SKIN DISEASES AND SYPHILITIC AFFECTIONS.**

**Pictorial Atlas of Skin Diseases and Syphilitic Affections (American Edition).** Translation from the French. Edited by J. J. PRINGLE, M.B., F.R.C.P., Assistant Physician to the Middlesex Hospital, London. Photo-lithochromes from the famous models in the Museum of the Saint-Louis Hospital, Paris, with explanatory wood-cuts and text. In 12 Parts. Price per Part, \$3.00. Complete in one volume, Half Morocco binding, \$40.00 net.

"I strongly recommend this Atlas. The plates are exceedingly well executed, and will be of great value to all studying dermatology."—STEPHEN MACKENZIE, M.D.

"The introduction of explanatory wood-cuts in the text is a novel and most important feature which greatly furthers the easier understanding of the excellent plates, than which nothing, we venture to say, has been seen better in point of correctness, beauty, and general merit."—*New York Medical Journal.*

**PRYOR—PELVIC INFLAMMATIONS.**

**The Treatment of Pelvic Inflammations through the Vagina.** By W. R. PRYOR, M.D., Professor of Gynecology in New York Poly-clinic. 12mo, 248 pages, handsomely illustrated. Cloth, \$2.00 net.

"This subject, which has recently been so thoroughly canvassed in high gynecological circles, is made available in this volume to the general practitioner and student. Nothing is too minute for mention and nothing is taken for granted; consequently the book is of the utmost value. The illustrations and the technique are beyond criticism."—*Chicago Medical Recorder.*

**PYE'S BANDAGING.**

**Elementary Bandaging and Surgical Dressing.** With Directions concerning the Immediate Treatment of Cases of Emergency. For the use of Dressers and Nurses. By WALTER PYE, F.R.C.S., late Surgeon to St. Mary's Hospital, London. Small 12mo, with over 80 illustrations. Cloth, flexible covers, 75 cents net.

"The directions are clear and the illustrations are good."—*London Lancet.*

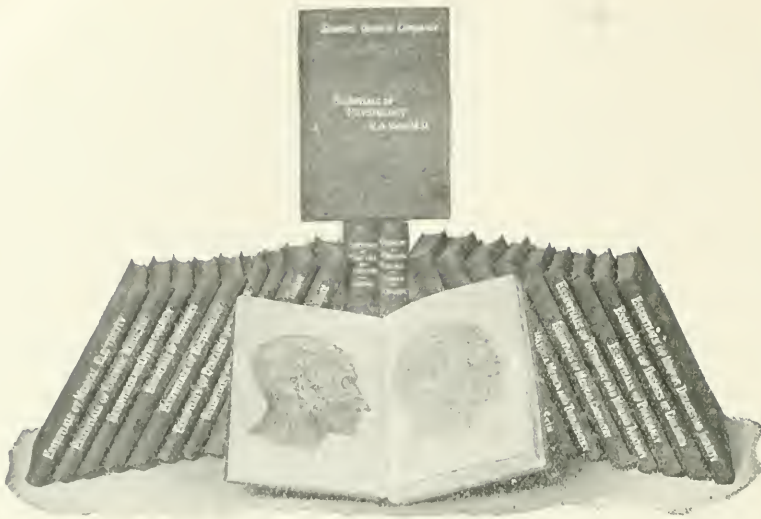
"The author writes well, the diagrams are clear, and the book itself is small and portable, although the paper and type are good."—*British Medical Journal.*

**RAYMOND'S PHYSIOLOGY.**

**A Manual of Physiology.** By JOSEPH H. RAYMOND, A.M., M.D., Professor of Physiology and Hygiene and Lecturer on Gynecology in the Long Island College Hospital; Director of Physiology in the Hoagland Laboratory, etc. 382 pages, with 102 illustrations in the text, and 4 full-page colored plates. Cloth, \$1.25 net.

"Extremely well gotten up, and the illustrations have been selected with care. The text is fully abreast with modern physiology."—*British Medical Journal.*





# SAUNDERS' QUESTION COMPENDS

Arranged in Question and  
Answer Form.

THE MOST COMPLETE AND BEST  
ILLUSTRATED SERIES OF  
COMPENDS EVER ISSUED.

Now the Standard Authorities in Medical Literature . . . .

with Students and Practitioners in every City of the United States and Canada.

OVER 175,000 COPIES SOLD.

## THE REASON WHY.

They are the advance guard of "Student's Helps"—that DO HELP. They are the leaders in their special line, well and authoritatively written by able men, who, as teachers in the large colleges, know exactly what is wanted by a student preparing for his examinations. The judgment exercised in the selection of authors is fully demonstrated by their professional standing. Chosen from the ranks of Demonstrators, Quiz-masters, and Assistants, most of them have become Professors and Lecturers in their respective colleges.

Each book is of convenient size (5 x 7 inches), containing on an average 250 pages, profusely illustrated, and elegantly printed in clear, readable type, on fine paper.

The entire series, numbering twenty-three volumes, has been kept thoroughly revised and enlarged when necessary, many of the books being in their fifth and sixth editions.

## TO SUM UP.

Although there are numerous other Quizzes, Manuals, Aids, etc. in the market, none of them approach the "Blue Series of Question Compends;" and the claim is made for the following points of excellence:

1. Professional distinction and reputation of authors.
2. Conciseness, clearness, and soundness of treatment.
3. Quality of illustrations, paper, printing, and binding.

Any of these Compends will be mailed on receipt of price (see next page for List).

# Saunders' Question-Compend Series.

Price, Cloth, \$1.00 net per copy, except when otherwise ordered.

"Where the work of preparing students' manuals is to end we cannot say, but the Saunders Series, in our opinion, bears off the palm at present."—*New York Medical Record*.

1. **ESSENTIALS OF PHYSIOLOGY.** By H. A. HARE, M.D. Fourth edition, revised and enlarged.
2. **ESSENTIALS OF SURGERY.** By EDWARD MARTIN, M.D. Seventh edition, revised, with an Appendix and a chapter on Appendicitis.
3. **ESSENTIALS OF ANATOMY.** By CHARLES B. NANCREDE, M.D. Sixth edition, thoroughly revised and enlarged.
4. **ESSENTIALS OF MEDICAL CHEMISTRY, ORGANIC AND INORGANIC.** By LAWRENCE WOLFF, M.D. Fifth edition, revised.
5. **ESSENTIALS OF OBSTETRICS.** By W. EASTERLY ASHTON, M.D. Fourth edition, revised and enlarged.
6. **ESSENTIALS OF PATHOLOGY AND MORBID ANATOMY.** By C. E. ARMAND SEMPLE, M.D.
7. **ESSENTIALS OF MATERIA MEDICA, THERAPEUTICS, AND PRESCRIPTION-WRITING.** By HENRY MORRIS, M.D. Fifth edition, revised.
- 8, 9. **ESSENTIALS OF PRACTICE OF MEDICINE.** By HENRY MORRIS, M.D. An Appendix on URINE EXAMINATION. By LAWRENCE WOLFF, M.D. Third edition, enlarged by some 300 Essential Formulæ, selected from eminent authorities, by WM. M. POWELL, M.D. (Double number, \$1.50 net.)
10. **ESSENTIALS OF GYNÆCOLOGY.** By EDWIN B. CRAGIN, M.D. Fourth edition, revised.
11. **ESSENTIALS OF DISEASES OF THE SKIN.** By HENRY W. STELWAGON, M.D. Fourth edition, revised and enlarged.
12. **ESSENTIALS OF MINOR SURGERY, BANDAGING, AND VENEREAL DISEASES.** By EDWARD MARTIN, M.D. Second ed., revised and enlarged.
13. **ESSENTIALS OF LEGAL MEDICINE, TOXICOLOGY, AND HYGIENE.** By C. E. ARMAND SEMPLE, M.D.
14. **ESSENTIALS OF DISEASES OF THE EYE, NOSE, AND THROAT.** By EDWARD JACKSON, M.D., and E. B. GLEASON, M.D. Second ed., revised.
15. **ESSENTIALS OF DISEASES OF CHILDREN.** By WILLIAM M. POWELL, M.D. Second edition.
16. **ESSENTIALS OF EXAMINATION OF URINE.** By LAWRENCE WOLFF, M.D. Colored "VOGEL SCALE." (75 cents net.)
17. **ESSENTIALS OF DIAGNOSIS.** By S. SOLIS COHEN, M.D., and A. A. ESHNER, M.D. Second edition, thoroughly revised.
18. **ESSENTIALS OF PRACTICE OF PHARMACY.** By LUCIUS E. SAYRE. Second edition, revised and enlarged.
20. **ESSENTIALS OF BACTERIOLOGY.** By M. V. BALL, M.D. Third edition, revised.
21. **ESSENTIALS OF NERVOUS DISEASES AND INSANITY.** By JOHN C. SHAW, M.D. Third edition, revised.
22. **ESSENTIALS OF MEDICAL PHYSICS.** By FRED J. BROCKWAY, M.D. Second edition, revised.
23. **ESSENTIALS OF MEDICAL ELECTRICITY.** By DAVID D. STEWART, M.D., and EDWARD S. LAWRENCE, M.D.
24. **ESSENTIALS OF DISEASES OF THE EAR.** By E. B. GLEASON, M.D. Second edition, revised and greatly enlarged.

Pamphlet containing specimen pages, etc. sent free upon application.



Saunders' for Students  
New Series and  
of Manuals Practitioners.

---

THAT there exists a need for thoroughly reliable hand-books on the leading branches of Medicine and Surgery is a fact amply demonstrated by the favor with which the SAUNDERS NEW SERIES OF MANUALS have been received by medical students and practitioners and by the Medical Press. These manuals are not merely condensations from present literature, but are ably written by well-known authors and practitioners, most of them being teachers in representative American colleges. Each volume is concisely and authoritatively written and exhaustive in detail, without being encumbered with the introduction of "cases," which so largely expand the ordinary text-book. These manuals will therefore form an admirable collection of advanced lectures, useful alike to the medical student and the practitioner: to the latter, too busy to search through page after page of elaborate treatises for what he wants to know, they will prove of inestimable value; to the former they will afford safe guides to the essential points of study.

The SAUNDERS NEW SERIES OF MANUALS are conceded to be superior to any similar books now on the market. No other manuals afford so much information in such a concise and available form. A liberal expenditure has enabled the publisher to render the mechanical portion of the work worthy of the high literary standard attained by these books.

Any of these Manuals will be mailed on receipt of price (see next page for List).

# Saunders' New Series of Manuals.

---

## VOLUMES PUBLISHED.

- PHYSIOLOGY.** By JOSEPH HOWARD RAYMOND, A.M., M.D., Professor of Physiology and Hygiene and Lecturer on Gynecology in the Long Island College Hospital; Director of Physiology in the Hoagland Laboratory, etc. Illustrated. Cloth, \$1.25 net.
- SURGERY, General and Operative.**—By JOHN CHALMERS DACOSTA, M.D., Professor of Practice of Surgery and Clinical Surgery, Jefferson Medical College, Philadelphia; Surgeon to the Philadelphia Hospital, etc. Second edition, thoroughly revised and greatly enlarged. Octavo, 911 pages, profusely illustrated. Cloth, \$4.00 net; Half Morocco, \$5.00 net.
- DOSE-BOOK AND MANUAL OF PRESCRIPTION-WRITING.** By E. Q. THORNTON, M.D., Demonstrator of Therapeutics, Jefferson Medical College, Philadelphia. Illustrated. Cloth, \$1.25 net.
- SURGICAL ASEPSIS.** By CARL BECK, M.D., Surgeon to St. Mark's Hospital and to the New York German Poliklinik, etc. Illustrated. Cloth, \$1.25 net.
- MEDICAL JURISPRUDENCE.** By HENRY C. CHAPMAN, M.D. Professor of Institutes of Medicine and Medical Jurisprudence in the Jefferson Medical College of Philadelphia. Illustrated. Cloth, \$1.50 net.
- SYPHILIS AND THE VENEREAL DISEASES.** By JAMES NEVINS HYDE, M.D., Professor of Skin and Venereal Diseases, and FRANK H. MONTGOMERY, M.D., Lecturer on Dermatology and Genito-Urinary Diseases in Rush Medical College, Chicago. Second edition, thoroughly revised and greatly enlarged.
- PRACTICE OF MEDICINE.** By GEORGE ROE LOCKWOOD, M.D., Professor of Practice in the Woman's Medical College of the New York Infirmary; Instructor in Physical Diagnosis in the Medical Department of Columbia College, etc. Illustrated. Cloth, \$2.50 net.
- MANUAL OF ANATOMY.** By IRVING S. HAYNES, M.D., Adjunct Professor of Anatomy and Demonstrator of Anatomy, Medical Department of the New York University, etc. Beautifully illustrated. Cloth, \$2.50 net.
- MANUAL OF OBSTETRICS.** By W. A. NEWMAN DORLAND, M.D., Assistant Demonstrator of Obstetrics, University of Pennsylvania; Chief of Gynecological Dispensary, Pennsylvania Hospital, etc. Profusely illustrated. Cloth, \$2.50 net.
- DISEASES OF WOMEN.** By J. BLAND SUTTON, F.R.C.S., Assistant Surgeon to Middlesex Hospital and Surgeon to Chelsea Hospital, London; and ARTHUR E. GILES, M.D., B.Sc. Lond., F.R.C.S. Edin., Assistant Surgeon to Chelsea Hospital, London. Handsomely illustrated. Cloth, \$2.50 net.

---

## VOLUMES IN PREPARATION.

- NERVOUS DISEASES.** By CHARLES W. BURR, M.D., Clinical Professor of Nervous Diseases, Medico-Chirurgical College, Philadelphia; Pathologist to the Orthopaedic Hospital and Infirmary for Nervous Diseases; Visiting Physician to the St. Joseph Hospital, etc.

\*<sub>3</sub>\* There will be published in the same series, at short intervals, carefully-prepared works on various subjects by prominent specialists.

---

Pamphlet containing specimen pages, etc. sent free upon application.



**SAUNDBY'S RENAL AND URINARY DISEASES.**

**Lectures on Renal and Urinary Diseases.** By ROBERT SAUNDBY, M.D. Edin., Fellow of the Royal College of Physicians, London, and of the Royal Medico-Chirurgical Society; Physician to the General Hospital; Consulting Physician to the Eye Hospital and to the Hospital for Diseases of Women; Professor of Medicine in Mason College, Birmingham, etc. Octavo volume of 434 pages, with numerous illustrations and 4 colored plates. Cloth, \$2.50 net.

"The volume makes a favorable impression at once. The style is clear and succinct. We cannot find any part of the subject in which the views expressed are not carefully thought out and fortified by evidence drawn from the most recent sources. The book may be cordially recommended."—*British Medical Journal*.

**SAUNDERS' MEDICAL HAND-ATLASES.**

For full description of this series, with list of volumes and prices, see page 2.

"Lehmann Medicinische Handatlanten belong to that class of books that are too good to be appropriated by any one nation."—*Journal of Eye, Ear, and Throat Diseases*.

"The appearance of these works marks a new era in illustrated English medical works."—*The Canadian Practitioner*.

**SAUNDERS' POCKET MEDICAL FORMULARY. Sixth Edition, Revised.**

By WILLIAM M. POWELL, M.D., Attending Physician to the Mercer House for Invalid Women at Atlantic City, N. J. Containing 1800 formulæ selected from the best-known authorities. With an Appendix containing Posological Table, Formulæ and Doses for Hypodermic Medication, Poisons and their Antidotes, Diameters of the Female Pelvis and Fœtal Head, Obstetrical Table, Diet List for Various Diseases, Materials and Drugs used in Antiseptic Surgery, Treatment of Asphyxia from Drowning, Surgical Remembrancer, Tables of Incompatibles, Eruptive Fevers, Weights and Measures, etc. Handsomely bound in flexible morocco, with side index, wallet, and flap. \$1.75 net.

"This little book, that can be conveniently carried in the pocket, contains an immense amount of material. It is very useful, and, as the name of the author of each prescription is given, is unusually reliable."—*Medical Record*, New York.

**SAYRE'S PHARMACY. Second Edition, Revised.**

**Essentials of the Practice of Pharmacy.** By LUCIUS E. SAYRE, M.D., Professor of Pharmacy and Materia Medica in the University of Kansas. Crown octavo, 200 pages. Cloth, \$1.00 net; interleaver for notes, \$1.25 net.

[See *Saunders' Question-Compends*, page 21.]

"The topics are treated in a simple, practical manner, and the work forms a very useful student's manual."—*Boston Medical and Surgical Journal*.

**SCUDDER'S FRACTURES.**

**The Treatment of Fractures.** By CHAS. L. SCUDDER, M.D., Assistant in Clinical and Operative Surgery, Harvard Medical School. Octavo, 433 pages, with nearly 600 original illustrations. Cloth, \$4.50 net.

**SEMPLE'S LEGAL MEDICINE, TOXICOLOGY, AND HYGIENE.**

**Essentials of Legal Medicine, Toxicology, and Hygiene.** By C. E. ARMAND SEMPLE, B.A., M.B. Cantab., M.R.C.P. Lond., Physician to the Northeastern Hospital for Children, Hackney, etc. Crown octavo, 212 pages; 130 illustrations. Cloth, \$1.00 net; interleaved for notes, \$1.25 net.

[See *Saunders' Question-Compends*, page 21.]

"No general practitioner or student can afford to be without this valuable work. The subjects are dealt with by a masterly hand."—*London Hospital Gazette*.

**SEMPLE'S PATHOLOGY AND MORBID ANATOMY.**

**Essentials of Pathology and Morbid Anatomy.** By C. E. ARMAND SEMPLE, B.A., M.B. Cantab., M.R.C.P. Lond., Physician to the Northeastern Hospital for Children, Hackney, etc. Crown octavo, 174 pages; illustrated. Cloth, \$1.00 net; interleaved for notes, \$1.25 net.

[See *Saunders' Question-Compends*, page 21.]

"Should take its place among the standard volumes on the bookshelf of both student and practitioner."—*London Hospital Gazette*.

**SENN'S GENITO-URINARY TUBERCULOSIS.**

**Tuberculosis of the Genito-Urinary Organs, Male and Female.** By NICHOLAS SENN, M.D., PH.D., LL.D., Professor of the Practice of Surgery and of Clinical Surgery, Rush Medical College, Chicago. Handsome octavo volume of 320 pages, illustrated. Cloth, \$3.00 net.

"An important book upon an important subject, and written by a man of mature judgment and wide experience. The author has given us an instructive book upon one of the most important subjects of the day."—*Clinical Reporter*.

"A work which adds another to the many obligations the profession owes the talented author."—*Chicago Medical Recorder*.

**SENN'S SYLLABUS OF SURGERY.**

**A Syllabus of Lectures on the Practice of Surgery, arranged in conformity with "An American Text-Book of Surgery."** By NICHOLAS SENN, M.D., PH.D., Professor of the Practice of Surgery and of Clinical Surgery, Rush Medical College, Chicago. Cloth, \$1.50 net.

"This syllabus will be found of service by the teacher as well as the student, the work being superbly done. There is no praise too high for it. No surgeon should be without it."—*New York Medical Times*.

**SENN'S TUMORS. Second Edition, Revised.**

**Pathology and Surgical Treatment of Tumors.** By N. SENN, M.D., PH.D., LL.D., Professor of Surgery and of Clinical Surgery, Rush Medical College; Professor of Surgery, Chicago Polyclinic; Attending Surgeon to Presbyterian Hospital; Surgeon-in-Chief, St. Joseph's Hospital, Chicago. *Second Edition, Thoroughly Revised.* Octavo volume of 718 pages, with 478 illustrations, including 12 full-page plates in colors. Prices: Cloth, \$5.00 net; Half Morocco, \$6.00 net.

"The most exhaustive of any recent book in English on this subject. It is well illustrated, and will doubtless remain as the principal monograph on the subject in our language for some years. The book is handsomely illustrated and printed, and the author has given a notable and lasting contribution to surgery."—*Journal of the American Medical Association*.

**SHAW'S NERVOUS DISEASES AND INSANITY. Third Edition, Revised.**

**Essentials of Nervous Diseases and Insanity.** By JOHN C. SHAW, M.D., Clinical Professor of Diseases of the Mind and Nervous System, Long Island College Hospital Medical School; Consulting Neurologist to St. Catherine's Hospital and to the Long Island College Hospital. Crown octavo, 186 pages; 48 original illustrations. Cloth, \$1.00 net; interleaved for notes, \$1.25 net.

[See *Saunders' Question-Compends*, page 21.]

"Clearly and intelligently written."—*Boston Medical and Surgical Journal*.

"There is a mass of valuable material crowded into this small compass."—*American Medico-Surgical Bulletin*.

**STARR'S DIETS FOR INFANTS AND CHILDREN.**

**Diets for Infants and Children in Health and in Disease.** By LOUIS STARR, M.D., Editor of "An American Text-Book of the Diseases of Children." 230 blanks (pocket-book size), perforated and neatly bound in flexible morocco. \$1.25 net.

The first series of blanks are prepared for the first seven months of infant life; each blank indicates the ingredients, but not the quantities, of the food, the latter directions being left for the physician. After the seventh month, modifications being less necessary, the diet lists are printed in full. Formulæ for the preparation of diluents and foods are appended.

**STELWAGON'S DISEASES OF THE SKIN. Fourth Ed., Revised.**

**Essentials of Diseases of the Skin.** By HENRY W. STELWAGON, M.D., Clinical Professor of Dermatology in the Jefferson Medical College, Philadelphia; Dermatologist to the Philadelphia Hospital; Physician to the Skin Department of the Howard Hospital, etc. Crown octavo, 276 pages; 88 illustrations. Cloth, \$1.00 net; interleaved for notes, \$1.25 net.

[See *Saunders' Question-Compends*, page 21.]

"The best student's manual on skin diseases we have yet seen."—*Times and Register*.

**STENGEL'S PATHOLOGY. Second Edition.**

**A Text-Book of Pathology.** By ALFRED STENGEL, M.D., Professor of Clinical Medicine in the University of Pennsylvania; Physician to the Philadelphia Hospital; Physician to the Children's Hospital, etc. Handsome octavo volume of 848 pages, with nearly 400 illustrations, many of them in colors. Cloth, \$4.00 net; Half Morocco, \$5.00 net.

**STEVENS' MATERIA MEDICA AND THERAPEUTICS. Second Edition, Revised.**

**A Manual of Materia Medica and Therapeutics.** By A. A. STEVENS, A.M., M.D., Lecturer on Terminology and Instructor in Physical Diagnosis in the University of Pennsylvania; Professor of Pathology in the Woman's Medical College of Pennsylvania. Post-octavo, 445 pages. Flexible leather, \$2.00 net.

"The author has faithfully presented modern therapeutics in a comprehensive work, and, while intended particularly for the use of students, it will be found a reliable guide and equally comprehensive for the physician in practice."—*University Medical Magazine*.

**STEVENS' PRACTICE OF MEDICINE. Fifth Edition, Revised.**

**A Manual of the Practice of Medicine.** By A. A. STEVENS, A. M., M. D., Lecturer on Terminology and Instructor in Physical Diagnosis in the University of Pennsylvania; Professor of Pathology in the Woman's Medical College of Pennsylvania. Specially intended for students preparing for graduation and hospital examinations. Post-octavo, 519 pages; illustrated. Flexible leather, \$2.00 net.

"The frequency with which new editions of this manual are demanded bespeaks its popularity. It is an excellent condensation of the essentials of medical practice for the student, and may be found also an excellent reminder for the busy physician."—*Buffalo Medical Journal*.

**STEWART'S PHYSIOLOGY. Third Edition, Revised.**

**A Manual of Physiology, with Practical Exercises. For Students and Practitioners.** By G. N. STEWART, M.A., M.D., D.Sc., lately Examiner in Physiology, University of Aberdeen, and of the New Museums, Cambridge University; Professor of Physiology in the Western Reserve University, Cleveland, Ohio. Octavo volume of 848 pages; 300 illustrations in the text, and 5 colored plates. Cloth, \$3.75 net.

"It will make its way by sheer force of merit, and amply deserves to do so. It is one of the very best English text-books on the subject."—*London Lancet*.

"Of the many text-books of physiology published, we do not know of one that so nearly comes up to the ideal as does Prof. Stewart's volume."—*British Medical Journal*.

**STEWART AND LAWRENCE'S MEDICAL ELECTRICITY.**

**Essentials of Medical Electricity.** By D. D. STEWART, M.D., Demonstrator of Diseases of the Nervous System and Chief of the Neurological Clinic in the Jefferson Medical College; and E. S. LAWRENCE, M.D., Chief of the Electrical Clinic and Assistant Demonstrator of Diseases of the Nervous System in the Jefferson Medical College, etc. Crown octavo, 158 pages; 65 illustrations. Cloth, \$1.00 net; interleaved for notes, \$1.25 net.

[See *Saunders' Question-Compends*, page 21.]

"Throughout the whole brief space at their command the authors show a discriminating knowledge of their subject."—*Medical News*.

**STONE'S NURSING. Second Edition, Revised.**

**Practical Points in Nursing. For Nurses in Private Practice.** By EMILY A. M. STONEY, Graduate of the Training-School for Nurses, Lawrence, Mass.; late Superintendent of the Training-School for Nurses, Carney Hospital, South Boston, Mass. 456 pages, illustrated with 73 engravings in the text, and 8 colored and half-tone plates. Cloth, \$1.75 net.

"There are few books intended for non-professional readers which can be so cordially endorsed by a medical journal as can this one."—*Therapeutic Gazette*.

"This is a well-written, eminently practical volume, which covers the entire range of private nursing as distinguished from hospital nursing, and instructs the nurse how best to meet the various emergencies which may arise, and how to prepare everything ordinarily needed in the illness of her patient."—*American Journal of Obstetrics and Diseases of Women and Children*.

"It is a work that the physician can place in the hands of his private nurses with the assurance of benefit."—*Ohio Medical Journal*.



**STONE'S MATERIA MEDICA FOR NURSES.**

**Materia Medica for Nurses.** By EMILY A. M. STONEY, Graduate of the Training-School for Nurses, Lawrence, Mass. ; late Superintendent of the Training-School for Nurses, Carney Hospital, South Boston, Mass. Handsome octavo volume of 306 pages. Cloth, \$1.50 net.

The present book differs from other similar works in several features, all of which are intended to render it more practical and generally useful. The general plan of the contents follows the lines laid down in training-schools for nurses, but the book contains much useful matter not usually included in works of this character, such as Poison-emergencies, Ready Dose-list, Weights and Measures, etc., as well as a Glossary, defining all the terms used in Materia Medica, and describing all the latest drugs and remedies, which have been generally neglected by other books of the kind.

**SUTTON AND GILES' DISEASES OF WOMEN.**

**Diseases of Women.** By J. BLAND SUTTON, F.R.C.S., Assistant Surgeon to Middlesex Hospital, and Surgeon to Chelsea Hospital, London ; and ARTHUR E. GILES, M.D., B.Sc. Lond., F.R.C.S. Edin., Assistant Surgeon to Chelsea Hospital, London. 436 pages, handsomely illustrated. Cloth, \$2.50 net.

"The text has been carefully prepared. Nothing essential has been omitted, and its teachings are those recommended by the leading authorities of the day."—*Journal of the American Medical Association.*

**THOMAS'S DIET LISTS. Second Edition, Revised.**

**Diet Lists and Sick-Room Dietary.** By JEROME B. THOMAS, M.D., Visiting Physician to the Home for Friendless Women and Children and to the Newsboys' Home ; Assistant Visiting Physician to the Kings County Hospital. Cloth, \$1.25 net. Send for sample sheet.

**THORNTON'S DOSE-BOOK AND PRESCRIPTION-WRITING.**

**Dose-Book and Manual of Prescription-Writing.** By E. Q. THORNTON, M.D., Demonstrator of Therapeutics, Jefferson Medical College, Philadelphia. 334 pages, illustrated. Cloth, \$1.25 net.

"Full of practical suggestions ; will take its place in the front rank of works of this sort."—*Medical Record, New York.*

**VAN VALZAH AND NISBET'S DISEASES OF THE STOMACH.**

**Diseases of the Stomach.** By WILLIAM W. VAN VALZAH, M.D., Professor of General Medicine and Diseases of the Digestive System and the Blood, New York Polyclinic ; and J. DOUGLAS NISBET, M.D., Adjunct Professor of General Medicine and Diseases of the Digestive System and the Blood, New York Polyclinic. Octavo volume of 674 pages, illustrated. Cloth, \$3.50 net.

"Its chief claim lies in its clearness and general adaptability to the practical needs of the general practitioner or student. In these relations it is probably the best of the recent special works on diseases of the stomach."—*Chicago Clinical Review.*

**VECKI'S SEXUAL IMPOTENCE.**

**The Pathology and Treatment of Sexual Impotence.** By VICTOR G. VECKI, M.D. From the second German edition, revised and enlarged. Demi-octavo, 201 pages. Cloth, \$2.00 net.

The subject of impotence has seldom been treated in this country in the truly scientific spirit that it deserves. Dr. Vecki's work has long been favorably known, and the German book has received the highest consideration. This edition is more than a mere translation, for, although based on the German edition, it has been entirely rewritten in English.

**VIERORDT'S MEDICAL DIAGNOSIS. Fourth Edition, Revised.**

**Medical Diagnosis.** By Dr. OSWALD VIERORDT, Professor of Medicine at the University of Heidelberg. Translated, with additions, from the fifth enlarged German edition, with the author's permission, by FRANCIS H. STUART, A. M., M. D. Handsome royal octavo volume of 603 pages; 194 fine wood-cuts in text, many of them in colors. Cloth, \$4.00 net; Sheep or Half Morocco, \$5.00 net.

"Rarely is a book published with which a reviewer can find so little fault as with the volume before us. Each particular item in the consideration of an organ or apparatus, which is necessary to determine a diagnosis of any disease of that organ, is mentioned; nothing seems forgotten. The chapters on diseases of the circulatory and digestive apparatus and nervous system are especially full and valuable. The reviewer would repeat that the book is one of the best—probably *the best*—which has fallen into his hands."—*University Medical Magazine*.

**WATSON'S HANDBOOK FOR NURSES.**

**A Handbook for Nurses.** By J. K. WATSON, M.D., Edin. American Edition, under supervision of A. A. STEVENS, A. M., M. D., Lecturer on Physical Diagnosis, University of Pennsylvania. 12mo, 413 pages, 73 illustrations. Cloth, \$1.50 net.

**WARREN'S SURGICAL PATHOLOGY. Second Edition.**

**Surgical Pathology and Therapeutics.** By JOHN COLLINS WARREN, M.D., LL.D., Professor of Surgery, Harvard Medical School. Handsome octavo, 832 pages; 136 relief and lithographic illustrations, 33 in colors; with an Appendix on Scientific Aids to Surgical Diagnosis, and a series of articles on Regional Bacteriology. Cloth, \$5.00 net; Half Morocco, \$6.00 net.

"A most striking and very excellent feature of this book is its illustrations. Without exception, from the point of accuracy and artistic merit, they are the best ever seen in a work of this kind. Many of those representing microscopic pictures are so perfect in their coloring and detail as almost to give the beholder the impression that he is looking down the barrel of a microscope at a well-mounted section."—*Annals of Surgery*.

**WOLFF ON EXAMINATION OF URINE.**

**Essentials of Examination of Urine.** By LAWRENCE WOLFF, M.D., Demonstrator of Chemistry, Jefferson Medical College, Philadelphia, etc. Colored (Vogel) urine scale and numerous illustrations. Crown octavo. Cloth, 75 cents net.

[See *Saunders' Question-Compends*, page 21.]

"A very good work of its kind—very well suited to its purpose."—*Times and Register*.

**WOLFF'S MEDICAL CHEMISTRY. Fifth Edition, Revised.**

**Essentials of Medical Chemistry, Organic and Inorganic.** Containing also Questions on Medical Physics, Chemical Physiology, Analytical Processes, Urinalysis, and Toxicology. By LAWRENCE WOLFF, M.D., Demonstrator of Chemistry, Jefferson Medical College, Philadelphia, etc. Crown octavo, 222 pages. Cloth, \$1.00 net; interleaved for notes, \$1.25 net.

[See *Saunders' Question-Compends*, page 21.]

"The scope of this work is certainly equal to that of the best course of lectures on Medical Chemistry."—*Pharmaceutical Era*.

CLASSIFIED LIST  
OF THE  
**MEDICAL PUBLICATIONS**

OF  
**W. B. SAUNDERS & COMPANY,**  
925 Walnut Street, Philadelphia.

**ANATOMY, EMBRYOLOGY,  
HISTOLOGY.**

|                                                                             |    |
|-----------------------------------------------------------------------------|----|
| Clarkson—A Text-Book of Histology, . . .                                    | 11 |
| Haynes—A Manual of Anatomy, . . .                                           | 15 |
| Heisler—A Text-Book of Embryology, . . .                                    | 15 |
| Nancrede—Essentials of Anatomy, . . .                                       | 20 |
| Nancrede—Essentials of Anatomy and<br>Manual of Practical Dissection, . . . | 20 |
| Semple—Essentials of Pathology, . . .                                       | 27 |

**BACTERIOLOGY.**

|                                                       |    |
|-------------------------------------------------------|----|
| Ball—Essentials of Bacteriology, . . .                | 8  |
| Crookshank—A Text-Book of Bacteri-<br>ology, . . .    | 12 |
| Frothingham—Laboratory Guide, . . .                   | 13 |
| Levy and Klempner's Clinical Bacte-<br>riology, . . . | 17 |
| Mallory and Wright—Pathological<br>Technique, . . .   | 18 |
| McFarland—Pathogenic Bacteria, . . .                  | 10 |

**CHARTS, DIET-LISTS, ETC.**

|                                           |    |
|-------------------------------------------|----|
| Griffith—Infant's Weight Chart, . . .     | 14 |
| Hart—Diet in Sickness and in Health, . .  | 15 |
| Keen—Operation Blank, . . .               | 17 |
| Lainé—Temperature Chart, . . .            | 17 |
| Meigs—Feeding in Early Infancy, . . .     | 19 |
| Starr—Diets for Infants and Children, . . | 28 |
| Thomas—Diet-Lists, . . .                  | 30 |

**CHEMISTRY AND PHYSICS.**

|                                                    |    |
|----------------------------------------------------|----|
| Brockway—Essentials of Medical Phys-<br>ics, . . . | 0  |
| Wolff—Essentials of Medical Chemistry, .           | 31 |

**CHILDREN.**

|                                                         |    |
|---------------------------------------------------------|----|
| An American Text-Book of Diseases<br>of Children, . . . | 5  |
| Griffith—Care of the Baby, . . .                        | 14 |
| Griffith—Infant's Weight Chart, . . .                   | 14 |
| Meigs—Feeding in Early Infancy, . . .                   | 19 |
| Powell—Essentials of Dis. of Children, .                | 21 |
| Starr—Diets for Infants and Children, . .               | 28 |

**DIAGNOSIS.**

|                                                      |    |
|------------------------------------------------------|----|
| Cohen and Eshner—Essentials of Di-<br>agnosis, . . . | 11 |
| Corwin—Physical Diagnosis, . . .                     | 11 |
| Macdonald—Surgical Diagnosis and<br>Treatment, . . . | 18 |
| Vierordt—Medical Diagnosis, . . .                    | 31 |

**DICTIONARIES.**

|                                      |    |
|--------------------------------------|----|
| Dorland—Pocket Dictionary, . . .     | 12 |
| Keating—Framingham Dictionary, . . . | 10 |
| Mueten—Nurse's Dictionary, . . .     | 20 |

**EYE, EAR, NOSE, AND THROAT.**

|                                                                               |    |
|-------------------------------------------------------------------------------|----|
| An American Text-Book of Diseases<br>of the Eye, Ear, Nose, and Throat, . . . | 5  |
| De Schweinitz—Diseases of the Eye, . .                                        | 12 |
| Gleason—Essentials of Dis. of the Ear, .                                      | 13 |
| Jackson—Manual of Diseases of Eye, . .                                        | 16 |
| Jackson and Gleason—Essentials of<br>Diseases of the Eye, Nose, and Throat, . | 16 |
| Kyle—Diseases of the Nose and Throat, .                                       | 17 |

**GENITO-URINARY.**

|                                                                              |    |
|------------------------------------------------------------------------------|----|
| An American Text-Book of Genito-<br>Urinary and Skin Diseases, . . . . .     | 6  |
| Hyde and Montgomery—Syphilis and<br>the Venereal Diseases, . . . . .         | 15 |
| Martin—Essentials of Minor Surgery,<br>Bandaging, and Venereal Diseases, . . | 18 |
| Saundby—Renal and Urinary Diseases, .                                        | 20 |
| Senn—Genito-Urinary Tuberculosis, . .                                        | 27 |
| Vecki—Sexual Impotence, . . . . .                                            | 30 |

**GYNECOLOGY.**

|                                         |    |
|-----------------------------------------|----|
| American Text-Book of Gynecology, . . . | 6  |
| Cragin—Essentials of Gynecology, . . .  | 11 |
| Garrigues—Diseases of Women, . . . .    | 13 |
| Long—Syllabus of Gynecology, . . . .    | 17 |
| Penrose—Diseases of Women, . . . . .    | 20 |
| Pryor—Pelvic Inflammations, . . . . .   | 34 |
| Sutton and Giles—Diseases of Women, .   | 30 |

**MATERIA MEDICA, PHARMACOL-  
OGY, AND THERAPEUTICS.**

|                                                                               |    |
|-------------------------------------------------------------------------------|----|
| An American Text-Book of Applied<br>Therapeutics, . . . . .                   | 5  |
| Butler—Text-Book of Materia Medica,<br>Therapeutics and Pharmacology, . . . . | 10 |
| Cerna—Notes on the Newer Remedies, .                                          | 10 |
| Griffin—Materia Med. and Therapeutics, .                                      | 14 |
| Morris—Essentials of Materia Medica<br>and Therapeutics, . . . . .            | 19 |
| Saunders' Pocket Medical Formulary, . .                                       | 20 |
| Sayre—Essentials of Pharmacy, . . . . .                                       | 20 |
| Stevens—Essentials of Materia Medica<br>and Therapeutics, . . . . .           | 28 |
| Stoney—Materia Medica for Nurses, . . .                                       | 30 |
| Thornton—Dose-Book and Manual of<br>Prescription-Writing, . . . . .           | 30 |

**MEDICAL JURISPRUDENCE AND  
TOXICOLOGY.**

|                                                                            |    |
|----------------------------------------------------------------------------|----|
| Chapman—Medical Jurisprudence and<br>Toxicology, . . . . .                 | 10 |
| Semple—Essentials of Legal Medicine,<br>Toxicology, and Hygiene, . . . . . | 27 |

**NERVOUS AND MENTAL DISEASES, ETC.**

Burr—Nervous Diseases, . . . . . 9  
 Chapin—Compendium of Insanity, . . 10  
 Church and Peterson—Nervous and Mental Diseases, . . . . . 10  
 Shaw—Essentials of Nervous Diseases and Insanity, . . . . . 28

**NURSING.**

Griffith—The Care of the Baby, . . . 14  
 Hampton—Nursing, . . . . . 14  
 Hart—Diet in Sickness and in Health, 15  
 Meigs—Feeding in Early Infancy, . . 19  
 Morten—Nurse's Dictionary, . . . . 20  
 Stoney—Materia Medica for Nurses, . . 30  
 Stoney—Practical Points in Nursing, . 29  
 Watson—Handbook for Nurses, . . . . 31

**OBSTETRICS.**

An American Text-Book of Obstetrics, 6  
 Ashton—Essentials of Obstetrics, . . . 8  
 Boisliniere—Obstetric Accidents, . . . 9  
 Dorland—Manual of Obstetrics, . . . . 12  
 Hirst—Text-Book of Obstetrics, . . . . 15  
 Norris—Syllabus of Obstetrics, . . . . 20

**PATHOLOGY.**

An American Text-Book of Pathology, 7  
 Mallory and Wright—Pathological Technique, . . . . . 18  
 Semple—Essentials of Pathology and Morbid Anatomy, . . . . . 27  
 Senn—Pathology and Surgical Treatment of Tumors, . . . . . 27  
 Stengel—Text-Book of Pathology, . . . 28  
 Warren—Surgical Pathology and Therapeutics, . . . . . 31

**PHYSIOLOGY.**

An American Text-Book of Physiology, . . . . . 7  
 Hare—Essentials of Physiology, . . . . 14  
 Raymond—Manual of Physiology, . . . 21  
 Stewart—Manual of Physiology, . . . . 29

**PRACTICE OF MEDICINE.**

An American Text-Book of the Theory and Practice of Medicine, . . . . 7  
 An American Year-Book of Medicine and Surgery, . . . . . 8  
 Anders—Text-Book of the Practice of Medicine, . . . . . 8  
 Lockwood—Manual of the Practice of Medicine, . . . . . 17  
 Morris—Essentials of the Practice of Medicine, . . . . . 19  
 Stevens—Manual of the Practice of Medicine, . . . . . 29

**SKIN AND VENEREAL.**

An American Text-Book of Genito-Urinary and Skin Diseases, . . . . . 5  
 Hyde and Montgomery—Syphilis and the Venereal Diseases, . . . . . 15

Martin—Essentials of Minor Surgery, Bandaging, and Venereal Diseases, . 18  
 Pringle—Pictorial Atlas of Skin Diseases and Syphilitic Affections, . . . 21  
 Stelwagon—Essentials of Diseases of the Skin, . . . . . 28

**SURGERY.**

An American Text-Book of Surgery, 7  
 An American Year-Book of Medicine and Surgery, . . . . . 8  
 Beck—Fractures, . . . . . 9  
 Beck—Manual of Surgical Asepsis, . . . 9  
 DaCosta—Manual of Surgery, . . . . . 12  
 International Text-Book of Surgery, . 15  
 Keen—Operation Blank, . . . . . 17  
 Keen—The Surgical Complications and Sequels of Typhoid Fever, . . . . . 17  
 Macdonald—Surgical Diagnosis and Treatment, . . . . . 18  
 Martin—Essentials of Minor Surgery, Bandaging, and Venereal Diseases, . 18  
 Martin—Essentials of Surgery, . . . . . 18  
 Moore—Orthopedic Surgery, . . . . . 19  
 Nancrede—Principles of Surgery, . . . 20  
 Pye—Bandaging and Surgical Dressing, 21  
 Scudder—Treatment of Fractures, . . . 26  
 Senn—Genito-Urinary Tuberculosis, . . 27  
 Senn—Syllabus of Surgery, . . . . . 27  
 Senn—Pathology and Surgical Treatment of Tumors, . . . . . 27  
 Warren—Surgical Pathology and Therapeutics, . . . . . 31

**URINE AND URINARY DISEASES.**

Saundby—Renal and Urinary Diseases, 26  
 Wolff—Essentials of Examination of Urine, . . . . . 31

**MISCELLANEOUS.**

Abbott—Hygiene of Transmissible Diseases, . . . . . 8  
 Bastin—Laboratory Exercises in Botany, . . . . . 9  
 Gould and Pyle—Anomalies and Curiosities of Medicine, . . . . . 13  
 Grafstrom—Massage, . . . . . 14  
 Keating—How to Examine for Life Insurance, . . . . . 16  
 Rowland and Hedley—Archives of the Roentgen Ray, . . . . . 21  
 Saunders' Medical Hand-Atlases, . 2, 3, 4  
 Saunders' New Series of Manuals, . 24, 25  
 Saunders' Pocket Medical Formulary, . 26  
 Saunders' Question-Compend, . . . . . 22, 23  
 Senn—Pathology and Surgical Treatment of Tumors, . . . . . 27  
 Stewart and Lawrance—Essentials of Medical Electricity, . . . . . 29  
 Thornton—Dose-Book and Manual of Prescription-Writing, . . . . . 30  
 Van Valzah and Nisbet—Diseases of the Stomach, . . . . . 30



# BOOKS JUST ISSUED.

## THE AMERICAN ILLUSTRATED MEDICAL DICTIONARY.

**For Students and Practitioners.** A Complete Dictionary of the Terms used in Medicine and the Allied Sciences, with a large number of Valuable Tables and Numerous Handsome Illustrations. Edited by W. A. NEWMAN DORLAND, M. D., Editor of the American Pocket Medical Dictionary. Handsome large octavo, 800 pages, bound in full limp leather, and printed on thin paper of the finest quality, forming a handy volume, only 1  $\frac{1}{4}$  inches thick.

This is an entirely new and unique work, intended to meet the need of practitioners and students for a complete, up-to-date dictionary of moderate price. The book is designed to furnish a maximum amount of matter in a minimum space and at the lowest possible cost. It contains double the material in the ordinary students' dictionary, and yet, by the use of a clear, condensed type and thin paper of the finest quality, is only 1  $\frac{1}{4}$  inches in thickness. It is bound in full flexible leather, and is just the kind of a book that a man will want to keep on his desk for constant reference. The book makes a special feature of the newer words, and defines hundreds of important terms not to be found in any other dictionary. It is especially full in the matter of tables, containing more than a hundred of great practical value. A new feature is the inclusion of numerous handsome illustrations, many of them in colors, drawn and engraved specially for this book. These have been chosen with great care and add infinitely to the value of the work. The book will appeal to both practitioners and students, since, besides a complete vocabulary, it gives to the more important subjects extended consideration of an encyclopedic character.

## BÖHM, DAVIDOFF, AND HUBER'S HISTOLOGY.

**A Text-Book of Human Histology.** Including Microscopic Technic. By DR. A. A. BÖHM and DR. M. VON DAVIDOFF, of Munich, and G. C. HUBER, M. D., Junior Professor of Anatomy and Histology, University of Michigan.

## FRIEDRICH AND CURTIS ON THE NOSE, THROAT, AND EAR.

**Rhinology, Laryngology, and Otology in their Relations to General Medicine.** By DR. E. P. FRIEDRICH, of the University of Leipsig. Edited by H. HOLBROOK CURTIS, M. D., Consulting Surgeon to the New York Nose and Throat Hospital.

## LEROY'S HISTOLOGY.

**The Essentials of Histology.** By LOUIS LEROY, M. D., Professor of Histology and Pathology, Vanderbilt University, Nashville, Tennessee.

## OGDEN ON THE URINE.

**Clinical Examination of the Urine.** By J. BERGEN OGDEN, M. D., Assistant in Chemistry, Harvard Medical School. Handsome octavo volume of over 408 pages, with 54 illustrations and 11 full-page plates, many in colors.

## PYLE'S PERSONAL HYGIENE.

**A Manual of Personal Hygiene.** Edited by WALTER L. PYLE, M. D., Assistant Surgeon to Wills Eye Hospital, Philadelphia. Octavo volume of 344 pages, fully illustrated.

## SALINGER AND KALTEYER'S MODERN MEDICINE.

**Modern Medicine.** By JULIUS L. SALINGER, M. D., Demonstrator of Clinical Medicine, Jefferson Medical College, and F. J. KALTEYER, M. D., Assistant Demonstrator of Clinical Medicine, Jefferson Medical College. Handsome octavo volume of over 800 pages, fully illustrated.

## STONE'S SURGICAL TECHNIC FOR NURSES.

**Surgical Technic for Nurses.** By EMILY A. M. STONEY, late Superintendent of the Training School for Nurses, Carney Hospital, South Boston, Massachusetts.













W100  
D446a  
1899

DeSchweinitz, George F.

American text-book of diseases of the  
eye, ear, nose and throat.

**MEDICAL SCIENCES LIBRARY**  
**UNIVERSITY OF CALIFORNIA, IRVINE**  
**IRVINE, CALIFORNIA 92664**

