



UC-NRLF



C 2 735 006

MEDICAL SCHOOL  
LIBRARY



EX LIBRIS







Digitized by the Internet Archive  
in 2007 with funding from  
Microsoft Corporation



THE ANATOMY AND HISTOLOGY OF THE HUMAN  
EYEBALL IN THE NORMAL STATE

ANATOMIE UND HISTOLOGIE  
DES  
MENSCHLICHEN AUGAPFELS  
IM NORMALZUSTANDE

SEINE ENTWICKLUNG UND SEIN ALTERN

*Von*

DR. MAXIMILIAN SALZMANN

*A. Professor der Augenheilkunde in Wien*

---

MIT 5 FIGUREN IM TEXTE UND 9 TAFELN IN LICHTDRUCK

---

LEIPZIG UND WIEN  
FRANZ DEUTICKE

1912

THE ANATOMY AND HISTOLOGY  
OF  
THE HUMAN EYEBALL  
IN THE NORMAL STATE

ITS DEVELOPMENT AND SENESCENCE


By  
DR. MAXIMILIAN SALZMANN  
*Titular Professor of Ophthalmology*  
*University of Vienna*

AUTHORIZED TRANSLATION

By  
DR. E. V. L. BROWN  
*Professor of Ophthalmology*  
*Also Clinical Professor and Chairman*  
*Department of Ophthalmology, Rush Medical College*

---

WITH 5 TEXT FIGURES AND 9 PLATES IN PHOTOCOLOTYPED



CHICAGO

1912

K

Published August 1912  
Second Impression June 1931

UNIVERSITY OF CHICAGO PRESS  
CHICAGO, ILLINOIS, U.S.A.

Composed and Printed By  
The University of Chicago Press  
Chicago, Illinois, U.S.A.

Q 11011  
S18a  
E5b  
1912

DEDICATED TO MY REVERED TEACHER  
THE THOROUGH STUDENT AND INVESTIGATOR OF THE  
NORMAL AND PATHOLOGIC ANATOMY OF THE EYE  
PROFESSOR ERNST FUCHS  
BY THE AUTHOR

49371





## PREFACE

As in the case with so many other books, this one has developed from the lectures which I have regularly given for years, and I only comply with an oft-expressed wish of my auditors when I put the substance of these lectures into print from the same point of view as the one by which I have allowed myself to be guided in the lectures.

This point of view is that a thorough knowledge of the normal anatomy and histology gives the most certain basis for the understanding of methods of clinical investigation and for judging pathologic changes—hence the reference to ophthalmoscopy, to the physiology of accommodation, and to pathologic processes here and there.

I should like to have the book considered from the point of view that it is the eye specialist and not the specialist in anatomy who writes it. For example, I have not gone into comparative anatomy in a detailed way. Important as this is for the determination of morphologic questions and much as I am personally interested in it, I hold it to be superfluous for the purpose at hand to enter into this branch of learning. Naturally, therefore, some details of cell-structure, nerve-endings, and the like, which for technical reasons one can study only on animals, are treated only briefly.

Probably no one will find fault with me because I have not encumbered the book with the ballast of a complete reference to the literature. Such would stand in no relation to the compass of the text, which I have made as compact as possible. Extended references to the literature are to be found in the most cited articles, especially in the corresponding chapters of the *Graefe-Saemisch Handbuch*. On the other hand, I will not deny that any choice from our enormously swollen literature is an arbitrary one. Forgiveness is herewith implored in advance from whomsoever feels slighted in this respect.

One cannot be original in a subject which has been so much worked in its entirety and in detail. Content and method of expression must necessarily move in the same paths as those to which the earlier works have held.

At the same time I feel I may say that I have not simply copied from others, but that my descriptions and my drawings have been made true to nature. I have borrowed only one drawing (Plate IX, 6)—from an embryologic work; all others are original and with very few

exceptions prepared from my own specimens. In so doing I have striven throughout to bring forth concrete pictures, i.e., each drawing is a true representation of the preparation concerned. Only the general drawings of the eyeball of the adult and of the newborn are schematic. In Plate I (Taf. I) some details of the zonula and vitreous are drawn in from other preparations and Plate III, 2 is also a combination of various teased preparations of the same eye.

I express my especial thanks to the publisher for his friendliness and for the sacrifice occasioned by the nature of the reproduction of the drawings, as well as to the Art Press of M. Jaffé in Vienna for the careful preparation of the plates, which have reproduced the characteristics of the original drawings in the truest way.

THE AUTHOR

VIENNA  
September, 1911

# CONTENTS

## PART I. ANATOMY AND HISTOLOGY OF THE ADULT EYEBALL

	PAGE
A. THE EYEBALL AS A WHOLE (MACROSCOPIC ANATOMY) . . . . .	3-16
I. Form, Size, Orientation . . . . .	3
II. Surface of the Eyeball . . . . .	7
III. General View of the Structure of the Eyeball (Division into Coats and Zones) . . . . .	10
IV. Asymmetry of the Eyeball . . . . .	16
B. SPECIAL ANATOMY AND HISTOLOGY OF THE EYEBALL . . . . .	17-186
Chapter I. The Sclera . . . . .	17-26
1. The Episcleral Tissue . . . . .	21
2. The Sclera Proper . . . . .	22
3. The <i>Lamina fusca sclerae</i> . . . . .	26
Chapter II. The Cornea . . . . .	26-40
a) The Cornea Proper . . . . .	28
1. The Epithelium of the Cornea . . . . .	28
2. Bowman's Membrane . . . . .	30
3. The <i>Substantia propria</i> of the Cornea . . . . .	31
4. Descemet's Membrane . . . . .	36
5. The Endothelium of the Cornea . . . . .	37
b) The <i>Limbus corneae</i> . . . . .	38
1. The Epithelium of the <i>Limbus corneae</i> . . . . .	38
2. The Stroma of the <i>Limbus corneae</i> . . . . .	39
Chapter III. The Structures of the Scleral Furrow . . . . .	41-48
Schlemm's Canal . . . . .	41
The Meshwork of the Iris Angle . . . . .	42
Chapter IV. The Perichorioidal Space and the Suprachorioidea . . . . .	48-52
Chapter V. The Chorioidea . . . . .	52-60
1. The Vessel Layer . . . . .	54
2. The Capillary Layer . . . . .	56
3. The Glass Membrane . . . . .	59
Chapter VI. The Pigment Epithelium of the Chorioidea . . . . .	60-63
Chapter VII. The Retina . . . . .	63-88
a) Microscopic Anatomy and Histology of the Retina . . . . .	65
1. The Layer of Rods and Cones . . . . .	66
2. The <i>Membrana limitans externa</i> . . . . .	68
3. The Outer Nuclear Layer . . . . .	69
4. The Outer Plexiform Layer . . . . .	71
5. The Inner Nuclear Layer . . . . .	72
6. The Inner Plexiform Layer . . . . .	73
7. The Ganglion-Cell Layer . . . . .	74

	PAGE
8. The Nerve-Fiber Layer . . . . .	76
Appendix. The Supporting Fibers . . . . .	78
9. <i>Membrana limitans interna</i> . . . . .	79
b) Histologic and Functional Divisions of the Retina. Its Blood-Vessels and <i>Fovea centralis</i> . . . . .	80
c) The Extreme Periphery of the Retina . . . . .	83
Chapter VIII. The Optic Nerve . . . . .	88-107
a) The Non-medullated Portion of the Optic Nerve . . . . .	88
1. Microscopic Anatomy and Histology . . . . .	88
2. Varieties of the Non-medullated Section of the Optic Nerve . . . . .	95
3. The Significance of the Ophthalmoscopic Picture in Relation to the Anatomy of this Region . . . . .	97
b) The Medullated Section of the Optic Nerve . . . . .	99
1. The Sheaths of the Optic Nerve . . . . .	100
2. The Optic-Nerve Trunk . . . . .	103
Chapter IX. The Ciliary Body . . . . .	107-125
a) The Uveal Portion of the Ciliary Body . . . . .	111
1. Suprachorioidea and Ciliary Muscle . . . . .	111
2. The Vessel Layer of the Ciliary Body . . . . .	115
3. The Elastic Lamella . . . . .	116
4. The Interlamellar Connective Tissue . . . . .	116
5. The Cuticular Lamella . . . . .	117
b) The Epithelial Covering of the Ciliary Body . . . . .	119
6. The Pigment Epithelium of the Ciliary Body . . . . .	119
7. The Ciliary Epithelium . . . . .	121
8. The <i>Membrana limitans interna ciliaris</i> . . . . .	123
Chapter X. The Iris . . . . .	125-148
a) The Uveal Portion of the Iris . . . . .	131
1. The Endothelium of the Iris . . . . .	131
2. The Anterior Border Layer . . . . .	131
3. The Vessel Layer . . . . .	133
b) The Ectodermal Layers of the Back Surface of the Iris . . . . .	138
4. Outer Leaf: <i>Dilatator pupillae</i> . . . . .	138
5. Inner Leaf: Pigment Epithelium of the Iris . . . . .	144
c) Variations in the Appearance of the Iris . . . . .	145
(Influence of the Width of the Pupil and Individual Variations)	
Chapter XI. The Vitreous. . . . .	148-155
Chapter XII. The <i>Zonula ciliaris</i> . . . . .	155-162
Chapter XIII. The Lens . . . . .	162-173
1. The Lens Capsule . . . . .	164
2. The Lens Epithelium . . . . .	167
a) The Epithelium of the Anterior Lens Surface . . . . .	167
β) The Epithelial Border and the Lens Vortex: The Formation of New Lens Fibers . . . . .	167
3. The Lens Substance . . . . .	170

	PAGE
Chapter XIV. The Chambers of the Eyeball and the Topography of This Region . . . . .	173-180
<i>a)</i> The Posterior Chamber . . . . .	173
<i>b)</i> The Anterior Chamber . . . . .	176
<i>c)</i> Content of the Chambers . . . . .	177
<i>d)</i> Topography of the Anterior Segment . . . . .	177
Chapter XV. The Vessels and Nerves of the Eyeball . . . . .	180-187
<i>a)</i> The Blood-Vessels of the Eyeball . . . . .	180
1. The Retinal System . . . . .	180
2. The Ciliary System . . . . .	181
<i>b)</i> Lymph Passages . . . . .	185
<i>c)</i> Nerves of the Eye ( <i>N. ciliares</i> ) . . . . .	186
 PART II. THE PHYSIOLOGIC CHANGES OF THE EYEBALL DURING LIFE (DEVELOPMENT AND SENESCENCE) 	
Chapter XVI. The Embryonal and Fetal Development . . . . .	191-203
Chapter XVII. The Eyeball of the Newborn . . . . .	203-206
Chapter XVIII. The Extrauterine Development and Growth of the Eyeball	207-211
Chapter XIX. The Appearances of Age in the Eyeball . . . . .	211-216
Literature Citations . . . . .	217-226
Explanation of Plate Figures . . . . .	227-232





PART I -

ANATOMY AND HISTOLOGY OF THE ADULT EYEBALL -

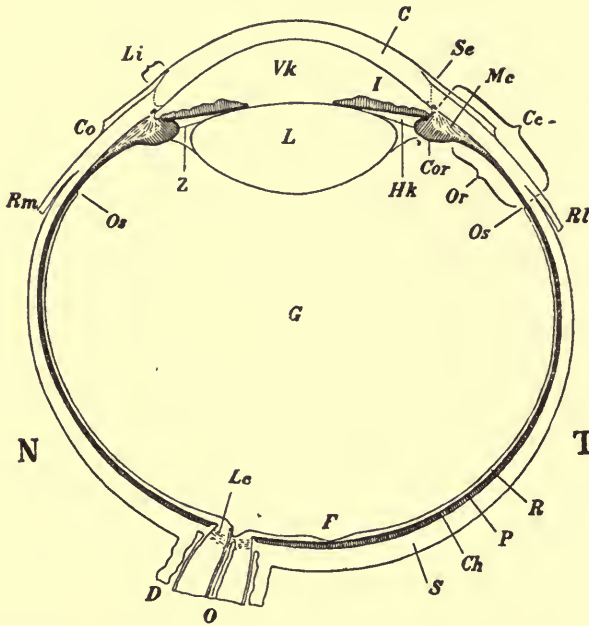


## A. THE EYEBALL AS A WHOLE (MACROSCOPIC ANATOMY)

### I. Form, Size, Orientation

(Text Fig. 1)

The eyeball (*bulbus oculi*) on the whole has the form of a sphere, yet there are some variations from a pure spherical form.



TEXT FIG. 1.—Right eye, schematic horizontal section. Magnification 3.

*N* nasal, *T* temporal side, *Co* conjunctiva sclerae, *C* cornea, *Li* limbus, *Se* sulcus sclerae externus, *S* sclera, *Rm* musculus rectus medialis, *Rl* musculus rectus lateralis, *I* iris, *Cc* corpus ciliare, *Cor* corona ciliaris, *Or* orbiculus ciliaris, *Mc* musculus ciliaris, *Ch* chorioidea, *P* pigment epithelium, *R* retina, *F* fovea centralis, *Os* ora serrata, *Vk* anterior chamber, *Hk* posterior chamber, *L* lens, *Z* zonula ciliaris, *G* vitreous, *Lc* lamina cribrosa, *O* nervus opticus, *D* dural sheath.

To begin with, one notes a shallow, circular furrow in the anterior segment separating a smaller transparent area of about 12 mm in diameter (cornea, *C*) from the remaining white opaque portion (sclera, *S*). This furrow (*sulcus sclerae externus*, *Se*) is not prominent in profile view, for it is filled out for the most part by the *conjunctiva sclerae* (*Co*); one recognizes it better if one allows the image reflected from a mirror onto the anterior surface of the cornea to move toward the sclera. A narrowing of the image then occurs in the horizontal direction (Tscherning, 227) as the neighborhood of the margin of the cornea is reached and an elongation or a division into two images is seen after it actually passes over the

margin of the cornea. The latter indicates the presence of a concavity in this location. This concavity is somewhat plainer on the nasal than on the temporal side.

The cornea is more sharply curved than the remainder of the surface of the eyeball. The foremost portions of the sclera are very weakly curved, and grade off very abruptly, almost conically, toward the equatorial portion, which again is somewhat more sharply curved.

The back half of the eyeball has a more uniform curvature than the front half, yet here, too, there are variations from the pure spherical form and I cannot accept the Merkel schema (151), which conceives of the form of the back half as that of a sphere.

In the first place, the **anatomic equator**, i.e., the sum-total of all those points maximally distant from the optic axis, does not go through an exact frontal plane, but lies farther forward on the nasal side, farther backward on the temporal side. Furthermore, the surface of the eyeball lying between the optic nerve and the nasal part of the equator is somewhat flattened, and the part lying temporal to the optic nerve is more strongly curved backward and outward.

The degree of this asymmetry varies much. In many cases it can only be made out by the accurate comparison of the profile of the eyeball with a circle of the same diameter; in many cases, however, it is so striking that one does not need any special means to recognize it.

24 mm may be looked upon as the normal **sagittal** or **long diameter** of the eyeball. The average of the dimensions given by various authors is as follows:

For the <sup>A.P.</sup>sagittal diameter 24.26 mm

For the transverse diameter 23.7 mm

For the vertical diameter 23.57 mm

The majority find the sagittal diameter to be the greatest, some, however, e.g., Leopold Weiss (235), the transverse; it is possible that racial peculiarities are responsible for this.

The limits within which the normal eye may vary have been determined, especially for the sagittal diameter, since this one is of the greatest importance in its relation to refraction. Schnabel and Herrenheiser (190) found an axial length of 22.5 to 26 mm in emmetropia. However, I doubt whether the upper limit is not carried too far, because, according to Elschmig (52), the form of the optic nerve entrance characteristic for the slightly myopic eye very frequently makes its appearance in such long emmetropic eyes.

Here as everywhere else the normal condition goes imperceptibly over into the pathologic, and the border line which one draws between the two is, necessarily,

somewhat arbitrary and must have a position varying with the individual conception. In my opinion the finding of emmetropia does not in and of itself guarantee the normal structure of the eye. The normal form and the normal internal make-up of the eye must be considered as well; I need only to mention here the operated myopic eye, which can be emmetropic under favorable circumstances and yet possesses the anatomic evidence of high-grade myopia and all the weakness of such an eye.

The eyeball of a man is about 0.5 mm larger in all dimensions than that of a woman. Sappey (186) gives the following figures (in the same order as above):

For the eyeball of a man  $24.6 \times 23.9 \times 23.5$  mm

For the eyeball of a woman  $23.9 \times 23.4 \times 23$  mm

The weight, according to L. Weiss (235), is 7.5 g, the volume 7.2 cm<sup>3</sup>.

For the orientation of the surface of the eyeball one makes use of the same constructions as on the surface of the earth.

The mid-point of the cornea determines the **anterior pole** of the eyeball. It lies diametrically opposite the **posterior pole**, which has no other anatomic characteristic, so can be found only by construction or measurement. The line of union between the two poles forms the **geometric axis** of the eyeball.

It is well to distinguish this from the optic axis, i.e., the line upon which the focal points of the refracting surfaces lie, as well from the visual line, i.e., the line of union between the fovea centralis and the nodal point of the optic system. In the strict mathematical sense an optic axis exists only in the rarest instances, for the foci of the three most important refracting surfaces (anterior corneal, anterior and posterior lental) do not lie upon one and the same straight line at all as a rule (Zeeman, 244). The visual line bears away strongly from the geometric axis in any case, for the fovea lies temporal to and below the posterior pole.

If one measures the geometric axis from the anterior surface of the cornea to the posterior surface of the sclera, it may also well be called the **outer axis**; if, however, one measures only to the light-perceiving layer, i.e., to the outer surface of the retina, one calls this dimension the **inner axis**. It is this dimension which comes into consideration in the refraction of the eye.

Those circles which can be drawn through both poles are called **meridians**; the **equator** is that circle which is equidistant from the two poles.

This is the *geometric* equator and according to the above statements does not coincide with the *anatomic* equator.

A section through the vertical meridian divides the eyeball into a **nasal** or **medial**, and a **temporal** or **lateral** half. The expressions "inner" and "outer" should never be used in the sense of medial and lateral, but only as follows: **inner** is that which lies nearer the mid-point of the



eye, **outer** that which lies nearer the surface. The expressions "forward" and "backward" do not refer to the sagittal direction alone but to the meridian as well: **forward** is that which lies nearer the anterior pole.

For example, the edge of the ciliary body bordering upon the trabeculum of the iris angle is called the anterior, that bordering upon the chorioidea, the posterior border, despite the fact that the difference in position in a sagittal direction is much less than in a frontal one. But if one were to refer to parts according to their actual position, the description would become extremely inconstant and confused.

Since we mainly make use of sections to illustrate anatomic relationships, it may be well to say something here concerning the direction of sections and what they are called.

The most important section direction is the **meridional**, i.e., a section in the plane of a meridian. Of the various meridians, the horizontal one comes mainly into consideration for anatomic purposes. It contains the most details, and **horizontal sections**, as they are called for short, are, therefore, the most instructive. Other meridians are only chosen for special purposes. **Frontal or equatorial sections** are sections parallel to the equatorial plane.

In most cases, however, a direction of sectioning must be chosen which does not coincide with any of these. In this case when the section is made at right angles to the meridian and at right angles to the surface of the bulb, I call it a **transverse section**, for it stands in the same relation to a meridional section of the area affected as does the cross-section to a longitudinal section.

When, on the other hand, the section falls parallel or tangential to the surface, it is called a **surface section**. Since, however, most of the surfaces of the bulb are curved, only tangential sections can be made, and in such sections the tissue is actually cut along the surface over only one small area; farther away from this place the sections become increasingly oblique (the same holds true for transverse sections).

For purely histologic purposes such surface sections are usually very useful, for even the area which is actually cut along the surface contains a very considerable number of tissue elements. On the other hand, surface sections are inadequate for anatomic purposes, in which the general view is more sought for, and must be replaced by **surface preparations**, i.e., by thin sections, which are only obtained by anatomic preparations.

Today there is a tendency to study sections only, because the modern staining methods lend themselves better to sections, and, indeed, sections give very beautiful and instructive pictures. Above all, the modern section methods contribute an incomparable amount to the topography. The older methods of anatomic preparation and the teased preparations do not, however, by any means deserve the disregard which they today receive. In the first place they show us the tissue elements in a much more



natural state, and warrant histologic conclusions far better than do cut preparations. Generally, one can very well combine modern staining with anatomic preparations.

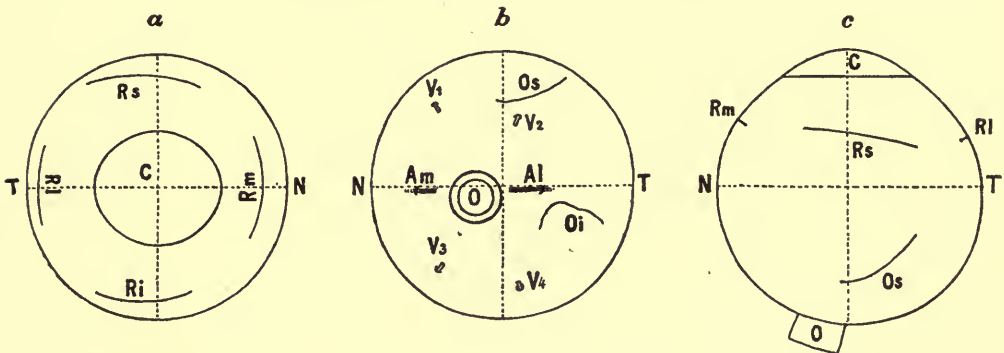
The making of surface and teased preparations demands of course much more care and skill than do cut preparations, and one must also reckon with a large percentage of failure. But one successful preparation of this kind may give data which one seeks in vain in hundreds of cut sections. So a thorough knowledge of anatomic and histologic relationships is only to be had by the use of both the older and newer methods.

The **physical conception** of the structures and tissue elements is, above all, the fruit of this combination of methods. It should be the first and most important object of histo-anatomic study. I, at least, consider it one of the main objects of teaching to convey a correct physical conception.

## II. Surface of the Eyeball

(Text Fig. 2)

In the examination of the outer surface of the eyeball the **cornea**, in front, first presents itself (Text Fig. 2 *a*, *C*). Its relation to the *sulcus sclerae externus* has already been spoken of. The cornea is slightly elliptical, for the horizontal diameter is greater than the vertical. The



TEXT FIG. 2.—Topography of the surface of the eyeball (right eye). Magnification 1.5.

*a* view in front, *b* from behind, *c* from above. *N* nasal, *T* temporal side, *C* cornea, *O* optic nerve, *Rm* line of insertion of the musculus rectus medialis, *Rl* line of insertion of the musculus rectus lateralis, *Rs* line of insertion of the musculus rectus superior, *Ri* line of insertion of the musculus rectus inferior, *Os* line of insertion of the musculus obliquus superior, *Oi* line of insertion of the musculus obliquus inferior, *Am* arteria ciliaris posterior longa medialis, *Al* arteria ciliaris posterior longa lateralis, *V<sub>1</sub>* *V<sub>2</sub>* *V<sub>3</sub>* *V<sub>4</sub>* venae vorticosae. The dotted lines in *a* and *b* indicate the two main meridians, in *c* the vertical meridian and the geometric equator.

*conjunctiva sclerae* continues over into the outer layers of the cornea and is also more firmly adherent to the sclera over the floor of the *sulcus sclerae*; farther back, however, it is united to the sclera by very loose connective tissue only. One is therefore compelled to leave a strip (stump) of conjunctiva, 1 mm or so in length, on the bulb at the time of enucleation. This stump contracts and in the anatomic preparation usually appears somewhat prominent or bulging. This tumefaction is therefore an artefact; when all the parts are *in situ* and uninjured, there

is no sudden change of level visible in the transition from the conjunctiva onto the cornea.

Farther away from the margin of the cornea but still in the anterior half of the bulb, one comes upon the lines of insertion of the recti muscles.

The following measurements are taken from Fuchs (65). They are the averages found in 31 emmetropic eyes.

Text Fig. 2, given herewith, does not agree exactly with these measurements; the figure presents a concrete case. Furthermore, a perspective foreshortening comes out in the marginal portions; therefore the insertion lines appear concave while in reality, i.e., when viewed at right angles to the surface, they are straight or weakly convex.

The insertion lines of the *m. rectus medialis* (*Rm*) and *m. rectus lateralis* (*Rl*) are vertical, straight, and usually symmetrical to the horizontal meridian (although that of the medialis lies somewhat lower, the lateralis somewhat higher).

The insertion lines of the *m. rectus superior* (*Rs*) and *m. rectus inferior* (*Ri*) are weakly convex forward and lie in an oblique plane so that the nasal end of the insertion lies nearer the cornea than the temporal end. Both lines of insertion are, moreover, shifted somewhat temporal.

The distance from the margin of the cornea and the breadth of the tendon (or length of the line of insertion) is shown in the following table:

	Distance from the Cornea	Width of Tendon
<i>M. rectus medialis</i> .....	5.5 mm	10.3 mm
<i>M. rectus lateralis</i> .....	6.9	9.2
<i>M. rectus superior</i> .....	7.7	10.6
<i>M. rectus inferior</i> .....	6.5	9.8

The insertion lines of the *m. obliqui* lie in the back half of the bulb—that of the *m. obliquus superior* above, that of the *m. obliquus inferior* temporal (Text Fig. 2, *b*, *c*).

The insertion line of the *m. obliquus superior* (*Os*) forms a 10.7 mm long bow with convexity backward. Its anterior end lies in about the same meridian as the temporal end of the insertion of the *rectus superior*. The greater part (sometimes the whole) of the insertion line lies temporal to the vertical meridian; the angle which it forms with the vertical meridian measures on the average 45°, but this is subject to wide variation. According to Fuchs, one can distinguish two types of insertion lines, the one having a more equatorial, the other a more meridional direction.

The *m. obliquus inferior* (*Oi*) has the shortest tendon of all the eye muscles (often practically none at all). One, therefore, often sees cross-

sections of muscle-fibers clinging to the outer surface of the sclera on the temporal side in horizontal sections through the posterior half of the eye; they belong to the *m. obliquus inferior*, and give one data as to which is the temporal side. The insertion line is 9.4 mm long and forms a bow with its convexity upward, but often shows gross irregularities, such as angular serrations or dehiscences. It lies for the most part below the horizontal meridian and makes an angle of some  $19^\circ$  with it. The posterior (nasal) end of the insertion comes to within 5 mm of the sheath of the optic nerve, the anterior (temporal) end lies in about the same meridian as the lower end of the insertion of the *rectus lateralis*.

The **optic nerve** (*O*), with its sheaths, forms a triangular rounded cord some 5 mm in diameter. It is inserted to the nasal side, so that the center of its insertion surface lies some 3 mm mesial to and 1 mm below the posterior pole.

On both sides of the optic nerve (nasal and temporal to it) the *arteriae ciliares posteriores longae* are visible as bluish stripes. They hold pretty closely to the line of the horizontal meridian and their line of union, therefore, goes slightly above the axis of the optic nerve. The point of entrance of the *arteria ciliaris posterior longa medialis* (*Am*) lies some 3.6 mm from the optic nerve, somewhat nearer the optic nerve than does that of the *a. c. p. l. lateralis* (*Al*), 3.9 mm away.

The vortex veins (*venae vorticosae*) are usually four in number and lie grouped in two pairs (an upper and lower). The points of exit of the upper pair lie on the respective sides of the vertical meridian, displaced somewhat nasally, and 7 mm (the superior nasal vein,  $V_1$ ) to 8 mm (the superior temporal vein,  $V_2$ ) behind the equator. The latter lies very close to the insertion of the *m. obliquus superior*. The lower pair ( $V_3$ ,  $V_4$ ) show a similar relationship to the vertical meridian, but lie, however, somewhat farther forward (5.5 to 6 mm behind the equator).

The decision as to whether an eyeball is the right or left one is made by the aid of the back segment, because in the anterior segment one does not notice difference enough between things in the upper and lower portions.

First one determines the horizontal meridian: anteriorly, by the long axis of the cornea, posteriorly, by the position of the optic nerve and the long posterior ciliary arteries. Then one searches for the lines of insertion of the obliques. The one reaching closer to the optic nerve, lying snugly on a long posterior ciliary artery, provided with a short tendon (or none at all), is the *obliquus inferior* and belongs on the temporal side. The other, lying farther from the optic nerve and the ciliary artery, provided with a longer tendon of insertion, belongs above. The bulb is, therefore, to be so oriented that the piece lying between the two insertion lines corresponds to the upper temporal quadrant; thereby the correct position, and, moreover, the side to which the eyeball belongs, is found.

### III. General View of the Structure of the Eyeball

#### (Division into Coats and Zones)

For the study of the grosser anatomy it is recommended to divide the eyeball, fresh or preserved in a very weak solution of formalin, into two.

The division may be made in a meridional or equatorial direction. Since the lens is easily dislocated in meridional cutting, it is well to freeze the eye before cutting it. The equatorial section can be made without any special preparation; one carries the section as far as it will go with a thin sharp knife and completes it with scissors.

It is at once seen that the eyeball consists of a firm **wall** and a softer, transparent **contents**.

We will first consider the **inner surface** of the wall of the eyeball in an equatorially halved eye.

The posterior segment of a wholly fresh eye presents about the same picture as with the ophthalmoscope except that the eyeground does not appear red but brown. One recognizes the entrance of the optic nerve as a circular or slightly oval disc of white color (Pl. VII, 1). The retinal vessels are empty or the veins filled with broken columns of blood; therefore, one sees only the larger branches. The region of the *fovea centralis* comes out temporal to the optic nerve entrance by its darker color. Toward the equator the markings of the vortices are seen (Pl. III, 5).

The retina is wholly transparent in a fresh state, but a cadaverous clouding soon occurs. This usually appears first in the region of the fovea and at the same time this region usually becomes detached and folded. Simultaneously the **yellow fleck** (*macula lutea*) comes forth in this region. In older cadaverous eyes the retina is completely opaque and usually detached, and the eyeground, therefore, shows a gray instead of a brown color.

In the anterior segment (Pl. II, 1) one notes first in the cut surface the jagged border of the retina (*ora serrata*, *Os*); it is much better seen in the cadaverous than in the fresh eye, because of the clouding of the retina. The zone lying in front of the *ora serrata* is considerably darker than that behind it, has no irregularities visible to the naked eye, and is known as the *orbiculus ciliaris* (*Or*). This zone is 4 mm wide on the average. Toward the lens it is succeeded by a crown of whitish, plainly prominent, radiating stripes: these stripes are the **ciliary processes** and the whole zone (1.5 to 2 mm wide) is called the *corona ciliaris* (*Cor*). Upon this follows the uniformly dark-brown back surface of the iris. The **lens** (*L*) must be first removed if one wishes to bring this into plain



view. The lens is a circular, disc-form structure, some 9 mm in diameter. Between it and the *corona ciliaris* is a narrow interval (scarcely 0.5 mm broad), the **circumlental space** (*Cl*), bridged over by the fiber-bundles of the *zonula ciliaris*.

In this way one can make out three **main zones** in the wall of the eyeball.

The **posterior main zone** extends from the optic-nerve entrance to the *ora serrata retinae*; the **middle zone** comprises the *orbiculus* and *corona ciliaris*, the **anterior zone** includes the iris on the inner, the cornea on the outer, surface of the eyeball.

The wall of the eye also shows a number of **main layers** (tunics); these are especially easy to make out in the posterior main zone and can be made into anatomic preparations.

Outside, there is a thick, firm coat, whose posterior white segment we know by the name sclera, and whose anterior transparent portion we have already come to know as the cornea; for the two together, i.e., the whole coat, the old name *tunica fibrosa* (Text Fig. 1, *S, C*) is best adapted. Then follows a more delicate, brown, vessel-rich coat, the *tunica vasculosa s. uvea* (Text Fig. 1, *Ch, Cc, I*). On the inner surface of this coat there lies an extremely thin coat consisting microscopically of a single-celled layer, which, likewise, is strongly pigmented, the *stratum pigmenti* (Text Fig. 1, *P*). Finally, inside this there lies the retina (Text Fig. 1, *R*). This is a part of the *tunica interna*; it is transparent during life except for its blood-vessels, and after death is lightly clouded and mostly detached.

The walls of the eyeball are, therefore, made up of four principal layers; from without inward there are: (1) *tunica fibrosa*, (2) *tunica vasculosa s. uvea*, (3) *stratum pigmenti*, (4) *tunica interna*.

The above-described main zones form from unequal development (differentiation) of the *tunica interna* and the *stratum pigmenti*. In the *tunica vasculosa* the zone borders are not sharp and in the *tunica fibrosa* only partly expressed.

For the purpose of the more detailed description we will take up the individual parts of the wall of the eyeball from without inward and from behind forward.

#### a) The Wall of the Eyeball

##### 1. The *tunica fibrosa*

This tough fibrous capsule of the eyeball is closed on all sides; it lends form and size to the eyeball, its firmness protects the delicate inner portions from insult. At the optic-nerve entrance its outer layers go over into the optic-nerve sheaths (Text Fig. 1, *D*). Its inner layers show

a round hole (*foramen opticum sclerae*). This is incompletely closed by a sieve-like perforated plate (*lamina cribrosa*, Text Fig. 1, *Lc*). Otherwise the continuity of the *tunica fibrosa* is broken only by fine canals (*emissaria*), which contain vessels and nerves going to the *tunica vasculosa*.

One can make out only two zones in the *tunica fibrosa*. The one corresponds to the middle and posterior zones of the bulb; here the tunic is white and opaque (sclera, Text Fig. 1, *S*). The other zone corresponds to the anterior zone of the bulb; here the coat is transparent and shining (cornea, Text Fig. 1, *C*). This part is, moreover, an integral part of the optical system.

#### 2. The *tunica vasculosa s. uvea*

This is the main organ of nutrition of the eyeball and the bearer of the intraocular musculature. It consists mainly of blood-vessels; the connective tissue system is poorly developed and colored brown by the richly branched pigment cells (chromatophores).

The *tunica vasculosa* lies snugly against the sclera, yet it is only grown to it at two places. These places have the forms of rings and may be designated from their position as the posterior and anterior insertion rings.

The posterior insertion ring lies about the optic nerve; the two tunics are here directly bound to one another. The anterior insertion ring lies on the border of the middle and anterior zones of the bulb (the corneoscleral border). The union of the two coats is partly direct, partly by means of a peculiar **meshwork**.

Between these two rings there extends a capillary space (the **perichorioidal space**), crossed only by a few blood-vessels and nerves, and bridged by extremely delicate tissue lamellae (*suprachorioidea*). One can, therefore, demonstrate the entire expanse of the *tunica vasculosa* with relative ease.

The posterior insertion ring is the most difficult to detach; this region must eventually be cut away. The anterior insertion ring can be very easily detached by means of blunt instruments; one then only needs to cut the efferent and afferent blood-vessels and the ciliary nerves and the *tunica vasculosa* is entirely separated from the *tunica fibrosa*.

One also recognizes only two zones on the outer surface of the *tunica vasculosa*, for here the border between the posterior and the middle zone is not visible; both appear uniformly brown, and, when the preparation lies in water, provided with fine floating brown shreds (suprachorioidal lamellae). Some meridional white bands stand out against the brown background: these are the ciliary nerves coursing forward along the outer surface of the *tunica vasculosa*.

A broader strand is present in the horizontal meridian, nasal as well as temporal; more accurately studied, this is seen to be made up of three



stripes: the central one is an *arteria ciliaris posterior longa*; the two by its side are nerves.

Forward, all these meridional bands sink into the **ciliary muscle**; the muscle itself is inserted directly into the anterior insertion ring as a whitish girdle about 3 mm broad. For the description of the anterior zone of the *tunica vasculosa*, see the iris (chap. x).

The *tunica vasculosa* shows two round holes: one behind for the entrance of the optic nerve (*foramen opticum chorioideae*), corresponding in its position exactly to *foramen opticum sclerae*, and one anterior for the entrance of light (**pupil**).

3. The *stratum pigmenti* and

4. The *tunica interna*

These are present in exactly the same expanse as the *tunica vasculosa* and, in general, intimately united to it. In their differentiation these three coats are so dependent upon one another that it is best to continue their description as zones rather than as coats.

#### a) POSTERIOR ZONE

The *tunica vasculosa* here forms the *chorioidea* (Text Fig. 1, *Ch*). This serves mainly as the nutritional source for the outer layers of the retina and for this reason possesses a distribution of blood-vessels of its own.

The *stratum pigmenti* is made up of a smooth, regular, easily detachable cell-layer (pigment epithelium of the chorioidea, Text Fig. 1, *P*).

The *stratum pigmenti* belongs developmentally to the *tunica interna* (cf. chap. xvi), but anatomically it is classified with the *tunica vasculosa*; especially in cadaver-eye does the pigment epithelium of the chorioidea appear as a covering of the latter, whereas only the corresponding portion of the *tunica interna* (the retina) is detached. But the addition of "the chorioidea" to this term should never be used to mean more than the zone in this case.

The *tunica interna* is highly differentiated in this zone and developed into a regular stratified coat of nerve tissue (retina, Text Fig. 1, *R*), which functionates as the organ for the reception of visual impressions.

The term retina is used by authors in many different senses. We use it in the *narrower* sense, i.e., to designate that membrane which receives the visual impressions. By many authors the retina is synonymous, however, with the tissues arising out of the optic vesicle, and the term, therefore, is used in the *wider* sense of the word. In this sense the *stratum pigmenti* is also included and the posterior zone is then designated as the *pars optica retinae*. I will not dispute the justification for such a conception of the term retina, but I think that it is more to the purpose to use the word retina in the narrower sense with the beginner, for it is almost always used in this narrower sense in ophthalmology and pathology.

$\beta$ ) MIDDLE ZONE

Since one cannot separate the *stratum pigmenti* and *tunica interna* from the *tunica vasculosa* macroscopically in this zone, one designates the totality of all three coats, in so far as they belong to the middle zone, as the **ciliary body** (*corpus ciliare*, Text Fig. 1, Cc).

According to the division of its inner surface, the ciliary body is divided into two adjacent zones, about which we have learned above (p. 10); the posterior one is the *orbiculus ciliaris*, or flat portion (*pars plana*, Or), the other the *corona ciliaris*, or folded portion (*pars plicata*, Cor).

The ciliary body is the organ for the nourishment of the vitreous and lens, secretes the aqueous, and performs the act of accommodation.

The main mass of the ciliary body belongs to the *tunica vasculosa* and is designated as the *pars uvealis corporis ciliaris*. Like the chorioidea, it is rich in blood-vessels, yet these show another distribution. Above all, however, it is characterized by the **ciliary muscle** (Mc).

The *stratum pigmenti* adheres firmly to the inner surface of the *pars uvealis c.c.*, and, as in the chorioidea, is a single layer of pigmented cells although of slightly different characteristics than there. It should be designated as the pigment epithelium of the ciliary body.

The *tunica interna* is reduced to a simple layer of unpigmented cells (**non-pigmented ciliary epithelium**, or **ciliary epithelium** for short).

Those who use the expression retina in the wider sense call the pigment epithelium, together with the non-pigmented ciliary epithelium, the *pars ciliaris retinae*.

 $\gamma$ ) ANTERIOR ZONE

The totality of all three coats (*tunica vasculosa*, *stratum pigmenti*, and *tunica interna*), so far as they belong to the anterior zone, bear the name *iris* (Text Fig. 1, I). Its most important function is that of a diaphragm, and for this reason it is suspended entirely free in the interior of the eye, i.e., lies separated from the *tunica fibrosa* by a wide space, the anterior chamber (Vk), and is provided with a round opening of changeable width (**pupil**). The *tunica vasculosa* ends at this opening, and the *stratum pigmenti* goes over into the *tunica interna* (transition point or border of the optic cup; cf. chap. xvi).

The *tunica vasculosa* portion of the iris is called the *pars uvealis iridis*; the *stratum pigmenti* is differentiated into an epithelial muscle (*dilatator pupillae*); the *tunica interna*, as in the ciliary body, has a pure epithelial character; it takes on here, however, the function of making the interior of the eye dark and appears, therefore, as the *pigment epithelium* of the *iris*.

When the term retina is used in the wide sense, the *dilatator pupillae* and pigment epithelium of the iris form the *pars retinalis iridis*, s. *pars iridica retinae*.

	ANTERIOR ZONE		MIDDLE ZONE		POSTERIOR ZONE	
1. Tunica fibrosa	Cornea		Sclera			
	Anterior chamber		Perichoroidal space (suprachorioidea)			
2. Tunica vasculosa	Pars uvealis iridis —Sphincter pup.		Pars uvealis corporis ciliaris		Chorioidea	
3. Stratum pigmenti	Iris (Pars iridica retinae)	Dilatator pupillae (+Sphincter pup.)	Corpus ciliare (Pars ciliaris retinae)	Pigment Epithelium of the Ciliary Body	Pigment Epithelium of the Chorioidea  Retina (sensu strictiori)	(Pars optica retinae)
4. Tunica interna		Pigment Epithelium of the Iris		Unpigmented Ciliary Epithelium		

In the above chart I have sought to give a survey of the division of the eyeball into coats and zones with the idea of making the connection of the various parts, as well as the somewhat confused nomenclature, more easily understood.

Only the following need be said in advance about the developmental history of the eyeball: coats 3 and 4 come from the primary optic vesicle and the tissues belonging to these coats are, therefore, of ectodermal origin; layers 1 and 2 arise from mesoderm; only the blood-vessels (mesoderm) of the retina and the epithelium of the cornea (ectoderm) constitute exceptions to the above rule; the same is true of the deposition of ectodermal elements (*sphincter pupillae*) in the iris mesoderm.

b) The Contents of the Eyeball

The vitreous (*corpus vitreum*, Text Fig. 1, G) forms the main mass of and completely fills out the interior space encompassed by the posterior zone, and that surrounded by the middle zone, partially. Behind and to the sides it lies against the inner surface of the retina; in front it presents a concavity (*fossa patellaris*) in which the lens (*L*) lies. This is mainly held in its place behind the pupil by the *zonula ciliaris* (*Z*), a fiber system given off from the inner surface of the ciliary body.

The space yet remaining is filled out by aqueous, and is divided by the iris into a posterior (*Hk*) and an anterior chamber (*Vk*).

#### IV. Asymmetry of the Eyeball

When looked at from the outside the asymmetry of the eyeball is at once apparent in the unequal remoteness of the lines of insertion of the eye muscles, in the oblique position of the anatomical equator, and especially in the entrance of the optic nerve to one side.

The interior of the eye also shows this asymmetry in many places. In general, it may be said that all intervals are smaller on the nasal side, larger on the temporal side.

Pupil and lens are slightly displaced to the nasal side; in the pupil this can be seen even in the living eye; the shifting of the lens is recognized by the fact that the circumlental space (Pl. II, 1, *Cl*) is narrower on the nasal than on the temporal side.

The form of the ciliary muscle (Text Fig. 1) approaches more nearly the type of that in hyperopia on the nasal side, in myopia on the temporal side (cf. chap. ix), and, corresponding to this, there are slight differences in the formation of the iris angle and the position of the canals of Schlemm in relation to the root of the iris. Most striking, however, is the difference in the length of the ciliary muscle (nasal about 5 mm, temporal 6 mm). As a result the retina reaches farther forward on the nasal than on the temporal side (Pl. II, 1).

The emissaria as a rule are longer and lie farther back on the temporal than on the nasal side.

Moreover, the upper and lower halves are not symmetrical, yet the differences are for the most part slight and, therefore, not conspicuous.



## B. SPECIAL ANATOMY AND HISTOLOGY OF THE EYEBALL

### CHAPTER I. SCLERA (SCLEROTICA)

The outer surface of the sclera has a dull-white color. A very delicate fine connective tissue clings to it and forms a union with **Tenon's capsule**—that layer immediately surrounding the eyeball in the orbit. Only rarely does the outer surface of the sclera contain any pigment; it rather comes to view in the form of slate-gray flecks about the canals of the anterior ciliary vessels (**congenital melanosis of the sclera**).

The inner surface of the sclera appears much smoother and in front it has an almost silky luster; posteriorly, it takes on an increasingly brown color and a duller appearance, on account of the greater number of the suprachoroidal lamellae which cling to it and the appearance of pigment cells in the sclera itself. The cut surface shows a tendonous reflex in places.

The thickness of the sclera varies greatly with the individual; in youth and in the female sex it is, in general, thinner. The maximal scleral thickness (Text Fig. 1) is at the posterior pole (1 mm and over; according to Stilling [213], it varies between 0.5 and 1.6 mm). From here the thickness gradually decreases to 0.4–0.6 mm toward the equator. The minimal thickness is immediately beneath the recti muscles close to the lines of insertion of their tendons (0.3 mm). The tendons show a varying thickness at the insertion lines but in many cases they are as thick as the sclera itself (0.3 mm) so that immediately in front of the insertion a thickness of 0.6 mm is attained and held to the margin of the cornea.

At its margin the tendon texture is usually quite sharply set off from that of the sclera. One observes the following varieties of position and direction in this border line: (1) The border runs at right angles to the surface of the sclera just at the place where the interval between the sclera and tendon disappears; the sclera forms a step. (2) The border runs obliquely from in front and without, backward and inward, i.e., the innermost layers of the tendon (those lying nearest to the sclera) lie farther backward; the outer ones go farther forward over into the scleral tissue. (3) The tendon, as a whole, courses obliquely inward into the sclera and disappears farther forward in the scleral tissue: the tendon takes root, so to say, in the sclera.

All the vessels and nerves supplying the uvea pass through the sclera; they are only loosely imbedded in special canals. Following an older conception of the lymph circulation, one designates these canals as **emissaria**.

The emissaria of the **short posterior ciliary arteries** course in very different ways, sometimes straight, sometimes obliquely, sometimes bent at an angle; the inner ends often lie nearer the optic-nerve entrance than do the outer ones.

The emissaria of the **long posterior ciliary arteries**, of the **ciliary nerves** and of the **vortex veins** course very obliquely from without and behind, inward and forward. The outer (posterior) portion of such an emissarium courses wholly flat, almost parallel to the outer surface of the sclera (Pl. III, 3) and the outer opening of the emissarium is bordered in front by a sharp semilunar margin and passes over onto the outer surface of the sclera behind in a furrow. The inner end of the emissaria is more steep, has the sharp semilunar border behind, and in front passes over into an albeit short and only slightly prominent furrow. In longitudinal section the emissarium, therefore, forms a flat bow with its concavity inward.

The long posterior ciliary arteries are accompanied by large nerves; a cross-section of a given emissarium (Pl. II, 2) shows, therefore, two rounded canals, close together and separated only by a thin vaginal wall of scleral tissue. The artery (*A*) lies in the one canal, the nerve (*N*) in the other; both are fastened to the wall of the emissarium by loose connective tissue. According to Fuchs (65), the length of this emissarium is 3 to 7 mm. Its direction is strictly meridional and horizontal. The rest of the ciliary nerves show a wholly similar relationship.

The emissaria of the **vortex veins** (Pl. II, 3) vary more from the meridional direction; their inner ends are farther removed from the vertical meridian than their outer. (For the position of the latter see p. 9.) The length of the emissaria is usually 3 mm; the upper temporal, only, may attain a length of 4.6 mm (Fuchs, 65). The cross-section of the emissarium shows a broad and low lumen (Pl. II, 4); the thin vein wall lies with its long side against the sclera and no space intervenes; on the short side, only, is some loose connective tissue interposed.

The emissaria of the **anterior ciliary arteries** course much less obliquely, are often almost perpendicular to the surface, and often extremely wide. The **intrascleral nerve loops** described by Axenfeld (10) can be observed here and there in these emissaria. There are variations in the course of the ordinary ciliary nerves, and, according to Fritz (64), are most often found under the *musculus rectus superior*, but do not by any means occur in all eyes.

The affected ciliary nerve is especially thick, courses in a normal way from behind throughout the perichorioidal space, then presses into the emissarium to the outer surface of the sclera, bends sharply about there, and goes back again through the emissarium into the interior of the eye and into the ciliary body, where it divides up like the others. The caps of the loop are made especially thick by a deposition of nuclear-rich connective tissue and may even contain ganglion cells (Fritz, 64).

Good drawings of such nerve loops have been published by Naito (164), Groenouw (78), and especially by Meller (150). Although Axenfeld and Naito make mention of no blood-vessels, I hold, with Fritz, that anterior ciliary arteries are constantly or very frequently associated with nerve loops.

When the nerve loops are not so beautifully cut (longitudinally) as in the reported drawings, they often give beginners very considerable difficulty in recognizing them as nerve loops. One must think of this possibility when one finds the continuity of the sclera sharply broken in the region of the posterior border of the ciliary muscle and this place filled out by a clear, nuclear-rich tissue with fibers of another course. The demonstration of medullary sheaths in this tissue makes the diagnosis.

The structures going through all of the emissaria (blood-vessels or nerves) are for the most part bound to the wall of the emissarium by loose tissue only. Outwardly, this tissue is a continuation of the loose connective tissue which unites the Tenon's capsule to the bulb (Pl. II, 3, *Te*); inwardly, it is a continuation of the suprachorioidea and, therefore, characterized by pigmentation. These tissues go over into one another in the middle of the emissarium; often there is here a firmer fixation to the wall, especially along the vortex veins. Yet many times pigment cells (chromatophores) can be followed throughout the entire length of the emissaria out onto the surface of the sclera.

Corresponding to the situation of this tissue, the spaces found on each side of the sclera (perichorioidal and Tenon's spaces) extend into the emissaria and, indeed, at the ends of the canals these spaces between the walls of the canal and the vessel or nerve become very plain and visible without any special help. With respect to the middle of the canal, views vary. According to the older conception of Schwalbe (194), the perichorioidal and Tenon's space are lymph spaces and the emissaria are to be looked upon as communications between the two. It was, however, admitted, even by the supporters of this view (Fuchs, 65), that it was difficult or impossible to inject the emissaria. A later investigator (Langer, 136) denies any communication between Tenon's and the perichorioidal space, and conceives of the spaces found, in his opinion, at the ends of the emissaria, as well as the perichorioidal and Tenon's spaces as a whole, as articular spaces. The oblique direction of most of the emissaria,

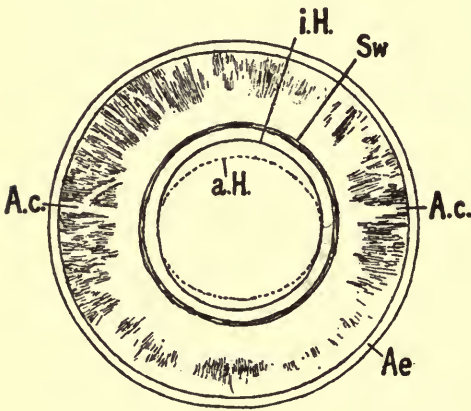


in any case, has the effect of preventing tearing and bending in the motion of the eyeball or in the shifting of the chorioidea in the act of accommodation.

In any case, simple anatomic study shows every emissarium to be a *locus minoris resistentiae*, and this comes fundamentally into consideration in the matter of the extension of malignant tumors.

The union of the sclera with the optic nerve and its sheaths will be more accurately discussed in the consideration of the optic-nerve entrance (chap. viii).

The inner surface of the sclera presents a shallow furrow close to its anterior limit (**scleral furrow**, or *sulcus sclerae internus*, Text Fig. 3, *Sw-iH*). The back margin of this furrow projects a little forward and somewhat toward the interior of the eye, and is known as the **scleral spur** or better as the **scleral roll** (Pl. III, 1, *Sw*).



TEXT FIG. 3.—Tunica fibrosa, anterior half. Viewed from within. Magnification 2.

*Ae* equatorial cut surface, *Ac* white stripes corresponding to the course of the long posterior ciliary arteries, *Sw* scleral roll (back margin of the scleral furrow), *iH* inner corneal margin (unbroken line), *aH* outer corneal margin (dotted line).

The ciliary body is inserted into it (here one finds the anterior insertion ring of the uvea). The anterior border of the furrow slopes very gradually over onto the inner surface of the cornea; the breadth of the furrow is about 0.75 mm. On the floor of the furrow, close to its posterior margin, lies **Schlemm's canal** (Pl. III, 1, *Sch*); the rest of the depression is filled out by the **meshwork** of the **iris angle**. With respect to the histology of this portion, see chap. iii.

On the meridional section the **corneal margin of the sclera** in the **fresh** cadaver-eye appears to the naked eye to be a pretty sharp line, because the white of the sclera stands out well from the transparent cornea. But even when magnified by the *loupe* the sharpness of this border is lost in part and entirely so in the fully prepared and stained section, cleared and mounted in balsam; the sclera takes on a somewhat denser stain than does the cornea, but these differences merge imperceptibly into one another. One must, therefore, use fresh material to study the position and course of the corneoscleral margin.

In horizontal sections the border line is then seen to run from without inward toward the ciliary body in a direction about parallel to the optic



axis. However, it then bends about a little along the inner surface toward the axis (Pl. I; the corneoscleral border is indicated by a punctate line). The floor of the scleral furrow is therefore formed of scleral tissue, as, indeed, preparations of the inner surface also show, although the corneoscleral margin is soon collinear with its posterior border.

When, on the other hand, one studies a vertical section, a very oblique course of the corneoscleral border is shown, so that its outer end lies 1 mm or more nearer the optic axis than does the inner one. (Concerning the effect which this has upon the form of the cornea, consult chap. ii.)

The corneoscleral border, therefore, meets the outer surface of the sclera at an acute angle (less than  $90^\circ$ ). This is the main reason why in life the white of the sclera does not appear sharply set off from the transparent cornea; a very narrow transition zone, which is, nevertheless, always demonstrable with the *loupe*, is present. Moreover, the circumstance that the conjunctiva gradually goes over onto the transparent cornea contributes to this obscuration of the corneal margin.

Above and below, therefore, this extension of the sclera over onto the cornea is much more outspoken than along the nasal and temporal margins; indistinctness of the border is correspondingly more marked. Owing to the fact that the upper margin of the cornea is the one of preference for operative procedures, these relations become of great importance for operative technique.

---

The sclera as a whole shows a very uniform structure, but one can always make out certain modifications of the structure toward the outer surface and—in this by no means strict sense of the word—one can speak of various layers. These layers from without inward, are: (1) the episcleral tissue; (2) the sclera proper; (3) the *lamina fusca sclerae*.

#### 1. *The Episcleral Tissue*

This is of a looser structure than the sclera proper, its bundles are more delicate, more tortuous, and course in varying directions. Outwardly, it extends over into the loose tissue which fills out Tenon's space. Toward the inner side its bundles are firmer, thicker, and the mattressing is more close. In this way it graduates over into the tissue of the sclera proper. It is especially characterized by relatively numerous vessels, and so is easily differentiated from the vesselless tissue which fills out Tenon's space, as well as from the tissue of the sclera, which is scanty in vessels. Therefore one makes out the episcleral tissue best in much inflamed eyes, where the individual tiny vessels are filled full of blood.

Behind the insertion line of the recti muscles, the episcleral tissue forms only a very thin layer with a very loose net of vessels. In front

of this insertion line it is much more strongly developed and rich in vessels, since the eye muscle-tendons also add a similar tissue—a thicker layer, with larger blood-vessels (*perimysium*). This tissue continues, equally thick, forward into the *sulcus sclerae externus*, and here goes over into the *limbus corneae* (Pl. I, *Es*). A large number of thick elastic tissue fibers are mixed with this tissue.

The vessels in the back part of the episcleral tissue are branches of the posterior ciliary artery, those in the fore part of the tissue, of the anterior. These branches form a network in the usual way, that is to say, one artery is accompanied by two veins; the meshes of this net are very wide in the back part and first become increasingly narrow in front of the recti muscles and toward the border of the cornea. A thicker capillary and venous net exists only in this anterior zone of the sclera; a marked filling of this net produces the so-called ciliary injection.

## 2. *The Sclera Proper*

This is a dense fibrous tissue in which the bundles cross in the most varied directions and often divide at sharp angles. At least one obtains this impression in surface-sections. The cross-section (at right angles to the surface) (Pl. II, 5) shows, on the other hand, long band-like stripes (apparently representing bundles which have been cut in their long axis), and short oval or lance-formed fields (apparently cross-sections of bundles), and, if one bases his studies of the course of the fibers in the sclera solely upon such cross-sections, one is very easily led to the view that there are two main directions of the scleral bundles, meridional and equatorial.

Indeed, there are places in which equatorial bundles are solely or mainly present. The immediate neighborhood of the optic nerve is such a place. A second is the scleral roll and its immediate neighborhood. However, in the remaining portions of the sclera the bundles possess a most varying direction.

I think that one obtains the best conception of the structure of the sclera from a consideration of the inner surface. Here, even though one is not able to follow the course of the individual bundles, one can recognize the prevailing direction from the silky reflex of the inner surface, or bundles of a certain direction can be made out, to some extent.

The one can recognize an equatorial fibrillation (concentric to the border of the cornea) just along the posterior edge of the scleral furrow; farther back the fibers form more marked loops with their convexities turned backward, and in this way they gradually go over into meridional bundles. If one conceives of these loops as being given off from all points of the corneoscleral border, one realizes that a crossing

with a prevailing circular course in front and a meridional one behind comes about.

In the body of the sclera one cannot, of course, follow the bundles in this way, but it is very easy to believe that a similar principle rules here, i.e., all the bundles form loops, and whether they appear as meridional, oblique, or equatorial bundles depends solely upon the way in which the loop is sectioned. I do not trust myself to state anything more definitely concerning the scleral fibrillation, despite the thorough studies which Ischreyt (111) has made concerning them.

The bundles are quite delicate in the anterior section and have sharp borders; in the posterior section one sees considerably larger bundles with subdivisions which do not have exactly the same direction and are not sharply separated from one another. In short, the structure of the sclera, which is difficult enough to make out anywhere, becomes more and more complicated as one proceeds backward.

On surface view the individual scleral fiber-bundle shows a fine parallel striation. The dimension of the bundle in the direction of this striation is spoken of as the **length** of the bundle, the dimension at right angles to and striation and parallel to the surface of the sclera, as the **breadth**, and the dimension at right angles to the surface of the sclera as the **thickness** of the bundle.

We must look upon the length of the bundle as an unconditionally great one; in any case one cannot measure it microscopically, because the bundles are always cut off. In thickness, the bundle measures 10 to 16  $\mu$  in the anterior segment (when pure cross-sections are studied); the breadth varies according to the locality. In general, I hold this to be 100 to 140  $\mu$  in the anterior segment, and the relation of the thickness to the breadth to be something like 1 to 10 or 12; the cross-section, therefore, has a somewhat elongated lance-form. The circular bundles of the scleral roll are much narrower (30 to 50  $\mu$ ), and the relation of the thickness to the breadth is 1 to 3. The cross-section is oval or has the form of a myrtle leaf. In the posterior section one is so often in doubt where the border of the bundle lies that one cannot accurately measure it.

The bundles, almost throughout, course parallel to the surface; even when the intermixing of the bundles shows slight variations from this direction, it is scarcely noticeable. Only along the emissaria are bundles found which have a course that is oblique, or, indeed, at right angles to the surface; it is the narrow sides of the individual canals which are flanked by such bundles.

The *funiculus scleroticæ* described by Hanover (87) (according to him, a remnant of the fetal cleft) appears to be only such a bundle flanking a posterior ciliary artery.



The individual bundle consists of fine collagenous fibrillae, coursing parallel to each other and to the length of the bundle; the fine striation visible in surface-sections comes from this and gives the direction to the entire bundle. The longitudinal section shows either a similar striation or a more homogeneous appearance (Pl. II, 5, *l*). Cross-sections do not show the individual fibrillae but only groups of them; the entire cross-section of the bundle is divided into smaller angular fields in this way, giving it a peculiar appearance which I call the cross-section marking for short (Pl. II, 5, *q*).

Aside from the collagenous fibers, ordinary elastic ones, i.e., fibers staining with orcein, are visible. They occupy the periphery of the bundle and only a few extend into the interior between the groups of fibrillae. As a whole the elastic fibers course parallel to the direction of the bundles. They are very much more delicate than in other tissues, and, therefore, are to be made out in longitudinal section and in surface preparations only by strong staining. They are more easily seen in cross-section.

**Between** the bundles, especially in the angles formed by the crossing of the bundles, lie the fixed cells of the scleral tissue; they are also visible in the posterior portions, on account of the incomplete separation of the bundles from one another.

After Held's stain these cells come out in surface-sections as membranous structures, with an extremely thin and only very faintly stained body going over into finer and broader extensions. The fine extensions seem to course in the direction of the collagenous fibrillae, the broader ones across these. The cells are united with one another by means of these processes; they form a syncytium, yet I think that this is not as completely closed on all sides as in the cornea. The cell-nuclei are very irregular in form owing to the position of the cell; for the most part, however, they are longish, have a fine chromatin mesh and 1 to 3 very small nucleoli. The long-strung-out spindle-form cells, which are not infrequently seen in surface-sections, likewise appear to be provided with very long nuclei lying mainly in the angles between the bundles; these may in part be only side views of flat cells.

With certain stains the scleral bundles seem to me to possess border membranes in the anterior segment; for example, beside the elastic fibers the orcein stain shows an extremely fine, weak, brownish layer surrounding the bundle. These membranes are connected with the cells in any case; according to Pes (171), they connect the elastic fibers with the cell-processes.

The blood-vessels of the sclera fall into two groups. The one makes

use of the sclera only for passage, and subdivides into capillaries in other tissues; the vessels of the uvea belong in this group. The points of entrance for these have already been described as the emissaria. There are, however, a large number of smaller vessels in the sclera, which do not, properly, supply this membrane itself, e.g., in the neighborhood of the optic nerve. Here several branches of the short posterior ciliary arteries form an anastomotic ring about the optic nerve (the circle of **Zinn** or **Haller's** vascular circle, or the *circulus arteriosus nervi optici* (Leber), which, as the name suggests, serves for the supply of the optic nerve, especially the *lamina cribrosa*. Moreover, in the most anterior portion of the sclera just behind and outside Schlemm's canal relatively numerous vessels are present, for the anterior ciliary veins pass through here.

How insignificant the second group is, i.e., how few vessels the sclera possesses in and of itself, comes out best in the region of the equator: here and there a capillary lumen is visible, but in a cursory inspection this tissue appears entirely devoid of vessels.

The nerves of the sclera are branches of the ciliary nerves; they branch off in the perichorioidal space and broaden out (especially in the inner two-thirds of the sclera) and form a trabeculum similar to that in the stroma of the cornea.

According to Smirnow (209) and Agababow (6), there are three sorts of endings in the scleral tissue: free sensory endings, trophic ones in connective-tissue cells, vasomotor ones in vessels. Finally, Agababow describes a rich nerve-fiber net in the *lamina fusca*. In any case, most of these findings are not marked in human eyes; only sensory endings have been proven for the human (by Smirnow).

In general, the anterior part of the sclera is, furthermore, perforated by numerous finer nerves which supply the cornea (Fritz, 64).

The histologic relations of the tendon insertions are best studied in sections which go at right angles to the line of insertion, i.e., meridional sections in the case of the recti muscles. The tendon itself (Pl. I, *Mr*) consists of a mass of exactly longitudinal coursing bundles of collagenous fibrillae supported by thick elastic fibers. Aside from the difference in the size of these fibers, it is made up of the same tissue as the sclera; the texture only is different: in the tendon all the bundles are parallel, hence the peculiar silky reflex; in the sclera itself the bundles are much crossed, hence the dull-white appearance. The tendon in this way goes directly over into the tissue of the sclera; the bundles of the tendon spread apart and interweave with the cross and oblique bundles. The tendon-bundles go over into the direction of the scleral bundles concerned and only the cessation of the thick elastic fibers marks the border line.

3. *Lamina fusca sclerae*

Near the inner surface the connective-tissue bundles become smaller and flatter, the elastic fibers more numerous and thicker; branched pigment cells (chromatophores) appear here and there in the interspaces of the tissue. Finally, along the inner surface itself the whole is closed off by an endothelial layer. This insignificant modification of the scleral tissue on its inner surface is the *lamina fusca*.<sup>1</sup>

The name of the *lamina fusca* is given to it by the brown color which the pigment cells lend to the inner surface of the sclera. It cannot be isolated, for it goes continuously over into the tissue of the sclera itself. What one brushes away is only the lamellae of the suprachorioidea clinging to the *lamina fusca*.

In a histologic sense the *lamina fusca* forms the transition over into suprachorioidea. The new tissue elements appearing in it are identical with those of the suprachorioidea and will be more accurately described under that heading.

The pigmentation of the *lamina fusca* is not uniform; anteriorly, immediately behind the scleral roll (Text Fig. 3, *Sw*), it is as good as colorless, and, moreover, farther back the brown color only appears in flecks. Farther back it usually becomes more intense along the larger ciliary nerves; the pigmentation is weaker along the larger nerves and in particular corresponding to those bundles which, with their accompanying nerves, form the long posterior ciliary arteries; for this reason two broad white streaks appear especially prominent in the horizontal meridian along the inner surface of the sclera (Text Fig. 3, *Ac*).

## CHAPTER II. THE CORNEA

The cornea has the form of a strongly curved meniscus, to which in and of itself one must ascribe a weak refracting power, because it is thinner in the center (0.8 mm) than it is at the edge (1 mm, or slightly more).

The measurement of the thickness of the cornea is difficult, because the stroma swells up easily in water; sections hardened in Mueller's fluid also usually show the cornea in a swollen condition. The swelling is mainly inward; a marked tumefaction develops at the edge of Descemet's membrane (see Pl. I), and the entire inner surface becomes wavy. In this respect formalin-alcohol hardening conserves the cornea better.

<sup>1</sup> The meaning of this term is not the same to all authors; by it many understand that part of the suprachoroidal lamellae which remains clinging to the sclera after detachment of the uveal tract, others probably, the whole suprachorioidea as well. It is perhaps best to allow this expression to drop entirely into disuse.

The radius of curvature of the anterior surface is 7.84 mm on the average (computed from the 43.03 D. of average corneal refraction given by Steiger, 211).

This radius of curvature only holds true, however, for the central third of the cornea, the so-called optical zone, which is curved almost exactly like a sphere; the peripheral parts are notably flattened and more so upon the nasal than upon the temporal side. Aside from this there usually exists a certain degree of meridional asymmetry, i.e., the vertical meridian is somewhat more strongly curved than the horizontal one.

We are very little informed concerned the curvature of the posterior surface. Merkel and Kallius (151) hold it to have the curvature of a sphere and the central portion to be concentric with the anterior surface. According to this, its radius of curvature would be something like 7 mm. Tscherning (227) has measured it ophthalmometrically in the living and has found very great differences in the curvature of the anterior and posterior surfaces. He holds the radius of curvature for the posterior surface to be 6.22 mm.

Viewed from the front, the cornea appears weakly elliptical with the longer axis horizontal. According to Priestley Smith (174), the horizontal diameter of the cornea varies between the extremes of 10.5 and 13.5 mm, but usually is between 11 and 12 mm. The average for eyes of all ages is 11.6 mm: for males 11.65, for females 11.54. The vertical diameter is some 1 mm less.

Looked at from behind (within), the cornea appears completely circular with a diameter close to the long diameter of the anterior surface. This is due to the form of the corneoscleral border discussed above. These relations come out very beautifully if one looks at the anterior half of the *tunica fibrosa* after the removal of the other membranes and the contents of the bulb (Text Fig. 3); one then sees the oval contour of the anterior surface (*aH*) outlined in the circular contour of the posterior surface (*iH*).

A plane going through the outer visible border of the cornea is called the **base of the cornea**, and the distance between it and the center of the cornea the **height of the cornea**; this amounts to about 2.6 mm. It increases with the curvature of the cornea and also with the size of the cornea, for a larger segment of a given sphere is higher than a smaller one. Large corneae are, therefore, easily held to be more sharply curved, because they are especially high.

Looked at from within, the cornea seems deepened, just as it appears set forward when looked at from without. The margin of this concavity shows a very weak rounding which, so to speak, is the negative



of the *sulcus sclerae externus* and lies along the inner border of the *sulcus sclerae internus*. The configuration of the sinus angle (cf. chap. xiv), so important for pathology, is, therefore, in part conditioned by these relations.

Apart from the indistinctness of the marginal portions, the cornea everywhere has a uniform transparency, at least in middle life. These two zones concerning which we now speak, cannot, therefore, be macroscopically separated from one another in life and are only characterized by their microscopic structure. Bowman's membrane, in particular, does not extend over the entire cornea; it ceases about 1 mm from the border (Pl. I, *b*) and the remaining marginal portion of the cornea, which, too, is characterized by further anatomic peculiarities, is known as the **limbus corneae**.

The limbus is therefore a zone of about 1 mm width limited centrally by the margin of the Bowman's membrane and peripherally by the corneoscleral border, and, properly speaking, includes only the anterior layers of the cornea. For the purposes of description, solely, we think of the limbus as bordered by a plane going through the depths of the cornea from the border of Bowman's membrane to the border of Descemet's membrane.

The remainder forms the **cornea proper**, which is, therefore, characterized anatomically by two basal membranes. I begin with the description of the cornea proper, because it is then easier to describe the limbus as the transition zone between the sclera and cornea.

#### *a) The Cornea Proper*

In this portion one distinguishes 5 layers from before backward (without inward): (1) Epithelium; (2) Bowman's membrane; (3) Stroma-corneae; (4) Descemet's membrane; (5) Endothelium.

#### I. THE EPITHELIUM OF THE CORNEA

##### (Pl. II, 6, *Ep*)

Over the greater part of the cornea this has a uniform thickness of 37 to 58  $\mu$ ; a slight increase in thickness is first noted near the edge of Bowman's membrane. It possesses two wholly smooth border surfaces, an anterior, formed by the anterior surface of the cornea, and a posterior, which is in contact with Bowman's membrane; the cross-section, therefore, shows two exactly concentric contours, exactly parallel when small stretches are looked at by high power.

In the great regularity of the anterior surface (the anterior contour in the microscopic preparation) the epithelium of the cornea probably



surpasses the epithelium of all other parts of the body, and this regularity has a connection with the function of the anterior surface as a part of the optic system. The great brilliancy of the cornea, the regular reflex of its anterior surface, is only present when the epithelium is completely intact.

Unfortunately, one rarely sees this normal structure of the epithelium in the microscopic preparation, since it is easily subject to mechanical lesions and post-mortem changes, such as drying, and also because the hardening fluids act upon the epithelium before they do upon the deeper portions and to a greater extent.

The corneal epithelium is a stratified pavement epithelium of 5 to 6 layers of cells.

The deepest layer (**basal** or **foot-cells**, *b*) lies directly over Bowman's membrane, and consists of cylindrical cells of some 18  $\mu$  in height and 10  $\mu$  in breadth; each cell turns an absolutely flat surface (foot) toward Bowman's membrane, and a rounded end (head) to the succeeding cell-layer. The nucleus is slightly oval ( $5 \times 7 \mu$ ) and lies with its long axis at right angles to the surface of the cornea.

As shown by these figures, the basal cells of the corneal epithelium are characterized by a considerable size and rich protoplasm. The protoplasm is for the most part somewhat lighter than that of the succeeding cell-layers. Yet places are found in the basal cell-layer in which the protoplasm stains darker; these cells are longer, as well, and have concave sides; their nucleus is displaced into the head and is obliquely oval. These are the cells seen passing up into the next layer (H. Virchow, 234) (Pl. II, 6, the cell next to the last on the right).

According to v. Ebner (48), the basal cells are positive, monaxial, and double refracting, with the optic axis perpendicular to the surface.

The second layer ("**wing**" cells) consists of polyhedral elements with convex anterior surfaces and concave posterior ones; the edges between these concave surfaces are more or less drawn out into the shape of wings. The long axis of the nucleus is parallel to the surface of the cornea, and the protoplasm is of a darker color than that of the basal cells. The cells of the middle layers are not double refracting (v. Ebner).

While the cells of the second layer are of about equal size in all three dimensions, a beginning flattening is apparent in the third layer, i.e., the cells are larger parallel to the surface and the nuclei are more oval. The transition to the very flat cells of the surface layer (*o*) (i.e., 5th to 6th) is carried out in this way. These cells are very large in surface expanse (up to 46  $\mu$ ) but are very thin, in general, and only measure some 4  $\mu$  in the region of the nucleus. This thickening projects backward toward the

deeper layers, while the anterior surface is wholly flat. The complete regularity of the anterior surface of the epithelium comes about in this way.

The nuclei of the surface cells are likewise much flattened ( $2.5 \times 12$  mu), stain less densely than those of the deeper layers, but show normal structure and no indications of dissolution, therefore no keratosis, as in the epidermis. According to v. Ebner (23), the surface cells are negative, monaxial, double refracting, with the optic axis perpendicular to the surface.

The union of the cells with one another is formed by means of cell-bridges, as in the epidermis. The cell-outlines acquire a similarity to ladders, because these bridges shrink easily and become drawn out into threads. The totality of the space between these bridges forms the **intercellular canal** or **lymph system**; it can be injected with fluid and is often found widened in pathologic conditions (e.g., in glaucoma).

The intercellular spaces are plainest between the basal cells; toward the surface they gradually disappear. They do not come out plainly after all hardening fluids; with Mueller's fluid one usually gets simple linear cell contours; formalin-alcohol, and other similar reagents, bring out the cell-bridges better; one sees them best, however, in pathologic cases.

Leucocytes (wandering cells) are quite often found in this system of spaces. They are characterized by their very heavy staining, constricted, or fragmented nuclei. Under normal conditions they are probably only to be found between the bases of the foot-cells just in front of Bowman's membrane (Pl. II, 6; a little to the left of the center). Under pathologic conditions they are much more numerous and extend farther into the epithelial layers. Concerning the nerves of the epithelium see P. 35.

## 2. BOWMAN'S MEMBRANE (*Lamina elastica anterior*)

(Pl. II, 6, B)

This membrane has a uniform thickness of 10 to 16 mu throughout almost its entire expanse, and, with the exception of its pores, is wholly structureless, showing neither cell-nuclei nor fibrillation. Its anterior surface is sharply set off from the epithelium and has a curvature concentric with the anterior epithelial surface. It is absolutely smooth; I have not seen the fine serrations described by H. Virchow (234) in any of my preparations.

When, therefore, a larger expanse of epithelium has been lost, as after a slight burn, the recognition of such a loss of substance is often very difficult; the curvature of the cornea appears unchanged but, when one gets the reflection of the image of the mirror from the margin of the loss of substance, the step caused by the desquamation of the epithelium is recognized.

On section, the posterior surface of Bowman's membrane does not show so sharp a contour as the anterior, for it merges with the most superficial lamellae of the corneal stroma. Furthermore, it is not possible to detach Bowman's membrane from the stroma.

In its staining reaction it agrees fully with the stroma lamellae, and only in its homogeneity does it differ from the fibrillar appearing lamellae. Bowman's membrane is therefore to be looked upon as a specially modified superficial stroma layer.

The sole details of structure which one occasionally but by no means constantly recognizes in cross-section of Bowman's membrane are the **pores** for the *rami perforantes* of the corneal nerves. These are not characterized by a different staining but solely by their extremely delicate contours. Corresponding to each pore there are two contours, visible only by very sharp focusing; they are usually parallel to one another, although not coursing exactly at right angles to the surface.

In most eyes the periphery of Bowman's membrane is sharpened from behind forward.

### 3. THE *Substantia propria* OF THE CORNEA (*Stroma corneae*) (*Substantia propria corneae*)

(Pl. II, 6, 9, C)

This forms the main mass of the cornea, comprising about 90 per cent of the entire thickness.

No tissue of the eye has been more thoroughly and carefully studied than the corneal stroma, and yet we are far from a full understanding of its structure. It is not my task to go into all the disputed questions and small details; those who wish to familiarize themselves with these things should consult H. Virchow's (234) exhaustive and critical presentation. The following description will be limited to the most important structural details, especially to those which one can see in sections after ordinary stains, and these alone can serve as the basis for consideration of pathologic conditions.

The circumstance that the spaces in the tissue in which the nuclei lie do not unite with one another and course, throughout, parallel to the surface is the most striking thing seen in a section perpendicular to the surface; this is characteristic of the corneal stroma and differentiates it from the sclera, as well as from pathologic scar-tissue. This picture comes out in any section, independent of its direction, provided it is perpendicular to the surface. From this alone one can draw the conclusion that the *stroma corneae* is made up of lamellae parallel to the surface.

That which lies between two spaces is not, however, a simple lamella; this strip of tissue is not a unit of structure but a still larger number of finer outlines parallel to the surface can be made out (Pl. II, 9), i.e., it is made up of a large number of very narrow strips and the structure is uniform only in these narrow strips—only such a strip is to be looked upon as the elementary **stroma lamella**.

One cannot, by any means, see the elementary lamellae in all places on section. The corneal stroma is, unfortunately, very subject to swelling, and wave-like undulations or nickings of the lamellae are frequently present. So it is clear that the outlines of the elementary lamellae can be seen only where the section goes exactly at right angles to the surface; if the cut goes the least bit obliquely to the border line, it vanishes completely. The elementary lamellae are, as a rule, better and easier seen in the posterior than in the anterior layers of the stroma.

When no cells lie between them, the surfaces of the elementary lamellae are quite firmly and flatly united to one another; but when cells are found, the neighboring lamellae are separated from one another and from the cells in hardening, and in this way the spaces already spoken of arise.

Neighboring spaces do not, however, lie in the same level; for if one follows out the whole surface expanse of a lamellar-complex inclosed between two superimposed spaces, one sees forthwith that it divides up and its component parts stick to other lamellar-complexes, etc. In a surface preparation of the cornea each cell requires a separate focus.

The individual elementary lamella consists of fine, straight connective tissue fibrillae, strictly parallel to one another. However, the direction of the fibrillae varies from lamella to lamella. The appearance of the lamellae upon cross-section (Pl. II, 7) is, therefore, different: if the fibrillae run perpendicular to the cut surface (*q*), the lamellae appear portioned off in a peculiar way—as if the fibrillae had been divided into small bundles. On the other hand, when the fibrillae course parallel or nearly parallel to the cut surface (*l*), the lamellae are finely striated or homogeneous. (High-power magnification and a narrow aperture are necessary to make out this striation.) One recognizes this change of direction as well as the parallelism of the fibrillae in each individual lamella still better in surface-sections.

According to Tartuferi (220), the corneal stroma is permeated by numerous elastic fibers, coursing mainly in the direction of the corneal lamellae; they lie between the lamellae and form nets with beaded meshes (perifascicular nets); at times there are membranous expansions at the nodal points. These fibers arise from the corneal cells, according to Lieto Vollaro (141) and Seefelder (202). An especially thick layer of



such elastic fibers lies just in front of Descemet's membrane and has been called the *lamina elastica corneae* by Seefelder.

According to my observations, these elastic fibers course mainly in the direction of those collagenous fibrillae in the particular lamellae which they support, as in the sclera. The fine undulations described and depicted by Tartuferi are apparently a result of his method of preparation. Seefelder's drawings and my preparations show them absolutely straight (Pl. II, 8, *f*).

The elastic fibers of the cornea are objects difficult of demonstration by the microscope; the ordinary staining methods do not show them at all, as a rule. They can be demonstrated most easily by the molybdcid-acid-hematoxylin method of Held after fixation in Zenker's fluid, as Seefelder has shown. This method is, in general, a very simple one and, too, is indispensable for the demonstration of the corneal cells.

The reason that I have deferred discussion of the dimensions of the elementary lamellae is that we have had to rely very much upon conjecture in this matter. The thickness is easiest to measure: in places such as those shown in Pl. II, 7, where the individual lamellae have separated from one another, I estimate the thickness of the cross-section of the lamella to be 1.3 mu. In other places I have found the thickness to be as great as 2.5 mu. Pes (170) gives the thickness of an elementary lamella as 1 mu.

The breadth of a lamella, i.e., its expanse parallel to the surface and at right angles to the direction of the fibrillae, cannot be directly measured with exactness, because one cannot follow the individual lamella for so great a distance with certainty. But it is certain that the figure of 10 to 20 mu, which Pes gives as the breadth, falls far short of the actual breadth.

The length of the lamella, i.e., its expanse in the direction of its fibrillae, attains the width of the whole cornea, according to H. Virchow. We must, therefore, look upon the lamellae as broad, thin bands, which cross each other at wide angles, even of 90°, and lace in and out among each other at very narrow angles, so that they vary only slightly from a course parallel to the surface.

In the anterior layers of the cornea the spaces are shorter and the variation from a course parallel to the surface is greater than in the posterior layers. One must, therefore, conceive that the lamellae in front are narrower and thread in and out among each other more than do those behind.

This oblique fiber course is especially plain in many places just behind Bowman's membrane. Such trains were called the *fibrae arcuatae* by the

older authors. They appear to me to have a certain relation to the nerve pores of Bowman's membrane, and possibly they are only trains of fibers which accompany the corneal nerves, in case, indeed, they are not the nerves themselves.

The greater thickness of the marginal parts of the cornea is due to the greater number of lamellae, found only in the posterior layers. If one follow these layers from the periphery toward the center, for example, one sees that from place to place the most posterior lamellae (those nearest Descemet's membrane) become thinner and finally disappear (end in wedges).

The cells of the cornea are fixed and wandering cells. The **fixed corneal cells** lie in the spaces of the stroma and for this reason are flat elements placed parallel to the surface. The cell-body consists of a delicate membrane, which only increases to a notable thickness in the neighborhood of the nucleus, as shown on cross-section (Pl. II, 6, 9). On surface-section the cell-body is not visible after ordinary staining and only Held's stain shows it to be an extremely weak staining, finely granular or reticular structure of irregular form with a few broad processes (Pl. II, 8). One gets a similar picture in gold preparations, as drawn by Druault (46) and Fuchs (69). The cells build a closed network, or better a trabeculum or syncytium, by the help of these processes.

The nuclei of the corneal cells are markedly flattened, their thickness reaching only 2  $\mu$  or less. Therefore, in cross-section or when on edge, they seem to be very narrow, elongated, and dense staining; on surface view, on the other hand, they stain very weakly and are of a great variety of form, with rounded angles, lobulated, constricted like a kidney, or elongated. In general, they are larger than the nuclei of the sclera; rounded forms have a diameter of some 12  $\mu$ ; elongated forms may attain a length of 27  $\mu$ . The nucleus has a very delicate and fine-meshed chromatin net and 1 to 3 very fine nucleoli lying in a district poor in chromatin.

According to Ballowitz (14), each cell contains a microcentrum in the neighborhood of the nucleus in the form of two central bodies united by a bridge; yet no radiating arrangement of the protoplasm can be made out about this microcentrum.

According to the view of v. Recklinghausen (177), the cells and their processes lie in an extensively subdivided system of canals and canaliculi (lymph canal system), which provides for the circulation of the fluid and the nutrition of the cornea. Since then it has been conclusively shown by Leber (138) that this view is untenable. The union between the cells and the *substantia propria* is only more easily broken up than is the union

between the respective lamellae of the *substantia propria*, and for this reason one can inject the canal system about the cells, and for the same reason the wandering cells are principally found lying between the fixed cells and the *substantia propria*.

The **wandering cells** are migratory leucocytes with clear or weakly granular protoplasmic bodies and heavy staining, lobulated or fragmented nuclei (Pl. II, 8, *w*). Their form is determined by the amount of room which the cell has; in the clefts they are pressed down flat; within the lamellae they appear to be drawn out into long spindles conforming to the direction of the fibers.

Blood-vessels are entirely absent in the stroma of the cornea proper; on the other hand, a richly developed nerve-plexus is present; this is distributed over Bowman's membrane and to the epithelium, as well as to the stroma.

#### The Nerves of the Cornea

Unfortunately ordinary stains do not bring out the corneal nerves at all. To demonstrate them one uses gold chlorid, or better the Dogiel methyl-blue method, which makes the finest branches and the nerve-endings visible.

According to Hoyer (107), 60, and according to Dogiel (43), 60 to 80, small branches enter the periphery of the cornea; the finer ones lie forward, the coarser ones behind. They contain medullated as well as non-medullated fibers; the former lose their medullary sheaths 0.3 to 0.5 mm from the margin of the cornea (Hoyer); they give off non-medullated fibers (which break up into finer fibrillae, Dogiel) at the nodes of Ranvier, as well as at the ends of the medullated fibers.

In this way an extensive branching of the small trunks comes about, and they and their branches press toward the center of the cornea and toward the surface. The totality of this branching and anastomosing forms the **plexus proprius** of the cornea (H. Virchow); the peripheral parts of the cornea are supplied by the anterior branches, the middle by the posterior. The *plexus proprius* is not found at all in the posterior layers of the cornea, is coarser and looser in the middle layers, and becomes finer and finer and more richly subdivided as it approaches the surface. It ends near Bowman's membrane in a reticular formation (the **terminal net** of H. Virchow).

From this the perforating bundles and fibers (the *rami perforantes* of the older authors) are given off; these go obliquely toward Bowman's membrane and come out through its pores. Thus they reach a position beneath the epithelium, break up then into fibrillae and broaden out between the epithelium and Bowman's membrane as the **basal expansion**

(H. Virchow) (**subepithelial plexus**, of the older authors). Part of the fibrillae or branches from the basal expansion extend directly forward in the intercellular spaces of the epithelium (**intraepithelial expansion**).

The nerves in the stroma end by little plates, according to Dogiel; these are irregular, quadrilateral or spade-form, flat structures with dentate or serrated edges. These endings are found only along the border of the cornea. According to Dogiel, the nerves do not unite with the corneal cells.

Hooked and looped endings as well as end-skeins (identical with W. Krause's end-bulbs) are found immediately beneath the epithelium at the limbus and also beneath the marginal portions of Bowman's membrane. The nerves in the epithelium itself end by round or pear-shaped end-bulbs.

#### 4. DESCMET'S MEMBRANE (*Lamina elastica posterior*)

(Pl. II, 9, D)

This is a typical "glass membrane."

By "glass membranes," in general, one means highly refractile, structureless (homogeneous) membranes of great firmness and elasticity; at times they have an indistinct lamellation.

Their homogeneity is shown by the fact that no striation or reticulation of their structure comes out even under the highest magnification of their surface; moreover, it is shown by the form of broken and torn edges, for these show an irregularly rounded or slightly angular line. Sometimes the torn edge has a terrace form, indicating a certain degree of lamellation; at times this same formation comes out in different layers as a variation of the staining.

The firmness of "glass membranes" is shown by their resistance to chemical agents and by the lack of histolytic effect of pus in pathologic cases. With respect to their elasticity it should be said that they, the glass membranes, are not elastically distensible in the sense that rubber is; they are only elastic in so far as they have the tendency to take on a certain form of their own, somewhat as a watch-spring does. This certain form is a curve just the opposite of that which the membrane has *in situ*, i.e., the membrane shows a tendency to roll up toward the side opposite. Moreover, the membrane *in situ* rests in a certain state of tension; so wounds of a glass membrane gape plainly, although not widely.

With respect to their formation, the glass membranes are to be looked upon as *cuticulae*, i.e., as surface secretion products of a layer of cells along their base, i.e., along the side (of the cells) turned toward the connective tissue.

Descemet's membrane can be detached from the corneal stroma with relative ease, and so shows two equally plain and sharp contours upon cross-section. In its staining reactions it shows a distinct difference from the corneal stroma. Even with eosin a slight difference is made out, and this is still plainer by Van Gieson's stain: the stroma appears deep fuchsin-red, the Descemet's membrane rose-red to orange-yellow, according to the



degree of differentiation. Most striking, however, is the difference after staining for elastic fibers with orcein or resorcin-acid-fuchsin, for then the stroma is without stain, and Descemet's membrane dense brown or violet; yet the stain is by no means as intense as it is in the case of the elastic fibers or in the intima of arteries.

In any case, there is a great difference between the Descemet's and Bowman's membrane, and the name *lamina elastica posterior* is, therefore, much better adapted to Descemet's membrane than is *lamina elastica anterior* to Bowman's.

Pathology furnishes a further difference between the two membranes. Not the slightest trace of regeneration is found in lesions of Bowman's membrane, while lesions of Descemet's membrane are covered over after some time by a new glass membrane.

Descemet's membrane is 5-7  $\mu$  thick in the mid-portions; toward the border the thickness increases to 8-10  $\mu$ . In the immediate neighborhood of the border wart-like elevations appear along the inner surface, as a rule (Pl. IV, 1, *w*). These are almost semispherical or semiellipsoidal, sharply demarkated projections between which the inner surface is again smooth. The breadth of this wart zone (Pl. III, 2, *w-d*) increases with age, as does the thickness of the whole membrane. The border proper of Descemet's membrane and its relation to the scleral meshwork will be spoken of in connection with the latter.

#### 5. THE ENDOTHELIUM OF THE CORNEA

(Pl. II, 9, *En*)

This is a layer of single cells measuring some 5  $\mu$  in height and 18-20  $\mu$  in width. Unlike other endothelia, these cells are rich in protoplasm and the nucleus is completely imbedded in it. Upon cross-section, the cells, therefore, appear almost rectangular, with a slightly oval, non-prominent nucleus; the protoplasm is often grossly granular or shows normal granular vacuoles; the outlines of the individual cells are sometimes oblique or curved.

In surface view the nuclei appear round (7  $\mu$ ) and are quite regularly arranged, so that most of the cells retain a rounded six-sided form (Pl. III, 2, *D*). The cell-outlines are not always entirely clear, because of the oblique course already spoken of, so that by a change in the focus a change in the form of the cell is produced. But if one compare these cells with those of other endothelia, whose cell-outlines, as is well known, can only be demonstrated by special methods of preparation, the cells of the corneal endothelium must be said to be sharply defined.

From a purely morphologic standpoint, therefore, this layer is more like an epithelium than an endothelium; yet on the basis of its developmental history one

must regard it as endothelium (cf. chap. xvi) and, furthermore, it is continuous with endothelium of the usual appearance.

The endothelium extends over nearly the entire inner surface of Descemet's membrane. Only in the region of the wart zone does it take on another appearance, especially noticeable on surface view (Pl. III, 2); the cell-outlines disappear completely, the granulation of the protoplasm likewise, the nucleus becomes somewhat larger, oval, and goes back into the interspaces between the warts, so that an irregular distribution of the nuclei results. The height of the cells also decreases, especially over the warts (Pl. IV, 1), where only a very thin scarcely distinguishable protoplasmic covering is present.

#### b) *The Limbus corneae*

This, as already indicated, forms a transition zone between the cornea proper on the one side and the adjacent tissues (conjunctiva and sclera) on the other side. In the limbus there are combined certain characteristics of the neighboring structures, e.g., the transparency which at least a greater part of the limbus has in common with the cornea, the vascularization and the richness in special nerve-endings which characterize the conjunctiva. The limbus, moreover, shows transitions, for in its territory the stroma of the cornea goes over into that of the conjunctiva, of the episcleral tissue, and of the sclera.

The borders of the limbus have already been given, but since the corneoscleral border is so difficult to recognize in stained specimens, the following is given as an aid to orientation for the beginner (Pl. I). The borders of Bowman's and Descemet's membranes can be found even with moderately low power; if one think of the ends of these two membranes as united by a line, this line is almost parallel to the outer part of the corneoscleral border and lies 0.75 to 1 mm from it. The difference which the corneoscleral border shows in the horizontal and vertical meridian also comes out in the line of union between the borders of the two basal membranes.

Accordingly, one can differentiate only two layers in the limbus: the epithelium and the stroma.

#### I. THE EPITHELIUM OF THE LIMBUS CORNEAE

Even over the marginal portions of Bowman's membrane the epithelium is somewhat thicker than it is in the middle; over the limbus this thickening increases and in the neighborhood of the corneoscleral border attains its maximum (80 to 90  $\mu$ ). The back border of the epithelium (toward the stroma) loses its straight course and becomes wavy; indeed,

papillary forms appear at times. The thickening of the epithelium is due to an increase in the number of layers; their number mounts up to 10 or more.

As in the cornea proper, the epithelium is stratified and squamous; only the appearance of the basal cells is altered in the region of the limbus. While the basal cells of the cornea proper are larger and rich in protoplasm and have nuclei which in size and staining are no different from those of the next layer, the basal cells at the very limbus are at once small, scant in protoplasm, and have small dense-staining nuclei. The epithelium retains this kind of basal cells in its further course over the conjunctiva and they are characteristic for the conjunctival epithelium. The rest of the cells keep the peculiarities of the corneal epithelial cells, and the low cylindrical cells which appear on the surface and are characteristic for the conjunctiva, first appear beyond the corneoscleral border. One sees, therefore, that the transition of corneal epithelium into conjunctival epithelium does not take place throughout the entire thickness of the layer all at once, but along the base before it does on the surface.

Since, too, the basal cells are more closely pressed together, the epithelium of the limbus and of the conjunctiva shows a **dark seam** along its base, even by low power (Pl. I). This seam is often found even at the border of Bowman's membrane, but often first appears a considerable distance from it. It is not rare to find small islands of basal cells strewn along and first united into an unbroken line in the conjunctiva sclerae.

## 2. THE STROMA OF THE LIMBUS CORNEAE

The stroma of the outer layers loses its regularity even opposite the marginal portions of Bowman's membrane. Beyond the limits of this membrane it loses the regular arrangement of its spaces (parallel to the surface) and takes on the appearance of an ordinary connective tissue—first in the outer layers only, then in the deeper ones as well. It seems to be especially the appearance of blood-vessels which brings about this alteration in appearance.

Occasionally one sees fine capillaries just beneath the surface immediately outside the margin of Bowman's membrane. Farther away the lumina are more numerous, are encountered also in the deeper layers, and are intermixed with larger vessels as well. This brings us into the territory of the **superficial marginal vessel-loops**, the only vessel-net of the cornea, its sole organ of nutrition. The area occupied by the marginal vessel-loops shows, on meridional section, the form of a triangle with its apex at the border of Bowman's membrane and its base continued into the conjunctiva, sclera, and the episcleral tissue.



The marginal loop net is supplied by the terminal branches of the anterior ciliary arteries. Leber has made a beautiful drawing of it (138); according to him, when viewed from the front it is seen to be made up of very fine, small straight arterial branches, which build bow-formed anastomoses. From these arches the final branches are given off; these are very fine (5 to 6  $\mu$ ); they course on farther in a meridional direction and then suddenly coil about into the venules. The venous trunks of the loops are, for the most part, at least twice as wide as the arterial ones and unite with their neighbors to form a finely subdivided net, emptying into the episcleral venous net.

On the other hand, the layers lying deeper, on a level with the sclera, are vesselless in the region of the limbus, or at the most provided with a few vessel-loops scarcely going beyond the border of the sclera. These layers go over into the sclera in such a way that at first the lamellae preserve their transparency, but gradually they take on the form and staining reactions of scleral bundles.

Elastic fibers are also found in the limbus but they are very sparse in comparison with those in the adjacent tissues.<sup>1</sup> They are most numerous and extend farthest centralward in the superficial layers of the limbus, those layers continued into the conjunctiva and the episcleral tissue; they only come out here and there in the deeper layers. Their frequent appearance is a sure sign of scleral tissue.

I cannot refrain from once more remarking that in many particulars the microscopic specimen does not appear to agree with the findings in life. The beginner most readily falls into the error of considering that the sclera reaches farther central than is actually the case, for he forms his judgment upon the staining of the tissues, and the darker staining of the sclera as a matter of fact does extend somewhat beyond the border into the limbus.

Another confusion which easily occurs is the following: the conjunctiva and the episcleral tissue seem to be sharpened and to end in the limbus, and the sclera to thicken the cornea to just this extent. In reality the course of the connective-tissue bundles, parallel to the surface, is not essentially disturbed, as one can see best in those pathologic cases in which inflammatory infiltration of the conjunctiva and the episcleral tissues extends over onto the cornea.

It is, therefore, entirely justifiable to speak of a *conjunctiva corneae*, i.e., the superficial layers of the cornea may be considered as a continuation of the *conjunctiva sclerae*. However, this expression must be extended to include not alone the epithelium and Bowman's membrane but the most superficial lamellae of the stroma, as well.

The nerve-endings found in the limbus have already been considered with the nerves of the corneal stroma.

---

<sup>1</sup> Although one speaks of elastic fibers, for short, only those which are positively stained by orcein or resorcin-fuchsin are meant.

## CHAPTER III. THE STRUCTURES OF THE SCLERAL FURROW

## THE CANAL OF SCHLEMM AND THE MESHWORK OF THE IRIS ANGLE

(Pl. III, 1)

Close to the bottom of the scleral furrow (cf. p. 20), i.e., separated from the scleral tissue by only a thin layer of tissue, one or more lumina are seen; these have a closed endothelial covering and are usually considerably larger and more prominent than the spaces of the meshwork of the iris angle which lie farther inward. These lumina form the **Schlemm's canal**, *sinus venosus sclerae* (Merkel), *circulus venosus ciliaris* (Leber) (*Sch*).

The expression canal is incorrect for this structure in that it relatively seldom is a single elongated lumen, and then for a stretch of only 0.2 to 0.5 mm in a horizontal direction; usually there are two or more lumina; they lie side by side or over one another in the scleral furrow. Seen from the surface, Schlemm's canal is like the bed of a great stream which flows along undivided for a stretch, then is divided into several branches for a stretch. For this reason the form of the lumen changes in various sections of the same eye.

The endothelial lining of Schlemm's canal has the same appearance as in other vessels and forms an extremely thin membrane with nuclei projecting inward. Aside from the endothelium, Schlemm's canal has no real wall, at least none such as one finds in other vessels of the same size; it seems to be simply entrenched in the adjoining tissue. On the other hand, it is not correct to say that the endothelium lies immediately upon the sclera, for a loose tissue, poor in fibers but rich in cells, is interposed between the two, as a rule; sometimes this is only a thin layer, sometimes it is quite well developed. One sees this layer best in sections stained with Van Gieson; the tissue is then sharply set off from the deep red of the sclera by its yellow color.

One encounters a similar tissue on the chamber side of the canal, usually, only there it is less developed or is not present as a continuous layer and is poorly differentiated from the neighboring trabecular meshwork. On the other side it extends along the veins (*v*) going off from Schlemm's canal into the sclera.

Schlemm's canal is in any case closed off from the spaces in the meshwork lying inward to it, i.e., no visible breaks in its wall are present. For this reason only solutions, or the finest suspensions, such as ink, pass into the canal; cells remain in the meshwork of the iris angle and lie outside the wall of Schlemm's canal.

On the other side, however, the canal communicates freely with the venous system by means of vessels given off here and there along the

scleral side of the canal; these go obliquely outward and backward into the sclera and unite with the anterior ciliary veins (*V*) while still within the sclera. An actual capillary net for the supply of the canal does not exist, and it must be that some of the deeper limbus capillaries give off blood to it; in any case it seems to connect laterally with the ciliary venous system as a whole, if one may judge from the direction of its blood stream (Leber, 1138).

In prepared specimens the lumen of the canal is usually empty or contains only a few red blood cells. Complete filling of the whole canal with blood only comes about in a stasis of the venous system, e.g., in persons who are hanged.

In the question as to whether or not the canal contains blood or aqueous during life, I am disposed to the view that it contains aqueous. It is certainly demonstrated that its main rôle is to carry away the aqueous, and its position to one side of the actual course of the blood-stream warrants the supposition that it carries aqueous. On the other hand, a slight circulation disturbance during life or hypostasis in the cadaver is probably quite sufficient to fill it partially or entirely with blood owing to its open communication with the veins.

Possibly it is not superfluous to call attention to the fact that a hypostasis, i.e., a post-mortal sinking of the blood owing to the force of gravity, can play a certain rôle in the fairly well closed vessel system of the eye, small as it is; this is true not only of cadaver-eyes but also of eyes enucleated in life which have been placed in a slow-working conservation fluid. The hypostasis is shown by the fact that the veins, or even the capillaries, on one side of the bulb are completely filled with blood, on the opposite side, empty. The matter of the side upon which the filling is found naturally depends upon the position of the eyeball while the sinking is going on.

Schlemm's canal occupies only about the posterior half of the scleral furrow, and not even all of this, since the scleral roll (*Sw*), springing axialward from its back border, overhangs the furrow considerably. The **meshwork of the iris angle** (H. Virchow) fills out the rest of the depression.

Considered in and of itself, this peculiar structure presents itself as a three-sided prismatic band, of which the anterior edge is extremely sharp and unites with Descemet's membrane (at *D*) and the most posterior lamellae of the cornea (at *T*). Behind, it unites with the scleral roll, the anterior surface of the ciliary body and, by a devious way, with the root of the iris (*r*), as well. Its outer surface borders directly upon the corneal and scleral tissue in front and upon the inner wall of Schlemm's canal, or the loose tissue surrounding it, farther backward; its inner surface is free and turned toward the chamber space.

Its union with neighboring structures can best be demonstrated by pure anatomic preparations. If one detaches the ciliary body from its



insertion to the sclera from behind, one obtains quite a complete preparation of the meshwork. A seam, consisting of the meshwork and the marginal portions of Descemet's membrane, of whitish color and more than 1 mm in width, then remains clinging to the anterior end of the ciliary body.

If one now separate the iris from the ciliary body, the innermost meshwork, united with the iris root as well, stays attached to it, while the main mass of the meshwork along with the border of Descemet's membrane remains hanging to the ciliary body. In this way one separates two portions, which, at least in the main, are different from one another in their gross structure as well as in their histologic composition. Seefelder and Wolfrum (205) have retained the old name *ligamentum pectinatum* for the part remaining in union with the iris, and support Rochon-Duvigneaud (182) in calling the rest the *trabeculum sclero-corneale*. H. Virchow (234) has recently introduced the term **uveal** for the former and **scleral** for the latter meshwork.

These two portions are of very unequal bulk; the uveal meshwork is a delicate, thin structure which one can barely make out with the dissecting *loupe*. By far the greater part of the whole structure belongs to the scleral meshwork.

When one studies a meridional section, the uveal meshwork (*i*) appears to be made up of only a few obliquely or longitudinally cut sections of delicate trabeculae lying wholly superficial along the inner surface; these do not give the idea of a special formation at all and are entirely overlooked by the beginner. One may about as well say that only scleral meshwork is visible in meridional section, for it makes up so much of the whole mass.

The study of surface and teased preparation as well as of cut sections is unconditionally necessary for a proper conception of the make-up of the entire meshwork. The method of obtaining these was given above. I begin with the description of the scleral meshwork and first its anterior border.

In the first place this border is united with the border of Descemet's membrane. As already noted (pp. 37-38), the marginal portions of this membrane are characterized by warts and changes in the endothelium. The actual border (*D*) is, apparently, sharp and plain; the membrane often maintains the same thickness to the border; in other cases it becomes rapidly sharpened off near the border.

As a matter of fact the glass membrane does not stop here but continues over the trabeculae of the iris angle as a very thin layer. The appearance of an ending is only brought about by the fact that the glass

membrane thins out so suddenly, and especially by the fact that as one follows along Descemet's membrane toward the root of the iris one necessarily at length comes upon a hole in the membrane in the situation where naturally the membrane stops in the given section.

At the end of Descemet's membrane lies the **anterior border ring** (Schwalbe). It sets immediately upon the outer surface of this membrane or appears to be imbedded in its substance (Pl. IV, 1, *vG*). It is a flat bundle of circularly fibrillated connective tissue supported by elastic fibers which stain well with orcein. It varies in its position, thickness, and breadth very much in different eyes as well as in different portions of the same eye, yet one seldom misses it completely in meridional sections.

In surface preparations (Pl. III, 2, *vG*) it stands out owing to its fairly compact and circular fibrillation, i.e., fibrillation parallel to the margin of the cornea; it represents the most anteriorly placed (corneal) area in which one finds circularly fibrillated connective tissue supported by elastic tissue. The most anterior spaces opening into the anterior chamber are encountered first posterior to it. When the meridional section goes through one of these foremost spaces (as in Pl. IV, 1, at *d*), one sees how the Descemet's membrane, which is still thick at the anterior surface of the border ring, bends about the margin of the space and continues over the outer surface of the border ring as a thin glass membrane; farther forward it again merges into Descemet's membrane or goes over into the deeper portions of the meshwork.

The anterior border ring can to a certain extent be looked upon as the superficial or circular root (with respect to the anterior chamber) of the meshwork. In a histologic sense it is in no respect different from the meshes lying immediately posterior to it. Since its fibers leave their meridional course and spread apart from one another in bundles, the thick, compact anterior border ring passes backward over into a mesh of flat, compressed, thin bands (Pl. III, 2, right part of the drawing). Glass membrane and endothelium, somewhat modified, continue over the trabeculae and round out the spaces of the meshwork.

The most posterior lamellae of the cornea also go over into the meshwork, and this transition is completed even 0.1 to 0.2 mm in front of or axial to the end of Descemet's membrane. In meridional sections one sees at this point (Pl. IV, 1, *T*) a group of longish nuclei between the 2 or 3 most posterior lamellae, i.e., those immediately bordering Descemet's membrane. These nuclei belong to the endothelium. With the proper stain one also recognizes a lighter homogeneous seam (glass membrane) interposed between the endothelial nuclei and the connective tissue; the latter has a meridional fiber-direction, and yet does not show

any elastic tissue fibers by orcein staining. These first make their appearance farther back, where the division and threading of the bundle is richer, and the direction of the fibers more nearly circular. At last the trabeculae take on wholly the same appearance as those coming out of the anterior border ring. The border of Descemet's membrane and the anterior border ring are, therefore, to a certain extent undermined.

Still clearer is the transition of the corneal tissue into the meshwork in teased preparations (Pl. III, 2, left side of the drawing). The fiber mass of the particular corneal lamella divides up into narrower bundles, which, however, are always very flat, and bend about into a meridional direction (*T*). These bundles contain a glass membrane and an endothelial covering and become ordinary trabeculae (*Tr'*) in the course of further subdivision and reticulated union. One may, therefore, look upon these as constituting the deep or meridional root of the meshwork.

The *trabeculum sclerocorneale*, or the **scleral meshwork**, thereupon comes out of both roots. Its trabeculae are pressed down flat (perpendicular to the surface of the bulb) and form a mesh in which a coursing of the fibers parallel and circular to the surface predominates. One may then just as well speak of a structure of fenestrated lamellae formed by the union of obliquely coursing bundles. One obtains this impression in meridional sections especially. The holes (windows) in these lamellae are drawn out in a circular direction in the middle layers and are of varying size and distance apart, so that the trabeculae lying between them are sometimes broader; sometimes narrower. The spaces between superimposed lamellae do not lie over one another.

The bulk of the meshwork (or the number of the trabeculae) increases from before backward, partly because new trabeculae radiate into the meshwork from the floor of the scleral furrow, although this only holds true for the portion lying in front of Schlemm's canal, in greater measure because the lamellae increase by new branchings. Whereas anteriorly, behind the border of Descemet's membrane, possibly 3 or 4 lamellae lie over one another, their number mounts up to 15 to 20 at the posterior end (in front of the scleral roll).

On the outside (toward Schlemm's canal) the trabeculae lose their dominant circular direction, the branches become more stellate, the meshes more rounded and smaller, the trabeculae more delicate (Asayama, 9).

The individual trabecula (Pl. II, 10) consists of four elements. Its foundation is formed by a thick non-nucleated bundle of collagenous fibrillae; the fibrillae run parallel to the long axis of the trabecula, therefore, mainly circular (*b*). This connective tissue is supported along its surface by relatively thick elastic fibers (*f*); they course in nearly the



same direction as the collagenous fibrillae and are, therefore, cut obliquely in meridional sections and appear as points, which do not disappear upon change of focus but, at best, change their position. They are not plainly visible by ordinary staining yet their presence brings about a very much sharper definition of the tissue, a darker contour.

A glass membrane (*g*) succeeds the elastic fibers; this is thicker along the surfaces than upon the edges of the trabecula. It possesses all the tinctoral and morphologic peculiarities of Descemet's membrane and can be followed into it. The trabeculae do not arise simply by a splitting up of Descemet's membrane, as depicted by the older authors, but are rather entirely covered over by a continuation of Descemet's membrane.

The whole is finally covered by an endothelium (*e*) which, as usual, shows no cell borders, so one can recognize the individual cells only through the prominent oval nuclei. The cell-body usually forms an extremely thin membrane, at least along the sides of the individual trabeculae, which one cannot differentiate from the contour of the membrane; the cells contain protoplasm (are thicker) only in the angles and corners of the meshwork and partially fill out the angle. The spaces in the meshwork, which from the course of the fibers would otherwise be angular, are thereby rounded out. If the section goes close to such an angle it encounters only the rounded endothelial cell although the converging trabeculae still appear separated, and one obtains the impression that the endothelium forms a bridge between the individual trabeculae (to be seen in most of the places marked *e*).

The endothelium of the meshwork is also only a continuation of the endothelium of the cornea. It covers over all the trabeculae and so clothes all the spaces of the meshwork, but is not united in any way with the endothelium of Schlemm's canal. No cell-nuclei other than those of the endothelium are found in the scleral meshwork; the entire structure contains neither blood-vessels nor nerves.

Two stains are especially to be recommended for the study of histologic structure of the trabeculae: the orcein stain and that of Van Gieson. The first brings out the elastic fibers clearly; the glass membrane stains also slightly though far less heavily than does Descemet's membrane. Van Gieson's stain colors all connective tissue an intense red, the glass membrane rose-red to orange-yellow, the protoplasmic body of the endothelium a pale yellow. Finally, absolutely meridional sections are indispensable; one then gets pure cross-sections of the trabeculae and clear pictures, and the sections do not need to be as thin by half.

It should be an easy thing in this way to distinguish endothelium from glass membrane—two layers which are not differentiated with the necessary precision in all contributions concerning the meshwork. Moreover, the endothelium is perishable; it is thrown off in eyes with advanced cadaverous appearances, and it likewise may disappear under pathologic conditions.

The glass membrane, however, is indestructible, and even in the severest pathologic changes the cross-section of the trabecula (aside from the endothelium) maintains its characteristic appearance.

Posteriorly, the main mass of the meshwork goes over into the scleral roll, as stated above. This consists of a large number of wide and narrow connective-tissue bundles with the exact appearance of scleral fiber-bundles and pursuing an absolutely circular course (for dimensions see p. 23). Peripherally they are supported by large elastic fibers; these fibers are even a trifle larger than those in the meshwork. A connective tissue lies between the circular bundles in the form of a mattress-work and completely fills out the interspaces; this tissue is incompletely separated into bundles in which the fibrillae have a more oblique course. The trabeculae go directly over into this tissue, and as a rule one can see two rows of elastic fibers in every such stripe; these are apparently the continuations of the layers of elastic fibers present on the two surfaces of a trabecula. Anteriorly and inward the scleral roll has no sharp limits; the circular bundles become smaller and so finally disappear in each direction.

Schwalbe (194) spoke of the scleral roll as the posterior border ring of the meshwork (*ligamentum pectinatum* in his terminology), and this name has, indeed, a certain justification, for the scleral roll varies considerably in its structure from that of scleral tissue. On the other hand the histologic peculiarities are not limited to the scleral roll but extend to the parts of the sclera lying outside and behind it as well. Here, too, the circular fibrillation predominates, the bundles are narrow, and the large elastic fibers are present. Gradually this formation goes over into ordinary scleral tissue (H. Virchow).

The size of the scleral roll shows individual variations, but it never includes the whole thickness of the meshwork. A limited number of trabeculae (lamellae) are always excluded, and these course past the inner border of the scleral roll and proceed directly to the fore surface of the ciliary body and are lost there in the intermuscular connective tissue.

The **uveal meshwork** (H. Virchow, 234), *ligamentum pectinatum* of Seefelder and Wolfrum, is the inner portion, that going to the iris root; it springs in part from the inner surface of the scleral meshwork a slight distance from the border of Descemet's membrane, in part, although probably to a lesser extent, from the border of the latter (Pl. III, 2, *i*).

Moreover, in its further course the uveal meshwork is pressed against the scleral and, therefore, usually passes by and around the sinus angle in a bow, i.e., goes along the anterior surface of the ciliary body over to the



root of the iris (Pl. III, 1). As already noted, one sees very little of this portion on a meridional section; only a surface preparation clears up its formation (Pl. III, 3). The trabeculae which make up the uveal meshwork are not flattened down, as in the scleral meshwork, but rounded like wire, provided here and there with roll-like thickenings, so that they appear turned out as by a lathe; in any case expansions come out only at the nodal points of the meshwork.

These trabeculae form a very loose reticulum made up of wide polygonal meshes with a tendency to stretch out in a meridional direction.

The histologic make-up of these trabeculae is the same as that of the trabeculae of the scleral meshwork, except that the **elastic fibers fail**, and the differentiation of the central strand of connective tissue from the glass membrane is less complete, its contours are softer as the artist says. Thereby the trabeculae belonging to the uveal meshwork are easily distinguished from those of the scleral, even in ordinary staining (Pl. II, 10, *i*). The transition to iris tissue (Pl. III, 3, *I*) is completed as follows: the endothelium goes over into that of the anterior surface of the iris; the glass membrane vanishes, the central connective-tissue strand becomes fibrillated and so merges into the connective-tissue stroma of the iris. The pigmented cells of the anterior surface of the iris (chromatophores) often dispose themselves along these trabeculae, even as far as the scleral meshwork.

In addition, the so-called **iris processes** appear here and there, yet they are not to be found in all eyes. They are cord-like structures projecting from the anterior surface of the iris at the ciliary border and consisting of the same elements as iris tissue; they are considerably thicker than the trabeculae of the iris angle and pigmented, when the iris itself is. These processes more or less tortuously bridge over the iris angle and unite with the uveal meshwork. For further details of their relationship to the relief of the anterior surface of the iris, see chap. x.

#### CHAPTER IV. THE PERICHORIOIDAL SPACE AND THE SUPRACHORIOIDEA

The perichoroidal space is an extremely narrow cleft lying between the inner surface of the sclera and the outer surface of the uvea; it has almost as great an expanse as the sclera itself. Its forward limit is formed by the insertion of the ciliary muscle into the scleral roll; behind, toward the optic nerve, the space becomes less plain to the eye and probably ceases altogether some distance in front of the nerve, especially on the

temporal side in the region of the *fovea centralis*. Extensions of this space go into the emissaria (see p. 19).

The lumen of the perichoroidal space is probably nil in life, i.e., the two border walls and the lamellae lying between them adjoin each other directly. In the hardened eye, however, one often finds this space distended, especially when Mueller's fluid is used for fixation.

The two coats cling firmly together whenever blood-vessels go from the chorioidea to the sclera, or vice versa, as in the localities of the vortex veins and the short posterior arteries. Pathologic detachments of the chorioidea, therefore, usually stop at the vortex veins or are traversed by furrows at these places.

As a section through the entire eye shows best, the whole perichoroidal space is traversed by delicate lamellae going from the uvea to the sclera, i.e., coursing from in front and within, outward and backward, but in such an oblique direction that when *in situ* they appear to lie parallel to the bordering walls. These lamellae fuse together here and there, and from place to place contain large round openings. The whole perichoroidal space is in this way subdivided into smaller portions, which, however, communicate through the openings.

The number of lamellae lying over one another in any given place is something like 6 or 8. In the posterior part of the perichoroidal space the lamellae are shorter, the unions between the uvea and sclera, therefore, more frequent; fewer lamellae lie over one another. Forward, they are longer, therefore the union is more loose and the lamellae apparently more numerous. In the region of the ciliary muscle the lamellae gradually disappear between the muscle-bundles, so that in this zone the number of the lamellae steadily decreases from behind forward and the most anterior reaches of the perichoroidal space immediately behind the scleral roll seem entirely empty.

Nothing is easier to make than a surface preparation or a teased specimen of the suprachorioidea; one needs only to tear off one of the delicate brown fragments which always cling to the outer surface of the uveal tract in greater or lesser number with a fine forceps. One may mount it in glycerin or water and study it without further preparation, or stain as desired and mount it in Canada balsam. Only in such a preparation can one study the arrangement of the suprachoroidal lamellae; the meridional section only brings out the lamellae as extremely fine lines, in which nothing more than nuclei and chromatophores can be made out.

Each suprachoroidal lamella (Pl. IV, 2) has an **endothelial coat** as a basis; this is an entirely transparent, structureless, extremely fine membrane with only here and there an oval, or somewhat irregular, very flat nucleus and 1-2 fine nucleoli (*e*). This membrane is supported by a rich plexus of **elastic fibers** (*f*). These fibers stain in the usual way, notably

heavier than those of the sclera, but always much more delicately than those of ordinary connective tissue. They are straight or weakly bowed; for the most part they form a plexus, i.e., the fibers cross in various directions and the angular branchings and insertions here and there seem to form a reticulum. No particular direction predominates; only at the margins of openings in the lamellae do the fibers press together and form a sort of ring.

The **chromatophores** (*ch*) form the third structural element essential to the suprachorioidea; these are flat, branched cells whose bodies as well as processes are densely filled with fine brown pigment; the nucleus is oval or irregular, and likewise flat. In places where elastic fibers pass over the cell the pigment fails, as a rule, and it looks as if the cell were cut in pieces, especially in unstained preparations. The form of the cells varies greatly: in the outer layers of the suprachorioidea the cells, as in the *lamina fusca sclerae*, are plump and have only a few short broad processes. In the inner layers the processes are more slender, longer, and plainly set off from the nucleated cell-body.

The chromatophores, which we meet here for the first time, are an important and characteristic constituent part of the whole uveal tract. Much as they vary in their form and in their content in pigment in the different parts, yet certain properties are common to all forms: Their pigment consists of very fine round granules, finer and more of a black brown (*melanin*) than the epithelial pigment. In comparison with other forms of cells their processes are thick and are pigmented, as is the cell-body. The number of these processes, their length and size vary within wide limits; there is an unmistakable tendency to surface union in the form of nets, or a meshwork in space. Many times they form, therefore, a syncytium. Yet one finds places enough where the chromatophores are so sparse that there can be no thought of a reticulum.

Muench (160) believes he has found a cross-striation of the protoplasm of the chromatophores, especially in the processes. He holds this cross-striation to be mainly the expression of a very closely wound spiral. The muscular nature of the chromatophores follows from the spiral structure, according to Muench. In addition to this there is union with nerve-fibers.

I will not dispute these contentions, especially since Lauber (137) and Schock (191) have corroborated them, yet I have not so far been able to see the cross-striations. I cannot see what purpose so richly developed a net of muscular elements could have in the chorioidea. According to this view, the chorioidea must possess a much greater contractility than the iris. But so far as we know, the chorioidea has no active motion, and, moreover, the experiments of Muench indicate at most only a certain elasticity, nothing more. Moreover, the chorioidea should possess no motion, at least in its back portions, because then any exact localization of visual impressions would be impossible.

All these fixed structures of the suprachorioidea are so thin and flat and so united to the endothelium which forms their groundwork, that the cross-section of an individual suprachorioidal lamella often appears only



as a simple fine contour. At best the cross-section has a measurable thickness only when a nucleus or the body of a pigment cell is involved. It is hardly possible to say, therefore, on which side the endothelium and on which side the other elements lie. To judge from the few places especially favorable for observation, the endothelium lies sometimes on the chorioidal, sometimes on the scleral surface side of the lamella, in places, indeed, on both sides, probably as a result of the fusion of neighboring lamellae.

Moreover, wandering cells are present in varying numbers. They differentiate themselves from the endothelium, with which they may, of course, be confounded by the beginner, by their dense-staining nucleus and the plain non-pigmented but frequently granular protoplasmic seam.

The entire suprachorioidea is without vessels, i.e., it possesses no capillary system and, with the exception of the strands now to be described, no collagenous connective tissue. Two large arteries, the *a. ciliares posteriores longae*, do, indeed, course through the perichorioidal space, but they give off no branches in the suprachorioidea. The finer structure of these strands (see pp. 12-13) is as follows (Pl. III, 4). The artery (*A*) is bordered on each side by a strand of collagenous tissue, which contains a varying amount of smooth muscle-fibers (*m*). The latter are connected with the ciliary muscle, into which the artery finally enters; they have a longitudinal direction and are, therefore, only seen in cross-sections (Pl. III, 4). Ciliary nerves are found on both sides of this connective tissue strand; one of these is regularly larger (*N*<sub>1</sub>), the other smaller (*N*<sub>2</sub>). The latter branches off from the larger while it is still within the emissarium. The larger nerve lies below the artery on the nasal side, above on the temporal side. The nerves are flattened down at right angles to the bulb wall and show an oval cross-section; the whole strand is finally surrounded by suprachorioidal lamellae.

The remaining isolated ciliary nerves show the same form and investiture. The fibers of the ciliary nerve have sheaths of Schwann like all peripheral nerves; they are nearly all medullated but in varying degrees; the neurolemma is extremely thin.

The ciliary nerves give off many finer branches, which break up into still finer plexuses in the inner layers of the suprachorioidea and farther on in the chorioidal stroma; many of these branches consist of only a few or a single non-medullated fiber. In the nodal points of these plexuses, and here and there in the course of the nerve branches, larger ganglion cells are interposed (Pl. IV, 2, *n*). These ganglion cells are all multipolar, according to the statements of the authorities, and serve vasomotor

purposes. They have their endings in the blood-vessels of the chorioidea (cf. chap. v).

The presence of smooth muscle-fibers in the suprachorioidea will be considered in the description of its union with the ciliary muscle (chap. ix).

#### CHAPTER V. THE CHORIOIDEA (CHORIOIDES)

The chorioidea is a quite thin, soft, brownish membrane possessing a certain degree of elasticity, and standing under a moderate tension during life, or it shows a slight tendency to gape on a solution of its continuity.

Its outer surface is quite uniformly brown and dull, on account of the suprachorioidal lamellae which cling to it; its inner surface is smooth and under water shows a weak reflex—the pigment epithelium must first be teased away.

By transmitted light, and, for the most part, even when against the light background of the sclera, one sees the larger vessels as clear streaks, the interspaces as brown flecks. The intensity of this pigmentation depends in general upon the complexion: brunettes have a more densely pigmented chorioidea than do blondes. The vessel system is easiest made out in the anterior portions of the chorioidea, because the chorioidea is in general thinner here, the vessels larger and disposed more in a single layer.

That which first strikes the observer are the *vortices*, figures formed by the confluence of the veins. Each such vortex (Pl. III, 5) includes, however, not simply the veins of the chorioidea but also those of the two other zones of the uvea (with few exceptions); these veins from in front are quite straight, those from the sides and behind are more tortuous and the lateral ones form bows with their convexities forward. The larger stems arising out of the union of these vessels lie in front of the center of the vortex, for the most part, and, therefore, converge in their further course backward; in this way the whole figure comes to have the appearance of a sheaf or a fountain. The point where all the vessels unite is widened into an **ampulla** of 1.5 to 2 mm (Fuchs, 65), and the somewhat narrower **vortex vein** goes out of this and soon enters the sclera (see p. 18).

The position and number of the vortices is shown by the exit points of the vortex veins, with which we are already familiar (p. 9). The vortices lie about the length of the emissaria in front of and somewhat more removed from the vertical meridian than do the points of exit of the veins. So the vortices come to lie 2.5 to 3.5 mm behind the equator and, like the veins, are grouped into two pairs, an upper and lower. The distance between the members of a pair is about half as great as the distance between the pairs (Fuchs, 65). Not infrequently the number of the vortices is greater than that of the veins, i.e., instead of one vortex



there are two separated halves, and the corresponding veins unite within the sclera.

The vessel system is more compact and the interspaces more obscured by pigment in the region of the posterior pole; to the naked eye this part of the chorioidea, therefore, appears only flecked with brown. But with the not inconsiderable magnification of the ophthalmoscope one can, however, see the larger vessels here when the interspaces are either abnormally heavily pigmented (tessellated fundus) or not pigmented at all (albinotic fundus). In moderate pigmentation of the interspaces the fundus is uniformly red.

From this it follows that the visibility of the chorioidal vessels is dependent not only upon the pigmentation of the spaces between the vessels but also upon the color of the pigment epithelium. By themselves the chorioidal vessels, aside from the capillaries, would easily be seen with the ophthalmoscope, as shown by those pathologic cases in which the pigment epithelium and the choriocapillaris are destroyed but the other layers of the chorioidea are intact. The pigment epithelium lies over the vessel system of the chorioidea like a brown veil, and the darker this veil is the more it obscures the details of the chorioidea.

In study by the ophthalmoscope one obtains the impression that the larger vessels of the chorioidea form a richly divided network. This is a misconception, however, as a more accurate anatomic study and especially injection experiments (Leber) show, and is brought about by a repeated crossing of the vessels. Since we see the vessels very indistinctly and do not see their thin walls at all, we look upon the crossings as anastomoses. In reality these are much more rarely present than one would think from the ophthalmoscopic picture; only the capillaries form an actual net.

The thickness of the chorioidea is usually given as very slight; but, when one remembers that the vessels are often empty after death and the whole membrane, therefore, collapsed, one must come to the conviction that the chorioidea is essentially thicker than it appears in most sections. One must, therefore, consider areas in which the vessels are filled with blood, then it develops that the region of the posterior pole has a thickness of 0.22 mm (183). Wolfrum (240) also found a similar figure—0.3 mm for the thickest place. Toward the periphery the membrane gradually decreases to one-half (0.1 to 0.15 mm).

In the histologic study of the chorioidea I prefer the hardening in Mueller's fluid to all others; the hardening in formalin, especially, is not at all adapted to finer study, because the chorioidea is always thereby much compressed. Besides cut sections, surface and teased preparations should be studied. To obtain these, one cuts a piece

of the chorioidea out of the hardened bulb, first brushes the pigment epithelium away from the inner surface, and lays the piece, inner surface down, in a dish filled with water or weak alcohol, fixes it with a finger of the left hand and begins to tease at the outer surface with a fine forceps. First one removes suprachoroidal lamellae (and one should study the inner lamellae; the nerve-fibers and ganglion cells are found here) and then one comes upon the larger vessels. One grasps the wall of one and pulls in the direction in which the finer branches lie. In this way one can gradually remove the whole layer; finally there remains a thin unpigmented layer: this contains the capillaries and glass membrane. A separation of these two in an anatomic way is impossible, yet by tearing this membrane one very easily produces step-like borders, i.e., the capillary layer clings to one fragment, the glass membrane, a slight distance in front, to another in a way entirely adequate for the study of the finer structure of these layers.

The cohesion between the vessel layer and the capillary layer is decidedly less than that between the other layers, otherwise one could not make a pure preparation of a great expanse of the capillary layer, but a real space does not exist between these two. In well-stained specimens the connective-tissue stroma is seen to be continuous.

If the suprachorioidea, which was described in the preceding chapter as a tissue filling out the perichoroidal space, be not considered, this anatomic preparation of the chorioidea shows a division into three main layers: (1) The vessel layer (*stratum vasculare*); (2) The capillary layer (*choriocapillaris*); (3) The glass membrane (*lamina vitrea, s. elastica chorioideae*).

#### I. THE VESSEL LAYER

(Pl. IV, 3, Gf)

This layer forms the main mass of the chorioidea and is the bearer of the macroscopic markings—those visible with the ophthalmoscope.

A further division of this layer into one with vessels of larger caliber and one, inward, with vessels of lesser caliber (Sattler, 187) can be made out in the thicker parts of the chorioidea. The richer development of the whole vessel system, and the principle of the arrangement whereby the caliber of the vessels decreases from without inward, condition this stratification.

The matter is not to be taken thus literally: often enough one is in doubt where to place the limits of the two layers, and transitions in caliber are numerous. I cannot, therefore, accept the view of Nuël (166) that the separation of these two layers is equally as sharp as that between the vessel layers and the choriocapillaris, and I do not, therefore, recognize any "intervascular space."

According to Nuël, the arteries predominate in the layer of larger vessels; this, also, is probably true only for the posterior (polar) portions of the chorioidea and is apparently only the result of a sharp separation in space which the arteries and the venous trunks of the chorioidal vessel

system show (cf. chap. xv). On the other hand the veins very markedly predominate over the arteries in the layer of the middle-sized vessels. This latter statement is without doubt correct, at least in so far as one encounters more venous lumina than arterial lumina in this layer. Yet the increase in venous lumina is certainly in part only an apparent one, for the veins are more tortuous and, therefore, more often cut across.

In the region of the *fovea centralis*, where the chorioidea attains its maximum thickness, the layer of larger vessels and the perichoroidal space disappears entirely, according to Nuël, while the smallest veins increase appreciably in size and many times lie over one another in layers. In the equatorial parts of the chorioidea the separation of the larger from the smaller vessels is likewise lost, for the smallest arteries and veins go over into the capillary layer, while the rest of the vessels are broadened out into a single layer.

Histologically, the vessels show the ordinary structure (Pl. III, 6). The arteries (*A*) have a plainly developed muscularis, which can be followed into the arterioles (precapillary branches); there it becomes reduced and, according to Wolfrum (240), consists of polymorphous structures whose branches surround the vessel lumen like polyps. An adventitia of finely fibrillated, almost homogeneous, collagenous tissue, traversed by thick elastic fibers, follows upon the muscularis.

The veins (*V*) have perivascular sheaths (*p*), i.e., a second protoplasmic tube, provided with flat nuclei, about the endothelial lumen (*e*), whereupon follows the connective-tissue adventitia. This is relatively better developed about the small vessels than about the larger ones, yet varies greatly in its development with the age of the individual.

The **chorioidal stroma** fills out the vessel interspace. This consists mainly of the same elements as the suprachorioidea, except that here collagenous fibrillae are added. From without inward the stroma very gradually changes in its make-up; the outermost layers still contain many endothelial membranes and flat chromatophores, so that they scarcely differentiate themselves from the adjacent suprachoroidal lamellae. Indeed, the farther inward one goes the more the dimensions of the chromatophores increase; their bodies become smaller, their processes more slender. Their position changes, also, in that they become related to the vessel walls, i.e., their processes broaden out parallel to the vessel wall. The endothelium becomes less prominent or goes over into connective-tissue cells, the elastic fibers become finer, collagenous tissue increases in amount.

The small vessels lying immediately outside the capillary layer still contain a few chromatophores in their interspaces, but inside this layer,



i.e., inside the border line between the vessel and capillary layer, no more chromatophores are found. Here the stroma consists only of collagenous and elastic fibers mixed with a few flat cell-nuclei.

Numerous nerve-fibers, the last branches of the ganglionated plexus beginning in the suprachorioidea, traverse the chorioidal stroma, especially in company with the arteries (*n*). Moreover, one also encounters ganglion cells (*g*) in the inner strata of the vessel layer, although only scatteringly.

Its further branchings and endings have been studied by Bietti (24) by Golgi's method. According to this author, a meshwork of the very finest sort is interposed between the above described nerve-fibers. Other nets surround the arteries; their fibrillae show many varicosities and end with club-form or spherical swellings in the vessel musculature. Another finer nerve-plexus lies beneath the *lamina vitrea*.

The statements concerning the presence of smooth muscle-fibers in the chorioidal stroma (outside the vessel walls) are founded principally upon a contribution of H. Mueller (159).

According to this author, the smooth muscle-fibers together with a plexus of small nerve bundles lie along the sides of the arteries. They are easiest to find by the side of the long posterior arteries (cf. p. 51), are present, as well, however, along the short posterior arteries. According to Schweigger (195), these smooth muscle-fibers lie by the side of a plexus of clear ganglionated nerve-fibers in the innermost vessel layer. Wolfrum (240), on the other hand, absolutely denies the presence of muscular elements outside the walls of the arteries.

The demonstration of smooth muscular fibers in the chorioidal stroma is one of the most difficult things in histology, and I can say that I have not been able to see them there with certainty up to this time, i.e., in the stroma of the chorioidea proper. It is certain, on the other hand, that smooth muscle-fibers are present in the suprachorioidea and, furthermore, far behind the *ora serrata* (cf. chap. ix, 1).

These muscle-fibers play a very subordinate rôle, in any case. The generalization of Fukala (70), therefore, that the whole uveal tract, with the exception of the posterior pole, is invested with a muscle-net, certainly is improbable. It can only be explained by a misunderstanding and is apparently a resuscitation of the statement of Iwanoff (115) concerning the endings of the ciliary muscle, and the data of F. Eilhard Schultze (196) concerning the reticular arrangement of the muscle tissue along the inner surface of the ciliary muscle, and the above statements of H. Mueller.

## 2. THE CAPILLARY LAYER (*Choriocapillaris*)

(Pl. IV, 3, C)

The layer can be spoken of as characteristic of the chorioidea, for the most important difference between the equatorial portions of the chorioidea and the most posterior zone of the *orbiculus ciliaris* consists in the

presence of this layer in the one and its absence in the other. Furthermore, the chorioidea is different from all the other vessel-containing portions of the eye in that its capillaries are broadened out into one plane, i.e., they do not build a meshwork, as elsewhere, but do form a net, which is, moreover, characterized by the width of the individual capillary vessels; while elsewhere the capillaries are so narrow that the blood corpuscles can only pass one after another in single file, and even then must often stretch out, there is room for several blood corpuscles side by side in the capillaries of the chorioidea. In addition, local widenings of the vessel by sac-like distentions of the capillary wall are frequent.

The network of the capillary layer is especially thick in the posterior parts of the chorioidea, i.e., in the region of the *fovea centralis retinae* and its immediate neighborhood; its meshes are rounded and the interspaces of the capillaries smaller than the lumina themselves (Pl. IV, 7). The smallest arteries and veins pass from without fairly perpendicular into the capillary layer (Passera, 168), and break up, star-like, into capillaries, i.e., each of these small vessels divides up at once into capillaries upon its entrance into the capillary layer, and these radiate out in all directions. In teased preparations one sees these small afferent and efferent vessels in optical cross-section only (*x*); one recognizes these relations better on cross-sections (Pl. IV, 3, *V*).

Farther toward the periphery the meshes of the capillary net continually become wider and longer (Pl. IV, 1). The main difference is due, however, to the fact that not only do the capillaries show distentions and great variation of caliber, but also that the smallest arteries and veins course in the capillary layer itself, and the break-up into capillaries takes place by feathery or dendritic branchings.

In the region of the *ora serrata* the network becomes remarkably loose and finally ceases with irregularly projecting loops or extensions. The capillary net is more or less interrupted over the recurrent arteries (*A*).

A net of narrow capillaries lying inside the choriocapillaris (cf. chap. ix, 4), is found on the border between the chorioidea and ciliary body, according to Sattler (187).

The **capillaries** (Pl. III, 7), as elsewhere, consist of simple endothelial tubes strewn with oval, quite densely-staining nuclei (*e*), which, according to Wolfrum, lie either in the interspace or on the outer side of the capillary wall, i.e., on the vessel-layer side. The interspaces (interstices) of the capillary net (*i*) are filled out by an almost homogeneous non-nucleated **stroma**; special stains are necessary to show its very fine collagenous and elastic fibrillae.



The collagenous tissue forms the main mass of this stroma; it is an extremely delicately fibrillated tissue, staining only a faint rose-red by Van Gieson. Outward it is continued into the stroma of the vessel layer, which in its innermost layers, as already reported, contains the same constituents as the tissue filling out the capillary interstices. The elastic fibers are especially fine, and, according to Wolfrum, are found mainly in the immediate neighborhood of the capillary wall; they are united inwardly with the elastic lamella of the glass membrane and outwardly with the **subcapillary fibrillar net**.

This net (*f*), likewise, consists of collagenous and somewhat larger elastic fibrillae and separates the capillary layer from the vessel layer. Since the places at which the smallest arteries and veins go over into the capillaries are separated from one another by relatively wide intervals, these expansions of the stroma lying between the capillaries and the layer of the smallest vessels take on a flattened-out or reticular character, and occasionally give the impression of an independent layer, especially in teased specimens. Cell-nuclei also lie in the subcapillary fibrillar net; Sattler, in his time, considered them to be the nuclei of an endothelial membrane, but Wolfrum now looks upon them as nuclei of connective-tissue cells, because they belong to the branched cells and have granular protoplasm (*sc*).

One can see the nuclei in question best in surface preparations of the capillary layer treated with a nuclear stain, such as haemalaun. Two systems (or kinds) of cell-nuclei then come forth in the otherwise unstained tissue. One system belongs to the capillaries; the nuclei are rounded or oval and stain quite densely; they lie partly in the contour of the capillaries, partly (apparently) in the lumen. The other system (the subcapillary nuclei) belongs to a plane lying farther outside; a slight turn of the micrometer screw is, therefore, necessary to focus upon the subcapillary nuclei if one has previously had the capillary wall in focus. The nuclei are larger, of more irregular form and less densely stained, and do not correspond in their position to the capillaries, i.e., sometimes they lie over the capillaries, sometimes over the interspaces.

With respect to these nuclei, I can only corroborate the view of Wolfrum; an endothelial membrane such as Sattler postulates would presuppose at least a cleft space. But no such thing is to be seen in well-stained sections; the stroma of the capillary layer goes uninterrupted over into the stroma of the vessel layer and, indeed, its collagenous as well as its elastic elements.

A fine nerve-plexus lies beneath the glass membrane, therefore between it and the choriocapillaris, according to Bietti (24) and Smirnow (208).

3. THE GLASS MEMBRANE (*Lamina vitrea s. elastica*)

This possesses the physical and on weak magnification also the morphologic peculiarities of glass membranes in general. One must use a very high magnification to recognize, on its outer surface, not a homogeneous, but an extremely fine and faint, network. The torn edges of the surface preparation (Pl. III, 7) very often show a terraced form, i.e., there are present two contours which do not coincide, an indication that the glass membrane itself consists of two further lamellae.

In cross-section (Pl. IV, 3, *Lv*) the glass membrane appears as a very highly refractile membrane, some  $2\ \mu$  thick, firmly grown to the stroma of the capillary layer especially, whose elements, as already stated, arise at least in part from those of the glass membrane. Yet a stroma is present only in the interspaces of the capillary net; the individual endothelial tubes lie immediately on the glass membrane without any intervening layer.

The outer contour of the glass membrane—that turned toward the capillary layer—is sharper, darker, often not exactly straight, and finely granular; the inner contour, turned toward the pigment epithelium, is more delicate—“softer” in the sense of the artist—and entirely straight and uniform, except for the depositions which appear in old age. These variations are also simply expressions of the fact that the glass membrane is made up of two lamellae.

Toward the entrance of the optic nerve the membrane, which in general has a quite uniform thickness, becomes much thicker (3 to 4  $\mu$ ), and the two lamellae can be made out more easily. Concerning the ending of the glass membrane at the optic-nerve entrance, compare the anatomy of the optic-nerve entrance (chap. viii, *a*).

From their position the two lamellae making up the glass membrane can be called the **outer** and **inner**; from their nature they may also be distinguished as **elastic** and **cuticular** lamellae.

The **outer** or **elastic lamella** (Pl. III, 7, *el*) bears the above reported clear network, first described by Sattler. Smirnow (208) later demonstrated a dense plexus of finest elastic fibers in this network by the orcein stain. The Sattler network corresponds to the larger bundles of this elastic mesh only, and Smirnow has called it the *stratum elasticum supra-capillare*. As stated, this is united with the elastic fibers of the capillary interstices and to a certain extent closes off the whole elastic system of the capillary layer inward. In general, this lamella has no measurable thickness; by itself it appears only as a contour on cross-section, and, moreover, the elective elastic fiber stain only makes this contour sharper, not broader. In the region of the optic-nerve entrance, alone, the elastic

lamella is thicker and to the same extent that the glass membrane, in general, is thickened. Its fibrillae come out more plainly and take on a more and more circular course.

Some 0.1 mm from the edge of the optic-nerve canal, where the choriocapillaris disappears as a closed layer, the subcapillary elastic fiber net appears over the glass membrane and this latter gives off larger and more numerous elastic fibers. A circular mesh of elastic and collagenous fibers of considerable thickness arises in this way; on cross-section it appears as a layer of some 2  $\mu$  thickness and, on account of the rich mass of elastic fibers which it contains, it stains quite otherwise than the neighboring structures. As a result of the circular course of the fibrillae, this layer appears finely punctate or granular upon meridional section of the papilla, but, on the other hand, longitudinally striated in sections tangential to the border of the papilla.

The **inner** lamella (Pl. III, 7, *cu*) is entirely homogeneous, like other glass membranes, and is apparently a cuticular formation of the pigment epithelium, as shown by the pathologic cases in which a certain kind of regeneration or hyperplasia of this lamella takes place; it should, therefore, be called the **cuticular** lamella.

By ordinary staining this lamella seems to form the main mass of the glass membrane, i.e., the cuticular lamella makes up almost the entire thickness of the glass membrane.

Wolfrum (240) recognizes a *lamina elastica chorioideae* and a basal membrane of the pigment epithelium. The latter is only about one-half as thick as the former and gives a protoplasmic as well as a collagenous tissue-staining reaction. A space, traversed by finest collagenous fibrillae, lies between the two membranes. It appears that these details can only be demonstrated by special staining methods, especially such as Held's protoplasmic stain, and are, therefore, not visible after ordinary stains.

I have not seen collagenous tissue between the two membranes in my preparations up to this time, yet the presence of this tissue has nothing improbable about it, since such can be easily demonstrated in an analogous situation in the ciliary body without special staining.

## CHAPTER VI. THE PIGMENT EPITHELIUM OF THE CHORIOIDEA<sup>1</sup>

To the naked eye this forms a thin, uniformly brown covering over the inner surface of the chorioidea. A darker, indistinct area about twice the size of the papilla (Usher, 230) comes out only in the region of the *fovea centralis retinae*. Even moderate magnification shows a fine flecking, due to the fact that not all the cells are so pigmented as to be equally dark; this is also visible by the ophthalmoscope: the characteristic granulation of the fundus comes from the pigment epithelium.

<sup>1</sup> For the justification of the term see p. 13.



The pigment epithelium is made up of a single layer of protoplasmic cells with a diameter of about 16  $\mu$ , most of which appear six-sided upon surface view (Pl. III, 8). This hexagonal form is due to the regular arrangement and uniform size of the cells; when individual cells are smaller than the rest, they have less than six corners, when larger, more. Viewed in this way, the cell-body appears uniformly filled with pigment; the round or weakly oval nucleus, measuring about 7  $\mu$  in diameter, is more or less surrounded by pigment; the cell borders, on the other hand, come out as sharp, unstained stripes of almost 1  $\mu$  width. The so-called **cement substance** consists of neurokeratin, a material which, too, covers over the surface of each cell on the side toward the chorioidea in a thin layer (Kuhnt, 128).

Seen in cross-section (Pl. IV, 3, *P*), the cells appear more quadrilateral, their height is only about half their breadth (8  $\mu$ ), the pigment fills out only the inner part of the cell and leaves a thin layer of the protoplasm bordering the glass membrane outward entirely free, so that a part of the nucleus is very plainly visible. The outer half of the protoplasm shows a radial structure, according to Kuhnt. The cement substance is only partly seen on cross-section—where it runs exactly at right angles to the direction of section. The form of a pigment epithelial cell is a low six-sided prism, according to this.

Each pigment epithelial cell carries a large number of fine processes (*PF*) along its inner surface; these project inward between the outer members of the rods and cones. Since it is extremely difficult to obtain the retina *in situ*, these pigment processes are very rarely seen in the human, especially, since on account of their fineness they are only to be made out as such in extremely thin sections. In sections of ordinary thickness (15 to 20  $\mu$ ) they are fused into a uniformly pigmented stripe. I can, therefore, give nothing more in detail concerning their form; I suspect they represent moulds of the interspaces between the outer members of the visual cells.

The relation of the outer members of the visual cells to the pigment epithelium is much better seen in the retina of amphibians (frogs, tritons), because these animals have colossal rods and pigment epithelium in comparison to warm-blooded animals. The phototropic shifting of the pigment is also much more easily demonstrated in these animals.

I have measured the length of the pigment processes in a faultlessly fixed human retina and found it to be 5  $\mu$ ; it is, however, possible that the processes are still longer and that the pigment only mounted up to this height. Whether a shifting of the pigment (**phototropic pigment displacement**) by illumination also takes place in mammalia, and in man

in particular, has not yet been definitely settled (Garten, 73); the displacement of the pigment must in any case be very slight.

The pigment granules (Pl. III, 9) are rounded in the outer portion of the cell, longish, like crystal needles in the inner portion, notably in the processes.

With the ultramicroscope, the rounded granules appear deep red-brown, the long ones, on the other hand, a light brownish yellow (Raehlmann, 176). Kuhnt (126) calls the pigment of the epithelium *fuscina* on account of its color and form; it is very resistant to chemical influences, but bleaches in acids when in the light.

The crystal-needle form is not marked in man and the granules look more like rods or spindles. According to Raehlmann, a large number of very small particles in the form of light-yellowish bacterial rods are to be seen only by ultramicroscopic means, in addition to the above-described pigment granules. Moreover, some of the fuscina needles consist of and are made up of several such short rods bound to a longer one by a protoplasmic substance. This latter substance is reddish in the darkened eye of an animal and bleaches out in the light, just as visual purple does, and for this reason Raehlmann holds it to be identical with the visual purple.

The pigment epithelium of the chorioidea is especially distinguished from all other pigment cells of the eye by the elongated form of the granules. When, therefore, the epithelium of the chorioidea breaks up and its granules are carried away, their origin can be recognized from their longish form. It is, nevertheless, incorrect to reverse the conclusion that round pigment granules exclude origin from the pigment epithelium of the chorioidea, because first, it also contains rounded granules in the normal state, and second, its pigment may be completely transformed into roundish granules in pathologic conditions.

As one may note, I have avoided the term *cap* for the part of the cell turned toward the chorioidea and *base* for the portion bearing the processes. Much as they are used, they stand in direct conflict with the fact that elsewhere that side of the epithelium turned toward the mesoderm is called the base (cf. the expression "basal membrane," "basal cells").

In general, the pigment epithelium of the chorioidea shows a very uniform development; variations from the type are found only in the region of the *fovea centralis* and *ora serrata*.

In the region of the fovea (Pl. III, 10) the cells are higher (11 to 14 mu) and narrower (9 to 11 mu), the cement ridges are more delicate also; this is the main reason for the darker color of this region. In the neighborhood of the *ora serrata* one encounters exceptionally large cells, often with several nuclei, along with moderately large and normal-sized cells (Text Fig. III, 11); the diameter of such cells may attain 60 mu or more. The regularity of the epithelial layer also suffers thereby, and the pigmentation is often quite lacking in uniformity. At the very fore end of the retina the cells are again smaller and parallel to the border of the retina; in this way stripes arise; sometimes these are plain, sometimes not (often somewhat lighter than the neighborhood); these separate



the pigment epithelium of the chorioidea from that of the ciliary body. These stripes follow exactly the course of the *ora serrata* or reproduce its zig-zag form in a weaker way. In any case the border zone of the epithelium is clearly seen, for the pigment epithelium of the ciliary body appears much darker than that of the chorioidea.

The region of the *ora serrata* is probably very often the seat of light pathologic changes, especially in older individuals, which have not occasioned any functional disturbance in life. These changes are of the same order as those resulting from light chorioiditis: partly a disappearance, partly a hyperplasia of the pigment epithelium and a fusion of the same to the retina.

#### CHAPTER VII. THE RETINA<sup>1</sup>

The retina is a soft inelastic membrane, completely transparent during life except for the blood stream in the vessels; at the *foramen opticum chorioideae* it is united with the intraocular end of the optic nerve (*papilla nervi optici*); in front it ends with a more or less dentate border (*ora serrata*). At both these places the union with the neighboring structures is a firm one; otherwise the outer surface of the retina is only united to the pigment epithelium in the above-described way, and this union is a relatively loose one;<sup>2</sup> a separation of this connection (*ablatio retina*, detachment of the retina) is, therefore, frequent not only under pathologic conditions but also as an artefact and post-mortal appearance. Artificial and post-mortal detachment of the retina stops, however, at the optic nerve and *ora serrata* (pathologic detachment often extends beyond the *ora serrata*). The inner surface of the retina is smooth and aside from the slight bulgings occasioned by the larger blood-vessels and from the *fovea centralis*, is even, as well, and, therefore, reflects light in young individuals (the retinal reflex of ophthalmoscopy).

The retina is thickest at the border of the optic nerve, especially above and below it (some 0.4 mm), a little less on the nasal side and very much less on the temporal (Pl. IV, 4). The retina thins out toward the periphery to about 0.14 mm, rapidly at first, then more gradually. Only the temporal side forms an exception.

<sup>1</sup> In the stricter or clinical sense of the word; cf. the remarks on p. 13.

<sup>2</sup> According to a newer conception (Halben, *Die Kopulation der Netzhaut mit der Aderhaut durch Kontaktverbindung*, Berlin, 1910), this union is much more firm than one has heretofore held it to be. A simple mechanical pull is not sufficient to separate the connection between the two membranes. A primary insult to those organs concerned in the copulation, i.e., to the rods or the pigment processes, is necessary.

Here lies the **fovea centralis**; this is an obliquely oval, flattened funnel-form depression (Pl. V, 4) with its center some 3.5 mm away from the border of the *foramen opticum chorioideae* and a little below the middle of it; its size is about the same or a trifle greater than that of the *foramen opticum chorioideae* (Dimmer, 40); the horizontal diameter may measure up to 2 mm.

The edge of the depression forms a low wall (*w*) sloping off very gradually into the normal level of the retina but is more steep toward the center, and is uniformly bevelled (*clivus*, *cl*). The larger the fovea the more gradual, the smaller the more steep this declivity is, yet its angle never attains more than 25°. According to Kuhnt (130), a flat area (**fundus foveae**) lies in the center of the fovea, and exactly in the middle of this is a small, very concave little depression, the **foveola**. According to Dimmer, however, a *fundus foveae* is found only in a very large flat fovea, otherwise the *clivus* goes directly over into the foveola, in the region of which the radius of curvature of the retina is only something like 0.04 mm.

In the same way, the relative thickness of the walls of the retina in the region of the fovea is as follows: the wall is somewhat higher on the nasal side (0.275 to 0.41 mm) than on the temporal side (0.22 to 0.35 mm); in the foveola the thickness of the retina is 0.075 to 0.12 mm; all these measurements are taken from Dimmer.

The so-called retinal reflexes, which are often so marked, especially in young hypermetropic individuals, have an extremely changeable appearance in the extra-foveal portions of the retina, since the slightest alteration of the direction of the incoming light causes the reflex to disappear, possibly to reappear elsewhere. In the foveal region, however, the retinal reflexes have a greater constancy in form and presence because here there are only two places on the inner surface of the retina which can so reflect light that it will pass through the aperture of the ophthalmoscope and, therefore, become visible to the observer as reflected light (Pl. VII, 1). These places are the wall and the foveola: the wall has the form of a ring and gives a ring-form reflex, the so-called *macular reflex*; the foveola acts like a concave mirror and produces a reduced, inverted image of the part of the ophthalmoscope in front of the pupil. The *foveolar reflex*, therefore, usually has a crescentic form, because one almost always uses a perforated mirror (Dimmer, 39).

Since the *clivus* is directed so much away from the course of the rays which enter the eye, the light reflected from it cannot again go out through the pupil; in its sphere the reflex of the inner surface of the retina fails completely, therefore, and this is one reason why the region of the fovea appears darker than the neighborhood in the ophthalmoscopic picture; a second one is the slight thickness of the retina, a third the denser pigmentation of the epithelium (cf. p. 61).

On anatomic study the district of the *fovea centralis* shows a citron to orange-yellow color (**yellow spot**, **macula lutea**). The greatest intensity of this color is found in the immediate neighborhood of the center

(the foveola). The very center itself has a much more weak but still yellow color (because of the lesser thickness of the cerebral layers in this situation); the yellow color gradually fades away toward the periphery; it is impossible, therefore, to give accurate dimensions for the yellow spot although it is usually larger than the fovea.

The lighter color (citron-yellow) occurs in young persons (Chevallereau and Polack, 31), the darker color (orange) in older persons.

The *macula lutea* is seen best in not-too-old cadaver-eyes, in which the retina is already clouded. In entirely fresh eyes, enucleated during life, one sees the yellow color as little as with the ophthalmoscope, provided the retina is transparent and *in situ*. The apparent reason for this is that the transparent yellow color (lacquer-color) lies upon a brown background, or, to the ophthalmoscope, a red background. In the latter case there is added the factor that the source of light which one ordinarily uses for this purpose is itself very yellow. If one uses daylight, on the other hand, one can see the yellow spot in darkly pigmented individuals with the ophthalmoscope, although under these circumstances it seems considerably smaller than the macula in the cadaver (Dimmer, 42).

When one detaches the fresh retina immediately after the enucleation of the living eye, broadens it out on a slide, and studies it upon a white background, one at once sees the yellow fleck, as recently re-established by Chevallereau and Polack in a number of cases.

Gullstrand (81), on the other hand, accounts for the *macula lutea* as a post-mortal appearance, because he has succeeded in so detaching the fresh retina by patiently shaking it in a physiologic salt solution, that it appears completely colorless.

#### a) *Microscopic Anatomy and Histology of the Retina*

The investigation of the structure of the retina is one of the most difficult tasks in histology, not alone because its extremely complicated make-up can only be analyzed by special methods, but because the retina is an extremely delicate and perishable structure. The retina is subject to cadaverous changes much earlier than other tissues, irrespective of whether the bearer of the eye dies or the eye is enucleated during life, and with no other tissue of the eye must one so often and insistently ask himself the question whether that which one sees under the microscope actually corresponds to the relations in life or whether one has before him a post-mortem change, or an artefact, wholly aside from the matter of pathologic alterations. The history of the investigation of the retina is rich in errors of this sort and has, indeed, even recently furnished opportunity for criticism (cf. "*macula lutea*").

From this comes the demand that only absolutely fresh, healthy material be used in the study of the retina, which unfortunately is not so easy to obtain in man. Naturally the best are the normal eyes sacrificed because of large tumors of the neighborhood.



Severe injuries come second into consideration, eyes which must be enucleated immediately after the injury. Yet even the freshest material must be quickly fixed, otherwise cadaverous changes at once supervene. Such rapidly working fixation fluids as osmic acid,  $3\frac{1}{2}$  per cent nitric acid, concentrated sublimate solution, Zenker's fluid, are best adapted for this purpose and must work from the side of the vitreous; the eye must come into the fixing fluid cut up—and, indeed, it is then a piece of good fortune to obtain a wholly unobjectionable preparation.

Every section perpendicular to the surface of the retina shows very plainly, even on weak magnification, the stratification of this membrane. This picture, surprising in its regularity, is brought about by the fact that two non-nucleated layers, or layers which stain very poorly, alternate with nuclear-rich ones; after nuclear stains, such as haemalaun, two layers, especially, come out as sharply-stained stripes: the two nuclear layers. A third less intensely stained stripe, inward to these, represents the ganglion-cell layer. This much is sufficient for a cursory orientation of the layers of the retina.

On more accurate study one recognizes nine layers in the retina; they are given herewith from without inward: (1) layer of rods and cones; (2) *membrana limitans externa*; (3) outer nuclear layer; (4) outer plexiform layer; (5) inner nuclear layer; (6) inner plexiform layer; (7) ganglion-cell layer; (8) nerve-fiber layer; (9) *membrana limitans interna*.

The connection between the individual layers is effected in part by an extension of the elements from one to another, in part by a system of special **supporting fibers**. In the description of the individual layers one begins with the extrafoveal districts of the retina, not because one expects to find the type of the retina in the structure of this district, but because this structure extends over the greatest part of the retina and any section through the eyeball can be made use of for the study of the extrafoveal district; the extreme peripheral portions are of course excluded.

#### I. THE LAYER OF RODS AND CONES

(Pl. IV, 3, SZ)

On weak magnification this layer appears finely striated in a direction at right angles to the inner surface of the chorioidea; this is due to the palisade arrangement of its elements. The thickness of the whole layer is greatest in the middle of the *fovea centralis*—in my preparations 58 to 67  $\mu$ , according to Greeff (76) 85  $\mu$ ; Dimmer (41), on the other hand, considers the greater thickness of this layer in the fovea to be an artificial effect. Toward the periphery the thickness decreases quite rapidly, so that only 1 mm from the center of the fovea the whole layer is, indeed, only some 40  $\mu$  thick. Farther on the thickness decreases much more slowly (37 to 40  $\mu$  in the equatorial portions). Heinrich Mueller



(158) gave somewhat larger figures (minimum 40  $\mu$ ) for the peripheral portions. Even by low power the rod-and-cone layers can be seen to have two divisions, an outer less densely stained and an inner more densely stained one; the border between the two portions lies about half-way between the ends of the pigment processes and the *membrana limitans externa*. It is the difference between the outer and inner members of the elements which brings out this division into two portions.

The elements out of which this layer is constructed are of two kinds: The **rods** are slender cylindrical structures with a length corresponding to the thickness of the entire layer, a breadth, however, of only 2  $\mu$  or less. Each rod is provided with a somewhat longer, slenderer, highly refractile **outer member** (*a*), and a shorter, thicker, finely granular **inner member** (*i*).

The outer member is double refracting and shows very fine longitudinal furrows (stripes); it consists of a hull of neurokeratin and a contents made up of small diagonal plates some 0.5  $\mu$  thick held together in roulette form by a cement substance. A disintegration of the outer member into its platelets or amorphous droplets comes about very easily after death or in various fluids, and a shepherd's staff or looped bowing of the ends apparently represents a fore-stage of this destruction.

The inner member, of which the protoplasm is not so highly refractile, also shows a fine longitudinal striation in the portions adjacent to the *membrana limitans externa*. This is due to the last extensions of Mueller's supporting fibers, the so-called *fiber-baskets*. The *fiber apparatus*, a system of fibers which course longitudinally on the surface and within cross at narrow angles, lies in the outer third of the inner member. Furthermore, the inner member contains a diplosome near the outer end, according to Held (93). From this a thread (*outer thread*) is given off outward, going through the hull of the entire outer member. A second thread extends inward (*inner thread*), and can in any case be followed to the *limitans externa*.

With the exception of a 3 to 4 mm wide zone at the *ora serrata*, the outer members of the rods contain the **visual purple**, a transparent red coloring matter which bleaches out rapidly in the cadaver, but regenerates in the dark, as long as the union with the pigment epithelium is preserved. The visual purple makes the whole retina appear red, with the exception of the above-mentioned peripheral zone and the rod-free area of the fovea. Yet one only sees this in the fresh retinae of eyes which have been previously kept in the dark.

One cannot see the visual purple in man with the ophthalmoscope because the fundus (pigment epithelium and chorioidea) is already colored red; but in animals which have a white fundus, like the crocodile, a so-called *tapetum retinale*, the visual purple is visible and one can follow its blanching with the ophthalmoscope, likewise in certain fishes (Abelsdorff, 1).

The cones are flask-form structures likewise possessing a thinner **outer** and a thicker **inner member**. The outer member is narrowed conically

toward the apex, the inner member bays out, yet the form and dimensions of the cones vary a great deal with their location.

The longest and slenderest cones are found in the center of fovea (for the measurements see p. 66), for their inner member is only 2.5  $\mu$  thick (Greeff, 75). These **foveal cones** (Pl. V, 3, *fZ*) look more like rods than they do like the other cones, but their cone nature is made clear by the absence of visual purple. The **extrafoveal cones** decrease in length toward the periphery, particularly in the outer member, which is reduced to a miniature cone of 6  $\mu$  length at the *ora serrata*. The inner member is some 3  $\mu$  shorter than the neighboring inner members of the rods and takes on a more and more bellied form toward the periphery (up to a diameter of 7.5  $\mu$ , according to Greeff).

With respect to the finer structure there is great similarity between rods and cones: both show the same constituents. The thread apparatus is especially well developed in the cones; it consists of a thick fiber mesh and occupies two-thirds of the inner member.

The cones contain no visual purple.

The distribution of the rods and the cones and their relations to each other are best studied in surface preparations of the retina—in which the thicker cones appear as larger discs, the thinner rods as smaller discs.

In the center of the fovea is a district containing only cones; it has a diameter of about 0.5 mm—according to Fritsch (63), only 0.15 mm. But the very slender cones are found only in the middle of this district and in irregular arrangement; toward the border of this field the cones are notably thicker and are arranged in oblique rows (Fritsch, 63); a beautiful drawing of the cone-mosaic of the fovea has been published by Heine (92). Outside this field the rods appear; at first they are strewn about among the cones; soon, however, they become united into a simple circle about each cone. Farther on the rods become more and more numerous and the cones wider apart until some three to four circles of rods intervene between two cones (Pl. V, 2). This distribution is attained some 4 to 5 mm away from the center of the fovea and is then maintained quite constantly to the periphery. In the most extreme periphery the cones are again relatively increased.

## 2. MEMBRANA LIMITANS EXTERNA

(Pl. IV, 3, *Le*)

This is an extremely delicate, sieve-like, perforated membrane, visible as a fine, continuous, or streaked line only in absolutely perpendicular sections. The holes correspond exactly to the elements of the rod-and-cone layer in number and position, for they serve for the exit of the fibers going out from these elements.

The *m. limitans externa* belongs to the supporting tissue of the retina. It is connected with Mueller's fibers on one side and fine fibers, so-called fiber-baskets (see above), go off from the other side of it (outside).

According to Leboucq (139), it, as well as the fiber-baskets, is, as a whole, a remnant of the original intercellular cement of the fetal retinal cells.

The greater length of the foveal cones makes the *m. limitans externa* show a slight bulging inward in the center of the fovea, the so-called **fovea externa**. What was said concerning the greater thickness of the rod-and-cone layer in the fovea holds true, of course, for these as well.

### 3. THE OUTER NUCLEAR LAYER

(Pl. IV, 3, *ak*)

This layer consists mainly of thickly placed, rounded, or weakly oval structures (outer nuclei) in which a thin protoplasmic mantle and a densely-staining nucleus can be made out. The nucleus forms so large a portion of the outer nuclear element that the whole layer seems to be made up solely of nuclei.

The thickness of this layer is about 4.6  $\mu$  nasal to the optic-nerve entrance and is there some 8 or 9 nuclei wide. From here toward the periphery its thickness decreases gradually but only very slowly without essential alteration of its appearance. Temporal to the optic nerve the layer is, in general, somewhat thinner, and in the direction of the center of the fovea its thickness decreases still more to 22  $\mu$  at the border of the rod-free field, and here it is only 4 nuclei thick. From here on it again increases in thickness, partly from an increase in the number of nuclei, but especially because these are more widely spaced apart, and attains a maximum of about 50  $\mu$  in the center of the fovea (Pl. V, 4).

Even in ordinary preparations one can distinguish two kinds of nuclei, yet in my experience this difference is but little noticeable in preparations from Mueller's fluid and much more striking in formalin and sublimat fixation. This difference affects only the nuclei. The one kind of nuclei is smaller (5.7  $\mu$ ), more rounded, and more densely stained (Pl. IV, 3, *s*); the other is larger, plainly oval (5 $\times$ 7  $\mu$ ) and more weakly stained (Pl. IV, 3, *z*).

The main bulk of the outer nuclear layer is made up of the first form while in the extrafoveal portions of the retina those of the second form are found only outside, right next to the *m. limitans externa*. In the territory of the rod-free field of the fovea only nuclei of the second form are found and the entire thickness of the nuclear layer is, therefore, made up by them. About this field the nuclei of the first form appear, at first in the innermost layers of the nuclear layer, then they rapidly increase in

number, while the more sparse appearing nuclei of the second form make an unbroken layer immediately along the *m. limitans externa* only. Farther away from the fovea the number of these nuclei continues to decrease, they are more and more separated from one another, and the intervals are filled with the nuclei of the first form, which henceforth make up the main mass.

From this distribution alone, it may be suspected that the smaller, denser stained nuclei of the first form belong to the rods, the larger, more weakly-stained nuclei of the second form to the cones. As a matter of fact each element of the rod-and-cone layer is bound to an outer nucleus by a fiber, which one can see without the employment of unusual methods of preparation, for example, in sections through the middle of the fovea, where the outer nuclear layer is especially loose (Pl. V, 3).

Each rod, for example, is extended inward as a fine, tortuous, and varicose fiber (**rod-fiber**); this goes through the corresponding hole in the *m. limitans externa* into the outer nuclear layer and at a varying distance from this membrane distends into the **rod granule** containing one of the smaller, denser stained nuclei; the protoplasmic mantle of the granule is extremely thin, so that it seems to consist almost solely of the nucleus. The fiber continues beyond the cell and ends in a small bud in the outer plexiform layer.

In the same way each cone goes over into a fiber (**cone-fiber**), but this is much thicker in its distal part, i.e., between the cone and its granule, than is the rod-fiber, and very short, because the cone granule is placed just within the *m. limitans externa*. The **cone granule** is somewhat more spindle-form, because its nucleus is oval and somewhat more protoplasm is present at the two ends of the granule. The proximal part of the fiber is throughout longer than the distal and more slender than it, but still is always heavier than a rod-fiber. The cone-fiber, likewise, ends in the outer plexiform layer, but at a deeper level than the rod-fiber, and, indeed, with a conical swelling (**cone swelling, or cone-foot**) from which short lateral branches go off.

Only in the center of the fovea, where cones only are present and the cone granules must be placed over one another in layers, is the distal portion of the cone-fiber thinner and longer.

The direction of the rod-and-cone-fiber in the extrafoveal parts of the retina is perpendicular to the surface. In the region of the fovea the direction becomes an oblique one and in keeping with this the outer nuclei are arranged in oblique rows.

Concerning the presence of cross-striations in the outer nuclei, i.e., an arrangement of the chomatin substance in cross-bands, opinions are much divided. I can discover nothing of this sort in my preparations.



Here and there the cone nuclei lie beyond the *m. limitans externa* (the nucleus then seems to lie in the inner member of the cone) and the affected cone shows an abnormal structure. The significance of this appearance is not yet clear.

#### 4. THE OUTER PLEXIFORM LAYER (*Internuclear layer*)

(Pl. IV, 3, *ap*)

This layer shows a thickness of some 20  $\mu$  in the extrafoveal portions of the retina, contains no cell-nuclei, and, therefore, takes only tissue stains, such as eosin. It consists of a densely interwoven reticulum of fibrous elements arranged principally in two directions—perpendicular to the surface of the retina and parallel to it (at least these directions predominate over the oblique ones). This structure is difficult to analyze and by low power and defective staining gives the impression of granulation; therefore, this layer was called the outer granular layer by the older authors; by higher magnification and better staining of thin sections it has a fine reticular appearance.

Two well-separated portions can be made out, an outer and an inner. The outer portion (*f*) is the thicker; it includes some two-thirds of the entire layer; it is, however, very subject to swelling and often appears still thicker. The meshes are loose and a direction parallel to the surface rules. It is the proximal portions of the rod-cone fibers (see above) which call forth this picture, and the border between the two portions is formed by the proximal ends of the cone-fibers (the previously reported cone swellings), which all lie at the same level.

The inner portion (*r*) is much thinner and shows the fine reticular (plexiform) structure in a typical way; it is, therefore, more closely meshed and stains more densely than the outer portion. It is made up mainly of the fine extensions of the horizontal cells of the inner nuclear layer (see the same). In addition, Mueller's supporting fibers have a part in the formation of the entire layer; their fine extensions run parallel to the surface.

In the neighborhood of the fovea the appearance of the outer plexiform layer changes in a remarkable way. The rod-and-cone-fibers take on a more and more oblique direction and finally, in the immediate vicinity of the foveal center, are arranged almost parallel to the surface. Thereby, as well as through the marked condensation of the cone-fibers, which are exclusively present in the center of the fovea, the outer portion loses every trace of a reticular meshwork and takes on a fibrous appearance. This modification of the outer plexiform layer bears the names of **Henle's outer fiber layer** (Pl. V, 3, 4, *Hf*).

This layer can be made out even at the temporal border of the papilla;

the more one approaches the center of the fovea, the longer the cone-fibers become, the more they are superimposed in layers, and the thicker the whole fiber layer is. It attains a maximum thickness of 40 to 50  $\mu$  at about the border of the rod-free field, then thins rapidly, and is reduced to a minimum in the very center of the fovea.

Since the outer fiber layer is equally well developed on all sides of the fovea, a nearly circular area of almost 8 mm diameter concentric with the fovea is formed in which the fibrillation has a component directed radial to the foveal center.

The inner portion of the outer plexiform layer maintains the same appearance and the same thickness in the region of the fovea as in extrafoveal parts of the retina.

It is very difficult to obtain good preparations of the outer fiber layer, for this layer is to a particular degree subject to swelling. This is also the reason why the region of the fovea is so easily detached post-mortem.

#### 5. THE INNER NUCLEAR LAYER

(Pl. IV, 3, *iK*)

This layer has a thickness of about 30  $\mu$  in the extrafoveal portions of the retina; it is, therefore, appreciably thinner than the outer nuclear layer, to which it is very similar in appearance in ordinary sections. The inner nuclei, which make up this layer, are closely placed together; indeed, the layer consists almost wholly of cell-nuclei with thin mantles of protoplasm from which processes of varying number and direction go off. Here and there one finds larger cells with a rich protoplasm, wholly of the appearance of ganglion cells, and provided as well with Nissl's granules; part of the nuclei also show a more elongated form; these are the nuclei of Mueller's fibers and lie about the middle of the inner nuclear layer.

This is nearly all one can see by the usual staining of cut sections. The extremely complicated structure of this layer is only revealed by the methods of Golgi and Ramon y Cajal.

According to Greeff (75), one can distinguish the following elements in the inner nuclear layer:

(1) The **horizontal cells**, and, indeed,

*a*) the **outer horizontal cells**: these are small flat cells whose processes broaden out in a direction parallel to the surface and end in the outer plexiform layer. They lie in the outer portion of the inner nuclear layer.

*b*) The **inner horizontal cells**: these are larger than the former and likewise broaden out in a direction parallel to the surface; their end branches mount up toward the outer plexiform layer. Some of these have a descending (proximal or inward directed) process as well, ending in the inner plexiform layer. They lie at a plane farther inward than do the outer horizontal cells.

2. The **bipolar cells**. According to their union, these are divided into:

a) The **rod bipolars**: each of these has a basket of ascending (distal or outward) processes and by means of these is in contact with the ends of the rod-fibers. The descending (proximal) process is a single fiber coursing through the inner plexiform layer, and invests a cell of the ganglion-cell layer by means of its less thick branches.

b) The **cone bipolars**: these lie very close to the outer plexiform layer, their ascending (distal) processes broaden out parallel to the surface of the retina and come in contact with the proximal ends of the cone-fibers. The descending (proximal) process ends in the inner plexiform layer with branches parallel to the surface. Some of these cells are characterized by especially numerous ascending processes (giant bipolars, Greeff).

3. The **amacrin cells**: these form a continuous layer in the innermost portion of the inner nuclear layer. Their pear-shaped body measures 10 to 13.7  $\mu$  and gives off a single process inward. One finds:

a) **Stratified** amacrin cells: these have only one process ending in the inner plexiform layer with a superficially parallel branching.

b) **Disseminated** amacrin cells: the process branches many times and ends in all parts of the inner plexiform layer.

c) **Association** amacrin cells: their protoplasmic processes (dendrites) end in the first sublayer of the inner plexiform layer, the axis cylinder process courses parallel to the surface for a long stretch on the border between the inner nuclear layer and the inner plexiform layer and breaks up into numerous branches. These cells also come in contact with the centrifugal fibers.

4. The already reported **nuclei of Mueller's supporting fibers**.

Toward the fovea the thickness of the inner nuclear layer very gradually increases and attains a maximum of 57 to 66  $\mu$  between the wall about the fovea and its center; from there on it thins out very rapidly and practically disappears in the center of the fovea. Widely isolated cells are often seen along the inner surface of Henle's fiber layer (Pl. V, 3).

Although the layers of the retina are entirely without vessels as far as the outer plexiform layer, capillary vessels belonging to the system of the *arteria centralis retinae* are found even in the inner nuclear layer (Pl. IV, 3, c).

## 6. THE INNER PLEXIFORM LAYER

(Pl. IV, 3, *ip*)

This layer shows individual variations in thickness from 18 to 36  $\mu$ ; in some instances, however, it maintains the same thickness in all parts of the retina, even in the neighborhood of the fovea. It is wanting only in the middle of the fovea and, indeed, in a somewhat greater expanse than the inner nuclear layer.

It possesses a finely reticular appearance, like the inner portion of the outer plexiform layer, to which in this respect it is, in general, similar, and permits several **secondary** or **sublayers** (usually five) to be recognized; these are darker stripes coursing absolutely parallel to the surface of the retina and apparently caused by a thicker interweaving of the fiber mesh. These sublayers arise because the end branches of the

nerve-cells, coursing parallel to the surface, only lie at certain levels of the inner plexiform layer. The nerve-cells specially concerned in the formation of the sublayers are the cone bipolars and the stratified amacrin cells of the inner nuclear layer (along with their proximal processes), and the stratified ganglion cells with their distal processes. In general, the sublayers are not very clearly marked in the human retina; in the retina of the birds they come out much more plainly.

Although the structural elements of the inner plexiform layer, including the corresponding parts of the supporting fibers, are without nuclei, yet this layer is not wholly devoid of nuclei. It is crossed by retinal vessels and, moreover, other isolated displaced cells are present (ganglion or amacrin cells?).

#### 7. THE GANGLION-CELL LAYER

(Pl. IV, 3, G)

This layer has a thickness of 10 to 20  $\mu$  in the nasal part of the retina and consists of a single row of ganglion cells separated from one another by Mueller's fibers. Besides these, neuroglia cells are present. In the neighborhood of the optic nerve the ganglion cells form a closed row; farther toward the periphery they are more and more separated from one another, and the spaces are filled out by the nerve-fiber layer.

Temporal to the nerve the ganglion-cell layer is somewhat thicker and the cells superimposed in two layers. This superimposition increases constantly in the direction of the fovea until, finally, at the wall of the fovea 5 to 7 layers of ganglion cells are present. The thickness of the whole layer is thereby increased to 57-85  $\mu$  on the nasal side, and 45-75  $\mu$  on the temporal side (Dimmer, 40).

From these relations in thickness it follows that the wall of the fovea is mainly formed by the ganglion-cell layer. From here on, the thickness of the layer decreases rapidly toward the center of the fovea, and it is lost or fused with the rudiment of the nuclear layer while still in the region of the clivus (Pl. V, 4).

Since the same relations are repeated on all sides of the fovea, there arises a fairly extensive district in the retina in which the ganglion cells are superimposed.

This area (**area centralis**, Chievitz, 32) has about the same extent as the other fiber layer of Henle, i.e., a circular surface area of about 4 mm radius; from the fact that the stratification of the ganglion cells in layers can be made out under all circumstances, even in advanced cadaverous changes, we have here a sure means of differentiating the temporal from the nasal side of the retina and the section need not necessarily go through the fovea.



The individual ganglion cells show a most varied appearance. In the extrafoveal portions of the retina very large ganglion cells with a diameter of up to 30  $\mu$  occur; their nuclei are almost exactly round, clear, and 10 to 11  $\mu$  in diameter. The nuclei contain large shining nucleoli. More numerous than these are the smaller ganglion cells with a more oval nucleus of 8 to 9  $\mu$  in diameter and a 11 to 12  $\mu$  protoplasmic body. Only the smaller forms are found in the neighborhood of the fovea, and, corresponding to the general arrangement, the cell-body is obliquely elongated.

The ganglion cells are multipolar and have numerous protoplasmic processes (dendrites), which broaden out in the inner plexiform layer and are for the most part provided with axis cylinders going over into nerve-fibers of the adjoining layer. The protoplasm contains the so-called Nissl granules; these are granules and shoals of varying size, of rounded or polyhedral form, giving an elective stain especially with blue dyes, ordinary and polychrome methyl blue, thionin, etc., and at times also with hematoxylin. The granula extend into the protoplasmic processes as well, but not into the cylinders.

The peculiarities of the Nissl granula in man are little known; on technical grounds they have been best studied in lower animals (Bach, 13; Birch-Hirshfeld, 25; Abelsdorff, 2; only the latter writer depicts a cell in man). In the normal retina of an eye enucleated for orbital carcinoma which I was able to study, the large cells contained granula varying much in size, quite uniformly distributed through the protoplasm, usually with a granula-free zone immediately about the nucleus; the smaller cells contained correspondingly small granula. In general, it is very surprising how well these structures, which otherwise are very easily disintegrated, are retained in detachment of the retina following traumatic inflammation.

Other fixative and staining methods bring out a fibrillar structure in the cell-body and its processes. Dogiel (44) discovered these structures with his methyl-blue method; then Emden (57) demonstrated them by the method of Bethe, and finally Bartels (16) in the human with the method of Bielschowsky. According to Bartels, the fibrillae course from one process to another, and in this way pass by the cell-body; in part, too, they radiate from the processes toward the nucleus and possibly form there a network. The fibrillae are extremely fine and smooth (without nodosities); they lie more loosely in the protoplasmic processes; in the axis cylinder processes they are closely pressed together.

According to Dogiel, the protoplasmic processes of cells of the same type are united into nets. According to the authors named, it follows from the fibrillar structure

that no fundamental difference exists between the protoplasmic processes and the axis cylinder process; both are of a nervous nature and the fibrillae are genuine conducting organs.

The controversy as to whether the ganglion cells have a granular or a fibrillar structure appears to me to be quite useless; both structures may very well be present at the same time and only one or the other come out after a certain fixation. A view which in a certain sense lies between these two extremes is that of Held concerning the net-like structure of the body and the processes of the nerve-cells (*Archiv. fur Anatomie und Physiologie*, anatomische Abteilung, 1897, p. 204), yet the observations of this investigator were not made on the retina.

The Nissl granules cover the diplosome of the ganglion cell; this structure is, therefore, only visible in the embryonal eye, before the development of the granula (cf. chap. xvi).

According to the manner in which the dendrites end in the inner plexiform layer (wholly analogous to the amacrin cells), one distinguishes **stratified** and **disseminated** ganglion cells. The former spread their end brushes out in one or more planes of the inner plexiform layer and in this way produce their sublayers. The diffuse ones branch like a tree and end everywhere throughout the inner plexiform layer. A part of the cells send no axis cylinders into the nerve-fiber layer; they are looked upon as displaced amacrin cells.

The neuroglia cells, which we meet here for the first time in the retina, have smaller and more densely-stained nuclei than the ganglion cells, and a flat body. Golgi preparations make them look like **spider cells** here, as in the nerve-fiber layer, i.e., cells provided with numerous fine processes.

## 8. THE NERVE-FIBER LAYER

(Pl. IV, 3, N)

This layer is thickest (20 to 30  $\mu$ ) about the circumference of the optic-nerve entrance, and, indeed, about the upper, nasal and lower portions.

Toward the periphery its thickness decreases, rapidly at first, then more slowly. In the extreme periphery the nerve-fibers and the ganglion-cell layer flow together, so to say, i.e., the few ganglion cells still present in this zone lie between the nerve-fibers and reach to the basal cones of the supporting fibers.

At the temporal border of the optic nerve the nerve-fiber layer is very much thinner (some 11  $\mu$ ); its thickness decreases still farther toward the fovea; it goes a little way beyond the wall of the fovea, then disappears entirely (Pl. V, 4).

Unlike the rest of the layers of the retina, in which a direction parallel to the surface or a plexus formation predominates, the nerve-fiber layer shows an exquisite fibrous structure, in which the elements are in general arranged radial to the optic-nerve entrance. In the entire nasal half of the

retina this convergence toward the optic nerve is not disturbed; in the temporal half, however, the arrangement of the fibers varies in that those fibers which pass the area of the fovea on their way to the optic nerve bow away from it and go around it in circles above and below the fovea. In this way a sort of raphe arises in the meridian of the fovea on the temporal side in the periphery; from this the fibers go off like feathers, above and below, and finally at the temporal border of the fovea itself they form an actual ring (Greeff, 65). Only the few fibers of the fovea itself and those which course from the portions lying between it and the optic nerve run fairly straight. Since, furthermore, these fibers remain close to one another and frequently show isolated disease, one calls this the **papillomacular bundle**; the loss of its function calls forth the appearance of typical central scotoma.

The fibrous structure of the nerve-fiber layer is responsible for the fact that extravasation into this layer appears to be made up of fine striae or short streaks arranged radial to the optic nerve. Extravasates in the other layers of the retina appear as rounded flecks, on the other hand.

The nerve-fibers in the retina are everywhere grouped in small bundles; these unite into a sort of net, with narrow elongated meshes. Rows of Mueller's fibers lie in these meshes and the rows have the same direction as the nerve-fibers. The nerve bundles are spread out in one plane, as a general thing; the nearer one approaches the optic nerve, however, the more slender and the higher the bundles become, until when very close to the optic nerve, they become superimposed and in this way go over into the grouping characteristic of the optic nerve itself.

The nerve-fiber layer, therefore, presents a varying picture dependent upon whether the section runs parallel or at right angles to the fibers; on longitudinal section the nerve-fiber layer shows a fibrillation parallel to the surface and only shows the Mueller's fibers indistinctly; the cross-section, on the other hand, shows the Mueller's fibers very plainly, and the cross-sections of the individual small nerve-fiber bundles lying in the arcades formed by Müller's fibers have a reticular appearance. One sees the picture of the longitudinal section in meridional sections and the cross-section picture in equatorial sections. As a result of the unusual course of its fibers, the region of the fovea makes an exception: one sees the cross-section picture on the temporal side in a horizontal section through the fovea; on the nasal side of the fovea, i.e., between it and the papilla, one sees the longitudinal section picture. A vertical section of the fovea shows the cross-section picture on each side of the depression.

Aside from the nerve-fibers and Mueller's supporting fibers, the layer in question also contains **neuroglia**. As in the optic nerve this consists of cells and fibers. The cells have a longish, quite densely-staining

nucleus, whose axis is directed parallel to the course of the nerve-fibers (Pl. IV, 3, *gl*), and a small amount of protoplasm of varying form. The fibers are very fine and form a meshwork between the nerve-fibers. (For more details concerning the neuroglia, see chap. viii.)

Finally, the nerve-fiber layer also contains the larger retinal vessels, branches of the *arteria* and *vena centralis retinae*. They are imbedded in the nerve-fiber layer and also in part in the ganglion-cell layer, and do not bulge the inner surface of the retina inward at all or not appreciably so. The vessel wall is relatively little developed, especially the muscularis of the arteries; the adventitial connective tissue is sharply set off against the surrounding nerve tissue. According to Kreuckmann (123), the glial reticulum ends at the vessel wall in a sort of border membrane, which he calls the *limitans perivascularis*.

These tissues (glia and vessel wall), which have originated from different embryonal layers, are not infrequently separated under pathologic conditions, and, for instance, in atrophic conditions of the retina resulting from obliteration of the vessels, an interspace is formed into which the pigment epithelium frequently grows; the well-known picture of pigmentary degeneration of the retina arises in this way.

The modern methods of study (Dogiel's methyl-blue staining, Golgi's and Ramon y Cajal's methods) bring to light still other details not to be recognized in ordinary sections (Greeff, 65). The nerve-fibers are clear, non-medullated fibers, varying from an immeasurable fineness up to a thickness of 3-5  $\mu$ . Divisions of the fibers occur and among the typically coursing fibers one finds individuals which cross the others.

The majority of the fibers come from the ganglion cells of the retina, and are, therefore, centripetal and serve for the conduction of visual sensations. Aside from these, fibers are, however, found of which the nerve-cells do not lie in the retina and which, therefore, are centrifugal conductors. According to Ramon y Cajal, these are larger than the centripetal, yet they course in the nerve-fiber layer with them. If one follows such a fiber in a centrifugal direction, one sees it course through the ganglion-cell layer and the inner plexiform layer and end in an amacrin cell, by means of a perivascular nest, and at other amacrin cells by processes. These fibers do not press deeper into the retina than the layer of the amacrin cells.

Moreover, the region of the fovea is not entirely devoid of nerve-fibers. A delicate ring is found at the place where the nerve-fiber layer seems to cease in ordinary preparations, according to Dogiel, and from this a wide-meshed plexus of fibers extends over the floor of the fovea.

#### APPENDIX. THE SUPPORTING FIBERS

##### The Radial or Mueller's Fibers

(Pl. IV, 3, *M*)

All of the layers of the retina heretofore discussed contain a framework which is not of a nervous nature, i. e., it does not serve either for the perception or conduction of light (in a centripetal or centrifugal direction). This framework consists of elongated cells, the radial or Mueller's sup-



porting fibers already repeatedly mentioned. They course through the extrafoveal portions of the retina parallel to the surface; starting along the inner surface of the retina in conical expansions (closely placed bases), they form quite closely placed rows of small nerve-fiber bundles in the nerve-fiber layer, diverge and break up beyond the ganglion-cell layer. From the inner nuclear layer on, the fibers lie isolated and are uniformly distributed.

They participate especially in the formation of the plexiform layers in that they give off numerous fine extensions parallel to the surface in the level of these layers. Furthermore, they form the reticulum of the nuclear layers by means of wing-like processes, go over into the *membrana limitans externa*, and finally end between the inner members of the rods and cones in the above-reported fiber-baskets by means of fine fibrillae. Their cell nature is shown by a longish nucleus lying in a mid-level of the inner nuclear layer.

Since the Mueller's fibers possess no processes or branchings (or only a few) in the territory of the nerve-fiber and ganglion-cell layers, they are much more plainly set off from the surrounding tissues in these layers and are to be seen without special aid in ordinary preparations, especially when the section falls at right angles to the course of the nerve-fibers, because one then has the rows of fibers before him in profile view. In the rest of the layers they are not to be made out so off-hand; they and their relations to these layers come out plainly by the method of Ramon y Cajal or Held's stain.

The nerve-fibers do not go **through** the basal cones, as stated by Greeff, but **between** them.

In the neighborhood of the fovea, the superficially perpendicular course of the supporting fibers present in the extrafoveal territory of the retina (perpendicular to the surface) gives way to an increasing obliquity and, indeed, in the same sense as the clivus does, but it does not exactly copy this declivity. The bending away from the surface is most marked in the region of the outer fiber layer—in the rest of the layers it is less so, so that, in general, an S-form curve is brought about.

#### 9. MEMBRANA LIMITANS INTERNA

(Pl. IV, 3, *Li*)

In the matter of the definition of this term two views are still opposed, as they were in earlier periods. The one holds the *membrana limitans interna* to be the inner limitation of the retina formed by the uninterrupted apposition of the basal cones of Mueller's supporting fibers and logically considers the anatomically demonstrable membrane lying inside the basal cones to be the border membrane of the vitreous, and calls it the **membrana hyaloidea**.

The other calls the latter the *membrana limitans interna retinae* and, therefore, denies the existence of a hyaloidea.

Against the first conception it is to be argued that a limitation of the retina is probably effected by the totality of the basal cones of the supporting fibers, but only so in the sense that it is a mathematical surface, not an actual border membrane. The second definition of the *m. limitans interna* has for it that this membrane is anatomically demonstrable, that is, has a measurable thickness and all the properties of a glass membrane. In any case, one must say that this membrane has just as much relation to the vitreous as it has to the retina, and that it looks like the inner glass membrane of the retina in one preparation and like the outer border membrane of the vitreous in another.

How Tornatola (224) comes to deny the existence of a membrane between the retina and vitreous altogether cannot be understood without seeing the preparations concerned. I have seen the membrane in many hundreds of eyes under normal as well as under the most varied pathologic conditions, and so has everyone else seen it. There has only been contention concerning what it should be called and to what it belonged. I myself (184) have in my time called it the hyaloidea, following Retzius, but I now prefer the name *limitans interna*, because it seems to me that the majority of authors so designate it, and because an analogous membrane is present on the inner surface of the ciliary epithelium.

So far as has yet been described, there lies between the retina and the vitreous one (and only one) anatomically demonstrable membrane, the *membrana limitans interna retinae*. It is a glass membrane of 1 to 2  $\mu$  thickness, which in surface view sometimes shows the impressions of the basal cones of Mueller's fibers as irregular polygonal fields. It continues uninterrupted over the *fovea centralis*, without any essential change; it is, on the other hand, gradually lost at the optic-nerve entrance and also possibly in many eyes at the *ora serrata*. (For more details see chap. ix, 8.)

#### b) *Histologic and Functional Divisions of the Retina. Its Blood-Vessels and Fovea Centralis*

Following the detailed description of the structure of the retina, a short survey of the significance of the individual elements and their reciprocal relations is in order. In anticipation of some details of developmental history of the eyeball, one may distinguish between elements of ectodermal and of mesodermal origin in the retina.

The **elements of ectodermal origin** are partly framework elements, partly nerve-cells.

The **framework elements** are partly of the same nature as the retina proper (Mueller's supporting fibers and the two *membranae limitantes*), partly of the same nature as in the optic nerve (neuroglia). The latter is, however, found only in those layers which represent a direct expansion of the optic nerve.

The **nerve-cells** of the retina are grouped in three superimposed planes. Just how these planes are united opinions differ. A majority of the authors hold firmly to the view of Ramon y Cajal that the cells subsequent to one another (in the sense of nerve conduction) (the **neurons**) are not united but only lie in contact with one another, or are surrounded by their branches. Another view, espoused by Apathy and Bethe, looks upon the **neurofibrilla** as the essential structural element of the nervous system and conceives of a continuity of the neurofibrillae.

It is certain that the individual layers possess a degree of independence of one another, e.g., atrophic processes are often limited to one plane. In any case the neuron theory of Ramon y Cajal contributes more to the understanding of these conditions than does the neurofibrillar theory.

The retina contains three neurons: they are named in the sense of their conduction, therefore, in this case in the centripetal direction.

The first neuron is represented by the rods and cones and the outer nuclei belonging to them. Its elements are broadened out into a simple surface layer; only the nuclear portions are superimposed in layers, because of their greater volume. This neuron serves for the reception of the individual light impressions and the mosaic arrangement of its elements makes possible a separation of the respective impressions in space and the appreciation of the picture projected through the optical system. This is the **sensory epithelium** (neuroepithelium) of the retina (Schwalbe). In the matter of its nutrition the first neuron is entirely dependent upon the choriocapillaris, because it contains no blood-vessels. It therefore happens that a circumscribed atrophy of the choriocapillaris leads to a coextensive atrophy of the pigment epithelium and of the first neuron of the retina, so that the subjective functional defect (the scotoma) and the objective ophthalmoscopic change (the atrophic area) exactly correspond in this instance.

The second neuron is represented by the nerve-cells of the inner nuclear layer. These cells come in contact with several elements of the first neuron. However, there are cells here which serve exclusively for the union of the elements with one another. Finally, centrifugal nerve-fibers come into contact with individual elements of this neuron. It is to be conceived that nervous processes, even of a high order, take place in this layer.

The third neuron is formed by the ganglion cells; it is the longest of all, for its axis cylinders reach through the optic nerve, the chiasm and *tractus opticus* as far as the brain (outer geniculate body, optic thalamus and *anterior corpora quadrigemina*, Bernheimer, 23).

The second and third neurons possess a vessel system of their own in

the branches of the *arteria centralis retinae* and the veins of the same name. These are the only **elements of mesodermal origin** in the retina. The largest branches lie superficially in the nerve-fiber layer, yet the ganglion-cell layers are usually absent beneath them and even the inner nuclear layer shows a thinning; on the other hand, the inner surface of the retina is bulged slightly forward. The finer branches pass deeper into the nerve-fiber layer and the most extensive branching is found in the ganglion-cell layer.

According to His (105), the capillary net of the retina consists of narrow capillaries (5 to 6  $\mu$ , seldom wider), and is, naturally, most developed in the posterior segment of the retina. Fine branches (**art. afferantes**) are here given off at right angles from place to place; these first break up into capillaries some 0.13 to 0.25 mm from the main vessels. In this way a space free from capillaries arises on each side of the main vessel. This first arterial capillary net lies in the nerve-fiber layer; from it there ascend branches to the inner nuclear layer and each of these forms a venous capillary net on the outer and inner surface of this layer. The venous radicals (**venae efferentes**) then form from these, descend again to the nerve-fiber layer, and empty into larger veins at right angles.

The capillaries go as far as the outer surface of the inner nuclear layer and no farther. The border between the first and second neuron (Pl. IV, 3, *x*) is, therefore, also the border between the avascular portion of the retina (the **sensory epithelium**) and the vascular portion (**cerebral layers** of Schwalbe).

Toward the *ora serrata* the vessel net becomes more and more simple. The peripheral limit of the retinal vessel system does not, however, coincide with the border of the retina, but lies about 1 mm farther back; a few wide irregular projected loops form the border of the retinal vessel system. These loops have a somewhat wider caliber than the rest of the capillaries, and, if one so wishes, one may speak of a direct transition of arteries into veins here. I have not been able to make out an outspoken circular course of the terminal venous branches in my preparations.

The **fovea centralis**, of which the gross anatomic relations have been described above, arises mainly from a spreading apart of the cerebral layers. For, aside from isolated cells of the second neuron and the very sparse nerve-fibers found on the floor of the fovea, this area contains only elements of the first neuron. Along with the cerebral layers, the retinal vessels also fail in the center of the fovea. A capillary-free area of 0.4 to 0.5 mm size and irregular form is present in most cases. Yet this area varies appreciably, probably with the size of the fovea in general.



With the ophthalmoscope this vessel-free area appears larger, because a magnification of only 14 times in the direct image does not permit the capillaries to be seen; the finest ophthalmoscopically visible vessels extend only a little way over the wall about the depression in the retina indicated by the macular reflex.

Since the histologic relations of the *fovea centralis* have already been described somewhat more accurately in connection with the individual layers, it seems superfluous to give a special histologic description of the fovea. Still, certain peculiarities of the retina in this region may well be again briefly pointed out. A circle, tangent to the temporal border of the disc, drawn about the center of the fovea contains in its compass (the *area centralis*) two remarkable histologic findings: the thickening of the ganglion-cell layer and the outer fiber layer of Henle. The area, naturally, has no sharp limits; therefore, its size can only be approximately given. The wall about the fovea is formed by the ganglion-cell layer. In the middle of the fovea is an area scarcely of 0.5 mm, characterized by extreme attenuation of the cerebral layer and by absence of the retinal vessels, as well as by the presence, exclusively, of cones. But the slender foveal cones are found only in the very center of this area.

Here everything is arranged to increase functional capacity as much as possible. The fovea lies in the optic axis (although not exactly so), where the picture projected by the optical system is the sharpest. The inner layers of the retina are spread apart, for they can only obscure the image; the shadow-producing retinal vessels fail entirely. Only the elements of higher dignity, the color-perceiving cones, are present, and these, moreover, possess a fineness found in no other part of the retina. Each cone is united with but a single bipolar cell and, furthermore, with but one ganglion cell possibly, so each individual light sensation is conducted isolated from the rest. The center of the *fovea centralis* thus becomes the seat of the highest function of the eye—that of central vision.

The yellow color of the *macula lutea* is conditioned by a coloring matter distributed through all the elements of the cerebral layer, although through the outer fiber layer to a lesser degree (Dimmer, 40).

### c) *The Extreme Periphery of the Retina*

When the retina is viewed from its surface, its (anterior) border (*ora serrata retinae*) appears more or less toothed (in biologic terminology), i.e., sharp projections are directed toward the *corona ciliaris* and separated from one another by rounded bays. The length of the teeth is subject to great variation; in their maximal development they may reach to the *corona ciliaris*.

As a rule the teeth are not uniformly developed in the entire circumference of the border of the retina, but are plainer on those sides where the ciliary body is shorter, i.e., especially, therefore, on the nasal side (Pl. II, 1); on the temporal side they often fail completely, and the border is then only finely and irregularly wavy or angular.

The teeth correspond in position to the intervals between the ciliary processes and all the irregularities of development in the *corona ciliaris* are reflected in the *ora serrata*. Depending upon their length, the form of the teeth varies from that of a triangle to an awl; the bays are rounded out as a whole, but often show several smaller projections and in this way acquire an undulating or slightly jagged outline.

That which appears to be the border of the retina in a surface preparation by no means coincides with the corresponding border of the pigment epithelium, for the border of the retina usually lies farther forward (cf. p. 62). One can get the best general view of the topographic relations of these two borders after the retina has been detached from the uvea in a hardened eye; the pigment epithelium of the chorioidea (posterior zone of the pigment epithelium) remains with this, but the pigment epithelium of the ciliary body remains attached to the retina, at least far enough so that one can recognize its limits. The finer details vary greatly. Schoen (193) differentiates four types, yet it is not always an individual difference alone, for the relations in different parts of the same eye are not always the same.

In many eyes one finds peculiar cavities in the tissues (**Blessig's cysts, Iwanoff's retinal oedema, cystoid degeneration**) in the most peripheral portions of the retina. On surface view (Pl. V, 5) they appear as rounded pores, or, through confluence of adjoining cavities, as lobulated or meandering or dendritically branched clear flecks, often separated by a narrow partition only.

The first traces appear very early in life, between perhaps the years of 16 and 20, and at first immediately behind the teeth of the *ora serrata*. From here the cavities broaden out backward and toward the sides, and the originally isolated flecks flow into a closed zone, which always becomes broader with the years. But the cavities increase not only in extent but also in size; the individual cavities enlarge and so merge with one another in age that only column-like pieces of the separating walls remain.

Cystoid degeneration is, therefore, probably to be considered as physiologic despite the great individual variations in grade and extent of the change; it increases with age, somewhat as the far point always moves away with the years. The cavities are not, however, peculiarly

senile appearances, for one may encounter them in beautiful formation even between the ages of 30 and 40.

The thickness of the retina is markedly decreased by the formation of cavities. In such eyes the minimum thickness is not just at the border of the retina but behind the zone of the cavities (Pl. V, 6).

Great difficulties lie in the way of one who wishes to produce a picture of the histologic structure of the extreme periphery of the retina, for light pathologic changes can occur in this region which entirely escape the control of clinical observation.

The extreme periphery of the retina is not accessible to ordinary ophthalmoscopic study. This region is only visible to the ophthalmoscope under especially favorable circumstances, such as coloboma of the iris with aphakia (Reimar, 178), or in tumors which press the *ora serrata* toward the optic axis. Traptas (225) has given a method (pressing in the wall of the bulb with the finger), but we still lack a comprehensive investigation of the ophthalmoscopic appearance of this region, and especially a control of these findings through anatomy.

In addition, it happens that the most peripheral portions of the retina are blind (Donders, 45). The visual field, as well known, has an extent of only 60° at the most on the nasal side; on the temporal side it has one of 90° or even more. If one construct this angle in the schematically cross-sectioned eye (Text Fig. 1) with one side along the visual axis and the apex at the posterior nodal point (which falls at about the posterior pole of the lens), one notes that a 4 mm broad zone of the retina, at least on the temporal side, is devoid of a visual function. When a pathologic condition develops in this zone it is, therefore, neither appreciable objectively (by the ophthalmoscope) nor subjectively (by testing the function).

Yet the appearance of the outermost periphery of the retina is altered by age, alone. It is, therefore, fundamentally incorrect to base the description upon the relations in children's eyes only, for then all later changes are classified as pathologic, which most certainly is not correct.

The fact that the outermost periphery of the retina is blind should cause a high degree of astonishment, because the histologic structure of the retina does not justify this observation. The organs for the reception of light-stimuli (the rods and cones) reach, indeed, to the border of the retina; the elements simply spread apart somewhat, becoming thicker and shorter; therewith the number of the rods decreases much more than the cones (Greeff, 75). With the cessation of the rod-and-cone layer the *limitans externa* bends down toward the pigment epithelium and, according to Wolfrum (242), goes over into the cement ridges lying between the pigment epithelium and the non-pigmented ciliary epithelium. The anterior border of the *limitans externa* coincide exactly with the border in the pigment epithelium.

The two nuclear layers become correspondingly thinner toward the border of the retina, but otherwise show no striking changes. At the same time nuclei (outwardly displaced inner nuclei?) appear in the outer



plexiform layer; the border line between the two nuclear layers thereby becomes indistinct, and finally they fuse into one at the border itself.

No changes can be made out in the inner nuclear layer. The ganglion-cell layer, together with the nerve-fiber layer, cease 0.5 to 1 mm behind the *ora serrata*. To the same extent in which these elements disappear, the supporting tissue increases in mass; the outermost periphery of the retina, therefore, contains only scattered neuroglia cells in place of ganglion cells, only closely pressed basal cones of Mueller's fibers in place of nerve-fibers, and, therefore, looks cross- or diagonally striated. The *limitans interna retinae* often becomes notably thinner, and, so, often indistinct toward the *ora serrata* (cf. chap. ix, 8).

At the border itself, the retina of the adult (and the description relates only to such) is sharply set off against the ciliary epithelium (Pl. V, 6). Since now this is much thinner than the retina, there arises a step at the border of the retina, sometimes rounded, sometimes sharply angular, sometimes falling abruptly at right angles, sometimes overhanging the ciliary epithelium. Not only are individual variations found here, but the form of the border of the retina changes in different sections from the same eye. For example, the more the section approaches the apex of a tooth of the *ora serrata*, the more the border of the retina overhangs. In such sections one sees a sort of spur made up of a loose reticulum with a few irregularly arranged nuclei projecting into the vitreous from the inner surface of the retina. When the section goes exactly through the front of a tooth, this spur lies upon the inner surface of the ciliary epithelium. Usually there rules a relationship similar to that of the *pterygium corneae*, which also is grown fast along the middle line while the marginal portions are undermined. This comparison should, however, only serve for the visualization of the relations; I am far from the intention of conceiving of the origin of the *ora serrata* as similar to that of the pterygium. One now and then sees, rather, a little group of elongated, fibrillated ciliary epithelium cells at the border of the retina, after the manner of a buttress.

The first traces of cystoid degeneration are shown in a rarification of the interior of the retinal tissue close to the border and its transformation into a widespread reticulum. The formation of actual smooth-walled cavities, mostly rounded in form, takes place later. But numerous small isolated cystic spaces are always found at the posterior border of the degenerated zone in the far-advanced cystic degeneration of older people.

Such young cavities, so to say, lie in the outer plexiform layer, and soon extend from there into the outer nuclear layer, often more into the



inner nuclear layers; they are rounded or oval, sharply bordered, mostly empty, and more rarely divided by remnants of the outer plexiform layer into planes. The immediate neighborhood of the cavities shows no striking changes.

The larger cavities (Pl. V, 7) reach so close to the *m. limitans externa* that only a layer of outer nuclei remains; indeed, even this may disappear. The larger spaces extend inward as far as the inner fiber layer, yet a covering made up of remnants of the nerve-fiber layer and the *m. limitans retina* almost always remains. The tissue intervening between the spaces, which more and more back up against each other, thickens itself into partitioning walls made up of tensely spanned protoplasmic fibers provided with longish nuclei between which lie the spaced-apart outer nuclei. This is associated with a very considerable increase in the thickness of the retina—to almost double the original thickness.

The highest grade of cavity formation consists in a further reduction of the partitioning walls to individual columns and extensive confluence of the cavities. Further histologic changes do not appear. This highest grade is better recognized in surface preparations of the entire retina than in individual sections. The cavities, however, never break through the limits set for them by the two *m. limitantes*; even in their most extensive development they remain intraretinal.

I should consider the following to be pathologic changes: complete absence of rods and cones in the outermost periphery and the fixation of the *limitans externa* to the pigment epithelium, as well as the occasional occurrence of high-grade thinning of the peripheral portions of the retina, with loss of the regular stratification without cavity formation.

The peculiar morphologic relations of the *ora serrata* have been first thoroughly studied in the last decades and various theories concerning their origin have been put forth.

According to Schoen (193), in the newborn the border of the retina shows a straight course and only microscopic little juttings, some 850 in number, are present. He holds this condition to be the normal one; the larger microscopically visible juts first appear later; they are, therefore, acquired and are, for Schoen, equivalent to a pathologic condition. The cause of this diseased condition is the pull of the zonular fibers attached to the juts, and this again arises from overstraining of the accommodation.

It is not difficult to disprove this theory, because the premises are not warranted. E. von Hippel (102) found larger teeth at the *ora serrata* in the newborn. The zonular fibers are not, in general, inserted directly into the border of the retina, and even if this were so, the pull of the zonula could not bring about the jutting form but only a uniform displacement of the border of the retina, because zonular fibers are also richly present in the situations corresponding to the bays of the *ora serrata*.

O. Schultze (198), on the other hand, proceeds from the development of the retina and the ciliary epithelium. In the fourth month of pregnancy the border

between the two lies just behind the ciliary processes and extends into the ciliary valleys by broad, short projections. In further development, the retinal border constantly moves backward behind the processes, and the teeth become more and more drawn out. These, too, on their part now undergo more or less regression and leave behind more markedly pigmented stripes, the *striae ciliares* (cf. chap. ix).

This theory is not, indeed, entirely satisfactory, but has much more in its favor than that of Schoen. It is exactly the opposite of this. Whereas Schoen has the *ora serrata* develop in extrauterine life, O. Schultze considers it as congenital and admits, indeed, the possibility of later regression.

## CHAPTER VIII. THE OPTIC NERVE (NERVUS OPTICUS)

Besides the intraocular, only the orbital portion of this nerve, which represents the union of the retina with the brain, will be described.

By the **intraocular** or **bulbar** portion of the optic nerve, one understands the part lying within the bulb wall, that portion remaining behind on the bulb after a properly made enucleation, i.e., when the optic nerve is cut through at the level of the outer surface of the sclera. The **orbital** or **retrobulbar** portion is that lying between the eyeball and the *canalis opticus*.

The division into a **non-medullated** and a **medullated** section is better than this division. The border between these two sections falls pretty nearly at the outer surface of the *lamina cribrosa*, and still lies, therefore, within the bulbar portion. This limit is, of course, not an absolutely sharp one, for the medullary sheaths of nerve-fibers do not all cease at the same place, but it has the advantage of being a natural limit, one which bears the most important differences in structure.

### a) *The Non-medullated Portion of the Optic Nerve*

(Pl. IV, 4)

#### I. MICROSCOPIC ANATOMY AND HISTOLOGY

This portion can be further subdivided into a retinal, chorioidal and a scleral portion. These portions correspond to the like-named coats of the bulb wall through which, one after another, the optic nerve passes.

When one follows the nerve-fiber layer in a centripetal direction in a meridional section, one sees the nerve-bundles curve over the chorioidal foramen in bows into the line of the optic-nerve axis. Since the nerve-fiber layer and with it the entire thickness of the retina increases in thickness toward the optic nerve, this transition area bulges a little toward the interior of the eye (*papilla nervi optici*). The prominence is, however, insignificant and scarcely deserves the name papilla, espe-

cially since what one designates as such in ophthalmoscopy has nothing whatever to do with the prominence.

A depression arises in the middle of the papilla from the bowing apart of the nerve-fibers; sometimes this has the form of a funnel, sometimes that of a crater. The first form, characterized by an ending in a sharp angle, is called the **vessel funnel**; the latter form, showing a more or less flat floor, is called the **physiologic excavation** (*Ex*). These terms are used with respect to the variations in the ophthalmoscopic picture; an essential anatomic difference, aside from the form of the depression, does not exist. In general, the form and size of the depression is subject to very great individual variation.

The retinal portion of the optic nerve really forms only a ring; the temporal quadrant of this ring is lower and thinner than the other three quadrants as a result of the lesser bulk of the nerve-fiber layer on this side of the optic nerve. The physiologic excavation, therefore, does not lie exactly in the middle of the optic nerve, but is shifted a little to the temporal side. The larger blood-vessels mount up along the nasal wall of the excavation to its depths; the temporal border is crossed only by very fine vessels going to the fovea.

The blood-vessels of the retina come together in the upper and lower quadrant of this ring and unite into upper and lower main branches (*arteriae* or *venae papillares superior et inferior*). The union of the two *arteriae papillares* into a trunk, (*arteria centralis retinae*) takes place while the vessels are still in the level of the retina at an angle of about  $90^\circ$ ; still the plane of this angle is usually placed sagittally. The two *venae papillares*, however, remain separated up to the beginning of the scleral portion of the optic nerve and first unite here in it, i.e., in the *lamina cribrosa* or on its inner surface. A very considerable part of the *arteria centralis retinae*, therefore, lies inside the *lamina cribrosa*, whereas the *vena centralis retinae* is just formed at it.

In the retinal part of the optic nerve the vessels lie wholly superficial, i.e., they are not covered by nerve-fibers; on the other hand they possess a thin glial covering on the vitreous side. This attains a special thickness on the floor of the physiologic excavation and, to a certain extent, forms the bulbar closure of the bundle, the central supporting tissue strand, which accompanies the *arteria* and *vena centralis* in their further course in the axis of the optic nerve. The glial covering of the floor of the excavation has been designated as the **central supporting tissue meniscus** (*Me*) in this sense by Kuhnt. Sometimes this tissue extends still farther into the optic nerve along the central vessels (Elschnig's **intercalary tissue**, 52).



An actual *limitans interna*, as defined on pp. 79–80, does not exist in the region of the physiologic excavation. For this is the place where the *arteria centralis retinae* goes over into the *art. hyaloidea* in fetal life, and here lies the entrance of the *canalis hyaloideus* (about which contention has again recently arisen; cf. chap. xi). Pathologic cases show that a special delimitation from the vitreous fails here; for vascularized tissue very easily grows out into the vitreous from this place in inflammations (*retinitis proliferans*, cicatrices in the later stages of the septic endophthalmitis).

The rest of the layers of the retina (from ganglion-cell to rod-and-cone layer) end at the border of the optic nerve, the inner earlier than the outer layers, corresponding to the bow-form course of the nerve-fibers. Furthermore, the layers thin out toward the border and thereby compensate for the increase in thickness in the nerve-fiber layer to a certain extent. As a matter of fact, however, these layers do not reach clear up to the optic nerve but a thinner or thicker non-stratified layer of tissue, **the intermediary tissue** of Kuhnt (129) (*im*), is interposed between the border of the retina and the most peripheral nerve-fiber bundles.

The pigment epithelium reaches up to the intermediary tissue at the optic nerve, or nearly so; its border portions are, however, often not uniformly developed and show abnormalities of pigmentation, i.e., an excessive pigmentation or one defective, even to complete loss of color.

However, the pigment epithelium never extends as far as does the glass membrane of the chorioidea. Of all the layers of the retina and chorioidea, this is the only one which reaches clear up to the optic nerve; indeed, its slightly forward curved end even covers it over somewhat.

The hole in the glass membrane of the chorioidea (*foramen opticum laminae vitreae chorioideae*) forms the inner opening of the optic-nerve canal (scleral, sclerotic, or **entrance canal of the optic nerve**); it is formed by the union of the *foramina optica chorioideae* and *sclerae* and measures some 0.5 mm in length. Its inner opening is about 1.5 mm wide; the outer opening, measured at the level of the outer surface of the *lamina cribrosa* or pial sheath, is usually much wider. Its cross-section varies only a little or not at all from the form of a circle; the longitudinal section, on the other hand, varies remarkably in individuals. The varieties will be discussed more in detail later on.

The wall of the canal is formed by a white or whitish-colored fibrous tissue, which is plainly set off from the chorioidal layers, but not from adjacent sclera and, therefore, appears as a continuation of it like a selvage surmounting the *foramen opticum sclerae* inwardly and extending clear to the glass membrane of the chorioidea (*Gr*).



This tissue has been called the connective-tissue ring, the scleral ring, the sheath extension, and the **border tissue**. I prefer the latter (Elschnig's term), because it does not commit one to anything. This border tissue is much more strongly developed on the temporal than on the nasal side. It separates the rest of the layers of the chorioidea (from the choriocapillaris to the suprachorioidea) from the optic nerve, so that none of the layers come in direct contact with the optic nerve. This border tissue shows its greatest thickness at the level of the inner surface of the sclera; outside this it thins rapidly and has completely disappeared before the outer opening of the optic-nerve canal is reached. It does not go over into the pial sheath of the optic nerve, for this has altogether another histologic composition. The name "sheath extension" is not at all well chosen, therefore.

The elements of the border tissue do, however, probably extend into the framework of the optic nerve, and especially at the end of the inner surface of the sclera. It builds a thick trabeculum in connection with the elements of the sclera proper at the *foramen opticum sclerae*, and this surrounds the individual optic-nerve fiber-bundles and separates them from one another. In and of itself this framework has the appearance of a sieve; it, therefore, bears the name **cribriform plate** (*lamina cribrosa*, *Lc*).

The optic-nerve canal shelters the chorioidal and scleral portions of the non-medullated section of the optic nerve. The former is a solid strand, even when the physiologic excavation is not very deep. This portion as well as the scleral and the adjoining medullated section has, of course, the form of a ring, if one takes only the nerve-fiber mass into consideration; the lumen of this ring is wholly filled out by connective tissue and blood-vessels. Commencing at least with the scleral portion of the optic nerve, this tissue and these vessels form a round cord, the **central supporting tissue strand** (*cB*), which courses exactly in the axis of the optic nerve. It contains one large artery (the *arteria centralis retinae*) on the nasal side, and, as a rule, only one large vein (the *vena centralis retinae*) on the temporal side. The *lamina cribrosa* has a large central opening for the passage of this strand, and is, moreover, united to it by means of tissue.

In the entire non-medullated section of the optic nerve the individual nerve-fiber bundles remain strictly separated from one another; there are no anastomoses. The optic-nerve trabeculum fills out its interspaces and this, therefore, forms closed ensheathing walls between the nerve bundles.

An exact longitudinal section through the non-medullated part of the optic nerve, which, indeed, cannot always be obtained on account of the

form of the scleral canal, shows, therefore, a regular longitudinal striation caused by the alternation of non-nucleated nerve-fiber bundles and nuclear-rich separating walls. Seen in longitudinal section, these are called the **nuclear columns** (*Ks*). The cross-section, on the other hand, shows the ensheathing walls as a continuous network of rounded meshes.

The framework is weakly developed in the retinal portion and at the level of the inner opening of the optic-nerve canal; it thickens, however, in the chorioidal portion, as the optic-nerve canal widens and the nerve bundles spread apart. The fibrillation becomes more and more plainly transverse as one approaches the *lamina cribrosa*; the trabeculum of the chorioidal portion is, therefore, called the **lamina chorioidalis** (*Lch*) by many, while our *lamina cribrosa* is given the name **lamina scleralis**.

This latter is nothing else than the framework of the scleral portion; it is differentiated from the remaining portions of the optic-nerve framework histologically, however, and is less developed than these. It does not, therefore, deserve to be described as a special structure.

It is useless to discuss whether the *lamina cribrosa* is a continuation of the inner scleral layers or a modification of the septal system of the medullated section of the optic nerve. Each view has as much for as against it. The same is true of the question whether the border tissue belongs to the chorioidea or to the sclera or is a continuation of the pial sheath.

The fact is that here various supporting tissue structures meet and merge. The supporting tissue is continuous, as everywhere else in the body, and we only separate various portions from one another for purposes of description.

Taken as a whole, the *lamina cribrosa* shows a certain concavity inward, more outspoken in the more overhanging nasal side of the optic-nerve canal. Its fibers, therefore, show an oblique course at the border, i.e., they are not parallel to the inner surface of the chorioidea; and when one makes a cross-section of the optic nerve at the level of the *lamina cribrosa*, the center of the section shows layers of the *lamina cribrosa* lying farther inward than do the marginal portions of the *lamina cribrosa*.

The thickness of the *lamina* can be placed at 0.2 to 0.3 mm; it cannot be given accurately, because the cribriform plate is not very sharply demarkated inwardly or outwardly. In any case the *lamina cribrosa* completely or nearly completely fills out the *foramen opticum sclerae*, and the border of its outer surface lies pretty nearly at the level of the root of the pial sheath or the bulbar end of the intervaginal space (*I*). The center of the outer surface, however, lies considerably behind this level.

The fibrillation of the cribriform plate is tense and directed transversely, i.e., wholly, or almost, at right angles to the course of the nerve bundles; its trabeculum is much thicker than the framework of the chorioidal

portion of the optic nerve. For this reason it is very easily differentiated from the adjoining portions of the optic-nerve framework.

The peculiarities of its structure come out still more clearly on the surface-section, i.e., on cross-section of the nerve at the level of the *lamina cribrosa* (Pl. VI, 1). The trabeculae are broad, the angles are rounded off, the fibers course straight, the nuclei are numerous. Above everything else, however, each nerve-fiber bundle is strictly separated from its neighbor; no interruptions of the framework are present.

---

Histologically, the non-medullated section of the optic nerve agrees most closely with the nerve-fiber layer of the retina. Its varicose non-medullated fibers are arranged in plainly separated bundles; immeasurably fine glial fibers support the nerve-fibers and interlace with them. Golgi preparations show that part of the glial fibers course longitudinally or obliquely, but the main mass courses transversely, i.e., perpendicular to the direction of the nerve-fibers between which they run. The direction of this portion of the glial fibrillation is, moreover, to be made out without recourse to special stains, for these fibers appear in part as fine cross-lines crossing the longitudinal striation (brought out by the nerve-fibers), in part as little points (cross-sections) between the nerve-fibers.

Glial cells appear only here and there inside the nerve-fiber bundles, in large numbers, on the other hand, between the bundles, so that the framework of the optic nerve seems rich in cells everywhere. The individual glial cells have a rounded or oval nucleus of 6 to 9  $\mu$  in length and an irregular stellate protoplasmic cell-body. The glial fibers are in close relation to the cells through whose protoplasm they course. However, as Weigert's neuroglia stain shows, they are different from the protoplasm and constitute independent fibers lying at one and the same time intra- and extracellular, grouped about the nuclear center. The Golgi stain does not differentiate cells and fibers, and by this method the glial cells, therefore, show up as longish, deep black masses. A large number of extremely fine processes go out in the most varied directions (so-called spider cells).

Kuhnt's **intermediary tissue** consists of pure glial tissue, i.e., it contains no nerve-fibers; the same is true of the covering of the physiologic excavations and the **central supporting tissue meniscus**. The fibrillation is circular in the intermediary tissue and in the lateral walls of the excavation; in the meniscus the fibers interlace in various directions (Jacoby, 109).

The gliae also appear as a constituent of the border of the optic nerve.



The **border tissue** is more or less richly permeated with glial fibers or consists almost exclusively of glia (Elschnig, 52), at least in the portions immediately bordering on the optic nerve. In my own experience this latter does not, indeed, seem to be the usual occurrence. As a rule the foundation of the border tissue is a dense collagenous tissue such as is found in the sclera; a sharp separation of the two is not, therefore, possible. The fibrillation is mainly circular, the bundles are finer than in the sclera proper. A rich mass of elastic fibers is intermingled; near the optic nerve and at the level of the inner surface of the sclera the amount of elastic fibers attains its maximum; this place, therefore, takes on an especially dark color after elective staining (orcein, etc.). Finally, pigment cells of the chorioidea (chromatophores) enter into the composition of the border tissue in varying amount. In addition, there is still the glial tissue shown by Jacoby. It is true that such elements require a special elective stain (Weigert's glia stain) for their demonstration, which unfortunately often miscarries. Still one can recognize the presence of glial fibers, to a certain extent without any such stain, although not everything in the border tissue which stains yellow by Van Gieson's stain takes the orcein stain.

The **lamina cribrosa** is similarly constituted (Pl. VI, 1); glial fibers and cells with elongated, transversely placed nuclei, elastic fibers, collagenous fibers and numerous capillaries make up the cribriform plate. The latter arise from the Hallerian or vascular circle of Zinn (see p. 25), along with elements of the sclera (collagenous and elastic fibers), and enter the cribriform plate in a meridional direction. The majority of the structural elements seem, however, to come out of the border tissue, for surface-sections show them bending obliquely out of their circular course toward the axis of the eye.

The indistinct demarkation of the *lamina cribrosa* from the neighboring portions of the framework of the optic nerve has been already reported. The histologic structure of the framework of the optic nerve makes this clear. As one proceeds inward (in the centrifugal direction) one notes that the collagenous and elastic elements become more and more sparse, so that finally there remains only a fine glial tissue with plain transverse fibrillations and elongated nuclei; the elastic fibers persist longest in the marginal portion of the optic-nerve framework. Thus, one always finds a few fine elastic fibers radiating out of the border tissue into the framework of the optic nerve at the level of the chorioidea, but they are limited to the immediate neighborhood of the border tissue. The framework of the chorioidal portion of the optic nerve as a whole consists entirely of glia, and only the more outspoken transverse course and the greater size



and richness of the fibrillation brings to mind and seems to justify the name **lamina chorioidalis** in the *lamina cribrosa*.

When one proceeds outward (in the centripetal direction), on the other hand, one notes that the glia constantly decreases and the collagenous fibrilla increases. In this way the cribriform plate goes over into the septal system of the medullated section of the optic nerve. This system contains only collagenous and elastic fibrillae.

Blood-vessels are found in all portions of the optic nerve, their mass and origin, only, vary; but they are found only in the framework (between the bundles), not inside the nerve-fiber bundles. The retinal and chorioidal section of the optic nerve, however, contains no mesodermal elements in its framework, aside from the vessels and their adventitia. These first appear in the *lamina cribrosa*, the elastic elements first and then the collagenous fibrillae. The *lamina cribrosa*, therefore, forms a sort of transition structure between the purely ectodermal (glial) framework of the retinal and chorioidal section and the partly mesodermal, partly glial framework of the medullated section. The *lamina cribrosa*, as well as the border tissue, is, however, especially characterized by the intricate interweaving of the ectodermal and mesodermal elements, whereas in the medullated portion of the optic nerve, as well as in the central supporting tissue strand and its branches (the retinal vessels), the ectodermal and mesodermal elements are sharply separated and plainly set off from each other.

According to Krueckmann (124), who repeatedly quotes Held, this sharp separation is due to the fact that the glial fibers abut upon the mesodermal tissue by conical formed ends—"end feet," and a border membrane similar to the *limitans perivascularis*, described in the nerve-fiber layer of the retina (p. 78), arises, by the confluence of these little extremities. As a result of this, according to Krueckmann, the glial portion of the border tissue is separated from the mesodermal portion, as everywhere else, by *limitans* of this nature.

A splitting up of the *lamina vitrea* at the margin of the optic nerve, once described by Heine (91) does not exist. The membrane named ends abruptly at the optic nerve; it is, however, so firmly fastened to the framework of the nerve that this follows every pull upon the *lamina vitrea*. The tensely spanned glial fibers of the optic-nerve framework in myopic eyes then appear to be derived from the edge of the *lamina vitrea*.

## 2. VARIETIES OF THE NON-MEDULLATED SECTION OF THE OPTIC NERVE

The variations found in this region have been thoroughly studied by Elschmig (52) and accurately analyzed in their relations to the ophthalmoscopic picture, as well. I will here only very briefly sketch the form of the varieties found.

In as far as they relate to ophthalmoscopy, one can really look upon

all of them as varieties of the optic-nerve canal; the formation of the other parts depends for the most part upon the structure of the optic-nerve canal. The nerve-canal varies with respect to its width, its form, and its direction.

Numerical estimates of the width of the nerve-canal must be made as if of a certain level; the inner opening is adapted for this purpose, because it is well characterized and can be sharply brought into view, on the one hand, and conveys most of interest in the relation to the ophthalmoscopic image of the papilla, on the other hand. Its horizontal diameter varies between 1.26 and 1.6 mm (a mean of 1.5) according to my measurements. Its form varies only a little from that of a circle; at times the vertical diameter is a trifle greater and the opening, therefore, weakly elliptical.

The form of the nerve-canal varies from that of a cone to a cylinder. The sides of this basic form can be straight or bayed out or in.

By the direction of the nerve-canal we understand its axis, characterized anatomically by the central vessels. This direction may be perpendicular to the inner surface of the chorioidea, i.e., the nerve-canal may form a straight cone or cylinder, or be inclined. In the latter case the center of the inner opening of the canal seems displaced away from the outer opening (the *lamina cribrosa*); the nerve-canal is oblique, and, as the case may be, **temporally oblique**, **nasally oblique**, or **inferiorly oblique**, according to the direction in which the inner opening is displaced. The central vessels, of course, take part in this obliquity.

The size of the excavation depends principally upon the width of the optic-nerve canal; in a narrow, cylindrical canal a vessel funnel only, not a genuine excavation, is formed. The form of the excavation is determined by the direction of the optic-nerve canal. In a temporally oblique canal, the nasal border of the excavation is steep, indeed, even overhanging, the temporal flat; in an inferiorly oblique canal the upper border is steep; in a nasally oblique the temporal border should be steep, but this difference is not well enough marked to be of moment, because the temporal border is usually so very low.

In the temporally oblique canal the border tissue is especially well developed on the temporal side; in a wide canal the glial portion predominates, as if the glial tissue would fill out the superfluous space.

A light temporal obliquity of the nerve-canal is the most frequent form; the nasal side then forms a more acute angle with the inner surface of the chorioidea than does the temporal side. Marked obliquity (so that the angle named is obtuse on the temporal side) does, indeed, occur in emmetropic eyes as well, yet even then it is associated with a strik-

ingly long optic axis and so represents a transition to myopia. Wholly symmetrical nerve-canals are in any case more rare than slightly oblique. Properly speaking, nasally and inferiorly oblique canals are, indeed, malformations, since such eyes are usually below par in function; yet it is no more permissible to draw a sharp distinction between normal and malformed eyes here than it is in myopia.

### 3. THE SIGNIFICANCE OF THE OPHTHALMOSCOPIC PICTURE IN RELATION TO THE ANATOMY OF THIS REGION

That which one calls the disc or papilla in ophthalmoscopy (Pl. VII, 1) corresponds to the area of the *lamina cribrosa* visible in the inner opening of the optic-nerve canal. In symmetric or only slightly oblique canals the margin of the inner opening forms a border projecting (overhanging) on all sides. One can, therefore, never see the side walls of the canal, and the inner opening often seems to be entirely filled out by the *lamina cribrosa*.

The *lamina cribrosa*, in and of itself, appears clear white with washed-out gray stipplings; the latter correspond to the translucent bundles of optic-nerve fibers which pass through the cribriform plate. In normal eyes the *lamina cribrosa* never lies completely bared. The layer which covers it is only so thin over the floor of the physiologic excavation that the white of the cribriform plate and also part of the stippling is visible. In the marginal portions of the optic-nerve papilla there is such a thick layer of nerve tissue in front of the *lamina cribrosa* that the stippling is invisible and a uniform reddish color results. The latter is to be looked upon as the actual color of the nerve-fiber mass and, on its part, is due again to the blood contained in the capillaries. On the other hand, the grayish admixture which one sees so often in this marginal portion of the optic disc is solely a contrast in appearance in connection with the clear floor of the excavation.

The red of the eyeground and the peculiar granulation comes mainly from the pigment epithelium. The part played by the blood of the chorioidal vessels is almost nil in a smoothly red eyeground, according to Marx (147); that is to say, in a fundus of such appearance the pigment epithelium is so densely pigmented that one cannot see the chorioidal vessels through it. When the chorioidal vessels are visible, as in less pigmented epithelium, the blood in the vessels as well as the chorioidal stroma has an influence upon the color of the fundus. The chorioidal vessels appear as red stripes; the interspaces, when they are densely pigmented, appear darker, blacker (tessellated fundus), when they are weakly pigmented lighter, brownish to yellowish. The contours of the



chorioidal vessels are very indistinct, because the pigment epithelium obscures these contours like a brown veil.

Only when the pigment epithelium contains absolutely no pigment at all and the chorioidal stroma is, likewise, non-pigmented (albinotic fundus) are the chorioidal vessels visible as plainly contoured red stripes on a yellow-white background, for the color of the fundus is dependent upon chorioidea alone.

If one excludes these cases which properly belong in the territory of anomalies, one can say that the limits of the red color of the fundus and that of the pigment epithelium coincide. In many cases the red of the fundus does not reach clear up to the optic-nerve sheaths, but a narrow white strip (**connective tissue** or **scleral ring**) is interposed between the two. This ophthalmoscopic appearance may have various anatomic bases; it may be due either to border tissue which is not wholly covered by pigment epithelium, or it may be that the side wall of the scleral canal, which becomes of a greater obliquity, is visible in a perspective foreshortening of the latter—therefore, the lightest grade of distraction crescent. The dark, black seam (**chorioidal ring**), by which the red fundus is often separated from the optic disc or scleral ring, is due to a heavier pigmentation of the epithelium, therefore bears its name incorrectly.

When the nerve-canal is straight, the trunk of the central artery is not visible, or, properly speaking, visible only in optical cross-section, for the artery courses in the line of vision of the observer; for the same reason, its first branching makes an apparent angle of  $180^{\circ}$ .

It can be closed in a temporally oblique nerve-canal, if the nasal border of the excavation is unusually steep or, indeed, overhanging, i.e., when the reddish-gray color of the nasal part of the optic disc is sharply set off from the white of the excavation and especially when the first division of the *arteria centralis retinae* forms a temporally open angle, for in an oblique nerve-canal the plane of the branching is inclined away from the line of vision. The trunk of the central artery is not, however, visible as a rule, because a very thick mass of nerve-fibers covers up the nasal part of the optic disc.

The image is different in a nasally oblique canal. The first of the central arteries then presents an angle open nasally (**reversed vessel distribution**), and the trunk of the central artery is wholly and plainly visible over a long stretch, because the nasal wall of the excavation on which the artery lies is now visible throughout almost its whole extent. The **vessel entrance**, i.e., the place where the central vessels come forth out of the *lamina cribrosa*, then appears strongly displaced toward the temporal side, for we project everything into the plane of the inner opening of the nerve-canal, although it really lies at the deeper level.



b) *The Medulated Section of the Optic Nerve*

(Pl. VI, 2)

This begins immediately behind the *lamina cribrosa*, therefore, about 0.5 mm behind the inner surface of the chorioidea. Its thickness increases up to the level of the outer surface of the sclera and then remains constant. Since the cross-section does not vary essentially from the form of a circle, the orbital section of the optic nerve forms a cylindrical strand 3 to 3.5 mm thick.

This strand is surrounded by connective-tissue sheaths, which are united with the sclera on one hand and with the brain membranes on the other, and are named on account of their analogy to the latter. With the addition of these sheaths the thickness of the optic nerve increases to 4 to 4.5 mm.

Directly at the *lamina cribrosa* a thin connective-tissue layer is given off as an immediate covering for the optic nerve (the **inner** or **pial sheath**, *P*); it clings firmly to the outer surface and extends into the supporting tissue framework (the **septa**). The outer layers of the sclera, which are not united to the *lamina cribrosa*, turn back with a part of their fiber-bundles and form a second coat of some 0.5 mm thickness (the **outer** or **dural sheath**, *D*); it forms a hollow tube united to the inner sheath by only a few trabeculae. Between these two there lies a space, the **intervaginal space**; this begins at the root of the pial sheath and opens centrally into the cavity of the skull.

The intervaginal space is divided into two spaces by a delicate membrane, the **arachnoidal sheath** (*Ar*). The outer space, between the dural and arachnoidal sheaths, is called the **subdural space** (*sd*) and is a narrow cleft-like space, broken only by the trabeculae which course from the dural to the pial sheath. The inner space, between the arachnoidal and the pial sheath, is called the **subarachnoidal space** (*sar*) and contains a richly subdivided system of finer and grosser trabeculae (**subarachnoidal trabeculae**) constituting the union between the arachnoidal and the pial sheaths; this space is wider than the subdural space, or capable of appreciable widening in any case.

The **central supporting tissue strand** courses in the axis of the optic nerve for a distance of 7 to 12 mm from the eyeball. Thereupon it turns downward at almost a right angle and leaves the optic nerve. In the medullary section it has a plain connective-tissue hull, which goes over into the pial sheath at the exit point and so is to be looked upon as a continuation (invagination) of the pial sheath. In this way, too, the orbital section of the optic nerve can be further divided into a (centrally) vascular and a (centrally) avascular portion.

## I. THE SHEATHS OF THE OPTIC NERVE

The outer and inner sheaths have exactly the same structure; they consist of tough fibrous tissue, in the moderately tortuous bundles of which the collagenous fibrillae are mixed with numerous elastic fibers. These are larger than are those of the sclera, often branched and provided with membranous expansions at the branching points. The arrangement of the fibers on the surfaces turned toward the intervaginal space is predominantly a circular one, on the surface turned away from the intervaginal space, mainly a longitudinal one. The cells are usually flat connective-tissue cells with membranous bodies, and have, therefore, a certain similarity to endothelia; they lie on the surface of the connective-tissue bundle. So far as one can judge from ordinary stains, there is no essential difference between them and the cells of the sclera.

Near the bulb the **dural sheath** often splits into several layers separated by open spaces. I have not been able to convince myself that an endothelium is present in these spaces; yet one sees flat cells on the walls of the spaces here and there, though these may be only ordinary connective-tissue cells. The dural sheath shows an especially noticeable splitting where a posterior ciliary artery courses through it (see chap. xv).

According to authorities, a space (the **supravaginal space**) lies outside the dural sheath; this is a continuation of the Tenon's space and is bordered outside by an extension of Tenon's fascia. But this supravaginal space is no more clearly a space than is Tenon's space, and is rather only a very loose layer of connective tissue similar to subconjunctival tissue, in which fluid can easily broaden out. On the other hand, the dural sheath is sharply delineated and provided with a plain endothelium on its inner surface. A good many blood-vessels and nerves are present, the former principally on the outer surface of the dural sheath.

The **pial sheath** shows identically the same structure, only it is much thinner and has a circular fibrillation on its outer surface. The **trabeculae of union** between the dural and pial sheaths (Pl. IV, 5, *Vb*) are pretty thick cylindrical strands made up of bundles of longitudinally coursing collagenous fibrillae reinforced by large elastic fibers, and, like all the surfaces bounding and passing through the intervaginal space, covered by plain endothelium. These trabeculae run through the intervaginal space very obliquely, so that only cross or oblique cuts of these trabeculae are seen in sections; they are, therefore, easily distinguished from the elastic fibers and the subarachnoidal trabeculae by their size. The vessels, too, are carried by these trabeculae to the inner sheath.

The rest of the structures filling out the intervaginal space usually show another make-up; collagenous tissue is, indeed, the substratum

here also, but elastic fibers fail, and the cells of the connective tissues are replaced by endothelium.

The actual **arachnoidal sheath** (*Ar*) is a continuous membrane of some 10  $\mu$  thickness. The following layers can be made out: an endothelial covering (outer endothelium, *aE*) lies on the outside (that turned toward the dural sheath); its cells appear spindle-form on cross-section, i.e., the oval nucleus is surrounded by some protoplasm. One very frequently sees proliferations of this endothelium, even in eyes which are otherwise normal; it then appears to have several layers for stretches; indeed, even spherical pearls, made up of rounded, concentrically stratified endothelium, may form, and then concentric concretions develop from a degenerative process.

The outer endothelium is succeeded by a very delicate layer of non-nucleated connective tissue made up of small stellate expansions whose processes build a network (Pl. IV, 6, *a*). Some clearly demonstrable tiny bundles with a tortuous course go inward from the centers of these little stars. Several of these little bundles, which consist solely of collagenous fibrillae, course farther on parallel to one another, and these groups cross and interweave; in this way there arises a second, heavier layer of connective tissue (*i*) inside the stellate expansions, made up of bundles.

The inner endothelium follows this layer; this seems to be exactly like the outer endothelium, yet it has no tendency to proliferation. The inner endothelium forms the inner surface of the arachnoidal sheath proper, i.e., the one turned toward the pial sheath (Pl. IV, 5, *iE*).

The **subarachnoidal trabeculae** (Pl. IV, 5, *sb*) forms out of the second (inner) connective tissue; groups of little bundles of fibrillae unite into a larger bundle and leave the arachnoidal sheath, covered with a continuation of the inner endothelium. These primitive subarachnoidal trabeculae, therefore, consist only of non-nucleated strands of collagenous fibrillae covered by a plain endothelial membrane made up of a thin layer of protoplasm strewn with oval, somewhat prominent nuclei.

The primitive trabeculae unite into a meshwork and in this way permeate the whole subarachnoidal space. The nearer one approaches the pial sheath, the larger the trabeculae become (*SB*), and within these larger trabeculae are a few cells and elastic fibers as well.

Finally, these trabeculae go over into the pial sheath; their endothelium passes into the (outer) endothelial covering of the pial sheath, and their fibers into the outer circular fiber layer of the connective tissue.

The trabeculae of union, which traverse the entire intervaginal space, do not enter the arachnoidal sheath, but the latter is invaginated inward



along these trabeculae and envelops them still for a long stretch. The cross-section of such a trabeculae of union (*Vb*), therefore, shows a core of firm connective tissue with elastic fibers surrounded by a delicate layer of exactly the same structure as the arachnoidal sheath.

In general, the subdural and subarachnoidal spaces are entirely separate from one another, for the arachnoidal sheath is continuous and free from dehiscences.

The following is to be said concerning the union of the sheaths of the optic nerve with the sclera. When it is stated that the outer half or two-thirds of the sclera goes over into the dural sheath, it is meant that the intervaginal space reaches to this depth. Only a part of the scleral fiber-bundles go over into the dural sheath; these bundles in the sclera course directly up to the optic nerve and then bend about in a sharp bow into the longitudinal fiber course of the dural sheath; they are, therefore, visible throughout their whole course. Numerous cross-sections of scleral fiber-bundles also appear at the insertion of the dural sheath; these are bundles which do not enter the dural sheath and are deflected in flat curves out around the optic nerve.

These deflected bundles may intermingle extensively with these which go over into the dural sheath; the root of the dural sheath is then broad and deep. In other eyes these deflected bundles are systematically compressed into a layer, and then the dural sheath is sharply set off from the sclera. It can come about, for example, that the outer third of the sclera does not go over into the dural sheath at all, and thus appears to be a continuation of the middle third (consult *Elschnig*, 52).

The distance between the root of the dural sheath and the optic nerve is also subject to variation. The greater this distance, the wider the anterior end of the intervaginal space seems. When, therefore, the end of the dural sheath retracts after enucleation, as it does regularly to a greater or less extent, it sinks into the widened end of the intervaginal space, and this then shows an angular bending about into the course of the scleral fibers.

The intervaginal space is always wider at its anterior end than in the orbital part of the optic nerve, because just behind the *lamina cribrosa* the optic nerve does not yet possess its full thickness. The inner scleral layers, united only with the pial sheath and the *lamina cribrosa*, always close off the intervaginal space in front, and to a certain extent form the anterior wall. The form of this anterior end of the intervaginal space is subject to many variations and often is not alike on the two sides of the optic nerve, yet one cannot establish fixed types. The oblique direction of the optic-nerve canal is, as a rule, associated with a more marked



widening of the intervaginal space; one finds such a widening on the nasal side in a temporally oblique canal, especially.

The arachnoidal sheath usually ends in the angle which the dural sheath makes with the anterior wall of the intervaginal space, at times even farther back, for it goes over into the dural sheath.

The pial sheath usually shows a thickening at its scleral end, so that the angle between it and the anterior wall of the intervaginal space is rounded out. The most anterior part of the pial sheath consists of connective-tissue bundles, which, in the main, have a circular course; since, too, the neighboring portions of the sclera are almost exclusively made up of such fiber-bundles, a delimitation of the pial sheath from the sclera is not possible. The longitudinal fibers can be followed some distance farther forward, but they do not form so compact a mass that one can speak of a continuation of the pial sheath up to the *lamina vitrea chorioideae*. When, therefore, some authors speak of the border tissue as a sheath extension, they have chosen a subjective conception, or a form of presentation and description, in order to make the complicated anatomic relations more demonstrable; it is not an extension in the strict sense of the word.

## 2. THE OPTIC-NERVE TRUNK

This consists of a large number of rounded nerve-fiber bundles separated from one another partly by glial tissue and partly by connective tissue trabeculae. This separation is, however, an incomplete one. The individual nerve-fiber bundles exchange fibers here and there.

The connective tissue trabeculae (*septa*) carry the vessels to the nerve-tissue and form a closed system (septal system) united on one side with the pial sheath and on the other side with the central connective-tissue strand, in so far as this is present; as described above, it goes over into the *lamina cribrosa* in front. The *septa* do not, however, inclose the individual nerve-fiber bundles on all sides, but only unite groups of bundles, and, indeed, they do not form a continuous septal wall between such bundles, but only along stretches; otherwise the framework is made up of oblique and cross trabeculae. The grouping of the bundles into *septa* changes in every cross-section; the partitioning walls formed by the glial tissue mount up over the *septa* and to a certain extent form its continuation and bridge over its interspaces.

The make-up of the septal system can most easily be studied in longitudinal sections after staining by Van Gieson (Pl. VI, 4). The longitudinal section of the optic nerve gives a surface view of the *septa* in some places, a longitudinal section of the *septa* in others.

In the surface view, the septa ( $S_1$ ) sometimes appear as expanded plates, sometimes as narrow bundles of connective tissue carrying blood-vessels of varying caliber. They bridge over a few of the nerve-fiber bundles, then bend out of the plane of the section, so that one cannot follow them any farther. On the longitudinal section each septum ( $S_2$ ) appears as a narrow strip of connective tissue, or as a row of cross-sections of rounded connective-tissue bundles broken by larger interspaces. The interspaces are filled out by rows of glial cells ( $Gl$ ). After a short distance the cross-section of connective tissue stops altogether and only the rows of glial cells continue; cross-sections of connective tissue appear thereafter in one or another place. The glial cells, therefore, appear arranged in regular longitudinal stripes, and when one follows such a stripe he sooner or later comes upon a septum.

In this description I have an ideal longitudinal section in mind; it is to be remembered in the study of the preparation, however, that even after a careful choice of the direction of the section, it is only rarely possible to maintain the exact longitudinal direction of the septa for long stretches, because the nerve normally shows an **S**-shaped curve, and the end farthest away from the bulb is slightly bent. The accurate production of cross-sections is easier.

In such a section (Pl. VI, 2) the septal system appears more continuous and better delimited and subdivided into irregular polygonal fields with rounded angles. Yet even these are not set off on all sides, and many septa appear to be discontinued after they have pressed some distance into the nerve-fiber mass. The largest septa are called the *primary*, the weaker and more incomplete ones the *secondary* septa. Their incompleteness is, however, only apparent: they are trabeculae which course obliquely to the plane of section, and, therefore, fall into the plane of section only in part.

Upon cross-section, as well, the "incomplete" septa are continued by empty glial tissue, that is, glial tissue containing no nerve-fibers. When one stains the cross-section of the nerve by Weigert's method (Pl. VI, 6), the nerve-fiber bundles appear much sharper and more completely separated from one another, because after this staining the connective tissue and the glia take on the same light-brown nuance.

Aside from these glial continuations of the "incomplete" septa, glial cells are found in the nerve-fiber mass, apparently in irregular arrangement. But this lack of regularity is only an apparent one, for in longitudinal section these glial cells correspond to regular rows which accompany septal trabeculae, either farther above or below.

From this one comes to the conviction that the glial cells in the

medullated section of the nerve, as in the non-medullated, are found only on the surface of the individual nerve-fiber bundles, i.e., where these are not separated by septa. The pure glial septal walls arise as extensions of the septa. But neither does the glial framework effect a complete separation of the individual nerve-fiber bundles from each other, for these fibers anastomose in places, and the cells lying inside the nerve-fiber mass are nothing else than the ends of the glial framework at the anastomosis of the nerve-fiber bundles. .

The tissue of the septa is ordinary connective tissue; the collagenous fibrillae form delicate bundles, which as a rule course crosswise or obliquely, depending upon the direction of the particular trabecula; however, they also course longitudinally in the case of the larger septa. Elastic fibers are numerous and, in general, take the course of the collagenous fibrillae. These sparse nuclei are slender and stain deeply. The blood-vessels (Pl. VI, 3, *g*) lie throughout in the septal tissue and, with few exceptions, are branches of the sheath vessels; the heaviest part of the septal system likewise carries the largest vessels.

The glial tissue agrees wholly with that of the non-medullated section of the nerve (see p. 101). As above reported, the cells lie at the periphery of the individual bundles, in part, therefore, between the septa and the nerve-fiber mass. For the most part, however, they lie in the prolongations of the septa, which, accordingly, consist of cells and a reticulum of glial fibers. The glial fibers also press into the interior of the nerve-fiber bundles, and insinuate themselves between its fibers in a cross, oblique, or, in part, longitudinal direction. They are thickest on the surface of the nerve-fiber bundle. Inward they are less numerous, yet they permeate all the nerve-fiber bundles, so that one sees portions of glial fibers (Pl. VI, 5, *gl*) everywhere between the cross-sections of the nerve-fibers.

The glial tissue is sharply separated from the connective tissue of the septa; neither connective-tissue fibers nor vessels press down into the nerve-fiber bundles, nor do glial fibers press into the septal system. The nerve-fiber mass often shrinks a little in the hardening fluid, and then cleft-like spaces form between the septa and the surface of the nerve-fiber mass; the spaces are mostly bridged over by glial fibers, but often appear quite empty. These spaces do not possess an endothelial lining; they can, therefore, best be explained as artefacts. They are apparently the same spaces as those produced by injections of the nerve trunk and which have been looked upon as lymph spaces (Pl. VI, 3, *Ly*).

The nerve-fibers are of the same sort as those found in the white substance of the brain and spinal cord. They are fine fibers consisting only of an axis cylinder and medullary sheath without a sheath of Schwann;



their thickness varies usually between 2 and 5  $\mu$  (Pl. VI, 5, *n*). The finer fibers have been looked upon as the actual visual fibers, the thicker ones as pupillary fibers (von Gudden, Westphal, and others). When hardened, these fibers show varicosities, i.e., nodular swellings. The very great variation in the size of the cross-section of the fibers is due to the fact that the section cuts many fibers through the nodes and others through non-nodular portions.

The varicosities have been pretty generally looked upon as artificial products. Bartels (17) has demonstrated a very large number of primitive fibrillae in the axis cylinder.

At the periphery of the optic nerve a more or less well-marked, plain layer of flattened and compressed bundles is found; this consists only of glial tissue (fibers and cells), and contains no nerve-fibers (Greeff's **peripheral glial mantle**, 74) (Pl. VI, 2, 6, *glm*). A structure analogous to this is found in the brain and spinal cord; it is indicated even in the newborn, but is not as plainly visible as later on account of the defective development of the medullary sheaths (Kiribuchi, 118; Greeff, 74). These bundles are separated from the nerve-fiber bundles by stretches of connective tissue septa, coursing parallel to the pial sheath (**peripheral septa** of Fuchs, 66).

At the posterior end of the central connective-tissue strand the peripheral glial mantle is turned in, like the pial sheath itself, and continues along the central connective-tissue strand for a varying distance (Pl. VI, 2).

This place, usually spoken of as the **entrance of the central vessels**, lies below and somewhat nasal, according to Deyl (38), almost straight below, according to Strahl (214). Its significance lies mainly in the fact that it corresponds to the posterior end of the fetal cleft (cf. chap. xvi), and in the developed eye represents the only visible trace of this phase of the embryologic development so important for the study of anomalies.

The main axis of the central connective-tissue strand consists of a tubular continuation of the pial sheath (for a covering), and of the two central vessels (*arteria et vena centralis retinae*) as contents. The covering consists of longitudinally fibrillated connective tissue and agrees in every histologic particular with the septal system, into which it is directly continued. Between it and the central vessels, and, likewise, in the interspaces between the two vessels, there is a loose connective tissue much split up into longitudinal spaces (lined by epithelium?).

The central vessels give off only a few small branches in the trunk of the optic nerve, and these are mostly veins. Therefore, they maintain their caliber unchanged up to the *lamina cribrosa*. The *arteria centralis*



*retinae* does not, as a rule, show any evidence of contraction, but has a wide-open lumen of some 0.13 mm diameter, a weakly developed intima, a 0.02 mm thick muscularis, and an equally weak adventitia. The vein wall consists solely of endothelial and connective tissue.

Fine nerve branches enter with the central vessels, and form a ganglion-cell-free plexus about the central artery; this can be followed into the papilla (Krause, 122).

It is not rare to find the optic nerve changed in a peculiar way on cross-section; one finds swollen or knotted areas in which the nerve-fibers are not cut across, as usual, but longitudinally or obliquely; therefore they appear very indistinct, so that the whole node, which, in general, is sharply set off from the normal tissue, is recognized even by low magnification and, indeed, macroscopically in uncut tissues by another color (Pl. VI, 6, c). These changes were described by Siegrist (207), and were considered to be areas of fatty degeneration. However, it came out in the discussion of Siegrist's paper that these appearances are well known, and have usually been looked upon as cadaverous appearances. Elschnig (53) finally demonstrated that the cause of these changes is the bruising of the optic nerve by instruments in the preparation of the orbital contents. The **fleck-form** degeneration of the optic nerve of Siegrist is, according to this, listed as an artefact.

## CHAPTER IX. THE CILIARY BODY (CORPUS CILIARE)

### (Pl. I)

The ciliary body forms a girdle of about 5 to 6 mm in breadth, narrower on the nasal side and above (4.6 to 5.2 mm), broader on the temporal side and below (5.6 to 6.3 mm). A meridian going obliquely from temporal and above, nasal and downward, separates the narrower from the broader part (Pl. II, 1). The description of the outer surface has been given above (pp. 12-13), likewise the characteristics of the two zones on the inner surface: the **orbiculus ciliaris** and the **corona ciliaris** (p. 10).

The *orbiculus ciliaris* is the broader of the two zones. Some 2 mm throughout belongs to the *corona ciliaris*, the rest to the *orbiculus ciliaris*. The significant difference in the breadth of the entire body depends, therefore, upon the expanse of the latter. In general, the inner surface of the *orbiculus ciliaris* is considerably darker than that of the chorioidea. This depends, however, only upon the pigment epithelium. The following details of its color can be recognized under certain circumstances.

Immediately in front of the *ora serrata* its color is often darker than in the middle, or about a millimeter in front of the *ora serrata* one sees an especially dark girdle, which reproduces the zig-zag form of the *ora serrata* with absolute accuracy, although in a meridionally enlarged proportion,

therefore exaggerated to a certain extent. Corresponding to the teeth of the *ora serrata*, there are narrow radial striae which open into the corresponding valleys of the ciliary body (**striae ciliares**, O. Schultze).

The dark girdle is not always visible; often it is developed only in the broader part of the *orbiculus ciliaris* and is entirely absent in many eyes. But the *striae ciliares* (Pl. IV, 10, *St*) are always to be seen except in those cases in which the pigmentation is, in general, so intense that one cannot make out any difference. The color is usually darker in front toward the *corona ciliaris*.

Although one speaks of the *orbiculus ciliaris* as the flat portion of the ciliary body, this is not to be taken absolutely literally. For example, the dark girdle always shows a slight prominence when well developed. Slight differences in level are also to be found over the orbiculus. The same is true of the *striae ciliares*. In the most anterior portion of the orbiculus, just behind the corona, one sees a system of little warts or folds in many eyes; these are very much smaller than the ciliary processes and only visible when looked at with the *loupe* under strong focal light (sunlight is best). These warts (Pl. IV, 10, *w*) are elongated, sausage-like structures with their long diameters meridional; they are often arranged in chains and three or four such rows are found in a ciliary valley.

The **corona ciliaris** is much more uniformly developed throughout its entire circumference than in the *orbiculus ciliaris*. The difference between the nasal and temporal sides is slight and amounts to only a few tenths of a millimeter at the most.

The meridional white striation, so striking even on macroscopic examination, is due to the summits of the **ciliary processes** (**processus ciliares**). These striae give the name to the zone and number about 70 in the entire circumference.

Each process (Pl. I) presents a plate or ridge projecting axial (toward the lens) and inward; it is about 2 mm long (in the meridional direction) and 0.8 mm high (in a radial direction). The free border, or **ridge**, of the process—that turned toward the lens and the vitreous—is less pigmented than the side surface and the interspace and, therefore, appears clear upon the neighboring dark background (Pl. IV, 10, *Pc*).

The interspaces (**ciliary valleys**) between the processes carry numerous similar projections; posteriorly these go over into the above-mentioned warts; in front they become larger and here and there they grow to especially large prominences (*plicae ciliares*) in the neighborhood of the iris root, but they always remain much smaller than the ciliary processes. These plicae are as darkly pigmented as the floor of the ciliary valley and, therefore, are not plainly visible in macroscopic examination. Finally,

the whole system of elevations and projections is succeeded in front by a circular ridge which juts forth about opposite the border of the lens (sims of H. Virchow, 232).

Smaller irregularities in the development of the *corona ciliaris* frequently appear without particular reference to location; thus here and there the ciliary valleys are wider or the individual processes are notably lower than their neighbors (Pl. II, 1). The marked individual variations in this region have recently been elucidated through the excellent drawings by Hess (101).

At its posterior border, the ciliary body is not any thicker than the peripheral parts of the chorioidea; where the ciliary muscle begins, however, some 3 mm behind the anterior border, the thickness of the ciliary body gradually increases and attains a maximum of 0.8 mm at its very anterior border. With this maximal thickness the ciliary body ceases as such, as a rule, and thereby acquires a three-sided prismatic form; an **outer** surface is turned toward the sclera, an **inner** toward the vitreous, and a narrow **anterior** surface is turned toward the center of the cornea or the pupil.

The ledge formed by the outer and anterior surfaces borders on the scleral roll (Pl. III, 1, *Sw*); here one finds the insertion of the ciliary body into the sclera, as well as the anterior insertion of the uveal tract, in general. The inner and the anterior surfaces unite in a rounded ridge projecting in the direction of the border of the lens; this will be spoken of as the **inner ledge**; it is crowned by the sims.

The insertion of the **iris root** into the anterior surface lies in the neighborhood of this ledge, whereas the meshwork of the iris angle, in so far as it does not go over into the scleral roll, unites with the peripheral parts of the anterior surface of the ciliary body. There remains a narrow strip of the anterior surface between the two in many eyes; this is covered only by the innermost lamellae of the trabeculum (the uveal meshwork) and so takes part in the limitation of the anterior chamber. In other cases the anterior layers of the iris extend to the scleral meshwork as a much-broken layer and so cover over this remnant of the anterior surface.

The direction of the anterior surface varies even under normal conditions, and even more so when one takes into account eyes with an abnormally long axis; and, indeed, as follows:

1. The direction of the anterior surface is more nearly sagittal; if one erect a line perpendicular to the inner surface of the sclera at the inner ledge, the foot of this line falls behind the scleral roll; the ciliary muscle is, in general, longer—the **myopic type**, so called because it is found in pronounced form in eyes with axial myopia.

2. The anterior surface is more frontally placed; the perpendicular line drawn from the inner ledge to the inner surface of the *tunica fibrosa* falls in front of the insertion of the ciliary muscle; the muscle is, in general, shorter—**hypermetropic type**, because it is found mainly in eyes of lessened axial length.

Aside from these individual differences one notes differences as well between the nasal and temporal sides in many eyes, such as the ciliary body approaching the type of hypermetropia on the nasal side, and that of myopia on the temporal side.

The greater part of each ciliary process sets upon the inner surface, a smaller part extends over the inner ledge to the iris root, and even reaches a short way over onto the back surface of the iris. In a side view the ciliary process appears uniformly rounder, aside from small indentations, similar to the circumference of the pinna of the ear. But one only obtains this view in the meridionally bisected eyeball or in very thick meridional sections. The microscopic preparation also shows interruptions and defects in the ciliary processes, even when the direction of section is most carefully thought of (Pl. I); these are not actual interruptions but only uncapped depressions of the side surfaces. One recognizes these relations much better in transverse sections of the *corona ciliaris* (Pl. VII, 2); here, where one has a whole series of ciliary processes in cross-section before him, one is convinced that the continuity of the tissue is nowhere broken, but that the side surface is only wrinkled and the ridges somewhat rounded off.

In the study of meridional sections the error is not infrequently made of holding the sime or an incomplete cut through the process to be the entire process. One can protect himself against this error if one give heed to the pigmentation of the epithelium; the pigmentation of the epithelium is very much less upon the very height of the projection, and then only does the section actually go through the ridge of the ciliary process.

The histologic peculiarities of the ciliary body are easiest made clear by a comparison with the posterior zone of the bulb:

	Middle Zone	Posterior Zone
Pars uvealis	Musculus ciliaris and suprachorioidea	Suprachorioidea
	Vessel layer of the ciliary body	Vessel layer of the chorioidea
	—	Choriocapillaris
	Elastic lamella	Elastic lamella { Lamina
	Intermediary connective tissue	— { vitrea
	Cuticular lamella	Cuticular lamella { chorioideae
Pars epithelialis	Pigment epithelium of the ciliary body	Pigment epithelium of the chorioidea
	Ciliary epithelium	Retina { Layers 1 to 8
	Membrana limitans interna ciliaris	Membrana limitans interna



a) *The Uveal Portion of the Ciliary Body*

## I. SUPRACHORIOIDEA AND CILIARY MUSCLE

If one follows the suprachorioidea from behind forward new structural elements—smooth muscle-fibers—appear even in the equatorial region or, at times, still farther posterior, therefore in the territory of the chorioidea. They are grouped in bundles singly or for the most part branched and then forming three or more rayed stellate little figures (**muscle-stars**, Pl. IV, 8).

The muscle-stars are flattened, in keeping with the lamellar structure of the whole layer, and, therefore, appear only as very slender spindles on meridional section. Their true form and their distribution in the plane of the surface can only be studied in teased preparations of the chorioidea. They are disposed over both surfaces of the suprachorioidal lamella, and their fibers go out in tufts of elastic fibers radiating into the elastic plexus of the neighboring lamellae (*f*).

Sparse and separated by wide interspaces to begin with, the muscle-stars become more numerous and more distinct as one approaches the posterior border of the ciliary muscle; finally, they run together into polyhedral meshes (Pl. IV, 9, *st*). The ciliary nerves bifurcate in the same zone and form a wide-meshed plexus by means of their larger and smaller branches.

The **ciliary muscle** proper (*M*) begins with these meshes of muscle-bundles. A closed framework soon develops out of this, i.e., the bundles disposed in various planes unite with one another and the muscle mass becomes thicker and thicker through further branching. This structural framework is maintained throughout the entire ciliary muscle, only the prevailing direction changes gradually, so that the ciliary muscle falls into various portions.

In the outer layers of the muscle the bundles have an almost pure meridional direction, i.e., the meshes of the framework are narrow and drawn out in the meridional direction; therefore, one sees almost no intermediary tissue. The respective layers of muscle-bundles, indeed, show many unions in the direction parallel to the surface, but among themselves these bundles are only sparsely united with one another; the suprachorioidal lamellae go deeply in between these layers and their denser pigmentation can be followed for a long distance into the muscle. This portion of the muscle itself, therefore, appears to be lamellated and on meridional section to be composed of many longitudinally disposed bundles. It is called the **meridional portion**, from the direction of the bundles.

Forward the thickness of this portion gradually increases up to one-third of the maximum of the entire muscle. At the very fore part it again thins and ends at the scleral roll: the muscle-fiber bundles go over into finely fibrillated connective tissue, likewise of a meridional course; this tissue presses in between the circular bundles of the scleral roll and probably continues farther into the lamella of the scleral trabeculum. Occasionally individual cross-sections of bundles are seen at the anterior end of the meridional portion.

The suprachorioidea is at length completely lost in the meridional portion of the ciliary muscle; the majority of the lamellae enter the posterior border of the ciliary muscle along with the muscle-stars, and the few lamellae which lie outside this gradually go over into the muscle-bundles from the outer surface. So it comes about that the most anterior part of the perichoroidal space is entirely free of suprachoroidal lamellae. Not infrequently one sees a short muscle-bundle inserted into the *lamina fusca sclerae* at the very front, and, therefore, not taking part in the general detachment of the ciliary body (Sattler, 188).

The **radial portion** succeeds the meridional portion inward. In this the structure of the framework is most pronounced and the section, therefore, shows an irregular net-form marking. Many of the bundles appear to end blind; these are the obliquely coursing bundles whose continuation falls in the next section. The interstices of the framework are filled out by a pretty dense connective tissue, which carries the blood-vessels and the especially numerous nerve branches, and in heavily pigmented eyes also contains a few scattered chromatophores. This portion received its name from the fact that a fan-like radiation of the surface was read out of a divergence of the bundles. Yet one is at great pains to find such an arrangement of the musculature, and I would prefer to call it the reticulated portion.

The radial portion attains its greatest thickness in the neighborhood of the inner ledge of the ciliary body. A special ending is not to be ascribed to this portion, for the framework turns back into itself. For example, this closure of the framework by means of many circular coursing muscle-bundles is to be seen in the form of a net along the inner surface of the muscle (F. E. Schultze, 196).

The union with adjacent structures, especially the surface union with the vessel layer of the ciliary body, is only mediated by the interstitial connective tissue of the muscle, which goes directly over into the connective tissue of the vessel layer. In a similar way the anterior end of the radial portion unites with that portion of the scleral framework which does not enter the scleral roll: the connective tissue substratum of the

trabeculum of the iris angle goes over into the interstitial connective tissue of the muscle.

On the side of the anterior chamber, in the delimitation of which just this portion of the muscle takes some part, the muscle framework is bordered by a thin layer of connective tissue united with the meshwork of the iris angle, on the one hand, and with the iris stroma on the other hand. This layer, as well as the most anterior portions of the interstitial tissue, is especially rich in fine, wavy, elastic fibers; these are pressed together at the inner border of the scleral roll, for instance, and radiate out from here toward the root of the iris and into the muscle. Chamberward the trabeculae of the uveal meshwork course to the root of the iris covered by and snugly inclosed in this layer. In general, this layer varies greatly in its density and composition in various individuals.

At the inner ledge of the ciliary body lies the **circular portion** of the ciliary muscle, the so-called **Mueller's muscle**, named after its discoverer, Heinrich Mueller (157). As its name indicates, it is characterized by the circular course of the bundles and, therefore, appears as a group of cross-sections in the meridional section. The intermediary tissue is looser than in the radial portion; it has more of the appearance of the stroma of the iris, whose root lies just in front of this portion.

But the circular portion likewise forms only a part of the muscle framework; the meshes are much drawn out in a circular direction, and do not form a separate part independent from radial portion. Unions and transitions between the two portions occur, so that in most sections one cannot state exactly how far the circular portion extends. In any case the drawings of Iwanoff (114) do not correspond to the actual conditions in this respect.

The form of the ciliary muscle, especially, and thereby that of the entire ciliary body, depends upon the grade of development of the circular portion. In the myopic type the circular portion is very weakly developed or fails entirely; in the hypermetropic type it is very strongly developed, on the other hand, and, therefore, causes the inner ledge to project forward and inward.

It at once comes to mind that these various types of the ciliary muscle are nothing more than the expression of the particular requirements of accommodation for the refraction concerned. For the hyperope, who must accommodate for distant vision, certainly uses much more accommodation in his whole life than does the myope, who can work even at near objects without any particular accommodation. But this relationship must not be so conceived of that the ciliary muscle of the hyperope is thought of as hypertrophic, and that of the myope as atropic, because the whole mass of the muscle in the myopic type may be even greater than in the hyperope.

Now Heine (90) has shown that the eserized (contracted) muscle approaches the



hyperopic type, the atropinized (relaxed) muscle the myopic type. It is, therefore, conceivable that the different types are nothing more than different states of contraction of the muscle. Against this it is to be argued that, as a rule, there is no occasion for the hyperope to accommodate just before the eye comes to anatomic study, as for example in the last hours of life if the eye is removed from the cadaver, nor during the anaesthesia if it is enucleated during life. Finally, the same variations are found even in the newborn (see chap. xvii).

All things considered, one must conclude that the form of the ciliary muscle depends upon its length, i.e., the longer the muscle from whatever cause, the more the myopic type comes to expression, the shorter it is, the more the hypermetropic type comes out. The transitory changes in its length, by contraction, have the same effect as the permanent ones—those which develop either as a congenital variation or as a result of the elongation or shortening of the sagittal diameter of the eye.

The fibers which make up the ciliary muscle are ordinary smooth muscle-fibers, although the nuclei are not so markedly rod-form but more oval than is generally the case.

The blood-vessels peculiar to the ciliary muscle lie throughout in its interstitial tissue and have a small caliber. The larger arteries encountered in horizontal sections of the ciliary muscle are the main branches of the long posterior ciliary or anterior ciliary arteries; for these vessels course through the muscle; they usually lie in a large area which is free from muscle-fibers.

Behind the root of the iris and in front of the circular portion of the muscle or in it one encounters the cross-section of an artery, the *circulus arteriosus major*, in all meridional sections; this vascular circle, therefore, hardly belongs to the ciliary muscle, for its branches supply the ciliary processes and mainly the iris. Large veins are not found in the ciliary muscle; its blood is partly carried backward by the smaller vessels of this sort through the vessel layer, partly outward through the sclera; the latter vessels are the *venae ciliares anteriores*; they also take care of the outflow from the canals of Schlemm (see p. 44).

The ciliary nerves branch before entering the ciliary muscle, form first a wide-meshed plexus, and then, continuing to branch, pass on through the muscle. The nerves to the ciliary muscle itself, as well as those for neighboring parts, are given off from this plexus. This is particularly true of those for the iris and the deeper layers of the corona. This plexus consists mainly of medullated fibers and, aside from larger ganglion cells, usually contains small bipolar ganglion cells, which are in all probability motor cells (H. Mueller, 159; Iwanoff, 115).

There are but few contributions extant upon the finer relations of the nerves of the ciliary muscle. Agababow (4) has found motor endings in the muscle-fibers in the shape of straight fibers, or fibers dividing at sharp angles, by the aid of the methyl-blue



stain, and end arborizations with pretty large branches ending by nodular expansions. These lie in the interstitial connective tissue and were considered to be sensory endings serving the muscle-sense. Finally, Agababow found the so-called reticular plate, i.e., an extremely fine fibrillar net, which can only be resolved by the aid of the oil immersion system. Yet accurate data concerning the situation of this layer is lacking.

## 2. THE VESSEL LAYER OF THE CILIARY BODY

This is a direct continuation of the vessel layer of the chorioidea, for the vortex veins carry away the blood not only from the chorioidea but also from the anterior portion of the uveal tract, especially from the iris and the ciliary processes. Since, however, the arterial trunk for this vascular region runs through the perichoroidal space and the ciliary muscle, the vessel layer of the ciliary body contains only veins of varying caliber, with the exception of a few arteries running back to the chorioidea. These vessels course nearly parallel to one another and occasionally anastomose at narrow angles at the vortices; therefore, one gets only longitudinal or very oblique sections of these vessels on meridional cuts, on the other hand, almost pure cross-sections on transverse cuts; in the *orbiculus ciliaris* these vessels are broadened out into what is scarcely more than a single layer, i.e., narrow and wide vessels lie on the same plane (Pl. VII, 4, 5, *Gf*).

The larger elevations of the ciliary body, the ciliary processes, the sims, the *plicae ciliares*, and the warts in the valleys are due to local thickenings of the vessel layer with a corresponding superimposition of the vessel lamina. The ciliary muscle has no part in any of these formations; its inner contour courses along straight beneath the elevations (Pl. VII, 2), as the transverse section shows. In particular, each ciliary process (*Pc*) conceals a richly subdivided framework of wide capillaries and small veins supplied by a small artery from in front, and sends several veins backward into the *orbiculus ciliaris*.

In respect to its histologic structure, the vessel layer of the ciliary body also agrees with that of the chorioidea, except that the chromatophores are less numerous and almost completely disappear toward the front in many eyes. The ciliary processes only exceptionally contain chromatophores; for this reason the collagenous connective tissue comes out more prominently and is denser in this region. In the anterior part of the ciliary processes especially (toward the iris root), this tissue morphologically assumes a sclerosed appearance, and these places then stain an intense red by Van Gieson. Fine elastic fibers are irregularly intermixed with the collagenous tissue.

## 3. THE ELASTIC LAMELLA

(Pl. VII, 4, 5, *el*)

This is a continuation of the lamella of the same name in the *lamina vitrea chorioideae* and forms the inner limitation of the vessel layer in the *orbiculus ciliaris* and posterior part of the *corona ciliaris*. In the *orbiculus ciliaris* it is seen, after all stains, as a fine, very sharp straight line in case the section goes perpendicular to the surface, for this lamella courses absolutely smooth over the *orbiculus ciliaris*.

The slight wrinkling shown in Pl. VII, 4, 5 is brought about by a detachment of the ciliary body from the sclera.

Naturally, it comes out still more plainly after elective staining for elastic fibers, e.g., orcein. This stain resolves it into a net of elastic fibers.

With the transition to the elevations of the *corona ciliaris*, this smoothness of the lamella is lost and it therefore disappears in the unstained state at this place, for it is usually cut obliquely by the section. In the orcein preparation it can, however, still be followed as far as the middle of the corona. The fiber net constantly becomes looser and finally rays off in irregular bundles into the collagenous tissue of the vessel layer. This lamella cannot therefore be demonstrated over the anterior declivities of the ciliary processes.

## 4. THE INTERLAMELLAR CONNECTIVE TISSUE

(Pl. VII, 4, 5, *iB*)

This is evidently a continuation of the delicate layer of collagenous fibrillae found by Wolfrum (240) between the two layers of the glass membrane of the chorioidea (cf. p. 60). While special methods are necessary to demonstrate the collagenous fibrillae in the chorioidea, this connective-tissue layer attains such a thickness in the ciliary body that ordinary stains, especially Van Gieson's stain, make it plainly visible.

For example, when one follows the *lamina vitrea chorioideae* toward the ciliary body, the membrane (which so far has appeared as a single membrane) splits into two lamellae, even before it reaches the *ora serrata retinae*; the outer elastic lamella maintains its bow-string course still farther; the inner cuticular membrane, however, becomes wavy and separated farther and farther from the elastic lamella as one nears the end of the retina. At first the space appears empty (by Van Gieson's stain), then there appears a longitudinally fibrillated collagenous tissue, which becomes thicker and firmer in the *orbiculus ciliaris*, and stains much more intensely red with fuchsin than does the stroma of the vessel layer. Here and there, the interlamellar tissue contains elongated

nuclei, but no blood-vessels. In surface view, the wavy fibrillae show a meridional course, as is well depicted by Henle (94).

Sattler (187) found a special capillary system in the posterior part of the ciliary body and the most anterior portion of the chorioidea; this consists of narrow capillaries and lies inside the choriocapillaris. It can, therefore, be suspected that this second capillary system has its seat in the interlamellar connective tissue. Since Sattler himself found it in only half of the eyes, it may well be only an abnormality; I have found such capillaries in only a few otherwise normal eyes.

Upon the cessation of the elastic lamella, the interlamellar connective tissue merges with the vessel layer.

##### 5. THE CUTICULAR LAMELLA

(Glass membrane of the ciliary body of the older authors, outer glass membrane of the *pars ciliaris retinae*, 184)

(Pl. VII, 4, 5, *Cu*)

This is a continuation of the lamella of the same name in the chorioidea and is of the same structure as it; it covers the whole uveal portion of the ciliary body as far as the neighborhood of the iris root. It is, in general, very thin, and possesses a greater thickness only in the anterior third of the ciliary processes, where it attains the thickness of Descemet's membrane in older persons (Pl. VIII, 11, *Cu*). In this location it is, moreover, easiest demonstrable, especially by Van Gieson's stain; the weakly red-colored membrane then stands out plainly from the brilliant red sclerosed connective tissue of the vessel layer.

Yet Wolfrum (240) is of the opinion that the clearer layer described is only hyalinized connective tissue, and that the cuticulum proper is here as thin as in the *orbiculus ciliaris*.

The difficulty of seeing the cuticular lamella in the other parts of the ciliary body is much less due to the thinness of the membrane than it is to the numerous uneven areas on the inner surface of the ciliary body; these are formed in part by its union with the interlamellar connective tissue. The irregularities consist of ridges of varying height and size; they show many horn-like branchings and often run together into a closed network, so that the inner surface of the ciliary body has a honeycombed appearance. Heinrich Mueller (156) first accurately described this structure and it is called the *reticulum of Heinrich Mueller* after him.

Surface preparations are absolutely necessary for the study of the reticulum; only in this way does the network come out properly and one who has once seen such a surface preparation will never have the idea that the reticulum is brought about by a wrinkling of the inner surface from the contraction of the ciliary muscle.

For making such a preparation cadaver-eyes are best; the epithelial covering of the ciliary body is then more easily detached from the cuticular lamella, for the cadaverous degeneration only destroys the protoplasmic parts and leaves the more resistant glass membranes unchanged. The retina is bluntly detached at the *ora serrata*, the pigment epithelium and all of the layers lying inside then comes away with it, and if a few remnants of pigment remain behind in the deeper meshes it does not interfere with the recognition of the reticulum. One then turns the preparation over and deftly removes the ciliary muscle and the vessel layer. The inner surface side is then laid up and the preparation is mounted in glycerin or stained with Mallory's hematoxylin and mounted in Canada balsam.

In this way one gets a general view of the whole *orbiculus ciliaris*. The corona, alone, does not permit the making of such a preparation, because the folding of the surface is too marked; this zone is better studied in sections.

In general, three varieties of the reticulum with respect to height of ridges and width of meshes can be made out; naturally, these are not sharply separated from one another.

1. The larger meshes (Pl. VII, 4) are rounded or polygonal, and have a width of 40 to 50  $\mu$  and a depth of as much as 40  $\mu$ ; the ridges (*l*) are thick and high, often thickened at the free border and finely striated on the surface.

2. The small meshes (Pl. VII, 3, 5) have only about one-half or one-third the diameter of the large meshes and are very much more irregular; the ridges are low and narrow.

3. Among these appear ridges characterized by special thickness, height, and striation; in general, they have a meridional course; the immediately adjacent meshes are, therefore, very deep. These high ridges go over into low and narrow ridges at the sides and ends, and the whole figure thereby takes on a branched appearance or has similarity to a bone corpuscle (Pl. VII, 3; the darkest portion of the reticulum).

The reticulum extends over nearly the entire inner surface of the ciliary body, although a narrow strip in front of the *ora serrata* and the ridges of the ciliary processes are practically free from it.

Starting in front of the *ora serrata* one usually encounters large meshes right where the reticulum as a whole begins. Not infrequently they are closed off into a girdle, which is then visible even with a *loupe*, and copy the form of the *ora serrata* (cf. p. 108).

Furthermore, the *striae ciliares* are sometimes formed by several rows of large meshes. The small meshes, or a zone with an indistinct reticulum, follow immediately upon the large meshes in front. In any case the small meshes are encountered in the fore part of the orbiculus as a closed zone, and in this are the high and thick, bone-corpuscle-like ridges (Pl. VII, 3).



The reticulum again becomes less plain over the *corona ciliaris*, in particular in the ciliary valleys in front, inward along the sides of the processes, and disappears, as above stated, over the ridges of the ciliary processes, i.e., in so far as they show a lighter color, or is reduced to wholly insignificant irregularities.

On section the reticulum appears only as an angular contour when weakly developed—something like the silhouette of a far-off mountain chain. When well developed, however, narrow projections stand out, bordered by parallel smooth sides with rounded edges, or (in the larger ridges) often ending with a thickened rolling margin. The height of the ridges varies much (Pl. VII, 4); as a rule, the heavier ridges are also the higher. The inner surface of the orbiculus also takes on a slight unevenness from the varying development of the reticulum. In this way a closed large-meshed zone forms an even, wall-like thickening; the *striae ciliaris*, likewise, stand out somewhat above the level of the remainder of the inner surface, and the bone-corpuscle-like ridges behind the *corona ciliaris* form correspondingly elongated hummocks.

The thin ridges (Pl. VII, 5) often consist of only the cuticular lamella; the thicker ones, however, contain a connective tissue arising from the layer at the base of the interlamellar connective tissue (Pl. VII, 4); it is this which lends the reported striation to the surface view. The layers of the ciliary body lying farther outward take no part in the formation of the reticulum; the elastic lamella, in particular, courses smoothly beneath the ridges.

### b) *The Epithelial Covering of the Ciliary Body*

(*Pars ciliaris retinae* of the authors)

#### 6. PIGMENT EPITHELIUM OF THE CILIARY BODY

(Pl. VII, 2, 4, 5, P)

This is the direct continuation of the pigment epithelium of the chorioidea and, like this, consists of a single layer of pigmented epithelial cells. Only in so far as this layer is compelled to lie in the deepenings of the reticulum, does there come about a heaping up of cells and this is without loss of the principle of a single layer. The inner ends (the heads) of the cells show a straight border, the pigment processes characteristic of the chorioidal pigment epithelium are absent; colorless cement ridges are not visible in the pigment epithelium of the ciliary body; the cell borders, like the cell muscles, can only be seen in bleached sections. The pigment consists of larger darker granules, which are throughout rounded;

therefore, the pigment epithelium of the ciliary body as a whole appears darker and blacker than does that of the chorioidea.

The form of the cells changes in various parts of the ciliary body. Where the inner surface is smooth, as just in front of the *ora serrata*, the cells are short and cylindrical, some 6  $\mu$  broad and 18 to 23  $\mu$  high; the nucleus is oval and placed with the long axis at right angles to the inner surface of the ciliary body. The large meshes of the reticulum are filled out by pigment (Pl. VII, 4), the cell layer as a whole goes down into the depression, and its cells take on an irregular polyhedral form. These evaginations of the pigment epithelium do not possess a lumen, only a funnel-form depression on the inner surface of the pigment epithelium. The layer as a whole undergoes an appreciable thickening by these evaginations (as much as 60 to 80  $\mu$ ) and seems just so much darker on the surface view than do the smooth portions (darker girdle in front of the *ora serrata* and the *striae ciliares*).

The small meshes (Pl. VII, 5) are too narrow for the pigment epithelium to lie in them as a layer; they are, therefore, only filled out by correspondingly displaced cells, and here one often sees the base of the cell, i.e., the side of it turned toward the uveal portion, free from pigment granules. The pigment epithelium over the ridges of the ciliary processes becomes significantly lower (Pl. VIII, 11, *P*) (height of the cell 10 to 15  $\mu$ ), the cells come to have more breadth than height, and the nuclei stand obliquely. The pigmentation, likewise, decreases appreciably, so that one can recognize borders and nuclei even without depigmentation (Pl. VII, 2). This explains the whitish color of the ciliary ridges.

The union between the individual pigment epithelial cells is possibly no more firm than it is in the territory of the chorioidea. But the reticulum brings about a considerable increase of the surface and effects a firmer fixation (anchoring) of the pigment epithelium by means of its many projections. As a matter of fact, the pigment epithelium cannot be removed wholly intact, even in a macerated eye; pigment remnants remain behind, especially in the large meshes.

The outer surface of the pigment epithelium everywhere forms a perfect mould of the inner surface of the cuticular lamella. This is best seen in sections of cadaver-eyes in which even a desquamation of the epithelium has begun. Over the crests of the ridges, too, the epithelium stands away and the ridges of the reticulum never reach through the entire thickness of the pigment epithelium; it never comes in contact with the next layer, the ciliary epithelium.

Aside from the evaginations of the pigment epithelium brought about by the reticulum, there are other evaginations very similar to those of

genuine glands. These are the flask-form epithelial plugs engirt by the cuticular element—lamellae which pass through the interlamellar connective tissue and the elastic lamellae and with their thickened ends reach as far as the vessel layers. A lumen is not, however, demonstrable in these structures; they therefore lack an essential morphologic element of a gland. Such “glands” are found in the anterior part of the orbiculus especially, but even here only scatteringly.

Whether or not one should consider these structures glands, as does Treacher Collins (226), seems to me to be a matter of no importance. There is no doubt that the ciliary body secretes the aqueous, but we have no warrant that this function is reserved for the reported “glands” and that the rest of the inner surface of the ciliary body takes no part therein.

#### 7. THE CILIARY EPITHELIUM

(Pl. VII, 2, 4, 5, CE)

This also forms a simple smooth layer of cells, aside from several folds in the anterior part of the orbiculus. The protoplasm of these cells is, in general, free from pigment; pigment is found in the ciliary epithelium only anteriorly in the neighborhood of the iris root.

This layer corresponds to the entire retina *sensu strictiori*, with the exception of the *membrana limitans interna*; one can convince himself of this best in the eye of the newborn, where the transition of the retina into ciliary epithelium is still a wholly gradual one (Pl. IX, 1). Its union with the pigment epithelium is a great deal more firm in any case than is that of the retina with the pigment epithelium of the chorioidea, for artificial and post-mortal detachment stop at the border of the retina. This union is apparently effected by a cement substance like that uniting the individual ciliary epithelial cells to one another; but I cannot make out a special membrane corresponding to a continuation of the *membrana limitans externa*. Not infrequently one sees small vacuoles between the pigment epithelial cells and ciliary epithelium in cadaver-eyes, and here the points in which they are united are drawn out into pedicles.

The form of the cells varies from that of a cylinder to a cube, and, in general, their height increases from behind forward.

Immediately in front of the overhanging border of the retina, some particularly long-drawn-out fiber-like cells appear, as reported on p. 86; otherwise the cells in the most posterior parts of the orbiculus are 6 to 9  $\mu$  broad, and some 30  $\mu$  high, therefore markedly cylindrical. The elongated nuclei lie nearer the outer ends of the cells. Although most of the cells are straight or inclined slightly forward, or bowed, small groups of cells show a distinct bend backward. A peculiar crossing



of the cells arises in this way, a microscopic chiasma, so to speak (drawn by von Ebner, 120). When a closed large-mesh zone is formed in the reticulum of H. Mueller, the cells in this zone are still higher (40 to 60  $\mu$ ) and the roll is thereby heightened.

The inner ends of the cells show a form varying much with the direction of the cells; the inner surface of the whole layer is not always smooth, and frequently shows irregular, tooth-like projections (Pl. VII, 4). According to Addario (3), the inner ends of the cells go over into finely striated granular, pointed processes, 2 to 3 times as long as the cell itself, and broaden out upon the inner surface of the ciliary epithelium, partly in the direction of the corona, partly toward the *ora serrata*.

The union between the cells here is, moreover, often a loose one; clefts and vesicular spaces are found between the cells, especially in those eyes which show cystoid degeneration of the retina. This spacing up of the ciliary epithelium is apparently analogous to the so-called degeneration of the retina.

Even in the anterior parts of the orbiculus the cells are still cylindrical, although much lower than in the posterior parts, and very unequal in height, for ridges of the *membrana limitans interna ciliaris* (cf. p. 124) are found here and the cells sink down in between them. These ridges occasion irregularities of the ciliary epithelium, because of their increased thickness, especially in the eyes of older persons; indeed, it may come about that the epithelium between two ridges is actually folded (Pl. VII, 5).

When one studies such eyes in meridional section, the ridges come out less plainly; on the other hand, the irregularities of the ciliary epithelium are more difficult to understand: the cell borders disappear for a distance (longitudinal section of a ridge), then the ciliary epithelial cells are piled up on top of each other for a stretch (longitudinal section of a fold). Only transverse sections of the orbiculus give us a clear picture.

Over the crests of the ciliary processes the cells are cubical (12 to 15  $\mu$  broad, 10 to 15  $\mu$  high), and the nuclei are rounded (Pl. VIII, 11; the less pigmented cells).

As one follows the ciliary epithelium still farther toward the iris root, some pigment appears even in the anterior part of the ciliary processes, first in the portion lying outside of the nucleus. The protoplasm itself does not stain at all in this portion; the pigment granules are much scattered. At the same time, this pigmentation is sufficient to make the anterior declivity of the ciliary crests appear notably darker than the posterior part (Pl. IV, 10). In the neighborhood of the iris root the pigmentation



rapidly increases and an enlargement of the cells takes place at the same time (Pl. VIII, 11).

The so-far unpigmented ciliary epithelium thus undergoes a transition into a pigmented epithelium, which is uniform over all parts of the iris and goes over onto this without any line of demarkation. In this way the border between the ciliary epithelium, and the pigment epithelium of the iris does not fall at the root of the iris but somewhat behind it. This is quite without significance for the function of the eye, and in some other respects; its significance lies solely in that it demonstrates *ad oculos* that the pigment epithelium of the iris belongs to the *tunica interna*, that is to say, to the inner layer of the optic vesicle, and not to the outer, as one would be led to believe from its pigment content.

That which was said about the border portions of the retina holds true in an analogous way for the ciliary epithelium; it is often extremely difficult to draw the line between normal relations on the one hand and artefacts and pathologic conditions on the other hand. It is certain that the ciliary epithelium has a greater smoothness and regularity in young eyes than in old. Certain it is, too, that the lens usually shrinks considerably in the hardening fluid (about 1 mm in the equatorial diameter), and that the shrinking causes a greater tension upon the zonula fibers and thereby draws upon the ciliary epithelial cells. Under such circumstances special care is necessary in forming judgment concerning variations in the ciliary epithelium.

#### 8. THE MEMBRANA LIMITANS INTERNA CILIARIS

(Inner glass membrané of the *pars ciliaris retinae*, 184)

(Pl. VIII, 2, 4, 5, *Li*)

A structureless, connected layer is to be made out on the inner surface of the ciliary epithelium, at least in the adult eye; it is plainly differentiated from the protoplasm of the ciliary epithelial cells by its staining reaction and homogeneous structure. This *membrana limitans interna* is probably best looked upon as a cuticular formation of the ciliary epithelium and corresponds in its position to the *membrana limitans interna retinae*. In eyes fixed while still warm, it adjoins the protoplasm of the ciliary epithelium without any intervening space; in cadaver-eyes, however, it is detached from this, and the inner space seems to be filled out with a clear coagulated fluid.

This detachment does not take place along the whole extent of the membrane but in sections, and forms relatively short, often very regular bows or arcades (Pl. VII, 2). In the places where two arcades meet this membrane sinks down in between the epithelial cells in the form of a ridge, and is thereby more firmly fixed.

Such ridges (Pl. VII, 5, *l*) are most plainly developed in the anterior part of the *orbiculus ciliaris* and have here a meridional direction, as comparison of meridional and transverse sections, and especially teased preparations, show. The ridges do not course entirely straight, however, but zig-zag, and often give off short lateral branches at the ends. Yet a regular net-formed union does not come about, as in the reticulum of Heinrich Mueller to which this ridge system has similarity in its relation to the epithelium. Neither the ridges of the *membrana limitans interna ciliaris* nor those of the cuticular lamella project as far as the outer border of this layer.

On the free surface the membrane is very thin, often scarcely measurable; the ridge may, however, attain considerable thickness. In young individuals, of course, the cross-section of such a ridge appears narrow and has parallel sides, and can be very easily overlooked. In older people, however, the cross-section appears distended like a flask and not infrequently shows lobulated branchings. These thickenings of the ridges, apparently increasing with years, call forth irregularities and even foldings of the ciliary epithelium. Each ridge can be considered a fold or duplication of the *membrana limitans interna ciliaris* whose two leaves lie closely opposed and are fused to one another; often one sees a delicate separating line and at times fine zonula fibers lying therein (cf. chap. xii).

Surface preparations of this membrane can only be obtained from fresh eyes, and even then very many cells still cling to the sides of the ridges, so that only a few places give a pure picture of the ridges in such a preparation. I have sketched this appearance (*loc. cit.*, 184; Text Fig. 10). Transverse sections through the orbiculus are the most instructive; meridional sections cut the ridges longitudinally, give only a very indistinct picture and, therefore, easily permit misinterpretations.

Ridges are likewise present in the ciliary valleys, yet their arrangement is less regular. On the crests of the ciliary processes they go over into a circular direction, i.e., they course obliquely over the crests and thereby give rise to an appearance recalling that of the large intestine and its haustra.

The *membrana limitans interna ciliaris* is easily demonstrable in all these places, and, moreover, can be prepared anatomically. In the most posterior portions of the orbiculus, however, it is otherwise; I am in doubt whether or not a special membrane is present here. The ciliary epithelium certainly appears very plainly set off from the vitreous in section, but more than a contour between the two I cannot see. It is not represented by the anatomic preparation which I once considered proof of a connection between the *membrana limitans interna ciliaris* and the *membrana limitans interna retinae* (*loc. cit.*, 184; Text Fig. 9),

because this contained a part of the vitreous base as well. According to Addario (3), it is the superimposed, imbricated, inward prolongations of the ciliary epithelial cells, which give rise to the appearance of a membrane. The ends of these processes would go over into vitreous fibrillae; such a consideration excludes the conception of a border membrane. Wolfrum, on the other hand, holds that there is a delicate basal membrane in this situation.

The *limitans interna retinae* is also at times very indistinct in the neighboring border portions of the retina. I have described a very peculiar proliferation of the Mueller supporting fibers into the vitreous in a case of probable congenital keratoconus (185). As it later developed, Iwanoff had already described and depicted similar changes in the year 1865 (113), and since then I have found this condition indicated in some other eyes. The proliferation does not appear to have a pathologic significance; it only indicates that the delimitation of the supporting tissue of the peripheral portions of the retina from that of the vitreous is a defective one, and the developmental history of the vitreous gives the key to this.

The *limitans interna retinae*, like the *limitans interna ciliaris*, has, therefore, the tendency to fade away toward the most posterior zone of the *orbiculus ciliaris*. Whether it actually does so or not or is only there reduced to a membrane so thin that it vanishes, I leave unsettled. Probably this is not uniform in all eyes and at all ages.

In front the *limitans interna ciliaris* can be followed as far as the ciliary epithelium remains unpigmented, in any case.

Wolfrum (242) will only admit a limitans in those places where no zonula fibers are given off. This is only a logical sequence of his views concerning the relations of the zonula fibers to the ciliary epithelial cells (cf. chap. xii).

## CHAPTER X. THE IRIS

Severed from its connections, the iris forms a circular plate closely resembling a diaphragm, such as one uses in optical instruments; yet, in fact, it is not broadened out into a plane, but forms the mantling surface of the base of a low truncated cone, because the lens presses the central portion forward.

The outer (peripheral) margin of this plate, that united to the ciliary body, is called the **ciliary border** (*margo ciliaris*) or iris root, the circular opening in the middle is called the pupil, and the limiting margin the **pupillary border** (*margo pupillaris*). The pupil does not lie exactly in the center but slightly to the nasal side.



The diameter of the ciliary border (considered as a circle) is the same as that of the cornea (some 12 mm) and is unchanging; the width of the pupil changes very considerably during life, and likewise the breadth of the iris (considered as a ring). In the thickest portions, the iris measures some 0.4 to 0.6 mm, depending, naturally, upon the state of contraction of the pupil. Since, too, the iris thins out appreciably toward both borders, one can only differentiate two surfaces, an anterior and a posterior.

With the exception of the most extreme periphery, the anterior surface of the iris can easily be seen, even during life. This is, indeed, actually covered by sclera only above and below, but, since the cornea magnifies the image of the iris, the outermost periphery is necessarily invisible even upon this ground. One can, therefore, see the anterior surface of the iris in its whole extent only in an anatomic preparation. This can easily be made by tearing the iris away from the ciliary body, for just as occasionally after injuries in life, the dead iris tears away from the ciliary body because this place is the weakest of the whole anterior part of the uveal tract.

An iris prepared free in this way can be spread out flat and studied out under moderate magnification just as it is. Strong magnification cannot, moreover, be made use of, partly because of the thickness of the iris, partly because of the necessity of study by reflected light.

In the study of the iris from in front (Pl. VIII, 1) with the pupil moderately wide, one sees a fine, black-brown seam (*Ps*) at the pupil-border; this breaks up into a chain of little beads under the loop. As readily understood, this seam is best seen in a blue iris, and especially when the lens behind it is clouded.

Out of the often very complicated markings of the anterior surface of the iris there comes first a zig-zag line, located about 1.5 mm from the pupil when it is of middle width. This **angular line** (*Z*), usually called the small circle (or ruffle, Krueckmann, 125), separates the anterior surface into two zones: an inner, the **pupillary zone**, *annulus iridis minor* Merkel (*Pz*), and an outer, the **ciliary zone**, *annulus iridis major* Merkel (*Cz*). The two zones vary in structure and also at times in their color.

The name small circle, the *circulus iridis minor*, really denotes the anastomosing circle lying in this situation in the vessel system of the iris. But that which one sees on the anterior surface of the iris is not the anastomosing circle itself but only contains it. If one wishes to learn the real significance of this border line, those cases must be drawn upon in which remnants of a persistent fetal pupillary membrane are present. One then recognizes that such threads go out from the angular line, bridge over the pupillary zone, and so extend to the lens capsule. The zig-zag line is, therefore, the insertion point of the fetal pupillary membrane (Lohmann, 144), or rather its physiologic remnant.

The pupillary zone as a whole slopes pretty uniformly away from the pupil-border. It carries numerous ridges and trabeculae, which go out from the angular line, and in its neighborhood form a net-form marking,



more radially striated toward the pupillary border. Larger, sharply limited cavities, the **pupillary crypts** ( $k_2$ ), arise by a wide separation of the individual trabeculae which go to make up the net, usually just at the angular line; net-like trabeculae are again united on the floor, or visible only as wavy radial stripes.

As a rule, a crypt appears darker than the neighborhood, partly because the floor is thrown into a shadow by the steep borders, partly because a thinner layer of connective tissue is present and the darker color of the back surface of the iris shimmers through.

In general, the number, size, and position of the crypts is subject to considerable variation. At times isolated crypts lie on the other side of the angular line in the ciliary zone.

When the pupillary zone has an especially delicate structure, one can at times make out the *sphincter pupillae* as a whitish band of about 1 mm in width shimmering through from below, immediately adjoining the pupil-border.

As a rule, the ciliary zone shows a more uniform structure. A marking made by fine, radially wavy stripes dominates here; the blood-vessels of the iris produce this. The striation is seen best in the middle of the ciliary zone. In the neighborhood of the angular line it is often entirely covered over as a result of the more marked development of the anterior connective-tissue layers, and this part is, moreover, also the thickest part of the whole iris. The inner half of the ciliary zone is pretty smooth; in the outer half, on the other hand, one sees the so-called **contraction furrows** ( $f$ ) coursing obliquely over the meridional striations; these are sharply demarkated circular furrows, running concentric with the ciliary border, deepened when the iris is narrowed, and almost eradicated when the iris is broadened. An individual contraction furrow extends over a greater sector of the iris, but never over the whole iris. The furrows are fixed structures like the folds of the skin in the hollow of the hand, and are to be made out even when obscure (as slight deepenings or by another color).

In the very neighborhood of the ciliary border **crypts** again appear (**peripheral, or ciliary crypts**,  $k_1$ ). They are much smaller and shallower than the pupillary ones and form little groups or rows between which the larger branches of the iris vessels and of the nerves course. So the outermost periphery of the iris (the **marginal zone**; Fuchs, 67) again has a net-form structure and a darker coloring.

This zone is usually not visible in the living eye; but anatomic preparations show that it extends to the very ciliary border, and this is thereby broken up into a number of teeth which run from the anterior

surface of the ciliary body to the meshwork of the iris angle. When such a tooth is separated wholly from the substrata and bridges over the iris angle to the meshwork, it becomes an **iris process**. All these extensions of the iris tissue go over into the uveal meshwork (cf. p. 48).

As is well known, the color of the anterior surface of the iris varies greatly, yet in general two types can be distinguished, the light (mostly blue-gray), and the brown iris. The two types are not, however, separated alone by their color, but they differ as well in the relief of the anterior surface; in the blue iris many more details of the deeper layers can be recognized; the radial fibrillation comes out much more markedly, the crypts are more numerous and larger; the contraction furrows, on the other hand, are only to be seen by oblique illumination. The brown iris shows a grosser relief; the ciliary zone is smoother, the crypts are more sparse and smaller, the contraction furrows, on the other hand, are more plain and are visible as clear lines even in a partly obliterated state. When the pupil is narrow, one can also see radial furrows well in the smooth part of the ciliary zone.

The posterior surface of the iris (Pl. VIII, 2) has an almost uniformly dark brown—almost black—color in all cases, and appears smooth to the naked eye. On moderate magnification and a strong focal light, such as sunlight, a fine relief of radial and circular folds comes out.

The radial folds form two systems independent of one another. The one consists of numerous shallow little furrows (*rF*), goes out from the pupil-border, and gradually loses itself about 1 mm away. This furrow system (Schwalbe's contraction folds) bends about the pupil-border onto the anterior surface with the pigment epithelium and produces the crenations of the pigment seam visible from in front, for this notching is nothing more than the optical cross-section (the profile) of the furrow system.

The second system contains fewer but deeper furrows, called **structural furrows** (structural folds, Schwalbe), because they are present in the vessel layer as well. They begin about 1.5 mm from the pupil-border, are narrow and deep at first, then broaden out and flatten down toward the ciliary border (*SF*). Alongside them are still shorter, shallower furrows. The number of well-developed structural furrows is significantly less than the number of ciliary valleys; there are two or three valleys to one structural furrow. The circular furrows (*cF*) are considerably finer than the radial. They are found only in the region of the structural-furrow system, and cross these in very regular arrangement.

At the very ciliary border the pigment ceases somewhat earlier than does the vessel layer, for the torn surface (the iris root) is turned somewhat

backward. The torn edge of the pigment covering also shows a wavy margin, because the ciliary processes are to some extent grown to the back surface of the iris.

The preparation of sections in the three main directions is demanded: for an accurate understanding of the anatomy and histology of the iris. These directions and the pictures corresponding to them are:

(1) The meridional or radial section (Taf. I), i.e., the section in the direction of the iris radius and perpendicular to the surface of the iris, shows a very irregular limitation in front. The various crypts are recognized as interruptions of the most anterior layer of the tissue ( $k_1$ ,  $k_2$ ), the contraction furrows as sharp angular indentations of this layer ( $f$ ); the maximum thickness in the region or neighborhood of the angular line, the gradual slope of the anterior surface toward the pretty sharp border of the pupil, the bending of the posterior pigment covering, and the ending of this layer are seen at the pupil-border. One sees the **sphincter pupillae** stretching out from this border into the stroma of the iris, the firm connective tissue which supports it from behind and unites it with the posterior surface of the iris; one recognizes the more uniform thickness of the ciliary zone and the thinning toward the root of the iris.

When the section falls between two structural furrows, the posterior margin of the iris, as a whole, appears straight as a line; in other cases, it shows a step slightly ciliaryward to the peripheral margin of the *sphincter pupillae*. In the ciliary portion the circular furrows appear as regular crenations of the pigment covering, while this appears smooth toward the pupil-border because the furrows lying here course in the direction of the section.

(2) The section at right angles to the radius may be called the **transverse section**. Yet such a section is strictly a transverse one at only a single point owing to the radial course of most of the structural elements. The farther one goes from this point the more oblique are the elements encountered, and the less clear is the picture. Naturally, the picture varies according to the part of the iris through which the section goes; the lateral portion of such a section always contains the more ciliaryward lying portions.

In general, the transverse section shows a smoother course along the anterior border of the iris; on the other hand, the structural furrows on the back surface come out very plainly; the posterior limitation is a wavy line.

(3) The **surface-section**, i.e., the section parallel to the surface expanse of the iris, presents apparently the least instructive picture, partly because the individual layers of the iris are much too lacking in evenness for the



section not to vary into either the next higher or lower layer. Nevertheless, the surface-section is of great significance for the histology of the iris.

Like the ciliary body, the iris contains portions of the *tunica vasculosa*, the *stratum pigmenti*, and the *tunica interna* (cf. p. 14); yet there is such an intergrowth of these coats in the territory of the iris that a division of the layers of the iris on this basis cannot be carried out.

The arrangement of the layers of the iris is regular only in the middle part of the ciliary zone; therefore the following survey holds true only for this portion, and the beginner will do well to take up the study of the microscopic anatomy of the iris with this portion.

The part of the iris belonging to the *tunica vasculosa* is called the **pars uvealis iridis**. It consists mainly of a continuation of the vessel layer of the ciliary body—the **vessel layer of the iris** (Pl. VIII, 3, G). On the anterior surface, this layer is characterized by the disappearance of the vessels and the preponderance of the cells of the **anterior border layer** (*vG*); on the side of the anterior chamber this is closed off by an **endothelium** which is connected with the endothelium of the trabeculae of the iris angle and thereby with that of the posterior surface of the cornea.

The layers belonging to the *stratum pigmenti* and the *tunica interna*, therefore, the layers of ectodermal origin, have many times been placed together under the name **pars retinalis iridis**, or **pars iridica retinae**. Here, to prevent misunderstanding, they will be designated as the **ectodermal layers of the posterior surface of the iris**. (Compare what was said on p. 13 concerning the conception of the **retina**.)

The continuation of the *stratum pigmenti* grows into an epithelium muscle, the **musculus dilatator pupillae** (*Di*) in the region of the iris; it appears to divide again into two layers, namely, a non-nucleated, membrane-like layer in front (**posterior border lamella**) and a layer of nucleated, pigmented, spindle-form elements behind it (**layer of the pigmented spindle cells**). The continuation of the *tunica interna* is a simple epithelium of densely pigmented cells, the **pigment epithelium** of the iris (*P*).

So, from in front backward the iris may be divided into the following layers:

- |  |   |                          |                               |
|--|---|--------------------------|-------------------------------|
| a) Pars uvealis iridis                               | { | 1. Endothelium           |                               |
|  | { | 2. Anterior border layer |                               |
|  | { | 3. Vessel layer          |                               |
| b) Ectodermal layers of the back surface of the iris | { | 4. Dilatator pupillae    | { a) Posterior border lamella |
|  | { | 5. Pigment epithelium    | { β) Pigmented spindle cells  |

The *sphincter pupillae* and the *clump cells* are also, indeed, of ectodermal origin, although anatomically they are imbedded in the vessel layer of the iris and will be considered after the vessel layer.



*a) The Uveal Portion of the Iris (Pars uvealis iridis)*

## 1. THE ENDOTHELIUM OF THE IRIS

In general, it is true that it has been settled that the anterior surface of the iris is covered by an endothelium, but the descriptions of this layer differ greatly. Aside from the possibility of an imbricated covering of endothelial cells (Arnold, 8), which in and of itself is very improbable, the endothelium is sometimes described as similar to that of Descemet's membrane although made up of smaller cells (Iwanoff, 115), sometimes as a weakly granular membrane possessed of a moderate number of nuclei which can be isolated by maceration in Mueller's fluid (von Michel, 155). Moreover, it is demonstrable only in young individuals, and, in general, with much greater difficulty in the human than in animals (Koganei, 119).

The endothelium of the iris is, indeed, an object very difficult of histologic demonstration. The endothelium practically cannot be demonstrated in sections, because the anterior border layer with its numerous cells and nuclei lies immediately under it. Only when these cells are very densely pigmented, as in dark brown irides, can one recognize nuclei on the surface here and there; these are surrounded by an unpigmented protoplasm. Such cells are probably to be looked upon as endothelial cells, but one must not confound them with wandering cells; they are found much too sparsely to give the impression of a connected cell-layer.

The classical method for the demonstration of cell borders (by silver nitrate) brings out a very complicated system of lines in the normal iris of older people (Pl. VIII, 4); here, larger cell-like fields alternate with numerous very small slender and often poorly demarkated fields. One does not get the impression that the borders form a single layer of flat cells. Other elements than the endothelial cells of the anterior border layer are possibly drawn into the formation of particular portions of the anterior iris surface.

## 2. THE ANTERIOR BORDER LAYER

(The anterior stroma leaf; Krueckmann, 125)

This is only a modification of the iris stroma, yet it differs from this in its greater density, and is of special significance because it has to do with the color of the iris.

It is principally made up of cells between which there are only a very few collagenous fibrillae and numerous nerve-endings, but no blood-vessels.

The cells are chromatophores, like the stroma cells, and usually possess only two or three processes (sometimes more, sometimes less). These processes are often arranged in little bundles, especially in the zone of the contraction furrows, so that a porous appearance is produced in the anterior border layer (Pl. VIII, 5). A net-form union probably exists between them. Through repeated superimposition of such cells and

through the crossing of the processes there arises a very thick plexus, very difficult of solution, and which gradually goes over into the iris stroma behind (inward) by a gradual spacing up of the cell framework and an increasing preponderance of collagenous interstitial substance.

In the middle portions of the iris, where it is quite smooth, the plexus is very uniformly developed in all directions; at the border of the crypts, however, the processes are arranged more parallel to this border.

The pigment, the mass of which varies a great deal, individually, consists of finer and grosser granules. Concerning the endings of the nerve-fibers, which are demonstrable only by the methyl-blue method, see below (p. 134).

The thickness of the anterior border layer varies a great deal in the different portions of the iris. It fails entirely at the entrances of the crypts; only in the places where a pupillary crypt is large and extends obliquely into the stroma has the wall of the crypt facing forward a thick border layer. Furthermore it is very much thinner on the floor of the contraction furrows than in the neighborhood; on this account the contraction furrow can never be completely obliterated. It is thickest on the border of the pupillary and the ciliary zones and thereby obscures the structure of the vessel layer.

The anterior border layer gives the color to the iris, not alone through its pigment content but also its density; blue irides have a delicate border layer and almost unpigmented cells; brown irides have a thick border layer and very heavily pigmented cells.

A complete absence of pigment in the border layer and in the stroma probably occurs only in the newborn and in very young children. These, therefore, at times actually have blue eyes, for the blue color is only due to the fact that a clouded but colorless medium (border layer and stroma) lies in front of a dark background (pigment epithelium). A complete absence of pigment scarcely occurs in the adult, and the blue of such eyes appears dulled, runs into gray, or more rarely into a greenish hue.

This difference also comes out when the color in different sectors of the iris varies. A different color in the two eyes of the same individual (one eye blue, the other brown), *heterochromia iridis*, can up to a certain extent be physiologic and is due to the above-reported state of the border layer; it is, however, also often pathologic, especially when the individual is, in general, of the brunette type. In these cases the blue eyes very easily get iridocyclitis and cataract, and it has been shown anatomically that in such cases the blue color of the iris is only the expression of a chronic disease (atrophy of the iris; Fuchs, 68).

Albinism is a developmental anomaly and, therefore, does not come into consideration here. In passing, it may only be mentioned that it is due to the lack of color of the pigment epithelium. The stroma pigment does not need to fail entirely in such eyes.

## 3. THE VESSEL LAYER

This forms the main mass of the iris. It contains the numerous larger blood-vessels and nerve-plexuses, held together by a very loose delicate stroma.

The blood-vessels of the iris enter the iris root between the peripheric crypts (Pl. VIII, 1) in larger bundles and branch into finer branches as soon as they have passed the zone of these crypts; these pass through the ciliary zone in a radial direction in several layers. They give the ciliary zone its meridional striation. The vessels usually show a corkscrew-like winding, for only in this way can they adapt themselves to the changing states of contraction in the iris tissue. The narrower the pupil the broader the iris, and the blood-vessels must be just so much the more stretched out, and then the meridional section shows longitudinal sections of the vessels almost exclusively. On the other hand, the wider the pupil, the narrower the iris, and just so much closer are the windings of the vessels upon the meridional section; each vessel is then broken up into a series of cross-sections.

In the pupillary portion this course is somewhat changed partly in the formation of anastomoses (smaller circle), partly in the supply of the *sphincter pupillae*; many circular vessels are also to be found here.

All of the vessels of the iris are characterized by a thick adventitia; this consists of a finely fibrillated and therefore almost hyalin-appearing collagenous tissue, the thickness of which often exceeds the diameter of the vessel lumen. The arteries possess a thin muscularis and a very weak intima, which many times does not stain by orcein; the veins have perivascular sheaths (perithelium) bordering immediately upon the endothelium.

According to Leber (138), the arteries of the iris give off a pretty wide-meshed capillary net in the ciliary zone going through the entire thickness of the vessel layer; a special capillary net is found neither on the anterior nor on the posterior surface. The capillary net first becomes narrower at the *sphincter pupillae*. The last ends of the arteries bow over into the veins.

The nerves of the iris likewise advance through the root of the iris in larger trunks and then build a plexus in front of the larger vessels (Pause, 169); often these branches consist of only a few fibers, which, aside from the meridional course, also run obliquely and crosswise. But the nerves can only be followed over longer stretches and, therefore, identified with certainty in teased preparations. Only in such preparations does one get an idea of the richness of the iris in nerves. Nerves are practically not to be recognized in cut sections.



The nerves in the larger trunks and branches are partly medullated, partly non-medullated. The individual branches possess a thick connective-tissue hull (neurilemma), which in this respect is like the adventitia of the blood-vessels. Moreover, the relations of the neighboring stroma cells to the nerves is the same as in the case of the blood-vessels.

The nerve-fibers end partly in the stroma (sensory fibers), partly in the vessels (sympathetic fibers), partly in the *sphincter pupillae*, partly in the dilatator (motor fibers). Yet there is only very little known concerning the nature of the ending in man, for the study encounters enormous difficulties as a whole in the human iris on account of its thickness and richness in pigment.

According to Meyer (153), a sensory net lying immediately under the endothelium goes out of the wide-meshed plexus of the iris nerves in rabbits; furthermore, the motor fibers for the sphincter, which form a net made up of long-strung-out meshes between the muscle-fibers and the vasomotor fibers of the iris vessels and form two plexuses in each artery, one in the adventitia, the other in the muscularis, are also given off by this same plexus. Retzius (179) also demonstrated numerous nerve-fibers in the posterior border lamella. Muench (162), finally, postulates a union of the nerve-fibers and the stroma cells (cf. p. 135).

Opinions concerning the presence of ganglion cells in the iris are divided. Meyer depicts two cells in a human iris which look exactly like ganglion cells, yet no union with nerve-fibers can be made out; I myself have, upon one occasion, but only upon one occasion, seen an unquestionable ganglion cell in the iris. The views of Muench concerning this matter will be given consideration later on (p. 135).

The spaces between the blood-vessels and the nerves are filled out by the iris stroma proper. This is an extremely delicate, loose, collagenous tissue containing the pigmented stroma cells (chromatophores), non-pigmented stroma cells, clump cells, and, finally, sparse wandering cells.

The collagenous intervening tissue (Pl. VII 6, *b*) consists of very delicate and discrete fibrillae of such fineness that only intensive staining, e.g., Mallory's hematoxylin, give a clear picture. The fibrillae are not arranged in bundles. Their course in the middle parts of the iris and in the depths of the vessel layer is meridional. Toward the ciliary border they go over into a fiber plexus and also in the pupillary zone they change the course of their fibers. The intermediary substance is most markedly developed behind the *sphincter pupillae* (cf. p. 137).

Elastic fibers, i.e., fibers which stain with orcein, fail almost entirely in the iris; a few isolated fibers of this nature are found, but only in the peripheral portions; these are apparently radiations of the elastic framework at the insertion of the ciliary muscle into the scleral roll. In



connection with closely compressed collagenous fibrillae they course into the iris in a meridional direction.

According to de Lieto Vollaro (143), elastic fibers are also found in the tissue behind the sphincter, yet so far I have not been able to see these fibers. In any case, the elastic tissue of the iris is very much less in amount than in the other portions of the uveal tract. This is all the more striking because when wounded the iris shows an especial tendency to gap.

The chromatophores are grouped principally about the vessels and the nerves—the adventitia (and especially the neurilemma) of which they invest with their processes. The interstices proper between the vessels are permeated by a very loose framework of stroma cells. This framework is somewhat thicker in the pupillary zone, especially in the neighborhood of the sphincter and at the ciliary border of the dilatator lamella.

Each chromatophore shows a small oval body, which stains well, and an oval nucleus not surrounded by pigment; the processes are slender and long (up to 100  $\mu$ ) and few in number. They unite with those of their neighbors into a plexus. The pigment is finely granular, and for the most part much paler than in the chromatophores of the chorioidea.

With respect to the direction of the cell-processes one can only say that no particular direction rules in the anterior part of the vessel layer, and that a meridional course comes out in the depths. Especially in the very deepest stroma layer immediately in front of the dilatator one encounters very much elongated, bipolar chromatophores with a meridional direction. Finally, one sees divergent stroma cells radiating out from the thickened places in the dilatator lamella at the ciliary border toward the anterior iris surface.

Aside from the chromatophores, non-pigmented stroma cells are also found. These likewise possess processes, yet these are much more delicate and fine. This kind of cells is held to be nerve-cells by Muench (162).

According to this author, there are no transitions between the two kinds of stroma cells. In man the distinction is often difficult—when the chromatophores are little pigmented—yet their processes are larger than are those of the unpigmented stroma cells. In the much more heavily pigmented iris of apes the difference is much more plain.

Muench (160) held, furthermore, as reported above (p. 50), that the chromatophores are muscle cells and states that they are united with nerve-fibers; the latter form a network, the nodal points of which are the above-described unpigmented stroma cells, and either press into the body of the chromatophore or are attached to it by means of conical insertions.

Aside from the chromatophores, characterized by their processes, larger pigment cells are found in the neighborhood of the *sphincter pupillae* and occasionally also in the neighborhood of the ciliary border. They are without processes and therefore rounded; their pigment is made up of large, round, and very dark granules. They have long been known by the name **clump cells** (Koganei, 119) (Pl. VIII, 3, 10, *K*). Their true nature has, however, only recently been made clear by Elschinig and Lauber (55); they are cells displaced out of the ectodermal layers of the posterior surface. This is shown not only by the structure of the pigment but also by its density (it covers the cell-nucleus), and finally by the circumstance that these cells are just as intensely pigmented in blue irides as in brown. These cells have renounced their epithelial nature in only one matter; they have lost the tendency to form closed bands and lie wholly isolated in the stroma. These cells are also to be found in the *sphincter pupillae* and in the connective tissue behind this muscle. The most conclusive proof of their nature is, however, found in those cases in which there is a defect in the sphincter and the cells radiate out from the posterior surface through this into the iris stroma (cf. *loc. cit.*, 55; Pl. XIX, Fig. 1).

The number of wandering cells is very small, at least in the normal iris: these are small, round, sharply contoured cells with homogeneous or weakly granular protoplasm and a small, heavily stained, round or lobulated nucleus. Other forms are probably pathologic, even when no other diseased changes are found in the iris, for the iris is very easily affected in diseases of the other tissues of the eye or body.

In general, the iris stroma is set off from the anterior chamber by the anterior border layer and the endothelium. This delimitation, however, fails in the crypts; the crypts are places in which the aqueous bathes the stroma of the vessel layer. On histologic examination, the peripheral crypts appear as simple defects of the anterior border layer and of the endothelium and in this way a deeper layer of the stroma is exposed; the form of these crypts is, therefore, that of pit-like deepenings.

The larger pupillary crypts are hollowed out of the stroma of the iris, on the other hand; they often stretch out toward the periphery in such a way that the peripheral border of the crypt appears undermined. Many times the entrance to such a crypt is bridged over by free trabeculae (Pl. I shows a cross-section of a trabecula at *k*<sub>2</sub>). Viewed from the front, the floor of such a crypt is not entirely obscured by a border layer and this is only much weaker developed here than on the anterior surface of the iris. According to Fuchs (67), who first studied the histologic relations

in these crypts more accurately, the endothelial covering is interrupted at the crypts and the spaces in the tissue of the iris stroma communicate freely with the anterior chamber. At the same time it is not possible to inject the tissue spaces of the iris from the chamber.

The vessel layer undergoes a special modification in the pupillary zone of the iris by the interposition of the structure which contracts the pupil (*m. sphincter pupillae*). From a developmental standpoint this muscle belongs to the ectodermal layers of the iris, it is true, yet throughout its development it is so completely imbedded in the vessel layer that it can only be treated in connection with the vessel layer in the anatomic description of the iris.

The *sphincter pupillae* (Pl. VIII, 3, *Sph*) forms an annular band some 0.9 mm broad, of which the inner (pupillary) border is entirely closed off by the border of the pigment epithelium (*Ps*). I doubt very much whether, in general, a true connective tissue limitation is present.

The sphincter is made up of bundles which cross each other at very narrow angles and form a framework similar to that in the ciliary muscle. The direction of the bundles is purely circular on the surface of the muscle (concentric with the pupil-border) and parallel with the surface of the pupil. The bundles are thick, the intervening tissue sparse. Toward the back surface the framework is somewhat more loose, the bundles more slender, the intervening tissue richer, the variations from the strictly circular course more marked, and, moreover, bundles are found which course obliquely toward the dilatator lamella or the pigment epithelium (Pl. VIII, 10). The intervening tissue of this part and the connective tissue lying behind the sphincter is especially rich in collagenous fibrillae and, therefore, shows a much denser structure than the rest of the iris stroma; according to de Lieto Vollaro, elastic fibers are also found in it.

As a result, the sphincter shows a well-marked limitation in front on meridional sections but not behind toward the supporting connective tissue. Both layers thicken gradually from the pupil-border toward the ciliary border of the sphincter and attain there a thickness of 0.1 to 0.17 mm.

The bundles of the sphincter consist of smooth muscle-fibers. Possibly they have a shorter, more oval, therefore, less rod-form nucleus, but otherwise they agree completely with those of the usual form. Their protoplasm stains pretty heavily with eosin, ammonia-carmin, indigo-carmin, takes on a yellowish to orange-yellow nuance by Van Gieson's stain, and shows sharp, plain contours, for each fiber is surrounded by



a delicate sheath of connective tissue; myoglia fibrillae are not found in the sphincter fibers (Forsmark, 59).

The connective tissue behind the muscle apparently serves to support it and effects a firmer union between the *dilatator pupillae* and sphincter, on the one side, and with the pupil-border, on the other.

Concerning the union between the sphincter and the *dilatator pupillae*, see the latter.

b) *Ectodermal Layers of the Back Surface of the Iris*

4. OUTER LEAF: *Dilatator pupillae*

The recent embryologic investigations of Grynfeldt (80), in animals, of Heerfordt (88), von Szili, Jr. (216), and Herzog (95), in man, have first made clear the nature and the origin of the *dilatator pupillae* to us: the *dilatator pupillae*, like the sphincter, is an **epithelial muscle**, i.e., its fibers develop out of epithelial cells, and, indeed, out of those of the outer layer of the optic vesicle. But while a complete transition of the epithelial cell into a muscle cell occurs in the *sphincter pupillae*, this takes place in only a part of the cells (its basis) in the *dilatator pupillae*; the head of the cell has an epithelial character and maintains pigmentation.

Therefore, when typically developed, the dilatator element appears as a spindle-form cell with an oval nucleus and a moderately pigmented protoplasm, extended at each end into an unpigmented fiber-like process (Pl. VIII, 7). Since these processes correspond to the cell-basis, they lie at another level (farther forward) than the nucleated head of the cell, and in a cursory look at the section the *dilatator pupillae*, therefore, appears to be made up of two layers: one, a non-nucleated membranous layer in front (posterior border lamella or border membrane of Fuchs, Bruch's or Henle's membrane) and the other, a layer of nucleated pigmented spindle cells (anterior pigment layer of Fuchs, anterior epithelium of Gruenhagen and others).

This description contains much which is not at once to be seen in the preparation but can only be deduced from the whole outcome of the investigation. We have, indeed, made considerable progress in the recognition of the anatomic make-up of the posterior layers of the iris by means of the various methods of bleaching the section, yet owing to the fact that it is scarcely ever possible to isolate the dilatator element completely and intact, phantasy still plays a certain part. In order now to meet the criticism that I have been guided more by phantasy than by the actual circumstances I add a purely anatomic description of the *dilatator pupillae*.



The **posterior border lamella** (Pl. VIII, 8, 9, *hG*) is a layer of some 4  $\mu$  thickness, which does not always show a sharp delimitation, behind at least. On meridional section (Pl. VIII, 8) it appears almost homogeneous or indistinctly striated longitudinally; on surface-section it shows a plain though fine, straight meridional striation; on transverse section (Pl. VIII, 9) it breaks up in very small, rounded or angular fields united into little groups, but forming a continuous layer as a whole; it shows the staining reaction of protoplasm: ammonia-carmin stains it especially densely, Van Gieson stains it orange-yellow; orcein- and resorcin-acid fuchsin stains are negative. From all of this it follows that this layer is made up of straight protoplasmic fibers coursing meridionally and forming a pretty uniform layer not plainly separated into bundles. When typically developed, cell-nuclei are not found in this layer.

Aside from the above-described protoplasmic fibers, the posterior border lamella contains a second kind of fibers, especially characterized by the fact that they stain intensely and electively with iron-hematoxylin. These fibers were first observed by Widmark (237), later more accurately described by Forsmark (59) and at the same time recognized as identical with the constituent portion of the smooth muscle tissue, called myoglia by Benda (19).

The myoglia fibers, according to Benda, lie intra- and extracellular; the same relationship, therefore, exists as in the cells and fibers of the neuroglia. So far as can be recognized in the drawings of Widmark and Forsmark at hand, the myoglia fibers of the dilatator lie almost exclusively between the protoplasmic fibers or on their surface; in part, too, they press down in between the pigmented spindle cells.

Upon meridional section the layer of **pigmented spindle cells** (Pl. VIII, 8, 9, *sp*) is only indistinctly set off against the posterior border lamella, toward the pigment epithelium, however, very sharply. The borders between the cells can scarcely be made out at all. These borders are seen best in depigmented preparations as fine lines running obliquely toward the posterior border lamella and going over into the longitudinal striations of it. Possibly, however, these lines are caused by the myoglia fibers. The nuclei of the spindle cells are long and placed parallel to the border lamella. The protoplasm contains a moderate amount of pigment not covering the nucleus; its granules are throughout of the same size, form, and color as those of the pigment epithelium. The thickness of the entire layer is 8  $\mu$ .

The spindle-form suggested in the meridional section comes out with entire clearness in the surface view (Pl. VIII, 7). Here the cells show a regular spindle form, they are some 7  $\mu$  broad, and approach 60  $\mu$  in length; the nucleus shows the same form as on meridional section, i.e., a breadth of 4 to 6  $\mu$  and a length of something like 14  $\mu$ . The axes of the spindle cells and likewise those of the nucleus have a strictly meridional

direction.<sup>1</sup> The pigment is located principally in the tapering portion of the spindle and in the unstained preparation the whole layer seems to be made up of narrow triangular flecks of pigment.

Finally, upon the transverse section (Pl. VIII, 9) the cells appear small and almost quadrilateral, the nuclei likewise are small and rounded; the lateral borders of the cell are quite as plain as the posterior border of the whole layer. A nucleus is not visible in every cell in very thin sections of this kind, for many spindles are encountered in the tapering portion, and the cross-sections of these are smaller and lower than the portions which contain nuclei. Despite these and other smaller irregularities the transverse section shows that the layer of pigmented spindle cells is a single cell-layer; in other sections one cannot recognize this with such certainty.

That the posterior border lamella and the pigmented spindle cells belong together is indicated in various ways: (1) The two layers are not clearly set off from one another. (2) The direction of the fibers of the posterior border lamella and of those of the spindle cells is exactly the same. (3) It is not possible to separate the two layers from each other. (4) In many cases these two layers cannot be kept apart in the section. According to Grunert (79), this is the case when the eye has been under the effect of eserine—therefore, when the dilatator is relaxed. Then there is only one layer of spindle cells visible between the iris stroma and the pigment epithelium but no border lamella. Grunert, therefore, holds the posterior border layer to be a contraction-appearance of the dilatator. However, one sees this reputed contraction-appearance, i.e., the posterior border lamella, in a perfectly typical way in most eyes when, moreover, these have not been under the effect of atropin, and despite this the pupil (as usual) is pretty small. According to de Lieto Vollaro (142), the dilatator elements are not separated in the fresh state, but fused together into a "myoid plate."

In this manner the *dilatator pupillae* extends along the posterior surface of the vessel layer of the iris from the ciliary border of the sphincter pupillae almost to the root of the iris in an absolutely uniform development and with a strict maintenance of meridional fibrillation. The course and development of its elements change only in the region of the sphincter zone and in the neighborhood of the root of the iris itself.

On the pupil side the dilatator has no sharp border; its elements finally go over into epithelial cells by means of incompletely formed fibers. These transition forms are partly developed fibers (on one side, i.e., cells which carry a process of only one side), therefore, of a clubbed form

---

<sup>1</sup> This description is rather confined to the middle portions of the iris.

(Herzog), or cells with a wholly irregular form and pigmented throughout (Pl. VIII, 10, *Di*). Some 0.2 to 0.3 mm in front of the pupil-border the outer leaf of the optic vesicle again takes on a purely epithelial character; a double-layered pigment epithelium is, therefore, present in this border zone. But the anterior layer of epithelium is not regular here, by any means; some cells are larger, and I have found very much enlarged multinucleated cells in this zone, structures which very much recall to one giant cells. Occasionally attempts at the formation of epithelial muscle cells are also found here.

Throughout the entire sphincter zone and its immediate neighborhood the elements of the dilatator are united to those of the sphincter. The former thereby loses its surface expansion: a bundle of pigmented fibers is separated away from place to place, goes over into a bundle of ordinary muscle-fibers, and in this way into the muscle framework of the sphincter. Such radiations are found at the ciliary border of the sphincter, and on its posterior surface.

The former lie at the pupillary ends of the structural furrows. On account of the fact that the structural furrow reaches pretty deep into the vessel layer the dilatator only needs to continue on from the end of the furrow in its original direction to get to the ciliary border of the sphincter. Such a bundle consists, peripherally, of pigmented dilatator cells, centrally (in the neighborhood of the sphincter) of ordinary smooth muscle-fibers, and, just as the peripheral portion seems to be a branching of the dilatator, so the central portion appears to be a derivative of the sphincter. On surface-section these bundles (Pl. VII, 6, *Sp*) seem to branch off from the sphincter like the spokes of a wheel from the axis, and for this reason this bundle is called the **spoke bundle**. The name Michel's **pigment spur** has been derived from its appearance in meridional section when the pigmented dilatator elements are more prominent (Pl. VIII, 3, *Sp*).

As a rule, the above-described spoke bundle contains the only radially directed smooth muscle-fibers in the iris. In many eyes, however, such radial smooth muscle-fibers appear farther peripheric and then form bands which strengthen the *dilatator pupillae*; these are placed on its anterior surface, i.e., that turned toward the iris stroma. This variation has been more accurately studied by Widmark (237) and Forsmark (59), who would discredit some of the older descriptions of the dilatator (or of the spoke bundle). Forsmark found such strengthening bands in a sixth of his material.

The unions of the *dilatator pupillae* to the posterior surface of the sphincter are notably weaker, but more numerous than the spoke bundles and consist usually of a single or a few fibers. On meridional



section one sees dilatator fibers from place to place; they rise up from the back surface and course through the firm connective tissue to the sphincter in bows with the concavity directed forward (Pl. VIII, 3, *e*). Yet one can seldom follow them this far because they go out of a meridional direction. On transverse section one obtains a variety of pictures: incompletely developed dilatator fibers, which go off in front, and sphincter bundles coursing obliquely backward, also called Fuchs's pigment spur on account of their incomplete pigmentation, are seen in the neighborhood of the border of the pupil (Pl. VIII, 10). Farther away from the pupillary border one sees cross-sections of the dilatator elements in the connective tissue often lying in a circle about the vessels, after the manner in which Fuchs (67) has drawn them.

The dilatator, therefore, appears to go over into the sphincter everywhere or the two muscles together form a closed framework, probably without free endings.

The ciliary border of the *dilatator pupillae* about corresponds to the place where the posterior surface of the iris bends about onto the inner surface of the ciliary body (at the posterior chamber angle), but only approximately so, for the position of this border changes, indeed, from section to section. At its ciliary border the dilatator no longer forms one simple lamella, but there occurs a change in direction of the elements: they become oblique and circular in part, and lie over one another. Only a small portion maintains the meridional direction and from place to place they ray out in the form of small bundles into the tissue of the iris root and toward the anterior surface of the ciliary body; according to Ewing (58), these radiations correspond to the ciliary valleys. The rest of the fibers form arcades and in this way close off the dilatator lamella at the periphery (Pl. VIII, 6). Whether a union with the ciliary muscle exists here, as stated by some authors, is doubtful.

For the demonstration of the ciliary border of the dilatator one must not tear the iris from the ciliary body; one must rather so remove the ciliary body that the immediate environment of the posterior chamber angle remains still in connection with the iris, and carefully brush off the pigment epithelium. If one will then lay the preparation so obtained back surface up, the dilatator cells and their course can be recognized by the peculiar hatched appearance of the pigmentation. The ciliary border of the dilatator is often only incompletely retained on the torn iris. Surface-sections give a no more satisfactory general view of the dilatator, although individual details, e.g., the circular course of the margin, are visible in such sections.

On meridional section (Pl. I) the ciliary border of the dilatator presents itself as a thickening, varying, however, with every section. The arcades come out as cross-sections of the bundles of the spoke cells and



lie for the most part in front of the meridional coursing fibers when the latter are present. The arcades are often widely removed from the posterior surface and completely imbedded in the iris tissue or in the tissue of the iris root. Its position, also, is subject to much variation. As soon as the exclusively meridional direction of the dilatator element ceases, the separation into the posterior border lamella and pigmented spindle cells ceases. The fine unpigmented processes fail in the cells of the border of the dilatator; its spindle-form body is more or less pigmented throughout its entire extent.

It is fundamentally incorrect to think of the appearance of the dilatator as always as typical as depicted. In the first place the structural furrows disturb things, and one should, therefore, make it a rule to use sections for study in which the posterior layers of the iris are cut strictly perpendicular to the surface expanse. Moreover, aside from such hindrances to its recognition, it does not always show the same appearance; the influence of the state of contraction (Grunert) was emphasized above. Finally, it lies in the nature of the affair, in the incompleteness of the differentiation process which the dilatator elements have gone through, so to speak, that one meets different varieties. Remnants of undifferentiated epithelium such as described by Grunert and Szili, and completely developed smooth muscle-fibers represent the extremes of the variations.

It is only in this way that one can understand why the descriptions of the various authors often vary so very much from one another; only in this way is it conceivable that strife lasted so long as to whether there was a dilatator at all, although its existence was unconditionally demanded by physiology and pharmacology. This is not the place to go into the abundant literature of the dilatator; the articles cited in the text contain further references and are adequate to orient the reader concerning the variation of the views. The definition of the term muscle-fiber had a special influence upon this mooted question. So long as only striped and smooth muscles were known opponents of the dilatator had to be, for as a matter of fact a dilatator made up exclusively of such elements does not exist. It was only when the knowledge came that muscle-fibers can develop out of epithelial cells that unanimity concerning the dilatator was possible. Yet even today there are differences in the conceptions which have not been worked out; for instance, Muench (161) endeavors to find the dilatator mainly in the stroma-cell net of the vessel layer.

As already repeatedly stated, an intergrowth of the mesoderm and the ectodermal elements takes place in the development of the iris. Forsmark has set up the view that the degree of differentiation of these ectodermal elements into muscle-fibers depends upon the position into which it has been thrown by development; elements entirely separated from the native soil and wholly imbedded in the iris stroma grow out fully into smooth muscle-fibers (the sphincter and the strengthening band of the dilatator); such as remain *in situ*, on the other hand, i.e., on the surface of the mesoderm, only undergo this differentiation in the basal portion (typical dilatator cells). But, original as this conception is, it can have no general value, for the clump cells are ectodermal elements which have been completely separated from the native soil and have maintained their epithelial structure throughout.

## 5. INNER LEAF: PIGMENT EPITHELIUM OF THE IRIS

This layer has an epithelial character throughout. Its cells are so densely filled with dark-brown, round, gross pigment granules that neither cell borders nor nuclei are visible. It is unconditionally necessary that one study bleached preparations in order to come into a clear visualization of the composition of this layer. One then very easily recognizes the individual cells as elements having a height of 36 to 55  $\mu$ , a breadth of 16 to 25  $\mu$ ; they are prismatic or more pyramidal elements with round nuclei no larger than in other epithelial cells (7  $\mu$ ), and only seem strikingly small in comparison with the size of the cells; they contain one or two nucleoli lying close to the nuclear membrane.

The pigment epithelium seems most regular in a transverse section through the ciliary zone (Pl. VIII, 9, *P*)—a simple layer of uniformly high cells. Meridional sections through this zone show a slight irregularity, because they run at right angles to the circular furrow system (Pl. VIII, 8, *P*). The furrows appear as sharp incisions, the rolls between them as rounded caps; in the neighborhood of the root of the iris the rolls are higher and often project forward a great deal. The cells on the floor of the furrows are low (35  $\mu$ ) and often wedge-form (triangular); in the flatter rolls the cells are simply higher and somewhat pyramidal, i.e., the lateral cell borders diverge toward the inner surface. Indeed, the higher the rolls become, the more marked duplication of the epithelium there is; the highest rolls are outspoken folds of epithelium. The dilatator, however, courses smoothly over all these folds and furrows; the circular furrows of the ciliary zone, therefore, lie only in the pigment epithelium.

The same is true for parts of the radial furrows in the sphincter zone, namely, for those in the immediate neighborhood of the pupil-border (Pl. VIII, 10, *P*). Farther away from the pupil-border the radial furrows also go down into the vessel layer of the iris and the structural furrows of the ciliary zone do the same. In all these furrows the pigment epithelium and the dilatator sink down in to an equal extent.

The pupil-border of the pigment epithelium is the limit of the optic vesicle, the place where the outer leaf of the vesicle turns about into the inner one, or the **transition point**. As a rule, this projects a little over the pupillary limit of the *pars uvealis* and bends about this border a bit toward the front (**physiologic ectropium of the pigment epithelium**; Pl. VIII, 3, *Ps*). For this reason the transition area is visible from in front as a pigment seam (Pl. VIII, 1, *Ps*). Since the outer leaf has a purely epithelial structure in the neighborhood of the transition, the iris

possesses a doubled pigment epithelium in the neighborhood of the pupil-border.

In bleached sections the place of transition itself has the appearance of the apex of an epithelial fold and the cells in question are of wedge shape. As already noted, it is almost in contact with the pupil-border of the sphincter, a permanent indication that the *sphincter pupillae* develops out of the border of the optic vesicle.

Many authors add a *membrana limitans interna* to the description of the pigment epithelium of the iris, similar to that which the ciliary epithelium possesses. I have, indeed, seen an extremely thin colorless membrane on the free surface of the pigment epithelium in many preparations, but it is unusually delicate and cannot be isolated over any considerable expanse.

### c) *Variations in the Appearance of the Iris*

(*Influence of the width of the pupil and individual variations*)

In an organ possessing such great mobility as the iris, the appearance must vary according to the state of contraction of its muscle.

The pupil width may vary between 1.3 and 9 mm during life; the average width is 4 mm. These figures are, however, not taken from the actual pupil, but from the enlarged image which the cornea gives of it. This image is one-eighth larger than the actual pupil in a normally deep chamber of  $3\frac{1}{2}$  mm and the actual pupil lies about 0.54 mm farther forward. The above-given limits, therefore, correspond to an actual pupil width of 1.1 to 8 mm.

According to Albrand and Schroeder (7), the pupil becomes very much widened (8 mm) just before death; then, however, slowly narrows from day to day. Therefore, an average pupil width is usually found in the cadaver. Fixation fluids bring about a slight narrowing of the pupil as a rule; therefore, it comes about that in the hardened cadaver-eye the pupil width is usually only 2 to 3 mm.

It is not possible to fix the pupil at the extreme widths caused by atropin and eserine during life for anatomic study. The effect of these poisons upon the pupil passes off after death or after the enucleation of the eyeball, and the limits between which the pupil can vary in anatomic preparations are 2 and 5.5 mm. The width of the iris (the radius of the iris, i.e., the distance of the ciliary border from the pupillary border) varies between 5 and 3 mm (Pl. VIII, 12, 13).

From this general survey it is evident to what extent we can accurately study the influence of the width of the pupil upon the appearance of the



iris; we can study the changes of the anterior iris surface throughout the full extent of the movement of the pupil, since these observations can be made in the living; in respect to the posterior iris surface and the inner make-up we are dependent upon anatomic preparations.

Yet the posterior iris surface can be studied in the living eye by the method of Hess (100); for the most part, however, we are thrown back upon anatomic preparations for this, and with respect to its inner make-up, therefore, must be satisfied with a lesser play in the width of the pupil.

According to Fuchs (67), the following changes in the anterior surface come into play in the **narrowing** of the pupil: the pigment seam of the border of the pupil becomes broader and its crenation more plain; the pupillary zone is broader, its ridges take on a meridional course, the crypts stretch out into meridional spaces, the angular line becomes more angular. When the sphincter is visible, its width remains the same or increases somewhat; yet the broadening of the sphincter is relatively less than that of the pupil zone, and the angular line, therefore, moves away from the ciliary border of the sphincter. The vessels in the ciliary zone stretch out, the contraction furrows are smoothed out and the border zone comes out partially from behind the corneoscleral border.

On the posterior surface of the iris one notes an appreciable increase of the radial folding at the pupil-border (Hess, 139), while the circular furrow system is almost obliterated as far as to the most peripheral furrows in the neighborhood of the ciliary border.

On cross-section (Pl. VIII, 13) the sphincter is shown to be broader and probably also thicker, and lies more nearly parallel to the posterior surface. The whole pupillary border is more bowed about toward the front; the border of the pigment epithelium covers the pupil-border of the sphincter (ectropium of the pigment epithelium becomes more marked).

In the **widening** of the pupil the pigment seam of the pupillary border becomes narrower or disappears entirely, the pupil zone narrows a great deal, and the anterior or surface of the iris falls abruptly away from the now more prominent angular line toward the pupil-border. The angular line is stretched out and has almost entirely lost its angular form; likewise the crypts are drawn out to oblique clefts. The sphincter has become narrower but not to the same extent as the pupillary zone, for the angular line has mounted up over the sphincter. The vessels in the ciliary zone are more tortuous, the contraction furrows are deeply incised, the border zone has become invisible. The radial foldings on the posterior surface are less marked, the circular ones more marked.

On cross-section the iris seems to be blunt (Pl. VIII, 12), the sphincter appears shorter, narrower, and more obliquely placed, i.e.,



its ciliary border is farther removed from the posterior surface than is the pupillary border. The pigment epithelium has retracted, and does not any longer cover the pupil-border of the sphincter (the ectropium has disappeared).

The dilatator lamella, however, remains straight in all widths of the pupil, it never shows foldings or bowings except where the iris as a whole is bowed or folded, and on this ground alone it is evident that the pupil-dilating principle must lie in this layer. The mesodermal layers of the iris remain behind, decidedly, in the widening of the pupil, and, therefore, apparently only passively follow the pull of the dilatator lamella.

Although the iris has doubled its width in the narrowing of the pupil, its thickness only increases one-third at the most, according to Fuchs. This striking lack of relationship seems an anomaly upon first thought, but is very easily explained by the fact that the thickness of the iris does not depend upon the breadth of the iris, but only upon the extent of the surface expanse. This, however, does not increase in the same ratio as the breadth of the iris.

In Fig. 4 the outer circle represents the fixed periphery of the iris (the ciliary border); its radius may be looked upon as 6 mm. The middle circle has a radius of 3 mm and would signify the maximal width of the pupil in anatomic preparation. In this pupil width of 6 mm the surface of the iris is

$$6^2\pi - 3^2\pi = (36 - 9)\pi = 27\pi.$$

When the pupil is narrowed to 2 mm (inner circle) the surface of the iris amounts to

$$6^2\pi - 1^2\pi = (36 - 1)\pi = 35\pi.$$

In this the breadth of the iris has increased from 3 to 5 mm, i.e., two-thirds; the surface of the iris, however, not quite one-third. The average thickness of the iris must, therefore, increase to this extent, and this corresponds exactly to the observations.

Of course the iris of the normal eye is not completely broadened out into a plane, but this has no essential influence on the relation of the iris surfaces in a narrow and wider pupil.

Finally, in no other part of the eye is individual variability so great as in the iris. It is widely known how much the color of the iris varies, the same holds true of the thickness of the iris, of the relief, of the internal structure. A thorough description of these varieties is impossible, it

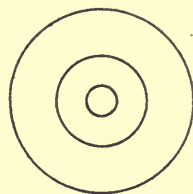


FIG. 4.—Iris surface and pupil widths; magnification 2. Explanation in the text.

would eventuate in an individual description. Moreover, the most important variations have already been reported in the proper place.

As a curiosity only, it should be reported that the variation in color and marking of the iris called forth remark even in antiquity, and finally has been worked out to a system of "eye diagnosis," the rankest nonsense which uncritical and unscientific nature-study in connection with mysticism and speculation could bring forth in the hands of credulous laymen and unscrupulous impostors (206).

## CHAPTER XI. THE VITREOUS (CORPUS VITREUM)

The vitreous as a whole has the form of a sphere flattened sagittally and marked in front by a round della. The posterior half and the lateral part of the surfaces show the mould of the shell of the retina; the della, **patellar fossa** (*fossa patellaris*), is the negative of the posterior surface of the lens, to which it is opposed. The transition from the *fossa patellaris* over into the outer convex surface of the vitreous presents a low wall, on the back of which the posterior half of the *corona ciliaris* lies in undisturbed topographic relations and receives the shallow radial impressions of the ciliary processes.

The vitreous is fixed to the papilla and, less firmly, to the inner surface of the retina, most firmly, however, at the *ora serrata* and to the ciliary epithelium in a zone some 1.5 mm broad immediately adjacent to the *ora serrata*. When the vitreous draws together under the influence of fixation and hardening fluids, when under pathologic relations it is shrunken down to a minimum—it clings at this point. Even severe injuries do not tear away the living vitreous in this situation, and when it is torn from it part of the ciliary epithelium goes with it, and the end of the retina loses its attachment.

Since, furthermore, this zone is of significance in respects other than purely anatomic, it may be justifiable to give it a special name, and I would call it the *base of the vitreous* (Pl. I, *Gb*). (Wolfrum, 242, calls this the zone of origin of the vitreous.)

In front of the base the vitreous borders upon a free space (the posterior chamber); in this region its fixation is less firm, for it is united to the bulb wall (the ciliary body) directly only here and there by delicate processes and mediately by zonula fibers.

Where the vitreous adjoins the lens, a more firm union is again present in the form of a ring of 8 or 9 mm diameter concentric with the lens border; here lies the **ligamentum hyaloideo-capsulare** (Pl. I, *Lhc*) described by Wieger (238).

The portion of the anterior surface of the vitreous lying inside this ring is not grown to the lens but can easily be drawn away as soon as the resistance of the *ligamentum hyaloideo-capsulare* has been overcome. A capillary space lies between it and the lens, the post-lenticular space of Berger (21).

Nasal, close to the axis of the vitreous, courses a canal (**central canal** of Stilling, 212; **canalis hyaloideus** or **Cloquet's canal**). This begins in front of the papilla in a funnel-form widening (*area martegiani*) and courses through the vitreous in an almost sagittal direction. Its width is 1 to 2 mm; the free end sometimes narrows to a point and usually strikes the lens nasal to its posterior pole. According to Bribach (27), the canal only extends 4 mm from the papilla into the vitreous in some eyes, and splits up into a few fine branches.

In order to make the canal visible one must inject it; according to Stilling, this often succeeds merely by simply dropping a colored solution onto the posterior surface of the freed vitreous. According to Schwalbe, one may also obtain a filling of the central canal by an injection beneath the pial sheath of the optic nerve. According to the latest demonstration of Stilling (*Zeitschrift für Augenheilkunde*, Bd. 25, S. 15), a narrow canal is found in the mammalian eye only in the newborn; in the developed human eye, on the other hand, a wider lymph space is present; this is filled out by a soft, tortuously folded substance.

On the other hand, Wolfrum (239) denies the existence of a preformed canal in this situation, and explains the central canal as an artificial product arising by the tearing off of the vitreous from the papilla. In this matter the hypothesis of Stilling has been completely corroborated by the newer investigations of Schaaff (189) and Bribach; the latter has, moreover, published stereoscopic photographs of the injected canal.

---

In the fresh state the vitreous presents a completely transparent entirely colorless mass of jelly-like but firm consistency.

The vitreous exceeds all of the other refracting media of the eye in transparency with the exception of the aqueous. In its optical relations it agrees with the latter and with water; according to Freytag (61), its index of refraction is 1.3334 to 1.3350 (a mean of 1.334). Moreover, the vitreous maintains this transparency a long time after death (even in a weak formalin solution); it merely becomes thready and of lessened consistence.

Even in this condition the microscopic examination does not bring out the least trace of a structure in the vitreous, and so it is conceivable that in earlier periods, when none of the modern histologic aids were available, one did not understand how to begin to study the vitreous,

and that the most varied views concerning its structure were expressed. Indeed, even the existence of such a structure was denied.

That it must, however, possess such is evident from the fact that it has a form and a consistency of its own; its elements do not flow apart over its supporting base, it can be weighed, etc. (H. Virchow, 233). One can press fluid out of it or filter it off from the incised vitreous; it apparently consists, therefore, of a framework of firmer substance and a fluid filling out the meshes of the latter.

But an idea of the arrangement of the elements of the framework can only be obtained from hardened preparations. On account of the delicacy of the structure the sections should not be too thin but very strongly stained. Retzius (180) used rubin for this, I myself have used the phospho-molybdic-acid hematoxylin of Mallory, yet many other stains give good results.

It then develops that the whole framework of the vitreous goes out from the base of the vitreous. Out of the somewhat complicated fibrillation of this portion a thicker layer is first separated off and this extends along the inner surface of the retina backward as the **posterior border layer** (Pl. I, *hG*). Even by low-power magnification one sees a fine striation parallel to the surface and usually slight waviness, which is probably the result of the shrinking of the tissue in the imbedding—a peculiar picture which one does not find in any other tissue of the eye and which I can only compare with the flowing hair of a woman. The posterior border layer is thickest immediately at the *ora serrata*; farther backward it is always thinner, since the innermost layers constantly turn off into the interior of the vitreous. In this way the posterior border layer finally breaks up entirely and, indeed, the border layer is in pretty firm union with the *membrana limitans interna retinae* opposite the entrance of the optic nerve in the *area martegiani*, and when the vitreous is detached as a result of the hardening the limitans follows, as a rule.

That portion of the fibrillation of the base of the vitreous which does not enter the posterior border layer, radiates into the interior of the vitreous, broadening out like a fan, and forms the loose, often shreddy, **body of the vitreous**, along with the branches of the border layers.

As above reported, the anterior border of the base of the vitreous lies about 1.5 mm in front of the *ora serrata*, that is, the more compact mass of the base of the vitreous is inserted as a wedge about this distance away. Yet a very loose framework extends still farther forward to the middle of and even beyond the *orbiculus ciliaris* and then is gradually lost.

About the middle of the *orbiculus ciliaris*, therefore about 2 mm in front of the *ora serrata*, a thickening of the framework of the vitreous



again appears. This often begins with a pretty sharp border in the above-reported looser framework and stretches out from there over the whole of the anterior surface of the vitreous. It separates the vitreous from the posterior chamber and from the lens and is, therefore, called the **anterior border layer** (Pl. I, *vG*). Like the posterior border layer it shows a striation parallel to the surface and is easily thrown into circular folds.

The anterior border layer is much thinner than the posterior and maintains this thickness unchanged up to the border of the lens; it then thins out in the territory of the lens and in the middle of the *patellar fossa* reaches a minimum without wholly dissolving away. As in the posterior border layer, the thinning comes about by a variation off into the body of the innermost layers.

Naturally, the anterior border layer is sharply bordered off from the posterior chamber, but it is also much more sharply set off inward (toward the body of the vitreous) than is the posterior border layer. It therefore gives the impression of a membrane in many eyes in cross-section, especially when it has been compressed by hardening and when its thickness does not exceed that of the lens capsule. This is the reason why many authors speak of a hyaloidea in this section of the vitreous. This hyaloidea is identical with the anterior border layer. Proof of this is furnished by its histologic structure, and this will be discussed later.

The anterior border layer can easily be prepared as a continuous coat, and when laid out flat it presents a circular disk about 18 mm in diameter.

To prepare the anterior border layer one chooses an eye which has been well fixed in Mueller's fluid, halves it at the equator, and carefully removes the loose shreds of the vitreous body from the anterior segment. If one can keep from touching the wall of the eye in doing this the body can be completely removed without injuring the border layer.

One now separates the retina bluntly from the *ora serrata* and carefully removes everything remaining in connection with the retina. A greater resistance is felt first at the posterior border of the *corona ciliaris* and then at the border of the lens, yet this can be overcome by pulling on the already detached portions.

The whole of the tissue detached in this way is stained deeply, incised radially, and laid out flat. Aside from the entire anterior border layer, such a preparation contains the posterior half of the zonula, the base of the vitreous, and the border portion of the retina. A simple pull backward on the base of the vitreous completely separates the border layer from the portion clinging to it.

Prepared free in this way, the anterior border layer shows many circular folds; in the region of the *corona ciliaris* the impressions of the ciliary processes are visible as flat meridional furrows, and between these

there sometimes lie delicate membranous clinging structures (the "*ligamentes cordiformes*" of Campos, 30), which likewise have a meridional course. A portion of the zonula fibers have clung to the border layer (*innermost* zonula fibers; see chap. xii), or have left fine canals impressed on it; individual zonula fibers ray out into the border layer and go over into circular fibers. Where the border layer clings to the lens, a darker ring sometimes comes out and the stump of the *ligamentum hyaloideo-capsulare* clings to it as a delicate circular fringed seam.<sup>1</sup>

The most important difference, however, between the posterior and the anterior border layer is that the posterior border layer is connected with the *membrana limitans interna retinae* throughout, while the anterior border layer is separated from the analogous *membrana limitans interna ciliaris* by the posterior chamber. The separation is not everywhere a complete one, in so far as the posterior chamber is in places crossed by delicate **extensions of the vitreous**.

So the posterior zone of the anterior border layer is nevertheless very much connected with the *membrana limitans interna ciliaris* and, indeed, by means of fine vitreous fibrillae, which course from behind and within, forward and outward, and wind in and out tortuously between the zonula fibers which are numerous, even here.

Another system of vitreous extensions appears in the posterior part of the *corona ciliaris*. Corresponding to each ciliary valley one often sees here a wing-like process directed meridionally, elevating itself out of the anterior border layer from a three-sided prismatic base; it then divides up into very tortuous bands and finally into finest fibrillae, and so ends at the *membrana limitans interna ciliaris*. These processes are easiest seen in transverse sections going through the *corona ciliaris* (Pl. VII, 2, *Lc*), and in them I think I have recognized the **ligamentes cordiformes** described by Campos (30).

A structure united to the lens capsule but not with the *limitans interna ciliaris* and likewise belonging in the category of these extensions of the vitreous is the already reported **ligamentum hyaloideo-capsulare** (Wieger, 238).

Just in front of the place where the anterior border layer reaches the lens capsule, a delicate fibrillar mass (Pl. I, *Lhc*) rises up out of the border layer on a three-sided prismatic base and, diminishing in bulk, extends along through the zonula fibers to the lens capsule. It can be followed as far as the equator of the lens or, indeed, even beyond this to the anterior zonula fibers. Its appearance has been described above

<sup>1</sup> With respect to this and many other details not noted here I refer the reader to my monograph (184).

in the surface preparation of the border layer; the dark ring at times visible at this place does not really come from the ligament itself but from a thickening of the border layer.

I have allowed the named used by Wieger for this structure to remain, because this author is the only one who describes a special substratum structure for the fixation of the vitreous to the lens. If his description differs to any extent from my own, this is mainly due to the difference in technique. The name does not, indeed, fall in with the nomenclature used by me, because I cannot look upon the border layer as the *hyaloidea*, as Wieger does. It only surprises me that no one else has reported this extension of the vitreous; as a matter of fact it is very easily seen after ordinary staining.

It does not need to be proven that this structure has a relationship to the fetal *tunica vasculosa lentis*, for throughout it corresponds in its position to this fetal structure. When, however, I speak of this as a remnant of the vascularized fetal lens capsule, it is not to be taken literally. The ligament does not arise out of the vessels of this capsule; ectodermal vitreous tissue has simply developed along these vessels.

It is made clear from this description, therefore, that the vitreous possesses throughout a thicker rind or border layer. This fails in only two places: one is the *area martegiani*, the entrance to the central canal; the other lies between the base of the vitreous and the margin of the anterior border layer. This latter has the form of a circular cleft and on account of its relation to a portion of the zonula fibers I have called this place the **zonular cleft** (184) (Pl. I, Z). The zonular cleft is, however, not a free open space, but only a place where the delicate framework of the body of the vitreous comes out onto the surface. Whether or not, as Kuschel (153) thinks, it is an efferent for the fluid of the vitreous must first be established by experimental means.

The question whether or not the vitreous has a surrounding membrane of its own, a **hyaloidea**, has long been a matter of contention. In post-mortal or artificial detachment of the vitreous from the retina, in any case, one sees a plain membrane on its inner surface as a rule, but this is nothing more than the *membrana limitans interna retinae* (see p. 79). It is a matter open to discussion whether this covering belongs to the retina or to the vitreous, and in keeping with this, one may call it either the *membrana limitans interna retinae*, or the *hyaloidea* as the case may be; but one thing is certain: aside from this, no other (second) membrane exists between the bases of the Mueller's fibers and the border layer of the vitreous.

---

The vitreous tissue consists of a framework of extremely delicate and soft fibrillae and of a fluid lying in interspaces. Both substances must possess exactly the same refracting capacity, otherwise it would be impossible to account for the complete transparency of the vitreous.

Living fixed cells, blood-vessels, and nerve-fibers are entirely absent in the fully formed vitreous.

Body (nucleus) and rind (border layer) are differentiated particularly by the density of the framework and their texture. The nucleus is best studied in teased preparations: one tears out the loose body shreds with a pincette and stains them a few hours with Mallory's hematoxylin. High power then shows numerous fine fibrillae closely interwoven and forming a tissue having the appearance of a spider-web. The fibrillae are immeasurably fine and extremely soft, and the whole framework can be very easily distorted. Angular granules are found strewn about here and there in this framework, and are considered by Wolfrum (239) to be the end processes of the embryonic radial vitreous fibers (cf. chap. xvi). Moreover, one ordinarily sees a fine granular precipitate upon the fibrillae. This probably arises out of the fluid of the vitreous.

Since such a vitreous shred is drawn out when it is torn away and bruised by the pincette and pressed down flat by the coverslip, such a preparation can give only an approximate idea of the structure of the fibrillae and their number. The actual texture of the body of the vitreous, the interweaving of the fibrillae in all three directions, in short, the framework which it forms, can only be made out in sections; these, however, must not be too thin, because of the delicacy of the tissue. On the other hand, the border layers consist of a large number of very delicate superficially parallel lamellae, and the striation which they show upon cross-section is only the optical cross-section of these lamellar systems and appears the same whether the section is meridional or transverse. The lamellation of the border layer comes out very plainly in surface and teased preparations. In the first place, there is no difficulty in splitting the border layer parallel to the surface, and each of the membranes obtained in this way furthermore shows a large number of lamellae, which one can recognize in microscopic study, especially by the terrace formation.

Each lamella consists of a net of fibrillae. These are much finer even than the fibrillae of the body. They are so fine that the net cannot be completely traced out optically, even with the strongest magnifications, although the lamellae do not appear homogeneous even in moderately high magnifications.

When the individual lamellae are followed from within outward, an increasing fineness of the elements and an increasing density of the net is made out. Yet the most peripheric lamella—that bordering immediately on the posterior chamber—is not entirely homogeneous, although it acts very much like a homogeneous membrane in all of its relations.



The angular granules seem to be entirely absent in the border layers; on the other hand, living cells are found on the outer surface of the posterior border layer and at the vitreous base also. These have been called the **subhyaloid cells** by some authors (Pl. V, 8). They do not form a continuous coat. They are wholly isolated cells separated by fairly wide interspaces, provided with simple or fragmented nuclei and a granular protoplasm. It is relatively seldom that these cells are round; for the most part they show several processes, often possess node-form or vesicular thickenings. When the protoplasm contains larger vesicles with a clear content, they are called **physaliphores**. All these cell forms are to be considered wandering cells; the absence of the closed union and the presence of amoeboid movements, which Iwanoff (113) saw in them in the living vitreous, speak for this.

There are no membranes inside the vitreous. A few authors, as Straub (215), consider the vitreous to be made up of a large number of membranes, but the conception apparently has its origin in unsuitable fixation; in pathologic cases also the fibrillae so press together that a membrane is simulated.

According to Addario (3), the vitreous fibrillae come out of the apices of the inner extensions of the ciliary epithelium (cf. p. 122), and on this basis he considers the posterior zone of the ciliary epithelium to be the matrix of the vitreous. There is much to be said for this view: the firm unions of these parts, the development of the definitive vitreous, the deleterious influence which inflammations of the ciliary body have upon the vitreous; but the transition of the vitreous fibrillae into the ciliary epithelium in the adult eye probably should not be taken so literally; the two kinds of tissue are sharply separated from one another.

Tornatola (224) even conceives of a connection of the vitreous fibrillae with Mueller's supporting fibers of the retina. Whoever believes in the existence of the *membrana limitans interna retinae* cannot agree with the view of Tornatola (cf. p. 79).

## CHAPTER XII. THE ZONULA CILIARIS (Z. ZINNII, LIGAMENTUM SUSPENSORIUM LENTIS)

By the zonula one understands that system of fibers spanned out between the inner surface of the ciliary body on the one side and the equatorial zone of the lens and the anterior border layer of the vitreous on the other side; it mainly fixes the lens in its position and has an effect upon the form of the lens through the function of the ciliary body.

In order to obtain a general view of the zonula one looks at the anterior segment of the eyeball from behind under intensely focalized light and moderate magnification (Pl. IV, 10). One then perceives, even in the anterior portion of the *orbiculus ciliaris*, a fine, silk-like, shiny meridional striation (better seen in hardened eyes than in fresh ones), which extends into the ciliary valleys but leaves the processes free. From the middle of

the corona on, fine, shiny, still very plainly separated fibers come out of the ciliary valleys close to the processes and course over the anterior part of the corona through the circumlental space to the posterior surface of the lens. The fibers are apposed to the side surfaces of the processes, so that they appear to come from them, and each ciliary process is flanked by two rows of zonula fibers. A similar picture is obtained in the view from the front after the removal of the iris: two fiber-bundles appear to run from each ciliary process to the anterior surface of the lens.

The number of the processes is something like 70, so the zonula is divided up into some 140 meridional rows or lamellae (Retzius, 180) apposed to the ridges of the ciliary processes in the circumlental space (the free portion of the zonula).

In order to obtain the zonula in a single preparation, one proceeds as in the preparation of the anterior border layer. When one makes this preparation from the hardened eye only the posterior half of the zonula—that from the *ora serrata* up to the posterior border of the *corona ciliaris*—comes into view. In the fresh eye, on the other hand, the zonula can be prepared as a whole in this way, whereby, of course, the *limitans interna ciliaris* and more or less of the epithelial covering of the ciliary body comes away with it.

In this way one is very easily convinced that the posterior border of the zonula, in so far as it forms a closed fiber layer, lies some 1.5 mm in front of the *ora serrata*, therefore at the anterior border of the base of the vitreous. This border, the **posterior zonula border** of many authors, reproduces the form of the *ora serrata* in such a way that the border of each tooth is correspondingly withdrawn from the corona, and the finer undulations of the border of the retina correspond to the marked zig-zag outline of the posterior border of the zonula. Like the large mesh zone of the reticulum of H. Mueller (p. 118), the posterior border layer is, therefore, a caricature of the *ora serrata*. But this posterior limit of the zonula is not the limit of all the fibers. A minority of the fibers come from points lying still farther back, and, indeed, a good many from the inner surface of the ciliary body in the region of the base of the vitreous, and some few out of the vitreous itself, partly as radiations into the body of the vitreous, partly (on the nasal side) out of the posterior border layer in the neighborhood of the *ora serrata* (Pl. I).

All of these fibers arising out of the vitreous or passing through the base of the vitreous course through the zonular cleft and unite with the main mass springing from the posterior border of the zonula. So many fibers arise out of this that a closed layer of meridionally coursing fibers covering up all the others at once forms and stretches over the whole

*orbiculus ciliaris* in this manner, lending to it the above-reported fine striation.

If one wishes to be further oriented concerning the origin of the zonula fibers and their topographical relations one must turn his attention to sections. Such preparations then show that, with the exception of the whitish crests of the processes, fine zonula fibers also go off from the entire inner surface of the ciliary body as far as the sims and unite with those coming from behind, already grown to larger fibers. So it comes about that, in general, the larger zonula fibers lie inward over the orbiculus, i.e., toward the side of the vitreous, the finer fibers, on the other hand, outward, i.e., on the side of the ciliary epithelium (Pl. VII, 2, 5, Z).

The direction of these fine fibers (auxiliary fibers, Garnier, 72) is, in general, the same as that of the larger ones—from behind and without, forward and inward; over the orbiculus they course almost parallel to its inner surface; toward the front they mount up more and more abruptly, and the most anterior are placed nearly perpendicular to the inner surface of the ciliary body.

Moreover, aside from these **straight coursing fibers**, fibers which **course backward** are found in the anterior part of the orbiculus and the posterior part of the corona; these were called the **orbiculo-ciliary fibers** by Czermak (34), i.e., fibers which course from without and in front backward and inward. There arises thereby a narrow-angled crossing of the fine zonula fibers very well seen in meridional section (Taf. I), for example, just behind the *corona ciliaris*. This double anchorage brings about a stronger fixation of the entire zonula fiber mass at the posterior border of the *corona ciliaris*, and this is the reason why with few exceptions the zonula fibers break away at this place.

Those which do not are relatively weak fibers coursing close to the anterior border layer of the vitreous, and often imbedded in canals in the border layer; for this reason I have called them the **innermost fibers** (posterior zonula bundle of Retzius, 180; central layer of Graf Spee, 210). They come from far back, have no fibers uniting them to the inner surface of the ciliary body, and have nothing to do with the divisions of the latter; they are the only fibers which even occasionally course along the crests of the ciliary processes (Pl. VII, 2, *iz*); they end at the posterior surface of the lens or in the border layer of the vitreous.

The rest of the zonula fibers vary away from the processes and course into the valleys. The whole complex of zonula fibers entering into one ciliary valley thus divides into two halves, which then course farther on along the side surfaces of the processes and finally go over into the free part of the zonula in meridional rows.

The outline of each row forms a triangle, the apex of which lies in the posterior part of the corresponding ciliary valley and its base in the equatorial zone of the lens capsule. The anterior surface of the triangle is straight; the posterior surface describes a bow apposed to the wall about the *fossa patellaris*.

The triangle is, however, by no means uniformly filled out with zonula fibers, as O. Schultze (197) states, but the fibers are massed toward the anterior and the posterior sides and a much smaller number of fibers course in the middle portion. The anterior fibers are the largest and are inserted in front of the equator of the lens; they form the **main anterior train of fibers** (Topolanski, 222) and the totality of the main anterior train of fibers, in all about 140 rows, forms the **anterior zonular leaf** (Pl. I, *vZ*).

The posterior fibers are finer than the anterior; they unite or cross over with the most anterior ones coming from the corona, and in this way they form a double fan, or a figure similar to a row of tangents to a curve or an evolute (Schoen, 192). These fibers, whose insertion is on the posterior surface of the lens, i.e., lies behind the *equator lentis*, form the **main posterior train of fibers** (Topolanski), and their totality forms the **posterior zonular leaf** (Pl. I, *hZ*).

The middle or equatorial fibers are inserted into the equator of the lens or in the immediate neighborhood of it. They are the weakest of all and least regularly developed (Pl. I, *qZ*).

This description depicts the type or the principle of arrangement of the zonula. It is fundamentally incorrect, however, to expect to find this principle carried out with mathematical accuracy. To begin with, the individual rows are, indeed, strictly meridional; the irregularity of the ciliary processes makes the individual fibers go out of the row, and finally the fibers diverge after their exit from the ciliary bodies in a frontal direction as well, or they branch in this direction.

When one looks at a very thick section—one comprising several ciliary valleys—under weak magnification, it does, indeed, seem as if the zonula fibers uniformly fill out the entire space which the older anatomists called Petit's canal (O. Schultze, 197). But when one carries through a section tangential to the equator, it is at once seen that the cross-sections of zonula fibers are not uniformly distributed through this space, but are at least thicker along the anterior and posterior sides. The study of the insertion zone on the lens leads to the same result (cf. chap. xiii).

No description is able to give with absolute accuracy any intermediate conception between the regularity and irregularity of arrangement which characterizes the organized structure. The one emphasizes the plan of the whole arrangement and



this description then naturally emphasizes the regularity; the other sees only the variations from the rule and for this reason denies any law. The truth lies in the mean between the two extremes.

All of the heretofore described elements of the zonula (and these form by far the greater majority) possess a meridional direction or vary only insignificantly from this direction. Moreover, the majority unite the inner surface of the ciliary body to the equatorial zone of the lens.

Although then, we look upon these as the most important, functionally, and accordingly designate them as the typical zonula fibers, there still remains a minority of fibers having another direction and united with other structures; these we will call **atypical** zonula fibers for short, from which, however, it is not to be understood that they are to be considered of no significance functionally.

To the atypical zonula fibers belong in the first place those coming out of the vitreous and the backward-coursing zonula fibers, which we have already discussed. Here, too, belong the **inter-** and **intraciliary** fibers of Czermak (34), fine fibers uniting two ciliary processes with each other. Furthermore, the short and thick fibers going out of the *corona ciliaris* directed at right angles to the typical fibers and serving for the fixation of these, described by Retzius (180), belong here. But in my opinion these fibers do not unite with the typical fibers, but radiate into the border layer of the vitreous or go over into circular fibers.

For if one makes an anatomic preparation of the border layer of the vitreous in the manner heretofore described and looks at the surface, one sees a varying number of zonula fibers radiate into it (Pl. VIII, 14). One part of these fibers belongs to the innermost zonula fibers (see p. 157); the other part (*k*) consists of shorter or longer stumps, which apparently come from the *corona ciliaris*, for the radiations into the vitreous lie in this region. The individual fibers are thereby broadened out into the form of a narrow triangle and then break up into a large number of fine divergent processes. At times only a part of the fibers radiate into the vitreous layer, and the remainder course on farther to the lens, or one fiber-bundle takes root at two or three places in the vitreous body in this way (*m*). The greater part of the fiber processes very soon lose themselves in the border layer, the other part bends about in a sharp curve into the circular course.

These **circular** zonula fibers (*cZ*) sometimes stretch over a great part of the border layer, always following the *corona ciliaris* or rather the wall which lies around the *fossa patellaris*. The border layer itself is always pretty strongly folded in such places and for this reason one is not able to follow the individual circular zonula fibers over wide stretches. When,

however, two radiations lie close to one another, a few fibers of union can very easily be made out, and it is to be suspected that the most of the circular fibers sooner or later go over again into typical ones, i.e., into meridional-coursing zonula fibers.

The transition of meridional into circular fibers can only be plainly seen in surface preparation of the anterior border layers; the circular fibers themselves may, however, also be seen in meridional sections, for example, when they are numerous and large, for the cross-section of the zonula fibers stand out clearly on account of their size and characteristic appearance in contrast with the finer fibrillation of the border layer itself. They lie in part, certainly, in the border layer and not simply upon it. A strong folding of the border layer indicates the place where circular zonula fibers are to be found (Pl. I, *cZ*). In transverse sections of this region the circular fibers appear cut along their length, even on weak magnification, and stand out thereby from the typical fibers, which are cut across, throughout.

The circular zonula fibers have already been incidentally described by various earlier authors, yet it is doubtful whether or not all these statements relate to man. With the introduction of modern imbedding and section technique they have, however, been forgotten, for it must be that the interciliary fibers of Czermak belong in this category. I have again demonstrated their regular presence and have more accurately described their situation and their course (184).

According to Graf Spee (210), two additional girdles of circular fibers are found, one between the *ora serrata* and the *corona ciliaris* and one at the border of the patellar fossa.

---

The zonula throughout consists of structureless, non-nucleated fibers, clear as glass, which are stiff in comparison with other fibers, i.e., they show no tendency to wavy undulation when they are relaxed, but rather show angular nickings.

The finest fibers are encountered in the posterior border of the zonula and everywhere along the inner surface of the ciliary body. They are much too fine to be accurately measured; they are, however, considerably thicker than the vitreous fibrillae, and in sections are especially differentiated by their taut, straight course. The largest zonula fibers have a thickness of 30 to 40  $\mu$ ; all possible transitions lie between.

The cross-section of a large fiber (Pl. VII, 5, *Z*) shows an irregular form from elevations and constrictions, and these are to be noted as fine longitudinal striae in the longitudinal view. This would show, apparently, that we have in these larger fibers bundles of finer ones, but the constituent parts of such a bundle are so thoroughly fused into one another that neither the lines of separation nor the special cement

substance can be made out. A similar fusion is also found where the zonula fibers cross. The compound nature of the large fibers is shown, too, by the fact that it breaks up into fine fibers at the ends.

These branches are either brush-form, i.e., the fine fibers diverge in all directions, or fan-like, i.e., the fibers diverge out into one plane from a given point, or like a feather, i.e., the fine fibers gradually divide off from the large one. The purest of the two first types are found at the inner (axial) ends, i.e., at the insertion into the lens capsule and the vitreous; the third type appears along the inner surface of the *orbiculus ciliaris*.

If, indeed, the large zonula fibers do not with certainty form a histologic unit it is certainly not possible to distinguish between elementary **fibrillae** and compound **fibers** in an unexceptionable way; one does not know where to draw the line among the multitudinous transitions in size and form on a cross-section.

With respect to the tinctorial relations the zonula fibers agree with the glass membranes (cuticular formations). It follows that a certain affinity for orcein is present. It is a striking fact that they take the Weigart neuroglia stain (Agababow, 5). Yet it is going too far to deduce from this a relationship to neuroglia, for, in my preparations at least, other elements, which have not the least relationship to neuroglia, take this stain as well.

The typical zonula fibers unite with cuticular structures at both ends, in my opinion, with the lens capsule on the one side (cf. chap. xiii), and with the *limitans interna ciliaris* on the other side.

With respect to the first point, i.e., the union with the lens, not the slightest difference of opinion exists. So far as the second point is concerned, i.e., the union with the *limitans interna ciliaris*, there are a number of authors who differ in their views.

Schoen (192) thinks one zonula fibrilla proceeds out of each ciliary epithelial cell. According to Terrien (221), they come out between these cells and take their origin from the glass membrane of the ciliary body (our cuticular lamella, p. 117). Wolfrum (242), finally, claims to have followed the finest extensions of the zonula fibrillae through the protoplasm of the epithelial cells up to the cement ridge between the ciliary epithelium and the pigment epithelium.

It is conceivable that all of the authors who consider that the zonula fibers are given off from the ciliary epithelium do not admit the existence of a *limitans interna ciliaris*, at least in those places where the zonula fibers are given off.

Special relations exist between the ridges which the *limitans interna ciliaris* forms in the anterior part of the orbiculus and the straight- and backward-coursing zonula fibers. On transverse section (Pl. VII, 5), one sees the cross-sections of new fine zonula fibers here and there between the closely apposed leaves of such a ridge, and in other places small rows of zonula fibers lie just over the ridges, out of which they apparently



come, as shown by their oblique course. In these places the zonula fibers certainly do not press into the protoplasm of the ciliary epithelium. They remain keyed in between the leaves of the ridge which incloses them in a fold.

It appears to me highly probable, although I cannot yet prove it, that these fibers pass over the ridges, but do not end in them, i.e., that they are fibers which come from behind and appear on the ridges, describe a flat bow, and come out in front again as straight-coursing fibers.

Nothing can be accurately stated concerning the union of the zonula fibers with the tissue of the vitreous. One can follow such a zonula fiber only a short distance into the tissue of the vitreous, then it disappears; whether or not it goes over into vitreous fibrillae remains unsettled.

The cells occasionally seen upon the zonula fibers have been subjected to very different interpretations. According to my observations, one finds the same cells on the outer surface of the vitreous base as along the posterior border layer. Occasionally such cells are displaced still farther forward onto the zonula fibers. They are all wandering cells. The folds and rolls of the ciliary epithelium may give rise to confusion, as for instance, when, as in older people, the *membrana limitans interna ciliaris* projects forward between the ridges and the meridional section cuts them longitudinally. Perhaps the cell-layer between the ciliary epithelium and the zonula described by Graf Spee (210) belongs in this category. No cells—not even wandering cells—are found in the free part of the zonula.

I have not been able to convince myself of a direct connection between the zonula fibers and the border of the retina or the supporting tissue of the retina, as contended for by Schoen (192).

### CHAPTER XIII. THE LENS (LENS CRYSTALLINA)

The lens has the form of a <sup>yet</sup> biconcave lens with unequal sides and rounded border; accordingly, one differentiates an **anterior** and a **posterior lens surface**, and a lens border or *equator lentis*. The center of the anterior surface is designated as the **anterior lens pole**, that of the posterior surface as the **posterior lens pole**, and the line of union between the two, the **axis of the lens**.

Looked at from in front or behind, the lens has a circular form and a diameter of about 9 mm<sup>r</sup> (Pl. II, 1). This dimension is the frontal or equatorial diameter. The lens border is not entirely smooth, but pro-

<sup>r</sup> All of the measurements and statements, where not expressly otherwise stated, relate to a middle age of life and with the lens focused for distance. Concerning the influence of the age of life upon the lens, see chap. xviii.



vided with rounded or dentate prominences corresponding to the ciliary valleys and apparently arising from the pull of the zonula fibers. It is not a form of hardening effect, for it can be seen in the living lens as well (Magnus, 146; Topolanski, 223). According to Hess (96), they are more marked in atropinized eyes than in eserinizied eyes.

The form of the anterior surface varies only a little from that of the surface of a sphere. At its vertex the radius of curvature is 8.4 to 13.8 mm—an average of 10.64 mm—according to the numerous measurements of Tscherning's (228) students, Auerbach, Saunte, Maklakoff, and others; and, according to the latest measurements of Zeeman (244), the average in emmetropes is 11.05 mm.

The form of the posterior surface is that of a paraboloid with a vertex curvature of 4.6 to 7.5 mm, an average of 5.98 mm. A flat circular furrow (concavity forward) has been found by several authors in the peripheral zone of the posterior surface; Zeeman (243) has found it in the living by the doubling of the image reflected by the posterior lens surface at a distance of 3.5 mm from the optic axis, and von Pflugk (172) in the newborn after fixation of the form of the lens by his freezing method.

From ophthalmometric measurements, the thickness or sagittal diameter of the lens is 2.9 to 5.1 mm, an average of 3.7 mm (Tscherning), an average of 3.76 mm in emmetropes, according to Zeeman. In anatomic study, however, the thickness of the lens will be found greater, and according to the old measurements of Pourfour du Petit, contributed by Tscherning, an average of 4.7 mm—according to Krause, 4.9 mm.

Meridional asymmetry has not heretofore been certainly proven for the lens, yet many things speak for this and, too, for the fact, that the lens possesses a slight degree of meridional asymmetry or in any case acquires it, in later life.

A correct conception of the form and size of the lens can only be obtained by a study of fresh material. All of the fixation and hardening means lead to a considerable shrinking and change of form in the lens. The equatorial diameter shortens about 1 mm, and the anterior surface takes on a stronger curvature.

But the fresh lens also changes its form markedly, and the curvature of the surfaces is lost as soon as it is separated from its connections. The task of fixing the natural form of the lens, i.e., that present in life, is an especially difficult one; von Pflugk thought he had solved this with his freezing method; according to Hess (99), this succeeds only after previous fixation with formalin.

The lens is completely clear and transparent in the fresh state, but, according to Hess (97), it is never entirely without color, and even in youth has a tinge of yellow which always becomes more marked with age.

The union of the lens with its environment is effected by means of two structures: the *zonula ciliaris* unites it with the ciliary body, the

*ligamentum hyaloideo-capsulare* with the vitreous body. The first union is by far the more important one, for even in complete relaxation of the zonula (and still more after it is separated) the lens loses its fixed position and sinks from gravity. Complete dislocation (luxation) of the lens is only possible, however, when the *ligamentum hyaloideo-capsulare* has also been torn.

In histologic respects, three different constituent parts of the lens can be demonstrated. From without inward, they are: the lens capsule, the lens epithelium, and the lens substance. The latter is a product of the epithelium, and, thanks to the never completed growth of the lens, one finds the lens substance in process of formation at every age of life. The histologic peculiarities of this will be described under the heading of "epithelial border."

#### I. THE LENS CAPSULE

(Pl. IX, 3, 4, K)

This is a typical glass membrane, i.e., a structureless, highly refracting, very firm elastic membrane, highly resistant to chemical and pathologic influence, whose wound borders have a marked tendency to roll outward. A lamellar composition is not ordinarily seen, yet a thin superficial lamella often appears in the region of the lens equator; it carries the last extensions of the zonula fibers and has been called the **zonular lamella** by Berger (20), the **pericapsular membrane** by Retzius (180).

The lens capsule forms a closed hull about the lens. Solely upon practical grounds, such as those of operative technique, one differentiates an **anterior capsule**, i.e., that part drawn over the anterior surface, and a **posterior capsule**, the covering of the posterior surface.

The thickness of the lens capsule shows wide variation among individuals and at different ages, for it increases appreciably in thickness with age. But the thickness of the capsule also varies in different zones in the same lens. The table on p. 165 gives a survey of the measurements of this variation.

In general, the anterior capsule and the region of the equator is thicker than the posterior capsule. The minimum thickness lies at the posterior pole under all circumstances.

Since this is constant and easy to be made out, it can be made use of for the orientation of the surfaces of the lens, e.g., anomalies in the position or situation of the lens.

The thickest portions of the capsule form two zones concentric with the equator, one on the anterior, one on the posterior surface. The zone of maximum thickness of the anterior surface lies about 3 mm from the

anterior pole or 1 mm inside (axial to) the insertion girdle of the anterior zonula fibers. The zone of the maximum thickness of the posterior fibers lies still farther peripheralward, somewhat inward from the posterior zonular insertions and the *ligamentum hyaloideo-capsulare*. Not infrequently this maximum exceeds that of the anterior, as for instance, in the child's eye (see No. 1 of the table).

The thickness of the equatorial zone varies much; the measurement given in the table is taken from immediately behind the epithelial border, where a relative minimum lies. In front of and behind this place the capsule is somewhat thicker.

No.	AGE	THICKNESS OF THE LENS CAPSULE IN MU				
		Anterior Pole	Maximum of the Anterior Surface	Equator	Maximum of the Posterior Surface	Posterior Pole
1.....	14 days	6	8	3	18	2.5
2.....	2.5 years	8	12	7	18	2
3.....	7 "	8	13	9	17	2
4.....	9 "	8	15	8	22	2
5.....	15 "	9	14	14	23	3
6.....	19 "	12	23	17	26	3
7.....	23 "	11	18	14	21	3
8.....	26 "	10	18	10	17	3
9.....	32 "	12	16	16	21	2.3
10.....	35 "	14	21	17	23	4
11.....	36 "	9	21	16	22	3.4
12.....	40 "	16	22	16	18	3
13.....	41 "	11	18	18	23	3
14.....	48 "	11	22	15	28	3.4
15.....	53 "	14	25	16	23	3
16.....	56 "	18	23	14	16	3
17.....	71 "	14	21	9	9	2.3

The greatest interest attaches to the zones of the maxima. The anterior maximum corresponds to that place in which Tscherning (227) found a flattening of the anterior lens surface in accommodation; the posterior maximum corresponds to that place in which Zeeman (243) and von Pflugk (172) have seen concavities. Both maxima lie somewhat axial to the insertions of the zonula fibers, but they are not brought about by these, for at the very places of insertion the thickness of the capsule is less.

The insertion of the zonula fibers follows a zone concentric with the equator and inclosing it. The anterior zonula fibers reach much farther over onto the anterior than do the posterior zonula fibers onto the posterior surface. As a result, the equator does not lie in the center of this zone but it divides it somewhat in the relation of 3 to 2 (Pl. I). Measured along the surface, the whole insertion zone is about 2 mm broad; measured along a chord, 1.3 to 1.9 mm. depending upon the degree of rounding of

the lens border; its posterior border coincides almost exactly with the insertion of the *ligamentum hyaloideo-capsulare* into the lens capsule.

The angle at which the zonula fibers are inserted into the lens capsule varies between  $0^\circ$  and  $90^\circ$ , for the most anterior and posterior fibers approach the lens capsule in a tangential direction, the middle ones at right angles; the fibers lying in between show an angle of insertion increasing as they approach the equator. The zonula fibers are broken up first upon the lens capsule into the last finest extensions (in so far as this has not already occurred in the free portion), and then continue a stretch farther on over the capsule in a meridional direction (Pl. IX, 1). Especially is this true of the tangentially inserted fibers, i.e., those lying at the borders of the insertion territory (they are inserted with band-like expansions); their expanse reaches about 0.4 mm farther forward beyond the margins of the insertion zone.

The middle zonula fibers (*qZ*) divide previously into brushes of finest fibers, which course without further subdivision to the surface of the capsule and then go partly forward, partly backward.

The extensions of the zonula fibers remain on the surface of the lens capsule throughout, as can best be seen in equatorial sections; zonula fiber extensions, which show varying size upon cross-section, lie only upon the outer surface of the lens capsule. On surface view they show a meridional striation, which is not wholly uniform, i.e., it is made up of larger and smaller elements; this is due to the fact that the border fibers extend beyond the limits of the insertion zone. In general, they extend over a girdle 2.7 mm broad (measured along the surface). The borders of this girdle are circles concentric with the equator (parallel circles); this is especially plain on the anterior lens surface on account of the uniform length of the zonula fiber extensions (*vZ*). When, however, one observes the actual points of insertion of the zonula fibers, and, therefore, excludes the extensions coursing over the surface of the lens capsule, there appears a girdle of measurable breadth and not mathematical lines, as stated by Schoen (160), although marked individual variations are shown; if one takes into consideration only the fibers lying on the surface of the whole fiber mass the insertions form very wavy lines, especially on the posterior surface (*hZ*). This alternating projection and retraction of the most superficial fibers is probably the reason why the older anatomists conceived of the zonula as a ruffled, folded membrane.

On the inner surface of the posterior capsule one not infrequently sees a system of lines which inclose polygonal cell-like fields; these are the impressions of the bases of the lens fibers in a thin layer of coagulated fluid, which is secreted as a post-mortal appearance between the lens substance and the lens capsule.



## 2. THE LENS EPITHELIUM

This extends beneath the lens capsule over the whole anterior surface of the lens up to the equator (and sometimes a short distance beyond it).

This epithelium is disposed in two biologically different zones: the one, covering over the anterior lens surface, has no relation to the formation of lens fibers and even under pathologic conditions is not capable of forming such (its pathologic product is the capsular cataract); yet it plays a significant part in the nutrition of the lens and its insult leads to a clouding of the lens substance. On the other hand, the narrow seam of the epithelium, which lies at the equator of the lens, the **epithelial border**, furnishes the lens fibers and thereby cares for the growth of the lens; this growth continues throughout the whole of life, although, indeed, with gradually decreasing intensity.

## a) The Epithelium of the Anterior Lens Surface

In the neighborhood of the anterior pole these cells are 11 to 17  $\mu$  broad and 5 to 8  $\mu$  high; the nuclei are round in surface view and have a diameter of 7  $\mu$  (Pl. IX, 2); in cross-section they are elliptical. The arrangement of the cells is not a regular one and as a result the form of the cells is not regular. In a fresh state the cell borders appear as fine sharp lines whose position and course change with varying focus, i.e., the lateral separating surfaces do not lie at right angles to the capsule but are bowed. This comes out more clearly when the epithelium is impregnated with silver (Brabaschew, 15), and then one sees two systems of separating lines which do not coincide. Spaces are not infrequently found between the cells, and the portions connected are drawn out into bridges between the cells, and the individual cells take on a more or less stellate form (Hosch, 106). This latter appearance is apparently a result of the shrinking of the cell, probably coming about through various influences; possibly, too, it occurs during life.

Farther toward the periphery the arrangement remains the same, but the cells are notably smaller (8 to 12  $\mu$  in surface expanse) and higher (9 to 15  $\mu$ ), i.e., the cells approach the cylindrical form, and the nuclei back up toward the inner end of the cell and become spherical (Pl. IX, 3—the uppermost cells of the epithelium).

 $\beta$ ) The Epithelial Border and the Lens Vortex (Becker, 18): the Formation of New Lens Fibers

At the epithelial border the heretofore irregularly arranged cells are arranged in meridional rows. It is the service of Rabl (175) to have recognized this linear arrangement as a typical appearance in the mammalian lens and to have brought out its fundamental significance for

the structure of the lens substance. In man, especially, in the adult, these rows are very short and indistinct, probably because the cells grow out so soon from the lens fibers.

When one studies an exactly meridional section of this region (Pl. IX, 3), a broadening of those parts abutting upon the capsule is seen to be the first change in the epithelial cells. The first of these cells (cell 6 from above) takes on, thereby, the form of a truncated pyramid and the cells following become more and more oblique. The obliquity, however, affects only the part of the cells turned toward the capsule at first; the inner parts of the cells (in which the nuclei lie) retain their form. These cells (11 and 12 from above) also take on an oblique direction; the nucleus becomes larger and oval on cross-section. Farther along the inner part of the cell elongates more and more, its obliquity increases and soon exceeds that of the outer part, so that the whole cell acquires a bowing (concavity forward and toward the capsule).

Under further elongation the cell, or rather the young lens fiber, interposes its inner (now its anterior) end between the epithelium and the older part of the lens substance, while the outer end is constantly pushed backward by the subsequently growing cell. The nucleus thereby becomes displaced farther forward, yet in a degree varying a great deal among the different cells.

The nuclei of the epithelium, along with those of the young lens fibers, form a very characteristic figure on meridional section, the peculiarities of which are to be recognized even by moderate magnification; the older authors called it the **nuclear zone**, Becker, the **nuclear bow**. In the epithelium proper of the anterior lens capsule the nuclear row runs parallel to the capsule; in the neighborhood of the epithelial border it is somewhat removed from the capsule and at the very epithelial border bows about to the front in a sharp curve or angle, but at the same time the nuclei fall more and more into this order.

If one calls that end of an epithelial cell turned toward the surface the **free end** (as does Rabl, 175), or the **head** of the cell (in analogy to the basal cells of the corneal epithelium), the end turned toward the mesoderm the **basis** on the other hand, and the line of union between the two the main axis, these poles of the lens epithelium are oriented according to the development as follows: the bases of the cells lie on the lens capsule, the heads of the cells look toward the lens substance, and the main axes are at right angles to the capsule.

In the transition into a lens fiber the epithelial cell grows in the direction of the main axis, but at the same time this undergoes a rotation of  $90^\circ$  with the inner end forward. The bases of all the lens fibers,

therefore, come to lie in the posterior part, the heads in the anterior part of the lens.

By the rotation of the individual elements during development there arises that peculiar figure seen at the epithelial border in a meridional section called by Becker (18) the **lens vortex**.

The expression lens vortex was used by the earlier authors and by Rabl, too, to indicate those figures which arise through the meeting of the fibers in the lens stars. Schwalbe called this figure at the epithelial border the border vortex, for this reason.

The lens vortex forms an inward-projecting roll as a result of the pressing together of the heads of the cells, and the youngest lens fibers, therefore, acquire a concavity forward. Because now each fiber is thinner over this roll than in front of or behind it, the concavity gradually flattens out inward and finally goes over into a definite convexity (corresponding to the curvature of the equatorial portions of the lens). In only one place, at the nucleus, is the young fiber thicker. But these areas are not superimposed and in this way they are smoothed out.

In a strictly meridional section there is a meridional row of epithelial cells with lens fibers coming out of these, and when one follows the direction of the epithelial cells from before backward (the lens fibers in the direction from without inward), one surveys at the same time a whole row of different developmental stages of which the differences in respect to age are nearly uniform. The temporal interval of the developmental process thus corresponds to a juxtaposition in space, and this series has, in general, the character of an arithmetical progression.

The more vigorous the growth of the lens, e.g., in children, the slighter are the differences in age in this series; the more developmental stages, one after another, one has before him, the more gradual is the transition of the epithelium into the lens substance, the more round and long is the nuclear bow. The more indolent the growth, e.g., in old people, the greater are the differences in age in a series, the fewer the developmental stages visible at one time, the sharper is the demarkation of the epithelium from the lens substance, the shorter and more angular is the nuclear bow.

That which proceeds from a meridional row of epithelial cells remains constant in the meridian. The complete lens fibers form rows, therefore, even as do the epithelial cells, and because the individual elements of these rows have significantly elongated in the direction of their main axes, each such row has two dimensions: it becomes a meridional or **radial lamella** (Rabl, 175), the most important textural element of the lens structure.

## 3. THE LENS SUBSTANCE

In middle life the outer layers of the lens substance are very soft and without color (**cortex**), the deeper layers are appreciably harder and more or less of a yellow color (**lens nucleus**). Corresponding to the consistence, the index of refraction also changes; according to Halben (85), it varies between 1.36 (cortex) and 1.4452 (nucleus). Heine (89) gives the nucleus a maximum index of 1.41.

As Halben has shown by his differential refractometer, the transition of the cortex into the nucleus is completed to a certain depth pretty suddenly, i.e., there is a rapid increase of the index of refraction. A transition, indeed, does exist, but this is not as gradual as Matthiessen (148) had earlier conceived it to be. The thickness of the transition zone is so slight that the image reflected by it is quite plain, as Hess (97) and his students have shown.

For example, when one studies the images of the lens with an intense linear light, one perceives a dimmer and weaker picture, it is true, but yet another, alongside of the two well-known Purkinje-Sanson images of the anterior and posterior surfaces (which, according to Hess, should rather be spoken of as the anterior and posterior cortex images); these move in the same direction as the neighboring cortex images and are directed the same as these. They are thrown by the anterior and posterior nuclear borders and carry the names anterior and posterior nuclear images. According to Freytag (60), the anterior becomes constant after the twenty-fourth, the posterior after the thirty-first year of life. With increasing age, these little images increase in luminosity, i.e., the difference in the index of refraction becomes greater.

With the exception of the central portions, the whole lens substance is made up of the characteristic **radial lamellae** of Rabl, described above (Pl. IX, 4). The number of the lamellae on the surface in the adult can be considered as 2,100 to 2,300. With increasing depth the number of lamellae decreases, partly because the individual lamellae sharpen out, partly because neighboring lamellae fuse. In this way the lamellae become more and more indistinct the nearer one approaches the center (Pl. IX, 5); in the center the arrangement of the sagittally coursing fibers is irregular (Rabl's central fibers). The human lens is, in general, characterized by slight regularity in the matter of formation of the lamellae.

Since the formation of new lens fibers progresses about the whole circumference of the lens equator and a new fiber is started at about the same time in each radial lamella, the lens substance acquires a **stratification** conditioned by the difference in the age of the fibers. By maceration, e.g.,



cooking, these layers or lamellar-complexes can be separated from one another: the lens can be split up into leaves parallel to its surface.

Within such a layer the fibers are arranged as follows: The fibers are strictly meridional only in the neighborhood of the equator and only here do they form a uniform layer. As soon as one comes upon the surfaces of the lens in following out the fibers, one perceives a division into sectors, and the lines of separation (sutures) of these sectors form a stellate figure on each lens surface with the center at the pole (the so-called **lens star**; Pl. II, 1).

The lens star is indicated in a normal lens, even during life, on lateral illumination, and often comes out much more plainly in incipient cataracts. In the anatomic preparation, too, the cadaverous appearances, or the effect of fixation fluids, often brings out the lens stars; at other times one can make them visible by a precipitation of silver along the cement lines.

The lens star is not a regular figure. In the adult one can usually count 9 to 12 rays, the intervals between which are unequal; moreover, the points of union between neighboring rays and the pole do not coincide exactly, so that at the pole itself a figure with fewer arms arises, but I have never found the star figure as irregular as Fridenberg (62) draws it.

In each sector the lens fibers first course parallel to the middle line, then bow away from the radii of the star, and therefore meet at the star ray in very blunt angles.

The two stars of the lens (the anterior and the posterior) are, as a rule, so oriented that the rays of the one fall in the interspaces of the other, for which reason the fibers reaching to the pole on the one side cease at the end of a star ray on the other.

In the succeeding layers the figure of the lens star is repeated, yet with increasing depth it becomes more and more simple, until finally it is reduced to a three-rayed star, the anterior one of which has the form of an inverted, and the posterior that of an erect **Y**. One sees exactly these same relations in the lens star when one recurs to an earlier stage in life. For it is a peculiarity of the lens that it always grows by a superimposition of newer layers upon the old. For this reason one finds all the peculiarities which the lens shows in early childhood or in embryonal life at corresponding depths of the adult lens.

The elements of which the lamellae, as well as the layers, are made up are the lens fibers. These are flatly compressed, prismatic, almost band-like cells of considerable length. If there were a complete regularity in arrangement each fiber would be somewhat longer than one-fourth of

a lens meridian; as a result of the alteration of the lens-star, according to Becker, the length actually varies between 7 and 10 mm.

The breadth of the lens fiber, i.e., the dimension at right angles to the length and parallel to the surface, amounts to 8 to 12, an average of 10  $\mu$  in the region of the equator. Near the end of the star ray the fiber gradually broadens out to double this size, and at the same time takes on a bowing. Only those fibers reaching to the pole or to the division-places of the star rays, or their ends, escape this bowing and the broadening of the ends.

The thickness of the fiber, i.e., the dimensions at right angles to the surface, scarcely amounts to 2  $\mu$ ; only at the point where the nucleus lies does it reach 5  $\mu$ .

The cross-section of a lens fiber has the form of an elongated six-sided figure with two long and four short sides; the long sides are parallel to the surface, and the fibers lie upon one another with these sides apposed (Pl. IX, 4). But all these measurements and the form on cross-section only hold true for the young fibers, those arranged regularly in lamellae. The relations of breadth and thickness and the form on cross-sections changes in the depth of the lens substance where the arrangement becomes irregular (Pl. IX, 5).

The young fibers, those lying near the surface, have smooth borders, a well-staining oval nucleus of about 12  $\mu$  in length, 7  $\mu$  in breadth and 4.6  $\mu$  in thickness, and a transparent body in which one can differentiate a firmer covering and tenacious fluid content.

With increasing age, i.e., at a depth of 0.15 mm, the cell-nucleus disappears. It first takes on an almost spherical form, then shrinks to a small, very intensely-staining fragment lying in a cavity of the size of the original nucleus. Finally, these last traces also disappear. In such an old lens fiber a fine serration appears along the edge, the content of the fiber thickens, and the fiber becomes homogeneous.

The union between the lens fibers is effected by a cement substance, more developed on the narrow sides of the fibers than it is on the broad sides; as usual, this can be brought out by silver nitrate. This same substance also appears in the neighborhood of the lens fibers, i.e., in the rays of the lens star, yet a more marked aggregation of homogeneous or drop-like coagulated substance signifies a cadaverous appearance or an artefact in these and in other places.

According to the above statements, the picture of the lens substance has a form differing a great deal according to the method of preparation.

The surface view of the lens substance can only be obtained by a splitting up of several layers. It shows the lens fibers as broad bands, the bowing toward the star rays, the broadening into these, etc.

A section through the lens in the plane of the equator cuts all the lens fibers cross-wise. This is the direction of section which best explains the texture of the lens substance. In Pl. IX, 4, 5 I have depicted a part of such an equatorial section through the lens of a two-weeks-old child; at this age the structure of the lens is still regular and, moreover, the central parts show the fibers well.

In the superficial layers (Pl. IX, 4) one sees the regularly developed Rabl lamellae; they appear as bands directed at right angles to the surface with borders formed by fine zig-zag lines. The cross-sections of the fiber out of which the bands are put together, are exactly superimposed, but they are not all of the same breadth, and often not of the same thickness. The fibers in one lamella are displaced half of the thickness of the fiber in the neighboring lamella, whereby the six-sided form of the cross-section arises. But even in the youngest portions of the lens, irregularities are seen here and there (lower part of the figure). Indeed, the farther one goes from the capsule, the greater become the irregularities, and at a depth of 1.3 mm (from the equator) (Pl. IX, 5) scarcely any indication of the lamellae remains; the form of the cross-section of the lens fiber is, therefore, very irregular.

The meridional section (Pl. IX, 3) shows the longitudinal section picture of the lens, fibers, i.e., narrow, smooth-bordered fibers, which are only a little thicker at the nucleus. It shows, furthermore, the lamellation (stratification) of the lens structure; each layer is thicker in the region of the equator than at the poles; as a result, the radius of curvature of the layers decreases with the depth to a marked extent and corresponds to the depth. The border of the lens stains less intensely, and the fiber contours are, therefore, plainer, the nucleus characterized by a greater affinity for coloring substances, and an indistinct fibrillation. On meridional section, too, one can at times see the cross-section picture of the lens substance, and, indeed, in the neighborhood of the pole; as soon as the section is other than exactly meridional, it may cut across the tapering end of a sector of lens fibers.

Under the influence of hardening fluids, artefacts very easily arise in the lens substance, i.e., spaces filled with a homogeneous fluid, or spheres of coagulated fluid, or a layer of fluid develops between the capsule and the lens substance.

#### CHAPTER XIV. THE CHAMBERS OF THE EYEBALL AND THE TOPOGRAPHY OF THIS REGION

##### a) *The Posterior Chamber*

The posterior chamber is bounded on the one side by the *tunica interna*, and, indeed, by the ciliary epithelium and the pigment epithelium of the iris, on the other side by the anterior border layer of the vitreous up to the *ligamentum hyaloideo-capsulare* and from there on by the surface of the lens. Since the pupil-border of the iris lies upon the lens, the posterior chamber has a limitation which is neither absolute nor fixed on this side. It is not the former, because the pupil-border of the iris is not grown to the lens. Yet it appears from the observations of Ulbrich (229) that no continuous stream of fluid flows from the posterior into the anterior chamber—the difference in pressure is only equalized from time to time,

usually after a change in the width of the pupils. The position of this border also changes as a result of the pupil play.

In this wider sense, the posterior chamber is a space of very complicated form, and for the purposes of description, it is, therefore, advisable to subdivide it into smaller portions.

The most posterior (peripheric) portion of the posterior chamber is that narrow cleft-form space which lies between the inner surface of the *orbiculus ciliaris* and the corresponding portion of the anterior border layer of the vitreous. I (184) have called this space the **orbicular space**, taking this name from Garnier (72), although it is not used by this author in exactly the same sense (Pl. I).

Behind, the orbicular space has no sharp border; its most posterior portion is extensively bridged over by the vitreous fibrillae and very gradually passes over into the body of the vitreous through the zonular cleft (see p. 153). The depth of the orbicular space is very slight at the posterior end, not greater than the thickness of the layer of zonula fibers, i.e., some 0.01 mm. Here the space is in reality wholly filled out by the zonula fibers. In the anterior part, however, the border layer of the vitreous is pressed away by the various projections of the ciliary body, the largest zonula fibers are displaced to the inner smooth wall of the space, and outwardly there remains a relatively free space, traversed only by the fine, straight, and backward-coursing fibers. The space is only present where depressions have arisen between adjacent projections of the ciliary body. In such places the depth of the orbicular space may amount to 0.1 mm.

In front, the orbicular space goes over into the second portion, the system of **ciliary valleys** (Pl. VII, 2). Since the anterior border layer of the vitreous is closely apposed to the posterior halves of the ciliary processes, the corresponding portions of the ciliary bodies are closed off into short canals which only communicate with one another in so far as the vitreous is not grown to the ciliary processes; it only lies close to them.

In the meridional direction these canals measure some 0.8 to 1.0 mm, in the equatorial direction some 0.3 at the posterior end, in front 0.2 mm, while their depth (in a radial direction) increases from behind forward up to something like 0.5 mm. In the middle of the *corona ciliaris* the surface of the vitreous bows away toward the lens, and the anterior halves of the ciliary valleys are thereby transformed into furrows, which in their course open up into the succeeding division of the posterior chamber. The arrangement of the zonula fibers in the ciliary valleys has been described on pp. 157-158. Aside from these, there still remains abundant space for the aqueous.



The third division of the posterior chamber is the **circumlental space**. By this usually one understands only the space between the crests of the ciliary processes and the border of the lens, as a matter of fact, therefore, only a linear dimension, which is, however, of great importance to physiology; yet its constant presence in all ages<sup>1</sup> and in all states of contraction of the ciliary muscle proves it only acts by the mediation of the zonula and in any case possibly of the vitreous (Tscherning, 228).

Considered as an actual space, its borders are: outward, the crests of the ciliary processes; inward, the equatorial portions of the lens; behind, the border layer of the vitreous. In front it really has no border; for the sake of nomenclature alone, one can think of the most anterior zonula fibers as forming this border. Its form is angular. Frontally it measures scarcely 0.5 mm; its expanse in the sagittal direction depends upon the form of the lens border. It is somewhat narrower on the nasal side than upon the temporal.

The fourth division is the **prezonular space** (Czermak, 34), or the **posterior chamber** in the **stricter sense**. This space lies between the posterior surface of the iris, on the one hand, the anterior surface of the lens, the most anterior zonula fibers and the anterior declivities of the ciliary processes, on the other hand. It opens into the circumlental space behind through the spaces between the zonula fibers, at the periphery into the ciliary valleys, axialward through the pupil into the anterior chamber.

The prezonular space has its greatest depth over the crests of the ciliary processes (0.4 to 0.6 mm), from thereon very gradually narrows toward the pupil and disappears a short distance before the pupil-border of the iris is reached. Toward the periphery it narrows rapidly and at the same time forms there a narrow angle. Since, however, the ciliary processes reach a little over onto the posterior surface of the iris, the periphery of the prezonular space has a wavy or cogged form.

The prezonular space is the only division of the posterior chamber which has no zonula fibers and contains only aqueous.

The older anatomists conceived of the zonula as a folded membrane running from the ciliary processes to the lens. Their posterior chamber, therefore did not reach farther than the zonula and corresponded to our prezonular space. The space between the zonula and the vitreous was called Petit's canal. The Petit's canal about coincides with the circumlental space, yet it appears that after certain methods of preparation, e.g., after insufflation of air, sections of the posterior chamber lying still farther backward become drawn into connection with it.

One can inflate the so-called Petit's canal with air because of the surface tension of the surrounding fluid; air is imprisoned, just as one can occasionally observe to his

<sup>1</sup> Exceptionally it disappears in senility (chap. xix).

discomfort in celloidin imbedding, between or beneath the zonula fibers in such a way that one cannot bring it out by mechanical means. Yet as soon as one attempts to inject the postulated canal with a colored aqueous solution, this at once goes over into the prezonular space.

b) *The Anterior Chamber*

Of much simpler form than the posterior chamber, the anterior chamber is bordered in front by the cornea, by the trabeculum of the iris angle at the periphery, and behind by the anterior surface of the iris and that portion of the anterior surface of the lens which at the time is exposed in the pupil.

The frontal diameter of the anterior chamber amounts to 11.3 to 12.4 mm, and is, therefore, about equal to the horizontal diameter or the anterior surface of the cornea; the vertical diameter is as great as the horizontal. The greatest depth of the anterior chamber is found in the middle and corresponds to the pupil (some 2.8 mm).

That which one designates as the chamber depth in the dioptric system of the eye is not, however, this value, but the distance of the anterior surface of the cornea from the anterior surface of the lens, because one can ignore the refraction of the posterior surface of the cornea for optical purposes. The optical chamber depth amounts to about 3.6 mm.

The individual variations of the chamber depth are considerable. Tscherning (228) added together 64 measurements of various authors (the most of them from Maklakoff); the chamber depths, measured ophthalmometrically, vary between 2.2 and 5.1 mm; most frequently these values lie between 3.4 and 4.1 mm.

Toward the periphery the depth of the anterior chamber gradually decreases; yet its minimum does not always lie at the border, but frequently somewhat farther axialward, somewhere between the border zone of the iris and the border of Descemet's membrane. Only in cases in which the iris thins out very gradually toward the ciliary border, is the periphery of the anterior chamber formed by an angle somewhat rounded off at its apex. When, however, as is usually the case, the thickness of the iris is not essentially changed in the region of the ciliary zone, the anterior surface of the iris descends abruptly toward the ciliary body, and then the outermost zone of the anterior chamber or the portion adjacent to the trabeculum (the **iris angle**, or the **chamber bay**) is wider than its entrance from the anterior chamber proper. The shallower the anterior chamber, in and of itself, the more noticeable is this difference, the more plainly does the chamber bay appear bowed backward.

Czermak (36) called attention to the significance of this configuration for the pathology of the eye and in this way established, as it appears to me, the only plausible explanation of the origin of peripheral synechia.

The trabeculum of the iris angle does not form a continuous wall; the numerous spaces in it stand in free communication with the iris angle itself, so that the aqueous can bathe the wall of the Schlemm's canal. This system of spaces is often called Fontana's spaces, because it was held to be an analogue of the **canalis fontanae**.

The reasons which speak against the use of this name have been brought out *in extenso* by Rochon-Duvigneaud (182), and especially by H. Virchow (234). Fontana's canal is bound up in the existence of a genuine "*ligamentum pectinatum*," i.e., in the presence of arrow-like iris processes. These, however, do not occur at all in man; when iris processes are present, they course in the plane with the anterior surface of the iris to the trabeculum. But even these are not present in all eyes, and when they do occur, are so sparse that they cannot be made use of as a limitation of a space. According to Rochon-Duvigneaud the whole iris angle is much more analogous to Fontana's canal.

The anterior chamber possesses an endothelial lining which is continuous over the cornea and through the trabeculum, incomplete, however, over the iris (spaces at the crypts), and in the territory of the pupil it is entirely absent.

#### c) *Content of the Chambers*

Both chambers contain **aqueous**, i.e., a completely clear, colorless, odorless, watery fluid of alkaline reaction. According to Leber (138), the specific gravity in man is 1.0034 to 1.0036, the content in solid substance is 0.82 per cent, including albuminous bodies, yet this is so slight a mass that the aqueous gives no notable coagulum on hardening. In the microscopical preparation, therefore, the chamber appears to be filled out only by the imbedding mass ("empty"). Any other content is, therefore, pathologic.

The index of refraction of the aqueous is 1.33366 to 1.33485, according to Freytag (61), and is, therefore, so very little different from the index of the vitreous that for the purpose of the dioptric system one is accustomed to think of a uniform medium in front of and behind the lens.

#### d) *Topography of the Anterior Segment*

The watery content of the chambers and the physical processes to which this is subjected in the dead eye, as well as the relative slight fixation of many of the parts which border the chambers, brings it about that the normal relations in position are easily disturbed. Therefore we should not look upon the relations found in the completed sections-preparation as corresponding necessarily to those present in life.

The depth of the anterior chamber is most easily extensively changed. Moreover, fluid still filters into Schlemm's canal after death, the eye becomes soft, and the anterior chamber shallow. The diffusion process between the almost pure water of the chamber and the relatively concentrated fixation fluid can also lessen the volume of the anterior



chamber in the eye, enucleated during life, wholly aside from shrinkage processes in the tissues of the eye, so it comes about that we have before us ordinarily an abnormally shallow anterior chamber in the completed preparation.

The decrease of chamber depth expresses itself in a throwing forward of the lens, and this, again, as long as the lens is plastic enough, is combined with a greater vaulting of its anterior surface. The iris thereby approaches the cornea and its conical form is increased.

Still more striking is the influence of the dislocation of the lens upon the form of the circumlental space. The border of the lens is shifted forward almost as much as the anterior lens pole; the ciliary body, on the other hand, remains pretty much in place. The narrower the circumlental space is, the more must it be distorted, the more must the direction of the zonula fibers which pass through it be changed.

A second process which disturbs the topography is the shrinking of the tissue. The changes which the whole process of fixation and hardening bring about in the lens have already been emphasized (p. 163). The shortening of the equatorial diameter of the lens widens the circumlental space and, indeed, to about double its natural size. The zonula fibers become tensely spanned, and this pull must, on its part, be again expressed at the ciliary body. Microscopic distortions at the insertion point of the zonula fibers are the result of hardening, but in no case the result of strained accommodation.

In connection with the shrinkage of the vitreous this pull also leads to the detachment of the ciliary body from the sclera. Since, however, the ciliary body is firmly fastened in front so that the detachment effects a rotation of the whole ciliary body about its *punctum fixum*, the anterior surface must approach more the frontal, the inner surface more the sagittal direction. The chorioidea naturally follows this detachment, at least the anterior portions and the whole perichoroidal space appears unnaturally wide.

But even when one succeeds in preventing all this, the shrinking of the imbedding mass can still change the topographic relations. The only way to get around these artefacts is to make use of fresh material, which one freezes before cutting. But only the grosser anatomic relations can be studied and measured in this way; finer details must be added afterward to the survey picture obtained. Some dimensions can be established during life, e.g., the ophthalmometer is a very desirable and useful means of testing the correctness of topographic relations and especially for adjudicating them.

How great the difference in the position of the parts can be is seen best by a comparison of Text Fig. 1 (p. 3) and Pl. I; Text Fig. 1 shows the normal topographic relations from the above-presented points of view, corrected as necessary; Pl. I, on the other hand, shows the relations of a cadaver-eye, which, in general, has been very well conserved.

Topographic relations can be much more easily reproduced by drawing than by description. It is, therefore, only necessary really to refer to Text Fig. 1; still I would emphasize here certain particularities, partly because of their clinical, partly because of their physiologic importance.

Since the frontal diameter of the anterior chamber is about equal to that of the horizontal diameter of the cornea, the root of the iris lies pretty nearly behind the outer border of the cornea in the horizontal meridian, and the removal of it from this (in the sagittal direction) is 1.6 to 1.8 mm



Above and below, however, the iris root lies considerably farther equatorial. When, therefore, one plunges a knife into the cornea 1 mm from its border, and presses the blade forward parallel to the base of the cornea, the inner wound falls far inside (axial to) the border of Descemet's membrane.

The height of the cornea is 2.6 mm. The plane of the iris root, therefore, lies at least 4.2 mm behind the vertex of the cornea. Since the distance of the lens from the vertex of the cornea is 3.6 mm, the anterior lens pole thus projects at least 0.6 mm in front of the plane of the iris root. The iris, therefore, forms a flat cone, especially in a narrow pupil.

It is a necessary result of this conical form of the iris that the sphincter is pressed against the lens with a certain component. This component is, however, only a small fraction of the whole force of the sphincter, for it is proportional to the sinus of that angle which the meridian of the iris forms with the frontal plane. The steeper the iris is inclined (the narrower the anterior chamber) the greater is this component.

Now, according to the observation of Ulbrich (229), it appears that this component is great enough to prevent for a time the passage of fluid out of the posterior into the anterior chamber. Only in this very limited sense can one speak of a **physiologic seclusion of the pupil**, never, however, in the strict sense in which Hamburger (86) uses this phrase.

The lateral portions of the anterior lens surface (lying behind the iris), the most anterior zonula fibers and the inner surface of the ciliary body (considered as a whole with the exception of the processes) lie almost exactly in one plane, and together form likewise almost a single conical mantle. This conical mantle under certain circumstances, especially in a shallow anterior chamber, may take on a certain concavity from the sines of the ciliary body. Attention was first directed to this concavity by Schoen (192), as an important support for his theory of accommodation, yet he has probably emphasized it unduly, and the preparations depicted by him as conclusive are not free from disturbances of topographic relations.

The apices of the ciliary processes, i.e., the points farthest axialward, lie distinctly in front of the lens equator and the wall about the petellar fossa of the vitreous lies on the posterior halves of the *corona ciliaris*.

It is only because of the magnification produced by the cornea that one cannot see the iris throughout its entire extent during life. For the same reason in a given case, e.g., in iridodialysis, one can see only the apices of the ciliary processes, and when viewed from in front the border of the lens almost coincides with the border of the cornea, although the frontal diameter of the lens is 2 to 3 mm smaller than the horizontal diameter of the cornea. The magnification occasioned by the cornea increases, indeed, with the depth; thus the iris appears magnified one-ninth, the

lens on the other hand, one-fifth, if one conceives of the plane of the lens equator as 5 mm removed from the vertex of the cornea. A structure lying in the focal point of the cornea, e.g., a posterior polar cataract, must appear magnified one-third.

The refraction of the cornea furthermore emphasizes the iris, therefore makes the anterior chamber appear shallower than it actually is. This principle holds true for everything which lies between the anterior surface of the cornea and the focal point of it (more accurately the nodal point of the whole eye).

Of course, the figures given apply only to an average (schematic eye).

## CHAPTER XV. THE VESSELS AND NERVES OF THE EYEBALL

So far as these are constituent parts of the tissue, they have already been mentioned in connection with it. Only a few details concerning the supply of the eyeball with blood-vessels and nerves are added here and the relations of the individual circulatory and innervation districts discussed.

### a) *Blood-Vessels of the Eyeball*

All of the arteries of the eyeball are branches of the *arteria ophthalmica* in the last instance. These course in part directly to the posterior parts of the eyeball and optic nerve, in part to the anterior segment by means of a roundabout way along the eye muscles. The veins empty their blood into the orbital veins, and by means of this partly direct into the *sinus cavernosus*, although anastomoses of the orbital veins with those of the face also occur.

But in the eyeball itself, there can be differentiated two vessel districts, according to Leber (138), whose classical presentation I follow in the main—the retinal or inner, and the ciliary or outer vessel system.

#### I. THE RETINAL SYSTEM

In the adult eye this is represented by the *arteria* and *vena centralis retinae*. Its territory is, especially, the retina, a minor portion of the optic nerve and its sheaths.

The *arteria centralis retinae* enters the optic nerve 7 to 12 mm behind and below the bulb. It first supplies the neighboring portions of the sheaths, then its immediate neighborhood in the optic nerve, in the axis of which it courses farther on to the bulb. Its part in the supply of the optic nerve is, therefore, a minor one; only at the *lamina cribrosa* does it give off a larger number of fine branches. Here and in the intrachorioidal

section of the optic nerve the last capillary anastomoses between the retinal and the ciliary vessel systems are found, but from the inner end of the optic nerve canal on, the retinal is completely separated from the ciliary system, as a rule. This portion of the *arteria centralis retinae* is an end artery in the sense of Cohnheim, and, furthermore, all of the blood carried by the *arteria centralis retinae* is carried away by the *vena centralis retinae*.

The *arteria centralis retinae* divides into an upper and lower main branch (*arteriae papillaris superior et inferiores*) on the inner surface of the papilla and these, again, into a nasal and temporal branch (*arteriae nasales super. et inf., arteriae temporales super. et inf.*) (Pl. VII, 1). Yet even in respect to the branches of the second order there rules a significantly lessened regularity. Under further gable-like divisions the arteries broaden out into the retina mostly in a radial direction; the temporal branches alone course in wide bows above and below the fovea and, converging, send fine branches to the fovea. Finally, as a rule, a few fine branches go directly over the temporal border of the papilla to the fovea.

Concerning the capillary system the reader is referred to p. 82. The last extensions in the neighborhood of the *ora serrata* bow about in loops into the veins. These communications are, indeed, somewhat larger than the capillaries, but they only go back into the same vessel system, and cannot, therefore, functionate as collateral paths.

The distribution of the veins fully corresponds for the most part to that of the arteries; the *vena centralis retinae* accompanies the artery of the same name and, along with it, is united to the central connective-tissue strand (pp. 91, 106) by an extension of the pial sheath; it usually empties directly into the *sinus cavernosus*.

## 2. THE CILIARY SYSTEM

This supplies the rest of the coats of the eyeball, the neighboring portions of the optic nerve and its sheaths, as well as the conjunctiva. The arterial radical of this system divides into the posterior and anterior ciliary arteries; the venous radical is made up of the vortex veins and the anterior ciliary veins. Arteries and veins do not correspond to each other in this system, either their course or yet in circulatory areas, so that the arteries come out more strongly in one place, the veins in another place, especially in the uveal tract.

The number of the posterior ciliary arteries (*art. ciliares posteriores*) amounts to about twenty. They surround the optic nerve and enter the eyeball in its neighborhood and in the region of its posterior pole. At

first they are distributed to the episcleral vessel net (as far as the insertions of the recti muscles), then they pass into the sclera (emissaria; cf. p. 18).

Most of them pass directly out of the sclera into the chorioidea, and become known as the **short posterior ciliary arteries** (*art. cil. post. breves*). The course of these vessels shows great variation; some press into the dural sheath directly at the root and turn toward the optic nerve, others enter at a greater distance; sometimes, too, a short posterior ciliary artery branches off from a long one or, united with it, enters an emissarium.

The short posterior ciliary arteries supply the back half of the uveal tract and the optic nerve; those entering in the neighborhood of the dural sheath form a circle of anastomoses about the optic nerve by means of a few branches—the *circulus arteriosus nervi optici* (p. 25). The neighboring portions of the pial sheath, especially the very rich vessel net of the *lamina cribrosa*, are supplied by this.

Elschnig (52) has called attention to a special variation in the territory of the posterior ciliary arteries. A relatively large artery enters the dural sheath behind the bulb some 3 mm from the end of the inter-vaginal space and, splitting the dural sheath into two leaves, courses in this to the sclera, then goes along the insertion of the dural sheath over into a circular course, and extends about halfway around the circumference of the optic nerve, dividing up into finer branches.

According to Elschnig, the *circulus arteriosus nervi optici* is absent in such eyes; according to my observations (185), however, it is not always, but the branches of the abnormal artery enter the circulus or go directly into the chorioidea. At times, too, there is a larger recurrent branch for the pial sheath and the medullary section of the optic nerve. This variation occurs in about half the eyes; it very easily escapes observation, however, because the vessel does not lie in the horizontal meridian of the papilla.

As already noted, only a capillary connection exists between the retinal and ciliary systems, and this does not reach beyond the level of the chorio-capillaris. This rule, however, is subject to many exceptions.

Anastomoses of larger caliber, visible ophthalmoscopically, are rare and occur most frequently between the veins. A very large, band-like, flattened vein sometimes branches off from the central vein or one of its main branches, courses across through the tissue of the papilla, and disappears beneath the margin of the papilla (**optico-ciliary vein**, Elschnig, 49). Oeller (167) depicts an analogous artery.

The anatomic proof of such an anastomosis was first brought by Kuhnt (131); however, the vessel observed by him could not have been visible



ophthalmoscopically on account of its position behind the *lamina cribrosa*. Elschnig (51) then demonstrated a typical optico-ciliary vein in an eye affected with a neuritic optic-nerve atrophy. It went off from the central vein immediately in front of the *lamina cribrosa* and emptied into the vessel system of the chorioidea. In choked disk and other similar conditions such venous unions have been shown to exist heretofore, yet it is questionable whether these were not pathologic distentions of originally capillary unions.

Much more frequently it happens that a smaller or larger territory of the retina is not supplied by the central artery but by branches of the ciliary vessel system, or that it does not empty its blood into the central vein. Such abnormal vessels are called *cilio-retinal*.

According to Elschnig (50), the **cilio-retinal arteries** are throughout derivatives of the *circulus arteriosus nervi optici*, which either go directly from this through the sclera and the border tissue in an oblique direction into the non-medullated section of the optic nerve, or take the roundabout course through the chorioidea and, therefore, appear as branches of the chorioidal arteries. In both cases they attain the intrachorioidal section of the optic nerve and bend about the border of the chorioidal foramen into the retina, where they are distributed like typical retinal vessels. This bending is visible ophthalmoscopically as a hooked curve, the characteristic index of the cilio-retinal vessel.

**Cilio-retinal** (or, as Elschnig calls them, **retino-ciliary**) **veins** have been anatomically demonstrated in only a single instance (Kuhnt, 131); in this case the vein entered the sclera.

In the older ophthalmoscopic observations, especially those of Nettleship (165), there is much discussion about cilio-retinal veins. It has, however, been emphasized by Elschnig (50) that cilio-retinal veins are very much more rare than cilio-retinal arteries and, independent of Elschnig, I have come to the same conclusion. The well-established retino-ciliary veins are often associated with other similar anomalies, e.g., with optico-ciliary vessels (Elschnig, 50) or with abnormal vortex veins (Czermak, 35).

The cilio-retinal vessels are relatively frequent; Lang and Barrett (133) found them in 16.7 per cent of eyes, I, in 16.4 per cent. Elschnig (50) estimates their frequency at only 7 per cent, but possibly has in mind only the larger vessels.

Most frequent are the small macular vessels (11 per cent); these appear at the temporal border of the papilla, and go directly to the fovea. Vessels of a caliber such that the direction of their current can be determined with certainty ophthalmoscopically, are found in some 6 per cent and are almost exclusively arteries. They often represent those branches of the second or third order which circle about the fovea in a bow. Still larger arteries are rare; they may have the dignity of an *arteria papillaris* and then their place of origin is displaced just as much farther above or below as the vessel is large. Upon one occasion, I observed the complete absence of the central artery and the substitution of two cilio-retinal arteries for this vessel, as has also Bloch (26).

The great majority of the cilio-retinal arteries occur in the temporal half of the circumference of the optic nerve and supply part of the temporal half of the retina. Nasal cilio-retinal arteries are very rare and often associated with anomalies of the papilla.

The **long posterior ciliary arteries** (*art. cil. poster. longae*) are characterized by larger caliber and course in the horizontal meridian; there are, therefore, only two such arteries, one on the nasal, one on the temporal side. The long posterior ciliary arteries pass through their emissaria (p. 18) and the perichorioidal space (p. 51) without giving off branches, press into the ciliary muscle at its posterior border, and divide therein. These branches reach to the anterior surface of the ciliary body and there bend about along the root of the iris, but go over into the circular direction above and below, always coursing in the ciliary body. By union of these branches, as well as through anastomoses which bridge across the divisions, an arterial circle is constructed—the *circulus iridis major*.

The **anterior ciliary arteries** (*art. ciliares anteriores*) come from the straight eye muscles, and accompany each tendon in pairs; the *m. rectus lateralis* is usually accompanied by only one artery. The little trunks pass over the insertion of the tendon in the episcleral tissue with great tortuosity to within a distance of 3 to 4 mm of the cornea; then they divide into superficial and one large perforating branch. The former supply the episcleral vessel net, the border loop net of the cornea, and the bordering zone of the scleral conjunctiva.

The perforating branches pass through the sclera steeply, often at almost a right angle (emissaria; cf. p. 18), and then at once enter the ciliary muscle. It anastomoses there, partly with the long posterior ciliary arteries or its branches, partly with the *circulus iridis major*.

The system formed by the long posterior and the perforating branches of the anterior ciliary arteries supplies the anterior half of the uveal tract, the ciliary muscle first, then the *orbiculus ciliaris*, and the anterior portions of the chorioidea by means of backward-coursing branches (*art. recurrentes*), while the ciliary processes (p. 115) and the iris (p. 133) are supplied by the *circulus iridis major*.

The **vortex veins** (*venae vorticosae*) are the most important of the veins of the ciliary system (cf. pp. 9, 18, 52). They carry away almost all the blood from the uveal tract—the blood of the chorioidea, of the ciliary processes, and of the iris—and, moreover, for the greater part, that of the ciliary muscle. The blood takes another course only in the anterior parts of the ciliary muscle, i.e., through small veins, the **anterior ciliary veins** (*venae ciliares anteriores*), which go from the ciliary body over into the sclera just behind the scleral roll, take up there the drainage of the

Schlemm's canal, and finally attain the episcleral tissue in the neighborhood of the border of the cornea. Here they drain the marginal loop net and the neighboring conjunctival zone, and with these and the episcleral vein form a richly divided net, which, like the vortex veins, empties into the orbital veins.

The posterior portions of the episcleral tissue have their own small veins in the neighborhood of the optic nerve. The neighborhood of the optic nerve is very poor in veins as a result of this, and larger veins do not, in general, normally occur here. The posterior ciliary arteries, which course in the dural sheath, are only occasionally accompanied by large veins (Elschnig, 52).

**Abnormal vortices** have occasionally been observed in myopic eyes at the border of the chorioidal foramen, more rarely in eyes of normal form. Whether or not they are actually more frequent or can only be more easily seen with the ophthalmoscope in such eyes (on account of the atrophy of the pigment epithelium), remains still to be decided. Most of the cases have been observed ophthalmoscopically only. Axenfeld and Yamaschita (12) alone have made a short report of such an anatomic finding.

---

There is not much to be said concerning the vessels of the eye, histologically; their structure corresponds to the type. The muscularis of the arteries is more weakly developed inside the eye than in the orbit; this probably depends upon the fact that the walls of the intraocular vessel have only to bear the difference between the blood pressure and the intraocular pressure. One often comes upon the statement that the muscularis is absent in the arteries (in the retina and iris). This is not correct; smooth muscle-fibers of the wall can be followed even into the finer branches.

The veins are everywhere provided with perivascular sheaths; in general, their wall consists of connective tissue; muscle-fibers appear only in the vortex veins in the neighborhood of the outer surface of the sclera. According to my observations, these are directed crosswise or obliquely.

#### *b) Lymph Passages*

True lymph vessels occur only in the scleral conjunctiva, not, however, in the eyeball itself, nor in the orbit. On the other hand, larger spaces are present, which, among other purposes, serve to a greater or lesser extent for the movement of lymph. In this category belong the inter-vaginal space of the optic nerve, the perichorioidal space, and especially, the posterior and anterior chambers.

In times past one laid very great weight upon the results of injections, and all the pictures which arose with a certain regularity were attributed to preformed lymph channels. But how very little such experiments prove is shown by the example of the cornea, in which the idea of preformed channels for the lymph stream has been entirely given up. Even a splitting of tissue can occur systematically, especially where various component parts border upon one another.

The investigation of the lymph circulation and its paths now demand wholly other methods, which do not fall any more within the province of anatomy and histology; I must, therefore, refer the reader to the proper treatises, especially that of Leber (138), for an extended presentation.

*c) Nerves of the Eye (N. ciliares)*

Heretofore, posterior and anterior ciliary nerves were distinguished. Axenfeld (10) has, however, shown that these so-called anterior ciliary nerves are in most cases really posterior ciliary nerves which only vary from the typical in their course.<sup>1</sup> The posterior ciliary nerves are, therefore, in short, the ciliary nerves. They spring partly from the ganglion ciliare (*n. cil. breves*), partly from the *n. naso-ciliaris* (*n. cil. longi*); the latter carry sensory nerves to the eyeball, the former, a mixture of three kinds of fibers—sensory, motor and sympathetic fibers. The long ciliary nerves also lie in the neighborhood of ganglion ciliare and unite with the short nerves in the neighborhood of the optic nerve inside the sclera.

As a result of this, it is possible to render the eyeball completely insensible by cutting the ciliary nerves at their entrance into the eyeball (*neurotomia optico-ciliaris*), also by injection of cocaine in the region of the ganglion ciliare (method of regional anaesthesia of Elschmig; see Loewenstein, 145).

The number and, corresponding to it, the size of the nerve trunks before their entrance into the sclera seems to be subject to a wide variation. One can usually make out about ten of the larger nerves.

In the orbit the ciliary nerves show, outermost, a connective-tissue coat (neurilemma), after which there follows a second coat of flat protoplasmic cells—several layers in larger nerves—and mixed fine collagenous fibers. According to Gutmann (82), the nerve-fibers are almost exclusively medullated; according to Hahn (84), they are exclusively so; their caliber varies from 20  $\mu$  down to the greatest fineness. Most frequently I find fibers of 7 to 12  $\mu$  thickness, between which the fine fibers lie in small groups. All have nucleated (Schwann) sheaths. The spaces between the nerves are filled out by fine collagenous fibers.

<sup>1</sup> At the most genuine anterior ciliary nerves can occasionally be derived from the *n. naso-ciliaris*.



Furthermore, the ciliary nerves frequently contain ganglion cells in the neighborhood of the sclera, indeed, even in the latter itself, and since these ganglion cells often form little groups one may speak of **accessory episcleral ciliary ganglia** (Axenfeld, 11).

In the neighborhood of the optic nerve one finds many small nerve branches in the sclera (often consisting of only a few fibers); the course of these branches is very irregular. The larger ciliary nerves, however, course in very oblique emissaria (p. 18). One ciliary nerve regularly accompanies each of the long posterior ciliary arteries. While still within the emissarium this gives off a weaker branch, which crosses the ciliary artery, so that the artery at its entrance into the perichorioidal space is accompanied by two nerves (p. 51).

With the entrance into the emissarium the ciliary nerve loses its connective-tissue coat; the cell-coat is also reduced in its further course through the perichorioidal space to a simple layer of flat cells. In the place of them suprachorioidal lamellae appear as coats of the nerves in this space; the nerve itself has an elliptical cross-section.

The ciliary nerves traverse the perichorioidal space in a meridional direction and give off branches to the sclera and to the chorioidea while doing so (p. 51). The scleral branches, however, only partly supply this tunic (p. 25); in addition they bore through the sclera and course to the cornea through the episcleral tissue or the sclera itself. On cursory examination, these branches seem to be anterior ciliary nerves. The intrascleral nerve loops (pp. 18-19), which are occasionally found, can also give rise to the same confusion.

The main mass of the fibers of the ciliary nerves enters the *plexus ciliaris* in the ciliary muscle (p. 114). This supplies the ciliary muscle itself and provides the nerves for the ciliary processes, the iris, and for the deeper layers of the cornea. These latter enter the sclera behind the scleral roll and course by a short route to the cornea. The superficial layers of the cornea are supplied by the perforating branches lying farther backward. Concerning the finer subdivisions of the nerve, the reader is referred to the portion of the tissue concerned.



PART II

THE PHYSIOLOGIC CHANGES OF THE EYEBALL DURING LIFE  
(Development and Senescence)





That which the reader has come to know in Part I is the structure of the eyeball at the height of its development—after the completion of the body growth. Before this period in life there lies the period of development, after it comes the period of senescence. And although some details have already been reported on account of their connection with development and senescence, there yet remains a great deal to say, especially concerning the development, if the conception of the eye in the different periods of life is to be a complete one, if the anatomic structure and the significance of its parts is to be rightly understood.

## CHAPTER XVI. THE EMBRYONAL AND FETAL DEVELOPMENT

So rich a material has now been brought together in the normal charts of Keibel (1116), by the thoroughgoing researches of Seefelder,<sup>1</sup> and many other authors, that we may now consider the developmental history of the **human** eye to have been worked out, in the strict sense of the word. I, myself, have to thank the friendly consideration of the director of the I. Academic Institute of Human Anatomy of Vienna, Professor Jul. Tandler for the opportunity of using the rich collection of the institute to orient myself at least concerning the most important phases of the development of the eye by personal observation.

I have not gone into the details of histogenesis, but refer to the cited literature in this connection. Such a task demands a specialist in embryology, and that I am not. For the same reason I have intentionally avoided still undecided matters. I must also emphasize that the following should be looked upon only as a sketch of the developmental history of the human eye, making pretense to neither originality nor completeness.

Since the estimation of the age of very young embryos is extremely difficult in the human, it is now preferable to give only the greatest length (gr. l.) This is a measurement of the body-axis in the very first stages only, and these scarcely come into consideration in the development of the eye. After the appearance of the neck bend, the greatest length is the distance from the neck to the buttocks (neck-buttocks length), later that from the skull to the buttocks becomes the greatest (skull-buttocks length, SS). In the later stages of fetal life one measures this length or the skull-heel length, i.e., the length of the fetus with outstretched legs (cf. Michaelis, 154). Unfortunately, an accurate notation of the measurement is absent in many statements in which simply the length (l.) appears to be given.

Even in the earliest phases of development one finds considerable individual variations in respect to the time of its appearance. In such cases I have usually taken only the lower limit.

---

<sup>1</sup> The large treatise by Bach and Seefelder, *Atlas of the Developmental History of the Human Eye*, Leipsic, 1911, first began to appear while this work was in press, and could not, therefore, be made use of

Even before the complete delimitation of the medullary canal from the rest of the ectoderm, therefore before the time when there is still an open furrow at the apical end, two grooves, the **optic grooves**, appear on each side of the median line on the floor of this furrow. That which presents itself in the view from behind as a groove appears in the view from the side of the ventral cavity as an evagination, and in cross-section as a fold of the wall of the medullary canal; the cap of this fold abuts on the ectoderm (Pl. IX, 6; copied from Keibel, 116, No. 6, p. 24; Text Fig. 6 a).

This evagination takes on a lateral direction after the closure of the medullary canal and becomes transformed into a vesicular structure (the **primary optic vesicle**) in a gr. l. of 2.5 to 3 mm. This is separated from the medullary canal on the dorsal side by a constriction, the **pedicle of the optic vesicle**; at the same time the medullary canal has widened into the forebrain at its anterior (apical) end. On the ventral side, however, the wall of the optic vesicle goes smoothly over into that of the forebrain. The pedicle of the optic vesicle is, therefore, very short, and the lumen of the optic vesicle stands in wide-open communication with the lumen of the forebrain.

At the same time, several layers of mesoderm have interposed themselves between the ectoderm and the summit of the optic vesicle (Fuchs, *Textbook of Diseases of the Eye*, 12th German ed., Fig. 143; 4th English ed., Fig. 162). The optic vesicle is very poorly separated off from this, for the mesodermal cells enter into many protoplasmic connections with the cells of the wall of the optic vesicle, as well as with the ectoderm (Seefelder, 203).

This mesodermal layer has, however, only a short existence. Cirinzione (33) first demonstrated that this layer disappears with the invagination of the lens. Even at a gr. l. of 3.5 mm (collection of the I. Anatomic Institute of Vienna), the mesodermal cells have been reduced to a few scattered remnants, yet the unions of the ectoderm with the primary optic vesicle remain constant in the form of fine protoplasmic threads (**embryonal supporting tissue** of von Szily, 217).

The primordium of the lens now begins (at a gr. l. of 4 mm: Keibel, 116; Seefelder, 203) over the summit of the optic vesicle in the form of a thickening of the ectoderm (**lens plaque**), and soon sinks into a depression.

At the same time, but independently, the neighboring already thickened, distal part of the primary optic vesicle becomes concave (convex brainward); the primary optic vesicle begins to invaginate.

The much-used expression, "invagination," is not correct. The distal portion of the primary optic vesicle does not actually grow inward, but the margins grow out over the summit, and, indeed, from above (dorsal) and from the sides.

Therewith begins the transition of the primary into the **secondary optic vesicle** or the **optic cup** (Pl. IX, 7). The optic cup has a double wall; that portion of the primary optic vesicle which is not invaginated forms the **outer leaf** (*a*), the invaginated distal portion, the **inner leaf** (*i*) of the optic cup. Its **lumen** (*a*) has the form of a cleft and is connected with the lumen of the forebrain (*V*) through the wide lumen of the pedicle of the optic vesicle (*S*). The **cavity** of the optic cup arising through the invagination shelters the *lens primordium* (*L*) and is open laterally, i.e., toward the ectoderm, and below.

Meanwhile, small vessels of a capillary nature have developed in the mesoderm surrounding the optic cup.

To the extent to which the *lens primordium* sinks into a tiny **sac**, the optic cup also deepens and more and more surrounds the *lens primordium*. The opening of the optic cup thereby continues to differentiate itself more plainly into a laterally directed rounded portion (the **primitive pupil**) and into a downward-directed cleft (**fetal cleft, optic fissure**), which at first ends at the beginning of the pedicle of the optic vesicle.

The primordium of the lens is now surrounded on all sides by the margins of the optic cup and separated from this by the engirdling mesoderm; the mesoderm borders the *lens primordium* below, only in the region of the fetal cleft.

There is only a narrow interspace between the *lens primordium* and the inner leaf of the optic cup, and this is filled out by the **primitive vitreous**. This is nothing more than that layer between the ectoderm and the optic vesicle present immediately before the invagination of the lens; it consists, therefore, of von Szily's embryonal supporting tissue, which, to be sure, is not completely free of cells at any stage.

The borders of the fetal cleft approach each other and narrow the cleft more and more. Thereby an extension of the mesoderm becomes more and more plainly separated off and presses in through the fetal cleft into the cavity of the optic cup. A small vessel, a branch of a ring vessel, develops in this process at the border of the cup. The newly formed vessel ends blind behind the little lens sac at a gr. l. of 5 mm (Seefelder, 199), (at one of 7 mm l. according to Elze, 56); by the twenty-eighth day it extends through the entire optic cup, according to Calderaro (29), and is united with the vessels of the region behind. This is the primordium of the inner vessel system—the primitive *arteria hyaloidea*—and the annular vessel at the border of the cup is the primordium of the *circulus iridis major*.

At a gr. l. of 6.5 mm (Keibel, 116), the little lens sac has been closed off into a **lens vesicle**, the rounded lumen of which contains some desquamated cells. The lens vesicle at first remains connected with the ectoderm.



At a gr. l. of 8.5 mm the **closure of the optic cleft** begins (Seefelder, 203); the mesoderm between the edges of the cleft disappears, and these fuse together, and, indeed, each leaf of the optic cup by itself, so that thereafter not even the slightest trace of this union remains. The closure of the optic cleft begins in the middle and proceeds from there forward and backward. The primitive pupil is thereby closed off into a round opening directed toward the ectoderm (therefore at first still lateral, later toward the front). At first, however, there is no closure at the posterior end of the optic fissure.

At a gr. l. of 9.75 mm (Tandler, 219) the lens vesicle becomes completely constricted off from the ectoderm, and its lumen begins to narrow from behind (through elongation of the epithelial cells concerned). The mesoderm between the ectoderm and the lens vesicle now also begins to grow in, i.e., the formation of the **primitive cornea** begins.

In this stage (Pl. IX, 8) the pedicle of the optic vesicle (*S*) is always still very short and thick, but its lumen is already considerably narrower. A well-developed extension of the mesoderm passes into the cavity of the cup at the transition of the pedicle into the optic cup: the fissure in the cup is here still wide open (*Mf*). This extension (the primordium of the inner vessel system) is, moreover, united with the neighboring mesoderm at the border of the cup, although only below (ventral), and the border of the cup still has a notch at this place. In between, however, the optic fissure is closed, and, therefore, the cleft-like lumen of the optic cup (*A*) is continuous. The cavity of the optic cup is for the greater part taken up by the lens vesicle (*L*); ventral to this lies the process of mesoderm, and the remnant of the cavity is filled out by primitive vitreous (*G*). Between the border of the cup and the ectoderm, mesoderm is everywhere found, and this presses in like a wedge between the lens vesicle and the ectoderm (*H*).

It is difficult to give a comprehensive description of the further development of the eye; I, therefore, prefer now to treat the individual portions of the optic primordium separately.

The **pedicle of the optic vesicle** becomes the optic nerve. It now rapidly grows in length (Seefelder, 203). The suggestion of invagination, which up to this time was present at the anterior end, deepens to a plain furrow and extends farther backward. The pedicle of the optic vesicle still consists of epithelial cells, however, and maintains the primary lumen.

At a length of 14 to 15 mm the first nerve-fibers appear in the periphery of the pedicle of the optic vesicle, and the lumen narrows. At 23 mm length the pedicle of the optic vesicle is solid; as a result, the furrow is closed and the proximal portion of the *arteria hyaloidea* is closed into the



axis of the pedicle. The connection of the *arteria hyaloidea* with the neighboring mesoderm persists only at the posterior end of the furrow, where the central vessels enter later.

The nerve-fibers sprout in from the optic cup; at the same time the train of epithelial cells becomes spaced apart and forms a syncytium, i.e., an area of protoplasmic framework permeated with cell-nuclei (Krueckmann, 124). The glia fibers develop out of the protoplasmic processes, the glia cells out of the nucleated portion of the syncytium.

The primordium of the *vena centralis* is first visible at a length of 54 mm (Seefelder, 201). The connective-tissue septa grow in with the blood-vessels out of the neighboring mesoderm; the latter also furnishes the optic-nerve sheaths.

The **outer leaf of the optic cup** (*a*) develops into the *stratum pigmenti*.

Pigmentation begins even very early (at a gr. l. of 7 mm, Elze, 56), and, indeed, first in the equatorial regions (Lauber, 137). Yet in this respect there are great individual differences. At 9.75 mm gr. l. (Pl. IX, 8) the whole outer leaf is, indeed, sparsely but uniformly pigmented, yet still in several layers.

At 19 mm length (Dedekind, 37) the posterior part of the optic vesicle has already become one layer, which still thickens, however, toward the border of the cup. The single-layer portions consist chiefly of flat endothelial-like cells; they attain their cylindrical form first after birth (Seefelder, 208).

The **inner leaf of the optic cup** becomes differentiated into the retina but also contributes to the formation of the primitive vitreous.

Even at the beginning of the invagination of the primary optic vesicle (Pl. VIII, 7), the distal portion of its wall (*i*) is characterized by a greater thickness, and a nuclear-free layer is found along the basal surface (that turned toward the lumen)—the **marginal film** of His.

This marginal film develops further into an increasingly plain syncytium, the primordium of the **supporting tissue**. At a length of 11.3 cm a layer differentiates itself off from the heretofore undifferentiated thickly disposed nuclei inward. The nuclei in this are not so thickly disposed—the primordium of the **ganglion-cell layer**; it soon becomes much thickened.

The formation of the ganglion cells begins, as does the differentiation of the retina, in general, in the tempero-inferior quadrant, and this area later becomes the region of the fovea. Differentiation progresses peripheralward from here.

The first **nerve-fibers** appear in the border film at a length of 13 to 14 mm; at 65 mm the dendrites of the ganglion cells and their diplosomes and at the same time the **inner nuclear layer** differentiate themselves.

From this time on the thickness of the ganglion-cell layer again decreases as a result of the increase of the retina in surface expanse; its greater thickness is maintained only in the region of the differentiation center (primordium of the *area centralis*).

A cell-layer first appears on the side of the retina which was originally free (now lying on the pigment epithelium) at the end of the third month; this is the primordium of the **outer nuclear layer**. At the fifth month the rods appear as small caps projecting over the *membrana limitans externa*; the diplosomes lie in them, and at each cell a fine thread (the outer thread) goes into the pigment epithelium from the diplosome.

The amacrin cells separate away from the nuclei of the Mueller's fibers in the fifth month in the primordium of the *area centralis*, and there arises an intervening layer (Chievitz; transitory fiber layer, 32). This layer later again disappears, but traces of it are often found in extrauterine life.

At the end of the sixth month that reduction of the cerebral layer which leads to the formation of the **fovea centralis** begins in the middle of the *area centralis*. The distance between the fovea and the papilla is already as great as in the adult eye.

Although up to this time the development in the *area centralis* precedes that of the rest of the retina, it now falls behind, at least in respect to the development of the neuroepithelium, and even at birth the fovea is not yet completely developed (cf. chap. xvii).

The retinal vessels sprout out from the portion of the *arteria hyaloidea* (later the *art. centralis retinae*) inclosed in the optic nerve at a length of 10 cm (Versari, 231), or at the beginning of the fourth month (Seefelder, 201), and at once press into the nerve-fiber layer of the retina, in which they gradually broaden out farther. The vessel system is only completely developed in the eighth month. A *membrana vasculosa retinae*, therefore, does not exist at any time in man.

We have left the *lens primordium* as a hollow epithelial vesicle with somewhat elongated cells in the posterior wall (Pl. IX, 8). By further elongation of their axes these posterior cells grow out to lens fibers and so fill out the lumen of the lens vesicle (at a length of 13 mm according to Brueckner, 28). From there on the new formation of fibers is limited to the equatorial portions of the vesicle. The youngest fibers at the periphery are strongly concave toward the equator; this bowing is gradually lost toward the center, where a purer sagittal direction of the fibers is present (central fibers of Rabl, 175). Since all the fibers are nucleated, the nuclear bow extends through the entire lens (Pl. IX, 9).

At a length of 51 mm (collection of the I. Anatomic Institute of Vienna) there is already manifest a tendency to concentric stratification,

i.e., the fibers undergoing development are, as heretofore, strongly concave toward the equator; the middle fibers, however, show a convexity toward the equator (transition fibers of Rabl), and only the central fibers are strictly sagittal.

At 60 mm length (collection of the I. Anatomic Institute of Vienna) a plain cortex of concentric layers of fibers with three-rayed lens stars is already present. The form of the lens is still almost spherical. The further growth then continues as in the adult, with only this difference, that the number of undeveloped lens fibers is much greater and their concavity more outspoken.

At the beginning (at the time of the invagination) the cells of the *lens primordium* also contribute to the make-up of the **primitive vitreous**, and, indeed, by the formation of conical basal processes (**lens cone** of von Lenhossek, 140); this subsequently breaks up into fine fibers which unite with similar fine filaments proceeding from the inner leaf of the optic cup. The prevailing direction of the fibers is radial (embryonal supporting tissue of von Szily).

The lens vesicle is soon closed off from the neighboring structures by a cuticula (later the lens capsule), and thereby sacrifices any further influence on the development of the vitreous.

The mesodermal process which presses in through the optic cleft grows about the lens on all sides and forms the **capsula perilenticularis** (Cirincione, 33). Vessels appear in this in the seventh week, and at the same time the undifferentiated mesoderm disappears; in the ninth week the *capsula perilenticularis* goes over into the **tunica vasculosa lentis** (Pl. IX, 9, *Tv*), which consists only of vessels. Numerous branches of the *arteria hyaloidea* sprout out to the sides and toward the front, and the latter form the *tunica vasculosa lentis*, a net of vessels which wholly surrounds the posterior half of the lens and unites with the primordium of the outer vessel system along the entire border of the cup.

Up to a SS of 20 mm (second month) all the vessels have the same caliber, according to Calderaro (29). A trunk (the **arteria hyaloidea proper**) then differentiates itself, and courses from behind (as the branch of the *art. ophthalmica*) through the pedicle of the optic vesicle and the axis of the primitive vitreous. It gives off lateral branches in the vitreous (**vitreous vessels**) and divides into several branches in the neighborhood of the lens; these carry the blood to the *tunica vasculosa lentis*. The drainage in front, at the border of the cup, proceeds into the outer vessel system, and this place is called the isthmus (Pl. IX, 9, *I*), since the border of the optic cup almost always lies close to the lens.

At 31 mm length (Seefelder, 203) a conical or rod-form structure



develops—**zaffo prepapillare** (Calderaro, 29), **glial mantle** (Seefelder, 203)—at the place where the *arteria hyaloidea* passes out of the optic nerve into the vitreous. According to Seefelder, it consists of glia cells, arranged in two layers, and when fully developed may attain a length of 2 mm (Calderaro). This glial mantle fills out the excavation arising at the entrance of the optic nerve occasioned by the spreading apart of the optic-nerve fibers (Seefelder, 200). Fibrillae are set into the surface of the glial mantle; these course straight as a string to the lens and there spread apart like a crater (**central vitreous body** of Retzius).

The disappearance of the inner vessel system begins at the fifth month with the vessels of the vitreous proper; the circulation in the *arteria hyaloidea* ceases in the sixth month, according to Calderaro; in the seventh month it is transformed into a filament, and this disappears also between the eighth and ninth month. According to Seefelder, however, the *arteria hyaloidea* carries blood much longer. With the disappearance of the *arteria hyaloidea* and its glial mantle the excavation again opens.

That which later becomes the central canal appears to be identical with the cavity of the central vitreous body of Retzius, if I have understood Seefelder (203) correctly. However, according to the view of this author, it also becomes filled out with vitreous tissue and Seefelder, like Wolfrum, therefore, denies the existence of a central canal (p. 149).

The *tunica vasculosa lentis* undergoes regression at the same time as the *arteria hyaloidea*. Only that portion of this artery lying in the optic nerve persists, and from this time on supplies only the retinal vessel system; it becomes the **arteria centralis retinae**.

After the development of the lens capsule the predominantly radial fibers of the primitive vitreous are united rather with the retinal primordium, and, indeed, with the marginal film. The formation of further radial fibers proceeds from this (Wolfrum, 239); these are then united by cross-anastomoses. Protoplasmic unions with the vitreous vessels, which, in general, are pure endothelial tubes, do, however, also come about. The cross-anastomoses at length acquire predominance in the fundus and so go over gradually into the permanent structure.

Finally, the retina also becomes closed off from the vitreous by a cuticulum (the subsequent *membr. limitans interna*). However, the formation of radial fibers proceeds farther in the region of the *pars coeca* (see p. 199), which has arisen meanwhile, so that the definitive vitreous is mainly connected with the ciliary epithelium and appears to proceed out of this (vitreous basis).

The formation of these zonula fibers from the cells of the *pars coeca* goes on in a way similar to the development of the vitreous fibers. They



are only to be distinguished from the fibers of the vitreous by the fact that they are larger and form no cross-anastomoses (Wolfrum, 239).

The views of the embryologists have undergone a significant change in the last decades with respect to the genesis of the vitreous. Previously the vitreous was held to be a mesodermal structure. Now, with a few exceptions, the trend of the views is that the mesoderm forms only the vitreous vessels, that, however, the framework of the vitreous is of ectodermal origin. In respect to the finer details the views are still very much at variance; I, myself, have mainly followed the more intermediate views of Koelliker, von Szily, and Wolfrum.

Even the fetal vitreous is very poor in cells (aside from the vitreous vessels); these cells are explained in various ways, but, as it appears, the later works are agreed that these cells form no essential part of the fetal vitreous.

In the mesoderm surrounding the optic cup, a layer of capillary vessels very early becomes differentiated off—one lying immediately on the outer leaf of the optic cup (the primitive **choriocapillaris**). At a SS of 19 mm, according to Dedekind (37), there is a thicker layer of mesoderm (the primordium of the sclera) (Pl. IX, 9, *S*) outside this capillary layer, and in the posterior part of the chorioidal primordium a second layer of larger vessels is already demonstrable. Likewise the vortex veins are laid out, as well as the long posterior ciliary arteries, the temporal of which appears as a direct extension of the *arteria ophthalmica*.

The primitive cornea (Pl. IX, 8, *H*) differentiates itself in a similar way, i.e., forms out of that layer of mesoderm which has interposed itself between the ectoderm and the lens vesicle. This layer, which in the seventh week is still completely undifferentiated, divides into an outer (anterior), i.e., lying immediately under the ectoderm avascular, and into an inner (posterior) vascular layer (Seefelder, 216).

The anterior, much thicker layer (Pl. IX, 9, *H*) is the primordium of the corneal stroma; the posterior layer (*IP*) is pretty thick at the border of the cup, much thinner in the middle, and is best designated as the **lamina irido-pupillaris** (Jeannulatos, 110). The border of this portion is formed by a layer of regularly arranged cells (primordium of the endothelium) at a length of 26 mm, and this layer ends opposite the cup border in a group of such cells (primordium of the scleral trabeculum).

The *lamina irido-pupillaris* is united at the **isthmus** (*I*) with the *tunica vasculosa lentis*, the vessels of which bend about the border of the optic cup.

Toward the end of the third month the *pars coeca* of the optic cup is laid out, i.e., the border of the optic cup grows out into an epithelial fold, which in the course of further development always becomes more closely articulated to the peripheral portion of *lamina irido-pupillaris*.

The *pars coeca*, like the optic cup itself, has two leaves, an outer and an inner. The outer leaf is intensely pigmented and is soon disposed in meridional folds (primordium of the ciliary processes), while the inner unpigmented layer at first courses smoothly over these folds. The transition area of the *pars coeca*, or the forward displaced border of the optic cup, is not folded. At this place a narrow space exists between the two leaves (analogous to the lumen of the primary optic vesicle, or possibly to the last remnant of this lumen, the **ring sinus** of Szili, 216).

At the beginning (Szili, 216; Lauber, 137) or toward the end of the fourth month (Seefelder, 204) a club-like (or possibly better, roll-like) thickening appears at the transition place—the primordium of the **sphincter pupillae**. Herewith begins the development of the iris proper.

The *sphincter primordium* consists of ectodermal cells, derivatives of the transition area, in part also of the outer layer (Juselius, 112). It is united wholly to the *pars coeca* (Pl. IX, 10, *Sph*) to begin with, but imbeds itself, however, in further development, in the mesoderm. Yet numerous connections with the *pars coeca* always remain.

According to Seefelder (204), the unfolding of the anterior chamber begins in the fifth month, and, indeed, first in the region of the *iris primordium*. From there it gradually advances toward the axis of the eye, and is only completed in the sixth month. Still its peripheral limit is then at the border of Descemet's membrane.

The iris angle then forms; the mesoderm between the primordium of the scleral trabeculum and that of the iris becomes spaced apart and transformed into a loose framework, the uveal framework of H. Virchow (234). This framework, therefore, fills out the entire iris angle in the fetus; later it disappears except for a slight remnant at the periphery of the chamber bay.

A complete separation of the corneal primordium and its endothelium, on the one side, from the *lamina irido-pupillaris*, on the other side, follows in the development of the anterior chamber. The further development of the anterior layer is quite simple (Pl. IX, 10): the ectoderm becomes the corneal epithelium (*E*), the mesoderm becomes the corneal stroma (*C*), and the above-reported cell-layer, the endothelium (*D*); this latter at first consists of small, quite high cells. The Descemet's membrane arises as a cuticulum out of the endothelium, and is demonstrable from the fourth month on. According to the newest investigations, a pre-corneal vessel net does not exist (Hirsch, 103).

The *lamina irido-pupillaris* shows a thicker zone in the periphery covered posteriorly by the *pars coeca*—the primordium of the iris (*I*). The vessels of the *tunica vasculosa lentis* (*Tv*) enter the *lamina irido-pupillaris* at the inner margin of the *iris primordium*.

By far the greater remnant of the *lamina irido-pupillaris* is a delicate membrane consisting mainly of vessels and called the pupillary membrane (*Pm*).

With the further growth of the eye, the iris continues to broaden out along with the contemporary growth of the *pars coeca*, and the impression is therefore given that the iris grows out of the chamber angle. In fact the pupil always becomes larger with the age of the fetus; this is only due to the fact that its increase in size does not keep pace with that of the whole eyeball.

The *iris primordium*, therefore, consists of a mesodermal layer (part of the *lamina irido-pupillaris*) and two ectodermal layers, i.e., the anterior zone of the *pars coeca*. The mesoderm of the *iris primordium* at first goes continuously over into the pupillary membrane, and the vessel system of the iris forms a *continuum* with that of the pupillary membrane. Furthermore, the vessel system of the iris takes up the drainage of the *tunica vasculosa lentis*. The circulation in the pupillary membrane is, therefore, independent of that of the *tunica vasculosa lentis*. Later, the border between the iris and the pupillary membrane moves back onto the anterior surface of the former, probably because of the greater development of the *sphincter pupillae* and its neighborhood (Brueckner, 28).

The **pars uvealis iridis** develops out of the mesodermal layer of the *iris primordium*; stroma cells differentiate themselves in it in the fourth month, the anterior border layer in the seventh month (Lauber, 137).

At first, the outer leaf of the *pars coeca* consists of high cylindrical cells ciliaryward, of low cylindrical cells in the region of the *sphincter primordium* (*Sph*). On the border between the two forms of cells, Michel's spur arises; and the clump cells arise through detachments from this, and from the pigment spurs lying farther forward.

The ciliary zone of the outer leaf becomes differentiated into the *dilatator pupillae*. According to Heerfordt (88), the bases of the cells fuse to a diffusely pigmented lamella in the twenty-second week. In the twenty-fourth to the twenty-eighth week, pigment disappears from this lamella, and fine meridional fibrillae become visible in it. In the thirtieth to the thirty-second week bundles of fibrillae become separated off from one another—the subsequent fibers of the posterior border lamella. Meanwhile, the height of the cells gradually decreases.

The inner leaf of the *pars coeca* takes on pigmentation and, indeed, progressively ciliaryward from the transition area. This pigmentation has attained the iris root at a length of 19 cm (Juselius, 112).

The ring sinus disappears at the end of the seventh month, according to Szili, yet the connection of the two leaves remains more loose at this



place than in the ciliary part of the iris; in posterior synechia the ring sinus at times again opens.

The pupillary membrane persists longer than the *tunica vasculosa lentis* (Brueckner, 28). Its resorption begins in the eighth month, and, indeed, first in the center. The small iris circle and the pupillary crypts form after the disappearance of the pupillary membrane, while the ciliary crypts open after the completion of the regression of the uveal framework in the ninth month.

According to Seefelder (204), the development of the ciliary body sets in at the end of the third month by a folding of the outer leaf of the *pars coeca*. The first muscle fibrillae are visible in the meridional portion of the ciliary muscle toward the end of the fourth month; the circular fibers first appear at the end of the sixth month with the opening up of the chamber bay.

The ciliary processes at first reach much farther over the iris (Taf. IX, 10, *Pc*) than they do in the developed eye. Moreover, to begin with, the ciliary body consists only of the *corona ciliaris*, i.e., the border of the retina lies at the posterior ends of the ciliary processes and sends short extensions into the ciliary valleys (O. Schultze, 198). The primordium of the ciliary muscle at first extends far behind the border of the retina (*R*).

It is apparent, therefore, that a shifting occurs in this region of the eyeball in further development. The ciliary processes shift out of the territory of the iris into that of the ciliary muscle and the border of the retina removes itself more from the ciliary processes. The backward displacement of the ciliary processes cannot well be an actual one, for its foundation is mesodermal tissue; the form only of the ciliary body really changes. But the border of the retina actually shifts backward in its relation to the posterior end of the ciliary muscle. Thereby the originally short projections of the border of the retina become drawn out to the long, sharp teeth of the *ora serrata* (cf. p. 88).

---

As already reported, the optic vesicle is laid out laterally, i.e., the primitive pupil looks to the side. After the closure of the optic cleft the direction of the eyes changes with the greater development of the skull; the pupils turn more toward the front, and that which was the posterior (caudal) half of the eye in the primordium becomes the lateral (temporal) half in the developed eye.

However, no notable rotation of the eye about its axis occurs, for the entrance of the central artery into the optic nerve (the place corresponding to the posterior end of the optic cleft) also lies below in the adult. The



*fovea centralis* has, therefore, no relation to the optic cleft, wholly aside from the fact that it develops at a much later period of fetal life. The physiologic excavation has just as little to do with the optic cleft.

## CHAPTER XVII. THE EYEBALL OF THE NEWBORN

(Text Fig. 5)

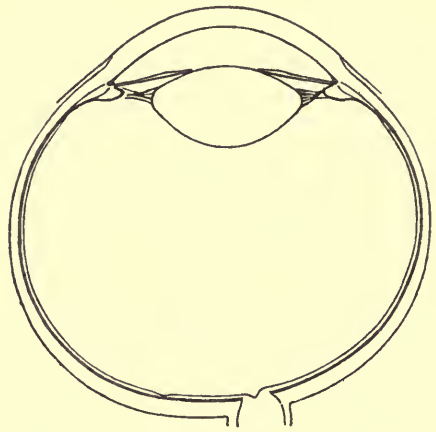
The size of the eyeball varies considerably at the time of birth; according to E. von Jaeger (108), the sagittal diameter varies between 16.1 and 19.1 mm. The mean of these, and, furthermore, the measurements of Koenigstein (121), Merkel and Orr (152), Weiss (235) and von Pflugk (172), is 17.3 mm.

The form of the eyeball also is subject to much change; while Weiss finds the equatorial diameter smaller than the sagittal, Merkel and Orr, as well as von Pflugk, estimate a somewhat higher average for it. All are agreed, however, that the variation from the form of a sphere (cf. p. 4) is greater in the newborn, and especially that the postero-temporal part is more markedly curved out. The distance of the cornea from the optic nerve is, therefore, found to be 0.3 to 0.5 mm less than the sagittal axis (Koenigstein); this asymmetry comes out plainly in some drawings of Weiss, also in the photographs of von Pflugk.

According to von Reuss (181), the horizontal diameter is usually 9 mm, according to Koenigstein, 10 mm. The cornea is, therefore, relatively large; its relations to the optic axis in the newborn is something like 1:1.8 (in the adult something like 1:2), or the cornea must grow one-fifth to one-fourth, the optic axis, however, at least one-third, in order to attain its definitive size.

The radius of curvature is given as 6.59 by von Reuss, as 7.3 by Merkel and Orr. According to the latter, the cornea is more curved at the border than in the central portions, therefore, a relation which is exactly the opposite of that in the adult eyeball.

Extensive investigations have been made concerning the insertions of the eye muscles by Weiss. They give so great a variation in the position and direction of the lines of insertion, that I must limit myself to



TEXT FIG. 5.—Left eyeball of the newborn. Schematic cross-section closely following a photograph of von Pflugk's. Magnification 3.

reference to the original work. Most striking and, as it appears, pretty constant is the relatively slight distance from the cornea at which the *m. rectus medialis* is inserted.

---

The sclera has its greatest thickness at the posterior pole, its least in the neighborhood of the cornea (E. von Hippel, 102). The thickness of the cornea varies a great deal and is subject to the influence of the fixation fluid perhaps in an even higher grade than in the adult. Von Hippel found a maximum of 1.12 mm in fresh eyes. Still greater thicknesses (2 mm, according to Hirschberg, 104) are possibly due to swelling.

Bowman's membrane shows the same thickness as in the adult (17 to 21  $\mu$ , according to von Hippel). The stroma of the cornea, like the sclera, is much richer in nuclei than in the adult eye. Descemet's membrane, on the other hand, is still very delicate (2  $\mu$ ).

According to von Hippel, the perichorioidal space is entirely absent; according to Merkel and Orr it is absent in the posterior portion; according to Lange (135), however, it is as much or as little present in the posterior segment as in the adult.

Pigment is absent in the stroma of the uveal tract (but not the cells which will later bear it); at the most, pigmented chromatophores are found in the neighborhood of the optic nerve. The iris also is almost always gray, therefore, and, indeed, on account of the delicacy of the *pars uvealis*, a pretty dark gray. In any case, the pigmentation of the anterior border layer sometimes develops in the first days of life.

The stroma of the uveal tract, furthermore, shows a preponderance of cells over collagenous intervening substance (Gutmann, 83), and, therefore, a greater richness in nuclei. The adventitia of the vessels is very weakly developed and, therefore, the marking of the iris is more delicate and uniform. The pupil is pretty narrow and, moreover, does not permit of maximal dilatation.

The iris angle (chamber bay) is sharp and narrow, the uveal framework (*ligamentum pectinatum*) still has its fetal character for the greater part, i.e., it fills out the iris angle to a great extent.

The ciliary processes still reach far over onto the posterior surface of the iris, they are thin and relatively smooth, i.e., the lateral folds and bulgings, as well as the little warts in the valleys, are only suggested. The ciliary muscle is already well developed and even the various types can be recognized (Merkel and Orr, Lange). The inner surface of the *orbiculus ciliaris* looks entirely smooth on cross-section (Taf. IX, 11).

The pigment epithelium of the chorioidea shows a uniform develop-

ment; the much enlarged cells at the *ora serrata* fail. On the other hand, according to Kuhnt (127), some larger cells, about which the smaller ones group themselves as centers, appear at pretty regular intervals. The pigmentation of the *stratum pigmenti* is very marked in comparison to the pigmentation of the uveal stroma, indeed, in many places it is actually more dense than in the adult. Such a place is the *corona ciliaris*; the summits of the ciliary processes are just as dark a brown as the valleys; the delicate radiating figure from which the *corona ciliaris* gets its name, is, therefore, not visible in the newborn. Likewise the *dilatator pupillae* appears much thicker and more densely pigmented.

The retina is, in general, well developed, to be sure, yet it still bears more of a fetal character in two places, namely, the region of the fovea and at the border.

The *fovea centralis* is shallow and the wall about it barely suggested. According to von Hippel (102), all the layers are still present on the floor of the fovea—a simple layer of ganglion cells and an inner nuclear layer, somewhat thinned and spaced up, to be sure, but yet always a plainly distinguishable layer. On the other hand, the external nuclear layer consists only of one layer of nuclei and the cones are short, thick, and few in number (Wolfrum, 241).

The distance between the fovea and the papilla is as great as in the adult.

According to von Hippel, the border of the retina shows plainly formed teeth, although they are not as long as in the adult eye.

The border of the retina shows an especially characteristic picture on meridional section (Taf. IX, 11), because it varies much from that of the later state. In particular, the retina (*R*) goes over into the ciliary epithelium more gradually. At the place where the inner plexiform layer ceases, or even somewhat farther posterior, the two nuclear layers fuse into one, and out of these fused nuclear layers there comes a tissue which strikingly recalls the first stages of the development of the retina in the embryo. This zone contains numerous uniform oval superimposed nuclei and to the inside a very narrow "border film." It thins very gradually into the ciliary epithelium (*CE*), which appears very much more uniform and lower than in the adult eye.

The border portion of the retina and this transition zone elevate themselves very readily from the pigment epithelium and then form a fairly high and sharp circular fold (*F*), which springs inward toward the vitreous and somewhat forward; this has often been called Lange's fold because this author (134) has made remark upon its regular occurrence. Yet it is to be looked upon as an artificial product, as Lange himself concedes (135).

The border of the retina always lies still farther forward, about at the posterior end of the ciliary muscle; the *orbiculus ciliaris* is, therefore, strikingly short (1.4 mm).

The pigment epithelium of the iris shows a relatively slight pigmentation, especially toward the ciliary border; its cells are small and the circular furrow system is absent. The *sphincter pupillae* is as broad as in the adult, but thinner.

The intraocular end of the optic nerve often shows a plain excavation—not simply a vessel funnel but an excavation with a lateral (elbow-formed) transposition of the nerve-fiber bundles. Remnants of the glial mantle of the *arteria hyaloidea* are at times still present. The diameter of the chorioidal foramen (the ophthalmoscopic papilla) measures about 1mm. The optic-nerve fibers behind the *lamina cribrosa* are still unmedullated.

The vitreous is of a more uniform consistence; the border layers are only weakly developed.

The zonula consists of numerous fine fibers; moreover, zonula fibers are given off even from the posterior chamber angle, indeed, even from the posterior surface of the iris, as far as the ciliary processes reach. Yet there fail any of the divisions characteristic of later periods of life; the fibers are uniformly distributed and of uniform size.

The statements concerning the form and the diameter of the lens read very differently. In the text and drawing (Text Fig. 5) I hold myself to the photograph of von Pflugk (172), since the method of this author offers the assurance that the relations of fresh cadaver-eyes are best conserved.

According to von Pflugk, the form of the lens in the newborn is not so fundamentally different from that of the adult as given by the older statements. The equatorial diameter amounts to 6.6 to 7 mm, the thickness to 3.4 to 4 mm. The radius of curvature of the anterior surface is 5 mm, that of the posterior 4 mm. The anterior surface flattens somewhat toward the equator, the posterior surface shows a slight concavity in the neighborhood of the equator; the equator itself is pretty sharp. The border of the lens is smooth and without crenations.

The lens capsule is delicate; only the thickening at the periphery of the posterior capsule, which even Becker (18) observed, is strongly marked (cf. the table on p. 165) and is especially striking on account of the delicacy of the remaining portion of the lens capsule. The nuclear bow of the lens is still long and rounded, the nuclei reach to a depth of at least 0.4 mm. The central portions of the lens, already characterized by a somewhat greater density, are without nuclei.

On account of the strong vaulting of the lens the anterior chamber is pretty shallow (2.3 to 2.7 mm, according to von Pflugk).



## CHAPTER XVIII. THE EXTRAUTERINE DEVELOPMENT AND GROWTH OF THE EYEBALL

According to the curve drawn by Weiss (235), the eyeball grows most rapidly in the first years of life, then more slowly. From the fourteenth year of life on there is again a somewhat greater growth up into the twenties. The growth of the eye keeps pace with the growth of the brain; in its whole period of growth the eye grows 3.25 times, the brain 3.76 times—the body, on the other hand, 21.36 times.

The rapid growth at the beginning mainly concerns the formation of the anterior segment. Von Reuss (181) has shown that the average diameter of the cornea in children between the first and sixth years is not much less than the average in the adult. This would therefore indicate that the cornea has attained almost its complete size in the course of the first year of life. According to the table published by Grod (77), it attains this in the second year of life.

While the cornea thereby grows 1.25 times, the neighboring scleral zone, i.e., the zone between the lines of the insertion of the recti muscles and the border of the cornea, broadens, in general, 1.358 to 1.374 times (on the average), according to Weiss, and the completed size of this segment is at times attained even in early childhood.

Only the nasal portion of this zone, i.e., the interval between the insertion of *m. rect. medialis* and the border of the cornea shows a much greater growth, for this distance is on the average 1.629 times greater in the adult. It appears that this greater growth sets in first in later childhood, yet the number of the cases is still much too small to cover the great individual differences, despite the comprehensive investigations of Weiss concerning this circumstance.

It has already been emphasized that the distance between the *fovea centralis* and the papilla is as great in the newborn (and even in the last months of fetal life) as in the adult. This portion of the wall of the bulb, at least that which concerns the retina and the pigment epithelium and probably the chorioidea also, does not grow any more, therefore.

The last increase of growth from the fourteenth year of life on appears mainly concerned with the enlargement of the posterior segment.

---

As we now turn to the finer anatomic and histologic developmental processes and attempt to arrange these chronologically, the development of the **medullary sheaths** in the optic nerve must be considered first. At the very latest this is completed in three weeks (Bernheimer, 22). On this account alone this process must receive special attention, because

it shows how the conditions of life as changed by birth affect development: it is the light which favors the development of the medullary sheaths. Prematurely born babes who have lived some time extra-uterine show farther advanced sheath development than fetuses of the same age which have remained *in utero*, for example.

The development of the *fovea centralis* requires a somewhat longer time. After four weeks a plain, steep-sided depression has formed (von Hippel, 102), and the cerebral layer is so far reduced in the center that one can no longer recognize a stratification. But the outer nuclear layer is always still poor in nuclei and the cones are short. The fovea first attains its full development months after birth (Wolfrum, 241).

The perichorioidal space must open up very soon after birth. At least Elschmig (54) has shown that a strong contraction of the ciliary muscle occurs even in the newborn, although it is still without plan, and this is probably not conceivable without an opening of at least the anterior part of the perichorioidal space.

As already stated, the cornea concludes the greater part of its growth in the course of the second year of life. The diameter of the cornea does not essentially change; later the radius of curvature alone is somewhat increased. According to von Reuss (181), in a 5- to 6-year-old child this is 7.36 mm on the average, increases by the twelfth year to 7.45 mm, and at the time of puberty nearly attains the average size for the adult.

With the increase in size of the cornea, the fibrillar intermediary substance develops more and more, so that the nuclear richness decreases. No further changes appear in Bowman's membrane. Descemet's membrane soon attains the thickness of 5  $\mu$ , and maintains this throughout the whole of childhood. Its periphery is still smooth at first. I have seen the earliest suggestion of warts in the ninth year of life.

The iris, too, undergoes further development during this period. The difference between the ciliary and the pupillary zone, which is pretty indistinct in the newborn, comes plainly in the course of the first half-year of the extrauterine life. The definitive iris color, however, needs a longer time for its complete development. In 2-year-old children one sees even a well-developed adventitia in the vessels of the iris, large crypts, and a very loose make-up in the interior. The connective tissue behind the sphincter thickens in the fourth year of life. The system of circular furrows in the pigment epithelium I have first seen completely developed in a 7-year-old, however.

Yet I would not attach too much weight to this and many other statements relating to age. They are not the result of thorough studies, but

of occasional observations, and it is conceivable that a great variability rules in this respect.

The development of the definitive form of the ciliary body also falls in this period. This depends upon the further carrying out of processes which have already begun in the latter period of fetal life: the border of the retina moves farther backward, or, more correctly stated, the mesodermal layers of the walls of the eye grow farther over the border of the retina. The material for the covering of the ever-broadening orbiculus appears to be that in the transition zone between the retina and the ciliary epithelium resembling the embryonal retina—that which is so characteristic of the eye of the newborn. In a 2-year-old child, for example, the demarkation of the retina from the ciliary epithelium is sharp, still the border is somewhat rounded; the tendency to the formation of the fold of Lange is still present. In the 7-year-old child, I find the same relations on the nasal side as in the adult, i.e., a marked projection of the retina over the ciliary epithelium.

The complete widening out of the angle of the iris appears to coincide with the backward displacement of the ciliary processes and occurs in the period between the second and fourth years of life.

In general, the ciliary processes maintain the appearance and the dark pigmentation which we have found in the newborn until an age of later childhood.

According to Kerschbaumer (117), the reticulum of H. Mueller is demonstrable in a child of  $1\frac{3}{4}$  years; still it is then very delicate in any case. In sections it is scarcely apparent at this age. It (as well as the interlamellar connective tissue) first appears in later childhood, or at the time of puberty, when it attains its complete development.

Unlike these processes which mostly come to an end in the first part of childhood, the lens grows throughout the whole of life; of course, the greatest changes in it are found in the first year of life. According to Dub (47), the equatorial diameter is 7.46 mm at the age of 10 to 11 months and the thickness of the lens 2.46 mm. The lens, therefore, has increased in the equatorial direction by this period, and has also become thinner. The explanation of this lies in the enlargement of the anterior segment, in particular of the ciliary ring, whereby the still soft and plastic lens is displaced in the frontal direction—through greater tension.

Both diameters increase in further growth, the equatorial to a greater extent than the sagittal; in a 3- to  $3\frac{1}{2}$ -year-old child the lens mass is  $8.46 \times 2.83$  mm, according to Dub. This further change of the lens-form apparently has its ground in the fact that the new-built fiber layers are thicker in the equatorial zone than at the poles, for this fact can be easily



established anatomically. For example, in a child of (probably) 12 years I measured the thickness of the less-stained cortex layers at the equator as 0.34 mm, at the anterior pole, however, as 0.14 mm. This difference gradually decreases with increasing age, and the thickness of the new-formed layers becomes more uniform.

An estimate of the growth of the lens is rendered difficult by the fact that the various figures have not been obtained by the same methods. The figures of von Pflugk (172), which were made on the basis of an eye of a newborn, were obtained in cross-section, after freezing, the figures for the adult, by ophthalmometric means; Dub (47), on the other hand, has measured isolated lenses and estimated their thickness on a hard base. At the same time the material studied is much too small to rule out disturbance by individual differences.

Now we know, however, that the severing of the zonula markedly changes the forms of the lens, and this change is still greater in young lenses than in old; indeed, in general, very slight forces are adequate to effect a notable change in the form of the lens (Heine, 89). According to this, the measurements contributed are not comparable, necessarily.

This much is certain, that, aside from the appositional growth, i.e., aside from the formation of new lens layers on the surface, still other factors affect the form of the lens. Such a factor is the enlargement of the ciliary ring; a second in all probability is the still-to-be-discussed sclerosis of the lens.

The inner part of the lens possesses a greater density, even in childhood; this is apparent from the way in which the lens substance absorbs after discission. This thickening (sclerosis) of the lens substance is, therefore, a process which has possibly set in in fetal life and has attained such a height somewhere in the thirties that spontaneous absorption is impossible and, therefore, the extraction must replace the discission.

It is highly probable that this thickening depends upon a loss of water, and that this goes on with a loss of volume. That such a shrinking must in part compensate for the increase in volume as a result of the appositional growth is easily understood. Yet we are without means of stating anything accurately concerning the degree of this shrinking.

The older the person is, the more the appositional growth of the lens decreases, i.e., the fewer the epithelial cells concerned in growth at any one given time. The influence which this has upon the appearance of the lens vortex has already been spoken of (p. 169). According to Becker (18), 25 cells form the nuclear bow of the lens in the newborn, only 8 in the 4-year-old child, and but 2 to 3 cells in the older person.

When the whole extrauterine development of the eyeball is surveyed, one sees at once that a few processes which in the course of the fetal development have not been completely brought to closure, e.g., the development of the fovea, are carried on further.

How much the use of the eye as a sense organ has an influence upon its develop-



ment still remains to be more accurately studied. The influence of light upon the development of the medullary sheaths in the optic nerve appears to be conclusively established. Furthermore, Grod (77) has established that the cornea lags behind 0.8 mm on the average in its growth when the lens is removed early (at the age of 1 to 9 years). Thereby a process discovered by Wesseley (236) in the course of animal experiments is also proven true for man, although in a lesser degree. Of course, the question still remains open, whether the factor which causes the cornea to remain smaller is a functional insult or another, possibly a mechanical one.

The growth of the eye without doubt makes greater demands upon the power of resistance of the tunics of the bulb. We see a tendency to the increase and thickening of the fibrillar intervening substance of the connective tissue, at first of the collagenous, and later also of the elastic fibers. According to Fuss (71), the latter attain their full development at the age of 10 to 11 years and increase somewhat in number from there on up to the thirties. The thickening of the cuticular membranes is probably to be ascribed to the same cause.

Finally, it is to be remembered that the optical relations also change decidedly with the growth of the eye. The hypermetropia of the newborn eye is not sufficient to compensate for the later addition to the axial length; an enlargement of the main focalizing limits of the optical system must occur, therefore, and this is affected for the most part by the flattening of the lens.

## CHAPTER XIX. THE APPEARANCES OF AGE IN THE EYEBALL

There are changes in the eyeball which gradually develop during the whole of life and which, therefore, have attained a higher grade in old people than in young. To these, among others, belong the sclerosis of the lens and its physiologic equivalent, the decrease of the accommodation, and the thickening of the glass membranes. Other changes occur first in the adult eye, but during the period of complete strength and vigor, and increase with age, like the cystoid degeneration of the retina. None of these conditions can properly be characterized as senile; to a certain extent they form an index of the individual, but they are not characteristic for the age of senility.

Among other things, the *arcus senilis* of the cornea, the clouding of the lens, the so-called *verruca* of the chorioidea, actually do set in in senility or a few years earlier. Therefore, these are actual senile appearances. Many of these can, however, also appear in younger individuals as pathologic processes, and possibly they are often such in senility. In general, therefore, one sees how uncertain the matter is, and, in particular, how wide the play for subjective conception.

According to Priestley-Smith (174), the diameter of the cornea decreases in great age; the average from 40 to 60 years is 11.48 mm, for persons over 60 years, 11.46 mm, and is 0.24 mm smaller than the

average from 20 to 30 years. Priestley-Smith seems to think of a true decrease of the cornea; it is also possible, however, that the limbus becomes more clouded and so limits the transparent area.

According to Steiger, the cornea in general flattens in age. More striking, however, is the frequency of perverse astigmatism. This increases gradually to the seventieth year of life, and from there on rapidly; the vertical meridian of the cornea flattens more than the horizontal.

In general, the sclera increases in thickness and becomes more rigid and less distensible, yet this thickening does not go so far that a notable limitation of the interior of the eyeball arises.

Throughout the whole *tunica fibrosa* a certain degree of **fatty degeneration** manifests itself in age. The sclera thereby loses its porcelain-white color and becomes more yellowish; in the cornea the degeneration makes itself manifest by clouding. Yet this clouding remains confined to the marginal portions of the cornea proper (exclusive of the limbus) and is, therefore, called *arcus senilis*, *gerontoxon*.

According to Takayasu (218), the fat lies in the intervening substance in finest round or elongated drops; the degeneration affects first the superficial layers of the corneal stroma and extends along the surface and into the depth. Little fat drops also appear in Bowman's membrane, yet these are finer than in the corneal stroma. Toward the periphery the degeneration is superficially limited by the border of Bowman's membrane; in the depths, however, it progresses farther toward the sclera, so that the peripheral border has a terraced appearance on cross-section.

In the uveal tract a greater development of the collagenous intermediary substance, or a thickening of this, makes itself manifest before anything else. One place in which especially dense sclerotic connective tissue develops is the anterior half of the bases of the ciliary processes. The interstitial connective tissue of the radial portion of the ciliary muscle also increases in amount, and the muscle-bundles thereby become narrower. The interlamellar connective tissue becomes thicker in the same manner.

In this category should perhaps be placed the senile miosis and especially the so-called rigidity of the *sphincter pupillae*, i.e., the resistance of the pupil to dilatation. It supposedly has its cause in the thickening of the connective tissue behind the sphincter (Fuchs, 67), if a formation of hyalin connective tissue at the border of the pupil is not the cause as in the case of Meller (149); this in any case does not any longer belong in the territory of physiology.

According to Kerschbaumer (117), changes in the vessel system of the chorioidea are frequent even in the fortieth year and are regular in

senility. These consist especially in clouding and thickening of the vessel walls, loss of the nuclei, etc. In the choriocapillaris this condition expresses itself by the loss of the endothelial nuclei, and a greater accentuation of the vessel contours; the whole layer thereby becomes more stiff and rigid.

The various glands and membranes (cuticular membranes) show a further and greater tendency to thickening in age and some a tendency to localized greater thickening or wart formation, as well.

The lens capsule only increases uniformly in thickness (cf. the table on p. 165); the Descemet's membrane gradually thickens in the center, but warts appear more and more plainly at the border; the wart zone broadens (Pl. IV, 1). Very striking, furthermore, is the thickening of the *limitans interna ciliaris*, especially its ridges. The results of this condition upon the ciliary epithelium have been described elsewhere (p. 122).

Most striking, however, is the tendency to the formation of warts in the glass membrane of the chorioidea. Since this appearance may also be a pathologic process, I limit myself to the description of that form which is found in the eyes of old people without other pathologic changes.

The **senile warts** (*verrucae* of most authors) occur at the periphery of the glass membrane of the chorioidea as small to medium sized, usually semispherical elevations (Pl. VII, 7). They are seated immediately upon the glass membrane, so that one can follow both lamellae of the membrane beneath the warts. When unstained, the warts themselves (at least in the hardened preparations) consist of a homogeneous, glassy, transparent substance; this stains only a little more intensely than the cuticular lamella. Without doubt there can at times be a thin stratum of ordinary cuticular substance on the surface and in the crevice about the base of the small warts; this substance stains feebly. Since the smallest of these structures also set directly on the glass membrane, one must look upon the warts as a secretion product of the pigment epithelium. The pigment epithelium courses over the warts, its cells are larger on the summit and thinner, and the nuclei are flattened.

With the ophthalmoscope the warts, therefore, appear somewhat lighter than their environment, and, since the pigment epithelium to a certain extent then appears in profile on the declivity of the warts, and a thicker layer is presented here (in the line of vision of the observer), the warts appear to be bordered by a fine, dark seam. The peripheral situation of the warts makes the ophthalmoscopic proof of them more difficult, because they are to be seen there only in the less magnified,



indirect image. One finds them decidedly more often, therefore, on anatomic than on ophthalmoscopic study.

Variations from this very frequent condition occur in the localization, the grade of development, and the structure of the warts.

As long as the formation of warts involves only the periphery of the fundus, it does not damage the function of the eye. At times, however, they attack the territory of the *area centralis* (and very extensively), or they attack it exclusively. They then make themselves manifest by a lowering of the visual acuity or, indeed, by a central scotoma.

Particularly large warts imbed themselves deeper in the retina, probably also lead to a total disappearance of the pigment epithelium over the summit, and thereby to further secondary changes in the retina. Large warts at times show a stratification about a core which lies at the base of the wart and is often degenerated; this may resemble particles of starch.

A calcification is frequently found in these warts, as also in those in the free portions of the glass membrane (H. Mueller, 156; Kerschbaumer, 117). One then finds numerous, very fine, highly refractile granules in the glass membrane, which is thereby rendered more clouded and fragile. These and other depositions likewise bring out a clouding in the substance of the warts. When the overlying pigment has disappeared, such warts appear as intensely yellowish-white flecks or show a plain, decided reflex (Nagel, 163), especially when they contain larger crystals.

When extensive atrophic processes are at the same time present in the retina, when the capillaries of the chorioidea are destroyed, a newly built connective tissue or bone lies beneath the warts, and one has a pathologic form of warts to deal with. Such changes are not the result but the cause of the wart formation, i.e., a proliferation of the pigment epithelium and an abnormal secretion of cuticular substance. The stratified concretions arising primarily in the cerebral layer of the retina or in the non-medullated section of the optic nerve have, in general, nothing to do with the pigment epithelium and are pathologic formations throughout.

The pigment epithelium in the eye of the aged is often subject to a certain amount of atrophy. This appears partly in a diffused form, and thereby brings out the tessellation of the fundus very much more plainly, partly in a circumscribed form. The latter occurs in the immediate neighborhood of the optic-nerve entrance and leads to conus or halo-like figures.

Such atrophic conditions are often found in the pigment epithelium in the neighborhood of the border of the retina and the border portions of the retina are frequently fixed thereby. It is, however, questionable whether these appearances are not in the territory of the pathologic.



Concerning the development of cystoid degeneration there has already been extended discussion (p. 84, etc.).

The irregularities appearing in the ciliary epithelium and their supposed cause have also been referred to elsewhere. However, actual growths of the ciliary epithelium may also come about; these lead to tufted or nodular excrescences. They appear on the crests of the ciliary processes. In connection with the more marked development of the connective tissue of the substratum, they bring about the plump appearance of the ciliary processes in the eye of the aged, especially, however, the nodular and racimose appearance of the ridges (Kerschbaumer, 117; Hess, 101), and, according to the latter author, also the greater extent of the whitish coloration. The individual excrescence is formed by the ciliary epithelium alone, and projects over the surface like half a sphere (Pl. VII, 2).

It is conceivable that not only the ciliary valleys but also the entire ciliary ring is thereby narrowed, and since, too, the lens is at the same time larger, a complete closure of the circumlental space can come about in the eye of the aged.

The border layer of the vitreous thickens and becomes condensed in age; at the same time the structure of the nucleus becomes spaced up, and large cavities filled with fluid appear (liquefaction of the vitreous, synchysis). The zonula fibers are also greatly thickened in age.

The lens increases in size up to the very greatest age, and although the rapidity of its growth is very much less than that in youth, a much longer time is allowed for it. Accurate statements concerning the growth of the equatorial diameter have been made by Priestley-Smith (173). In the third decade of life it has an average of 8.67 mm, in the eighth decade 9.64 mm. Along with this there is always a further individual play of at least 0.75 mm.

According to the same author, such senile lenses may be 5 to 6 mm or more thick. The ophthalmometric measurements of Saunte (published by Tscherning, 228) present a continuous increase of the thickness of the lens from 3.6 mm, in persons under 20, up to 4.5 mm in persons over 50 years of age.

From all this it is evident that at this period of life the lens increases uniformly in all diameters. According to Priestley-Smith, one can, therefore, deduce the form of the senile lens from that of the youthful lens if one thinks of it as surrounded by a shell some 0.5 mm thick. The margin of the senile lens is, therefore, much more strongly rounded.

The yellow coloring of the lens often attains such a height in great

age that the color perception, especially that for blue, becomes markedly disturbed (Hess, 98).

Corresponding to the slight growth of the lens fibers in age, the nuclear bow of the lens shows only a few transitional divisions from epithelium to lens substance, and the nuclear bow bends sharply and often very irregularly forward (Pl. IX, 3).

It is very difficult to decide to what extent opacifications should be accredited as senile appearances. It is, indeed, true that one practically never sees an eye in the aged in which the lens is completely free from clouding. Yet this clouding does not progress in all people to a complete formation of cataract. The senile cataract and all its initial stages, frequent as they are, had, therefore, better be treated as pathologic appearances.

One result of the enlargement of the lens, in part also of the defective secretion of aqueous, is the lessened depth of the anterior chamber. That the free space of the posterior chamber is also narrowed, and in a still higher degree, is shown by the enlargement and thickening of the ciliary processes, the lens, and the zonula fibers.

## LITERATURE CITATIONS

- (1) ABELSDORFF, Physiologische Beobachtungen am Auge der Krokodile. Arch. f. Anatomie und Physiologie, physiol. Abteil. 1898, pag. 155.
- (2) ——— Zur Anatomie der Ganglienzellen der Retina. Archiv f. Augenheilk., Bd. 42, pag. 188 (1900).
- (3) ADDARIO, Über die Matrix des Glaskörpers im menschlichen und tierischen Auge. Anatom. Anzeiger, Bd. 21, pag. 9 (1902).
- (4) AGABABOW, mitgeteilt von ARNSTEIN. Die Innervation des Ciliarkörpers. Anatom. Anzeiger, Bd. 8, pag. 555 (1893).
- (5) ——— Untersuchungen über die Natur der Zonula ciliaris. Archiv. f. mikroskopische Anatomie, Bd. 50, Heft 4 (1897).
- (6) ——— Über die Nerven der Sklera. Archiv f. mikroskopische Anatomie, Bd. 63, pag. 701 (1904).
- (7) ALBRAND UND SCHRÖDER, Das Verhalten der Pupille im Tode. Halle 1905.
- (8) ARNOLD, Über die Nerven und das Epithelium der Iris. Virchows Archiv, Bd. 27, pag. 345.
- (9) ASAYAMA, Zur Anatomie des Ligamentum pectinatum. v. Graefes Archiv, Bd. 53, pag. 113 (1901).
- (10) AXENFELD, Über intrasklerale Nervenschleifen. Bericht ü. d. 30. Versamml. d. ophthalm. Gesellsch. in Heidelberg 1902, pag. 134.
- (11) ——— Accessorische episklerale Ciliarganglien. Bericht ü. d. 34. Versamml. d. ophthalm. Gesellsch. in Heidelberg 1907, pag. 300.
- (12) AXENFELD UND YAMASCHITA, Präparat einer Strudelveue am hinteren Pole eines emmetropischen Auges. Bericht ü. d. 28. Versamml. d. ophthalm. Gesellsch. in Heidelberg 1900, pag. 194.
- (13) BACH, Die Nervenzellenstruktur der Netzhaut im normalen und pathologischen Zustande. v. Graefes Archiv, Bd. 41, Abt. 3, pag. 62 (1895).
- (14) BALLOWITZ, Zur Kenntnis der Hornhautzellen des Menschen und der Säugetiere. v. Graefes Archiv, Bd. 49, Abt. 1, pag. 8 (1899).
- (15) BARABASCHEW, Beitrag zur Anatomie der Linse. v. Graefes Archiv, Bd. 38, Abt. 3, pag. 1 (1892).
- (16) BARTELS, Die fibrilläre Struktur der Ganglienzellen der Netzhaut. Zeitschr. f. Augenheilk., Bd. 11, pag. 296 (1904).
- (17) ——— Über Primitivfibrillen in den Axenzylindern des Nervus opticus und über die Wertung variköser Axenzylinder. Archiv f. Augenheilk., Bd. 59, pag. 168 (1908).
- (18) BECKER, Über den Wirbel und den Kernbogen in der menschlichen Linse. Archiv f. Augenheilk., Bd. 12, pag. 127 (1883).
- Zur Anatomie der gesunden und kranken Linse, Wiesbaden 1883.
- (19) BENDA, Über den feineren Bau der glatten Muskelfasern des Menschen. Anatom. Anzeiger, Bd. 21, Ergänzungsheft pag. 214 (1902).
- (20) BERGER, Beiträge zur Anatomie der Zonula Zinnii. v. Graefes Archiv, Bd. 28, Abt. 2, pag. 28 (1882).
- (21) BERGER, Beiträge zur Anatomie des Auges im normalen und pathologischen Zustande. Wiesbaden 1887.
- (22) BERNHEIMER, Entwicklung und Verlauf der Markfasern im Chiasma nervorum opticorum des Menschen. Archiv f. Augenheilk., Bd. 20, pag. 133 (1889).
- (23) ——— Die Wurzelgebiete der Augennerven in GRAEFE-SÄMISCH, Handbuch d. ges. Augenheilk., 2. Aufl., Bd. 1, I. Teil, Kap. VI (1900).

- (24) BIETTI, Le fibre nervose della coroidea studiate col metodo di Golgi, *Annali di Ottalm.* Bd. 26, pag. 330; *HIRSCHBERGS Zentralbl. f. pr. Augenheilk.*, 21. Jahrg., pag. 523 (1897).
- (25) BIRCH-HIRSCHFELD, Beitrag zur Kenntnis der Netzhautganglienzellen unter physiologischen und pathologischen Verhältnissen. v. *Graefes Archiv*, Bd. 50, pag. 166 (1900).
- (26) BLOCH, Über abnormen Verlauf der Papillengefäße. *Klin. Monatsbl. f. Augenheilk.*, 44. Jahrg., II, pag. 413 (1906).
- (27) BRIBACH, Über den Zentralkanal des Glaskörpers. v. *Graefes Archiv*, Bd. 76, pag. 203 (1910).
- (28) BRUCKNER, Über Persistenz von Resten der Tunica vasculosa lentis. *Arch. f. Augenheilk.*, Bd. 56, Ergänzungsheft pag. 5 (1907).
- (29) CALDERARO, Recherche embriologique, anatomique e cliniche sulla persistenza dei tessuti jaloidei nell' occhio umano adulto. XI. intern. ophthalm. Kongress, Neapel 1909, pag. 468.
- (30) CAMPOS, La portion réfléchie de la membrane hyaloïde. *Archives d'Ophthalm.*, Bd. 18, pag. 748 (1898).
- (31) CHEVALLEREAU ET POLACK, De la coloration jaune de la macula. *Annal. d'Oculist*, Bd. 138, pag. 241 (1907).
- (32) CHIEVITZ, Die Area und Fovea centralis retinae beim menschlichen Fötus. *Intern. Monatsschr. f. Anatomie u. Physiologie*, Bd. 4, pag. 201 (1887).
- (33) CIRINCIONE, Über die Entwicklung der Capsula perilenticularis. *Archiv f. Anatomie u. Physiologie, Anatom. Abteil.* 1897, Supplementband pag. 170.
- (34) CZERMAK, Zur Zonulafrage. v. *Graefes Archiv*, Bd. 31, Abt. 1, pag. 79 (1885).
- (35) ———— Beitrag zur Kenntnis der sogenannten cilioretinalen Gefäße. *Wiener klinische Wochenschr.* 1888, Nr. 11.
- (36) ———— Einiges zur Lehre von der Entstehung und dem Verlaufe des prodromalen und akuten Glaukomanfalles. *Prager medizinische Wochenschr.* 1897.
- (37) DEDEKIND, Beiträge zur Entwicklungsgeschichte der Augengefäße des Menschen. *Anatomische Hefte*, Bd. 38, pag. 1 (1909).
- (38) DEYL, Über den Eintritt der Arteria centralis retinae in den Sehnerven beim Menschen. *Anatom. Anzeiger*, Bd. 11, pag. 687 (1896).
- (39) DIMMER, Die ophthalmoskopischen Lichtreflexe der Netzhaut. Leipzig und Wien 1891.
- (40) ———— Beiträge zur Anatomie und Physiologie der Macula lutea des Menschen. Leipzig und Wien 1894.
- (41) ———— Démonstration von Photogrammen nach Schnittpräparaten durch die Fovea. Bericht ü. d. 30. Versamml. d. ophthalm. Gesellsch. in Heidelberg 1902, pag. 362.
- (42) ———— Die Macula lutea der menschlichen Netzhaut und die durch sie bedingten entoptischen Erscheinungen. v. *Graefes Archiv*, Bd. 65, pag. 486 (1907).
- (43) DOGIEL, Die Nerven der Cornea des Menschen. *Anatom. Anzeiger*, Bd. 5, pag. 483 (1890).
- Die Nervenendkörperchen (Endkolben, W. Krause) in der Cornea und Conjunctiva bulbi des Menschen. *Archiv f. mikroskop. Anatomie*, Bd. 37, pag. 602 (1891).
- (44) ———— Zur Frage über den Bau der Nervenzellen. *Archiv f. mikroskop. Anatomie*, Bd. 41, pag. 62 (1893).
- (45) DONDERS, Die Grenzen des Gesichtsfeldes in Beziehung zu denen der Netzhaut. v. *Graefes Archiv*, Bd. 23, Abt. 2, pag. 255 (1877).
- (46) DRUALT, Appareil de la vision, in POIRIER ET CHARPY, *Traité d'anatomie humaine*, Tome V.
- (47) DUB, Beitrag zur Kenntnis der Cataracta zonularis. v. *Graefes Archiv*, Bd. 37, Abt. 4, pag. 26 (1891).
- (48) v. EBNER, Untersuchungen über die Ursachen der Anisotropie organisierter Substanzen. Leipzig 1882—nach H. VIRCHOW (233).



- (49) ELSCHNIG, Optico-ciliares Gefäß. Archiv f. Augenheilk., Bd. 18, pag. 295 (1888).
- (50) ——— Cilio-retinale Gefäße. v. Graefes Archiv, Bd. 44, Abt. 1, pag. 144 (1897).
- (51) ——— Über optico-ciliare Gefäße. Klin. Monatsbl. f. Augenheilk., 36. Jahrg., pag. 93 (1898).
- (52) ——— Der normale Sehnerveneintritt des menschlichen Auges. Denkschr. d. mathem.-naturw. Klasse d. k. Akademie d. Wissensch. in Wien, Bd. 70 (1900).
- (53) ——— Histologische Artefakte im Sehnerven. Klin. Monatsbl. f. Augenheilk., 40. Jahrg., Bd. II, pag. 81 (1902).
- (54) ——— Bemerkungen über die Refraktion der Neugeborenen. Zeitschr. f. Augenheilk., Bd. 11, pag. 10 (1905).
- (55) ELSCHNIG UND LAUBER, Über die sogenannten Klumpenzellen der Iris. v. Graefes Archiv, Bd. 65, pag. 428 (1907).
- (56) ELZE, Beschreibung eines menschlichen Embryo von zirka 7 mm grösster Länge. Anatom. Hefte, Bd. 35, pag. 409 (1908).
- (57) EMBDEN, Primitivfibrillenverlauf in der Netzhaut. Archiv f. mikroskop. Anatomie, Bd. 57 (1901).
- (58) EWING, Über ein Bauverhältnis des Irisumfangs beim Menschen. v. Graefes Archiv, Bd. 34, Abt. 3, pag. 1 (1888).
- (59) FORSMARK, Zur Kenntnis der Irismuskulatur des Menschen; ihr Bau und ihre Entwicklung. Mitteilungen aus der Augenklinik d. Carol. medico-chirurg. Inst. in Stockholm, Heft 7 (1905).
- (60) FREYTAG, Über den Einfluss der Linsenveränderungen auf die Refraktion des Auges. Archiv f. Augenheilk., Bd. 54, pag. 328 (1906).
- (61) ——— Vergleichende Untersuchungen über die Brechungsindices der Linse und der flüssigen Augenmedien des Menschen und der höheren Tiere in verschiedenen Lebensaltern. Wiesbaden 1907.
- (62) FRIDENBERG, Über die Figur des Linsensternes beim Menschen und einigen Wirbeltieren. Archiv f. Augenheilk., Bd. 31, pag. 293 (1895).
- (63) FRITSCH, Vergleichende Untersuchungen menschlicher Augen. Sitzungsber. d. kgl. preusz. Akademie d. Wissensch., Bd. 30, pag. 636—Anatom. Anzeiger, Bd. 30, pag. 462 (1907)—Verhandlungen d. anatom. Gesellsch., 22. Versamml., pag. 141 (1908).
- (64) FRITZ, Über den Verlauf der Nerven im vorderen Augenabschnitte. Sitzungsber. d. mathem.-naturw. Klasse d. k. Akademie d. Wissensch. in Wien. Bd. 113, pag. 273.
- (65) FUCHS, E., Beiträge zur normalen Anatomie des Augapfels. v. Graefes Archiv, Bd. 30, Abt. 4, pag. 1 (1884).
- (66) ——— Die periphere Atrophie des Sehnerven. v. Graefes Archiv, Bd. 31, Abt. 1, pag. 177 (1885).
- (67) ——— Beiträge zur normalen Anatomie der menschlichen Iris. v. Graefes Archiv, Bd. 31, Abt. 3, pag. 39 (1885).
- (68) ——— Über Komplikationen der Heterochromie. Zeitschr. f. Augenheilk., Bd. 15, pag. 191 (1906).
- (69) ——— Lehrbuch der Augenheilkunde. 12. Aufl. Wien und Leipzig 1910.
- (70) FUKALA, Was ist die Aufgabe des Brückeschen Muskels? Archiv f. Augenheilk., Bd. 36, pag. 65 (1898).
- (71) FUSZ, Zur Frage des elastischen Gewebes im normalen und myopischen Auge. Virchows Archiv, Bd. 183, pag. 465 (1906).
- (72) GARNIER, Über den normalen und pathologischen Zustand der Zonula Zinnii. Archiv f. Augenheilk., Bd. 24, pag. 32 (1891).
- (73) GARTEN, Die Veränderungen der Netzhaut durch Licht, in GRAEFE-SAEMISCH, Handbuch d. ges. Augenheilk., 2. Aufl., I. Teil, Kap. XII, Anhang pag. 72 (1908).
- (74) GREEFF, Das Wesen der sogenannten Fuchsschen Atrophie des Sehnerven. IX. internat. ophthalm. Kongress, Utrecht 1899, pag. 87.

- (75) ——— Mikroskopische Anatomie des Sehnerven und der Netzhaut, in GRAEFE-SAEMISCH, Handbuch d. ges. Augenheilk., 2. Aufl., I. Teil, Bd. I, Kap. V (1900).
- (76) ——— Über eine Fovea externa in der Retina des Menschen. Bericht ü. d. 30. Versamml. d. ophthalm. Gesellsch. in Heidelberg 1902, pag. 160.
- (77) GROD, Über die Dauerresultate der Operationen bei angeborenem Star. Arch. f. Augenheilk., Bd. 67, pag. 251 (1910).
- (78) GROENOUW, Intrasklerale Nervenschleifen. Klin. Monatsbl. f. Augenheilk., 43. Jahrg., Bd. I, pag. 637 (1905).
- (79) GRUNERT, Der Dilator pupillae des Menschen, ein Beitrag zur Anatomie und Physiologie der Irismuskulatur. Archiv f. Augenheilk., Bd. 36, pag. 319 (1898).
- (80) GRYNFELT, Le muscle dilatateur de la pupille. Montpellier 1899.
- (81) GULLSTRAND, Die Farbe der Macula centralis retinae. v. Graefes Archiv, Bd. 62, pag. 1 (1905).
- (82) GUTMANN, Zur Histologie der Ciliarnerven. Archiv f. mikroskop. Anatomie, Bd. 49, pag. 1 (1897).
- (83) ——— Über kollagenes und protoplasmatisches Gewebe der menschlichen Iris. Zeitschr. f. Augenheilk., Bd. 10, pag. 8 (1903).
- (84) HAHN, Untersuchungen über den histologischen Bau der Ciliarnerven. Wiener klinische Wochenschr. 1897, pag. 714.
- (85) HALBEN, Ein Differentialrefraktometer zur Bestimmung der Brechungsindices optisch inhomogener Medien, speziell der menschlichen Linse. Bericht ü. d. 32. Versamml. d. ophthalm. Gesellsch. in Heidelberg 1905, pag. 354.
- (86) HAMBURGER, Besteht freie Kommunikation zwischen vorderer und hinterer Augenkammer? Zentralbl. f. pr. Augenheilk., 22. Jahrg., pag. 225 (1898).
- (87) HANNOVER, Funiculus scleroticae, un reste de la fente foetale dans l'oeil humain. Kopenhagen 1876—NAGELS Jahresbericht f. 1876.
- (88) HEERFORDT, Studien über den Musculus dilatator pupillae. Anatom. Hefte, Bd. 14, pag. 487 (1900).
- (89) HEINE, Beiträge zur Physiologie und Pathologie der Linse. v. Graefes Archiv, Bd. 46, pag. 525 (1898).
- (90) ——— Die Anatomie des akkommodierten Auges. v. Graefes Archiv, Bd. 49, pag. 1 (1899).
- (91) ——— Beiträge zur Anatomie des myopischen Auges. Archiv. f. Augenheilk., Bd. 38, pag. 277 (1899).
- (92) ——— Demonstration des Zapfenmosaiks der menschlichen Fovea. Bericht ü. d. 29. Versamml. d. ophthalm. Gesellsch. in Heidelberg 1901, pag. 265.
- (93) HELD, Zur weiteren Kenntnis der Nervendfüsse und zur Struktur der Sehzellen. Abhandlg. d. mathem.-physikal. Klasse d. k. sächs. Gesellsch. d. Wissensch., Nr. 2, pag. 145—NAGELS Jahresbericht f. 1904, pag. 23 (1904).
- (94) HENLE, Eingeweidelehre, Braunschweig 1866.
- (95) HERZOG, Über die Entwicklung der Binnenmuskulatur des Auges. Archiv f. mikroskop. Anatomie, Bd. 60 (1902).
- (96) HESS, Arbeiten aus dem Gebiete der Akkommodationslehre. v. Graefes Archiv, Bd. 42, Heft 1, pag. 288 (1895).
- (97) ——— Pathologie und Therapie des Linsensystems in GRAEFE-SAEMISCH, Handbuch d. ges. Augenheilk., 2. Aufl., II. Teil, Bd. VI, 2. Abteil., Kap. IX (1905).
- (98) ——— Über Blaublicht durch Gelbfärbung der Linse. Archiv f. Augenheilk., Bd. 61, pag. 29 (1908).
- (99) ——— Die Akkommodation bei Tauchervögeln. Archiv f. vergleichende Ophthalm., Bd. I, pag. 153 (1910).
- (100) HESS, Beiträge zur Kenntnis akkommodativer Änderungen im menschlichen Auge. v. Graefes Archiv, Bd. 65, pag. 170 (1910).

- (101) ——— Über individuelle Verschiedenheiten des normalen Ciliarkörpers. Archiv f. Augenheilk., Bd. 67, pag. 341 (1910).
- (102) v. HIPPEL, E., Über das normale Auge des Neugeborenen. v. Graefes Archiv, Bd. 45, pag. 286 (1898).
- (103) HIRSCH, Ist die fötale Hornhaut vaskularisiert? Klin. Monatsbl. f. Augenheilk., 44. Jahrg., Bd. II, pag. 13 (1906).
- (104) HIRSCHBERG, Beiträge zur Anatomie und Pathologie des Auges. Archiv f. Augenheilk., Bd. 8, pag. 49 (1879).
- (105) HIS, Abbildungen über das Gefäß-System der menschlichen Netzhaut und derjenigen des Kaninchens. Archiv f. Anatomie u. Physiologie, anatom. Abteil. 1880, pag. 224.
- (106) HOSCH, Das Epithel der vorderen Linsenkapsel. v. Graefes Archiv, Bd. 20, Heft 1, pag. 83 (1874) und Bd. 52, pag. 484 (1901).
- (107) HOYER, Über die Nerven der Hornhaut. Archiv f. mikroskopische Anatomie, Bd. 9, pag. 220 (1873).
- (108) v. JAEGER, E., Über die Einstellungen des dioptrischen Apparates im menschlichen Auge. Wien 1861—nach WEISS (235).
- (109) JAKOBY, Über die Neuroglia des Sehnerven. Klin. Monatsbl. f. Augenheilk., 43. Jahrg., Bd. I, pag. 129 (1905).
- (110) JEANNELATOS, Recherches embryologiques sur le mode de formation de la chambre antérieure chez les mammifères et l'homme. Thèse de Paris 1896—nach SEEFELDER (203)
- (111) ISCHREY, Über den Faserbündelverlauf in der Lederhaut des Menschen. v. Graefes Archiv, Bd. 48, pag. 506 (1899).
- (112) JUSÉLIUS, Die Entwicklung des hinteren Pigmentepithels der Iris aus der sekundären Augenblase und sein Verhältnis zur Irismuskulatur und den spontanen Iriszysten. Klin. Monatsbl. f. Augenheilk., 46. Jahrg., Bd. II, pag. 19 (1908).
- (113) IWANOFF, Beiträge zur normalen und pathologischen Anatomie des Auges. v. Graefes Archiv, Bd. 11, Abt. 1, pag. 135 (1865).
- (114) ——— Beiträge zur Anatomie des Ciliarmuskels. v. Graefes Archiv, Bd. 15, Abt. 3, pag. 284 (1869).
- (115) ——— Der Uvealtraktus in GRAEFE-SAEMISCH, Handbuch d. ges. Augenheilk., 1. Aufl., Bd. 1, Kap. III (1874).
- (116) KEIBEL, Normentafeln zur Entwicklungsgeschichte des Menschen, Heft 8. Jena 1908.
- (117) KERSCHBAUMER, R., Über Altersveränderungen der Uvea. v. Graefes Archiv, Bd. 34, Abt. 4, pag. 16 (1888) und Bd. 38, Abt. 1, pag. 127 (1892).
- (118) KIRIBUCHI, Über die Fuchssche periphere Atrophie des Sehnerven. Archiv f. Augenheilk., Bd. 39, pag. 76 (1899).
- (119) KOGANEI, Untersuchungen über den Bau der Iris des Menschen und der Wirbeltiere. Archiv f. mikroskop. Anatomie, Bd. 25, pag. 1 (1885).
- (120) KÖLLIKER, Handbuch der Gewebelehre des Menschen. Bd. 3, bearbeitet von v. EBNER, 1902.
- (121) KÖNIGSTEIN, Histologische Notizen, IV. Das Wachstum des embryonalen Auges. v. Graefes Archiv, Bd. 30, Abt. 1, pag. 135 (1884).
- (122) KRAUSE, Die Nerven der Arteria centralis retinae. v. Graefes Archiv, Bd. 21, Abt. 1, pag. 296 (1875).
- (123) KRÜCKMANN, Über Pigmentierung und Wucherung der Netzhautneuroglia. v. Graefes Archiv, Bd. 60, pag. 350 und 452 (1905).
- (124) ——— Über die Entwicklung und Ausbildung der Stützsubstanz im Sehnerven und der Netzhaut. Klin. Monatsbl. f. Augenheilk., 44. Jahrg., Bd. I, pag. 162 (1906).
- (125) ——— Erkrankungen der Uvea, in AXENFELD, Lehrbuch der Augenheilkunde. Jena 1909.
- (126) KÜHNE, in HERMANN'S Handbuch der Physiologie, Bd. 3.



- (127) KUHNT, Zur Kenntnis des Pigmentepithels. Zentralblatt f. d. medicin. Wissensch. 1877, pag. 337.
- (128) ——— Zur Architektonik der Retina. Bericht ü. d. 10. Versamml. d. ophthalm. Gesellsch. in Heidelberg 1877 in klin. Monatsbl. f. Augenheilk., 15. Jahrg., Beilageheft pag. 72.
- (129) ——— Zur Kenntnis des Sehnerven und der Netzhaut. v. Graefes Archiv, Bd. 25, Abt. 3, pag. 179 (1897).
- (130) ——— Über den Bau der Fovea centralis des Menschen. Bericht ü. d. 13. Versamml. d. ophthalm. Gesellsch. in Heidelberg 1881, in klin. Monatsbl. f. Augenheilk., 19. Jahrg., Beilageheft pag. 141.
- (131) ——— Über einige Altersveränderungen im menschlichen Auge. Ibidem pag. 38.
- (132) KUSCHEL, Die Architektur des Auges und ihre hydrostatischen Beziehungen zum intraokularen Stromgefälle. Zeitschr. f. Augenheilk., Bd. 17, pag. 114 (1907).
- (133) LANG AND BARRETT, On the frequency of cilio-retinal vessels. Ophthalm. Hosp. Reports, Vol. 12, p. 59 (1888).
- (134) LANGE, Vorzeigung infantiler Netzhautpräparate. Bericht ü. d. 23. Versamml. d. ophthalm. Gesellsch. in Heidelberg 1893, pag. 236.
- (135) ——— Zur Anatomie des Auges des Neugeborenen. Klin. Monatsbl. f. Augenheilk., 39. Jahrg., pag. 1, 202 (1901).
- (136) LANGER, Ist man berechtigt, den Perichoroidalraum und den Tenonschen Raum als Lymphräume aufzufassen? Sitzungsber. d. mathem.-naturw. Klasse der k. Akad. d. Wissensch. in Wien, Oktober 1890, Bd. 99, Heft 3.
- (137) LAUBER, Beiträge zur Entwicklungsgeschichte und Anatomie der Iris und des Pigmentepithels der Netzhaut. v. Graefes Archiv, Bd. 68, pag. 1 (1908).
- (138) LEBER, TH., Die Zirkulations- und Ernährungsverhältnisse des Auges, in GRAEFE. SAEMISCH, Handbuch der ges. Augenheilk., 2. Aufl., I. Teil, Bd. 2, XI. Kap. (1903).
- (139) LÉBOUCQ, Contribution à l'étude de la rétine chez les mammifères. Arch. d'Anatomie microscop. 1909, pag. 155—NAGELS Jahresbericht f. 1909, pag. 7.
- (140) v. LENHOSSÉK, Die Entwicklung des Glaskörpers. Leipzig 1903.
- (141) DE LIETO VOLLARO, Sulla esistenza nella cornea di fibre elastiche colorabili col metodo di Weigert. Loro derivazione dai corpuscoli fissi. Annali di Ottalm. 1907, pag. 713.
- (142) ——— Sulla morfologia della membrana dilatatrice della pupilla dell' uomo Annali di Ottalm., Bd. 37, pag. 301 (1908)—NAGELS Jahresber. f. 1908, pag. 16.
- (143) ——— Il tessuto elastico nell' iride dell' uomo adulto e di alcune specie di vertebrati. Archiv f. vergl. Ophthalm., 1. Jahrg., pag. 49 (1910).
- (144) LOHMANN, Über die typische Exzentrizität des kleinen Irisringes. . . . Klin. Monatsbl. f. Augenheilk., 44. Jahrg., Bd. II, pag. 68 (1906).
- (145) LÖWENSTEIN, Über regionäre Anästhesie in der Orbita. Klin. Monatsbl. f. Augenheilk., 46. Jahrg., Bd. I., pag. 592 (1908).
- (146) MAGNUS, Über Blasenbildung am Linsenäquator. Klin. Monatsbl. f. Augenheilk., 29. Jahrg., pag. 291 (1891).
- (147) MARX, Die Ursache der roten Farbe des normalen ophthalmoskopisch beobachteten Augenhintergrundes. v. Graefes Archiv, Bd. 71, pag. 141 (1909).
- (148) MATTHIESSEN, Über das Gesetz der Zunahme der Brechungsindices innerhalb der Kristalllinse der Säugetiere und Fische. v. Graefes Archiv, Bd. 31, Abt. 2, pag. 31 (1885).
- (149) MELLER, Über hyaline Degeneration des Pupillarrandes. v. Graefes Archiv, Bd. 59, pag. 221 (1904).
- (150) ——— Die histologischen Veränderungen des Auges bei Keratitis disciformis. Klin. Monatsbl. f. Augenheilk., 43. Jahrg., Bd. II, pag. 335 (1905).
- (151) MERKEL UND KALLIUS, Mikroskopische Anatomie des Auges, in GRAEFE-SAEMISCH, Handbuch d. ges. Augenheilk., 2. Aufl., I. Teil, Bd. I, Kap. I (1901).
- (152) MERKEL UND ORR, Das Auge des Neugeborenen an einem schematischen Durchschnitte erörtert. Anatom. Hefte, Bd. 1, pag. 271 (1892).



- (153) MEYER, A., Die Nervenendigungen in der Iris. *Archiv. f. mikroskop. Anatomie*, Bd. 17, pag. 324 (1879).
- (154) MICHAELIS, Altersbestimmung menschlicher Embryonen. *Archiv f. Gynäkologie*, Bd. 78, pag. 267 (1906).
- (155) MICHEL, Über Iris und Iritis. *v. Graefes Archiv*, Bd. 27, Abt. 2, pag. 171 (1881).
- (156) MÜLLER, HEINR., Anatomische Beiträge zur Ophthalmologie. *v. Graefes Archiv*, Bd. 2, Abt. 2, pag. 1 (1855).
- (157) ——— Anatomische Beiträge zur Ophthalmologie. *v. Graefes Archiv*, Bd. 3, pag. 1 (1857).
- (158) ——— Anatomisch-physiologische Untersuchungen über die Retina des Menschen und der Wirbeltiere. *Zeitschr. f. wissensch. Zoologie*, Bd. 8, pag. 1 (1857)—GREEFF (75).
- (159) ——— Über glatte Muskelfasern und Nervengeflechte der Chorioidea im menschlichen Auge. *Verhandl. d. Würzburg. physik.-mediz. Gesellsch.*, Bd. X, Heft 2 und 3, pag. 179.—*Gesammelte Schriften*, pag. 201.
- (160) MÜNCH, Über die muskulöse Natur des Stromazellnetzes der Uvea. *Zeitschr. f. Augenheilk.*, Bd. 12, pag. 525 (1904).
- (161) ——— Zur Anatomie des Dilator pupillae. *Zeitschr. f. Augenheilk.*, Bd. 13, pag. 1 (1905).
- (162) ——— Über die Innervation der Stromazellen der Iris. *Zeitschr. f. Augenheilk.*, Bd. 14, pag. 130 (1905).
- (163) NAGEL, Hochgradige Amblyopie, bedingt durch glashäutige Wucherungen and kristallinische Kalkablagerungen an der Innenfläche der Aderhaut. *Klin. Monatsbl. f. Augenheilk.*, 13. Jahrg., pag. 338 (1875).
- (164) NAITO, Ein Beitrag zur Kenntnis der intraskleralen Nervenschleifen. *Klin. Monatsbl. f. Augenheilk.*, 40. Jahrg., Bd. II, pag. 122 (1902)
- (165) NETTLESHIP, Cilio-retinal blood-vessels. *Ophthalm. Hosp. Rep.*, Vol. 8, p. 512 and Vol. 9, p. 161 (1877).
- (166) NUEL, De la vascularisation de la choroïde et de la nutrition de la rétine principalement au niveau de la fovea centralis. *Arch. d'Ophthalm.*, Bd. 12, pag. 70.
- (167) OELLER, Atlas der Ophthalmoskopie 1897, A, Taf. IV, 3. Lieferung.
- (168) PASSERA, La rete vascolare sanguigna della membrana coriocalpillare dell' uomo. *Ric. nel Laboratorio di Anat. della R. Univers. di Roma*, V., pag. 133 (1896).
- (169) PAUSE, Über die Nerven der Iris. *v. Graefes Archiv*, Bd. 23, Abt. 3, pag. 1 (1877).
- (170) PES, Über einige Besonderheiten in der Struktur der menschlichen Cornea. *Archiv f. Augenheilk.*, Bd. 55, pag. 293 (1906).
- (171) ——— Sulla fina anatomia della sclerotica. *Annali di Ottalm.*, Bd. 37, pag. 331—NAGELS Jahresbericht f. 1908.
- (172) v. PFLUGK, Die Fixierung der Wirbeltierlinsen, insbesondere der Linse des neugeborenen Menschen. *Klin. Monatsbl. f. Augenheilk.*, 47. Jahrg., Bd. II, pag. 1 (1909).
- (173) PRIESTLEY-SMITH, On the growth of the crystalline lens. *Transactions of the Ophth. Soc. of the U.K.*, Vol. 3, p. 79 (1883).
- (174) ——— On the size of the cornea in relation to age, sex, refraction and primary glaucoma. *Transactions of the Ophth. Soc. of the U. K.*, Vol. 10, p. 68 (1891).
- (175) RABL, Über den Bau und die Entwicklung der Linse (3. Teil), *Zeitschr. f. wissensch. Zoologie*, Bd. 67, Heft 1 (1890).
- (176) RAEHLMANN, Zur Anatomie und Physiologie des Pigmentepithels der Netzhaut. *Zeitschr. f. Augenheilk.*, Bd. 17, pag. 1 (1907).
- (177) v. RECKLINGHAUSEN, Die Lymphgefäße und ihre Beziehung zum Bindegewebe. Berlin 1862—W. VIRCHOW (233).
- (178) REIMAR, Über die ophthalmoskopische Sichtbarkeit der Ora serrata und der Processus ciliares. *Archiv f. Augenheilk.*, Bd. 41, pag. 102 (1900).
- (179) RETZIUS, Zur Kenntnis vom Bau der Iris. *Biologische Untersuchungen*, N.F., Bd. 5 (1893).

(180) ——— Über den Bau des Glaskörpers und der Zonula Zinnii in dem Auge des Menschen und einiger Tiere. *Biolog. Untersuch.* N.F., Bd. 6, pag. 67 (1894).

(181) v. REUSZ, Untersuchungen über den Einfluss des Lebensalters auf die Krümmung der Hornhaut nebst einigen Bemerkungen über die Dimensionen der Lidspalte. *v. Graefes Archiv*, Bd. 27, Abt. 1, pag. 27 (1881).

(182) ROCHON-DUVIGNEAUD, Recherches anatomiques sur l'angle de la chambre antérieure et le canal de Schlemm. *Archives d'Ophthalm.*, Bd. 12, pag. 732 und Bd. 13, pag. 20, 108.

(183) SALZMANN, Durchschnitt durch das menschliche Auge. *Augenärztliche Unterrichtstafeln*, herausgeg. v. H. MAGNUS, Breslau 1899, Heft 18.

(184) ——— Die Zonula ciliaris und ihr Verhältnis zur Umgebung. Wien u. Leipzig 1900.

(185) ——— Über die pathologische Anatomie und die Pathologie des Keratokonus. *v. Graefes Archiv*, Bd. 67, pag. 1 (1907).

(186) SAPPEY, after FRANK BAKER, The anatomy of the eyeball, in NORRIS AND OLIVER, *System of disease of the eye*. Philadelphia 1897, Vol. I, p. 113.

(187) SATTLER, Über den feineren Bau der Chorioidea des Menschen, nebst Beiträgen zur pathologischen und vergleichenden Anatomie der Aderhaut. *v. Graefes Archiv*, Bd. 22, Abt. 2, pag. 1 (1876).

(188) ——— Anatomische und physiologische Beiträge zur Akkommodation. Bericht ü. d. 19. Versamml. d. ophthalm. Gesellsch. in Heidelberg 1887, pag. 3.

(189) SCHAAFF, Der Zentralkanal des Glaskörpers. *v. Graefes Archiv*, Bd. 67, pag. 58; Bd. 71, pag. 186 und Bd. 75, pag. 200 (1908 bis 1910).

(190) SCHNABEL UND HERRENHEISER, Über Staphyloma posticum, Conus und Myopie. *Zeitschr. f. Heilkunde*, Bd. 16 (1895).

(191) SCHOCK, Die Endausbreitung des Nervus sympathicus in der Iris. *Archiv f. vergl. Ophthalm.*, 1. Jahrg., pag. 293 (1910).

(192) SCHOEN, Die Funktionskrankheiten des Auges. Wiesbaden 1893.

(193) ——— Die Funktionskrankheiten der Ora serrata und des Ciliarteiles der Netzhaut. *Archiv f. Augenheilk.*, Bd. 30, pag. 128 (1895)—Separatdruck. Wiesbaden 1895.

(194) SCHWALBE, *Lehrbuch der Anatomie des Auges*. Erlangen 1887.

(195) SCHWEIGGER, Über die Ganglienzellen und blassen Nerven der Chorioidea. *v. Graefes Archiv*, Bd. 6, Abt. 2, pag. 320 (1860).

(196) SCHULTZE, F. E., Der Ciliarmuskel des Menschen. *Archiv f. mikroskop. Anatomie*, Bd. 3 (1867).

(197) SCHULTZE, O., Mikroskopische Anatomie der Linse und des Strahlenbändchens, in GRAEFE-SAEMISCH, *Handbuch d. ges. Augenheilk.*, 2. Aufl., I. Teil, Bd. I, Kap. IV (1900).

(198) ——— Über die Entwicklung und Bedeutung der Ora serrata des menschlichen Auges. *Verh. der physik.-medizin. Gesellsch. in Würzburg*, N.F., Bd. 34, pag. 131 (1902).

(199) SEEFELDER, Weitere Demonstration embryonaler menschlicher Augen. Bericht ü. d. 35. Versamml. d. ophthalm. Gesellsch. in Heidelberg 1908, pag. 312.

(200) ——— Über die Entwicklung der physiologischen Exkavation des Sehnerveneintrittes beim Menschen. XI. internat. ophthalm. Kongress, Neapel 1909, pag. 491.

(201) ——— Untersuchungen über die Entwicklung der Netzhautgefäße des Menschen. *v. Graefes Archiv*, Bd. 70, pag. 448 (1909).

(202) ——— Über die elastischen Fasern der menschlichen Cornea, dargestellt nach der Färbemethode von HELD. *v. Graefes Archiv*, Bd. 73, pag. 188 (1909).

(203) ——— Beiträge zur Histogenese und Histologie der Netzhaut. *v. Graefes Archiv*, Bd. 73, pag. 419 (1910).

(204) ——— Das Verhalten der Kammerbucht und ihres Gerüstwerkes vor der Geburt, in GRAEFE-SAEMISCH, *Handbuch der ges. Augenheilk.*, 2. Aufl., I. Teil, Bd. I, Anhang zu Kap. II (1910).

(205) SEEFELDER UND WOLFRUM, Zur Entwicklung der vorderen Kammer und des Kammerwinkels beim Menschen, nebst Bemerkungen über ihre Entstehung bei Tieren. v. Graefes Archiv, Bd. 63, pag. 430 (1906).

(206) SELIGMANN, Augendiagnose und Kurpfuschertum. Berlin 1910.

(207) SIEGRIST, Über wenig bekannte Erkrankungsformen des Sehnerven. Archiv. f. Augenheilk., Bd. 44, Ergänzungsheft, pag. 178 (1901).

(208) SMIRNOW, Zum Baue der Chorioidea propria des erwachsenen Menschen (Stratum elasticum supracapillare). v. Graefes Archiv, Bd. 47, pag. 451 (1899).

(209) ——— Die weisse Augenhaut als Stelle der sensiblen Nervenendigungen. Anatom. Anzeiger, Bd. 18, pag. 76 (1900).

(210) SPEE, GRAF F., Über den Bau der Zonulafasern und ihre Anordnung im menschlichen Auge. Anatom. Anzeiger, Bd. 21, Ergänzungsheft, pag. 236 (1902).

(211) STEIGER, Beiträge zur Physiologie und Pathologie der Hornhautrefraktion. Archiv f. Augenheilk., Bd. 29, pag. 98 (1894).

(212) STILLING, Zur Theorie des Glaucoms. v. Graefes Archiv, Bd. 14, Abt. 3, pag. 259 (1868).

(213) ——— Zur Anatomie des myopischen Auges. Zeitschr. f. Augenheilk., Bd. 14, pag. 23 (1903).

(214) STRAHL, Zur Entwicklung des menschlichen Auges. Anatom. Anzeiger, Bd. 14, pag. 298 (1898).

(215) STRAUB, Beitrag zur Kenntnis des Glaskörpergewebes. v. Graefes Archiv, Bd. 34, Apt. 3, pag. 7 (1888).

(216) Szili, A., Beiträge zur Kenntnis der Anatomie und Entwicklungsgeschichte der hinteren Irisschichten. v. Graefes Archiv, Bd. 53, pag. 459 (1902).

(217) v. Szily, A., Über das Entstehen eines fibrilären Stützgewebes im Embryo und dessen Verhältnis zur Glaskörperfrage. Anatom. Hefte, Heft 107 (1908).

(218) TAKAYASU, Beiträge zur pathologischen Anatomie des Arus senilis. Archiv f. Augenheilk., Bd. 43, pag. 154 (1901).

(219) TANDLER, Über einen menschlichen Embryo vom 38. Tage. Anatom. Anzeiger, Bd. 31, pag. 49 (= KEIBEL, Normentafeln Nr. 42).

(220) TARTUFERI, Über das elastische Hornhautgewebe und über eine besondere Metall-impregnationsmethode. v. Graefes Archiv, Bd. 56, pag. 419 (1903).

(221) TERRIEN, Recherches sur la structure de la rétine ciliaire et l'origine des fibres de la zonule de Zinn. Paris 1898.

(222) TOPOLANSKI, Über den Bau der Zonula und Umgebung, nebst Bemerkungen über das albinotische Auge. v. Graefes Archiv, Bd. 37, Abt. 1, pag. 28 (1891).

(223) ——— Linsenranderhebungen. Klin. Monatsbl. f. Augenheilk. (1892), 30. Jahrg., pag. 89.

(224) TORNATOLA, Sulla membrana limitante interna della retina nei vertebrati. Anatom. Anzeiger, Bd. 24, pag. 536 (1904).

(225) TRANTAS, Moyen d'explorer par l'ophtalmoscope et par translucidité la parti antérieure du fond oculaire, le cercle ciliaire y compris. Archives d'Ophthalm. Juin 1900.

——— Ophthalmoscopie du corps ciliaire. Gazette médicale d'orient, 46. Jahrg., Nr. 9 (1901).

(226) TREACHER COLLINS, The glands of the ciliary body in the human eye. Transactions of the Ophthalm. Soc. of the U.K., Vol. 11, p. 53 (1892).

(227) TSCHERNING, Optique physiologique. Paris 1898.

(228) ——— Hermann v. Helmholtz und die Akkommodationstheorie, übersetzt von Thorey. Leipzig 1910.

(229) ULBRICH, Klinische Beobachtungen über die Druckverhältnisse in der vorderen und hinteren Kammer. Archiv f. Augenheilk., Bd. 60, pag. 283 (1908).

(230) USHER, A note on the chorioid at the macular region. Transactions of the Opth. Soc. of the U.K., Vol. 26, p. 107 (1906).

(231) VERSARI, La morfogenesi dei vasi sanguigni della retina umana. Ricerche fatte nel laboratorio della R. Università di Roma 1904, Bd. 10.

——— Über die Entwicklung der Blutgefäße des menschlichen Auges. Anatom. Anzeiger, Bd. 35, pag. 105 (1909).

(232) VIRCHOW, H., Über die Form der Falten des Corpus ciliare bei Säugetieren. Morpholog. Jahrbücher, Bd. 11, pag. 437—NAGELS Jahresber. f. 1885, pag. 10.

(233) ——— Fächer, Zapfen, Leiste, Polster, Gefäße im Glaskörperraum von Wirbeltieren, in MERKEL UND BONNET, Ergebnisse d. Anatomie und Entwicklungsgeschichte, Bd. 10 (1900).

(234) ——— Mikroskopische Anatomie der äusseren Augenhaut und des Lidapparates, in GRAEFE-SAEMISCH, Handbuch d. ges. Augenheilk., 2. Aufl., I. Teil, Bd. I, Kap. II (1908).

(235) WEISS, L., Über das Wachstum des menschlichen Auges. Anatom. Hefte, Bd. 8, pag. 193 (1897).

(236) WESSELY, Über Versuche am wachsenden Auge. Münch. mediz. Wochenschr. 1909, Nr. 44.

(237) WIDMARK, Über den Musculus dilatator pupillae des Menschen. Mitteil. a. d. Augenlinik d. Carol. med.-chir. Inst. in Stockholm, Heft 3, pag. 25 (1901).

(238) WIEGER, Über den Canalis Petiti und ein Ligamentum hyaloideo-capsulare. Inaug. Dissert. Strassburg 1883.

(239) WOLFRUM, Zur Entwicklung und normalen Struktur des Glaskörpers. v. Graefes Archiv, Bd. 65, pag. 220; Bd. 67, pag. 370 (1907, 1908).

(240) ——— Beiträge zur Anatomie und Histologie der Aderhaut beim Menschen und bei den höheren Wirbeltieren. v. Graefes Archiv, Bd. 67, pag. 307 (1908).

(241) ——— Untersuchungen über die Macula lutea der höheren Säugetiere. Bericht ü. d. 35. Vers. d. ophthalm. Gesellsch. in Heidelberg 1908, pag. 206.

(242) ——— Über den Ursprung und Ansatz der Zonulafasern im menschlichen Auge. v. Graefes Archiv, Bd. 69, pag. 145 (1908).

(243) ZEEMAN, Über die Form der hinteren Linsenfläche. Klin. Monatsbl. f. Augenheilk., 46. Jahrg., I, pag. 83 (1908).

(244) ——— Linsenmessungen und Emmetropisation. v. Graefes Archiv, Bd. 78, pag. 93 (1911).



## EXPLANATION OF PLATE FIGURES

### PLATE I

The iris and the ciliary body with their environment, meridional section; magnification 30.

*Mr* tendon of the musculus rectus medialis, *Es* episcleral tissue, *Co* conjunctiva sclerae, *CS* corneoscleral border, *b* border of Bowman's membrane, *d* Descemet's membrane, *k*, ciliary, *k*<sub>2</sub> pupillary crypts, *f* contraction furrows; *iz* innermost, *cZ* circular, *vZ* anterior, *qZ* middle, *hZ* posterior zonula fibers.

*hG* posterior border layer of the vitreous, *gB* vitreous base, *Z* zonular cleft, *vG* anterior border layer, *Lhc* ligamentum hyaloideo-capsulare, *Gk* vitreous nucleus.

### PLATE II

1. Anterior half of the eye seen from within; magnification 3.

*N* nasal, *T* temporal side, *Os* ora serrata retinae, *Or* orbiculus ciliaris, *Cor* corona ciliaris, *Cl* circumlental space, *L* posterior surface of the lens with the lens star.

2. Emissarium of the lateral long posterior ciliary artery; cross-section, magnification 87.

*A* artery, *M* ciliary nerve.

3. Emissarium of the superior temporal vortex vein; longitudinal section; magnification 23.

*Os* tendon of the musculus obliquus superior, *Te* extension of Tenon's space at the exit of the vein, *V* the lumen of the vortex vein itself, *S* sclera, *Pch* perichoroidal space, *Ch* chorioidea, *P* pigment epithelium.

4. Emissarium of a vortex vein; cross-section somewhat behind the center; magnification 87.

5. Details of the sclera, middle reaches, region of the ciliary body, meridional section; magnification 285.

*A* small artery, surrounded by loose connective tissue, *c* capillary, *q* cross-sectioned, so-called equatorial bundle, *l* longitudinal section, meridional bundle.

6. Anterior layers of the cornea, meridional section; magnification 400.

*Ep* epithelium, *o* superficial, *b* basal cells, *B* Bowman's membrane with a nerve pore, *C* stroma corneae, *s* spaces therein.

7. Elementary lamellae of the stroma corneae; spontaneous dehiscence in meridional section; magnification 450.

*z* a fixed corneal cell, *q* cross-sectioned, *l* longitudinally sectioned, elementary lamellae.

8. Fixed corneal cells seen from the surface, Held's stain; magnification 375.

*w* a wandering cell, *f* elastic fibers.

9. Posterior layers of the cornea, meridional section; magnification 475.

*C* stroma corneae, *s* spaces with fixed cells, *D* Descemet's membrane, *en* endothelium.

10. Details of the trabeculum of the iris angle, inner layers, meridional section; magnification 510.

*i* trabecula of the uveal framework, the upper one cut longitudinally, the lower, cut across; the remaining trabeculae belong to the scleral framework, *b* collagenous connective tissue, *f* elastic fibers, *g* glass membrane, *e* endothelium.

### PLATE III

1. The scleral furrow with its environment, meridional section; magnification 96.

*C* cornea, *D* border of Descemet's membrane, *vG* the anterior border ring, *T* deep root of the scleral framework, *i* uveal framework, *Sch* lumina of the Schlemm's canals, *V* efferent veins of these canals, *Sw* scleral roll, *Pch* beginning of the perichoroidal space, *Mc* musculus ciliaris, *I* iris root.

2. Anterior border of the framework with its roots, surface view, combination picture from teased preparations; magnification 112.

*D* smooth portion of Descemet's membrane and endothelium with plain cell borders, *w* beginning of the wart zone (the warts appear as darker flecks), *vG* anterior border ring, *d* border of Descemet's membrane, *T* deep root of the framework, *i* uveal framework, *Tr* inner reaches of the scleral framework with diagonal spaces, *Tr'* outer reaches of the framework with more roundish spaces.

3. Uveal framework, surface view, teased preparation; magnification 112.

*T* part of the scleral framework, *e* endothelial cells undergoing detachment, *I* transition into the tissue of the iris root.

4. A long posterior ciliary artery with its accompanying nerves in the perichoroidal space, equatorial section; magnification 75.

*Ch* chorioidea, *S* sclera, *A* artery, *m* connective tissue with tiny bundles of smooth muscle-fibers, *N<sub>1</sub>* the larger, *N<sub>2</sub>* the smaller, accompanying nerve.

5. A vortex vein, surface view; magnification 5.

6. Details of the inner reaches of the vessel layer of the chorioidea, teased preparation; magnification 285.

*V* part of a small vein, *e* its endothelium, *p* its perivascular sheath, *a* its adventitia; *A* small artery, *m* its muscle-fibers, *b* connective tissue of the stroma; *ch* chromatophores, *w* wandering cells, *n* nerve-fibers, *g* ganglion cells.

7. Details of the innermost layers of the chorioidea, terrace-form torn border, teased preparation, Held's stain; magnification 430.

*cu* cuticular lamella, *el* elastic lamella of the glass membrane of the chorioidea, *k* lumina of the capillaries, *r* red blood corpuscles therein, *l* a leucocyte, *e* nuclei of the endothelium of the capillary wall, interstices of the capillary layer; the dark points along the contours of the capillaries are the optical cross-sections of the elastic fibrillae, *f* subcapillary fibrillar net, *sc* subcapillary cells.

8. Pigment epithelium of the chorioidea, middle-zone, surface view; magnification 472.

9. Individual pigment granules of the pigment epithelium of the chorioidea; magnification 1,500.

10. Pigment epithelium of the chorioidea from the region of the fovea centralis, surface view; magnification 472.

11. Pigment epithelium of the chorioidea in the neighborhood of the ora serrata retinae, surface view; magnification 472.

#### PLATE IV

1. Ending of Descemet's membrane, and the anterior border of the trabeculum of a 53-year-old man, meridional section; magnification 300.

*C* stroma corneae, *T* deep root of the trabeculum, *D* Descemet's membrane, *w* its warts, *d* its border, *vG* anterior border ring, *En* endothelium of the cornea, *i* a fiber of the uveal trabeculum.

2. Elements of the suprachorioidea, teased preparation, staining with Mallory's phosphomolybdic-acid hematoxylin; magnification 300.

*ch* chromatophores, *f* elastic fibers, *e* endothelial nuclei, *n* branch of a nerve with a ganglion cell.

3. Chorioidea and retina nasal to the optic-nerve entrance, meridional section; magnification 286.

*S* sclera, *Su* suprachorioidea, *Gf* vessel layer of the chorioidea, *A* artery, *V* small vein, emptying at right angles into the choriocapillaris *C*, *Lv* lamella vitrea chorioideae, *P* pigment epithelium, *Pf* its pigment processes, *SZ* rod-and-cone layer, *a* outer member, *i* inner member, *Le* membrana limitans extranea, *aK* outer nuclear layer, *s* rod nucleus, *z* cone nucleus, *ap* outer plexiform layer, *f* the distal fibrous division, *r* the proximal reticular division, *x* border between the neuroepithelium and cerebral layer, *iK* inner nuclear layer, *c* capillaries, *ip* inner plexiform layer, *G* ganglion-cell layer, *N* nerve-fiber layer, *gl* glial nuclei, *Li* membrana limitans interna, *M* basal cones of Mueller's supporting fibers.

4. Entrance of the optic nerve (papilla nervi optici), horizontal section; magnification 31.

*T* temporal, *N* nasal side, *D* dural sheath, *Ar* arachnoidal sheath, *P* pial sheath, *I* intervaginal space, *Ma* medullated portion of the optic nerve, *cB* central connective-tissue strand, *V* vena centralis retinae,

*A* arteria centralis retinae, *Lc* lamina cribrosa (l. scleralis), *Lch* lamina chorioidalis, *Ks* nuclear column, *Me* central connective tissue meniscus, *Ex* physiologic excavation, *S* sclera, *Pch* perichorioidea, *Ch* chorioidea, *gr* border tissue, *R* retina, *im* intermediary tissue.

5. The trabecular work of the intervaginal space, longitudinal section; magnification 288.

*Ar* arachnoidal sheath, *aE* its outer endothelium, *iE* its inner endothelium, *Vb* trabecula of union between the dural and pial sheaths in cross-section, surrounded by an invagination of the arachnoidal sheath, *sb* primitive subarachnoidal trabeculum, *SB* large subarachnoidal trabeculum, *P* pial sheath.

6. Arachnoidal sheath, surface-section; magnification 410.

*a* outer reticular connective-tissue layer, *i* inner connective-tissue layer consisting of separated bundles, *E* endothelium nuclei.

7. Choriocapillaris in the neighborhood of the posterior pole, natural injection through hypostasis, surface view, teased preparation; magnification 65.

*x* the places where the smallest arteries and veins unite with the capillary layer.

8. A small bundle of smooth muscle-fibers in the suprachorioidea, surface view, teased preparation, staining with Mallory's phospho-molybdic-acid hematoxylin; magnification 200.

*ch* chromatophores, *e* endothelial nuclei, *n* non-medullated nerve-fiber, *m* smooth muscle-fibers supported by numerous elastic fibers coursing out in pencil-formed brushes (*f*).

9. Posterior border of the ciliary muscle, surface view, teased preparation; magnification 32.

*M* meridional portion of the ciliary muscle, *st* muscle-stars, *N* branches of the ciliary nerves.

10. A sector of the inner surface of the ciliary body and of the circumlental space; magnification 15.

*Os* ora serrata retinae with 2 teeth (*z*) each of which continue into a stria ciliaris (*St*), *Or* orbiculus ciliaris, *Pc* ciliary processes, *w* the small warts between, *Cl* circumlental space with the posterior zonula fibers, *L* border of the lens.

#### PLATE V

1. Choriocapillaris in the neighborhood of the ora serrata retinae, natural injection, surface view, teased preparation; magnification 56.

The smaller lighter vessels belong to the vessel layer of the chorioidea, *A* a recurrent artery.

2. The rod and cone mosaic in the extrafoveal territory of the retina, surface-section at the level of the inner members; staining with Mallory's hematoxylin; magnification 400.

The larger disks are the cross-sections of cones, the smaller, of rods.

3. Details from the center of a very flat fovea; rod-free area, temporal half, horizontal section; magnification 300.

*Li* membrana limitans interna retinae, *iK* rudiment of the cerebral layer, *Hf* Henle's outer fiber layer, *aK* outer nuclear layer, *Le* membrana limitans externa, *Z* cone layer, *fZ* the thin foveal cones.

4. The nasal half of a small fovea centralis, horizontal section; magnification 47.

*F* middle of the fovea (so-called foveola), *cl* clivus, *w* wall about the fovea, *g* larger blood-vessel in the ganglion-cell layer, *Li* membrana limitans interna, *N* nerve-fiber layer, *G* ganglion-cell layer, *ip* inner plexiform layer, *iK* inner nuclear layer, *Hf* Henle's outer fiber layer, *aK* outer nuclear layer, *Sz* rod-and-cone layer, *P* pigment epithelium, *Ch* chorioidea, *S* sclera.

5. Border portion of the retina with cystic degeneration, surface view; magnification 55.

*Pc* pigment epithelium of the ciliary body, *R* retina, *H* cystic spaces, for the most part confluent into dendritic figures.

6. Border portions of the retina with cystic degeneration, meridional section; magnification 47.

*Ce* ciliary epithelium, *Os* ora serrata, *R* retina, *Ch* chorioidea; the place indicated by *X* is drawn under seven times magnification.

7. Cystoid degeneration of the retina (from the place marked *x* in 6); magnification 315.

*Li* membrana limitans interna, *G* rudiment of the nerve-fiber and ganglion-cell layer, *g* retinal vessel, *ip* inner plexiform layer, *iK* inner nuclear layer, *ap* outer plexiform layer, *aK* outer nuclear layer, *H* cystic spaces, *Le* membrana limitans externa, *SZ* rod-and-cone layer.

8. Cells on the surface of the base of the vitreous; staining with Mallory's hematoxylin; magnification 255.

## PLATE VI

1. Middle layer of the lamina cribrosa, surface-section, staining with Van Giesen; magnification 255.

*B* the connective-tissue glial trabeculae, *q* blood-vessels therein, *N* nerve-fiber bundle.

2. Cross-section of the optic nerve at the posterior end of the central connective-tissue strand, staining by Van Giesen; magnification 22.

*D* dural sheath, *sd* subdural space, *ar* arachnoidal sheath, *sar* subarachnoidal space, *P* pial sheath, *Glm* peripheral glial mantle, *V* vena centralis retinae, *A* arteria centralis retinae.

3. Details from 2; magnification 312.

*s* connective-tissue septa, *g* blood-vessels therein, *Gl* glial extension of the septa, *N* nerve-fiber bundle, *Ly* spaces arising from shrinking.

4. A piece of the medullated portion of the optic nerve in longitudinal section; magnification 90.

*S<sub>1</sub>* surface view of the septa, *S<sub>2</sub>* longitudinal section of the septa, *Gl* glial continuation of the septa, *N* nerve-fiber bundle.

5. Details of the cross-section of a nerve-fiber in the medullated portion of the optic nerve, Mallory's stain; magnification 950.

*n* nerve-fibers, *gl* glial fibers, *z* a glial cell.

6. The superficial portions of the optic-nerve trunk, cross-section, Weigert's stain for medullary sheaths; magnification 63.

*D* dural sheath, *sd* subdural space, *Ar* arachnoidal sheath, *sar* subarachnoidal space, *P* pial sheath, *Glm* peripheral glial mantle, *N* nerve-fiber bundle, *S* septa, *Q* artefact arising through squeezing.

## PLATE VII

1. The fundus of a 13-year-old girl with a brown iris, seen with the ophthalmoscope; papilla, retinal blood-vessels, macular and foveal reflex.

2. Corona ciliaris (posterior half) and neighboring portions, transverse section; magnification 47.

*Gk* nucleus of the vitreous, *vG* anterior border layer, *Lc* ligaments-cordiformes, *Z* cross-sections of the zonula fibers in the ciliary valleys, *iz* innermost zonula fibers, *Li* membrana limitans interna ciliaris, *CE* ciliary epithelium, *P* pigment epithelium, *Gf* vessel layer of the ciliary body, *Pc* ciliary processes, *Mc* ciliary muscle (innermost layers of the radial portions).

3. Reticulum of H. Mueller in the anterior part of the orbiculus ciliaris, surface view, teased preparation, stained by Mallory's hematoxylin; magnification 285.

The arrow below indicates the direction of the meridian and points forward.

4. Orbiculus ciliaris in the neighborhood of the ora serrata retinae, transverse section, bleached; magnification 320.

*Gb* vitreous base, *Li* membrana limitans interna ciliaris (?), *CE* ciliary epithelium, *P* pigment epithelium, *l* ridges of the reticulum of H. Mueller (large meshes), *Cu* cuticular lamella, *iB* interlamellar connective tissue, *el* elastic lamella, *Gf* vessel layer of the ciliary body.

5. Orbiculus ciliaris in the neighborhood of the corona ciliaris, transverse section, bleached; magnification 380.

*vG* anterior border layer of the vitreous, *Z* cross-sections of the zonula fibers in the orbicular space, *Li* membrana limitans interna ciliaris, *l* its ridges, inclosing in part finest zonula fibers, *CE* ciliary epithelium, *P* pigment epithelium, *Cu* cuticular lamella (small meshes of the reticulum of H. Mueller), *iB* interlamellar connective tissue, *el* elastic lamella, *Gf* vessel layer of the ciliary body.

6. Ciliary border of the sphincter pupillae with the spoke bundles, surface-section; magnification 348.

*Sph* sphincter pupillae, *Sp* spoke bundle, *K* clump cells, *b* collagenous intermediary substance of the iris stroma.

7. Senile warts of the glass membrane of the chorioidea, magnification 390.



## PLATE VIII

1. Drawing of the anterior iris surface (yellowish-gray iris, flecked here and there by rust-brown) unstained, reflected light; magnification 9.

*Pz* pupillary zone, *Cz* ciliary zone, *Ps* pigment seam of the pupil-border, *k<sub>2</sub>* pupillary crypts, *Z* angular line (smaller circle), *N* brown fleck, *f* contraction furrow, *k<sub>t</sub>* ciliary (peripheral) crypts in the border zone.

2. Relief of a posterior iris surface, under reflected light; magnification 9.

*rF* radial furrows of the pupillary zone, *SF* structural furrows, *cF* circular furrows, *C* anterior border of the corona ciliaris.

3. Pupillary zone of the iris, meridional section; magnification 60.

*vG* anterior border layer (with endothelium), *G* vessel layer, *Di* dilatator pupillae, *P* pigment epithelium, *Sph* sphincter pupillae, *Sp* spoke bundle, *e* radiations of the dilatator into the sphincter from behind, *Ps* pigment seam of the pupillary border, *K* clump cells.

4. The markings upon the anterior surface of the iris arising after treatment with silver nitrate; magnification 636.

5. Plexus of the chromatophores in the anterior border layer of a brown iris—out of the outer half of the ciliary zone, surface view, teased preparation; magnification 375.

6. Ciliary border of the dilatator pupillae, surface view; magnification 28.

*SF* structural furrows.

7. Elements of the dilatator pupillae in the middle of the ciliary zone, surface view, teased preparation; magnification 375.

8. Ectodermal layers of the posterior iris surface, meridional section, bleached; magnification 260.

*Str* stroma of the vessel layer of the iris, *hG* posterior border lamella, *sp* layer of the pigmented spindle cells, *P* pigment epithelium.

9. Ectodermal layers of the posterior iris surface, transverse section, bleached; magnification 330.

Annotations as in 8.

10. Posterior layers of the pupillary zone of the iris, transverse section, bleached; magnification 300.

*Str* stroma of the vessel layer, *Sph* sphincter pupillae, *K* clump cells, *Di* pupillary border of the dilatator pupillae constructed out of transition forms between typical dilatator elements and epithelial cells; in the center is a union with the sphincter, *P* pigment epithelium.

11. Inner layers at the anterior declivity of a ciliary process (transition of the ciliary epithelium into the pigment epithelium of the iris), meridional section; magnification 375.

*Li* membrana limitans interna ciliaris, *CE* ciliary epithelium, *P* pigment epithelium of the ciliary body, *Cu* cuticular lamella, *Gf* vessel layer of the ciliary body (processes).

12. Narrow iris (iris breadth 3 mm, pupil width 5 mm); magnification 20.

13. Broad iris (iris breadth 5 mm, pupil width 2.5 mm); magnification 20.

14. Radiations of zonula fibers into the anterior border layer of the vitreous; a detail out of a surface preparation of the anterior border layer, stained with Mallory's hematoxylin; magnification 67.

*vG* anterior border layer, finely folded, *m* a meridional zonula fiber radiating into the border layer at two places, *k* a short bundle of zonula fibers coming from the corona ciliaris, radiating in its entirety into the border layer, farther above a smaller similar bundle, *cZ* circular zonula fibers.

## PLATE IX

1. Equatorial zone of the lens capsule with the insertion of the zonula fibers, surface view, teased preparation; magnification 37.

*vZ* anterior zonula fibers, *Zl* meridional striations of the zonular lamella, *qZ* middle (equatorial) zonula fibers, *EG* location of the epithelial border, *hZ* posterior zonula fibers.

2. Lens epithelium treated with silver nitrate, surface view; magnification 540.

3. The lens vortex of a 59-year-old man, meridional section; magnification 333.

*Zl* zonular lamella with ligamentum hyaloideo-capsularis, *K* lens capsule, *E* lens epithelium, *Eg* epithelial border, *l* lens substance.

4. Superficial layers of the lens of a 2-weeks-old child, equatorial section; magnification 308.

*K* lens capsule, *E* lens epithelium, *L* lens substance (Rabl's lamellae).

5. Deeper layers of the same preparation (1.3 mm below the surface); irregular arrangement and form of the lens fibers.

6. Optic grooves in an open medullary canal, embryo of 2.6 mm gr. 1.; magnification 21. (Copy from Keibel, normal plates (116) No. 6, p. 24, Text Fig. 6 a.)

*E* ectoderm, *W* wall of the medullary canal, *A* the optic grooves, *M* mesoderm.

7. Transition of the (primary) optic vesicle into the optic cup, beginning of the lens invagination, embryo of 5.2 mm gr. 1., section in the direction of the optic cleft; magnification 66.

(Collection of the I. Anatomic Institute of Vienna.)

*E* ectoderm, *L* lens primordium, *M* mesoderm, *W* wall of the medullary canal (forebrain), *V* lumen of the same, *S* lumen of the pedicle of the optic vesicle, *A* lumen of the (primary) optic vesicle, *a* outer leaf of the optic cup, *i* inner leaf of the eye-cup.

8. Completely formed optic cup, optic cleft for the most part closed, lens vesicle constricted off, beginning of the formation of the definite cornea, embryo of 9.75 mm gr. 1., section in the direction of the optic cleft; magnification 66.

(Collection of the I. Anatomic Institute of Vienna; Keibel, normal plates (116) No. 42, Tandler, 207.)

*E* ectoderm, *L* lens vesicle, *M* mesoderm, *Mf* mesodermal processes in the cavity of the optic cup, *H* primitive cornea, *G* primitive vitreous, *W* wall, *v* lumen of the forebrain, *s* lumen of the pedicle of the optic vesicle, *A* lumen, *a* outer, *i* inner wall of the optic cup.

9. Anterior segment of the eyeball, embryo of 28.5 mm gr. 1.; magnification 40.

(Collection of the I. Anatomic Institute of Vienna.)

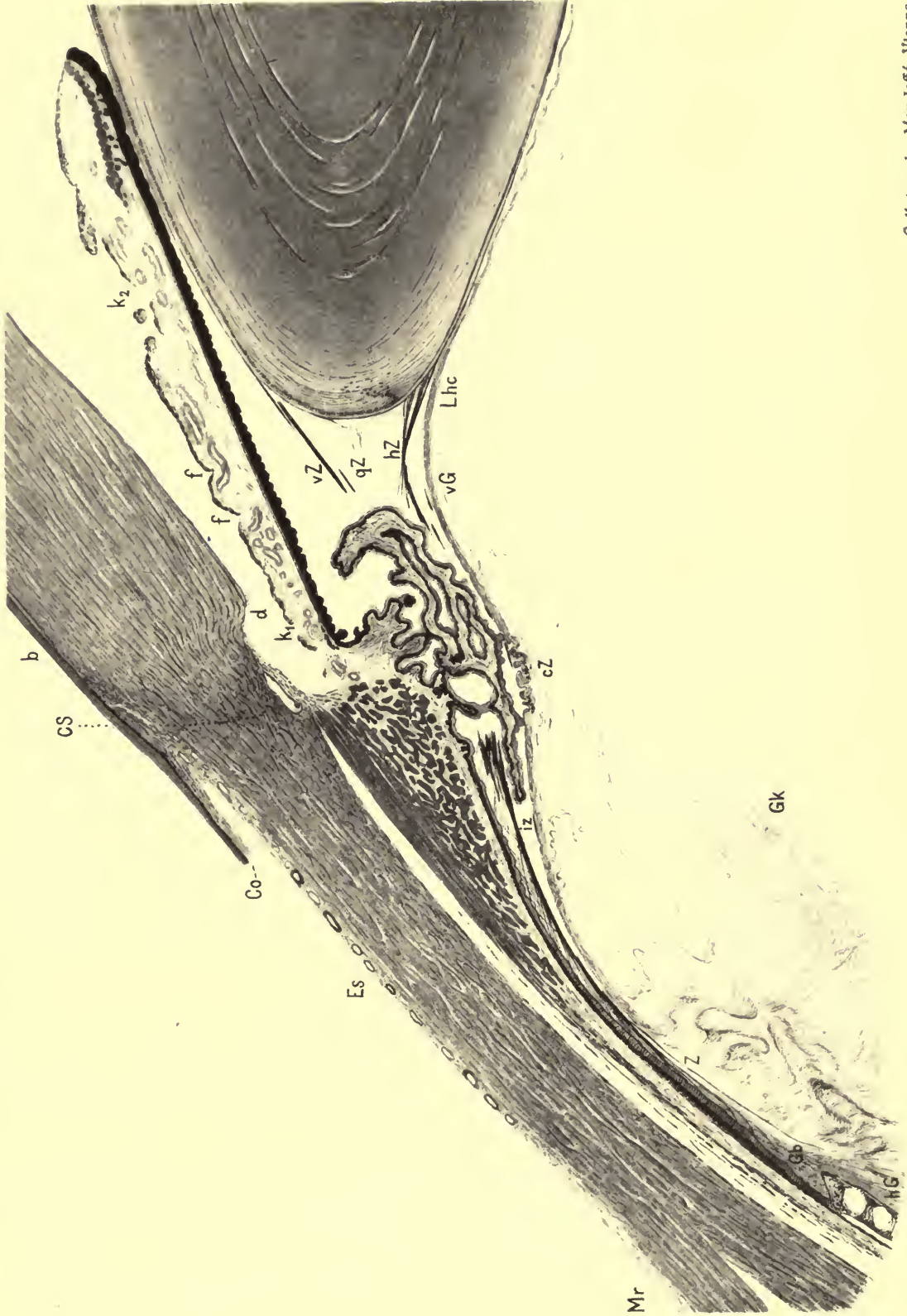
*E* ectoderm, *Fo* primordium of the fornix conjunctivae, *H* primordium of the cornea stroma, *IP* lamina irido-pupillaris, isthmus, *L* lens, *Tv* tunica vasculosa lentis, *G* vitreous with its vessels, *R* retina (inner leaf of the optic cup), *P* pigment epithelium (outer leaf of the optic cup), *S* sclera (the primordium of the chorioidea is not plainly visible because of the low magnification). The clefts between *H* and *IP*, as well as between *R* and *P*, are artefacts.

10. Primordium of the iris and of the ciliary body, fetus of 18 cm l., meridional section; magnification 35.

*E* epithelium of the cornea, *C* corneal stroma, *D* endothelium of the cornea, *Li* limbus, *S* sclera, *Vk* anterior chamber, *Pm* pupillary membrane, *I* iris primordium, *Sph* sphincter primordium, *Pc* primordium of the corona ciliaris, *Mc* primordium of the ciliary muscle, *P* pigment epithelium, *R* retina, *G* vitreous, *Z* zonula primordium, *Tv* tunica vasculosa lentis, *L* lens.

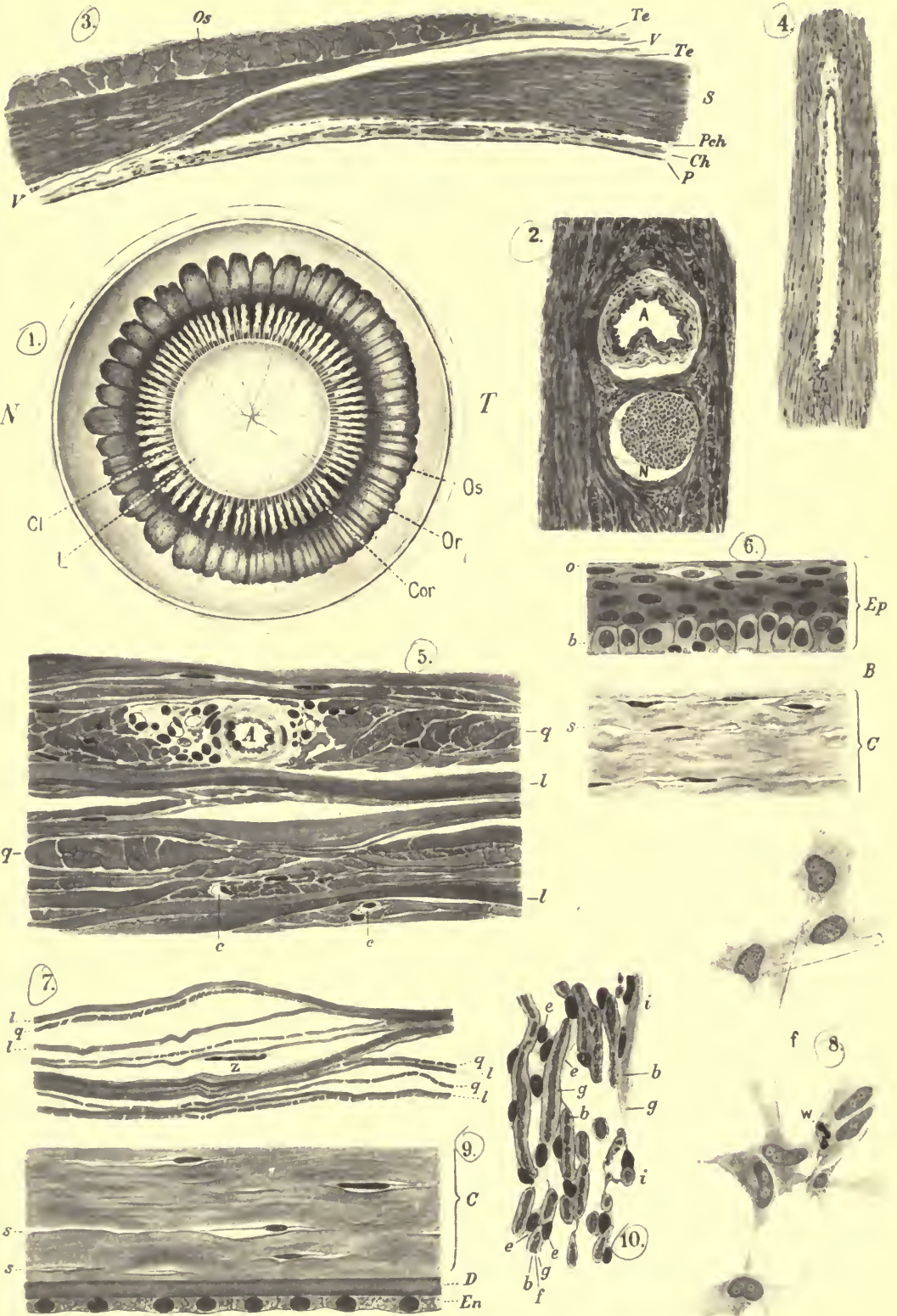
11. The border of the retina (ora serrata) of the newborn, meridional section; magnification 116.

*R* retina, *F* apex of the so-called Lange's fold, *CE* ciliary epithelium, *P* pigment epithelium, *U* uveal tract, *S* sclera.












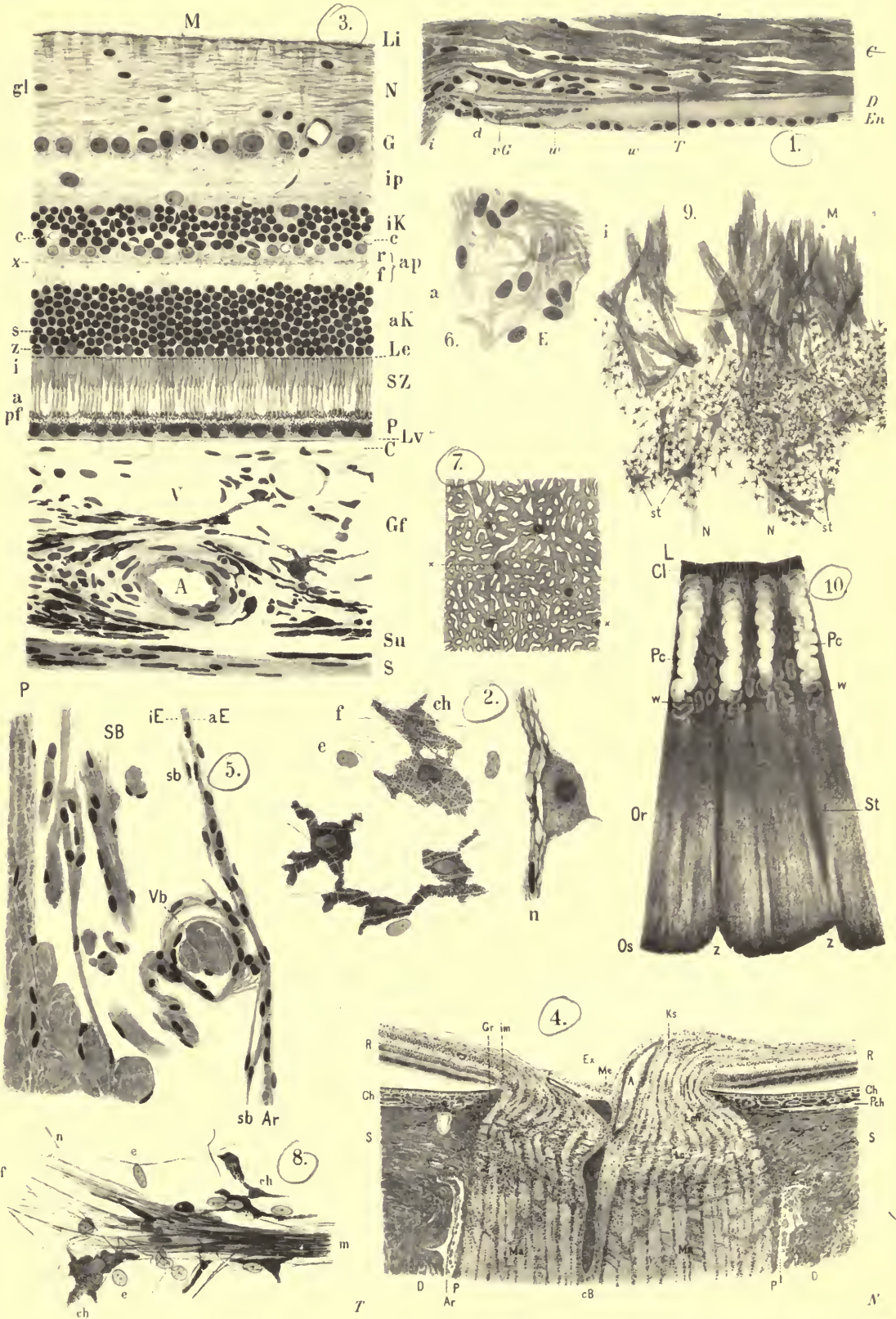


Collotype by Max Jaffé, Vienna.



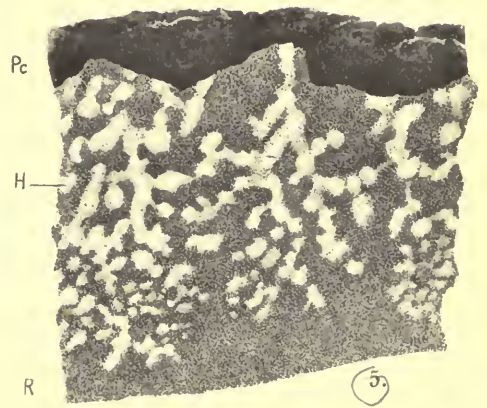
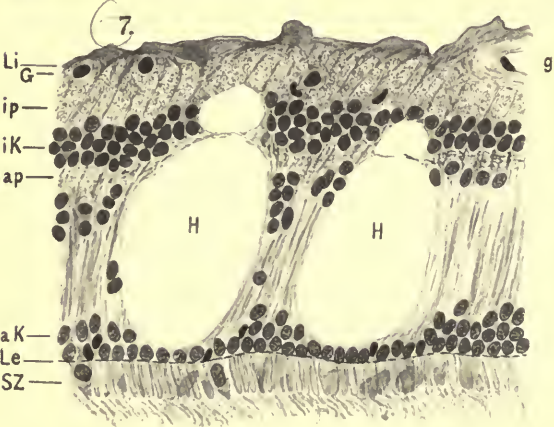


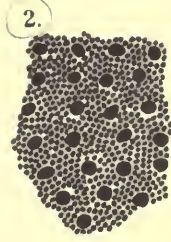
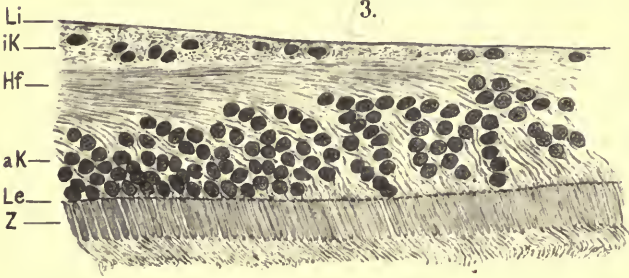







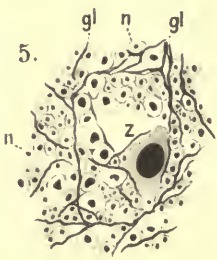
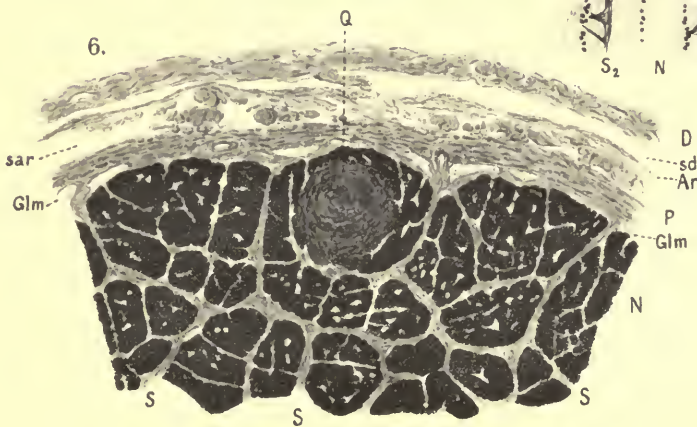
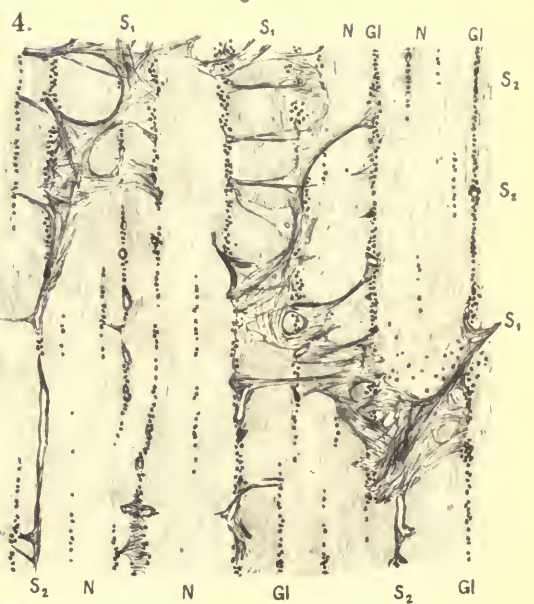
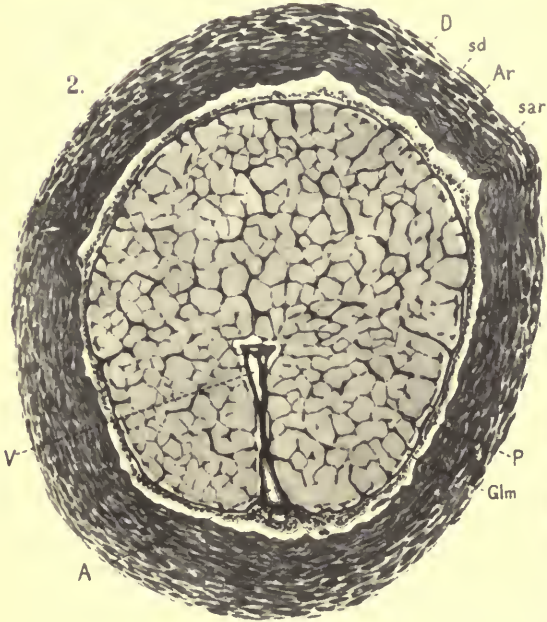
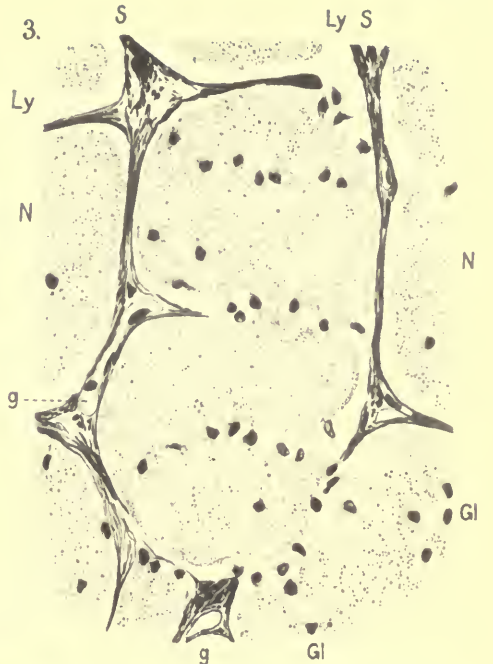
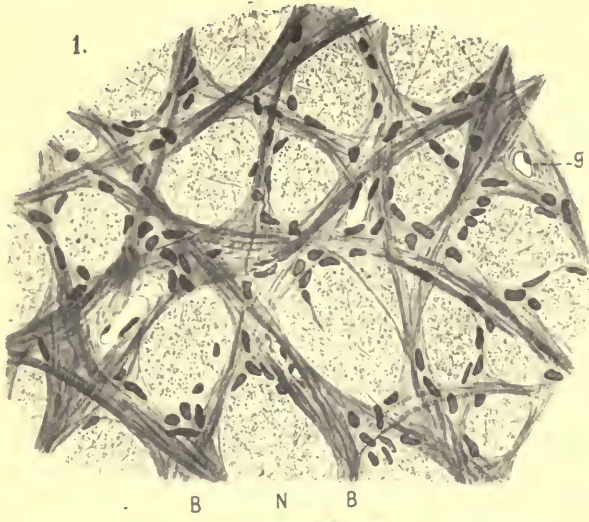




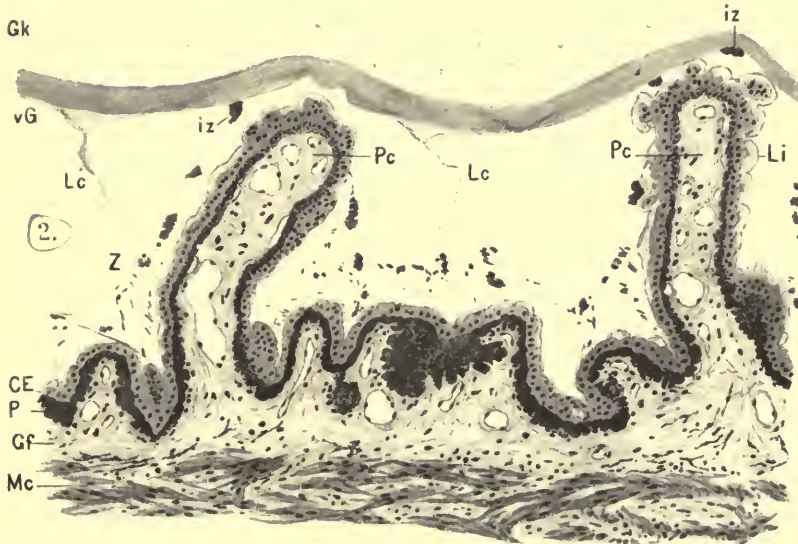
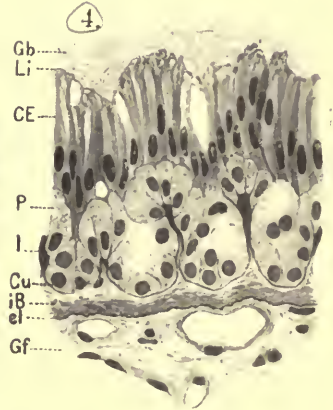
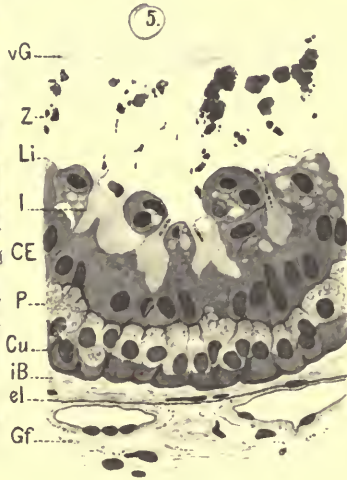
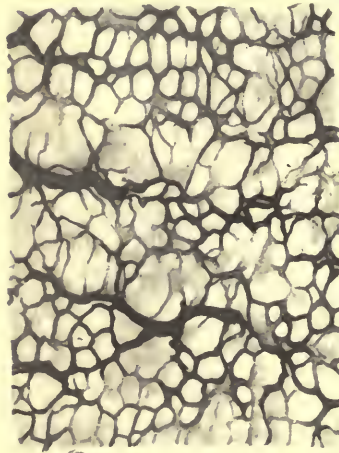
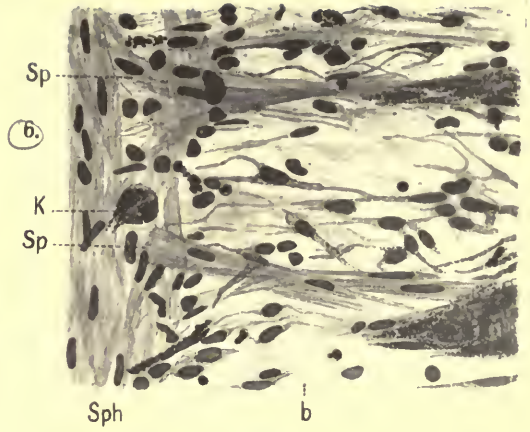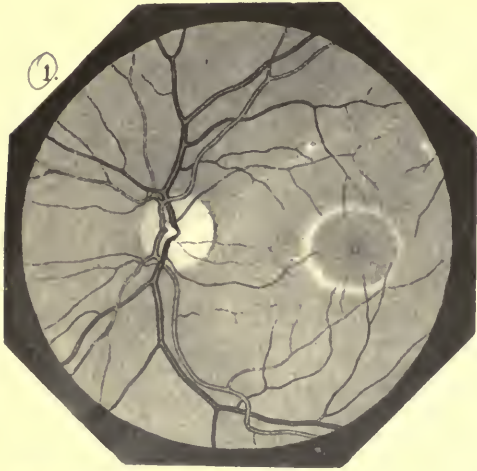




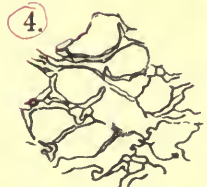

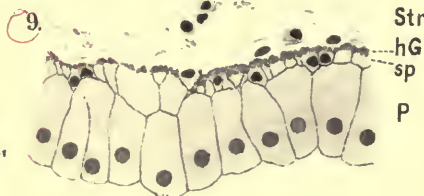
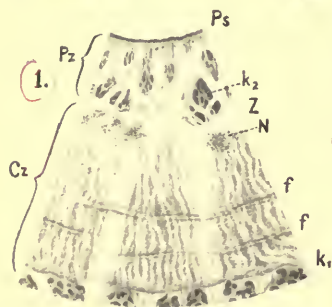
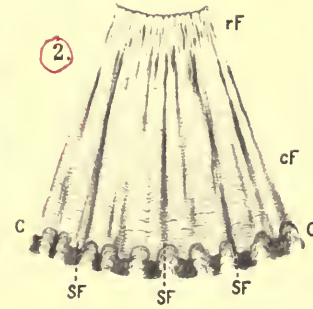
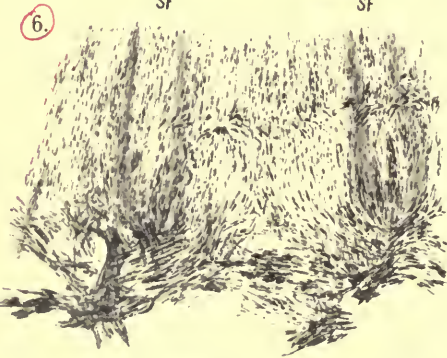
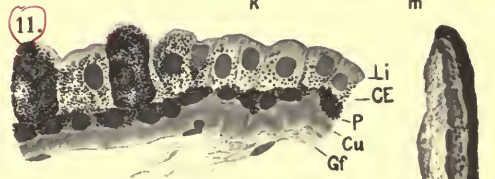
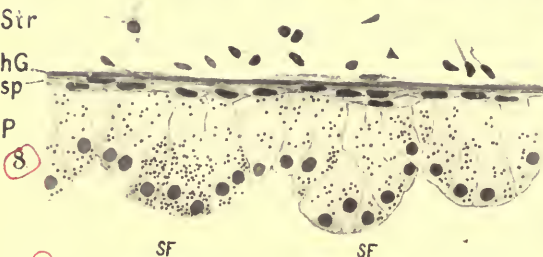
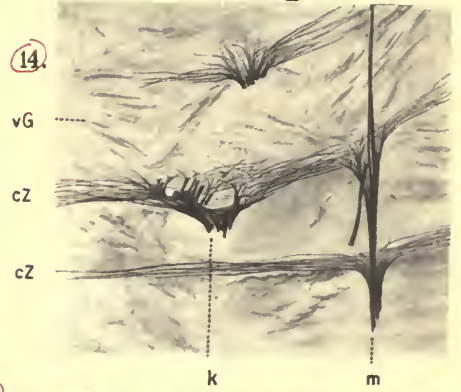
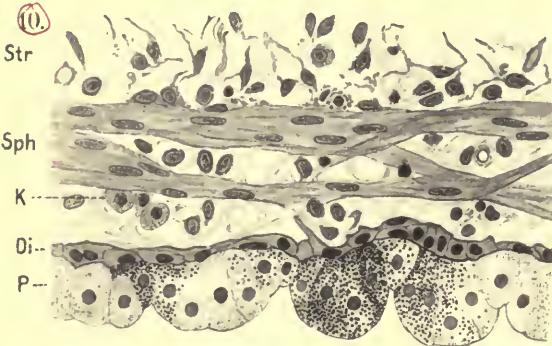
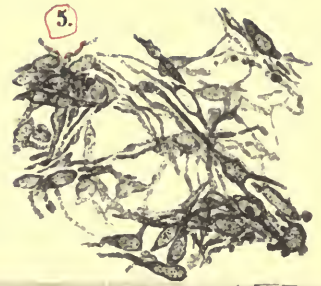
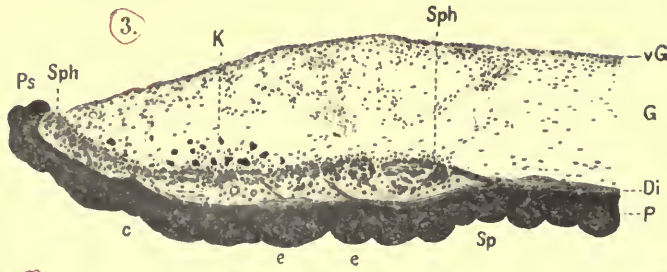




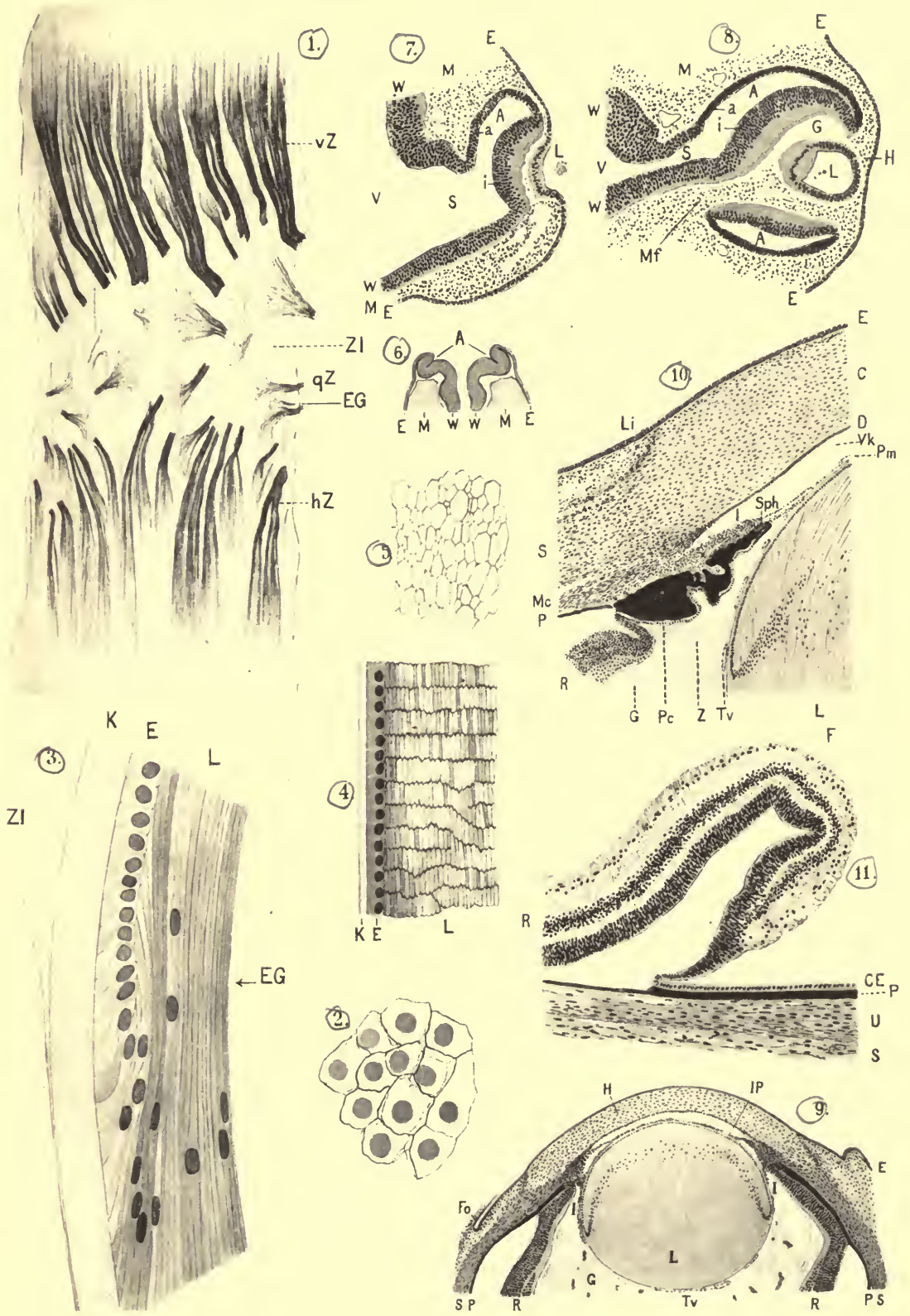


















THE LIBRARY  
UNIVERSITY OF CALIFORNIA  
San Francisco Medical Center

THIS BOOK IS DUE ON THE LAST DATE STAMPED BELOW

Books not returned on time are subject to fines according to the Library Lending Code.

Books not in demand may be renewed if application is made before expiration of loan period.

14 DAY

JAN - 2 1972

RETURNED

DEC 18 1972

~~JUN 3 1976~~

~~INTERLIBRARY LOAN~~

~~14 DAYS AFTER RECEIPT~~

~~Univ. of  
California,  
IRVINE~~

~~JUN 17 REC'D~~

RETURNED

JUL 2 1976

25m-10,'67 (H5525s4) 4128

Q511  
S18a  
E5b  
1912

49371

Salzmann, Maximilian  
Anatomy and histology of  
the human eyeball in the  
normal state.


49371

