

With the author's Consent

OBSERVATIONS ON THE RELATION

OF THE

4.

PRINCIPAL FISSURES AND CONVOLUTIONS
OF THE CEREBRUM

TO THE

OUTER SURFACE OF THE SCALP.

BY

ROBERT W. REID, M.D., F.R.C.S.,

LECTURER ON ANATOMY, MEDICAL SCHOOL OF ST. THOMAS'S HOSPITAL.

(Reprinted from THE LANCET, Sept. 27, 1884.)

LONDON :

PRINTED BY BALLANTYNE, HANSON & CO.

CHANDOS STREET, STRAND, W.C.

1884.



PRINCIPAL FISSURES AND CONVOLUTIONS OF THE CEREBRUM.



A GOOD deal has been written about the relation of the sulci and convolutions of the cerebrum to the outer surface of the bony cranium, especially with regard to the various sutures. Frequently these sutures are not to be felt through the scalp, and practically, therefore, such relations are of little value to any one examining the head from a medical or surgical point of view. Hence it occurred to me that a gap might be filled up in regional anatomy by describing the relation of the principal sulci to the outer surface of the scalp, and consequently I made a series of investigations on the dead body to try if possible to make out some guides by which, on examining a person's head, one might readily be able to localise the chief sulci, and thereby the position of the principal convolutions. Of course it is impossible to draw a line on the scalp exactly to follow a sulcus of the brain, for the simple reason that the sulci are never in any two brains precisely alike, or the shape of the head exactly the same in all cases. We must also remember that, as the surface area of the outside of the scalp is greater than the surface area of the corresponding part of the cerebrum, any lines drawn on the scalp to represent the sulci will be longer than the sulci themselves, and the spaces between those lines, indicating

the convolutions, will be larger than the convolutions themselves.

What I propose to do is to show that by taking large and easily felt landmarks on the head, and drawing from these certain lines, those lines will indicate accurately enough for all practical purposes the position of the principal sulci, and that by removing in any of these lines a piece of the scalp and skull an inch square, or by applying the one inch trephine to the skull, with the centre pin on the line, we can expose the fissure in any part of its course.

The landmarks which can easily be felt on the outside of the scalp, and with reference to which lines can be drawn to indicate the position of the sulci, are the glabella, or depression between the two nasal eminences just above the root of the nose, external occipital protuberance, superior curved line of the occipital bone, parietal eminence, posterior border of the mastoid process, depression just in front of the external auditory meatus, external angular process of the frontal bone, frontal part of temporal ridge, and the supra-orbital notch. If the last is not to be felt, its position will be at the junction of the inner with the middle thirds of the supra-orbital margin. We shall also suppose that the base line (Fig. 1), from which all perpendicular lines are drawn, runs through the lowest part of the infra-orbital margin and the middle of the external auditory meatus.

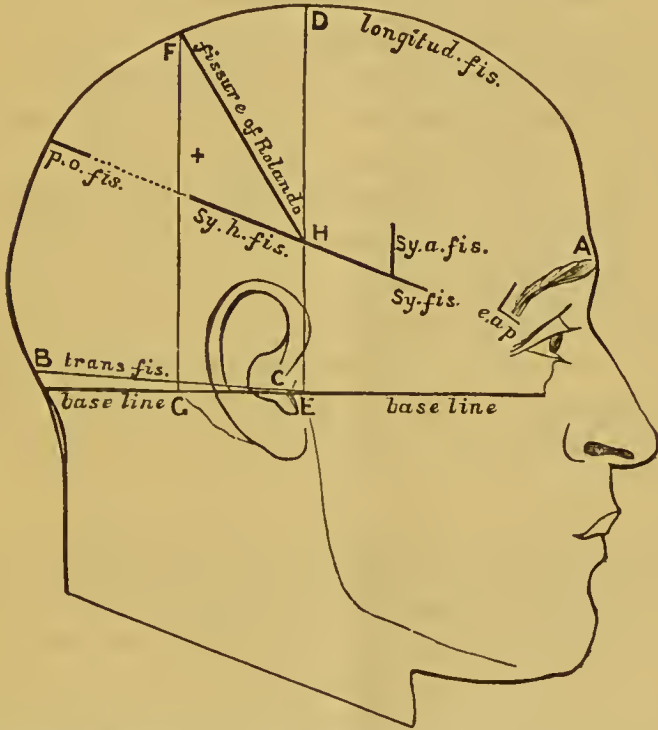
Longitudinal fissure of cerebrum.—This of course is readily indicated by a line running along the middle line of the top of the head from the glabella to the external occipital protuberance (A B, Fig. 1).

Transverse fissure.—This is indicated by drawing a line along the superior curved line of the occipital bone from the external occipital protuberance to the external auditory meatus—that is, along the line of junction of the head with the neck posteriorly (B C, Fig. 1).

Fissure of Sylvius.—To find this draw a line from a point one inch and a quarter behind the external angular process of the frontal bone to a point three-quarters of an inch below

the most prominent part of the parietal eminence. Measuring from before backwards, the first three-quarters of an inch of the line will represent the main fissure, and the rest of the line will indicate the horizontal limb. The ascending limb will start from the posterior end of the line indicating the main fissure—that is, two inches behind and slightly

FIG. I.



A, Glabella. B, External occipital protuberance. *e. a. p.*, External angular process of frontal. B C, Transverse fissure. A B, Longitudinal fissure. *Sy. fis.*, Sylvian fissure. *Sy. h. fis.*, Horizontal limb of fissure of Sylvius. *Sy. a. fis.*, Ascending limb of fissure of Sylvius. D E, Perpendicular line from depression in front of external auditory meatus to middle line of top of head. F G, Perpendicular line from posterior end of base of mastoid process to middle line of top of head. F H, Fissure of Rolando. *p. o. fis.*, Parieto-occipital fissure. + Most prominent part of parietal eminence.

above the external angular process,—and run vertically upwards for about an inch. (See Fig. I.)

Fissure of Rolando.—To find this and, at the same time, the region of the ascending frontal and parietal con-

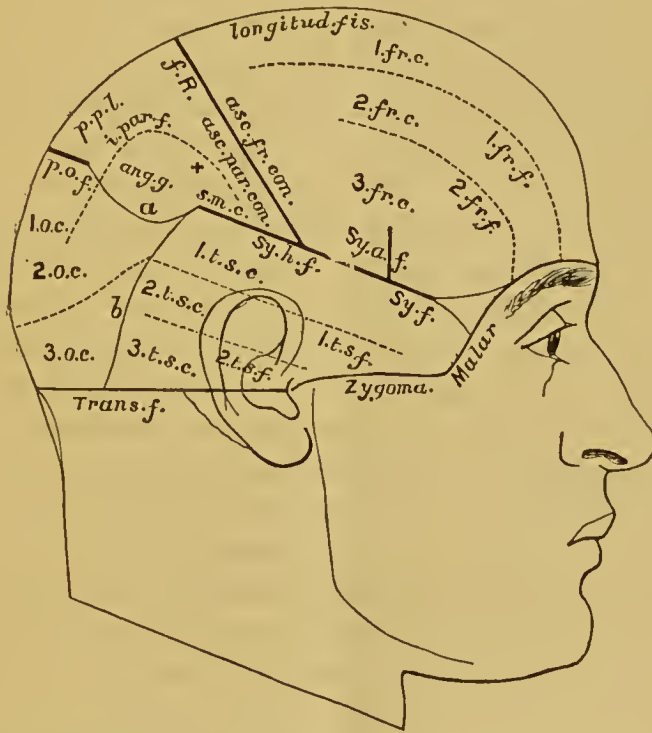
volutions, first indicate on the surface of the scalp the longitudinal fissure and the horizontal limb of the fissure of Sylvius; next, from the base line draw two perpendicular lines to meet the line for the longitudinal fissure, one (D E, Fig. 1) from the depression in front of the external and auditory meatus, and another (F G, Fig. 1) from the posterior border of the mastoid process at its root. We shall thus have described on the surface of the head a four-sided figure, bounded above and below by the lines for the longitudinal fissure and horizontal limb of the fissure of Sylvius respectively, and in front and behind by the two perpendicular lines. If we now draw a diagonal line (F H, Fig. 1) from the posterior superior angle to the anterior inferior angle of the space, this diagonal line will lie over the fissure of Rolando. In the majority of cases the fissure of Rolando does not actually run into the fissure of Sylvius, a convolution bridging across at that point; hence the lowest half-inch or so of the line would cross this convolution. In those cases where the two fissures join, the fissure of Rolando would be indicated by the whole length of the line.

External parieto-occipital fissure.—This fissure is more variable in its position than any of the other principal fissures of the cerebrum, and consequently any indication of it on the surface of the scalp must be approximately accurate. If we continue the line for the horizontal limb of the fissure of Sylvius onwards to the line indicating the longitudinal fissure, we shall find that on trephining over the inner inch of this line we shall expose the external parieto-occipital fissure, or some part of it. In most cases we have seen the whole of the fissure in the opening so made, in others it showed itself in the posterior half of the opening, and in still fewer cases it was seen in the anterior half.

Having now indicated the position of the principal fissures, it will be comparatively easy to map out the areas of the frontal, parietal, temporo-sphenoidal, and occipital lobes, with their chief sulci and convolutions as far as they are in relation with the outer surface of the scalp.

The *frontal lobe* will be bounded above by the line for the longitudinal fissure, below by the line for the trunk and horizontal limb of the Sylvian fissure, behind by the line for the fissure of Rolando, and in front by a line just above and parallel with the supra-orbital margin. A line drawn from

FIG. 2.



+ Most prominent part of parietal eminence. *a*, Convex line bounding parietal lobe below. *b*, Convex line bounding temporo-sphenoidal lobe behind. *1 fr. c.*, First frontal convolution. *1 fr. f.*, First frontal fissure. *f. R.*, Fissure of Rolando. *Sy. f.*, Sylvian fissure. *Sy. h. f.*, Horizontal limb of Sylvian fissure. *Sy. a. f.*, Ascending limb of Sylvian fissure. *p. o. f.*, Parieto-occipital fissure. *i. par. f.*, Intra-parietal fissure. *ang. g.*, Angular gyrus. *s. m. c.*, Supra-marginal convolution. *1 t. s. c.*, First temporo-sphenoidal convolution. *1 t. f. s.*, First temporo-sphenoidal fissure. *1 o. c.*, First occipital convolution. *p. p. l.*, Postero-parietal lobule.

the supra-orbital notch backwards to within three-quarters of an inch of the line for the fissure of Rolando, and parallel with the line for the longitudinal fissure, will indicate the

first frontal fissure. The frontal part of the temporal ridge will indicate the second frontal fissure. The first, second, or third frontal convolutions will thus be mapped out. The ascending frontal convolution will occupy a space about three-quarters of an inch broad parallel with, and in front of, the line for the fissure of Rolando. (See Fig. 2.)

The *parietal lobe* will be marked out by the line for the longitudinal fissure superiorly, and in front and behind by the lines for the fissure of Rolando and the parieto-occipital fissure respectively. Below, the line for the horizontal limb of the fissure of Sylvius will separate it from the temporo-sphenoidal lobe. The interval between the posterior end of the Sylvian line and the outer end of the parieto-occipital line is occupied by the junction of the postero-parietal lobule (*p. p. l.*, Fig. 2) with the first annectant convolution and the angular gyrus (*ang. g.*, Fig. 2) with the second annectant convolution, the arrangement of these convolutions with regard to one another being very variable, the angular gyrus usually projecting somewhat more posteriorly than the postero-parietal lobule. We can therefore only indicate the separation of this part of the parietal lobe from the neighbouring temporo-sphenoidal and occipital lobes by drawing a line (α , Fig. 2) slightly convex downwards from the posterior end of the Sylvian line to the outer end of the parieto-occipital line. An irregularly triangular space will thus be marked out to indicate the parietal lobe. If in this space we draw a line from a point half an inch outside the outer extremity of the parieto-occipital line to a point about an inch above and behind the anterior and inferior angle of the space, this line will lie over the *intra-parietal fissure* (*i. par. f.*, Fig. 2). The line must be curved, with its convexity directed forwards and inwards, and parallel in its anterior third or so with the line for the fissure of Rolando, and about three-fourths of an inch behind it. In the space above the intra-parietal sulcus we shall have, in front, parallel with the whole length of the fissure of Rolando, the ascending parietal convolution, and behind, the postero-parietal lobule.

The space below the sulcus will indicate, in its anterior part, the supra-marginal convolution (*s. m. c.*, Fig. 2), filling up the most prominent part of the parietal eminence, and, in its posterior part, the angular gyrus (*ang. g.*, Fig. 2).

Temporo-sphenoidal lobe.—This lobe, like the last, is somewhat difficult to indicate posteriorly, because it becomes continuous there with the parietal and occipital lobes without any distinct line of demarcation. Its outline will lie in the lower part of the temporal region, extending a little beyond the temporal ridge behind. It will be bounded above by the line of the main trunk and horizontal limb of the fissure of Sylvius, below by the upper border of the zygoma and a line carried back from the posterior end of that to a point midway between the external occipital protuberance and the posterior border of the mastoid process at its root. The anterior border or apex of the lobe will extend as far forwards as the posterior superior border of the malar bone. Behind, the lobe will be bounded by a slightly convex line (*b*, Fig. 2) with the convexity directed backwards, extending from the posterior end of the Sylvian line to the posterior end of the line indicating the lower boundary of the lobe. A line running about one inch below and parallel with the line for the main trunk and horizontal ramus of the fissure of Sylvius will indicate the first temporo-sphenoidal fissure (*1 t. s. f.*, Fig. 2), and another line about three-quarters of an inch below and parallel with the last will indicate the second temporo-sphenoidal fissure (*2 t. s. f.*, Fig. 2). Thus the first, second, and third temporo-sphenoidal convolutions will be mapped out (*1 t. s. c.*, *2 t. s. c.*, *3 t. s. c.*, Fig. 2).

The *occipital lobe* will occupy the remaining surface of the scalp. It will be bounded above by the parietal lobe, below by the superior curved line in its inner half—that is, the part of the line unoccupied by the lower limit of the temporo-sphenoidal lobe. Internally the line of the longitudinal fissure, and externally the convex line for the posterior border of the temporo-sphenoidal lobe, will bound it. The area of the lobe being marked out, the first, second, and third occipital

convolutions can be readily filled in (1 *o. c.*, 2 *o. c.*, 3 *o. c.*, Fig. 2).

The above description has been taken from a series of dissections made by myself and kindly allowed to be carried on by the demonstrators of morbid anatomy in the post-mortem room of St. Thomas's Hospital. It has been frequently tested on the dead body and found to be accurate, and is merely intended to afford for practical purposes a general idea of the surface of the cerebrum in relation to the scalp. It does not take into consideration the shape of the head in different races, or in those heads which present an abnormal outline from pathological conditions.