BOIVIN ON THE UTERUS

PLATES.

PRACTICAL TREATISE

OF

THE DISEASES OF THE UTERUS AND OF ITS ANNEXES,

FOUNDED

UPON A GREAT NUMBER OF CLINICAL OBSERVATIONS.

ATLAS OF 41 PLATES,

REPRESENTING

THE PRINCIPAL MORBID ALTERATIONS OF THE FEMALE GENITAL ORGANS;

BY Mme BOIVIN,

DOCTEUR EN MEDECINE, MID-WIFE, PRINCIPAL SUPERINTENDANT OF THE MAISON ROYALE DE SANTÉ, DECORATED WITH THE GOLDEN MEDAL OF THE CIVIL MERIT OF PRUSSIA, MEMBER OF SEVERAL LEARNED SOCIETIES;

AND BY A. DUGÈS,

PROFESSOR OF MEDECINE AT MONTPELLIER, MEMBER OF THE LEGION OF HONOUR, CORRESPONDING MEMBER OF THE ACADEMIE ROYALE DE MEDECINE, ETC., ETC.

LONDON,

DULAU AND C^o^, 37 SOHO-SQUARE;

EDINBURGH, BY CHARLES SMITH.

Dublin, HODGES, AND SMITH.
Cambridge, DEIGHTON.
Manchester, R. ROBINSON.

Oxford, PARKER.
Belfast, JOHN HODGSON.
Nottingham, DEARDON.

1834.

Fig. 1.

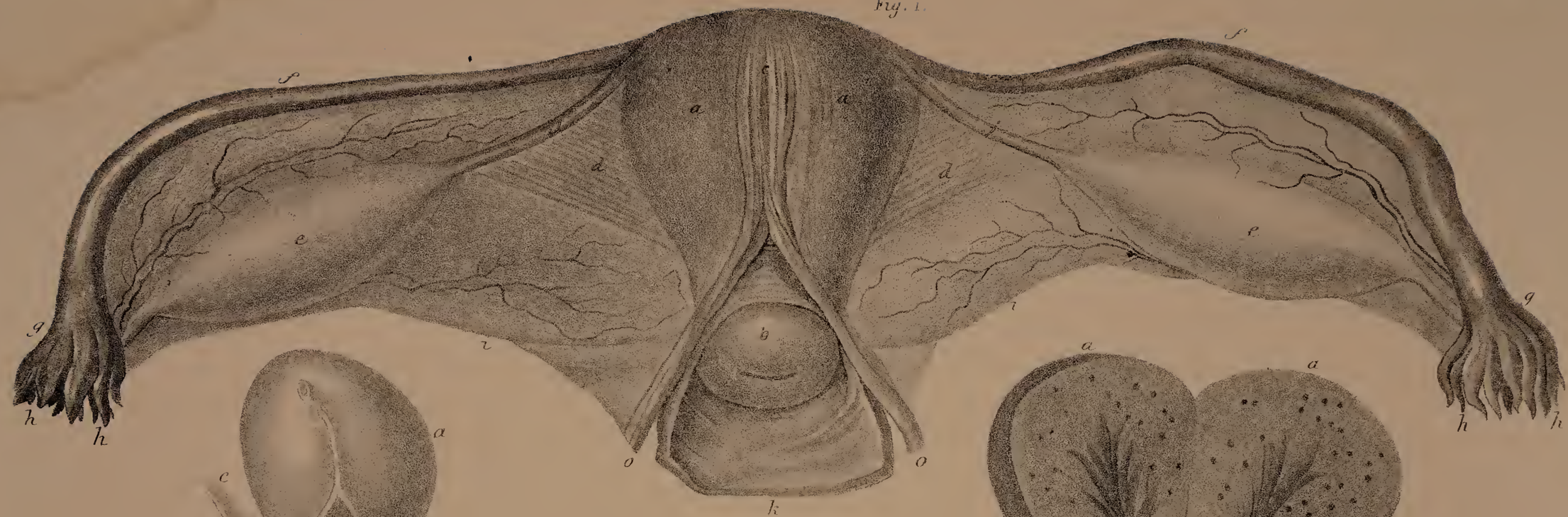

Fig. 3.

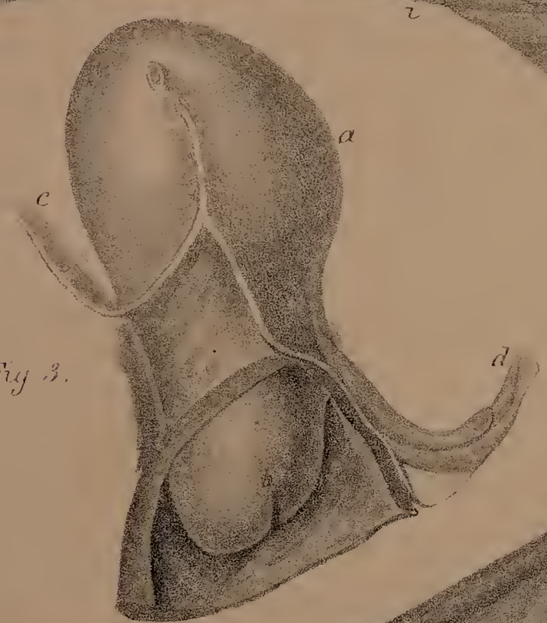

Fig. 4.

Fig. 2.

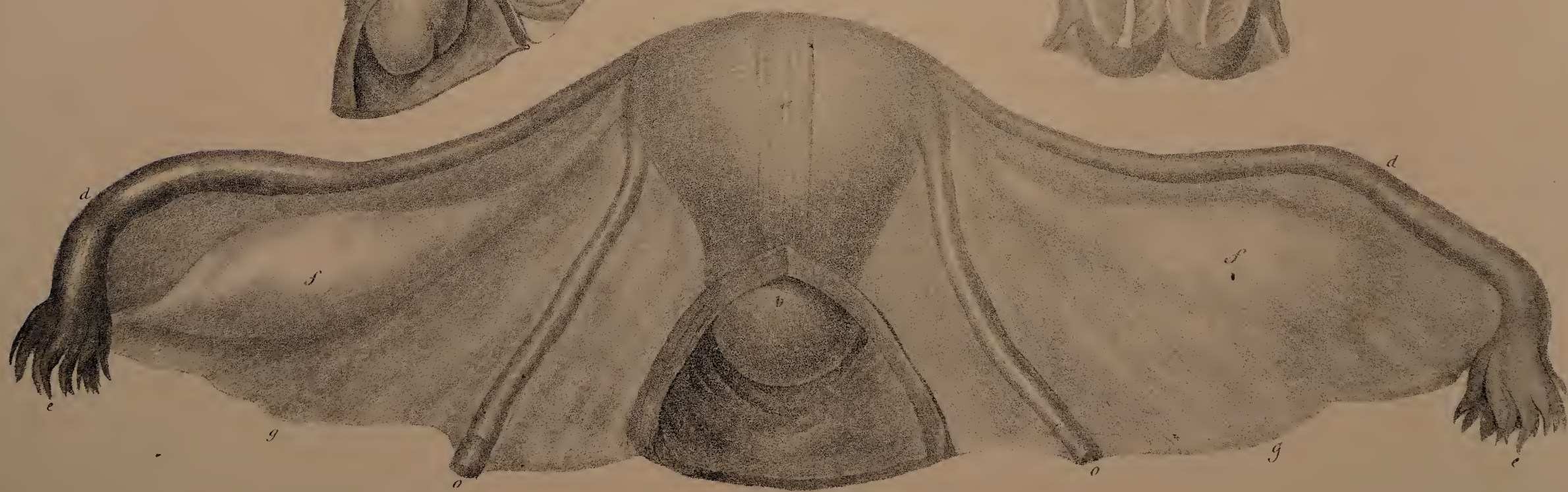

UTERUS IN DIFFERENT STATES.

EXPLANATION OF THE PLATE.

Fig. 1.re *Uterus in a state of vacuity in a woman who never had any children. The organ is seen on its posterior partition.*

A, A. Body of the uterus.
B. Opening of the neck of the womb.
C. Median line, or fibrous longitudinal plan of the uterus.
O, O. Posterior, or *utero sacral* ligaments, arising from a prolongation of the fibres of the body and neck of the organ.
D, D. Pinions of the matrix; prolongation of the posterior oblique fibrous plans, forming the *ligaments of the ovaries.*
E, E. Ovaries.
F, F, Fallopian or uterine tubes.
G, G. Enlargement of the tube.
H, H. Its fringed edges.
I, I. Large ligaments or folds of the peritonœum.
J, J. String of the ovary.
K, K. Anterior portion of the vagina seen on its anterior face.

Fig. 2. *Uterus seen on its anterior face.*

A. Median line, or longitudinal anterior fibrous plan.
B. Anterior lip of the mouth of the womb, longer than the posterior lip; it prevents the utero-vaginal orifice to be seen.
C, C. Origin of the round ligaments or upper pubian strings.
O, O. Upper pubian cords, or round ligaments.
D, D. Fallopian tubes.
E, E. Their fringed edges.
F, F. Ovaries seen through the tissue of the large ligaments.
G, G. Large ligaments or folds of the peritonœum.

Fig. 3. *Uterus seen in profile.*

A. Posterior partition more projecting and more rounded than the opposite partition.
B. Posterior lip of the mouth of the womb, more elevated than the anterior lip, representing the *bec-de-flûte.*
C. Vesico-uterine fold of the peritonœum.
D. Recto-vaginal fold of the same membrane.

Fig. 4. *View of the internal face of the uterus at the time of the flow of the menses, the organ opened on one of its edges and at its base.*

A. Body of the uterus there may be seen a median depressed line, and drops of blood.
B. Internal orifice of the uterine neck.
C. External orifice. Between these two orifices is found the cavity of the neck and the numerous folds which compose the apparel of a considerable developpement of this portion of the uterus during pregnancy and in some other circumstances. (See plate 2, fig. 6.)

Fig. 1.



Fig. 2.



Fig. 3.



Fig. 4.



Fig. 5.

Fig. 6

MOUTH OF THE NECK OF THE WOMB

IN THE NORMAL STATE.

EXPLANATION OF THE PLATES.

Fig. 1re. *In a girl before the marriageable age* — Fig. 2. *In a girl at the age of puberty.* — Fig. 3. *In a woman who has had commerce with man.* — Fig. 4. *During the menstruel excretion in a woman who has not had children.* — Fig 5. *In a woman who has been brought to bed at her full time.—Slight scars on the angles of the orifices.*—Fig. 6. *Uterus of a woman who died during the first weeks of her pregnancy.*

This figure 6 represents the organ open on one of its lateral edges, and shews the internal face of its two partitions of a dark red and of a soft tissue. Each of them, in the body, is impressed by a longitudinal furrow situated in the middle, and corresponds to a projecting line at each partition of the neck.

The neck of the organ, of a violet-white, offers in its cavity (already as large as that of the body) numerous folds, some simple, others complex, taking different directions; it is in these folds that are found, in great number, mucuous follicules; there may be seen, often, at their surface, some globulous concretions at one time, in a state of transparency containing a fluid, at others in a calcareous state. They are sometimes in such number, and so close to each other, that they hide all the folds of the neck, and even obstruct entirely the cavity.

But in the normal state, in a woman recently pregnant, these folds are gorged by a glairous thick matter, which exactly fills up the cavity of the neck, and serves, as it were, for its stopper, till the end of pregnancy, when this glairous matter flows out in abundance, lubricates, and prepares the vagina and its orifices for dilatation during the labour.

A,A. Body of the uterus.
B,B. Internal orifice.
C,C. External orifice.

Bouvier Dugès, Pl. 3.

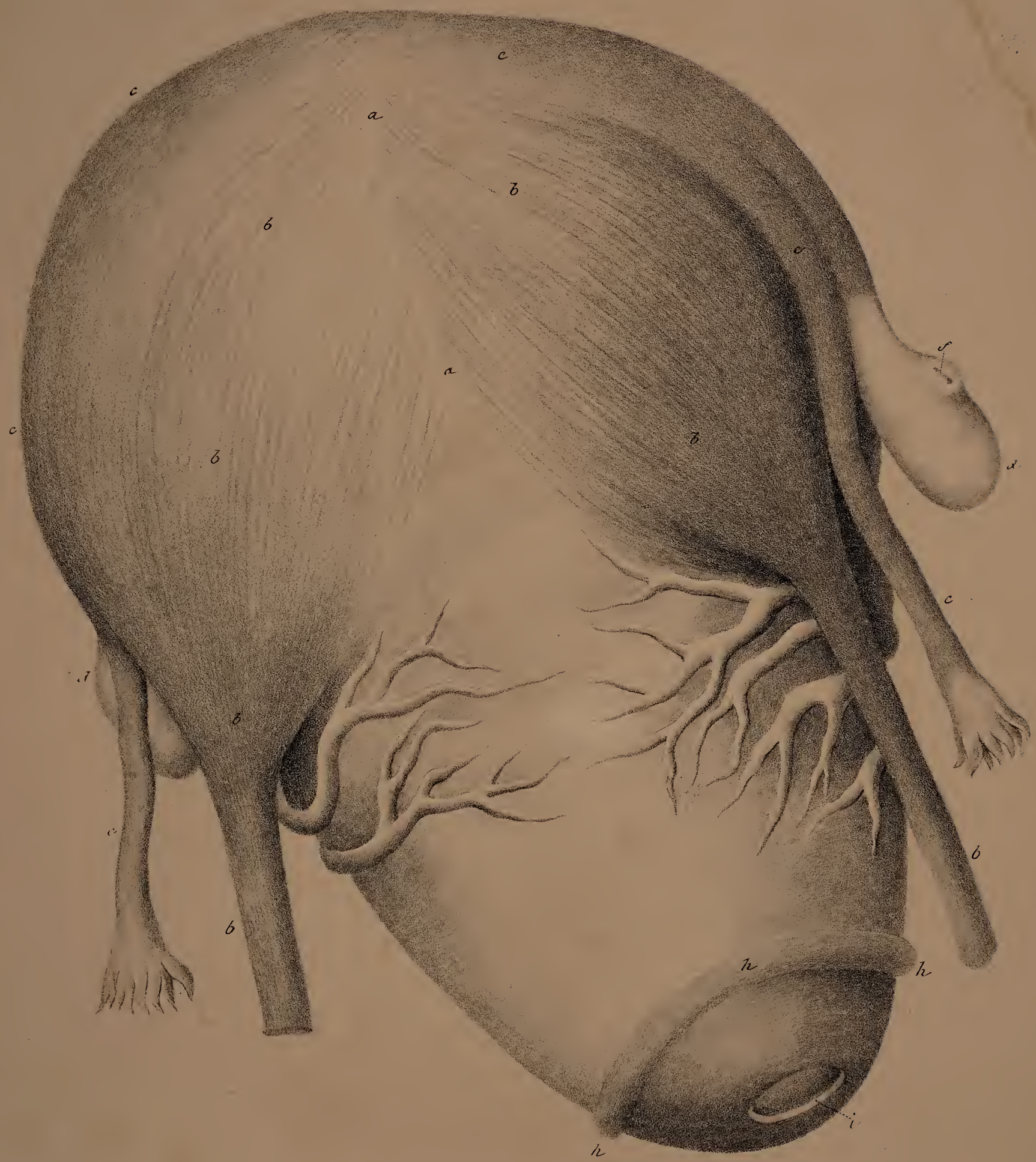

REPRESENTING THE DISPOSITION

OF THE FIBROUS PLANS OF THE UTERUS IN THE STATE OF PREGNANCY,

AT THE FULL TIME, SEEN ON THE ANTERIOR FACE OF THIS VISCERA.

EXPLANATION OF THE PLATES.

The organ is reduced to two thirds of its general size.

A. Median line of the uterus of which the upper extremity is inclined to the left, the most general direction. If the disposition of the median fibrous plans of the uterus, at the state of the greatest developement of this organ, be compared with the same plans in the uterus in a state of vacuity (plate 1st) a great difference may be remarked. The longitudinal fibres have disappeared, or rather their direction is changed, by their spreading from the base upwards, in the course of the developement of the uterus; in the 5th or 6th month of pregancy, these fibres spread out in the manuer of palm leaves, or of a fan open; (see pl. XXII.) and at the end of pregnancy, this median plan only represents a network of interlacing fibres throughout the whole length of this line.

B, B. The plans of the upper fibres, and the plans of the lower and transversal fibres, are united with a portion of the same plans of the fibres of the posterior face, into one bunch, in order to form the sub-pubian cords; these cords from the lengthening they have nudergone at their base, thus reach the two lower thirds of the body of the uterus.

It is upon the median line, on each side of the pubis, before, and upon the lower region of the sacrum, behind, that the plans of the exterior fibres of the uterus find their principal points of support, during the contraction of that organ.

C, C. The tubes, whose fibres take rise in the median line, at the bottom of the uterus, and which extend themselves transversally to the angles, to be reunited in form of tubes which terminate freely in an open fringed orifice, called the enlargement of the tube. (*pavillon de la trompe.*)

D, D. The ovaries aproximated, and almost at the level of the surface of the body of the uterus, from the effect of pregnancy.

E, E. The neck of the uterus containing a portion of the amniotic bag and the head of the fœtus. The neck of the uterus comprehends the space between the two points where the two upper pubian cords divide themselves from the uterus.

This lower portion of the uterus, of a pinkish-white, contrasts in a striking manner with the rest of the organ which is of a lively red. The tubes and the cords are rather less coloured.

F. Yellow body.

G. Uterine veins corresponding to the insertion of the placenta, upon the posterior division next to the neck.

H. Section of the vagina.

I. External dilated orifice letting a portion of the fœtal membrane be seen.

Nota. It is purposely that we have not represented the disposition of the different vessels of the body of this organ. This subject will be treated in a distinct description.

Boivin _ Dugès. Pl. 4.

UTERUS AFTER THE RECENT DELIVERY

OF A FŒTUS AT ITS FULL SIZE, SEEN ON ITS ANTERIOR FACE, AND STILL COVERED BY THE PERITONŒUM.

ITS COLOUR IS ALL OVER OF A LILAC-PINK.

EXPLANATION OF THE PLATES.

A. Median line turned round in two opposite directions.
B, B. Origin of the tubes.
I, I. Tubes.
C, C. Origin of the round ligaments.
O. Ovaries.
D, D. Plans of the exterior concentric fibres, designated by J. Sue by the name of *quadri-twin muscles*, and compared by Alph. Leroy to the nuts in wood. A similar disposition is remarkable upon the opposite partition.

This disposition of the fibrous plans of the uterus, so different from what we have seen in the virgin uterus, also from the same organ in a state of pregnancy, very often still differs from this in several other circumstances useless to mention here. But since we have continued our researches upon the structure of the uterus, we have found that all these puckers are only formed at the expense of the peritonœum and of the *sub-peritoneial uterine* tunic which covers the real fibrous plans of the uterus. These, in contracting themselves have nearly preserved, their primitive disposition; this disposition, we have recognised since we have been able to take off entirely the two tunics which envelope the uterus, and adhere to it in an excessively close manner, especially upon the median and upper regions.

This new discovery of the true disposition of the fibrous plans of the matrix after delivery, has been made the subject of a memoir inserted in the bulletin of the medico-practical society. 1830 (*see the 2 following figures*)

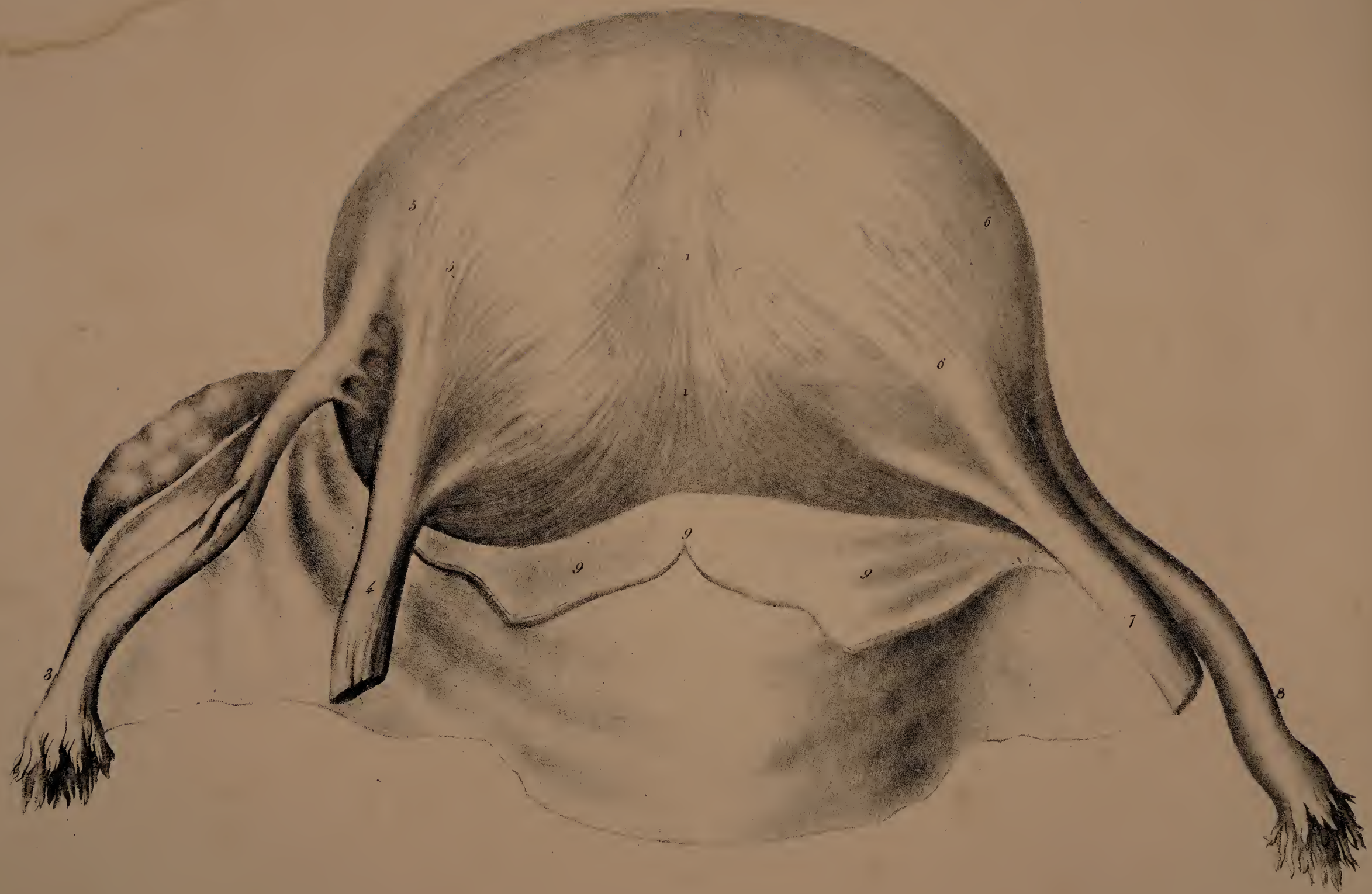
1
1
1
5
5
6
6
9
9
9
4
7
3
8

VIEW OF THE ANTERIOR FACE OF THE UTERUS,

RECENTLY EMPTIED OF A FULL GROWN FOETUS, AFTER HAVING BEEN DEPRIVED OF THE PERITONEUM AND SUBPERITONEAL-UTERINE TUNIC.

EXPLANATION OF THE PLATE.

1, 1, 1. Median plan of the uterus.
2. Right ovary.
3. Right tube.
4. Upper pubian cord, or right round ligament.
5. Fibrous plans common to the round ligament, and to the tube of the right side.
6. Fibrous plans common to the round ligament 7, and to the left tube 8.
9, 9, 9. Shreds of the muscular tunic of the peritoneum which covers the anterior face of the body of the uterus.

Nota : In consequence of the separation of some portions of the fibrous plans of the uterus, the effect of the developement of the organ, it may be seen how necessary was this muscular tunic which embraces in a close manner the bottom and the body, and maintains them, thus, in their respective relative positions. Without this conservative means, ruptures of this viscera would be much more frequent.

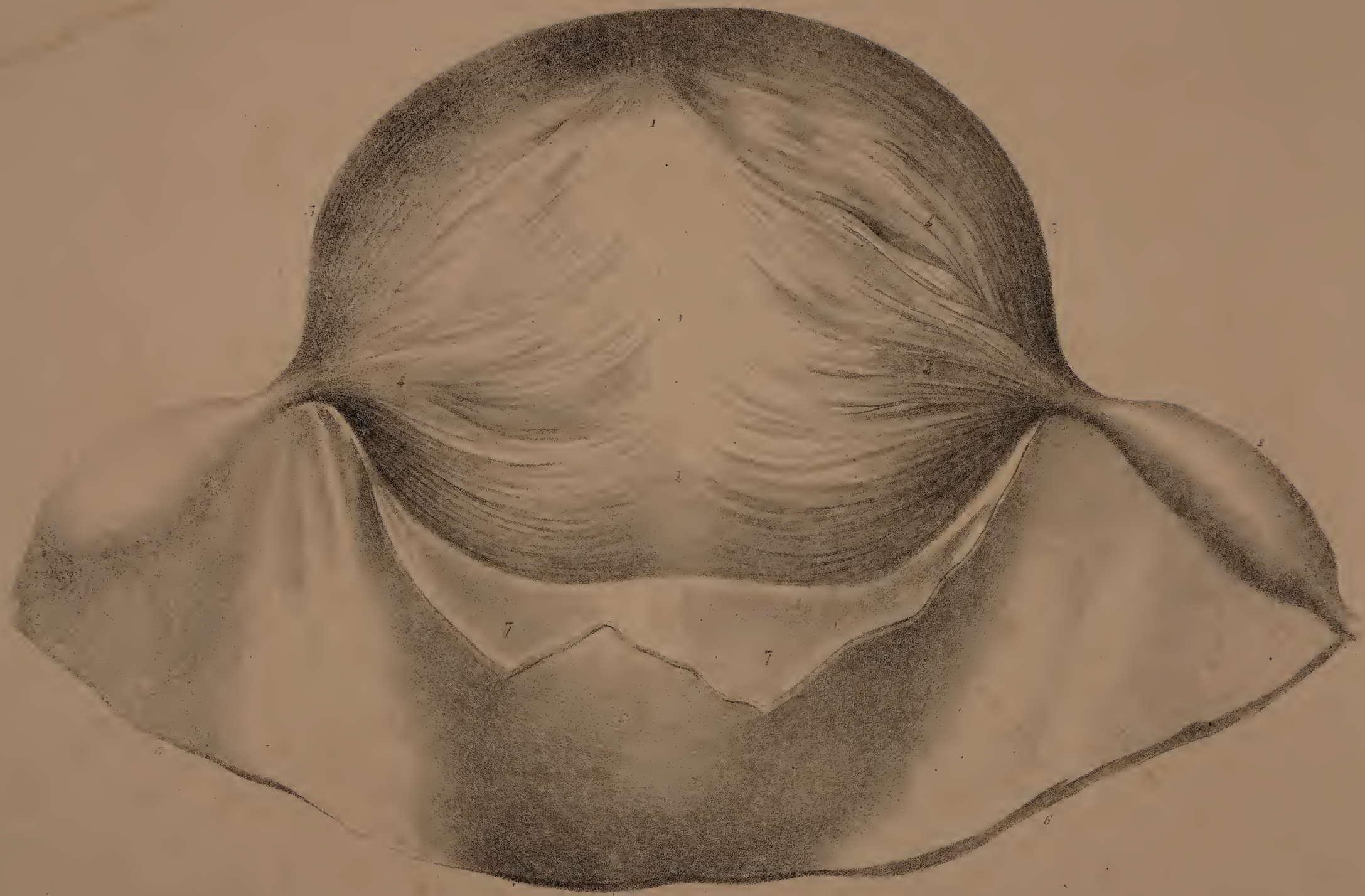
1
5
2
4
4
3
2
7
7
6

VIEW OF THE POSTERIOR FACE OF THE UTERUS,

REPRESENTED IN THE PRECEDING PLATE (nº V.) THE PERITONEUM IS TAKEN OFF.

EXPLANATION OF THE PLATE.

It will be remarked upon this side of the uterus that the fibrous plans which lead to the ovaries take rise in a common centre, that is to say in the median line and at the bottom of this viscera.

1, 1, 1. Median line.
2, 2. Ovaries.
3, 3. Fibrous plans common to the tubes and ovaries.
4, 4. Fibrous plans proper to the ovaries.
5, 5. Oblique ascendant plans common to the ovaries and to the upper pubian cords.
6, 6. Large ligaments.
7, 7. Shreds of the sub-peritoneal tunic and of the portion of the peritoneum which covered the described plans.

Nota. We will remark here that the pinions of the ovaries as well as their ligament had disappeared during the pregnancy. That their effacement was to the profit of the posterior division of the uterus. The organ in developping itself, took up the fibrous tissue which seems to be kept in reserve in the state of vacuity to furnish means for the increase of the uterus during pregnancy.

The ovaries, which, in a state of vacuity, were at three or four inches of distance from the angles of the uterus, are only, at the end of gestation, at some lines distance from the body of this organ, and nearly in the middle of its lateral edges. It may be seen by this disposition how much the ovaries are exposed to compression and to ontward shocks, as they have nothing more than the very thin divisions of the abdomen to protect them in an advanced state of pregnancy. (*see* for this last case: plate III.)

Boinin – Dugès. Pl. 7.

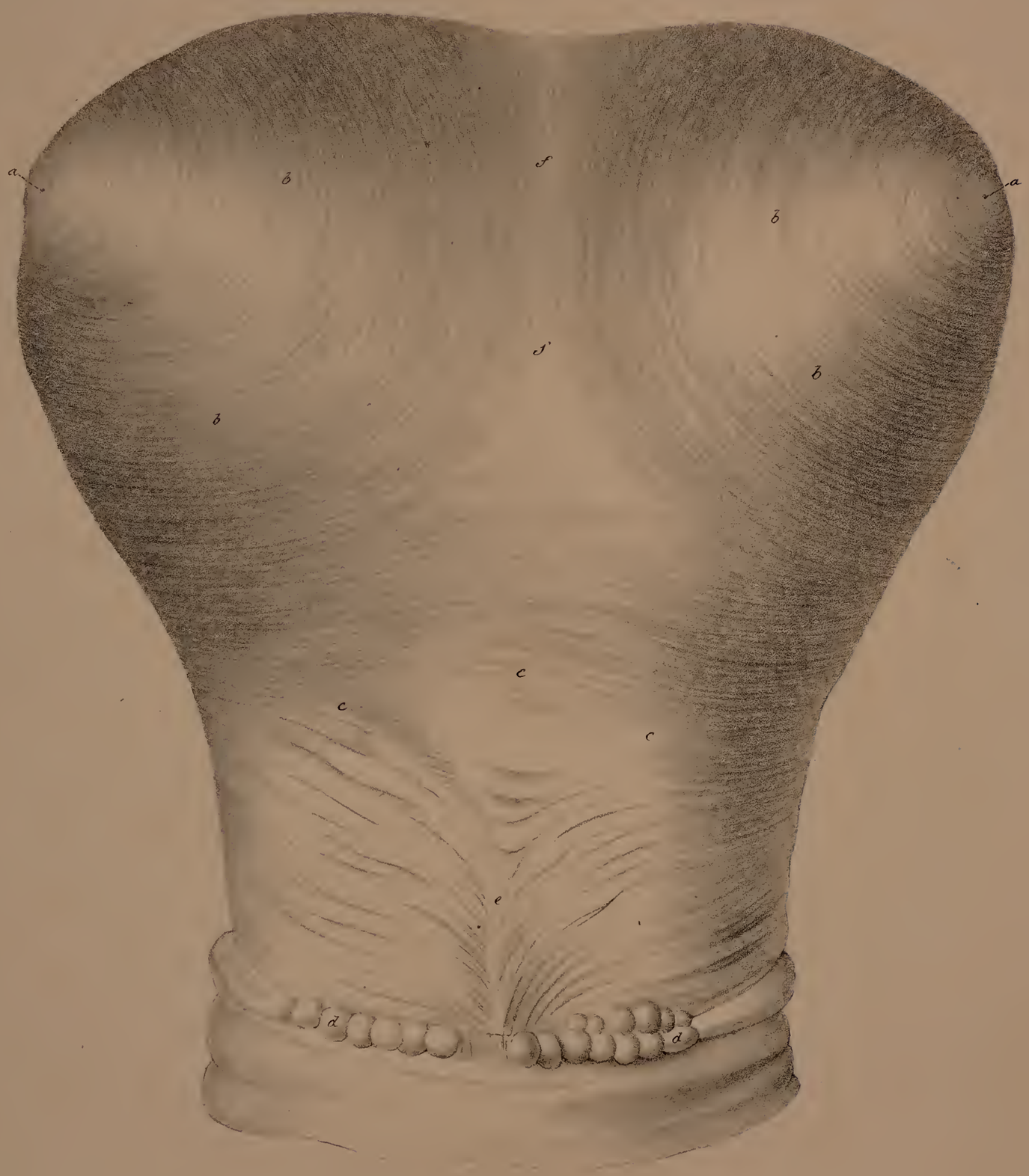

VIEW OF THE UTERUS ON ITS INTERNAL FACE,

AFTER ITS RECENT DEPLETION OF THE FULL GROWN FŒTUS. INTERNAL POSTERIOR PARTITION.

THE PLACENTA WAS INGRAFTED ON THE OPPOSITE PARTITION.

EXPLANATION OF THE PLATE.

A, A. Internal orifice of the tubes : *utero-tubar.*

B, B. Plans of the concentric fibres of the internal lateral regions, or *expulsatory muscles* of *Ruish.*

This observer had never remarked this disposition but on one side only, whether the opposite plan had become effaced, whether it had been covered and altered by the presence of the placenta, or lastly whether this celebrated anatomist did not sufficiently persevere in his researches; he has never mentioned more than one plan of these fibres, which we have always found *double*, when the placenta was not ingrafted on one of them; but there was always some portion of it to be seen.

F, F. Internal median line; disposition of its fibres.

C, C, C. Internal orifice of the uterus.

D, D. External orifice forming on the vagina a light corded pad at the surface of this canal.

E. Median line of the posterior division of the neck which gives birth to the numerous folds which are seen on its surface.

Nota. These folds are only perceptible when the neck has remained in a state of collapsus; they are so thin and so intimately fastened one upon the other, that most frequently they cannot be distinguished but in shaking the piece in clear water. If afterwards you plunge the piece into water strongly saturated with sulphate of alumine, you will see the partitions of the neck drawn up in every way its folds change their direction, its orifices contract themselves, that of the opening of the neck of the womb drawn into the neck, and retake its mamelonneous form. This phenomenon takes place instantly and under the eyes of the experimentor, when the solution is sufficiently strong.

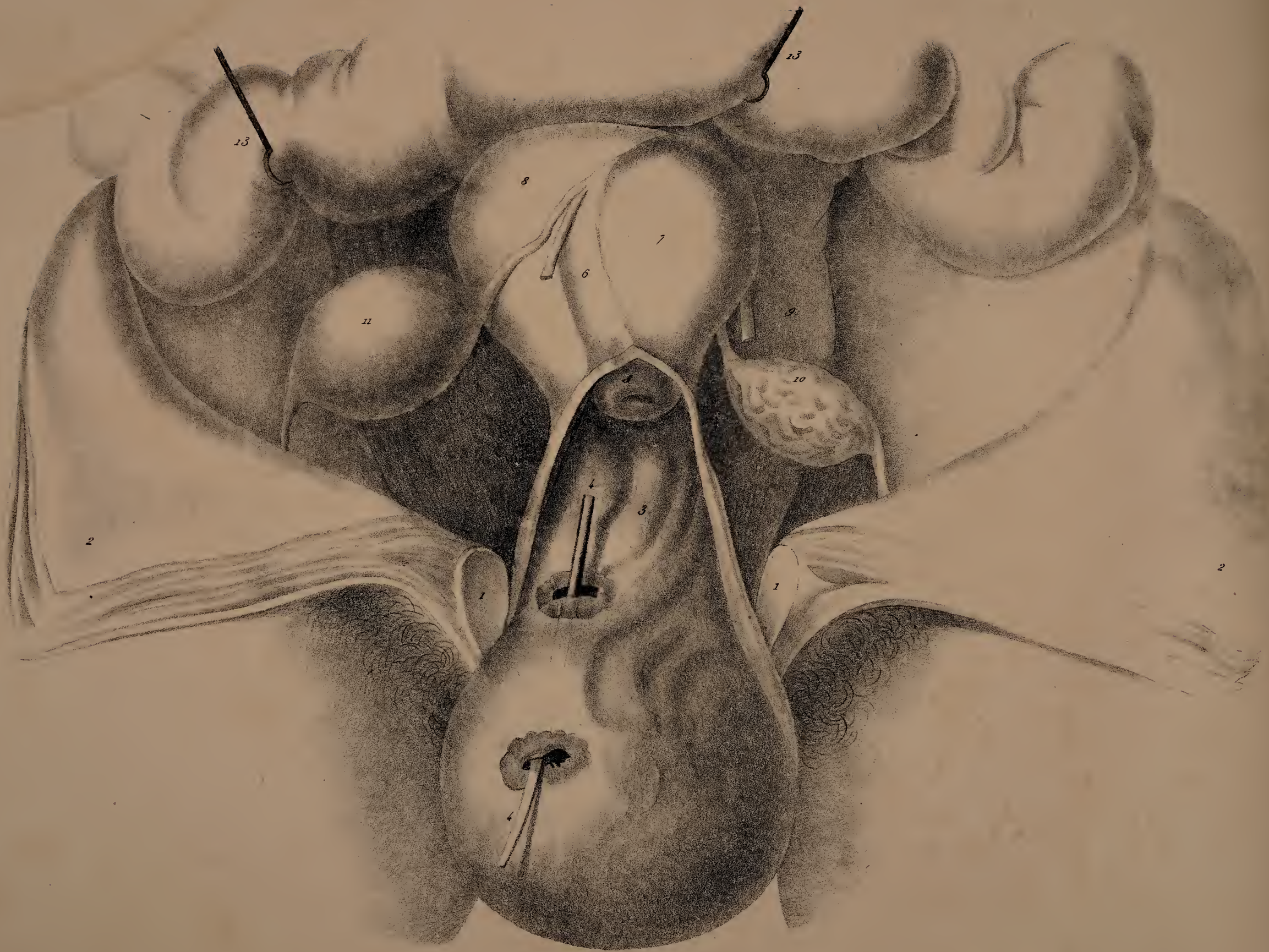
13
13
8
7
6
11
9
10
5
4
3
2
2
1
1
4

PROLAPSUS OF THE VAGINA.

EXPLANATION OF THE PLATE.

Taken at first for a descent of the matrix to which a pessary was applied, this prolapsus of the vagina having returned. The pyramidal form which it assumed caused it to be taken for a polypus to which a ligature was applied; the accident happened a second time : second ligature applied, which was followed like the first time by the fall of a large tumor ; this was scarcely off, when a third appeared, of the same size and the same apparent texture as the first two. These tumors, (which appeared successively and spontaneously in less than a month), whose nature and seat had been misunderstood, were occasioned by the presence of an enormous mass of diffluent encephaloïdal tissue, which had been devolopped between the rectum and the vagina, covered by the posterior division of this last canal; it had formed a tumor as large as the fist at the bottom of the vulva.

1, 1. Cut of the pubis.
2, 2. Shreds turned over of the abdominal partitions.
3, 3. Posterior division of the vagina of a bluish livid red.
4, 4. Tube passed into the openings resulting from the application of the two ligatures after the interval of a month. (in the first days of January 1830, and the 28th of the same month. The third tumor appeared on the 12th of February.)
5. End of the neck of the womb.
6. Body of the uterus almost the whole of which was comprised between two white fibrous tumors with smooth surfaces, to which the neck appeared soldered. This organ was situated almost at the level of the umbilical.
7. Anterior fibrous tumor.
8. Posterior tumor.
9. The rectum thrown back and very lengthened, was dragged out with the uterus.
10. The left ovary of a green yellow, hard, and wrinkled on its surface.
11. Right ovary, transparent, membranous, containing a serous and diaphaneous fluid.
12. The right psoas.
13. The lower intestines lifted up to shew the parts which have been just described.

Fig. 1.

Fig. 3.



Fig. 2.

Fig. 4.



Fig. 5.

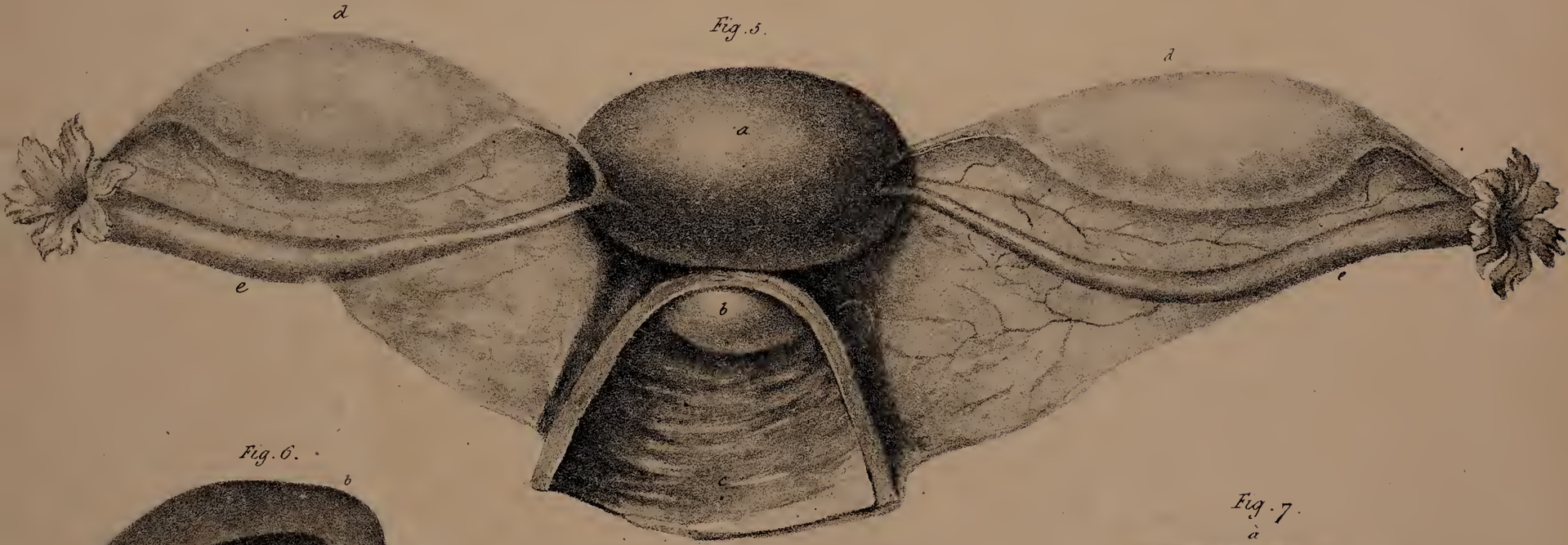

Fig. 6.

Fig. 8.



Fig. 7.

DISPLACEMENTS OF THE UTERUS BY DESCENT.

EXPLANATION OF THE PLATES.

Fig. 1.rst Semi-prolapsus having taken place at the end of a regular delivery.

A. vagina.
B. End of the neck of the womb.

Fig. 2. Complete prolapsus in consequence of a fall.

A. Vagina turned over.
B. End of the neck of the womb. The accident was recent.

Fig. 3. Stays aud adherences of the vagina.

A. End of the neck of the womb hid by the anormal stays.
B. Stays of the vagina.

Fig. 4.

A. Morbid prolongation of the vagina upon the orifice of the neck of the womb.
B. Tumefaction of the end of the neck of the womb.
C. Little red soft vascular tumors.

ANTEFLEXION OF THE UTERUS.

Fig. 5. The uterus folded upon itself presents its bottom in front.

A. Bottom of the uterus.
B. Anterior lip of the month of the womb.
C. Internal face of the vagina.
D, D. The ovaries situated above and before, instead of being behind and below the tubes.
E, E. The tubes having in the same manner followed the displacement of the uterus.

Fig. 6. The uteurs bent forward seen in profil.

A. The bottom of the uterus.
B. Elbow formed by the flexure of the uterus, point corresponding to the internal orifice.
C. Anterior lip of the month of the womb.
D. Vertical cut of the body and neck of the uterus.
E. Internal face of the vagina.

Fig. 7. Extroversion of the neck of the uterus.

A. Body of the uterus.
B. Internal edge of the opening of the womb.
C,C. Internal face of the neck become external by its overturn.
D. Accidental orifice of the neck of the matrix.

Fig. 8. Extroversion of the uterine neck seen on its face.

A, A. Edge of the external orifice.
B, B. Median lines of the internal face of the neck.
C. Accidental orifice.

Fig. 1.

Fig. 2.

COMPLETE PROLAPSUS OF THE UTERUS.

EXPLANATION OF THE PLATE.

Fig. 1st Complete prolapsus of the uterus, with the ouverturn of the vagina and of the bottom of the bladder, taken from a woman alive, 60 years of age, being in her dotage since some months.

A. External or utero-vaginal orifice of the uterus.
B. Superior orifice of the vagina having become inferior.
C, C. Mucous face of the vagina.
D. Urinary passage.
E, E. A style is passed downward in the neck of the bladder, and an *ideal* opening is practised to the partition of the vagina corresponding to the bladder, in order to shew the overturn of the urinary organ.
The bottom of the uterus was nearly at the superior angle of the ideal opening, the woman made water in compressing the tumor; the water mounted by the urinary passage D. But there was always a little of the liquid remaining in the bladder.
F, F. Ulceration determined by the flow of the water upon this overturned portion of the vagina.
G. The clitoris.

Fig. 2. Complete prolapsus of the uterus with the ouverturn of the vagina, having passed to the chronic state.

The woman who was suffering under this infirmity entered the maison de santé on the 27th of may 1832, on account of a stomack complaint which had been treated for a long time as an organic disease of that viscera. She spoke but occasionally of the descent of her matrix which she had for upwards of 30 years.

This woman never had but one child at the age of 28. On the 8th day after her delivery, she renewed her habitual occupations of *groom* her husband keeping a livery stable. Nearly immediately she felt an extraneous voluminous body coming out of her vagina. The phisician she sent for, replaced the organ in its natural situation, maintained it there by means of a large pessary, and kept her in her bed during a fortnight. The pessary incommoding the patient she took it off; she put-it on again, and again left it off entirely. It appears that the complete prolapsus did not take place for sometime afterwards. It was at the age of fifty (epoch of the total cessation of the menses) that the matrix entirely passed out of the vulva, and it was after this epoch that it remained hanging out, without occasionning any other accident than some dragging sensations in the groins and in the inferior regions of the sacrum. The mucous of the vagina had taken all the characteristics of the skin of the adjacent tissues. There was scarcely any remains of ancient wrinkles which furrowed this membrane before its overturn and its exposition to the open air. I easely replaced the tumor within, but the patient never would submit again to the trial of the application of the pessary. The perineum being lacerated to the anus, and the case requiring a mechanical instrument of a very large dimension, I did not insist to overcome the repugnancy of the patient who, as I said, was accostumed to her new state.

A. The clitoris.
B. The urinary passage.
C,C. The nymphœ, or small lips.
D, D. Large lips of the vulva.
E,E. The mucous surface of the vagina withered, having taken the aspect of skin; This canal, entirely overturned, contained the uterus entire which was of a very small size.
F. Small pediculated tumor at the right angle of the orifice of the end of the neck of the womb.
G. The epithelium of the end of the neck of the womb, excoriated, leaves naked the portion of mucous which covers this vaginal extremity of the uterine neck.

Fig 2

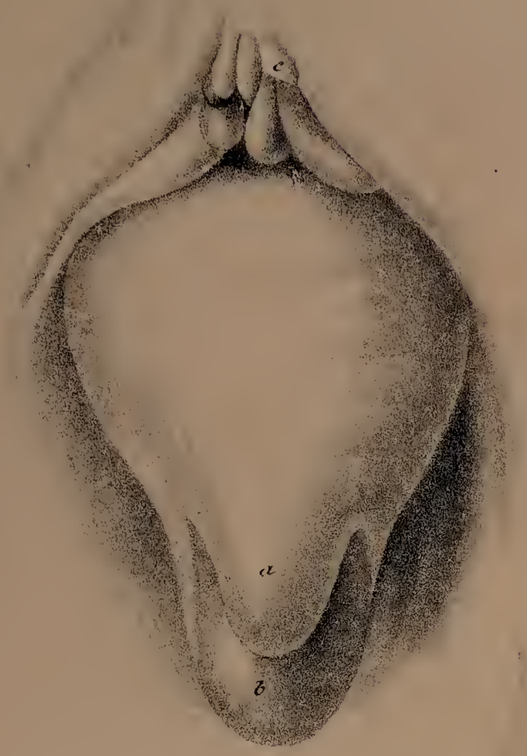



Fig 3.



Fig 4.

Fig 5.

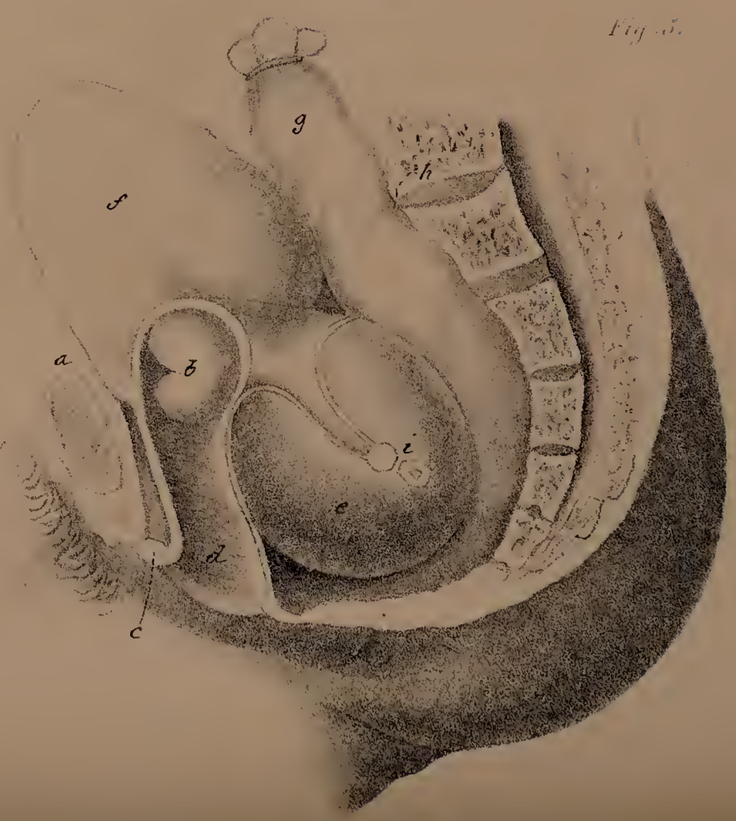

ELONGATION OF THE NECK OF THE UTERUS,

ITS FLATTENED FORM. — CRURAL HERNIANTE AND RETRO-VERSION OF THE UTERUS.

EXPLANATION OF THE PLATE.

Fig. 1.rst Prolongation of the neck of the uterus and prolapsus of this organ.

A. Posterior lip of the mouth of the womb very much lengthened and much more projecting than the anterior lip B.
C. Pediculated excrescences of the prepuce of the clitoris.

Fig. 2. The same neck of the uterus seen in profil.

Fig. 3. Crural hernia of the uterus.

A. Left portionof the abdominal partitions seen on its external face.
B. Right portion of the same divisions seen on its internal face.
C. Pubian region.
D. The left thigh.
E. The right thigh.
F. The vulva.
G,G. The cover of the tumor opened and turned over upon the thigh.
H. The matrix overturned and shewing in front its posterior face.
I. The uterine tube.
J. The left ovary.
K. The right tube.
L. The right ovary changed into a cyst.
M. An other cyst adhering to the right ovary and to the matrix.
N. Greasy mass strongly adhering to the matrix, and to the bag, and continning withit.
O. Prolongations of the epiploom which are cut, and overturned. (These 3 figures are copied from the original drawings of Mr. le professeur J. Cloquet.)

Fig. 4. Cut of the basin seen in profil representing the anteversion of the uterus in the commencement of pregnancy.

A. Right pubis.
B. The sacrum.
C. The bladder.
D. The urethra.
E, E. The rectum.
F. The cut of the tube and of the ligament on the left side of the ovary.
G. Body of the uterus.
H. Lateral portion of the uterus which is not covered by the peritoneum.
I. End of the neck of the womb.
J. The vagina.

Fig. 5. Retroversion of the uterus in the commencement of preguancy.

A. Right pubis.
B. End of the neck of the womb.
C. Urethral canal.
D. Vagina.
E. Body of the uterus.
F. The bladder in its greatest developement.
G. The rectum.
H. The sacro-vertebral angle.
I. Cut of the tube and of the ligament of the left ovary.

Fig. 1.

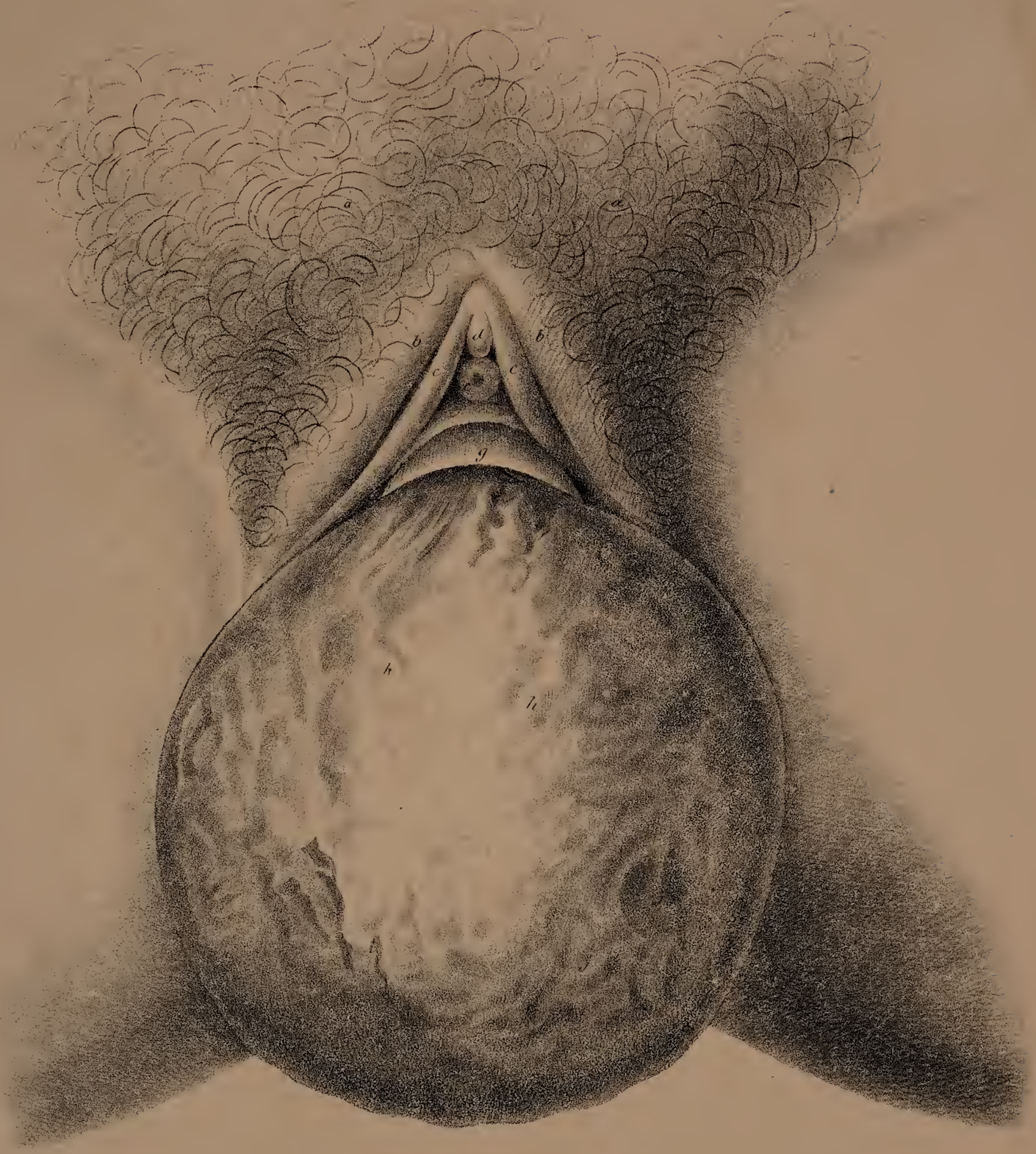

Fig. 2.



OVERTURN OR INTROVERSION OF THE UTERUS,

OCCASIONED BY THE HURRIED EXTRACTION OF THE PLACENTA.

EXPLANATION OF THE PLATE.

The restitution of the organ was attempted, but without succets, by several professional persons. This woman arrived at the *Maison de Santé* on the 6th day after her delivery.

Fig. 1st.

A. *Mont de Venus.*
B, B. The great lips of the vulva.
C, C. The small lips or nymphœ.
D. The clitoris.
E. The urinary passage.
F. The anterior external edge of the vagina.
G. The anterior edge of the external orific.
H, H. The internal face of the matrix having become external.
I, I. Some circulor lines of the plan of the concentric fibres.
G,G,G. Projecting points where the placenta was inplanted.

Fig. 2. The same overturned uterus, seen five years after the accident.

A. External orifice of the uterus.

B. Internal face of the overturned uterus presenting at its base some small reddish points.

During the 24 hours subsequent to the accident, the woman had an abundant loss of blood, which terminated in a profound long symcope. Not only the hemorrhagy had ceased, but there was not any more red lochia. The impossibility of making water and the consequent suffering were the only accidents which accompanied this serious event. Not being able to succeed in the reduction, and the excretion of the urine taking place soon after without assistance, the rest was left to the resources of nature and time. This woman who had come to Paris, for her clandestine delivery, returned to her homeabout fortnight after her entrance in the *Maison de Santé.* It was only five years after (when the came to request our advice in order to procure the return of her menses) thot we learnt she had been ever since deprived of this flow, and that we observed, by sight and touch, the state in which the uterus had remained.

Fig. 1

Bouvier – Dugès. Pl. 13.

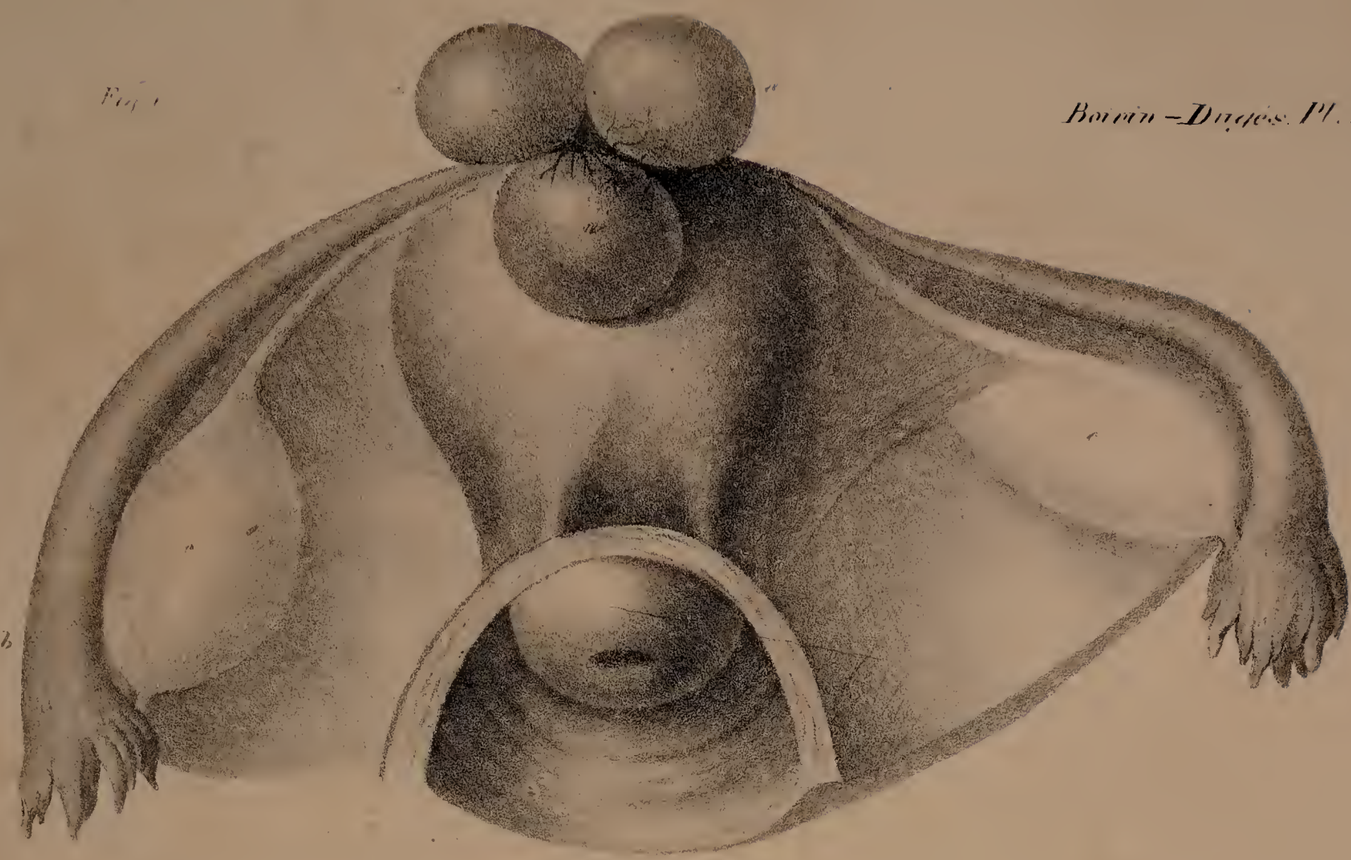



Fig 2.

Fig. 3.

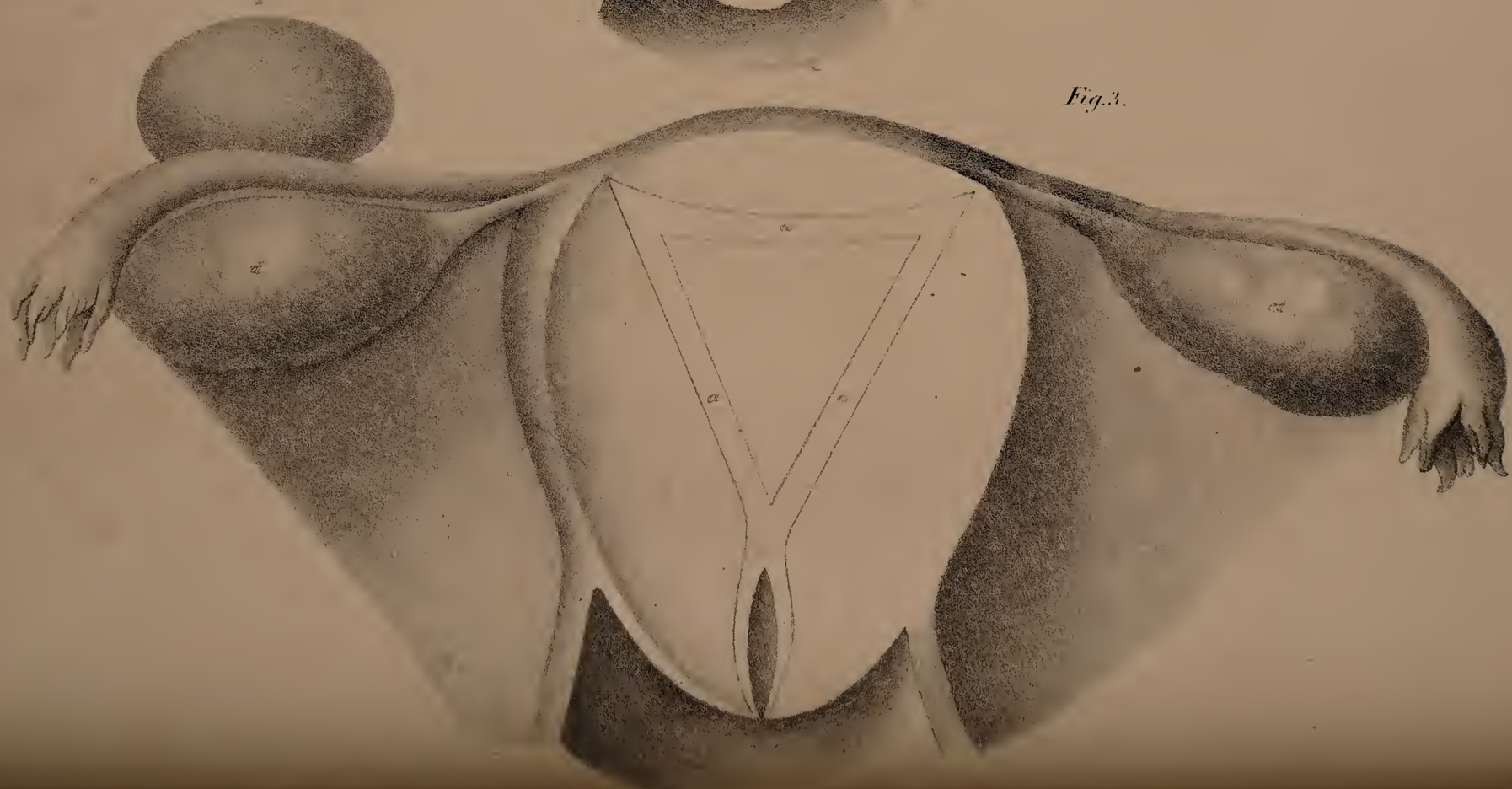

CASE OF COMPLETE OBLITERATION

OF THE CAVITY OF THE UTERUS AND TRANSFORMATION OF THE TISSUE OF THE ORGAN.

EXPLANATION OF THE PLATE.

The woman who furnished us with this case, was 50 years of age, she had been treated some years before, for a cancer in the nose; she died of a tuberculous phthisis of the lung.

FIG. 1.

A, A. Developped tumors at the exterior of the bottom of the uterus; this organ is seen on its posterior division. The three developped tumors behind the peritoneum, were of a white tissue, chalky, and very hard. The sharp instrument could not enter without the help of a hammer. Their surface was injected with numerous blood vessels of a very vivid red, arising from a pedicle.

B, B. The tubes.

C, C. The ovaries which were perfectly healthy.

FIG. 2.

Cut in its thickness in two equal portions, the uterus of the fig. 1rst, presented no cavity; the totality of the organ was composed of white compact substance, which could be cut like white soap, of which it had the aspect and the consistence. This woman had never been with child. (see the text. vol. 2. where several cases of this nature are related.)

FIG. 3. Other portion of the uterus of a woman brought in dying apoplectic.

The uterus cut through its thickness in two, did not offer any cavity, but a line A,A,A perfectly triangular, of a bluish white, of the hardness of cartilage, shewd traces of the ancient cavity of this viscera.

At the point B of the neck, a longitudinal furrow shewd the cavity of this portion of the uterus. It is by this opening that the blood escaped which had flowed in great abundance during the preceding days, and had its source behind the cartilaginoïdal layer of the posterior partition of the organ; it was possible at that place to separate this hard and thick layer.

C, C. The tubes were short but healthy.

D, D. The ovaries of a dark yellow were of a soft and greasy tissue.

E. Upon the left ovary a cyst was developped, of the size of an ordinary plum, full of a yellowish serosity.

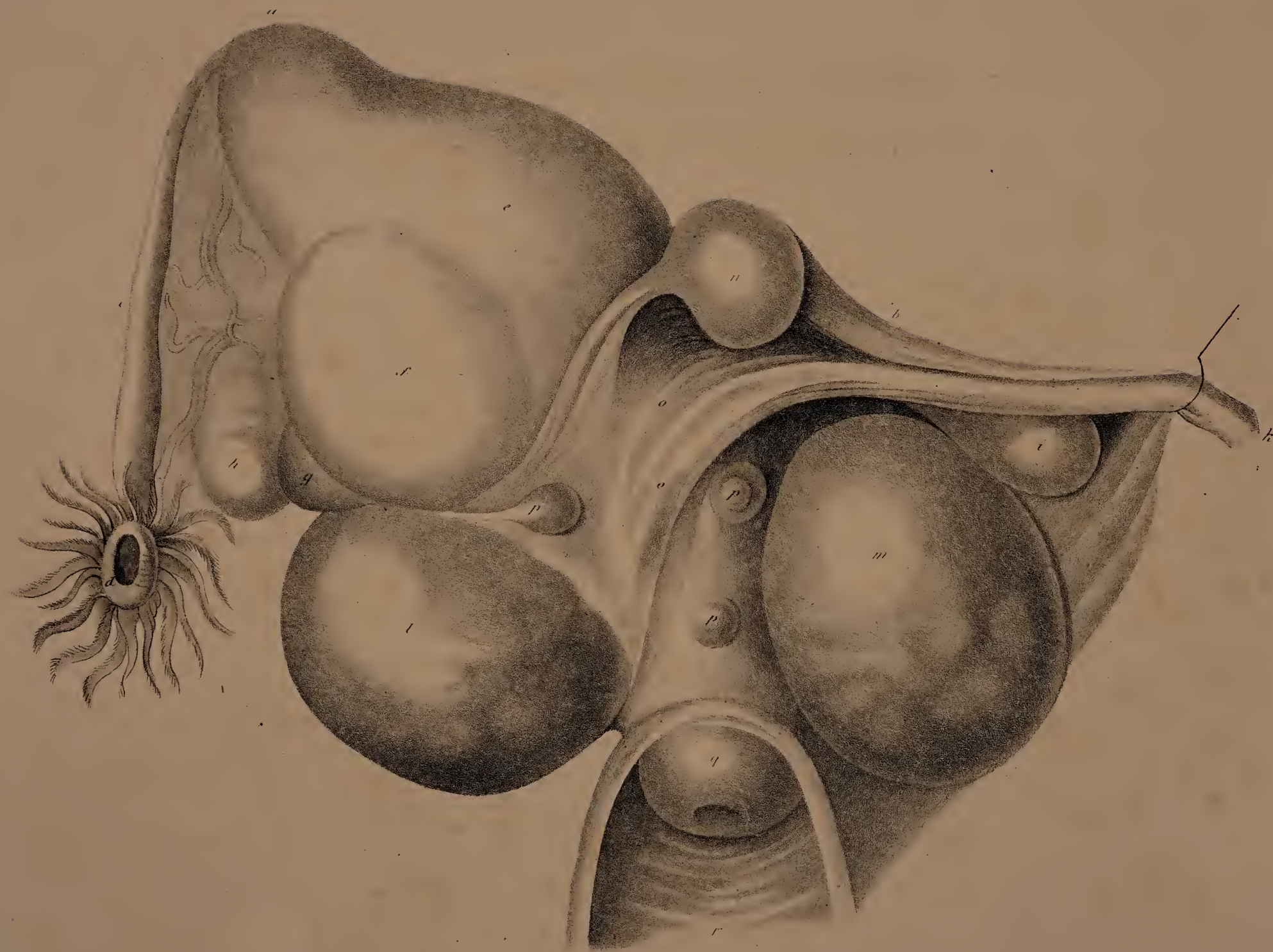
a
e
n
b
f
o
k
h
g
i
o
p
p
m
d
l
p
q
r

INTERSTITIAL FIBROUS TUMORS OF THE UTERUS.

THIS CASE HAD BEEN TAKEN FOR AN EXTRA-UTERINE PREGNANCY.

EXPLANATION OF THE PLATE.

Three tumors of various sizes were found in different regions of the matrix, and by the form and situation that they assumed gave to it the figure of a phrygian cap, or that of a cone.

A. Lateral right angle of the uterus forming the summit of the cone.
B. Place where the left lateral angle corresponds.
C. Right fallopian tube.
D. Enlargement of the tube hypertrophied. Seen under water, its long and numerous fringes presented on their lateral sides, some little threads similar to those which are observed on the edges of the gills of fish.
E. First tumor which had the form of a cone of which the small extremity answered to the tubular orifice.
F. Second hemi-spheric tumor.
G. Small portion of the third tumor which was oblong.
H. Right ovary.
I. Left ovary.
K. Round ligament, or right sub-pubian cord, the left cord was a little behind, between the tumor G and the tumor F.
L, M. Poly-lobed larded tumors, developped in the cellular tissue.
N. Pediculated hyatidiformed transparent tumor, full of a yellowish and limpid serosity.
O, O. Folds of the vesico-uterine peritoneum.
P, P. Tubercles in the state of crudity.
Q. End of the neck of the womb in the normal state, of a reddish brown.
R. Portion of the vagina.

A line drawn from the angle A to the orifice of the neck of the womb Q, would give the length and the direction of the cavity of the uterus. It formed a narrow canal of eight inches in length. The uterus was mobile.

Fig. 1.

Fig. 2.



Fig. 3.

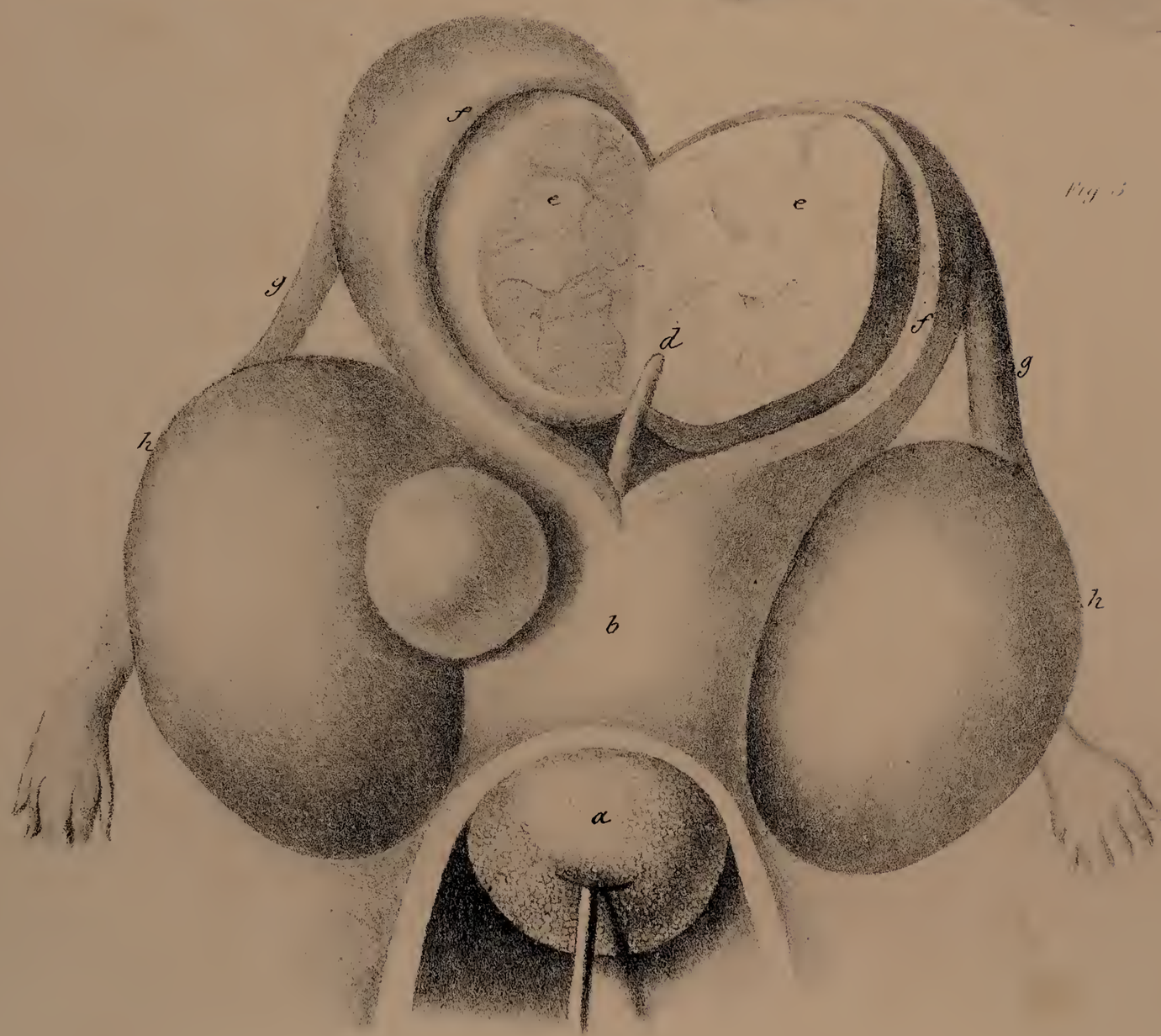

SEVERAL CASES OF TUMORS

OF THE UTERUS OCCUPYING DIFFERENT REGIONS OF THE ORGAN.

EXPLANATION OF THE PLATE.

Fig. 1rst. Interstitial fibrous tumor with sanguine congestion of the end of the neck of the womb, and melania of the left ovary. Case observed in a woman, who died of a chronic affection of the circulatory system.

A. Anterior face of the uterus.
B. Posterior face of the organ and seat of the tumor.
C, C. Right tube turned round.
D. Albugineous cover of the right ovary.
E, E. Right ovary developped on its inferior edge.
F, F. Fibrous bands arising from the cord of the ovary.
G. Opening made with the scalpel upon the peritoneal membrane of the ovary.
H. Black thick matter, contained in the ovary.
I. Tumefied month of the womb, of a livid red.

Fig. 2. Fibrous tumor of the fig. 1rst.

This body divided in two portions, represents the tissue of which it is composed, that is to say, of several small bodies, more or less hard, which had their fibres radiated from the center to the circumference.

Fig. 3. Fibrous tumor developped in the proper cavity of the uterus

This pathologic piece of the genital internal apparel offers several different affections of the organs of which it is composed.

A. The end of the neck of the womb more than double its ordinary volume, presents a rough surface like chagreen Its tissue is extremely. hard.
B. The neck of the uterus, developped in proportion to the mouth of the womb, is of a white tissue, rather cartilaginous; its internal face is smooth, and leaves not the least trace of its wrinkles.
C. Cavity of the uterus.
D. Style introduced in the orifice of the neck, and which penetrates into the uterine cavity.
E, E. Polly-lobed tumor occupying the proper cavity of the uterus and adhering to it only by a very thin lamellous tissue, which easely allowed its denucleation.
F, F. Divisions of the uterus (of a very elastic red tissue) on which were seen its different fibrous plans.
G, G. Fallopian tubes.
H, H. Ovaries converted into two cysts with fibrous red divisions, full of purulent yellowish matter, and of the consistency of pap.
I, I. Portion of the vagina.

(This woman, who entered the *Maison de Santé*, in order to be treated for a *sciatica* died of a *pleuro-pneumonia*.


h
i
i
k
k
k
d
l
m
m
j
o
b
a
b
c
c
d
d
g
e
f
f

CASE OF AMENORRHIA.

TUBERCULES IN THE CAVITY OF THE UTERUS AND IN ITS ANNEXATIONS IN A YOUNG GIRL, 16 YEARS OLD.

EXPLANATION OF THE PLATE.

A, A. The uterus open on its right lateral edge, and upon its bottom, shews a white tumor B,B upon each face of the organ.

B, B. This white granulated matter, of solid oppearance, is liquified by scraping, and penetrates into the proper tissue of the matrix.

C, C. Internal face of the neck of the uterus.

D, D. Internal or mucous face of the vagina.

E. Each of these tumors is composed of one or several cysts containing a solid and pultacious matter like dutch cheese.

G. The left tube, shorter than the other, is healthy.

H. This right ovary, soft, of a darkish tissue, only contains a mucous matter of a dark blue, a few vessels of vivid red, and a black body with a smooth surface, as large as a filbert, and of compact tissue.

J, J. The right tube offered three swellings upon its length, which wer determined by the presence of three voluminous tubercules K, every one of them provided with a cover or solid cyst; they are represented divided in their thickness. The tube was of a dark red, of a tissue thicker than in the normal state and generally more developped in its length.

L. The enlargement of the tube as well as its fringes, are converted into a mass of granulated tubercules of solid consistency.

M, M. The large ligament of the right side is strewed with numerous tubercules in the solid state.

Fig. 1.

Fig. 2.

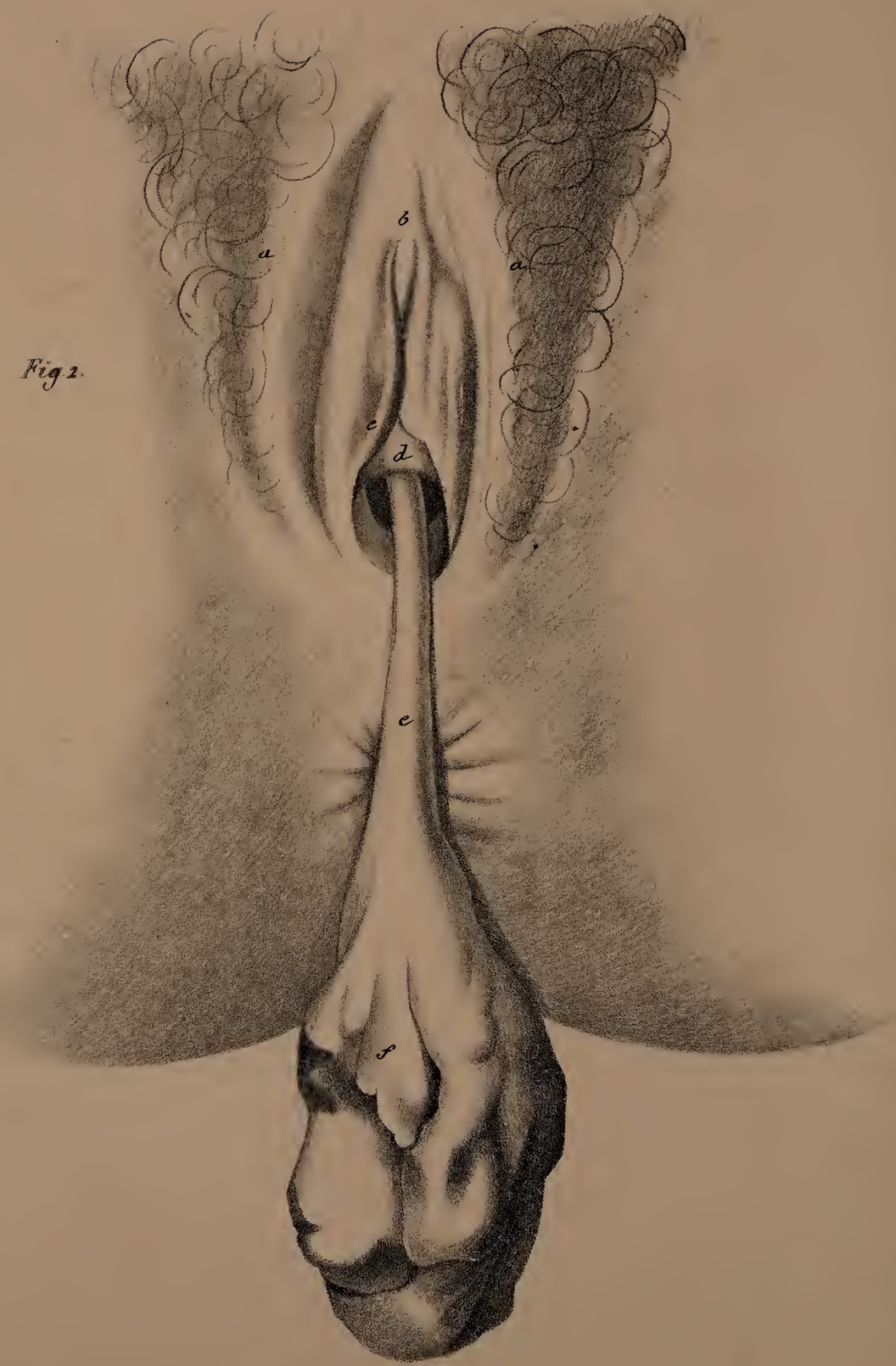

VESICULAR ABORTION WITH THE FOETAL MEMBRANES.

EXPLANATION OF THE PLATE.

Fig. 1st. Vesicular abortion with the fœtal membranes

This body represented ontwardly a red spungy, ovoidal mass, flattenned on its two opposite sides, without any opening when it came out of the uterus. Its volume was half the size that is here represented the tumor being opened through its length and seen on its internal face.

A, A, A. Serous or amniotic membrane. The chorion cannot be distinguished. The membrane appeared to us to be single.

B. Fold of this membrane in which there still remained a small spoonful of serous fluid. At the time of the expulsion of the mass, it contained a tolerable quantity of it.

C, C, C. Three small red tumors, of the size of a cherry, of a solid consistency, containing a lardy substance.

D. Another periform tumor, surmounted by a second smaller, and of the same nature.

E. A transparent pediculated vesicule situated under a great number of other vesicules resembling those which composed the tissue of the whole mass.

F, F, F. Vesicules of the whole mass, situated on the exterior of the amniotic membrane.

Fig 2. Polypus like the clapper of a bell. (1)

This tumor was developped in a maiden woman, aged 40, it was closely shut up in the vagina; and it was pulled out with much trouble by means of ringed pincer. Its tissue was lobular, its surface unequal, and its pedicle several inches long.

A. Large lips.
B. The clitoris.
C. Small lips.
D. Anterior edge of the orifice of the vagina.
E. Semi-lunar ligament of the hymen.
F. Body of the polypus.

(1) Operation performed by J. Cloquet and copied from his original drawing of it.

Nota : This case offers a new proof that the pedicle is not the result of the dragging of the weight of the tumor.

Fig. 1.

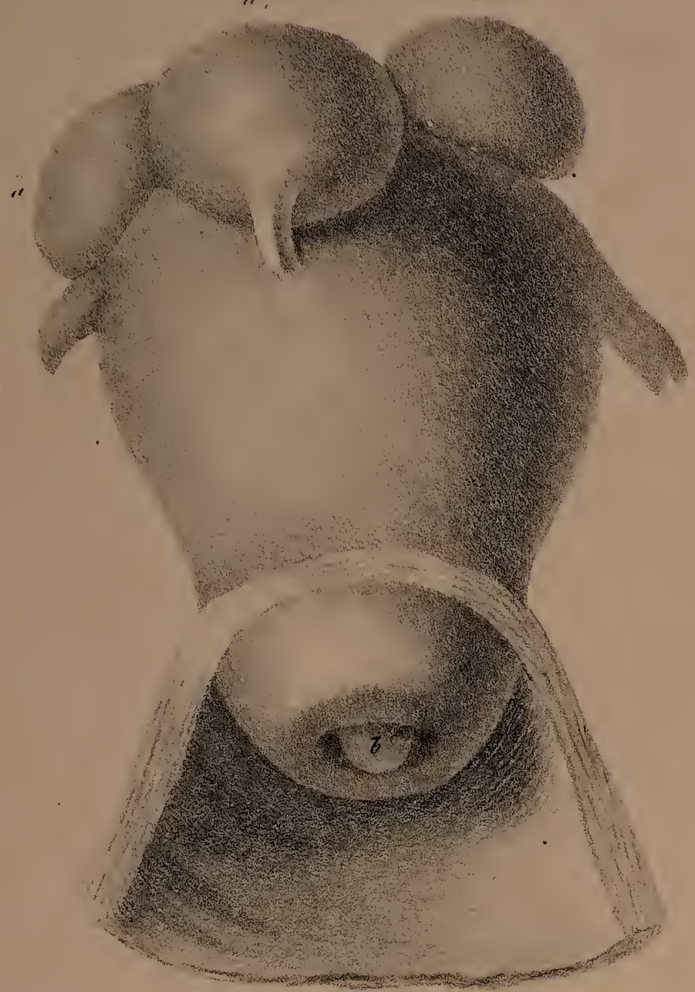

Fig. 2.

Fig. 3.

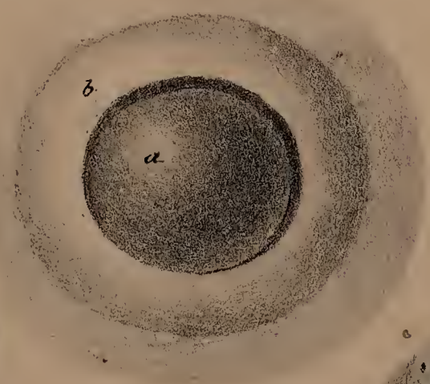

Fig. 5.

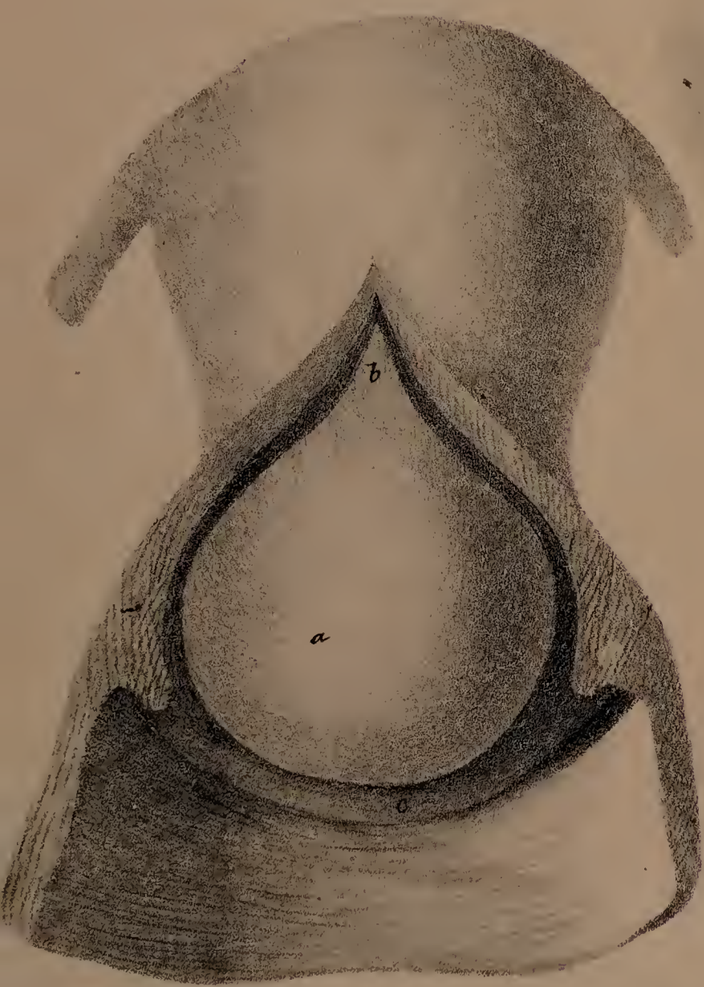

Fig. 4.



POLYPI OF THE UTERUS. (METRORRHAGIA.)

EXPLANATION OF THE PLATE.

FIG. 1rst.

The uterus, of at least double its size, presents outside and at its bottom, three pediculated tumors A,A,A.

B. Another small pisiform tumor, presents itself at the orifice of the neck of the womb.

FIG. 2.

The same uterus opened on its right lateral edge, presents in the interior of the neck, three little red pediculated bodies, of which each one contains a small cyst filled with an uncoloured albuminous matter flowing out when pricked by the point of the instrument.

A. Anterior division of the uterus.
B. Anterior lip of the mouth of the womb, longer than the other, on its external face the small polypus took its rise.

Nota. The body and the neck of the uterus were very soft.

FIG. 3.

A. Polypus which is in the orifice of the neck of the womb, and which coincided with a cancer of the right breast; no menses. No flow of any kind.
B. Orifice of the end of the neck of the womb.

FIG. 4.

Uterus very developped, greatly injected, of a very soft tissue, containing in its cavity a fibro-cellular tumor, A, adhering by a thin accidental membrane, B.

C, C. The neck very long and of a violet white.

FIG. 5.

A pediculated polypus inserted into the bottom of the cavity of the uterus, its fall happened spontaneously. The woman died some days afterwards, of an affection of the lungs.
B. Pedicle of the polypus.
C. Edge of the external orifice of the uterus.

Fig. 1.

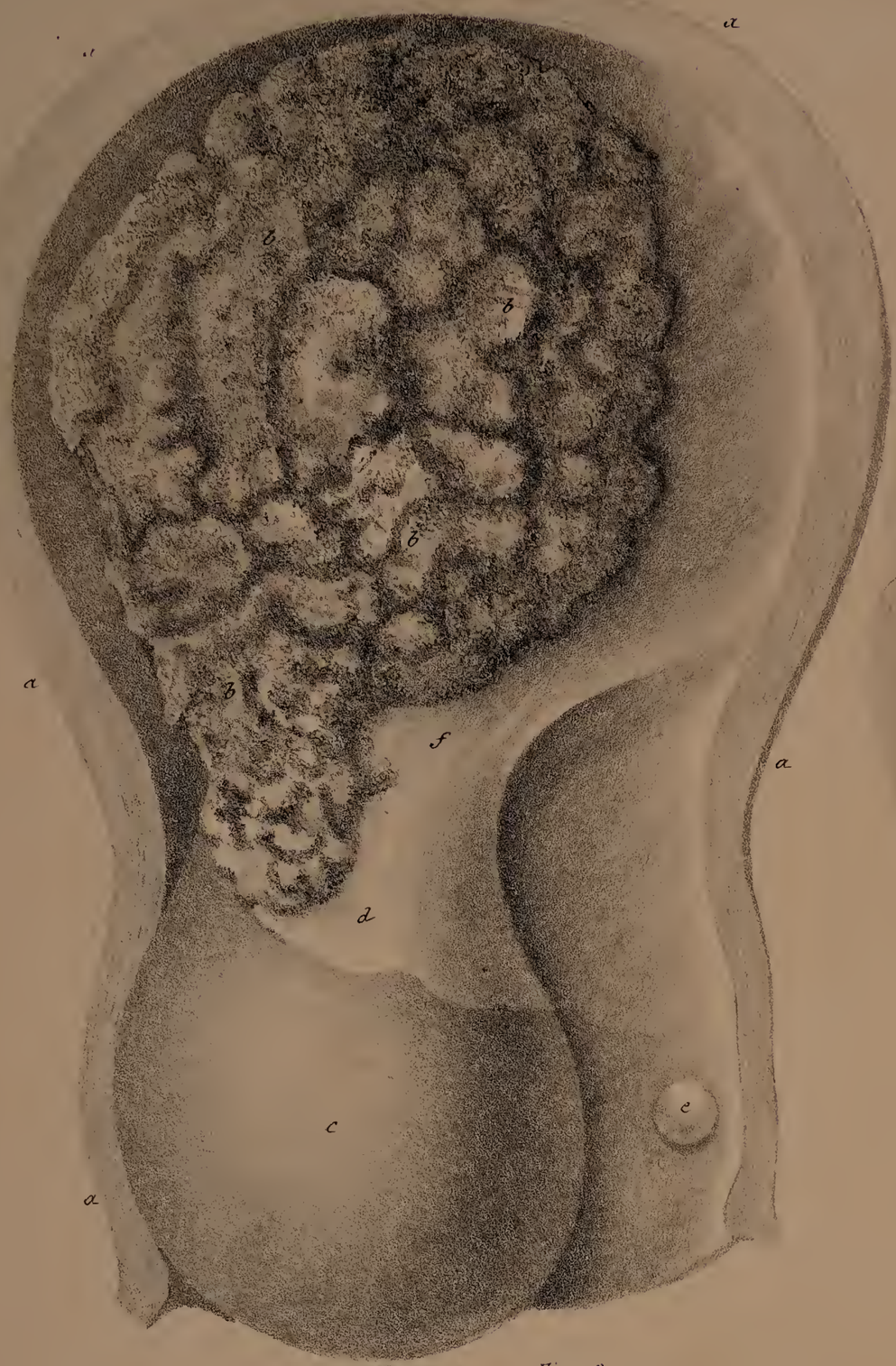

Fig. 2.

Fig. 3.

Fig. 4.



POLYPI OF THE CAVITY OF THE UTERUS.

EXPLANATION OF THE PLATE.

FIG. 1^rst. Posterior portion of the uterus of a woman, who died of an affection of the brain, the second day after her delivery, which had been natural.

A, A. Longitudinal cut of the uterus.
B, B. Traces of the places where the placenta was situated.
C. Palmated pediculated polypus, F, of an encephaloïdal tissue.
D. Shred of the decayed membrane, or ephichorion.
E. Solid tubercle of a yellowish white.

FIG. 2. Polypus in the form of a clapper of a bell.

A. Body of the polypus.
B. Frail pedicle which took its rise at the posterior middle face of the neck of the uterus.
C. Portion of the neck out of the vagina D.

The base of this pedicle E, had the aspect of a little placenta; the tumor was lumpy on its surface and covered with a fine membrane and with numerous veiny vessels.

FIG. 3. Hollow polypus of enormous dimensions, and which was treated by ligature, with success, by professor Dubois.

A, A, A. Folds formed by the application of the ligature.

FIG. 4. Vertical cut of the same polypus.

A, A. The slice presents a tissue composed of several fleshy superposed, reddish layers.
B, B. The internal face of the tumor offers a membranous appearance, and presents several furrows resulting from the reduction of the size of the tumor.
C, C. Orifices which opened outwardly and by which blood and others liquids flowed out, before the ligature was applied.
D, D. Folds resulting from the application of the ligature.

This tumor appeared to be formed by the concretion of the plastic fluid of the uterus, during a certain period of time that the woman had no flow of the menses. The successive addition of these pseudo-membranous layers gave rise to a kind of bag which served as a lining to the organ whose form it had taken. This bag, probably detached at first at its bottom, at last presented itself at the orifice and was fixed in it in the manner of an uterus in the case of over-turn of that organ.

This pathologic piece shewn to several medical men, was taken for an over-turned uterus. But certainly the uterus had remained in its natural situation.

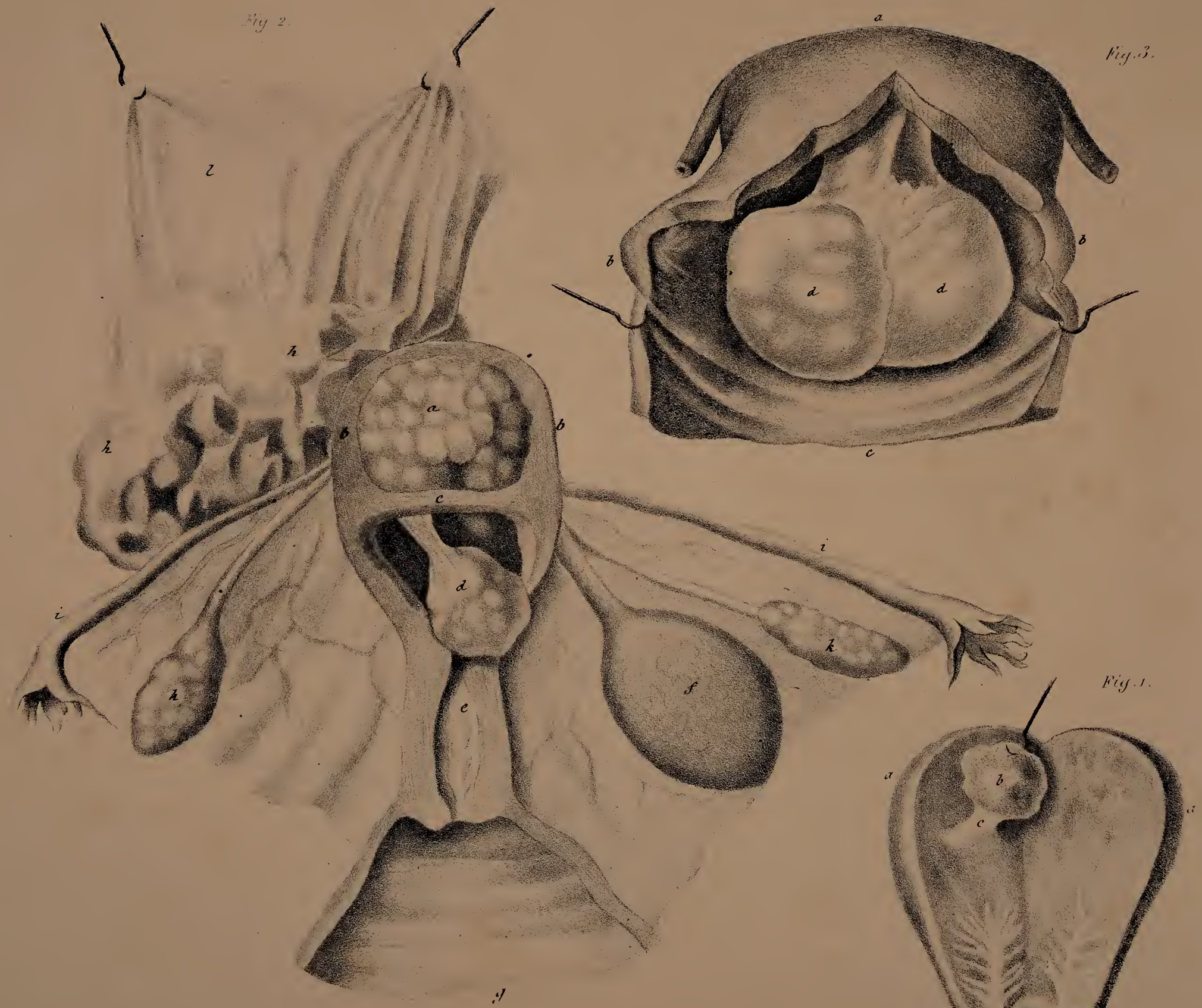
Fig. 2.
l
h
h
a
b
b
c
d
i
i
k
k
f
e
g
Fig. 3.
a
b
b
d
d
c
Fig. 1.
a
b
c
a

POLYPI OF THE CAVITY OF THE UTERUS.

EXPLANATION OF THE PLATE.

FIG. 1er. Uterus coming from a woman who had a miscarriage three months before her death.

A, A. The body of the uterus of a pale red. It was very soft.

B. Small softish, spungy, red body, adhering by a very fine and transparent lamellous tissue, to the internal face of the uterus.

FIG. 2. Pathologic piece taken from a woman of 70 years of age. All the lymphatic ganglions were very full. — The matrix seen on its posterior face.

A. Rounded, stony, unequal concretion, surrounded by the substance of the uterus.

B. Substance of the organ developped in its bottom, separated, by a thin partition from the cavity of the uterus.

C. Partition of the cavity of the uterus.

D. A pediculated vesiculous, soft polypus, (containing many little vesicles, filled with a yellowish fluid) occupies the whole of the lower cavity of the uterus, and is inserted in the bottom of it. (*The pedicle does not depend on the traction of the polypus,* for, this pedicle was bent down on itself, and the little polypus filled up all this cavity; upon the plate it has been drawn down.) At the bottom of the uterus, four or five small agglomerated vesicles, filled with a transparent fluid and projecting upon the divisions of the uterus.

E. The neck of the uterus offered no alteration : it was very narrow in its superior portion.

F. Flattened, yellowish, soft body, holding, to the uterus by a long vascular pedicle; over which climb several flexible arteries. This body is formed of several yellow granulations, and of some small concretions.

G. The vagina.

H. Is a very hard concretion of the size of the fist, yellow, very heavy, rugged with tubercles, adhering, by the membranous ligatures, to the anterior part of the matrix and vagina, and to the epiploom. This large tumor, sawed, offered a composition of very firm, white, fibrous tissue, in small quantity, reuniting the unequal grains of the stony, white, friable, opaque tissue, with another still harder yellowish and half transparent.

These three substances were mixed and united intimatly.

Description and drawing from M. J. CLOQUET, extract from his port-folio.

I, I. Tubes very healthy.

K, K. Atrophied ovaries.

L. The epiploom weighs at least a pound and a half.

FIG. 3. Pediculated polypus of the uterus.

This figure is copied from Clarke; he attributes the longitudinal depression to the presence of the canal of the urethra.

The tumor is attached to the bottom of the uterus by a narrow neck. It passed from the uterus into the vagina.

A. Bottom of the uterus; the anterior division of the organ opened to shew the form and the point of attachment of the polypus.

B, B. Section in two portions, of the end of the neck of the womb.

C. The vagina.

D. The tumor.

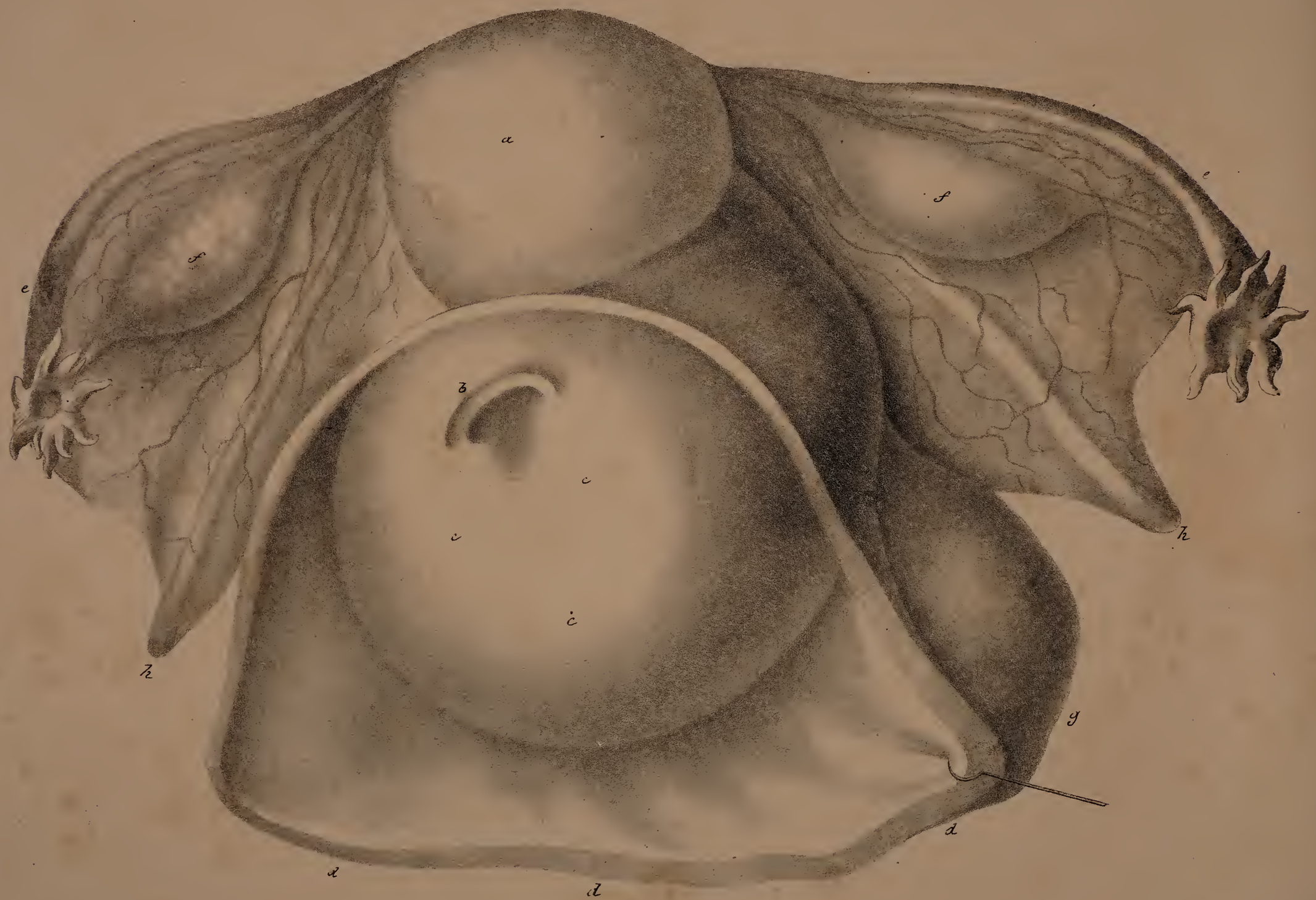
a
f
f
e
e
b
c
c
c
h
h
g
d
d
d

SCHIRRHOUS DEGENERESCENCE

OF THE ANTERIOR LIP OF THE MOUTH OF THE WOMB.

EXPLANATION OF THE PLATE.

This portion of the uterus had acquired this enormous size, without passing into a state of ulceration. The violent metrorrhagies, of which the patient died, were occasioned by the extreme dilatation of the numerous vessels of the internal face of the uterus.

The uterus is seen on its posterior division.

A. Body of the uterus having three times its ordinary size.
B. Posterior lip of the month of the womb.
C,C,C. Anterior lip of the mouth of the womb.
D,D,D. Vagina largely developped, its wrinkles effaced by the presence of the tumor.
E,E. Fallopian tubes in the normal state.
F,F. Ovaries, both healthy.

The ovarian vessels were very voluminous and the large ligaments strongly injected.

G. Portion of the bladder over-turned.
H. Round ligaments seen through the peritoneum.


c
c
b
d
d
d

VERTICAL CUT OF THE UTERUS,

WHICH IS THE SUBJECT OF THE PRECEEDING PLATE.

EXPLANATION OF THE PLATE.

This figure represents the thickness of the anterior lip of the mouth of the womb, and its extent. The orifice, seen in the plate XXI, is here placed behind; it is indicated by the style A, which penetrates into the cavity B of the uterus. The extreme thickness of the partitions of the bodies of this viscera, may be remarked.

C, C. Whitish granulations which penetrate the tissue of the uterus.

B. Numerous orifices of the vessels of the uterine cavity, which produced a mortal hemorrhagy.

D, D. Cut of the tumor formed by the anterior lip of the mouth of the womb. There may be seen a multitude of hard granulations of a bluish white, as if cartilaginous, crammed into the totality of the tissue of the organ.

Fig. 1.

Fig. 3.

Fig. 2.

SCHIRRHOUS TUMEFACTION.

EXPLANATION OF THE PLATE.

Fig. 1. Schirrhous tumefaction of the posterior lip of the mouth of the womb.

This tumefaction has been found upon the uterus of a woman who died of tuberculous phthisis, after a miscarriage at the 6th month of pregnancy.

A. Bottom of the uterus.

B. *Palmated* disposition of the fibrous plans of the uterus during pregnancy.

C,C,C,C. Tubes grouped on the posterior surface of the uterus, and each of them describing a handle in which are framed the ovaries which are strongly adherent to the posterior division of the uterus, by numerous morbid folds of the large ligaments.

D,D. Ovaries.

E,E. Large ligaments.

F. Posterior lip of the mouth of the womb, of a schirrhous tissue, and nearly of an inch in thickness.

G. Hitaditiforn tumor on the superior and the exterior left angle of the bottom of the uterus. This cyst, of the form and size of a fig, was transparent and contained a serous and yellowish-fluid.

Fig. 2.

Schirrhous end of the neck of the womb; orifice largely open; its edges thin, hard, and cut.

This disposition which was found in a woman eminently lymphatic, was accompanied with very abundant flow of the whites.

Fig. 3.

Tumefaction; induration of the end of the neck of the womb, strewed on its surface with livid points, on a violet ground, equally accompanied with abundant flow of the whites.

This lady was fair, pale, having all her muscles soft and flabby; her mother and sister, thus affected, had both died of a cancer of the matrix.

Fig. 2

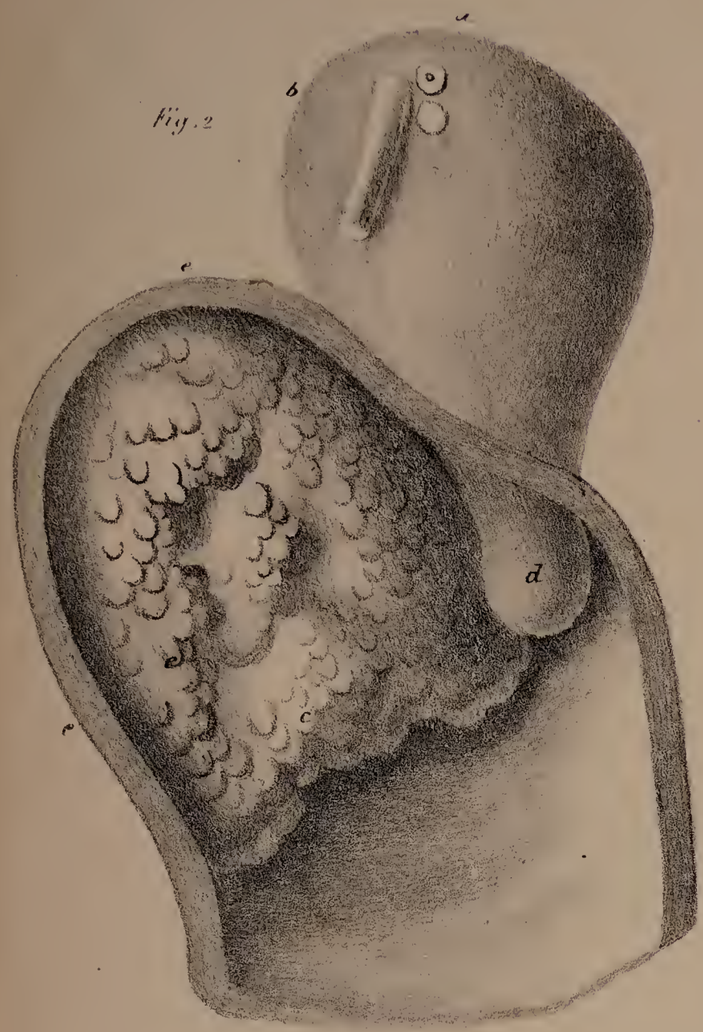

Fig. 1.

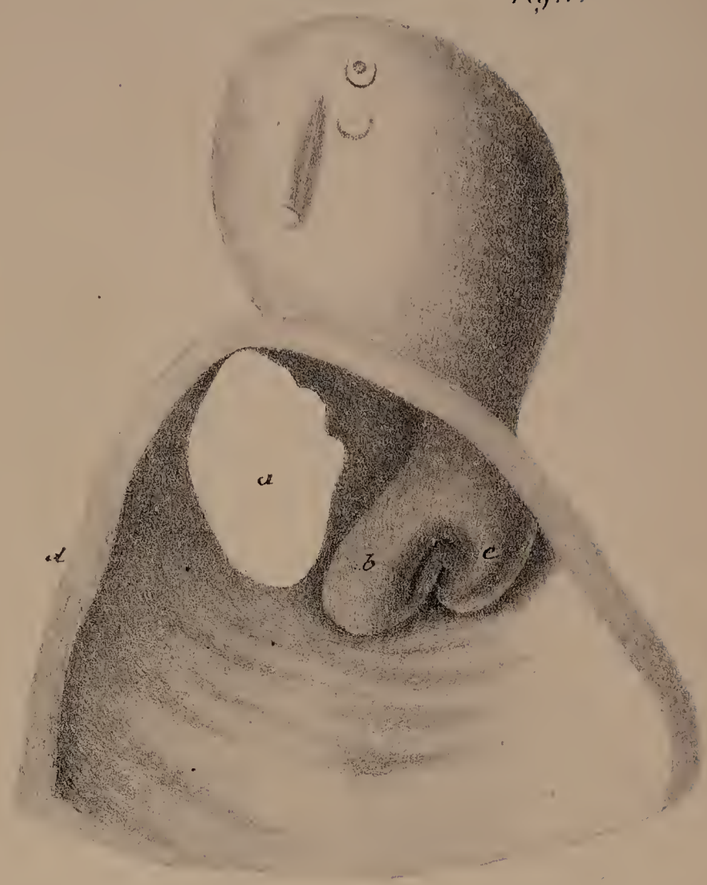

Fig. 3.

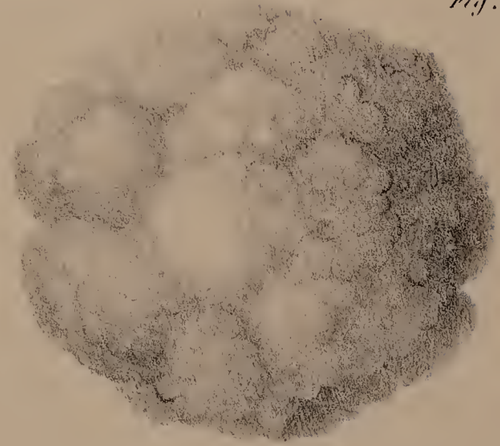

Fig. 4.

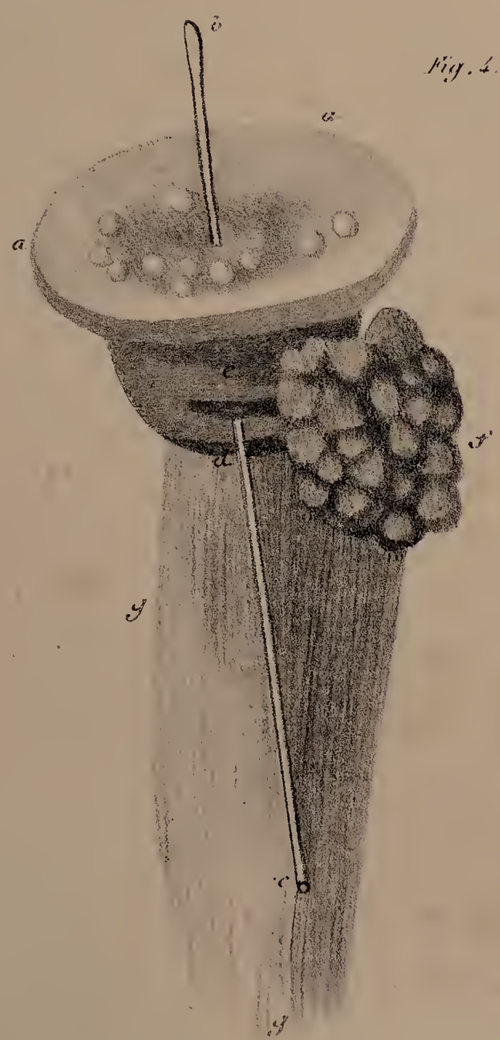

Fig. 5.

FUNGUS CANCER OR CAULI-FLOWER

OF THE END OF THE NECK OF THE WOMB.

EXPLANATION OF THE PLATE.

This affection is accompanied with considerable flooding, and also with a secretion of limpid serosity, inodorous, and prodigiously abundant.

Fig. 1.

A. Body of the uterus supposed in the natural state; but it will be remarked that the *posterior lip* of the month of the womb directs itself to the left, and that the *anterior lip*, the converted into an enormous tumor, designated under the name of *cauli-flower*, leans to the right.
B. Anterior partition of the hody of the uterus.
C,C. Cauli-flower of the anterior lip of the mouth of the womb.
D. Posterior lip of the month of the womb.
E,E. Portion of the vagina developped by the tumor.

Fig. 2.

View of the peduncle of the cauli-flower, after its separation, by means of cisors curved on the flat side. A ligature had previously been thrown over the neck of the tumor in order to bring it out of the vulva. The cut of the tumor presents a larded tissue which soon degenrated into a frightful cancer, from which, this woman died ten or twelve days after the operation.

Fig. 3.

An other cauli-flower less developped than the preceding; it was tried ad first, to bring the tumor to the vulva, with hooks thrusted several times in it, and wich always carried away a shred of the tumor. The day after, a ligature was applied, as in the preceding case, and the excision of the tumor was performed with flat cisors; at the same time, the whole of the end of the month of the womb was taken off.

Fig. 4.

Portion cut off from the neck of the uterus of the fig. 3.
A. Overturned portion of the neck, of which the thin and very softened tissue afforded the opportunity of bending down one of its edges, in order to shew the granulations of the internal surface.
B.C. Style passed into the neck, through its external orifice.
D. Anterior lip of the month of the womb.
E. Posterior lip.
F. Remains of the tumor after its ablation.
G,G. Shreds of very fine membranes, strongly injected with blood which covered the tumor.

Fig. 5.

Cicatrice of the stump of the neck of the uterus, a fortnight after the operation.

Nota. This last tumor after its excision, had lost its form and the three quarters of its size; the first which had been taken off entirely and at once, has kept nearly all its form and size, only its coloration of a lively red, was quickely dissipated in water, in which it was directly immersed.

Its coloration, therefore depended on the membrane by which it was covered, it penetraded into the interstices of the granulations of the tumor, as the pia-mater does between the circumvolutions of the brain. When this membrane was taken off, the tumor absolutely represented the granulated surface of the cauli-flower, a name which has been borrowed from the English.

Boivin Dugès Pl. 25.

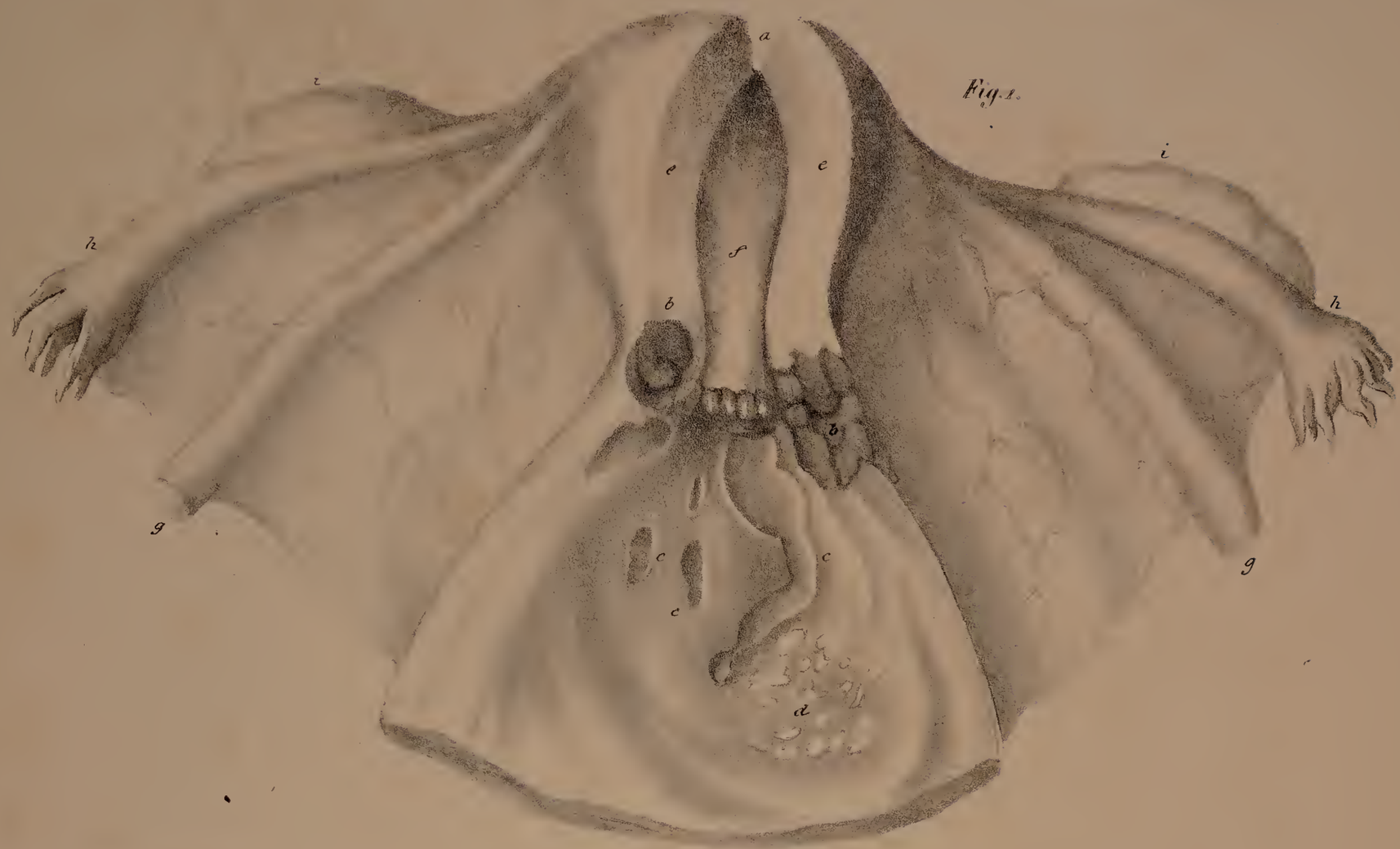

Fig. 1.

Fig. 2.

EXCISION OF THE NECK OF THE UTERUS.

EXPLANATION OF THE PLATE.

FIG. 1. Excision of the neck of the uterus. (1)

This piece had been the subject of a serious discussion; the woman, from whom it had been taken, had had an ulcer of the neck of the uterus. She was admitted at the *Ecole pratique de la faculté de médecine de Paris*. After an examination by several phisicians, it was recognised that the ulcer was of a cancerous nature, and found necessary to take off the diseased portion with cisors. M. Bougon, surgeon of this school performed the operation. The tumor removed, there ensued a violent inflammation of the uterus, which rapidly gained the peritoneum, and of which the woman died a few days afterwards.

The parts, after death, were examined with care by a great number of phisicians and surgeous: some of them persisted in their opinion that it was a cancer of the neck of the uterus; others perceived nothing, in it, but a venereal affection, which might have been treated with means milder, and surer in their results; those perceived in the ulceration which remained, upon the posterior partition of the vagina, all the characteristics of a venereal ulcer, whilst the operator and his friends would acknoledge, in it, nothing but the effect of cisors curved on the flat side, which had pinched and damaged the vagina during the attempts of excision of the neck. Such are the details, given to us, upon this case, by Dr. Guillou.

We have copied the piece as exactly as possible, and we present it here without any commentary.

A. Cut of the uterus upon its anterior partition.

(1) Figure of an uterus, which has been communicated to us by Dr. GUILLOU.

B. Place of excision of the end of the mouth of the womb.
C,C,C. Ulceration of the surface of the vagina, either having preceeded the operation, or being the result of it.
D. Little granulations which were remarkable at the surface of the vagina.
E,E. Thickness of the partitions of the matrix. Firm tissue and in the normal state.
F. Cavity of the uterus.
G,G. Sub-pubian cords.
H,H. Fallopian tubes, of a more intense red than in the natural state.
I,I. Healthy ovaries.
K,K. Large ligaments, strongly injected, thickened tissue.

Fig. 2. In a chaste girl.

A. Uterus seen on its posterior partition.
B. Rectum overturned to shew the adherences with the uterus.
C,C. Morbid membranes.
D,D. Tuberculous tumors common to the uterus and to the rectum.
E. Right tube obliterated and adhering to the ovary.
F. The right ovary.
G. Broken cyst presenting the form of the corolla of a lily.
H. Left tube, in the morbid state, adhering to the ovary.
I. Left hypertrophied ovary.
J. Large ligament.

Fig. 1.

Bouvier—Pinges Pl. 26

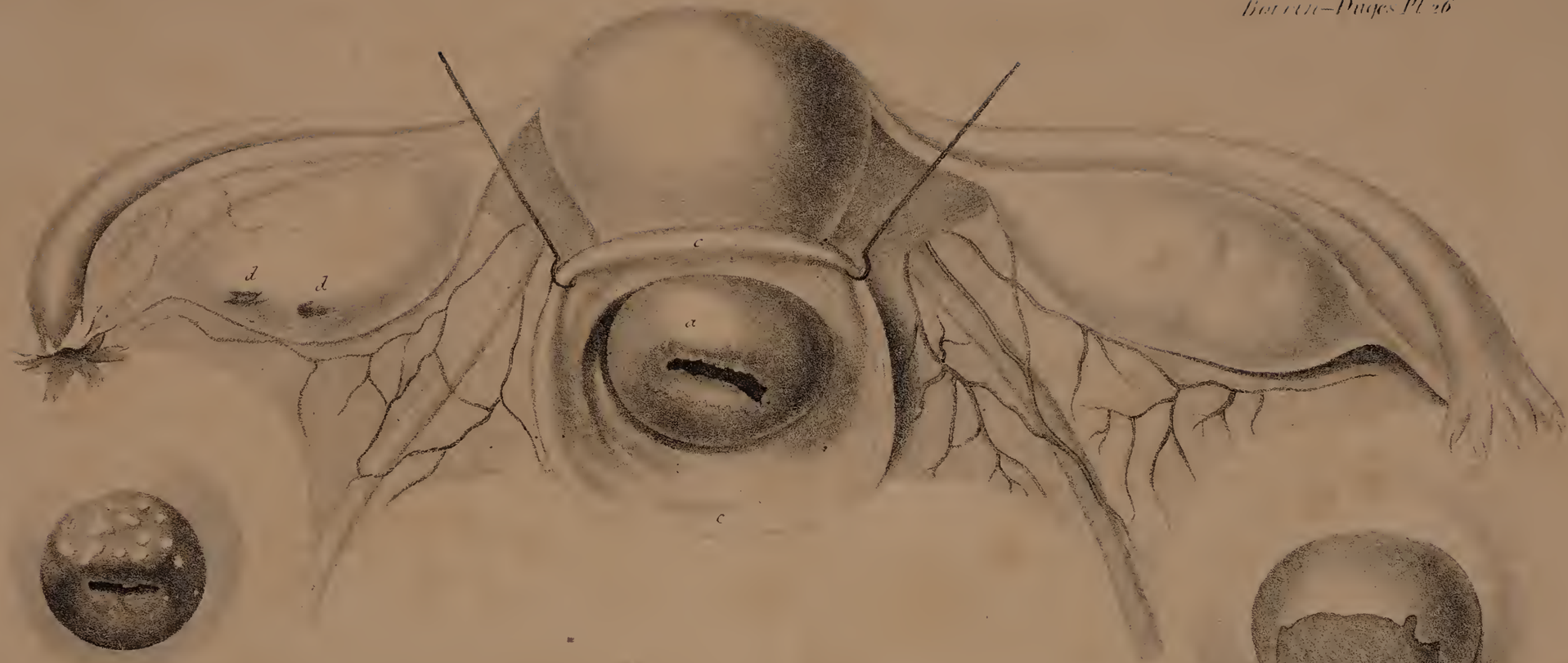

Fig. 3.

Fig. 5.

Fig. 2.

Fig. 4.



EROSIONS, SUPERFICIAL ULCERATIONS,

MILIARY VESICLES OF THE END OF THE NECK OF THE WOMB.

EXPLANATION OF THE PLATE.

FIG. 1re.

Uuterus seen at its posterior partition·
A. Sanguine congestion of the end of the neck of the womb.
B. Erosion of the edges of its orifice.
C, C. Superior portion of the vagina.
D, D. Recent little scars upon the left ovary. (the right ovary altho' healthy, is double the usual size).

FIG. 2.

End of the neck of the womb of a lady aged 24, maried and without children subject to an abundant flow of the whites. The epithélium of the end of the neck of the womb was almost entirely worn away. This portion of the uterine neck was almost constantly bathed in a very abundant secretion of puriform matter, coming from the interior of the matrix.

FIG. 3.

End of the neck of the womb of the natural size, of a lively red, strewed with miliary, whitish, soft vesicles on the surface. This state was accompanied with irregularity in the evacuation of the menses and emission of blood during coïtion.

FIG. 4.

End of the neck of the womb much tumefied; very extensive ulceration; Blennorhagic flow extremely abundant, accompanied by violent pain and very serious symptoms, snch as fever, diarrhiœa and metrorrhagia etc.

FIG. 5.

Tumefaction, ulceration of the end of the neck of the womb, habitual whites, frequent loss of blood.

Fig. 1.

Fig. 2.



Fig. 3.

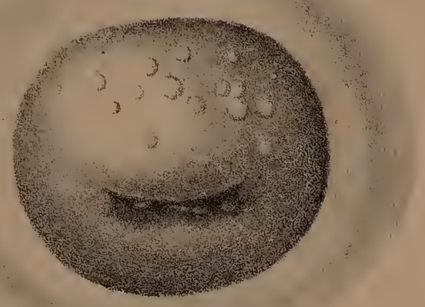

Fig. 4.

Fig. 5.

Fig. 6.

Fig. 7.

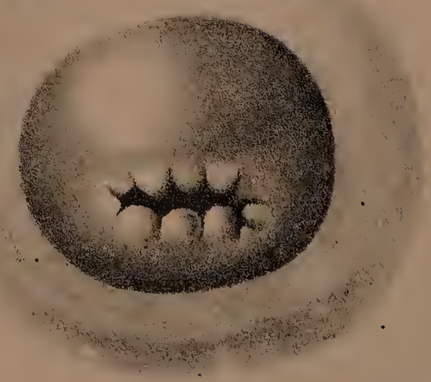

DIFFERENT AFFECTIONS

OF THE END OF THE NECK OF THE WOMB.

EXPLANATION OF THE PLATE.

FIG. 1er.

A young woman of 18 years of age; sanguine congestion with white granulations at the surface of the end of the neck of the womb; soft tissues, sanguine transsudation under pressure; more abundant emission during coïtion. Herpetic affection suppressed at the epoch of menstruation. Habit of masturbation.

FIG. 2.

Granulated concretion, superficial ulceration, sanguine congestion of the end of the neck of the womb. Dysmenorrhœa cured.

FIG. 3.

Granulated concretion, crosion, dysmenorrhœa, emission of blood during coïtion; cured.

FIG. 4.

Considerable tumefaction, hardness of the end of the neck of the womb; red spots on its surface; extreme sensibility to the touch; dysmenorrhœa treated with success by antiphlogistics and anodynes; afterwards pregnant; long labour, arising from the hardness and thickness of the divisions of the neck. (The mother of this lady, died of a cancer in the matrix).

FIG. 5.

Two little tumors of the size of a pea. Upon the anterior lip of the month of the womb; tumefaction of this part of the uterus, with bloody congestion; coloration of a bluish red. This disposition coincided with a tumor of the breast, which resisted the compressive method. (The mother of this lody had a serious affection of the neck of the uterus, cured by M. le docteur Marc.)

FIG. 6.

Tumefaction, sensibility of the end of the neck of the womb; its orifice surrounded by numerous transparent vesicles, resembling white currants, accompanied by plentiful loss of blood. These vesicles disappeared by the treatment of styptic injections; the flooding by means of a tonic regime, became much rarer.

FIG. 7.

End of the neck of the womb n° 6, seen after the disappearance of its vesicles, several months later; but the métrorrhagia returned, a pleutiful purulent discharge issuing from the orifice, shewing an ulceration in the interior of the neck, which brought on, later a complete perforation of this canal: and that of the bladder, and some time afterwards, the death of the patient.


Fig 1.
Fig 2
Fig 3
Fig 4
Fig 5
Fig 6
Fig 7.
a
Fig 8

DIFFERENT DEGENERESCENCES

OF THE END OF THE NECK OF THE WOMB.

EXPLANATION OF THE PLATE.

FIG. 1.

A. Sanguine congestion with enormous tumefaction of the anterior lip of the month of the womb, which is surmounted by a fibrous crest C, the lively red of which contrasts strongly with the brown colour of the part affected.

B. Posterior lip of the month of the womb.

The subject from whom this pathologic piece was taken, was a woman addicted to the use of strong lignors and to masturbation. She never had any children.

FIG. 2.

Gangrenous aspect of the neck of the uterus after the spontaneous destruction of the tumor.

FIG. 3.

End of the neck of the womb very developped, very hard, lumpy on its surface, of a pinky white; orifice widely open, very hard angular edges. State considered as the result of a venereal affection. Abundant métrorrhagia, excess of coïtion; habit of masturbation. This woman never had any children.

FIG. 4.

Induration, slight tumefaction of the end of the neck of the womb; colour light pink, smooth surface. A woman, long subject to abundant discharges both red and white. Excess of coïtion. The ulceration existed in the interior of the neck: it only appeared on the exterior part of the neck near the orifice, some few weeks before her death.

FIG. 5.

Ulceration of the anterior lip of the neck, the posterior very much lengthened. Purulent matter flowing abundantely out of the cavity of the matrix.

This state was accompanied by an abcess; formed in one of the ovaries, which burst in the bladder, and discharged in this way a considerable quantity of pus. The affection of the neck has remained just the same during seven years. (Patient of docteur ESPIAND.)

FIG. 6.

Schirrhous degerenescence of the end of the neck of the womb, accompanied by abundant loss of blood, pain in all the genital parts, calculous secretions in the bladder, and wens on different parts of the body; there was one on the top of the head, which was attacked by such violent inflammation, that a crucial incision was obliged to be made on the hairy scalp.

FIG. 7.

Cancerous ulceration of the neck of the uterus.

A. The organ seen on its anterior face.

B. Right ovary surrounded by the tube of the some side.

C. Anormal adherencies of the peritoneum.

D, D. Left ovary and tube in a healthy state.

E, E. Granulated shreds of the edges of the ulcer.

FIG. 8.

Vertical cut upon the median line of the same uterus; its cavity is limited to a slight furrow. Upon its white, thick partitions, several layers of larded tissues, mixed with bluish white granulations, may be remarked.

Bonnin Nuges Pl. 29

Fig. 1.

Fig. 2

Fig. 3.

TUBERCLES AND ULCERATIONS

OF THE INTERNAL GENITAL APPAREL; OSSIFICATION OF THE UTERINE VESSELS.

COMPLETE DESTRUCTION OF THE NECK OF THE UTERUS.

EXPLANATION OF THE PLATE.

FIG. 1er.

The uterus seen on its posterior partition, the body of which is rounder and more projecting than in the normal state, without being much more voluminous.

A. Body of the uterus.
B. Left tube surrounding the ovary of the same side.
C. Left ovary.
D. Ligament of that ovary.
E, E. Anormal adherenices of the large ligament.
F. Portion of the right ovary.
G. Other portion of the right ovary, whose ulcerated surface shews the tissue to have become tuberculated.
H. The rectum.
I, I. Ulcerated tuberculated mass, at the uterine face of the rectum

FIG. 2.

The same uterus seen on its anterior face.

A. The bottom of the uterus.
B. The rectum.
C. The bladder lowered to let the anterior face of the body of the uterus be seen.
D. Left tube.
E. Portion of the left ovary.
F. Left sub-pubian cord.
G. Right sub-pubian cord; at its root; ulceration and osseous concretion.
H. Right ovary, adherent to the lateral edge of the bottom of the uterus
I, I. Tuberculous and ulcerated portion of the right ovary.
K, K. Right tube.
L. Tubercles of the anterior and right lateral division of the uterus.

FIG. 3.

The same uterus, cut vertically in its thickness.

A, A. The cavity of the uterus is completely obliterated by a white solid substance, of the consistency of tallow.
B. Posterior partition of the vagina.
C. Tuberculous concretion upon the internal face ot the vagina.
D, D. Slashed edges of the orifice, remains of the end of the neck of the womb.
E, E, E. Uterine vessels, for the most part, ossified.
F, F. Cut of the right ovary.

fig. 2.

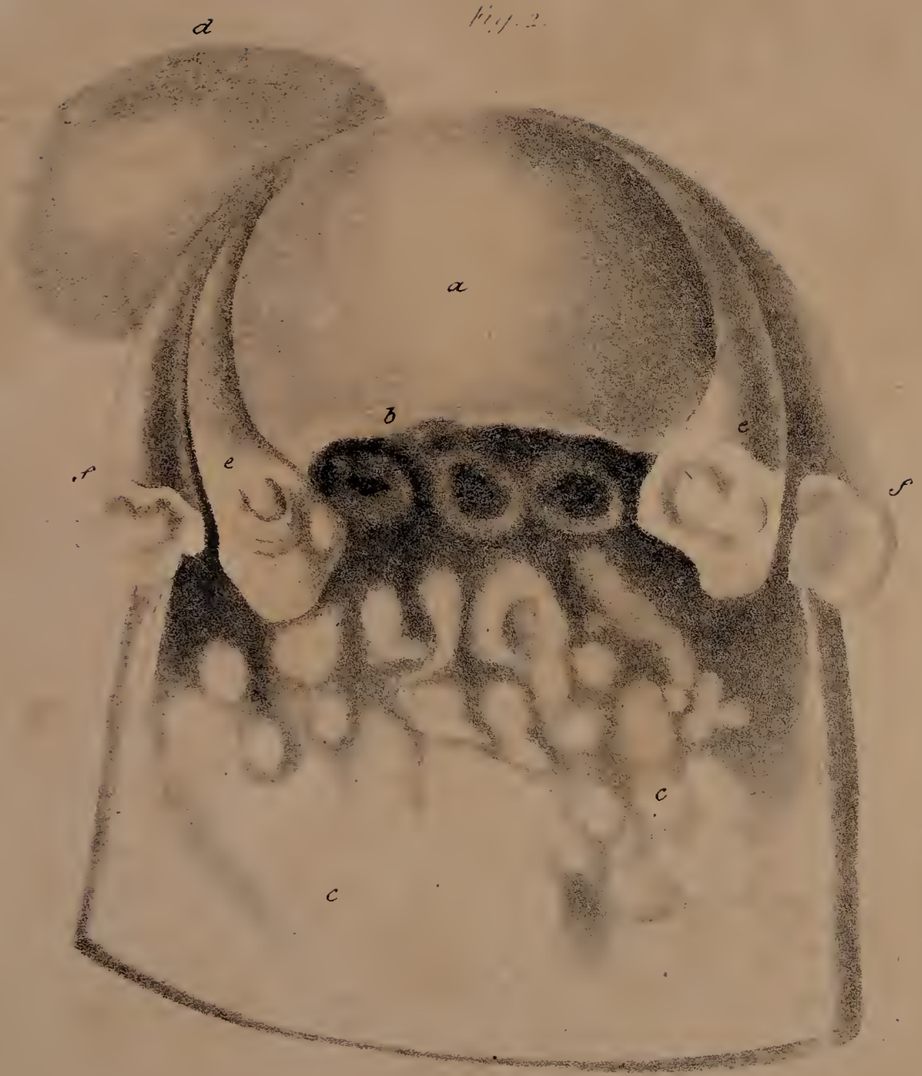

fig. 1

CANCEROUS DEGENERESCENCE.

EXPLANATION OF THE PLATE.

FIG. 1. Cancerous degenerescence of the uterus with destruction of the neck of the organ.

A. Vertical cut of the uterus, upon its median line, into two lateral portions.

B. The thickening of each partition, and the red colour of its lardy tissue, is remarkable on the slice of each portion. There only remained a slight furrow of the cavity occupied by a small pediculated fibrous body C.

D,D. The bladder opened on its pubian division, to shew the cancerous ulcer of this organ corresponding to the posterior division of the neck of the uterus, entirely destroyed by an ulcer of the same nature, and whose edge, of a blackish grey, was in every respect similar to that of fig. 2. The end of the neck of the womb was not injured.

F,F. Round pad of a larded tissue, three lines in thickness, cut into pretty regular festoons, presenting upon its outer edge a dirty grey substance.

FIG. 2. Uterus seen on its posterior face.

Total destruction of the neck of the uterus, of a portion of the tubes and ovaries which were stuck to each side of the organ. The tubes were obliterated and destroyed by cancerous degenerescency, as well as the cords of the ovaries, and the ovaries themselves.

A. The body of the uterus without the least trace of the cavity or of the orifice.

B. Ulcerated portion presenting an unequal surface, of a slaty grey.

C,C. Concretions of a mixed dirty grey and yellow on the mucous surface of the vagina.

D. A very fat tumor, of a dark yellow.

E,E. Ligaments of the ulcerated ovaries.

F,F. Equally ulcerated tubes.

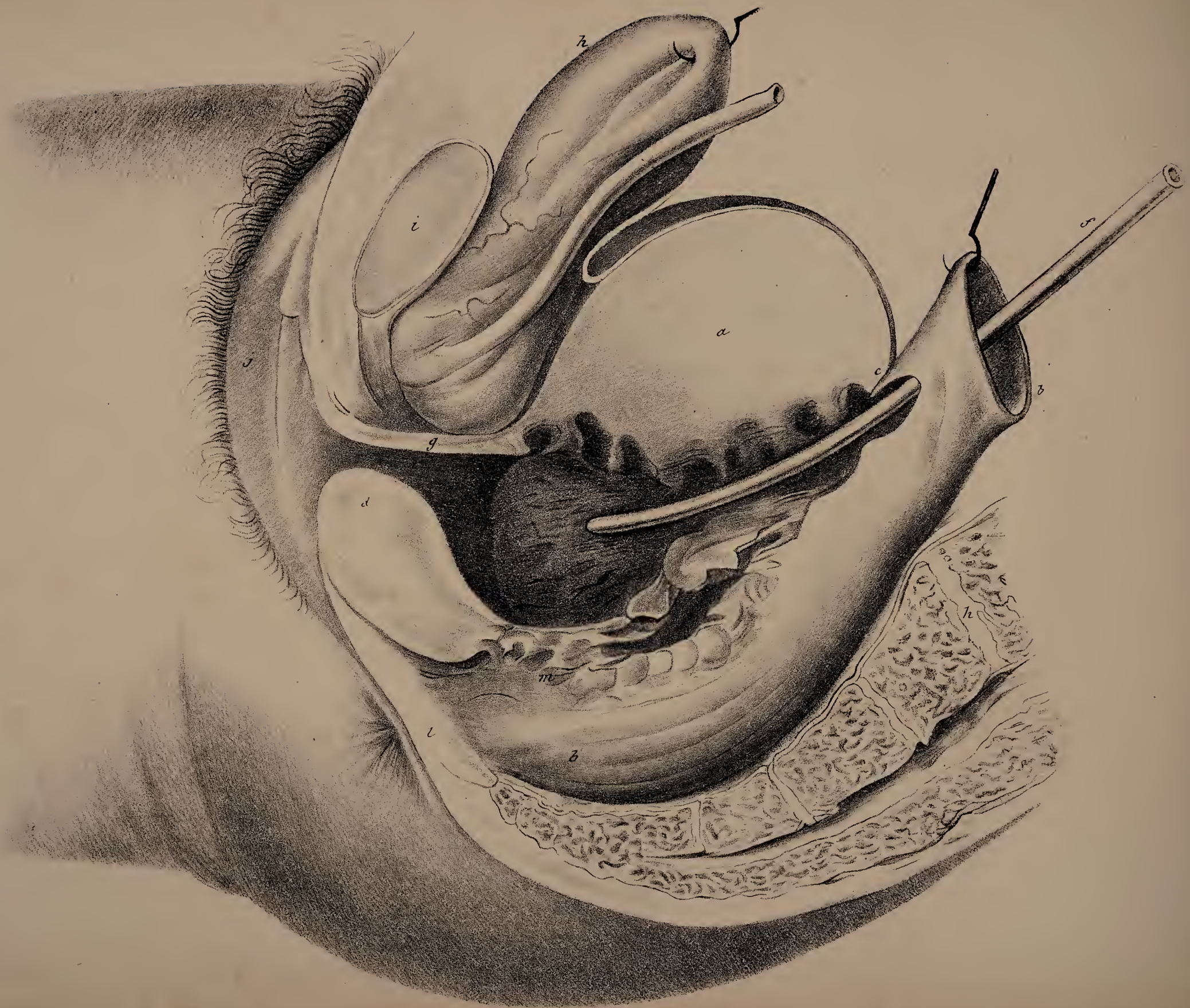
h
i
a
s
c
b
g
d
h
m
l
b

CUT OF THE BASIN SEEN IN PROFIL.

CANCER OF THE UTERUS, OF THE RECTUM, OF THE POSTERIOR DIVISION OF THE VAGINA, WITH THE TOTAL

DESTRUCTION OF THE END OF THE NECK OF THE WOMB, WITHOUT PREVIONS HEMORRHAGIA.

EXPLANATION OF THE PLATE.

The woman who furnished this pathologic piece, had been subject for a long time to an obstinate constipation. She experienced no other results than borborygm, intestinal colics and violent pain in going to stool; a function wich was performed only every 8, 12, or 15 days.

It was after some violent efforts to go to stool, that the patient perceived that the excrements issued from the vagina. It was difficult to ascertain the state of these parts, the posterior edge of the orifice of the vagina, very thick and hard, was nearly raised to the level of the lower edge of the pubis; we could scacerly introduce the finger in it.

Death soon relieved the patient from this disgusting infirmity.

A. The uterus without the least trace of cavity, its tissue ressembled white soap both in colour and consistency.
B. The rectum. Perforation from diminution of the rectum.
C,C. Perforation of the tissue of the uterus, from the bottom of the organ to its orific, occasioned by the stercoraceous matter wich had made its way through.
M. Thickened portion of the rectum; its intimate adherency to the posterior division of the vagina. This last canal was equally affected by the same degenerescency.
D. Interior and tumefied edge of the vagina which favored the retention of the stercoraceous matter in this vulvo-uterine sheath.
E,E. Stercoraceous matter coming from the rupture indicated by the style F.
G. Anterior division of the vagina.
H. The bladder. — The right pubis.
J. The large right lip.
K. The sacrum.
L. The sphincter of the anus.


Fig. 1
a
d
c
h
h
g
g

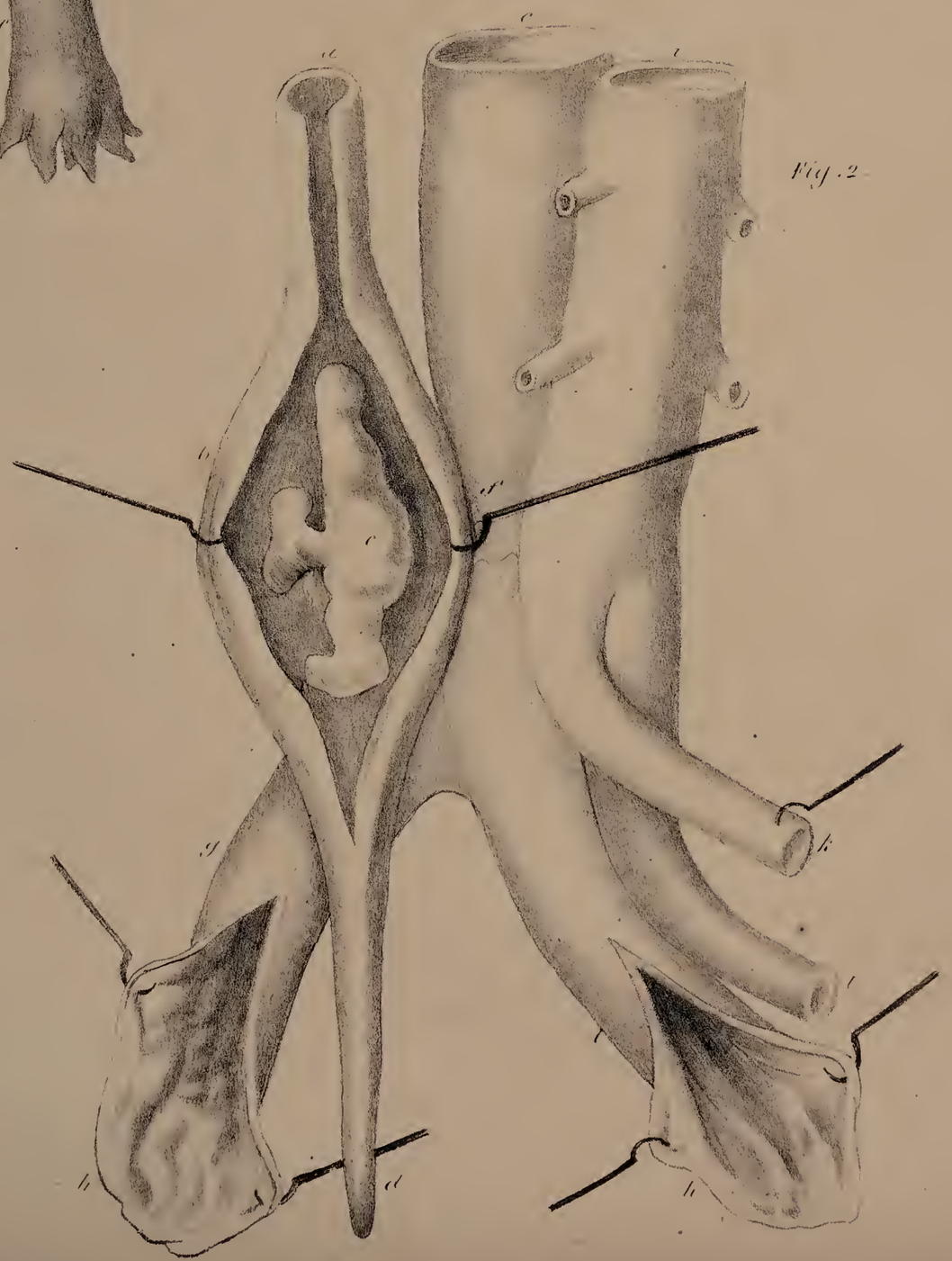
Fig. 2
a
c
b
b
c
g
h
h
l
l


Fig. 3
a
b
b
c

UTERUS AFFECTED WITH SOFTNESS.

EXPLANATION OF THE PLATE.

FIG. 1. Uterus affected with softness joined to phlebites of this organ, in a woman of 23 years of age, three weeks after her delivery.

This pathologic, piece which was communicated to us by M. Collineau, principal phisician to the prison St Lazare) is represented opened anteriorly upon its median line.

A,A. Longitudinal cut.
B,B. Cavity of the body of the organ.
C,C. Cut of the proper tissue of the uterus, of a dark red, spungy like that of the spleen.
D. Shred of the placenta, remaining attached to the uterus.
E,E,E. Veinous vessels with white enclosures, thick, and considerably dilated, which were taken at first, upon inspection only, for tuberculous abscesses: these canals were filled with a thick yellow pus.
F,F Tubes.
G,G. Ovaries.
H,H. Origin of the sub-pubian cords.

FIG. 2. Urethra occupied by a branchy calculus.

The figure represents the urethra occupied by a stone, which, by its ramifications, has caused a contraction of the inferior vena cava, a great dilatation of the veins of the basin, a congestion of the vessels of the uterus, and in the end, an ulceration of this organ. Original drawing of M. J. CLOQUET, with the following explanation:

« I found in a woman of fifty, the urethra filled by a branching calculus, this urethra is obliterated, changed in the under part into a large schirrous cord. The tumor wich it forms, compresses the lower vena-cava so much, that this vein becomes a sort of funnel, and barely admits the passing of a woman's probe. Above, it is empty, under, it is entirely filled with the solid filaments which occupy the whole of the capacity of the large veins of the basin, and of the upper part of the thighs. Below the members, which are infiltrated, the veins contain fluid blood; the large veins of the basin and of the thigh are filled withd this *fibrine*, and lined with a false membrane which adheres to this *fibrine*, like in aneurysms. The aorta artery is perfectly free; there is an abcess in the right lumbar region. Considerable infiltration in the back and in the basin. All the organs contained in the pelvian cavity, the matrix, the tubes, the lymphatic ganglions are swelled and schirrous. The pus of the abscess has a faint smell: I do not thinck that it comes from a caries. »

A. Right urethra.
B. Dilated point.
C. Branching calculus.
D. Extremity of the obliterated and schirrous urethra.
E. Lower vena cava.
F. Its strangled part.
G. Internal iliac veins.
H,H. Internal face of the internal iliac veins.
J. Lower aorta.
K. Internal iliac artery pulled aside to exhibit the disposition of the urethra and the compression it has produced on the trunk of the vena cava.
L. Internal iliac artery of the left side.

FIG. 3. Varicoceles of the sub-pubian cords.

This varicose state of the two round ligaments of which one specimen alone is here given, was met with, in a woman of sixty years of age; knotty, twisted veins, filled the inguinal canal completely; the aspect which these two varicose ligaments assumed, caused a belief in the existence of two bags of inguinal hernia, (Copied from the original of M. J. CLOQUET).

A. Inguinal canal.
B. Varices of the veins of the sub-pubian cords.
C. Fibrous tissue of the cord.

Fig. 1

Barrier Dugès l'aîné



Fig. 2

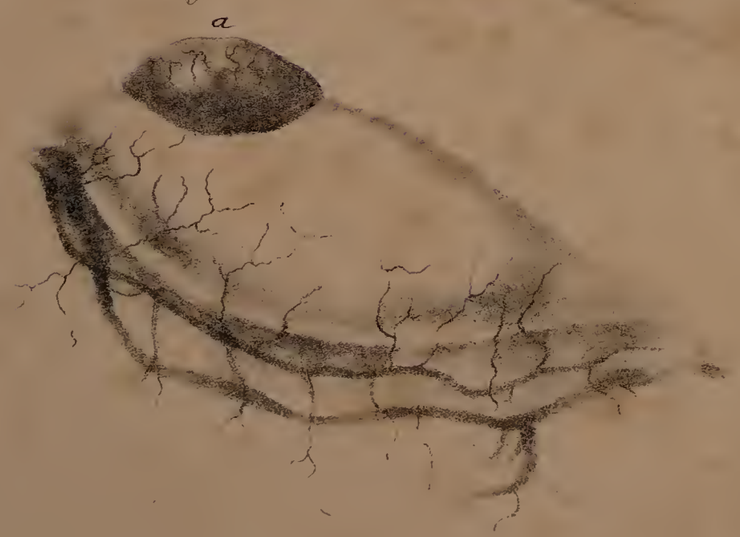

Fig. 3

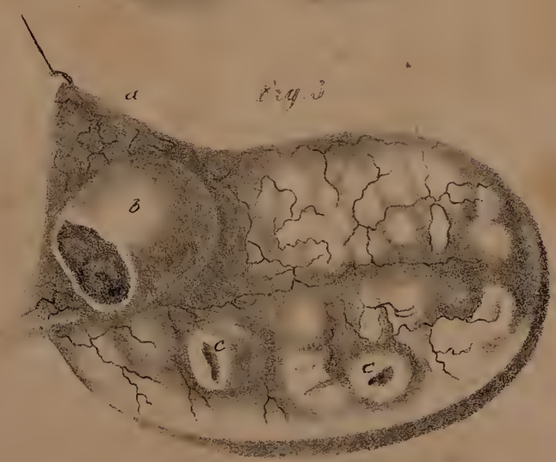

Fig. 4

MELANOSES OF THE UTERINE TUBES.

EXPLANATION OF THE PLATE.

FIG. 1. Melanoses of the uterine tubes with obliteration of their orifices. Bloody congestion of the uterus. Miliary vesicles upon the end of the neck of the womb.

The woman to whom this uterus belonged was brought in, dying, to the *Maison de santé*, in sept.r 1831. Hemiplegic since some days, and in a high degree of suffocation.

At the first view, all the visceras were found emphysématous.

A, A. The uterus of double its natural size, of a dark red, and of a soft tissue. The internal face discharging, under pressure, a quantity of little drops of blood. This woman had long been subject to abundant metrorrhagia.

B, B. The miliary vesicles upon the end of the neck of the womb.

These vesicles contained a mucous humor flowing at the point of the scalpel.

C, C. The tubes, of the size of a small hen's egg, were obliterated at their free extremity 1. The fringes were, in part, shut up in the larger part of the tube 2. The interior of these two canals were injected with a dark blue matter. They were furrowed in their length by greyish crests 3.

D. The right ovary also contained blackish vesicles, with a mucous tissue of the same colour; it contained besides a black ovoidal body, of a compact tissue, and of the size of a small nut.

E. Left ovary hypertrophied, of double its natural size, otherwise healthy.

F. On the external face of the body of the uterus, a long membraneous vesicle was filled with a serous yellowish humor.

This disposition appears to us that which preceeds the hydropisia of the tubes and that of the ovary, a disposition which may also be called by the name of *melanoses*.

The figures 2, 3 and 4 represent the ovaries of a woman who died of confluent small pox, in the seventh month of her pregnancy.

FIG. 2. Right ovary with a red brown tumor.

A. Tumor of a red brown, vascular.

FIG. 3. The same seen on its interior.

A. Vascular membrane of the tumor.

B. Cyst contraining a solid black substance.

C, C. Other small cysts, containing the same substance.

FIG. 4. Left ovary of the same subject.

A. Recent cicatrice.

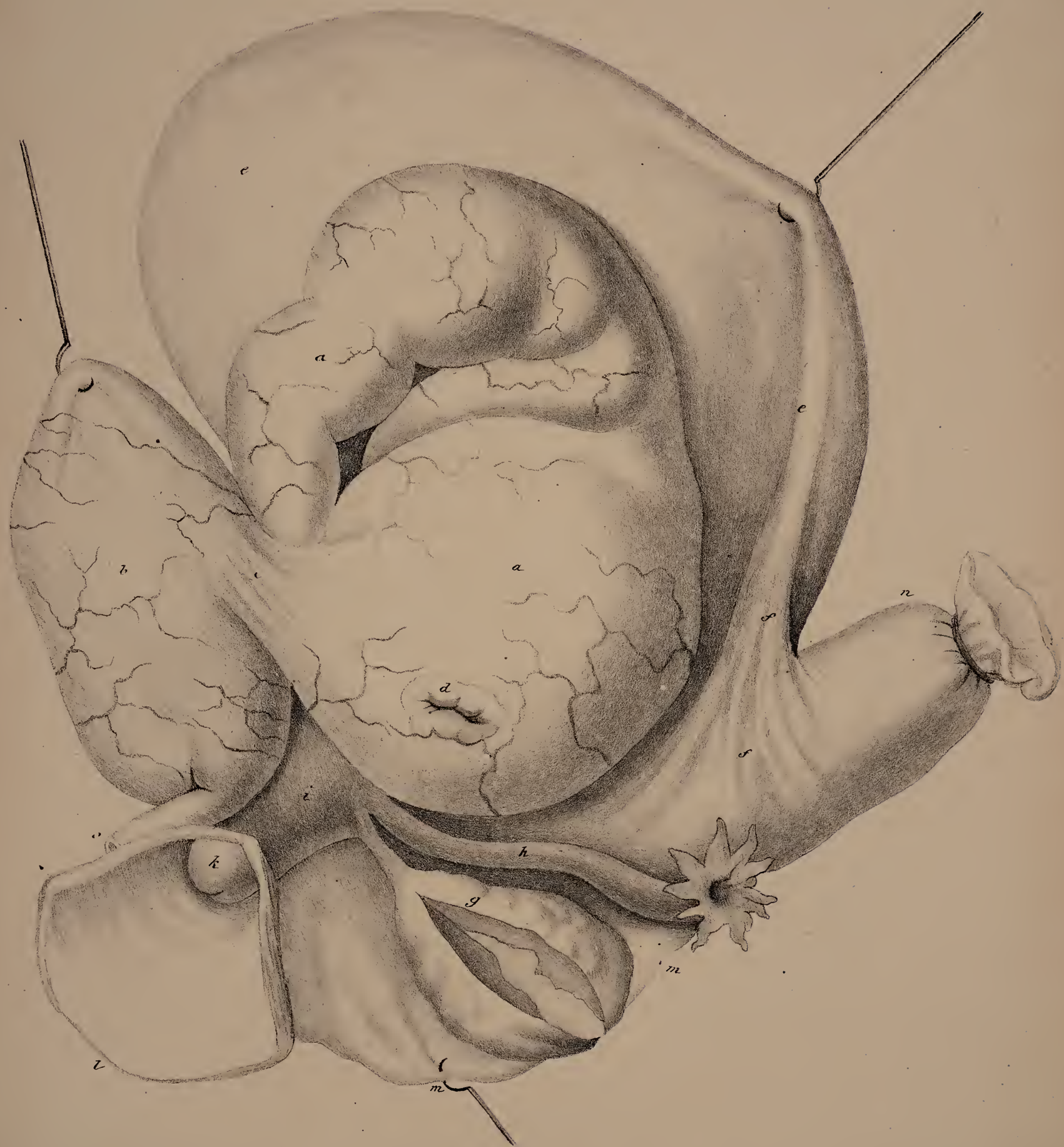
e
a
e
b
c
a
n
f
d
f
i
h
k
g
m
l
m

HYDROPISIA OF THE LEFT OVARY AND TUBE.

EXPLANATION OF THE PLATE.

This figure represents a hydropisia of the left tube and ovary in a young girl who was suspected, wrongfully of having been recently delivered.

A. The left tube is adherent at C to the posterior division of the bladder.

B. Numerous vessels of a lively red were remarked there.

D. Enlargement of the tube and external orifice of the tube obliterated, the fringed edges have entirely disappeared.

E, E. Left ovary developped under the form of a thick voluminous cyst, adherent to the rectum, by the meaus of false membranes F, F.

G. Right ovary, plaited, hard and rough at its surface; it is opened in its length in order to exhibit its cavity which contained a little puriform matter.

H. Right tube in a normal state.

I. Body of the uterus.

K. End of the neck.

L. The vagina opened lengthwise.

M. Large right ligament.

N. The rectum.

O. Canal of the urethra.

The observation of this case, is in my *memoire sur les causes de l'avortement, observation* XX, page 96.

Fig. 1

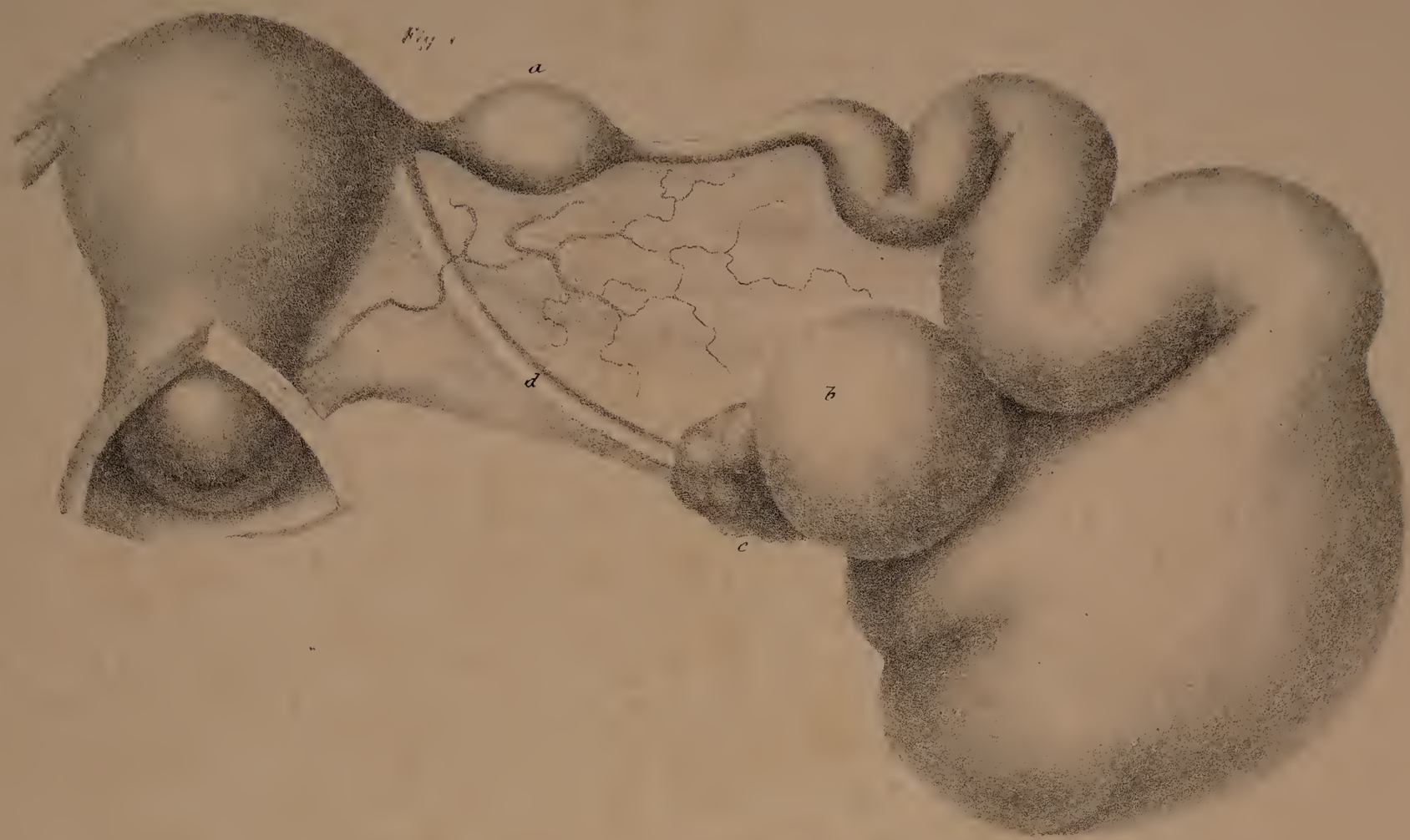

Fig. 2

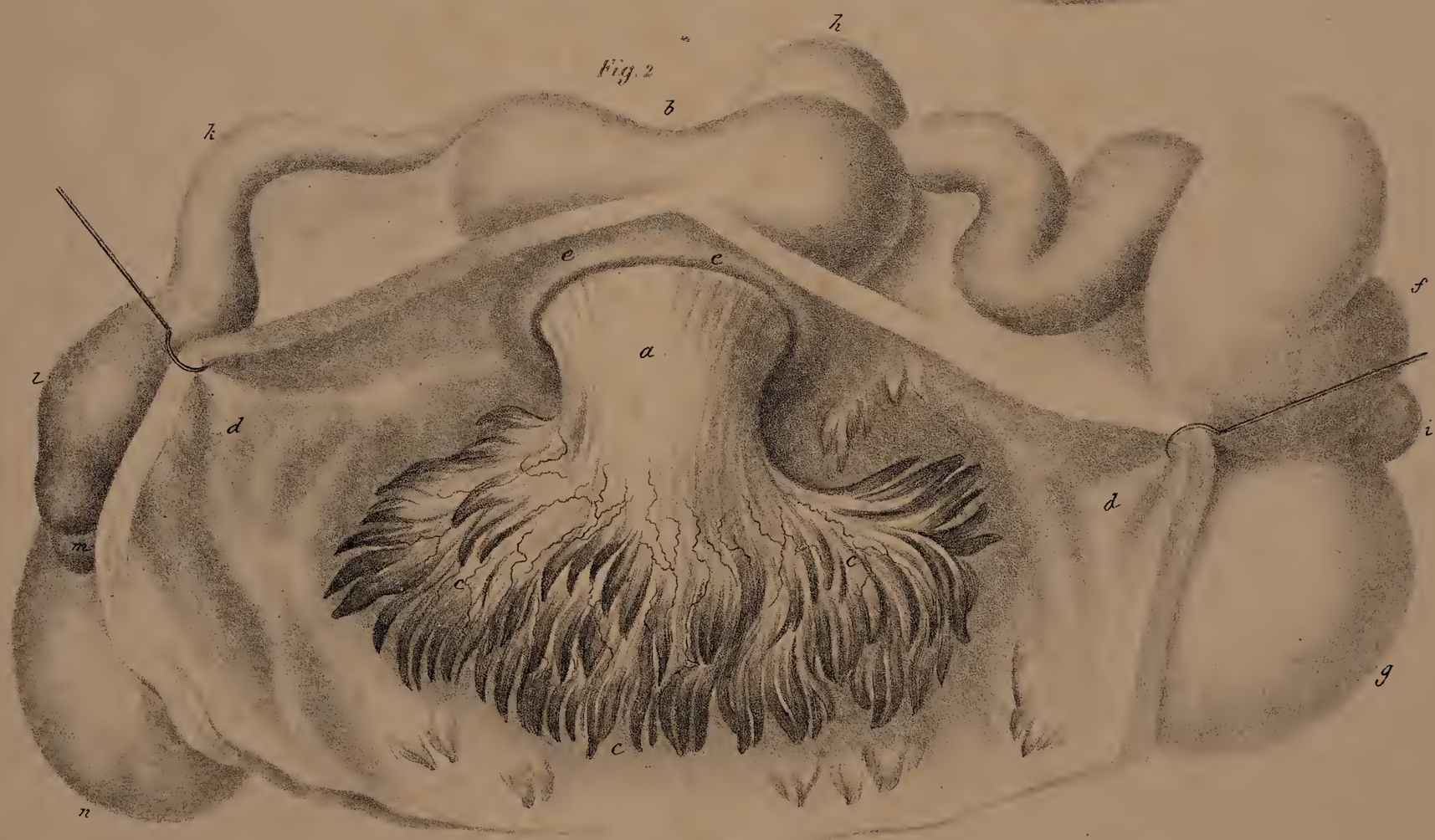

Fig. 3

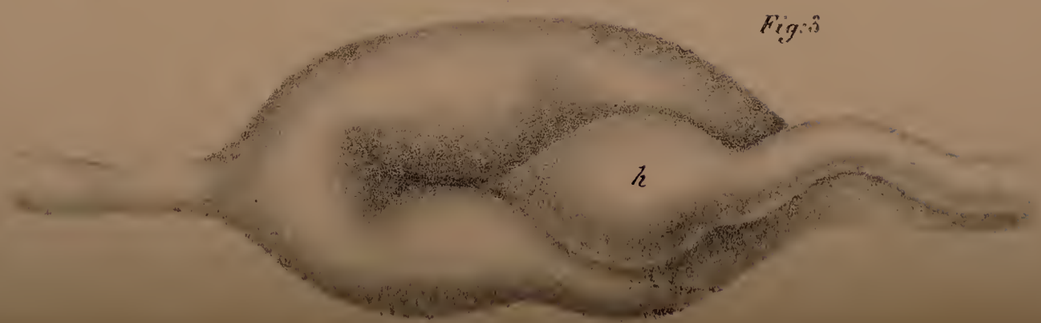

TWO CASES OF ENCYSTED HYDROPISIA

OF THE TUBE.

EXPLANATION OF THE PLATE.

Fig. 1. Hydropisia of the right tube. — The uterus seen on its posterior division.

This piece was found on a woman of fifty years old, by M. J. Cloquet.

A. Dilated tube which forming flexures, contracting itself more and more, to terminate, (near its insertion into the uterus) in forming a cavity with thick whitish enclosures, with cells *not communicating withs the uterus.* The surface of the tube was strewed with many vessels.

B. Serous cyst of the ovary, adherent to the developped portion of the tube.

C. The ovary.

D. Ligament of the ovary. The hydropisia of the tube is formed by a yellowish transparent fluid.

Fig. 2. Cancerous polypus. — Hydropisia of the two tubes and ovaries. — Uterus depressed on its bottom, seen on its anterior face.

The woman from whom this pathologic piece was extracted, was sixty years of age.

A. A cancerous polypus, supported by a large white pedicule, of a firm tissue, as if fibrous, implanted at the bottom of the matrix, and continuing with th[illegible], of which it causes the over-turn into the [illegible] of a funnel.

B. This polypus joins itself, in an insensible manner, with the tissue of the matrix. In the lower part, it spreads itself out into, soft, pultaceous, reddish brown fringes, strewed with numerous vessels and falling into pudritity.

C,C. The size of this polypus determines a great enlargement of the vagina. D, which presents some fringes as if schirrous.

E,E. The neck of the uterus is very dilated (of the largeness of a half crown), fibrous, resisting, letting the bottom of the uterus pass out at the point where it continues with the pedicles of the vagina. The mucous membrane of the vagina is swelled, soft, pulpy, and offers slight, superficial ulcerations, and besides some vegetations in the form of the comb of a cock.

The left tube presents a hydropisia. It forms a winding cyst, of small size, at the place where it answers to the preceding tubercle, and where it terminates in a *cul-de-sac*, swelled, twisted and folded down on itself at the farther extremity, F, it bends down and backward, and fastens its elf to the surface of an oblong cyst, formed by the ovary G.

This tube is filled with a yellow, mucous fluid, ressembling a jelly, and with a faint smell. There, the internal extremity of the tube is terminated by a kind of *cul-de-sac* H, and the external by a considerable swelling, in which, may be still recognised the fringes of the tube which project in the inside, I.

This dilatation communicates, by a rather large, round opening, with the cyst of the ovary, G.

G. The cyst of the left ovary is oblong, with white thick enclosures, which do not communicate. The ovary is fastened and extended upon it. This cyst is wrinkled and flattened. Under, another cyst exists filled with a tuberculous matter.

K. The right tube offers a similar dilatation, but less considerable, it also terminates in a *cul-de-sac* L, at 2

inches and a half from the uterus; its other extremity, contracted, communicates with a small cavity M, formed by the (*pavillon*) large part of the tube. This cavity offers a little sinuous opening, a real small canal of a blackish colour, and wich goes into the large cyst of the corresponding ovary, N. The fluid passes easily by this little canal of the cavity of the tube L, into that of the cyst N. This is almost empty. The liquid it contains is but little, serous, fluid and not at all glutinous. (This description belongs, as well as these two figures, to M. le professeur J. Cloquet).

Fig. 3.

The same matrix, seen above, offers a triangular cavity, formed by three large folds, and in which the finger may be introduced. It passes across the neck of the uterus.

H. A great tubercle, as if schirrous, comparable, for its phisical properties, to the verrucuous tumors of the skin, is nearly engaged in this cavity of the uterus. This schirrous tumor H, answers to the insertion of the tube, and completely obstructs it.

Boivin – Duges. Pl. 26.

TUBARY PREGNANCY OBSERVED

(A LA MATERNITÉ) IN A YOUNG WOMAN, IN 1816.

EXPLANATION OF THE PLATE.

The fœtus was developped in the left tube. After the spontaneous rupture of the canal, which had been, for it, an organ of incubation, the woman, soon fell a victim to the accident. The fœtus was found situated upon the iliac fossa, FF.

The matrix soft, red, and pretty large, was lined with a reddish, pulpy membrane.

A. Large lobe of the liver.
B. Biliary vesicle.
C. The stomach.
D. The epiploom adherent to the left tube.
E. Intestines.
F,F. Cyst formed by the left tube.
G. Body of the uterus.
H. Fœtus.
I. Umbilical cord.

This figure is copied from the original drowing of M. J. Cloquet.

Nota. It is an error of the engraver's that the letters C,C,C. which indicates the intestines, are also placed for the epiploom, whose adherent portion is marked D. observe also of a DD, the large raised up portion of the epiploom, wrongly indicated by *e,e.*

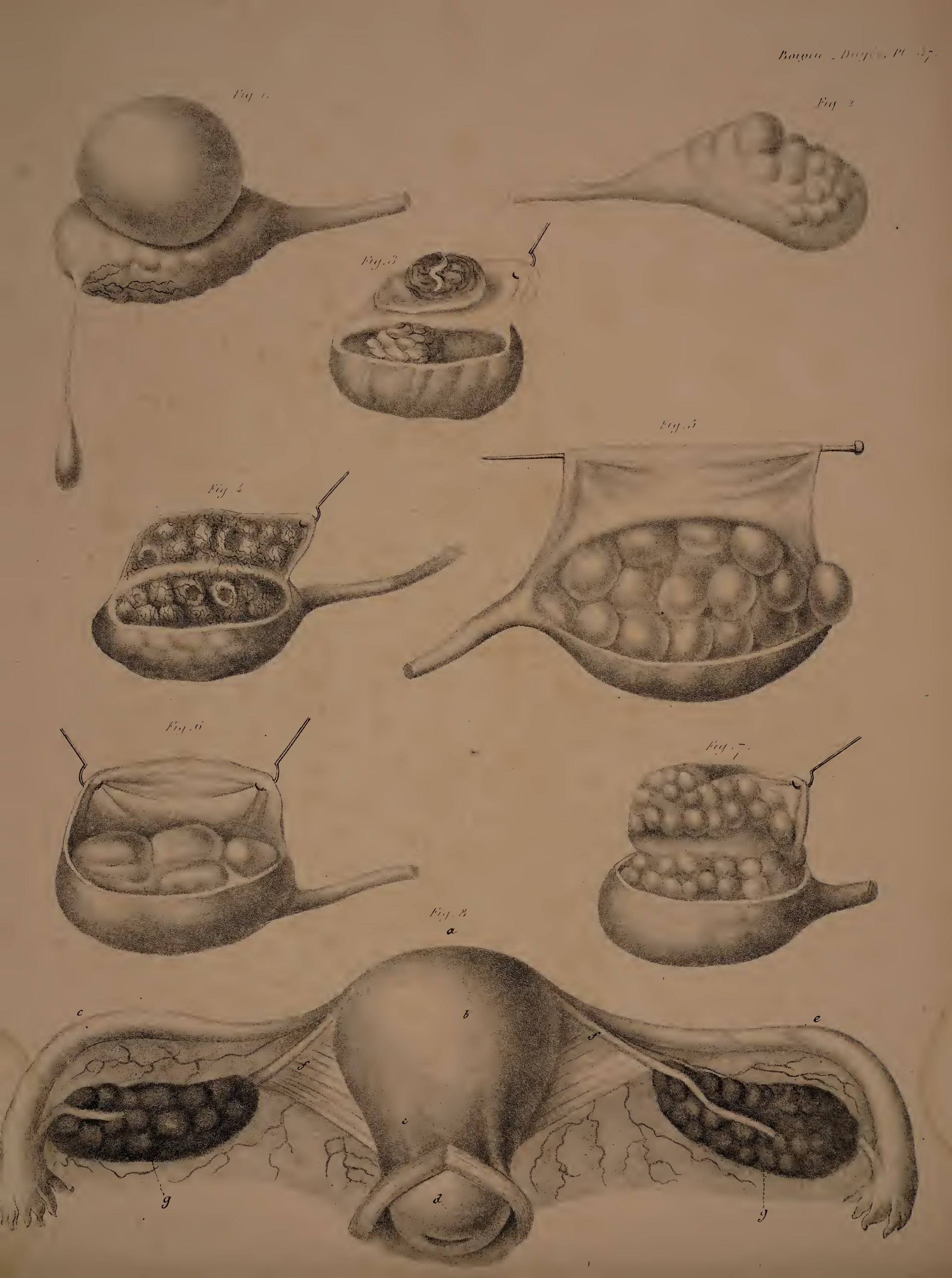
Fig. 1.
Fig. 2
Fig. 3
Fig. 4
Fig. 5
Fig. 6
Fig. 7.
Fig. 8
a
b
c
d
e
f
g

REPRESENTING DIFFERENT AFFECTIONS

OF THE OVARY IN AN EARLY STATE.

EXPLANATION OF THE PLATE.

Fig. 1. Representing different affections of the ovary in an early state.

Ovary taken from a young girl, a maid, aged 18. who died of a pulmonary phthisis. She had only had her menstrual discharge a few times.

The right ovary very large, is surmounted on its upper face, by a transparent cyst of the size of a large plumb, and containing a yellowish fluid some what mucous. Cut in slices, the interior of the ovary presented several uncoloured vesicles. Another cyst, of the size of a pea, also transparent, was suspended by a long thread to the edge of the ovary.

Fig. 2.

Ovary of a woman recently married, who died of a typhus fever.

Fig. 3.

The same ovary, cut in its thickness, shews the slice of the little tumor of the first. This organised body is the yellow body or *corpus luteum*.

Fig. 4.

Ovarites. Each vesicle was injected with vessels of a lively red, and of an extreme fineness.

Fig. 5.

Ovary of the size of a large egg, taken from a woman of eighteen years of age, recently brought to bed at her full time. She had renewed her occupation of washer-woman, eight days after her delivery, in very severe weather. She died at the end of the 15th day of a metrorrhagia, and of a most violent epistaxis. The very large vesicles are of the colour of mother of pearl, and surrounded by a mucous fluid, like that which they contain.

Fig. 6.

A young girl, also a washer-woman, who died of a meningites, and whoh ad never had her menses regular, from the time they first commenced. The uterus was atrophied; the two very large white ovaries, of a soft tissue, containing transparent vesicles. In the left, the hydatidiform bodies, were of the size of a nut, and contained a transparent fluid, and sticky when fingered.

Fig. 7.

Ovary of the same subject, rather less than the other; the vesicles less large, and in a greater number, containing a fluid of the same nature.

Fig. 8.

This pathologic piece was taken from a girl, aged 18, who had died of an acute gastro-enterites. This girl being upon the point of marriage, had found some impediments to it.

A. Uterus of a dark red.
B. The body of the uterus more developped, was of a firm tissue.
D. End of the neck of the womb.
E,E. the tubes of a lively red, and much developped.
F,F. Wings of the ovaries.
G,G. Ovaries of double their usual-size, lumpy on their surface, ressembling in the disposition of their granulations and colour, two bunches of black currants: the surface of each slice was black and represented grey circles, formed by the vesicles which were found cut in different ways.

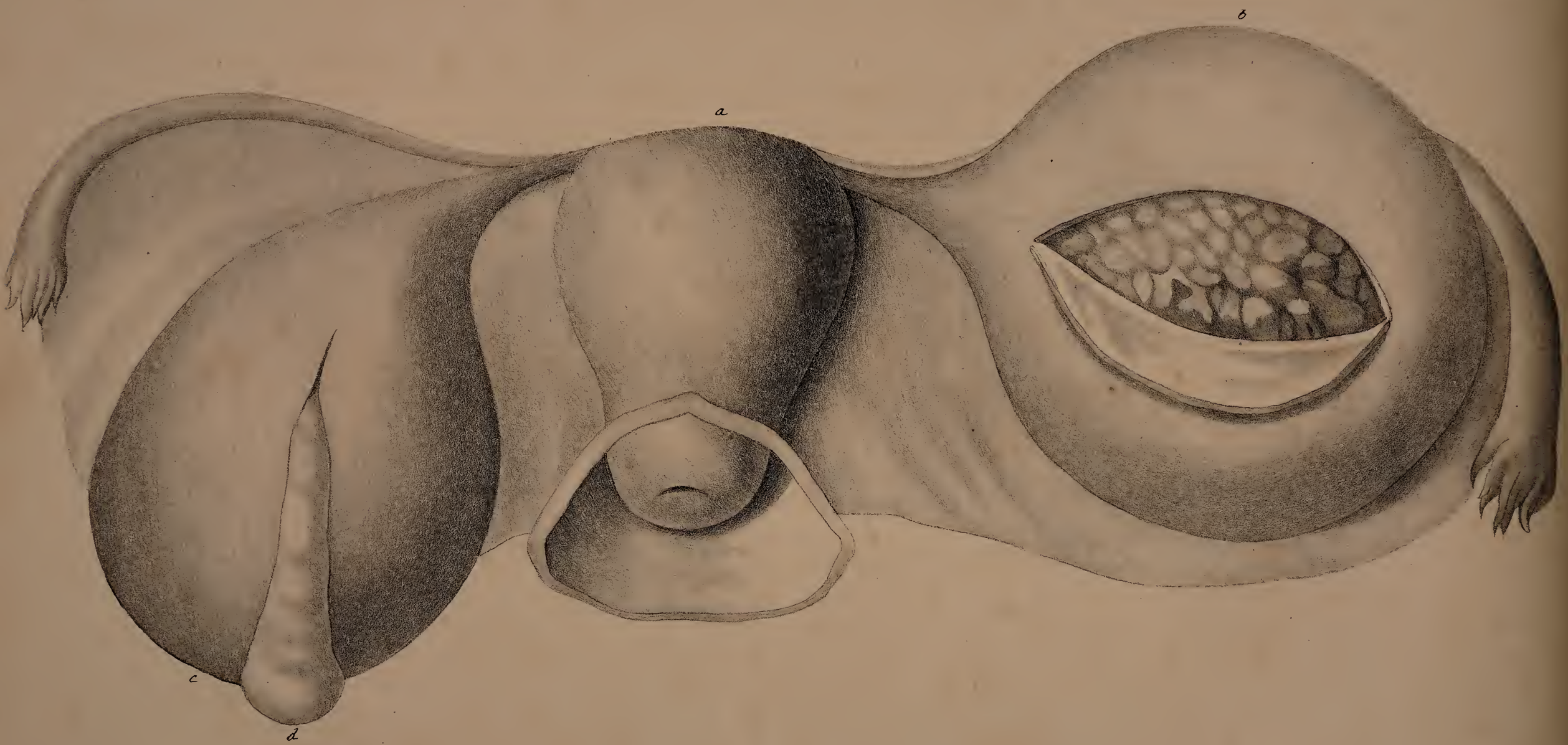
a
b
c
d

UTERUS COMING FROM A WOMAN

AGED 24, WHO WAS THOUGHT TO BE 4 MONTHS AND A HALF GONE WITH CHILD,

AND WHO DIED OF AN ENTERO-PERITONITES. SHE HAD NEVER HAD A CHILD.

EXPLANATION OF THE PLATE.

The uterus, seen on its posterior division, was double its natural size. Its tissue, of a dark red, was soft, its orifice in the normal state.

A. Right ovary, spherical, of the size of the fist, filled with a solid, tenacious, greenish matter, and with a penetrating smell. The cyst, of a violet-brown on the outside, was about a line in thickness; its internal face was lined with a fine and consistent membrane.

B. The left ovary, of a conical form, of the size of a Swan's egg, of a soft tissue, was filled with a thick, purulent, yellowish white, and well mixed matter. This organ, was covered with putridity and adhered to the sigmoïdal flexure of the colon.

D. Matter contained in the cyst.

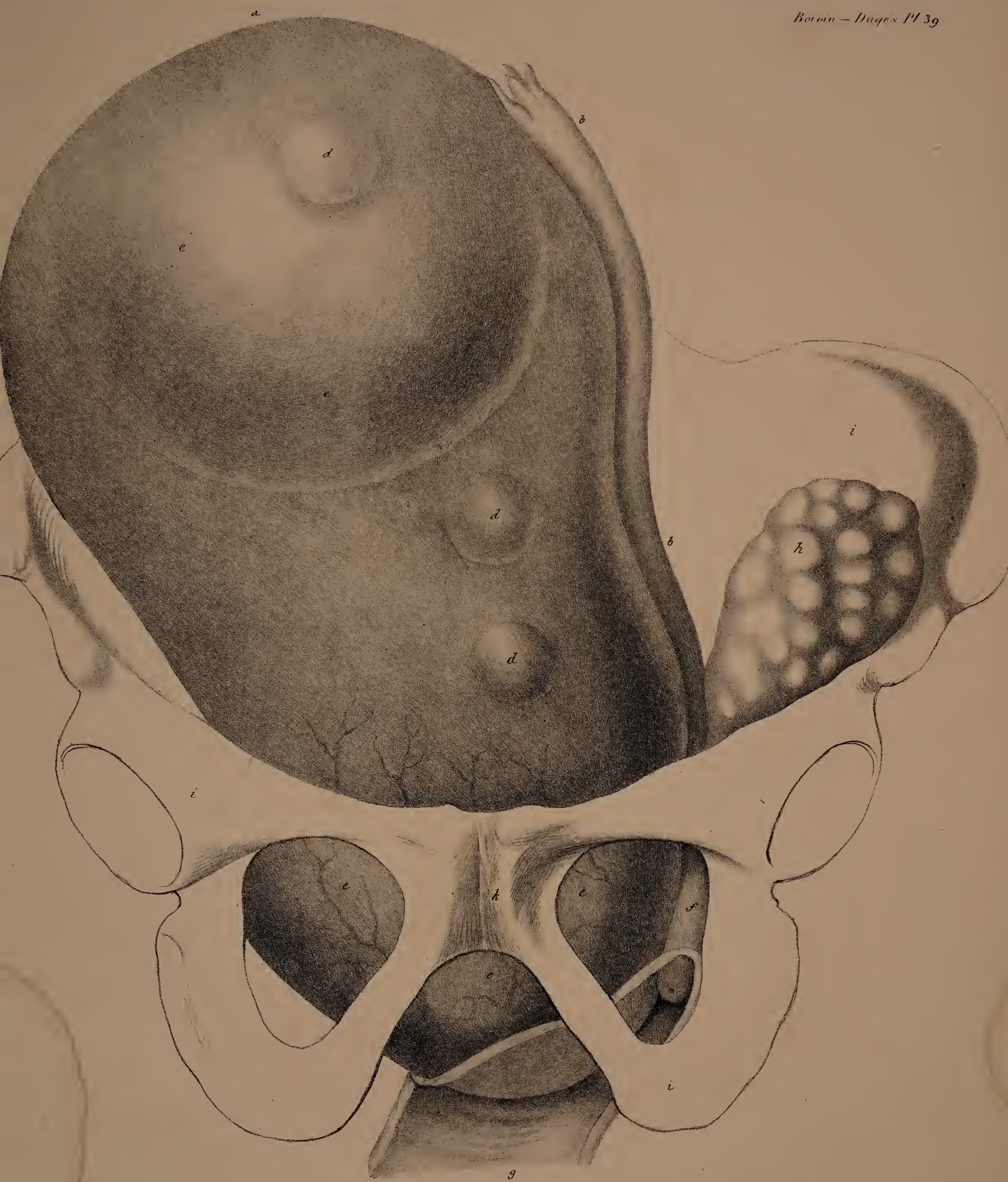
a
b
d
e
e
d
d
b
h
i
i
e
k
e
f
e
i
g

DEGENERESCENCY OF THE TWO OVARIES

IN A WOMAN OF 22 YEARS OF AGE.

EXPLANATION OF THE PLATE.

The right ovary, of the weight of seven pounds, took this extraordinary growth, in nine months : what gave rise to the belief of a fœtal pregnancy, were the pains which came on at the 9th month, exactly similar to those of labour. The lower extremity of the tumor being engaged in the basin, several accoucheurs were successively called; some took this tumor for the head, others for the breech of the child; the late Désormeaux who was consulted, recognised the existence of an extra-uterine tumor , of which it was then difficult to ascertain the nature. The patient was brought to the *maison de santé*, and we were able, but with much difficulty to recognise the uterus in a state of vacuity. After having remained 20 days in the establishment, the patient died of a consecutive peritonites (1).

Autopsia. The lower intestines were thrown out on the left; the upper limit of the tumor , A , was in contact with the large lobe of the liver, which was covered by it to a great extent. This mass was only adherent, by a membrane-vasculous tissue extremely loose, at the tube, on the same side, B,B.

The tube was very red, and of a size and length proportionned to the anormal developement of the ovary.

C,C. Mammiform swelling of the tumor, occasioned by a collection of limpid serosity.

E,E. Inferior region of the tumor, envelopped in the peritoneum, in a state of inflammation.

F. Atrophied uterus.

G. The vagina pushed backwards with the uterus, and covering a portion of the tumor.

H. Left ovary, transformed into a mass composed of hard bodies, close together, presenting at its surface inequalities which indicated the individuality of each portion of the tumor.

I, I, I. The basin.

K. Symphyses of the pubis.

(1) See : *Mémoire sur l'une des causes de l'avortement;* Observation XXVI of false pregnancies, page 123.

Fig. 1.

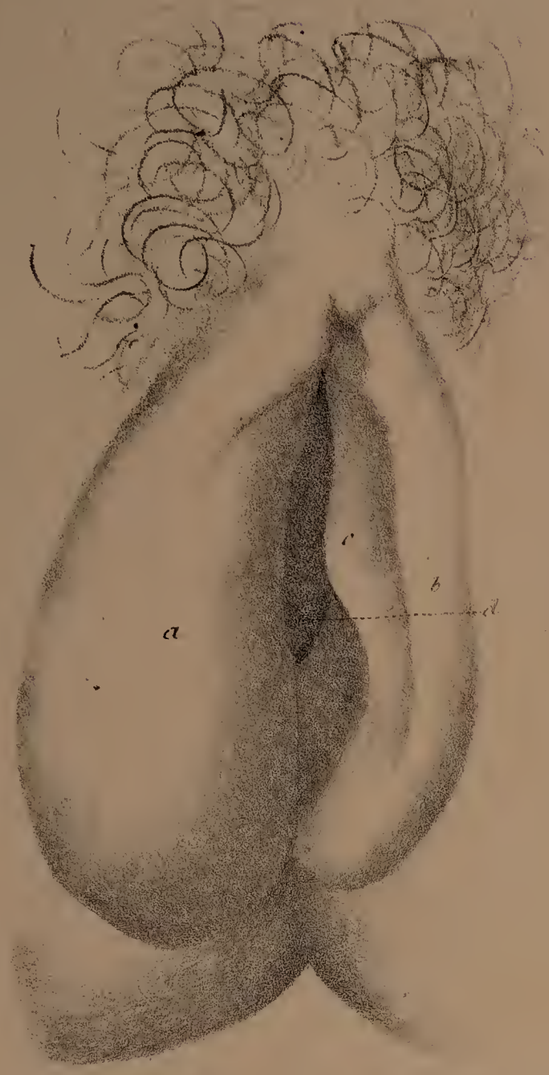

Fig. 2.

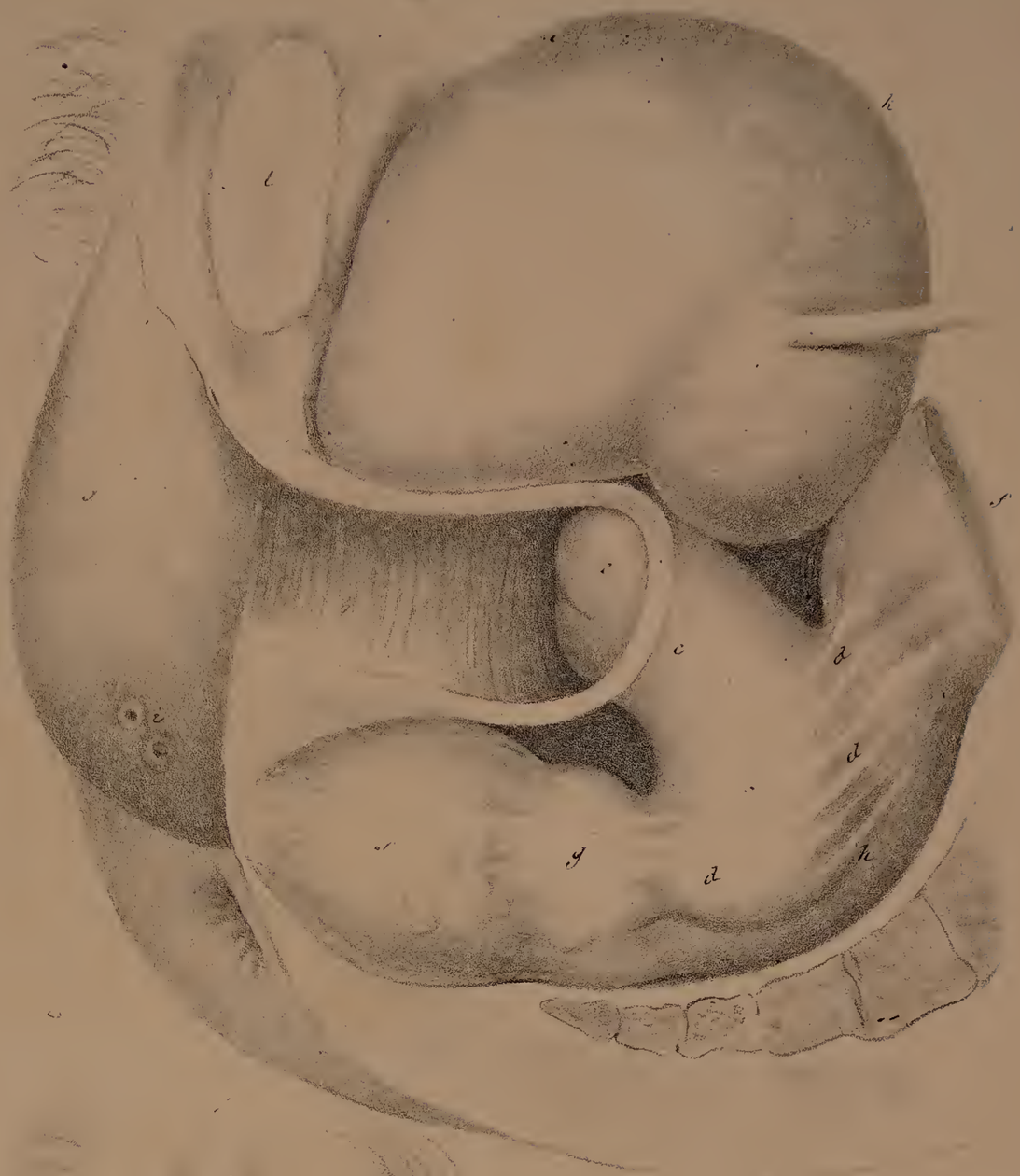

Fig. 3.



Fig. 4.

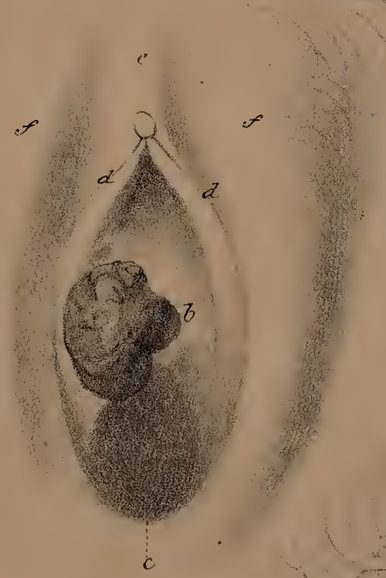

Fig. 5.

Fig. 6.

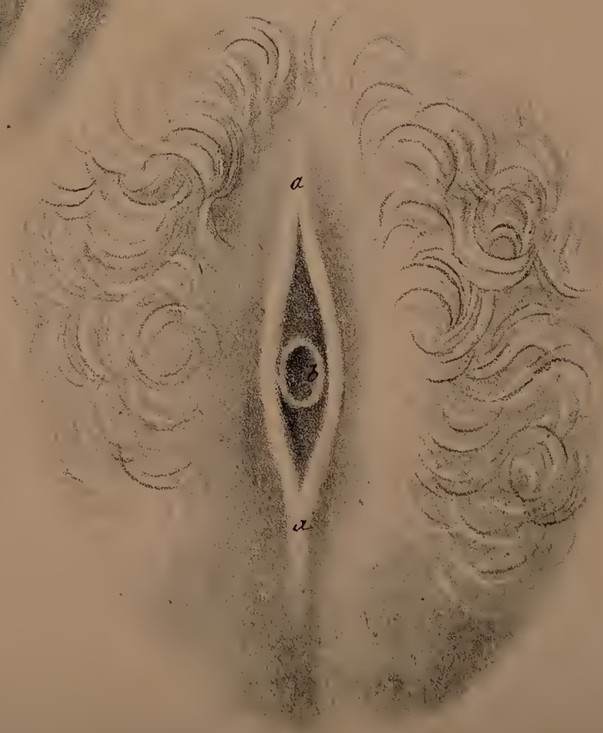

REPRESENTING DIFFERENT AFFECTIONS

OF THE UTERO VULVAR APPAREL.

EXPLANATION OF THE PLATE.

FIG. 1.

Encysted tumor of the large lip of the right side, accompanied by a cancerous affection of the matrix, and a total destruction of that organ.

A. Large lip tumefied.
B. Lip in a normal state; that of the opposite side is efface. Copied from an origidnal drawing of professor J. Cloquet.

FIG. 2.

Cut of the basin seen in profil, representing a part of the genital apparel, and of the organs affected by a stercoraceous fistula, which, from the rectum, communicated behind the vagina, untill the inferior edge of the right lip of the vulva.

A. Right lip of the vulva.
B. The vagina.
C. Neck of the uterus.
D,D,D. Body and bottom of the uterus.
E. Anterior lip of the end of the neck of the womb.
F,F. Rectum; very thick tuberculous ring cause of the first contraction of the rectum.
G. The contracted part of the rectum.
H. Fistula.
I. Bottom of the bladder.
K. Articular face of the right tube L.

FIG. 3.

Encephaloïdal tumor of the urinary passage, treated by antéphlogistics, compression by means of an uretral bougie and excision of the partly atrophied tumor.

A. Polylobed tumor.
B. Urinary passage.
C. The orifice of the vagina.
D,D. The small lips.
E. The clitoris.
F. The large lips.

FIG. 4.

Fungous tumor of the urinary passage, taken off by the curved flat cisors.

A. Red, soft tumor.
B. Orifice of the urinary passage.

We have met with several cases of this nature, cured by excision, and cauterisation.

FIG. 5.

Pancreatic cancer of the vulvar apparel, in a woman who died of a tuberculous affection of lungs, liver, and uterus.

A,A,A. Lobules of the small lips. Lobules of the clitoris.
C,C. Large lips, all this mass, supported by a common pedicle, could be raised up before the pubis; this is what the patient did, in order to make water.

FIG. 6.

Represents the vulva shut up by a long cicatrice, in a woman of 66 years of age. The great lips, had been during a long time, the seat of a tetter, accompanied by an insupportable itching; this woman, who lived with her husband during 30 years, never had any children.

A,A. Cicatrice which indicates the reunion of the large lips; the urinary passage alone, remained open.

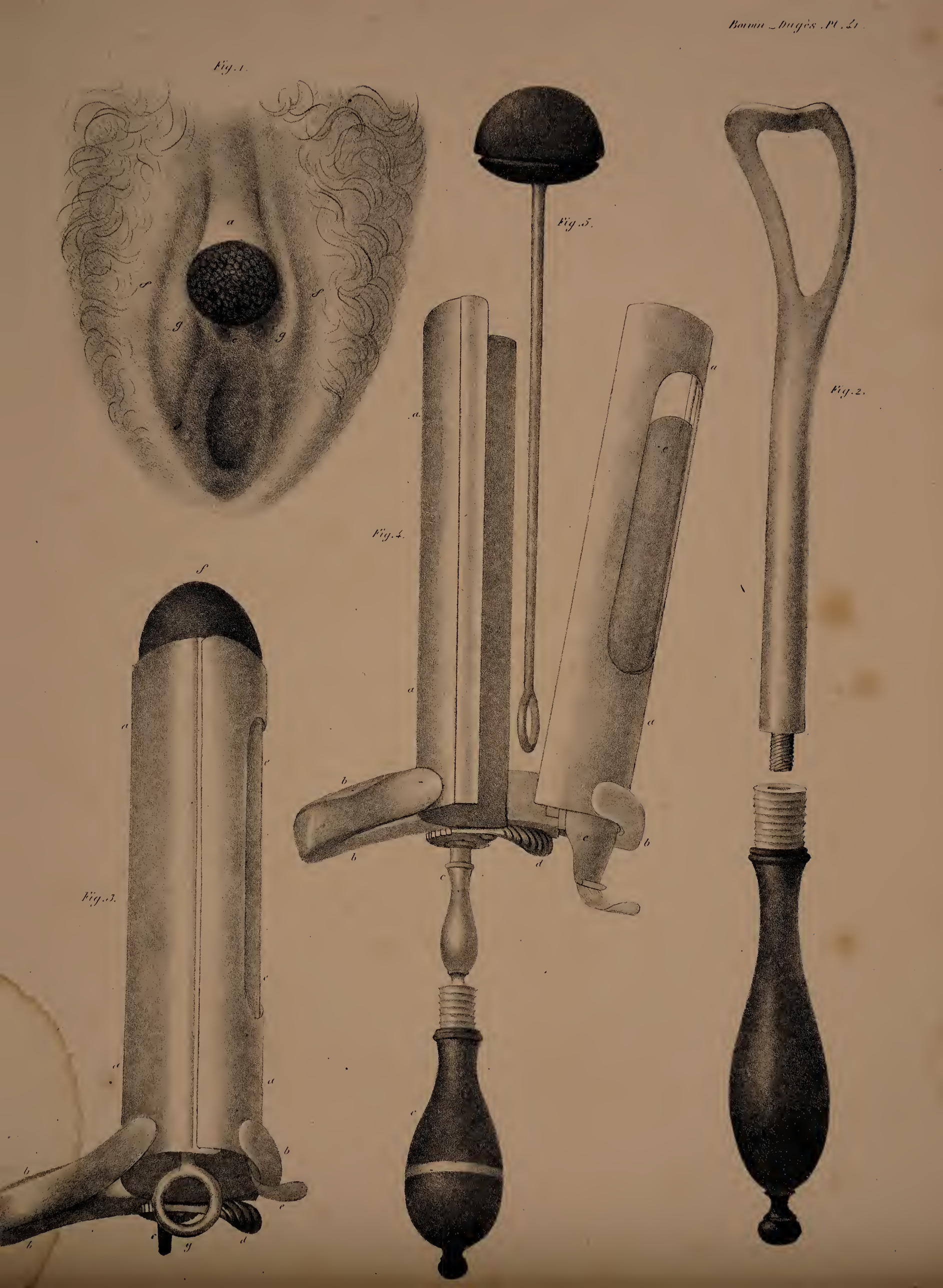
Fig. 1.
a
f
f
g
c
g
Fig. 2.
Fig. 3.
Fig. 4.
Fig. 5.

HEMATODE CANCER OF THE CLITORIS,

THE " SPECULUM BRISÉ " OF Mde BOIVIN, WITH THE NEW AND SUCCESSIVE

MODIFICATIONS WHICH SHE HAS GIVEN TO THIS INSTRUMENT. (1)

EXPLANATION OF THE PLATE.

Fig. 1.

It represents the clitoris affected since a long time with an itching which was obliged to be continually rubbed with linen, or bathed with cold water, some time with oxycrat, without effecting more than a passing relief. This state was followed by a flow of blood, which, the patient thought, came from the uterus. In order to reassure herself she came to us to examine her.

It was easy to see that this woman mistook the organ affected; the tumor formed by the clitoris, projected out of the middle of the vulva, and fell upon the urinary passage, therefore each emission of urine was excessively painful.

This granulated surface, of a brown-red, bleeding at the

(1) Since nearly a year when the first volume of the text of this work was published where there is a notice upon the speculum, page 70. Several persons have claimed the honour of the improvements which belong to us. As these persons attached sufficient importance to it, as to occupy the *Académie royale* with a thing which had appeared to us of too small value to merit the attention of this learned body, we think it right to repeat here, particularly for those who do not possess the text of this work, the different changes which the *speculum* has undergone, to bring it into the condition represented in the 41st plate of this atlas.

In 1819, the speculum such as M. Recamier, then, had made, was a simple polished, smooth pewter tube. M. Dupuytren, added a bended handle of the same metal; almost at the same time, M. Dubois, caused a large slope to be made upon the exterior edge, in order to examine urinary fistulas. Such was the form of the instrument, when we made the application for the first time, under the eyes of professor Duméril, *maison royale de santé.*

It was also in the service of M. Dumeril, that I again sloped the uterine part of the tube, for a case of disease in the uterine neck, which required the application of this instrument.

1819. 2° It was at the same epoch and in the same place, that I had the tube cut into two equal portions Length-wise; these two portions, in form of gutters, were reunited at their edges, by means of a ringed pincers, whose bowed branches were fixed and soldered at the exterior extremity of each fragment of the tube. Thus, the speculum reduced in size, became much more easily introduced; once entered, any degree of stretching might be effectuated, which the exploration of the parts, or the application of medical treatment might require; and it was then fixed by means of a pressing vice placed of the point of junction of the ringed branches of the instrument.

1821. But the negligence shewn in the confection of the instrument made me feel the necessity of adding to it an extra top (un embout), in pewter, which covering the uterine edges of the instrument, opposed the going back of the mucous of the vagina, which often causes great pain.

1823. The ringed branches rendered the instrument not commodious to put in the pocket; I replaced these by a box in copper, soldered on the exterior edge of the left gutter; this box is destined to receive an elbowed pot-hanger soldered on the right gutter; the hook moved in the box by means of a watch-pinion, with wheels catching each other, on a pivot, adapted to the notch of the hook; the pivot placed on the out side, at the centre of the horizontal lever, by means of a key, made, the cursor of the hook, move from left to right. A latch placed near the wheel of the moving pivot, served to fix the two gutters at the degree of distance which had been obtained.

In 1829. I had the instrument made in silver, with a long slope on it, shut by a plate which slides, in an external groove, and can be taken off after introduction, whether for the examination of the vagina, or to apply leeches upon some parts of this sheath, or any medicaments judged necessary.

In 1832. I. had a slight bending added to the horizontal branch, and the gutters opened still more at their internal extremity. This last instrument which is fabricated of nickel, appears to me to offer all desirable advantage for the exploration of the internal genital parts. It is made by Samson, mecanical cutler, *rue de l'Ecole de médecine.*

slightest touch, offered, in our opinion, no way of cure but excision. The pecuniary means of this woman not permitting her to remain at the *Maison de Santé*, where I wished her to enter, she went to the *Hopital Saint-Louis*, under M. Jobert, in February or March 1832. The clitoris was amputated, and the woman perfectly cured. She has, since, gone into Belgium.

A. Body of the clitoris.
B. Granulations.
C. Urinary passage.
The vagina.
FF. Great lips of the vulva.

Fig. 2.

Levier fenêtré. To bring the neck of the uterus to the centre of the vagina, in cases of displacements, where the orifice of the organ does not agree with the opening of the speculum.

A,A,A. *Speculum* shut, and prepared for its introduction into the vagina.
B,B. *Cursor* or horizontal branch.
C. Pivot.
D. Latch to fix the instrument.
F. *Embout.*
G. Ring of the stem which bears the *Embout.*

Fig. 4.

The *Speculum* open.
B. *Cursor.*
C,C. Key adapted to the pivot.
D. Latch.
E,E. Plate with grooves; the *embout,* and its stem which can be pusched in, or out, after having turned the key two or three times.

Nota. We consider the instrument as having two extremities : we call *uterine* extremity, the one which touches the uterus that which bears the *embout,* we call the other the free extremity of the speculum, because in truth it remains free outside of the parts, during the application of this instrument.

END OF THE EXPLANATION OF THE PLATES.