

THE  
CONVOLUTIONS

OF THE



HUMAN CEREBRUM

TOPOGRAPHICALLY CONSIDERED.

BY

WILLIAM TURNER, M.B. LOND., F.R.S.E.

SENIOR DEMONSTRATOR OF ANATOMY IN THE UNIVERSITY OF EDINBURGH.

EDINBURGH: MACLACHLAN AND STEWART,  
BOOKSELLERS TO THE UNIVERSITY.

LONDON: ROBERT HARDWICKE. GLASGOW: JAMES MACLEHOSE.

---

1866.



RECEIVED

15 09 00 30 27 0 10

1900

1900

THE following description of the mode of arrangement of the  
Convolutions of the Human Cerebrum, embracing the most recent  
investigations, is based on a Lecture delivered at the request of the  
Members of the Royal Medical Society, in their Hall, on the  
9th March 1866. It appeared in the *Edinburgh Medical Journal*  
for June of this year; and in preparing this reprint I have  
availed myself of the opportunity of bringing out a little more  
fully some of the anatomical details.

UNIVERSITY OF EDINBURGH,  
*June 1866.*



## THE CONVOLUTIONS OF THE HUMAN CEREBRUM.

---

FROM an early period of anatomical research, the convolutions of the human cerebrum have been regarded as the parts of the nervous system most intimately associated with the performance of the intellectual processes; and their structure, connexions, and mode of arrangement have at various times had bestowed on them a large share of attention by the anatomist and physiologist. Not only by the older writers, but up to the end of the last century, it was customary, in describing the convolutions, to speak of them as if they had no constant arrangement—a mere maze, a riddle, a chaotic mass—and to figure their folds like the coils of the small intestine, with which, indeed, they were not unfrequently compared. Even Vicq d'Azyr,<sup>1</sup> who laboured so assiduously at the elucidation of the structure of the brain, was not able altogether to free himself from this conventional mode of delineation, though in the explanation to his first plate he states that the convolutions were drawn from nature. From the beginning of the present century, a greater amount of care has been bestowed on their representation, and various attempts have been made to unravel their complexities and to discover some order and method in their arrangement. Sömmering, Gall and Spurzheim, Burdach, Rolando, Arnold, Cruveilhier, Leuret, Valentin, Foville, Solly, and Huschke, have all contributed by their labours various important facts to this department of anatomical inquiry, and have assisted in showing that some of the convolutions possess in all brains well-defined positions and relations.

So long, however, as anatomists confined themselves to the study of the convolutions in the fully developed cerebrum, many difficulties lay in the way of obtaining an exact conception of their mode of arrangement. For, in the course of development, not only are the convolutions, which first appear, to a greater or less extent

<sup>1</sup> Œuvres de Vicq d'Azyr, vol. vi. p. 27, Pl. 1, 1805.

subdivided by secondary fissures, but these secondary sulci, as well as some at least of those which mark the primary subdivisions of the hemisphere, are bridged across by one or more secondary gyri, so that the boundaries of the fundamental convolutions in the different lobes are rendered indistinct. The more highly convoluted a brain is, the more complex a disposition do these secondary gyri and sulci assume.

Of late years much attention has been paid, not only to the development of the brain in the human embryo, but to the comparative study of that organ, more particularly in the higher mammalia, with especial reference to the arrangement of the convolutions in man, and through the application of these well-known methods of anatomical research, much additional light has been thrown on the subject. The names of Tiedemann and Reichert are intimately associated with the developmental aspect of the inquiry, whilst with that of its comparative study the name of the late Professor Gratiolet, of Paris, stands out with great prominence. The last-named author<sup>1</sup> approached the subject by tracing the gradual appearance of the convolutions as he passed upwards from the smooth-brained marmoset monkey, to the more complex cerebrum of the orang or chimpanzee, amongst the quadrumana, and thence to the human cerebrum. In this manner he was enabled to determine which gyri, so far as regards order of appearance, are to be looked on as primary, and which as secondary. The facts obtained by this mode of research may be applied, as far as they are in accordance with those derived from the study of the mode of development of the human cerebrum, to the elucidation of the arrangement of the convolutions in the brain of man himself. M. Gratiolet has also the merit of having introduced a system of nomenclature, so much more precise and simple than any previously employed, that it has been adopted, with some slight modifications, by many subsequent writers, not only in France, but in Germany and Britain. In Germany, the late Professor Rudolf Wagner, of Göttingen, tested the observations of Gratiolet by the examination both of several quadrumanous brains, and of a series of human cerebra possessing a highly complex arrangement of the convolutions. In this country, also, the subject, with especial reference to M. Gratiolet's mode of description, has been carefully inquired into by Professors Huxley, Rolleston, and Marshall, and by Mr Flower. Through the conjoined labours of these anatomists, our knowledge

<sup>1</sup> *Memoire sur les Plis cerebraux de l'Homme et des Primatès.* Paris, 1854.

not only of the form, size, and relations of the great subdivisions of the hemisphere, but of the topography of the individual convolutions has been very materially advanced; so much so, indeed, that we can now localize the different gyri, and give to each its appropriate name. In drawing up the following description, I have based my statements on the examination of a number of apparently healthy brains,—partly male, partly female,—obtained either from the dead-house or dissecting-room, and presumably from natives of the British Islands. At the same time, constant reference has been made to the descriptions and drawings of the various distinguished anatomists who have written on the subject.

In entering on the study of the arrangement of the convolutions, it will be found convenient to look, in the first place, at those which are situated on the outer surface, and the anterior (orbital) part of the under surface; and, secondly, at those which lie on the inner face, and the posterior (tentorial) part of the under surface of each cerebral hemisphere. On each of these surfaces certain well-defined convolutions may be distinguished, which, though they may present some variations in arrangement in different individuals, have, in all well-formed brains, such precise connexions and relations as to enable the anatomist to state that they are homologous structures. The separation of the convolutions from each other is indicated on the surface by numerous fissures, some of which are short and shallow, and not unfrequently vary so much in extent and arrangement in different brains that they must be regarded as quite of secondary importance. Others, again, are deeper, more uniform both in position and extent, and possess, therefore, for topographical purposes, a primary value. Of these more constant fissures, some not only indicate the superficial separation of the different convolutions from each other, but also the subdivision of each hemisphere into smaller lobes. In most of our anatomical text-books<sup>1</sup> only one of these primary fissures—viz., the fissure of Sylvius—has been described in a sufficiently precise and accurate manner, and it has been employed to separate the hemisphere into an anterior and a medio-posterior lobe, the subdivision of the latter into its median and posterior parts being indicated not by a fissure, but by an artificial line corresponding to the outer edge of the

<sup>1</sup> When the lecture was delivered the second part of the new edition of Quain's Anatomy, in which a short account of the mode of arrangement and method of nomenclature employed by Gratiolet is incorporated, had not been published.

cerebellum. The recognition of other constant fissures on the surface of the hemisphere has enabled the descriptive writer to subdivide it not merely into three lobes, but into five, each of which possesses certain relations to the great subdivisions of the cranium. These lobes are distinguished by the names frontal, parietal, occipital, temporo-sphenoidal, and central.

*1st, The External and Antero-Inferior (Orbital) Surfaces of the Hemisphere. Figs. 1, 2, 3.*

On these surfaces the following fissures, to which special names have been applied, and which, therefore, merit a separate description, may be distinguished without any difficulty:—The fissure of Sylvius (S`S), the fissure of Rolando (R), the external parieto-occipital fissure (PO, Fig. 2), and the intra-parietal (IP), and parallel (P) fissures. The fissures of Sylvius and Rolando, and the parallel fissure, are usually more distinct than the remaining two, for the latter are not unfrequently bridged across by one or more secondary gyri, which form superficial connecting bonds between the convolutions forming their proper boundaries. The fissures of Sylvius and Rolando, and the external parieto-occipital fissure are important because they mark the lines of separation of the hemisphere into its five lobes; the parallel and intra-parietal fissures, again, are situated within certain of these lobes, and express the lines of separation of individual convolutions.

*The fissure of Sylvius (S`S).*—This well-known fissure has long been recognised by descriptive writers. It is not only the first to appear on the surface of the hemisphere in the course of development, being visible about the fourth month,<sup>1</sup> but it may be seen even in the smooth and lowly organized brains of the lower mammalia. When studied in the human brain it is found to be not unfrequently subdivided into two parts, a horizontal and an ascending limb.

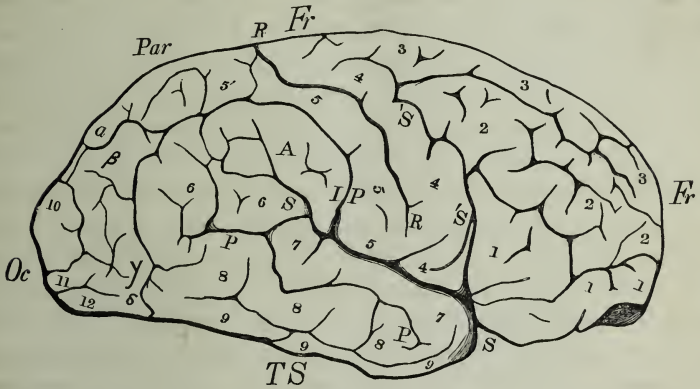
The horizontal part (S) is that which is constant and best known. It forms a deep fossa on the outer face of the hemisphere, and passes from before backwards, and with a slight obliquity upwards. Its length varies from 2·5 to 3·5 inches. It is often somewhat undulating, and at its posterior end not unfrequently bends more or less sharply upwards. In some rare cases it may extend so far upwards as to become continuous with the intra-parietal fissure. It may terminate either simply without dividing, or it may bifur-

<sup>1</sup> Reichert, pl. xi., fig. 32.



cate or trifurcate, in which cases one branch may ascend, and another may pass obliquely downwards and backwards.

FIG. 1.



*Note of Explanation to FIG. 1.*—This and the succeeding outline figures are drawn from nature, with the help of the camera lucida, from the brain of a Scotchman, aged 23:—Fig. 1. A profile view.—Fr., Fr., frontal lobe. Par., parietal lobe. Oc., occipital lobe. T. S., temporo-sphenoidal lobe. S. S., horizontal; and 'S.' 'S.', ascending limb of the Sylvian fissure. R., R., fissure of Rolando. I. P., intra-parietal; and P. P., parallel fissures. 1, 1, 1, inferior; 2, 2, 2, middle; and 3, 3, 3, superior frontal gyri. 4, 4, ascending frontal; and 5, 5, 5, ascending parietal gyri. 5', outer part of postero-parietal lobule. 6, 6, angular gyrus. 7, 7, superior; 8, 8, 8, middle; and 9, 9, 9, inferior temporo-sphenoidal gyri. 10, superior; 11, middle; and 12, inferior occipital gyri. A., supra-marginal lobule.  $\alpha$ ,  $\beta$ ,  $\gamma$ ,  $\delta$ , first, second, third, and fourth annectent gyri.

The ascending limb ('S') is not unfrequently continuous with the anterior end of the horizontal part (fig. 1). It ascends in the substance of the frontal lobe, anterior to the convolution afterwards to be described as the ascending frontal 4, 4, for a greater or less distance. Its extent varies considerably in different brains, and is determined by the mode of origin of the three tiers of frontal convolutions. When these arise superficially from the ascending frontal gyrus, the extent of this fissure is short; and if the origin of the inferior frontal gyrus should be quite superficial from the lower end of the ascending frontal, then the ascending limb of the Sylvian fissure is cut off from the horizontal. This subdivision of the Sylvian fissure corresponds to that described by Mr Huxley, in the quadrumanous brain, as the antero-parietal sulcus.<sup>1</sup>

*The fissure of Rolando (R).*—This fissure, although known to

<sup>1</sup> On the Brain of *Ateles paniscus*.—Proc. Zool. Soc. of London, vol. xxix. p. 257, 1861.

Vicq d'Azyr, was first accurately described by the Italian anatomist Rolando,<sup>1</sup> after whom it was named by Leuret,<sup>2</sup> the distinguished French physiologist. By Huschke,<sup>3</sup> Reichert,<sup>4</sup> and Rudolf Wagner,<sup>5</sup> it has been termed the sulcus hemisphæaræ centralis (Central-furche). It occurs constantly in the human brain, and is met with in the brains of the great majority of the quadrumana. It appears in the brain of the human fœtus about the sixth month of intra-uterine life.<sup>6</sup> It commences a little above the horizontal limb of the Sylvian fissure, and ascends obliquely backwards and upwards in a slightly undulating manner until it reaches the edge of the great longitudinal fissure of the cerebrum. It is bounded both in front and behind by a well-marked convolution, each of which ascends from the Sylvian fissure as far as the great longitudinal fissure. These convolutions will be distinguished in the following description as the ascending frontal (4, 4) and parietal (5, 5) gyri. Short secondary fissures, continuous with the fissure of Rolando, not unfrequently pass into the ascending gyri. At their lower ends the two ascending convolutions usually become continuous with each other, and cut off the fissure of Rolando from that of Sylvius; but I have now more than once seen the fissure of Rolando prolonged so far downwards as to be continuous with that of Sylvius. I have also seen, on both sides of the same brain, the fissures of Rolando separated from the longitudinal fissure by a broad superficial convolution, which connected together the upper ends of the ascending frontal and parietal gyri. In no case have I seen a connecting convolution bridge across this fissure in any part intermediate between its two extremities, and I know of but one brain, that of the clinical physician, C. H. Fuchs, figured by R. Wagner, in Pl. 1 of his 2d Abhandlung, in which this has been represented. The fissures of Rolando on the two sides reach the longitudinal fissure sometimes opposite each other, at others the right a little in front of the left, or *vice versa*, and they form the sides and apex of a V-shaped figure, the apex of which is always nearer the posterior than the anterior end of the cerebrum. The more highly developed the frontal lobe of the brain is, the more oblique is the

<sup>1</sup> Della Struttura degli Emisferi Cerebrali.—Mem. della Reale Accademia delle Scienze di Torino, vol. xxxv. p. 103, 1831.

<sup>2</sup> Système Nerveux, vol. i. p. 398, 1839.

<sup>3</sup> Schaedel, Hirn und Seele, p. 137, 1854.

<sup>4</sup> Der Bau des menschlichen Gehirns, 1859 and 1861.

<sup>5</sup> Vorstudien zu einer wissenschaftliche Morphologie des menschlichen Gehirns, 1860, p. 15.

<sup>6</sup> Reichert, tab. xii. figs. 47, 48.

fissure of Rolando, and the further is the apex of the V thrown backwards. In this description the fissure of Rolando will be regarded as separating the frontal from the parietal lobe.<sup>1</sup>

FIG. 2.

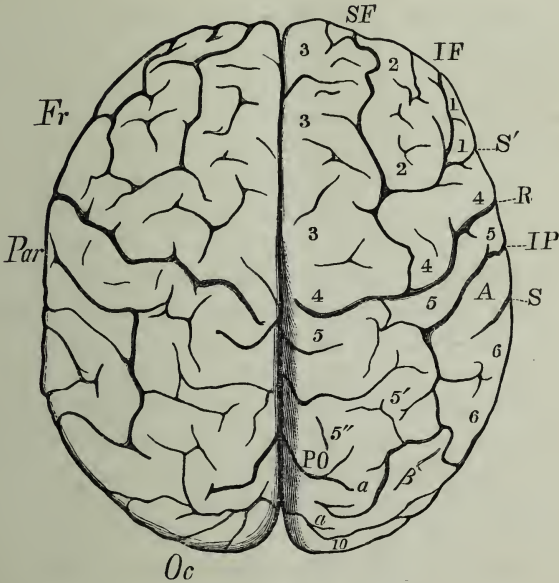


FIG. 2.—Vertex view of the Brain represented in Fig. 1. The same letters and numerals indicate the same parts. In addition, note PO, the parieto-occipital fissure, the external part of which, unshaded, is continuous with the internal part represented in shadow. SF, supero-frontal, and IF, infero-frontal fissure.

*The external parieto-occipital fissure (PO, Fig. 2).*—Various names have been applied at different times to this fissure. Burdach<sup>2</sup> had evidently recognised it as continuous with the upper end of his fissura posterior, and the name posterior fissure has been applied to it by Reichert and Wagner. By Gratiolet and other writers on the cerebral anatomy of the quadrumana—a group in which it is much more strongly marked than in man—it has been

<sup>1</sup> The fissure of Rolando is supposed by many anatomists to lie directly under the coronal suture, but M. Broca (sur le Siége de la Faculté du Langage articulé, Paris, 1861), from positive observations, has shown that it is posterior in position. From the examination of eleven adult male brains, he found that, at the middle line, the fissure was some distance behind the suture, whilst at the outer end it approached much more closely to it.

<sup>2</sup> Vom Baue und Leben des Gehirns, vol. ii. p. 166, 1822.

named the external perpendicular, or vertical, or posterior transverse fissure. The name parieto-occipital is, however, to be preferred to any of the above, because it expresses that it serves as the line of separation between the parietal and occipital lobes. This fissure appears in the development of the human brain about the sixth month.<sup>1</sup>

It is situated at no great distance in front of the posterior end of the cerebrum. It commences at the great longitudinal fissure, where it is continuous with the internal parieto-occipital fissure, and, through its continuity with the latter, its position, even in those cases in which it is feebly marked, may be always recognised. In some brains it appears simply as an indentation in the margin of the hemisphere, but in others it extends for some distance more or less transversely outwards. I saw it in the right hemisphere of a female brain pass rather more than two inches outwards; and in another specimen, also the right hemisphere, it proceeded for four-tenths of an inch outwards, and then extended downwards as far as the lower margin of the outer surface of the hemisphere. The imperfect definition of this fissure in the majority of human brains, as compared with its remarkable distinctness in the brains of most quadrumana, is owing to the presence in the former of certain superficial well-marked secondary convolutions which bridge it over and connect the parietal with the occipital lobe. The closer the first of these bridging gyri lies to the longitudinal fissure the shorter is the external parieto-occipital fissure. Sometimes two or three secondary sulci proceed from it, which may pass either forwards or backwards into the parietal or occipital lobe. The corresponding fissures of the two hemispheres may be exactly opposite, but more frequently one lies a little in front of the other.

*The intra-parietal fissure (IP).*—This fissure is figured in all the more accurate drawings of the human and quadrumanous brain, though no special description has been given of it. It lies within the parietal lobe, from which circumstance I have termed it intra-parietal.<sup>2</sup> It may be recognised at the sixth month of intra-uterine life. It is situated immediately behind and ascends parallel to the ascending parietal gyrus, and then bends almost horizontally

<sup>1</sup> Reichert, pl. xii. figs. 46, 48.

<sup>2</sup> See my "Notes more especially on the Bridging Convolution in the Brain of the Chimpanzee," in which I have also pointed out the amount of variability which this ape displays in the mode of arrangement of the annectent gyri.—Proc. Roy. Soc., Edinburgh, Session 1865-66, p. 578.

backwards, and extends for a varying distance in different brains ; in some cases it may be traced between the first and second bridging convolutions, as in the right hemisphere of figs. 1 and 2. Its ascending part separates the supra-marginal gyrus (A) from the ascending parietal (5) ; its horizontal part separates the supra-marginal gyrus from the ascending parietal lobule (5'). Not unfrequently one or more secondary gyri bridge it across superficially ; a frequent seat for such a connecting convolution is at the angle of junction of its ascending and horizontal portions, excellent representations of which may be seen in the brains of the Bushwomen figured by Professors Gratiolet and Marshall.<sup>1</sup> The intra-parietal fissure is usually separated from the horizontal part of the fissure of Sylvius by that portion of the supra-marginal gyrus which joins the lower end of the ascending parietal convolution. In Gratiolet's Bushwoman it may be seen, however, that they are continuous with each other ; and I have observed the same arrangement in more than one European brain (See fig. 1).

When the hemisphere is viewed in profile, three fissures may be traced passing for a greater or less distance upwards and backwards on its outer face. These are from before backwards, the ascending limb of the Sylvian fissure, the fissure of Rolando, and the intra-parietal fissure,—of which the fissure of Rolando always mounts the highest. They may, more especially the first-named, be continuous with the horizontal limb of the Sylvian fissure, and then seem as it were to radiate from it, but not unfrequently they commence at some little distance above it, and it is owing to their position and direction that the ascending frontal and parietal convolutions are so accurately defined.

*The parallel fissure* (P), (Antero-temporal, Huxley).—This fissure is situated in the temporo-sphenoidal lobe. It lies below and parallel to the Sylvian fissure, hence Gratiolet has termed it the parallel fissure. It may be seen in the brain of a sixth-month human fœtus,<sup>2</sup> and it is well marked in the brains of the quadrumana. It runs more or less tortuously backwards and upwards. Posteriorly, it extends into the angular gyrus, and not unfrequently gives off secondary sulci ; by one of these it sometimes becomes continuous with the Sylvian fissure, and occasionally it, or one of its branches, passes quite through the angular gyrus, and separates superficially the second bridging convolution from that gyrus. When the Sylvian and parallel fissures are connected by an intermediate

<sup>1</sup> Philosophical Transactions. 1863.

<sup>2</sup> Leuret and Gratiolet, pl. 29, fig. 13.

sulcus, as in fig. 1, the first temporo-sphenoidal and angular gyri are no longer continuous superficially with each other.

*Lobes of the Cerebrum.*—Although the usual plan adopted by anatomists was to divide the hemisphere into two, or at the most three, lobes, yet attempts were occasionally made by descriptive writers to introduce a more complete subdivision. In a Treatise on the Structure of the Brain, published in 1822, Burdach describes the hemisphere as consisting of five lobes, an anterior, superior, posterior, inferior, and central. Arnold also, in his systematic work, speaks of four lobes, anterior, superior, posterior, inferior. But this method of description, on account probably of the boundaries of the different lobes not being indicated with sufficient exactness, did not meet with much acceptance. In 1854, Gratiolet re-introduced the system of more complete subdivision, gave to each lobe precise limits, and distinguished them by names indicating their position in the cavity of the cranium. The nomenclature and mode of subdivision employed by Gratiolet have been adopted by most subsequent writers, and, with a slight modification in the posterior boundary of the frontal lobe, will be used in this description.

*The Frontal lobe (Fr)*, as its name indicates, forms the anterior end of the cerebrum. It is subdivided into two lobules, a frontal and an orbital. *The frontal lobule* extends from the anterior end of the cerebrum to the fissure of Rolando. It includes the convolution which ascends in front of that fissure as far as the margin of the great longitudinal fissure, and which may be called, therefore, the *ascending frontal gyrus* (4, 4). By Gratiolet (*Mémoire*) this lobule is not considered to extend so far back as the fissure of Rolando, and the convolution here termed ascending frontal gyrus is included by him in the parietal lobe and named first ascending parietal convolution; under this arrangement the posterior boundary of the frontal lobe is the ascending limb of the Sylvian fissure (anteroparietal, Huxley). But it seems to me that the gyrus ascending in front of the fissure of Rolando is more appropriately placed in the frontal lobe, as it is separated superficially from the other parietal convolutions by that fissure, and it is not unfrequent to find it cut across by secondary sulci into two or three stages, which are quite continuous with those gyri which run from behind forwards and form the three stages of the frontal lobe.

In front of the ascending frontal gyrus the convolutions run from behind forwards, and extend as far as the anterior end of the cere-

brum, where they become continuous with the convolutions of the orbital lobule. They are more or less perfectly subdivided into three stages or tiers, *a superior, a middle, and an inferior*, by two fissures running in the antero-posterior direction, which are named the *supero-frontal (S F)* and *infero-frontal (I F) sulci*.

The superior frontal gyrus (3, 3, 3) lies along the edge of the great longitudinal fissure in its anterior part; the inferior, or infero-external gyrus (*pli surcilier*) (1, 1, 1), bounds the frontal lobule inferiorly and externally; the middle (2, 2, 2) lies intermediate. These convolutions all spring from and are continuous with the ascending frontal gyrus. So far as my observations go, the origin of the superior frontal gyrus is always superficial, but that of the middle or inferior may be either superficial or concealed; the latter more especially in those cases in which the ascending limb of the Sylvian fissure passes far upwards in front of the ascending frontal gyrus. In the more richly convoluted brains these frontal gyri are still further subdivided by short secondary fissures, and the supero- and infero-frontal sulci are bridged across by small secondary gyri, so that it is sometimes difficult to say to which tier a particular portion of convolution should be referred. Wagner has especially recognised this arrangement in the complex human brains he has described; and Gratiolet states that the superior gyrus is frequently subdivided into two secondary convolutions. When the frontal lobe is largely developed, the superior frontal convolution mounts upwards and backwards for a considerable distance along the margin of the great longitudinal fissure.

*The orbital lobule* (Fig. 3) is slightly concave and rests on the roof of the orbit. In it may be recognised a well-marked fissure (O), the olfactory sulcus, which is for the most part concealed by the olfactory bulb and peduncle. The convolution (17), situated internal to this sulcus, forms the anterior part of the great marginal gyrus. External to the olfactory sulcus are several small irregularly arranged fissures which sometimes assume a triradiate form (TR) and subdivide this part of the lobule into three gyri,—an internal, 1'', a posterior, 1', and an external, 1'''. The internal lies on the outer side of the olfactory sulcus, the posterior is situated in front of the most anterior convolution of the island of Reil (C), and the external is blended with the anterior terminations of the superior, middle, and inferior frontal gyri.

*The Parietal lobe* (Par) extends from the fissure of Rolando backwards to the parieto-occipital fissure. Four distinct convolutions

may be recognised in it, which have been termed ascending parietal gyrus, postero-parietal lobule, lobule of the supra-marginal gyrus, and the angular convolution.

FIG. 3.

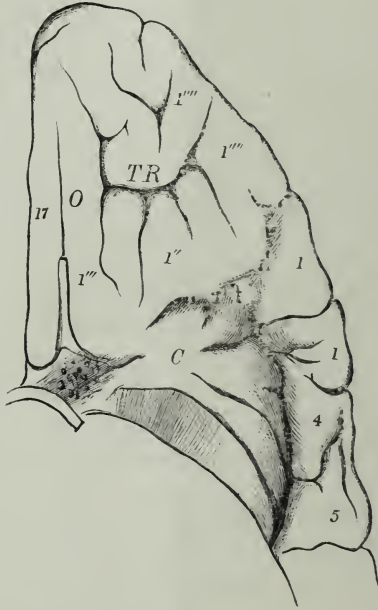

FIG. 3 displays the Orbital Lobule and the Island of Reil.—17, anterior part of the convolution of the margin of the longitudinal fissure; O, olfactory sulcus; TR, triadriate sulcus; 1'', posterior; 1''', internal; 1''''', external gyri of the orbital lobule; C, Island of Reil with its radiating convolutions; 1, 1, under surface of the inferior frontal gyrus; 4 and 5, under surfaces of the lower ends of the ascending frontal and parietal gyri. The temporo-sphenoidal lobe has been to a great extent removed in order to display the island.

*The ascending parietal convolution* (5, 5, 5) passes obliquely backwards and upwards from the Sylvian to the great longitudinal fissure. It is named by Gratiolet,<sup>1</sup> deuxième pli ascendant. It bounds the fissure of Rolando posteriorly. It and the ascending frontal form two of the best defined convolutions of the cerebrum, and have frequently been described by anatomists. They constitute the second and third vertical convolutions of Rolando, and are named the first and second superior convolutions by Leuret (Pl. 16), the antero- and medio-transverse parietal by Foville (Pl. 10), the anterior and posterior central gyri by Huschke and Wagner, and the antero- and postero-parietal by Huxley. Gratiolet himself, modifying

<sup>1</sup> Mémoire, pp. 26, 60.



somewhat the names he employs in his special monograph, terms them, in his explanation to Leuret's seventeenth plate, the ascending frontal and parietal convolutions. The ascending parietal gyrus frequently exhibits several knee-shaped bends and indentations, and is partially, but, so far as my experience goes, never wholly cut across by secondary fissures.

*The postero-parietal lobule* (Huxley), (Lobule du deuxième pli ascendant, Gratiolet) (5', 5'') springs from the posterior part of the upper end of the ascending parietal gyrus and extends backwards as far as the external parieto-occipital fissure. It corresponds in part to the lobule described by Huschke and some other German anatomists as the præcuneus (Vorzwickel). It is bounded externally by the intra-parietal and internally by the great longitudinal fissure. When the intra-parietal fissure is bridged across by secondary gyri, this lobule is connected to the supra-marginal lobule, or to the angular gyrus or to both. It is frequently subdivided into two parts, an inner (5'') and an outer (5'), by a sulcus running more or less in an antero-posterior direction; and in the more richly convoluted human brains, these are again subdivided by several additional small sulci, so as to exhibit a very complex appearance. This lobule is connected to the upper part of the occipital lobe by the first annectent convolution (*a, a*), the size and position of which modify considerably the extent of the parieto-occipital fissure. When large and arising close to the edge of the longitudinal fissure, it may join almost immediately the occipital lobe, and then the external parieto-occipital fissure is little more than a mere depression. If the annectent gyrus should sweep outwards before joining the occipital lobe, then the fissure is much longer and may even bifurcate or still further subdivide, so as to split up this convolution into secondary gyri. I have seen the first annectent convolution apparently cut off at its origin from the postero-parietal lobule by the parieto-occipital fissure, but when the lips of that fissure were parted the two were seen to be continuous and in its further passage the annectent gyrus came to the surface and assumed a large size before it joined the occipital lobe. Gratiolet attached great importance to the size and position of this convolution in the human brain; by him it was first called pli supérieur de passage, a name which has been variously translated by English anatomists as first-bridging, annectent, or connecting gyrus.<sup>1</sup>

<sup>1</sup> Some excellent observations and remarks on the variability displayed by the premier pli de passage in the human cerebrum are recorded by Professor Rolleston in the *Natural History Review*, vol. i. p. 211. See also his Lecture in the *Medical Times and Gazette*, 22d February and 15th March 1862.

*The lobule of the supra-marginal convolution* (Gratiolet) (A, fig. 1) lies between the lower end of the ascending parietal convolution and the summit of the horizontal limb of the Sylvian fissure. It corresponds to that part of the posterior transverse convolution of Foville which forms the anterior boundary of that fissure at its upper end. It is very variable both in size and form. Sometimes it is irregularly quadrilateral, at others more elongated. Not unfrequently it is subdivided by secondary sulci into smaller gyri. Usually it is continuous superficially with the lower end of the ascending parietal convolution, though, when the intra-parietal fissure joins the Sylvian, it is cut off from it (fig. 1). It is often prolonged directly into either the ascending parietal gyrus or the postero-parietal lobule by a secondary gyrus passing across the intra-parietal fissure. It is usually continued posteriorly into the angular gyrus, but in those rare cases in which the Sylvian fissure is prolonged into the intra-parietal it is cut off from it superficially.

*The angular gyrus* (pli courbe, Gratiolet) (6, 6) lies at the summit of the fissure of Sylvius. Its exact limits are not at all times easily defined; but it may be regarded as bounded in front by the supra-marginal lobule, above by the intra-parietal fissure, behind by the occipital lobe, whilst inferiorly it is prolonged into the temporo-sphenoidal lobe with the first and second convolutions of which it is usually continuous, though sometimes secondary fissures disconnect it superficially from one or other or both of these gyri. It is frequently continuous with the postero-parietal lobule by a secondary gyrus bridging over the intra-parietal fissure. Its relation to the occipital lobe is regarded by Gratiolet as one of great importance. He has described a convolution, the second annectent gyrus (deuxième pli de passage  $\beta$ ), as passing from the angular gyrus to the occipital lobe, and as assuming a size and superficial position very characteristic of the human cerebrum. In twelve brains specially examined with the object of determining the arrangement of this second annectent gyrus, I found it superficial in all, though varying somewhat in size and complexity, and, except in two specimens, in all it was superficially continuous with the angular gyrus, so that the parieto-occipital fissure was in that region completely obliterated. The exceptions consisted of the brain already alluded to, in which the parieto-occipital fissure extended as far as the lower margin of the outer face of the hemisphere, and of the brain from which the figures were drawn in which a secondary sulcus springing from the intra-parietal seemed to disconnect the second annectent and angular gyri, but separation of the

edges of the fissure displayed the continuity of one with the other. The angular gyrus, the second annectent gyrus, and the part of the occipital lobe into which the latter is prolonged, are almost equivalent to the transverse occipital convolution of Foville.

*The Temporo-Sphenoidal lobe (T S)* lies behind and below the horizontal limb of the Sylvian fissure. The convolutions which are seen on its outer aspect are simple in arrangement, they lie one below the other, parallel to the fissure of Sylvius, and are distinguished from above downwards, as, first, second, and third, or superior, middle, and inferior temporo-sphenoidal gyri.

*The superior temporo-sphenoidal convolution (7,7)* forms the posterior lip of the horizontal limb of the Sylvian fissure, and corresponds to the posterior part of the convolution of that fissure as described by Foville. From being parallel to that fissure, Gratiolet has termed it the parallel convolution. It is usually simple in form, presents but few tortuosities, and though secondary fissures do pass into it they usually possess no great depth. It is separated from the middle temporo-sphenoidal gyrus by the parallel fissure. By its upper end it is continuous with the angular gyrus.

*The middle (8, 8, 8) and inferior (9, 9, 9) temporo-sphenoidal convolutions* lie parallel to each other and to the superior. They are more or less perfectly separated from each other by a sulcus, the postero-temporal, which is not unfrequently bridged across by secondary gyri. Secondary sulci often pass for some distance into the substance of these convolutions, more especially into the second. The upper ends of these gyri are prolonged into the lower part of the occipital lobe by the third ( $\gamma$ ) and fourth ( $\delta$ ) annectent gyri (troisième et quatrième plis de passage, Gratiolet). These connecting convolutions are superficial throughout, are more or less tortuous, and subdivided, not unfrequently, into smaller gyri by secondary fissures.

*The Occipital lobe (Oc)* forms the posterior end of the cerebrum. Its anterior boundary is the parieto-occipital fissure, though its exact limit in this direction, when the first and second bridging convolutions are large and tortuous, is not at all times easy to define precisely in the human cerebrum. Relatively to the size of the brain this lobe is in man especially small. It is described by Gratiolet as subdivided into three stages of convolutions, a *superior* (10), *middle* (11), and *inferior* (12); but from the fissures which indicate this separation frequently not being parallel, from the pre-

sence of several secondary sulci, and from the mode in which this lobe is connected to the parietal and temporo-sphenoidal by the annectent gyri, the exact line of demarcation of the three stages is often defined with difficulty.

*The Median or Central lobe* (C, fig. 3) is more generally known as the *Insula* or *Island of Reil*, after its first describer.<sup>1</sup> It may be recognised at the fifth month of embryo life, and from its constancy and early appearance is to be regarded as one of the primary subdivisions of the hemisphere. In the fœtus, and even up to the time of birth, it may be seen without difficulty when the outer surface of the cerebrum is examined; but as the growth and development of the lips of the Sylvian fissure proceed, the island becomes so included within it that the margins of the fissure have to be widely everted, or even partially removed, before its form and relations can be properly studied. In the adult it occasionally happens that the more anterior part of the island is visible without any dissection. I have seen such a condition on both sides of the brain of an aged Scotchwoman; M. Gratiolet has observed it on the left side of a European brain; and Mr Marshall states that, in the brain of the Bushwoman he examined, each Sylvian fissure was so patent as to allow the insula, which was less subdivided than is customary, to be seen. This lobe consists of from five to seven short and almost straight gyri (*gyri operati*) which radiate outwards and backwards from about the region of the *locus perforatus anticus*. The sulci between these gyri are short, possess no great depth, and sometimes are so faintly marked that the separation of some of the convolutions from those immediately adjacent is not very apparent. Anteriorly the island is closely related to the orbital lobule, with the postero-internal part of which its most anterior convolution is continuous. Externally it is separated by a deep sulcus from the inferior frontal gyrus, and from the lower ends of the ascending frontal and parietal gyri where they form the anterior lip of the Sylvian fissure. By its deep aspect the *Island of Reil* is closely related to the thin grey lamella, called by Arnold *nucleus tæniæformis*, which forms the outermost part of the extra-ventricular portion of the grey substance of the *corpus striatum*.<sup>2</sup>

The position of the individual convolutions on the outer surface and their general relations in their respective lobes having now

<sup>1</sup> Reil's *Archiv*, Halle, 1809, p. 144.

<sup>2</sup> Very illustrative views of the deep relations of the insula are given by Reichert in figs. 35 and 36 of his 6th plate, Part 2.

been examined in detail, it may be well, in the next place, to look at them collectively, and see what their arrangement may be, when considered as members, not of one lobe merely, but of the entire body of convolutions on the outer face of the hemisphere. If the examination be restricted, in the first instance, to those which lie above the horizontal limb of the Sylvian fissure, and the fissure of Rolando be taken as the starting line, it will be seen that a well-defined convolution extends in the vertical transverse direction immediately in front of, and a second immediately behind, that fissure, from the margin of the longitudinal fissure downwards and outwards to that of Sylvius. These are the ascending frontal and parietal gyri. From the anterior of these gyri the convolutions extend in the postero-anterior direction to the anterior end of the cerebrum, and form the three tiers (more or less distinct in different individuals) of the frontal gyri. From the posterior of these gyri, also, convolutions extend in the antero-posterior direction as far as the posterior end of the cerebrum, but their separation into tiers is not so clearly marked as in the anterior group. Still we may regard the postero-parietal lobule, the first annectent gyrus, and the superior occipital convolution, which are continuous with each other, as forming collectively a superior tier. The supra-marginal lobule, the angular gyrus, the second annectent and middle occipital gyri, may be looked upon as members of a second or inferior tier, though their foldings are often so complex as to add materially to the difficulty of determining their continuity. The gyri of the temporo-sphenoidal lobe, again, are characterized by their correspondence in direction with the horizontal limb of the Sylvian fissure, below which they lie. By their upper ends they blend with the middle and inferior occipital gyri and with the angular gyrus of the parietal lobe, and thus, as it were, continue the posterior convolutions of the inferior tier downwards and forwards to the tip of the temporo-sphenoidal lobe.

In this manner the convolutions just referred to are so associated together as to be grouped around, and form, if one may so express it, a cap or hood, which encloses the convolutions of the median lobe or Island of Reil, and this in so effectual a manner that it is rare to find any of that structure exposed. It is by the great development of the inferior frontal gyrus, the lower ends of the two ascending convolutions, the supra-marginal lobule, the angular and superior temporo-sphenoidal gyri, that the lips of the Sylvian fissure are so closely approximated, that the island is completely concealed within it.

2d, *The Internal and Postero-Inferior (Tentorial) Surfaces of the Hemisphere* (Fig 4.)

It is convenient to study these surfaces together, as the gyri and sulci of the one are, to some extent, prolonged into the other.

*The calloso-marginal fissure (i, i, i)* has been represented in all the best drawings of the brain, from the time of Vicq d'Azyr, but, until very recently, few writers have applied to it any descriptive name. Gratiolet has termed it the fronto-parietal fissure, but the name calloso-marginal, employed by Mr Huxley, seems to be more appropriate. Reichert figures it as present at the twentieth week of embryo life. It commences below the anterior end of the corpus callosum, turns round the genu of that body, but separated from it by the gyrus fornicatus, runs backwards about midway between the corpus callosum and the margin of the longitudinal fissure, and, when a little in front of the posterior end of the great transverse commissure, it then turns upwards to reach the upper edge of the inner face of the hemisphere. A fissure is prolonged backwards from it along the inner face for some distance through that lobe-like mass which has been named by Foville the quadrilateral lobule (18'), but in the human brain it only occasionally reaches the parieto-occipital fissure. Short secondary fissures proceed from the calloso-marginal sulcus into the marginal and callosal convolutions between which it lies, and it is not unfrequently bridged across by one, two, or three secondary gyri.

*The convolution of the corpus callosum, gyrus fornicatus* (18, 18, 18) has been generally recognised since it was described by Malacarne, Sömmering, and Vicq d'Azyr. It commences immediately in front of the anterior perforated space, ascends in front of the genu of the corpus callosum, runs backwards in close relation to the upper surface of that body, turns down behind its posterior free end, cuts off the calcarine from the dentate fissure, and becomes continuous with the uncinata convolution (19). By some writers the anterior end of the uncinata convolution, called also the gyrus hippocampi, is regarded as the inferior and posterior part of the gyrus fornicatus, which is thus considered to be prolonged downwards as far as the tip of the temporo-sphenoidal lobe, *i. e.*, to the entrance to the fissure of Sylvius. The convolution of the corpus callosum, from indications of its presence appearing about the fifth month of embryo life, from its well-defined form and arrangement in the adult brain, and from the existence in it of a readily recognised band of fibres, named by Solly<sup>1</sup>—from their position and direction—the superior

<sup>1</sup> The Human Brain. 2d Edition, p. 254, 1847.

longitudinal commissure, is evidently to be regarded as one of primary morphological importance.

The *marginal convolution* (17, 17, 17) corresponds to the anterior part of the convolution of the margin of the great longitudinal fissure of Foville. It commences on the under surface of the hemisphere in front of the anterior perforated spot, lies immediately internal to the olfactory sulcus (see 17, fig. 3), and then runs upwards and backwards, forming the marginal convolution of the inner face. Sometimes the fissure of Rolando breaks imperfectly its continuity. In this description it is considered to extend only as far as the place where the calloso-marginal sulcus reaches the upper margin of the hemisphere, for behind that place the quadrilateral and occipital lobules constitute the marginal convolutions of the great longitudinal fissure. Foville, however, carries it all the way round the posterior end of the cerebrum as far as the point of the middle (temporo-sphenoidal) lobe. It is more or less subdivided in different brains by secondary sulci, and is usually broader opposite the anterior end of the cerebrum than in the rest of its extent.

FIG. 4.

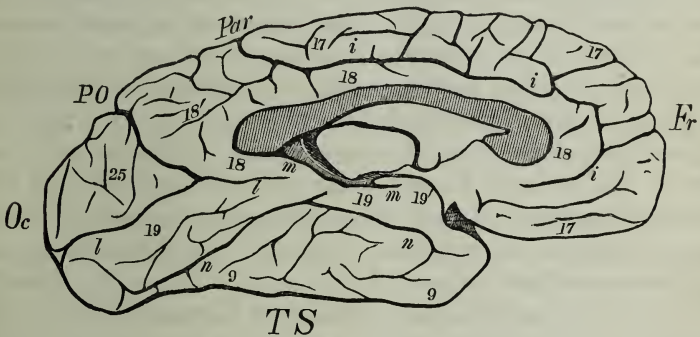


FIG. 4. Inner Face and Tentorial Surface of the Hemisphere.—*i, i, i*, calloso-marginal fissure; *l, l*, calcarine fissure; *m, m*, dentate fissure; *n, n*, collateral fissure; P O, internal parieto-occipital fissure; 17, 17, 17, marginal gyrus; 18, 18, convolution of corpus callosum; 18', quadrilateral lobule; 19, 19, uncinete gyrus, of which 19' is the *crochet* or recurved part; 25, the cuneus or occipital lobule; 9, 9, the inner face of the inferior temporo-sphenoidal gyrus.

The *internal parieto-occipital fissure* (PO) commences at the margin of the great longitudinal fissure, where it is continuous with the external parieto-occipital sulcus, and extends in a curved manner (with the concavity forwards) downwards and forwards until it joins the calcarine fissure. In the human cerebrum, in contrast with what is seen in the brains of many quadrumana, no

annectent gyrus bridges it across superficially, so that it presents a striking contrast to the external fissure of the same name. This fissure was apparently recognised by Vicq d'Azyr, and regarded by him as separating the middle from the posterior lobe,<sup>1</sup> and it has been carefully figured by Burdach, Foville, Cruveilhier, etc. Gratiolet has named it the internal perpendicular fissure, but the term parieto-occipital applied to it by Mr Huxley, expresses more precisely its relations. Between this fissure and the posterior part of the calloso-marginal sulcus, which turns up to the free edge of the marginal gyrus, is an irregularly four-sided convolution, named by Foville the *quadrilateral lobule* (18'). In different brains this is variously subdivided by smaller fissures into secondary gyri.

*The calcarine fissure* (Huxley), (posterior part of the fissure of the hippocampus of Gratiolet), (*l, l*), usually commences at the posterior end of the cerebrum in a bifurcated manner, though I have seen it arise quite simply, and at some distance in front of the hinder end of the hemisphere. It runs forwards, is joined by the parieto-occipital fissure, and extends as far as the postero-inferior part of the gyrus fornicatus, which separates it from the dentate fissure. The calcarine fissure possesses great depth, and it indicates, on the surface of the hemisphere, the position, in the interior of the posterior cornu of the ventricle, of the elevation called hippocampus minor or calcar avis. Several ridges of cerebral substance project into it, one of which, at the posterior part of the fissure, corresponds to the calcarine gyrus of Mr Flower.<sup>2</sup> Reichert figures<sup>3</sup> both the calcarine and internal parieto-occipital fissures, quite continuous with each other, in the brain of a fœtus about twenty weeks old, and from their early appearance he puts them in the same class as the Sylvian fissure,—as possessing, therefore, a greater developmental importance than an ordinary sulcus. In the angle between the calcarine and parieto-occipital fissures is a triangular lobe called the *occipital lobule* (25), which is more or less subdivided into secondary gyri. This lobule was first described by Burdach as the *cuneus* (Zwickel), a name which it still bears in the German descriptive writings.

*The dentate fissure* (Huxley) (anterior part of the fissure of the hippocampus, Gratiolet) (*m, m*) lies immediately posterior to the lower end of the great transverse fissure of the cerebrum and marks externally the position of the hippocampus major internally. Its floor is formed by the grey matter of the fascia dentata, or *corps*

<sup>1</sup> Plate xxii. p. 141.

<sup>2</sup> On the Posterior Lobes of the Cerebrum of the Quadrumana.—Phil. Trans., 1862, p. 192.

<sup>3</sup> Plate xi. fig. 36.



*godronné*,—so called from its plaited appearance,—which lies immediately internal to the tænia hippocampi, where it terminates abruptly, whilst on the other side it is continuous with the grey matter forming the exterior of the uncinatè gyrus. By its lower end this fissure is prolonged into the recurved part of the uncinatè gyrus (19'), whilst superiorly it ends beneath the posterior end of the corpus callosum.

*The collateral fissure* (Huxley) (*n, n*) is situated below the calcarine fissure, and extends somewhat irregularly along almost the entire length of the tentorial surface of the cerebrum. It is not unfrequently subdivided by short gyri passing across it, and secondary fissures branch off from it. It lies below the floors of the posterior and descending cornua of the lateral ventricle, and in a part of its extent the eminentia collateralis is in relation to it.

The convolutions on the tentorial face of the hemisphere are three in number. *The superior internal temporal* (pli godronné) forms the floor of the dentate fissure, and its position is indicated in Fig. 4, by the short parallel lines situated immediately above the dentate fissure. The white line immediately above these again is intended to represent the tænia hippocampi.

*The middle internal temporal*, uncinatè or hippocampal gyrus (19, 19), is bounded, on the one hand, by the calcarine and dentate fissures; on the other, by the collateral fissure. At its lower end it enlarges and forms a recurved portion (19'), called by Vicq d'Azyr the *crochet*, and by Gratiolet the lobule of the hippocampus. As already stated, its anterior part is considered by some anatomists to form the posterior portion of the gyrus fornicatus.

*The inferior internal temporal gyrus* (9, 9) lies below the collateral fissure, and is simply a portion of the inferior external temporo-sphenoidal gyrus, which turns round the lower margin of the hemisphere and forms a part of the internal aspect.

From the time of Vicq d'Azyr and Gall, when the arrangement of the gyri was first systematically examined, down to the present day, anatomists have observed that the convolutions of the brain are not absolutely symmetrical in the two hemispheres of the same cerebrum. The more precise investigations of later years enable one to say that the want of symmetry especially occurs in the secondary gyri, and that it is most strongly marked in the brains which possess the greatest complexity in the arrangement of their convolutions. The observations of Professor Wagner, who enjoyed several opportunities of examining the brains of men endowed

with great powers of intellect, seem to point to the conclusion that the more richly convoluted brains co-exist with great intelligence.<sup>1</sup> Again, it would appear that the average female brain has not such complex convolutions as the average male brain; and from the careful descriptions furnished by Professors Gratiolet and Marshall of the brains of two Bushwomen, it would seem that the number of secondary gyri is smaller in the brain of the savage than in that of the European.

In estimating, however, the comparative value of the convolutions in different individuals, not only should we look at the number of gyri seen on a surface examination, but the depth of the sulci, the thickness of the grey matter, and the quality of the tissue composing the convolutions ought to be considered. A brain with deep sulci, conjoined with a thick layer of grey substance, but with comparatively simple gyri, might present as great an extent of grey matter as one the convolutions of which are much more tortuous though less deep. *That* grey matter is presumably the most active which contains the greatest amount of nerve cells in a given area; but what the comparative quantity of nerve cells may be in a given extent of convolutions from corresponding parts of the brain in individuals of different sexes, or of different races, or even in convolutions taken from different parts of the brain of the same individual, we have at present no definite information. Structurally, therefore, one may say, *that* cerebrum presents the most complex organization in which, with a large proportion of nerve cells in its grey matter, the foldings of the surface are complex, the sulci are numerous and deep, and the grey substance possesses relatively considerable thickness.

<sup>1</sup> The careful drawings and descriptions which R. Wagner has put on record of the brains of five men distinguished for the extent of their attainments in various departments of knowledge, enable one to form a conception of the elaborate appearance the surface of the cerebrum may present, when the development of secondary gyri and sulci has largely taken place. The brain of Gauss, one of the most distinguished mathematicians and astronomers of the present century, figured by Wagner in plates 2, 3, and 4, of his first part, seems at first sight to present so complex an arrangement of its convolutions that the determination of those which are fundamental may well appear to be a difficult task. But, by the exercise of a little attention, first one and then another primary gyrus stands out clearly, until at length the plan of construction becomes evident. Unfortunately, there do not appear to be any facts at present before us to enable one to state what degree of complexity the female brain may assume in its most highly developed condition, as up to the present time no description or drawing of the brain of a highly intellectual woman has been recorded.

The precise morphological investigations of the last few years into the cerebral convolutions have led to the revival in Paris of discussions, in which the doctrine of Gall and his disciples—that the brain is not one but consists of many organs—has been supported by new arguments, and the opinion has been expressed that the primary convolutions, at least, are both morphologically and physiologically distinct organs. Hence both the physiologist and pathologist have been induced to take an interest in a subject which, at the first glance, might seem as if it lay almost exclusively within the province of the morphological or descriptive anatomist. For, instead of the vague and too often loose descriptions of the seats of morbid products to which, through the imperfection of anatomical modes of expression, they were not unfrequently compelled to resort, they have at last been provided with a method of description and a system of nomenclature of that precise character that a lesion affecting the surface of the hemisphere can now be localized with great exactness, the particular convolution or convolutions it affects can be distinctly expressed, and the means can thus be afforded of making an exact comparison of the morbid appearances seen after death in one brain with those which may be observed in others. By combining the results obtained from the examination of a large number of diseased brains, and studying them in connexion with carefully recorded clinical histories of the cases taken during life, it will in time be seen if a lesion in a given convolution is always associated with a particular train of symptoms. If this should be found to be the case, then some authority may be claimed for the view that the convolutions are physiologically distinct organs. Already some steps have been taken which seem to lead in this direction. The observations of M. Paul Broca,<sup>1</sup> that, in some cases under his charge, loss of the cerebral faculty of speech (aphasia) co-existed with a lesion of the posterior third of the inferior left frontal gyrus, seem to point to that convolution as the seat of the faculty of spoken language. Dr Sanders has also communicated to the Medico-Chirurgical Society of our city a case in which a similar defect in the power of speech occurred along with a lesion in the same locality.<sup>2</sup> Such observations have put this aspect of the subject into that stage that, to use the words of Dr Sanders, “it requires and invites fresh investigation.”<sup>3</sup>

<sup>1</sup> Bulletin de la Société Anatomique, 1861–63.

<sup>2</sup> Edinburgh Medical Journal, March 1866.

<sup>3</sup> Dr Sanders has recently met with a second case of aphasia in which the arteries of the brain were highly atheromatous and a well-marked yellow soft-

But, in pursuing this inquiry, it should be kept in mind that a convolution, though separated superficially from its neighbours by fissures, yet becomes continuous with them at the bottom of these fissures, so that the grey matter of the one blends with that of another. Again, adjacent gyri, though in many respects they may present precise morphological positions and relations, are not unfrequently connected together by secondary gyri, either altogether superficial or partially concealed within the dividing fissure, so that we cannot with them, as with a group of muscles, make a subdivision into distinct organs without effecting an artificial separation of their constituent parts. A true physiology, and consequently a definite pathology of the cerebral convolutions, can only be arrived at when not only the intimate structure of the grey matter is ascertained, but after the connexions of the numerous fibres passing to and from it at both their extremities have been determined. Many years of laborious inquiry and careful observation will have to be expended on this department of the subject before we can hope to see it placed on a definite basis; but just as it is desirable before studying the geology of a district to have the surface carefully surveyed and accurately mapped out, so it is advisable that the topography of the convolutions of the human cerebrum should be satisfactorily ascertained before an analysis of the intimate structure and deep connexions of the grey matter can be put forth with the necessary exactness.

ening on the left side of the anterior and external parts of the Island of Reil, extending outwards and forwards to a portion of the under surface of the posterior part of the inferior left frontal gyrus, was found. The softening also penetrated inwards to the external and anterior part of the corpus striatum. Dr Sanders kindly gave me the opportunity of seeing the specimen. See Proc. Med. Chir. Soc., Edinburgh, 8th May 1866, and Lancet, 16th June. Three cases are briefly alluded to by Dr J. Hughlings Jackson in the Ophthalmic Review, April 1866, in which, with extreme defect of speech, the convolutions of the insula were amongst the structures affected.

If these cases are to be regarded as something more than mere coincidences, it would certainly appear as if the grey matter of the insula and adjacent frontal gyrus were of importance in connexion with the faculty of speech.