




MEDICAL SCHOOL
LIBRARY



Gift of
H.M. Fishbon, M.D.





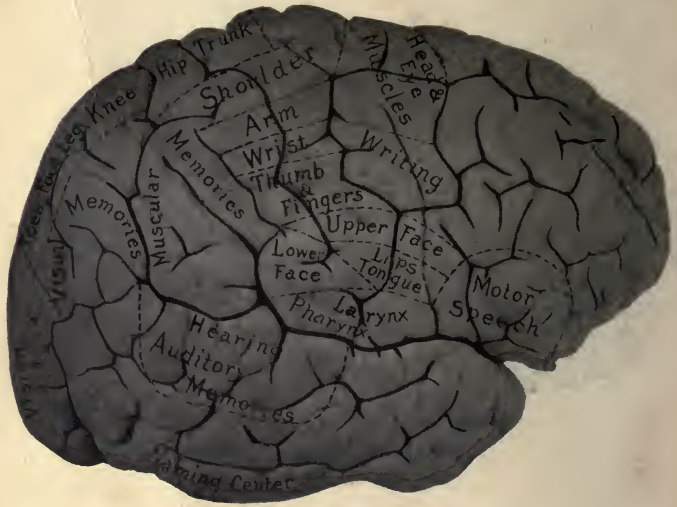


FIG. I.
CONVEX SURFACE OF CEREBRUM CORTICAL AREAS.

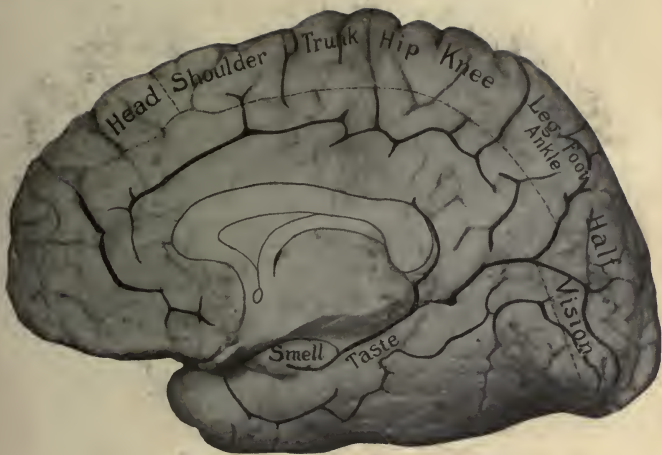


FIG. II.
CORTICAL AREAS ON MEDIAL SURFACE OF CEREBRUM.



Digitized by the Internet Archive
in 2007 with funding from
Microsoft Corporation

ANATOMY
OF THE
BRAIN AND SPINAL CORD

WITH SPECIAL REFERENCE TO
THE GROUPING AND CHAINING OF NEURONES
INTO CONDUCTION PATHS.

FOR STUDENTS AND PRACTITIONERS.

2 BY
HARRIS E. SANTEE, M. D., PH. D.,

PROFESSOR OF ANATOMY IN THE COLLEGE OF PHYSICIANS AND SURGEONS,
MEDICAL DEPARTMENT, UNIVERSITY OF ILLINOIS; PROFESSOR OF
ANATOMY IN HARVEY MEDICAL COLLEGE, CHICAGO.

WITH A PREFACE BY

WILLIAM T. ECKLEY, M. D.,

PROFESSOR OF ANATOMY IN THE MEDICAL AND DENTAL DEPARTMENTS,
UNIVERSITY OF ILLINOIS.

THIRD EDITION
REVISED AND ENLARGED.

CHICAGO:
E. H. COLEGROVE.
1903.

Qm 4/51

523

1903

COPYRIGHT, 1903, BY HARRIS E. SANTEE
CHICAGO, ILL.

1120 30 VIII
1000 1000 1000

QM451
S23
1903

1/2

P R E F A C E .

It is with pleasure I respond to the author's invitation to write an introductory page, and I sincerely acknowledge the compliment.

My remarks, necessarily few, are in the nature of convictions founded on a study of this and the previous edition, on a comparison of this work with others of similar nature, on a long personal acquaintance with the author, an appreciation of his conception of anatomy and his methods of teaching the same. To peruse the book, is to convince one of its value as a contribution to our literature; to know the author, is to enhance the desirability of the book.

It is needless to comment on detail, logical arrangement and orderly subordination of minor to major parts, looking to the ultimate desideratum of a monograph on the brain and spinal cord, for the use of students and practitioners. Such features are possessed by books in general. My remarks will be directed to what I consider superior qualities, these incidentals which relieve the tedium of scientific detail and indelibly impress the practical value of a subject.

The composition, relation and contour of the operculum and posterior part of the inferior frontal gyrus, become more interesting, when it is shown that "They constitute the region of speech." In like manner, that "The temporal lobe is the probable seat of the centers of taste, smell and hearing," and that "The ascending frontal, ascending parietal and superior parietal convolutions are the best known motor areas of the cortex," are physiological observations which

PREFACE.

instruct and fascinate alike. In this manner, throughout the book, the author invokes function of a region to gain an anatomical end.

The olfactory lobe in man, represented by the bulb, tract, trigone, area of Broca and anterior perforated space, finds the lobar antecedent and a reason for its name, in the lower animals, and in this way the author elucidates a point which were incomprehensible to the student without such comparison.

The adult human brain is complex, stable, coherent and heterogeneous, but as a simple, comprehensible means to a great teaching expedient, the author invokes the precepts of embryology to show that this composite brain had a simple vesicular prototype whose simple cavity became complex ventricles, whose simple spongioblasts became complex neuroglial network, whose simple primitive neuroblasts became neurones, with cell-bodies and dendrites in cortex and ganglia, and medullated axones forming the white substance of the brain.

Numerous illustrations might be drawn from every chapter of the book to show like superior teaching qualities, but observations which even the most casual perusal of the book itself makes apparent add nothing of value to criticism.

In his presentation of the tracing of impulses, Dr. Santee has done more to simplify the complex conduction paths to and from the brain than any author after whom I have read. In this respect his book excels, and must appeal to teachers of anatomy, practitioners of medicine and students alike.

The conception of a motor nerve according to many is a tangible band of white matter (as the anterior tibial) associated above with a plexus. Dr. Santee's conception, however, is a path composed of numerous neurones extending

PREFACE.

from a cortical area in the neighborhood of the Rolandic fissure through the pyramidal tracts of the spinal cord to both co-ordinated and inco-ordinated muscles. His conception of a sensory conduction path is not the ordinary one which leaves the student in doubt as to the location of trophic cells of centripetal nerves, but the embryological one which recognizes sensory spinal and sensory cranial nerves as growing toward and into the brain, from posterior root and cephalic ganglia respectively. Such a conception of motor and sensory nerves enables a student to read intelligently the degenerations. Again, it is superior teaching that ascribes function to the definite tracts of fibers, to-wit: "The pyramidal tracts are motor;" "Gower's tract probably carries thermic and pathetic impulses;" "Goll's column carries impulses of the muscular sense;" "All varieties of impulse are carried by Burdach's column;" "The direct cerebellar tract conveys impulses of equilibrium received especially from the viscera."

In conclusion, Dr. Santee's "Anatomy of the Brain and Spinal Cord" is concise, exact, scholarly, and possesses superior qualities in the manner of elucidation; it gives the most comprehensive exposition of the conduction paths of the brain and spinal cord of any book in our language, and is destined to become popular everywhere.

Very truly,

W. T. ECKLEY.

CONTENTS.

CHAPTER I.

	PAGE.
MEMBRANES OF THE BRAIN.....	1-6
Dura Mater.....	1-4
Middle meningeal artery.....	3
Arachnoid.....	4-5
Pia mater.....	5-6
Table 1. Grand divisions of brain.....	6-7

CHAPTER II.

THE CEREBRUM.....	8-51
<i>Section 1.</i>	
Exterior surface.....	9-24
Convex surface.....	9-14
Fissures.....	9-11
Lobes and convolutions.....	11-14
Medial and tentorial surface.....	14-17
Fissures.....	14-16
Lobes and convolutions.....	16-17
Basal surface.....	17-24
Medial structures.....	18-21
Lamina cinerea.....	18
Tuber cinereum.....	18
Pituitary body.....	19
Corpora albicantia.....	19
Optic commissure.....	20
Lateral structures.....	21-24
Orbital lobe.....	21
Island of Reil.....	22
Olfactory lobe.....	22
<i>Section 2.</i>	
Interior surface of cerebrum.....	24-51
Internal capsule.....	25-28

CONTENTS.

	PAGE.
Corpus callosum.....	28-30
General cavity of cerebrum.....	30-31
Fornix.....	32-33
Septum lucidum.....	33
Fifth ventricle.....	33-34
Lateral ventricle, body	34-42
Corpus striatum.....	35-37
Taenia semicircularis.....	37
Optic thalamus.....	37
Choroid plexus.....	38
Cornua, anterior, posterior and middle.....	38-42
Third ventricle.....	42-43
Boundaries	43-44
Roof epithelium.....	44-45
Pineal body.....	45-46
Velum interpositum.....	46-47
Choroid plexus and tela.....	46
Anterior commissure.....	47
Optic thalamus.....	48-50
Hypothalamic region.....	50
Geniculate bodies, external and internal.....	50-51

CHAPTER III.

THE MID BRAIN.....	52-65
Surfaces.....	52-54
Interior.....	54-65
Crustae.....	54-56
Intermediate bundle.....	55
Temporal cerebro-cortico-pontal tract.....	55
Pyramidal tract.....	55-56
Frontal cerebro-cortico-pontal tract.....	56
Substantia nigra.....	56-57
Tegmentum	57-65
Aqueduct of Sylvius.....	58
Corpora quadrigemina.....	59
Internal geniculate body.....	60
Fibers of tegmentum.....	60-65
Posterior longitudinal bundle.....	61

CONTENTS.

	PAGE.
Anterior longitudinal bundle.....	62
Fillet or lemniscus.....	62-63
Superior peduncle of cerebellum.....	64
Olivary bundle.....	64
Tract from red nucleus.....	65

CHAPTER IV.

GRAY AND WHITE MATTER OF CEREBRUM AND MID BRAIN..	66-99
Neurone.....	66-70
Sustentacular tissue.....	67
Cortical gray matter.....	70-76
Motor areas.....	70-71
Somæsthetic area (common sensory).....	70
Special sense areas.....	71
Association centers.....	71-72
Effect of lesions in special areas.....	72
Layers of typical cerebral cortex.....	72-74
Exceptions.....	74-76
Ganglionic gray matter.....	76-84
Corpus striatum.....	76-78
Caudate nucleus.....	76
Lenticular nucleus.....	76
Lesions in corpus striatum.....	77
Optic thalamus.....	78-81
Nuclei of thalamus.....	78-79
White matter of thalamus.....	79-80
Lesions of lateral nucleus and nucleus of pulvinar	78
Nucleus hypothalamicus (Luysi).....	81
Nucleus ruber (red nucleus).....	81
Geniculate bodies.....	82
Corpora quadrigemina.....	82-83
Substantia nigra.....	83-84
Central, or ventricular, gray matter.....	84-85
Lamina cinerea and tuber cinereum.....	84
Middle commissure (massa intermedia).....	84
Nuclei of oculomotor and trochlear nerves.....	84
Projection fibers—Motor.....	85-89
Internal capsule and crusta.....	85-89

CONTENTS.

	PAGE.
Pyramidal tract.....	86-89
Cranial fibers.....	87
Upper extremity fibers.....	87
Trunk fibers.....	88
Lower extremity fibers.....	88
Frontal cerebro-corticopontal tract.....	86
Temporal cerebro-corticopontal tract.....	86
Intermediate bundle.....	86
Tegmentum.....	88
Descending tract from red nucleus.....	88
Anterior longitudinal bundle.....	88
Lesions of motor tracts.....	89
Projection fibers—Sensory.....	89-91
Tegmentum.....	89
Internal capsule—common sensations.....	89-91
Three systems of Flechsig, or cortical fillet.....	89-90
Ansa peduncularis.....	89
Ansa lenticularis.....	89-90
Anterior stalk of thalamus.....	90
Lesions of cortical fillet.....	90
Internal capsule—special sensations.....	90-91
Acoustic radiations.....	90
Optic radiations.....	90-91
Lesions of acoustic and optic radiations.....	90-91
Commissural fibers.....	91
Corpus callosum.....	91
Anterior commissure.....	91
Lyre, or commissura hippocampi.....	91
Association fibers.....	91-94
Short.....	91
Certain lesions of.....	92
Long.....	92-94
Cingulum.....	92
Fornix.....	92
Uncinate fasciculus.....	93
Lesion of.....	93
Superior longitudinal fasciculus.....	93
Interruption of.....	93

CONTENTS.

	PAGE.
Inferior longitudinal fasciculus.....	93
Fasciculus occipito-frontalis.....	93
Perpendicular fasciculus.	94
Blood supply of cerebrum and mid-brain.....	94-99
Cortical system of arteries.....	95-96
Ganglionar system of arteries.....	96-97
Veins.....	98
Lymph spaces.....	99

CHAPTER V.

HIND BRAIN.....	100-128
-----------------	---------

Section 1.

Cerebellum.....	100-118
Functions.....	100
Hemispheres and vermis.....	100-101
Medullary vela.....	101-102
Cerebellar peduncles.....	101-103
Superior surface.....	103-107
Fissures and lobes.....	103-107
Inferior surface.....	107-111
Fissures and lobes.....	107-111
Interior.....	111-118
Gray matter.....	111-114
Cortical.....	111-113
Functions and lesions of.....	113
Ganglionar.....	113-114
White matter.....	114-118
Projection fibers.....	114-116
Cerebellar peduncles.....	114-116
Commissural fibers.....	116
Association fibers.....	117
Blood supply.....	117-118

Section 2.

Pons.....	118-128
Surfaces.....	119-120
White matter of Pons.....	120-125

CONTENTS.

	PAGE
Transverse fibers.....	121-122
Ventral.....	121
Middle.....	121
Dorsal.....	121-122
Longitudinal fibers.....	122-125
Ventral (pyramidal).....	122
Middle (formatio reticularis).....	123
Fillets.....	123-124
Posterior longitudinal bundle.....	124
Anterior longitudinal bundle.....	124
Olivary bundle.....	124-125
Tract from red nucleus.....	125
Root of trifacial nerve.....	125
Dorsal longitudinal fibers.....	125
Superior cerebellar peduncles.....	125
Valve of Vieussens.....	125
Gray matter of pons.....	126
Nuclei pontis.....	126
Nuclei of formatio reticularis.....	126
Cranial nerve nuclei.....	126
Superior olivary nucleus.....	126
Lesions of pons.....	127
Blood supply of pons.....	127

CHAPTER VI.

MEDULLA OBLONGATA.....	128-149
Surfaces.....	129-133
Ventral.....	130-131
Lateral.....	131-132
Dorsal.....	132-133
Interior—white matter.....	133-145
Formatio reticularis and raphe.....	134-135
Transverse fibers.....	135-136
External arciform anterior and posterior.....	135
Internal arciform.....	136
Sensory, or fillet, decussation.....	136
Cerebello-olivary tract.....	136
Dorso-ventral fibers—nerve roots.....	136-137

CONTENTS.

	PAGE.
Longitudinal fibers.....	137-145
Pyramids.....	138
Formatio reticularis alba.....	138-139
Interolivary fillet.....	139
Posterior and anterior longitudinal bundles..	139-140
Formatio reticularis grisea.....	140-141
Antero-lateral ground bundle.....	141
Triangular tract (Helwig).....	141
Antero-lateral cerebellar tracts.....	141-142
Tract from red nucleus.....	142
Fasciculus gracilis.....	142-143
Fasciculus cuneatus.....	142-143
Fasciculus Rolandi.....	143-144
Direct cerebellar tract.....	144
Restiform body.....	144-145
Fasciculus solitarius.....	145
Fasciculus teres.....	145
Interior—gray matter.....	146-149
From anterior horn.....	146-147
From posterior horn.....	147
Added nuclei.....	147 149
Lesions of medulla.....	149

CHAPTER VII.

FOURTH VENTRICLE.....	150-158
Boundaries.....	150-153
Eminentia teres.....	151-152
Fovea superior.....	151-152
Locus coeruleus.....	151-152
Trigonum hypoglossi.....	152
Trigonum vagi.....	152-153
Trigonum acustici.....	152-153
Table II. Origins of cranial nerves.....	153-158
Ventral nuclei, motor.....	156-157
Dorsal nuclei, sensory.....	157-158
Blood supply of medulla oblongata.....	158

CHAPTER VIII.

MENINGES OF SPINAL CORD.....	159-161
Dura mater.....	159

CONTENTS.

	PAGE.
Arachnoid	160
Pia mater.....	160-161
Ligamentum denticulatum.....	161
Nerve and blood supply.....	161

CHAPTER IX.

THE SPINAL CORD	162-184
Enlargements of cord.....	163
Ventricle of cord.....	163
Surface.....	163-165
Fissures.....	163-165
Gray matter of cord.....	165-171
Substantia gelatinosa.....	166
Substantia spongiosa.....	166
Anterior horn of crescent.....	166-168
Lesions of.....	167-168
Center of crescent.....	168-169
Posterior horn of crescent.....	169-170
Gray commissure of cord.....	170-171
White matter of cord.....	171-182
Anterior commissure.....	171-172
Nerve roots.....	179-182
Tracts (longitudinal).....	172-179
Ascending.....	172
Descending.....	172
Mixed (ascending and descending).....	173
Antero-lateral ground bundle.....	173-174
Anterior and posterior longitudinal bundles..	173-174
Uncrossed (direct) pyramidal.....	174
Antero-lateral descending cerebellar.....	174
Antero-lateral ascending cerebellar.....	175
Triangular (Helwig) olivary of cord.....	175
Direct cerebellar.....	175-176
Crossed pyramidal.....	176-177
Crossed descending from red nucleus.....	176
Lesions of pyramidal tracts.....	177
Marginal (Lissauer).....	177
Postero-lateral (Burdach).....	177-178

CONTENTS.

	PAGE.
Cornu commissural.....	178
Septo-marginal.....	178
Comma.....	178
Postero-median (Goll).....	179
Lesions in posterior columns.....	179
Roots of spinal nerves.....	179-182
Anterior roots.....	180
Origins—superficial and deep.....	180
Lesions of lower motor neurones.....	180
Posterior roots.....	180-182
Central terminations.....	181
Superficial (apparent).....	181
Deep (real).....	181-182
Lesions of posterior roots.....	182
Blood supply of the cord.....	182-184

CHAPTER X.

TRACING OF IMPULSES.....	185-201
Efferent, or motor, paths, through.....	185-190
Pyramidal tracts.....	185-186
Frontal cerebro-corticopontal tract.....	186-187
Temporal cerebro-corticopontal tract.....	187
Intermediate bundle.....	187
Red nucleus—direct and indirect.....	188
Short fiber paths (formatio reticularis).....	188-190
Facial paralysis, nuclear and nerve trunk.....	189
Abducent paralysis and irritation.....	189-190
Afferent paths, general sensation.....	190-193
Columns of Goll and Burdach.....	190-192
Direct.....	190-191
Indirect.....	191-192
Cranial nerves and medial fillet.....	191
Direct cerebellar tract.....	191-192
Antero-lateral ascending cerebellar tract.....	192-193
Short fiber paths (antero-lateral ground bundle)....	193
Lesions of sensory tracts.....	193
Afferent paths, special sense.....	194-197
Olfactory.....	194

CONTENTS.

	PAGE.
Optic.....	194-195
Auditory.....	195-197
Cochlear.....	195
Vestibular.....	196
Gustatory.....	197
Lesions of special sense tracts.....	197
Reflex paths.....	198-201
Varieties of reflex arcs.....	198
Spinal reflexes.....	198-199
Defecation, etc.....	198-199
Cranial reflexes.....	199
Spinal and cranial reflexes.....	199-200
Cranial and spinal reflexes.....	200-201
Respiratory.....	200
Auditory.....	200
Pupillary.....	200-201

CHAPTER XI.

EMBRYOLOGY OF BRAIN AND SPINAL CORD.....	202-224
Neural crest.....	202-204
Cranial nerve ganglia.....	202-203
Spinal and sympathetic ganglia.....	203-204
Neural tube.....	204-224
Three histologic layers.....	205
Neuroglia.....	205
Mantle.....	205
Ependymal.....	205
Flexures.....	206
Table III. Brain vesicles and derivatives.....	207-208
1. Prosencephalon.....	208-213
Hemisphere vesicles.....	208-213
Foramen of Monro and lateral ventricles.....	208
Olfactory lobe.....	208
Fissures, primary and permanent.....	209-210
Special thickenings.....	210-211
Fusion of Hemispheres with one another.....	211-212
Fusion with thalamencephalon.....	212
Velum interpositum.....	212-213

CONTENTS.

	PAGE.
2. Thalamencephalon	213-214
Optic vesicle.....	213
Thalamus	214
External geniculate body.....	214
Posterior commissure	214
Pineal body.....	214
3. Mesencephalon	214-215
Tegmentum.....	215
Corpora quadrigemina.....	215
Internal geniculate body	215
Aqueduct of Sylvius.....	214
Substantia nigra.....	215
Crustæ.....	215
4. Epencephalon.....	215-216
Cerebellum.....	215-216
Vermis.....	216
Hemispheres.....	216
Penduncles	216
Pons.....	216
Nuclei of pons.....	216
Nuclei of cranial nerves.....	216
5. Metencephalon.....	217-219
Internal surface.....	218
External surface.....	218
Three histologic layers.....	218-219
Ependymal.....	218
Mantle	218-219
Neuroglial.....	219
Spinal cord.....	220-224
Ventral and dorsal zones.....	220-221
Histologic layers.....	221
Mantle layer—gray substance.....	221-222
Tracts of fibers—when medullated.....	222-223
Fissures of cord.....	223-224

CHAPTER I.

THE MENINGES OF THE BRAIN.¹

Three membranes invest the brain and spinal cord. They are, from without inward, the Dura Mater, the Arachnoid, and the Pia Mater. Each membrane forms a protecting sheath for the cranial or spinal nerves piercing it.

THE DURA MATER.²

Structure and Relations.—It is a very dense and inelastic membrane composed of white fibrous and yellow elastic tissue. It is lined with flat endothelial cells which constitute its internal surface. The dura is made up of two layers, but they are in most places closely united. The external layer constitutes the endosteum of the cranial bones. It is their nutrient membrane. Through the cranial foramina and sutures it is continuous with the external periosteum. The internal layer of the dura separates from the outer layer, at the foramina, to form sheaths for the nerves and, along the sinuses, to form the internal boundary of those venous spaces and to produce the great incomplete partitions, called processes, which project centrally into the great fissures of the brain.

Processes.—From the inner surface of the dura the great processes³ are given off. The *falx cerebri* and *falx cerebelli* hang vertically in the great longitudinal fissure of the cere-

(1) Meninges encephali.

(2) Dura mater encephali.

(3) Processus duræ matris.

brum and the posterior notch of the cerebellum; and, into the great transverse fissure, extends horizontally the *tentorium cerebelli*. The falx cerebri is attached in front to the crista galli and behind to the internal occipital protuberance and superior surface of the tentorium; the falx cerebelli continues from the inferior surface of the tentorium, along the occipital crest, to the posterior border of the foramen magnum. The attachment of the tentorium cerebelli is to the internal protuberance and the lateral arms of the crucial ridge forward to the petrous bone; and, then, it is along the superior border of the petrous bone to the clinoid processes of the sphenoid. A large median notch between its anterior border and the dorsum ephippii, *incisura tentorii*, transmits the mid-brain. The *diaphragm sellæ* is a small centrally perforated sheet of dura which covers the pituitary fossa.

Sinuses.—Large venous passages lined with endothelial cells, and called sinuses, are situated between the layers of the dura. In the convex and in the free border of the falx cerebri are, respectively, the *superior*⁴ and the *inferior*⁴ *longitudinal sinus*. The superior extends from the foramen cæcum back to the *torcular Herophili*,⁵ at the internal occipital protuberance. Joining the common vein⁶ of Galen, at the margin of the tentorium, the *inferior longitudinal sinus* becomes the *straight*,⁷ whose course is through the middle of the tentorium to the torcular. The *occipital sinus*⁸ (or sinuses) traverses the falx cerebelli from the foramen magnum upward to the same point. In the torcular Herophili the *lateral sinuses*⁹ rise. Grooving the horizontal arms of

(4) Sinus sagittalis superior, et inferior.

(5) Confluens sinuum.

(6) Vena cerebri magna.

(7) Sinus rectus.

(8) Sinus occipitalis.

(9) Sinus transversus (sing.).

the crucial ridge, each runs outward in the tentorium to the base of the petrous bone, where it receives the superior petrosal sinus; it then turns downward through the sigmoid fossa and unites with the inferior petrosal sinus in the jugular foramen. Situated on either side of the sella Turcica is a continuation of the ophthalmic vein, the large *cavernous sinus*,¹⁰ whose division at the apex of the petrous bone forms the two petrosal sinuses.¹¹ The *circular sinus*¹² (around the sella) joins the two cavernous to each other; and the inferior petrosal sinuses communicate with one another through the *transverse* or *basilar sinus*.¹³ The *petrosal sinuses*, from the bifurcation of the cavernous sinus, follow outward the corresponding border of the petrous bone; the *superior petrosal* empties into the lateral sinus at the base of the petrous bone; and the *inferior petrosal*, running outward to the jugular foramen, unites with the lateral sinus in forming the internal jugular vein.

Along and within the superior longitudinal sinus are the **Pacchionian bodies**.¹⁴ They are enlarged villi of the arachnoid, and seem to afford an outlet for the sub-arachnoid fluid into the superior longitudinal sinus.

The **arteries** which supply the dura are the anterior and posterior ethmoidal from ophthalmic; from internal carotid, the anterior meningeal; the great and small meningeal which are branches of internal maxillary; meningeal branches of the ascending pharyngeal and occipital; and the posterior meningeal from the vertebral artery.

The *middle meningeal*¹⁵ is largest. It is accompanied by

- (10) S. cavernosus.
- (11) Sinus petrosus superior, et inferior.
- (12) S. circularis.
- (13) S. basilaris.
- (14) Granulationes arachnoideales.
- (15) Arteria meningeae media.

a vein and surgically is important because of its course over the motor area. Ascending from the foramen spinosum it divides near the upper border of the squamosa into two large branches, the anterior and posterior. The posterior runs horizontally backward just below the squamo-parietal suture and then ascends over the posterior half of the parietal bone. The anterior branch runs upward a half-inch behind the coronal suture. It may be located, according to Quain, at one inch, one inch and a half, and two inches behind external angular process and above the zygoma.

The following **nerves** give branches to the dura:—trochlear, ophthalmic, Gasserian ganglion, the tenth and twelfth cranial; and the sympathetic. The motor fibers supply the meningeal arteries.

Six points of difference in the dura of the cord.—Absence of processes, of sinuses, of Pacchionian bodies, and of perios-teal function. It is covered on both surfaces by endothelium and separated from the vertebræ by areolar tissue, fat and the meningo-rachidian veins.

ARACHNOID OF BRAIN.

In structure it is a delicate, fibrous, web-like membrane covered externally with endothelium. Internally it is joined to the pia mater by innumerable fibrous trabeculæ, the sub-arachnoid tissue. The trabeculæ and all spaces formed by them possess a single layer of endothelial cells. Conical elevations of fibrous tissue with their investing epithelium constitute the villi seen on the outer surface.

Relations.—The arachnoid¹⁶ follows the inner surface of the dura and is prolonged, as a sheath, upon the nerves which pierce it. It does not dip into the sulci of the brain. From

(16) Arachnoidea encephali.

the pia it is separated by the subarachnoid spaces.¹⁷ The *anterior subarachnoid space* (cisterna pontis, interpeduncularis et chiasmatis), in front of the medulla, pons and mid-brain and between the temporal lobes of the cerebrum; and the *posterior* (cisterna cerebello-medullaris), between the medulla and cerebellum, contain most of the subarachnoid fluid. The posterior communicates with the fourth ventricle through the foramen of Magendie¹⁸ and the foramina of Key and Retzius.¹⁹

The vessels seen for a short distance in the arachnoid belong to the pia mater. Its nerves are doubtful. Perhaps branches of the inferior maxillary, of the facial and of the spinal accessory supply it.

In the arachnoid of the cord fewer trabeculæ join it to the pia; and these, in great part, are collected to form a fenestrated septum in the posterior median line. The medullispinal veins are covered by the arachnoid, lying between it and the pia.

PIA MATER OF THE BRAIN.²⁰

Structure.—It is a vascular membrane composed of a close network of veins and arteries held together by fibro-elastic areolar tissue. The endothelium covering its outer surface is continuous with that of the subarachnoid trabeculæ and spaces. **Relations.**—The pia closely follows the brain surface. Internally, it sends supporting trabeculæ into the brain, which transmit blood-vessels; and externally it forms an investing sheath for the cranial nerves. Two important processes are formed by it; the velum interpositum (which forms the superior choroid tela²¹) is tucked into the choroid

(17) Cavum subarachnoideale (sing.).

(18) Apertura mediana ventriculi quarti.

(19) Apertura lateralis ventriculi quarti (sing.).

(20) Pia mater encephali.

(21) Tela choroidea ventriculi tertii.

(anterior great transverse) fissure between the fornix and the inter-brain. A second process is tucked in over the fourth ventricle, between the medulla and cerebellum. It forms the inferior choroid tela,²² which roofs over the inferior part of the fourth ventricle, and is of triangular shape. The inferior choroid tela is pierced by three foramina (Magen-die, and Key and Retzius). They open into the fourth ventricle.

The **arteries** of the pia are the anterior, middle and posterior cerebral, the anterior and posterior choroids, and the anterior and posterior inferior cerebellar and superior cerebellar with many branches.

Veins are numerous in the pia; the veins of Galen and of the choroid-plexuses of the lateral, third and fourth ventricles and the basilar vein; cerebral veins, superior, medial and inferior; and superior, lateral and inferior cerebellar veins. All of them empty into the sinuses.

Seven cranial nerves—3rd, 5th, 6th, and 7th, 9th, 10th and 11th—and the sympathetic supply the pia mater and its blood-vessels.

The *pia mater of the spinal cord* has two layers, the outer of which is the more vascular and contains the spinal arteries and the tributaries of the medulli-spinal veins. It forms three processes, namely, the anterior septum, which occupies the anterior median fissure, and the ligamentum denticulatum of each side.

TABLE 1.

GRAND DIVISIONS OF BRAIN.

The brain may be conveniently studied in four grand divisions:

(22) Tela choroidea ventriculi quarti.

I. Cerebrum,²³ composed of—1. Hemispheres,²⁴ which include:

Their cortex and medulla,
 Corpora striata, and
 Olfactory lobes,
 With connecting links of the hemispheres:
 Corpus callosum,
 Fornix,
 Commissura hippocampi and
 Anterior commissure; and

2. Inter-brain,²⁵ or Thalamencephalon, which includes:

Lamina cinerea,
 Tuber cinereum and infundibulum,
 Corpora albicantia,
 Optic thalami,
 Middle commissure, and posterior (in part).
 Pineal body,
 External geniculate bodies,
 Optic tracts and commissure.

II. Mid-brain, Crus Cerebri, or Pedunculus Cerebri²⁶

Crustæ, (the bases or pedes pedunculi)
 Substantia nigra
 Tegmentum
 Corpora quadrigemina
 Internal geniculate bodies.

III. Hind-brain²⁷—

Pons
 Cerebellum.

IV. After-brain²⁸—

Medulla.

(23) Prosencephalon.

(24) Telencephalon.

(25) Diencephalon.

(26) Mesencephalon.

(27) Metencephalon.

(28) Myelencephalon.

CHAPTER II.

THE CEREBRUM.

The cerebrum is that part of the brain which especially characterizes man. In man only does it reach such predominant development. Though a mere outgrowth of the anterior brain-vesicle in the beginning, it completely overshadows all other parts of the brain by the seventh month of embryonic life, extending farther forward, backward and lateralward than any other part. Reference to the table given above shows that the cerebrum is made up of the *hemispheres* and the *inter-brain*. It constitutes an ovoid mass, flattened inferiorly, which fills the vault of the cranium and rests, below, upon the floor of the cranial cavity in the anterior and middle fossæ and upon the tentorium cerebelli over the posterior fossa. Viewed from above, it is sufficiently round to suggest a sphere; and, being divided in the median line by the great longitudinal fissure, the lateral halves are called hemispheres. In the floor of the great longitudinal fissure the corpus callosum can be seen joining the hemispheres together; and beneath it, concealed from view, are the fornix, anterior commissure, and commisura hippocampi. Those are the connecting links, proper, of the hemispheres. Inferior to them, is found the inter-brain. The latter forms an additional union of the hemispheres, as may be seen by viewing the base of the brain. In order to fix important landmarks and to learn the location and relations of the gross structures

of the cerebrum, it is necessary to study in detail the topography of the exterior and interior surface. It is that with which the present chapter deals. For the minute anatomy of the cerebral structures, see Chapter IV.

SECTION 1. THE EXTERIOR SURFACE.

The exterior surface of the cerebrum¹ is composed of a thin sheet of gray matter varying in thickness from one-sixth to one-quarter of an inch. That gray matter forms a bark-like covering for the underlying white substance and is, therefore, called the *Cortex*. It is thrown into irregular elongated folds named *Convolutions*, or *Gyri*, by deep linear depressions, which greatly increase the relative amount of cortical substance. The linear depressions are called *Fissures*, or *Sulci*; and, in consequence of them, the gray substance is increased in bulk to 58½ per cent of the entire cerebrum (De Regibus).

The exterior surface is conveniently studied in three regions, namely, the Convex Surface, the Medial and Tentorial Surface, and the Basal Surface.

FISSURES OF THE CONVEX SURFACE.²

Two fissures are very extensive. The **great longitudinal fissure**³ separates the hemispheres of the cerebrum. It contains the falx cerebri. The cerebrum is separated from the cerebellum by the **great transverse fissure**.⁴ This fissure continues forward above the mid-brain, and terminates in the cerebrum between the inter-brain and the hemispheres as **choroid fissure**. The tentorium occupies its posterior part. The *fissura choroidea* contains the *velum interpositum*. Three

- (1) Prosencephalon.
- (2) *Facies convexa*.
- (3) *Fissura longitudinalis cerebri*.
- (4) *Fissura transversa cerebri*.

interlobular fissures⁵ are found on the convex surface of each hemisphere:

(1) **The Fissure of Sylvius**⁶ begins in the vallecule at the base of the brain. It runs outward between the frontal and the temporal lobe, along the lesser wing of the sphenoid bone; and, turning upward, on the convex surface it divides into an anterior, a vertical and a horizontal ramus. Into the frontal lobe project the small anterior and vertical rami. They are separated by the foot (posterior end) of the inferior frontal gyrus, called the *frontal operculum* (*operculum*, a cover). Below the anterior ramus is a knuckle of the same frontal convolution which forms the *orbital operculum*; and, between the vertical and horizontal rami, is located the *fronto-parietal operculum*, constituting the connecting gyrus between the precentral and postcentral convolutions. The opercula cover the island of Reil. The horizontal limb of the Sylvian fissure separates the temporal lobe from the parietal. Near the crotch and within the fissure of Sylvius is situated the island of Reil. A line drawn from *the Sylvian point*, one and one-quarter inches behind the external angular process of the frontal and one and a half inches above the zygoma, backward to a point three-quarters of an inch below the parietal eminence, lies directly over the horizontal ramus of this fissure.

(2) **Fissure of Rolando.**—Beginning just above the horizontal limb of the fissure of Sylvius, is the fissure of Rolando, or Central fissure,⁷ which extends upward and backward almost to the great longitudinal fissure. Its upper extremity is about half an inch behind the middle of a line drawn from the nasal eminence to the external occipital protuber-

(5) Fissuræ interlobulares.

(7) Sulcus centralis.

(6) Fissura lateralis cerebri.

ance (the sagittal meridian). With this line the fissure of Rolando forms an anterior angle of 67 to 73 degrees. The fissure of Rolando forms the boundary between the frontal and the parietal lobe. It is developed in two parts, superior and inferior, which join at an angle open backward, the genu, and both parts may present an anterior concavity.

(3) **Parieto-occipital Fissure.**⁸—If the line locating the horizontal limb of the fissure of Sylvius be extended back to the sagittal meridian its posterior end marks the location of the parieto-occipital fissure (external part). The greater part of this fissure is on the internal or medial surface of the hemisphere. To the extent of half an inch the external parieto-occipital fissure separates the parietal and occipital lobes from each other.

LOBES AND CONVOLUTIONS OF THE CONVEX SURFACE.

(1) **The Frontal Lobe**⁹ comprises the anterior polar region of the hemisphere back to the Rolandic and the Sylvian fissure. It is subdivided by three sulci: The precentral sulcus¹⁰ (superior and inferior parts), which is parallel with the fissure of Rolando (central), and the superior and inferior frontal sulci.¹¹ The two latter extend downward and forward from superior and inferior precentral sulci, respectively, and separate from each other the *superior, middle* and *inferior frontal convolutions*.¹² The *ascending frontal convolution*¹³ (precentral) lies between the precentral sulcus and the fissure of Rolando. It is joined to the ascending parietal convolution¹³ (postcentral) by the paracentral lobule,¹⁴

(8) Sulcus occipito-parietalis.

(9) Lobus frontalis.

(10) Sulcus præcentralis.

(11) S. frontalis superior, inferior.

(12) Gyrus frontalis superior, medius, inferior.

(13) G. centralis anterior, posterior.

(14) Lobulus paracentralis.

above the central fissure, and by the fronto-parietal operculum, below it. The fronto-parietal operculum and posterior part of the inferior frontal gyrus constitute the *region of speech*. In the foot (posterior end) of the middle frontal gyrus is the *writing center* (Gordinier).

(2) **The Parietal Lobe**¹⁵ is situated behind the fissure of Rolando and above the horizontal limb of the Sylvian fissure. From the posterior end of the latter to the external parieto-occipital fissure, the lobe is separated from the temporal, below, and the occipital, behind, by an imaginary line. The sulci of this lobe are the intraparietal,¹⁶ with an anterior and a posterior ramus (joined by the genu) which are parallel with the central and the great longitudinal fissures, respectively; and the postcentral sulcus,¹⁷ which ascends from the genu of the intraparietal almost to the great longitudinal fissure. The anterior limb of the intraparietal fissure and the postcentral sulcus separate the *ascending parietal convolution*¹⁸ from the superior parietal and inferior parietal.¹⁹ The posterior limb of the intraparietal fissure separates the *superior* and *inferior parietal convolutions* from each other. Indefinite sulci subdivide the inferior parietal into *supra-marginal*,²⁰ *angular*,²¹ and *postparietal gyri*, which wind over the upturned ends of the Sylvian and first and second temporal sulci, respectively. The best known *motor areas* of the cortex are contained in the ascending frontal, ascending parietal and superior parietal gyri; in the foot of the inferior and middle frontal convolutions; in the quadrate and paracentral lobules, and in the marginal gyrus.

(15) Lobus parietalis.

(16) Sulcus interparietalis.

(17) S. postcentralis.

(18) Gyrus centralis posterior.

(19) Lobulus parietalis superior, inferior.

(20) Gyrus supramarginalis.

(21) Gyrus angularis.

The area of general sensation, *somæsthetic area*,²² nearly coincides with the great motor areas; it is a little more extensive as it includes much of the limbic lobe.

(3) **Occipital Lobe.**²³—It forms the posterior pole of the hemisphere. With the parietal and temporal lobes it is directly continuous, being marked off from them by an imaginary line drawn from the preoccipital notch to the external parieto-occipital fissure. The parieto-occipital fissure bounds it to the extent of half an inch; rarely, the external perpendicular fissure bounds it in front. Its sulci²⁴ and convolutions vary much; usually the following are found: The superior occipital sulcus, vertical, or longitudinal, in direction, and the middle and inferior,²⁴ which are horizontal, divide the lobe into *superior*, *middle* and *inferior convolutions*.²⁵ The superior occipital sulcus is often continuous with the intraparietal fissure. The inferior occipital sulcus follows the lower border of the convex surface. The superior and inferior convolutions form the corresponding borders of the lobe and trend toward the occipital pole. The middle occipital gyrus is in the angle between them and may reach the medial border. The *visual memory center* is located in the convex surface of the occipital lobe and in the angular gyrus.

(4) **The Temporal Lobe**²⁶ is that part of the cerebral hemisphere behind the main stem and below the horizontal limb of the fissure of Sylvius. It rests in the middle fossa of the skull; and is probably the seat of the *centers of taste, smell and hearing*. The first temporal sulcus²⁷ (or parallel sulcus) and the second temporal sulcus²⁷ divide the lobe into three

(22) *Soma*—body—*Aesthesia*—perception, or feeling.

(23) *Lobus occipitalis*.

(24) *Sulci occipitales laterales*. S. oc. transversus.

(25) *Gyri occipitales laterales*.

(26) *Lobus temporalis*.

(27) *Sulcus temporalis superior, medius*.

horizontal convolutions, named, from the Sylvian fissure downward, the *first*, *second* and *third temporal convolutions*.²⁸ In the third and fourth fifths of the first temporal convolution, and in the transverse temporal gyri, concealed in the fissure of Sylvius, is the *receptive center of hearing* (Barker).

Annectant convolutions are small links joining the greater gyri. The first annectant joins the superior parietal and superior occipital convolutions. To the middle occipital gyrus, the angular or postparietal is linked by the second annectant and the middle temporal by the third. The fourth annectant unites the inferior temporal and inferior occipital convolutions. There are other less constant annectants.

(5) **The Island of Reil**²⁹ is also called the central lobe. Situated within the fissure of Sylvius, it is bounded at the base of the brain by the sulcus limitans insulæ (anterior, external and posterior).³⁰ The sulcus centralis insulæ divides it into *anterior* and *posterior lobule*, each of which is composed of from two to four convolutions.³¹ The frontoparietal operculum and inferior frontal convolution, together with the temporal lobe, cover the insular convolutions, hence the name, *gyri operati*, also applied to them.

FISSURES OF THE MEDIAL AND TENTORIAL SURFACE.

The middle third of this surface³² is made by sagittal section through the connecting links of the hemispheres and the inter-brain. The free surface presents six fissures.

(1) **Calloso-marginal Fissure**.—Beginning under this middle cut surface and extending forward, upward and backward until it half encircles the corpus callosum; and then turn-

(28) Gyrus temporalis superior, medius, inferior.

(29) Insula.

(30) Sulcus circularis (Reil).

(31) Gyri insulæ—G. breves, Gyrus longus.

(32) Facies medialis.

ing upward to the convex border and ending just behind the fissure of Rolando, is the calloso-marginal fissure.³³ It separates the gyrus fornicatus and the marginal convolution from one another by its anterior part; and, by its upturned posterior end, separates the paracentral lobule from the quadrate lobe.

(2) **The Parieto-occipital Fissure** (internal part)³⁴ extends upward and backward from just beneath the thick posterior margin of the corpus callosum, the splenium, to the border of the medial surface, where it is continuous with the external parieto-occipital fissure. It is situated between the quadrate and the cuneate lobe.

(3) **Calcarine.**—From near the middle of the parieto-occipital, the calcarine fissure³⁵ extends in a curve downward and backward between the cuneate lobe and the fifth temporal (lingual) convolution and ends bifid. The anterior part of the parieto-occipital fissure, in its formation, may be common either to that fissure or to the calcarine.

(4) **Hippocampal Fissure.**—A crescentic fissure, convex downward, winds from the splenium of the corpus callosum forward beneath the optic thalamus nearly to the end of the temporal lobe, where it is closed by the uncus. It is the dentate or hippocampal fissure.³⁶ On the surface of the temporal lobe this fissure appears to be identical with the temporal extension of the great transverse fissure, the *choroid fissure*; but, deeply, it lies posterior to it and is separated from the choroid fissure³⁷ by the fascia dentata.

(5) **Choroid Fissure.**—It is of horseshoe shape and extends from the foramen of Monro backward,—and downward,—and forward to near the pole of the temporal lobe. On its con-

(33) Sulcus cinguli.

(34) S. parieto-occipitalis.

(35) Fissura calcarina.

(36) F. hippocampi.

(37) Fissura choroidea.

vexity it is bounded by the fornix. The fissure is a complete one, involving the whole hemisphere wall. A single layer of epithelium separates it from the lateral ventricle. The pia mater, dipping into it, forms the choroid plexus of that ventricle. The fissure is again peculiar in the fact that between the roof of the third ventricle and the fornix it is directly continuous with the same fissure on the opposite side. In this antero-superior part, which is in direct continuity with the great transverse fissure, is the velum interpositum.

(6) **The Collateral Fissure**³⁸ is situated below the dentate, parieto-occipital and calcarine fissures, and is developed in three parts. The collateral fissure bounds, inferiorly, the hippocampal and the fifth temporal convolution; and separates them from the fourth temporal (fusiform) gyrus.

LOBES AND CONVOLUTIONS OF MEDIAL AND TENTORIAL SURFACE.

They form two concentric rings, interrupted antero-inferiorly at the vallecule Sylvii, which encircle the corpus callosum and optic thalamus. The two rings are separated from one another by a broken fissure, the *limbic fissure*, made up of the calloso-marginal (except its posterior end), the post-limbic sulcus, and the anterior part of the parieto-occipital and collateral fissures.

Central Ring.—The *gyrus fornicatus*³⁹ and *hippocampal convolution*⁴⁰ joined by the isthmus,⁴¹ at the posterior border of the corpus callosum, form the central ring. The former begins under the corpus callosum in the frontal lobe anterior to the fissure of Sylvius; and the latter terminates as uncus just behind that fissure in the temporal lobe. The central ring forms the chief part of the *limbic lobe*.

(38) Fissura collateralis.

(39) Gyrus cinguli.

(40) Gyrus hippocampi.

(41) Isthmus gyri fornicati.

The **Peripheral Ring**, from before backward, is composed of the *marginal convolution*,⁴² ending in the *paracentral lobule*⁴³; the *quadrate lobe*,⁴⁴ bounded antero-inferiorly by the postlimbic sulcus; the *cuneate lobe*⁴⁵; the *fifth temporal convolution* (infracalcarine, or lingual)⁴⁶; and the *fourth temporal*, or fusiform, *convolution*.⁴⁷ A slight sulcus (third temporal) separates the last from the third temporal gyrus on the convex surface. The quadrate and paracentral lobules and the posterior third or half of the marginal gyrus contain motor centers, for the opposite side of the body, the head, arm, trunk and leg centers being located in this order from before backward.

The *uncinate convolution* is the combined hippocampal and fifth temporal gyri.

Limbic Lobe.—It is composed of the following parts, viz.: (1) The gyrus fornicatus and hippocampal convolution; (2) the nerves of Lancisi and peduncle of the corpus callosum; and (3) the pillars and half the body of the fornix, one-half of the septum lucidum, and the fascia dentata. It is encircled by the limbic fissure. The limbic lobe probably contains the centers of smell and taste, which are localized in the hippocampal gyrus and uncus. Together with the olfactory lobe it constitutes the Rhinencephalon.

BASAL OR INFERIOR SURFACE.

The basal surface of the cerebrum⁴⁸ comprises the inferior surface of the hemispheres and of the inter-brain. It extends from the anterior poles of the hemispheres back to the fissure of Sylvius, laterally; and, in the median line, to the

(42) Gyrus frontalis superior.

(43) Lobulus paracentralis.

(44) Præcuneus.

(45) Cuneus.

(46) Gyrus lingualis.

(47) Gyrus fusiformis.

(48) Facies basalis cerebri.

posterior perforated lamina and crustæ of the mid-brain. The great longitudinal fissure splits it into lateral halves in front, separating the frontal lobes of the cerebrum from each other. The fissure extends back to the upturned part (*lamina terminalis*) of the lamina cinerea and to the corpus callosum. The length of the fissure is considerably less than one-third of the cerebral axis.

The medial structures of this surface, named from before backward, are as follows:

Lamina cinerea,
Optic chiasm, or optic commissure,
Tuber cinereum, and infundibulum,
Pituitary body,
Corpora albicantia.

These are often called interpeduncular structures. Constituting the *base of the inter-brain*, they form a continuous sheet beneath the third ventricle and optic thalami, which joins, antero-laterally, the anterior perforated lamina and the cortex of the internal orbital convolution.

The **Lamina Cinerea** is the most anterior of the medial structures. It is a thin lamina of ash-colored (*cinereum*) gray matter. Arching from behind forward over the superior surface of the optic commissure to which it is attached, it then turns upward and backward, the reflected part constituting the *lamina terminalis*, and meets the rostrum of the corpus callosum. In the angle of turning is the optic recess. The lamina terminalis, which is seen in the floor of the great longitudinal fissure, forms part of the anterior boundary of the third ventricle.

Tuber Cinereum.—At the posterior border of the optic commissure, the lamina is continuous with the tuber cinereum. Here the gray matter is thickened and centrally prom-

inent. The bulbous *infundibulum* projects downward from it to rest in the sella Turcica, where it forms the posterior lobe of the pituitary body. The upper half of the infundibulum is hollow (funnel-like). Its cavity forms the lowest part of the third ventricle. In man the bulb of the infundibulum is solid at maturity, though hollow in the embryo. It is composed largely of fibrous tissue, notwithstanding the fact that it is developed from the floor of the Thalamencephalon. From the base (superior end) of the infundibulum, the tuber cinereum extends in continuity with the anterior perforated lamina and hypothalamic gray matter on each side of it; and, behind, the corpora albicantia mark the boundary between it and the posterior perforated lamina of the mid-brain.

The lamina cinerea and tuber cinereum form the *inferior, or great, gray commissure* of the inter-brain.

The **Pituitary Body** (hypophysis) is composed of two lobes bound together by connective tissue. A sheet of dura mater (diaphragma sellæ) holds them in the pituitary fossa. The *anterior lobe*, the larger, is derived from the epithelium of the mouth cavity; and, in structure, resembles the thyroid gland. Its closed vesicles, lined with columnar epithelium (in part ciliated), contain a viscid jelly-like material (pituita), which suggested the name for the body. The anterior lobe is hollowed out on its posterior surface (kidney-shape) and receives the posterior lobe, the *infundibulum*, into the concavity. The pituitary body appears to have an inhibitive action on growth and is found diseased in acromegalia.

Corpora Albicantia.—Two white bodies, as large as a small pea, the corpora albicantia,⁴⁹ are situated one on either side of the median line, between the tuber cinereum and the pigmented gray matter of the posterior perforated lamina. Each

(49) Corpora mamillaria.

is formed by a loop in the anterior pillar of the fornix and is, therefore, composed of white fibers on the surface. There is gray matter in the interior, which may contain the ends of the fornix fibers and be the seat of origin of the ascending bundle, the bundle of Vicq d'Azyr.⁵⁰ The latter terminates in the optic thalamus. (Note 14, page 226.)

Immediately behind the corpora albicantia is the posterior perforated lamina. This is the exposed part of the substantia nigra of the mid-brain, perforated for the passage of the postero-median ganglionic arteries to the optic thalami and walls of the third ventricle. The pons and crustæ bound it behind. Issuing from the inner side of the crusta⁵¹ is the large motor oculi, or third cranial, nerve⁵²; and coursing over its surface from behind forward, is the smaller trochlear or fourth nerve.⁵³ The crustæ will be described with the mid-brain to which they belong.

The Optic Chiasm (*chiasma opticum*) remains to be described. It is situated medially beneath the lamina cinerea, in the optic groove of the sphenoid bone. The fibers of the optic nerves and tracts compose it. There are three sets of these fibers, namely, the *intercerebral*, *direct* and *decussating*. A fourth group of fibers, called interretinal and said to be commissural for the retina, has been hitherto described, but their existence is very doubtful. The intercerebral fibers are not found in the optic nerves, but form a commissure (Gudden's) for the internal geniculate bodies. The direct and decussating fibers run through tract and nerve and join the brain with the retina of the same and of the opposite side, respectively. In most vertebrates below mammals and

(50) Fasciculus thalamomamillaris.

(51) Basis pedunculi cerebri (sing.).

(52) Nervus oculomotorius.

(53) N. trochlearis.

in the mouse and guinea pig, the optic fibers all decussate in the chiasm. Normally in man and the higher mammals, the lateral half of each retina receives direct fibers and the medial half crossed fibers. The **optic nerves**⁵⁴ extend from the front of the commissure into the orbits through the optic foramina and terminate in the ganglionar cells of the retinae. The **optic tracts**⁵⁵ connect the commissure with the brain. Each tract winds outward and backward around the cerebral peduncle, and divides into an internal and an external root.⁵⁶ The roots wind around the optic thalamus and disappear (superficial origin) at the corresponding geniculate body. The fibers of the *external root* may be traced to the external geniculate body (80 per cent. Von Monokow), to the optic thalamus (nearly all the 20 per cent. remaining), and the rest to the anterior quadrigeminal body. The optic radiations of the internal capsule connect these centers with the medial occipital cortex. The *internal root* rises from the internal geniculate body and optic thalamus. The nuclei of the optic fibers are probably connected with the cerebellum by the fillet.

Notice now the *base of the hemispheres*, comprising the orbital and olfactory lobes.

Orbital Lobe.—The inferior surface of the frontal lobe, resting on the orbital plate of the frontal bone, is called the orbital lobe.⁵⁷ It is separated from its fellow by the great longitudinal fissure, and is bounded behind by the vallecula Sylvii and fissure of Sylvius, overlapped by the temporal lobe. More accurately, the posterior boundary is the anterior perforated space and the anterior fissure of Reil. The orbital lobe is concave transversely and is divided by a

(54) Nervi optici.

(55) Tractus optici.

(56) Radix medialis, lateralis.

(57) Lobus orbitalis.

Triradiate, or an H-shaped fissure,⁵⁸ directed fore and aft, into *internal, anterior* and *posterior orbital convolutions*.⁵⁹ The internal orbital convolution lies beside the great longitudinal fissure, and is continuous with the marginal convolution on the medial surface. Its anterior end joins the superior frontal convolution; its posterior, the trigone and area of Broca. The internal orbital convolution is subdivided by the sulcus olfactorius, which contains the olfactory tract; and that part of the convolution medial to the olfactory fissure is called the *gyrus rectus*. The anterior and posterior orbital convolutions may be traced to the convex cerebral surface in continuity with the middle and inferior frontal gyri.

If the anterior part of the temporal lobe be removed, the under surface of the island of Reil is brought into view. The sulcus limitans insulæ⁶⁰ bounds it on three sides (anterior, external and posterior), and separates it from the posterior orbital gyrus, in front; the frontal and fronto-parietal opercula, externally; and from the temporal lobe, behind. (See lobes of convex surface.)

Olfactory Lobe.—This term includes the remainder of the structures forming the inferior surface of the cerebrum. The reason for calling them the olfactory lobe⁶¹ is found in the lower animals; and in the human embryo, where it exists as a prominent hollow process of the cerebral hemisphere. A constriction (*fissura prima*) divides this diverticulum into the *anterior* and *posterior olfactory lobule*. In the human adult the anterior olfactory lobule is represented by the bulb, the tract, the trigone and the area of Broca. The anterior perforated lamina (or space) represents the posterior lobule.

*The Olfactory Bulb*⁶² is an ovoid mass of brain matter

(58) Fissuræ orbitales.

(59) Gyri orbitales.

(60) Sulcus circularis (Reil).

(61) Lobus olfactorius.

(62) Bulbus olfactorius.

about a half-inch long and one-sixth of an inch in diameter. It rests between the orbital lobe and the cribriform plate of the ethmoid bone. Below and on each side, it is composed of cortical gray matter (four layers) from which rise the twenty or thirty olfactory nerves.⁶³ The nerves, after entering the nasal fossa through the cribriform plate, are distributed to the Schneiderian membrane. The cells of Max Schultze in the Schneiderian membrane are the real cell-bodies of the olfactory nerve fibers (axones), hence the latter grow upward to the bulb. The fibers form the first layer of the bulb, *olfactory nerve layer*, and arborize about the dendrites of the large mitral cells to form the second layer,—the *stratum glomerulosum*. In the third layer of the gray matter are found great *mitral cell-bodies*, whose medullated axis-cylinders, or axones, form the white matter of the bulb; and, continued backward, constitute the olfactory tract.

Olfactory Tract.—The tract⁶⁴ is triangular in section, nearly an inch long and one line in width. It is concealed in the olfactory sulcus. At its base it divides into *external* and *internal root*,⁶⁵ which inclose between them the trigone into which some fibers may be traced, forming the *middle root*.⁶⁵ The external root courses backward and outward and terminates in the uncus at the anterior extremity of the hippocampal convolution. It crosses the anterior perforated space. The internal root bends sharply inward, toward the median line, and runs between the trigone and area of Broca. Its fibers turn into Broca's area and the gyrus fornicatus. Thus the two roots unite the opposite ends of the limbic lobe. From the bifurcation of the olfactory tract, a few fibers proceed into the trigone and frontal lobe.

(63) Nervi olfactorii.

(64) Tractus olfactorius.

(65) Striæ olfactoriæ, lateralis, medialis, intermedia.

The Trigone and Area of Broca.—The triangular portion of cortex between the inner and outer olfactory roots, called the trigone,⁶⁶ is continuous medially with Broca's area.⁶⁷ The internal root marks the boundary between them. Both are bounded behind by the fissura prima (transverse part), and the oblique part of the same fissure separates the area of Broca from the peduncle of the corpus callosum. The area of Broca is limited in front by a slight curved depression, the fissura serotina. On the medial surface, Broca's area joins the gyrus fornicatus.

Some of the fibers of the middle root of the olfactory tract probably pass through the anterior commissure; and, after piercing the opposite corpus striatum, terminate in the temporal lobe. They constitute the only olfactory decussation known.

The *Posterior Olfactory Lobule* is identical with the anterior perforated lamina.⁶⁸ It is separated from the trigone by the transverse fissura prima. Internally, it is in direct continuity with the lamina cinerea. The optic tract bounds it, postero-medially. Externally, it forms the floor of the vallecula Sylvii, where it is overlapped by the temporal lobe. Superiorly, it is continuous with the base of the corpus striatum. Coursing over the inner and outer border of the anterior perforated lamina are the callosal peduncle and external olfactory root, which converge and meet in the hippocampal convolution. The perforations of the lamina are for the antero-lateral ganglionic arteries.

SECTION II.—INTERIOR SURFACE OF THE CEREBRUM.

The boundaries of the cerebral ventricles constitute the interior surface of the cerebrum. Considering all the cere-

(66) Trigonum olfactorium.

(67) Area parolfactoria (Broca).

(68) Lamina perforata anterior.

bral cavities together, we notice that they occupy a wedge-like space. In shape the wedge is rectangular; and it stands, base upward, against the corpus callosum. Its beveled surfaces look toward the hemispheres. The blade is driven downward as if to split the cerebrum into lateral halves, the edge resting on the medial structures at the base of the brain. The space is inclosed laterally between the diverging internal capsules, which, within the hemispheres, decussate with the lateral extremities of the corpus callosum. The two structures most necessary to an understanding of the cerebral cavity, therefore, are the internal capsule¹ and corpus callosum.

Internal Capsule.—Looking at the base of the brain, we see two broad bands of nerve fibers, the crustæ,² issue from the front of the pons and, diverging upward and forward, enter the hemispheres beneath the optic tracts. These peduncular fibers are reinforced by additional fibers within the hemisphere. The fibers then radiate toward the cerebral cortex in the form of a hollow cone or funnel. *This funnel-like group of fibers is the internal capsule.* The bell of the funnel opens upward and outward and contains the lenticular nucleus; its solid spout, directed toward the pons and medially, is the crusta. Antero-inferiorly the fibers in the bell of the funnel diverge to opposite sides of the fissure of Sylvius and produce a break in its continuity, the *hiatus Sylvii*; otherwise the funnel is complete. As the internal capsule proceeds into the hemisphere, it impales the corpus striatum in such manner as to place the caudate nucleus and amygdala upon its circumference and to inclose within its walls (to capsulate) the lenticular nucleus. The lenticular nucleus is separated externally from the claustrum by a thin layer of fibers called the external capsule.³

(1) Capsula interna. (2) Bases peduncul. (3) Capsula externa.

Inferior Lamina.—The internal capsule⁴ is flattened from above downward. It has, therefore, a superior and an inferior lamina, which, posteriorly, are continuous with each other; but, anteriorly, are separated by the fissure of Sylvius. The inferior lamina (or inferior ramus, as seen in sagittal section) is a very thin layer and bevels down to a sharp edge anteriorly. In front it presents a free border. Its fibers pass outward beneath the lenticular nucleus and, after winding over the amygdala and the descending horn of the lateral ventricle, terminate in the parietal and temporal lobes.

Motor Fibers.—It contains part of the Temporo-pontal motor tract which extends from the temporal cortex to the nucleus of the pons.

Sensory Fibers.—And also the following sensory fibers are found in the inferior lamina, viz., the Ansa Peduncularis (common sensory) running from the thalamus to the somæsthetic cortex, and part of the Acoustic Radiations (special sensory) which extend from the internal geniculate body to the auditory cortex in the superior and transverse temporal gyri. In the angle between the descending horn and the body of the lateral ventricle, the inferior lamina joins the superior.

The Superior Lamina (or superior ramus) of the internal capsule contains most of the crusta. It is a thick and strong sheet of fibers. Often it is considered as identical with the "internal capsule," the inferior lamina being disregarded. The superior lamina ascends, fan-like, from the crusta to the lateral extremity of the corpus callosum, with which it intercrosses. It has a free border anteriorly, though imbedded in the corpus striatum. Upon its internal surface rest the optic thalamus, below and behind, and the caudate nucleus, above and farther forward. It thus separates the optic thala-

(4) Capsula interna.

mus and caudate nucleus from the lenticular nucleus. A bend near the middle of the superior lamina, called the *genu*, divides it into an *anterior*⁵ and a *posterior segment*,⁶ which tend slightly outward from the genu and form an angle with each other, open outward, of about 120 degrees.

Motor Fibers.—The *fibers of the genu* of the internal capsule are very largely motor and constitute the Pyramidal Tract. They may be traced from the Rolandic area of the cortex, through the genu of the internal capsule and middle three-fifths of the crusta, and on down into the spinal cord, where they end in ramifications about the cell-bodies in the anterior horn of gray matter. From these same spinal cell-bodies other fibers rise which constitute the motor part of the spinal nerves. Fibers of the pyramidal tract also end in the mid-brain pons and medulla: their end-tufts are related to the nuclear cell-bodies of motor cranial nerves. The *anterior segment* (*pars frontalis*) of the internal capsule contains a motor tract which extends from the prefrontal cortex through the inner one-fifth of the crusta to the nucleus of the pons and motor nuclei of cranial nerves (Flechsig). It is the Fronto-pontal Tract.⁷ In the *posterior segment* (*pars occipitalis*), behind the pyramidal tract, and also partly in the inferior lamina, is another motor tract, described by Flechsig. It rises from the temporal cortex and running beneath and behind the lenticular nucleus and through the outer one-fifth of the crusta, terminates in the nucleus of the pons, and also in nuclei of motor cranial nerves (Spitzka). That is the Temporo-pontal Tract.⁸

Sensory Fibers.—In both segments of the internal capsule there are common sensory fibers which rise chiefly in the

(5) *Pars frontalis.*

(6) *Pars occipitalis.*

(7) *Tractus cerebro-cortico-pontalis frontalis.*

(8) *T. cerebro-cortico-pontalis temporalis.*

optic thalamus and end in the somaesthetic cortex. They constitute the Cortical Fillet and convey ordinary sensations. In the *anterior segment* is the Anterior Stalk of the Thalamus which ends in somaesthetic cortex anterior to the pre-central fissure. The *posterior segment* contains the Ansa Lenticularis, which conveys ordinary sensations from the thalamus to the somaesthetic cortex chiefly in the upper Rolandic area. At the junction of the superior and inferior laminae of the internal capsule are the special sense fibers. The Optic Radiations⁹ and Auditory Radiations¹⁰ occupy the retro-lenticular part of the internal capsule. The former extend through it from the optic thalamus and external geniculate body to the cuneus; the latter rise in the internal geniculate body and end in the superior and transverse temporal convolutions. Many fibers of the internal capsule give off branches (collaterals) which pass through the corpus callosum to the opposite hemisphere; other fibers may be traced entire through the same course to the cortical cells of the opposite side. (For fibers of inferior lamina see page 26.)

The superior lamina of the internal capsule, proceeding outward and upward into the hemisphere, decussates with the corpus callosum and enters into the corona radiata. Together with the caudate nucleus, optic thalamus and tænia semicircularis, which lie on its internal surface, it forms the entire lateral boundary of the general cavity of the cerebrum. It thus determines the lateral part of the interior cerebral surface.

Corpus Callosum.—The entire roof of the cerebral cavity, representing the base of the wedge, is formed by the corpus callosum. A part of the anterior boundary is also formed by it. The corpus callosum is a thick sheet of fibers four

(9) Radiatio occipito-thalamica (Gratioletti).

(10) Radiatio temporothalamica.

inches broad, from before backward, which joins the hemispheres together. It constitutes the great white commissure, being composed chiefly of those medullated cortical axones which end in arborizations about cortical cells of the opposite hemisphere. It contains some fibers which, after passing through it, turn down in the internal capsule; and, also, collaterals from capsular and association fibers. The corpus callosum is placed nearer to the anterior than the posterior pole of the hemispheres. Separating the hemispheres above, it is seen in the bottom of the great longitudinal fissure. It is about an inch in transverse length.

The *upper surface* is concave from side to side; and divided, medially, by a longitudinal raphe. Transverse striæ are plainly visible. A few longitudinal striæ are also found running on either side of the raphe, the nerves of Lancisi¹¹; and others run near the lateral end of the callosum.¹¹ At the anterior and at the posterior border, the corpus callosum is bent downward (scroll like); hence, it is superiorly convex from before backward.

Its *inferior surface* is concave antero-posteriorly and near its posterior border is fused with the body of the fornix. Anterior to that fusion, it is joined to the fornix, along the median line, by the septum lucidum.

The *posterior border* is flexed downward about forty-five degrees. Giving passage to the fibers which join the middle and posterior parts of the hemispheres, the posterior border is the thickest part of the corpus callosum. It is on that account called the pad, or *splenium*.

The *anterior border* is bent downward and then backward, sweeping through 180 degrees of flexion. It terminates in a sharp edge (sharp point, seen in sagittal section) called the

(11) Striæ longitudinales mediales et laterales.

rostrum. The rostrum is continuous with the lamina terminalis at the base of the brain. It sends downward on either side a band of fibers, continuous with the nerves of Lancisi, which constitutes the peduncle of the corpus callosum. Each peduncle, after passing across the anterior perforated lamina, ends in the uncus of the hippocampal gyrus. The transverse fibers of the rostrum, in the hemisphere, form the floor of the anterior horn of the lateral ventricle.


Genu and Truncus.—The down-turned part of the corpus callosum is the genu. It joins the rostrum to the main body, the truncus. The genu forms part of the anterior boundary of the cerebral cavity; the truncus forms the roof. Fibers uniting the frontal lobes of the cerebrum pass through the genu, and in the hemisphere, bound the anterior horn of the lateral ventricles above and in front. Those fibers arching forward and forming the roof of the anterior horn are called the *forceps minor*. The *forceps major*, composed of fibers from the splenium which bend backward into the occipital lobe, lies in the roof and inner wall of posterior horn.

Each *lateral extremity* of the corpus callosum is overhung by the gyrus fornicatus, which covers the lateral longitudinal striæ (tæniæ tectæ).¹² Inclosed between the gyrus fornicatus and corpus callosum is the fissure-like ventricle of the callosum, which represents part of the fissura prima of the embryo. Under the splenium the fissura prima is continued in the hippocampal fissure.

The boundaries of the general cavity of the cerebrum may be given as follows:

Roof (base of wedge)—
Corpus callosum.

(12) Striæ longitudinales laterales.



Floor (edge of wedge)—

Tegmentum (Mid-brain),
 Posterior perforated lamina (Mid-brain),
 Tuber cinereum,
 Infundibulum,
 Lamina cinerea.

Lateral wall (beveled surface)—

Internal capsule,
 Caudate nucleus,
 Tænia semicircularis,
 Optic thalamus.

Anterior wall (border of wedge)—

Lamina terminalis,
 Anterior commissure,
 Genu of corpus callosum.

Posterior wall—

Corpora quadrigemina (Mid-brain) and
 Posterior commissure (with aqueduct of Sylvius beneath
 them),
 Pineal body,
 Great transverse fissure, containing the velum interpositum,
 Splenium (being bent down slightly behind the cavity).

The cerebral cavity thus bounded is subdivided by two partitions. The body of the fornix, together with the velum interpositum and roof epithelium of the third ventricle, forms a *horizontal partition* which divides the cavity into an upper and lower chamber. The superior chamber is divided into two lateral chambers, the lateral ventricles, by a *double vertical partition*, the septum lucidum. The inferior chamber is the third ventricle.

The **body of the fornix**¹³ is a triangular sheet of fibers, whose base is attached to the under surface of the splenium of the corpus callosum, and whose bifid apex extends forward to the rostrum and to the anterior commissure. Its lateral borders rest on the optic thalami, the velum interpositum alone intervening. And the narrow chamber between the optic thalami (the third ventricle) is separated from the broader, superior part of the cerebral cavity by the body of the fornix. The body of the fornix is produced by the approximation of two bundles of white fibers, one belonging to each hemisphere. These bundles are the pillars of the fornix.

The *posterior pillar*¹⁴ may be traced from the uncus (as corpus fimbriatum), and from the hippocampus major, its chief origin, upward through the descending horn and into the floor of the body of the lateral ventricle, where it unites with its fellow of the opposite side in forming the body of the fornix. At the apex of the body of the fornix, which is the anterior end, the bundles again separate and become the anterior pillars. The posterior pillars are united at the back part of the body of the fornix by a few transverse and oblique fibers which form the *lyre*, or *commissura hippocampi*. The commissure is best seen when the corpus callosum and fornix are viewed from below; its fibers connect each posterior pillar of the fornix with the optic thalamus, hippocampus major and uncus of the opposite side.

The *anterior pillars*,¹⁵ one on either side, pass down in front of the optic thalami, bounding the foramina of Monro; and then descend to the corpora albicantia, at the base of the brain. On the way down the pillars pass behind the anterior

(13) Corpus fornicis.

(14) Crus fornicis.

(15) Columnæ fornicis.

commissure, beyond which each pierces the inner part of the optic thalamus of the same side. The fibers of the anterior pillars probably terminate in the corpora albicantia, from which other fibers take their origin (the bundles of Vicq d'Azyr)¹⁶ and ascend to the anterior nuclei of the optic thalami.

The *upper surface* of the body of the fornix is convex from before backward. It forms the postero-median part of the floor of the lateral ventricle. Medially, it is joined to the corpus callosum by the septum lucidum.¹⁷

The *septum lucidum*, a double-walled sagittal partition, divides the superior chamber of the cerebral cavity into lateral halves, the *lateral ventricles*. The septum lucidum is crescentic in outline. Its convex border fits, medially, into the concave surface of the body, genu and rostrum of the corpus callosum. Its concave border rests upon the fornix. Each wall of the septum lucidum is a part of the original medial wall of the cerebral hemisphere and is, therefore, composed of cortical and medullary matter. The walls inclose a part of the great longitudinal fissure, called the *fifth ventricle*. That fissure, in embryo, was open down to the velum interpositum on the inter-brain; but its lower part becomes cut off and inclosed by the development of the fornix, anterior commissure and corpus callosum. The cerebral cavity is thus divided into four ventricles, viz.:

Two lateral (the ventricles of the hemispheres),

Fifth (the ventricle of the great longitudinal fissure), and

Third (ventricle of the inter-brain).

THE FIFTH VENTRICLE.

This is the fissural ventricle, or the ventricle of the sep-

(16) Fasciculus thalamo-mamillaris.

(17) Septum pellucidum.

tum.¹⁸ The fifth ventricle is a very narrow, antero-posterior cleft between the walls of the septum lucidum, with which it coincides in extent. It is situated within the concavity of the corpus callosum between the lateral ventricles, above and anterior to the third ventricle. Below and posteriorly it is bounded by the fornix. It is not a part of the embryonic brain cavity, but of the great longitudinal fissure. Therefore it does not communicate with any other ventricle, each of the others being a part of the cavity of the neural tube from which both brain and cord are developed. Instead of ependyma, which lines other ventricles, the lining of the fifth is modified pia mater. A lymph-like fluid fills it.

THE LATERAL VENTRICLE.

The hemispheres contain the largest of the six ventricles. Situated one on either side of the median line, the ventricles of the hemispheres are very naturally called the lateral ventricles.¹⁹ Each represents a branch of the cavity of the embryonic neural tube. In consequence, the lateral ventricles communicate with all others except the fifth. By the *foramen of Monro*, each directly communicates with the third ventricle; and through that, indirectly, with the fourth and sixth. The foramen of Monro²⁰ is situated between the front of the optic thalamus and the anterior pillar of the fornix. It extends between the anterior extremity of the third ventricle (the aulla) and the junction of the anterior horn with the body of the lateral ventricle. The lateral ventricles are lined with ependyma, which is a transparent membrane composed of two layers, viz., neuroglia, with a covering of columnar ciliated epithelial cells. Over the optic thalamus

(18) Cavum septi pellucidi.

(19) Ventriculi laterales.

(20) Foramen interventriculare (Monroi).

(the part seen in the lateral ventricle) and the choroid plexus, the neuroglial layer is absent.

The lateral ventricle may be studied best in four parts: the central part or body; the anterior, the middle or descending, and the posterior cornu.

The body of the lateral ventricle²¹ is the ventricle of the parietal lobe of the cerebrum. The following are its boundaries:

Roof—Corpus callosum.

Floor (from before, backward and inward)—

Caudate nucleus of the corpus striatum,

Tænia semicircularis,

Optic thalamus (covered by epithelium),

Choroid plexus (covered by epithelium),

Fornix.

Medial wall—Septum lucidum.

External wall—Internal capsule.

The corpus callosum forms a complete roof for the body of the lateral ventricle. The roof inclines upward and outward from the septum lucidum, the inner wall of the ventricle, to the superior lamina of the internal capsule, which forms its outer wall. The floor of the body of the ventricle is formed by the five parts, as named above, which will now be considered in the order given.

Corpus Striatum.—The striated body is the basal ganglion of the hemisphere. It is an ovoid mass of gray matter imbedded, for the most part, in the cerebral medulla; but it is continuous below with the anterior perforated lamina and extends above into the floor of the lateral ventricle. It measures two inches from before backward, an inch and a quarter transversely, and, from above downward, one inch and a half.

(21) *Ventriculus lateralis (pars centralis)*.

It is placed anterior and external to the optic thalamus. It is a reddish-gray body and the streaked appearance of the corpus striatum is due to the white capsular fibers which pierce it. The striated body is an important way-station in the motor conduction path and perhaps one of less importance in the sensory path. The internal capsule divides it into two nuclei, namely, the lenticular nucleus (extraventricular part),²² and the caudate nucleus, which is seen in the lateral ventricle. Anterior to the free borders of the superior and inferior capsular laminae, the two nuclei are united with each other, with the anterior perforated lamina and with the lower end of the claustrum.

The *Lenticular Nucleus* occupies the cone-like cavity of the internal capsule, by whose laminae it is separated from the ventricle. It is shorter fore and aft than the caudate nucleus. It resembles a biconvex lens with a somewhat thickened anterior border, when viewed in horizontal section. In transverse vertical section through its center, it is triangular in shape. The hypotenuse and base are formed, respectively, by the superior and inferior laminae of the internal capsule. The external capsule forms the perpendicular and separates the lenticular nucleus from the *claustrum*. The latter is a thin sheet of isolated gray matter, found just medial to the island of Reil. In extent and position, fore and aft, the island of Reil and lenticular nucleus coincide. The lenticular nucleus is subdivided by two white laminae, parallel with its external surface, into three zones. The outer zone, called the *putamen*, is deeply pigmented, and, like the caudate nucleus, is of a reddish-gray color; but the two inner zones, having less pigment, are of a pale yellowish tint. They form the *globus pallidus*.

The *Nucleus Caudatus* (the tailed nucleus) is a pear-shaped

(22) *Nucleus lentiformis*.

body of reddish-gray color, situated on the perimeter of the internal capsule. It is the intra-ventricular part of the striated body and forms a strip of the ventricular floor along the outer wall. The *bulb*²³ of the caudate nucleus is directed forward. It is seen in the anterior horn of the lateral ventricle. From the bulb the nucleus tapers as it proceeds backward through the body of the ventricle. Its *tail*, or *surcingle*,²⁴ turns downward in the roof of the middle horn, and ends in a considerable swelling, called the *amygdala*,²⁵ near the apex of the horn. The caudate nucleus is covered on its ventricular surface by ependyma. The opposite surface, resting against the fibers of the internal capsule, is irregular and serrated.

The **Tænia Semicircularis**²⁶ lies just internal to the nucleus caudatus. It is a band of white fibers traversing the floor of the body of the ventricle and the roof of its descending horn, but covered by the vein of the striate body. It may be said to rise from the amygdala. Ascending to the ventricle, it passes forward between the caudate nucleus and the optic thalamus to the foramen of Monro, where it divides into two bundles. One of them joins the anterior pillar of the fornix. The other, passing over the anterior commissure, terminates in front of it in a mass of cells between the septum lucidum and the nucleus caudatus. Perhaps some fibers terminate in the latter.

Optic Thalamus.²⁷—A fusiform part of this ganglion of the inter-brain is visible in the floor of the lateral ventricle, between the tænia semicircularis and the choroid plexus. It extends throughout the ventricular body from the foramen of Monro to the descending horn. A transparent layer of

(23) Caput nuclei caudati.

(26) Stria terminalis.

(24) Cauda nuclei caudati.

(27) Thalamus.

(25) Nucleus amygdalæ.

epithelium, extending from the fornix to the tænia semi-circularis, and representing the hemisphere wall, covers it. The optic thalamus will be described with the third ventricle and inter-brain.

The **Choroid Plexus**²⁸ of the lateral ventricle is the vascular border of the velum interpositum. It projects, laterally, from beneath the fornix and its posterior pillar into the floor of the body of the ventricle and the inner wall of the descending horn. The epithelium, above mentioned, invests it; and it borders the fornix like a ruffle. It is called choroid plexus (*chorion*, a membrane) because it is membrane-like. The anterior choroid artery²⁹ from the internal carotid and the postero-lateral choroid, a branch of the posterior cerebral, supply the plexus. The former pierces the temporal lobe and enters the apex of the descending horn of the ventricle; the latter passes in through the great transverse and choroid fissures, following the velum interpositum. The choroid vein carries the blood away. At the foramen of Monro, it is joined by the vein of the striated body and forms the vein of Galen. The vein of Galen³⁰ courses backward in the velum interpositum and unites with its fellow of the opposite side; and then the common vein of Galen,³¹ uniting with the inferior longitudinal sinus, forms the straight sinus.

The floor of the body of the lateral ventricle is completed by the superior surface of the fornix.

The cornua³² of the lateral ventricle are three in number.

The **anterior cornu**³³ projects from the body of the ventricle forward and outward around the bulb of the caudate

(28) Plexus choroideus ventriculi lateralis.

(29) Arteria choroidea anterior.

(30) Vena cerebri interna.

(31) V. cerebri magna (Galen).

(32) Cornua ventriculi lateralls.

(33) Cornu anterius ventriculi lateralis.

nucleus. It is the ventricle of the frontal lobe and is deep and narrow. Its boundaries are as follows:

Roof—Corpus callosum (forceps minor).

Floor—Rostrum.

Anterior wall—Genu.

Inner wall—Septum lucidum.

Outer wall—Caudate nucleus.

The **posterior cornu**³⁴ is directed backward and downward in a curve concave inward, from the ventricular body into the occipital lobe. Its extremity bends medially toward the calcarine fissure, with which the horn is parallel. That fissure produces the ridge along the inner wall called the *hippocampus minor*.³⁵ The posterior horn is roofed over by fibers from the splenium of the corpus callosum, which turn down outside the horn and also form part of the external boundary. A well-marked bundle of fibers from the splenium, *forceps major*, is found passing along the medial border of the roof into the occipital lobe. The white matter of the occipital lobe forms the remaining boundaries. The anterior extremity of the posterior cornu is continuous, laterally, with the beginning of the descending horn. At the junction of the two is a triangular area, the *trigonum ventriculi*.

The **middle, or descending, cornu**³⁶ is the ventricle of the temporal lobe. Its course is crescentic as it follows the perimeter of the internal capsule. It first runs outward and backward from the body of the ventricle, then it turns downward, and finally it proceeds forward and inward to within an inch of the apex of the temporal lobe. In horizontal section just below the general cavity of the ventricle, the descending horn is triangular. In that position it has a *posterior wall or floor*, an *inner wall*, and a curved *antero-external*

(34) Cornu posterius ventriculi lateralis.

(35) Calcar avis.

(36) Cornu inferius ventriculi lateralis.

wall or roof, which is continuous above with the outer wall and floor of the body of the ventricle.

The parts found in the walls of the descending cornu may be enumerated as follows:

Roof (or antero-external wall)—

Pulvinar of optic thalamus (covered by epithelium),
 Inferior lamina of internal capsule, partially covered
 by surcingle and amygdala of caudate nucleus, and
 tænia semicircularis.

Floor (or posterior wall)—

Eminentia collateralis,
 Hippocampus major and pes hippocampi,
 Posterior pillar of fornix and corpus fimbriatum.

Inner wall (medial)—

Epithelium (of hemisphere wall) covering,
 Pulvinar,
 Choroid plexus,
 Choroid fissure, and
 Dentate fascia.

The structures in the roof of the descending horn have been sufficiently described. They are easily understood when it is recalled that the roof of the horn is continuous with the outer wall and floor of the ventricle; the *internal capsule* (inferior lamina), the *surcingle* and *amygdala* and the *taenia semicircularis* form it.

Beginning at the *trigonum ventriculi*³⁷ and extending along the outer border of the floor to the end of the descending horn is a low ridge caused by the collateral fissure. It is the *eminentia collateralis*. In front of it and internal to it is a prominent ridge, the *hippocampus major*,³⁸ which en-

(37) *Trigonum collaterale*.

(38) *Hippocampus*.

larges downward to a lobulated extremity, called the *pes hippocampi*.³⁹ The ridge is due to the infolding of the floor over the hippocampal fissure on the medial surface of the cerebrum. The ventricular surface of the hippocampus major is formed by a lamina of white matter, the alveus, but the deeper part is cortical matter composed almost entirely of pyramidal cell-bodies. The *posterior pillar of the fornix* rests in the concavity of the hippocampus, where most of its fibers originate, but a small bundle of them, the *corpus fimbriatum*, passes beyond it to its origin in the uncus.

A *layer of epithelium*, representing the hemisphere wall, forms the floor of the choroid fissure and the **whole inner wall** of the descending cornu. It covers the cushion-like projection (the pulvinar) of the optic thalamus, which forms a small part of both roof and inner wall. Behind and superiorly, it is attached to the pillar of the fornix, from which it extends forward and outward to the tænia semicircularis. The epithelium covers the *choroid fissure*, which otherwise would form a communication between the horn and the exterior. Through the choroid fissure the border of the velum interpositum projects toward the ventricle, and, pushing the epithelium before it into the horn, forms the *choroid plexus*. Within the fissure there is a serrated free border of cortex called the *dentate fascia*.⁴⁰ The dentate fascia folds medially in front of the hippocampal fissure and with the hippocampus major forms an S-shaped fold of the cortex. The S-shape is perfect in the left hemisphere, when viewed with the frontal lobes upward and the convex surface of the brain toward the spectator. The top of the letter is the fascia dentata; the superior curve is the hippocampus, produced by

(39) *Digitationes hippocampi*.

(40) *Fascia dentata hippocampi*.

the hippocampal fissure, the upper concavity; the lower concavity, open toward the ventricle, is the groove between the hippocampus major and the eminentia collateralis.

THE THIRD VENTRICLE AND INTER-BRAIN.

The **inter-brain**⁴¹ is medial in position. It is situated beneath the fornix and the layer of epithelium extending from the border of the fornix to the tænia semicircularis. The velum interpositum only intervenes between them. Laterally, it is bounded by the superior laminae of the internal capsules. The ventricle of the inter-brain is the third⁴² in number. The **third ventricle**, therefore, is medially located; and is at a lower level than the ventricles of the hemispheres. Through the foramina of Monro, its anterior part (the aula) communicates with each lateral ventricle, and the aqueduct of Sylvius connects it, behind, with the fourth ventricle. The third ventricle is fissure-like. It is a narrow, vertical cleft about an inch in length from before backward and a quarter of an inch broad at its widest part. It separates the optic thalami, and extends almost to the inferior surface of the cerebrum. The *roof* follows the curve of the fornix and arches from the posterior commissure forward to the anterior commissure. The *anterior wall* extends from the upper border of the anterior commissure down to the optic recess, at the angle of flexion in the lamina cinerea. The *floor* describes two arches, convex toward the ventricle. The first arch, very convex and short, stretches between the optic recess and the infundibulum, in which the floor reaches its lowest point. The distance from the infundibulum to the anterior orifice of the aqueduct of Sylvius is spanned by the

(41) Diencephalon.

(42) Ventriculus tertius.

second arch. It is long and rather flat. Its posterior extremity is but a sixteenth of an inch below the posterior commissure; the anterior orifice of the Sylvian aqueduct separates them. The ventricle is thus contracted behind to the size of the Sylvian aqueduct, with which it is continuous. The *lateral walls* are close together throughout. At one point near the middle they come together and are joined by the gray, or middle, commissure.⁴³ Antero-superiorly, the lateral wall is perforated by the foramen of Monro.⁴⁴ That foramen constitutes the slight separation between the front of the optic thalamus and the anterior pillar of the fornix. It opens into the lateral ventricle at the junction of the anterior horn with the body. The ependyma which lines the third ventricle is continuous through the foramen of Monro with the lining of the lateral ventricle. But one layer of the ependyma is present in the roof of the ventricle; that is the epithelial layer. The third ventricle, like all true ventricles, is occupied by cerebro-spinal fluid.

The following are the boundaries of the third ventricle:

Roof—

Posterior commissure and commissura habenularum,
Roof epithelium and pineal body,
Velum interpositum and choroid plexuses,
Fornix.

Anterior wall—

Epithelium, covering
Pillars of fornix and anterior commissure.
Lamina terminalis.

Floor—

Lamina cinerea and optic commissure,

(43) *Massa intermedia.*

(44) *Foramen interventriculare.*

Tuber cinereum and infundibulum,
 Corpora albicantia,
 Posterior perforated lamina (of mid-brain),
 Tegmentum (of mid-brain).

Posteriorly—

Ventricle is continuous with aqueduct of Sylvius.

Lateral walls—

Optic thalamus,
 Anterior pillar of the fornix, and
 Foramen of Monro between them.

Roof.—A band of white fibers passes across the back part of the third ventricle and supports the posterior end of the roof epithelium. That band is the **posterior commissure**.⁴⁵ It crosses immediately in front of the corpora quadrigemina. Beneath it is the anterior orifice of the aqueduct of Sylvius. The pineal body is above and behind it, and the commissure is inclosed between the ventral and dorsal pineal laminae. The posterior commissure stretches from one optic thalamus to the other; but most of its fibers terminate in the parieto-occipital region. It contains four sets of fibers, viz.: (1) Commissural fibers between the optic thalami (?); (2) the upper decussation of the posterior longitudinal bundles; (3) some fibers from the pineal stria, derived from the optic tract near the external geniculate body, which cross to the opposite nucleus (upper part) of the motor oculi (Darkschewitsch); and (4) fibers from the fillet crossing to the opposite hemisphere.

The **roof epithelium** of the third ventricle stretches from the posterior commissure to the anterior commissure and laterally, is attached to the upper internal border of the optic thalamus. It is the superficial layer of the ependyma;

(45) Commissura posterior.

but it is, here, the only adult representative of the roof of the neural tube (the thalamencephalon). Anteriorly, this same epithelium investing the anterior commissure and pillars of the fornix, is the only representative of the neural wall (prosencephalon) down to the lamina terminalis. The roof epithelium presents two longitudinal folds suspended in the ventricle. The lower layer of the velum interpositum, constituting the *superior choroid tela*,⁴⁷ invests the roof epithelium of the third ventricle superiorly; and, dipping down into the longitudinal folds, that inferior layer of the velum interpositum forms the *choroid plexuses*⁴⁸ of the third ventricle, which are continuous with those of the lateral ventricles through the foramina of Monro. At the back part in the middle line, there is a pouch-like evagination of the roof epithelium in the embryo, which develops into the pineal body.

Pineal Body, or Conarium.—It is a cone-shaped body,⁴⁹ a quarter of an inch high and one-sixth of an inch in diameter, joined to the roof of the third ventricle by a flattened stalk or peduncle.⁵⁰ It is also called the *epiphysis*. The pineal body is situated in the floor of the great transverse fissure, directly below the splenium of the corpus callosum, and rests between the superior quadrigeminal bodies on the dorsal surface of the mid-brain. It is closely invested by pia mater. The pineal stalk splits into a dorsal and a ventral lamina. The ventral lamina, passing behind the posterior commissure, disappears beneath it; but the dorsal stretches forward over the commissure in continuity with the roof epithelium. The borders of the dorsal lamina are thick-

(47) *Tela choroidea ventriculi tertii.*

(48) *Plexus choroideus ventriculi tertii.*

(49) *Corpus pineale.*

(50) *Habenula.*

ened, pineal striæ,⁵¹ and contain fibers which are derived from the anterior pillar of the fornix. (Note 1, add., P. 225.) The pineal striæ also contain optic fibers which pass through the posterior commissure to the nucleus of the oculomotor nerve.

The interior of the pineal body is made up of closed follicles surrounded by ingrowths of connective tissue. The follicles are filled with epithelial cells mixed with calcareous matter, the brain-sand (*acervulus cerebri*). Calcareous deposits are found also on the pineal stalk and along the choroid plexuses. The function of the pineal body is unknown. It is supposed to represent a cyclopiian eye. In the *Hatteria*, a New Zealand lizard, it projects through the parietal foramen and presents an imperfect lens and retina and, in its long stalk, nerve fibers.

The *velum interpositum*, a double triangular fold of pia mater, is interposed between the epithelium of the third ventricle and the medial part of the floor of the two lateral ventricles. Its apex is just behind the anterior commissure, and its base, directed backward, is continuous, by the upper layer, with the pia of the occipital lobes; and, by the inferior layer, it is continuous with the pia on the dorsal surface of the mid-brain and cerebellum. Each border constitutes the *choroid plexus of the lateral ventricle*, and is seen (through the epithelium) in the floor of its body and along the inner wall of its descending horn. The inferior lamina of the *velum interpositum* forms the *superior choroid tela*;⁵² medially it invests the roof epithelium of the third ventricle, and, laterally, it covers the medial half of the upper surface of each optic thalamus. It forms the two *choroid plexuses of*

(51) *Stria medullaris thalami*.

(52) *Tela choroidea ventriculi tertii*.

the third ventricle,⁵³ which depend from its medial portion. Between the inferior and superior lamina is enclosed some arachnoid tissue; and the veins of Galen pass back through it from the foramina of Monro to the tentorium cerebelli, where they join with the inferior longitudinal sinus in forming the straight sinus.

Anterior Wall.—The **anterior commissure**⁵⁴ is a very distinct round bundle of white fibers about an eighth of an inch in diameter. It is seen in the anterior wall of the third ventricle supporting the roof epithelium. The epithelium there bends down between the pillars of the fornix and invests the ventricular surface of the commissure. The anterior commissure rests upon the upper extremity of the lamina terminalis, between the pillars of the fornix, behind, and the rostrum of the corpus callosum, in front. With the last two structures it is developed from the hemisphere vesicles. It is the most important connecting link between the hemispheres in vertebrates without a corpus callosum (all below mammals). Bending shortly backward the anterior commissure pierces the inferior part of the globus pallidus and then radiates toward the cortex, some of its fibers entering the external capsule. It contains two groups of fibers: (1) the anterior group,⁵⁵ which is the commissure of the rhinencephalon, called the *pars olfactoria*; and (2) the posterior group,⁵⁶ the *pars occipito-temporalis*. The former connects the limbic lobes and joins each to the opposite olfactory tract; the latter ends in the inferior part of the occipital and in the temporal cortex. In man it is larger than the *pars olfactoria*. The upturned part of the lamina cinerea, called

(53) Plexus choroideus ventriculi tertii.

(54) Commissura anterior (cerebri).

(55) Pars anterior.

(56) Pars posterior.

lamina terminalis, extends from the anterior commissure and rostrum of the corpus callosum down to the flexure which incloses the optic recess; it completes the anterior boundary of the third ventricle.

The **floor** is very narrow. It is formed by the interpeduncular structures plus the tegmentum, namely: lamina cinerea (with optic chiasma below it), tuber cinereum and infundibulum, corpora albicantia, posterior perforated lamina and the tegmentum. The last two are the middle and dorsal portions of the mid-brain; the others belong to the inter-brain, and all extend laterally beneath the optic thalami. The corpora albicantia, located on either side of the median line, may be excepted from the ventricular floor, as they are directly beneath the thalami (see base of cerebrum).

The third ventricle has its **lateral wall** formed by the optic thalamus and the anterior pillar of the fornix. The pillar of the fornix, diverging from its fellow, proceeds downward and backward to the corpus albicans through the medial part of the thalamus. In the ventricle it is covered by the ependymal epithelium. It bounds the foramen of Monro in front.

Optic Thalamus.—It is the great ganglion of the inter-brain. The thalamus (*thalamos*, a bed)⁵⁷ is an important sensory way-station. In it or in the hypothalamic nuclei almost every impulse of general sensation, in its journey to the cerebral cortex, is transferred to a higher neurone. The third ventricle separates the thalami from each other, except at the mid-point where they are joined by the middle (gray) commissure.⁵⁸ The thalamus is situated behind and medial to the corpus striatum, and projects backward over the superior surface of the mid-brain. Laterally, it rests against the superior lamina of the internal capsule, which

(57) Thalamus.

(58) Massa intermedia.

separates it from the lenticular nucleus. The optic thalamus is shaped like an egg, with the small end directed forward. It has an anterior and a posterior extremity and four surfaces: Superior, inferior, internal and external.

Extremities.—The anterior extremity of the thalamus is lost in a large group of fibers (anterior stalk) which, running through the anterior segment of the internal capsule, ends in the gyrus fornicatus and the frontal lobe of the cerebrum.

The posterior end presents a large pillow-like prominence, the pulvinar; and beneath it is a smaller swelling, which forms the lowest point of the thalamus, the external geniculate body. The internal geniculate body (of the mid-brain) is also continuous with this extremity internal to the pulvinar. The two geniculate bodies constitute the metathalamus.

Surfaces.—The internal, or medial, surface of the optic thalamus forms the lateral wall of the third ventricle. It is joined to the internal surface of the opposite thalamus by the middle commissure. Both this and the superior surface are composed of a thin lamina of longitudinal white fibers, the stratum zonale.

The superior surface of the thalamus is divided by an oblique groove, the choroid groove, corresponding in position to the border of the fornix, into two areas. The area inside the groove is covered by the velum interpositum and the fornix. Internally, it is bounded by the pineal stria and attachment of the roof epithelium. Posteriorly, next the stria, is a triangular depression bounded, behind, by a transverse groove in front of the corpora quadrigemina, and by a slight groove, the sulcus habenulæ, externally. That de-

pressed surface is called the trigone of the habenula.⁵⁹ Beneath the triangle is one of the thalamic nuclei. The outer area is seen in the floor of the lateral ventricle. It presents an anterior elevation, the anterior tubercle,⁶⁰ beneath which is the anterior nucleus of the thalamus. A sheet of epithelium, extending from the fornix to the tænia semicircularis, covers this outer area and separates it from the ventricular cavity.

A special lamina of fibers, the external medullary lamina, derived from the fillet, forms the external surface of the optic thalamus and rests upon the superior lamina of the internal capsule.

The inferior surface blends with the superior surface of the tegmentum and substantia nigra, and forms the laminae and nuclei of the tegmental region. (See below.)

Hypothalamic tegmental region⁶¹ is composed of three layers: (1) Stratum dorsale next the optic thalamus; (2) Zona incerta, the middle; and (3) the nucleus of Luys, or hypothalamic body, the inferior. The nucleus of Luys⁶² is but the terminal part of the substantia nigra. The reticular formation of the tegmentum, continuing beneath the optic thalamus, forms the zona incerta. The stratum dorsale is made up as follows: (a) Fibers from the posterior longitudinal bundle (Meynert); (b) the superior peduncle of cerebellum (Forel), in which is the upper end of the red nucleus⁶³ of the tegmentum; and (c) the fillet.⁶⁴

The **external geniculate body** (geniculum, a little knot or

(59) Trigonum habenulæ.

(60) Tuberculum anterius thalami.

(61) Hypothalamus.

(62) Nucleus hypothalamicus.

(63) Nucleus ruber.

(64) Lemniscus.

knee)⁶⁵ forms a slight swelling at the lowest point of the optic thalamus. It marks the apparent end of the outer root of the optic tract and is the terminal nucleus of eighty per cent of its fibers. It is joined to the superior quadrigeminal body by the superior brachium. In appearance it is dark colored and laminated; its gray matter, which contains pigmented multipolar cell-bodies, is divided into thick layers by thin laminae of fibers from the optic tract. The processes of the multipolar cell-bodies help to form the optic radiations.

The **internal geniculate body**⁶⁶ belongs to the mid-brain. It is placed at the end of the inner root, as the external geniculate is at the end of the outer root, of the optic tract. It rises up from the groove between the optic thalamus and corpora quadrigemina, and is joined to the inferior quadrigeminal body by the inferior brachium. The superior brachium sweeps around it in front, passing between it and the external geniculate body. The internal geniculate body is gray in color and is not laminated. Its cell-bodies are small, and fusiform in shape. They perhaps give origin to the intercerebral fibers (Gudden) of the optic tract and to a large number of the acoustic radiations.

(65) *Corpus geniculatum laterale.*

(66) *Corpus geniculatum mediale.*

CHAPTER III.

MID-BRAIN.

The brain just behind the cerebrum is the mid-brain.¹ It is the connecting link between the inter-brain and the hemispheres, in front, and the pons, behind. This has suggested the name isthmus, sometimes applied to it, though isthmus is more specifically applied to the constriction behind the corpora quadrigemina. It is developed from the middle of the five brain vesicles, the mesencephalon. The cerebral hemispheres almost conceal it from view; they overhang it dorsally, and the temporal lobes, inclosing it between them, bend medially and cover part of its ventral surface. Only the median part of the ventral surface is visible in the complete brain. The form of the mid-brain resembles a flattened cylinder. Its axis, a half inch long, is pointed upward and forward, and its long diameter, which varies from an inch to an inch and a quarter in length, is directed transversely.

SURFACES.

The mid-brain has four surfaces, viz., the ventral and dorsal, which are free, and the superior and inferior, representing the ends of the cylinder, which are attached. The two latter are parallel with each other and are formed by section.

The **superior surface**, sloping downward and forward, meets the ventral surface at an acute angle. Its inclination is that of the back part of the floor of the third ventricle.

(1) Isthmus rhombencephali and mesencephalon.

External to the floor of the ventricle, it is attached to the optic thalami and internal capsules. The blending of it with the thalami forms the structures of the hypothalamic tegmental regions, and the continuations of the extreme lateral portions, the crustæ, constitute the superior laminae of the internal capsules of the hemispheres. In the median line behind the third ventricle it is attached to the posterior commissure.

The **inferior surface** joins the upper surface of the pons. It is a little narrower than the superior surface. It is about one inch broad and measures three-quarters of an inch dorso-ventrally.

The **ventral surface** of the mid-brain looks downward and forward. It is deeply grooved longitudinally by the *median sulcus*,² and is slightly concave from above downward. It is separated on either side from the dorsal surface by the *sulcus lateralis*.³ Though partially concealed by the temporal lobes of the cerebrum, the ventral surface is unattached. It is formed by a prominent band, the *crusta*,⁴ at either side; and by a median structure, the *posterior perforated lamina*,⁵ which is inclosed between the two crustæ. The posterior perforated lamina forms the floor of the median sulcus. The inner border of the crusta is free and overhangs the perforated lamina slightly. Thus is formed the *oculomotor groove*⁶ between the crusta and perforated lamina, whence the third cranial nerve takes its superficial origin. The fourth nerve courses forward over the ventral surface, but is not attached to it.

- (2) Fossa interpeduncularis.
- (3) Sulcus lateralis mesencephali.
- (4) Basis pedunculi.
- (5) Substantia perforata posterior.
- (6) Sulcus nervi oculomotorii.

The **dorsal surface** of the mid-brain, though free, is entirely concealed by the cerebral hemispheres. It forms part of the floor of the great transverse fissure and is covered by pia mater. The *lateral sulcus* bounds it on each side. From the sulcus lateralis it elevates abruptly toward the median line, where it presents a longitudinal groove. This produces two ridges which are subdivided by a transverse groove into the four eminences (colliculi) of the *corpora quadrigemina*. On either side, anterior and a little external to the quadrigeminal bodies, is the *internal geniculate body*. There are thus presented six eminences on the dorsal surface of the mid-brain. The entire dorsal surface is formed by the tegmentum.

INTERIOR.

The mid-brain is made up of three great divisions, namely:

(1) The ventral part, composed of the two crustæ; (2) the substantia nigra, which is the middle part; and (3) the dorsal part, called the tegmentum, composed of lateral halves united by a raphe.

The crustæ⁷ are two rounded bands of white fibers, limited by the medial and the lateral sulci, which form the ventral part of the mid-brain. They are in contact at the front of the pons, from which they diverge upward and forward and pierce the inferior surface of the cerebrum beneath the optic tracts. Entering the cerebrum just external to the optic thalamus, the fibers of each crusta spread out, fan-like, in the internal capsule. Excepting the medial fillet, a part of which enters the inferior lamina, and a part of the temporal cerebro-corticopontal tract which takes the same course, the crusta enters only into the superior lamina of that inner capsule.

(7) Basis pedunculi (sing.)

The *deep portion* of each crusta is occupied by the intermediate bundle, whose fibers arise in the corpus striatum and terminate in the nucleus pontis (Flechsig). The *superficial portion* should be studied in three parts:

(1) The *outer fifth* of each crusta, the temporal cerebro-corticopontal tract, is composed of efferent fibers which rise in the temporal cortex, in the superior, middle and inferior gyri (Dejerine). Proceeding through the inferior lamina and the occipital segment of the superior lamina of the internal capsule, and through the lateral part of the crusta, they terminate chiefly in the nucleus of the pons; a few end in motor nuclei of cranial nerves (Spitzka). The fibers are probably interrupted in the thalamus or lenticular nucleus. They form a segment of the indirect motor path. These fibers are medullated later than the pyramidal tract (Flechsig).

(2) The *middle three-fifths* of the crusta is for the most part motor. It is called the pyramidal tract.⁸ Its fibers rise in the Rolandic area of the cerebral cortex; they form the genu and anterior two-thirds of the posterior segment of the internal capsule, the middle three-fifths of the crusta, the ventral longitudinal fibers of the pons, and the pyramid of the medulla. Below the medulla they are continued in the direct and crossed pyramidal tracts of the spinal cord. Those fibers of the pyramidal tract which innervate the muscles of speech and of the face run through the genu of the internal capsule and constitute the medial portion of the tract. Immediately behind the face fibers, in the capsula interna, and external to them, in the tract, are fibers which innervate the muscles of the arm. Still behind these, in the internal capsule, and external to them, in the pyramidal tract of the

(8) Fasciculus longitudinalis pyramidalis.

crusta, are fibers for the innervation of the trunk and leg muscles, the leg fibers being most posterior and most external. Intermingled with the pyramidal fibers are a few fibers from the cerebellum. The cerebellar fibers, upon reaching the pons through the middle peduncle of the cerebellum, ascend with the ventral longitudinal fibers of the pons and are sparsely scattered throughout the crusta.

(3) The *inner fifth* of the crusta is composed of the medial fillet and the frontal cerebro-cortico-pontal tract. The origin of the latter is probably in the pre-Rolandic cortex, at the anterior end of the first frontal and at the feet of the second and third frontal gyri; and, perhaps, in the middle of the gyrus fornicatus. It is motor. This motor tract is contained in the anterior segment of the upper lamina of the internal capsule. Its termination is in the nucleus of the pons and in the motor nuclei of cranial nerves (Flechsig). It constitutes a stage of an indirect motor path, like the fibers of the outer fifth of the crusta, and the indirect path is continued to the opposite half of the cerebellum by neurones whose cell-bodies are in the nucleus pontis (Flechsig). The medial fillet⁹ (sensory) exists as a distinct bundle in this part of the crusta. Superiorly, it enters the hypothalamic region, and ends in the ventro-lateral nucleus of the optic thalamus. A few of its fibers join the ansæ lenticularis et peduncularis and run uninterrupted to the cortex; they form a part of the inferior lamina of the internal capsule, and then, of the medullary laminae of the lenticular nucleus. The medial fillet is the afferent cerebral tract of the spinal and of all the cranial nerves with the exception of the cochlear division of the auditory.

The Substantia Nigra.—The central part of the mid-brain

(9) Lemniscus medialis.

is a sheet of pigmented gray matter. The substantia nigra is visible at the base of the brain between the crustæ, where it is called the *posterior perforated lamina*,¹⁰ and its margin comes to the surface in each lateral sulcus. Antero-posteriorly, it extends from the pons forward to the corpora albicantia and nucleus of Luys. Dorsal to it is the tegmentum. Transversely, the substantia nigra is convex downward, but it is slightly concave longitudinally. The third nerve pierces it and comes out through the oculomotor groove. It contains small pigmented multipolar cell-bodies, some of which constitute a relay for certain fibers of the medial fillet (Barker). There is an aggregation of these cells located medially just in front of the pons, the *interpeduncular ganglion*.¹¹ According to Forel, this ganglion is connected by a bundle of fibers, the fasciculus retroflexus, with the nucleus habenulæ of the optic thalamus. The antero-lateral portion of the substantia nigra forms the *nucleus of Luys*, or *nucleus hypothalamicus*, on either side. The nucleus Luysi lies ventro-lateral to the red nucleus,¹² and is separated from it by the zona incerta.

The Tegmentum.—The dorsal division of the mid-brain, being the largest and covering the other two divisions, is in consequence called the tegmentum (the cover). It fits ventrally into the concavity of the substantia nigra, and is bounded by the lateral sulcus on each side. Dorsally, it presents the internal geniculate bodies and the corpora quadrigemina. The tegmentum is very thick medially. In transverse section it has a pentagonal form, the curve of the substantia nigra representing two sides. Superiorly, the anterior extremity of the tegmentum blends with the optic

(10) Substantia perforata posterior.

(11) Ganglion interpedunculare.

(12) Nucleus ruber.

thalami in the hypothalamic regions. The tegmentum is continuous with the pons behind (caudalward). It contains the cavity of the mid-brain, the aqueductus Sylvii.¹³

The Aqueduct of Sylvius.—The aqueduct is a very slender canal connecting the third and fourth ventricles. So it is the “*iter a tertia ad quartum ventriculum.*” It is situated near the dorsal surface of the tegmentum, directly beneath the sulcus longitudinalis. It is a half-inch long. In shape it is V-like, above; elliptical, in the middle, with a vertical major axis; and T-form, below, where it joins the fourth ventricle. Its height varies between a sixteenth and an eighth of an inch. Like other ventricles, it is lined with ependyma. A layer of gray matter, thickest on the sides and floor, surrounds the aqueduct of Sylvius. It is continuous with the gray matter of the fourth ventricle. In it are the nuclei of the oculomotor (third) and the trochlear (fourth) cranial nerves.

Nuclei of the Oculomotor and Trochlear Nerves.—Both nuclei extend the entire length of the aqueduct, and the oculomotor¹⁴ is prolonged into the wall of the third ventricle, where it receives a bundle of fibers from the opposite pineal stria and optic tract. The nuclei are composed of several elongated masses of gray matter, which contain cell-bodies of various sizes. They lie side by side in each half of the floor of the aqueduct, and are associated with the optic tract (external root) by fibers in the posterior commissure and by association neurones in the superior quadrigeminal bodies. By this connection certain reflex ocular movement, accommodation for distance and pupillary contraction are accomplished. The oculomotor nucleus is next the median line and behind unites with its fellow across it. For the most part

(13) Aqueductus cerebri.

(14) Nucleus oculomotorius.

the third nerve, motor oculi, rises from the nucleus of the same side; but it also contains crossed fibers from the opposite nucleus and from the posterior longitudinal bundle of the opposite side. Some of the last are derived from the nucleus of the abducent (sixth) nerve and, after crossing to the third nerve, supply the internal rectus of one eyeball; while the sixth, rising from the same nucleus, supplies the external rectus of the other eye. Thus is *conjugate deviation* accounted for. The third nerve passes down to the oculomotor groove through tegmentum and substantia nigra. The root fibers of the fourth nerve, trochlear (patheticus)¹⁵ proceed dorsally and caudalward from the nucleus. They decussate with the fibers from the opposite nucleus in the superior medullary velum (the valve of Vieussens), from which they emerge on either side of the frenulum. They then continue in the opposite nerve around the side and over the ventral surface of the mid-brain. The nucleus of the trochlear nerve (also the abducent) likewise receives impulses from the optic tract.

The **corpora quadrigemina** are four bodies (colliculi) which stand upon the quadrigeminal lamina and constitute a large part of the dorsal surface of the mid-brain. They are seen in the floor of the great transverse fissure, invested by pia mater and overhung, anteriorly, by the pineal body. The crucial groove separates them and marks out a larger superior pair,¹⁶ elongated from before backward, and a hemispherical inferior pair.¹⁷ The internal geniculate body lies in front and a little external to the corpora quadrigemina. A ridge made up of white fibers, the superior brachium,¹⁸ joins

(15) N. trochlearis.

(16) Colliculi superiores.

(17) Colliculi inferiores.

(18) Brachium quadrigeminum superius.

each superior quadrigeminal body to the corresponding external geniculate body, sweeping around the internal geniculate body in front and externally. The inferior brachium¹⁹ forms an oblique ridge between the inferior quadrigeminal body and the corpus geniculatum internum of the same side. The superior peduncle of the cerebellum and lateral fillet²⁰ form two ridges which end at the back of each inferior quadrigeminal body. The corpora quadrigemina (superior colliculi) constitute the great center for the association of ocular movements and reflexes with optic and auditory impulses and impulses of common sensation. The inferior colliculi constitute a relay, or way-station, in the auditory path.

Structure.—The corpora are composed chiefly of gray matter. The upper and lower fillet and the valve of Vieussens form a layer of fibers, the quadrigeminal lamina, upon which they rest and which separates them from the gray matter around the aqueduct of Sylvius. They also contain many fibers in their interior and are covered, superficially, by a thin layer of white matter. (See quadrigeminal bodies, Chapter IV., pages 82-83.)

The **internal geniculate bodies**²¹ form a part of the tegmentum. They are derived from the mesencephalon with the remainder of the mid-brain to which they belong; but for convenience, they were considered with the external geniculate bodies under the heading “inter-brain,” which see. The internal geniculate bodies form the relay in the auditory path next above the inferior quadrigeminal bodies.

Fibers of the Tegmentum.—The tegmentum is a continuation of the dorsal longitudinal fibers and the formatio reticu-

(19) B. quadrigeminum inferius.

(20) Lemniscus lateralis.

(21) Corpus geniculatum mediale (sing.).

laris of the pons, and of the gray matter in the floor of the fourth ventricle; and, in addition, has the geniculate and quadrigeminal ganglia forming its dorsal portion. It is composed of symmetrical halves united by a median raphe. Each half contains innumerable transverse and longitudinal fibers with small masses of gray matter in the meshes. Intersecting the many transverse fibers are six distinct bundles of longitudinal fibers. They descend from cerebrum and mid-brain, or ascend from parts below. Those six bundles are as follows:

(1) *The Posterior Longitudinal Bundle*²² lies beside the raphe, just ventral to the gray matter of the Sylvian aqueduct. It is traceable from the anterior cornu of gray matter in the spinal cord where its ascending fibers rise (Tschermak). Being chiefly an association tract, it receives fibers, in the pons, from the cerebellum; and from sensory nuclei of the cranial nerves, in the medulla and pons. It carries motor fibers from the sixth to the third nerve; also descending motor fibers from the nucleus of the motor oculi to the genu of the seventh, or facial, nerve. These latter supply the frontalis, pyramidalis nasi, orbicularis palpebrarum and corrugator supercilii muscles. Through the raphe the posterior longitudinal bundle partially decussates with its fellow (lower decussation). These fibers pass into the opposite third and fourth and other motor cranial nuclei. The remainder of the bundle, decussating through the posterior commissure (upper decussation), ends in the pineal body and stratum dorsale of the hypothalamic region. It connects the cerebellum with opposite nuclei of the cranial nerves and the latter with each other. It associates the motor oculi with

(22) Fasciculus longitudinalis medialis.

the abducent and facial nerves, and the optic with the abducent. It also associates spinal and cranial nerves.

(2) *Anterior Longitudinal Bundle*.—Just ventral to the posterior longitudinal bundle is the fasciculus from the superior corpus quadrigeminum to the cilio-spinal and other centers in the cord. It is the pupillo-dilator tract.

(3) *The Fillet*.—Near the upper end of the pons, in the ventral part of the formatio reticularis, the fillet, or lemniscus, forms a very broad band of fibers on either side of the median raphe. The fillet is equal in width to half the transverse diameter of the mid-brain. It continues into the ventral portion of the tegmentum, but immediately divides into two fasciculi, viz., the interolivary fillet,²³ and the lateral, or lower, fillet.²⁴ Farther forward a small bundle leaves the lateral part of the interolivary fillet and runs up to the superior quadrigeminal body. That bundle is called the superior fillet,²⁵ and what remains is the medial fillet.²⁶

Function.—The fillet forms a segment in the direct sensory tract. It carries spinal and cranial impulses to the corpora quadrigemina and optic thalamus.

Interolivary Fillet.—The fibers composing the interolivary fillet rise chiefly in the nucleus gracilis and nucleus cuneatus of the opposite side of the medulla oblongata. They cross over in the sensory decussation of the medulla; and, excepting a small bundle, terminate in the ventro-lateral nucleus of the optic thalamus. Fibers are added from masses of gray matter along the whole course of the interolivary fillet, especially from the terminal nuclei of sensory cranial nerves; and

(23) Lemniscus interolivaris (comprising L. medialis and L. superior).

(24) Lemniscus lateralis.

(25) Lemniscus superior.

(26) Lemniscus medialis.

others, also, from the cerebellum. On the other hand, certain fibers leave the fillet and end in the nuclei along its course, that is, are interrupted, and other fibers continue in their stead. A small bundle of fibers separating from the lateral part of the interolivary fillet and running to the superior quadrigeminal body, forms the *superior fillet*. It associates ocular movements with sensations from cranial and spinal nerves. The medial fillet bends ventrally as it runs through the mid-brain. It pierces the substantia nigra, in which it undergoes a partial relay, and then continues forward, with the inner fifth of the crusta, to its termination in the thalamus. From the thalamus the impulses are carried by the anterior stalk and ansæ lenticularis et peduncularis to the somaesthetic area of the cortex.

The *lateral, or lower, fillet*²⁷ forms an oblique ridge on the dorsum of the tegmentum. It trends upward and inward over the superior cerebellar peduncle to the inferior quadrigeminal body, where its fibers terminate. It rises chiefly from the ventral and dorsal parts of the cochlear nuclei (principally the opposite one) and ends in the inferior quadrigeminal body. It undergoes partial relay in the nucleus of the superior olive and of the trapezoid body on each side, and the nucleus of the lateral fillet on the same side, and it receives a small bundle of fibers from the anterolateral ascending cerebellar tract. The greater number of its fibers cross through the trapezium; some are uncrossed. Thus the lateral fillet forms the second stage in the auditory conduction path. The auditory nerve constitutes the first stage, the lateral fillet the second stage, the inferior brachium the third, and the acoustic radiations the fourth stage. The last

(27) Lemniscus lateralis.

stage ends in the cortex of the superior and the transverse temporal convolutions.

(4) *The Superior Peduncle*²⁸ of the cerebellum continues upward from the dorsal surface of the pons. It forms a ridge near the median line of the mid-brain which ends in front at the inferior corpus quadrigeminum. The lower fillet winds inward over its anterior extremity. It is joined to its fellow by a sheet of white matter, the valve of Vieussens.²⁹ The fibers of the cerebellar peduncles bend ventrally beneath the corpora quadrigemina and then, for the most part, decussate, inferior to the iter, through the median raphe. These crossed fibers with the few uncrossed run forward toward the inferior surface of the optic thalamus, where they inclose the red nucleus, and help to form the stratum dorsale of the hypothalamic region (Forel). Many of the fibers terminate in the red nucleus and from it others rise and proceed forward to the thalamus. Though most of the superior cerebellar peduncle is centripetal and forms a segment of an indirect sensory tract, it also contains efferent fibers which rise in the red nucleus.

(5) *The Olivary Fasciculus*.—This is the bundle³⁰ which takes form at the inferior olive, where it probably rises. It runs through the formatio reticularis of medulla and pons up to the mid-brain. In the tegmentum it pierces the decussation of the superior cerebellar peduncles, running ventral to the longitudinal bundles; and then, bending lateralward, it ascends external to the posterior longitudinal bundle. It ends in the globus pallidus of the lenticular nucleus (Flechsig). Flechsig believes that the olivary bundle and

(28) Brachium conjunctivum.

(29) Velum medulare anterius.

(30) Fasciculus tegmenti centralis.

the fasciculus triangularis of Helwig (in the spinal cord) are parts of the same afferent conduction path.

(6) *The Crossed Descending Tract of the Red Nucleus.*—Formed by axones from that nucleus, it immediately decussates with its fellow of the opposite side and descends, in the medial part of the lateral fillet, to the medulla; it then mingles with the antero-lateral ascending cerebellar tract, in the medulla; and, in the cord, occupies the dorso-lateral part of the crossed pyramidal tract. It ends in the lateral horn and center of the gray crescent. It may be traced to the lumbar segments of the spinal cord.

CHAPTER IV.

THE GRAY AND WHITE MATTER OF THE CEREBRUM AND MID-BRAIN.

In the mid-brain, white matter is found in the crustæ and tegmentum, separated by the gray substantia nigra; and on its dorsum are the corpora quadrigemina and internal geniculate bodies composed of gray matter. Gray matter forms nearly the whole of the inter-brain. The deep part of the hemispheres is white matter; a thin envelope of gray matter, the cortex, incloses it. Imbedded in that white matter, is the basal ganglion of the hemisphere, called the corpus striatum. Both the gray and the white matter are richly supplied with blood vessels.

The Neurone.—The essential element in the nervous system is the neurone. The neurone comprises the cell-body, its processes and end-organs. The *cell-body, perikaryon, or neurone center*, is a reticulated mass of protoplasm of variable form, and ranges between ten microns and fifty microns in size. It is nucleated and may possess several nucleoli. Its shape, which is spherical, fusiform, pyramidal, stellate or polygonal, is dependent upon the number and mode of origin of its processes. The processes of the neurone are from one to eight or a dozen in number and are of two kinds, namely, the dendrites and the axones. *Dendrites*, like the cell-body, are protoplasmic in composition and of irregular contour, except in sensory nerves, where they are fibrillar, like axones. They branch richly and end in beaded points.

They conduct toward the cell-body and are therefore afferent, or sensory. (N. 2, Add.) *Axones, or neuraxones*, are smooth and fibrillar in character. They give off many side branches, called collaterals, and terminate by multiple division in an *end-brush*, which is in relation with another neurone or with a muscle fiber. In the latter case the fibers of the end-brush spread out into disc-like platelets, *motorial end-plates*, and underneath the sarcolemmæ apply themselves to the fibers of a muscle. Axones conduct from the neurone center. They are efferent, or motor. Both axones and dendrites are usually insulated by the white substance of Schwann, which forms their medullary sheaths. In all probability neurones differ in chemical constitution and in electric status, hence chemicals, electricity and diseases appear to exercise a selective power and affect certain neurones without influencing others (see note on neurone, p. 68).

In the brain and spinal cord and in the optic nerves two forms of **sustentacular tissue** are found supporting the neurones. (1) Neuroglia, which is most abundant in gray matter. It is an epiblastic structure made up of richly branched nucleated cells whose processes form a fine reticulation in the larger meshes of the connective tissue network (N. 3, Add.) (2) Connective tissue network.—That is of mesoblastic origin and is formed by branching processes from the inner surface of the pia mater. It transmits the blood-vessels into the nervous substance. The neurones constitute 53 per cent of the brain and cord (cell-bodies, 6 per cent) and the sustentacular tissue 47 per cent (Donaldson).

The **white matter** of the cerebro-spinal axis is made up chiefly of bundles of medullated axones imbedded in neuroglia and supported by connective tissue. The fibers possess no neurolemma.

The **gray matter** of the central nervous system is composed of cell-bodies and dendrites, chiefly, but also contains axones. These nerve elements are supported by connective tissue and blood vessels and are imbedded in a great abundance of neuroglia. The nerve fibers in the gray matter are to a large extent non-medullated.

NOTE.

In the first edition of this work the name of the nerve element was spelled "neuron" according to Waldeyer. But the new spelling, already used by Profs. Barker and Gordinier in their excellent works, has been employed in the revised edition to avoid confusion. Shaefer uses neuron in the sense of axone and Wilder of Cornell makes it synonymous with cerebro-spinal axis.

The neurone is a nervous entity and in the embryo is structurally independent of all other neurones. When fully developed in man perhaps a very small number of neurones are united together by concrescence or protoplasmic bridges, but their predominant relation is certainly that of contact, or synapsis.

TYPES OF NEURONES.

1. The first type has a long axone, which preserves its identity though it may give off many collaterals. Found in brain and spinal cord (Deiter).
2. The second type has a short axone, breaking at once into branches of apparently equal importance, the dendraxon. Found in cerebrum and cerebellum (Golgi's cells).
3. The third type has two or more axones—diaxon, triaxon, polyaxon—as in the first layer of the cerebral cortex (Cajal).

ORDERS OF NEURONES.

1. The first order has distal process in relation with the periphery, as spinal-ganglion or anterior cornu neurones.
2. The second order has cell-body or distal process in relation with neurone of first order. In like manner there are neurones of the third, fourth, fifth order, etc.

FUNCTIONS OF NEURONES.

1. Afferent. 2. Associative. 3. Efferent.

QUALITIES PECULIAR TO DENDRITES :

1. They may be absent or very numerous.
2. They are protoplasmic in composition like the cell-body.
3. In contour they are irregular, knobbed or gemmulated.
Except in sensory cranial and spinal nerves (Cajal).
4. End in sharp points, or in sensory neurones of first order, they may end within bulbous or spherical end-organs.
5. Afferent in conduction: (1) sensory; (2) excito-reflex; and (3) trophic (?).

QUALITIES PECULIAR TO AXONES :

1. Single or multiple (absent in latent neurones).
2. Fibrillar in character.
3. Smooth and regular in contour.
4. Terminate in form of end-tufts which in motor neurones of the first order form motorial end-plates.
5. Efferent in conduction: (1) motor; (2) inhibitory; (3) trophic (?); and (4) secretory (?).

On section both dendrite and axone undergo Wallerian degeneration in the disconnected part. That part remaining in connection with the cell-body atrophies and degenerates late, degeneration of Nissl.

The gray matter of the cerebrum and mid-brain is conveniently grouped into three classes:

- I. Cortical.
- II. Ganglionar.
- III. Central, or Ventricular.

I. THE CORTICAL GRAY MATTER.

It consists of a thin envelope, the cortex (or bark), which forms the surface of the hemispheres and incloses the (white) medulla, the centrum semiovale. The cortex varies in thickness from a line to a quarter of an inch. Thickest on the surface of the convolution, it grows thinner to the bottom of the sulci. It is of a reddish, or yellowish, gray color depending on the richness of the blood supply. By long observation of lesions in the brain and by anatomical and physiological investigation the cortex has been mapped out into quite definite areas. Psychic function, probably, is dependent upon the associated activity of all parts of the brain; but common sensory and motor regions have been defined with considerable exactness. The latter are found in the equatorial zone of the hemisphere (Figure 1). That sensori-motor region is called the *motor area* (or Rolandic area) when referring to the efferent, or motor, tracts which rise in it; and, when reference is made to the sensory tracts which terminate in it, the sensori-motor region is called the *somæsthetic area*. Notice in Fig. 1 that the *motor speech center* and *head area* comprise the foot of the inferior frontal convolution and the lower two-fourths of the central gyri; the *writing center* of Gordinier and the *upper extremity area* occupy the foot of the middle frontal, a part of the superior frontal and the third fourth (numbered upward) of the central convolutions; and the *trunk* and *lower extremity areas* are contained in the upper

one-fourth of the central convolutions and in the superior parietal gyrus. The head, shoulder, trunk and lower extremity are also represented, and in this order, in the marginal gyrus, the paracentral and quadrate lobules (see Fig. 2). In the same figure the *centers of smell* and *taste* may be observed in the uncus and hippocampal convolution and the *visual center* in the cuneus. The latter extends somewhat into the convex portion of the occipital lobe. Locate the remaining special centers on the convex surface (see Fig. 1). In the angular and occipital convolutions is the center for *visual memories*; in the supramarginal gyrus appears to be the center for *motor memories*; the *sensory auditory center* is seen in third and fourth fifths of the superior and in the transverse temporal gyri, and the center of *auditory memories* is in the immediately adjacent cortex. The *naming center* is probably in the third temporal convolution.

All the above motor, somæsthetic and special sense areas are provided with projection fibers which connect them with definite muscle groups and surface regions and with the organs of special sense. Other parts of the cerebral cortex possess no projection fibers; they are believed to be associative in function. *Anterior association center*.—According to Flechsig, that part of the frontal cortex which is anterior to the motor and somaesthetic regions determines the temperament and individuality of the person; while the *posterior association center*, composed of those portions of cortex situated between the sensory and motor regions of the equatorial zone, in front, and the visual cortex of the occipital lobe, behind, determine the intellectuality of the individual. To acquire knowledge of the external world is thus the function of the posterior association center. Flechsig regards the island of

Reil as the *middle association center* and lesions in it have been found associated with paraphasia.

Destructive lesions of parts of the motor or sensory cortex cause merely loss of certain motions and sensations represented by those parts, but ablation of association centers disconnects the sensory, the memory and the motor regions (as in aphasia), causes change of temperament and impairment of the so-called moral and intellectual faculties. Ablation of the visual memory center or auditory memory center produces mind-blindness in the former and in the latter mind-deafness.

To the naked eye a fresh section of the cerebral cortex shows a stratified arrangement; sometimes three gray laminae can be made out which are separated by the inner and outer white lines of Bailarger; and, in the hippocampus major, a superficial (reticulated) white layer also is easily seen. **A typical section of cortex**, which is usually taken from the parietal lobe, presents under the microscope five layers, as follows:

(1) *The Superficial, Molecular, or Neuroglial Layer.*—It is next the pia mater and is believed to be associative in function. Neuroglia forms the bulk of it, but it contains (a) a few irregular cell-bodies (Neurones of Cajal) possessing dendritic and from one to three axonic processes; and (b) a fine network composed of gray and medullated nerve fibers. These medullated fibers form the superficial white layer, above referred to, visible to the naked eye in the hippocampus major. The fibers in the neuroglial layer are for the most part dendrites of cell-bodies in adjacent laminae. The neurones of the first layer probably give rise to the short association fibers of the cerebral cortex. (N. 4, Add.)

(2) *The Second Layer* is the *layer of small pyramids*.

The pyramids are closely packed together. They point toward the pia. Their dendrites run outward and ramify in the neuroglial layer; their bases, from which the axones issue, are directed toward the white core of the convolution. The axones, after piercing the deeper gray laminae, receive the white substance of Schwann and enter into the formation of the medulla (the centrum semiovale) of the hemisphere. The small pyramids are believed to be chiefly commissural and associative in function.

(3) *Third, the Layer of Large Pyramids.*—The large pyramids have the same direction as the small ones. They are arranged in elongated groups separated by radiating fibers. The pyramids are largest in the Rolandic area, and the grouping is most distinct near the underlying fourth layer. The function of the large pyramids is chiefly motor (Dana), but it is also commissural and associative (Cajal). Their dendritic processes pass outward; their axones, as medullated fibers, run down into the white center and capsula interna. Seven or eight collaterals are given off from each axis-cylinder process before it becomes medullated, and these collaterals ramify in the adjacent gray matter, basal ganglia, etc.

The third layer is as thick as the two overlying it; it varies between one-fiftieth and one-twenty-fifth of an inch. Its formation is like that of the cornu Ammonis, the hippocampus major.

(4) *Fourth, the polymorphous layer,* is a very thin one, about a hundredth of an inch in thickness. Its cell-bodies are small and irregular. They possess many dendrites and one axone, or axis-cylinder process. A few of the latter, piercing the third and second layers of gray substance, ramify in the first; the larger number of them proceed into the white

center and comprise a great number of the commissural and long association fibers (Cajal). Probably others become efferent projection fibers. (Note 5, Add.)

(5) *Fifth*.—This is the layer of fusiform cell-bodies. It has the formation of the claustrum, hence the synonym for the fifth layer, the claustral formation. It is placed next the white center. It is a thick layer, one-twenty-fifth of an inch, and merges imperceptibly into the medulla beneath it. The cell-bodies in the main have their long axes perpendicular to the surface of the hemisphere; but, beneath the fissures, they are parallel with it. In the convolutions they lie between the radiating fibers. Under the sulci they are parallel with the association fibers which join adjacent gyri. The commissural and long association fibers belong for the most part to the fusiform and polymorphous neurones. (N. 5 and 6, Add.)

To this typical cortex there are **four principal exceptions**, viz.:

(a) On the medial surface of the occipital lobe, near the *calcarine fissure*, there are six to eight layers produced by the division of the layer of large pyramids by a lamina of irregular cell-bodies, with or without the presence of the normal fourth layer. The latter may divide the fifth layer. There are very few large pyramids in this situation.

(b) The gray cap of the *olfactory bulb* has but four layers, namely: *first*, the nerve fiber layer composed of the non-medullated fibers of the olfactory nerves which join the bulb from below; *second*, the stratum glomerulosum, the glomeruli being made up of the synapses formed by the olfactory fibers and the dendrites of the mitral neurones; *third*, the layer of mitral cell-bodies, whose protoplasmic processes ramify in the second layer and whose axones pass into

the medullary stem, after piercing the granular layer; and, *fourth*, the granular layer, which lies next the medullary stem and is composed of small irregular neurone-centers, like those in the rust-colored granular layer of the cerebellum. The last two (the third and fourth) are sometimes called the granular layer, thus reducing the number to three. The axis-cylinder processes of the mitral (or conical) neurones, medullated, form the olfactory tract.

Destruction of the olfactory bulb, olfactory tract or olfactory area in the cortex causes almost exactly the same result, viz., anosmia in the same side of the nose. The olfactory path is, chiefly, if not entirely, uncrossed.

(c) In the *hippocampus major* are five layers of cortical matter, which represent the first four of typical cortex. The *first layer*, the one bounding the dentate fissure, is the involuted medullary lamina. This is the regular network of medullated fibers, but is more highly developed than in typical cortex. It is just beneath the pia, a little neuroglia only intervening. The *second layer* is composed of closely packed small cell-bodies (granules). It is the stratum granulosum. There are no neurone-centers in the *third layer*, but a dense network of pyramid and granule dendrites. The first three layers represent the neuroglial layer of typical cortex. The *fourth* is a very thick layer and is made up of pyramids of medium size. To the fourth layer the second and third layers in typical cortex correspond. The medullated axones of the pyramids constitute the thin lamina of white matter called the alveus which forms the ventricular surface of the hippocampus major. *Fifth*.—Between the alveus and the pyramids is a thin polymorphous layer, which resembles the fourth layer of parietal cortex.

(d) The fourth exception to the typical cortex is found in

the *floor of the fissure of Sylvius*. It consists of a very great thickening of the fusiform layer. All five laminae are present. This cortex resembles the claustrum.

The *claustrum* (a rampart) is an isolated sheet of gray matter, in structure much like the fifth layer of the cortex. It is cortical matter, according to Meynert. It is a vertical antero-posterior sheet placed medial to the island of Reil, and lateral to the external capsule. The surface in contact with the external capsule is smooth, but the external surface is convoluted to coincide with the gyri insulae. At its lower border it joins the lenticular nucleus. It is made up of fusiform cell-bodies, which lie between the fibers of the uncinate fasciculus (see below—association fibers).

II. GANGLIONAR GRAY MATTER.

It is found in the great ganglia which have already been considered. They should be re-studied in this connection. They are as follows:

1. In the hemisphere:

Corpus striatum, composed of the caudate and the lenticular nucleus.

2. In the inter-brain:

The optic thalamus, the external geniculate body, nucleus Luysi and red nucleus.

3. In the mid-brain:

The internal geniculate body, the anterior and the posterior quadrigeminal body, a lateral half of the substantia nigra, and other less important nuclei in the tegmentum.

The **corpus striatum** is an ovoid mass of reddish-gray matter containing pigmented multipolar cell-bodies of various sizes, those of large size being more numerous in the *nucleus*

lenticularis than in the *nucleus caudatus*. The axones of those cell-bodies run both toward the pons and toward the cerebral cortex. The corpus striatum, therefore, forms a way-station in an efferent conduction tract and, perhaps a less important one, in an afferent tract.

Of the *Centrifugal Fibers* note the following three bundles: (a) A large bundle of axones from the striate body, the intermediate tract, runs down through the internal capsule and crusta to the nucleus pontis. It forms a thin intermediate zone between the pyramidal tract and substantia nigra in the mid-brain. Axones from the nucleus pontis continue the tract to the cerebellum (Flechsig). (b) Edinger's bundle rises in the caudate nucleus and in the putamen of the lenticular nucleus and, running through the anterior segment of the internal capsule, terminates in the optic thalamus, chiefly; but also in the substantia nigra and inferior quadrigeminal body. (c) The centrifugal axones of the *ansa lenticularis*. They rise principally from the putamen of the lenticular nucleus. After running through the medullary laminae of that nucleus they proceed medialward beneath the globus pallidus. The greater number end in the nucleus of Luys; certain others terminate in the optic thalamus and the remainder in the tuber cinereum and gray matter in the lateral wall of the third ventricle.

The best known *Centripetal Fibers* received by the corpus striatum are (a) certain fibers of the medial fillet contained in the *ansa lenticularis*, and (b) the olivary bundle (Flechsig). They arborize about the cell-bodies in the globus pallidus, whence other axones rise and continue to the somesthetic area of the cerebral cortex.

Lesions of the corpus striatum affect the internal capsule and may cause, if extensive, hemiplegia and hemianesthesia

of the opposite side of the body and partial deafness chiefly in the opposite ear and hemianopia of the corresponding halves of both retinae.

The optic thalamus¹ is made up chiefly of gray matter containing multipolar and fusiform cell-bodies. The white matter, the internal medullary lamina, divides the gray into **nuclei**, of which Nissl has described about twenty. They may be grouped as follows:

(1) The *internal, or medial, nucleus* is joined to the opposite inner nucleus by the gray (or middle) commissure and is continuous with the gray matter in the wall and floor of the third ventricle; but the internal medullary lamina separates it from the other nuclei of the same thalamus.

(2) The *external, or lateral, nucleus* is the largest. It extends from dorsal to ventral surface the entire length of the thalamus (Burdach). It forms the terminal nucleus for the larger part of the tegmental fibers and the nucleus of origin for most of the fibers of the ansæ peduncularis et lenticularis and anterior stalk of the thalamus. Destruction of this nucleus interrupts the common sensory path, and causes hemianesthesia of the opposite side.

(3) The *nucleus of the anterior tubercle*, or anterior nucleus, receives the anterior pillar of the fornix through the bundle of Vicq d'Azyr.

(4) The *posterior nucleus* is a small one. It is situated under the pulvinar between the geniculate bodies.

(5) The *nucleus of the pulvinar* is an important one. It receives about twenty per cent of the optic fibers and gives rise to a corresponding number of the afferent fibers in the optic radiations to the occipital lobe, hence a lesion of the pulvinar impairs vision.

(1) Thalamus.

(6) The *nucleus of the habenula* belongs to the epithalamus. It lies beneath the trigonum habenulæ. It receives fibers from the rhinencephalon through the pineal stria, also fibers from the optic tract, and originates a bundle of fibers, fasciculus retroflexus (Meynert), which may be traced back through the tegmentum to the interpeduncular ganglion in the substantia nigra.

(7) The *central nucleus* (center median of Luys) is situated deep in the thalamus below and between the internal and external nuclei and dorsal to the red nucleus. It gives origin to some fibers of the ansa lenticularis which run to the cortex.

The **white matter** of the optic thalamus has, for the most part, an indefinite arrangement. Into it enter the tegmental and fillet fibers and end, chiefly, in the lateral nucleus. It also receives axones or collaterals from every part of the cerebral cortex and sends fibers to the somaesthetic and special sense areas. The white matter forms the S-shaped internal medullary lamina and is continued in numerous bundles of fibers which enter the hemisphere. These bundles are as follows:

(1) The *anterior pillar of the fornix*, having pierced the thalamus, descends to the corpus albicans, while the bundle of Vicq d'Azyr,² which rises there, ascends to the thalamus and terminates in its anterior nucleus.

(2) From the external surface two groups, which rise chiefly in the lateral nucleus, proceed into the cortex of the general sensory region (the somaesthetic area): (a) The inferior is the *ansa peduncularis*. It passes below the lenticular nucleus with the internal capsule, and enters into both the medullary laminae of that nucleus and the external capsule.

(2) Fasciculus mamillaris.


It ends chiefly in the cortex of the ascending frontal and ascending parietal convolutions. Its fibers are medullated at the beginning of the ninth month (Flechsig). (b) The superior group is the *ansa lenticularis*, which pierces the superior lamina of the internal capsule and then the nucleus lenticularis, where some of its fibers are interrupted. It assists in forming the external capsule and ends in the central gyri, the paracentral lobule, the foot of the superior frontal convolution and the entire limbic lobe. The fibers of the *ansa lenticularis* become medullated at the end of the ninth month (Flechsig).

(3) The *anterior stalk* streams from the anterior end of the lateral nucleus, via the frontal segment of the internal capsule, into the frontal lobe. The fibers of the stalk end in the cortex at the foot of the inferior and middle frontal gyri, the anterior half of the superior frontal convolution and the middle of the gyrus fornicatus. Its fibers receive their medullary sheaths near the end of the tenth month (Flechsig). From the same part of the cerebral cortex the frontal cerebro-corticopontal tract rises.

The *ansæ peduncularis et lenticularis* and the anterior stalk of the thalamus are called the *cortical fillet*; they carry ordinary sensations, chiefly from the fillet and superior cerebellar peduncles, up to the somaesthetic cortex. Interruption of the cortical fillet stops all common sensory impulses.

(4) A large pencil of fibers, the *optic radiations*,³ passes from the pulvinar and external geniculate body through internal capsule to the visual centers in the occipital lobe. A number of the optic radiations are efferent and end in the superior quadrigeminal body. Destructive lesion of the optic radiations of either side produces hemianopia of the same side of both retinae.

(3) *Radialio occipitohalamicæ.*



(5) Another pencil of fibers radiates from the region of the internal geniculate body through internal capsule to the auditory area in the temporal lobe. It constitutes the *acoustic radiations*.⁴ If the acoustic radiations be destroyed the result is partial deafness affecting chiefly the opposite ear.

The **red nucleus**⁵ of the tegmentum is situated beneath the optic thalamus. It is a way-station in the indirect sensory tract, receiving the opposite superior cerebellar peduncle and, by its axones, continuing the tract to the optic thalamus and somaesthetic cortex. It also receives efferent axones and gives origin to two bundles: (a) One centrifugal bundle of axones (the crossed descending tract), after crossing over in the tegmentum, descends, first, with the medial portion of the lateral fillet; second, through the lateral area of the medulla, and, third, through the dorso-lateral part of the crossed pyramidal tract in the spinal cord. Gradually diminishing, it disappears at the first lumbar segment. It ends in the lateral horn and center of the gray crescent of the spinal cord. (b) The red nucleus also sends a bundle of axones through the opposite superior peduncle of the cerebellum to the corpus dentatum.

The **nucleus hypothalamicus** (Luysi) is a pigmented bi-convex mass of gray matter placed ventro-lateral to the red nucleus, and between it and the fibers of the crusta. It constitutes an important relay for certain fibers of the medial fillet. Certain descending fibers from the striate body terminate in this nucleus. It is also joined to the lamina cinerea and tuber cinereum by a bundle of fibers that accompanies Gudden's commissure along the medial part of the optic tract. This bundle constitutes Meynert's commissure.

(4) *Radiatio temporothalamica.*

(5) *Nucleus ruber.*

The *external geniculate body*,⁶ which receives eighty per cent of the optic fibers (Von Monokow) and forms a relay in the optic path, and the *internal geniculate body*,⁷ which is a way-station in the auditory tract, have been sufficiently described. Ablation of the former interrupts the optic path, and of the latter the auditory path.

The **superior pair of the corpora quadrigemina**⁸ represent the corpora bigemina, the optic lobes, of birds, fishes and reptiles. They are composed of three laminae: (1) The superficial white matter, the *stratum zonale*. That layer with the fibers of the interior is continuous, through the superior brachium, with the optic tract and radiations. Many of them are crossed fibers. (2) The *stratum cinereum* forms a cap of gray matter beneath the stratum zonale. In structure it resembles the gray substance of the inferior bodies. (3) Its multipolar cell-bodies increase in size toward the second gray layer, the *stratum opticum*. In that, the cell-bodies are very large. They are grouped in masses between the abundant fibers from the outer root of the optic tract, which arborize about them. They give rise to axones which associate the optic fibers with the nuclei of the third, fourth and sixth cranial nerves, and with the cilio-spinal center in the cervical cord. The stratum opticum rests upon the quadrigeminal lamina. Some gray matter is scattered through the latter, and Tartuferi calls it the "*stratum lemnisci*." The superior quadrigeminal body forms a terminal nucleus for certain fibers of the superior lemniscus, which bring to it ordinary sensations from spinal and cranial nerves.

A bundle of fibers (the anterior longitudinal bundle) rises from the superior quadrigeminal body, and descends along

(6) *Corpus geniculatum laterale*.

(7) *Corpus geniculatum mediale*.

(8) *Colliculi anteriores corporum quadrigeminae*.

the ventral surface of the opposite posterior longitudinal bundle to the anterior cornu of gray matter in the spinal cord. This bundle rises in relation with the optic fibers and ends in the cilio-spinal center, which gives origin to white rami communicantes, and in other motor centers. It forms one segment of a reflex arc concerned in dilating the pupil.

Destructive lesions affecting the superior quadrigeminal bodies produce loss of reflex movement of the eyeballs, loss of pupillary reflex and loss of accommodation.

In the **inferior pair of the quadrigeminal bodies**⁹ the white fibers are continuous, behind, with the lateral fillet; and with the inferior brachium, antero-externally. The deep part of the inferior bodies is gray matter. It contains a network of fine fibers, and small multipolar cell-bodies. The latter are in relation with the terminal end-tufts of the lateral (lower) fillet fibers, and give origin to the fibers of the inferior brachium. The inferior bodies are united beneath the sulcus longitudinalis both by decussating fibers of the fillet and by gray matter. In distinction from the superior bodies, the inferior pair may be called the auditory lobes; they are well marked only in those mammals having highly specialized organs of hearing, and form an important way-station in the auditory conduction path, hence their destruction causes the same symptoms as interruption of the acoustic radiations, namely, deafness affecting chiefly the opposite ear.

Substantia Nigra.—The small pigmented multipolar cell-bodies which make up the substantia nigra form, first, a terminal nucleus for certain fibers of the medial fillet and a nucleus of origin for other fibers which continue in that tract (Barker); and, second, a terminal way-station for the fasciculus retroflexus of Meynert and for certain fibers of

(9) Colliculi posteriores corporum quadrigeminorum.

Edinger's bundle from the corpus striatum (see pages 77, 79). Beyond this terminal station the efferent tracts are probably continued, but they have not been traced.

III. CENTRAL, OR VENTRICULAR, GRAY MATTER.

It is located (1) in the floor and walls of the third ventricle, (2) in the middle commissure of that ventricle, and (3) around the Sylvian aqueduct.

(1) The **lamina cinerea and tuber cinereum** form a sheet of gray substance that connects the inferior surfaces of the hemispheres and may be called their inferior (or great) gray commissure. From the floor of the third ventricle it extends laterally beneath the optic thalamus, and is continuous with the anterior perforated lamina. The gray matter of the floor extends up a short distance on the medial surface of the thalamus opticus; and in that upturned part is located the anterior end of the motor oculi nucleus. The inferior gray commissure receives efferent fibers through the ansa lenticularis from the corpus striatum, and is joined to the nucleus of Luys by the fibers of Meynert's commissure.

(2) The **middle commissure**¹⁰ joins the internal nuclei of the optic thalami. It is continuous with this upward extension of the gray floor of the third ventricle. In the middle commissure are cell-bodies and transverse fibers. The latter appear to be loops which reach only to the median line; at least many of the fibers do not cross to the opposite side.

(3) The **nuclei of the oculomotor** (third) and of the **trochlear** (fourth) **cranial nerves** are found in the gray matter about the Sylvian aqueduct. In it also is a part of the motor nucleus of the trigeminal, or fifth, nerve. Lesions which involve the trochlear and oculomotor nuclei, as a rule,

(10) *Massa intermedia.*

also involve the fibers of the tegmentum, and the result is ocular paralysis on the same side and impaired sensation (hemiataxia) on the opposite side of the body.

The white matter of the cerebrum and mid-brain is composed of three definite systems of fibers:

1. Projection, or peduncular, fibers.
2. Transverse, or commissural, fibers.
3. Association fibers.

I. PROJECTION FIBERS.

They are composed, first, of the medullated axis-cylinders of the large and medium-sized pyramids and of a few of the polymorphous neurones in the cerebral cortex; and, second, of medullated axones of neurones whose centers are situated in masses of gray matter below the cerebral cortex. The projection fibers are therefore both centrifugal and centripetal. They run through the mid-brain to the cerebral cortex and vice versa, connecting the cortex, directly or indirectly, with all parts of the body, throwing or projecting a picture of every part and organ upon the cerebral cortex. Many of the fibers are interrupted in the basal ganglia, especially of the centripetal fibers. Within the hemisphere the projection fibers help to form the centrum semiovale and the corona radiata and then, converging, form the internal capsule. More distally, in the mid-brain, they are divided into two great groups of fibers, the crusta and the tegmentum, separated by the substantia nigra.

CENTRIFUGAL, OR MOTOR, PROJECTION FIBERS.

The Crustae comprise most of the centrifugal, or motor, fibers, namely, the intermediate bundle, the frontal cerebro-corticopontal tract,¹¹ the pyramidal tract and the temporal

(11) Tractus cerebro-corticopontalis frontalis.

cerebro-cortico-pontal tract.¹² The *intermediate tract* extends from the corpus striatum through the deep part of the crusta to the motor cranial nuclei and to the nucleus pontis, whose axones run by way of the middle cerebellar peduncle to the cortex of the opposite hemisphere of the cerebellum. It thus forms a segment of an indirect (through the cerebellum) efferent, or motor, path. The *fronto-pontal tract*¹¹ rises from the feet of the second and third frontal gyri and the anterior half of the first frontal gyrus and from the middle of the gyrus fornicatus. It traverses the centrum semiovale, corona radiata, anterior segment of the internal capsule and internal one-fifth of the crusta to the ventral area of the pons, where it terminates in the nucleus pontis (chiefly) and in the nuclei of motor cranial nerves (Flechsig). According to Dejerine, the *temporo-pontal tract*¹² extends from the temporal lobe through the inferior lamina (and posterior part of the superior lamina) of the internal capsule and outer one-fifth of the crusta to the same nucleus; but according to Spitzka some of its fibers end in nuclei of motor cranial nerves. Thus it should be noted that, with the exception of those fibers to motor nuclei of the cranial nerves, each of the three tracts above mentioned—viz., the intermediate, fronto-pontal and temporo-pontal—constitutes a segment of an indirect efferent path which is interrupted in the nucleus pontis and then continued by the axones of that nucleus through the middle peduncle of the cerebellum.

Axones from the Rolandic cortex constitute the **Pyramidal Tract**.¹³ Descending through the centrum semiovale, corona radiata, genu and anterior two-thirds of the posterior segment of the internal capsule, the pyramidal tract comprises the

(11) Tractus cerebro-cortico-pontalis frontalis.

(12) T. cerebro-cortico-pontalis temporalls.

(13) Fasciculus longitudinalis (pyramidalis) pontis.

middle three-fifths of the crusta, the ventral longitudinal fibers of the pons, the pyramid of the medulla and the crossed and uncrossed pyramidal tracts of the spinal cord. The fibers of the pyramidal tract, with a few exceptions, cross over to the opposite side; they end in the motor nuclei of cranial and spinal nerves. Fibers enter the nucleus of the trochlear (or fourth cranial) nerve on the same side and a few descend to the motor nuclei of other cranial nerves and to the anterior cornu of gray matter in the spinal cord without decussation; all other pyramidal fibers terminate on the side opposite to their origin. *Cranial fibers.*—Those fibers of the pyramidal tract which end in the nuclei of cranial nerves rise in the lower (two-fourths) and anterior part of the Rolandic, or motor, area, including also that part of the marginal convolution situated above the genu of the corpus callosum. They run through the genu of the internal capsule and, chiefly, through the inner portion of the middle three-fifths of the crusta; a considerable number run through the outer portion of the pyramidal area. They terminate in the motor nuclei of cranial nerves. *Upper extremity fibers.*—The fibers of the pyramidal tract that end in the cervical part of the spinal cord, and through it innervate the muscles of the upper extremity, take their origin from that part of the central convolutions (third fourth) adjacent to the foot of the middle frontal gyrus, the foot of the superior frontal gyrus and the adjoining part of the marginal gyrus next behind the head center and directly above the anterior part of the truncus corporis callosi. These fibers run through the posterior segment of the internal capsule just behind the genu, and through the crusta immediately external to the cranial fibers. Those fibers which innervate the muscles of the thumb, fingers and hand, rise lowest down in the arm

area of the cortex and occupy the posterior part of the arm bundle in the internal capsule and the external part of it in the crusta. The fibers which control the shoulder muscles rise in the upper part of the cortical area and form the anterior and internal part of the arm bundle in the capsula interna and crusta, respectively, while the wrist, fore-arm, elbow and arm are innervated by means of fibers which are intermediate in both origin and course. *Trunk fibers.*—The trunk fibers of the pyramidal tract rise in the superior fourth of the ascending frontal gyrus and in the contiguous part of the marginal convolution immediately in front of the paracentral lobule. In the internal capsule the trunk fibers run just behind those to the fingers and just external to them in the crusta. *Lower extremity fibers.*—A large number of the pyramidal fibers terminate in the lumbar enlargement of the spinal cord and carry impulses to the nerves of the lower extremity. They originate in the upper fourth of the ascending parietal convolution, in the superior parietal gyrus and in the paracentral and quadrate lobules. The hip fibers rise farthest forward and the toe fibers farthest backward, immediately in front of the parieto-occipital fissure. The fibers have the same relative position in the internal capsule; in the crusta the hip fibers are internal and the toe fibers external. Fibers which innervate the muscles of the thigh, leg and small toes have this same relative position and order between the hip and great toe fibers both in their cortical origin and in their course through the internal capsule and crusta.

Several bundles of centrifugal fibers are found in the tegmentum, namely, the anterior longitudinal bundle, the crossed descending tract of the red nucleus, a small part of the superior peduncle of the cerebellum, the descending root of the

trifacial nerve and certain fibers in the *formatio reticularis*. With these exceptions the *tegmentum* is centripetal, or sensory.

Destruction by clot, tumor, or otherwise, of any of the above motor tracts causes (upper segment) paralysis of the particular muscles innervated through that tract.

CENTRIPETAL, OR SENSORY, PROJECTION FIBERS.

The sensory fibers of the *tegmentum* comprise the olivary bundle, the fillets, the optic tract (outer root), and the greater part of the posterior longitudinal bundle and superior cerebellar peduncle; perhaps, also, certain fibers in the *formatio reticularis*. Excepting a small number of fibers, all these bundles terminate in the basal ganglia; but the paths of conduction are continued through the *internal capsule*. In the *capsula interna* the centripetal projection fibers constitute the three systems of Flechsig (the cortical fillet) and the optic and acoustic (and gustatory?) radiations. The former end in the somæsthetic area of the cerebral cortex, the latter in the visual, auditory and gustatory cortex.

The exact origin of the **Three Systems of Flechsig** has not been determined, but they are known to rise, chiefly, in the lateral nucleus of the optic thalamus. The *ansa peduncularis* (first system of Flechsig) runs through the internal capsule behind the pyramidal tract in the inferior lamina. Some of its fibers enter the medullary laminae of the nucleus lenticularis and others enter the external capsule; ultimately they all terminate in the central convolutions. The *ansa lenticularis* (second system of Flechsig) issues from the lateral surface of the thalamus higher up than the former loop and mingles with the pyramidal fibers in the internal capsule. A number of its fibers pierce the internal capsule (superior

lamina) and are interrupted in the lenticular nucleus; they assist in forming the medullary laminae of that nucleus and form a part of the external capsule. The lenticular loop terminates in the upper part of the central convolutions, the foot of the superior frontal gyrus, the paracentral lobule and the entire limbic lobe. From the anterior end of the optic thalamus streams a great pencil of fibers, called the *anterior stalk* (third system of Flechsig). It mingles to a small extent with the fibers of the pyramidal tract, but runs chiefly through the anterior segment of the internal capsule. The anterior stalk terminates in the feet of the inferior and middle frontal convolutions, in the anterior half of the superior frontal gyrus and in the middle of the gyrus fornicatus. The three systems of Flechsig convey common sensory impulses to the somæsthetic area of the cerebral cortex. They are often called the *cortical fillet*.

If the *cortical fillet* be severed, all common sensory impulses to that hemisphere are interrupted and complete loss of sensation on the opposite side of the body (hemiataxia) results.

The *Acoustic Radiations and the Inferior Brachium* continue the auditory path from the end of the lateral fillet, in the inferior quadrigeminal body, to the internal geniculate body and then, through the retrolenticular part of the internal capsule, to the transverse temporal gyri and the third and fourth fifths of the superior temporal convolution (Barker). Interruption of these fibers produces deafness in the opposite ear, which is not complete because the acoustic path is not wholly crossed.

The *Optic Radiations* rise in the external geniculate body and in the pulvinar of the optic thalamus. They continue the visual conduction path through the retrolenticular region

of the internal capsule to the cortex of the cuneate lobe. Half-blindness in the same side of both retinae results from section of the optic radiations.

II. COMMISSURAL FIBERS.

They connect opposite sides of the cerebrum. They are contained chiefly in the corpus callosum, the anterior commissure, and the commissura hippocampi (N. 7; Add.).

The *Corpus Callosum* is the great link between the hemispheres. Its fibers connect both similar and dissimilar parts of the cortices. It is made up of cortical axones, a few of them being projection fibers; and collaterals from the association and projection fibers. All callosal fibers, except the few peduncular fibers, end on the opposite side in arborizations within the cortex.

The Anterior Commissure joins the opposite temporal and occipital lobes together (pars occipito-temporalis); and the limbic lobes with each other and with the contra-lateral olfactory tract (pars olfactoria).

The Commissura Hippocampi, the lyre, unites the hippocampus major, the uncus and the optic thalamus with their fellows of the opposite side.

III. ASSOCIATION FIBERS.

These fibers remain on the same side and connect parts of the same hemisphere. They are situated within or close to the cortex, the various parts of which they serve to unite. The **Short Association Fibers** are probably the axones of the irregular cell-bodies (Cajal's) situated in the neuroglial layer of the cortex. They unite contiguous parts of the same convolution and associate together adjacent convolutions. They comprise *arcuate* and *tangential* fibers. They are the more numerous and very important. Among them are fibers

which connect the visual sensory area with the visual memory area and the auditory sensory with the auditory memory area. Interruption of these association fibers gives rise to certain forms of sensory aphasia (N. 4, Add.).

The **Long Association Fibers** are collected into bundles. The long association fibers rise chiefly from the polymorphous and fusiform layers of the cerebral cortex, but also, to some extent, from the pyramids in the second and third layers (Cajal). They are axones. Proceeding out of the lobe in which they rise, they arborize about neurones in more or less distant parts of the cortex. The long association fibers dip down into the centrum semiovale and bring into harmonious action the widely separated cerebral centers. Among the best known are the following bundles:

(1) *The Cingulum*, or the fillet of the gyrus fornicatus, is a bundle of fibers in the falciform gyrus (the fornicate and hippocampal gyri), which almost entirely encircles the corpus callosum. It extends from the anterior perforated lamina, through the gyrus fornicatus and hippocampal convolution, to the uncus. The fibers have been divided into three groups by Beevor, namely: (a) The anterior, which joins the anterior perforated lamina and internal olfactory root to the fore part of the frontal lobe. (b) The horizontal, which unites the frontal lobe and the gyrus fornicatus. And (c) the posterior fasciculus, which associates the lingual and fusiform gyri with the hippocampal gyrus and pole of the temporal lobe.

(2) *The Fornix*.—Each lateral half of the fornix¹⁴ is a bundle of association fibers. Its anterior end (or pillar) is connected with the corpus albicans; and, through the bundle of Vicq d'Azyr, also with the optic thalamus. The posterior

(14) Corpus fornicis.

pillar, descending in the middle horn of the lateral ventricle, for the most part, disappears in the hippocampus major (its origin); but a small bundle of its fibers, constituting the corpus fimbriatum, continues to the uncus.

(3) *The Uncinate Fasciculus* is a bundle,¹⁵ with some sharply curved fibers, which arches over the main stem of the Sylvian fissure, and connects the uncus and the orbital part of the frontal lobe. It is situated near the basal surface. Its fibers spread out at both ends in the cortex, and they especially join the internal and posterior orbital and the third frontal convolution with the limbic lobe (Barker). Like the cingulum and fornix, it is connected with the rhinencephalon. Lesion in any one of these three bundles causes disturbance of smell.

(4) *The Superior Longitudinal Fasciculus*¹⁶ is a sagittal bundle located beneath the convex surface of the hemisphere, just above the horizontal ramus of the fissure of Sylvius. It joins the frontal cortex with the parietal and the external temporal. It thus associates the auditory and the visual memory centers with the motor speech center; hence, aphasia is the result of its interruption.

(5) *The Inferior Longitudinal Fasciculus*¹⁷ is about on a level with the lateral ventricle. It passes near the outer wall of the descending and posterior cornua of that ventricle, and connects the temporal lobe to the occipital. In the temporal lobe its fibers cross at right angles those of the inferior lamina of the internal capsule. This fasciculus unites the auditory and visual memory centers, and thus associates the memories of things seen with the memories of things heard.

(6) *The Fasciculus Occipito-frontalis* (Forel).—This is

(15) Fasciculus uncinatus.

(16) Fasciculus longitudinalis superior.

(17) Fasciculus longitudinalis inferior.

a large bundle of fibers formerly regarded as a part of the corpus callosum. It is situated between the cingulum and the superior longitudinal bundle, just external to the lateral ventricle. It extends from the cortex of every part of the frontal lobe to the cortex of the convex surface and lateral border of the occipital lobe. Posteriorly, the fibers diverge to form a fan-like sheet, and that sheet enters into the external boundary of the descending horn of the lateral ventricle and into the floor, lateral wall and roof of the posterior horn, hence the synonym, *tapetum*. Its particular function is unknown.

(7) *The Perpendicular Fasciculus*.¹⁸—This is a very broad vertical bundle located just in front of the occipital lobe. Anteriorly, it extends from the inferior parietal convolution, above, down to the second and third temporal; and, posteriorly, it joins the superior occipital convolution with the middle and inferior occipital and with the fusiform gyrus of the temporal lobe. Its function is doubtful.

NOTE.

The student will find many obscure points cleared up by a careful study of the embryology of the cerebrum (see Chap. XI., page 202).

BLOOD SUPPLY OF THE CEREBRUM AND MID-BRAIN.

The blood supply of the cerebrum and mid-brain is derived from the anterior choroid and the anterior and middle cerebral arteries, all branches of the internal carotid; and from the posterior cerebral arteries, which are terminal branches of the basilar artery. They form a remarkable anastomosis at the base of the brain, the circle of Willis.¹⁹ The **Circle of Willis** (really a heptagon) extends from a

(18) Fasciculus perpendicularis. (19) Circulus arteriosus.

point in the great longitudinal fissure, anterior to the optic commissure, back to the pons. It is about an inch and a half long, and one inch in transverse diameter. In front are the anterior cerebral arteries converging forward from the internal carotids and uniting through the anterior communicating artery.²⁰ The posterior communicating artery²¹ forms the lateral boundary of the circle. It forms the anastomosis between the internal carotid artery and the posterior cerebral. The posterior cerebral arteries bound the circle behind. The superior cerebellar arteries send several branches to the dorsum of the mid-brain.

The large *distal branches* of the cerebral arteries are distributed chiefly to the cortex and medulla of the hemispheres; while the small *proximal branches* supply the ganglia and inter-brain. The former belong to the cortical system, the latter to the ganglionic system.

CORTICAL SYSTEM.

The Anterior Cerebral Artery²² enters the great longitudinal fissure. Winding around the genu of the corpus callosum, it runs back on the medial surface of the hemisphere to the parieto-occipital fissure. It has three branches: (1) Anterior internal frontal, which supplies the internal orbital convolution and olfactory bulb, the superior frontal and the anterior half of the middle frontal gyri. (2) Middle internal frontal, which is distributed to the corpus callosum, gyrus fornicatus, marginal convolution and upper end of the ascending frontal convolution. And (3) Posterior internal frontal, which supplies the quadrate lobe and part of the superior parietal convolution.

The Middle Cerebral Artery²³ runs in the fissure of Sylvius. It has four distal branches: (1) External and infe-

(20) A. communicans anterior.

(22) Artera cerebri anterior.

(21) A. communicans posterior.

(23) Artera cerebri media.

rior frontal, to the anterior and posterior orbital and third frontal convolutions; (2) Ascending frontal, and (3) Ascending parietal, to convolutions of the same name. The ascending frontal also supplies the foot of the middle frontal gyrus; and the ascending parietal artery, a part of both the superior and inferior parietal convolutions. And (4) Parieto-temporal, which supplies the supragmarginal and the angular and the superior and middle temporal gyri.

The Posterior Cerebral Artery,²⁴ winding from the basilar artery²⁵ outward around the mid-brain, breaks up into three cortical branches on the tentorial surface of the hemisphere. Their distribution is as follows: (1) Occipital, to the cuneus and the convex surface of the occipital lobe; (2) Uncinate, to the same convolution (hippocampal and lingual), and (3) Temporal (or temporo-sphenoidal), to the fourth, third and part of the second temporal gyri.

These vessels of the cortical system and their many branches pierce the hemispheres perpendicular to the surface. They are distributed, the *short*, to the cortex, and the *long*, to the medulla of the hemispheres. To a limited extent they anastomose with one another, but they do not communicate with the ganglionic system.

GANGLIONIC SYSTEM.

Small arteries from the circle of Willis and from the cerebral arteries near the circle constitute this system. It is made up of six groups of vessels:

(1) **Antero-median Ganglionic.**—They rise from the anterior cerebral arteries and anterior communicating. Piercing the lamina cinerea (and a few of them, the anterior perforated lamina) they supply the bulb of the caudate nucleus and anterior wall of the third ventricle.

(24) Artera cerebri posterior.

(25) A. basillaris.



(2, 3) **The Antero-lateral Ganglionic Arteries** take their origin, on either side, from the middle cerebral artery, a little outside the circle of Willis. They pierce the anterior perforated lamina and are distributed to the striate body, internal capsule and optic thalamus. One of this group is the *lenticulo-striate artery*. It supplies almost the entire corpus striatum. On account of its frequent rupture, it is called the artery of cerebral hemorrhage (Charcot).

(4) **Postero-median Ganglionic.**—These are branches of the posterior cerebral and posterior communicating arteries. They supply the interpeduncular structures and crustæ; and (after piercing the posterior perforated lamina) the walls of the third ventricle and medial parts of the optic thalami.

(5, 6) **Postero-lateral Ganglionic Arteries.**—They rise, on either side, from the posterior cerebral artery after it has wound around the crusta. They are distributed to the posterior part of the optic thalamus, the geniculate bodies and corpora quadrigemina.

The ganglionic arteries pass to their distribution without communicating with one another or with the cortical arteries. They are *end-arteries* of Cohnheim. Between the cortical and ganglionic systems, there is an area poorly supplied with blood. That is the area of cerebral softening.

Choroid Arteries.²⁶—They are three in number.

Anterior Choroid.—Coming from the internal carotid artery, the anterior choroid artery²⁷ enters the apex of the descending horn of the lateral ventricle; and supplies the inferior two-thirds of the choroid plexus, a part of the velum interpositum, the hippocampus major and corpus fimbriatum.

*The Postero-lateral Choroid*²⁸ is a branch of the posterior

(26) Arteriæ choroideæ.

(27) Arteria choroidea anterior.

(28) A. choroidea postero-lateralis.

cerebral. It is distributed to the upper third of the choroid plexus of the lateral ventricle and to the velum interpositum.

*Postero-medial Choroid.*²⁹—Also a branch of the posterior cerebral artery, it supplies the choroid plexuses of the third ventricle; and, with branches from the superior cerebellar, completes the supply of the velum interpositum. The postero-lateral and postero-medial choroid vessels have their origin, course and distribution wholly within the great transverse and choroid fissures.

Veins.³⁰—The velum interpositum and lateral and third ventricles are drained by the *common vein of Galen*.³¹ The veins of Galen (*Vv. cerebri internæ*) are formed, one on either side, at the foramen of Monro, by the union of the veins of the striate body³² and choroid vein and receive the basilar.³³

The Superior Cerebral Veins,³⁴ eight to twelve in number, carry away the blood from the superior surface of the hemisphere. They run obliquely upward and forward into the superior longitudinal sinus.³⁵ Just before emptying into the sinus they receive most of the medial veins.³⁶

The Medial Cerebral Veins.—They drain the medial surface of the hemisphere. The veins of that surface which do not empty into the superior cerebral veins unite and form the inferior longitudinal sinus.³⁷

The base of the cerebrum and border of its convex surface are drained by the *Inferior Cerebral Veins*.³⁸ On the tento-

(29) *Arteria choroidea postero-medialis.*

(30) *Venæ.*

(31) *V. cerebri magna.*

(32) *V. corporis striati (sing.).*

(33) *V. choroidea.*

(34) *Vv. cerebri superiores.*

(35) *Sinus sagittalis superior.*

(36) *Vv. cerebri mediales.*

(37) *Sinus longitudinalis inferior.*

(38) *Vv. cerebri inferiores.*

rial surface of the hemisphere, these veins empty, against the current, into the lateral and superior petrosal sinuses.³⁹ Those from the temporal and frontal lobes empty into the cavernous sinus,⁴⁰ excepting the small anterior cerebral vein and the deep Sylvian vein, which unite with the inferior striate veins in forming the basilar. The *basilar vein* receives additional blood from the interpeduncular structures, the uncinatè gyrus and the middle horn of the lateral ventricle and from the mid-brain as it winds around it to empty into the corresponding vein of Galen near its termination. In or near the fissure of Sylvius there are two inferior cerebral veins of large size: The *middle cerebral vein*,⁴¹ which runs from the under surface of the temporal lobe, medialward, along the fissure of Sylvius to the cavernous sinus; and the *great anastamotic vein* of Trolard, whose course is much the same, but in front of, the Sylvian fissure. Rising on the parietal lobe, it winds inward along the lesser wing of the sphenoid bone to the anterior extremity of the cavernous sinus. The main trunks of all the cerebral vessels are contained in the pia mater.

There are no lymphatic vessels in either the brain or spinal cord; perivascular lymph spaces carry the fluid from the interior to the subarachnoid spaces.

(39) Sinus transversus and S. petrosus superior.

(40) Sinus cavernosus.

(41) Vena cerebri media.



CHAPTER V.

HIND-BRAIN.

SECTION I. THE CEREBELLUM.

The hind-brain is composed of the cerebellum and the pons. The cerebellum is the dorsal portion of the hind-brain. It is called the *little brain*. Its weight is about five ounces, slightly more than one-tenth of the whole brain. It is situated in the posterior fossa of the skull, under the tentorium cerebelli and dorsal to the pons and medulla oblongata. Between it and the last two structures is inclosed the fourth ventricle.¹

Function.—The cerebellum is an important way-station, or relay, in the indirect motor and indirect sensory paths. In response to impulses received from skin, muscles, tendons, joints and viscera, it is also believed to originate impulses which co-ordinate muscles and maintain equilibrium. Moreover, according to Russell, each cerebellar hemisphere exercises an important inhibitory function, through the superior peduncles, upon the opposite side of the cerebrum. *Divisions.*—The cerebellum is made up of two lateral parts, the hemispheres,² and a central part, uniting the hemispheres together, called the vermis cerebelli, or worm.

The **Cerebellar Hemispheres** measure two inches from before backward and about the same in thickness, antero-medially; but they taper rapidly toward the lateral borders.

(1) *Ventriculus quartus.*

(2) *Hemisphaerium cerebelli.*

They are joined together by the worm, which forms the most elevated part of the cerebellum.

The **vermis, or worm**, is a small elongated lobe, shorter and much thinner than the hemisphere. In animals lower than mammals, it is the only part of the cerebellum present. Its transverse ridges give it a worm-like appearance. It unites the upper half of the medial aspect of the hemispheres, their lower halves being separated by an antero-posterior groove, called the valley, or *vallecula*.³ The upper surface of the vermis is called the superior worm, or *vermis superior*; and the lower surface, the inferior worm, or *vermis inferior*. The superior and inferior surfaces are separated from one another at the posterior end of the worm by the great horizontal fissure;⁴ anteriorly, the medullary body⁵ of the cerebellum separates them. At either end of the worm is a notch bounded by the vermis and the hemispheres, the anterior and posterior cerebellar notches.

The *posterior cerebellar notch*, *incisura cerebelli posterior*, is occupied by the falx cerebelli. A prolongation of the medullary body of the cerebellum issues from the *incisura cerebelli anterior*, or *anterior cerebellar notch*.

The **Medullary Body** splits, in its medial part, into two laminae: a superior, which forms the superior medullary velum and three pairs of peduncles, and an inferior, which is the inferior medullary velum. Separating at an acute angle, the two laminae form the tent and lateral recesses of the fourth ventricle.

The *inferior medullary velum*⁶ is the inferior lamina of the medullary body. It is a short plate of white matter, not

(3) *Vallecula cerebelli*.

(4) *Sulcus horizontalis cerebelli*.

(5) *Corpus medullare*.

(6) *Velum medullare posterius*.

more than a quarter of an inch long. It ends in a concave border from which a sheet of epithelium continues down over the fourth ventricle; and together they form the inferior half of the roof of that cavity. Laterally, the inferior velum extends to the flocculus of the hemisphere, and blends with the middle cerebellar peduncle. Of the worm it covers the nodulus, antero-superiorly. It bounds, dorsally, the lateral recesses of the fourth ventricle.

The *Superior Lamina of the Medullary Body* joins the cerebellum immediately to the pons. The superior lamina is made up of three pairs of cerebellar peduncles and the superior medullary velum.⁷ They are the prolongations of the white matter which constitutes the corpus medullare of the cerebellum.

The *superior peduncles* (crura ad cerebrum, or brachia conjunctiva) converge as they pass forward and upward to the inferior quadrigeminal bodies, where they disappear. They are joined to one another by a thin plate of white matter, the *superior medullary velum*, or valve of Vieussens; with the valve, they form the dorsal longitudinal fibers of the pons; and, as such, the roof and lateral boundaries of the superior half of the fourth ventricle. Beneath the corpora quadrigemina and aqueduct of Sylvius, most of the fibers of the superior cerebellar peduncles decussate, and pass into the hypothalamic region of the opposite side. They end chiefly in the red nucleus, which they surround.

The *inferior peduncles* of the cerebellum (crura ad medullam)⁸ issue from the cerebellum between the superior and middle peduncles. They first run ventrally to the dorsal surface of the pons, near the posterior border; and then, bending downward and backward (a flexion of more than 90

(7) Velum medullare anterius.

(8) Corpora restiformia.

degrees), they converge in the posterior areas of the medulla toward the calamus scriptorius. They help to form the floor and to bound laterally the inferior half of the fourth ventricle. In the medulla they are called the restiform bodies.

The *middle peduncles* (*crura ad pontem*)⁹ join the cerebellum to the lateral borders of the pons. They are continuous with the ventral (or superficial) transverse and the middle transverse fibers of the pons. The middle peduncles are external to the superior and inferior peduncles, and are opposite the widest part of the fourth ventricle.

Great Horizontal Fissure.—The cerebellum has one great fissure which divides it into upper and lower surface. The sulcus horizontalis cerebelli is shaped like a horseshoe; its extremities are located on either side of the medullary body, from which the fissure runs backward, dividing the border of each hemisphere and the posterior end of the worm. In the great horizontal fissure the remaining important fissures of the cerebellum terminate. They are nearly parallel with one another; hence, the cerebellum is laminated, not convoluted like the cerebrum. The extremities of the great horizontal fissure are separated from the fourth ventricle by a sheet of epithelium, on either side, uniting the borders of the superior and inferior medullary laminae, and bounding externally the lateral recesses. When the cerebellum is separated from the pons and medulla it presents along its anterior border between superior and inferior medullary laminae the transverse fissure.

SUPERIOR SURFACE OF THE CEREBELLUM.

The superior surface¹⁰ of the cerebellum is bounded by the great horizontal fissure and the superior lamina of the medul-

(9) *Brachia pontis.*

(10) *Facies cerebelli superior.*

lary body. It is divided into five continuous lobes by four crescentic fissures, called interlobular fissures.¹¹

Fissures.—The interlobular fissures divide the worm and both hemispheres; and each lobe is composed of a central and two lateral portions, called lobules. These fissures are named in accordance with their relations to the lobules in the worm, viz.:

(1) *The Precentral Fissure*,¹² which is located in the anterior cerebellar notch. It is between the lingula and lobulus centralis, in the worm; between the fraenum and ala, in the hemisphere.

(2) *The Postcentral Fissure*,¹³ in the worm, separates the lobulus centralis from the culmen; and, in the hemisphere, the ala from the anterior crescentic lobule. The fissure follows the anterior border of the superior surface. Both central fissures terminate on the dorsum of the superior medullary lamina.

(3) *Preclival Fissure.*—Behind the culmen and anterior crescentic lobules is the preclival fissure. It bounds the clivus and posterior crescentic lobules in front. It ends at the junction of the anterior and middle thirds of the antero-lateral border in the great horizontal fissure.

(4) *The Postclival Fissure* is located in the posterior cerebellar notch, from which it curves outward and forward in the superior surface of the hemispheres. It separates the clival lobe from the folium cacuminis, in the worm, and the postero-superior lobules in the hemispheres. It ends in the horizontal fissure at the junction of the posterior and middle thirds of the antero-lateral border.

(1) Fissuræ interlobulares.

(2) Sulcus præcentralis cerebelli.

(3) Sulcus postcentralis.

Fissures and lobules of the upper surface of the cerebellum from before backward:

<i>Hemisphere.</i>	<i>Worm.</i>	<i>Hemisphere.</i>
Frænulum.	Lingula.	Frænulum.
	<i>Precentral fissure.</i>	
Ala.	Lobulus centralis.	Ala.
	<i>Postcentral fissure.</i>	
Anterior crescentic.	Culmen.	Anterior crescentic.
	<i>Preclival fissure.</i>	
Posterior crescentic.	Clivus.	Posterior crescentic.
	<i>Postclival fissure.</i>	
Postero-superior.	Folium cacuminis.	Postero-superior.
	<i>Great horizontal fissure.</i>	

Lobes of Superior Surface.—These include the divisions of the worm and of the hemispheres, and are five in number.

Lingula and Frænula (Lobus lingulæ).—The lingula¹⁴ is a very small lobule of the vermis entirely concealed in the anterior cerebellar notch by the overhanging central lobule. It is a tongue-shaped group of four or five rudimentary transverse laminae. It rests upon the superior medullary velum, with which its white center is continuous. Laterally, the lingula tapers off and is represented, if at all, in the hemisphere by a very thin folium called the frænulum.¹⁵ The frænulum is bounded by the superior cerebellar peduncle in front, and by the precentral fissure behind. The precentral fissure separates the lobe of the lingula from the central lobe.

Central Lobule and Alæ (Lobus centralis).—The lobulus centralis is situated between the precentral and postcentral fissures, in the anterior cerebellar notch. It covers the lingula and in turn is overhung by the culmen. Four or five

(14) Lingula cerebelli.

(15) Vinculum lingulæ cerebelli.

small transverse laminae make it up. On sagittal section, it is seen to form a single branch of the corpus trapezoides (arbor vitae). The laminae of the central lobule, continuing into either hemisphere, form a triangular or wing-like lobule, the ala (ala lobuli centralis).

Culmen and Anterior Crescentic Lobules (Lobus culminis).—In the culmen¹⁶ the surface of the cerebellum reaches its highest elevation. It is a large lobule and occupies more than half of the upper surface of the worm. It is made up of three or four prominent laminae, which extend laterally into the hemispheres; and, there, form the anterior crescentic lobules.¹⁷ The latter occupy about one-third of the upper surface of the hemispheres. The preclival fissure separates the culmen and anterior crescentic lobules (the lobe of the culmen) from the clival lobe.

Clivus and Posterior Crescentic Lobules (Lobus clivi).—The clivus¹⁸ forms the posterior slope, as the culmen forms the summit, of the monticulus cerebelli. The clivus has about half the extent of the culmen. Its laminae are continued into either hemisphere, where they form the large posterior crescentic lobule.¹⁹ The increased size in the hemisphere is due to the expansion of the secondary folia found in the worm. The anterior and posterior crescentic lobules constitute the quadrate lobe,²⁰ which forms the anterior two-thirds of the superior surface of the hemisphere. The clivus and its hemispherical extensions are inclosed between the preclival and postclival fissures.

The Folium Cacuminis and Postero-superior Lobules

- (16) Culmen monticuli cerebelli.
- (17) Pars anterior lobuli quadrangularis.
- (18) Declive monticuli cerebelli.
- (19) Pars posterior lobuli quadrangularis.
- (20) Lobus quadrangularis.

(*Lobus cacuminis*) lie behind the postelival and in front of the great horizontal fissure. The *folium cacuminis*²¹ is the terminal lamina in the superior worm, and occupies the posterior cerebellar notch. It is beset with rudimentary folia, which are largely developed in the hemispheres. The postero-superior lobule²² is, therefore, very large in comparison with the *folium cacuminis*. It expands lateralward to the posterolateral border of the hemisphere, which it forms. It comprises the posterior third of the hemisphere's superior surface.

INFERIOR SURFACE OF THE CEREBELLUM.

The inferior surface of the cerebellum²³ is prominent laterally and depressed centrally (as the organ is viewed inverted); the hemispheres being separated by the antero-posterior groove, called the *vallecula*.²⁴ The valley is occupied by the inferior worm and is bounded on either side by a small fissure, between the worm and the overhanging hemisphere, called the *sulcus valleculæ*. The inferior cerebellar surface is limited by the great horizontal fissure and the medullary body of the cerebellum. It is more complex than the superior surface; and its fissures are more sharply curved forward as they pass from the worm into the hemispheres.

Fissures of Lower Surface.—The interlobular fissures of this surface are very deep. They are three in number, namely:

(1) *The Postnodular Fissure* is in the anterior end of the worm between the nodule and uvula. In the hemisphere it winds forward and outward between the inferior medullary velum and the tonsil, and then continues lateralward between

(21) *Folium vermis*.

(22) *Lobulus semilunaris superior*.

(23) *Facies cerebelli inferior*.

(24) *Vallecula cerebelli*.

flocculus and digastric lobule to the anterior end of the great horizontal fissure.

(2) *The Prepyramidal Fissure*, between the uvula and pyramid, is very concave in the hemispheres. It curves outward and forward around the tonsil, separating it from the digastric lobule. It terminates behind the flocculus in the postnodular fissure.

(3) *The Postpyramidal Fissure*, between the pyramid and tuber valvulæ, is near the posterior end of the worm. It forms an oblique groove in either sulcus valliculæ, from which three concentric fissures extend into the hemispheres. The anterior of the three (the pregracile), usually considered the postpyramidal fissure in the hemisphere, separates the digastric lobule from the postero-inferior lobule; the remaining two (midgracile and postgracile) subdivide the postero-inferior lobule into anterior and posterior slender and inferior semilunar sub-lobules. The last is bounded behind by the great horizontal fissure.

Fissures and lobules of the lower surface of the cerebellum, from before backward:

<i>Hemisphere.</i>	<i>Worm.</i>	<i>Hemisphere.</i>
Flocculus.	Nodule.	Flocculus.
	<i>Postnodular fissure.</i>	
Tonsil.	Uvula.	Tonsil.
	<i>Prepyramidal fissure.</i>	
Digastric lobule.	Pyramid.	Digastric lobule.
	<i>Postpyramidal fissure.</i>	
Postero-inferior lobule.	Tuber valvulæ.	Postero-inferior lobule.
	<i>Great horizontal fissure.</i>	

Lobules of Lower Surface.—They are not continuous with one another from the worm to the hemisphere as on the

upper surface. Excepting the posterior lobules, only a small ridge beneath the sulcus valleculæ joins them together. The inferior lobes are four in number. Each is composed of a central and two lateral lobules. The lobule in the worm gives the name to the lobe.

Nodus and Flocculi (Lobus noduli).—The nodule²⁵ is a small lobule at the anterior end of the inferior worm. It is composed of three or four laminae, which project from the middle of the lower surface of the inferior medullary velum. It comprises a single branch of the arbor vitæ. Though larger, it is the counterpart of the lingula on the superior velum. It is bounded by the sulcus valleculæ on either side. The inferior medullary velum extends laterally from the nodule, and blends with the middle peduncle of the cerebellum. In front of the tonsil, a fold of gray matter (peduncle of flocculus)²⁶ appears on the velum. That gray matter enlarges more externally to a tufted mass, called the flocculus. The flocculus is separated from the tonsil and digastric lobule by the postnodular fissure. The whole line of structures, namely, the nodule, velum, peduncle and flocculus, form the lobe of the nodule.

Uvula and Tonsils (Lobus uvulæ).—The uvula²⁷ comprises a considerable part of the vermis inferior behind the nodule. It broadens backward and is widest next the pyramid. Bounded on either side by the sulcus valleculæ, it projects into the valley like the uvula into the isthmus of the fauces. Three moderate sized laminae and six or eight small folia make up the uvula. A slight ridge, the *furrowed band*, joins it to the tonsil²⁸ in the hemisphere. From the furrowed band the tonsil expands downward and backward, forming a lobule of nearly a dozen sagittal laminae. The tonsil (or

(25) Nodus vermis.

(27) Uvula vermis.

(26) Pedunculus flocculi.

(28) Tonsilla cerebelli.

amygdala) overhangs the side of the uvula and conceals the furrowed band, medially; and, behind, it conceals the connecting ridge between the pyramid and digastric lobule. The fossa containing the tonsil is the bird's nest (*nidus avis*). Behind the uvular lobe, composed of the above three lobules, are the prepyramidal fissure and the lobe of the pyramid.

Pyramid and Digastric Lobules (*Lobus pyramidis*).—As seen from the surface, three or four distinct laminae make up the pyramid,²⁹ which is the most prominent lobule of the inferior worm. A low connecting ridge joins the pyramid to the digastric lobule in the hemisphere. The digastric (or biventral) lobule³⁰ is triangular in outline. Its base looks toward the flocculus and is bounded by the postnodular fissure; its apex is continuous with the connecting ridge. The laminae composing it radiate from the apex toward the base, and are divided into two groups by a very deep intralobular fissure. The postpyramidal fissure bounds it postero-externally, and separates it from the postero-inferior lobule.

Tuber Valvulae and Postero-inferior Lobules (*Lobus tuberis*).—The tuber valvulae³¹ forms the posterior end of the inferior worm. It resembles the lobules of the vermis superior, because its half dozen tertiary laminae are continued into the hemispheres, the sulcus valliculae not cutting them off. The great horizontal fissure separates it from the folium cacuminis of the superior worm. The postero-inferior lobule³² comprises the posterior two-thirds of the inferior surface of each hemisphere, extending from the digastric lobule to the postero-lateral border. Twelve to fifteen laminae compose the lobule. They are divided into three groups by the mid-

(29) *Pyramis vermis*.

(30) *Lobulus biventer*.

(31) *Tuber vermis*.

(32) *Lobulus semilunaris inferior*.

gracile and postgracile fissures; the groups are named the anterior slender, or pregracile, posterior slender, or postgracile, and inferior semilunar. The inferior semilunar sublobule, only, is continuous with the laminae of the tuber.

GRAY MATTER OF THE CEREBELLUM.

The gray matter of the cerebellum is composed of cortex which covers the cerebellar laminae and of ganglia imbedded in the medullary center.

1. CORTICAL GRAY MATTER.

The cortex of the cerebellum (*substantia corticalis*) is made up of two microscopic layers, viz., (1) a superficial, molecular, or gray cellular layer, and (2) a deep, nuclear, or rust-colored granular layer.

(1) **Superficial, Molecular, or Gray Cellular Layer.**—Thickest on the laminae and thinnest beneath the fissures, this layer contains small spheroidal, or stellate, cell-bodies with their processes, and large flask-like cell-bodies with their dendrites and axones (the cells of Purkinje) and a close network of fibers.

Cells.—The bodies of *Purkinje's cells* are located near the deep surface of the cellular layer (*stratum gangliosum*). Each has one axone which, after piercing the granular layer, becomes a fiber of the medullary center (a projection fiber). From the outer end of each cell-body antler-like processes, the dendrites, are given off; they ramify toward the surface in a plane at right angles to the intralobular fissures. The *spheroidal cell-bodies* form an outer and inner layer. They have rich dendritic processes and one axis-cylinder each. The dendrites ramify throughout the cellular layer. In the *outer layer* the stellate cell-bodies are smaller than in the inner

layer. Their axis-cylinders run parallel with the surface and at right angles to the intralobular fissures. They branch freely and terminate in a manner unknown. The *inner layer* contains the "basket cells." Their axis-cylinder processes run parallel with the former, and give off vertical branches which descend to Purkinje's corpuscles and inclose them in a basket-work of filaments.

Fibers of the gray cellular layer have three sources: (a) The dendritic and axonic processes of neurones within the layer; (b) the processes of cell-bodies in the granular layer. The latter comprise, first, the neuroglial fibers of Bergmann (vertical), which extend from the granular layer outward to the surface of the lamina, where they form a feltwork like the limiting membranes of the retina; and, second, the axones of the cell-bodies in the granular layer, whose T-branches run parallel with the interlobular fissures in the superficial layer. (c) The fibers of the medullary center (projection fibers) rise or end largely in the cellular layer. The axones of Purkinje's neurones compose most of the centrifugal projection fibers. The centripetal fibers, which rise either in other parts of the brain or in the spinal cord and ganglia, terminate in end-tufts or moss-like appendages (Cajal) chiefly in the superficial layer.

(2) **The Deep, Nuclear, or Rust-colored Granular Layer** is of uniform thickness. It blends centrally with the medullary body.

Cells of the Granular Layer.—The granules are small round, or stellate cell-bodies, largest near Purkinje's cells, closely packed externally, but scattered among the projection fibers centrally. Each granule has one axone. It runs out into the cellular layer, branches T-like, and forms many of the tangential fibers of that layer. Dendritic processes are

abundant. They ramify chiefly within the granular layer. The neuroglial cell-bodies, which originate the vertical fibers of Bergmann, lie near the cells of Purkinje (N. 8, Add.).

Among the **fibers** of the granular layer are included the processes of the granules and glia cell-bodies, and the efferent and afferent projection fibers.

The **functions** of the stellate cells, the "basket cells" and the granule cells are probably receptive and associative; they receive impulses through the centripetal projection fibers and transfer those impulses to the dendrites or bodies of Purkinje's cells. Purkinje's cells originate impulses for the co-ordination of muscular action (Gordinier), and for the inhibition of nervous activity in the opposite cerebral hemisphere (Russell). Hence lesions in the cerebellum produce inco-ordination, irritability and, rarely, convulsions.

II. GANGLIONAR GRAY MATTER.

The ganglia of the cerebellum are the corpus dentatum and the three nuclei of Stilling.

The Corpus Dentatum¹ is a wavy, sinuous pouch of yellowish-brown gray matter imbedded in the medullary body of each hemisphere. It is filled with white fibers, which issue from its anterior, open end² and form the greater part of the superior cerebellar peduncle. Stellate cell-bodies (from 6 microns to 40 microns in diameter) are the essential element of both the corpus dentatum and Stilling's nuclei.

Nuclei of Stilling.—One of these, a club-shaped mass, the cork-like *nucleus emboliformis*, partly closes the hilus of the dentate body. Medial to that is an elongated antero-posterior ganglion, bulbous behind, called the *nucleus globosus*. The third nucleus is in the anterior end of the worm, just above

(1) Nucleus dentatus.

(2) Hilus nuclei dentati.

the fastigium of the fourth ventricle. It is called the nucleus of the highest point of the roof, *nucleus fastigii*. In the two last the stellate cell-bodies are larger than in the nucleus emboliformis or corpus dentatum; but, otherwise, they are alike in structure. The nucleus fastigii and nucleus globosus form the terminal station for the *acustico-cerebellar tract*, which tract sends collaterals to the nucleus emboliformis and corpus dentatum. In this manner these nuclei are associated with the vestibular nuclei (auditory) of the opposite side.

WHITE MATTER OF THE CEREBELLUM.

The white matter of the cerebellum is arranged in three systems similar to that of the cerebrum:

- I. Projection, or peduncular, fibers.
- II. Commissural fibers.
- III. Association fibers.

I. PROJECTION FIBERS.

These include all fibers of **the medullary body**³ as it issues from the anterior cerebellar notch. The fibers are in continuity with the branches of the medullary body⁴ and together constitute the *arbor vitæ*. Dividing medially into a superior and an inferior lamina (united laterally), the medullary body forms the tent⁵ and lateral recesses⁶ of the fourth ventricle. The *inferior lamina* is the inferior medullary velum,⁷ whose fibers pass into the nodule and flocculi. The *superior lamina* forms the superior medullary velum and three pairs of cerebellar peduncles.

Superior Peduncles.—Two bundles of fibers make up the

(3) *Corpus medullare*.

(4) *Laminæ medullares*.

(5) *Fastigium*.

(6) *Recessus lateralis ventriculi quarti*.

(7) *Velum medullare posterius*.

superior peduncles.⁸ They are afferent and efferent. *First*, the fibers to the cerebrum which are axones of cell-bodies situated chiefly in the corpus dentatum, but which are combined with a few axones of Purkinje's cells. This group of fibers ends chiefly in the opposite red nucleus, where the second group rises. The *second group*, rising in the opposite red nucleus, ends in the corpus dentatum. The greater number of fibers in the superior peduncles decussate in the tegmentum. The *superior medullary velum*⁹ arches over the fourth ventricle between the superior peduncles. It is composed chiefly of longitudinal fibers running between the worm and the cerebrum. One distinct bundle, derived from the spinal cord, passes through it to the worm. It is the antero-lateral ascending cerebellar tract (Hoche). The decussating root-fibers of the fourth nerve (trochlear) course transversely through the superior velum, also certain commissural fibers of the hind-brain.

Middle Peduncles.—They pass to the pons and form its ventral and middle transverse fibers. They also are both afferent and efferent. The fibers of the middle peduncle¹⁰ rise, *first*, from every part of the cerebellar cortex. They cross one another in the peduncle, fibers from the anterior part of the hemisphere running to the posterior portion of the pons, and vice versa. Passing toward the median line, the fibers end in the nuclei pontis and nuclei of the formatio reticularis on both sides of the raphe. *Second*, the remaining fibers are axones of cell-bodies situated mainly in the opposite nucleus pontis. The latter form a segment in the indirect motor paths contained, above the pons, in the medial and lateral fifths and the intermediate bundle of the crusta

(8) Brachia conjunctiva.

(9) Velum medullare anterius.

(10) Brachium pontis.

Collaterals from both groups of fibers ascend and descend in the pons. They run upward with both crustæ, but chiefly with the opposite one; and they accompany the fillet and posterior longitudinal bundle of the same side to the nuclei of the third, fourth and sixth cranial nerves.

The Inferior Peduncles can be traced to the upper part of the hemispheres and to the worm. Inferiorly, they become the restiform bodies¹¹ of the medulla oblongata. The bundles of component fibers are very numerous: (1) The direct cerebellar tract, whose origin is in Clark's column of the cord and termination in the superior worm. (2) The external arciform fibers of the medulla (posterior and anterior), which rise in the nucleus gracilis and nucleus cuneatus and end in the vermis superior, the former on the same and the latter on the opposite side. (3) The acustico-cerebellar tract from the nuclei of the vestibular nerve to the opposite nucleus fastigii and nucleus globosus. (4) A bundle from the lateral nucleus of the medulla to the cerebellar cortex on the same side. (5) The antero-lateral, descending cerebellar tract, which runs from the cortex of the cerebellum to the anterior gray horn in the cord. (6) The internal arciform fibers to the opposite lower olive, the cerebello-olivary tract.

Most of the fibers which leave the cerebellum by way of the middle and inferior peduncles are axones of Purkinje's cells; they connect the cerebellum with the motor nuclei of cranial and spinal nerves.

II. COMMISSURAL FIBERS.

The cerebellar hemispheres are joined by transverse fibers, of which there are two sets, namely: One near the anterior end of the worm beneath the central lobe, and the other at the posterior end of the worm.

(11) *Corpus restiforme* (sing.).

III. ASSOCIATION FIBERS.

Antero-posterior fibers join the cerebellar laminae to one another. They arch beneath the fissures, and remain in one hemisphere.

BLOOD SUPPLY OF CEREBELLUM.

Three pairs of arteries supply the cerebellum. The superior cerebellar, from the basilar, supplies all the superior surface except a narrow zone at the posterior border; and the anterior inferior cerebellar, also from the basilar, and the posterior inferior cerebellar, from the vertebral, supply the inferior surface and the posterior part of the superior surface.

The **superior cerebellar artery**, rising from the basilar just behind the posterior cerebral, from which it is separated by the oculomotor nerve, winds dorsally around the mid-brain and distributes branches to the geniculate bodies, corpora quadrigemina, velum interpositum and dorsal surface of the pons, besides the vermis superior cerebelli and nearly all the superior surface of the hemisphere. It anastomoses with both the inferior cerebellar arteries. The **anterior inferior cerebellar** is given off by the basilar near its origin. It runs lateralward, behind the flocculus, keeping close to the anterior border of the hemisphere. In its course it passes anterior to the abducent nerve and posterior to the facial and auditory nerves. The **posterior inferior cerebellar artery** is the largest branch of the vertebral and is given off just before the vertebral arteries unite and form the basilar. Passing first between the root-bundles of the hypoglossal nerve and then between those of the spinal accessory and vagus nerves, the posterior inferior cerebellar artery bends at a right angle backward and runs between the medulla and the cerebellar hemisphere where it divides into an internal and an external

branch. The *Internal branch* follows the sulcus vallecule and gives branches to the medial part of the hemisphere and the vermis inferior. It anastomoses with its fellow of the opposite side. The *External branch* runs lateralward from the posterior cerebellar notch over the inferior surface of the hemisphere; its terminal branches wind around the posterolateral border and communicate with the superior cerebellar artery on the upper surface of the hemisphere. The undivided trunk of the posterior inferior cerebellar artery gives small branches to the medulla oblongata and supplies the choroid tela of the fourth ventricle.

Three sets of veins carry the blood away. The *superior cerebellar veins* pour their blood against the current into the straight sinus. The *inferior cerebellar veins* empty in like manner into the lateral sinus; and the *lateral cerebellar veins*, into the superior petrosal sinus.

The trunks of both veins and arteries ramify in the pia mater.

Lymphatics.—There are no lymphatic vessels in the cerebellum, but the perivascular lymph spaces carry out the lymph and pour it chiefly into the subarachnoid space.

SECTION II. THE PONS VAROLII.

The pons is the ventral part of the hind-brain, the cerebellum being its dorsal portion. The pons is developed from the floor of the epencephalon. It is so named because it forms the connecting link, or bridge, between the mid-brain, above, and the cerebellum and medulla oblongata, below; between the medulla and cerebellum, and between the two cerebellar hemispheres.

In *shape* the pons is roughly cylindrical. A coronal section of it resembles an inverted transverse section of the penis.

It has a broad basal or ventral part¹² and a narrow dorsal portion.¹³

Size.—The pons is about one inch long. It is a little broader than long, and measures an inch, dorso-ventrally.

Position.—It rests in the anterior end of the groove which extends from the foramen magnum to the dorsum sellæ, and lies between and ventral to the hemispheres of the cerebellum.

Superiorly, it joins the mid-brain; and, behind, it is continuous with the medulla oblongata.

Surfaces of the Pons.—The pons has four surfaces, viz., superior (attached); inferior (attached); ventral (free), and dorsal (free); and two borders, namely, right and left lateral, continuous with the middle peduncles of the cerebellum.¹⁴

The *Superior and Inferior Surfaces* are made by section, and are directly continuous with the mid-brain above and the medulla below.

Ventral Surface (Tuber annulare).—The ventral surface of the pons looks downward and forward, and rests on the sphenoid bone behind the sella Turcica. It is divided into lateral halves by the sulcus basilaris, containing the basilar artery. Antero-posteriorly, the surface is slightly convex, and is markedly so from side to side. It shows transverse striations, which converge laterally, due to the fibers that form it, and enter the middle peduncles of the cerebellum. The fibers of the tuber annulare are not exactly transverse in direction. Those at the anterior end of the pons are arched, convex forward, and form a rounded margin, which covers the lower part of the crustæ of the mid-brain; at the posterior extremity of the pons, the fibers are convex backward

(12) Pars basilaris pontis.

(13) Pars dorsalis pontis.

(14) Brachia pontis.

and partially conceal the pyramids of the medulla oblongata. The two roots of the 5th nerve (trifacial)¹⁵ issue from the lateral border (Henle) of this surface, a little in front of the middle.

The Dorsal Surface of the pons is concealed by the cerebellum. *Medial Portion.*—It presents a median longitudinal elevation due chiefly to the *superior peduncles* of the cerebellum¹⁶ and *valve of Vieussens*.¹⁷ The peduncles converge forward and upward and run beneath the inferior quadrigeminal bodies of the mid-brain. The valve spans the interval between the peduncles and forms the floor of the slight groove which separates them. A low and narrow ridge runs from the corpora quadrigemina down the middle of the valve. It is called the *frenulum*. In the superior medullary velum (or valve of Vieussens), the 4th cranial nerve (n. trochlearis) decussates and issues from its lateral portion on each side of the frenulum.

Lateral Portion.—Each lateral portion of the dorsal surface is depressed. On this depressed portion, the *lateral fillet*¹⁸ produces a low ridge which, trending upward and toward the median line, winds over the anterior end of the superior peduncle and terminates at the inferior corpus quadrigeminum. This ridge is joined by a much slighter one, which runs from the valve outward and forward over the posterior end of the superior peduncle; it is caused by a bundle of fibers from the antero-lateral ascending cerebellar tract.

WHITE MATTER OF THE PONS.

The pons is composed of transverse and longitudinal white fibers and of gray matter. The transverse fibers are found in

(15) Nervus trigeminus.
(16) Brachia conjunctiva.

(17) Velum medullare anterius.
(18) Lemniscus lateralis.

the ventral portion¹⁹ of the pons; the longitudinal, in the dorsal part,²⁰ and also intersecting the middle transverse fibers.

TRANSVERSE FIBERS OF PONS.

The transverse fibers form three consecutive layers in the ventral area of the pons, viz., the ventral, the middle, and the dorsal layer. They lie one upon another.

The **Ventral Transverse Fibers** (superficial transverse)²¹ form a thin layer constituting the tuber annulare, or ventral surface of the pons.

Middle Transverse Fibers (ventral deep-transverse).— These form a thick lamina dorsal to the ventral transverse fibers and in contact with the ventral lamina. They are intermingled with longitudinal fibers running from the crustæ (middle three-fifths) down to the pyramids of the medulla oblongata and with fibers of the fronto-pontal, intermediate and temporo-pontal tracts which end in the pons. In the meshes between the intersecting fibers are masses of gray matter called the *nuclei pontis*. The middle and ventral transverse fibers form the middle cerebellar peduncles.²² They are made up (1) of axones of Purkinje's cells which end in the nuclei pontis and nuclei of the formatio reticularis on both sides of the pons, and (2) of axones of cell-bodies in these same nuclei, especially the nuclei pontis, which terminate in the cerebellar cortex of the opposite side.

The **Dorsal Transverse Fibers** (dorsal deep-transverse) compose a thin layer on the dorsum of the middle transverse and pyramidal fibers, separating them from the formatio reticularis. The dorsal transverse lamina is best marked in the posterior part of the pons, where it is called the *trapezium*.

(19) Pars basilaris pontis.

(20) Pars dorsalis pontis.

(21) Fibræ pontis superficiales.

(22) Brachia pontis.

The trapezium forms the boundary between the dorsal and ventral areas of the pons. It rises chiefly from the nuclei of the cochlear nerve and, after decussating in the raphe, is continued up in the lateral fillet to the corpus quadrigeminum inferius. A few fibers join the tract directly from the cochlear nerve. The nuclei of the trapezium, of superior olive and of lateral fillet form way-stations for a number of its fibers. The trapezium and lateral fillet form the second stage in the auditory conduction path, the auditory impulses having reached the trapezium and lateral fillet through the auditory nerve are continued (a) through the brachium inferius and (b) the acoustic radiations to the temporal cortex.

LONGITUDINAL FIBERS OF PONS.

Like the transverse, the longitudinal fibers of the pons are arranged in three distinct laminae, viz., the ventral, the middle and the dorsal. The last two are in contact with one another in the dorsal area²³ of the pons; but the ventral lamina is separated from the middle by the trapezium.

The Ventral Longitudinal Fibers (ventral deep-longitudinal) are the motor fibers of the crustæ. The pyramidal fibers²⁴ run from the middle three-fifths of each crista down through the middle transverse layer of the pons to the pyramids of the medulla oblongata. They form a thick bundle on either side of the median line, which presses down the ventral transverse fibers and produces the sulcus basilaris. The ventral longitudinal fibers are to a small extent made up of fibers, probably collaterals, from the middle cerebellar peduncles (chiefly from the opposite one) which run both toward the cerebrum and the spinal cord. The *nuclei pontis*, one on either side, are situated among them. The pyramidal

(23) Pars dorsalis pontis.

(24) Fasciculi longitudinales pontis (pyramidales).

tracts diminish in size during their descent, because of the fibers which leave them to decussate and end in the nuclei of motor cranial nerves.

Middle Longitudinal Fibers (dorsal deep-longitudinal).—These are contained in the *formatio reticularis*. They are dorsal to the trapezium, and lie in the floor of the fourth ventricle. *Laterally*, the middle lamina is in contact with the dorsal longitudinal layer, the superior peduncles of the cerebellum lying directly on it; but, *medially*, the two laminae are separated from one another by the fourth ventricle. The middle longitudinal fibers are mingled with many oblique fibers; and, thus, there is produced the net-like arrangement suggesting the name, *formatio reticularis*. The *formatio reticularis* of the pons is continued in the medulla oblongata. Considerable gray matter is found in the meshes, especially in the part next the fourth ventricle. The latter contains the nuclei of the fifth, sixth and seventh cranial nerves and a part of the nucleus of the eighth nerve. The remaining gray matter constitutes the nuclei of the *formatio reticularis*, etc. In the *formatio reticularis* are contained six distinct bundles of longitudinal fibers: The fillet, the anterior and the posterior longitudinal bundle, the olivary bundle, the crossed descending tract from the red nucleus, and in the lower part of the pons the ascending root of the trifacial nerve. According to Hoche, also, the antero-lateral ascending cerebellar tract (N. 9, Add.).

(1) *The Fillet*²⁵ *Fibers* form a broad flat bundle next the trapezium. The width of the bundle is almost equal to half the transverse axis of the pons; the lateral fillet lies just beneath the dorsal surface, and the medial runs along the raphe. Anterior to the pons we have the medial, superior

(25) Lemniscus—L. Lateralis, L. Medialis, L. Superior.

and lateral fillets, which have been traced through the tegmentum of the mid-brain to the optic thalamus and the superior and inferior quadrigeminal bodies.

(2) *Posterior Longitudinal Bundle*.²⁶—It is a small fasciculus situated near the raphe, and just beneath the gray matter in the floor of the fourth ventricle. It is continued down into the anterior column of the spinal cord without decussation. Both ascending and descending fibers are found in it. Its longest ascending fibers rise in the anterior cornu of gray matter in the spinal cord. Fibers are added to it from the sensory nuclei of cranial nerves, and from the cerebellum by way of the middle peduncles. Along its course fibers leave it and end in the motor nuclei of cranial nerves, especially the third and fourth. The bundle ends in the hypothalamic region. Many of its fibers decussate through the raphe in the medulla, pons and mid-brain; the remainder cross through the posterior commissure. Motor fibers run through the posterior longitudinal bundle from the nucleus of the sixth to the third nerve and from the motor oculi to the facial nerve.

(3) *The Anterior Longitudinal Bundle*²⁷ descends from the superior quadrigeminal body ventral to the posterior longitudinal fasciculus, through the mid-brain, pons and medulla; and, in the cord, it runs along the apex of the anterior cornu of gray matter, in which it terminates, chiefly in the cervical region. It is the pupillo-dilator tract.

(4) *The Olivary Bundle*²⁸ is an ascending tract. It begins at the dorsal surface of the inferior olive, from which it probably rises. It ascends through the formatio reticularis of the medulla, pons and mid-brain, and, according to Flech-

(26) Fasciculus longitudinalis medialis.

(27) Fasciculus ventralis.

(28) Fasciculus tegmenti centralis.

sig, ends in the globus pallidus of the lenticular nucleus, though certain fibers may continue through the lenticular loop, without interruption, to the cortex. The olivary bundle is probably the second stage in the afferent tract of which the triangular tract of Helwig is the first stage. In the posterior part of the pons, the olivary bundle lies on the lateral part of the trapezium, between it and the fillet. Higher up it is in the center of the *formatio reticularis*, hence its synonym, *central tegmental tract*.

(5) *Crossed Descending Tract of the Red Nucleus*.—It is found in the pons among the medial fibers of the lateral fillet. It runs from the red nucleus through the raphe, in the upper part of the mid-brain; and, from there, descends to the lumbar region of the spinal cord (Barker). Its fibers gradually disappear in the lateral horn and center of the crescent of gray matter (see *Mid-Brain*, p. 65).

(6) *Ascending Root of the Trifacial or Fifth Nerve* (inferior sensory root).²⁹—In the lower half of the pons is seen a small bundle of fibers which begins near the tubercle of Rolando in the medulla oblongata. It runs forward close to the lateral part of the floor of the fourth ventricle and joins the superior sensory root ventral to the superior cerebellar peduncle.

The Dorsal Longitudinal Fibers (superficial longitudinal) form the medial portion of the dorsal surface of the pons. They bound laterally and form the roof of the superior half of the fourth ventricle. The dorsal longitudinal fibers compose the *superior peduncles* of the cerebellum and the *valve of Vieussens*. The peduncles rest on the *formatio reticularis*. Between them the valve arches over the fourth ventricle (see *Cerebellum*, pages 102, 114).

(29) *Tractus spinalis nervi trigemini*.

GRAY MATTER OF THE PONS.

In the pons gray matter is found in two situations: (1) In the interstices between the middle transverse and ventral longitudinal fibers, the nuclei pontis; and (2) in the formatio reticularis, the floor of the fourth ventricle.

The **nuclei pontis** are masses of gray matter, on either side the raphe, containing the bodies of multipolar nerve cells. They receive many fibers from the middle peduncles of the cerebellum and each contributes many to the opposite peduncle. The nucleus pontis of each side receives the terminals of the descending tracts which form the inner and outer fifths of the crusta and the intermediate bundle of the same, and thus connects these tracts with the cerebellum.

The **gray matter of the formatio reticularis** includes the superior olive; the nuclei of the trapezium; the nuclei of the formatio reticularis; and the nuclei of the fifth, sixth and seventh cranial nerves, and a part of the dorsal nucleus of the auditory nerve. The nerve nuclei will be further noticed in the description of the fourth ventricle.

*Superior Olivary Nucleus.*³⁰—It is situated in the lateral part of the formatio reticularis in the dorsal portion of the trapezium. It contains small bodied nerve cells; and, in this respect, resembles the olive of the medulla. In size it is microscopic. The superior olive constitutes a subordinate relay in the auditory path, receiving fibers from the cochlear nuclei of both sides and contributing fibers to both lateral fillets. In their course to the fillets, fibers of the auditory path form the trapezium (N. 10, Add.).

Nuclei of the Formatio Reticularis.—These nuclei are scattered in the reticular formation from the medulla to the superior quadrigeminal bodies. They contain the bodies of

(30) Nucleus olivaris superior.

large multipolar cells, hence the name adopted by Koelliker, Nucleus magnocellularis diffusus. The nuclei are interposed in the frequently interrupted tracts of the reticular formation. Their neurones, which are both ascending and descending in conduction, send their axones toward the raphe, where they cross to the opposite side. Axones of Purkinje's cells and collaterals from the nuclei of cranial nerves terminate in relation with them.

Lesions in the pons are usually attended by crossed paralysis. The paralysis and anesthesia of parts supplied by spinal and by bulbar cranial nerves are on the opposite side, but the fifth, sixth and seventh cranial nerves of the same side as the lesion are apt to be involved. Conjugate deviation occurs when the nucleus of the sixth nerve is affected; and strabismus when the root fibers, but not the nucleus, are involved. The strabismus is external if the lesion be irritative and internal if the root fibers are destroyed. Destructive lesion in the nucleus of the seventh nerve causes inferior paralysis of the face, the frontalis, pyramidalis nasi, corrugator supercilii and orbicularis palpebrarum not being affected. Complete facial paralysis occurs if the root-fibers of the facial nerve be destroyed in the genu or beyond it.

BLOOD SUPPLY OF PONS.

The vertebral, basilar, posterior cerebral and superior cerebellar arteries supply the pons. The short and transverse branches of the basilar artery furnish the greater portion of blood to the ventral area of the pons, while the superior cerebellar artery supplies the valve of Vieussens³¹ and the superior cerebellar peduncles.³² The branches enter the median raphe, also the substance of the pons elsewhere, especially along the nerve roots, and run at right angles to the surface into it.

(31) Velum medullare anterius.

(32) Brachia conjunctiva.

CHAPTER VI.

THE AFTER-BRAIN, OR MEDULLA OBLONGATA.

Situation.—The medulla oblongata is the distal, or caudal, part of the brain. It may be regarded as the expanded intracranial portion of the spinal cord, hence the synonym, *spinal bulb*. It occupies the basilar groove of the occipital bone, posterior to the pons; and is continuous with the spinal cord through the foramen magnum. Dorsally, it is in part concealed in the valley of the cerebellum. The vertebral arteries wind forward around it, and form the basilar at its junction with the pons.

Size.—The medulla is about an inch long, and dorso-ventrally, is a half-inch thick. Its width at the lower end is a half-inch, also. At the upper extremity it measures from three-quarters of an inch to one inch in width.

Its **shape** resembles an inverted frustum of a cone flattened dorso-ventrally at the base. The truncated apex of the frustum, which is nearly circular in outline, is continuous with the spinal cord; and the flattened base joins the pons Varolii. On the ventral surface, a transverse groove marks the boundary between the medulla and pons. The medulla oblongata is a bilateral organ composed of symmetrical halves. In the interior, the two halves are united by both gray and white matter in the raphe, but on the surface they are partially separated by the **anterior** and the **posterior median fissure**.¹ These fissures are continuations of the same

(1) Fissura mediana anterior, posterior.

in the spinal cord, but neither extends the whole length of the medulla. The anterior median fissure is interrupted in the lower part of the medulla by the crossing of two large tracts of fibers, forming the decussation of the pyramids; while only through the lower half of the medulla does the posterior median fissure extend.

Origin.—The medulla oblongata is developed from the metencephalon (myelencephalon) of the embryo. The metencephalic floor and walls thicken and form the greater part of the medulla. Inferiorly, the roof undergoes some thickening; but it stretches out into a single layer of epithelium, superiorly, which is continuous at its upper end with the inferior medullary velum of the cerebellum.

Ventricle.—The common cavity of the fourth and fifth brain vesicles persists in the mature brain as the fourth ventricle. The fourth is, therefore, the ventricle of the adult hind-brain and after-brain.

SURFACES.

The Medulla Oblongata presents four surfaces: The ventral, dorsal and two lateral, separated by the ventro-lateral and dorso-lateral grooves. In the upper medulla, the surfaces are clearly defined; but they become less distinct as they descend to the posterior and nearly circular extremity.

*The Ventro-lateral Groove*² separates the ventral from the lateral surface, and is in line with the exits of the anterior roots of the spinal nerves. No corresponding groove exists in the cord. From the ventro-lateral groove issue the roots of the hypoglossal nerve. The abducent (or sixth) nerve rises in line with it from the transverse groove between the pons and the medulla.

Dorso-lateral Groove.—The postero-lateral fissure of the

(2) Sulcus lateralis anterior.

spinal cord, continued into the medulla, becomes the dorso-lateral groove.³ Through the fissure in the cord, pass the posterior roots of the spinal nerves; from the groove in the medulla, rise the accessory root of the eleventh and the roots of the tenth and ninth cranial nerves. The seventh and eighth cranial nerves rise together at the anterior end of the groove. The last two come out between the medulla and pons. The dorso-lateral groove is not parallel with the axis of the medulla, but bends outward and forward as it ascends. Inferiorly, it is obliterated for a short distance by the crossing of the direct cerebellar tract from the lateral to the posterior surface. This groove separates the lateral from the dorsal surface.

The Ventral Surface⁴ of the medulla, bounded on either side by the ventro-lateral groove, extends from the transverse sulcus behind the pons down to the spinal cord. It is made up of symmetrical halves united, below, by the decussation of the crossed pyramidal tracts; but separated, above, by the anterior median fissure, which terminates at the posterior end of the pons in a blind foramen (foramen cæcum of Vicq d'Azyr). On either side of the median fissure, the ventral surface presents a fusiform eminence, most prominent near the pons, called the *pyramid*. Two tracts of longitudinal fibers form the pyramid, viz.: The crossed pyramidal tract, next the anterior median fissure; and the uncrossed (direct) pyramidal tract, which runs next the ventro-lateral groove. Transverse fibers are also seen crossing the pyramid from within outward. A small bundle runs near the pons, called the *ponticulus* of Arnold; and a more or less continuous sheet of fibers, the *anterior external arciform fibers*, emerges from the anterior median fissure and winds around the me-

(3) Sulcus lateralis posterior.

(4) Facies anterior.

dulla to the dorsal surface, where its fibers enter the restiform body.

The ventral surface is identical with the surface of the two anterior areas of the medulla.

Lateral Surface.—There are a right and a left lateral surface.⁵ Each is bounded by the ventro-lateral and the dorso-lateral grooves; and is inclosed between the roots of the hypoglossal nerve, ventrally, and those of the ninth, tenth and the accessory portion of the eleventh, dorsally. Lateral surface is synonymous with surface of the lateral area. The lateral surface is formed above by the *olivary body*,⁶ below, by the *lateral tract*; and winding backward over both, the *anterior external arciform fibers*.

The Olivary Body is an elongated eminence, a half-inch in length, situated just behind the pons. It is produced by the olivary nucleus in the lateral area of the medulla; and, superficially, is composed of fibers from the antero-lateral ground bundle of the lateral tract.

*Lateral Tract.*⁷—It is made up of three great bundles of fibers: The *antero-lateral ground bundle*,⁸ which, splitting into a superficial and a deep lamina, incloses the olivary nucleus; the *antero-lateral descending cerebellar tract*,⁹ running down the ventro-lateral groove; and the *antero-lateral ascending cerebellar tract*,⁹ which runs up the dorso-lateral groove. At the junction of the medulla with the spinal cord the *direct cerebellar tract* passes from the lateral to the dorsal surface. The *anterior external arciform fibers*,¹⁰ running from the ventral surface backward to the restiform body, may

(5) *Facies lateralis.*

(6) *Oliiva.*

(7) *Funiculus lateralis.*

(8) *Fasciculus proprius antero-lateralis.*

(9) *Fasciculus antero-lateralis superficialis (descendens and ascendens).*

(10) *Fibræ arcuatæ externæ.*

be so numerous as to conceal the lateral tract and lower part of the olive.

The Dorsal Surface of the medulla¹¹ comprises all the surface inclosed between the diverging dorso-lateral grooves. It embraces the surfaces of the two posterior areas of the medulla.

Inferiorly, it is divided into lateral halves by the posterior median fissure,¹² and presents four bundles of fibers in each half. From the fissure outward they are as follows: The fasciculus gracilis, fasciculus cuneatus, fasciculus of Rolando, and the direct cerebellar tract.

The *fasciculus gracilis* is a continuation of the postero-median column of the spinal cord, and the *fasciculus cuneatus* and *fasciculus of Rolando* are in direct continuity with the postero-lateral column of the cord. These three bundles leave the surface and end in the gracile, cuneate and Rolandic nuclei of the medulla. The *direct cerebellar tract* is continued up from the lateral column of the spinal cord. Remaining on the surface, it runs up to the cerebellum through the restiform body.

Superiorly, the dorsal surface, on either side, is formed by a large rounded band of fibers, the *restiform body*.¹³ Of the superficial fibers in the medulla, the direct cerebellar tract, the antero-lateral descending cerebellar tract and the anterior and posterior external arciform fibers are continued into the restiform body; and, as we have already learned, the restiform body contains, in addition to the above three tracts, the acustico-cerebellar tract, the tract from the lateral nucleus and the cerebello-olivary tract. It is also called the inferior peduncle of the cerebellum. A single layer of flattened *epithelial cells* stretches between the two restiform bodies, and roofs over the posterior part of the

(11) *Facies posterior.*

(12) *Fissura mediana posterior.*

(13) *Corpus restiforme.*

fourth ventricle. It is the roof epithelium. By it the dorsal surface is completed.

The Roof Epithelium, seen in the mid-dorsal surface of the medulla, is of triangular shape; its base is attached to the inferior medullary velum of the cerebellum; its apex, which is directed downward, covers the inferior angle of the fourth ventricle; and, laterally, it is attached to the clava, the cuneate tubercle and the restiform body. The line of attachment to the restiform body runs, first, obliquely upward and outward; and then, transversely outward, inferior to the lateral recess. The borders of the epithelium become thickened by the addition of neuroglia, and are in continuity with the ependyma of the ventricle. The thickened apex of the epithelial lamina is called the *obex*. With the pia mater investing it, termed the *inferior choroid tela*,¹⁴ this roof epithelium is perforated in the median line near its apex by a foramen, the foramen of Magendie,¹⁵ and over each lateral recess by the foramen of Key and Retzius.¹⁶ These foramina establish communication between the subarachnoid space and the ventricle. On either side of the median line, a longitudinal invagination of the epithelial lamina dips into the ventricle and is occupied by a vascular fold of pia mater. The latter constitutes the *choroid plexus*¹⁷ of the fourth ventricle. If the roof epithelium be torn away, as it usually is with the pia, a rough line of separation is seen winding over the restiform body. That line is the *ligula*. Two layers of ependyma form it.

WHITE MATTER OF MEDULLA.

The medulla is made up of white and gray matter, which together bound ventrally and laterally the inferior part of

(14) *Tela choroidea ventriculi quarti.*

(15) *Apertura mediana ventriculi quarti.*

(16) *Aperturæ laterales ventriculi quarti.*

(17) *Plexus choroideus ventriculi quarti.*

the fourth ventricle and surround the upper extremity of the sixth ventricle.

For the most part the white matter of the medulla is continuous with the longitudinal fibers of the pons and spinal cord, above and below, respectively; and with the inferior peduncles of the cerebellum, dorso-laterally. To these add the bulbar roots of the eighth to the twelfth cranial nerves to complete the list.

Formatio Reticularis.—Superficially, the white matter is collected into great bundles of fibers, such as the *pyramids*, *lateral tracts* and *restiform body*; but, in the deep parts of the medulla, the white matter enters into a great network called the *formatio reticularis*, which has gray matter in its meshes and embraces all the medulla between the ventricular gray matter, dorsally, and the pyramid, olivary nucleus, and restiform body, ventro-laterally. The *formatio reticularis* contains many scattered fibers, processes of its intrinsic neurones, which form a frequently interrupted and, for the most part, a crossed ascending and descending tract. It is continuous, above, with the reticular formation of the pons, and, below, with the ground bundles of the spinal cord. It contains several distinct fasciculi of longitudinal fibers of which the following are the best understood: The *posterior* and *anterior longitudinal bundles* and the *descending crossed tract of the red nucleus*, which run throughout the medulla and are continued in the cord; and, in the upper part of the medulla, the *interolivary fillet* (medial and superior), the *olivary bundle* and the *inferior*, or spinal, *root of the fifth cranial nerve*. Transverse and oblique fibers are, likewise, numerous in the reticular formation. They are the *internal arciform fibers*. In the *formatio reticularis* is much gray matter which may be considered as the disintegrated H-shaped column continued up from the spinal cord.

Raphe.—Fibers form only a part of the raphe which unites the lateral halves of the medulla. The raphe is, primarily, a sagittal lamina of neuroglia containing the bodies of nerve-cells and decussating, dorso-ventral and longitudinal fibers: (a) The decussating fibers are chiefly the internal arciform. A few are commissural fibers between the nuclei of the posterior five cranial nerves. (b) Issuing from the anterior median fissure, the dorso-ventral fibers become the anterior external arciform fibers. Traced dorsally, some of them are found continuous with the acoustic striæ in the floor of the fourth ventricle, while the greater number rise from the opposite nuclei gracilis et cuneatus. (c) The origin and destination of the longitudinal fibers are unknown.

The white matter of the medulla is divided by the direction of its fibers into three classes or systems: (1) Transverse fibers; (2) Dorso-ventral fibers; and (3) Longitudinal fibers.

(1) **The Transverse Fibers** of the medulla are chiefly the external and internal arciform fibers.¹⁸ The *anterior external arciform fibers*¹⁹ rise in the nucleus gracilis and nucleus cuneatus of the opposite side, decussate in the raphe and issue from the anterior median fissure and ventral surface of the medulla, whence they have been traced over the surface to the restiform body. Perhaps a few are interrupted in the external arciform nucleus. The *posterior external arciform fibers*¹⁹ rise from the same nuclei and enter the cerebellum, through the inferior peduncle, without decussation. Both groups of fibers end in the cortex of the vermis cerebelli superior. The *internal arciform fibers* are contained in the formatio reticularis. They are disposed in two groups, viz.:

(18) *Fibræ arcuatæ.*

(19) *Fibræ arcuatæ externa anterior, posterior.*

Those of the sensory decussation, and those of the olivary peduncle.

The fibers of the *Sensory Decussation*²⁰ rise chiefly from the nucleus gracilis and nucleus cuneatus. Bending ventrally through the posterior horn of gray matter, they decussate through the median raphe; and, then, the greater number run forward toward the cerebrum as the *interolivary fillet* (medial and superior fillets); the remainder constitute the deep part of the *anterior external arciform fibers*. The sensory, or fillet, decussation is nearer the pons and dorsal to the decussation of the pyramids.

The *Olivary Peduncle* is a sheet of fibers extending between the two olivary nuclei of the medulla. It is the inferior portion of the *cerebello-olivary tract*.²¹ It is composed of axones from Purkinje's cells. Descending to the medulla through the inferior cerebellar peduncle, it pierces the olive, crosses through the raphe and terminates in the olivary body of the opposite side. The cerebello-olivary tract connects the cerebellar hemisphere with the opposite nucleus.

(2) **The Dorso-ventral Fibers** of the medulla are found in three situations: (a) In the raphe, (b) between the anterior and lateral areas, and (c) between the lateral and posterior areas.

(a) The dorso-ventral fibers of the raphe are the *anterior external arciform fibers*. These can be traced to the cerebellum through the restiform body. Their origin is chiefly in the nuclei gracilis et cuneatus. Some of them seem to be interrupted in the arciform nuclei on the ventral surface of the pyramids. The root-bundles of the eighth to the twelfth cranial nerves constitute the remaining groups of dorso-ventral fibers. By them the medulla is divided into areas.

(20) Decussatio lemniscorum.

(21) Fibræ cerebello-olivares.

(b) *The root-bundles of the hypoglossal nerve*²² run from the ventricular gray matter, near the median line, ventro-laterally to the ventro-lateral groove, where they emerge. Inclosing between them and the raphe, the *anterior area*, they also separate it from the *lateral area*. The anterior and lateral areas are bounded dorsally by the thick sheet of gray matter in the floor of the fourth ventricle.

(c) *The medial root*²³ *of the auditory nerve*, the roots of *glosso-pharyngeal*²⁴ and *vagus*²⁵ and the *accessory root of the eleventh*²⁶ form the third group of dorso-ventral fibers. From the dorso-lateral groove, which is their superficial origin, they may be traced through the medulla to ventricular gray matter external to the column of cells from which the twelfth nerve rises. They separate the *lateral* from the *posterior area*. The posterior area comprises everything dorsal to the above roots of the eighth to eleventh cranial nerves. It thus includes the gray matter in the floor of the fourth ventricle.

(3) **Longitudinal Fibers.**—In the medulla, the longitudinal fibers are chiefly continuations of the same in the spinal cord. They can be best located by reference to the three areas bounded by the above dorso-ventral fibers, namely, Anterior, Lateral and Posterior areas.

ANTERIOR AREA.

The anterior area of the medulla lies between the raphe and the roots of the hypoglossal nerve, and between the ventral surface and the gray matter in the floor of the fourth ventricle. Excepting that part forming the crossed pyramidal tract and the interolivary fillet, it is continued in the

(22) Nervus hypoglossus.

(23) Radix nervi vestibularis.

(24) Radix nervi glossopharyngel.

(25) Radix nervi vagi.

(26) Radix cerebri n. accessorii.

anterior column of the spinal cord. It is naturally divided into a ventral and a dorsal part, or the region of the pyramid²⁷ and the region of the *formatio reticularis alba*.

The *Pyramid*, with the arciform nucleus imbedded in it, and the arciform fibers winding over it, occupies the **ventral portion** of the anterior area. It is the continuation of the pyramidal tract and is composed of the axones of cortical cells in the Rolandic region of the cerebrum. The pyramidal tract diminishes in size as it descends through the pons and medulla, because some of its fibers terminate in ramifications about the cells of cranial nerve-nuclei. In the lower part of the medulla, the pyramid breaks up into the *uncrossed* (direct) *pyramidal tract*²⁸ (10 to 20 per cent of the pyramid), which descends along the anterior median fissure in the same side of the spinal cord; and the *crossed pyramidal tract*²⁹ (80 to 90 per cent of the pyramid), which, after decussating with its fellow through the anterior median fissure, runs down in the lateral column of the opposite side of the cord. The fibers of the direct tract cross in succession to the opposite side of the cord, through the anterior, or white, commissure; and there, with the fibers of the crossed pyramidal tract, terminate in fibrillar end-tufts about the cell-bodies in the anterior cornu of gray matter. Thus the pyramid forms a crossed cerebral tract for efferent (motor) cranial and spinal nerves. A small number of pyramidal fibers (20 per cent, Marchi) descend in the lateral column of the cord without decussation. They account for the weakness on the well side, and for slight motion on the paralyzed side, which are commonly observed in hemiplegia. (N. 15, Add.)

(27) *Pyramis medullæ oblongatæ.*

(28) *Fasciculus cerebro-spinalis anterior (ventralis).*

(29) *Fasciculus cerebro-spinalis lateralis.*

The dorsal part of the anterior area is occupied by the *formatio reticularis alba*. Gray matter from the anterior horn is sparsely scattered throughout the reticular formation, but it contains the bodies of very few nerve cells and is of a light color. The *internal accessory olivary nucleus* is imbedded in it near the pyramid and among the fibers of the fillet; and three definite bundles of longitudinal fibers have been demonstrated in it, namely, the Interolivary Fillet, the Posterior and the Anterior longitudinal bundles.

Interolivary Fillet.—Just dorsal to the pyramid in the anterior area of the medulla, is a large bundle of fibers called the interolivary fillet.³⁰ Situated between the inferior olivary bodies, it is on that account called the interolivary fillet. Superiorly, it is continued in the *medial* and *superior fillets*.³¹ The interolivary fillet rises from the nucleus gracilis and nucleus cuneatus of the medulla and crosses through the median raphe in the sensory decussation. As the fillet runs brainward through the reticular formation of the pons and mid-brain, it receives fibers from the terminal nuclei of sensory cranial nerves, except the cochlear nuclei, and from the middle peduncles of the cerebellum. Externally, it is accompanied for a short distance in the pons by the lateral fillet.³² The interolivary fillet is composed of ascending axones which constitute a "cerebral" tract for the afferent, or sensory, fibers of spinal and cranial nerves. It carries ordinary sensations to the superior quadrigeminal body by the superior fillet, and to the optic thalamus by the medial fillet.

The *Posterior Longitudinal Bundle*³³ is a small fasciculus composed of fibers continued up from the anterior column of

(30) Lemniscus interolivaris.

(31) Lemniscus medialis et lemniscus superior.

(32) Lemniscus lateralis.

(33) Fasciculus longitudinalis medialis.

the spinal cord. Its origin is in the anterior horn of gray matter. In the medulla it runs along the median raphe in contact with the ventricular gray matter, and is augmented in the medulla and pons by fibers from the terminal nuclei of the sensory cranial nerves and by fibers from the nuclei of the abducent nerves and the middle cerebellar peduncle. Further forward, some of these fibers and others of spinal origin leave the bundle to end, chiefly on the opposite side, in the motor cranial nerve-nuclei, especially the third. Fibers join the posterior longitudinal bundle in the mid-brain from the motor oculi nucleus, and descend to the genu of the facial nerve. The posterior longitudinal bundle ends, superiorly, in the thalamus or hypothalamus. It associates spinal and cranial nerves with one another, forming part of a reflex arc. It also connects the cerebellum with opposite cranial nuclei and probably conducts ordinary sensation to the thalamus (see Mid-Brain).

Anterior Longitudinal Bundle.—The pupillo-dilator tract³⁴ rises from the superior quadrigeminal body, and is seen just ventral to the posterior longitudinal bundle, which it accompanies all the way down to its chief termination in the ciliospinal centers of the cervical cord (see Mid-Brain).

LATERAL AREA.

Contents: *Superficially*, the antero-lateral ground bundle and antero-lateral descending and ascending cerebellar tracts; *Deeply*, the formatio reticularis grisea. Imbedded in the formatio reticularis are the *nucleus ambiguus*, the *lateral nucleus*, the *olivary nucleus* and *external accessory olivary nucleus*.

The gray matter of the formatio reticularis grisea is a

(34) Fasciculus longitudinalis ventralis.



part of the disintegrated anterior gray horn and, unlike that of the anterior area, it contains the bodies of many large nerve cells.

*Antero-lateral Ground Bundle.*³⁵—The whole lateral column of the spinal cord, except the crossed pyramidal and direct cerebellar tracts, is continued into the lateral area of the medulla. Composed of ascending and descending axones which are commissural and associative for different segments of the spinal cord, the lateral ground bundle ascends into the medulla, and runs in part beneath and in part superficial to the olivary nucleus; beyond the olive, it is continued in the *formatio reticularis grisea* of the medulla and reticular formation of pons and mid-brain. Among the fibers of the antero-lateral ground bundle, ventral to the olive, is the *triangular tract*³⁶ of Helwig and, dorsal to the olive, the *olivary bundle*. The former is believed to end in the olive of the medulla and the latter to rise from it. They are made up of ascending axones and, according to Bechterew, form a functionally continuous tract.

The *Antero-lateral Descending Cerebellar Tract*³⁷ rises in the cerebellar cortex. It forms part of the inferior peduncle of the cerebellum, through which it reaches the medulla. In the lateral area, it descends along the ventro-lateral groove, between the lateral tract and pyramid, to the corresponding area of the cord. It ends in the anterior cornu of gray matter. Fibers from the cerebral cortex are scattered through the bundle in the cord, and it was once regarded as a part of the direct pyramidal tract (N. 11, Add.).

*Antero-lateral Ascending Cerebellar Tract.*³⁷—Taking its

(35) *Fasciculus proprius antero-lateralis.*

(36) *Tractus triangularis (Helwigi).*

(37) *Fasciculus antero-lateralis superficialis, descendens and ascendens.*

origin from the base of the anterior cornu and center of the crescent of gray matter, chiefly on the opposite side of the spinal cord, and crossing through the anterior commissure, it ascends mingled with the fibers of the above descending tract, along the lateral surface of the cord. It runs along the dorso-lateral groove and through the *formatio reticularis* of the medulla and pons; and then, turning backward, it reaches the superior cerebellar worm through the valve of Vieussens. A small bundle of its fibers winds over the superior cerebellar peduncle, and joins the lateral fillet in its course to the inferior quadrigeminal body; that bundle ends in the optic thalamus. The antero-lateral ascending cerebellar tract is closely related to the direct cerebellar tract. Both carry sensory impulses to the vermis cerebelli superior, though from different parts of the cord.

The *Crossed Descending Tract of the Red Nucleus*, running dorsal to the inferior olive, is mingled with the fibers of the antero-lateral ascending cerebellar tract, in the medulla; it continues down the cord, in the dorso-lateral portion of the crossed pyramidal tract, to the lateral horn and center of the gray crescent as far as the first lumbar segment.

POSTERIOR AREA.

The longitudinal fibers of the posterior area form many bundles; and the bundles are different in upper and lower medulla. The *formatio reticularis* is small, but is present throughout this area.

The **lower, or closed, medulla** contains: The Fasciculus gracilis,³⁸ Fasciculus cuneatus,³⁹ Fasciculus of Rolando and Direct cerebellar tract (named from the posterior median fissure outward). In the upper or ventricular medulla are:

(38) Fasciculus gracilis.

(39) Fasciculus cuneatus.

The Restiform body, at the surface; and the Inferior (or spinal) root of the fifth cranial nerve, the Fasciculus solitarius and Fasciculus teres in the interior.

The *Fasciculus Gracilis* is the superior end of the postero-median column (Goll's column) of the spinal cord. Near its extremity it expands and forms the *clava*, and then tapers off and disappears along the side of the fourth ventricle. The clava is due to the nucleus gracilis, in which the fibers of the column end. A small number of fibers continue, without interruption, into the fillet and external arciform fibers. Like the cuneate column, the fasciculus gracilis is composed of ascending branches of the posterior roots of the spinal nerves.

Fasciculus Cuneatus.—It is separated from the posterior median fissure by the gracile bundle; and is the continuation of the greater portion of the postero-lateral column (Burdach's column) of the spinal cord. It ends about the cells of the nucleus cuneatus and accessory nucleus cuneatus, which form the *cuneate tubercle* seen on the surface. A few fibers from this bundle are directly continued in the interolivary fillet, and two small bundles, inclosing the inferior (or spinal) root of the fifth nerve, run as posterior external arciform fibers to the cerebellum. The fibers of the fasciculus cuneatus⁴⁰ are ascending branches of the posterior roots of the spinal nerves.

Fasciculus of Rolando.—From the cuneate column, a small bundle of fibers, taking a more lateral course, runs over and ends within the nucleus of Rolando. It constitutes the fasciculus Rolandi. This column is not separately represented in the spinal cord. The nucleus of Rolando, in which it terminates, is situated beneath the restiform body. The

(40) Fasciculus cuneatus.

nucleus causes a slight eminence on the surface called the *tuberculum Rolandi*.

The *Direct Cerebellar Tract*⁴¹ in the lower medulla crosses the dorso-lateral groove, from the lateral column of the cord to the posterior area of the medulla; it then ascends to form a large part of the restiform body, the inferior peduncle of the cerebellum. It takes its origin from the vesicular column of Clark in the spinal cord. It ends very largely on the opposite side in the superior cerebellar worm.

Restiform Body.—In the **upper medulla**, forming the lateral part of each posterior area, is a large rounded bundle of fibers, called the restiform body.⁴² It is the largest bundle in the medulla. Forming the inferior peduncle of the cerebellum, it terminates in the cerebellar cortex of both the hemisphere and worm. It is made up of the following: Ascending—(1) Direct cerebellar tract; (2) External arciform fibers, anterior and posterior; (3) The acustico-cerebellar tract from the nuclei of the vestibular nerve to the nucleus fastigii and nucleus globosus of the opposite side; and (4) A tract from the lateral nucleus to the same side of the cerebellum. Descending—(1) Antero-lateral descending cerebellar tract, and (2) The cerebello-olivary tract, which ends in the inferior olive opposite to its origin.

The restiform body is inclosed between the *medial* and *lateral roots of the auditory nerve* (eighth).⁴³ Ventral to it and between the roots, is the ventral part of the *cochlear nucleus*; on its lateral surface and among the fibers of the lateral root, is the dorsal, or lateral, part of the same nucleus. The *vestibular nuclei*, the dorso-medial (Schwalbe), the dorso-lateral (Deiter), and the superior (Flechsig and

(41) Fasciculus cerebello-spinalis.

(42) Corpus restiforme.

(43) Nervus acusticus.

Bechterew) are situated dorsal and medial to the restiform body.

The *Inferior Root of the Fifth Nerve*⁴⁴ is the main sensory root. It leaves the superior sensory root in the pons; and, running down in the lateral portion of the posterior area, it terminates ventral to the restiform body about the cells of the nucleus Rolandi.

Fasciculus Solitarius.—The respiratory bundle is a small, round bundle imbedded in the middle of the ventricular gray matter of the posterior area. It forms an accessory sensory root for the ninth and tenth cranial nerves. It descends near the main nuclei of those nerves and along the medial aspect of the posterior horn of gray matter in the cord. It ends on both sides of the median line in the gray matter along its course. The solitary bundle may be traced from the upper part of the medulla down to the eighth cervical segment of the spinal cord (Cajal). Many of its fibers cross through the raphe and, after giving off collaterals to the interolivary fillet, terminate about cells on the opposite side. It is believed to associate the nuclei of the nerves controlling the muscles of respiration, hence the synonym, respiratory bundle.

Fasciculus Teres.—On either side of the median line and extending almost the whole length of the floor of the fourth ventricle, is a lozenge-shaped eminence, called the fasciculus teres. In the pontine part of the ventricular floor, it ends as the eminentia teres. It tapers off to a point in the posterior angle of the ventricle (hypoglossal trigone), and the two fasciculi form the nibs of a pen, the *calamus scriptorius*. It is composed of a flat band of fibers covering the hypoglossal nucleus, posteriorly, and the terete and the abducent nucleus,

(44) Radix spinalis nervi trigemini.

anteriorly. The ascending portion (genu) of the root of the facial (or 7th) nerve and fibers from the formatio reticularis make up the fasciculus teres.

• GRAY MATTER OF MEDULLA.

The gray matter of the medulla is composed, (1) of that continued up from the spinal cord, and (2) of added nuclei not represented in the cord.

(1) By the dilation of the central canal of the spinal cord forming the fourth ventricle, the posterior cornua of the H-shaped column of gray matter are pushed outward to a transverse direction; and the bases of the anterior cornua are brought into the floor of the ventricle. The expansion of the canal, together with the decussation of the crossed pyramidal tracts through the anterior cornua and of the interolivary fillets through the posterior and anterior cornua, disposes the **H-shaped Column** as follows:

Anterior Horn.—From the base of the anterior cornu⁴⁵ is derived a column of cells, the *hypoglossal nucleus*, which lies along the median raphe beneath the fasciculus teres. The head of the anterior cornu is broken up by the crossed pyramidal tract into the *nucleus lateralis*, in the lateral area, near the dorso-lateral groove; and the *nucleus ambiguus*, a large column of cells, coinciding in extent with the inferior olive, and seen as a pear-shaped mass in the lateral area, which is the motor nucleus for the ninth, tenth and accessory part of the eleventh cranial nerves. The lateral nucleus is probably terminal to certain fibers in the antero-lateral ascending cerebellar tract, and it gives rise to a tract of fibers which runs through the restiform body to the cortex in the same side of the cerebellum. The gray matter of the formatio reticularis alba et grisea belongs to the anterior cornu. It is

(45) Columna anterior.

of a light color (alba) in the anterior area, where there are the bodies of but few cells. In the lateral area the cell-bodies are numerous and the color is gray (grisea).

The *Posterior Horn*⁴⁶ is decapitated by the fillet. Its base forms a column of cells, external to the nucleus ambiguus and hypoglossal nucleus, which contains the chief *sensory nucleus* of the *pneumogastric* (10th), of the *glossopharyngeal* (9th), and of a part of the *auditory* (8th) nerves. It forms likewise the *accessory cuneate nucleus*. The head of the posterior horn forms the *nucleus of Rolando*. That nucleus is the inferior sensory nucleus of the trifacial (5th) nerve. In it the so-called ascending root of the fifth terminates. The posterior horn furnishes the gray matter for the reticular formation of the posterior area.

It should be noted that the chief nuclei derived from the H-shaped column lie in the floor of the fourth ventricle.

(2) **Added Nuclei.**—The medullary gray matter not represented in the spinal cord makes up the following nuclei: Nucleus gracilis, nucleus cuneatus, olivary nuclei, and nucleus of external arciform fibers.

Nucleus Gracilis and Nucleus Cuneatus.—They are situated near the dorsal surface of the medulla, beneath the gracile and cuneate bundles, whose fibers terminate in them: they give origin to the interolivary fillet and the anterior and posterior external arciform fibers, the two former constituting the sensory decussation; and they produce, respectively, the *clava* and *cuneate tubercle*.⁴⁷ The *accessory cuneate nucleus* is a continuation of the vesicular column of Clark at the base of the posterior gray horn in the spinal cord. From it a small fasciculus rises which, as posterior

(46) Columna posterior.

(47) Tuberculum cuneatum.

external arciform fibers, runs within the restiform body to the cerebellum. The nucleus gracilis and cuneatus are connected with the posterior cornu, but have no representative in the cord.

*The Olivary Nucleus*⁴⁸ of the medulla (inferior olivary nucleus) is a sinuous, pouch-like collection of gray matter resembling the corpus dentatum of the cerebellum. It is situated near the lateral surface of the medulla and is invested superficially and deeply by fibers from the antero-lateral ground bundle. Its open *hilum* looks medially and is filled with fibers, the cerebello-olivary tract,⁴⁹ which join it to the opposite hemisphere of the cerebellum. On either side of the olivary nucleus is an accessory nucleus—the *internal accessory*,⁵⁰ in the anterior area among the fibers of the inter-olivary fillet, and the *external accessory*,⁵¹ in the lateral area. The olivary nucleus, covered by fibers of the antero-lateral ground bundle, forms the olivary body (oliva). The triangular tract of Helwig, or the olivary bundle of the spinal cord, enters the ventral surface of the olivary body and is believed to terminate in it. The olivary bundle of the brain, the central tegmental tract, appears to rise from the olive in the medulla and to continue the ascending conduction tract to the globus pallidus of the lenticular nucleus (Flechsig). The latter tract is situated just dorsal to the olive. The inferior olive receives two tracts of descending fibers, namely, the vestibulo-olivary and the cerebello-olivary. And according to Koelliker, it gives origin to axones which descend through the lateral column of the spinal cord to the anterior gray cornu.

(48) Nucleus olivaris inferior.

(49) Fibræ cerebello-olivares.

(50) Nucleus olivaris accessorius medialis.

(51) Nucleus olivaris accessorius dorsalis.

Nucleus of the External Arciform Fibers.—There are several masses of gray matter, containing the bodies of nerve cells, scattered among the anterior external arciform fibers. These form a large sheet-like mass on the ventral and medial surface of the pyramid. It is called the arciform nucleus,⁵² and probably constitutes a relay for certain of the anterior external arciform fibers. The arciform nucleus is continuous above with the nucleus pontis.

Lesions in the medulla are very fatal and death usually occurs before any sensory or motor phenomena can be observed; but rarely the pyramidal tracts alone have been involved or the pyramidal tracts together with one or more of the roots of the ninth to the twelfth cranial nerves. In the last case, crossed paralysis is produced, affecting the cranial nerves on the same side and the opposite spinal nerves. In progressive bulbar paralysis the motor nuclei of the medulla are involved as a preliminary to the degeneration of the anterior gray cornu in the spinal cord (Glossolabio-laryngeal paralysis).

(52) Nucleus arcuatus.

CHAPTER VII.

FOURTH VENTRICLE.

The common cavity of the hind-brain and after-brain is the fourth ventricle.¹ The fourth ventricle is contained in the pons and medulla, and is ventral to the cerebellum. It is broadest at the junction of the pons and medulla. Above and below that junction, it contracts to the size of the aqueduct of Sylvius and central canal of the spinal cord, with which it is continuous. Dorsally, it communicates with the subarachnoid space through three foramina (Magendie, and Key and Retzius). It is a gable-roofed chamber with a diamond-shaped floor. The long axis of the floor is parallel with the spinal cord, and extends from the superior extremity of the pons to the middle of the medulla. The transverse axis coincides with the junction of the pons and medulla. Thus the superior triangle of the floor is formed by the pons; the inferior, by the medulla oblongata. The fourth ventricle is lined with ependyma, which is complete throughout, except in the roof of the inferior part, where only the epithelial layer is present.

Boundaries.—The floor is formed by the pons and medulla. The lateral walls (superior triangle) are formed by the superior peduncles² of the cerebellum; and (inferior triangle) by the inferior cerebellar peduncles,³ fasciculus cuneatus and fasciculus gracilis. The roof is formed by the valve of Vieussens,⁴ superiorly; and the inferior medullary

(1) *Ventriculus quartus.*
(2) *Brachia conjunctiva.*

(3) *Corpora restiformia.*
(4) *Velum medullare anterius.*



velum and roof epithelium, inferiorly. The superior and inferior halves of the roof meet at an acute angle and form the tent⁵ of the fourth ventricle. On either side, the tent extends over the restiform body into the lateral recess. The *lateral recess* is a tunnel-like extension of the ventricular cavity. It is bounded, superiorly and ventrally, by the inferior cerebellar peduncle; dorsally, by the inferior medullary velum; and inferiorly, by the roof epithelium. The *choroid plexuses*⁶ of the fourth ventricle invaginate the roof epithelium and hang from the roof in the posterior part of the cavity.

Floor of the Fourth Ventricle.—Because of the origin of one or more roots of the posterior eight (fifth to twelfth) cranial nerves from the floor of the fourth ventricle, it is a very important area. A median groove⁷ forming the long axis of the diamond-shaped floor, divides it in two lateral halves, which are bisected transversely by a number of lines, the acoustic striæ.⁸ The acoustic striæ are produced by bundles of fibers which rise from the cochlear root in part, but chiefly from the cochlear nucleus of the auditory nerve. Plunging into the median groove, the greater number enter the opposite trapezium and lateral fillet; the remainder, according to Koelliker, become anterior external arciform fibers. The acoustic striæ divide each lateral half of the floor into a superior and an inferior triangle.

The *Superior Triangle* of the floor presents the eminentia teres, superior fovea, locus cœruleus and a part of the acoustic trigone.

(5) Fastigium.

(6) Plexus choroideus ventriculi quarti.

(7) Sulcus longitudinalis fossæ rhomboideæ.

(8) Striæ medullares.

The *Eminentia Teres*,⁹ the anterior extremity of the fasciculus teres,¹⁰ is located next the median groove. Beneath it are the nucleus teres (accessory to ninth and tenth cranial nerves), and nucleus of the abducent (sixth) nerve. External to it and in front of the striæ acusticæ is a small fossa, the fovea superior.

The Fovea Superior.—The fovea superior is near the lateral wall of the ventricle and marks the location of the facial (seventh) nucleus, which is deeply seated in the pons. Running forward and medially along the wall of the ventricle from the superior fovea, is a blue-floored groove, called locus cœruleus.

The *Locus Cœruleus* continues to the anterior angle of the ventricle. The color of the locus cœruleus is due to the substantia ferruginea, a pigmented layer of cell-bodies underlying it. The principal motor nucleus of the trifacial, or fifth, nerve lies beneath the anterior part of the locus cœruleus.

Inferior Triangle of the Ventricular Floor.—It presents: The hypoglossal trigone, trigonum vagi (fovea inferior, ala cinerea and eminentia cinerea) and most of the trigonum acustici.

The *Hypoglossal Trigone*¹¹ is the inferior half of the fasciculus teres. Its apex is in the inferior angle of the ventricle, and forms a nib of the calamus scriptorius; its base looks upward and is situated under the acoustic striæ. The twelfth nerve rises from the column of cells covered by it. External to the trigonum hypoglossi and inferior to the acoustic striæ is the inferior fovea, which forms the apex of the trigonum vagi.

(9) Colliculus facialis.

(10) Eminentia medialis.

(11) Trigonum nervi hypoglossi.

Trigonum Vagi.—The pneumogastric trigone is of a darker color than the ventricular floor around it, and is often called the *ala cinerea*. The *inferior fovea* forms the depressed and superiorly directed apex of the triangle; its floor rises inferiorly to the base, *eminentia cinerea*, which abuts against the lateral wall of the ventricle. The principal nuclei of the glosso-pharyngeal (or ninth) and the pneumogastric (or tenth) nerves are situated, respectively, beneath the fovea inferior and trigonum vagi.

The *Trigonum Acustici*¹² occupies the lateral angle of the ventricular floor. It is partly in the superior triangle, but chiefly in the inferior. Inclosed between the trigonum vagi and the ligula, its apex points downward, and its base looks upward and is crossed by the acoustic striæ. A slight tubercle, *eminentia acustica*, makes the base of the trigone, in the lateral angle most prominent. Beneath the acoustic trigone is the dorsal, or vestibular, nucleus of the auditory nerve; also the dorsal part of the cochlear nucleus, which is found in the acoustic tubercle.

ORIGIN OF CRANIAL NERVES.

According to Soemmering, there are twelve pairs of cranial nerves. Their origins (or terminations) are superficial and deep. The meaning of Superficial (apparent) origin, as commonly used, is the point of attachment of a nerve to the brain or cord surface; Deep (real) origin signifies the deepest point to which the fibers of a nerve can be traced. For *Motor Nerves* this nomenclature is correct, the deep origin being the nucleus in which the fibers rise that form the nerve; but it is exactly opposite to the truth for *Sensory Nerves*. The so-called deep origin of a sensory nerve is actually the *terminal nucleus* in which the fibers of the nerve

(12) Area acustica.

arborize and end. With these facts in mind examine the following table (N. 12, Add.).

TABLE II.

Name.	Superficial origin, or termination.	Deep origin, or termination.
1. Olfactory ¹³ (Smell)	{ Nerves .Olfactory bulb, surface... Tract.Three roots	{ Stratum glomeru- losum of olfac- tory bulb. Gyrus fornicatus. Trigonum olfac- torii. Uncus hippocam- pi.
2. Optic ¹⁴ (Sight)	{ Nerve.Optic commissure.... Optic tha- lamus, ex- ternal and internal Tract geniculate bodies, an- terior quadri- geminal body.....	{ Outer root—Ex- ternal geniculate body, optic tha- lamus, Anterior quadrigeminal body. Inner root—Optic thalamus, Inter- nal geniculate body.
3. Oculomotor ¹⁵ (Motor)	{ Interpeduncular fossa	{ Floor of Sylvian aqueduct.
4. Trochlear ¹⁶ (M.)	{ Valve of Vieus- sens	{ Floor of Sylvian aqueduct.

(13) Nervus olfactorius.

(14) Nervus opticus.

(15) Nervus oculomotorius.

(16) Nervus trochlearis.

5. Trifacial ¹⁷ (M. Sensory)	Pons, ventral sur- face	Motor root—Floor of fourth ventri- cle, and Sylvian aqueduct. Sensory root— Under superior cerebellar pe- duncle in pons, and Nucleus of Rolando in me- dulla.
6. Abducent ¹⁸ (M.)	Groove between pons and me- dulla	Floor of fourth ventricle be- neath eminentia teres.
7. Facial ¹⁹ (M.)	Groove between pons and me- dulla	Floor of fourth ventricle be- neath superior fovea.
Pars intermedia ²⁰ .. (Taste)	Between facial and auditory...	Beneath inferior fovea.
8. Auditory ²¹ (Hearing and space-sense)	Groove between pons and me- dulla	Vestibular root— Vestibular (or Dorsal) nucleus in ventricular floor, Spinal nu- cleus in cord, Nucleus fastigii and nucleus glo- bosus in cerebel- lum. Cochlear root— Cochlear (or ventral) nucle- us (ventral and dorsal parts) in dorso-lateral groove and on lateral surface of restiform body, and various nu- clei up to pos- terior quadri- geminal body.

(17) Nervus trigeminus.
(18) Nervus abducens.
(19) Nervus facialis.

(20) Nervus intermedius.
(21) Nervus acusticus.

9. Glossopharyngeal ²² (M. S. and taste)	{ Dorso-lateral groove of medulla	{ Ventricular floor, posterior triangle beneath foramen inferius.
10. Pneumogastric ²³ (M. S.)	{ Dorso-lateral groove of medulla	{ Ventricular floor, trigonum vagi.
11. Spinal accessory ²⁴ (M.)	{ Dorso-lateral groove of medulla	{ Closed medulla.
Accessory root ²⁵ ..	{ Dorso-lateral groove of medulla	{ Closed medulla.
Spinal root ²⁶	{ Lateral column of spinal cord.....	{ Intermedio-lateral column of cells in cord.
12. Hypoglossal ²⁷	{ Ventro-lateral groove of medulla	{ Ventricular floor beneath trigonum hypoglossi.
(M.)	{ Ventro-lateral groove of medulla	{ Ventricular floor beneath trigonum hypoglossi.

The posterior ten cranial nerves rise from two series of nuclei—(1) a ventral or anterior and (2) a dorsal or posterior series. The ventral series corresponds to the anterior cornu of gray matter in the spinal cord. It is entirely *motor and genetic*. The dorsal is regarded as a continuation of the posterior cornu and is *sensory* in function and *terminal*. Each series is composed of a double chain of nuclei: (a) A medial chain, derived from the base of the cornu and (b) a lateral chain, from the caput cornu.

(1) VENTRAL SERIES, MOTOR

(a) *The Medial Chain* is close to the median line, beneath the fasciculus teres and aqueduct of Sylvius. It gives *origin* to the Hypoglossal (12th), Abducent (6th), Trochlear (4th), and Oculomotor (3rd) nerves; also to accessory

(22) Nervus glossopharyngeus.

(23) Nervus vagus.

(24) Nervus accessorius.

(25) Radix cerebralis.

(26) Radix spinalis.

(27) N. hypoglossus.



motor roots of the 10th and 9th nerves in the nucleus teres; and to the 5th in the floor of the Sylvian aqueduct. All are efferent or motor.

(b) *Lateral Chain*.—This also is motor. It lies external to the medial chain, beneath the internal parts of the locus cœruleus and trigonum vagi. Converging slightly toward its fellow of the opposite side it extends downward into the closed medulla. It is regarded as the head of the anterior cornu. From the lateral chain of the ventral series rise: The accessory root of the spinal accessory (11th), posterior to the fourth ventricle; the chief motor roots of the Pneumogastric (10th) and Glosso-pharyngeal (9th); the root of the Facial (7th); and the principal motor root of the Trifacial (5th). The motor roots of the 11th, 10th and 9th nerves rise from the nucleus ambiguus.

(2) DORSAL SERIES, SENSORY.

(a) *Medial Chain of Nuclei*.—It corresponds to the base of the posterior gray cornu. Placed external to the ventral series, it is covered by the lateral part of the trigonum vagi, the acoustic trigone and superior peduncle of the cerebellum. It is entirely sensory and terminal, and it contains the principal sensory nuclei of the Pneumogastric (10th), and Glosso-pharyngeal (9th); the dorsal (vestibular) nucleus of the Auditory (8th); and the superior sensory nucleus of the Trifacial (5th).

(b) *The Lateral Chain* of the dorsal series is most external in position. It is located beneath the tubercle of Rolando and the restiform body. In it are contained the inferior sensory nucleus of the trifacial (5th), called the nucleus of Rolando; and the ventral (accessory) and lateral nuclei (the cochlear nuclei) of the eighth, or auditory, nerve. These nuclei are sensory, or afferent, and terminal.

The Olfactory (1st) and the Optic (2nd) are sensory, or afferent, and probably belong to the dorsal nerves, but this is difficult of demonstration.

BLOOD SUPPLY OF THE MEDULLA OBLONGATA.

Branches of the *posterior inferior cerebellar artery*, the *vertebral* and the *anterior spinal* supply the medulla. The first supplies the choroid tela. The branches to the nerve substance enter the median raphe or follow the roots of the bulbar nerves, suggesting the centrifugal and centripetal arteries of the spinal cord. The *veins* pursue the same course as the arteries. Both arteries and veins possess the perivascular *lymph spaces*. There are no lymphatic vessels.

CHAPTER VIII.

MEMBRANES OF THE SPINAL CORD.

Dura Mater.—Through the foramen magnum the membranes of the cord are continuous with those of the brain, with which they are very similar in structure. The *dura mater*¹ is attached to the margin of the great foramen and to the bodies of the first two or three cervical vertebræ; elsewhere its surface is free from bony attachment and does not possess the periosteal layer. Thus suspended, it hangs as an open sack, or sheath, and reaches down to the third sacral vertebra, where it is contracted to a fibrous cord which blends with the periosteum on the posterior surface of the coccyx.

The spinal cord and the cauda equina are contained in the dural sack. Externally, the surface of the *dura* is separated from the wall of the spinal canal by the meningo-rachidian veins,² areolar tissue and fat. It is composed of flat polygonal cells, like the inner surface. Its internal, serous surface is bathed with a small amount of cerebro-spinal fluid which separates it from the Arachnoid. For every segment of the spinal cord, it presents, on either side, a pair of foramina, through which run the anterior and posterior roots of the spinal nerves. Those nerve roots are invested by a sheath of *dura* prolonged from the margins of the foramina. The *dura mater* of the cord does not separate into two layers and forms neither sinuses nor processes. It performs no

(1) *Dura mater spinalis.*

(2) *Plexus venosi vertebrales interni.*

periosteal function and possesses no Pachionian bodies. Its two surfaces are formed by endothelium.

Arachnoid.—The arachnoid³ of the spinal cord forms a sack of the same length as the dural sheath, with which it is externally in contact. It presents two serous surfaces. Internally, bands of fibro-elastic tissue attach it to the pia mater, and form the *posterior fenestrated septum*.⁴ The medullary-spinal veins⁵ and a considerable space separate the arachnoid from the pia mater. That subarachnoid space is filled with fluid. By the *ligamenta denticulata* it is divided into the *anterior* and *posterior subarachnoid spaces*,⁶ which, through the foramen magnum, are continuous with the same spaces in the cranial cavity.

Pia Mater.—The pia⁷ of the cord is much stronger than that of the brain. It has two distinct layers, the inner of which is continuous with the brain pia and forms an epineurium for the cord and roots of the spinal nerves. The outer is the more vascular layer. Both layers dip into the anterior median fissure; they form the anterior septum which contains the anterior spinal artery. Only the inner layer is attached to the septum in the posterior median fissure. The outer layer forms the *linea splendens* along the front of the cord, and the *ligamentum denticulatum* on either side. The denticulate ligament is a longitudinal band whose smooth medial border is continuous with the pia along the middle of the lateral surface of the cord; its lateral border is notched and its twenty teeth, invested with arachnoid, are attached to the dura opposite the first twenty vertebræ. The two ligaments subdivide the space between the pia and arachnoid

(3) *Arachnoidea spinalis.*

(4) *Septum subarachnoideale.*

(5) *Venæ spinales externæ.*

(6) *Cavum subarachnoideale arterius and posterius.*

(7) *Pia mater spinalis.*

into anterior and posterior subarachnoid spaces. A filamentous extension of the pia below the cord proper forms the *filum terminale*. It descends in the arachno-dural sheath with the roots of the lumbar and sacral nerves, and all together constitute the *cauda equina*. For some distance the filum terminale contains gray matter and rudimentary fibers continuous with the spinal cord. The filum unites with the arachnoid and dura at the third sacral vertebra in forming the *central ligament* of the spinal cord. That ligament is inserted into the coccyx. The pia mater of the cord contains the trunks and large branches of the anterior⁸ and the two posterior spinal arteries,⁹ and the tributaries of the medullary spinal veins.¹⁰ The membranes of the spinal cord are supplied by recurrent branches of the spinal nerves and by the sympathetic.

(8) Arteria spinalis anterior.

(9) Aa. spinales posteriores.

(10) Venæ spinales externæ.

CHAPTER IX.

THE SPINAL CORD.

The spinal cord¹ is developed from the posterior part of the neural tube, and forms the corresponding portion of the central axis of the nervous system.

Extent.—It is continuous with the medulla oblongata, above; and, in the adult, reaches to the lower border of the first lumbar vertebra. Its length is seventeen to eighteen inches. In a very slender process, the *filum terminale*, the cord is continued beyond the first lumbar vertebra. That process and the lower spinal nerves form the *cauda equina*, which is inclosed in a sheath composed of the arachnoid and dura mater. The filum terminale, for some distance, contains a prolongation of the central gray matter and ventricle of the cord; and, also, a few fibers, which suggest the coccygeal nerves of lower animals.

In the fœtus before the third month, the cord and spinal canal are of equal length. At birth the cord reaches the third lumbar vertebra, and it continues to recede with the rapid growth of the vertebra to adult life.

Size.—The spinal cord is shaped like a cylinder, slightly flattened from before backward (dorso-ventrally). Its longest diameter is transverse and measures less than half an inch, except in the cervical and lumbar enlargements of the cord. In the latter, it equals a half-inch; and, in the former, it slightly exceeds it. The thoracic portion of the cord is

(1) *Medulla spinalis.*

small and nearly cylindrical in shape. Divested of its meninges and nerves the spinal cord weighs about one ounce and a half avoirdupois.

The *cervical enlargement*² extends from the medulla oblongata to the second thoracic vertebra. Its greatest diameter is on a level with the fifth intervertebral disk. It gives origin to the nerves which form the cervical and brachial plexuses.

The *lumbar enlargement*³ begins at the tenth thoracic vertebra and increases to the twelfth. Opposite the first lumbar vertebra, it tapers off almost to a point, the *conus terminalis*,⁴ but a very small process continues in the filum terminale. From the lumbar enlargement rise the nerves forming the lumbar and sacral plexuses.

Sixth Ventricle.—The central canal⁵ of the spinal cord is the representative of the cavity of the neural tube. It is just visible to the naked eye; but it extends throughout the cord and expands above into the fourth ventricle. In the filum terminale, it is also dilated, forming the *inferior rhomboid fossa*.⁶ It is lined with columnar ciliated cells which stand on a thick lamina of substantia gelatinosa Rolandi.

SURFACE.

Fissures of the Spinal Cord.—The spinal cord is incompletely divided into symmetrical lateral halves by the anterior and the posterior median fissure.

The *Anterior Median Fissure*⁷ is the broader and shallower of the two. It extends in length from the posterior end of the ventral surface of the pons (foramen cæcum of Vicq d'Azyr) down the anterior median line of the medulla and

(2) Intumescencia cervicalis.

(3) Intumescencia lumbalis.

(4) Conus medullaris.

(5) Canalis centralis spinalis.

(6) Fossa rhomboidea inferior.

(7) Fissura mediana anterior.

cord. As to depth, it equals one-third of the cord's axis. Its floor is formed by the anterior, or white, commissure. Both layers of pia mater dip down into it and inclose the anterior spinal artery and its branches. The anterior median fissure is interrupted at the junction of the cord and medulla by the decussation of the pyramids. In the lumbar enlargement it gradually disappears.

The *Posterior Median Fissure*⁸ is narrow and deep. It extends, longitudinally, down the posterior median line of the cord from the middle of the dorsal surface of the medulla. It divides the cord, dorso-ventrally, beyond its middle. The floor of the fissure is formed by the posterior, or gray, commissure, which, with the white commissure, separates the posterior from the anterior median fissure. The posterior median fissure is occupied by a lamina of connective tissue, the *posterior septum*, which is attached to the deep layer of the pia mater. In the posterior septum ramify branches of the two posterior spinal arteries and tributaries of the medulli-spinal veins.

Postero-lateral Fissure.—Each lateral half of the spinal cord is partially divided, near the junction of the posterior fourth with the anterior three-fourths of its semicircumference, by the postero-lateral fissure.⁹ The fissure is situated opposite the posterior cornu of gray matter, to which it transmits the posterior roots of the spinal nerves. It is continuous above with the dorso-lateral groove of the medulla. It separates the posterior surface and the antero-lateral surface from each other.

Antero-lateral Fissure.—It is convenient to regard the narrow longitudinal area, through which issue the anterior roots of the spinal nerves, as the antero-lateral fissure. The

(8) Fissura mediana posterior.

(9) Sulcus lateralis posterior.

anterior roots do not emerge in line one above another, nor is there any groove on the surface of the cord; thus the so-called fissure cannot be exactly located. It is situated opposite the anterior cornu of gray matter and in line with the ventro-lateral groove of the medulla oblongata. It subdivides the antero-lateral surface into anterior and lateral surfaces.

The *Posterior Intermediate Furrow*¹⁰ is a slight longitudinal groove which subdivides the posterior surface into postero-median surface and postero-lateral surface. From it a connective tissue septum extends into the cord and separates the columns of Goll and Burdach from each other. The posterior intermediate furrow is found only in the upper part of the cord, in the cervical and dorsal regions.

The spinal cord is composed of (1) Gray matter, in the central part; and (2) White matter, in the peripheral area. It is like the medulla and pons in having the white matter on the surface.

1. GRAY MATTER OF THE CORD.

A column of gray matter,¹¹ crescentic in section, extends through the center of each lateral half of the spinal cord. The crescent is convex medially; and is joined to its fellow, a little in front of the middle, by a transverse lamina of gray matter, called the *posterior commissure*.¹² It is joined to the white matter of the opposite side by the anterior commissure.¹³ The points of the crescent are directed forward and backward, respectively, and form the *anterior* and *posterior cornua*.¹⁴ Together, the two crescents and the gray

(10) Sulcus intermedius posterior.

(11) Substantia grisea

(12) Commissura posterior et c. anterior grisea.

(13) Commissura anterior alba.

(14) Columnæ anteriores and c. posteriores.

commissure form an *H-shaped column* of gray matter. The H-shaped column is well marked in the cervical and thoracic regions; but, toward the lower end of the cord, the crescents become short and thick and the gray column is almost cylindrical.

The gray matter of the cord is of two kinds: (1) The *substantia gelatinosa* Rolandi, which forms (a) a cap for the head of the posterior cornu and (b) an envelope for the central canal, or ventricle, of the cord. (2) The *substantia spongiosa*. The latter forms all the H-shaped column except the tips of the posterior horns and the thick sheath of the central canal. Imbedded in the neuroglia, there is a network of medullated nerve fibers, running longitudinally, dorso-ventrally and transversely, which gives it a spongy appearance under the microscope.

Gray Crescent.—It is made up of (1) The Anterior Cornu;¹⁵ (2) The Center,¹⁶ which is joined to its fellow of the opposite side by the gray commissure; and, (3) The Posterior Cornu.¹⁷ There is a lateral projection from the base of the anterior cornu in the cervical and upper dorsal region, called the *lateral horn*.¹⁸ The *reticula*, or *processus reticularis*, forms a lateral projection from the base of the posterior cornu. It is found in the cervical region.

(1) *The Anterior Cornu*¹⁵ is short and thick compared with the posterior cornu. It is thickest in the cervical and lumbar enlargements; in the mid-thoracic region it is more slender. It does not reach the surface of the cord as does the posterior cornu. It ends in a bulbous, serrated head, which points toward the antero-lateral fissure. From it the anterior

(15) *Columna anterior.*

(16) *Substantia intermedia grisea.*

(17) *Columna posterior.*

(18) *Columna lateralis.*

roots of the spinal nerves rise; and, together with the anterior root-fibers, it separates from each other the anterior and lateral white columns¹⁹ of the cord.

Cells.—The anterior cornu contains two columns of large vesicular cell-bodies,²⁰ a *medial* and a *lateral column*. These columns are continuous throughout the cord. Their axones compose the greater part of all anterior roots of the spinal nerves. From the lateral column, and from a part of the medial, the axones enter the spinal nerves of the same side; the remainder pass through the anterior (white) commissure²¹ to the opposite nerves. They are distributed to the muscles of the trunk and extremities. Those neurones whose centers are in the *medial column* are believed to innervate the dorsal muscles of the trunk. The muscles of the extremities are innervated by the *dorso-lateral column*; the ventral muscles of the trunk, by the *ventro-lateral column*. In the cervical region, the ventro-lateral column gives origin to the phrenic and spinal accessory nerves (Quain). The end tufts of the pyramidal fibers and of the descending cerebellar fibers are in relation with the dendrities or bodies of the cells of the anterior cornu. Fibers from the posterior roots of the spinal nerves and from cell-bodies within the cord, likewise, terminate in relation with them. The cells of the anterior cornu are both motor and trophic (?).

Lesions.—The cells in the anterior cornu are the seat of hemorrhagic inflammation and rapidly degenerate in acute anterior poliomyelitis: in progressive muscular atrophy and in amyotrophic lateral sclerosis they degenerate slowly. As a result of the first, sudden paralysis occurs. The muscles waste away in the second and third because the nerves con-

(19) Funiculus anterior and funiculus lateralis.

(20) Perikaryons.

(21) Commissura anterior alba.

trolling the muscles and their blood supply are gradually destroyed. In the last, the muscles are also spastic, because, as we shall see farther on, the involvement of the pyramidal tracts cuts off cerebral inhibition.

(2) *The Central Part of the Crescent*²² is both afferent and efferent. In it are located important reflex centers, such as, the Cilio-spinal, Secretory, Vaso-motor, Visceral, Genital, etc. In the lumbar enlargement are centers of defecation, micturition, erection, ejaculation, parturition; in the cervical enlargement the cilio-spinal, cardio-accelerator, etc., are found. The center of the crescent contains three columns of cell-bodies: The *intermedio-lateral column* of large vesicular cell-bodies,²³ situated near the lateral surface of the crescent; the *middle column* (Waldeyer), deep in the crescent at the junction of the gray commissure; and the *dorsal column* of Clark,²⁴ which is situated near the inner surface of the base of the posterior cornu. The neurones of the central part of the crescent are largely sympathetic; this is especially true of Clark's column and to less extent of the intermedio-lateral column.

The *intermedio-lateral column* is best marked in the thoracic region; but is also found in the cervical and lumbar cord. Its cell-bodies,²³ which are large and vesicular, are in relation with end-tufts of fibers from the posterior roots; and they give rise to efferent fibers that enter the anterior roots of the spinal nerves. Those fibers are probably sympathetic and supply the muscles of the glandular and circulatory systems (Morris). Other axones from this column enter the antero-lateral ascending cerebellar tract.

(22) *Substantia intermedia grisea.*

(23) *Perikaryons.*

(24) *Nucleus dorsalis.*



The *middle column* (Waldeyer) is composed of medium-sized neurone-centers,²³ which are most abundant in the cervical region, where this column is best shown. Fibers from the posterior spinal roots have been traced into the column and probably the cell-bodies give rise to some of the fibers of the antero-lateral ascending cerebellar tract. But very little is certainly known of the function of this column.

Clark's column (nucleus dorsalis) is continuous only through the thoracic region; but it is represented by the nuclei of Stilling in the cervical and lumbar regions and, in the medulla oblongata, by the accessory cuneate nucleus. Clark's cells are in relation with the end-tufts of fibers from the posterior roots of the spinal nerves. The axones of Clark's cells form the direct cerebellar tract, and help to form the anterior roots of the spinal nerves. The latter are sympathetic fibers, anabolic and inhibitory in function. They are distributed to the blood vessels, glands and muscular coat of the alimentary canal (Morris).

(3) *The Posterior Cornu*,²⁵ except in the lumbar cord, is slender. It is longer than the anterior cornu and reaches the surface in the postero-lateral fissure, where it receives the posterior roots of the spinal nerves. The posterior cornu presents a slight enlargement near its extremity, called the *caput cornu*,²⁶ which tapers off to the *apex cornu*.²⁷ The head is joined to the base of the horn by a constricted part, the *cervix*.²⁸ The head of the posterior horn is capped by the *substantia cinerea gelatinosa* of Rolando. The posterior cornu separates the posterior²⁹ from the lateral column³⁰ of the cord.

The *cells of the posterior cornu* are very numerous. They

(25) *Columna posterior.*

(26) *Caput columnæ posterioris.*

(27) *Apex columnæ posterioris.*

(28) *Cervix columnæ posterioris.*

(29) *Funiculus posterior.*

(30) *Funiculus lateralis.*

have smaller bodies than the cells of the anterior cornu and are less definitely grouped. In function they are afferent and associative. They are classified as follows: (a) The peripheral cells, having a body and one long process, the comet cells (Waldeyer); (b) the central cells; (c) the basal cells; (d) the cells of the substantia gelatinosa, which have small and round bodies (Gierke and H. Virchow); and (e) the solitary, fusiform-bodied cells, scattered throughout the posterior horn. The *dendritic processes* of the cells of the posterior cornu probably ramify in the gray matter adjacent to them. The *axones* run in various directions, viz., into the ground bundles, forming the septomarginal and cornu commissural tracts, and, perhaps, the comma tract; into Burdach's column; into the center and anterior cornu of the same side; and, very largely, into the gray crescent of the opposite side. These last fibers, together with the anterolateral ascending cerebellar tract, account largely for the immediate crossing of the main sensory path. Many fibers from the posterior roots of the spinal nerves terminate in ramifications about the cells of the posterior cornu on both sides, viz.: Those axones, forming the lateral group of small fibers in the posterior roots of the spinal nerves, end in relation with the small, round cell-bodies in the substantia gelatinosa Rolandi; other fibers end about the peripheral, the central, the basal and the solitary cell-bodies.

*The Posterior, or Gray, Commissure*³¹ completes the gray matter of the cord. It unites the two gray crescents together a little in front of their center, except in the lumbar region where it joins their centers. It forms the floor of the posterior median fissure; and, in front, is in relation with the white commissure. It is pierced longitudinally by the cen-

(31) Commissura anterior grisea, and c. posterior.

tral canal of the spinal cord, around which is a thick envelope of *substantia gelatinosa*. That part of the commissure in front of the canal and that behind it are frequently described as the *anterior* and *posterior gray commissures*. The posterior commissure is composed of neuroglia in which are imbedded the bodies of many nerve cells and a large number of medullated fibers. The medullated fibers are derived from the posterior roots of the spinal nerves, and from intrinsic neurones of the cord, whose centers are situated chiefly in the commissure and in the posterior cornu. The commissure contains a *long sensory tract* between the ventricle and dorsal surface (Ciaglinski). The long sensory tract is found in the thoracic portion of the cord and the discoverer believes it to be made up of ascending root-fibers which conduct pain and temperature impulses. It is in need of further investigation.

2. WHITE MATTER OF THE CORD.

The white matter³² of the spinal cord is disposed in its peripheral area and in the anterior commissure.³³ It is composed of medullated nerve fibers (axones and collaterals) imbedded in a small amount of neuroglia; and, like the gray matter, it is richly supplied with blood vessels. It is also supported by a connective tissue network derived from the pia mater. The fibers run *transversely*, *dorso-ventrally* and *longitudinally*.

Transverse fibers are found running between the longitudinal columns and the gray matter, or vice versa, and are continuous with the longitudinal fibers. The most definite lamina of transverse fibers is the anterior commissure.

The Anterior, or White, Commissure.—It connects the an-

(32) *Substantia alba*.

(33) *Commissura anterior alba*.

terior and lateral white columns of the cord with the opposite gray crescent. It is located in front of the gray commissure, and forms the floor of the anterior median fissure. It is composed of medullated fibers belonging to (a) the direct pyramidal tract, (b) the antero-lateral ground bundle, (c) the antero-lateral ascending cerebellar tract, and (d) of the crossed fibers to the anterior roots of the spinal nerves.

The dorso-ventral fibers of the spinal cord are those of the anterior roots of the spinal nerves, in their course from the gray matter to the surface of the cord; and of the posterior roots, running from the postero-lateral fissure to their destination in the gray matter.

The Longitudinal Fibers comprise most of the white matter in the cord, forming the *funiculus anterior*, *funiculus lateralis* and *funiculus posterior*. They are disposed around the gray crescent in bundles or tracts. The tracts are not visible to the naked eye, nor under the microscope in a healthy adult cord; they have been located by embryological, experimental and pathological investigations. The longitudinal fibers rise in the brain, in the spinal cord and in the spinal ganglia; some run upward and others downward, constituting the tracts of the cord. Thus the tracts are characterized as ascending, descending and mixed tracts.

✓ *Ascending Tracts:* (1) Antero-lateral ascending cerebellar tract, (2) Direct cerebellar tract, (3) Postero-lateral tract, (4) Postero-median tract, (5) Marginal tract of Lissauer, (6) Posterior longitudinal bundle, (7) Olivary bundle (Helwig's), and (8) Ciaglinski's long sensory tract, in the gray commissure.

✓ *Descending Tracts:* (1) Uncrossed (direct) pyramidal tract, (2) Crossed pyramidal tract, (3) Antero-lateral descending cerebellar tract, (4) Comma tract, (5) Septomar-





ginal tract; (6) Cornu commissural tract, (7) Anterior longitudinal bundle, and (8) Crossed descending tract of the red nucleus.

Mixed, Ascending and Descending, Tract.—The Antero-lateral ground bundle. ✓

The **Large Tracts of the Antero-lateral Column**³⁴ of the spinal cord are seven in number, viz., the antero-lateral ground bundle, two pyramidal tracts, three cerebellar tracts and the marginal bundle of Lissauer.

The **antero-lateral ground bundle**³⁵ occupies the deep part of the column. It embraces the anterior cornu of gray matter and covers the outer surface of the center of the crescent and the base of the posterior cornu. It approaches, but does not quite reach, the surface of the cord. It is separated from the anterior median fissure by the uncrossed (direct) pyramidal tract; the antero-lateral descending and ascending cerebellar tracts run between it and the surface of the cord; and, behind, it is in relation with the crossed pyramidal tract. The antero-lateral ground bundle is composed of ascending and descending fibers. It is a short fiber tract, associative and commissural in function. That part situated in the anterior column is largely commissural, between the anterior cornua; while the part in the lateral column is chiefly associative, and connects different segments of the cord on the same side. The antero-lateral ground bundle is continued in the *formatio reticularis* of the medulla, pons and mid-brain, constituting a short fiber tract which extends from the lower part of the cord to the basal ganglia of the cerebrum. Some of its ascending fibers form the *posterior longitudinal bundle*,³⁶ and extend up to the motor cranial nuclei and

(34) Funiculus antero-lateralis.

(35) Fasciculus proprius antero-lateralis.

(36) Fasciculus longitudinalis medialis.

hypothalamic region. Imbedded in the tract, also, between the anterior and lateral areas, is seen the *anterior longitudinal bundle*³⁷ as far as lumbar cord (Barker). The latter runs from the superior quadrigeminal body to the cilio-spinal and other centers.

The uncrossed (direct) pyramidal tract (Turek's column)³⁸ occupies a thin area next the anterior median fissure. It is a continuation of the same tract in the medulla. Its fibers are axones of cortical cells whose bodies are situated in the Rolandic region of the cerebrum. As the tract descends in the cord, the fibers decussate through the anterior commissure, and terminate in relation with the cells of the opposite anterior cornu. (N. 15, Add.)

The antero-lateral descending cerebellar tract (Marchi and Loewenthal's column),³⁹ together with the ascending antero-lateral cerebellar tract, occupies a thin peripheral area, broadest posteriorly, which extends from the direct pyramidal tract outward and backward, over the antero-lateral ground bundle, to the middle of the lateral surface of the cord. Its posterior border is in relation with the direct cerebellar tract and the crossed pyramidal tract. The fibers of the two tracts are mingled together; but the descending fibers are found, chiefly, in the anterior part of the common area and the ascending in the posterior part. The descending fibers are axones from the cortical cells (Purkinje's) of the cerebellum. They descend to the spinal cord through the inferior cerebellar peduncle and the lateral area of the medulla and, probably, end in the anterior cornu of gray matter. The descending cerebellar tract forms one segment of an indirect motor path (N. 11, Add.).

(37) Fasciculus ventralis.

(38) Fasciculus cerebro-spinalis anterior.

(39) Fascicularis antero-lateralis superficialis (descendens-ascendens).

Antero-lateral ascending cerebellar tract (Column of Gowers).³⁹—It is found chiefly in the posterior part of the area common to it and the descending tract. It is composed of axonic processes of cells whose bodies are situated in the center of the crescent and base of the anterior cornu, chiefly on the opposite side of the cord (v. Lenhossék). Most of the fibers of the antero-lateral ascending cerebellar tract cross near their origin through the anterior commissure of the cord. In the medulla, the tract ascends through the dorsal part of the lateral area, sending collaterals to the lateral nucleus; it then continues, through the *formatio reticularis* of the pons, to a point near the inferior quadrigeminal body, where it is bent backward over the superior cerebellar peduncle, and enters the *vermis cerebelli superior* through the valve of Vieussens (Hoche). According to Mott, two small bundles leave this tract at the angle, and run near the lateral fillet to the superior corpus quadrigeminum and optic thalamus. Gowers' tract carries thermic and pathetic impulses. The olivary bundle of the cord; the *triangular tract* of Helwig, is found near the middle of the area common to the antero-lateral cerebellar tracts; it may be traced to the lumbar region, where its longest fibers rise. It ends in the olive of the medulla oblongata and is afferent in conduction.

The **direct cerebellar tract** (dorso-lateral cerebellar tract)⁴⁰ runs posterior to the antero-lateral tracts. It is superficially located, and extends from the middle of the lateral surface of the cord back to the postero-lateral fissure, except in the lumbar cord. There its absence allows the crossed pyramidal tract to come to the surface. The direct cerebellar tract terminates in the superior worm of the cerebellum. In the medulla, it forms a part of the *restiform*

(40) *Fasciculus cerebello-spinalis*.

body. Its fibers are axones of Clark's vesicular cells. They convey impulses of equilibrium received, especially, from the viscera.

The **crossed pyramidal tract**⁽⁴¹⁾ forms a considerable part of the lateral column of the spinal cord. It is covered, superficially, by the cerebellar tracts in the cervical and dorsal cord; but in the lumbar cord, it forms part of the surface. Its deep surface is in relation with the posterior cornu of gray matter, the antero-lateral ground bundle and marginal bundle of Lissauer. The fibers composing it are axones of cell-bodies in the Rolandic region of the cerebral cortex. They rise with those of the uncrossed (direct) pyramidal tract,⁽⁴²⁾ and the two run as one tract down through the genu and anterior two-thirds of the posterior segment of the internal capsule, the middle three-fifths of the crusta, the ventral longitudinal fibers of the pons and the pyramid of the medulla. In the medulla the two tracts separate. The *crossed tract* decussates with its fellow through the anterior median fissure, pierces the anterior gray cornu and descends in the lateral column of the cord. It terminates in relation with the cell-bodies of the anterior cornu. The *uncrossed tract* follows the anterior median fissure as already described. Both end chiefly in the anterior gray cornu opposite to their cortical origin. According to Marchi, about twenty per cent of the fibers remain uncrossed. The pyramidal tracts are the cerebral motor tracts. By them motor and inhibitory impulses are carried to the cord. In the dorso-lateral part of the crossed pyramidal area is found the *crossed descending tract of the red nucleus*. It extends as far as the first lumbar segment and ends in the center of the gray crescent. It is efferent in function. (N. 15, Add.)

(41) Fasciculus cerebro-spinalis lateralis.

(42) Fasciculus cerebro-spinalis anterior.

Lesions.—The pyramidal tracts (especially the crossed) are involved in lateral sclerosis and in amyotrophic lateral sclerosis; and, as a consequence of it, both voluntary and inhibitory impulses from the brain are interfered with, hence the spastic paralysis and exaggerated reflexes. The pyramidal tract may be more or less involved in insular sclerosis and in bulbar paralysis, and the symptoms vary with the amount of sclerosis. Gliosis of the pyramidal and cerebellar tracts and the posterior tracts (Dejerine and Letulle) has been demonstrated in Friedrich's hereditary ataxia, and the involvement of the pyramidal tracts explains the spastic paralysis which affects both the arms and legs. In ataxic paraplegia (Gowers) there is diffuse sclerosis of the lateral and posterior columns of the cord. It is the degeneration in the pyramidal tracts that causes the spastic gait, incoördinated arm movements and early increase of the reflexes, observed in that affection.

The marginal tract of Lissauer⁴³ is a small tract composed of ascending branches of the outer set of fibers in the posterior roots of the spinal nerves. It is situated on the lateral surface and apex of the posterior cornu. Its fibers, after ascending a short distance, end about the cell-bodies of the substantia gelatinosa Rolandi.

Tracts of the Posterior Column of the Cord.⁴⁴—There are three tracts in this column, viz., the postero-lateral, the postero-median and the ground bundle, or fasciculus proprius, which may be divided into the comma tract, septo-marginal tract and cornu commissural tract. The last three are descending tracts.

Postero-lateral tract (Burdach's column).⁴⁵—It runs upward just medial to the posterior cornu of gray matter. It is

(43) Fasciculus marginalis.

(45) Fasciculus cuneatus.

(44) Funiculus posterior.

made up of ascending branches of the posterior roots of the spinal nerves and of intrinsic fibers whose cell-bodies are in the gray matter of the cord. It becomes the fasciculus cuneatus and fasciculus Rolandi, in the medulla; and it ends chiefly in the cuneate and Rolandic nuclei. A certain number of its fibers are continued directly into the interolivary fillet and others into the arciform fibers without interruption; and some of the fibers of Burdach's column end in the gray matter of the cord as they ascend. In the midst of the postero-lateral tract, in the cervical and upper thoracic cord, is a small bundle of descending fibers, the *comma tract*; in the lumbar and sacral segments are found two descending tracts, the *septomarginal* and the *cornu commissural*. The two latter tracts are entirely intrinsic, and there seems to be no doubt that the comma tract is in part so, as some of its fibers degenerate after section either of the posterior roots of the spinal nerves or destruction of the posterior horn of gray matter. Burdach's column conveys all kinds of common sensory impulses (N. 13, Add.).

The Cornu Commissural Tract is placed between the posterior cornu, the gray commissure and posterior septum. It extends up to the eleventh thoracic segment.

Septomarginal Tract (Bruce and Muir).—This tract is a semi-oval tract next the posterior septum in the third lumbar segment (Flechsig); and a triangular tract bounded by the septum and dorsal surface of the cord in the fifth sacral segment (triangle median, Gombault and Phillippe).

The Comma Tract.—It is comma-shaped in section, the head being directed forward. It is composed of descending branches of the posterior roots of the spinal nerves, and of intrinsic fibers of the spinal cord. It is considerably intermingled with fibers of the postero-lateral tract, and its termination is in the posterior cornu of the cord.

The postero-median tract (Goll's column)⁴⁶ ascends between the postero-lateral tract and the posterior median septum. Like the postero-lateral tract in the cervical region, it extends in depth ventrally to the gray commissure. It is composed of ascending branches of the posterior roots of the spinal nerves. Continued into the medulla oblongata, the postero-median tract becomes the fasciculus gracilis. It terminates at the clava, the fibers ending in relation with the cell-bodies of the nucleus gracilis. A number of fibers, diverging from the tract, end in the gray matter of the spinal cord, and a few, without interruption, continue in the interolivary fillet to the thalamus and in the arciform fibers of the medulla to the cerebellum. Goll's column carries impulses of the muscular sense, and is particularly involved in locomotor ataxia. All varieties of impulses of bodily sensation are carried by Burdach's column.

Lesions in the posterior columns cause disturbances of sensation, loss of reflexes and impaired equilibration. These columns are usually involved, by extensions from the posterior roots, in locomotor ataxia (posterior sclerosis), hence the paræsthesia, crises, loss of reflexes, contracted pupil, disturbed equilibrium and ataxic gait. They may be involved in insular sclerosis, and the sensory symptoms depend upon the extent of their degeneration. Section of the posterior column on one side in any segment of the spinal cord produces, on the same side, more or less loss of sensation in that part of the body supplied by the segment cut, and, on the opposite side, complete anæsthesia below the section.

ROOTS OF THE SPINAL NERVES.

Thirty-one pairs of spinal nerves rise from the side of the cord. Each nerve has two roots: an anterior, efferent or

(46) Fasciculus gracilis.

motor, root and a posterior, afferent or sensory, root. These roots descend more or less from their origin to the intervertebral foramen in which they unite to form the spinal nerve. The roots of the first cervical nerve are horizontal; those of the first dorsal nerve descend the width of two vertebræ, and those of the twelfth dorsal, the width of four vertebræ; while the roots of the coccygeal nerve extend from the first lumbar vertebra to the second piece of the coccyx, through ten vertebræ.

Anterior Root.—In all spinal nerves, except the first, the anterior root⁴⁷ is smaller than the posterior.⁴⁸ It is composed of from four to six fasciculi, which soon combine into two bundles. After piercing the dura mater, the anterior root unites with the posterior, beyond the latter's ganglion, and forms a spinal nerve. It is efferent, or motor, in function.

Superficial (apparent) Origin.—The anterior root is composed of medullated axones which issue from the narrow longitudinal area commonly called the Antero-lateral Fissure.

Deep (real) Origin.—The medullated axones rise from the Medial, Lateral, Clark's and Intermedio-lateral columns of cell-bodies on the same side, and from the Medial column of the opposite side.

Lesions.—The lower motor neurones (spinal and cranial) are probably in a state of toxic irritation in laryngismus stridulus, tetanus, acute ascending paralysis (Landry), strychnine poisoning, etc., hence the twitchings, spasms and convulsions. In spinal meningitis both the anterior and posterior roots are affected.

The posterior root⁴⁹ is the sensory, or afferent, root. It is larger than the anterior root, except in the case of the first cervical nerve; and is composed of from six to eight fas-

(47) Radix anterior.

(49) Radix posterior.

(48) Radix posterior.

ciculi, which also combine at once into two bundles. The posterior root pierces the dura mater separately. It unites with the anterior root in the intervertebral foramen. Near the outer end, it presents a swelling which contains large vesicular-bodied nerve cells, and is called a **spinal ganglion**.⁵⁰ (It is occasionally absent on the first nerve.) The posterior root, external to the ganglion, is made up of the *dendritic processes* (Cajal) of the ganglion cells. These dendrites extend to the most distant parts of the body; they are the sensory fibers of the spinal nerves. Internal to the ganglion, the posterior root is composed of *axones*, which rise from the ganglion cells. Both the axonic and dendritic processes are medullated.

Superficial Origin (apparent central termination).—The posterior roots of the spinal nerves enter the Postero-lateral Fissure; and, at once, divide into an outer set of small fibers and an inner set of large fibers with some small ones interspersed. The fibers of each set bifurcate into a large ascending and a small descending branch. Collaterals rise from the parent axone and from both branches.

Deep Origin (real central termination).—The ascending divisions of the outer set of fibers run a short distance along the external surface of the posterior cornu, and end in ramifications about the cell-bodies of the Substantia Gelatinosa Rolandi. They form the tract of Lissauer. The ascending divisions and collaterals of the inner set of fibers from the posterior root run (1) To the Gray Matter of the Cord, viz.: To all parts of the Posterior Cornu, to the Center of the Crescent, and to the Anterior Cornu on the same side, and, through the gray commissure, to the Center and Cornua of the opposite crescent. Those fibers end in relation with

(50) Ganglion spinale.

the dendrites or cell-bodies situated in those several regions. (2) To the Brain. Of the ascending fibers from the posterior roots of the spinal nerves, the remainder form the column of Goll and most of Burdach's column and ascend to the Gracile, Cuneate and Rolandic nuclei of the medulla oblongata. The greater number terminate in those nuclei, but a few continue, through the external arciform fibers, to the Vermis Cerebelli Superior, and, through the interolivary fillet, to the Cerebrum.

The descending branches of the posterior root-fibers have a short course. They end in the gray matter of the cord. According to Mott some of them enter into the comma tract. They are not well understood.

Lesion.—The posterior roots of the spinal nerves are first affected (Obersteiner and Redlich) in locomotor ataxia, and the lesion extends to the spinal ganglia (often) and to the posterior columns of the cord.

BLOOD SUPPLY OF THE SPINAL CORD.

The vessels supplying the cord are the anterior spinal artery⁵¹ and the two posterior spinal arteries,⁵² which rise at the foramen magnum from the vertebral arteries, and are reinforced by cervical, intercostal and lumbar arteries. The **anterior spinal artery** descends along the entrance to the anterior median fissure; it is formed by the union of two vessels, one from each vertebral. The **posterior spinal artery**, of either side, is in reality a pair of vessels which freely communicate, and are so placed as to embrace the posterior nerve roots. The larger vessel of the pair is external to the nerve roots, while the smaller is between them and the pos-

(51) Arteria spinalis anterior.

(52) Arteriæ spinales posteriores.

terior median fissure. The spinal arteries give origin to two sets of branches, namely, the centrifugal and centripetal arteries. Both sets are end-arteries and form rich longitudinal plexuses, which overlap each other but do not anastomose.

The *Centrifugal Arteries* rise, first and chiefly, from the anterior spinal artery. These enter the anterior median fissure and, running lateralward, supply the greater part of the gray matter. *Second*, a few centrifugal arteries rise from the posterior spinal arteries. Running into the posterior fissure, they are distributed to the posterior white columns, the posterior commissure and to Clark's column of cells.

The *Centripetal Arteries* rise from both the anterior and posterior spinal arteries. They enter the cord at right angles to the surface, and supply the white matter and the peripheral parts of the gray substance, including the tips of the cornua. Those branches to the cornua accompany the root-fibers.

Veins.—The veins⁵³ that carry the blood from the interior of the cord are the *fissural veins*, which issue from the fissures, the *root-veins*, which accompany the anterior and posterior root-fibers to the surface of the cord, and a small number of veins that issue from other parts of the surface of the spinal cord. All unite in forming the *Medullary-spinal Plexus*,⁵⁴ spread over the entire surface of the cord beneath the arachnoid membrane. In the upper cervical region, the plexus forms two or three small veins which empty into the vertebral or inferior cerebellar veins; elsewhere, by a branch along each spinal nerve, the plexus communicates with the

(53) Venæ.

(54) Venæ spinales externæ.

Meningo-rachidian Veins,⁵⁵ outside the dura mater, and is drained into the vertebral, intercostal, lumbar and sacral veins. No valves are found in the spinal veins.

Lymphatics.—Perivascular and perineural spaces carry the lymph from the spinal cord. There are no lymphatic vessels in the cord.

(55) Plexus venosi vertebrales interni.

CHAPTER X.

TRACING OF IMPULSES.

Having studied the grouping and chaining together of neurones, let us now make the knowledge practical by tracing impulses through the better known paths formed by these various neurone groups. The paths thus formed are of three kinds, namely: I. Efferent, or motor; II. Afferent, or sensory—General and Special sense; and III. Reflex.

I. EFFERENT, OR MOTOR, PATHS.

THE PYRAMIDAL PATHS are direct, as they do not pass through the cerebellum. Their impulses ultimately run either through the spinal or the cranial nerves, and are both motor and inhibitory. Hence the increased reflexes and spastic contractions of lateral sclerosis.

1. *Through the Spinal Nerves.*—Starting in the upper three-fourths of the Rolandic area of the cerebral cortex, motor and inhibitory impulses run down through the corona radiata, the anterior two-thirds of the posterior segment of the internal capsule, the middle three-fifths of the crusta, the ventral longitudinal fibers of the pons, and the pyramid of the medulla oblongata, whence they proceed either by the *crossed* or *uncrossed* (direct) *pyramidal tract* to the anterior gray cornu in the opposite side of the spinal cord. By the former route, the impulses cross over in the medulla, through the decussation of the pyramids, and descend in the lateral column of the spinal cord; but by the uncrossed route, they descend in the anterior column of the cord and decussate,

in succession, through the white commissure. Impulses by either route finally reach the anterior gray cornu of the spinal cord and, with the exception of a small per cent of them, they reach the cornu opposite to their Rolandic origin. The few undecussated fibers in the crossed pyramidal tract conduct uncrossed impulses to the anterior cornu of the same side. Thus are explained two symptoms of hemiplegia, viz., weakness on the well side and slight motion on the paralyzed side. From the anterior gray cornu of the spinal cord the nerve commotions are conducted by the efferent, or motor, fibers of the spinal nerves to the muscles of the neck, trunk and extremities.

2. *Through the Cranial Nerves.*—Impulses destined to the cranial nerves run chiefly from the lower two-fourths of the Rolandic area through corona radiata, genu of internal capsule and on, by the same path as the impulses to spinal nerves, down to the point where they leave the pyramidal tract to enter the nuclei of the cranial nerves, which they do in the vicinity of the several nuclei. They enter the nucleus of the fourth nerve on the same side, but they cross over to the nuclei of the third, fifth, sixth, seventh, ninth, tenth, eleventh and twelfth cranial nerves of the opposite side. By the above nine nerves innervation is conducted to the muscles of the orbit; the muscles of mastication, and expression; the muscles of the tongue, palate and ear; the digastric and styloid muscles; the muscles of the larynx, trachea and bronchi, and of the pharynx, œsophagus, stomach, and the intestines down to the rectum. And inhibitory impulses are carried to the heart.

THE CEREBRO-CORTICOPONTAL PATHS, FRONTAL AND TEMPORAL.—These paths are indirect, for spinal nerves, since they run through the cerebellum. *Frontal.*—The impulses

originate in the prefrontal region, at the anterior end of the superior and at the foot of the middle and of the inferior frontal gyri, and descend through corona radiata, the anterior segment of the internal capsule and the inner (medial) fifth of the crusta; or *Temporal*.—They rise in the temporal cortex and run through corona radiata, the posterior segment and inferior lamina of the internal capsule, and the outer (lateral) fifth of the crusta. In both paths they run to the nucleus pontis of the same side and to motor nuclei of the cranial nerves, whence they proceed to spinal or cranial nerves. (1) To spinal nerves they run through the middle peduncle of the cerebellum to the cerebellar cortex and, thence, continue down the antero-lateral descending cerebellar tract to the anterior gray horn of the spinal cord. Their course from the cerebellar cortex is through the restiform body, the lateral area of the medulla and the antero-lateral column of the cord. From the gray matter of the spinal cord the impulses are conveyed by the motor fibers of the spinal nerves to the muscles which they supply. (2) To cranial nerves, the impulses run from the synapses formed in the cranial nuclei, by the fibers of the fronto-pontal and temporo-pontal tracts, through the motor fibers of the nerves to their distribution.

THE PATH THROUGH THE INTERMEDIATE BUNDLE OF THE CRUSTA.—Cortical impulses of unknown origin are received by the corpus striatum and conveyed by a bundle of centrifugal axones, which form the deep portion of the crusta, to the nucleus pontis, chiefly of the same side. The impulses thus traverse the internal capsule and a broad but thin area in the crusta just ventral to the substantia nigra and dorsal to the pyramidal tract. From the nuclei pontis, they proceed to the cerebellar cortex by way of the middle peduncle of the

cerebellum, and may continue down the descending cerebellar tract as already given.

PATHS THROUGH THE RED NUCLEUS.—There are two, a direct and an indirect. Impulses run from some part of the cerebral cortex to the optic thalamus and red nucleus or to the corpus striatum and red nucleus. From the red nucleus they pursue either a direct or indirect route.

(1) *Direct Route.*—By the direct route, impulses run through the crossed descending tract of the red nucleus to the center of the gray crescent in the opposite side of the spinal cord. Crossing the median raphe at once, in the hypothalamic region, the impulses descend by way of the above tract through the ventral part of the formatio reticularis of the mid-brain and pons, in the medial part of the lateral fillet, then through the lateral area of the medulla among the fibers of the antero-lateral ascending cerebellar tract, and finally down the spinal cord, through the dorso-lateral portion of the crossed pyramidal area, to their destination in the gray matter. From the center of the gray crescent they proceed with or without interruption to the anterior roots of the spinal nerves, and are conducted to the muscles.

(2) *Indirect Route.*—Impulses from the red nucleus may also run through the superior cerebellar peduncle, chiefly the opposite one, to the corpus dentatum, and thence, by axones from that nucleus, to the cortex of the cerebellum. The descending cerebellar tract continues their path to the anterior cornu of the cord.

SHORT FIBER PATHS.—Those are paths in the formatio reticularis chiefly. (1) Impulses having reached the great ganglia of the cerebrum and mid-brain may run down the formatio reticularis of mid-brain, pons and medulla and the

antero-lateral ground bundle of the spinal cord to the gray crescent of the same, and continue through the anterior root fibers to their destination. On the other hand, the impulses, leaving *formatio reticularis* in mid-brain, pons or medulla, may enter the nuclei of motor cranial nerves and be conducted by them to the muscles supplied by cranial nerves. (2) The impulses may leave the *formatio reticularis* in the pons, and run to the cerebellar cortex through the middle peduncle of the cerebellum. From the cerebellum they may follow the ordinary course through the descending cerebellar tract to the anterior gray horn of the cord; or (3) Impulses having arrived at the cerebellar cortex by way of the superior or middle peduncles, may descend through the cerebello-olivary tract, in the restiform body, to the opposite inferior olive, and be carried on through descending axones of the olive, in the antero-lateral ground bundle, to the gray matter of the cord (Koelliker). (4) Impulses descend from the nucleus of the third cranial nerve by way of certain fibers in the posterior longitudinal bundle to the seventh nerve, where it enters into the *eminentia teres*, and through the facial nerve innervate the *frontalis*, *pyramidalis nasi*, *corrugator supercilii* and *orbicularis palpebrarum*. Hence these muscles are not paralyzed in nuclear facial paralysis. But if the lesion be in the *eminentia teres* or distal to it, then facial paralysis is complete. (5) Through certain fibers in the posterior longitudinal bundle which rise in the nucleus of the sixth cranial nerve and cross to the opposite nucleus of the motor oculi, impulses run from the nucleus of the abducent through the opposite third nerve to the internal rectus oculi. They explain the conjugate deviation observed in lesions affecting the nucleus of the sixth nerve. In nuclear lesions of the abducent nerve the external rectus of the same eye

and the internal rectus of the other eye are paralyzed if the nucleus is destroyed and stimulated if the nucleus is only irritated.

II. AFFERENT, OR SENSORY, PATHS.

The sensory paths conduct two varieties of impulses, viz., General and Special. The impulses originate in the end-organs of the cranial and spinal nerves, and by those nerves are conveyed to the cerebro-spinal axis, through which they reach the proper cortical area in the cerebrum.

1. GENERAL SENSATION.

THROUGH COLUMNS OF GOLL AND BURDACH.—Goll's column is believed to carry impulses of the muscular sense, while impulses of all varieties of general sensation are transmitted by Burdach's column. Impulses originating in the end organs of the spinal nerves traverse the dendrites of the spinal ganglion neurones, the cell-bodies in the ganglia (Cajal), and then the axones of the same. They enter the cord through the posterior roots of the spinal nerves, and ascend through the tracts of Burdach and Goll, in the posterior column of the cord, to the nuclei of that column in the medulla oblongata, chiefly the nucleus gracilis and nucleus cuneatus. Thence the impulses may proceed either by a direct or by an indirect route.

(1) *The Direct Route* carries the impulses by way of the interolivary and medial fillet, through the sensory decussation of the medulla, the formatio reticularis of pons and mid-brain and the crista of the mid-brain, to the ventro-lateral nucleus of the optic thalamus, from which they are conducted by the three systems of Flechsig—namely, the anterior stalk of the thalamus, the ansa peduncularis and the ansa lenticularis—to the somæsthetic area of the cerebral cortex. In their last

stage the impulses run from the optic thalamus through the internal capsule and corona radiata to the equatorial zone of the hemisphere.

(2) *Indirect Route*.—By that route impulses from the nucleus gracilis and nucleus cuneatus run to the cortex of the vermis cerebelli superior through the external arciform fibers; then on, through the superior peduncle of the cerebellum, to the red nucleus and optic thalamus. They traverse the restiform body of the same side, by way of the posterior external arciform fibers; or, by way of the anterior external arciform fibers, they traverse the sensory decussation of the medulla and the opposite restiform body to reach the vermis cerebelli superior. From the cerebellar cortex, the impulses continue through cortical axones to the corpus dentatum, whose axones conduct them to the red nucleus and optic thalamus of the opposite side. The greater number, therefore, cross over in the tegmentum of the mid-brain. Their course from the red nucleus and optic thalamus is through the three systems of Flechsig to the cortex.

THROUGH CRANIAL NERVES AND MEDIAL FILLET.—As crossed fibers from the terminal nuclei of the trifacial, the vestibular, the glossopharyngeal and the pneumogastric nerves join the medial fillet and run to the optic thalamus, so impulses of common sensation, transmitted by those cranial nerves to the medulla and pons, are carried by the medial fillet to the ventro-lateral nucleus of the thalamus on the opposite side. The systems of Flechsig, chiefly the ansa peduncularis, conduct them to the lower portion of the somæsthetic area.

THROUGH DIRECT CEREBELLAR TRACT.—Clark's column of cell-bodies in the spinal cord receives impulses concerning equilibrium from the posterior roots of the spinal nerves and

transmits them at once to the direct cerebellar tract through which they ascend along the dorso-lateral surface of the cord, along the posterior surface and through the restiform body of the medulla to the cortex of the superior worm of the cerebellum. To a small extent they cross in the worm to the opposite side. From the cerebellar cortex the journey is completed in four stages, as already described, namely: Corpus dentatum, opposite red nucleus, optic thalamus and cerebral cortex.

THROUGH ANTERO-LATERAL ASCENDING CEREBELLAR TRACT.—Pathetic and thermic impulses are conveyed by this tract. Those impulses enter the center of the gray crescent of the cord, partly on the same side, through the posterior nerve roots and Burdach's column. A large number decussate in the above cerebellar tract, crossing in the anterior commissure, and run upward through the antero-lateral ascending cerebellar tract of the opposite side to the cortex of the superior worm of the cerebellum and to the optic thalamus. In the cord they ascend along the ventro-lateral surface. They run dorsal to the olive in the lateral area of the medulla oblongata, and through the lateral part of the formatio reticularis of the pons to the angle in Gower's tract. From the angle, just behind the quadrigeminal bodies, the greater number of impulses run backward with the tract through the valve of Vieussens to the cortex of the vermis cerebelli superior; the remainder run forward to the optic thalamus, and from that to the parietal cortex. The common course of sensory impulses from the cerebellar to the cerebral cortex is, as already described, through corpus dentatum and superior peduncle to opposite red nucleus and optic thalamus, though they may run through the middle cerebellar peduncle to the pons and then, by way of the formatio

reticularis, the medial fillet, or the posterior longitudinal bundle, ascend to the optic thalamus. Having arrived in the thalamus, they proceed thence by the three systems of Flechsig to the somæsthetic cortex.

THE SHORT FIBER PATHS.—(1) The antero-lateral ground bundle and formatio reticularis contain ascending axones which may convey sensory impulses from the gray matter of the cord, received from the posterior roots of the spinal nerves, or from terminal nuclei in medulla and pons which receive the common sensory fibers of cranial nerves, upward to the optic thalamus of the opposite side. The course from the thalamus by way of the cortical fillet is now familiar.

(2) Again, impulses may leave the formatio reticularis in the pons and run through the middle cerebellar peduncle, by way of axones from the nuclei pontis, to the cortex of the cerebellum; and then continue by the ordinary course through the superior peduncle to the red nucleus and optic thalamus.

(3) Certain fibers of the antero-lateral ascending cerebellar tract diverge from the others, in the medulla oblongata, and terminate in the lateral nucleus. Impulses of pain and temperature, following the same course, enter the lateral nucleus, and are carried on through the restiform body to the cerebellum by the tract from the lateral nucleus to the cerebellar cortex, thence to the somæsthetic area as previously given.

Destruction of any of the above sensory paths causes loss of the especial variety of impulse which travels that path. Destruction of Goll's column produces loss of muscular sensations, and cases are on record in which a cord lesion abolished pain and temperature sensations while touch was not affected.

2. SPECIAL SENSATIONS.

Impulses producing the sensations of smell, sight, hearing and taste are carried from the respective organs of sense to the brain by the following nerves: The Olfactory; the Optic; the Auditory; and the Glossopharyngeal, chorda tympani and pars intermedia.

OLFACTORY PATH.—Impulses of smell originate in the upper third of the Schneiderian membrane. They run through the olfactory nerves to the second layer in the bulb, where they are transferred to the dendrites of the mitral cells. By the axones of the mitral cells they are carried backward through the olfactory tract and roots to the cerebral hemisphere. The internal, or medial, root conducts them to the area of Broca and anterior end of the gyrus fornicatus, whence through the cingulum and uncinata fasciculus they reach the cortical area of smell in the uncus hippocampi. By the middle olfactory root the impulses enter the trigone and complete their journey either in the same manner as given above or via the anterior commissure. The external, or lateral, root of the olfactory tract conducts the impulses directly to the uncus of the hippocampal convolution. Note that olfactory impulses are chiefly, if not entirely, uncrossed.

OPTIC PATH.—Impulses of sight originate in the rods and cones of the retina and traverse three or more series of neurones to the terminal nuclei of the optic tracts; namely, the rod and cone, the bipolar and the ganglionar neurones. The axones of the last form the optic nerves and the visual part of the optic tracts. From the right halves of both retina and from the left halves of both, impulses run through the corresponding tract to the external geniculate body and the pulvinar of the optic thalamus; also to the superior quadrigeminal body and the nucleus of the motor oculi nerve.

The two latter produce ocular and pupillary reflexes. From the lateral geniculate body and pulvinar the optic radiations carry the impulses through the posterior segment of the internal capsule to the half-visual center in the cuneus and (to a small extent) the convex part of the occipital lobe. Impulses from the nasal halves of the retinae decussate in the optic commissure; those from the temporal halves, for the most part at least, remain on the same side, but a few may cross through the quadrigeminal bodies and superior brachia.

AUDITORY PATHS.—There are two auditory paths, the Cochlear and the Vestibular. The former is concerned with hearing and the latter with equilibrium.

1. *The Cochlear Path.*—Impulses of hearing originate in the organ of Corti. They are transmitted by the rods and hair cells of Corti to the dendrites of the spiral ganglion. Traversing the dendrites and cell-bodies of that ganglion, they enter the axones, which form the cochlear nerve, and run backward to the terminal nucleus of that nerve in the medulla. Both the ventral and the dorsal, or lateral, portions of the cochlear nucleus (ventral auditory nucleus) receive the impulses of hearing. From the cochlear nucleus they run either lateral and dorsal to the restiform body and cross to the opposite side through the acoustic striæ and trapezium, or they run medial to the restiform body and enter at once into the trapezium. By either course they reach the lateral fillet, and chiefly the opposite one. The lateral fillets conduct the impulses to the inferior quadrigeminal bodies; the inferior brachia to the internal geniculate bodies, and the acoustic radiations to the third and fourth fifths of the superior temporal and to the transverse temporal gyri of the cerebrum.

2. *Vestibular Path.*—The extent of the vestibular conduc-

tion path is from the acoustic areas of the utricle saccule and semi-circular canals to the vestibular nuclei in the floor of the fourth ventricle and, thence, to the cerebellum and the cortical area of equilibrium in the parietal cortex. It is the path of the space sense. Through the vestibular nerve the impulses reach the dorso-medial, dorso-lateral and superior auditory (vestibular) nuclei in the floor of the fourth ventricle and the spinal nucleus, which has not been definitely located, and they probably reach the nuclei in the cerebellum also (globosus and fastigii). The impulses may pursue, from the terminal nuclei in the ventricular floor, either a direct or an indirect course to the cerebral cortex.

(1) By the direct course they run through the opposite medial fillet and certain fibers in the three systems of Flechsig(?).

(2) The impulses run to the cerebellum, by the indirect course, through the acustico-cerebellar tract, and probably through uninterrupted fibers of the vestibular nerve in the restiform body. They thus reach the opposite nucleus fastigii and nucleus globosus; perhaps a number also reach the corpus dentatum and cerebellar cortex. From the cerebellum the course of the impulses is, presumably, through the superior peduncle to the red nucleus and optic thalamus of both sides and thence to the cortex. They may excite in the cerebellum impulses of equilibration which descend to the motor nuclei of spinal nerves in the anterior horns of gray matter by way of the antero-lateral descending cerebellar tracts.

Impulses, believed to be concerned with reflexes, run from the vestibular nuclei in the floor of the fourth ventricle (a) to opposite nuclei of motor cranial nerves via the posterior longitudinal bundle; (b) to the quadrigeminal bodies through

the superior and lateral fillets; and (c) to the inferior olive and lateral column of the spinal cord by way of the vestibulo-olivary and vestibulo-spinal fibers.

THE GUSTATORY PATHS.—They extend from the tongue to the glossopharyngeal nucleus in the medulla and thence through the opposite medial fillet and inferior lamina of the internal capsule to the taste area in the gyrus hippocampi. There are two paths from the tongue to the ninth nucleus. Those impulses from the base of the tongue and the palate run through the ninth nerve and those from the anterior two-thirds of the tongue through the chorda tympani and pars intermedia to the medulla (A. F. Dixon) (see note). Possibly, gustatory impulses originating in the palate may traverse the descending branches of Meckel's ganglion and the great superficial petrosal nerve to reach the geniculate ganglion on the facial; and, then, continue through the pars intermedia to the glossopharyngeal nucleus. All impulses arriving at this nucleus complete their journey in two stages: First, through the medial fillet to the opposite thalamus; and, second, through internal capsule to the hippocampal cortex.

Destruction of the olfactory conduction path on one side causes anosmia on the same side; of the optic tract or radiations, hemianopia in the corresponding halves of both retinae; of the auditory path above the pons, deafness chiefly on the opposite side; and interruption of the gustatory path above the medulla oblongata abolishes taste on the opposite (?) side.

Note.—Edinbg. M. J., 1897, Vol. I, p. 395, A. F. Dixon.

Amer. J. Med. Science, 1898, Vol. I, pp. 502-532, Cases VI and VII, Keen and Spiller.

III. REFLEX PATHS.

There is no visible limit to the number of reflex paths. Hence no attempt will be made to give them completely, but a few examples of various kinds will be given which may assist the student to trace others and be suggestive of their great multiplicity and importance.

Reflex arcs are formed (1) by the sensory and motor fibers of spinal nerves, associated in the gray matter of the cord; (2) by the sensory and motor fibers of cranial nerves, which are connected in the brain; (3) by afferent spinal fibers, the posterior longitudinal bundle, chiefly, and efferent cranial fibers; and (4) by afferent cranial and efferent spinal nerve fibers, the two being associated by the anterior longitudinal bundle, the spinal root of the fifth nerve, the vestibulo-olivary and vestibulo-spinal tracts, the solitary bundle, etc.

(1) SPINAL REFLEXES.—In the simplest spinal reflexes, the afferent fibers of the arc arborize about the cell-bodies whose axones constitute the efferent fibers. Among them are the skin and muscle reflexes, such as the plantar, the patellar, the gluteal and the cremaster reflexes, the involuntary withdrawing of a part from a source of irritation, etc.

More complicated spinal reflexes are those of defecation, micturition, parturition, vasomotor reflexes, cardio-accelerator reflexes, etc. The impulses traverse at least three neurones in these reflexes. As an example, trace a defecation reflex.

Defecation Reflex.—The rectum is supplied by the third and fourth sacral nerves and by branches of the inferior mesenteric and hypogastric plexuses. Irritation of the sensory endings in the mucous membrane is caused, normally, by the presence of feces. The impulses caused thereby run to the special defecation center in the lumbar enlargement of the spinal cord, either by way of the sacral nerves or through

the sympathetic plexuses, the ganglionated cord, and the rami communicantes to the lumbar nerves, through the posterior roots of which they reach the center in the cord. From the defecation center the impulses pursue two courses: (a) They descend through the third and fourth sacral nerves and cause inhibition in the circular fibers of the rectum and contraction of the longitudinal muscle. (b) This action is immediately followed by impulses which pursue the sympathetic course, through the anterior roots of the lumbar nerves, the rami communicantes, the ganglionated cord, and the inferior mesenteric and hypogastric plexuses, to the rectum. They cause, in succession from above downward, contraction of the circular muscle of the rectum. The two series of impulses thus open a way for the passage of fecal matter; and, then, force it through the opening unless prevented by the voluntary contraction of the external sphincter.

(2) CRANIAL REFLEXES.—The simplest of these reflexes are such as spasm of the muscles of mastication caused by a bad tooth, in which both limbs of the arc are formed by the trifacial nerve. Again, the facial expression of pain due to the same cause. In this the impulses traverse the trifacial nerve and by the collaterals of its root-fibers reach the nucleus of the facial. Through the facial they cause contraction of certain muscles of expression.

Salivary reflexes, in which the sight of a fine dinner or the smell of it causes the flow of saliva; coughing, sneezing, vomiting reflexes and deglutition reflexes are more complicated, but, knowing the nerve supply of the parts involved, the student can trace the impulses.

(3) SPINAL AND CRANIAL REFLEXES.—Impulses received by the spinal cord through the afferent fibers of its nerves are transmitted by the posterior longitudinal bundle to the

nuclei of motor cranial nerves, or, perhaps, through Burdach's column and the interolivary fillet to the same nuclei. Thus is brought about the movement of the eyes toward the source of impulse, a change of facial expression to agree with the painful or pleasing character of the impulses, etc.

(4) CRANIAL AND SPINAL REFLEXES.—Of these there are many. Let us notice three.

Respiratory Reflex.—Any obstruction or irritation in the larynx or trachea sends an impulse through the pneumogastric nerve to its sensory nucleus and, through its descending branches, in the solitary bundle, to the nucleus ambiguus and nucleus of the phrenic nerve in the cervical cord, causing increased respiratory effort, coughing, spasm of muscles closing the glottis, etc.

Auditory Reflex.—Turning of the head upon hearing a sound, and the sudden starting, caused by hearing a loud sound, are illustrations of this reflex. The path for the latter is probably as follows: The auditory nerve, the vestibulo-olivary and vestibulo-spinal tracts, antero-lateral ground bundle and efferent fibers of spinal nerves.

Pupillary Reflexes.—Pupillary reflexes belong to the cranial and cranio-spinal group of reflexes. The cilio-spinal centers are in the cervical enlargement of the spinal cord, the pupillo-dilator in the upper and the pupillo-constrictor in the middle part of that enlargement. They receive optic impulses through the anterior (or ventral) longitudinal bundle from the corpora quadrigemina superiora. The superior quadrigeminal bodies receive those impulses by two routes: First, directly, through the fibers of the external root of the optic tract, and, second, indirectly, through centrifugal fibers in the optic radiations, and the superior brachium. By the latter route, the optic impulses which have reached the visual

area of the occipital lobe, by way of the intrinsic retinal neurones and the optic nerves, tracts and radiations, are returned to the optic thalamus and external geniculate body and then carried back to the superior quadrigeminal bodies. Thence, reaching the cilio-spinal centers through the anterior longitudinal bundle, the impulses take one of two courses: (a) They leave the spinal cord through the anterior roots of the upper thoracic nerves and run, in succession, through the rami communicantes, the cervical cord of the sympathetic, the cavernous plexus, the ciliary ganglion and the short ciliary nerves to the radiating fibers of the iris, causing dilation of the pupil. (b) From the pupillo-constrictor center, the impulses are carried upward by the posterior longitudinal bundle to the nuclei of the motor oculi nerve, where they are reinforced by optic impulses received directly through the superior quadrigeminal body and posterior commissure. The impulses reach the ciliary muscle and the circular muscle of the iris through the motor oculi, ciliary ganglion and short ciliary nerves. The results are contraction of the pupil and accommodation for distance.

CHAPTER XI.

EMBRYOLOGY OF THE BRAIN AND SPINAL CORD.

The brain and spinal cord are developed from the *neural tube*; the spinal and sympathetic ganglia and the ganglia of sensory cranial nerves are derivatives of the *neural crest*.

Very soon after conception there appears along the median line, in the back of the embryo, a plate of epiblast, called the medullary plate. That plate soon presents two longitudinal elevations, the medullary ridges, separated by a median furrow, the neural groove. The rapid growth and infolding of the medullary ridges roofs over and closes in the neural groove and thus forms the neural tube. That approximation of the medullary ridges produces a slight median elevation, which is the neural crest. By the fifteenth day after conception the neural tube and crest are complete, except posteriorly, where the neural groove is still open.

Meninges.—Later the neural tube becomes surrounded by mesoblast which forms the pia mater, arachnoid and dura mater.

The Neural Crest.—(1) The *cephalic portion of the neural crest* becomes broken into five pairs of ganglia, which, during development, shift their positions to the ventral side of the brain. Those ganglia are called the Jugular, Petrosal, Geniculate, Auditory and Gasserian. They give origin to the sensory parts of the pneumogastric, glossopharyngeal and facial nerves; all of the auditory nerve, and the sensory part of the trifacial. In all of the ganglia, except the auditory,

the cells develop into unipolar neurones; they remain bipolar in the auditory ganglion. The single processes of the unipolar neurones immediately divide, T-like, into peripheral and central fibers, which in appearance are axones. The peripheral fibers form the sensory part of the respective nerves and conduct impulses toward the cell-body, hence they may be considered dendrites (Cajal); the central fibers, the axones proper, form the part of the sensory nerve between the ganglion and the brain. From the auditory ganglion, which moves backward to a point behind the geniculate ganglion, the dendrites run outward to the acoustic areas of the internal ear; the axones enter the medulla oblongata. All the central axones of the several ganglia divide, T-like, upon entering the brain, and collaterals rise from the undivided fibers and from both branches of them. These axones and collaterals arborize, chiefly, in the terminal nuclei of the respective nerves; but certain of them, the excito-reflex fibers, terminate in nuclei of motor nerves.

(2) The *spinal portion of the neural crest* forms the thirty-one pairs of Spinal Ganglia situated on the posterior nerve-roots; and, also, the Vertebral, Prevertebral and Terminal Ganglia of the sympathetic system. The sympathetic ganglia wander widely. In them the epiblastic cells develop into multipolar neurones, the nonmedullated processes of which constitute the larger number of gray fibers in the sympathetic system. The cells of the spinal ganglia form unipolar neurones, like those of the jugular, petrosal, geniculate and Gasserian ganglia. Like them, also, the single processes divide, T-like, the peripheral arms of the T-branches forming the sensory part of each spinal nerve and the central arms (the axones) the posterior roots of those nerves. The latter enter the cord at the postero-lateral fis-

sure and, before and after dividing T-like into an ascending and a descending branch, give off collaterals. The descending fibers (axones and collaterals) arborize in the gray matter of the cord; the ascending axones and collaterals terminate chiefly in the spinal cord, and in the nuclei of its posterior columns, namely, the nucleus gracilis and nucleus cuneatus. A few ascending fibers end in the cerebellum and cerebrum.

The Neural Tube.—It is well formed at the fifteenth day. The cephalic, or closed, end of the tube is much larger than the caudal end, and presents at this time two constrictions that separate the *Primary Brain Vesicles* from one another—the *anterior*, the *middle* and the *posterior*. Behind the posterior primary vesicle, the neural tube remains small and of nearly uniform size; that part forms the spinal cord.

The neural tube, up to the fourth week, is composed of a single layer of long columnar cells whose ends form the exterior and interior surfaces of the tube. The cells contain a nucleus in their middle third and present a central and a peripheral clear zone. In the central clear zone, near the interior surface of the tube, there may be observed between the fourth and the fifth week a number of small, round, nucleated cells, the nuclei of which are in all stages of karyokinesis. These are the *germinating cells* (His). Soon they become elongated and send out a protoplasmic process from what was originally (i. e., before the formation of the neural tube) the deep, or proximal, end of the cell. Now they are *neuroblasts*, because they are the parents of the *neurones*. The protoplasmic processes form the *axones*, and other processes may or may not develop. Both the axones and dendrites grow in the direction of least resistance (His). While the neuroblasts are developing, the columnar cells of the neural tube undergo great changes. They become more

and more elongated and, by a process of vacuolation, their protoplasm becomes perforated and branched and so broken up as to entirely destroy the original outlines of the cells. The branches appear to unite and form a sort of radial net-work in the peripheral clear zone, called the *myelospongium*. The elements of the myelospongium are the *spongio-blasts*; they form the *neuroglia*. At this time the *Three Histologic Layers* begin to show, namely, (1) the outer layer (neuroglia), (2) the middle, or mantle, layer, composed of neuroblasts, and (3) the inner, or ependymal, layer; also at this time a lateral *longitudinal groove* appears, which extends from the mesencephalon to the caudal end of the tube. The groove is on the ventricular surface. It gives the lumen of the tube a diamond shape, on section, and separates the *ventral* from the *dorsal zone*. The ventral zone is motor and the dorsal is sensory.

BRAIN.

The brain vesicles grow rapidly. By the end of the fourth week a constriction is visible in the anterior primary vesicle and another in the posterior primary vesicle, dividing each into two and making in all *Five Secondary Brain Vesicles*, which freely communicate with one another and are numbered from before backward. They are:

1. Prosencephalon, or telencephalon.
2. Thalamencephalon, or diencephalon.
3. Mesencephalon.
4. Epencephalon.
5. Metencephalon, or myelencephalon.

These vesicles form the brain, their cavities becoming the ventricles. The neuroblasts of the mantle layer produce the neurones, whose cell-bodies and dendrites are found in the cortex and ganglia, and whose medullated axones form

the white substance. The supporting neuroglia is formed by the spongioblasts of the neuroglial and ependymal layers.

Flexures.—The cephalic portion of the neural tube is the seat of three flexures, two ventral and one dorsal. (1) *The mesencephalic flexure* (ventral) begins very early and amounts to nearly 180 degrees by the twenty-eighth day. It bends ventrally the thalamencephalon until it almost touches the epencephalon. Thus the inter-brain and pons are approximated. (2) *The cervical flexure* is also a ventral one, It is located at the junction of the fifth vesicle with the spinal cord, and corresponds to the bending of the head upon the body of the embryo. This flexion begins about the twenty-first day. By the end of the fourth week, it is completed and amounts to 90 degrees. (3) *The dorsal flexure* is beginning to form at the same time (fourth week). It occurs between the fourth and fifth brain vesicles, and is often called the *metencephalic flexure*. It reaches 180 degrees by the eighth week, when the dorsal part of the epencephalon (the cerebellum) rests upon the metencephalon (the medulla oblongata). The cervical and metencephalic flexures almost entirely disappear, but the mesencephalic flexure is permanent.



TABLE III.

BRAIN VESICLES AND THEIR DERIVATIVES.

Primary Vesicles.	Secondary Vesicles.	Derivatives and Ventricles.
Anterior (Fore-brain).	1st. The Prosencephalon.	Hemispheres and Anterior wall of third ventricle. (Foramina of <i>Monro</i> , lateral ventricles, hemispheres, corpora striata, olfactory lobes, fornix, anterior commissure, corpus callosum and lamina terminalis.)
	2d. The Thalamencephalon.	Inter-brain and third ventricle, except anterior wall. (Optic thalami, external geniculate bodies, posterior and middle commissures, pineal body, roof epithelium of third ventricle and the third ventricle, corpora albicantia, tubercinereum and infundibulum, lamina cinerea, retinae, optic nerves, chiasm and tracts.)
Middle (Mid-brain).	3d. The Mesencephalon.	Mid-brain and Aqueduct of <i>Sylvius</i> . (Crustae, substantia nigra, tegmentum, Sylvian aqueduct, corpora quadrigemina and internal geniculate bodies.)

Posterior (Hind-brain).	{	4th. The Epencephalon.	{	Hind-brain. (The pons and cerebellum.)	4th Ventricle.
		5th. The Metencephalon.		After-brain. (The medulla oblongata.)	

The cerebrum is developed from the anterior primary brain vesicle as is shown in the outline, being the more immediate descendant of the prosencephalon and thalamencephalon.

PROSENCEPHALON.

It is at first a single vesicle forming the fore part of the anterior primary vesicle. The median portion of its anterior wall (lamina terminalis) remains almost stationary; laterally, it is the seat of rapid growth and produces on either side a hollow diverticulum, whose cavity is the primitive lateral ventricle and whose walls form the substance of the hemisphere. The outgrowth is called the *hemisphere vesicle*, its constricted stalk contains the primitive *foramen of Monro*. The vesicles grow forward and outward at first, separated from one another by mesoblast which forms the falx. Later, growth occurs in succession, upward, backward and downward, until by the seventh month the hemisphere overhangs every other part of the brain.

Olfactory Lobe.—In the fifth week a hollow diverticulum grows out from the antero-inferior wall of the hemisphere vesicle and forms a prominent lobe. It preserves a lobular form in the horse, and in some other animals; but in man it soon becomes constricted by the *fissura prima* into an *anterior* and a *posterior lobule*, and loses its ventricular cavity. The anterior olfactory lobule develops the olfactory bulb, tract, trigone, and the area of Broca; the posterior lobule forms the anterior perforated lamina.

Primary Sulci.—The vesicle walls are of uniform thinness up to the second month, being composed of a single layer of columnar cells. During their rapid growth in the second and third months they become thrown into folds which encroach upon the cavity and present on the surface of the vesicle (or hemisphere) the primary sulci. The cause of the infoldings is, perhaps, the resistance of the slower growing cranium. The primary sulci are best developed in the third month. Their location nearly corresponds to the following permanent fissures: Sylvian, Parieto-occipital, Calcarine, Hippocampal, Collateral and Anterior Great Transverse (choroid) fissure. The hippocampal fissure is the inferior part of the Fissura Prima. The superior part of the latter corresponds to the fissure of the corpus callosum, and the anterior, which is transverse, separates the olfactory trigone from the anterior perforated space. For the most part the primary sulci have disappeared by the first of the fifth month (at this stage the cranium grows more rapidly than the brain vesicles); but the ventricular eminences produced by the sulci are permanent, namely, the hippocampus major and minor and eminentia collateralis. Possibly the caudate nucleus belongs in the same group.

Permanent Fissures.—In the sixth month the primary sulci are replaced by the important permanent fissures, which divide the hemisphere into lobes. Many of the smaller permanent sulci appear after birth. The permanent fissures, or sulci, are the result of depressions in the surface; they do not involve the whole thickness of the ventricular wall. Their object is probably to preserve a certain ratio between the cortex and the white matter in the hemisphere. (For the permanent fissures, see Exterior Surface of the Cerebrum.) Two of the permanent fissures are peculiar, namely:

(1) *The Fissure of Sylvius* is formed by the approximation of the anterior and posterior walls of the broad Sylvian valley, or primary sulcus, in the ventral border of the hemisphere. The bottom of the valley develops the corpus striatum and the island of Reil. The latter is concealed before birth by a backward and downward growth of the anterior wall, forming the orbital, frontal and fronto-parietal opercula. The forward and downward growth of the posterior wall completes the fissure and forms the temporal lobe.

(2) *The Anterior Great Transverse Fissure, or Choroid Fissure.*—It is produced by a curved invagination of the medial wall of the hemisphere vesicle. Beginning just behind the stalk of the vesicle, which contains the foramen of Monro, it extends backward to a point opposite to the posterior end of the optic thalamus, and then bends downward and forward toward the apex of the temporal lobe. It involves the entire thickness of the vesicle wall, though it is a permanent fissure, and the fold which it pushes into the lateral ventricle persists as a single layer of epithelium investing the choroid plexus, hence the name *fissura choroidea*. In the developed brain the anterior great transverse (choroid) fissure is situated between the fornix and the tænia semicircularis.

Thickenings.—The walls of the hemisphere vesicle thicken rapidly as the vesicle grows in size, and form the cortical and medullary substance. By the end of the second month the *corpus striatum* is well formed, near the middle of the floor of the hemisphere; and a ridge appears about the same time in the medial wall of the vesicle along the convexity of the anterior great transverse fissure. That ridge develops into a bundle of fibers constituting a *lateral half of the fornix*. Along the concave side of the same fissure another and

slighter ridge appears which is the primitive *tænia semi-circularis*.

Fusions.—The hemisphere vesicle so increases in size by the eighth week of embryonic life as to come in contact with its fellow of the opposite side, and with the dorsal and lateral surfaces of the thalamencephalon. At those two points of contact certain fusions occur:

(1) *Fusion of the Hemispheres with Each Other.*—The hemisphere vesicles touch one another in front of the lamina terminalis. The *area of contact* is at first small and is crescentic in shape. The convexity of the crescent looks forward and its horns diverge backward. Along the borders of this crescent the two hemispheres grow together. The crescents themselves, remaining free, form the *septum lucidum* and inclose between them the fifth ventricle. *First*, a strong round bundle of fibers is thrown across at the anterior inferior angle of the crescent, which is the *anterior commissure*. Pressure of the anterior commissure against the lamina terminalis causes the latter to be absorbed back to its lining epithelium. That epithelium separates the commissure from the third ventricle in the adult. *Second*, fusion occurs along the concave border (the postero-inferior) of the crescent. That border coincides with the fornix ridge above referred to; and fusion of the two ridges forms the *body of the fornix*. The anterior pillar hooks around the foramen of Monro, and turns back into the lateral wall of the thalamencephalon; the posterior pillar grows backward with the hemisphere. Certain fibers are thrown across between the posterior pillars to form the *commissura hippocampi*. *Last*, fusion occurs along the convexity of the crescent. It forms the *corpus callosum*. The rostrum and genu are first developed. Like the fornix, it grows with the hemispheres

backward until completed. With the development of the corpus callosum the borders of the crescentic area are completely fused and the *fifth ventricle* inclosed.

(2) *Fusion of the Hemispheres with the Thalamencephalon.*—Fusion occurs between the hemisphere vesicle and the lateral surface and a small part of the superior surface of the thalamencephalon. The blending of the medial wall of the hemisphere and the external surface of the thalamencephalon is produced by the growth of that fan-shaped group of fibers called the *superior lamina of the internal capsule*. The growth of the fibers which form the internal capsule from the cortex downward and from the optic thalamus and other ganglia upward is the cause of that blending. On the superior surface of the thalamencephalon, fusion takes place as far medialward as the oblique (choroid) groove on the optic thalamus (which see). Here the hemisphere wall is represented by a single layer of epithelium, which invests the optic thalamus on the superior surface external to the choroid groove. It is continuous toward the median line with the fold inclosing the choroid plexus; and it extends between the *tænia semicircularis* and margin of the fornix. The epithelium is in continuity with the ependymal lining of the lateral ventricle.

Velum Interpositum.—The growth of the meninges and brain vesicles occurs *pari passu*. The pia mater is at all times in contact with the surface of the vesicles; and it gives off branching trabeculæ which form the connective tissue network of the nerve substance. Wherever fusion between the brain vesicles occurs, the two layers of pia are absorbed; and they unite with one another just beyond the line of fusion. Thus the pia of the hemispheres unites above the corpus callosum and beneath the fornix, when those connect-

ing links are formed between the hemispheres. The pia beneath the fornix is, therefore, continuous with that covering the lower half of the medial wall of each hemisphere; and, by growth of the hemispheres and fornix, it is carried back over the pia investing the thalamencephalon. Fusion of the thalamencephalon with each hemisphere causes absorption of the double layer of pia mater upward to the choroid groove on the thalamus and union of the two laminae along that groove. The result is a triangular sheet made up of two layers of pia, the *velum interpositum*. The *velum interpositum* separates the fornix from the inter-brain in the mature organ. Its inferior layer, called the *superior choroid tela*, adheres in its median portion to the roof epithelium of the third ventricle. Two longitudinal folds in the superior choroid tela constitute the *choroid plexuses* of the third ventricle. The borders of the *velum* form the *choroid plexus* of each lateral ventricle.

THALAMENCEPHALON.

This is the posterior division of the anterior primary vesicle. It forms the **Inter-Brain** and the **Third Ventricle**, except its anterior boundary. Before the anterior primary vesicle is divided and the thalamencephalon constricted off from the prosencephalon, the *Optic Vesicle* makes its appearance on either side. It is a prominent diverticulum at first; but it grows, in man, less rapidly than the vesicle from which it rises. The optic vesicle becomes cupped, and is then the *primitive retina*. From it the *optic nerves* grow back to the ventral surface of the thalamencephalon, where they help to form the *optic chiasma* and *tracts*. Later, the tracts grow back along the side of the thalamencephalon, and become connected with the external geniculate body, optic thalamus and corpora quadrigemina.

The **Optic Thalamus** is formed by thickening of the **Lateral Wall** of the second vesicle. It fuses externally with the hemisphere (*corpus striatum*) and forms the *superior lamina of the internal capsule*. Internally, it fuses at one point with its fellow of the opposite side, forming the *middle commissure*. The medial surface presents a longitudinal groove, the *sulcus of Monro*, which is supposed to separate the ventral and dorsal zones of the thalamencephalon. A slight thickening of the postero-inferior wall of the thalamencephalon is the primitive *external geniculate body*.

From the **floor** of the thalamencephalon are developed the corpora albicantia (at first single); the tuber cinereum and infundibulum and the lamina cinerea.

The **Superior Wall**, or **Roof**, of this second vesicle stretches out and becomes very thin, except at its posterior extremity, where it develops a transverse white band, the *posterior commissure*. Immediately in front of this commissure, a diverticulum of the roof appears which is the primitive *pineal body*. Two longitudinal folds of the roof dip down into the ventricular cavity. These are followed by two like downward projecting folds from the inferior lamina of the velum interpositum, which constitute the *choroid plexuses* of the third ventricle.

MESENCEPHALON.

This is the **Embryonic Mid-Brain**. It is the third of the secondary vesicles. The elbow of the mesencephalic flexure of 180 degrees is formed by it; and that flexure almost brings the thalamencephalon and epencephalon in contact with one another beneath it. The mesencephalon remains small, but its walls thicken greatly. As a result of the thickening, its cavity is reduced to a slender canal, the *aqueduct of Sylvius*, in the floor of which develop the *nuclei*

of the third and fourth pairs of cranial nerves. The latter is developed in the constriction (isthmus of His) between the third and fourth brain vesicles. The walls of the mesencephalon form, *ventrally*, the substantia nigra and part of the tegmentum; and, *dorsally*, the remainder of the tegmentum. The down-growth of the motor fibers of the internal capsule, along the ventral surface of the mesencephalon, produces the *two crustæ*. About the third month the dorsal thickening is divided by a fore and aft groove, the sulcus longitudinalis. A transverse groove appears two months later and completes the *crucial groove* and the outline of the *corpora quadrigemina*. The antero-lateral part of the roof forms the *internal geniculate body*. By the growth of fibers which connect the geniculate bodies with the corpora quadrigemina, the *superior* and *inferior brachia* are formed.

EPENCEPHALON.

The fourth brain vesicle is the **Rudimentary Hind-Brain**. It forms the *pons* and *cerebellum*, the former from its floor and the latter from its roof. Superiorly, its cavity contracts to the size of the Sylvian aqueduct; it expands inferiorly and is broadest at the junction of the pons with the medulla oblongata. The ventricular surface presents on each lateral wall a *longitudinal furrow* which divides the epencephalon into a ventral and a dorsal zone. The *ventral zone* is composed of the floor and ventro-lateral, or basal, laminae, and the *dorsal zone* is made up of the roof and dorso-lateral, or alar, laminae. We shall find this division continued in the metencephalon and the spinal part of the neural tube.

Cerebellum.—A long transverse thickening may be observed in the superior part of the epencephalon-roof as early as the second month. The inferior part of the roof remains thin. At the third month that ridge presents a median

enlargement, divided by three transverse fissures, which is the embryonic *valve of Vieussens* and *vermis cerebelli*. The lateral portions of the transverse ridge grow rapidly after the third month. They form the *cerebellar hemispheres*. At first the hemispheres are smooth, but they become lobulated about the fifth month and foliated a month later. The *Cerebellar Peduncles* are completed at the same time. The *Inferior* appear first and produce a prominent ridge in each lateral wall of the epencephalon at the third month. A month later the *middle peduncles* are formed and the *superior* are completed about the fifth month. The peduncles are produced by the growth of axones from various masses of neuroblasts.

Pons.—The pons develops simultaneously with the cerebellum. The **ventral zone** of the epencephalon thickens greatly. The neuroblasts formed therein constitute the *nuclei of the pons* and of the *reticular formation*, and the *motor nuclei* for the *fifth, sixth and seventh pairs of cranial nerves*; the **dorsal lamina**, in the lateral wall of the epencephalon, produces the neuroblasts which form the *superior olivary nucleus* and the *superior terminal nucleus* of the sensory part of the *trifacial nerve*. From the nucleus pontis axones ascend through the lateral walls of the epencephalon to the cerebellum and others descend from the cerebellum by the same course to the pons. They form the *middle cerebellar peduncles*. At the same time, about the fourth month, the motor tracts composing the crustæ of the mid-brain grow downward into the ventral portion of the pons and the fronto-pontal, temporo-pontal and intermediate tracts end in the nuclei pontis. The pyramidal fibers to motor nuclei of bulbar and spinal nerves grow down through the pons, intersecting its transverse fibers.

METENCEPHALON.

The metencephalon forms the **Medulla Oblongata**. It is constricted off from the epencephalon at the twenty-eighth day; but, later, that constriction largely disappears and the common cavity of the two vesicles, broad in the middle and contracted to a slender canal at each end, persists as the *fourth ventricle* of the mature brain. Like the epencephalon, the fifth brain vesicle is divided at the third week into a *ventral* and a *dorsal zone* by a deep furrow on the ventricular surface of each lateral wall. That lateral furrow, as regards position, is represented in the mature organ by the *dorso-lateral groove* on the exterior surface of the medulla and it actually persists in the *superior* and *inferior fovea* of the fourth ventricle. The anterior and lateral columns of the medulla, which are anterior to the dorso-lateral groove, are therefore developed in the ventral zone; and the structures situated behind the dorso-lateral groove, namely, the posterior columns, the restiform bodies and the roof epithelium, are formed in the dorsal zone.

The roof of the superior half of the metencephalon stretches out widely and remains a single layer of epithelial cells. It forms no nerve tissue. Other portions of the metencephalon develop quite uniformly. But by the expansion of the roof, just mentioned, the dorsal extremities of the lateral walls are pushed outward and forward almost to the plane of the floor, and a transverse section of the vesicle in that region presents the form of a very broad capital V with the roof epithelium stretching between the two arms and converting the letter into a triangle. Transverse section through the lower half of the metencephalon at the third or fourth week shows an elongated ellipse with a dorso-ventral major axis.

Internal Surface.—The lateral wall, in both upper and lower regions, presents the longitudinal groove which separates the ventral and dorsal zones. The median ventral groove persists throughout and the lateral grooves are represented by the *fovea* of the fourth ventricle. The low eminence situated between the median and each lateral groove becomes the *fasciculus teres*.

External Surface.—On the external surface of the metencephalon and along the ventral border of the dorsal zone, there appears very early an oval bundle of descending fibers, called the *solitary bundle*. It is composed of axones from the jugular and petrosal ganglia, and constitutes the descending root-fibers of the ninth and tenth pairs of nerves. At about the same time axones from the Gasserian ganglion form a bundle of descending fibers on the lateral surface dorsal to the solitary bundle. They constitute the so-called ascending *root of the trifacial nerve*. Soon after the appearance of the solitary bundle and the “ascending” root of the fifth nerve, the posterior margin of the dorso-lateral lamina is folded outward and forward until it rests upon the external surface of the ventro-lateral lamina. That fold covers both the above bundles of fibers and places them in the position they occupy in the mature brain.

The Substance of the Metencephalon, like other divisions of the neural tube, presents, under the microscope, three distinct zones at the fourth week of embryonic life. The outer layer is composed of *neuroglia*; the middle, or mantle, layer of *neuroblasts*; and the inner, or ependymal, layer is made up of *columnar epithelial cells*.

The *Cells of the Inner Layer* become ciliated and form the lining of the ventricle.

The *Mantle, or Middle, Layer* undergoes most develop-

ment. Its neuroblasts form the *formatio reticularis* and the cranial nerve and other nuclei of the medulla oblongata. In the **dorsal zone** the neuroblasts form the *terminal nuclei* for the eighth, ninth and tenth cranial nerves and the *nucleus gracilis*, *nucleus cuneatus* and *nucleus of Rolando*. As early as the fourth week axones may be traced from the last three nuclei, ventro-medially, toward the point where they very soon form the *sensory*, or *fillet*, *decussation*. Neuroblasts which have wandered from the dorsal zone form the *olivary* and *accessory olivary nuclei* quite late in intra-uterine life (6th month). From the neuroblasts of the **ventral zone** are developed the gray matter and fibers of the *formatio reticularis alba et grisea*, and the *motor nuclei* of the twelfth, eleventh (accessory part), tenth and ninth pairs of cranial nerves.

The *Neuroglia Layer* forms the supporting matrix for the tracts of fibers, and the raphe of the medulla. By the third month the fasciculus gracilis, fasciculus cuneatus and fasciculus of Rolando, extensions of Goll's and Burdach's columns in the cord, have grown up to their terminal nuclei in the medulla. The restiform body is at that time well developed, and the tracts of the lateral area of the medulla are visible. The posterior longitudinal bundles appear near the median raphe in the ventral zone at about the same time; and, ventral to them, fibers from the sensory decussation form the interolivary fillets. The great motor tracts from the Rolandic area of the cortex reach the medulla at the fourth month. Growing downward, on either side of the median line, they conceal the interolivary fillets and form the pyramids of the medulla oblongata. The form of the medulla is completed two months later (the 6th month) by the appearance of the olivary bodies.

SPINAL CORD.

That portion of the neural tube which is situated behind the metencephalon is the embryonic spinal cord. It is of nearly uniform size from cephalic to caudal end. Inferiorly, it is open into the alimentary canal for a short time. The lumen of the neural tube is at first large and elliptical in shape. Later, at the sixth week, it has a diamond shape, the acute angles of the diamond being formed by the roof and floor of the canal, and it is lined with columnar ciliated cells. As the walls thicken the canal is contracted more and more until it reaches the capillary size of the adult cord. It is continuous with the fourth ventricle above and dilates to form the *inferior rhomboid fossa* in the *filum terminale*. The neural tube forms the whole substance of the spinal cord, with the exception of the great motor tracts that grow into it from the brain, and the sensory tracts and fibers that enter it from the spinal and sympathetic ganglia. At the sixth week of embryonic life the anterior and posterior roots of the spinal nerves are clearly seen; they are horizontal in direction. The cord extends the entire length of the spinal canal until the third month, when the caudal end begins to recede. It reaches only to the third lumbar vertebra at birth and, in the adult, but to the lower border of the first lumbar vertebra. With the rapid growth of the spinal column, the roots of the lumbar, sacral and coccygeal nerves become greatly elongated and, together with the *filum terminale*, form the *cauda equina*. *Meninges*.—The investing mesoblast of the neural tube develops the meninges of the spinal cord.

Zones.—By the sixth week of intra-uterine life the neural tube is divided into a ventral and a dorsal zone by a lateral groove on either side continuous with those dividing the

metencephalon and epencephalon. The tube presents externally, opposite to each lateral groove, a furrow called the *central fissure*, which is occupied later by the crossed pyramidal tract. The whole of the spinal cord anterior (or ventral) to the cervixes of the posterior cornua of gray matter is represented by the *ventral zone*. In the *dorsal zone*, the heads of the posterior cornua and the posterior columns are developed. The cervix of each posterior horn is formed by the thin lamina connecting the two zones.

Three Histologic Layers.—At a time somewhat earlier than the division into ventral and dorsal zones, even at the fourth or fifth week, the spinal part of the neural tube presents three microscopic layers, like those seen earlier in the metencephalon and other brain vesicles.

The *Outer Layer*, composed of neuroglia, is very thin except in the floor of the tube on either side of the median line; and later, in the corresponding parts of the roof. In those situations are formed the anterior and posterior columns of the cord. The central fissure (see above), also, presents a thickening of neuroglia through which grow the crossed pyramidal and direct cerebellar tracts.

The *Second Layer* is gray matter. It is the mantle layer and contains the neuroblasts. At the fourth or sixth week it is very thick, comprising nearly all of the neural tube. The *H-shaped column of gray substance* is derived from this layer. In the **ventral zone** the neuroblasts collect near the floor of the tube and form a large column on either side of the median line. The axones of the more ventrally located neuroblasts, *anterior cornua*, grow centrifugally out of the antero-lateral surface of the neural tube. They form the *anterior roots* of the spinal nerves. The more dorsally located neuroblasts develop axones also; but on account of

meeting resistance, according to His, they become longitudinal and form the *ground bundles* of the cord and the *antero-lateral ascending cerebellar* and *direct cerebellar tracts*. The gray matter in the **dorsal zone** becomes transformed into the *heads of the posterior cornua*; its neuroblasts form only intrinsic neurones, their processes remaining in the spinal cord. Axones from the spinal ganglia, forming the *posterior roots* of the spinal nerves, grow into the dorsal zone; and each axone divides T-like into a small descending and a large ascending branch, and also gives off many collaterals both before and after division. The ascending fibers for a time form the *oval bundle* of His on the surface of the tube; later, they constitute the tract of Lissauer, most of Burdach's and all of Goll's columns.

The *Third Layer*, the ependymal layer, lines the ventricle. It is composed of neuroglia covered, internally, by columnar ciliated cells, which appear about the fifth week.

The Longitudinal Tracts.—The white columns of the spinal cord are formed in the superficial, or neuroglial, layer. At first they are composed of non-medullated fibers, and it is a remarkable fact that the various tracts receive their myeline sheaths at definite periods between the fifth and ninth months of intra-uterine life (Flechsig). The ground bundles and the posterior columns first appear. They may be seen at the sixth week. The ascending cerebellar tracts follow. And the descending cerebellar and the direct and crossed pyramidal tracts are last to appear; they are not developed before the fourth or fifth month. According to Flechsig, the tracts of the spinal cord are medullated as follows:

1. The ground bundles of the posterior columns at about the fifth month.

2. The ground bundles of the anterior columns about the sixth month.

3. The ground bundles of the lateral columns from the fifth to the seventh month (antero-lateral, mixed column fifth to seventh month, and lateral limiting layer, sixth month).

4. The columns of Goll and Burdach (excepting ground bundles) between the sixth and seventh months.

5. The direct cerebellar tract at the seventh month.

6. The antero-lateral cerebellar tracts, ascending and descending, at the eighth month.

7. The direct and crossed pyramidal tracts at the ninth month.

Fissures.—The so-called *Posterior Median Fissure* is in reality a septum of neuroglia. At no time is it a true fissure. It appears to be formed by the approximation of the lateral walls of the neural canal. After the sixth week the approximation begins at the roof and gradually proceeds ventrally to the center of the cord. The ependyma which originally lined the dorsal part of the canal is thus fused into the posterior median septum of neuroglia.

The Postero-lateral Fissure is the groove between the lateral border of the posterior column and the dorsal border of the lateral column. It is the development of the posterior and lateral columns that produces this fissure. The embryonic central fissure is obliterated and the postero-lateral surface of the cord rendered prominent by the formation of the direct cerebellar and crossed pyramidal tracts.

Anterior Median Fissure.—That is a true fissure. It begins to be formed at the sixth week, when the earliest fibers of the antero-lateral ground bundle are developed. It deepens with the growth of the antero-lateral ground bundle and

is completed, in the fourth or fifth month, by the descent of the direct pyramidal tract. Those two tracts cause a bulging in the ventral surface on either side of the median line which increases with the medullation of the pyramidal tracts in the ninth month; and the ridges thus produced, failing to fuse completely, become the walls of the anterior median fissure. The partial fusion which does occur between the two ridges is due to the formation of the *anterior commissure* of the cord.

ADDENDA

Note 1. The fibers of the stria medullaris terminate in the nucleus of the habenula on both sides of the median line; those crossing over run through the dorsal lamina of the pineal stalk and form the commissura habenularum (page 46).

Note 2. Terminations of dendrites. (1) They may form synapses with other neurones; (2) They may end in free beaded points among the cells near a surface, or (3) They may end within special end organs, such as Kraus', Vater's, Meissner's Ruffini's and the Neuro-tendinous and Neuro-muscular spindles (page 67).

Note 3. There are three varieties of neuroglia cells, viz.: (1) The short rayed cells, found in the cortex of cerebellum and cerebrum, the processes of which are strong and richly branched. (2) The long rayed cells, located chiefly in the white substance, whose processes are long and fine and but little branched. And (3) the arborescent cells which lie near the surface in the cortex. Upon reaching the surface the tree-like branches form a limiting membrane of neuroglia (p. 67).

Note 4. The first layer of cerebral cortex contains a rich tangential network associative in function which, according to Cunningham, bears a direct relation to intellectuality. The network is made up of the processes of Cajal's cells, of the pyramids' dendrites, of axones from Martinotti's cells, and of other corticopital fibers which belong to the associative, the commissural and the afferent projection systems (page 72).

Note 5. The dendrites of the polymorphous cells in the fourth layer of cerebral cortex branch very richly in the deeper layers, but fail to reach beyond the pyramids. Those derived from Martinotti's cells ramify toward the white substance, while the axones of the same cells enter into the tangential network of the first cortical layer.

The distinction between fourth and fifth layers is not very clear and, accordingly, Cajal describes them together as the polymorphous layer (page 74).

Note 6. Two varieties of cells are found in the cerebral cortex which differ somewhat from those forming the typical layers. They are the dendraxones of Golgi and the inverted pyramids of Martinotti situated in the deep part of the cortex among the pyramids and polymorphous cell-bodies.

Golgi's cell appears to be associative in function, as both axones and dendrites terminate by multiple division in the immediate vicinity of the cell-body; neither reaches as far as the white substance of the hemisphere or the superficial layer of cortex.

Martinotti's cell is small and somewhat irregular in shape, but often resembles an inverted pyramid. Its dendrites arborize toward

but not into the white substance. It possesses a single axone which runs out to the neuroglial layer, where its T-branches and collaterals enter into the tangential network (page 74).

Note 7. The cerebral commissures are the corpus callosum; anterior, middle and posterior commissures; commissura hippocampi; commissura habenularum; and Gudden's and Meynert's commissures (page 91).

Note 8. The T-branches of the cerebellar granules run parallel with the intralobular fissures and pierce the dendritic planes of Purkinje's cells.

A thin layer of large granules is found next the bodies of Purkinje's cells. The axones of these large granules arborize within the granular layer toward the white substance and their dendrites ramify richly in the superficial layer. The large granules belong to the type of Golgi and are associative in function (page 113).

Note 9. The antero-lateral ascending cerebellar tract (Gowers') in the pons is found scattered in that part of the formatio reticularis which is lateral to the root of the abducent nerve, being continued from the formatio reticularis grisea of the medulla oblongata (page 123).

Note 10. Not all axones of the superior olivary nucleus enter the lateral fillet; a small number, constituting the stalk of the superior olive, run directly to the abducent nucleus, and others join the posterior longitudinal bundle and run to the nuclei of the trochlear and oculomotor nerves. In this manner there is formed the middle link of an auditory-ocular reflex arc (page 126).

Note 11. Fibers from nuclei of the formatio reticularis in the pons and medulla, from Deiter's nucleus and from Flechsig and Bechterew's nucleus probably join the cerebellar fibers in making up the antero-lateral descending cerebellar tract as described in this work (pages 141, 144, 174).

Note 12. The real origin of sensory nerves is found to be in their ganglia external to the brain and spinal cord. From the ganglion cells the dendrites run toward the periphery, constituting the sensory nerves; and the axones, which form the sensory roots, running centrally, plunge into the brain or cord and end in the terminal nuclei of the respective nerves (page 154).

Note 13. The cornu commissural tract is an ascending tract, according to Morris, but Hoche studied two cases of compression myelitis in which the degeneration was descending in this tract (page 178).

Note 14. A small bundle of axones from the corpus albicans descends along the floor of the third ventricle to the tegmentum of the mid-brain, but its destination is unknown (Cunningham).

Note 15. E. A. Schaefer has demonstrated that the fibers of the pyramidal tracts end in Clark's column and about the cells in the posterior horn of gray matter of the spinal cord, hence one or more neurones intervene between the pyramidal fibers and the large cell-bodies in the anterior horns.

INDEX.

A

PAGE.

Abducens nerve.....	129, 140, 155
Accessory nucleus cuneatus.....	143, 147
Accessory nucleus of ninth and tenth cranial nerves.....	152
Accessory sensory roots of ninth and tenth cranial nerves.....	145
Acervulus cerebri.....	46
Acoustic area.....	153
Acustico-cerebellar tract.....	114
Acoustic radiations.....	26, 51, 63, 81, 90, 122
Acoustic striae.....	151
Acoustic trigone.....	151, 153
Acoustic tubercle.....	153
Afferent, or sensory, conduction paths.....	190-197
After-brain, or medulla oblongata.....	7, 128-149
Alae cerebelli.....	105
Ala cinerea.....	152
Alar lamina (or dorso-lateral).....	215
Alveus of hippocampus.....	41, 75
Amygdala.....	25, 26, 37, 40
Anastamotic vein of Trolard.....	99
Angular convolution.....	12
Annectant convolutions.....	14
Anosmia.....	75
Ansa lenticularis.....	56, 77, 80, 84, 89
Ansa peduncularis.....	26, 56, 79, 89
Anterior association center.....	71
Anterior brachium.....	51, 59, 82, 215
Anterior cerebellar notch.....	101
Anterior cerebral arteries.....	95, 96
Anterior choroid tela.....	5, 44, 46, 213
Anterior communicating arteries.....	95

INDEX.

	PAGE.
Anterior choroid artery.....	117
Anterior commissure of cerebrum.....	7, 31, 43, 47, 211
Anterior commissure of cord.....	165, 171, 172, 224
Anterior cornu.....	166, 168
Anterior cornu of lateral ventricle.....	38
Anterior crescentic lobules of cerebellum.....	106
Anterior external arciform fibers.....	130, 131
Anterior great transverse fissure (or choroid).....	213
Anterior horn of gray matter.....	146
Anterior inferior cerebellar artery.....	117
Anterior longitudinal bundle.....	62, 82, 88, 124, 140, 173, 174
Anterior median fissure of cord.....	163, 164, 223
Anterior median fissure of medulla.....	128
Anterior nucleus of optic thalamus.....	78
Anterior olfactory lobule.....	22
Anterior orbital convolutions.....	22
Anterior perforated lamina.....	22
Anterior pillars of fornix.....	43, 44, 48, 79
Anterior quadrigeminal body.....	76, 82
Anterior root of spinal nerves.....	180
Anterior segment of internal capsule.....	27
Anterior spinal artery.....	161, 182, 183
Anterior stalk of thalamus.....	28, 49, 80, 90
Anterior tubercle of optic thalamus.....	50
Anterior white column of cord.....	167
Antero-lateral ascending cerebellar tract ...	115, 131, 140-142, 170, 174
Antero-lateral descending cerebellar tract..
.....	116, 131, 132, 140, 141, 144, 168, 174
Antero-lateral fissure of cord.....	164, 165
Antero-lateral ganglionic arteries.....	96
Antero-lateral ground bundle.....	131, 140, 141, 173, 174
Antero-median ganglionic arteries.....	96
Apertura mediana ventriculi quarti.....	5, 133
Aperturæ laterales ventriculi quarti.....	5, 133
Apex columnæ posterioris.....	169
Apex cornu posterioris.....	169
Apparent central termination of posterior spinal roots.....	181
Aqueduct of Sylvius.....	42, 43, 44, 58, 150, 214

INDEX.

	PAGE.
Arachnoid of brain.....	4
Arachnoid of spinal cord.....	160
Arachnoidea encephali.....	4
Arachnoidea spinalis.....	160
Arbor vitæ.....	114
Arciform fibers.....	116, 132, 135, 144, 147, 178
Arciform nucleus.....	149
Arcuate association fibers of cerebrum.....	91
Area acustica.....	153
Area of Broca.....	22
Area of cerebral softening.....	97
Area of general sensation.....	13
Area parolfactoria (Broca).....	24
Areas of medulla.....	136, 137
Arteria basilaris.....	96
Arteria cerebri anterior.....	95
Arteria cerebri media.....	95
Arteria cerebri posterior.....	96
Arteria choroidea anterior.....	38, 97
Arteria choroidea postero-lateralis.....	97
Arteria choroidea postero-medialis.....	98
Arteria communicans anterior.....	95
Arteria communicans posterior.....	95
Arteria meningea media.....	3
Arteria spinalis anterior.....	161, 182
Arteria spinalis posterior.....	161, 182
Arteriae choroideae.....	97
Arteries of dura mater.....	3
Arteries of pia mater.....	6
Artery of cerebral hemorrhage.....	97
Ascending frontal convolution.....	11
Ascending parietal convolution.....	11, 12
Ascending tracts of spinal cord.....	172
Association fibers of cerebrum.....	85, 91-94
Association fibers of cerebellum.....	117
Auditory center (sensory).....	71
Auditory conduction paths.....	63, 83, 90, 122, 195-197
Auditory cortex.....	26, 93

INDEX.

	PAGE.
Auditory lobes.....	83
Auditory memories.....	71, 93
Auditory nerves.....	137, 144
Auditory radiations (see acoustic radiations).	
Auditory reflex.....	200
Aula of third ventricle.....	34, 42
Axones (or neuraxanes).....	66, 67

B

Basal lamina (ventro-lateral).....	215
Basal or inferior surface of cerebrum.....	17, 24
Basis (es) pedunculi cerebri.....	7, 20, 25, 33, 53, 54
Basket cells of cerebellum.....	112
Biventral lobule..	110
Blood supply of cerebrum and midbrain.....	94-99
Blood supply of cerebellum.....	117
Blood supply of pons.....	127
Blood supply of medulla oblongata.....	158
Blood supply of spinal cord.....	182-184
Body of lateral ventricle.....	35
Borders of corpus callosum.....	29
Boundaries of fourth ventricle.....	150
Brachia pontis.....	103, 115, 119, 121
Brachium conjunctivum.....	64, 102, 115, 120, 127, 150
Brachium posterioris....	122
Brachium quadrigeminum inferioris.....	60
Brachium quadrigeminum superioris.....	59
Brain sand.....	146
Brain vesicles and derivatives.....	207, 208
Bulb of caudate nucleus.....	37
Bulbus olfactorius.....	22, 122
Burdach's column.....	177, 178

C

Calamus scriptorius.....	103, 145
Calcar avis.....	39
Calcarine fissure.....	15
Calloso-marginal fissure.....	14

INDEX.

	PAGE.
Canalis centralis spinalis.....	163
Capsula externa.....	25
Capsula interna.....	25, 26, 28, 31, 35, 36, 53, 54, 55, 211
Caput columnæ posterioris.....	169
Caput cornu posterioris.....	169
Caput nuclei caudati.....	37
Cardio-accelerator center.....	168
Cauda equina.....	161
Cauda nuclei caudati.....	37
Caudate nucleus.....	25, 31, 35, 39, 40, 76
Cavernous sinus.....	3
Cavum septi pellucidi.....	34
Cavum subarachnoidale.....	5
Cavum anterius and posterius.....	160
Cells of anterior cornu of spinal cord.....	167
Cells of Max Schultze.....	23
Cells of posterior cornu.....	169, 170
Cells of Purkinje.....	111
Center of gray crescent of spinal cord.....	167
Center of hearing.....	14, 71
Center of taste, smell, hearing.....	13, 71
Center of vision.....	8, 71
Central canal of spinal cord.....	150, 163
Central fissure (of cerebrum).....	10
Central fissure (embryonic).....	221
Central ligament of spinal cord.....	161
Central lobe.....	14
Central lobule and alæ of cerebellum.....	105
Central nucleus of thalamus.....	79
Central, or ventricular, gray matter of cerebrum.....	70, 84, 85
Centrifugal arteries of cord.....	183
Centrifugal fibers of corpus striatum.....	77
Centrifugal projection fibers of cerebrum.....	85-89
Centripetal arteries of cord.....	183
Centripetal fibers of corpus striatum.....	77
Centripetal projection fibers of cerebrum.....	89-91
Cerebellar hemispheres.....	100
Cerebellar notches.....	101

INDEX.

	PAGE.
Cerebello-olivary tract.....	116, 132, 136, 144, 148
Cerebral hemispheres.....	7, 8
Cerebellum.....	7, 100-118
Cerebro-corticopontal paths.....	186, 187
Cerebro-corticopontal tracts, frontal.....	56, 85
Cerebro-corticopontal tracts, temporal.....	55, 85
Cerebrum.....	7-99
Cervical enlargement of spinal cord.....	163
Cervix volumnæ posterioris.....	169
Cervix cornu posterioris.....	169
Chapter I.....	1-8
Chapter II.....	9-51
Chapter III.....	51-65
Chapter IV.....	66-99
Chapter V.....	100-127
Chapter VI.....	127-149
Chapter VII.....	150-158
Chapter VIII.....	159-161
Chapter IX.....	162-184
Chapter X.....	185-200
Chapter XI.....	201-224
Charcot's artery.....	97
Choroid arteries.....	97, 98
Choroid fissure.....	2, 9, 10, 15, 41, 213
Choroid groove of thalamus.....	49, 212
Choroid plexus of fourth ventricle.....	133, 151
Choroid plexus of lateral ventricle.....	35, 38, 40, 46, 213
Choroid plexus of third ventricle.....	43, 45, 48, 213, 214
Choroid vein.....	38, 98
Cilio-spinal center.....	168
Cingulum.....	92
Circle of Willis.....	94
Circular sinus.....	3
Circulus arteriosus.....	94
Cisterna cerebello-medullaris.....	5
Cisterna chiasmatis.....	5
Cisterna interpeduncularis.....	5
Cisterna pontis.....	5

INDEX.

	PAGE.
Clark's column of cells.....	168
Clastrum.....	25, 76
Clava	133, 143, 147
Clivus and posterior crescentic lobules	106
Cochlear nucleus (i).....	63, 144, 153
Collateral fissure.....	16
Colliculi of corpora quadrigemina.....	54, 59, 82, 83
Colliculus facialis.....	102
Columna (æ) anterior in medulla.....	146
Columna (æ) in spinal cord.....	165, 166
Columna (æ) fornicis.....	32
Columna (æ) lateralis.....	166
Columna (æ) posterior in medulla.....	147
Columna (æ) in spinal cord.....	165, 166, 169
Column of Clark.....	168, 169
Column of Burdach.....	177, 178
Column of Goll.....	179
Column of Gowers.....	175
Column of Loewenthal.....	175
Column of Turck.....	174
Column of Waldeyer.....	168
Comma tract.....	170, 178
Commissura anterior alba.....	165, 167, 171, 172
Commissura anterior cerebri.....	47
Commissura hippocampi.....	7, 32, 91, 211
Commissural fibers of cerebellum.....	116
Commissural fibers of cerebrum.....	85, 91
Commissure of Gudden.....	20, 51
Commissure of Meynert.....	81
Conduction paths.....	185-201
through antero-lateral ascending cerebellar tract.....	192, 193
antero-lateral ground bundle and formatio reticularis... ..	193
cerebro-corticopontal tracts.....	186, 187
cochlear nerve.....	195
columns of Goll and Burdach.....	190, 191
cranial nerves and medial fillet.....	191
direct cerebellar tract.....	191, 192
formatio reticularis.....	189, 190

INDEX.

	PAGE.
intermediate bundle of crusta.....	187, 188
ninth nerve and corda tympani.....	197
olfactory nerves, tract, &c.....	194
optic nerves, tract, &c.....	194, 195
pyramidal tracts.....	185, 186
red nucleus.....	188
vestibular nerve.....	196, 197
Confluens sinuum.....	2
Conjugate deviation.....	127, 189
Connective tissue of brain and cord.....	76
Conus medullaris.....	163
Conus terminalis.....	163
Convolutions or gyri.....	9
Cornu ammonis (hippocampus major).....	73
Cornu commissural tract.....	170, 178
Cornua of lateral ventricle.....	38-42
anterior.....	38, 39
middle.....	39-42
posterior.....	39
Cornu (a) ventriculi lateralis.....	39-42
anterior.....	38, 39
inferius.....	39-42
posterior.....	39
Corono radiata.....	28
Corpus (ora) albicans (antia).....	7, 18, 19, 33, 44, 57, 214
callosum.....	7, 8, 28, 30, 35, 39, 91, 211, 212
dentatum (a).....	113
fimbriatum (a).....	40
fornicis.....	32, 92
geniculatum laterale.....	51, 82
geniculatum mediale.....	51, 60, 82
mamillare (ia).....	19
medullare (cerebelli).....	101, 114
pineale.....	45
quadrigeminum (a).....	7, 31, 51, 54, 57, 59, 60, 166
restiforme (ia).....	102, 116, 132, 144, 150
striatum (a).....	7, 25, 35, 55, 56, 76, 84, 210
Cortex near calcarine fissure.....	74

INDEX.

	PAGE.
Cortex near Sylvian fissure.....	75
Cortical fillet.....	80, 90
Cortical gray matter of cerebellum.....	111-113
Cortical gray matter of cerebrum.....	70-76
Cranial reflexes.....	199
Cranial and spinal reflexes.....	200, 201
Crossed descending tract from red nucleus.....	65, 88, 125, 142, 176
Crossed paralysis.....	127, 149
Crossed pyramidal tract.....	130, 143, 147
Crossing of main sensory path.....	170
Crura ad cerebrum.....	102
Crura ad medullam.....	102
Crura ad pontem.....	103
Crus cerebri.....	7
Crus fornicis.....	32
Crusta (æ).....	7, 53-56, 66, 85-89, 215
Culmen monticuli cerebelli.....	106
Culmen and anterior crescentic lobules.....	106
Cuneate lobe.....	17, 90
Cuneate nucleus.....	132
Cuneate tubercle.....	133, 147
Cuneus.....	17

D

Declive monticuli cerebelli.....	106
Decussatio lemniscorum.....	136
Decussation of pyramids.....	129, 130
Deep nuclear, or rust-colored granular layer of cerebellum.....	112, 113
Deep origin of anterior root of spinal nerves.....	180
Deep origin of posterior root of spinal nerves.....	181, 182
Defecation center.....	168
Defecation reflex.....	198, 199
Degeneration of Nissl.....	68
Degeneration of Waller.....	68
Dendrites.....	66
Dentate fascia.....	40, 41
Derivatives of brain vesicles.....	207, 208
Descending tracts of cord.....	172, 173

INDEX.

	PAGE.
Descending root of trifacial nerve.....	88, 125
Development of brain.....	205-219
Development of cerebrum.....	208-214
Development of olfactory lobe.....	208
Development of interbrain.....	213, 214
Development of midbrain.....	214, 215
Development of cerebellum.....	215, 216
Development of pons varolii.....	216
Development of medulla oblongata.....	217-219
Development of spinal cord.....	220-224
Diaphragm sellæ.....	2
Diencephalon.....	7, 42, 205
Digitationes hippocampi.....	41
Digastric lobules of cerebellum.....	110
Direct cerebellar tract.....	116, 132, 142, 144, 169, 175
Direct pyramidal tract.....	130, 138, 174
Dorsal surface of pons.....	120
Dorsal transverse fibers of pons.....	121
Dorsal deep transverse fibers of pons.....	121
Dorsal deep longitudinal fibers of pons.....	123
Dorsal longitudinal fibers of pons.....	125
Dorsal nucleus of auditory nerve.....	153
Dorsal surface of medulla.....	132
Dorsal zone of embryo.....	205, 214, 215, 217, 219, 220
Dorso-lateral groove of medulla.....	129
Dorso-ventral fibers of medulla.....	136, 137
Dorso-lateral cerebellar tract.....	175
Dorso-ventral fibers of spinal cord.....	172
Dura mater encephali.....	1
Dura mater of spinal cord.....	159, 160
Dura mater spinalis.....	159, 160

E

Edinger's bundle.....	77, 84
Efferent or motor paths.....	185-190
Eighth cranial nerve.....	144
Ejaculation center.....	168
Eleventh nerve.....	131

INDEX.

	PAGE.
Embryology of brain and spinal cord.....	202-224
Eminentia acustici.....	153
Eminentia cinerea.....	152
Eminentia collateralis.....	40
Eminentia medialis.....	152
Eminentia teres.....	145, 151, 152
End-brush.....	67
End-arteries of Cohnheim.....	97
End-organs.....	66
Enlargements of spinal cord.....	163
Ependyma.....	205, 215, 216
Ependyma.....	34
Epiphysis cerebri (see pineal body)	
Epithalamus.....	78
Erection center.....	168
Exceptions to typical cortex.....	74
Exterior surface of cerebrum.....	9
External accessory olivary nucleus.....	148
External arciform fibers.....	116, 132, 135, 144, 147
External capsule.....	25
External geniculate bodies.....	7, 49, 50, 60, 76, 82, 90
External nucleus of optic thalamus (or lateral).....	78
Extremities of optic thalamus.....	49

F

Facial nerve.....	135
Facial paralysis.....	127, 189
Facies anterior (medullæ).....	130
Facies basalis cerebri.....	17
Facies cerebelli inferior.....	107
Facies cerebelli superior.....	103
Facies convexa.....	9
Facies lateralis.....	131
Facies medialis.....	14
Facies posterior (medulla).....	134
Falx cerebelli.....	1
Falx cerebri.....	1
Fascia dentata hippocampi.....	41

INDEX.

	PAGE.
Fasciculus antero lateralis superficialis (ascendens, descendens)	131, 141, 174
Fasciculus cerebello-spinalis.....	144, 175
Fasciculus cerebro-spinalis anterior (ventralis).....	138, 174, 176
Fasciculus cerebro-spinalis lateralis.....	138, 176
Fasciculus cuneatus.....	132, 142, 143, 150, 177, 219
Fasciculus gracilis.....	132, 142, 143, 150, 179, 219
Fasciculus longitudinalis (inferior).....	93
Fasciculus longitudinalis (medialis).....	61, 124, 139, 173
Fasciculus longitudinalis (superior).....	93
Fasciculus longitudinalis pyramidalis pontis.....	55, 86, 122
Fasciculus longitudinalis ventralis.....	140
Fasciculus marginalis.....	177
Fasciculus occipito-frontalis.....	93
Fasciculus perpendicularis.....	94
Fasciculus proprius antero-lateralis.....	131, 141, 173
Fasciculus retroflexus.....	79, 84
Fasciculus Rolandi.....	132, 142, 143, 219
Fasciculus solitarius.....	145, 218
Fasciculus tegmenti centralis.....	64, 124
Fasciculus teres.....	145, 218
Fasciculus thalamo-mamillaris.....	20, 33, 79
Fasciculus triangularis (Helwigi).....	64
Fasciculus uncinatus.....	93
Fasciculus ventralis.....	124, 174
Fastigium (ventriculi quarti).....	114, 151
Fibers of internal capsule.....	85-90
Fibers of tegmentum.....	60-65, 89
Fibrae arcuatae external anterior, posterior.....	131, 135
Fibrae cerebello-olivares.....	136, 148
Fibrae pontis superficiales.....	121
Fifth temporal, infracalcarine or lingual convolution.....	17
Fifth ventricle.....	33, 212
Fillet.....	50, 62, 123, 124
Fillet decussation.....	136, 219
Fillet of gyrus fornicatus.....	92
Filum terminale.....	161, 163
First temporal convolution.....	14

INDEX.

	PAGE.
First temporal sulcus.....	13
Fissura calcarina.....	45
Fissura choroidea.....	9, 16
Fissura collateralis.....	16
Fissura hippocampi.....	15
Fissura lateralis cerebri.....	10
Fissura longitudinalis cerebri.....	9
Fissura mediana anterior, posterior.....	128, 132, 163, 164
Fissura prima.....	22, 24, 30
Fissura transversa cerebri.....	9
Fissuræ interlobulares.....	10, 104
Fissuræ orbitales.....	22
Fissural ventricle (see fifth ventricle).	
Fissural veins.....	183
Fissure of Rolando.....	10
Fissure of Sylvius.....	10
Fissures of convex surface of cerebrum.....	9-11
Fissures of inferior surface of cerebrum.....	51
Fissures of lower surface of cerebellum.....	107, 108
Fissures of medial and tentorial surface.....	14-16
Fissures of spinal cord.....	163-165, 223, 224
Fissures of superior surface of cerebellum.....	104, 105
Fissures or sulci.....	9
Flexures of nural tube.....	206
Flocculi (cerebelli).....	109, 151
Floor of fourth ventricle.....	151
Folium cacuminis and posterior lobules of cerebellum.....	106
Folium vermis.....	107
Foramen caecum of Vicq d'Azyr.....	130
Foramen interventriculare (Monroi).....	34, 43
Foramen of Magendie.....	5, 133, 150
Foramen of Monro.....	32, 34, 42, 43, 44, 203, 211
Foramen of Key and Retzins.....	5, 133, 150
Forceps major.....	39
Formatio reticularis alba.....	138, 139
Formatio reticularis grisea.....	140
Formatio reticularis of medulla.....	134
Fornix.....	7, 31, 32, 35, 92, 210, 211

INDEX.

	PAGE.
Fossa interpeduncularis.....	53
Fossa rhomboidea inferior.....	163
Fourth cranial nerve.....	53, 120
Fourth temporal, or fusiform, convolution.....	17
Fourth ventricle.....	100, 129, 150-158, 217
Fovea inferior.....	152, 153, 218
Fovea superior.....	151, 218
Fraenula (cerebelli).....	105
Frontal lobe.....	11
Fronto parietal operculum.....	10, 12, 22
Fronto-pontal tract.....	27, 86
Function of cerebellum.....	100
Function of fillet.....	62
Functions of neurones.....	68
Functions of stellate, basket and granule cells.....	113
Funiculus anterior and f. lateralis.....	167
Funiculus antero-lateralis.....	173
Funiculus lateralis.....	131, 169
Funiculus posterior.....	169, 177
Fusiform cell bodies of cortex.....	74
functions of.....	74
Fusions of hemispheres with each other.....	211
Fusions of hemispheres with thalamencephalon.....	211

C

Ganglion interpedunculare.....	57
Ganglion spinale.....	181
Ganglionic gray matter of cerebellum.....	113
Ganglionic gray matter of cerebrum and midbrain.....	70-85
Ganglionic system of arteries.....	96, 97
General cavity of cerebrum.....	30
General sensory paths.....	190-193
Genital centers.....	168
Genu and truncus of corpus callosum.....	30, 31, 39
Genu of facial nerve.....	61, 140, 146
Genu of internal capsule.....	27, 86
Germinating cells (His).....	204

INDEX.

	PAGE
Globus pallidus.....	36, 64
Glossopharyngeal nerve.....	137, 156
Goll's column.....	143, 179
Gower's column.....	175
Gracile nucleus.....	132
Grand divisions of brain.....	6, 7
Granulationes arachnoideales.....	3
Gray and white matter of cerebrum and midbrain.....	66-99
Gray commissure of cord.....	168
Gray crescent of cord.....	165-171
Gray matter of brain and cord.....	68
Gray matter of cerebellum.....	103
Gray matter of cerebrum and midbrain.....	70-85
Gray matter of cord.....	165-171
Gray matter of formatio reticularis pontis.....	126
Gray matter of medulla.....	146, 149
Gray matter of pons.....	126, 127
Great longitudinal fissure.....	8, 9
Great transverse fissure.....	5, 31, 40, 49
Gudden's commissure.....	20, 51
Gustatory conduction paths.....	197
Gyri insulæ-Gyri breves-Gyrus longus.....	14
Gyri occipitales laterales.....	13
Gyri operi.....	14
Gyri orbitales.....	22
Gyrus angularis.....	12
Gyrus centralis, anterior, posterior.....	11, 12
Gyrus cinguli.....	16
Gyrus fornicatus.....	16
Gyrus frontalis, superior, medius, inferior.....	11
Gyrus fusiformis.....	17
Gyrus hippocampi.....	16
Gyrus lingualis.....	17
Gyrus rectus.....	22
Gyrus supramarginalis.....	12
Gyrus temporalis superior, medius, inferior.....	14

INDEX.

H

	PAGE.
Habenula.	45
Hatteria.	46
Helwig's triangular tract.	124, 141, 148, 175
Hemispheres of cerebellum.	100
Hemispheres of cerebrum.	7, 8
Hemisphere vesicle.	208
Hemispherium cerebelli.	100
Hemispherium cerebri.	7, 8
Hind-brain	7, 100-127
Hippocampal convolution.	16
Hippocampal fissure.	15
Hippocampus.	40
Hippocampus major.	40, 75
Hippocampus minor.	39
Histologic layers of embryo.	205, 218, 219, 221, 222
Histologic layers of spinal cord.	221, 222
H-shaped column of gray matter in medulla.	146, 166
Hylus nuclei dentati	113
Hypophysis cerebri.	19
Hypoglossal nerve	129, 131, 137, 156
Hypoglossal trigone.	145, 152
Hypothalamic body.	50
Hypothalamic nuclei.	48
Hypothalamic tegmental region.	50, 53
Hypothalamus.	50

I

Indirect motor paths.	55, 56, 86
Inferior cerebellar veins.	118
Inferior cerebral veins.	98, 99
Inferior fovea.	152, 153, 218
Inferior frontal convolution.	11
Inferior frontal sulcus.	11
Inferior gray commissure of cerebrum.	19
Inferior lamina of internal capsule.	26, 40
Inferior lamina of medullary stem.	101, 114
Inferior longitudinal fasciculus.	93

INDEX.

	PAGE.
Inferior longitudinal sinus.....	2, 47
Inferior medullary vellum.....	101, 133, 150
Inferior occipital convolution or gyrus.....	13
Inferior occipital sulcus.....	13
Inferior olivary nucleus.....	148
Inferior olive.....	64
Inferior parietal convolution.....	12
*Inferior peduncles of cerebellum (restiform body)...	102, 116, 150, 216
Inferior rhomboid fossa.....	163
Inferior sensory root of trifacial or fifth nerve.....	125, 143, 145
Inferior surface of cerebellum.....	107, 111
Inferior surface of cerebrum.....	24-51
Inferior surface of pons.....	119
Infundibulum.....	7, 18, 19, 214
Inner or ependymal layer of medulla.....	218
Insula.....	14
Interbrain.....	7, 42-51, 66
Interior of medulla.....	133, 149
Interior of midbrain.....	54, 65
Intermediate bundle of crusta.....	55, 77, 85, 86, 187
Intermedio-lateral column of cells.....	168
Internal accessory olivary nucleus.....	148
Internal arciform fibers.....	135, 116
Internal capsule.....	26-28, 31, 35, 36, 40, 53, 54, 55, 211
Internal geniculate bodies.....	7, 49, 50, 51, 54, 57, 60, 76, 82, 215
Internal nucleus of optic thalamus (or medial).....	78
Internal orbital convolution.....	22
Interolivary fillet.....	62, 139, 147, 178
Interpeduncular ganglion.....	57, 79
Interpeduncular structures.....	18, 48
Intraparietal fissure.....	12
Intumescencia cervicalis.....	163
Intumescencia lumbalis.....	163
Island of Reil.....	10-14, 22
Isthmus.....	16, 52
Isthmus gyri fornicati.....	16
Isthmus rhombencephali.....	52
Iter a tertia ad quartum ventriculū.....	58

INDEX.

J		PAGE.
Jugular vein—internal.....		3
L		
Lamina cinerea.....	7, 18, 31, 44, 47, 84,	214
Lamina perforata anterior.....		24
Lamina terminalis.....	19, 31, 43,	48
Laminae medullares (cerebelli).....		114
Large pyramids of cerebral cortex.....		73
function of.....		73
Lateral area of medulla.....		140
Lateral cerebellar veins.....		120
Lateral extremity of corpus callosum.....		30
Lateral fillet (or lower).....	60, 63, 83, 120, 122,	139
Lateral horn (of cord).....		166
Lateral nucleus of medulla.....		140
Lateral recesses of fourth ventricle.....	114, 133,	151
Lateral sinus.....		2
Lateral surface of medulla.....	131,	132
Lateral sulcus of midbrain.....		54
Lateral tract of medulla.....		131
Lateral ventricles.....	31, 33, 34-42	
Lateral white column of cord.....		167, 169
Lemniscus.....	50, 123,	124
Lemniscus interolivaris (L. medialis, L. superior).....	62,	139
Lemniscus lateralis.....	60, 62, 63, 120, 123,	139
Lemniscus medialis.....	56, 62, 63, 120, 123,	139
Lemniscus superior.....	62, 123,	139
Lenticular nucleus.....	25, 26, 36,	37
Lesions of acoustic radiations.....		9
Lesions of anterior corner.....		167
Lesions of anterior quadrigeminal bodies.....		83
Lesions of association centers.....		72
Lesions of corpus striatum.....		77
Lesions of cortical fillet.....		90
Lesions of lower motor neurones.....		180
Lesions of medulla.....		149
Lesions of motor and sensory cortex.....		72
Lesions of motor tracts (upper).....		89

INDEX.

	PAGE.
Lesions of olfactory tract, or cortex.....	75
Lesions of pons.....	127
Lesions of posterior column of cord.....	179
Lesions of posterior quadrigeminal bodies.....	83
Lesions of posterior roots of spinal nerves.....	182
Lesions of pyramidal tract.....	177
Lesions of sensory paths.....	193
Lesions of special sense paths.....	193
Lesions of trochlear and oculomotor nuclei.....	84
Ligamentum denticulatum.....	160
Ligula.....	133
Limbic lobe.....	16, 17
Lingula and trænula of cerebellum.....	105
Lissauer's tract.....	177
Lobes of cerebellum, inferior surface.....	108-111
Lobes of cerebellum, superior surface.....	105-107
Lobes and convolutions of cerebrum, convex surface.....	11-14
Lobes and convolutions of cerebrum, inferior surface.....	21, 24
Lobes and convolutions of cerebrum, medial and tentorial sur- face.....	16, 17
Lobulus biventer.....	110
Lobulus paracentralis.....	11, 17
Lobulus parietalis superior, inferior.....	12
Lobulus semilunaris inferior.....	107
Lobulus semilunaris superior.....	110
Lobus cacuminis.....	106
Lobus centralis (cerebelli).....	105
Lobus clivi.....	106
Lobus culminis.....	106
Lobus frontalis.....	11
Lobus lingulæ.....	105
Lobus noduli.....	109
Lobus occipitalis.....	13
Lobus olfactorius.....	23
Lobus orbitalis.....	21
Lobus parietalis.....	12
Lobus pyramidalis.....	110
Lobus quadrangularis.....	106

INDEX.

	PAGE.
Lobus temporalis.....	13
Lobus tuberis.....	110
Lobus uvulæ	109
Location of Rolandic fissure.....	10
Location of Sylvian fissure.....	10
Locomotor ataxia	179, 182
Locus coeruleus.....	151, 152
Loewenthal's column.	174
Long association fibers of cerebrum.....	92
Long sensory tract (Ciagliniski).....	171
Longitudinal fibers of cord.....	172, 179, 222
Longitudinal fibers of medulla.....	137-146
Longitudinal fibers of pons.	122, 125
Longitudinal sinus, inferior.....	2
Longitudinal sinus, superior.....	2
Longitudinal striae, lateral.....	30
Longitudinal striae, medial	29
Longitudinal tract of cord.....	172-179, 222, 223
Lower, or closed, medulla.	142
Lumbar enlargement of cord.....	163
Lymph spaces of cerebellum.....	118
Lymph spaces of cerebrum.....	99
Lymph spaces of spinal cord.....	184
Lyre	32, 91

M

Mantle (or middle) layer of embryo.....	205
Mantle layer of medulla.....	218, 219
Mantle layer of spinal cord.....	221, 222
Marginal convolution.....	17
Marginal tract of Lissauer	177
Massa intermedia.....	43, 48, 84
Medial cerebral veins	98
Medial fillet.	56, 63, 83, 139
Median sulcus of midbrain	53, 54
Medulla oblongata	7, 128-149
Medulla spinalis.....	168
Medullary stem of cerebellum	101-103, 114- 116

INDEX.

	PAGE.
Medulli-spinal veins	160, 161, 183
Membranes of brain	1-6
Membranes of spinal cord.....	159-161
Meninges encephali	1
Meninges of brain.....	1-6
Meninges of cord.....	159-161
Meningo-rachidian.....	4, 159, 184
Mesencephalon.....	7, 52, 205, 214, 215
Metathalamus	49
Metencephalon.....	7, 129, 205, 217-219
Methods of locating tracts of cord.....	172
Meynert's commissure.....	81, 84
Midbrain	7, 52-99
Middle association center.....	72
Middle cerebral artery.....	95
Middle cerebral vein.....	99
Middle commissure of cerebrum.....	7, 48, 84
Middle frontal convolution.....	11
Middle horn of lateral ventricle (descending)	39
Middle longitudinal fibers of pons	123-125
Middle occipital convolution or gyrus.....	13
Middle occipital sulcus	
Middle peduncle of cerebellum.....	103, 115, 216
Middle transverse fibers of pons.....	121
Micturition center.....	168
Mitral neurones.....	74
Mixed tracts of cords, ascending and descending.....	172, 173
Motor areas of cerebral cortex.....	12, 71, 72
Motor centers of medial surface of cerebrum.....	17
Motor fibers of internal capsule.....	27, 85-89
Motor fibers to arm.....	55, 87
Motor fibers to head.....	55, 56, 87
Motor fibers to leg and foot.....	56, 88
Motor fibers to trunk.....	56, 88
Motor head area.....	70
Motor lower extremity area.....	70
Motor memories.....	71
Motor nuclei of cranial nerves.....	55, 56, 87, 156, 157

INDEX.

	PAGE.
Motor oculi or third cranial nerve.....	20, 53, 58, 59, 140
Motor or efferent paths.....	185-190
Motor projection fibers of cerebrum.....	85-89
Motor projection fibers to cranial nerves.....	87
Motor speech center.....	12, 70, 93
Motor trunk area.....	70
Motor upper extremity area.....	70
Motor writing center.....	70
Myelencephalon.....	7, 205
Myelospongium.....	205

N

Naming center.....	71
Nerve supply of membranes of cord.....	161
Nerves of dura mater.....	4
Nerves of Lancisi.....	17, 29, 30
Nerves of pia.....	6
Nervi olfactorii.....	23, 154
Nervus opticus.....	21, 154
Nervus abducens.....	155
Nervus accessorius.....	156
Nervus acusticus.....	144, 155
Nervus cochlearis.....	120
Nervus facialis.....	155
Nervus glassopharyngeus.....	156
Nervus hypoglossus.....	137, 156
Nervus intermedius.....	155
Nervus oculomotorius.....	20, 154
Nervus trigeminus.....	120, 155
Nervus trochlearis.....	20, 59, 154
Nervus vagus.....	156
Neural crest.....	202-204
Neural tube.....	204-224
Neuraxones (or axones).....	67
Neuroblasts.....	204
Neuroglia.....	67, 205
Neuroglial layer of medulla.....	219
Neuron.....	68

INDEX

	PAGE.
Neurone.....	66
Neurone center (cell body).....	65
Neurons of cajal.....	72
Ninth nerve.....	131
Nodulus and flocculi.....	109
Nodulus vermis.....	109
Note on the neurone.....	68
Nuclei of cranial nerves (ventral series).....	156
Nuclei of cranial nerves (dorsal series).....	156
Nuclei of optic thalamus.....	78
Nuclei of pons.....	55, 56, 122, 126, 216
Nuclei of Stilling.....	113
Nuclei of Stilling (in cord).....	169
Nucleus accessorius dorsalis.....	148
Nucleus accessorius medialis.....	148
Nucleus ambiguus.....	140, 146
Nucleus amygdalae.....	37
Nucleus arcuatus.....	149
Nucleus candatus (see candate nucleus).....	37
Nucleus cuneatus.....	62, 136, 143, 147, 219
Nucleus dentatus.....	113
Nucleus dorsalis.....	168
Nucleus emboliformis.....	113
Nucleus fastigii.....	114
Nucleus globosus.....	113
Nucleus gracilis.....	62, 136, 143, 147, 219
Nucleus hypothalamicus.....	50, 57, 81
Nucleus lentiformis.....	36
Nucleus magno-cellularis.....	127
Nucleus of abducent, or sixth cranial nerve.....	145, 152, 216, 219
Nucleus of external arciform fibers.....	149
Nucleus of facial, or seventh cranial nerve.....	216
Nucleus of fifth nerve (inferior).....	147
Nucleus of formatio reticularis.....	126
Nucleus of glossopharyngeal, or ninth nerve.....	153
Nucleus of habenula.....	78
Nucleus of lateral fillet.....	63, 122
Nucleus of Luys (Luysi).....	50, 57, 76, 81, 84

INDEX.

	PAGE.
Nucleus of ninth, tenth and eleventh cranial nerves.....	146, 147, 219
Nucleus of pneumogastric, or tenth nerve.....	153
Nucleus of pons (see nucleus pontis).....	55, 56
Nucleus of pulvinar.....	78
Nucleus of Rolando.....	143, 219
Nucleus of superior olive.....	63, 122, 126, 216
Nucleus of third and fourth nerves.....	58, 59, 84, 215
Nucleus of trapezium.....	121, 122, 126
Nucleus of trapezoid body.....	63
Nucleus of trifacial, or fifth nerve (motor).....	152, 216
Nucleus of twelfth, or hypoglossal, cranial nerve.....	146, 219
Nucleus olivaris (medullae).....	148
Nucleus olivaris superior.....	126
Nucleus pontis.....	55, 56, 122, 126, 216
Nucleus ruber.....	50, 57, 81

O

Obex.....	133
Occipital lobe.....	13
Occipital sinus.....	2
Oculomotor groove.....	53
Oculomotor nerve.....	154
Oculomotor nucleus.....	58
Olfactory bulb.....	22, 74
Olfactory conduction paths.....	75, 194
Olfactory lobes.....	7, 22, 208
Olfactory nerve.....	154
Olfactory tract.....	22, 23
Olfactory trigone.....	22, 24
Olivary body (of medulla).....	131, 219
Olivary bundle of spinal cord.....	148
Olivary fasciculus.....	64, 77, 124, 141
Olivary nucleus external accessory.....	140
Olivary nucleus internal accessory.....	140
Olivary nucleus of medulla.....	140, 148
Olivary peduncle.....	136
Operculum.....	10, 12
orbital.....	10

INDEX.

	PAGE.
frontal.....	10
fronto-parietal.....	10, 12
Optic chiasm or commissure.....	18, 20
Optic conduction path.....	194, 195
Optic lobes.....	82
Optic nerve.....	154
Optic radiations.....	80
Optic recess.....	48
Optic thalamus (i).....	7, 26, 31, 35, 37, 44, 48, 76, 78-81, 214
Optic tracts and commissure.....	7, 18, 44
Optic vesicle.....	213
Orbital lobe.....	21
Orders of neurones.....	68
Origin of cranial and spinal ganglia.....	202, 203
Origin of cranial nerves.....	153-158
Origin of medulla.....	129
Origin of meninges.....	202
Origin of neurones.....	204
Origin of optic nerves, chiasm and tracts.....	213
Origin of spinal cord.....	162

P

Pachionian bodies.....	3
Paracentral lobule.....	11, 17
Parietal lobe.....	12
Parieto-occipital fissure.....	11, 15
Pars anterior commissurae anterioris.....	47
Pars anterior lobuli quadrangularis.....	106
Pars basilaris pontis.....	119, 121
Pars dorsalis-pontis.....	119, 121, 122
Pars frontalis capsulae internae.....	27
Pars intermedia.....	155
Pars occipitalis capsulae internae.....	27
Pars posterior commissurae anterioris.....	47
Pars posterior lobuli quadrangularis.....	106
Parturition center.....	168
Pedes pedunculi (see crustae).....	7
Peduncle of flosculus.....	109

INDEX.

	PAGE.
Pedunculus cerebri (see midbrain).....	7
Pedunculus flocculi.....	109
Perikaryon (or neurone center).....	66, 167, 168
Permanent fissures of cerebrum.....	209, 210
Perpendicular fasciculus.....	94
Pes hippocampi.....	40, 41
Petrosal sinuses, inferior and superior.....	3, 99, 118
Pia mater encephali.....	5
Pia mater of brain.....	5
Pia mater of spinal cord.....	160
Pia mater spinalis.....	5, 160
Pillars of fornix.....	20, 32, 210, 211
Pineal body.....	7, 31, 43, 45, 214
Pineal stalk.....	45
Pineal striae.....	46
Pituitary body.....	18, 19
Plexus choroideus ventriculi quarti.....	38, 133, 153
Plexus choroideus ventriculi tertii.....	45, 47
Plexus venosi vertebrales interni.....	159, 184
Pneumogastric or vagus nerve.....	130, 131, 156, 157
Pneumogastric trigone.....	153
Points of difference between dura of brain and cord.....	4
Polymonphous layer of cortex.....	73
function of.....	73
Pons varolii.....	7, 118-127
Ponticulus of Arnold.....	130
Postcentral convolution or gyrus.....	11
Postcentral fissure (of cerebellum).....	104
Postcentral fissure or sulcus.....	12
Postclival fissure.....	104
Postnodular fissure.....	107
Postparietal convolution.....	12
Postpyramidal fissure.....	108
Posterior association center.....	71
Posterior area of medulla.....	142-146
Posterior brachium.....	51, 83, 90, 215
Posterior cerebellar notch.....	101
Posterior cerebral arteries.....	95, 96

INDEX.

	PAGE
Posterior choroid tela (or inferior)	6, 133
Posterior communicating arteries	95
Posterior commissure of cerebrum	7, 31, 42, 43, 44, 53, 214
Posterior commissure of cord	165, 169
Posterior cornu in médulla	147
Posterior cornu of cord	166, 169, 171
Posterior cornu (or horn) of lateral ventricle	39
Posterior crescentic lobules of cerebellum	106
Posterior fenestrated septum	160
Posterior inferior cerebellar artery	117
Posterior intermediate furrow	165
Posterior longitudinal bundle	50, 61, 124, 139, 140, 173, 174
Posterior median fissure of medulla	128
Posterior median fissure of cord	164, 223
Posterior nucleus of optic thalami	78
Posterior olfactory lobule	22, 24
Posterior orbital convolution	22
Posterior perforated lamina (or space)	31, 44, 53
Posterior quadrigeminal body	63, 76 83
Posterior root of spinal nerves	180, 182
Posterior sclerosis	179
Posterior segment of internal capsule	27
Posterior spinal artery	161, 182, 183
Posterior white column of cord	169
Postero-inferior lobules of cerebellum	110
Postero-lateral choroid artery	38, 97
Postero-lateral fissure of cord	164, 223
Postero-lateral ganglionic arteries	97
Postero-lateral tract of cord	177, 178
Postero-medial choroid artery	98
Postero-medial tract of cord	179
Postero-medial ganglionic arteries	97
Postero-superior lobules of cerebellum	106
Precentral convolution	11
Precentral fissure, or sulcus, of cerebellum	104
Precentral fissure, or sulcus, of cerebrum	11
Preclival fissure	104
Prepyramidal fissure	108

INDEX.

	PAGE.
Primary brain vesicles.....	204
Primary sulci of cerebrum.....	209
Processus reticularis.....	166
Projection or peduncular fibers of cerebellum.....	114-116
Projection or peduncular fibers of cerebrum.....	85-91
Prosencephalon.....	7, 9, 205, 207, 208-213
Pulvinar of optic thalamus.....	40, 41, 49, 90
Pupillary reflex.....	200
Pupillo-dilator tract.....	124, 140
Putamen.....	36
Pyramid and digastric lobules.....	110
Pyramid of medulla....	130, 138
Pyramidal conduction paths.....	185, 186
Pyramidal tract.....	27, 55, 86, 89, 122
Pyramis medullae oblongatae.....	138
Pyramis vermis.....	110

Q

Quadrate lobe.....	17
Quadrigeminal bodies.....	57, 82, 83
Quadrigeminal lamina.....	60
Qualities peculiar to axones.....	68
Qualities peculiar to dendrites.....	68

R

Radiatio occipito-thalamica (Gratioleti).....	28, 80
Radiatio temporo-thalamica.....	28, 81
Radix anterior (nervi spinalis).....	180
Radix cerebralis nervi accessorii.....	137
Radix medialis lateralis (nervi optici).....	21
Radix nervi glossopharyngei.....	137
Radix nervi vagi.....	137
Radix nervi vestibularis.....	137
Radix posterior (nervi spinalis).....	180
Radix spinalis nervi trigemini.....	145
Raphe (of medulla).....	135
Real central terminations of posterior spinal roots.....	181
Recessus lateralis ventriculi quarti.....	114

INDEX.

	PAGE.
Red nucleus.....	50, 57, 64, 81
Reflex centers of cord.....	168
Reflex paths.....	198, 201
Region of speech.....	12, 70
Respiratory reflex.....	200
Restiform body.....	132, 133, 143, 144, 219
Reticula of cord.....	166
Rhinencephalon.....	17, 93
Rolandic nucleus.....	132
Roof epithelium of fourth ventricle.....	133, 151
Roof epithelium of third ventricle.....	31, 43, 44
Roots of auditory nerve.....	144
Roots of olfactory tract.....	23
Roots of optic tract.....	21, 51
Roots of spinal nerves.....	179, 182
Root veins.....	183
Rostrum of corpus callosum.....	30, 39

S

Second temporal convolution or gyrus.....	14
Second temporal fissure or sulcus.....	13
Secondary brain vesicles.....	205
Secretory centers.....	168
Sensory areas of cerebrum.....	70
Sensory conduction paths.....	190-197
Sensory decussation.....	62, 136, 147, 219
Sensory fibers of internal capsule.....	27, 89-91
Septomarginal tract.....	118, 170
Septum lucidum.....	31, 33, 35, 39 211
Septum pellucidum.....	33
Septum subarachnoideale.....	160
Seventh cranial nerve (facial).....	124
Short association fibers of cerebrum.....	91
Sinus basilaris.....	3
Sinus cavernosus.....	3
Sinus circularis.....	3
Sinus occipitalis.....	2
Sinus petrosus superior et inferior.....	3

INDEX.

	PAGE.
Sinus rectus.....	2
Sinus sagittalis superior and inferior.....	2, 98, 99
Sinuses of dura mater.....	2, 3
Sixth cranial nerve (abducent).....	61, 124
Sixth ventricle	162
Small pyramids of cerebral vortex.....	72
functions of	73
Solitary bundle	145, 218
Somæsthetic area.....	13, 26, 28, 70
Special-sense conduction paths.....	194-197
Spinal accessory nerve.....	156
Spinal and cranial reflexes.....	199, 200
Spinal bulb.....	128
Spinal cord.....	162-184, 220-224
Spinal cord in fœtus	162
Spinal ganglion	181, 203
Spinal reflexes.....	198, 199
Spinal root of trifacial (or fifth) nerve.....	143
Splenium of corpus callosum.....	29, 31
Spongioblasts.....	205
Stellate cells of cerebellum.....	111
Strabismus	127
Straight sinus.....	2
Stratum cinereum.....	82
Stratum dorsale hypothalami.....	50, 64
Stratum glomerulosum.....	74
Stratum lemnisci.....	82
Stratum opticum.....	82
Stratum zonale.....	49, 82
Stria medullaris thalami.....	46
Stria terminalis.....	37
Striæ longitudinales laterales et mediales.....	29, 30
Striæ medullares.....	151
Striæ olfactorii lateralis, medialis, intermedia.....	23
Subarachnoid spaces.....	5, 160, 161
Subarachnoid tissue.....	4
Substance of spinal cord.....	160-182
Substantia alba (of cord).....	171-182

INDEX.

	PAGE.
Substantia cinerea gelatinosa Rolandi.....	166
Substantia gelatinosa Rolandi.....	166
Substantia grisea.....	165
Substantia intermedia grisea.....	166, 168
Substantia nigra.....	7, 50, 54, 56, 57, 66, 76, 83
Substantia perforata posterior.....	53, 57
Substantia spongiosa.....	166
Sulcus (i) centralis.....	10
Sulcus centralis insulae.....	14
Sulcus cinguli.....	15
Sulcus circularis (Reili).....	14, 22
Sulcus frontalis superior et inferior.....	11
Sulcus horizontalis cerebelli.....	101
Sulcus interparietalis.....	12
Sulcus intermedius posterior (of cord).....	165
Sulcus (i) lateralis (mesencephali).....	53
Sulcus lateralis anterior (medullae).....	129
Sulcus lateralis posterior (medullae).....	130
Sulcus lateralis posterior (of cord).....	165
Sulcus limitans insulae.....	14, 22
Sulcus longitudinalis fossae rhomboideae.....	151
Sulcus mediana anterior (of cord).....	163
Sulcus mediana posterior (of cord).....	164
Sulcus nervi oculomotorii.....	53
Sulcus occipitalis (es) lateralis (es).....	13
Sulcus occipitalis (es) transversus.....	13
Sulcus occipito-parietalis.....	11, 15
Sulcus olfactorius.....	22
Sulcus postcentralis.....	12
Sulcus postcentralis cerebelli.....	104
Sulcus præcentralis.....	11
Sulcus præcentralis cerebelli.....	104
Sulcus temporalis superior et medius.....	11
Superficial longitudinal fibers of pons.....	125
Superficial, molecular, or gray cellular layer.....	111
Superficial, molecular, or neuroglial layer of cortex.....	72
Superficial origin of anterior root of spinal nerves.....	180
Superficial origin of posterior root of spinal nerves.....	181

INDEX.

	PAGE.
Superior cerebellar artery.....	117
Superior cerebellar veins.....	118
Superior cerebral veins.....	98
Superior fillet.....	63, 139
Superior fovea.....	151, 152, 218
Superior frontal convolution or gyrus.....	11
Superior frontal fissure or sulcus.....	11
Superior lamina of internal capsule.....	26, 53, 54, 211
Superior lamina of medullary stem.....	102, 114
Superior longitudinal fasciculus.....	93
Superior medullary velum.....	102, 115, 120
Superior occipital convolution.....	13
Superior occipital fissure or sulcus.....	13
Superior olivary nucleus.....	126, 216
Superior parietal convolution.....	11
Superior peduncle of cerebellum.....	
.....	50, 60, 64, 88, 102, 114, 115, 116, 120, 125, 150, 216
Superior surface of cerebellum.....	103-106
Superior surface of pons.....	119
Supramarginal convolution.....	12
Surfaces of corpus callosum.....	29
Surfaces of medulla.....	129-133
Surfaces of midbrain.....	52-54
Surfaces of optic thalamus.....	49
Surfaces of pons.....	119-120
Surfaces of spinal cord.....	163
Surcingle.....	37, 40
Sustentacular tissue of brain and cord.....	67
Sylvian fissure.....	10, 209, 210

T

Table I.....	6
Table II.....	154, 156
Table III.....	207-208
Taeniae tectae.....	30
Taenia semicircularis.....	31, 35, 37, 40, 211
Tail of candate nucleus.....	37
Tangential association of fibers of cerebrum.....	91

INDEX.

	PAGE.
Tapetum	94
Tegmentum.....	7, 31, 40, 50, 54, 57, 65, 66, 215
Tela choroidea ventriculi quarti.....	6, 133
Tela choroidea ventriculi tertii.....	5, 44, 46, 213
Telencephalon.....	205
Temporal lobe.....	13
Temporo-pontal tract.....	26, 27, 86
Tenth nerve.....	131
Tent of fourth ventricle.....	114, 151
Tentorium cerebelli.....	2, 9
Terminal nuclei of sensory cranial nerves.....	62, 153, 157
Thalamencephalon.....	7, 205, 213, 214
Thalamus	37, 48, 78-80
Three systems of Flechsig.....	89
Third cranial nerve.....	53, 61, 124, 140
Third temporal convolution.....	14
Third ventricle... ..	31, 33, 42
Third ventricle and interbrain.....	42-51
Time of medullation of tracts of cord.....	222
Tonsila cerebelli.....	109
Tonsil or amygdala of cerebellum.....	109
Torcular Herophili.....	2
Tracing of impulses.....	185-201
Tract from lateral nucleus to cerebellum.....	116, 132, 144
Tracts of antero-lateral column.....	172
Tracts of posterior column of cord.....	177, 179
Tractus cerebro-corticopontalis, frontalis (see fronto-pontal).....	27
Tractus cerebo-corticopontalis, temporales (see temporo-pontal).	27, 85, 86
Tractus olfactorius.....	23
Tractus opticus.....	21
Tractus triangularis (Helwigi).....	141
Tractus spinalis nervi trigemini.....	125
Transverse fibers of cord.....	171, 172
Transverse fibers of medulla	135
Transverse fibers of pons.....	121, 122
Transverse or basilar sinus.....	3
Transverse or commissural fibers of cerebrum.....	85, 91

INDEX.

	PAGE.
Trapezium.....	121, 122
Triangular tract of Helwig.....	124, 141, 148, 175
Trifacial nerve.....	155
Trigone and area of Broca (olfactory).....	24
Trigone of habenula.....	50
Trigonum acustici.....	152, 153
Trigonum collaterale.....	40
Trigonum habenulae.....	50, 79
Trigonum nervi hypoglossi.....	152
Trigonum olfactorium.....	24
Trigonum vagi.....	152, 153
Trigonum ventriculi.....	39, 40
Tri-radiate or H shaped fissure.....	22
Trochlear nerve.....	154
Trochlear nucleus (pathetic).....	58
Tuber annulare.....	119
Tuber cinereum and infundibulum.....	7, 18, 31, 44, 84, 214
Tuberculum anterius thalami.....	50
Tuberculum cuneatum.....	147
Tuber valvula and postero-inferior lobules.....	110
Tuber vermis.....	110
Turcks' column.....	174
Types of neurones.....	68
Typical cortex of cerebrum.....	72

U

Uncinate convolution.....	17
Uncinate fasciculus.....	93
Uncrossed (or direct) pyramidal tract.....	138, 174
Uncrossed pyramidal fibers.....	138
Upper, or ventricular, medulla.....	144
Uvula and tonsils.....	109
Uvula vermis.....	109

V

Vagus, or pneumogastric nerve.....	130, 137, 153, 156, 157
Vallecula cerebelli.....	101, 107
Vallecula Sylvii.....	10, 21

INDEX.

	PAGE.
Valley of cerebellum.....	101
Valve of Vienssens.....	58, 64, 102, 120, 125, 150
Varieties of reflex paths.....	198
Vasomotor centers.....	168
Vein of Galen.....	98
Veins, internal jugular.....	3
Veins, medulli-spinal.....	160, 161, 183
Veins, meningo-rachidian.....	4
Veins of cerebellum.....	118
Veins of cerebrum.....	98
Veins of pia.....	6
Veins of spinal cord.....	183, 184
Veins of striate body.....	98
Velum interpositum.....	5, 9, 31, 38, 43, 46, 212, 213
Velum medullare anterius.....	64, 102, 115, 120, 127, 130
Velum medullare posterius.....	101, 114
Vena cerebri interna.....	38
Vena cerebri magna (Galen).....	2, 38, 98, 99
Vena cerebri media.....	99
Vena choroidea.....	98
Vena corpora striati.....	98
Venae cerebri inferiores.....	98
Venae cerebri internae.....	98
Venae cerebri mediales.....	98
Venae cerebri superiores.....	98
Venae spinale externae.....	160, 161, 183
Ventral deep-longitudinal fibers of pons.....	122
Ventral deep-transverse fibers of pons.....	121
Ventral longitudinal fibers of pons.....	122
Ventral surface of medulla.....	130
Ventral surface of pons.....	119
Ventral transverse fibers of pons.....	121
Ventral zone of embryo.....	205, 214, 215, 217, 219, 220
Ventricle of corpus callosum.....	30
Ventriculus lateralis.....	34
Ventriculus lateralis (pars centralis).....	35
Ventriculus quartus.....	100, 150
Ventriculus tertius.....	42

INDEX.


	PAGE.
Ventro-lateral groove of medulla.....	129
Vermis cerebelli.....	100, 101
Vermis inferior cerebelli.....	101
Vermis superior cerebelli.....	101
Vestibular nuclei of auditory nerve.....	144, 153
Vestibulo-olivary tract.....	148
Villi of arachnoid.....	4
Vinculum linguae cerebelli.....	105
Visceral centers.....	168
Visual center.....	71
Visual conduction paths.....	90
Visual memory center.....	13, 71, 93

W

Waldeyer's column of cells.....	168, 169
Wallerian degeneration.....	68
White matter of brain and cord.....	67
White matter of cerebellum.....	114-117
White matter of cerebrum and midbrain.....	85-94
White matter of medulla.....	134-146
White matter of pons.....	120-125
White matter of spinal cord.....	171-182
White matter of thalamus.....	79
White or anterior commissure of cord.....	171
Worm of cerebellum.....	100, 101

Z

Zona incerta.....	50
-------------------	----



6353349



3 1378 00635 3349

UNIVERSITY OF CALIFORNIA
MEDICAL CENTER LIBRARY

**THIS BOOK IS DUE ON THE LAST DATE
STAMPED BELOW**

Books not returned on time are subject to a fine of 50c per volume after the third day overdue, increasing to \$1.00 per volume after the sixth day. Books not in demand may be renewed if application is made before expiration of loan period.

~~DEC 15 1953~~

QM451	Santee, H.E.	52405
S23	Anatomy of the brain and	
1903	spinal cord.. 3d ed. rev.	

52405

40(8302)

