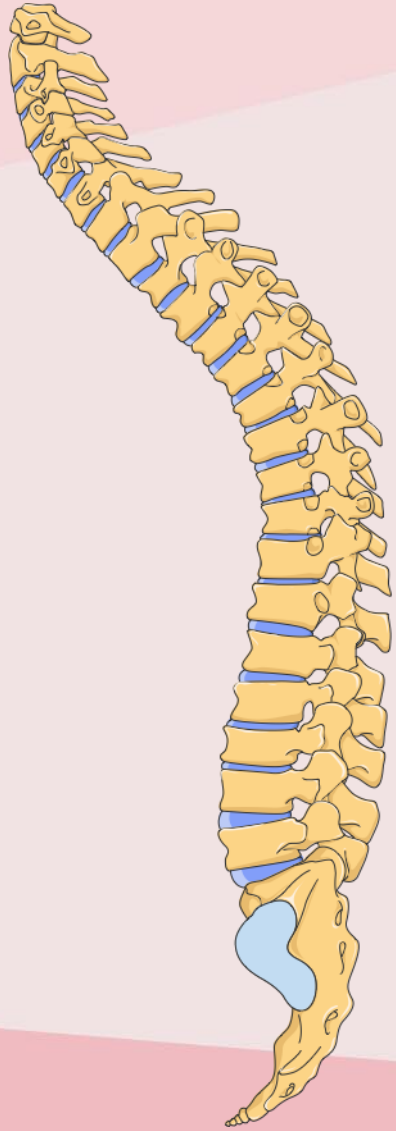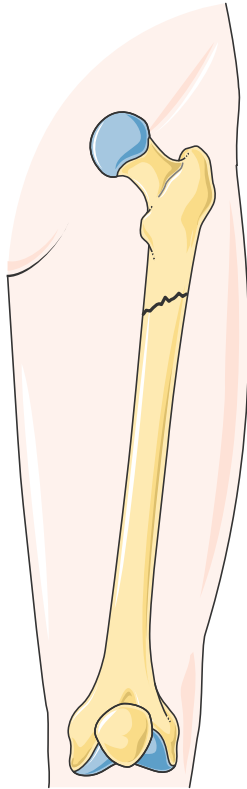
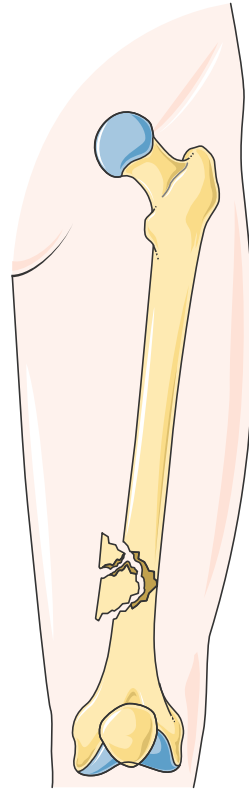


# Bone fractures

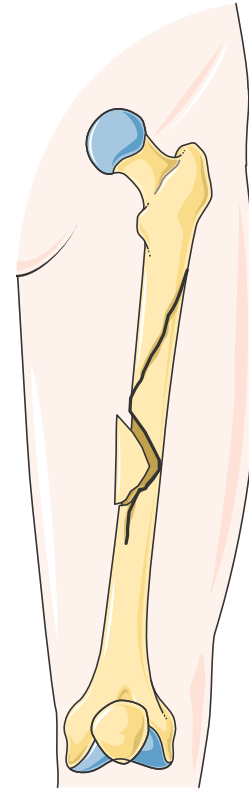
# Kind of fractures (1)



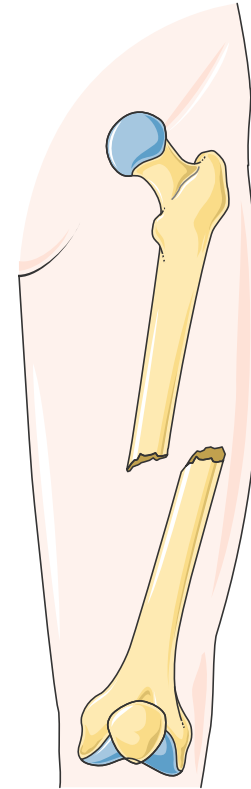
Oblique



Comminuted

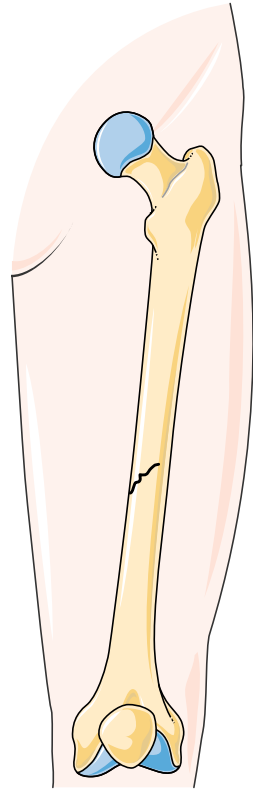


Spiral

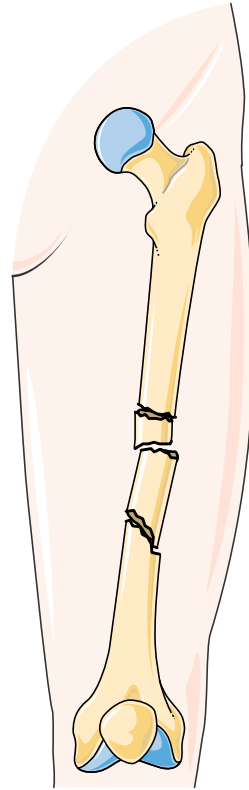


Compound

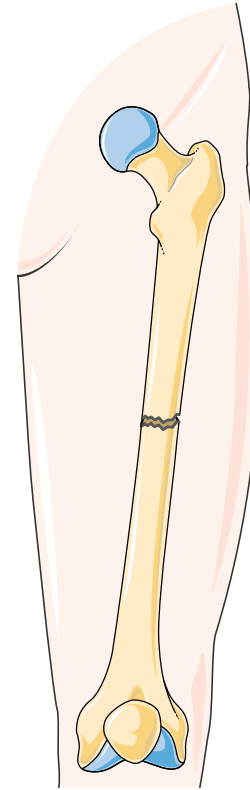
# Kind of fractures (2)



Greenstick

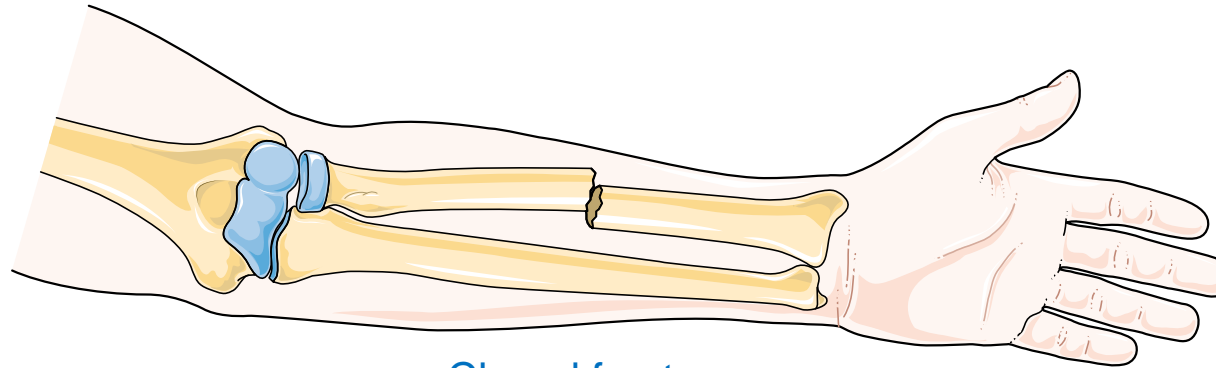


Segmental

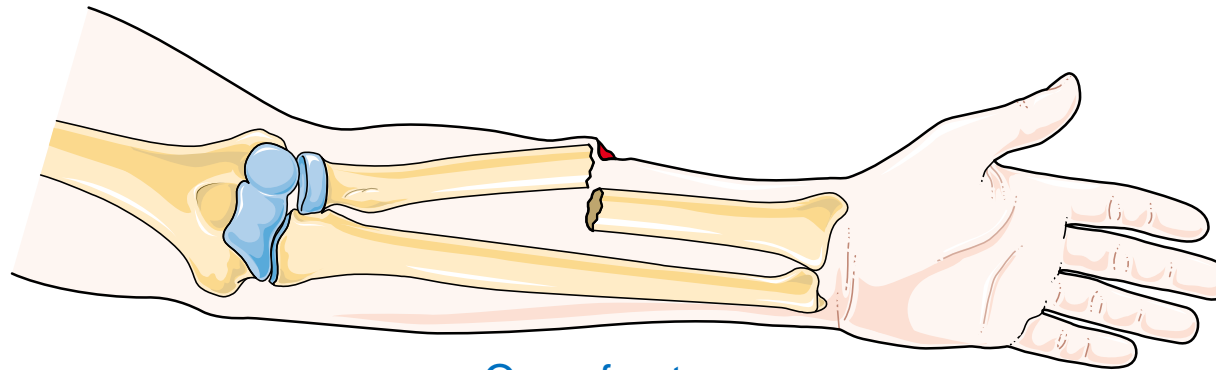


Transverse

# Kind of fractures (3)

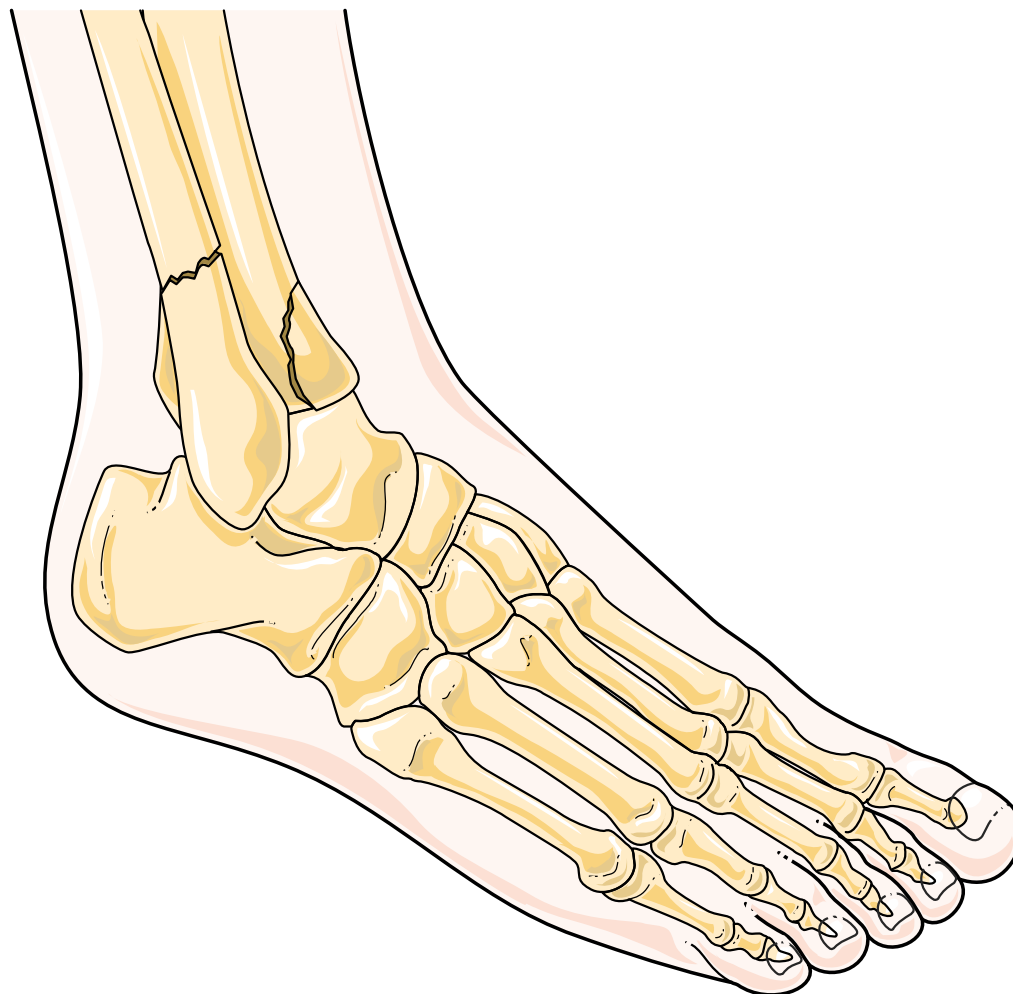


Closed fracture

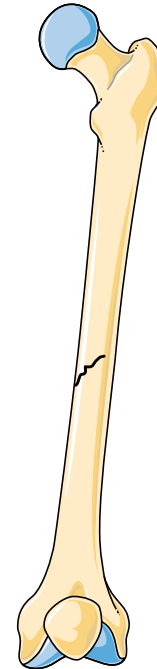
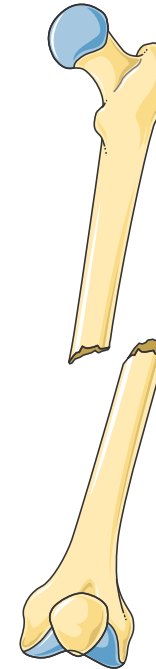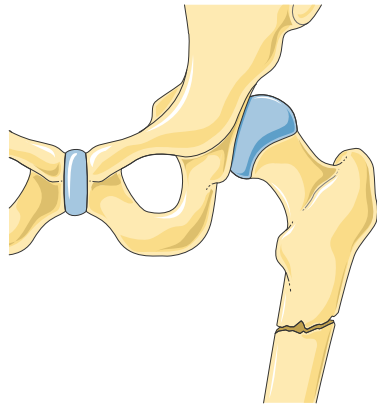
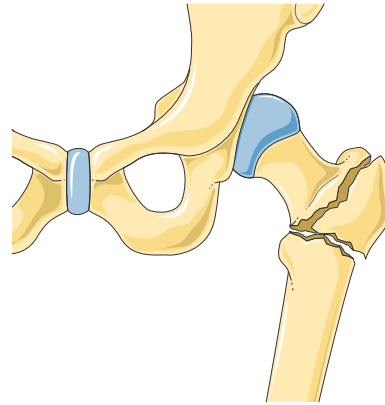
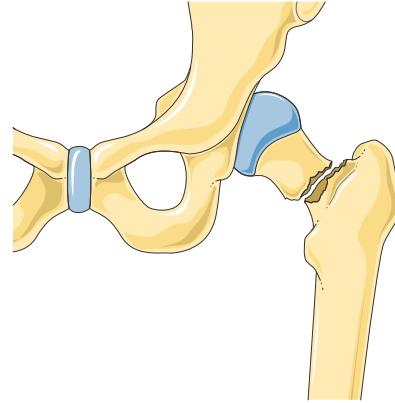
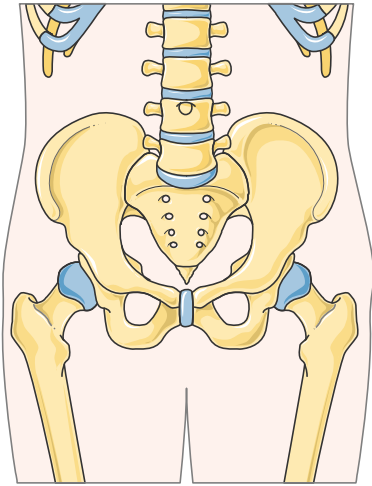


Open fracture

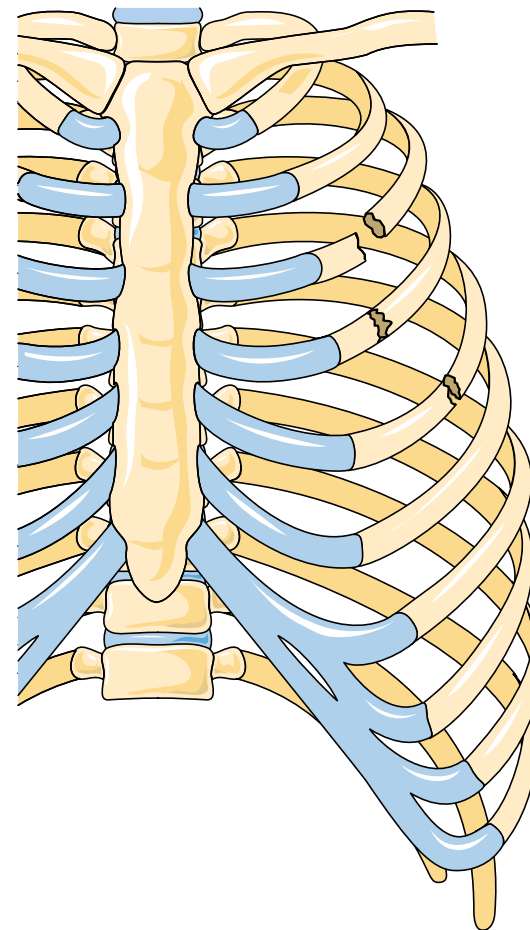
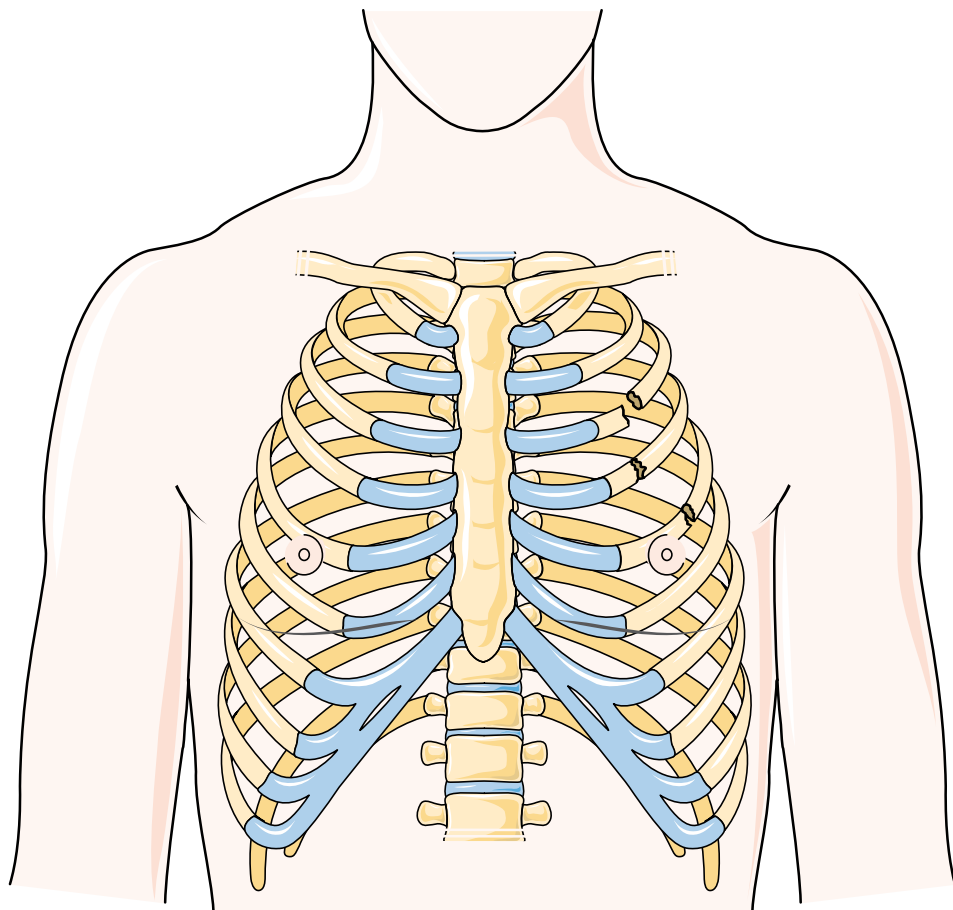
# Ankle fractures



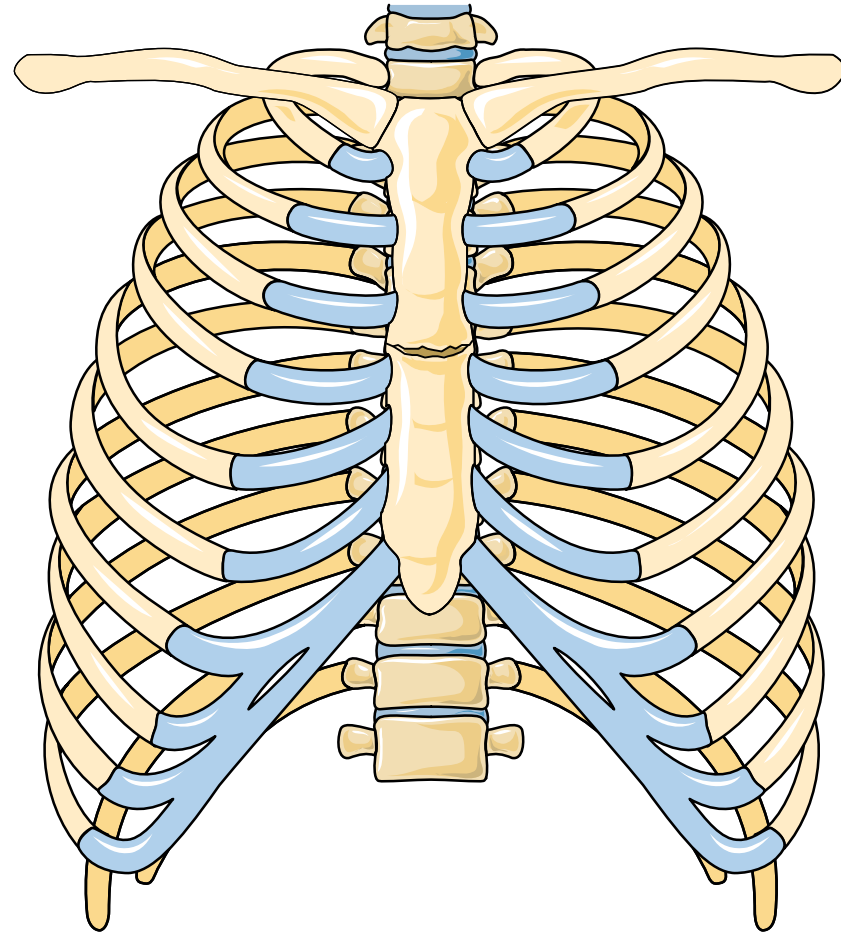
# Fracture of femur



# Rib fractures

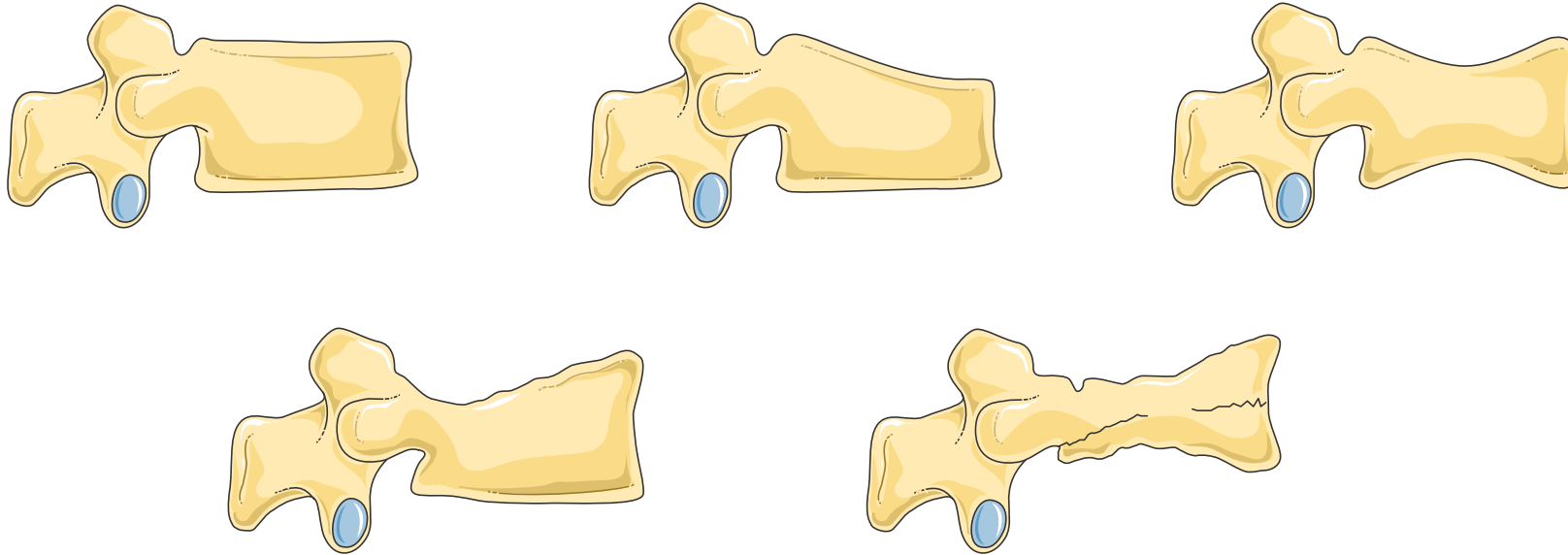


# Sternal fracture

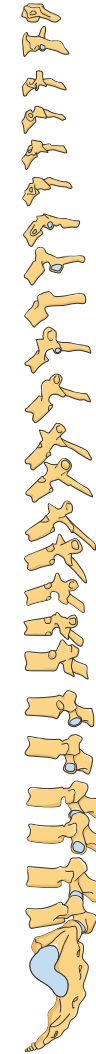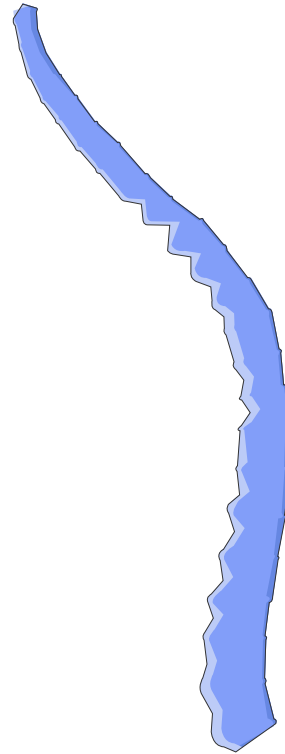
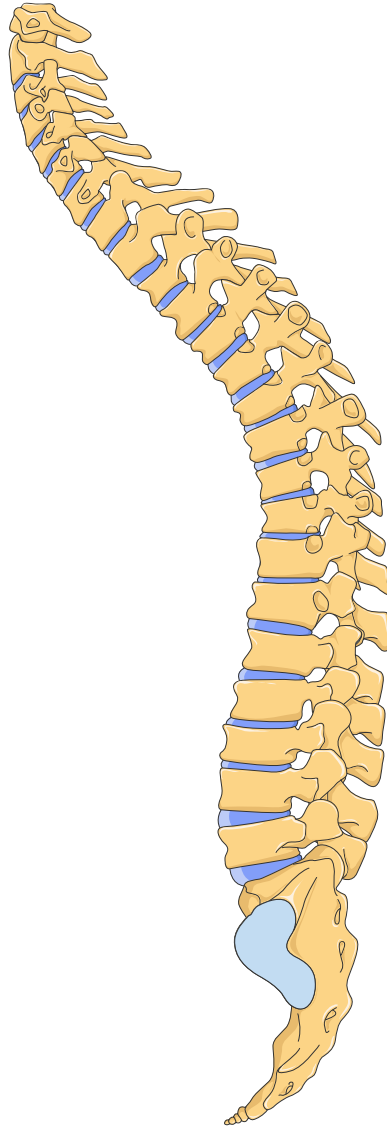




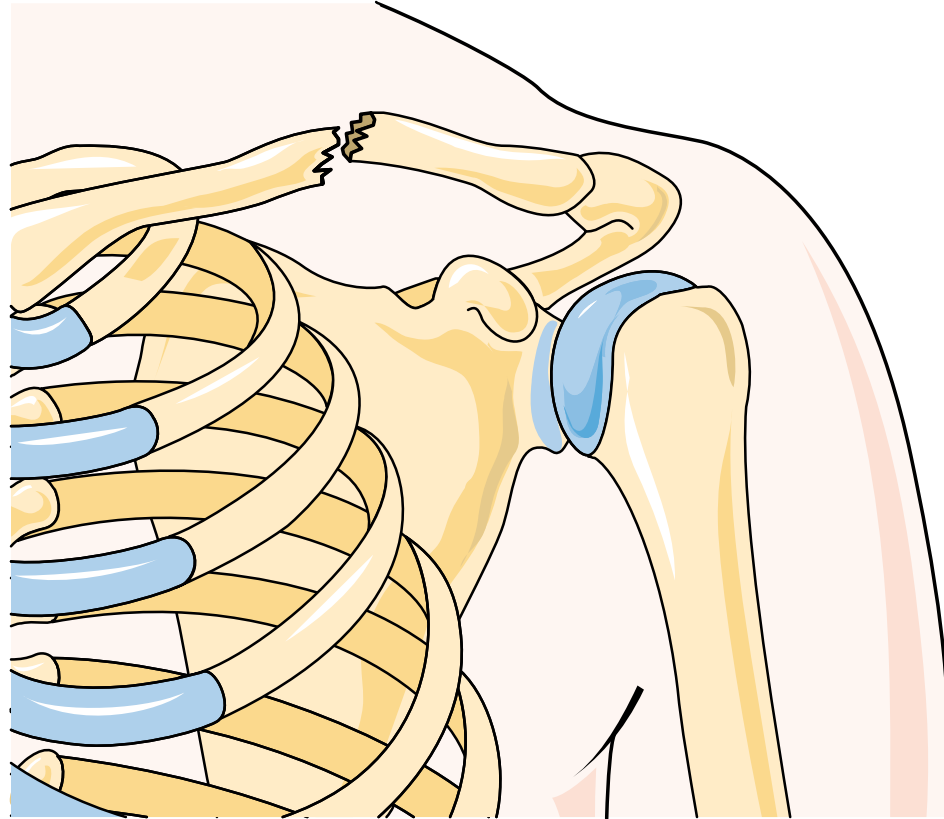
# Vertebral fractures



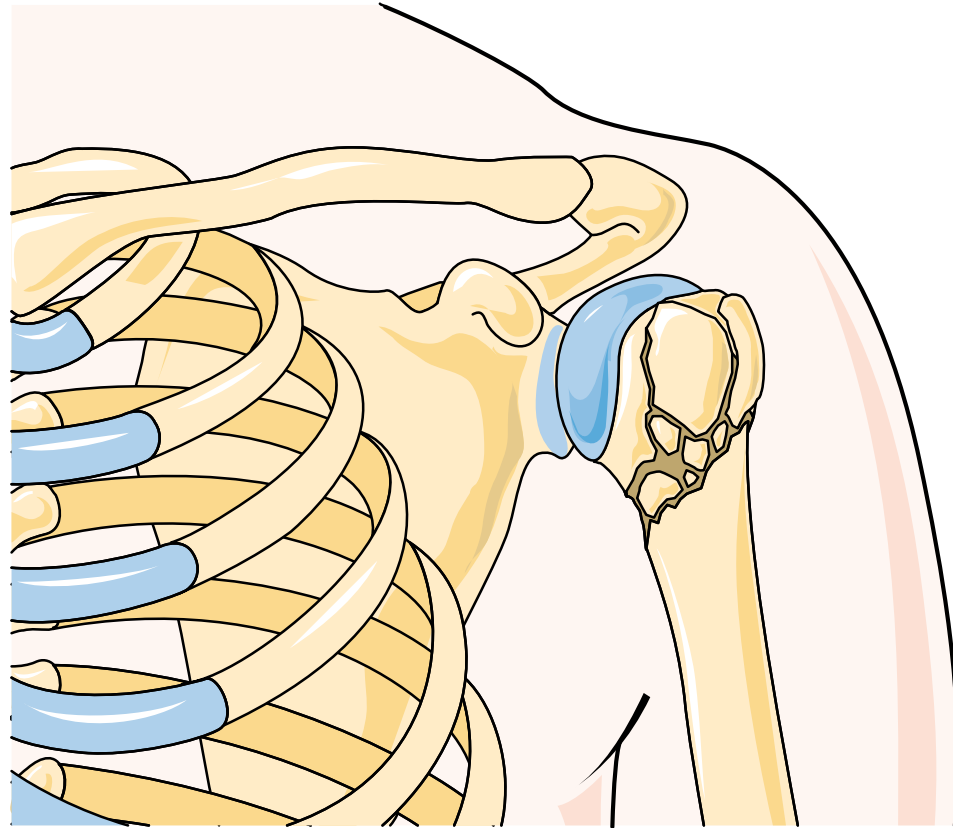
# Compression of the vertebrae



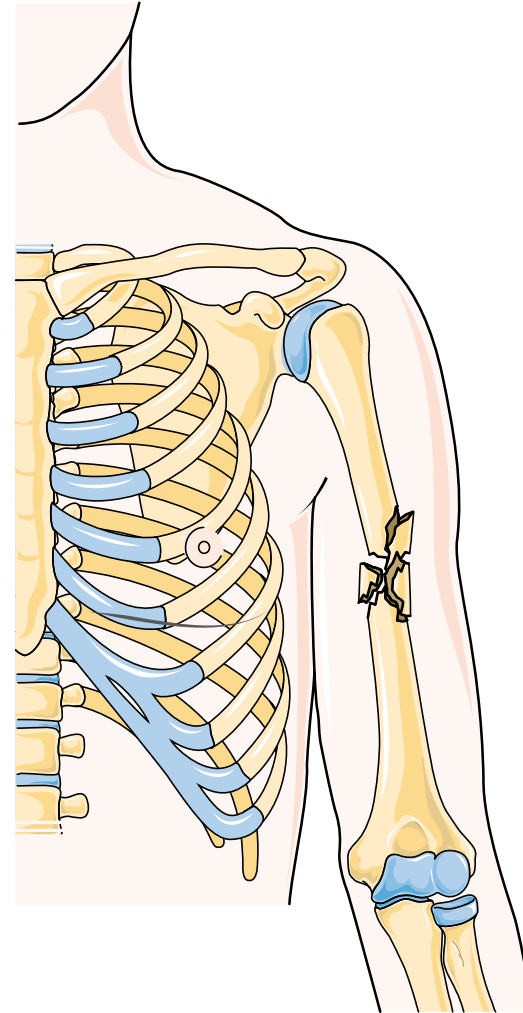
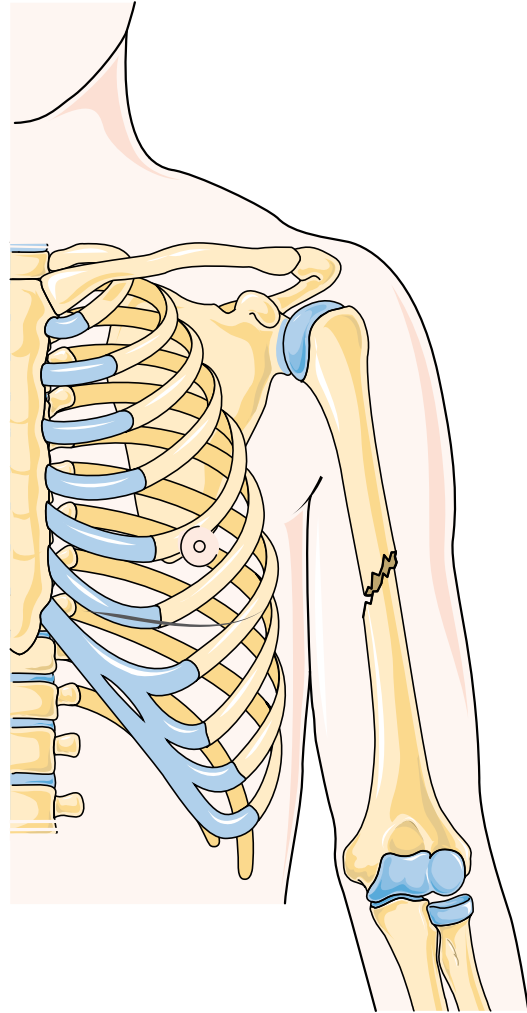
# Clavicle fracture



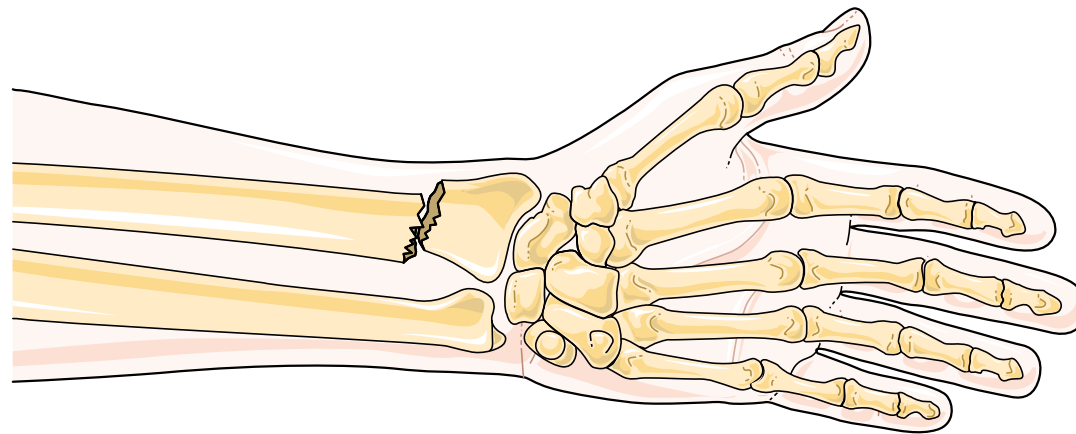
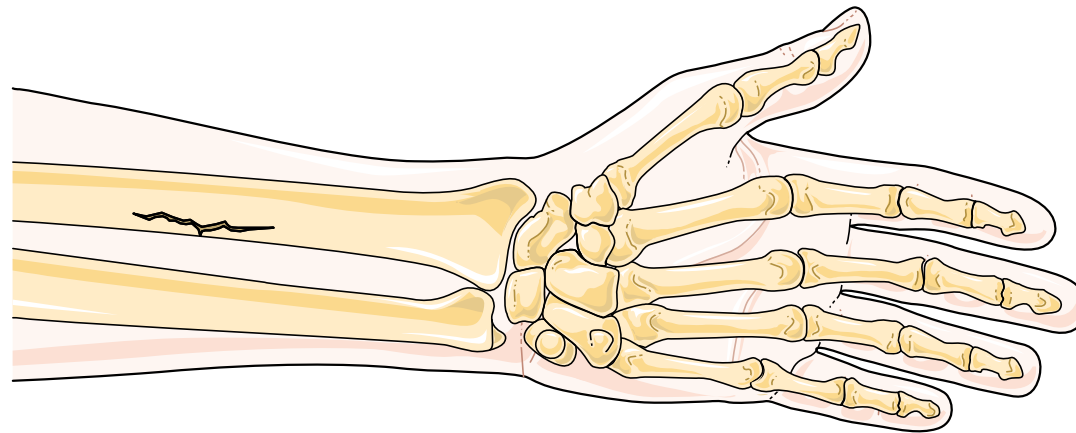
# Shoulder fracture



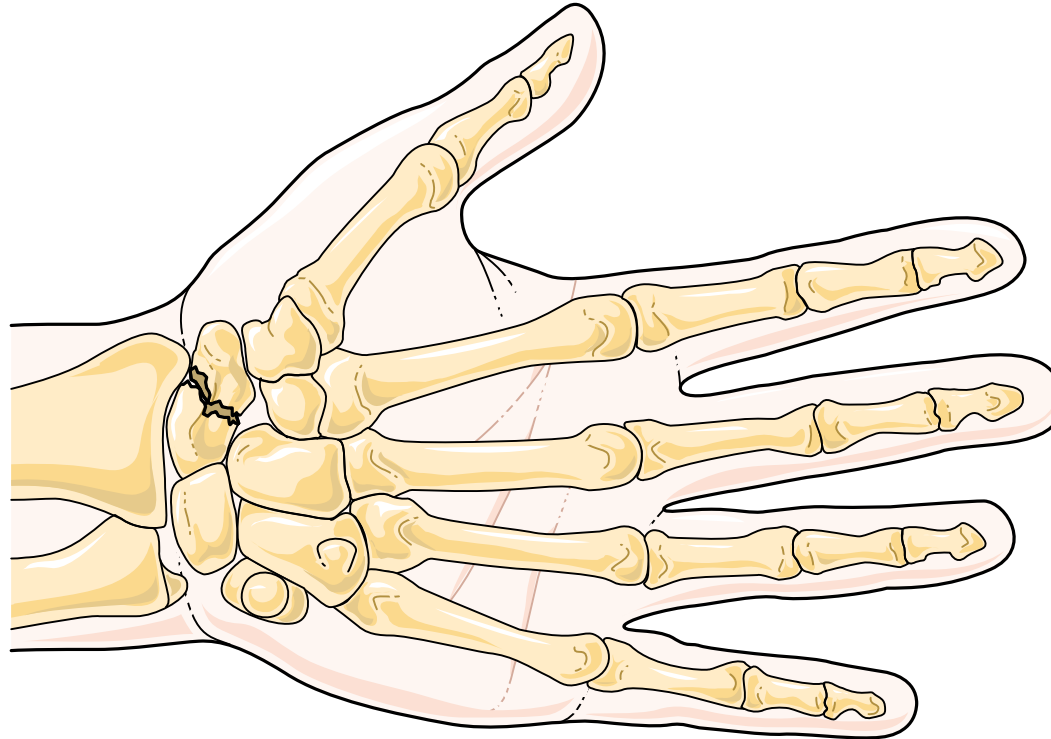
# Humerus fracture



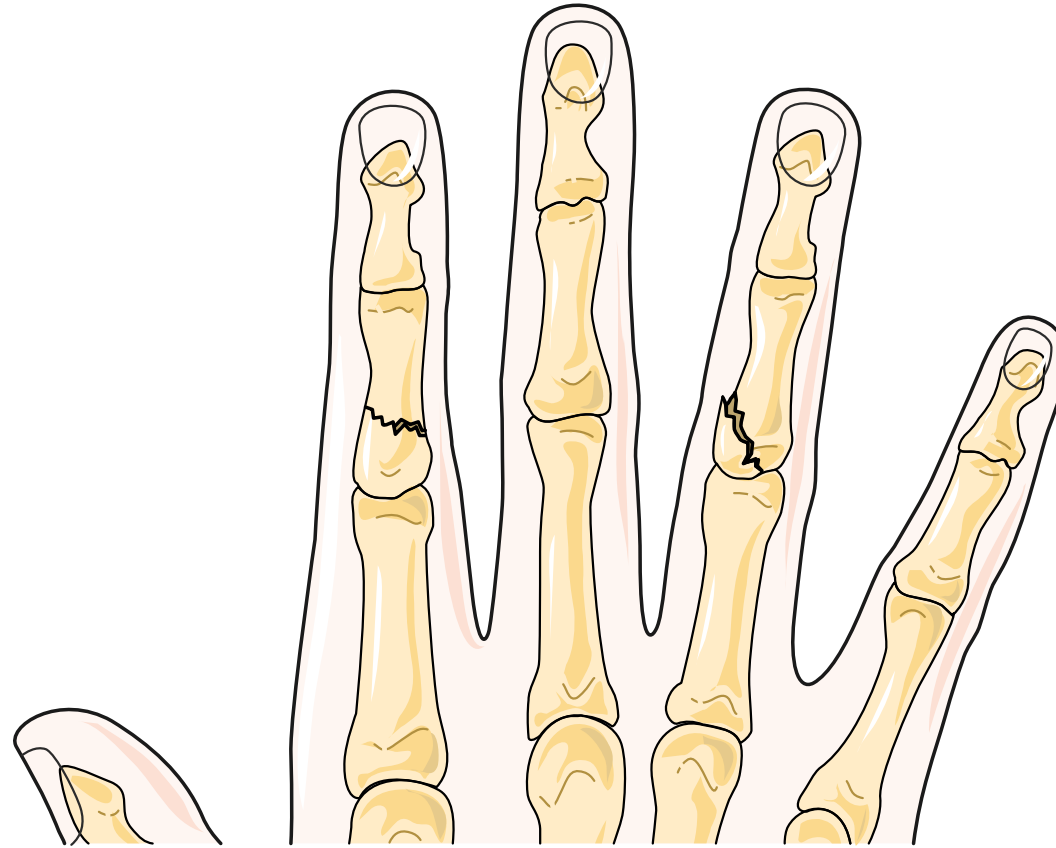
# Radius fracture



# Scaphoid fracture

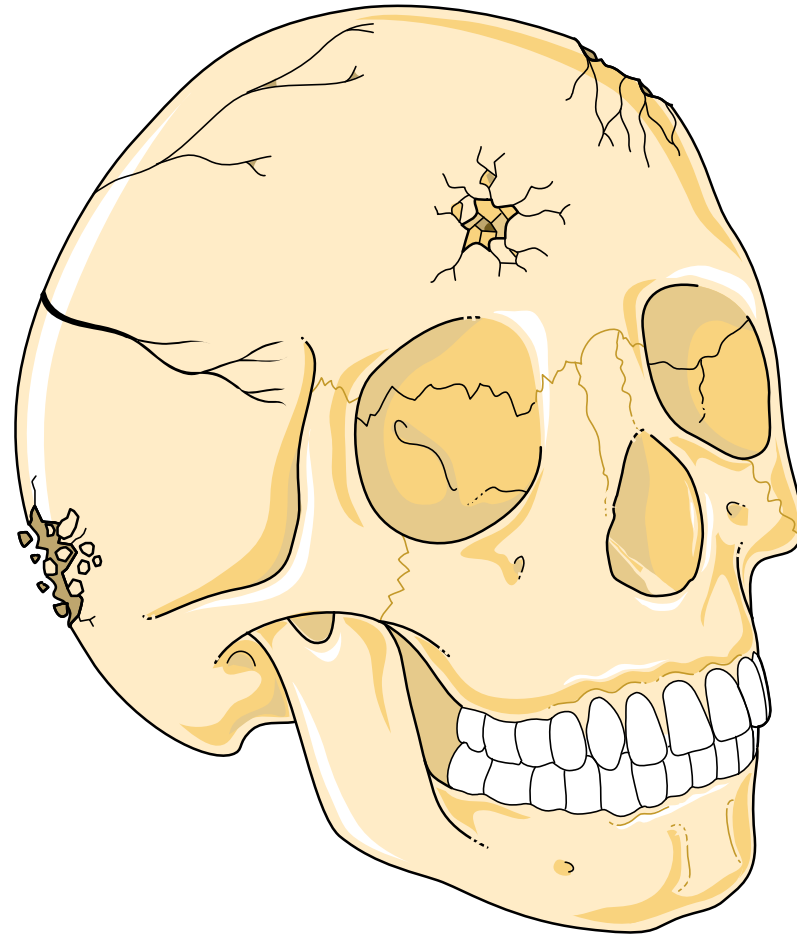


# Finger fractures

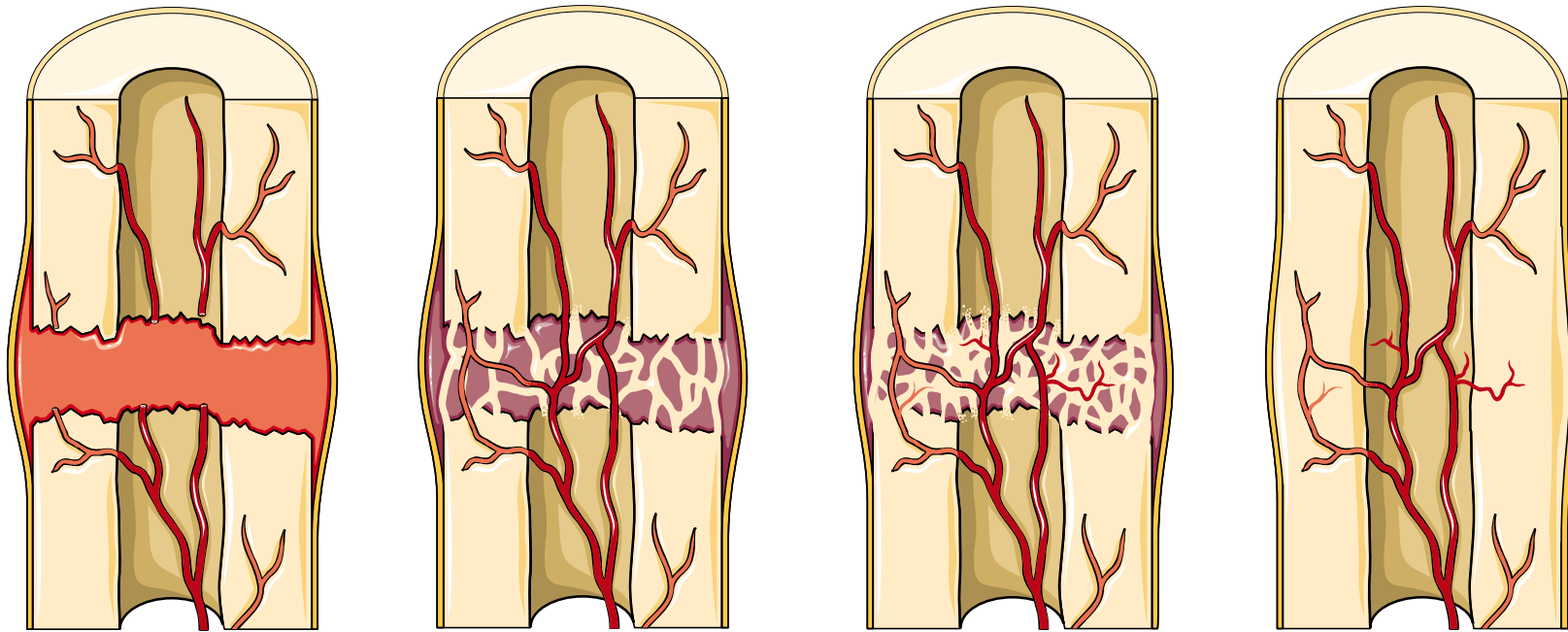




# Skull fractures



# Fracture repair



# Orthopedics

