

W. L. ZUILL,

➤ **Doctor of Veterinary Surgery** ◀

PHILADELPHIA, PA.

OFFICE: No. 1513 Race Street.

Graduate of American Veterinary College, University of the State
of New York.

QM
551

F89C
1878

THE

Roswell P. Flower Library

THIS BOOK IS THE GIFT OF

Dr W. L. Zuill


Cornell University Library
QM 551.F89c 1878

Compendium of histology.



3 1924 001 039 506

vet



Cornell University Library

The original of this book is in
the Cornell University Library.

There are no known copyright restrictions in
the United States on the use of the text.



Translated from the German, by permission of the Author

BY
GEORGE R. CUTTER, M.D.

SURGEON NEW YORK EYE AND EAR INFIRMARY; OPHTHALMIC AND AURAL SURGEON TO
ST. CATHERINE AND WILLIAMSBURGH HOSPITALS; SECRETARY OF THE NEW YORK
OPHTHALMOLOGICAL SOCIETY, ETC., ETC.

•

QM
551
F89C
187B.

~~Copyrighted by~~

COPYRIGHTED BY

G. P. PUTNAM'S SONS,

1876.

No. 1.

TRANSLATOR'S PREFACE.

THE science of Histology has made rapid advances of late years, and many new facts have been acquired in this department. This will be readily appreciated by those who are familiar with the excellent and exhaustive text-books of Frey and Stricker. But many are intimidated by the very copiousness of such works.

Even in Germany, where thoroughness is the great excellence, there is a demand for a compendium. That Professor Frey's little book meets this want, is proved by its enormous sale and the favorable notices of the press.

I hope that this translation may meet with the same kind reception as did that of our Author's work on Microscopic Technology.

GEORGE R. CUTTER, M.D.,

NO. 228 EAST TWELFTH STREET, NEW YORK.

August, 1876.

W. L. Still, M. D.
Veterinarian,
1526 Race St., Phila.

TRANSLATOR'S PREFACE TO THE THIRD EDITION.

IT has afforded me no small gratification that my translation of Professor Frey's work should have met with so very favorable a reception, both by the profession at large and by the medical press. Though brought into direct competition with several very able and well established works on the same subject, it has been adopted as a text-book by the more prominent colleges of Great Britain, the United States and Japan.

It was found necessary to make but very slight changes in the present edition.

GEORGE R. CUTTER, M.D.,

NO. 312 SECOND AVE., NEW YORK.

January, 1878.



AUTHOR'S PREFACE.

HISTOLOGY has, in the course of a few decades, triumphantly won its field; it has become an integral part of medical studies. The hand-books have necessarily become constantly more voluminous, in consequence of the immense wealth of materials.

A short compend of the most essential facts is desirable for students and practicing physicians. I have often heard this wish expressed.

May the attempt, which I herewith venture, be, therefore, indulgently received. The defects of this little book are very well known to the author.

H. FREY.

ZURICH, *July 10th*, 1875.

CONTENTS.

	PAGE
TRANSLATOR'S PREFACE.....	iii
AUTHOR'S PREFACE.....	v
FIRST LECTURE.	
General : the protoplasma, the cell, and its derivatives.....	1
SECOND LECTURE.	
Classification of the tissues.—Blood, lymph, chyle.....	20
THIRD LECTURE.	
The epidermis, or the epithelium	28
FOURTH LECTURE.	
The connective-substance group.—Cartilage, gelatinous tissue, reticular connective tissue, fat.....	41
FIFTH LECTURE.	
Connective tissue.....	51
SIXTH LECTURE.	
Bone tissue.....	60
SEVENTH LECTURE.	
Dentine, enamel, lens tissue.....	73
EIGHTH LECTURE.	
Muscular tissue.....	79
NINTH LECTURE.	
The blood-vessels.....	89
TENTH LECTURE.	
The lymphatics and the lymphatic glands.....	102
ELEVENTH LECTURE.	
The remaining lymphoid organs, with the spleen.—The so-called blood-vascular glands.....	117

	PAGE
TWELFTH LECTURE.	
Gland tissue	128
THIRTEENTH LECTURE.	
The digestive apparatus, with its glands.....	139
FOURTEENTH LECTURE.	
Pancreas and liver.....	150
FIFTEENTH LECTURE.	
The lungs.....	157
SIXTEENTH LECTURE.	
The kidney, with the urinary passages.....	163
SEVENTEENTH LECTURE.	
The female generative glands, the ovary with the efferent apparatus... 173	173
EIGHTEENTH LECTURE.	
The male generative glands, the testicles with the efferent apparatus. 183	183
NINETEENTH LECTURE.	
Nerve tissue.....	192
TWENTIETH LECTURE.	
The arrangement and termination of the nerve fibres.....	202
TWENTY-FIRST LECTURE.	
The central organs of the nervous system, the ganglia, and the spinal cord.. ..	215
TWENTY-SECOND LECTURE.	
The central organs of the nervous system, continued—the medulla oblongata, and the brain.....	224
TWENTY-THIRD LECTURE.	
The organs of sense—skin, gustatory, olfactory, and auditory apparatus	234
TWENTY-FOURTH LECTURE.	
The organs of sense, continued—the eye.....	246
INDEX.....	265

COMPENDIUM OF HISTOLOGY.

FIRST LECTURE.

GENERAL : THE PROTOPLASMA, THE CELL, AND ITS DERIVATIVES.

A DEEP abyss separates the inorganic from the organic, the inanimate from the animate. The rock-crystal on the one side—vegetable and animal on the other ; how infinitely different the image !

Is it, then, many will inquire, possible to bridge over this gulf? We answer, not at the present time. It is, perhaps, reserved for future generations of men to fill up this yawning chasm, by the aid of a more thorough knowledge of nature, and to comprehend the sphere of the material world as a unit.

What, we ask further, is the primary beginning of the organic?

An admirable English naturalist, Huxley, succeeded, in the year 1868, in making a marvelous discovery.

The bottom of our seas, at the most considerable depths, is covered over large tracts with a strange shiny substance. When this thing, called the bathybius, is drawn up by the

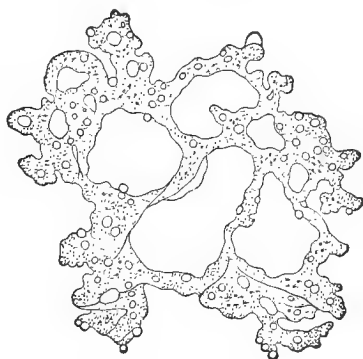


FIG. 1.—Bathybius.

dredge, and placed under the microscope—under that instrument which has conquered the mighty world of minuteness for natural science—a very peculiar image is presented to the astonished eye.

We perceive a transparent jelly, with diminutive granules in its interior. We also frequently meet with small corpuscles, surrounded by this, consisting of carbonate of lime. They look like our modern sleeve buttons.

And this mass lives ! It changes from one shape to another in slow metamorphosis, exhibiting a constant, though sluggish restlessness. Separated portions present the same slow mutability, the same life.

The mass formed by this bathybius is a nitrogenous carbon compound, distended in water, and of an extremely complicated chemical structure. It belongs to the group of albuminous bodies, and is called protoplasma. It coagulates in death, and also at a relatively slight elevation of temperature. The granules it encloses consist partly of coagulated albuminous substances, partly of fat ; mineral substances are also not wanting.

Leaving the dark deep, and turning to the sunny surface of the seas, we here meet with numerous small lumps of

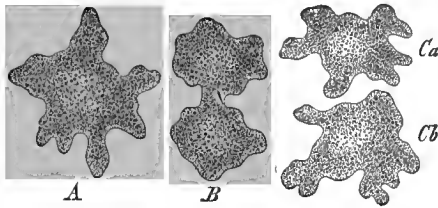


FIG. 2.—Protamoeba. A, undivided ; B, commencing, and C, completed division.

protoplasma, which show the same vital transformations, shooting out processes, sometimes short, sometimes longer, and drawing them in again ; such is the protamoeba of our Fig. 2. These are the

simplest organisms or forms of life. They increase by division.

One of our most distinguished investigators, Haeckel, has called such a lowest being a cytode.

We meet with similar organisms intermingled with these cytodes in the water ; as, for example, the amoeba (Fig. 3),

though in the interior of this constantly changeable protoplasm, together with excavations (*b*), and small foreign bodies (*c*), accidentally taken up from the neighborhood, a roundish structure with small punctiform contents (*a*),

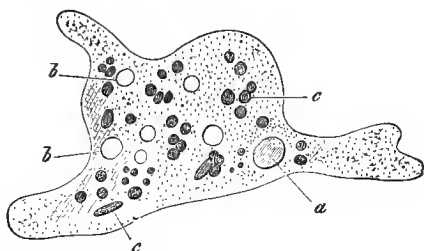


FIG. 3.—Amœba: *a*, nucleus; *b*, vacuoli; *c*, alimentary bodies taken in.

is found. The contained body bears the name of the kernel or nucleus; the small bodies enclosed within the latter are called nucleoli. The entire creature has the significance of a simple naked cell. What service the nucleus renders the amœba we are, at present, unable to say. We now leave these lowest creatures, and pass, at a bound, to the highest animal form—to examine the human body. Its parts have been called organs since the primitive days of medicine. They correspond to the separate pieces of one of our machines. It was also long since known that certain substances of our bodies, such as bone, cartilage, muscle, and nerves, were repeated in all portions of the organism and, slightly or not at all changed, enter into the structure of the most different parts of the body. These substances, which may be compared to the different materials of which the machine is formed, were early known to be composed of still smaller parts. They were compared to the products of the loom, and designated as tissues. This name has been retained, and that branch of anatomical science which treats of these homogeneous parts, is called the science of tissues, or Histology.

On attempting, with the aid of the knife and scissors, to separate such tissues, we, at first, succeed very readily; the fragments permit of a new division, and this may, perhaps, be repeated on those thus obtained. But at last—sometimes sooner, sometimes later—a period arrives when even the finest and sharpest tools become unserviceable; they are too blunt, too coarse.

Here, where the mechanical analysis terminates, the optical begins, by means of the microscope. The latter is an extraordinarily delicate one; the fragment, which the anatomist's scissors are unable further to divide, now proves to be infinitely compounded; it may still consist of thousands of the smallest elements.

These elements are again, in their turn, cells or their derivatives.

Thus, this structure, which forms in an independent manner the body of an amœba, now constitutes our tissues, although in a very conditional independence. The cell has, therefore, entered into the service of a mighty unity; it has to subordinate and conform itself; nevertheless, the thing remains a living individual, comparable to the officer of a modern state department. As he fulfils his individual duty in the service and as a member of a great whole, so, also, does the small cell labor unremittingly until its death.

It appears of interest that these very small living foundation-stones in the body of the higher animals always form cells, and that the cytodes of Haeckel have disappeared.

We have just said that the cells of the human organism were very small. Their diameter varies, in fact, from 0.076, 0.0375, 0.0228 down to 0.0057 mm. Thus it becomes possible that a small particle of the substance of the body, about a cubic millimetre, may contain an extraordinary multitude of them. It has been computed that such a particle of space of the human blood is capable of containing five million red cells, though it is true they only measure 0.0077 mm.



FIG. 4.—Various cells, with nucleus and protoplasma.

The cells present very considerable variations. The latter are gained subsequently with the development of the body. In the earliest period of embryonic life they were all still very similar.

The primitive form of a cell is that of a globe or of a body approximating a sphere. Thus appear the cells *d*, *e*, *g*, *b* of our Fig. 4. The cell, also, from

which in a momentous manner the bodies of all the higher animals have proceeded, the ovum (Fig. 5), presents itself as an elegant spheroidal structure.

From this primitive form two other forms, resulting from compression and adaptation, may be readily traced; the tall, slender, or, as we say, cylindrical cell (Fig. 6, *b*), and the flattened. The latter finally assumes the form of a lamella or scale (Fig. 7).

The bodies of other cells grow in two opposite directions, like processes. We thus obtain the spindle-shaped cell (Fig. 4, *c, f*). When such processes are numerous and are also branched, a singular thing appears, the stellate cell (Fig. 8).

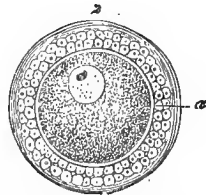
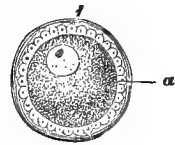


FIG. 5.—Young ova, from the ovarium of a rabbit.

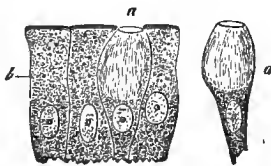


FIG. 6.—Cylindrical cells from the human small intestine; *b*, ordinary elements; *a*, so-called Becher-cells.

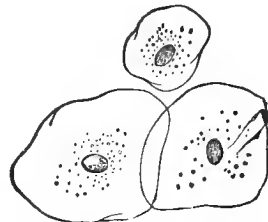


FIG. 7.—Epithelial scales from the human mouth.

The quantity of the cell protoplasm, and hence the magnitude of the body of the cell, is subject to great variation (Fig. 4).

While protoplasm occurs originally in every cell, it may subsequently be replaced by other materials. Thus, in the cells of our Fig. 7, a harder, more waterless substance—keratine—has been substituted. Other cells obtain a lodgment of dark, black pigment granules of great chemical resistance (Fig. 9). These dark molecules are called melanin. One of the most widely diffused structures of the human body is the

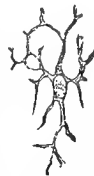

FIG. 8.—Stellate cell from a lymphatic gland.

colorless globular lymphoid cell. It also occurs in the blood (Fig. 10, *d*), and is at last transformed into a disc-shaped

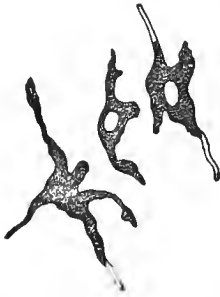

FIG. 9.—Pigmented connective-tissue corpuscle (stellate pigment cell from the mammalian eye).

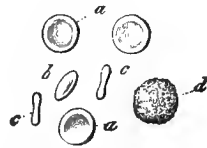


FIG. 10.—Disc-shaped cells of human blood, *a*, *a*, *a*. At *b*, half from the side; at *c*, seen entirely from the side; *d*, lymphoid cell.

structure (*a*, *b*, *c*), whose cell body contains a homogeneous red substance, of an extremely complicated chemical constitution, hæmoglobin. Other cells subsequently become reservoirs of fatty matters, often in a high degree.

We now pass to the kernel or nucleus. Its medium diameter may be assumed to be from 0.007 to 0.005 mm. It is originally a vesicle (Figs. 4 and 5), that is, a structure enveloped by a delicate covering. Nucleoli occur singly, double, or in greater number (Auerbach). Attention has very recently been directed to a circle of small molecules deposited between the nucleolus and the wall of the nucleus, and called the granule-sphere.

The nucleus may subsequently lose this vesicular character and assume a different arrangement. Thus it not unfrequently changes, later, into a firmer, more homogeneous structure (Fig. 7), or becomes granular. Should the growing cell become considerably lengthened, the nucleus also frequently assumes a more elongated form.

As a rule, the nucleus remains a definite, tolerably conservative constituent of the cell. Nevertheless, we meet with others of the latter which have lost by age the nucleus of an earlier period of life. Such non-nucleated cells form the most

external layers of the epidermis covering our skin (Fig. 11). Other cells (Fig. 12) contain, in complete contrast, double nuclei. Their signification will occupy us later. Very singular structures, of irregular form, and, in part, of extraordinary

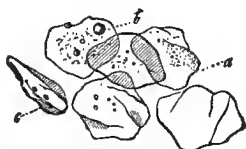

FIG. 11.—Non-nucleated cells of the epidermis.

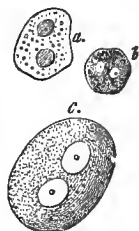


FIG. 12.—Cells with double nuclei; *a*, from the liver, *b* from the choroid of the eye, and *c*, from a ganglion.

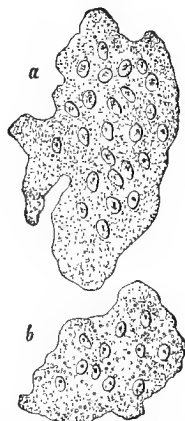


FIG. 13.—Multi-nuclear giant cell from the bone marrow of the new-born.

dimensions, occur in the bone marrow, and also in many abnormal tumors. They have been called myeloplaxes and giant cells (Fig. 13). Their larger specimens may contain a multitude of nuclei.

In these two things, the protoplasm and the nucleus, we have become acquainted with the essential constituents of the cell.

The youthful cell shows nothing further.

Later, it may become different. The surface of the cell body hardens, or from this vicinity is formed a firmer enveloping layer. Thus we have, when this remains very thin, what is called a cell membrane, while to a thicker covering is given the name of the cell capsule.

We just said, "this *may* occur;" but it *need* not. At the present time we occupy a standpoint different from that of

our predecessors. Towards 1840, Schwann, the founder of modern histology, erroneously ascribed the cell membrane as a third essential constituent to every cell, so that the cell would have two concentric envelopes, that of the vesicular nucleus and the external one of the cell body. The still frequently used name of "cell contents" is derived from that period.

It is impossible for any one to demonstrate where such a membrane really begins; that the surface of a cell protoplasm in contact with the surrounding objects may, and, in fact, often does become more solid, would not be denied by any one acquainted with the great changeability of protoplasm. We may only speak of a cell membrane when we are able to isolate the thing, and thus place it with certainty before the microscopist's eye. A smooth, sharp, dark line of demarcation on a possibly strongly changed cell corpse gives us nevertheless no proof of a membrane. We shall find later, it is true, that

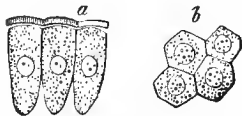


FIG. 14.—Cylindrical epithelium from the small intestine of the rabbit; *a*, Side view of the cells with the thickened and somewhat elevated seam, which is permeated by porous canals; *b*, View of the cells from above, whereby the apertures of the porous canals appear as small points.

the isolation of an envelope on a fat cell, for instance, is very easy. Taking, by way of example, our Fig. 14, the lateral surfaces of the cylindrical structure *a* are provided with a covering which is certainly recognizable. Above, at the broad part, it is otherwise. Here the cell membrane is wanting; and a thicker covering piece, permeated by very delicate longitudinal canals, overlays the protoplasm. We perceive a cell capsule on the mammalian ovum (Fig. 5, 2), while a more youthful ovulum (1) still appears membraneless. In cartilage tissue-cell capsules are quite ordinary occurrences; we shall there be more intimately occupied with them.

We proceed further; we inquire after the life of the cell. A life we have already ascribed to it, although a limited one in the service of the whole.

Can this, however, be demonstrated? This question is asked by many. We answer, yes. We recall to mind that

which we remarked above concerning the bathybius and protamœba, that constant mutability, that vital power of contraction of the protoplasm. Numerous cells of our body, as, for instance, the lymphoid cells (Fig. 10, *d*), show the same, and possess an "amœboid" change of shape.

When, by an artificial experiment, we produce an inflammation of the eyeball of a frog, instead of the clear aqueous of the normal condition, the contents of the anterior chamber soon appear more cloudy. In this less transparent fluid, we now meet with innumerable lymphoid cells which, in this case, are called pus corpuscles.

If we subject these cells in a conservative manner to microscopical examination, we recognize the vital metamorphosis, already familiar to us, of the protoplasm. Every shape which our Fig. 15 presents—and innumerable others also—may, one after the other, be assumed by one and the same cell, till finally, in death, it comes to rest as a spherical body (*l*). Formerly only these corpses were known.

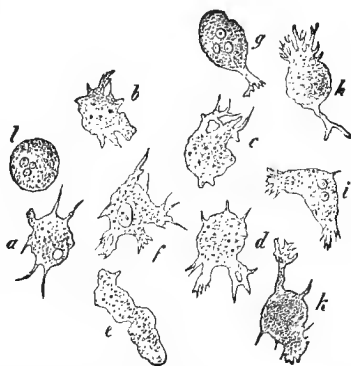

FIG. 15.—Pus cells from the inflamed eye of the frog; *a*, to *h*, the changes in the form of the living cell; *l*, dead-cell.

Still other remarkable things are connected with these peculiarities of the protoplasm.

If to this cloudy aqueous of the eye we add inoffensive coloring matters in a condition of the finest division, indigo or carmine, for instance, we see that the always restless protoplasm gradually takes up into the cell body one colored granule after the other (*b*). Even larger structures may be thus introduced. Fragments and even whole red blood corpuscles may thus enter into the lymphoid cells of the spleen. The amœba (Fig. 3), received its small alimentary corpuscles in exactly the same way. This introduction may take place, in

both cases, at any portion of the outer surface; the latter is, indeed, similar throughout.

By means of this vital transformation, our lymphoid cell is able, like an amœba, to shove itself over whatever it rests on; and thus, very slowly and sluggishly, it is true, wander about. This may be observed in the pus cell in the cloudy aqueous mentioned. In the magnificently transparent cornea of the normal eye of a frog, the lymphoid cells may be seen to wander through the corneal canals in the most distinct manner, so that they gradually pass over the entire microscopic field.

This has been rather drastically expressed by the words, "the cells devour and march."

Such amœboid cells may wander into other cell forms which have come to rest. The surfaces of the body have cell layers which are called epidermis or epithelium. This tissue participates actively in the catarrhal irritations of the mucous membranes. Lymphoid cells then wander from the deeper layers of the latter into the bodies of these epithelial cells (Fig. 16). These strange cells had already been observed before the vitality of the protoplasm was conjectured.

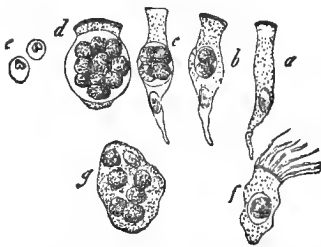


FIG. 16.—Pus corpuscles in the interior of epithelial cells from the human and mammalian body; *a*, Simple cylinder cell of the human biliary canal; *b*, one with two pus cells; *c*, with four, and *d*, with many of these contained cells; *e*, the latter isolated; *f*, a ciliated cell from the human respiratory apparatus with one, and *g*, a flattened epithelial cell from the human urinary bladder, with numerous pus corpuscles.

The process was then naturally not understood. It was then imagined that the lymphoid cells were produced within those of the epithelium.

A form of cell has long been known, a species of epithelium, which presents the most striking vital phenomena. This is the ciliary cell (*f*). Very small and thin cilia, which cover the free surface of the cell body, are constantly occupied in a

to and fro motion. These vibrations are repeated with such extraordinary rapidity that the human eye is unable to dis-

tinguish the individual ones. It is only on the death of the ciliated cell, when these oscillations are retarded, that they can be counted. We now know that these fine ciliæ are protoplasmic threads, and that their movements fall within the vital sphere of that remarkable substance. The rapid work of these small hairs and the sluggishness of ordinary protoplasm, it is true, present a difference which is still inexplicable.

Where there is motion in the domain of animal life, there is also sensation. Have the cells, the vitalized, minimal corner-stones of our bodies, the latter capacity? We may affirm this unreservedly.

When these changeable figures, as they were represented in our Fig. 15, are subjected to a weak electrical irritation, they rapidly return to the spherical form, to subsequently recommence the old play of forming processes.

Every organism, even the smallest and most simple, has a transmutability; that is, it gives off altered unserviceable particles of matter, it receives into itself new matter, and transforms it into the constituents of its own body. The mass of the organism then increases, it grows.

All this happens, likewise, to the cell. The perception of these vital actions is rendered difficult by the smallness and the obscure existence of our structures. That the cells grow may be abundantly shown and with the greatest certainty, as, for example, in the fat and cartilage tissues. That they take up and transmute matter; that is, make it something chemically different, may also be perceived without trouble. Melanin, the black pigment we mentioned above, is wanting in the blood. It is formed by the cell (Fig. 9). Choleic acid salts and biliary pigment, the former, at least, certainly not present in the blood, are productions of the living hepatic cell. The latter presents us, furthermore, with a striking example of the exchange of matter. Both the substances just mentioned appear later as ingredients of the bile. We could readily cite many such occurrences, but these few remarks may suffice; they show, at least, the coming and going of the materials.

The law of destruction adheres like a curse to the heels of

the Organic, from the infusoria, whose life is counted by hours, to the oak, whose existence lasts centuries, throughout this limited duration of life. Concerning the human organism, this highest cell-complex, there is a very ancient, well-known saying that it lives seventy years, and at the furthest eighty.

We now encounter the question: Are the cells, those vital corner-stones of our body, once for all present, to remain with us permanently as faithful companions to the day of death? Or does our body-cell, that delicate little thing, possess a more limited and, perhaps, compared with human life, only a very short existence?

We answer unreservedly in the latter acceptance.

The life of the body is long, under fortunate circumstances; that of our cells is short. We can present but a very defective proof of this, however, at the present time.

We again present a few examples. We have said above that the outer surface of our body is covered by layers of cells. The superficial layers are in loose connection; they are cells in old age. The friction of our clothing daily removes immense numbers of them. A cleanly person, who uses sponge and towel energetically every day, rubs off still greater quantities.

This takes place very actively in our mouth every day. We swallow; our tongue acts in speaking; drink and food pass this entrance of the digestive apparatus. Every one knows this. The mucous membrane of the mouth is, again, covered with a thick layer of epithelial cells. Here, also, many thousand senile cells are rubbed off daily. That which began at the entrance is continued throughout the entire digestive apparatus. An excess of cells is thus lost daily.

To show the duration of life of a cell variety, let us turn to the human nail. The latter, growing from a fold of skin, is a cell-complex. In the depth of the furrow, youth prevails; at the upper border—which we trim—old age. The deceased physiologist of Göttingen, Berthold, proved that a nail cell lives four months in summer and five in winter. A person,

dying in his eightieth year, has changed his nail two hundred times, at least—and the nail appeared such an inanimate, apparently unalterable thing !

We consider the nail cell a relatively long-lived constituent of the body. We believe that most of the cells of our body have a very much shorter existence. We repeat, however, that it is a matter of belief, for no one can prove it, at present ; but everything compels the view that, for example, the red blood corpuscles, of whose multitude we spoke above, have a much shorter existence than the elements of the nails, and they are certainly resembled by many other cell-varieties.

Most cells being destined to an early death, how do they die ?

Science can give to this, at present, but an insufficient answer. Certain cells, those of the outer surface of the body and of many mucous membranes, dry up in their old age ; the connection with the vicinity dissolves, the thing falls from its bed. The red blood cells die by being dissolved in the blood plasma. Others stick fast in the complicated tissue of the spleen, and are likewise children of death ; for the blood corpuscle lives only in the perpetual motion of the current ; rest stamps it with the impress of death.

Other cells show in their old age granules of lime salts. They mummify. In this condition they may, as cell corpses, possibly remain for a still longer time constituents of the body. Generally, however, they soon afterwards become dissolved.

A very disseminated form of death of animal cells, in healthy as in unhealthy life, is the so-called fat degeneration. In the place of the protoplasm, we perceive, in increasing quantity, molecules of fatty matter (Fig. 17). They finally destroy the cell life and cell body.

The human body daily loses, therefore, immense numbers of its living corner-stones. How does it replace this loss ?

We here enter a very interesting department of our science.

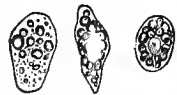

FIG 17.—Fatty degenerated cells from the Graafian follicles of the ovary.

Schwann, the founder of modern histology, taught: "What the crystal is in regard to the inorganic, so is the cell in the sphere of life." As the former shoots forth from the mother-lye, so also, in a suitable animal fluid, are developed the constituents of the cell, nucleolus, nucleus, covering, and cell contents.

This view was embraced during many years. It explained everything so conveniently!

This was, however, over-hasty. Two highly endowed investigators, Remak and Virchow, exposed the error; the former for the embryonic, the latter for the diseased human body.

The organic kingdom forms a continuity from the Bathybius to man. We do not hesitate an instant to acknowledge that this is also our conviction.

There is an old well-known saying: "Omne vivum ex ovo," and in imitation of this sentence: "Omnis cellula e cellula." *The cell arises from the cell; a spontaneous origin, in the sense of Schwann, does not occur.*

We know but one certain method of increase of the cells of our body.

The protamœba, Haeckel's non-nuclear cytoide (Fig. 2), divides itself into two beings by constriction. Each portion grows, by a predominant reception of material, to a new protamœba. This is also the method of propagation of the nucleated cell of the human body. Nucleus and protoplasm divide; from one structure are formed two, and so forth. Our figure (Fig. 18) shows this multiplying process of embryonic blood corpuscles. When, however, the cell has once become surrounded by an envelope or a capsule, when the protoplasm is imprisoned, then (Fig. 19) the contrast of the active and the passive is strikingly presented. The capsule remains stiff and quiet, the cell in prison

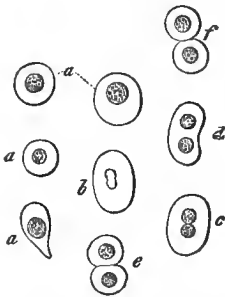


FIG. 18.—Blood corpuscles of a young deer embryo; at *a*, the most globular cells; *b* to *f*, their process of division.

maintains the old life. This multiplying process was, in old times, badly enough designated "endogenous cell formation." Mother and daughter cells were spoken of. The so-called mother cell is nothing but the cell capsule.

Does the process of division of the human cell take place slowly or rapidly? We believe the latter; although a proof can scarcely be presented

here. In the lower animal groups, at all events, processes of division occur which are completed with great rapidity.

We cannot yet leave the process of division, for we now encounter the question: Which constituent of the cell, nucleus, or protoplasm, here assumes the chief rôle? That a non-nucleated lump of protoplasm is capable of dividing, is shown by the protamœba. It is possible that the nucleus is only passively simultaneously constricted, an opinion to which we are inclined. Meanwhile cells which, in the undivided body, present two separated nuclei (Figs. 12, 18, 19), and the multi-nuclear myeloplaxes (Fig. 13), constitute a certain objection. Once more, therefore, uncertainty.

The blood, lymph, and chyle consist of cells suspended in a large quantity of fluid; in the blood, as we already know, these bodies are present in enormous numbers. Something similar is presented by a pathological product—pus. Should one speak here of tis-

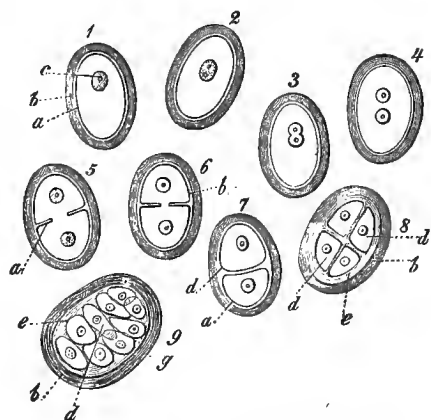


FIG. 19.—Diagram of dividing encapsulated bone cells; *a*, cell body; *b*, capsule; *c*, nucleus; *d*, endogenous cells; *e*, supplementary capsule formation.

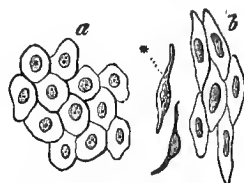


FIG. 20.—Simple flattened epithelium; *a*, of a serous membrane; *b*, of the vessels.

sues? According to our opinion it is permissible; still, we readily admit, the opposite view may be defended. Other tissues, such as the epithelium or the epidermis (Fig. 20), present the cellular elements in close conjunction. At the same time, even the first examination teaches us that our cells are not loosely crowded together; they are intimately united; they are plastered or cemented together. This

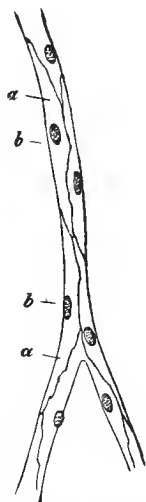


FIG. 21.—Capillary vessel from the mesenterium of the Guinea-pig, after the action of the nitrate of silver solution; *a*, vascular cells; *b*, their nuclei.

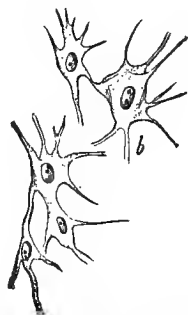
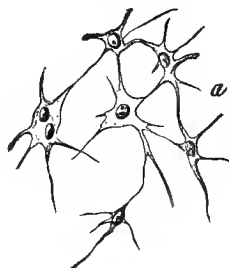

FIG. 22.—Cells of the enamel organ of a four months' human embryo.

substance, which is of very frequent occurrence in a minimal thin layer, is called either the tissue cement or the intercellular substance. If a portion of such tissue is placed for a short time in a very dilute solution of nitrate of silver and then exposed to the light, the tissue cement becomes black. This excellent accessory is nowadays very frequently used. In this manner we years ago recognized that the finest blood-

vessels, the capillaries, were formed of cemented, elongated cell lamellæ which become curved and joined together as a tube (Fig. 21).

Stellate cells (Fig. 22), may blend together through their processes, and form a very delicate net-work. The meshes may be filled up with homogeneous gelatinous matter, and also with a multitude of lymphoid cells. In the former case we again have a variety of intercellular substance.

The latter acquires a considerable thickness in many tissues, as in cartilage. At first (Fig. 23), this intermediate substance is homogeneous throughout. This condition is either main-

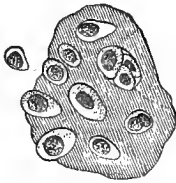

FIG. 23.—Cartilage of a young sheep fetus.

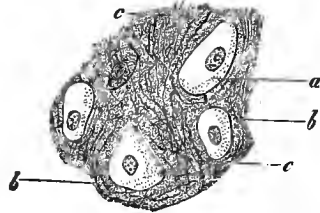


FIG. 24.—Cartilage from the auricle of a calf's ear; *a*, cells; *b*, intercellular substances; *c*, elastic fibres of the latter.

tained, or else fibres subsequently shoot out from the intercellular substance. Frequently (Fig. 24), we meet with them crossed in a felt-like or reticulated manner. They present an obstinate power of resistance to reagents. Such fibres are called elastic. Therefore—we repeat it—the elastic fibre is the result of a subsequent metamorphosis of an originally homogeneous substance.

Connective tissue is infinitely diffused through the human body. A small piece of this, taken from the embryonic body, shows us, together with cells, bundles of very fine fibrillæ, the connective-tissue fibres (Fig. 25). They have a quite similar origin. Subsequently, the con-

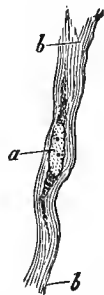


FIG. 25.—From the tendon of a hog's embryo; *a*, the cell; *b*, connective tissue fibrillæ.

nective tissue has also formed those elastic fibres, which we have just met with in cartilage.

From whence, however, does the tissue cement and the intercellular substance come? Have they been inserted from the neighborhood between the cells, or have the cells themselves produced these substances?

The latter is the case. These substances were once constituents of the cell body, at one time represented protoplasm. The formation of these substances was sometimes compared more to a secretive act of the cell, at others, more to a metamorphosis of the outer portion of the cell body. We think both occur, and the difference between these views is, in fact, of little importance.

A deposition may also take place from without upon a single cell or a cell-complex and enter into a closer union with it. The mammalian ovum (Fig. 5), shows a capsule. It is the elaboration of the small cells (*a*) covering the ovulum.

The capsule of the cartilage cells appears very similar to the ovum capsule. Its origin, however, is entirely different.

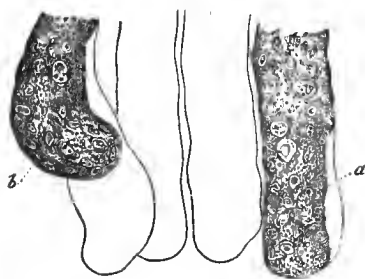


FIG. 26.—Tubular glands from the large intestine of the Guinea-pig. At *a*, a gland with the membrana propria showing in places; at *b*, escape of the contents through a rent in the latter.

The cartilage cells have themselves formed the cartilage capsule. We shall return to this subject later.

The glands (Fig. 26), consist of secretory cell-complexes surrounded by a hyaloid covering, the so-called membrana propria. This is not a secretory product of the cell-aggregation, as was formerly assumed. The membrane is trans-

formed from the connective tissue adjacent to the glandular cell-aggregation. It may remain structureless, but extremely flat stellate cells may also enter into its structure. They then appear as delicate, rib-like thickenings of this membrane.

We will add one more example of a widely diffused cell transformation; we allude to the transversely striated voluntary muscle.

This, a thick, cylindrical fibre, not unfrequently of considerable length, consists of a contractile, longitudinal and transversely striated substance. In the outer portions of the latter lie numerous nuclei with adherent protoplasmic remains. It is surrounded by a hyaloid sheath. The whole, however, arises from a single cell (Fig. 27). This (*a*), with a continual increase of the nuclei, grows into a thread; the protoplasm is transformed into the longitudinally and transversely marked substance (*c*); only a scanty remnant surrounds the nucleus, forming it into a rudimentary cell, and the homogeneous covering of the thing is derived from a transformation of the adjacent connective tissue.

The examples presented may suffice. They show, at least, how the most heterogeneous may result from what was originally similar, through subsequent cell metamorphosis, and they attest the high significance of the cell in the structure of the organism.

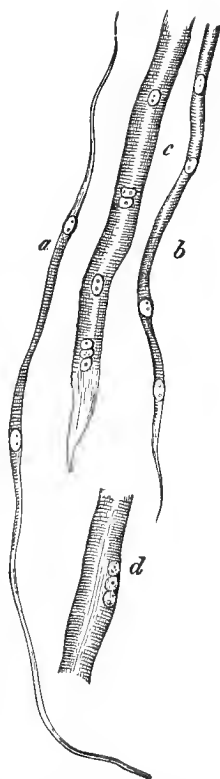


FIG. 27.—Development of the transversely striated muscular fibre (sheep embryo).

W. L. F. M. M. D.

Veterinarian,

1825 East 3rd St. Chicago.

SECOND LECTURE.

CLASSIFICATION OF THE TISSUES.—BLOOD, LYMPH, CHYLE.

A CLASSIFICATION of the tissues was, in the course of time, often attempted; but it is, and remains, a very difficult thing. A scientifically adequate arrangement can be founded only on the course of development of the elements. The latter is unfortunately not yet accurately established throughout. One might nevertheless proceed with strictness, by the aid of the history of development; the three well-known germinal plates from which the embryo arises might be employed as a basis of the arrangement. Still the representation of the tissues thus arranged would be attended with not inconsiderable difficulties.

We will, therefore, employ a preponderating artificial classification, which, with all its defectiveness, possesses, at least, the advantage of presenting the material in a more convenient form to the learner.

We distinguish:

A. Tissues of simple cells with fluid intermediate substance: 1. Blood; 2. Lymph; 3. Chyle.

B. Tissues of simple cells with scanty, firm, structureless intermediate substance: 4. Epithelium; 5. Nails; 6. Hair.

C. Tissues of simple or metamorphosed cells, with partly still homogeneous, partly fibrous, and, not rarely, more firm intermediate substances (connective-tissue group): 7. Cartilage; 8. Gelatinous tissue and reticular connective substance; 9. Fat tissue; 10. Connective tissue; 11. Bone tissue; 12. Dental tissue.

D. Tissues of metamorphosed, as a rule, unfused, cells, with scanty structureless intermediate substance: 13. Enamel tissue; 14. Lens tissue; 15. Muscular tissue.

E. Compound tissues : 16. Vessels ; 17. Glandular tissue ; and 18. Nerve tissue.

We shall, therefore, proceed in this manner, and turn first to the blood.

"Blood is quite a peculiar sort of juice," Goethe lets his Mephistopheles say. Modern science, after nearly a hundred years, endorses the apothegm completely.

If a little drop of this fluid, which appears homogeneous to the naked eye, is spread out in a thin layer under the microscope, we are surprised by a peculiar image. The homogeneous red has disappeared ; we perceive innumerable yellow-colored cells in a colorless fluid. The fluid is called plasma, the cells bear the name of the colored or red blood corpuscles (Fig. 10, *a*, *b*, *c*). Among the colored companions, still another, though not abundant, colorless structure may be noticed by closer examination. This is the lymphoid cell of the blood, the so-called white blood corpuscle (*d*).

The human red blood cells are diminutive structures ; they measure only 0.0088 to 0.0054 mm. Their smallness and their innumerable quantity renders it possible that a small space—a cubic millimetre of blood—may contain five millions of them.

Their form, as Fig. 10 showed, is spherical, the periphery appears yellow, the centre bright and nearly colorless. When the blood corpuscle rolls over the microscopical glass slide, the side view presents the appearance of *c*. Our cell, consequently, represents a circular disc, with excavated central portions of both broad surfaces.

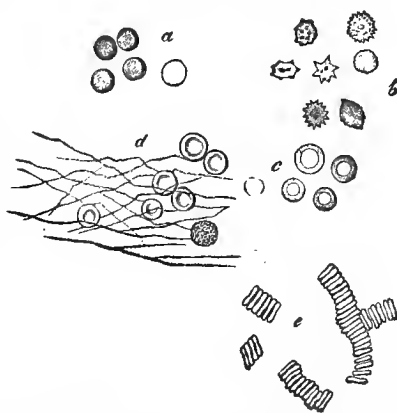


FIG. 28.—Red blood corpuscles of man : *a*, treated with water ; *b*, in evaporating plasma ; *c*, dried ; *d*, after coagulation ; *e*, rouleaux-like arrangement.

The red blood corpuscle is, besides, a very changeable

thing. In evaporating blood it becomes indented (Fig 28, *b*). Rapidly dried, it presents the appearance of *c*. On the addition of water, the cell becomes globular and loses its color. The coloring material, an extremely complicated substance, called hæmoglobin, has now become dissolved. Something similar is also seen in previously frozen blood. The colorless residue is called stroma.

A series of reagents, which have been applied to our structures during many years, act similarly, some distending, others shrinking; but by no treatment does a nucleus make its appearance. The human red blood corpuscle is, therefore, a non-nucleated cell.

Has the thing a membrane—does it possess a covering? we ask further. We answer negatively. An interesting experiment is here, according to our opinion, decisive. When living blood cells are warmed to 52° C., they commence a marvelous transformation. Indentations of the border rapidly

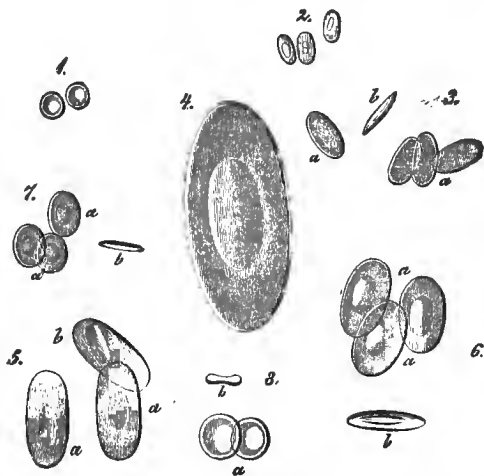


FIG. 20.—Colored blood cells; 1, from man; 2, camel; 3, pigeon; 4, proteus; 5, water salamander; 6, frog; 7, cobitis; 8, ammocetes. At *a*, surface view; *b*, profile (mostly after Wagner).

occur, and partial constrictions of the cell body rapidly follow, which either immediately break off or remain in connection

with the main portion by means of a thin, pedicle-like bridge. The strangest appearances are hereby presented to the eye. It is plain that only a membraneless cell body can present such constrictions.

The cells, these living corner-stones of our body, are otherwise quite similar in the various vertebrate animals; it is not so, however, with the blood. The differences in most of the mammalia are certainly slight. The form remains; only the diameters vary somewhat. A few ruminants, the camel, alpaca, and llama, have oval cells (Fig. 29, 2).

The blood corpuscles of birds (3), amphibia, and most fishes (3), appear elliptic; but in the middle of both broad surfaces we meet with an elevation. The diameter changes in an interesting manner. In birds, it is 0.0184 to 0.0150 mm.; in the squamigerous amphibia, 0.0182 to 0.0150; in osseous fishes (7), 0.0182 to 0.0114. Our cells reach prodigious dimensions in the ray and shark, 0.0285 to 0.0226 mm.; then among the batrachia, the frog (6) and the toad have blood corpuscles of 0.0226; the triton (5), up to 0.0325 mm.; and the salamander has still larger. The group of the pisciform amphibia have the largest of all. In the proteus they measure 0.057 mm. The cyclostomen, a low group of fishes, have, strangely, again, spherical bi-concave discs measuring 0.0113 mm. (8).

All these blood corpuscles behave, with reagents, similar to those of man and the mammalia. But in them all, on the contrary, there is a nucleus. Even in the dying cell it is visible. Many reagents—for example, water, very dilute acetic acid—let it show out from the now discolored cell as a granular structure (Fig. 30, *a*, *b*).

The second element of the blood, the lymphoid cell, is much more homogeneous. The form is, throughout, spherical; the size is, in man (Fig. 10, *d*; Fig. 31, 1 to 4), rarely 0.005, generally 0.0077 to 0.012 mm. The most of our structures, according to this, exceed the dimensions of the colored corpuscles. It is the same in the mammalia. In the remaining classes of the

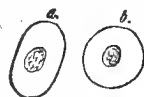

FIG. 30.—Blood cells of the frog with granular nuclei.

vertebrates, however, the lymphoid cell is smaller than the colored element.

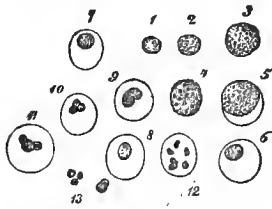


FIG. 31.—Lymph cells; at 1 to 4, unchanged; at 5, the nucleus and hull appear; the same at 6, 7, and 8; at 9, the nucleus begins to split, likewise at 10 and 11; at 12, it has split up into six pieces; at 13, free nuclear substance.

They show a molecular protoplasma, with a granular contour. A few lymphoid cells harbor, in addition, fat molecules (4). If water be allowed to act on them, the nucleus immediately begins to detach itself (5). After this we have nuclear forms, such as the cells 6, 7, and 8 possess. Other cells show a reniform (9), or triplicate nucleus (10, 11). This artificial production

may finally break up into a number of small fragments (12).

The lymphoid cells adhere readily, they are of a somewhat sticky nature. Their specific weight is less than that of the red blood corpuscles. During life we meet with the already described amœboid change of form, as well as a locomotion thereby induced; this takes place most actively in diluted plasma (Thoma). The cells can also be made to take up small foreign particles.

There are one, two to three colorless blood cells to 1,000 red ones in man. The number increases after a plentiful meal, after the loss of blood, and also under conditions which indicate a more active blood formation. An interesting phenomenon is presented by the spleen. The blood flowing into it shows the usual small number of lymphoid cells, while in the blood of the splenic vein 5, 7, 12, 15, and more of them occur. In the lower groups of vertebrate animals, the number of the colorless cells is more considerable; in the frog, the proportion of lymphoid cells to red blood corpuscles is 1 : 4-10.

The web of the frog and the tail of its larvæ are adapted to examinations of the circulation. The wonderful spectacle (Fig. 32), shows how the colored blood corpuscles readily and rapidly pass along and among each other, while the viscous lymphoid cells move much less rapidly, and not unfrequently adhere for a time to the inner surface of the vessel.

But whence do our lymphoid cells originate? First, from the lymph and chyle, that is, from the lymphatic glands, then from the spleen and bone marrow. They are carried away from both the latter parts by the blood current.

What becomes of our cells in the veins?

They become, in part, gradually transformed into red blood corpuscles, and cover the loss of the latter. Whether, however, a greater or only a lesser portion undergoes this metamorphosis, we are not yet able to say; for this, we

must first learn more accurately the duration of the life of the red blood corpuscles.

The manner of this metamorphosis we can state in some degree. The globular form changes to the specific one of the red blood cell, and the protoplasm is replaced by a homogeneous colored substance. In mammalia and man, finally, there is also a loss of the nucleus.

Isolated examples of such intermediate forms have been recognized in the blood for years, especially in that of the spleen, the mammary ducts and the bone medulla.

The bright red color of the arterial, and the dark of the venous blood is caused by a combination of oxygen with the hæmoglobin, or a reduction of the latter. Prolonged changes in the form of the blood corpuscles likewise exert a modifying effect on the color. Distended, they lend a darker color to our fluid; shriveled, a brighter one.

When a drop of blood is left to itself, it coagulates. The filiform separation of the fibrine is shown in our Fig. 28, *d*.

When blood is beaten, that is, the fibrine caused to coagulate, the cells sink, the red ones more rapidly, the colorless,

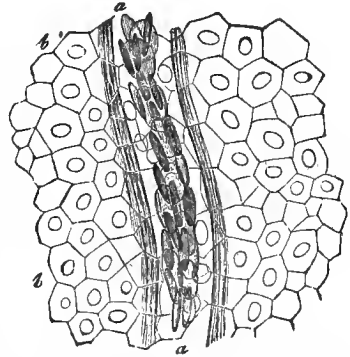


FIG. 32.—The blood current in the web of the frog; *a*, the vessel; *b*, the epithelial cells of the tissue.

lighter ones more slowly, the former arranging themselves in rolls (*e*).

We come, finally, to the blood formation of the embryo. The flat germinal layer, from which the human body arises, consists of three membranous cell layers lying one over the other, the horn layer (Hornblatt), the middle germinal layer, and the intestinal gland layer (Darmdrüsenblatt) (Remak). The heart, vessels, and blood proceed from this middle layer, from which, besides, many parts of the body originate.

The first blood appears very early, and consists only of colorless cells, formed of protoplasma and a vesicular nucleus. The homogeneous yellow substance gradually replaces the molecular protoplasma. We have now before us, nucleated colored blood corpuscles (Fig. 18, *a*), of 0.0056 to 0.016 mm.

At this period an increase also takes place by the way of division (*a* to *f*). Later, this procedure becomes extinct, and the cells assume more and more the specific form, the nucleus at the same time disappearing.

Let us now proceed to the lymph and chyle.

The fluid of the living blood, the plasma, constantly passes through the thin capillary walls into the adjacent tissues. It brings to the latter the nutrient materials, to the one these; to the second, again, others. The fluid becomes impregnated, however, with the products of decomposition of the tissues. The latter are again different.

The tissue fluids, which are in consequence so variable in their chemical constitution, finally collect in the fissures and spaces of the body. Thin-walled vessels are gradually developed from these; and then, uniting in larger trunks, they finally enter the blood passages. These are the lymphatic vessels; and the fluid contents, whose nature we have just described, are called lymph.

The walls of the intestines also have their lymph districts. Towards the close of active digestion they contain temporarily another cloudy or white fluid, which is very rich in albumen and fat. This is the lacteal juice or chyle. The canals bear the name of the chyliferous system of vessels.

The lymph appears colorless and clear as water. Taken from the smallest vessels, it may be without cells. It contains large quantities of them when drawn from the larger vessels, especially just after the passage of the latter through lymphatic glands or allied structures. Nevertheless, it is infinitely less rich in cells than the blood. They are the same lymphoid cells we became acquainted with in the blood (Fig. 31); further description is therefore unnecessary.

The lymph presents nothing further. In the chyle, on the contrary—and they cause the cloudy or whitish appearance of the fluid—we meet with innumerable infinitely fine dust-like molecules. With a strong magnifying power they show a peculiar, dancing, driving about, the so-called Brunonian molecular movement. But there is nothing strange in this. It is natural to all very small bodies suspended in water, small particles of fat, the smallest crystals, carmine granules, and the like. These dust-like particles consist of fat, surrounded by a very thin albuminous covering.

Red blood corpuscles may be met with in the lymph and chyle as incidental constituents, and occasionally as transition forms. I have seen the latter in the thoracic duct of the rabbit.

Red blood cells, pressed out from the blood-vessels, may also finally reach the lymphatics. There is no doubt that the actively emigrated colorless blood cells often penetrate these passages, and thus again commence the journey back into the blood.

W L Guile
Phila.
THIRD LECTURE.

THE EPIDERMIS, OR THE EPITHELIUM.

UNDER epithelium we understand closely-arranged cell layers, held together by a minimal quantity of cement (p. 16); it covers the surface of the body, the external as well as the internal.

All three plates of the germinal layer (p. 26), participate in the production of the tissue under examination. The horn layer supplies the covering of the corium, the so-called epidermis. The lower germinal plate forms the epithelium of the digestive apparatus and the organs arising from the latter. Not less important is the rôle of the middle cell layer. Manifold cavities originate in it; the passages of the vascular system, the so-called serous sacs, the articular cavities, down to innumerable small and diminutive tissue spaces. All these again have their epithelial cell covering. The latter is now called endothelium. The principle is correct; but the boundaries cannot yet be sharply drawn throughout.

Epithelium consists either of a simple cell layer, or the cells are stratified more or less manifoldly over each other. We distinguish, therefore, unstratified and stratified epithelium. The latter originates in the horn layer. The former is due to the intestinal gland, as well as the middle germinal plate.

The form of the cell varies. Many kinds of epithelium present only thin, flat, scale-like cells (Figs. 7 and 20). We speak now of flattened or pavement epithelium. In other varieties the cell is tall and slender. This is called cylindrical epithelium (Figs. 6 and 14). When the surface of the cylindrical cells has vibratory ciliæ (Fig. 33) we have the vibratile or ciliated epithelium.

The simplest unstratified pavement epithelium belongs in most, but perhaps not all its occurrences, to the endothelium. We find it in this way on the surface of the serous sacs, on the posterior wall of the cornea of the eye, over the lateral surfaces of the synovial capsules of the joints. The same endothelia are met with on the inner surface of the cardiac cavities and the vessels.

These cells, very thin lamellæ, appear sometimes broad and short (Fig. 20, *a*), on the serous membranes, again very narrow and long (*b*) on the inner surface of the arteries. The endothelium of the veins has a median character.

A larger blood-vessel is a complicated thing. In proportion as we descend to the smaller and still smaller branches, one outer layer after the other disappears from this complicated structure, and at last only the innermost endothelial layer remains. Large cells with lapped edges, and—induced by the position of the vascular tube—now much more strongly incurvated and in close connection, constitute the walls of the capillary (Fig. 21). The lymphatic vessels are also formed in the same manner, though their finest canals—and they occur in immense numbers throughout the body—show the outer surfaces of these endothelial cells grown into an intimate connection with the neighboring tissue, so that one might here speak of lacunæ.

The terminal respiratory portions of the lungs, the air vesicles or alveoli, have a layer of simple flattened epithelium which does not belong to the endothelium.

We pass over the others at present.

An interesting variety is found at the outer surface of the

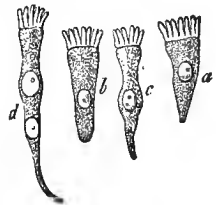

FIG. 33.—Various forms of ciliated epithelium.

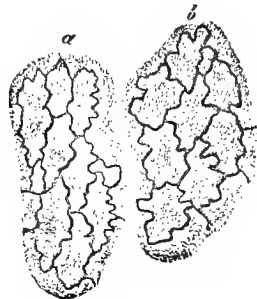


FIG. 34.—Endothelial cells after treatment with nitrate of silver.

retina. They were formerly called polyhedral pigment cells (Fig. 35). Their surface presents a delicate mosaic, as a rule, of a hexagonal form, of 0.0135 to 0.0204 mm. The quantity



FIG. 35.—Pigment epithelium of the retina of the sheep; *a*, ordinary hexagonal cells; *b*, a larger octagonal one.

of the pigment granules embedded in the soft, homogeneous substance of the cell body varies, so that the nucleus is sometimes visible, at others concealed. The outer portion of the cell remains free from these melanine molecules, which appear to form small crystals (Frisch). The profile view shows, however, that our cell, far from constituting a flat structure, possesses, rather, a certain, sometimes a considerable, height, which, at least, equals the diameter. It is thus in the lower vertebrate animals; here their body sends downwards a number of filamentous and spiny processes. The latter, at first, still contain pigment molecules, and surround in a sheath-like manner the rods and cones, the marvellous terminal apparatus of the retina. This is less frequent in mammalian animals. These pigmented cells extend beyond the limits of the specially nervous portion of the retina, over the so-called ora serrata, where they become smaller, more rich in pigment, and are in thin layers. In this manner they then cover the ciliary processes and the posterior surface of the iris.

Certain of the mammalia (the carnivora and ruminantia) have a bright, glistening place in the interior of the eye, called the tapetum. Our retinal epithelium is here unpigmented. In albinos this is the case throughout, and the cells present the appearance of a delicate pavement epithelium, as, for instance, in the white rabbit.

Many mucous membranes present material, and sometimes very considerable, layers of pavement epithelium. Among these are the conjunctiva of the eye, the mucous membrane of the nostrils and of the anus, the mouth and pharynx, the oesophagus, the urinary passages, and the vagina.

In the most superficial layers of the conjunctiva (Fig. 36, *a*)

we meet with flattened, not inconsiderable cells. In the middle layers these elements become smaller, but taller, more round, and, in the deepest layer (*b*), at last, cylindrical.

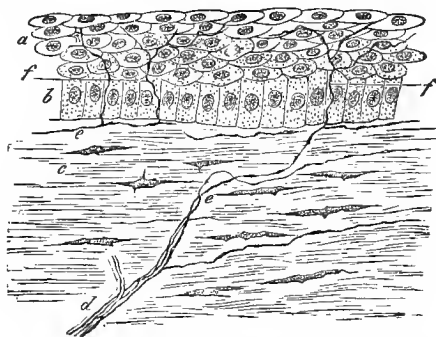


FIG. 36.—The cornea of the rabbit in vertical transverse section, after treatment with chloride of gold; *a*, the older, *b*, the young epithelial cells of the anterior surface; *c*, corneal tissue; *d*, a nerve branch; *e*, finest nerve fibres or primitive fibrillæ; *f*, their distribution, and termination in the epithelium.

With a greater increase of the epithelial stratification, the number of the upper and middle cell layers is much more considerable.

All the cells have a nucleus. The lowermost have a soft protoplasmic body; the superficial (Fig. 7) have become more solid and harder; they consist of corneous matter, or keratine, a derivative of the albuminous group. These cornified cells absorb weak alkaline solutions with avidity, becoming, at the same time, distended to a globular form.

A vertical transverse section, after the manner of our drawing, favors the supposition that our cells have a pretty regular form.

When, however, the cell cement has been dissolved by a suitable macerating medium, an entirely different appearance is presented. The stratified pavement epithelium now appears very much more like extremely polymorphous cells. They lock into each other with their pointed and leaf-like processes; the convex surface of one cell is in contact with the concave surface of its neighbor; the surface is rough and

sometimes indented (Lott, Langerhans). This was first seen in the epithelium of the urinary bladder. When the epithelial stratification is more developed, the cells of the lower and middle layers lock into each other with their enormous spines and ridges, like two brushes pressed together (Fig. 37). These "spinous and dentate cells" (Schultze) lead to an intimate clinching. This connection is, however, again dissolved upwards, and their deciduousness is thus promoted.

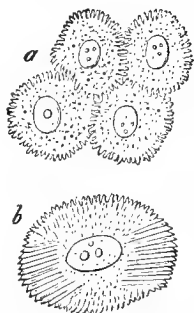


FIG. 37.—Stachel or ruff cells; *a*, from the deeper layers of human epidermis; *b*, cell from a papillary tumor of the human tongue.

The most dense formation of flattened epithelium covers the human corium. It has long been known under the name of the epidermis.

This corium projects in small papillæ of various shapes. They are called the sensitive or tactile papillæ. The epidermis forms a smoother covering over the whole; its deeper cell layers must, therefore, fill up the valleys between these papillæ.

These younger cell layers, which have a not inconsiderable thickness between the papillæ, while they are but slightly developed over their apices, present all the characteristics of a stratified epithelial mucous membrane. Collectively, it is called the Malpighian rête mucosum, or rête Malpighii. The layers of old cornified cells make their appearance by an abrupt transition. They bear the name of the epidermis in the strict sense of the word. Its thickness varies considerably; it may exceed a Paris line. The number of layers varies, in consequence, extraordinarily. The latter are the same scales as those on the surface of the mucous membranes, though the cells in contact with the atmospheric air have become dryer and harder. The nucleus, which these cells formerly possessed, has likewise been lost by the old, effete epidermis scale. They measure 0.0285 to 0.0450 mm.; in the mucous epithelium of the mouth, 0.0425 to 0.075 mm.

We will speak of the color of the human skin. If we

cover a red cloth with a piece of milk-glass, we have the flesh color presented to our eyes, and the thicker the piece of glass selected, the lighter the tone will be. It is thus with the complexions of Europeans. The corium during life appears red, in consequence of its extreme richness in blood; the epidermis is semi-transparent, whitish or whitish-yellow. The thinner the latter, the redder the color (lips, cheeks); the thicker the cell covering (the foot-sole, frequently the palm of the hand also), the paler the surface of the body.

In the skin of the dark human races, that of the negro, the nuclei in the deeper layers of the epidermis are diffuse brown; the cell bodies are also somewhat darker, and may also contain pigment molecules. In the darker portions of the bodies of the light races (the nipple and its areola) the same condition prevails. The coloring matter here conceals the red of the cutis.

All stratified epithelia, as we already know from what has preceded, are of a perishable nature. Millions of the superficial cells fall off daily, from rubbing, pressure, etc. The new formation takes place at the deepest layer, by a process of division. Between the latter cell layers, finally, immigrated lymphoid cells may also be met with.

The second form of epithelial tissue, the cylindrical, belongs to the digestive apparatus, from the entrance to the stomach to near the anus, likewise to the ducts of the liver and pancreas, the ducts of the lacteal and lachrymal glands, and also some portions of the sexual apparatus.

We there (Fig. 6, *b*, 14, *a*) meet, as a rule, with a single row of narrow, vertically elongated cells, with a sometimes superficially, sometimes more deeply lying nucleus, which contains a nucleolus. A thin layer of cement substance unites our cells, which, seen from above (Fig. 14, *b*) present a fine mosaic. Their height and breadth vary. In the human small intestine, the former is 0.0182 to 0.027, the latter 0.0057 to 0.009 mm. The lateral walls show an envelope; the free base may present naked protoplasm, as in the stomach; it may, also, however, show a different character. This is the case in the

small intestine (Fig. 14, *a*). There occurs here an already mentioned covering piece, 0.0017 to 0.0025 mm. high, formed of a firmer, very changeable substance, and permeated by very fine canals, the so-called porous canals. We shall have to mention the latter later in alluding to the absorption of the chyme.

That the cylindrical epithelial cells, many of them at least, are destroyed by a mucous metamorphosis of their interior ("Becher cells") we have shown in Fig. 6, *a*. The reparation remains unclear. It is not accurately determined that there is a deeper, younger layer of cells destined to this purpose.

Vibratory or ciliary epithelium (Fig. 29) is formed of modified cylinder cells. The same cell bodies, with similar variations in height and diameter, present themselves. Only the free surface, which has the ciliæ, those most restless protoplasmic filaments (p. 10), causes the peculiarity.

Ciliary epithelium lines the human respiratory apparatus. Commencing at the base of the epiglottis, it covers the larynx, with the exception of the lower vocal cords, which have stratified pavement epithelium; also the trachea and the bronchi, as far as their finest ramifications, but not the respiratory vesicles of the lungs (p. 29). We meet with it, further, in the olfactory organ, with the exception of limited places. The oviducts and uterus of the female, the *vascula efferentia*, the *coni vasculosi*, and the canal of the epididymis, as well as the upper half of the *vas deferens*, have this variety of epithelium. Finally, to pass over its more limited occurrence, the cavernous system of the spinal cord and brain "vibrates" in the embryo and neonatus.

The ciliæ are often of considerable size in the lower animals; in the higher, they become smaller and smaller. They appear exceptionally long, measuring 0.0226 to 0.034 mm., on the large epithelial cells of the canal of the epididymis, and very short, 0.0056 to 0.0038 mm., in the respiratory apparatus. A high degree of perishableness is impressed, as a characteristic sign, upon them all. Whether compensatory cells occur in ciliated epithelium is, perhaps, not yet accurately deter-

mined. They have, at all events, been frequently admitted. Mucous metamorphosis, as in the cylinder cells, is also frequently met with here.

Lymphoid cells may also occur between the cylinder and the ciliated cells; indeed, they may even penetrate to the interior of the cell body (comp. Fig. 16).

Let us here devote a few words to the remarkable ciliary motion.

Discovered in olden times, subsequently, especially of late days, frequently investigated, it has not yet been satisfactorily explained. Its occurrence in the animal kingdom is quite variable. Sometimes this part vibrates, at others that, sometimes nearly all the surfaces; at others, as in the arthropoda, not at all. What purpose does this work of the ciliæ serve?

If we fold a suitable detached piece of mucous membrane and examine the edge of the fold, we have the appearance of an undulating border, of a flickering candle-flame. If we look from above downwards on to it, it suggests the comparison to a field of grain agitated by the wind.

Small bodies suspended in the fluid medium, color granules, blood cells, sweep past the folded border, when we examine with a high magnifying power. When we use very weak lenses, the excursion proceeds more slowly; a cell will require several minutes to make its course.

When the ciliary motion is still in full vital energy, and several vibrations then take place in a second, the human eye is powerless. It is only when the action becomes retarded that we perceive the separate motions—the regular, synchronous, and homogeneous vibrations of the ciliæ. Attempts have been made to distinguish several varieties of these vibrations; as for example, a hook-like and an oscillatory.

We pass over this; but we must here mention an apparently strange condition. In the ciliary movement, we see the ciliæ vibrate towards one side, and the small passing bodies take the opposite direction!

The matter is readily explained. We first recognize the slower, less energetic direction of the vibration; the other, more rapid and powerful, we do not yet perceive. In which direction, however, will the current be driven? Manifestly, in the latter. Engelmann explains the more sluggish movement as a vital act of the protoplasm; the more rapid, as the effect of elasticity. We agree with him.

Later, as death approaches, both movements become distinct. The current finally ceases, only a to and fro fluctuation still remains.

The ciliary movement has nothing to do with the blood current, or with nerve life. It perishes rapidly in warm-blooded animals, often very slowly in the lower cold-blooded creatures. An elevation of the temperature to 44° and 45° C. kills them, likewise increasing cold. Everything which exerts a chemical influence likewise produces a destructive effect, occasionally with a temporary increase of the vibration—water, for example. It is an interesting observation, that dilute solutions of potash and soda may temporarily excite the paralyzed vibratory phenomenon to renewed energy (Virchow).

The true epithelium—that is, so far as it originates in the corneous and intestinal gland layers—is developed very early. Even in the human embryo of five weeks, according to Koelliker, the surface of the body is covered by a double layer of cells, a deeper one consisting of smaller rounded structures, and an upper one of larger, flatter, indented bodies. The former represents the primary rudiments of the *rête Malpighii*, the latter, the horny layer.

Closely related to the epidermis, and arising from it in the third month of fetal life, are the human nails. These obtuse quadrangular plates are arched outwards, and lie posteriorly, with the so-called nail roots, embraced within a deep furrow of the skin. At the sides, the furrow becomes from behind forwards more and more shallow. The anterior border of the nail remains free. The portion of the cutis covered by the nail bears the name of the nail-bed. The latter shows longitudinal rows of cutaneous papillæ.

sac shows externally (Fig. 39, *a*; 40, *i*) longitudinally, then transversely arranged connective tissue (40, *h*), and, finally, internally (39, *b*; 40, *g*), a hyaline boundary layer. At the bottom it juts forward as a vascular papilla (Fig. 39, *i*). It is the formative and nutritive organ of the whole.

On the hair itself we distinguish the hair-bulb (Fig. 39, *h*), resting on the papilla and the shaft (*l*). Only a slight portion

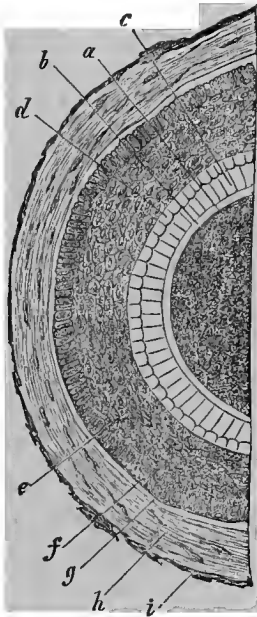


FIG. 40. — Transverse section through a human hair and its follicle; *a*, hair; *b*, epidermis of the same; *c*, inner, and *d*, outer layer of the inner root-sheath; *e*, outer root-sheath; *f*, its peripheral layer of elongated cells; *g*, hyaline membrane of the hair sac; *h*, its middle, and *i*, external layer.

of the latter is surrounded by the sac; the larger, often very long, remaining portion, projects freely from the skin, as, for instance, the hair on women's heads. As the corium is involuted, so also does the epidermis with its two layers, the *rête* Malpighii and the horny layer, dip down into the sac. These depressions are very appropriately named root-sheaths; and the insinuated *rête* Malpighii is distinguished as the external root-sheath (Fig. 39, *c*, 40, *e*), the horny layer of the sac as the internal (Fig. 39, *d*). The former requires no further description, it presents nothing special; but the latter acquires a modified structure. It consists of two layers of hyaline cells, an external layer of vertically arranged non-nucleated elements, of 0.0377 to 0.0451 mm. (Fig. 40, *d*), between which longitudinal clefts may be perceived, and an inner layer of radially arranged cells with nuclei (*c*). Downwards, in the depth of the sac, the external root-sheath becomes single.

The substance of the hair bulb (Fig. 39, *h*) shows the same cells as the external root-sheath, with colorless or pigmented molecules. Upwards the appearance changes; it then comes, or at least very frequently, to a differentiation into

cortex (*k*), and medulla (*l*). In the former we see the cells becoming longer and flatter, until finally they are quite dry, irregular, elongated cortical plates of 0.0751 mm., and frequently non-nucleated, in close union, forming the outer portion of the hair shaft. A diffuse coloring matter, light in blondes, deeper in dark-haired individuals, permeates the whole. Pigment granules and the finest air vesicles may appear in the spores and clefts

The medullary substance does not, by any means, occur in every hair, since in all lanugo hairs and also in many of those of the head it may be entirely or partially wanting. At first (Fig. 39, *k*), the cells of the hair bulb are perceived to be transformed into larger polyhedral elements of 0.0151 to 0.0226 mm. Further above follows the drying and shrinking of the elements, which have in the mean time become non-nucleated. Very small air vesicles enter the innumerable small spaces. A white hair thus receives its appearance, while in colored hairs the serrated substance glistens through the coloring of the cortex, as if tinged.

We have still one structure remaining, the epidermis or cuticle of the hair (Fig 39, *f*, 40, *b*). A double layer of hyaline obliquely standing cells covers the hair, as long as it is surrounded by the sac. With the latter terminates the outer cell layer, but not so the inner one. This covers the free hair, as a system of quite obliquely arranged, flat, non-nucleated lamellæ, covering each other in a tile-like manner, like a scaly coat of mail. Not unfrequently, after-pressure and maltreatment, the lamellæ present the appearance of regular transverse fibres (Fig 39, *f**).

Hairs are found over nearly the whole body, as so-called lanugo hairs, and in limited places as thicker, coarse hairs

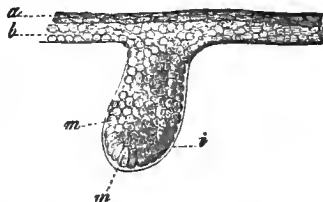


FIG. 41.—Rudiments of the hair of a human embryo of 16 weeks: *a*, *b*, epidermal layer; *m*, *m*, cells of the rudiments of the hair; *i*, structureless membrane covering them.

Its smooth or frizzled condition depends on the cross section. In the former hair it is round, in the latter oval or reniform. The growth of the hair takes place by a cell increase from the lower portion of the hair bulb. So long as the sac with its papilla remains uninjured, it regenerates the lost hairs; that is, such as are stunted in their hair bulbs and are separated from the papillæ. This power of reproduction is tolerably energetic, for the physiological loss of hair is not inconsiderable.

The origin of the embryonic hair commences at the end of the third or the beginning of the fourth month (Fig. 41). The epidermis forms with its deeper cells (*b*) a knobby downward growth. A structureless boundary layer, furnished by the impressed corium (*i*), leads to the formation of the hair sac. From the cell aggregations (*m, m*), are developed both the root-sheaths and the entire true hair with its cuticula. The hairs, like the nails, are, therefore, secondary epidermoidal structures.

FOURTH LECTURE.

THE CONNECTIVE-SUBSTANCE GROUP.—CARTILAGE, GELATINOUS TISSUE, RETICULAR CONNECTIVE TISSUE, FAT.

CONNECTIVE TISSUE, fat tissue, cartilage, bone, dentine, are well known constituents of the body. Their finer structure proved extremely heterogeneous at the commencement period of modern microscopy. It was in the year 1845 that Reichert recognized all these things as members of a natural unity. Science is indebted to him for the exposition of a "connective-substance group." Here Virchow accomplished further progress in the domain of pathology; and, indeed, also committed errors. Much labor has subsequently been bestowed upon this group; we have made further progress, but are still far enough removed from a conclusion.

All these tissues mentioned—and to these are to be added, as new acquisitions, gelatinous tissue and the reticular connective substance—arise from the middle germinal layer (p. 26). They are originally similar, but then, pressing on towards maturity, they assume quite variable forms. Connecting intermediate forms, however, remain. No one can, for example, draw a sharp boundary between gelatinous and ordinary connective tissue, or between the latter and cartilage. We meet in places, therefore, with a continuous transition of one connective substance form into another. Truly different tissues never do this. We meet, furthermore, in the animal kingdom, very frequently a substitution of one tissue of our group by another. That, for example, which in one creature is connective tissue is in another gelatinous tissue, or even bone. A temporary substitution also occurs. The parts of our skeleton were, for the most part, formerly cartilage. In morbid growths we meet with extraordinary frequency with such substitutions of the one for the other.

The connective-substance group, occurring throughout, forms a large part of our body, the general frame-work, in which the other tissues are embedded. They have rightly been called the scaffold and supporting substance of the body.

Let us now examine their individual varieties.

Cartilage tissue makes its appearance very early in the construction of the body, though frequently to disappear after a short duration of life. Most cartilage, accordingly, does not become old. Even at the hour of birth a considerable portion of the cartilage has fallen a sacrifice to a new secondary tissue, the osteoid or bone tissue. A portion of the cartilage lasts, however, till the death of the person, and may thus reach a great age.

The texture is distinguished, according to several varieties of the mature tissue, into : *a*, the hyaline ; *b*, the elastic ; *c*, a rather uncertain variety, the connective-tissue cartilage, an intermediate thing between cartilage and connective tissue.

In its first embryonic appearance, the progressing cartilage presents small spherical protoplasmic formative cells with vesicular nuclei and rather scanty homogeneous intermediate substance. The latter is still soft, and consists of albuminous matter. Soon, however, the cells increase in size ; the intermediate substance is augmented, and becomes more firm (Fig.

23). A chemical change also takes place gradually ; it becomes a gelatinous tissue ; on boiling, it yields chondrine.

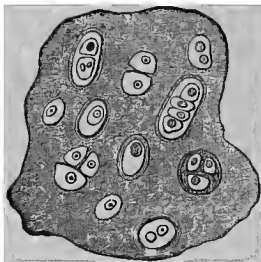


FIG. 42.—Diagram of a perfectly mature hyaline cartilage, with quite a variety of cells.

When the intercellular substance retains its original homogeneous character, it forms hyaline cartilage. Thin sections appear transparent like glass. The cells (Fig. 42) have also, in the mean time, assumed quite a variation in their appearance.

They appear larger, round, oval, wedge-shaped. A portion of them show capsules, and not

unfrequently the latter envelop so-called daughter cells (comp. Fig. 19).

How have these capsules and the intermediate substance been formed? Concerning this there has been much discussion. Nowadays we must say that both are cell products, are substances yielded by the cell, and were formerly a part of the cell body itself. In the ensiform process of the sternum of the rabbit, it is easy to recognize, without reagents, that the intercellular substance is formed only of the cemented capsules of the cartilage cells (Remak). By the aid of macerating media this can also, with greater difficulty, it is true, be demonstrated in other mammalian and human cartilage (Fig. 43). Here, also, the apparently homogeneous intermediate substance becomes divided into a system of concentric capsule layers, which embrace within them the cell or the cell group. The individual capsular systems are cemented to each other and likewise the external capsules of adjoining cells. From the similarity of the power of refraction is caused the phantasm of homogeneity; the cartilage cell lies in a chasm. When the innermost, last-formed capsule has preserved an additional, peculiar exponent of refraction, we perceive this (Figs. 42, 44) as something different from the remaining intermediate substance.

This division of the cells within their cavities, or, which amounts to the same, within their capsules, gains consider-

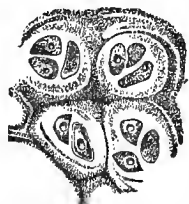

FIG. 43.—Thyroid cartilage of the hog. The basis substance is divided into cell-districts.

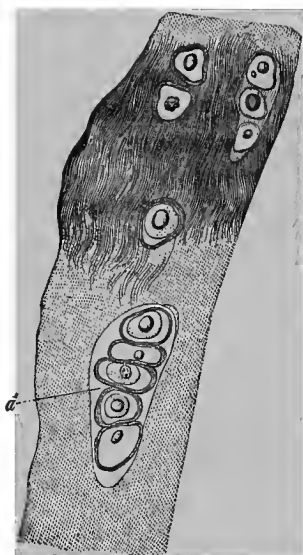


FIG. 44.—From the costal cartilage of an old man.

able dimensions in many mature cartilages (Fig. 44, *a*), so that we may meet with enormous capsules of 0.1 to 0.2 mm. with whole troops of contained cells. Not unfrequently, however, this exuberant increase foretells the approaching disappearance of the tissue.

Depositions of fat in the cell body, especially in the vicinity of the nucleus, then form very common transformations. They may begin very early. Later, the nucleus frequently becomes invested by a coherent spherical shell of fat (Fig. 44).

A subsequent metamorphosis of the apparently homogeneous intercellular substance into firm, delicate fibrillæ, which resist acetic acid, is frequently observed; this is especially constant in the interior of old costal cartilage (Fig. 44).

Calcification is, finally, a quite frequent occurrence in cartilage undergoing retrogression. Dark granules or crumbs

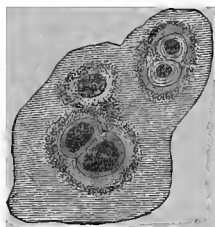


FIG. 45.—Commencing calcification of hyaline cartilage.

of lime salts surround the cells or cell groups, at first in an areolated manner. They increase in quantity; the whole intermediate substance acquires a dark, granular appearance; the capsules also become implicated in the deposition, and finally all is black and opaque; only the cells glisten through as bright gaps. The older investigators could not master this. Now-

adays we readily succeed by the aid of decalcification with chromic or lactic acids.

This calcified cartilage is, however, far from being or from becoming bone. We shall hereafter return to this subject.

Hyaline cartilage substance constituted originally almost our entire skeleton, with the exception of the portions forming the vault of the cranium and the bones of the face. This is the transitory cartilage. Remains of the same form the articular and costal cartilages and others. Other masses of cartilage have nothing to do with the skeleton. To these belong the larger cartilages of the larynx, and the cartilage

of the trachea and bronchia. The cartilage of the nose also appears to be hyaline.

The young, healthy, hyaline cartilage, but not that which is growing old, is without vessels.

An interstitial growth is evident ; the increasing size of the cartilage cells, the expansion of the capsules, and the increase of the intermediate substance remove every doubt. Is there, besides, an increase of substance by apposition? This is not known. The nutrition takes place either from the blood-vessels of a connective-tissue covering, the perichondrium, or, when the cartilage envelopes the bone, from the adjacent vessels of the latter.

Elastic or reticular cartilages arise from a supplementary metamorphosis, which commences during the embryonic period. Their number is not large. Among these are the epiglottis, the Santorinian and Wrisbergian cartilages of the larynx, the Eustachian tube, and the cartilage of the ear. The arytenoid cartilages of the larynx and the symphyses of the vertebræ present the same peculiarity only partially.

In reticular cartilage (Fig. 24) we generally meet with more abundant cartilage cells, surrounded by a homogeneous area, and the remaining intermediate substance permeated by a close net-work of fine elastic fibres. Considerable variations occur, however, in the different varieties of animals (Hertwig).

By connective-tissue cartilage is denoted a substance which presents small cartilage cells, surrounded by bundles of a connective tissue which becomes homogeneous in acetic acid. This variety is met with, for example, in the cartilaginous lips of the joints, and locally in the vertebral symphyses ; other parts of the latter present hyaline cartilage ; still others, only ordinary connective tissue. In the so-called cartilages of the eyelids only connective tissue can be recognized.

We pass to the gelatinous tissue and reticular connective tissue.

Cartilage presented the quality of solidity ; gelatinous tissue shows the character of softness in the highest degree. Its most simple variety, the vitreous of the eye, is the richest

in water of all the tissues of the body; it contains only 1.5 per cent. of solid constituents, of which a part must still be referred to a delicate pellicle surrounding and permeating the whole. And yet the origin of the cartilage and corpus vitreum are similar. We again meet with rounded, indifferent cells with a homogeneous, intercellular substance. In cartilage (Fig. 23) the latter early solidifies; in the vitreous it becomes watery and swells up, so that in a human embryo

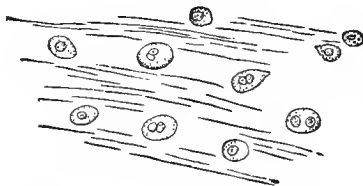


FIG. 46.—Tissue of the vitreous body of a human embryo.

of four months (Fig. 46) the protoplasmic cells, measuring 0.0104 to 0.0182 mm., are separated by considerable intermediate gelatinous tissue. The latter gives the reaction of mucous substance or mucin, that substance with which we have

already become acquainted (p. 36), as a product of the metamorphosis of the epithelial cells. For this reason our tissue has already been given the name of mucous tissue.

In the vitreous of the mammalia after birth, the formative cells become arrested, and, widely separated by the intervening gelatinous tissue, are only with difficulty recognized.

A higher development of the gelatinous tissue is constituted by the so-called enamel organ of the progressing tooth. The teeth, as is known, are formed and concealed in the jaws; the crown is first formed and the root last. The former is covered, at its commencement period, by a cap or bell-shaped structure, from the concave under surface of which the formation of the enamel takes place. Hence the name.

Here (Fig. 22) we meet with a net-work of delicate, nucleated stellate cells with a varying number of processes. Something like a cell division (*b*) is occasionally seen. The meshes are filled with a homogeneous gelatinous tissue containing mucus.

The same condition prevails, at an early period, in the Whartonian jelly of the umbilical cord. Later, we meet, in

addition, with connective-tissue bundles which lie externally to the now flattened cells. The system of spaces is again filled with gelatinous substance.

This is a tissue, therefore, which early disappears.

Under reticular connective tissue (Fig. 47) we understand a cellular tissue, in the meshes of which lie innumerable lymphoid cells. His has called this adenoid tissue. It appears to be frequently a secondary formation, proceeding from metamorphosed common connective tissue of the fœtal body.

Reticular connective tissue presents, in addition, many changes, according to age and locality. As its element (Fig. 8), we meet with a delicate, stellate cell with a nucleus of 0.0059 to 0.0075 mm. and a moderate-sized protoplasmic body. The latter sends out numerous processes, which repeatedly divide and thereby become constantly finer. By the conjunction of such adjacent branches, which have often arisen under a right angle, smaller nodal points are frequently formed, in which a nucleus is naturally wanting.

The delicate, mostly polyhedral meshes are usually rounded, but may also assume an elongated form. They are smaller in the new-born than in the adult. In the latter, during the period of health, the nucleus and cell body are usually shrunken, so that they may be overlooked. In irritated conditions, however, the former tense condition is rapidly re-established in the swelling tissue.

Such reticular connective tissue is met with in the lymph glands, as well as in a series of allied parts of the body, which we will combine as lymphoid organs, such as the tonsils, thymus gland, and Peyer's follicles. The Malpighian cor-

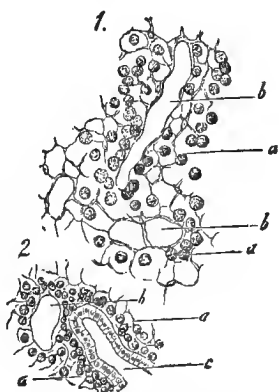


FIG. 47.—From a lymphoid follicle of the vermiform appendix of the rabbit. Fig. 1, reticular tissue with the meshes, *b*, and the remainder of the lymph cells, *a*; most of the latter have been artificially removed. Fig. 2, more superficial.

puscles of the spleen also belong here. The tissue of the spleen pulp is still more strongly modified.

The mucous membrane of the small intestine also contains our tissue; although the number of lymphoid cells is here much less, and the cell processes not unfrequently appear broader, lamelliform. In the large intestine, finally, something intermediate between our tissue formation and ordinary connective tissue is met with.

We now turn to the adipose tissue.

True connective tissue, to the consideration of which we shall soon arrive, appears partly as a firm, partly as a loose texture. In the latter case, as under the corium, under mucous and serous membranes, etc., it encloses irregular communicating spaces. These are frequently occupied by groups of peculiar cells, overladen with fat. This is fat tissue (Fig. 48, *a*).

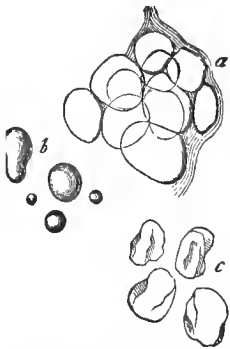


FIG. 48.—*a*, human fat cells, lying together in groups; *b*, free globules of fat; *c*, empty envelopes.

The cells appear large, measuring 0.076 to 0.13 mm., with nuclei of 0.076 to 0.009 mm. A thin covering closely envelops a single large drop of fat. The latter, from its strong refractive power, conceals the nucleus and the outlines of the envelope.

An appearance is thus caused as if there were free drops of fat, with a dark periphery by transmitted light, yellowish, silvery and bright by incident illumination. Still, the always considerable diameter, a slight polyhedral flattening of the elements which are closely pressed together, avert the mistake. Free fat forms spherical drops of every possible size (*b*).

The envelope, after its rupture and the escape of the contents, may be demonstrated as a thin, collapsed sac (*c*), likewise in an intact condition, after drawing out the fatty contents with alcohol or ether. The nucleus, lying quite excentrically, is readily recognized after tingeing with carmine.

The fat of the human body is a mixture of an oleaginous substance, triolein, which contains in solution certain quantities of more solid matter, tripalmitin and tristearin. When the latter increase, there are, on the cooling of the body at first, depositions of tuberculated forms, and finally of crystalline. We now perceive irregular needles, at one time tuft-shaped and stellate, radiating from a central point, again in crowded aggregations filling the whole cell. On warming they again disappear.

Adipose tissue takes a very active part in the material changes of the body; it is likewise a very vascular substance.

As a result of prolonged starvation, in exhausting diseases, a portion of the fatty contents disappear from the cell

(Fig. 49). The fat drop (*d*) is at first but slightly removed from the membrane.

A spherical cortex of gelatinous, finely granular substance (protoplasma?), surrounds the former; the nucleus now becomes visible.

The progressing deprivation

of fat is shown by the cells *a* to *f* and *h*. Finally (*g*), only a few fat globules remain; the entire cavity is now occupied by the gelatinous matter. Such examples have been designated, not especially happily, as fat cells "containing serum."

If the body outlasts this condition of emaciation, and subsequently, by a more abundant nourishment, resumes the old full appearance, the cells have again become filled with the fatty contents.

The massiveness of the adipose tissue varies considerably. It is greater in children and women than in men; more considerable in the blooming period of life than in senility. Here, above all, individuality asserts itself very powerfully. In high degrees of obesity, fat cells frequently occur in places where they do not belong, as, for example, between the muscular fibres. In far advanced emaciation, the panniculus adi-

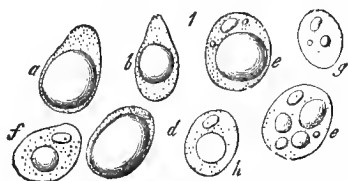


FIG. 49.—Impoverished fat cells from the subcutaneous cellular tissue of a human cadaver.

posus disappears; though certain parts, like the orbital cavity and the medulla of the central portion of the hollow bones, still obstinately retain the fatty contents within their cells.



FIG. 50. — Transformation of the connective tissue corpuscles into fat cells, from a human muscle, serving at the same time as a diagram of the embryonic origin.

Adipose tissue is of a secondary nature. It is entirely wanting in the earlier embryonic life. The fat cell arises from a metamorphosis of the cells of the connective tissue. The ordinary flat, lapped and pointed elements of the latter (Fig. 50, *a*) take up fat drops in increasing quantity (*b*); these flow together, the cell becomes rounder, losing its processes (*c*), and finally assumes the well-known appearance (*d*). There is also another coarsely granular connective-tissue cell, to which more attention has only recently been called, and which may possibly

be transformed into a fat cell. We regard the so-called cell membrane as a boundary layer formed from the adjacent connective tissue.

FIFTH LECTURE.

CONNECTIVE TISSUE.

TRUE connective tissue, the "cellular tissue" of the older anatomists, is very extensively diffused throughout the body. As a member of the whole tissue group, it also consists of cells and intercellular substance. The latter, on boiling, does not yield the chondrin of cartilage (p. 42), however, but ordinary glue or glutin. The intercellular substance here shows a further metamorphosis in a double direction; firstly, into the so-called connective tissue bundles and fibrillæ; and secondly, into the multiform elastic elements. The latter form fibres, reticular fibres, perforated membranes, limiting layers around connective-tissue bundles, and also around spaces which contain cells.

The longest known is the gelatine yielding fibrilla, the constituent which immediately attracts the eye. It appears in the form of a very fine, hyaline, unbranched filament, 0.0007 mm. in diameter, often very extensible, and at the same time possessing elasticity (Fig. 51, to the left).

These very readily isolatable fibrillæ very commonly unite into sometimes thinner, sometimes thicker bundles (in the figure to the right). Their elasticity very frequently produces an undulated or curly

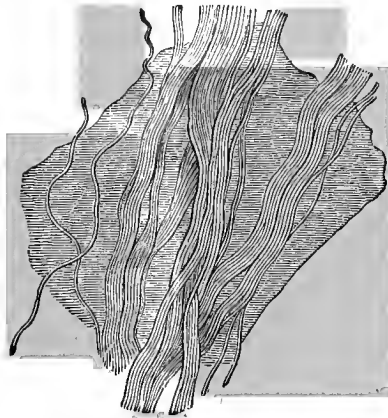

FIG. 51.—Connective-tissue bundles.

appearance in separated portions of the tissue. The interweaving of the fibres varies considerably. When loosely interwoven, the bundles running in one plane are united by homogeneous, membranous intermediate substance.

Acetic acid, an important reagent, causes the bundles to swell up rapidly and the fibrous appearance to disappear. By washing out, or neutralizing that reagent, the former appearance is restored.

Previously, the excess of connective-tissue fibrilla very frequently concealed the intermingled elastic elements. Now, in the acid preparation, the latter make their appearance

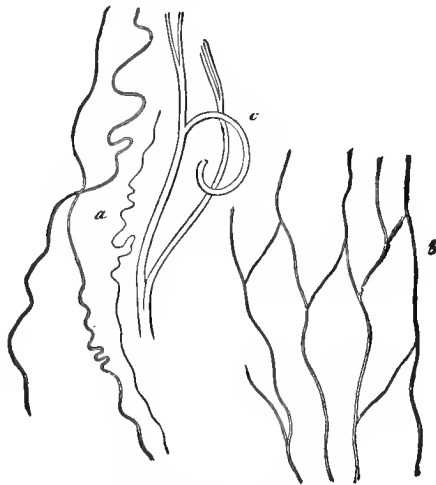


FIG. 52.—Human elastic fibres.

(Fig. 52). We perceive, firstly, the finest, frequently corrugated fibrillæ without ramifications (*a*). They remind one of the connective-tissue fibrillæ; but the darker appearance, and the power of resisting acetic acid, permit of no mistake. Other elastic fibres are larger.

Very frequently there are ramifications, and by the communication of the branches an elastic net-work is formed. We perceive such an one at *b*, with large meshes, and fibres which measure only 0.0014 to 0.0025 mm. in thickness.

If we search further, we meet with transitions to broader and thicker ramified fibres (*c*), which, in contradistinction to the extensible finer ones, gradually assume a considerable inflexibility and brittleness. Their diameter may increase to 0.0056 to 0.0065 mm.

In other places, the walls of the larger arteries, we find coherent elastic membranes, in which fine fibrillæ and reticular fibres are embedded as ledge-like thickenings. There also occur homogeneous layers of elastic substances which are perforated with little holes (Fig. 53, 1). Between these and a small-meshed reticulum of very broad, flat elastic fibres (2) it is, indeed, often impossible to make a demarcation.

These changing elastic elements are met with in still another condition. They form a structureless sheath around many connective-tissue bundles. As surely as an innumerable quantity of these bundles are without envelopes, and exhibit only a fibrillated cord, even so little can the presence of a sheath around others be doubted; as on those which pass from the arachnoid, at the base of the brain, to the larger blood-vessels, on the fasciculi of the tendons, on

much of the subcutaneous cellular tissue. If we apply reagents which produce considerable swelling, as acetic acid, a strange appearance is caused (Fig. 54). The sheath is torn into transverse portions, and these rapidly contract between the protruding portions of the connective-tissue bundle to

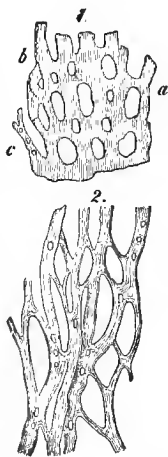


FIG. 53.—Elastic network from the aorta; 1, of the ox; 2, of the horse.

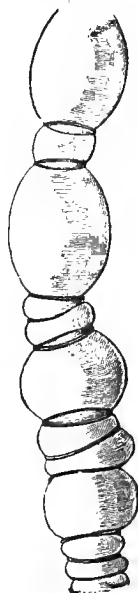


FIG. 54.—A connective-tissue bundle, from the base of the human brain, treated with acetic acid.

very delicate rings, which have a striking resemblance to an elastic fibre. Cotton fibres undergo a very similar change on the addition of ammoniac copper; only, everything is here more massive and easier to observe.

The most difficult part in the investigation of the connective tissue is formed by the cellular elements, the connective-tissue corpuscles of an earlier period. After manifold strayings, a greater light has only of late years been disseminated. Since the cells were, as a rule, usually concealed by the substance of the fasciculi, acetic acid was formerly generally used for the recognition of the former. This, and even water, immediately distorts the cells into caricatures. The latter have been almost universally known and described for tens of years; and capital has been made of them!

The cellular elements are distinguished into non-essential migratory, and essential fixed. The former are lymphoid cells, which, having escaped from the blood and lymphatic vessels, slowly wander through the channels of our tissue.

The ordinary fixed connective-tissue cell appears as a simple or complicated lamellar structure. An oval nucleus is surrounded by some protoplasm. The thin structure becomes extremely pale and veil-like at the periphery, and runs out into points or fibrillæ.

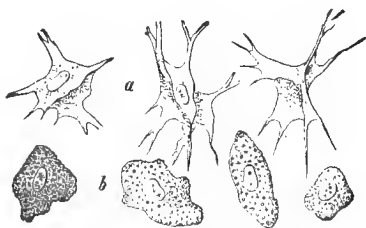


FIG. 55.—Cells of human connective tissue; *a*, flat and shovel-shaped elements; *b*, coarse granular cells.

Very frequently, however, there is also a varying number of lateral plates resting at different angles over the middle of these chief plates (Fig. 55, *a*), so that a certain resemblance to an irregular, crumpled shovel edge is produced (Ranvier, Waldeyer). Such cells lie in the firm connective tissue, in the spaces

between the fasciculi, and have, according to our views, assumed the described forms subsequent to the growth in thickness of those fasciculi. The procedure may be illustrated by

placing a lump of warm, soft wax between the points of three fingers and pressing them together.

There is still another cell formation met with in connective-tissue structures; they are often very rare; in places, however, quite numerous. They are larger, coarse granular structures, with a nucleus and an either rounded or spindle-shaped body, without that system of lamellæ and processes of the previous form (*b*). They have been met with in the vicinity of vessels, especially arteries, and have received the name of plasma cells (Waldeyer).

Fat cells may proceed from both varieties of cells, the flat and the coarse granular (p. 49).

Connective-tissue cells also assume an extremely peculiar appearance from receiving melanine granules into their body (Fig. 9). This is the "stellate pigment cell" of the earlier histologists. The coal or brown-black molecules are smaller than in the pigmented epithelium (p. 30). In man such cells are limited almost exclusively to the eye. In the lower vertebrates, such as many of the amphibia, this process of pigment embedding is enormously diffused, so that in every little piece of connective tissue the strangest cells are met with, occurring in every possible stellate form.

The flat connective-tissue cells and their colored associates (Fig. 56), show a slow, but unmistakable vital contractile power. This is not yet recognized in the plasma cell.

Connective tissue, whose immense diffusion in the human body we have already mentioned, by the arrangement and interlacing of its bundles, by its very dissimilar proportion of elastic elements, the extremely variable vascularity, and, finally, by the commingling of insoluble elements, forms substances which appear to the naked

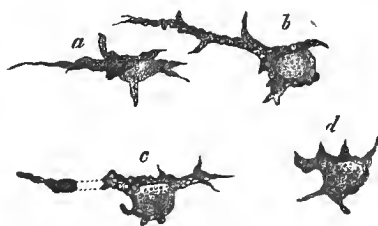


FIG. 56.—Gradual change of form of a pigmented connective-tissue corpuscle from a water newt, during 45 minutes.

eye as quite dissimilar things, and which in reality are very nearly related.

The usual system of anatomy recognizes primary bundles, that is, simple fibrous cords. A portion of these, held together by loose connective tissue, constitute secondary bundles, and from these latter tertiary are formed.

We have, firstly, as a badly selected name runs, "formless" connective tissue. Soft and extensible, it forms the general filling up substance of the organism. Membraniform connective-tissue bundles with homogeneous interstitial substance (Fig. 51), form thin lamellæ, which superimposed on each other at various angles, incompletely limit cavities. These are the so-called "cells" of the older anatomists, who gave our tissue the name of cellular tissue. The lamellæ are often nearly in contact with each other, but the space enclosed by them may also be completely filled by collections of fat cells. Where structureless connective tissue occurs in greater quantity it has received special names. Thus, one speaks of subcutaneous, submucous and subserous connective tissue. Elastic elements are here met with, sometimes scanty, sometimes more profuse, but never in excess.

We now come to the *formed* connective tissue, with its numerous varieties. This constantly arises from the formless variety without any sharp demarcation, so that this division of the anatomists is entirely artificial.

We enumerate here: 1. The *corneal* tissue. The cornea has on its anterior surface stratified pavement epithelium, on its posterior a simple cell covering. Under both epithelial coverings there is a hyaline layer. The anterior is called the lamina elastica anterior, the posterior the Descemet's or Demours' membrane. The hyaline corneal tissue consists of a net-work of decussating bundles, which may be divided into fibrillæ of extreme delicacy. The whole is permeated by a system of passages which have a sort of parietal layer. In these lie the "corneal capsules," which are flattened cells, comparable to a paddle-wheel. Wandering lymphoid cells are also not wanting.

2. *Tendinous* tissue. Longitudinal bundles of a fibrillary connective tissue with an elastic boundary layer arranged in a compact manner are met with. Between them one recognizes in transverse sections a system of indented and stellate spaces. In these lie, arching over the connective-tissue bundles, ordinary lamelliform and shovel-shaped connective-tissue cells, and also isolated lymphoid corpuscles. Only scanty, fine, elastic fibres occur in this extremely bloodless tissue.

3. The *ligaments* are, with the exception of the elastic, formed like the tendons.

4. The connective-tissue cartilage (see p. 45).

5. The so-called *fibrous membranes*. Firmly woven, non-vascular structures with a varying intermixture of elastic elements. Among these are the dura mater of the brain and spinal cord, the sclerotic of the eye; the firm envelopes of many organs, for example, of the kidneys, testicles, and spleen; furthermore, the fasciæ of the muscles, the coverings of the nerve trunks (the perineurium or neurilemma), the covering of the cartilage and bone (the perichondrium and periosteum). The latter is permeated by numerous blood-vessels, but which serve principally for the nutrition of the invested bone.

6. The *serous membranes*, which formerly were erroneously considered as entirely closed sacs, consist of a but slightly vascular net-work of connective-tissue bundles, occasionally with a considerable contingent of elastic-reticular fibres. The free surface is covered by endothelium. To this variety belong the pleura, pericardium, peritoneum and tunica vaginalis propria of the testicle. As more incomplete structures, we mention the arachnoid membrane of the brain and spinal cord, the synovial capsules (having a serous membrane only at the sides, and here covered by a simple layer of epithelial cells), and also the mucous pouches and the sheaths of the tendons. The serous cavities, like the passages between the connective-tissue bundles, must be regarded as belonging to the lymphatic apparatus, as we shall perceive hereafter.

7. The *corium*. More firmly interwoven, decussating connective-tissue bundles with numerous elastic fibres. The closely interwoven, very vascular tissue projects towards the surface in small papillæ of varying shape, in the form of the tactile bodies. It is continuous below, without any sharp demarcation, with the subcutaneous cellular tissue. Other foreign constituents consist of hairs, involuntary muscles, glands, nerves. As a covering, we are already familiar with the epidermis, the thickest pavement epithelium of the body (p. 32).

8. The *mucous membranes*. Also extremely vascular, but less compactly arranged, and with fewer elastic elements. In places it is enormously rich in glands. Smooth muscles form a widely diffused constituent. The surface frequently projects in papillæ. The ordinary connective tissue of the mucous membranes may, however, be replaced by reticular connective tissue (p. 47). We already know that the epithelial covering differs exceedingly (pp. 30, 33, and 34).

9. The *vascular membranes of the central nervous organs and of the eye*; that is, the pia mater, choroidal plexus and choroid. A thin, soft connective tissue, in the choroid a reticulum of pigmented cells, here shows throughout an enormous wealth of blood-vessels.

10. In the structure of the *vascular walls* connective tissue plays an important rôle. Nevertheless, the elastic element often increases to such an extent, that the connective-tissue bundles and cells recede. One speaks then of "elastic" tissue.

11. This predominance of the elastic elements is also presented by the ligaments and membranes of the respiratory organs, and likewise by the tissue of the lungs. The same is also seen in the outer layer of the œsophagus, the yellow ligaments of the vertebral column, and the ligamentum nuchæ of mammalian animals. Many of the latter structures have lost all connective-tissue bundles.

Connective tissue possesses but slight vital dignity; it comes into consideration in the structure of the organism, in

consequence of its physical properties. Only the more vascular connective-tissue structures take a more active part in the normal material changes.

During abnormal conditions, however, our tissue assumes a new and more vigorous life. From the cells other tissue elements may be formed. To determine the magnitude of this participation more accurate studies are indeed necessary, for the wandering lymphoid cells also play their part, and, in our opinion, in a very important manner.

We also mention the origin of the connective tissue. The terminations are again similar to those of cartilage. Membraneless protoplasmatic stellate and spindle cells are noticed at an early period, held together by a scanty intercellular substance, which is at first homogeneous. A transformation soon takes place in the latter and in the cells, the processes of the latter dividing into groups of fine connective-tissue fibrillæ (Fig. 25, *b*). These bundles of fibrillæ gradually approach the cell nucleus. The original cell protoplasm also becomes changed into bundles of fibrillæ; new protoplasm, taking the place of the old, surrounds the nucleus, to subsequently pass through the same process of metamorphosis (Fig. 57, *A*), till at last the cells lie outside of their children, that is, the bundles formed from them, in the shape of lamellæ, with notched margins, or irregular, paddle-wheel-like structures (see above).

In this intercellular substance, the genesis of which we now understand, the formation of elastic fibres and reticular fibres also takes place subsequently (*B*). How far the cellular elements participate in this requires still more accurate investigation.

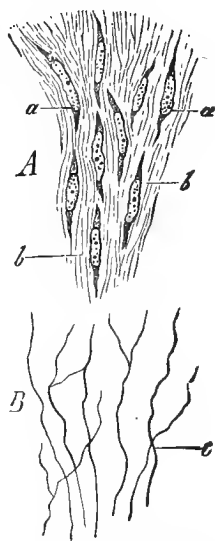


Fig. 57.—From the ligamentum nuchæ of a hog's embryo. *A*, side view; *a*, spindle cells in a fibrous basis substance, *b*; *B*, the elastic fibres *c*, brought out by boiling in a solution of potash (alcohol preparation).

SIXTH LECTURE.

BONE TISSUE.

WE now turn to the most complicated variety of connective substance : we refer to the osteoid or bone tissue.

It is distinguished for its considerable hardness and firmness. In man, this member of our tissue group is, with the exception of a covering to the tooth root, limited exclusively to the bones.

The anatomists divide the latter into long or cylindrical, broad or flat, and, finally, short or irregular bones.

Let us begin with the middle portion or diaphysis of the former, taking a radial longitudinal section sawn out from the dry femur (Fig. 58).

A very peculiar appearance is presented. The thin lamella is permeated by a system of longitudinal canals, connected, in a reticular manner, with a medium width of 0.1128 to 0.0149 mm. (*a*). The transverse branches open out onto the surface of the bone, as well as inwards into the medullary canals, and receive the nutrient vessels from both sides. They bear the name of the medullary or Haversian canaliculi.

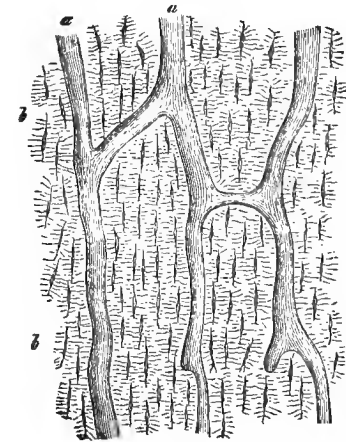


FIG. 58.—Vertical section through the human femur ; *a*, medullary canals ; *b*, bone corpuscles.

Transverse sections (Fig. 59) naturally present an entirely different appearance. The rounded and oblique spaces (*c*)

are transversely or obliquely opened longitudinal canals. Communicating horizontal canals are now also seen opened in a longitudinal direction or obliquely.

The bone substance presents, as is shown by the transverse section, a lamellated structure.

There is a double system of layers, however. Firstly, we meet with plates which pass through the entire thickness of the bone, in contact externally with the periosteum and internally limiting the great medullary canals. They are called general or fundamental lamellæ (α , α'). Another uncommonly abundant

system of lamellæ surround the individual medullary canals with a varying number of layers. These are the special or Haversian lamellæ (around c). The thickness of both varieties of lamellæ varies from 0.0065 to 0.0156 mm., and the arrangement is often far removed from making any claim to regularity. This stratification may also be recognized in longitudinal sections as a system of lines, though with less distinctness.

A plate of dry bone, let it be taken from where we will, always presents a further extremely peculiar structural condition; it appears black by transmitted and white by incident light, and consists of a marvellously complicated very fine canal-work with indented and radiated nodal points. The former passages are badly enough named calcareous canaliculi: the dilatations bear the name of the bone corpuscles or lacunæ (Figs. 58, 59).

The form of the lacunæ (Fig. 60, α) may be illustrated by calling them lens-shaped, or by comparing them to the figure

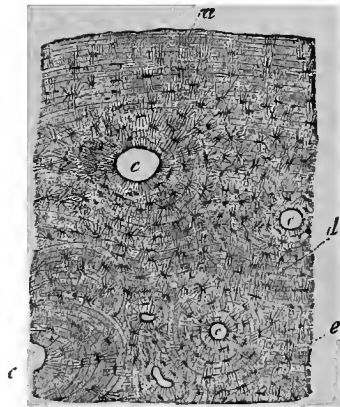


FIG. 59.—Transverse section of a human metacarpal bone; α , outer surface; c , medullary canals with the special lamellæ; α' , internal general lamellæ; e , bone corpuscles.

produced by two human hands when their volar surfaces rest over each other. The length is 0.1805 to 0.0541, the breadth

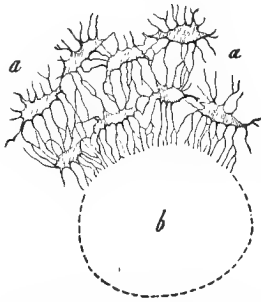


FIG. 60.—Lacunæ (*a, a*) with their numerous offshoots, opening into the transversely divided Haversian canal (*b*).

0.0068 to 0.0135, the thickness 0.0045 to 0.009 mm. The offshoots of this system of cavities, very narrow canals of 0.0014 to 0.0018 mm. diameter, permeate the entire tissue in innumerable multitudes, ramifying irregularly in a radial direction. They open (1) in the Haversian canals (*b*), (2) on the surface of the bone, and (3) in the large medullary cavity in the interior. Transverse and longitudinal sections (the tangential must also be added) teach this most distinctly.

In the dried bone, the marvellously complicated system of canaliculi has become filled with air in a condition of the finest division. An earlier epoch erroneously assumed the contents to be inorganic hardening material, to be the finest molecules of the so-called bone earths. Hence the name of the "calcareous canaliculi." If we place the small thin plate in turpentine oil, the thousands upon thousands of finest canaliculi rapidly fill with the fluid through capillary attraction. The bone corpuscle now presents the appearance of a cavity; the fine canaliculi disappear more or less in the basis substance.

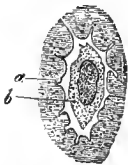


FIG. 61.—From the fresh ethmoid bone of the mouse; *a*, basis substance; *b*, the bone cell.

But what does this remarkable canal work contain during life?

We answer to this, there is in the lacunæ a protoplasmatic membraneless cell (Fig. 61, *b*). Whether this bone cell, the equivalent of the connective-tissue corpuscle, sends off capillary offshoots into the lacunæ, which is very probable, we do not yet know. The latter canicular system is certainly filled with transuded blood plasma. This fluid must, besides, be rather stagnant, for the frictional

resistance here imposes a veto to the circulation which is with difficulty removed.

Are the lacunæ and calcareous canals only cavernous systems excavated in the hard, solid basis substance, or have they a special parietes? After energetic macerating media, the previously decalcified bone presents a thin resistant boundary layer around the lacunæ and canaliculi. It appears to be a decalcified elastic substance. It was formerly erroneously considered to be a cell membrane.

Having become familiar with the most essential portion of the structure in the diaphysis, let us now turn to a very short discussion of the other parts of the skeleton. The beautiful regularity here disappears, sometimes to a less, sometimes to a greater degree. Even in the epiphyses of the cylindrical bones, in consequence of the thinness of the osteoid plates, the systems of lamellæ are present in a far less developed condition around the Haversian canals, and the inner fundamental lamellæ are absent. In spongy bone tissue the laminar arrangement may still be distinctly recognized in the thick trabeculæ and plates, while it disappears more and more with the decrease in size. In the cortical layers of flat bones, the medullary canals run parallel to the surface, generally starting from a point and assuming a radiate direction. In the short bones the course generally preponderates in one direction. Funnel-shaped apertures of the Haversian canaliculi may join together and form small medullary cavities, the prefigurations of the larger, etc.

The bones contain but little water, the compact having 3 to 7, the spongy 12 to 30 per cent. The organic, form-determining basis, amounting from 30 to 45 per cent. in the dry bone, is transformed by boiling into gluten, that is, the ordinary glue of the connective tissue. This is diffusely hardened by the embedded bone earths. By this is understood a mixture, amounting from 51 to 60 per cent., of lime salts with a slight admixture of magnesia salts. The bone earths yield about 86 per cent. of phosphoric acid, 9 of carbonate of lime, 3.5 of fluoride of calcium, and 2 of phosphate of magnesia.

When the bone is carefully decalcified its texture remains as of old. It is easy to cut the mass, which has now become semi-transparent. It is badly enough named the bone cartilage.

In the mechanical construction of the body, the bones come into consideration by reason of their solidity. They serve as a protection to softer organs, and form systems of levers moved by muscles. The less the proportion of bone earths contained, the greater the flexibility and cohesion. A preponderance of these mineral substances, on the contrary, renders the bone inflexible and brittle. The mutability of its materials is very considerable. In harmony with this is the double system of canals for the blood-vessels and lacunæ.

The larger cavities of the bone become filled with so-called bone marrow. This occurs in a double form, though with transitions. In the central portion of the long bones it appears as a yellow marrow, that is, as fat cells contained in loose connective tissue (p. 50). In the epiphyses, on the contrary, as well as in flat and short bones, we find a softer reddish or red substance containing, together with scanty connective tissue and isolated fat cells, very numerous lymphoid cells of 0.009 to 0.0113 mm. The latter elements, according to Neumann and Bizzozero (p. 25), present transitions into red blood corpuscles. Finally, we meet in the bone marrow, especially towards the surface, the myeloplaxes, which have become familiar to us in Fig. 13. The veins are without endothelium; they consist only of an adventitia (Hoyer). Altogether, the vessels of the medulla promise still further interesting conclusions.

We now turn to the theory of the origin of the bone tissue, osteogenesis. It forms a very difficult and complicated section of histology.

With the exception of a number of the bones of the cranium and face, as we have already said, all portions of the skeleton are preformed in cartilage. They afterwards present bone substance.

During a long period the direct metamorphosis of the

former tissue into the latter was unhesitatingly accepted. Sharpey, Bruch, H. Mueller, first demonstrated the erroneousness of this hypothesis.

Disregarding rare exceptions, the facts run, nowadays, in this way: The calcified cartilage does not become osteoid tissue, but rather melts down, and in the system of cavities thus obtained, the bone substance produced by the periosteum is established as a new tissue.

If we take a cartilage which is destined to end in this manner, two different processes are presented:

1. A local softening of the cartilage tissue (of the cells as well as of the intercellular substance) has taken place from the surface in an inward direction. Very irregular, manifoldly ramified passages have thus been formed. Vessels have grown into the latter from the perichondrium, accompanied by lymphoid and unripe connective-tissue cells. This substance has been not badly named the cartilage marrow. Until recently, it was erroneously assumed that the so-called cartilage marrow cells represented derivatives from cartilage cells which had penetrated the softened portion.

2. In the centre of such a cartilage, a calcification of the intercellular substance (p. 44) and very generally, also, an energetic formation of so-called daughter cells occurs (Fig. 62). This place has been called the point of ossification — badly enough, we add.

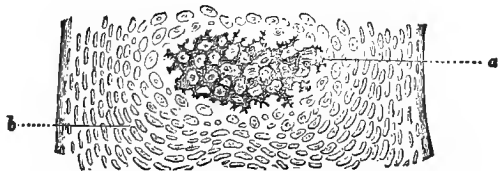


FIG. 62.—Dorsal vertebra of a human fetus of ten weeks in vertical section. *a*, calcified; *b*, soft cartilage.

For, although a further melting down of the calcified tissue occurs here forthwith, and, in the spaces thus formed, the first deposition of osteoid tissue commences immediately afterwards, this calcified cartilage has nothing whatever to do with the latter.

The two metamorphoses just mentioned proceed rapidly

side by side and against each other. The calcification of the cartilage spreads peripherally; the liquefaction and re-formation of the cartilage canals is constantly increasing in extent, and likewise in the domain of the calcified cartilage.

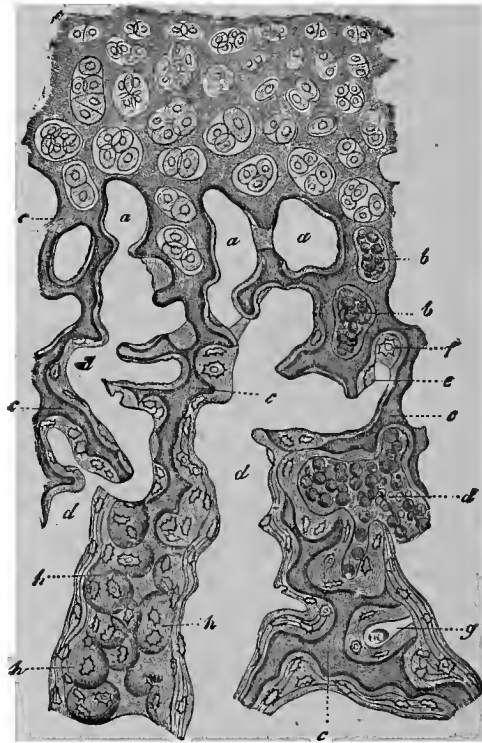


FIG. 63.—Ossifying border of a phalangeal epiphysis of the calf, in vertical section. At the upper part, the cartilage, with its irregularly disposed capsules, containing daughter cells; *a*, smaller medullary spaces, appearing in part as though closed, drawn empty; *b*, the same with narrow cells; *c*, remains of the calcified cartilage; *d*, larger medullary spaces, on the walls of which are depositions of thinner or thicker bone tissue, and in the latter case stratified; *e*, developing bone cell; *f*, an opened cartilage capsule, with an embedded bone cell; *g*, a partially filled cavity, covered externally with bone substance and containing a narrow cell; *h*, apparently closed cartilage capsules containing bone cells.

The latter must naturally first become physiologically decalcified before undergoing solution. This removal of a but just deposited lime salt is, up to the present time indeed, somewhat enigmatical.

Let us look at Fig. 63. At the upper part, the cartilage

still presents the old soft appearance. The cartilage cells lie here, in an epiphysis, irregularly. In a diaphysis they would be seen pressed together in longitudinal rows, or "ranked," as it has been expressed. Below, however, we meet with a cavernous tissue, the spaces of which, as a result of the preparation, in places no longer lodge the cartilage marrow contents (*a*), while it still remains preserved in others (*b*, *d*). Cloudy, dark trabeculæ of the most irregular form constitute the last remains of the liquefying decalcified cartilage (*c*). Even these trabecular remains are deprived of further repose.

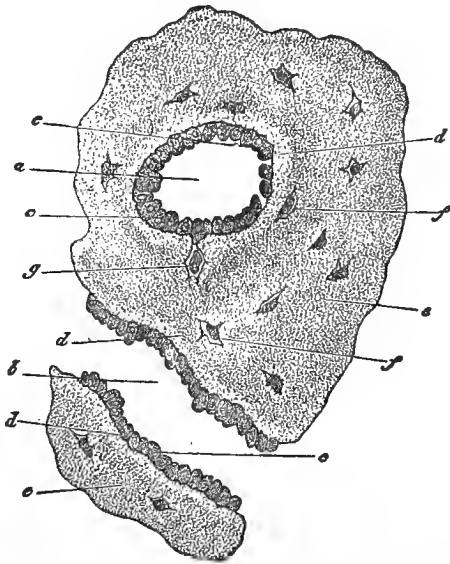


FIG. 64.—Transverse section from the femur of a human embryo of about eleven weeks; *a*, a transverse, and *b*, a longitudinally divided medullary canal; *c*, osteoblasts; *d*, the more transparent, younger. *e*, the older bone substance; *f*, lacunæ with the cells; *g*, cells still limited to the osteoblast.

If the contents of these cavernous passages are attentively examined at this period, their peripheral cells are found to have assumed an anomalous shape. They resemble, with their cubical bodies (Fig. 64, *c*), an irregular, badly developed cylinder epithelium. Gegenbaur, their discoverer, has

called them osteoblasts—and rightly, for they form the osteoid tissue.

As in a line of inordinately crowded soldiers, one or another will be pressed out in front, so does it happen to certain of these osteoblasts (*g*). They now assume indented or stellate shapes; homogeneous, but very soon diffusely calcified intercellular substance then appears around them. The latter as a thin layer—we might say, covering the irregular surfaces of the still remaining calcified cartilage trabeculæ like a wax impression—is the first lamella of the osteoid substance; the indented osteoblasts form the first bone cells, however. Our Fig. 63 shows this at its upper portion (*a, a, a*), also at the left, half way up (*c, d*).

Concerning the conception of the intercellular substance, whether it arises from a secretion of the cells or from the metamorphosed cell bodies, the same uncertainty of opinion prevails as with other members of the connective substance group.

We have here still more peculiar illusive appearances to consider. It is comprehended that by the continual liquefaction of the cartilaginous trabeculæ the cavities of the tissue become opened, and must then serve for the deposition of bone cells and homogeneous basis substance. When the conditions are as at *f* of our Fig. 63, the matter is at once clear, the place *g* is also, in a measure, appreciable. When, however, the cavities are ruptured from below or above, this does not fall within the plane of the section, and we have the deceptive appearance of closed cartilage cavities with endogenous bone cells.

This, which thus occurred for the first time, is repeated in rapid sequence manifoldly after each other. Lamella upon lamella with enclosed bone cells result (Fig. 63 in the lower half). We obtain in this way a stratified osteoid tissue. The remains of the cartilaginous tabeculæ disappear more and more with the continuing process of liquefaction.

But this thing, in its wild, confused irregularity is very dif-

ferent from the bone tissue which appears in such elegant regularity at a later day.*

Now, how does the latter arise from the former?

Two different opinions exist on this subject. According to the first, and we adhere to this for the most part, the osteoid tissue, which is formed at the expense of, and within the foetal cartilage, the so-called endochondral bone, has not a happy life. It yields to an early death, a speedy process of liquefaction, in order to permit the formation of the large medullary canals. On its surface is deposited, by the periosteum, into which the perichondrium has now become changed, and with the aid of a deeper osteoblastic layer, new bone tissue which, with a supplementary loss of its inner layers, persists in the outer portions and causes the regular, beautiful structure of the bone. This may be denoted as the apposition theory of osteogenesis. Koelliker has recently re-entered the lists for this with great energy.

Another view rejects the resorption of the endochondral osteoid tissue absolutely, and explains the transformation of the irregular cavernous bone of the commencement period into the regular of the later period of life, by interstitial growth alone. An industrious Russian investigator, Strelzoff, supported by German predecessors, has recently endeavored to substantiate this with greater accuracy.

We cannot enter further into this actually burning controversy. The truth, according to our views, lies more towards the former side. Nevertheless, the young bone certainly has an interstitial growth, which Koelliker also, naturally, acknowledges; but to what degree this occurs no one can, at the present time, state with accuracy. A resorption is surely, also, not wanting in the normal bone. This is proved by the Haversian spaces of healthy bone, if we disregard the long known abnormal resorption processes. Those who deny the demonstrative force of such facts are, in our opinion, not to be reasoned with further.

* The central portion of the cylindrical bone has also once had the same cavernous structure that is presented by the epiphysis.

Let us then investigate these Haversian spaces.

Our figure (Fig. 65), shows us three Haversian lamellar systems. The two hatched ones (*a, a*), present internally an indented resorption line (*b, b*). New bone lamellæ, maintaining the outline, have been deposited on this. To the right (*c*), a second liquefaction has overtaken the latter, for which a new lamellar formation endeavors to compensate

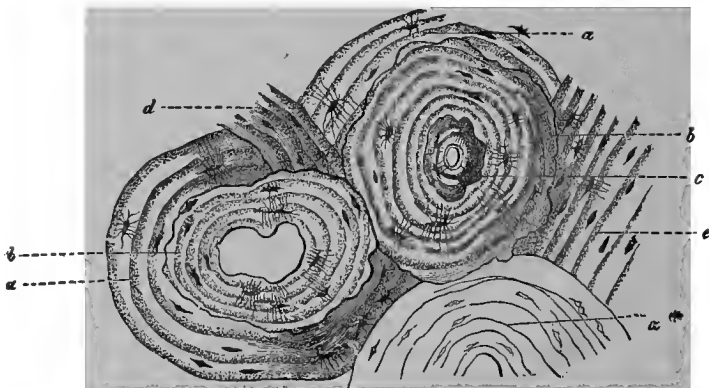


FIG. 65.—A human metacarpal bone in transverse section; *a**, a Haversian lamella system of the ordinary variety; *a, a*, two others which have undergone absorption internally (*b, b*), and thus form Haversian spaces, which are filled up by new lamellæ; *c*, supplementary absorption in one of these with deposit of new bone substance; *d*, irregular, and *e*, ordinary intermediate lamellæ.

Koelliker has ascribed to the multi-nuclear giant cells (Fig. 13), the property of dissolving the bone substance, and called them osteoclasts. We do not share in this view. Between the bone-producing osteoblasts of Gegenbaur and the bone-destroying elements of the first mentioned investigator, transition forms exist.

We hold fast to the absorption of the endochondral bone, therefore, and now inquire into the particulars of the peripheral reparation. This is produced by the periosteal bone; that is, the osteoid tissue, which is subsequently furnished from the inner surface of the periosteum.

An eminent French observer, Ollier, informs us that the detached living periosteum, whether it be retained in the body

of its owner, or whether it be transplanted into that of another animal, again produces new bone tissue, only the deepest layer must be uninjured.

If we examine this deepest layer with the help of the microscope, we discover our old friends, the osteoblasts. This cell layer then grows downwards in a conical form into a retrogressing, indifferent cell substance.

With the bone-producing force of the osteoblasts we are already familiar. Therefore the osteoblast-cones (*sit venia verbo*) produce the Haversian lamellæ, while the general lamellæ are produced by the flat osteoblast layer, which is immediately beneath the periosteum. In this manner is also explained the regular structure of the diaphysis and its increase in thickness. Concerning the latter, further remarks are scarcely necessary.

We may, therefore, say: The endochondral bone disappears as an embryonic structure, the periosteal remains during the subsequent life.

As we have already learned above, a number of cranial and face bones never were cartilage.

They arise from a soft, fœtal connective substance, and have been badly named the "secondary" bones. Here, also, when there is to be a production of osteoid tissue, we meet with osteoblasts and the same process of origin of the bone tissue as when formed from the periosteum. The development of the bone substance commences centrically in certain places, and advances from these peripherically. These are, therefore, true points of ossification, in contradistinction to the false, or the calcifying centres of endochondral bone.

That connective-tissue fragments are frequently hardened with the periosteal and secondary bones, we readily understand. These things—they sometimes appear like a board with nails driven in—have received the name of Sharpey's fibres.

Many modern investigations also favor an immediate transformation of one or another cartilage into osteoid substance,

and likewise of a connective-tissue structure. Still, a calcified connective tissue has not thus become bone.

The proliferous formative life of bone is met with more frequently in the abnormal than in the normal processes. Unfortunately, we cannot here enter into this subject.

SEVENTH LECTURE.

DENTINE.—ENAMEL.—LENS TISSUE.

THE tooth as a whole is known to everybody. We distinguish, (*a*) the crown, the free part, (*b*) then a middle portion surrounded by the gum, the neck, and, finally (*c*), the simple or multiple fang wedged into the alveolus of the jaw. Through the centre of the tooth passes a canal which has a cæcal termination above; and below, corresponding to the fang, it is simple or multiple in form, and has a free opening at the apex of the root. This is filled with a soft connective tissue, rich in vessels and nerves, the pulp.

The chief mass of the tooth, which is limited internally by the cavity, and is covered externally by a thin cortical layer, consists of the so-called tooth-bone or dentine, a modified osteoid tissue. The crown is invested by the enamel, the fang by the cementum; both substances meet at the neck.

Let us first of all examine the dentine (Fig. 66, *d*). It contains in a collagenous matrix a still greater quantity of lime salts than the osteoid substance. It is permeated by extraordinarily numerous, very fine canaliculi, 0.0011 to 0.0023 mm. broad, the so-called dentinal canals (*e, e*). Their course,

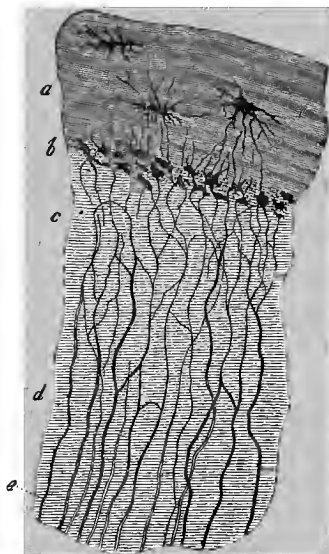


FIG. 66.—Human tooth-fang *d*, with cement covering *a*. At *b* the granular or Tomes' layer with interglobular spaces; at *c* and *e* the dentinal canals.

disregarding the most acute-angled ramifications and looped communications, is on the whole regular. They are, in general, perpendicular to the surface of the pulp cavity and therefore vertical on the vertex of the crown, oblique on its marginal portions, horizontal over the neck and fang, and at the apex of the latter reassuming an obliquely descending direction. A transverse section shows them radially arranged. By more careful examination, however, we meet with a number of smaller interesting variations (Kollman).

Filled with air they appear dark, saturated with fluid as transparent, readily disappearing canals. The condition of the lacunæ of bone is, therefore, repeated here. An elastic, calcified parietal layer, like that of the bone, is also not wanting in the dentinal canals. They are now much more easily recognized with the greater diameter of the tubuli.

Our dentinal canals open internally into the central cavity. The latter may be very well compared to a Haversian canal of the bone.

The fang is covered by cement, as we have already remarked. This (*a*), is a thin layer of bone substance, increasing downwards towards the apex of the root, generally without lamellar structure, but with delicate bone corpuscles.

A portion of the lacunæ of the latter communicate with the dentinal tubuli which have entered the cement or—more correctly said—pass over into the latter. At the margin of the bone covering and the dentine, numerous spaces occur, the so-called interglobular spaces (*b*), which may be mistaken for bone corpuscles.

Let us leave the enamel covering of the crown for the present, and turn to the contents of the dental cavity, the pulp.

In the progressing bone, as the previous lecture taught, the ruptured cavities were filled with unripe tissue, on the surface of which the osteoblasts appeared. Now the tooth pulp pos-

esses—and at a later stage as well—a similar cell covering. These (Fig. 67, *b*), are the dentinal cells or, as they have been characteristically named (Waldeyer), the odontoblasts, the sculptors of the tooth bone. Our cells, oblong, measuring 0.02 to 0.03 mm., are stratified. One or more of their fine, thread-like processes penetrate the dentinal tubuli peripherally. An able English investigator, Tomes, first saw such “soft fibres” here.

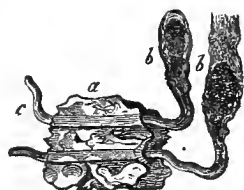

FIG. 67.—Two dentinal cells, *b*, which pass with their processes through a portion of the dentinal canals at *a*, and protrude from the fragment of dentine at *c*: after Beale.

The crown is covered with enamel, the hardest substance of the body. The organic form-determining basis amounts to only a slight per cent. (3.5 to 6), against a prodigious excess of bone earths.

The enamel (Fig. 68), a petrified epithelial production, consists of long, closely crowded polyhedral cylinders, the enamel prisms or enamel columns (*b*). They frequently appear to pass through the entire thickness of the enamel covering; their diameter is 0.0034 to 0.0045 mm.

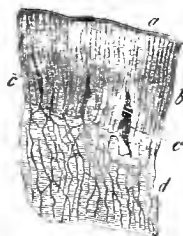

FIG. 68.—Peripheral portion of the dentine *d*, from the crown; with enamel covering, *b*; *a*, enamel membrane; *c*, the cavities filled with air.

Transverse polished sections of the enamel show a delicate hexagonal mosaic (Fig. 69).

A peculiar transversely striated appearance may be recognized in the isolated enamel prisms.

The surface of the enamel, finally, is covered by an uncommonly tough membrane. This is the cuticle of the enamel (Fig. 68, *a*).

Beneath the enamel the dentinal tubules form loop-like and reticular transitions (Fig. 68, *d*). In the hard brittle substance of the former, there has been a formation of numerous clefts (*c*), which may communicate with the canals of the dentine.



FIG. 69.—Transverse section of the human enamel prisms.

With the tolerably simple structure of the teeth, which has

been described, is connected a very complicated history of their origin. We here mention only the chief points.

That the teeth are formed in the maxillary bones, that in the infant the eruption first takes place after months and years, that the first teeth are for the greater part replaced by permanent ones, is known to all.

Two of the three germinal plates participate in the production of our structures, the corneous layer and the middle germinal layer. The former produces the enamel, the latter the pulp, dentine and cement.

On the free borders of the embryonic jaw appears at first a mound-like thickening of the pavement epithelium (Fig. 70, *a*). It presses

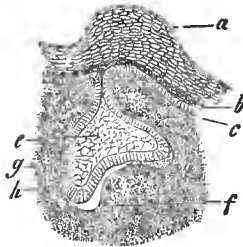


Fig. 70.—Tooth formation of a hog's embryo; *a*, epithelial mound; *b*, younger cell layer; *c*, the lowermost; *e*, enamel organ; *f*, tooth germ; *g*, inner, and *h*, outer layer of the progressing tooth sac.




Fig. 71.—Tooth sac of an older human embryo, partly diagrammatic; *a*, connective-tissue parietes of the tooth sac, with the outer layer at *a*¹ and the inner at *a*²; *b*, enamel organ, with its external *c*, and inferior cells, *d*; *e*, dentine cells; *f*, dentine with the capillary vessels, *g*; *i*, transition of the connective tissue of the parietes into the tissue of the dentine germ.

downwards into the soft substance of the maxillary tissue as a vertical elongated ridge. The former has been named the tooth papilla, the latter the enamel germ.

From place to place, springing up from the depths of the tissue of the jaw, convex papillar structures, the so-called tooth germs (*f*), grow towards the enamel germ. Here and there, increasing in diameter, they press in the under surface

of the enamel germ, and thus give this locally the form of a cap or bell. The latter is called the enamel organ (*e*).

Leaving the intermediate forms aside, let us pass at a bound to a later period. Here (Fig. 71) the enamel organ (*b*) has long since become separated by constriction from its point of origin, the epithelium of the jaw, and also thrown off the lateral bridge connecting it with the ridge of the enamel germ. It is covered on the upper convex and inferior concave surfaces with cylindrical epithelial cells (*c*, *d*). In the interior (*b*) we find gelatinous tissue (Fig. 22). Below (Fig. 71, *f*) we perceive the thick tooth germ, the progressing tooth crown. Both are enclosed within a connective-tissue capsule (*a*), the so-called tooth sac, with external (*a*¹) and internal (*a*²) layers. The sac and tooth germ finally become continuous with each other below.

The tooth germ bears on its surface the layer of odontoblasts (*e*). From them is produced the first thin cortical layer of the dentine. Layer on layer are subsequently formed over the longitudinally growing tooth germ. By this growth it finally obtains the neck and fang; its soft, vascular tissue remains more and more retarded in its further development, and becomes the pulp. From the epithelium at the concave surface of the enamel organ, occurs the formation of the enamel prisms (below *d*), whether these represent calcified portions of the cell body or secreted cell substances. The tooth, growing up, kills the enamel organ at last, and makes its eruption. Its cement may originate from the lower portion of the tooth sac. This persists, for the most part, as the periosteum of the alveolus.

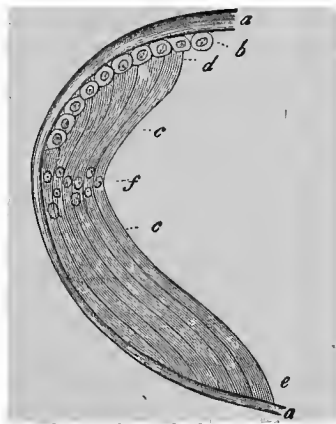


Fig. 72.—Crystalline lens; *a*, capsule; *b*, epithelium of the anterior half; *c*, lens fibres, with the anterior, *d*, and posterior ends, *e*; *f*, nuclear zone.

For the permanent teeth, a secondary enamel germ appears to branch off from the original one at a very early period.

To close with the epithelial productions, we here notice briefly the tissue of the crystalline lens of the eye. This (Fig. 72), arising from an ingrowth of the corneal plate of the foetus, is invested by a structureless capsule (*a, a*), which is thicker anteriorly and thinner posteriorly. The inner surface of the anterior segment of the capsule has an unstratified, low, cubical pavement epithelium (*b*).

The marginal zone of the latter, advancing towards the equator, undergoes a gradual transition into elongated nuclear elements, the so-called lens fibres (*c*). These are pale, hyaline elements, in the external portions of the organ, 0.009 to 0.0113 mm. ; in the internal, where they appear more firm, only 0.0056 mm. broad. The lens fibre, surrounded by a sort of envelope, has the value of a full-grown cell. The nuclei (*f*) lie adjacent to the equatorial zone. The arrangement is, in general, meridional. Transverse sections of the lens fibres present an elegant band of elongated hexagons (Fig. 73).



Fig. 73.—Lens fibres in transverse section.

EIGHTH LECTURE.

MUSCULAR TISSUE.

WE now return to the middle germinal layer of the embryonic germ, and discuss one of its most important and extensive productions; we refer to the muscular tissue.

This presents, in man and the higher animals, two quite different appearances. In the one we recognize as elements elongated, spindle-shaped cells of a homogeneous appearance (Fig. 74); in the other we meet with a longer, larger, striated fibre (Fig. 75, *a*).

One speaks, accordingly, of smooth and transversely striated muscles. Do not believe, however, that we have here to do with two entirely different things! In the first place, we meet with quite a number of intermediate varieties in the great multiform animal world; and then the two different representatives of the muscular tissue originate from extremely similar initial structures. The smooth element stops at a lower stage; the

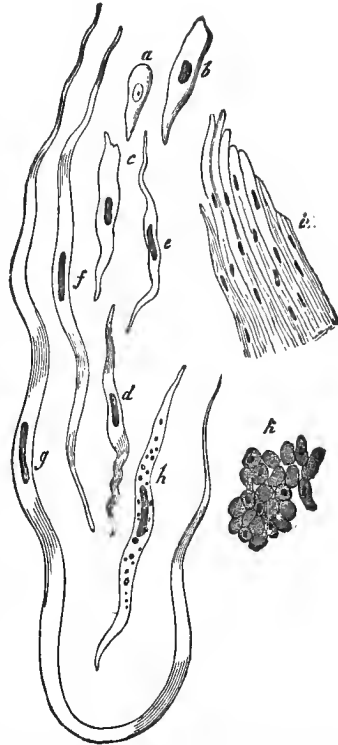


FIG. 74.—Smooth muscular tissue of man and the mammalia, *a*, a developing cell from the gastric region of a two-inch long hog's embryo; *b*, a more advanced cell; *c* to *g*, various forms of the human contractile fibre cell; *h*, one with fat granules; *i*, a bundle of smooth muscular fibres; *k*, transverse section through such a one from the aorta of the ox, with many nuclei in the plane of the section.

transversely striated has become further developed. The latter contracts rapidly and energetically, the former slowly and sluggishly; the latter constitutes the voluntary muscle, the former the involuntary acting. The heart, with transversely striated involuntary fibres, makes, it is true, an exception.

Pale, nucleated bands were formerly assumed to be the elements of the smooth muscles (Fig. 74, *i*). In the year 1847 Koelliker reduced the band into a series of cellular elements, linearly arranged behind each other, his contractile fibre cells. At that time this was an important discovery, a proof of the distinguished observer's sharp-sightedness.

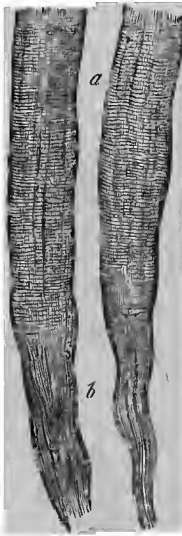


FIG. 75.—Two transversely striated muscular fibrillæ (*a*), with the connective-tissue bundles (*b*).

We perceive these contractile fibre cells at *a* to *b*. They are sometimes short, sometimes longer, not infrequently immensely long, spindle-shaped structures, 0.0282 to 0.2256 mm. and more in length, and of moderate diameter, 0.0074 to 0.0151 mm. The appearance of the membraneless cell body is, as a rule, entirely homogeneous, except when a deposition of fat (*b*) has taken place within it. An elongated nucleus (it is called rod-like) is readily seen. It contains one or more nucleoli. Occasionally we find the nucleus double or in even greater number.

Smooth muscles are widely diffused throughout the human body. From the œsophagus till near the end of the rectum they form the long known thick muscular layer, and, besides, a still finer one—the muscularis mucosæ—in the tissue of the mucous membrane. Smooth muscles are met with, furthermore, in the respiratory apparatus, as in the posterior walls of the trachea, in the circular fibrous membrane of the bronchi and their ramifications. According to many, our tissue is not wanting even in the respiratory vesicles of the lungs,

although we never could convince ourselves of this. The middle layer of the vessels, especially of the arteries, contains smooth muscle. Small bundles of the same occur in the corium; thus, in the hair-sacs, arrectores pilorum, furthermore, from the surface of the corium to the subcutaneous cellular tissue (J. Neumann), then, more connectedly, on the nipple and the areola, and especially in the so-called tunica dartos of the testicle. The walls of the gall-bladder are also muscular. In the urinary apparatus, in the calices, and pelvis of the kidneys, the ureters, and the bladder our tissue acquires a greater development. The male generative apparatus is likewise abundantly provided with smooth muscular substance; still more so that of the female. Even the ovary, according to our view, harbors this tissue. It forms connected layers in the oviducts. Altogether the most massive collection of the tissue is met with in the womb. During pregnancy it acquires a still greater increase. The lymphatic glands, the eye (sphincter and dilator pupillæ, choroid, the ciliary, orbital, and palpebral muscles) also have smooth muscles.

We meet with transversely striated tissue in all the muscles of the head, trunk, and limbs, the auricle, the external muscles of the eye, in the tongue, the pharynx, the upper portions of the œsophagus, the genitals, the termination of the rectum. Our tissue likewise forms the diaphragm and, modified, the heart.

As element (Fig. 75, *a*) we recognize in man at once a long, unramified, cylindrical, filamentous element of 0.0113, 0.0187 to 0.0563 mm., transverse diameter. This is the muscular filament, the muscular fibre, or, as is badly said, the primitive bundle.

Here, however, we at once notice a peculiarly complicated texture.

We meet with an envelope and contractile contents; the sarcolemma and sarcous element. The former, closely applied to the living muscular filament as a constant companion, may, in death, become elevated in a vesicular manner by the

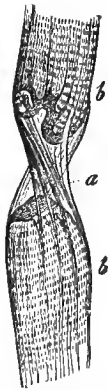


FIG. 76.—Muscular fibrilla torn across; *b, b*, sarcous portion; *a*, sarcolemma.

absorption of water. When the sarcous portion has been torn by traction, the sarcolemma, or primitive sheath (Fig. 76, *a*), appears most distinctly. It is a hyaline, aggregated, elastic membrane.

Directly superimposed on this envelope, one meets with numerous oval nuclei (Fig. 77, *c*), measuring 0.0074 to 0.0113 mm. The lateral surfaces, and the pole of the latter, are surrounded by a small quantity of a protoplasmic substance (*d*). This, a cell rudiment, has been called a muscle corpuscle (M. Schultze). This is the condition of the human muscle. In the lower animals, however, the nucleus also lies in the interior, and the same is the case in our heart muscle.

All this is readily understood.

Extraordinary difficulties are, on the contrary, presented by the substance surrounded by the sarcolemma, the sarcous elements. It is, in the first place, very changeable, and, with its infinitely delicate structure, we soon arrive at the limits of the microscopic solution possible at present.

In many cases, and regularly after the use of certain reagents, the sarcous elements appear as a bundle of fine, transversely striated, elongated fibrillæ, measuring 0.0011 to 0.0022 mm. It would appear, therefore (after the manner of the connective tissue), to be a primitive bundle.

With other methods of treatment, and also in the living muscle, we

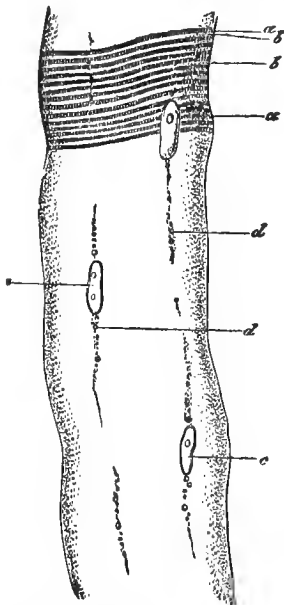


FIG. 77.—A muscular fasciculus of the frog by 800-fold enlargement; *a*, dark zones, with sarcous elements; *b*, bright zones; *c*, nuclei; *d*, interstitial granules (alcohol preparation).

see little or nothing of these fibrillæ. The filament permits the recognition of transverse lines only. It now appears, comparable to a Volta's pile, to consist of discs piled upon each other.

The fibrillæ, as well as the transverse discs, were both regarded as normal, pre-existing structures, and in this, according to our view, a double error was committed. In the living muscle there are neither fibrillæ or discs.

The first who here trod the correct path, a generation since, was the Englishman, Bowman. It is true that, with the optical aids of that period, he was unable to exhaust the subject; but we are also unable to do so at the present time, although we have at our disposal much more perfect microscopes.

According to the view of this distinguished investigator, the muscular filament consists essentially of an aggregation of small bodies, the sarcous prisms or sarcous elements which, united and holding together in the transverse direction, afford the appearance of a disc or a thin plate (*disc* according to Bowman) (Fig. 77, *a*) while, disposed in the longitudinal direction, they present that of the fibrillæ (Fig. 78, 1, *a*, *b*). Accordingly, neither fibrillæ or discs pre-exist. There is merely a disposition present

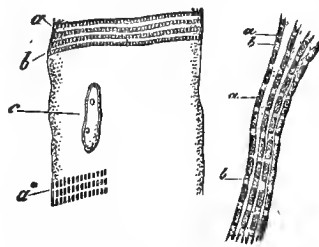


FIG. 78.—Two muscular fibrillæ. from the proteus, 1, and the hog, 2, magnified 1,000 times; *a*, sarcous prisms; *b*, bright longitudinal connecting medium. At *a** the sarcous elements are further apart, and the transverse connecting medium is visible; *c*, nucleus.

in the muscular filament to become divided, sometimes in the transverse, sometimes in the longitudinal direction. The cohesion in the latter direction is certainly the strongest; for the fibrillæ in the dead element are met with more frequently than transverse plates.

Let us next examine the muscular filament somewhat more closely, with the aid of the highest magnifying powers.

The transverse lines are readily resolved into dark transverse zones, separated by more transparent ones (2, *a*, *b*).

The former consist of sarcois elements (a^*) placed nearer each other. This may also be recognized without trouble by the aid of good and strong magnifying powers. They are elongated prismatic bodies, measuring 0.0017 mm. in the proteus, 0.0013 in the frog, 0.0011 to 0.0012 mm. in the mammalia and man.

The sarcois elements must, naturally, be joined one to the other.

If we split off one of the finest longitudinal filaments, that is a so-called muscular fibrilla (1), the longitudinal series of sarcois elements (a) are held together by the transparent longitudinal connecting medium (b). If we examine a muscular filament split up into transverse plates, the dark and light transverse zones are found to be connected by a transverse connecting substance, which extends over the outer surface from a and b of our Fig. 78, 2. Here the longitudinal connection is naturally, completely dissolved.

Up to about ten years ago, we thought the matter might thus be passably explained; but newer observations have been added and further doubts have arisen.

In the year 1863, the Englishman, Martyn, had already seen a dark transverse line in the transparent longitudinal connecting medium. These observations were afterwards corroborated and extended by Krause (Fig. 79). Let us name this thing (a), therefore, Krause's transverse line or disc.

But with this we have still not reached the end. At the same time another competent investigator, Hensen, found the dark transverse zone, the transverse series of sarcois elements, divided by a transparent transverse line. This is the Hensen's middle disc. Granules which were contiguous above and below to Krause's transverse line

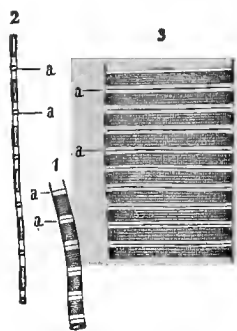


FIG. 79.—Krause's transverse discs; a , a , 1, a muscular fibrilla without; 2, one with strong longitudinal traction, both very strongly enlarged (Martyn); 3, muscular filament of the dog immediately after death.

were subsequently designated by Engelmann as accessory discs (Fig. 80 *b*).

From these singular observations, which touch and, perhaps, in part, exceed the limits of microscopic analysis, we are at present unable to derive an anyways reliable conclusion.

An old observation of Bruecke's is also interesting. The Bowman's sarcous elements refract the light double, the longitudinal connecting medium refracts simply.

We pass, finally, to some more simple structural conditions of the transversely striated muscle.

Among these are the so-called interstitial granules, small fat molecules (Fig. 77, *a*), which, commencing at the nuclear poles of the muscular corpuscles, permeate the filament in a linear longitudinal direction over shorter or longer distances.

The preparation of transverse sections through the frozen muscle (Fig. 81) was taught by Cohnheim. Groups of sarcous elements (*a*) are here recognized as a mosaic of small areas of transverse to hexagonal shape. Enclosing these are noticed a system of transparent, glistening lines (*c*) which must belong to the transverse connecting medium.

A modification of the transversely striated muscles is met with in the tongue and heart of the mammalia and man. These are ramified and reticularly connected filaments. In the former organ are noticed frequently repeated divisions at acute angles.

In the heart (Fig. 82), a narrow-meshed net-work is constituted by the abundant formation of anastomoses. A sarcolemma is probably wanting in these diminished filaments. The latter, furthermore, show strongly pronounced transverse and longitudinal markings. It is an interesting circumstance, finally, that this muscular reticulum consists of cemented cells (Fig. 82, to the right).

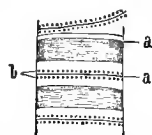


FIG. 80.—Piece of a dead muscular filament from the fly, after Engelmann; *a*, transverse discs; *b*, accessory discs.

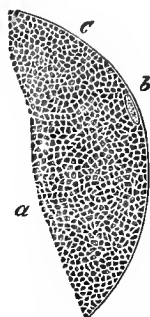


FIG. 81.—Transverse section through a frozen muscle of the frog; *a*, groups of sarcous elements; *c*, transparent transverse connecting medium; *b*, nucleus.

The remaining transversely striated muscles show the filaments arranged parallel, slightly prismatically flattened against each other (Fig. 83, *a*), and in man containing the muscular corpuscles (*e*) in their periphery. Between them occurs a scanty amount of connective tissue, the highway for vessels (*d*) and nerves. With rich living this may develop fat cells (Fig. 50).




FIG. 82.—Muscular filaments of the heart. To the right appear transparent boundaries and nuclei.

A varying number of muscular fibres unite into bundles, measuring 0.5 to 1 mm., which are separated from the neighborhood by abundant connective tissue. Such primary bundles then unite into secondary ones. The connective tissue covering of the muscle bears the name of perimysium externum, in contradistinction to the perimysium internum of the inner connecting substance between the filaments and bundles.

Smooth muscles also show a bundle-like grouping.

We come, finally, to the connection with the tendons. The latter tissue has already been described above, page 57.

With a rectilinear insertion (Fig. 75) the sarcoous substance (*a*) appeared to pass immediately over into the tendinous bundle (*b*); not so, however, with an oblique insertion, where an interrupted muscular end becomes apparent.

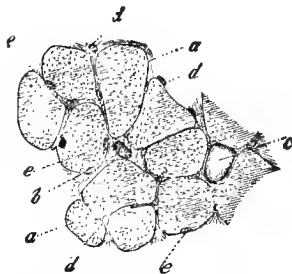


FIG. 83.—Transverse section through the human biceps brachii; *a*, the muscular fibres; *b*, section of a larger vessel; *c*, a fat cell lying in a large connective-tissue interspace; *d*, capillaries cut across in the thin connective-tissue layer between the several fibres; *e*, the nuclei (muskelkörperchen) of the latter lying on the sarcolemma.

Weismann first obtained convincing appearances here by

means of potash solutions (Fig. 84). The end of the filament, sometimes rounded, at others pointed, and again irregularly shaped, is always covered by sarcolemma (*b*). The tendinous bundle is attached by a corresponding excavation (*c*, *d*). During life the whole is united in the firmest manner by means of a cement substance.

The muscular filaments are of various lengths, but according to Krause do not exceed four centimetres. They terminate, therefore, repeatedly far from the end of the entire muscle, in its interior and in the form of points.

The muscular filament consists of various albuminous bodies. The sarcous elements, transverse and longitudinal connecting medium, are formed of modified members of this so little understood group of substances. The proportion of water present is considerable, corresponding to the softness of the tissue.

We turn to the embryonic development of our tissue.

The elements of the smooth muscles present nothing but cells grown into a spindle shape (Fig. 74). The rounded or oval developing cells (*a*, *b*) simply exchange their protoplasm with the homogeneous sarcous substance, the nuclei assume the rod form, and an envelope is altogether wanting.

We have already (Fig. 27) briefly mentioned the origin of the transversely striated fibre. After the example of Schwann, they were formerly considered to arise from the fusion and metamorphosis of formative cells arranged in rows. In the heart muscles, as we have already seen, something of the kind does, in fact, take place; but not so in the remaining voluntary muscles. Here the element is a single cell, which, it is true, undergoes a much more extended development than the contractile fibre cell of the smooth tissue.

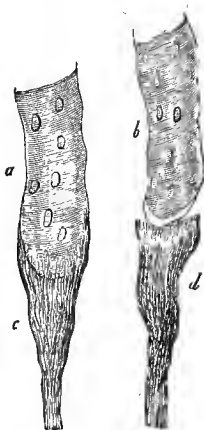


FIG. 84.—Two muscular fibrillas (*a*, *b*) after treatment with solution of potash, the one still in connection with the tendon (*c*), the other separated from the same (*d*).

In small embryos one obtains thin (0.0045 to 0.0068 mm.), but long (0.28 to 0.38 mm.) spindle cells, with one or two vesicular nuclei, and in the centre commencing formations of transverse lines, that is with a transformation into sarcofibrils. With an increase in nuclei, the structure increases not only in length but also in breadth. The transverse striation advances towards the ends, but leaves the axial portion still free. We still meet here with the old protoplasm. Later, however, after the longitudinal markings have also appeared, this protoplasm has disappeared, with the exception of a slight residue, which surrounds the nucleus and thus forms the muscle corpuscle. We find the latter, at last, in mammalia and man, displaced towards the periphery.

We have already above (p. 82), declared the sarcolemma of the transversely striated filament to be a homogeneous boundary layer furnished by the adjacent connective tissue. All investigators do not, however, coincide with our view.

The muscular filaments of the new born are still much finer than those of the adult. The subsequent increase in thickness explains in great part the growth of the muscle in transverse diameter. New fibres are also subsequently developed (Budge). This has, it is true, been recently disputed.

Weismann observed that the muscles of the frog divide in a longitudinal direction, with a prodigious increase in their nuclei. One then sees regular columns of nuclei descending near each other. The filament divides, one becomes two, which subsequently acquire the normal diameter by a growth in thickness. The two products of division may afterwards repeat the same cleaving process. A single muscular filament may in this way finally become a whole group of filaments.

Among the forms of retrogression of our tissue, fatty degeneration is the most frequent (Fig. 85).

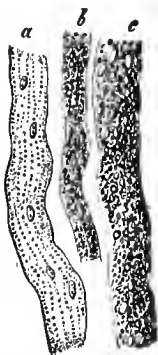


FIG. 85.—Fatty degenerated human muscular fibre; *a*, slighter; *b*, increased; *c*, highest degree.

NINTH LECTURE.

THE BLOOD-VESSELS.

ONE cannot really speak of a vascular tissue. Only the innermost layer consists of a simple layer of closely cemented endothelial cells. This is the original stratum; it forms the simplest, finest vascular tube.

All the remaining layers, on the contrary, which by their further aggregation reinforce the walls of the vessel—and they commence very soon—belong to tissues which we have already discussed; they consist of connective tissue and elastic substances, as well as layers of smooth muscles.

The blood is conducted from the heart, as is known, by immensely ramified systems of arteries. Its return is consigned to the not less ramified veins. Between them is intercalated, but without any sharp demarcation, the district of the capillaries. They maintain the nutrition of the organs and tissues, as well as the secretion of the glands.

The finest capillaries—they do not by any means occur in all parts of the body, however—have a calibre which just suffices to permit the passage of the blood cells, one after the other, though often with a certain lateral compression. Their lumen may, therefore, be assumed to be for man 0.0045 to 0.0068 mm. In other parts of the body, however, the finest capillaries present double this diameter.

Without being treated with a suitable reagent, their structure appears extraordinarily simple. A hyaline, structureless, extensible and elastic membrane contains embedded, from place to place, rounded or elongated oval nuclei of 0.0056 to 0.0074 mm., with nucleoli. In the finest capillaries the nuclei lie in the simplest manner behind each

other ; in somewhat larger ones an alternating position begins to take place.

If, however, we force a stream of dilute nitrate of silver solution through our capillary, it then appears to be composed of the plates and curved, nucleated, endothelial or vascular cells represented in Fig. 21. With stronger magnifying powers (Fig. 87), one recognizes in places, between the

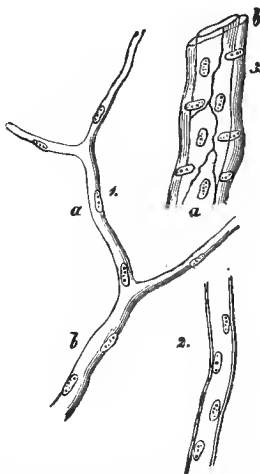


FIG. 86.—1, capillary with a thin wall, and the nuclei *a* and *b*; 2, capillary with double contoured walls; 3, small artery, with the endothelial layer *a*, and the middle-layer *b*.

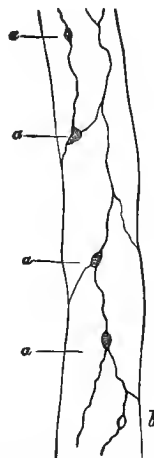


FIG. 87.—Capillary from the mesentery of the frog. At *a* and *b*, small apertures, "Stomata."

endothelia, larger and smaller, mostly rounded, dark corpuscles (*a, a*) or light circular markings (*b*). There are small openings here, through which the lymphoid cells, by their vital migration (p. 10), probably make an active exit, and the colored elements of the blood are passively forced out (p. 27). The former marvellous emigration has been known for years (A. Waller, Cohnheim).

In other capillaries (Fig. 86, 2) the walls are circumscribed by a double line. Here, there already appears to be the primary rudiments of a so-called tunica interna or serosa.

More frequently, there are capillaries where the endothelial tube is surrounded by a connective-tissue layer, a so-called adventitia capillaris. The latter is, for a certainty, the primary rudiment of the layer, which with increasing complexity occurs in all the larger vessels as the most external layer or adventitia. We here meet at first with either ordinary connective tissue, which has indeed remained at an earlier stage, with longitudinally arranged nuclei or cell remains (Fig. 89, *d*), or, when capillaries of lymphoid organs are concerned (Fig. 88, *b*), the reticular connective substance has become spread over the endothelial tube in an elegant manner, and the capillary is kept distended by this cellular reticulum, like the embroidery in a frame.

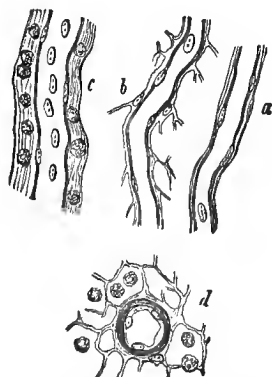


FIG. 88.—Capillary vessels and fine branches of the mammalia; *a*, capillary vessel from the brain; *b*, from a lymphatic gland; *c*, a somewhat larger branch with a lymph-sheath from the small intestine; and *d*, a transverse section of a small artery of a lymphatic gland.

Passing, now, to somewhat larger trunks, numerous variations of the structure occur. They coincide in part with the nature of the vessel, whether arterial or venous branches; they are also, in part, of a more individual or local nature.

Frequently, when we follow the capillaries towards the arterial tubes, we perceive branches where a layer, striking the eye by its transversely arranged nuclei (Fig. 86, 3, *b*), is met with around the endothelial tube (*a*). The former constitutes the very commencement of the muscular middle layer or tunica media of the vessels. An equally large venous branch usually has in the place of the latter layer a connective-tissue adventitia. Still, it often enough occurs in the finer arterial branches also, spread out over the muscular layer.

Let us take a small arterial trunk, after the manner of our Fig. 89. The endothelial tube is not drawn here. Lying on

this, and consequently as the innermost layer of the figure, we recognize at *b* a homogeneous, longitudinally striated,

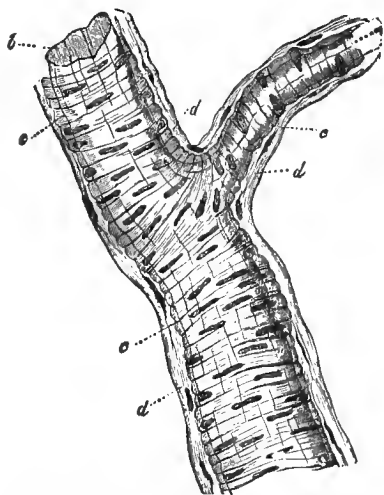


FIG. 89.—A small arterial trunk. At *b*, the homogeneous, non-nucleated inner layer; *c*, the middle layer, consisting of contractile fibre cells; *d*, the connective tissue external layer.

elastic membrane, the tunica serosa of the older anatomy. The same is surrounded by a layer of transversely running contractile fibre cells at *c*. The connective-tissue layer *d*, with longitudinally arranged cells, forms the last. Under certain circumstances, it may be very much thicker than in our figure.

Other small arterial trunks show the muscular layer to be constituted by several layers of fibre cells, lying over one another, as in Fig. 88, *d*, where the adventitia is again formed

of reticular connective tissue.

Larger trunks, finally, can no longer be surveyed in their totality, under the microscope. One must, therefore, examine singly the separately prepared layers, or make longitudinal and transverse sections through the hardened walls.

The further transformations, from those immediately following up to the most remote of the largest blood-vessels, consist in the following: The endothelial tube always remains a single layer; the connective-tissue adventitia does the same, but it increases in thickness; the connective-tissue bundles become more distinct, and elastic fibre reticula are more and more frequent, especially in the arteries. Both the middle layers, the serosa and media, begin on the contrary to become stratified; each of them consists of an increasing number of layers lying over each other. On this depends the growing thickness of the vascular walls. The inner

group of layers essentially preserve in their membranous layers the nature of the elastic tissue, and present the most heterogeneous varieties of the same with a longitudinal arrangement. The middlemost group changes into a system of alternating layers of elastic tissue and smooth muscles, both with a transverse direction, or also of connective tissue. The tunica media remains much thinner in veins than in arteries of similar size, and the result is that the walls of the former vessels are thinner. The endothelial cells of the arteries appear as narrow, lancet-shaped lamellæ; those of the veins are shorter and broader (p. 29).

Taking a small vein of about 0.25 mm. in calibre, we find succeeding the epithelium a serosa with fine, elastic, longitudinal reticula. The middle layer consists of several muscular layers, which have between them elastic reticula and connective-tissue layers. The adventitia shows longitudinally running connective tissue and a contingent of elastic fibres.

The appearance is different in middle-sized veins. The serosa has here become a group of layers. We now meet with homogeneous or striped layers with longitudinally arranged spindle cells, elastic membranes or elongated reticula. Indeed, even the elements of the smooth muscles may be continued in these inner groups of layers. The middle layers consist of connective tissue running transversely, with elastic reticula arranged in the same manner, and smooth muscles. Nevertheless, isolated elastic layers with longitudinal fibres also occur here. The adventitia is as usual; still it may also harbor contractile fibre cells.

The largest veins possess a similar serosa, though without the smooth muscles, while the media remains undeveloped and may be entirely absent. It shows scanty muscular elements, permeated by transverse connective tissue. Elastic longitudinal fibro-reticula have likewise maintained their position here. In the thick adventitia of many veins, one meets toward the interior with thick longitudinal muscles, as, for instance, that of the pregnant uterus, while the sinuses of the dura mater are entirely without muscles.

In the smaller arteries, the serosa and adventitia remain tolerably unchanged. Still, there frequently occur in the former reticular perforated elastic layers, so-called "fenestrated membranes," or free elastic longitudinal reticula; the media presents several layers of transversely directed muscles, lying over each other, and an elastic net-work is also developed in the fibrillated outer layer.

In the larger branches, the stratification of the inner and middle layers increases. In the latter, elastic plates with transverse fibres, are now interpolated between the muscular layers, and the elastic reticulum of the adventitia becomes thicker.

The largest arteries (Fig. 90) show under the endothelium (a), strongly stratified, the group of the inner vascular membrane (b).

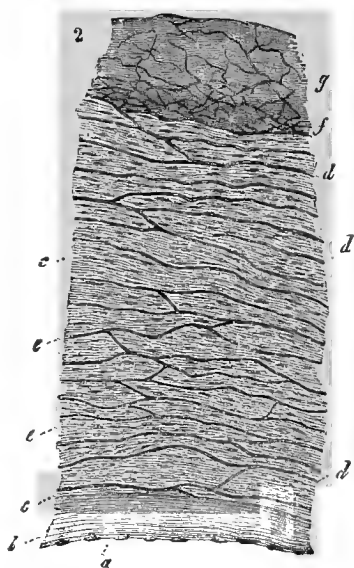


FIG. 90.—Transverse section through the walls of a large artery; *a*, endothelium; *b*, serosa; *c*, outer layer of the same; *d*, elastic, *e*, muscular layers of the media; *g*, adventitia; *f*, their elastic fibro-reticula.

The several lamellæ, in varying texture, present the entire multifariousness of the elastic tissue. Inwards, towards the endothelial covering, one may, indeed, meet with more homogeneous, or more striated layers with cellular reticula imbedded over each other (Langhans, von Ebner).

In the more middle group of layers the membranous character of the elastic fibrous net-work (*d*) becomes more and more prominent. Their fibres may be thinner or thicker; the membranous connecting substance may appear whole or perforated. The number of these elastic layers may increase to 30, 40, 50, and more. The muscles of the

middle layer (*e*) appear unequally developed; frequently not

to a high degree. The direction of the fibres is by no means exclusively transverse. In the outer portions of the media, fibrillated connective tissue occurs (Schultze, von Ebner). In the adventitia (*g*), finally, the elastic fibro-reticulum (*f*) acquires in an inward direction, in large mammalia, a very prodigious development.

The valves of the vessels consist of connective tissue with elastic intermixtures, and the endothelial covering.

Vasa vasorum is the name given to the capillary vessels which occur in the middle and outer layers of the larger trunks, and supply the nutritive materials to the walls of the vessel.

The vascular nerves terminate at the muscles of the media.

We pass to the arrangement of the capillary vessels in the human body.

It is known that they do not occur everywhere. Thus, the epithelial structures, with the crystalline lens, the cornea of the eye, and the permanent cartilages are non-vascular.

A peculiarity of the capillary division

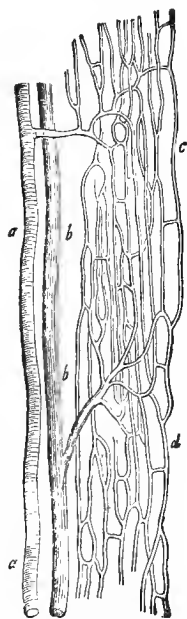


FIG. 91.—Vascular network of a transversely striated muscle; *a*, arterial, *b*, venous vessel; *c*, *d*, the capillary net-work.

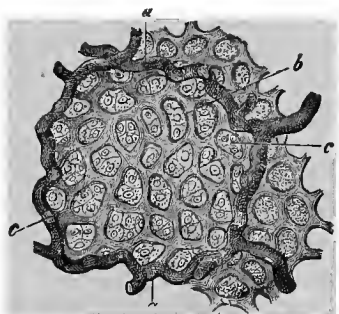


FIG. 92.—A pulmonary alveolus of the calf; *a*, larger blood-vessels, which run in the parietes of the alveoli; *b*, capillary net-work; *c*, epithelial cells.

consists in this, that the tubes by giving off branches do not become narrowed to a noticeable degree, and that by

the conjunction of the branches there are formed reticula of more regular, and frequently of extremely characteristic form.

The diameter of the capillaries (see above) is by no means the same in the different portions of the human body. The brain and retina present the finest of 0.0068 to 0.0065 mm, and less. The muscles have somewhat larger ones of 0.0074 mm. The calibre is again increased, somewhat, in those of the connective tissue, the external integument, and the mucous membranes. The lumen is greater in the capillaries of most of the glands, such as the liver, the kidneys, and the lungs. Here we have a diameter of 0.0099 to 0.0135 mm. The most considerable ones, finally, of 0.0226 mm., are seen in the bone medulla. That, with the larger blood corpuscles, even the finest capillaries of animals have a more considerable calibre, it is hardly necessary to remark.

The capillaries are sometimes more profuse, sometimes more scanty, in a part of the body. The size of the portion of the tissue comprised within their net-work is, accordingly, quite variable; it is small in the vascular, large in the non-vascular parts. The former have an energetic, the latter a sluggish assimilation. The lungs (Fig. 92) appear uncommonly vascular. Their capillary net-work, serving for respiration, is the most compact of the organism. The other glands approximate. The fibrous membranes, the tendons, the neurilemma are quite non-vascular.

The form of the capillary net-work is determined by the shape of the parts to be circumvoluted, the nature of the several elements, or of their arrangement.

We have, firstly, the straight, capillary net-work. A transversely striated muscle (Fig. 91) may represent this. The several filaments are surrounded by the uncommonly elongated meshes (*c*). The involuntary, smooth muscles also possess the same capillary net-work. Here, however, from the thinness of the elements, a bundle of fibres takes the place of the transversely striated filament.

Other parts with elongated elements—for example, the gas-

tric mucus membrane, with its long, thin, tubular glands—show a similar straight net-work.

We are familiar, from Fig. 48, with the fat cells, large, rounded structures. Their capillary reticulum, in correspondence with this, forms rounded meshes (Fig. 93). The small, arterial branch (*a*), and the small, venous branch (*b*) of an aggregation of these fat cells appear very distinct.

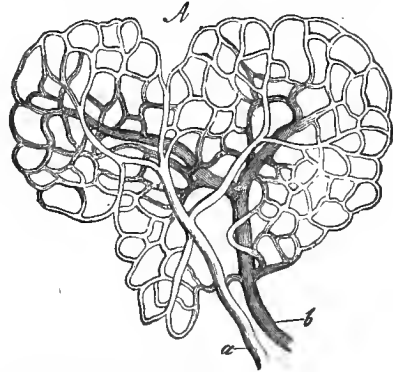


FIG. 93.—Vessels of the fat cells. The arterial (*a*), venous branches (*b*), with the rounded capillary network of a fat lobule.

We shall later, at the glands, become acquainted with very extended organs of a racemose structure. A rounded or elongated saccule (acinus) surrounds an aggregation of smaller parenchyma cells. The acini are likewise circumvoluted by a complete, quite similar, round network, like the individual fat cells.

A handsome, very characteristic arrangement is presented by the capillaries of the liver (Fig. 94). The liver—we shall return to it in greater detail subsequently—is divided into so-called lobules, into collections of radially arranged cells. The extensively developed capillary system maintains the same arrangement—a rounded, stellate one.

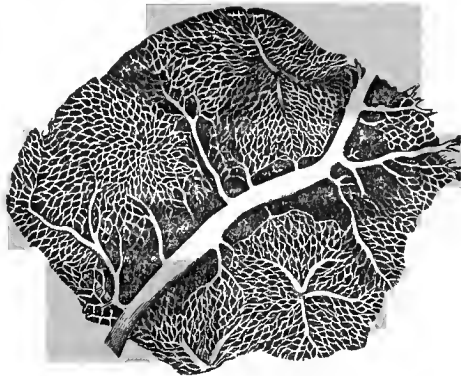


FIG. 94.—The capillary net-work of the rabbit's liver, crossed by a branch of the portal vein.

The human corium projects in microscopically small papillæ, which the thick epithelium (p. 32) surrounds with a smooth surface. The greater part of these papillæ contains a capillary vessel, which ascends on one side, bends over the top of the papilla, and descends on the other side. This is the capillary loop.

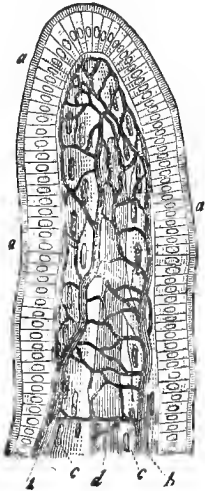


FIG. 95.—An intestinal villus; *a*, the cylindrical epithelium with its thickened seam; *b*, the capillary network; *c*, longitudinal layers of smooth, muscular fibres; *d*, central chyle vessel.

Larger papillæ occur on many of the mucous membranes; thus, on the dorsum of the tongue, as the so-called gustatory papillæ, the whole small intestine, as intestinal villi, to omit others. The simple capillary loops are here no longer sufficient (Fig. 95). Between them are interposed communicating capillaries and capillary net-works. Thus arises the looped net-work.

A quite peculiar formation is presented by the cortical layer of the kidney, in the so-called glomerulus or vascular coil (Fig. 96).

A microscopic arterial branch (to the right) divides, and each branch forms a convolution of closely crowded capillaries.

These portions, with educting canals, reunite, at last, into a single abducting vascular tube.

We here speak, therefore, of a centripetal (vas afferens) and a centrifugal vessel (vas efferens). From the latter arises, further below, a new capillary reticulum.

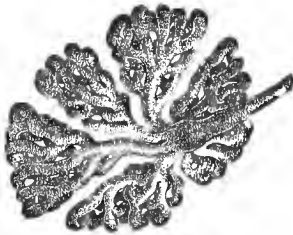

FIG. 96.—Glomerulus of the hog's kidney.

To study the capillaries, they must be injected from the larger trunks with transparent, colored (with carmine, Prussian blue) gelatine, at an elevated temperature. Opaque, granular masses (cinnabar, white lead, chrome yellow) were the more imper-

fect accessories of an earlier epoch. They are rarely used at present. Other vehicles for the coloring material, resinous, waxy masses, or etherial oils, are, at the most, only here and there employed for very special purposes.

The embryonic origin of the vessels is still attended with many obscurities.

The heart, a production of the middle germinal layer, is formed very early, and enters soon afterwards into activity. It is hollow from the commencement, and the large, adjacent blood-vessels likewise appear to possess the same characteristic.

With regard to the more particular details of this process, we must state that our present knowledge is little satisfactory.

According to Klein, the first large vessels of the hen's embryo are formed from cells of the middle germinal layer. The contents of the latter soon liquefy. A protoplasma shell now invests the enlarged and macerated cell-body with the original nucleus. From such cells are derived the first vascular wall, or endothelial tube, as well as the first blood corpuscles. The cell is said to swell, and the nuclei increase, and, as during this increase the nuclei assume a regular position, the protoplasma mantle finally divides into flat, endothelial cells. From these endothelial walls the first blood corpuscles are also said to take their origin by a process of constriction. They are said, however, to have another origin, also.

The first vascular walls and the first blood corpuscles, therefore, derive their origin from the same cells.

We add to this the important fact that it is only subsequently to the use of nitrate of silver solution that the primary vascular wall is resolved into the familiar endothelial cells.

A process of aggregation then leads, in a secondary manner, to the formation of the additional external vascular layers, a serosa, media, and adventitia. There is here, also, a great want of accurate observations.

Capillaries—we assume, at first, a homogeneous, nucleated protoplasma tube—are present at an early period.

They soon present further metamorphoses. These may be beautifully recognized in the transparent tail of the tadpole (Fig. 97). It is a sort of budding process.

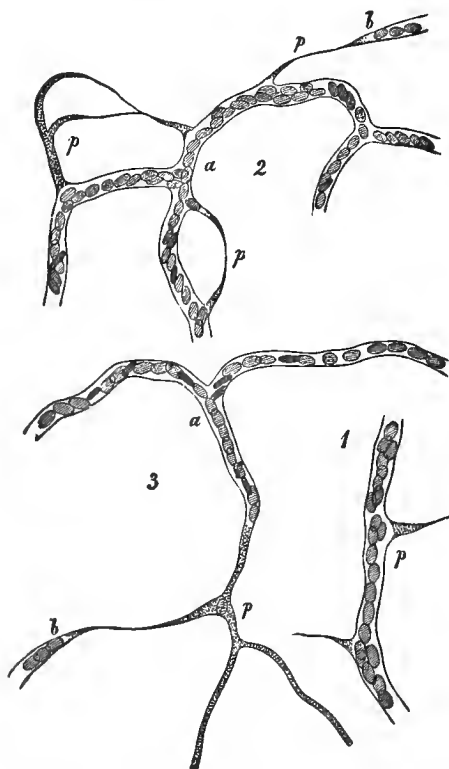


FIG. 97.—Development of finer capillaries in the tail of the tadpole; *p, p*, protoplasmic buds and cords.

From the parieties of already mature neighboring capillaries is supplied a protoplasm, capable of further independent development, in the form of pointed cones (Fig. 97, 1, 2, *p, p*). By their confluence (2) the latter are, at first, transformed into solid cords. If, then, the axial portion of the meanwhile enlarged cord melts down, we have the protoplasmic tube (3, *p*). By a further metamorphosis of the lat-

ter, the formation of new nuclei appears to take place. The endothelial tube is finally established by the protoplasmic walls and the young nuclear formation.

The abnormal new formation of vessels in later life likewise follows the old embryonic law.

W. L. Fuill, M. D.
Veterinarian,
1526 Race St., Phila.

TENTH LECTURE.

THE LYMPHATICS AND THE LYMPHATIC GLANDS.

WHAT is understood by lymph we have already mentioned in our second lecture (p. 27). It was the blood plasma which had passed out through the capillary walls, and which gave off the dissolved nutritive constituents to the tissues, and took up in exchange the products of the decomposition of the latter. We even then mentioned that this fluid, which is uninterruptedly supplied from the blood current, must necessarily be removed. The arrangement serving this purpose must now be discussed.

Our present course will, however, be the reverse of that followed in the previous lecture; for the large and medium lymphatic discharge tubes are more accurately known, while numerous uncertainties still prevail concerning the knowledge of the finer and finest elements.

Let us commence with the ductus thoracicus, the terminal large discharge tube of the lymphatics. We here meet with a condition corresponding to the walls of the veins.

The endothelium is surrounded as a serosa by several layers of a striated substance, and then by a net-work of longitudinal elastic fibres. As a middle layer, we have next, longitudinally running connective tissue, and then transverse muscles. The adventitia also shows remains of the latter tissue. Valves are not wanting here, nor afterwards in the finer lymphatics.

Descending to the latter, the stratification, as in the veins, becomes more simple; but more accurate studies are here still necessary. In small trunks of 0.2 to 0.3 mm., the four characteristic vascular layers have been found still present.

The adventitia, media and serosa gradually disappear, and

we have remaining only the endothelial tube with cells similar to those of the blood-vessels. Here also we still meet with valves and isolated nodal or ampulla-like enlargements. Such vessels remain distinctly demarcated from the immediate neighborhood. The relation of these passages to the blood-vessels varies greatly. For the most part, both vessels simply run alongside of each other. Not unfrequently an arterial branch is accompanied by a pair of lymphatic canals. One may then readily commit an error, namely, the assumption that the blood current is invested by a lymphatic. The latter condition does, indeed, actually take place (Fig. 88, *c*), although rarely, as many assert.

At last, however, the appearance of the lymphatics changes; the outer surface of our vascular cells has now grown firmly together with the surrounding tissues; thus there arises at the first examination the impression of a cavity and cleft. Formerly this was generally considered to be the true interpretation, until the employment of the dilute solution of nitrate of silver opened our eyes (Fig. 98, *a*).

For the examination of the finest terminal lymphatics, artificial injections are naturally again requisite; and, indeed, to a higher degree than in the capillaries of the blood passages, where under favorable conditions the colored cells permit the fine tubes to stand out. The lymph, a colorless fluid, poor in cells, does not do this, as is known, and only the chyle vessels, overladen with fat, become at times distinctly prominent without any further assistance.

But, as is known, the lymphatics have no affluent tube comparable to an artery; they show merely a capillary division and effluent canals, comparable to the veins. Filling the latter downwards is, almost without exception, prevented by the resistance of the valves. A highly celebrated modern anatomist, Hyrtl, rendered the service of discovering a very

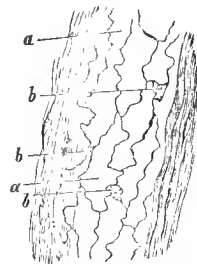


FIG. 98.--Lymphatic canal from the large intestine of the Guinea-pig: *a*, vascular cells; *b*, spaces between the same.

simple and at the same time extremely effective method of injection. We allude to his "puncturing method."

The point of a fine canule is carefully forced into a tissue which is thought to contain lymphatics, and an attempt is made to carefully and slowly inject a wounded lymphatic. Many of the attempts are, it is true, thoroughly unsuccessful, still practice makes the master, and with patience and perseverance the object is finally accomplished. Teichmann's elegant work on the lymphatics, not to mention others, has shown this.

Let us commence first with the chyloferous vessels which, at the termination of an abundant digestion, by their fatty contents stand out as dark canals.

In the intestinal villus (Fig. 95), there lies, occupying the axis, a cæcal canal (*a*), surrounded by a looped reticulum of capillaries (*b, b*). Its transverse diameter is 0.0187 to 0.0282 mm. At the first cursory examination it is a lacuna; with more accurate investigation one recognizes here, as elsewhere, the thin walls formed of plates of cemented endothelial cells.

The condition just mentioned also characterizes the remaining portion of the lymphatics. The canals of the latter are more irregular, angular and wider, and situated nearer the interior. They are again surrounded by the external, much finer and more regular capillary net-work of the blood current.

Let us now pass from the intestinal villi, further downwards, and examine the inferior flatter portion of the mucous membrane of the small intestine in which these cæcal lacteals from the intestinal villi bury themselves.

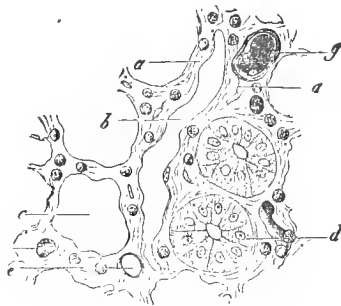


FIG. 99.—Transverse section through the mucous membrane of the small intestine of the rabbit (near the surface); *a*, the reticular connective tissue containing lymph cells; *b*, lymph canal; *c*, transverse section of a Lieberkühn's gland; the same with the cells; *e, f, g*, blood-vessels.

Let us look at Fig. 99. Here, in connective tissue con-

taining lymphoid cells (*a*), we discover the sections of blood-vessels (*e*, *f*, *g*) and of glands (*d* and *c*). Our attention is then attracted by an oblong cleft (*b*). It is a lymphatic canal consisting of endothelium.

Our three drawings, Figs. 100, 101 and 102, contain further representations of such lymphatic passages.

The cæcal commencements are quite perceptible in the first two figures.

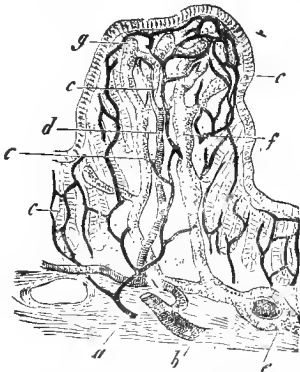


FIG. 100.—A colon papilla of the rabbit, in perpendicular section; *a*, arterial; *b*, venous trunk of the submucous tissue; *c*, capillary net-work; *d*, descending venous branch; *e*, horizontal lymphatic (sheathing an artery); *f*, lymph canals of the axial portion; *g*, their cæcal commencements.

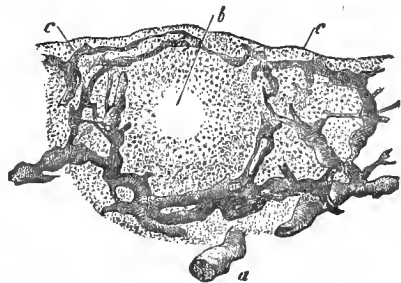


FIG. 101.—Trachoma gland from the conjunctiva of the ox, with injected lymphatics, in vertical section; *a*, submucous lymphatic vessel; *c*, its distribution to the passages of the follicle *b*.

Thus far all is clear and intelligible. But we now come to an uncertain and much disputed territory.

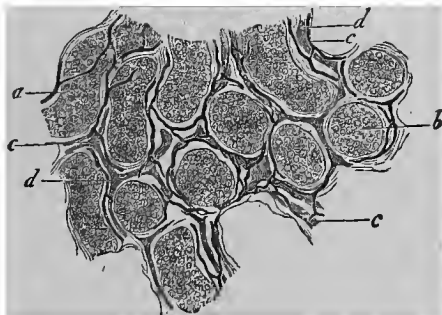

FIG. 102.—From the testicle of the calf. Seminiferous canals seen in more oblique, *a*, and more transverse sections, *b*; *c*, blood-vessels; *d*, lymphatics.

The connective tissue, this substance which is so infinitely

diffused throughout the human body, is permeated by millions of clefts and spaces. They receive nutritious plasma-
matic or lymphatic fluids, and contain wandering lymphoid cells. In the serous cavities and sacs we meet with an immense lymphatic lacunar system; nevertheless, the quantity of fluid is small.

Now, do these latter lymphatic passages, lined with endothelium, pass over continuously into these connective-tissue canals, and do the former open into the system of serous caverns?

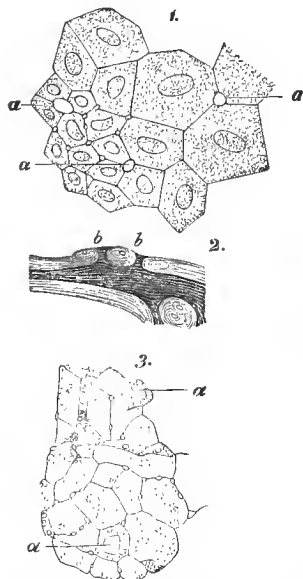
It is just these questions which we are now to answer. Let us tarry for an instant at the latter relations.

A communication of the lymphatics with the cavity of the serous sac has, for several years, been recognized with certainty. The names of Recklinghausen, Ludwig, Dybkowsky, Schweigger-Seidel and Dogiel deserve mention here.

Recklinghausen discovered at the under surface of the centrum tendineum of the rabbit (Fig. 103, 1), between the epithelium, apertures (*a*) of not inconsiderable size, or at least greater than the diameter of a red blood corpuscle. He saw how the milk and color granules entered here and reached the lymphatics of the diaphragm. Other short lateral passages of the lymphatics were then found to open into these apertures (2, *b*). No further doubt can, therefore, exist here.

FIG. 103.—1. Epithelium of the under surface of the centrum tendineum of the rabbit; *a*, apertures or stomata; 2, section through the pleura of the dog; *b*, free opening, short, lateral passage of the lymphatic canal; 3, epithelium of the mediastinum of the latter animal; *a*, pores.

The question assumes a different shape, however, concerning the relation of the above mentioned connective-tissue chasm to the vascular system.



According to Recklinghausen, these passages are directly connected with the lymphatics. He has given them the name of the "juice canals," a denomination which Waldeyer subsequently changed into "juice clefts."

I regret to be obliged to contradict the former investigator. The conservative injection teaches nothing of the kind. I dare to assert this after numerous personal studies, and I appeal, besides, to the testimony of distinguished investigators in this department of the technology of injection. I mention the names of Hyrtl, Teichmann, His and Langer. By immoderate pressure (in normal life it should never be attained), it is true, these chasms or stomata become filled with the colored mass. For an illustration, we refer to the small spaces between the vascular cells of the lymphatics (Fig. 98, *b*). We have distended them inordinately or, perhaps, forced out a soft substance filling the spaces.

The normal blood-vessels act in a similar manner. Here, by careful injection, no one fills the "juice clefts" of the connective tissue. No one could show a direct transition of the vessel into these passages.

Under abnormal conditions of the living body, however, with a vascular tube over-filled with blood, the stomata even here become permeable. If, now, the cadaver be artificially injected, the colored substance penetrates these juice passages (von Winiwarter, Arnold).

Thus we regard the matter at present.

Important constituents of the lymphatic apparatus of the mammalia are represented by the lymph-nodes or, as they were earlier less happily named, the lymphatic glands. They interrupt the course of the vessels simply or manifoldly. They are to be denoted as one of the chief forming places of the lymphoid cells. Within them takes place, furthermore, a lively reciprocative action between the lymph and the blood.

A lymphatic gland may appear globular, oval, or bean-shaped (Fig. 104). In the latter case it presents a so-called hilus most distinctly. When the former has reached a certain size,

induction lymphatic vessels, vasa afferentia, penetrate, for the most part manifoldly, into its convex surface (*f, f*). The educting vessel at the hilus (*h*) remains, at the same time, frequently single.

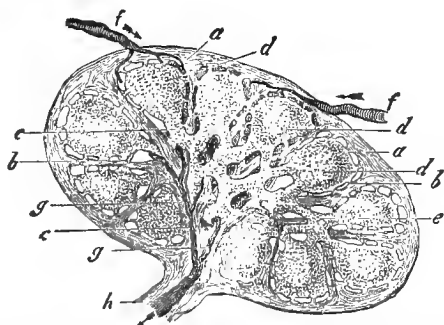


FIG. 104.—Section through one of the smaller lymphatic glands, with the current of the lymph—half diagrammatic figure; *a*, the capsule; *b*, septa between the follicles of the cortex (*d*); *c*, system of septa of the medullary substance as far as the hilus of the organ; *e*, lymph tubes of the medulla; *f*, lymphatic passages, which surround the follicles and flow through the spaces of the medulla; *g*, union of the latter into an afferent vessel (*h*) at the hilus.

It is surrounded by a connective-tissue sheath (Fig. 104, *a*, 105, *f*) with a muscular admixture. This capsule continues inwards in a similarly constituted but perforated septum (Fig. 104, *b, c*, 105, *g, k*), which finally unites towards the hilus in a thicker connective tissue mass (“hilus-stroma” of His). In the lymphatic glands of large animals this “septum system” is immensely developed; in small creatures it is often uncommonly slight.

We distinguish in the lymphatic glands a cortical and a medullary layer. The former consists of rounded or irregular bodies of 0.5 to 2 mm. and more, the follicles (*d*), which in the smaller organs are placed in single, and in larger glands in double or manifold rows.

The medullary substance is composed of reticularly united strands, which spring from the inner side of the follicle, pass through the septum, and thus constitute a connection between these structures of the cortical layer (Fig. 104, *e*, 105, *d, e*). The transverse diameter of the strands varies extraordinarily, from 0.04 to 0.13 mm. and more.

The follicles and medullary strands are never closely applied to the sheath and septa (Figs. 104, 105); a system of clefts is always left. We shall soon learn their signification.

The follicle (Fig. 105) consists of reticular connective tissue

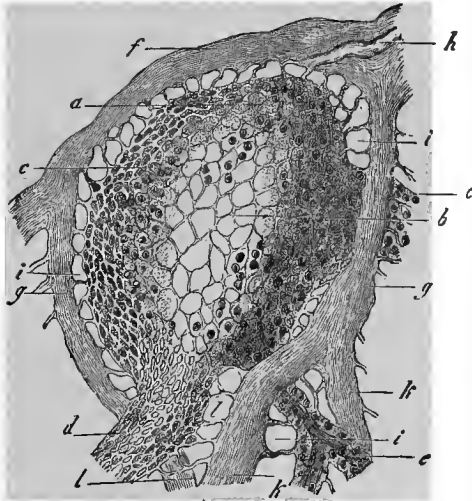


FIG. 105.—Follicle from a lymphatic gland of the dog, in vertical section; *a*, reticular framework of the more external, *b*, of the internal portion; *c*, fine reticulum of the surface of the follicle; *d*, origin of a larger, and *e* of a finer lymph tube; *f*, capsule; *g*, septa; *h*, division of the one; *i*, investment space and its tenter-fibres; *k*, vas afferens; *l*, attachment of the lymph tubes to the septa.

(Fig. 105, *b* and *a*), containing an excessive number of lymphoid cells. At the surface the meshes of the connective tissue reticulum become much more narrow (*c*).

From it arise fibres which, attached to the inner side of the capsule and the outer surface of the septa, keep the follicle stretched, as the frame does embroidery. I once named them "tenter-fibres," and the cup-like spaces permeated by them, the "investment spaces" of the follicle (*i*). The follicles themselves are held together in numbers, side by side, by connecting bridges of their own tissue.

The same tissue, containing lymphoid cells, and having either its own vessel in its axis (Fig. 105, *d*, *e*, 106, *a*) or an entire rectilinear capillary reticulum (Fig. 107, *a*), forms the

strands and reticulum of strands of the medullary substance. These "lymphatic tubes" are again, according to my demonstration, attached by similar tenter-fibres (*b*) to the septa (Figs. 105, *l*, and 107, *b*), and also connected together by a connective-tissue cellular network.

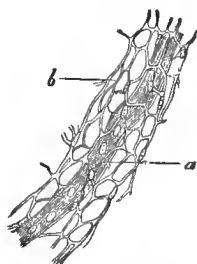


FIG. 106.—Lymph tube from a mesenteric gland of the dog; *a*, capillary vessel; *b*, reticular connective tissue, forming the tube.

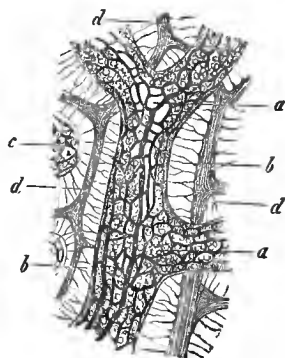


FIG. 107.—From the medullary substance of an inguinal lymphatic gland of the ox; *a*, lymph tube with the complicated system of vessels; *c*, piece of another; *d*, septa; *b*, connecting fibres between the tube and septum.

The lacuna system between the lymphatic tubes we call the lymphatics of the medullary substance. That this arises from the investment spaces of the follicle is taught by the Figures 104, *e*, and 105, *i*, *l*.

The blood-vessels attain the interior of the organ, for the most part, from the hilus. The arterial affluent, and venous effluent tubes are contained in isolated lymphatic tubes. In the follicles they form a broad-meshed, rounded, capillary network.

Besides these, other smaller vascular branches, surrounded by tenter-fibres, may enter our organ from the capsule.

What purpose is served by these spaces or canal-work between the capsule and septum system, on the one hand, and the follicles and lymph tubes on the other?

We have already answered this. It is the path of the lymph in the interior of the organ.

On perforating the capsule, the vasa afferentia lose their walls (Fig. 105, *h*); they become lacunar passages, but are, it

is true, still lined with the familiar endothelium in the cortex. In the medullary substance the latter cells are absent. The vas efferens, with its independent parietes, is again formed towards the hilus by the conjunction of the medullary canals. The formation of the vas efferens is not easy to examine, as I, the discoverer of this condition, know from former studies. Fig. 104, *f*, *g*, *h*, represents this current.

Under natural conditions, there are also lying in the cavernous passages of our organ, numerous lymphoid cells.

Whence come the latter? They have simply, we remark, emigrated actively and passively through the narrow-meshed, reticular surfaces of the follicles and lymphatic tubes. We thus comprehend that a vas afferens may present merely a few lymphoid cells, while the vas efferens may subsequently appear relatively rich in these cellular elements.

I do not need to remark that the current of fluid through the lymphatic gland can only be determined by the aid of troublesome artificial injections, as His and I can affirm. My studies were, at that time, the first.

ELEVENTH LECTURE.

THE REMAINING LYMPHOID ORGANS WITH THE SPLEEN. THE SO-CALLED BLOOD-VASCULAR GLANDS.

STRUCTURES, which are identical with the follicles of a lymphatic node, and appear partly single, partly grouped, but are always without the medullary substance of the former, are met with manifoldly in the human and mammalian body. In older times they were given the erroneous name of "glands."

Among these are included, as isolated occurrences, the so-called lenticular glands of the gastric mucous membrane; furthermore, the follicles in the mucous membrane of the small and large intestine, to which has been assigned the name of the solitary glands. Groups of lymphoid follicles form the amygdale or tonsils, then the Peyer's glands of the intestinal canal, as well as the so-called trachoma glands or lymphoid follicles of the conjunctiva. A large allied organ of the earlier period of life is presented in the thoracic gland or thymus. Finally, the spleen, with a similar although considerably modified structure, terminates this series.

We comprehend all these, including the lymphatic nodes, under the denomination of the "lymphoid" organs.

Commencing with a so-called solitary gland of the gastric or intestinal mucous membrane, we find it to be an ordinary lymphoid follicle surrounded by a cup-like cavity. The latter is again permeated by connective-tissue fibres which, passing to the tissue of the adjacent mucous membrane, constitute the connection with the neighborhood. The so-called solitary glands of the small intestine—as I ascertained years ago by injection—are again washed by the lymph. In regard to the "lenticular glands" of the stomach, the authen-

tication has not yet been furnished, but the facts are undoubtedly the same.

Let us now pass from the simple to the complicated.

Let us take the amygdale or tonsils (Fig. 108). These, subjected to many changes in the mammalia, show in the

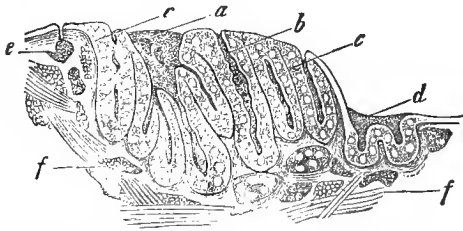


FIG. 108.—Tonsil of the adult (after Schmidt); *a*, larger excretory duct; *b*, more simple one; *c*, lymphoid parietal layer, with follicles; *d*, lobule, reminding one of a lingual follicle; *e*, superficial; *f*, deeper mucous follicle.

human body a complicated system of fossæ in the surface of the mucous membrane. The passages of these depressions open in part conjointly (*a*), in part separately (*b*). At the periphery of the follicular aggregation, there are often still smaller and shallower fossæ (*c*). The cavities are lined with the pavement epithelium of the mouth. A thick, lymphoid parietal layer (*c*), surrounded externally by a connective-tissue capsule, invests the entire system of fossæ. In this lymphoid tissue occur rounded bodies of a large-meshed structure and a brighter appearance. These are the follicles. In the narrow-meshed connecting tissue, one recognizes reticular passages which circumvallate these bodies. They form the paths for the lymph, as the injection shows.

Simplified formations are presented by the lingual follicles on the posterior portion of the dorsum of the tongue. Their structure reminds one of the place *d* of our Fig. 108.

The so-called trachoma glands have a similar structure, but spread out flatter, and are without fossæ (Fig. 101). They likewise present brighter follicles (*b*), as well as a narrower-meshed and therefore, again, more opaque connecting layer. In the latter runs a more developed lymphatic canal-work (*c*),

which surrounds the follicle with a reticular passage, and commences in a cæcal manner just beneath the epithelium.

Let us also discuss the Peyerian glandular plates. They belong to the lower portions of the human small intestine, and consist, according to their extent, of a very unequal number of aggregated lymphoid follicles. In mammals, where however great mutability prevails, they may also be met with in the large intestine. The human *processus vermiformis*, and in still higher development that of the rabbit, forms an enormously developed continuous Peyer's plate.

The shape of our follicle changes according to the species of animal. They are rounded in man (Fig. 109) and in the Guinea-pig, and strawberry-shaped in the small intestine of the rabbit, while in the vermiform process of the latter animal

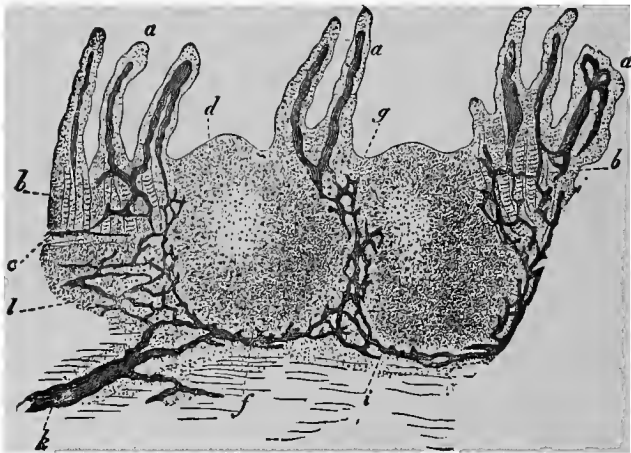


FIG. 109.—Vertical section through a human Peyer's patch; *a*, intestinal villi; *b*, Lieberkühnian glands; *c*, muscular layer of the mucous membrane; *d*, apex of the follicle; *e*, basis portion; *f*, lymph-passages around the follicle; *g*, at the base of the same; *h*, lymphatics of the sub-mucous tissue; *l*, lymphoid tissue of the latter.

an elongated thing, reminding one of the sole of a shoe, is met with. A similar appearance is presented by the Peyerian follicles in the ileum of the ox.

Let us now pass to a closer analysis of our structure.

In the follicle (Fig. 109), we distinguish three parts, the apex (*d*), covered only by epithelium, and projecting between adjacent villi (*a*) into the lumen of the intestine, then a middle zone (at the elevation of *c*), and, finally, a basis portion (*f*). The middle zone and basis portion are buried in the sub-mucous cellular tissue. Here—and we are reminded of the tonsils and trachoma follicles—the middle and lower portions are united by a more narrow-meshed lymphoid tissue. The surfaces of both these parts are again surrounded by a lymphatic canal-work in a reticular form. Not so in the follicles in the small intestine of the ox, and in the processus vermiformis of the rabbit. In these the basis portion is surrounded, similar to the follicles of a lymphatic gland, by a connected cup-like

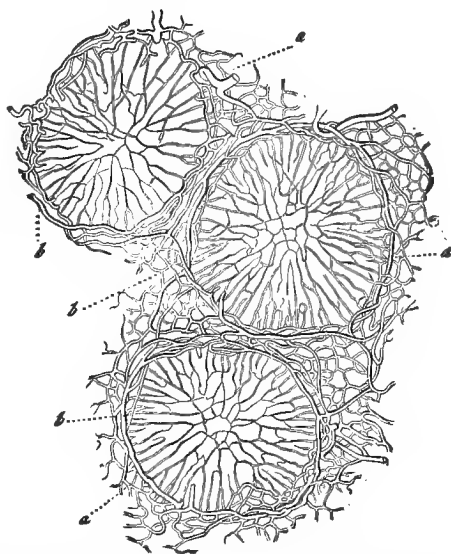


FIG. 110.—Transverse section, through the equatorial plane of three Peyerian follicles of the rabbit; *a*, the capillary net-work; *b*, the larger annular-shaped vessels.

lymphatic investment space, while in the middle zone, it is true, the reticular passages are still retained.

The lymphatic injection shows interesting conditions, reminding us of those of the lymphatic glands, and the discover-

ies made in the tonsils and trachoma follicles confirm what follows.

The chyle vessels of the intestinal villi (*a*), are the vasa afferentia (p. 108). Passing further down, they form the lymphatic net-work (*g, i*), which surrounds the follicle, as the thread does the toy ball of the child. From these arise, at the base of the follicle, the efferent lymphatics (*h*), comparable to the vas efferens of the lymphatic gland.

The capillary net-work of the Peyer's plates appears extraordinarily developed. Fine capillaries permeate the follicle in a radial direction (Fig. 110, *a*); additional tubes (*b*) form a no less elegant interfollicular net-work.

The thymus consists of lobular groups of a reticular connective tissue containing lymphoid cells. The interior of the lobule is hollow, connected on all sides with a convoluted main canal. Here we also meet with an elegant capillary reticulum, which differs in man and the calf in the arterial and venous arrangement. The lymphatic passages require more accurate investigation. The retrogression of the enigmatical organ begins before and with puberty. Fat cells in great quantity are developed at the expense of the lymphoid tissue.

The spleen constitutes the most difficult organ of the lymphoid group. It has been the object of many researches in old and modern times. We have, indeed, progressed further than our predecessors, but much still remains a matter of controversy. I here give only what I, after numerous personal studies, regard as correct.

Similar to a lymphatic gland, our organ is surrounded by a fibrous envelope containing sometimes more, sometimes less smooth muscular tissue. This sends off again, in an inward direction, an interrupted system of septa. The latter, also called the trabecular system of the spleen, is extensively developed in large mammals, while in small creatures (marmot, rabbit, Guinea-pig, rat and mouse) only scanty rudiments of it are met with. We are, therefore, once more reminded of the lymphatic glands (p. 108).

It is best to commence the investigation with one of the latter

creatures, a rabbit (Fig. 111), for instance. In the larger mammals, this system of septa considerably impedes our comprehension of the relations, which is already difficult.

The soft spleen tissue proper consists of two substances. In the first place, we find, scattered throughout the entire thickness of the organ, rounded, oblong or irregular structures

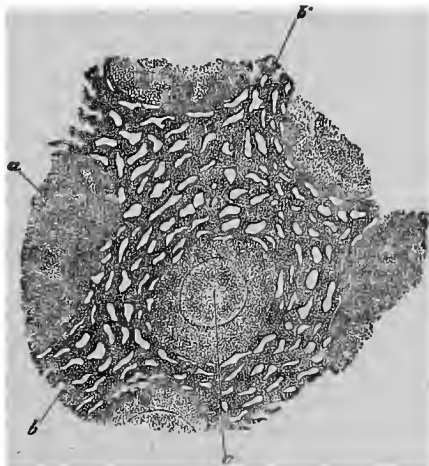


FIG. 111.—Rabbit's spleen; *a*, Malpighian corpuscles; *b*, reticular frame-work of the pulp.

of a whitish color. Sometimes they stand out sharply, at others they can only be recognized with difficulty. In many species of animals they are observed crowded, in others more scanty. Their size slowly decreases in the smaller mammalia. These are the Malpighian corpuscles of the spleen or—let us say at once—the lymphoid follicles of our organ (*a*).

Between them appears a very soft, and in consequence of its immense wealth of blood, dark red mass, the so-called spleen-pulp. The microscopic analysis of the same shows a system of reticularly connected canals (*b*), which connect adjacent Malpighian corpuscles with each other, and leave a likewise retiform space—or cavernous system between them. The pulp is, therefore, suggestive of the medullary substance of the lymphatic glands, as are the Malpighian corpuscles of the follicles of the latter.

Both portions of the spleen tissue are, however, shoved through each other; it is, therefore, impossible to speak here of a special, cortical, or medullary layer.

We next examine the lymphoid follicle; and here we again meet with the old familiar reticular connective tissue, filled with an excess of lymphoid cells, forming in the interior a larger meshed, on the surface a more narrow meshed reticulum. The capillaries of the interior are also readily recognized.

The tissue—we repeat—of the pulp strands (Fig. 112, *a*)

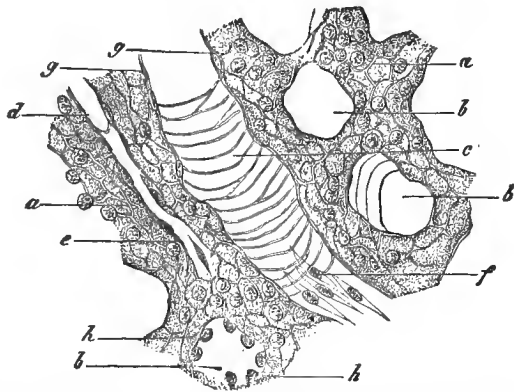


FIG. 112.—From the pulp of the human spleen brushed preparation (combination); *a*, pulp strand with the delicate reticular frame-work; *b*, transverse section of the caverni; *c*, longitudinal section of such a one; *d*, capillary vessel in a pulp tube dividing up at *e*; *f*, epithelium of the venous canal; *g*, side view of the latter; *h*, its transverse section.

arising from the surfaces of the Malpighian corpuscles presents, on the contrary, a considerable modification of the reticular connective substance, of extremely fine delicate texture and with very small meshes, so that only one or a few lymphoid cells find room in the latter. The surface of this pulp tube preserves the same reticular character. If we adjust the focus to the fundus of the caverni invested by them, we find numerous transversely arranged fibres (*c*). These passages are lined with flat, spindle-shaped cells (*f*), which, indeed, as the transverse section (*b*) teaches, have globular nuclei. We have once more before us a vascular endothelium;

only its cell borders are, by way of exception, not cemented to each other. If we also add to this that capillaries run in the axis of the pulp strands, and that in the narrow reticulum of its tissue regular red blood corpuscles are met with, sometimes fresh and unchanged, sometimes shrivelled and in various stages of disintegration, we have then described the most essential portion of the structure of the tissue of the spleen.

In order, however, to gain a further insight, we must now turn to the vascular arrangement of this strange organ.

This is very complicated and quite peculiar, and it is just here that the views of investigators are diametrically opposed to each other.

The *arteria lienalis* buries itself, in the ruminantia unramified, otherwise, as a rule, with several branches, directly into the so-called hilus. The latter become further divided in the interior, and finally break up, at an acute angle, into a number of fine terminal branches. These, called *penicilli*, and peculiarly formed, resemble the branches of a willow stripped of its foliage. On these branches (but no longer on the *penicillus*) sit the familiar Malpighian corpuscles, like the berries on the stem of the grape.

The arteries and the veins are still invested by a connective-tissue sheath, which is continuous with the septum system of the organ. This sheath, like the entire vascular expansion, is very different in the several varieties of animals; it is slight and rudimentary in the small, complicated and thick in the large mammalia.

Pausing now, however, at that of man, we find the arteries and veins, already divided into 4 to 6 branches, passing in and out of the organ. Up to trunks of 0.2 mm. they are invested in common by a connective-tissue sheath. The latter has at first a parietal thickness of about 0.25 mm., diminishing to 0.1 mm., whereby arteries of 0.2 and veins of 0.4 mm. are still invested in common. There is now a gradual separation of the venous from the arterial branches. The sheath in its original condition is continuous for a less distance over

the arteries ; it is gradually changed into a reticular connective tissue containing lymphoid cells, a metamorphosis in which the adventitia soon participates. The sheath structure is extended somewhat further over the venous branch ; at last its fibres begin to separate, and it is also lost in the septum or trabecular system of our organ.

From this lymphoid metamorphosis of the artery arise the already familiar Malpighian corpuscles of the spleen. They lie in part on the point of ramification of arterial branches, in part laterally on the unramified vascular tube. Finally—and it is a frequent occurrence—the arterial branch passes through the centre of the follicle. If we examine more closely, we find that no line of demarcation can be drawn between the separate follicles and this elongated lymphoid covering of the arterial branch. Every Guinea-pig's spleen teaches us this.

In the follicle, we never meet with a venous branch, but, rather, a capillary reticulum with rounded meshes, sometimes scantily and poorly developed, sometimes more abundantly. The source of supply varies ; sometimes it is branches of the follicular artery, sometimes it is through the adjacent pulp-tubes.

We have now to follow the further course of the arterial offshoots, the so-called penicilli of the spleen. They enter the pulp-tubes of our organ, to pass through their axis and to become capillaries. The capillary reticulum of the Malpighian corpuscle also, at last, sends its offshoots down into the adjacent pulp-tubes (Fig. 113, *e*).

Now, these capillaries of the pulp-tubes are quite peculiar.

We follow them by the greatest attention for a certain distance (on an uninjected spleen or in a good injected preparation), then the capillaries (Fig. 112, *d'*) commence to be uncertain and indistinct (*e*). Separated cell-demarcations may still be recognized ; but soon even these disappear. We are in the presence of a lacuna—a finest blood current without walls (Fig. 113, *e*).

Let us recall to mind that the tissue of the pulp-tube pre-

sents a reticulum with very narrow meshes, in the interspaces of which one, or, at the most, a few lymphoid cells find place; and let us not forget that the pulp-tubes possess, superficially, the same reticular character, covered by an endothelium consisting of separate, uncemented cells.

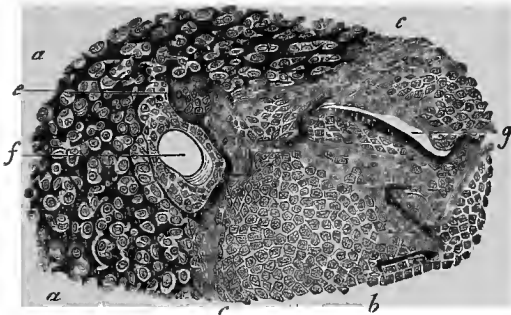


FIG. 113.—From the spleen of the hedgehog: *a*, pulp, with the intermediate currents; *b*, follicle; *c*, boundary layer of the same; *g*, its capillaries; *e*, transition of the same into the intermediate pulp-current; *f*, transverse section of an arterial branch, at the border of the Malpighian corpuscles.

If we adhere to this previously described textural condition, the lacunar capillary blood current, which arises after the loss of the capillary walls, will present no further considerable difficulty. As the failing branch of a drying brook wanders at last between the pebbles of its bed, slender and scanty, so is it with these finest blood currents. The lymphoid cells resemble the pebbles.

Still, the blood current contains cellular elements and the red blood corpuscles in excess. A portion of the latter slip through with their pliable, smooth surface; others stick fast.

For our colored elements, however, as we have already learned, movement is life, rest is death. Thus are explained those numerous corpses and fragments of the colored blood cells in the spleen, which we mentioned above (p. 119).

Something additional is also satisfactorily explained by this. The closely crowded amœboid lymph cells are capable of taking up into themselves the imprisoned blood corpuscle

or the fragments of its corpse (p. 9). These are the blood-corpuscle-containing cells of the spleen, occurrences which, many years ago, caused so much racking of the brains, and yet are, at present, so easy to interpret. Let us remember the amœba of our Fig. 3.

We have remembered the dead: let us now return to the living. What becomes of these finest blood currents after they have successfully passed through the narrow mesh-work of the pulp-tubes?

If our description has thus far been altogether comprehensible, the answer follows of itself. These currents enter the system of caverni, which Fig. 112 shows between the pulp-tubes *b* and *c*.

Let us pause for a moment. If we inject a rabbit's and a Guinea-pig's spleen, or the organ of a new-born child, from the vena lienalis, it is a mere child's play to instantly fill these reticular spaces between the pulp-tubes (Fig. 114, *c*).

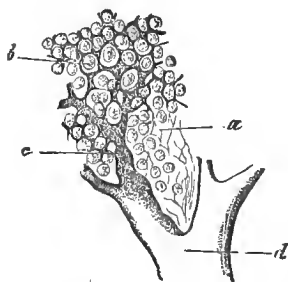


FIG. 114.—From the sheep's spleen (double injection); *a*, reticular framework of the pulp; *b*, intermediate pulp current; *c*, its continuation into the venous roots, with incomplete walls; *d*, venous branch.

Thus—we return to the inverted course once more—the lacunar pulp current passes over into these spaces of the pulp, into the “cavernous veins” of Billroth. From the latter, presenting many diversities, it is true, according to the variety of animal, arise two veins (*d*), enclosed in continuous although very thin walls.

We said previously (p. 121) the spleen was a burying-place of the red blood corpuscles. This requires no further discussion now. On the other hand, however, the spleen forms a generating focus of these elements, since it contributes lymphoid cells, the substitutes of those colored elements, to the blood current. This also requires no further discussion; certainly not, when we recall to mind the reticular surfaces of the Malpighian corpuscles, and of the pulp-tubes, and when

we think that milliards of lymphoid cells are here surrounded by perforated surfaces.

When our organ becomes enlarged in its pulp, the contact surfaces between the blood current and the lymphoid tissue increase materially. The latter now sends off more considerable quantities of its cells into the former. The number of the colorless blood corpuscles is thus necessarily increased. This is the lienal leucæmia, as it is called by the doctors, a disturbance of the equilibrium between the blood and spleen tissue, with the saddest consequences.

Lymphatic passages occur with certainty in the capsular and trabecular systems of the spleen. As to what is thought to have been met with in the true lymphoid tissue, it stands on a weak foundation.

In the embarrassment of our knowledge we here include several parts of the body which a former epoch has, like the lymphoid organs described, also called "glands," and for which their successors found the likewise very unsatisfactory name of the "blood-vascular glands."

We speak of the thyroid gland, the suprarenal capsule and the apophysis cerebri, structures which to the present time mock all physiological explanation, and once more confirm the old saying, that even the trees do not grow up into heaven.

The thyroid gland, the *glandula thyroidea* of the anatomist, lies, as is known, in front of the respiratory passage leading to the lungs. Every one in the Canton of Zurich knows that it forms the goitre, that national decoration. We physiologists are, unfortunately, scarcely able to say more concerning it than the people.

Let us, then, examine the strange organ somewhat more closely.

In a connective tissue frame-work we meet, closely approached to each other, rounded, oblong or even more irregular cavities of 0.05 to 0.1 mm. The inner wall is beset with a single layer of low cylindrical cells, 0.02 mm. high and 0.01 wide. The cavity is filled at an early period with a

homogeneous firm mass, an obscure derivative of the albuminous bodies, the so-called colloid. In the interstitial connective tissue we meet with a developed, round-meshed reticulum of blood capillaries 0.02 to 0.023 mm. broad; together with these there is a widely extended lymphatic canal-work. How far it stretches, whether it finally circumvolutes each cavity in a cap-like manner, as Boechat recently asserted, requires more accurate investigation. Previous injection studies by myself and Perneschko showed nothing of the kind.

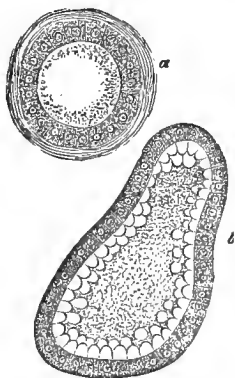


FIG. 215.—Colloid metamorphosis of the thyroid gland; *a*, gland-vesicle of the rabbit; *b*, commencing colloid metamorphosis of the calf.

At a later period of life—and the thyroid gland appears to grow old early—this colloid substance seems to increase more and more. The cavities become distended, the small parietal

cells are more and more compressed, and with them the interstitial connective tissue. In the further progress, these cavities flow together, forming larger ones.

It is assumed of the thyroid gland, like the apophysis cerebri and the suprarenal capsule entirely hypothetically, that it removes matters from the blood which, when the same are further metamorphosed, either indirectly or directly, are afterwards restored to the central fluid of the organism. Hence the denomination of the “blood-vascular glands,” a proof of our ignorance at that time.

Just as obscure are the suprarenal capsules, *glandulæ succenturiales*, structures which once at an earlier foetal period possessed an immense size, and subsequently remained more and more behind.

Here, also, we meet with a double mass, a cortical and a medullary layer. The former appears to have a radiated disposition, brownish, reddish or yellowish. The latter, much softer, is usually more transparent, grayish, red or yellowish. The least resistance is possessed by a border zone which in

man is clouded and narrow. It liquefies very readily after death.

A connective-tissue envelope, permeated by elastic elements, surrounds the organ. Inwards it forms a frame-work (Fig. 116, *b*); in the spaces of the latter lie soft cells. The superficial cavities are, as a rule, short; further inwards they acquire a radial elongation (*a*). Transverse sections of these spaces, which are connected at acute angles, frequently present oblong and bean-shaped formations. Inwards, towards the medullary border, the spaces again become smaller, more rounded, and the frame-work substance delicate and reticular, forming a sort of reticular connective tissue (Joesten).

The contents consist of coarse, granular, membraneless cells, closely pressed against each other, and containing molecules of albumen and fat. The cells measure 0.0135 to 0.0174 mm., with nuclei of 0.0056 to 0.0090 mm. In the boundary zone, towards the medullary substance, our cells lodge abundant brownish pigment molecules. A delicate connective tissue fibro-reticulum also permeates these cavities, which have no membrana propria.

It is likewise not easy to investigate the soft medullary substance.

The connective-tissue frame-work having again become somewhat more resistant, and at last fused with the connective tissue surrounding the veins, forms large oval cavities. They are larger than the peripheral ones of the cortical layer, without the radiated disposition of the latter. They turn their broad side, on the contrary, towards the surface of the organ. The medullary cavities are, however, rounder and smaller in man.

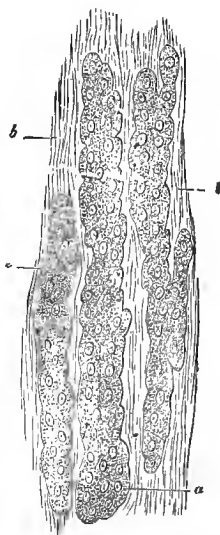


FIG. 116.—Cortex of the human suprarenal gland; *a*, gland cylinder; *b*, interstitial connective tissue.

In them occur, closely crowded, delicate granular cells, measuring 0.018 to 0.035 mm., with fine vesicular nuclei. The cells appear, in contradistinction to the cortical elements, very poor in fat molecules. The behavior of these medullary cells with chromate of potash is very remarkable, as Henle discovered. They become deeply browned, while the cortical cells are very slightly changed.

The vascularity is great, and the arrangement of the vessels peculiar in the suprarenal capsules. Numerous small arterial branches arising from various sources form a capillary reticulum in the cortex, with elongated meshes. These capillaries first combine in the medulla into considerable, but very thin-walled venous canals. The latter, having likewise a radiated direction, unite at acute angles, and thus largely developed occupy a considerable portion of the medulla. The latter large trunks finally open into the very wide veins situated in the centre of the organ.

The lymphatics are still little known.

In many mammals the medullary mass appears very rich in nerves, which may form considerable microscopic plexuses. There was, therefore, an inclination to consider it as related to the sympathetic.

The pituitary gland, the hypophysis cerebri, is smaller in the higher vertebrates than in the lower, and consists of two lobes; a small posterior one, of a nervous texture, and a larger anterior one, with the structure of a blood-vascular gland. Through the latter passes a canal lined sometimes with flattened epithelium (mammals), sometimes with ciliated cells, and which sinks into the infundibulum (Peremeschko). Rounded and oval, 0.0496 to 0.0699 mm. large gland spaces are enclosed by a connective tissue, rich in capillaries. In its interstices lie cells measuring 0.014 mm., with a considerable finely granular body. Colloid metamorphosis may be noticed.

The name of the coccygeal gland, *glandula coccygea*, has been bestowed on a small thing situated at the apex of the coccyx. It consists of a system of diverticulated arterial

branches of capillaries and veins, invested externally by granular cells.

The so-called ganglion intercaroticum also has a nearly related structure.

The granulated cells, such as we are familiar with in the suprarenal capsule, apophysis cerebri, and the two last named organs, belong to the form of coarsely granular connective-tissue cells that are so often met with in the neighborhood of the vessels (Fig. 55, *b*).

TWELFTH LECTURE.

GLAND TISSUE.

IN olden times they were very liberal in their conception of the glands. We have already learned this in the lymphoid organs, as well as the thyroid gland, suprarenal capsule and apophysis cerebri, which preceding generations of anatomists erroneously regarded as glands. A rounded, limited form, and a considerable vascularity was at that time sufficient to stamp a thing as a gland. We thus obtained the lymphatic, Peyerian, and thyroid glands, etc. Later, the physiological importance came more into the foreground. The true glands take materials from the blood, not alone or only principally in the interest of an egotistical nutrition, but rather in the service of the whole, whether it be to simply free the blood from decomposed substances, or to restore the latter, more or less metamorphosed, and serving for other purposes. On this rests the old distinction of excretion and secretion.

The gland requires an efferent canal system to remove its contents. We must lay great weight on this canal in connection with the gland; still the former may, under certain circumstances, be wanting, or may remain separate from the organ. This is shown by the human ovary. Here the wall of the glandular cavity is ruptured. The contents of the latter now escape through a rent. It does not thereby cease to be a gland, for we know of ovaria enough in lower animals which contain quite common glandular formations, provided with continuous canals.

No doubt can therefore prevail here.

How weak the matter is, however, with the so-called blood-vascular glands has already been taught by the previous lecture.

In modern times, however, the so advanced microscopic analysis has furnished characteristics which, in our opinion, permit of the certain recognition of a gland.

Each of our organs (Fig. 117) consists of two elements: 1st, of an, as a rule, hyaline and thin membrane, the so-called gland membrane, *membrana propria* (*a*); and 2d, of cellular contents (*b*) enclosed within the latter.

Without a blood supply, however, secretion does not take place. A non-vascular gland would be a nonentity. We therefore meet with a vascular net-work (*c*), circumvoluting the *membrana propria*, as a third integral constituent.

As further constituents, we have lymphatic vessels, muscular elements and nerves.

Let us now pass to the individual analysis.

The gland membrane appears, at the first examination, homogeneous, and, as a rule, very delicate. Exceptionally, however, it may acquire a thickness of 0.001 to 0.002 mm. It may also be replaced by undeveloped connective tissue (sebaceous glands of the skin). Finally, ordinary connective tissue or a muscular layer may form a reinforcing stratum around this limiting membrane.

In more recent times, a manifold system of quite flat stellate cells (Fig. 118) has been met with which, embedded in or resting on the homogeneous *membrana propria*, form rib-like thickenings of the latter, as for example, in the submaxillary and lachrymal glands.

Firm, extensible, and formed of a very unchangeable material, probably related to the elastic substance, the *membrana*

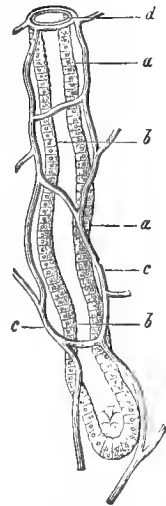


FIG. 117.—A mammalian Lieberkühnian gland; *a*, *membrana propria*; *b*, cells; *c*, capillaries; *d*, gland aperture.

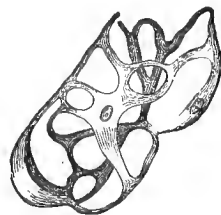

FIG. 118.—Plexus of star-shaped, flat, connective-tissue cells, from the *membrana propria*, isolated by maceration. From the submaxillary gland of the dog.

propria serves for the transudation and filtration of the blood plasma.

Its origin takes place in the nature of a boundary layer, formed from the adjacent connective tissue.

The form of the gland or of its constituents is determined by the membrana propria, or the connective tissue, by which it is frequently replaced. For the organ may, with microscopic dimensions, remain very simple, while, on the other hand (think of the liver and kidney), with an increased size, it may assume the most complicated structure.

We distinguish :

1. The tubular glands (Fig. 117). Here, the membrana propria forms a cæcal tube, generally of considerable length and of relatively slight diameter. Several such cæcal tubes, invisible to the naked eye, may come together in a common terminal portion, so that there is always a more distinct excretory duct.

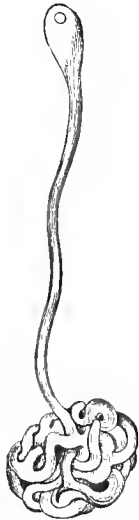

FIG. 119.—A convoluted gland from the conjunctiva of the calf.

Extraordinarily long reticular and cæcal elements, with many peculiarities, united in immense numbers, constitute the testicle and kidney. We speak now of the tubular glands.

Another modification is formed by the so-called convoluted glands (Fig. 119). The terminal portion of this small organ presents a peculiar convolution like the coil of a pack thread.

2. Another uncommonly diffused form is the racemose gland (Fig. 120). The membrana propria here appears as a microscopically small, rounded, elongated or irregularly formed saccule.* These "gland vesicles" are united at their openings in groups, and in this manner a lobule or acinus is

* It has been proposed to include the small racemose structures of the mucous membrane among the "tubular" glands, on account of their elongated saccules.

formed. It may acquire an excretory duct, and then the racemose gland, in its smallest and most simple form, is complete. But these most elementary structures are rare. As a rule (Fig. 120), several acini form the still small gland body. In larger and large organs the number of the gland lobules becomes very great.

It is scarcely necessary to remark that transitions occur between the tubular and racemose glands.

3. Finally, we have another gland with closed rounded gland capsules, which latter are contained in abundant connective tissue. This is the ovary. These rounded structures, which are constituted by a connective-tissue wall, are called the Graafian follicles. Among the cells it contains, one is noted for its size. This is the ovum (Fig. 5).

That the latter becomes free by the rupture of the follicular wall, we have mentioned above. Let us also add that the ruptured follicle is incapable of further repair, but rather goes to ruin by a process of cicatrization. The conditions are, therefore, in contradistinction to those presented by other glands, peculiar and anomalous enough.

The second and much more important constituent of our organ is presented by the gland cells. We shall subsequently see that they are nearly all derivatives of Remak's corneous and intestinal-gland layer. Even in subsequent life, this epithelial character is not renounced.

The inner surfaces of the membrana propria are thus lined, sometimes simply, sometimes in strata. In the excretory portion of the gland, an ordinary epithelium subsequently makes its appearance. The gland cell may be called a microscopically small chemical laboratory. With its body it forms the secretion, or changes the formative material received from the blood into the latter.

For this purpose our cells require a certain magnitude.

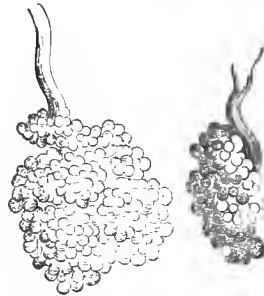


FIG. 120.—Human racemose parathyroid glands.

We shall, therefore, comprehend that those cells, flattened into the thinnest plates, such as we previously met with in the pavement epithelium, are absent.

The gland cell is a membraneless, cubical thing, occasionally somewhat flattened from above downwards, in other cases rendered cylindrical by lateral compression. The former shape is represented by the cells of the liver, with a size of 0.018 to 0.226 mm. (Fig. 121). The cells (Fig. 122, *b*) of the "gastric mucous glands" of the dog are taller and more slender. The elements of the Lieberkühnian glandular tubes of the small intestine have likewise assumed the cylindrical form, as our Fig. 117, *b* (representing a longitudinal section of this tube) teaches.

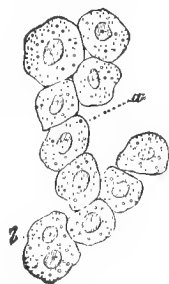


FIG. 121.—Human liver cells.

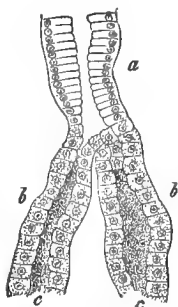


FIG. 122.—From a gastric mucous gland of the dog; *a*, lower portion of the excretory duct; *b*, commencement of the glandular canal.

Gland cells covered with ciliæ are very rarely met with in man. They are only known in the uterine tubes.

Many gland cells—we here allude chiefly to those of the liver and kidney—appear to constitute tolerably permanent structures. In others the cellular elements retain the great perishability of the epithelium, and perish in the formation of the secretion.

Let us take, for example, a sebaceous gland of the external integument, a small clustered structure. An acinus is shown in Fig. 123, *A*.

It is covered by several cell layers. In the cavity (*b*) we meet with a fatty mass, which subsequently becomes free as sebum cutaneum.

How has the latter been formed?

In the peripheral cells, those lying immediately against the wall of the gland vesicle, one already notices an increasing deposit of fat molecules. This is, therefore, the fatty degeneration which we have already mentioned at page 13. It causes the

retrogression of the tissue elements in a normal way here, as by a pathological process elsewhere. The gland cell swells with the increasing embedment of fat, and finally falls from its matrix. Suspended in the cavity of the acinus, it has now become a corpse. We meet, accordingly, in the

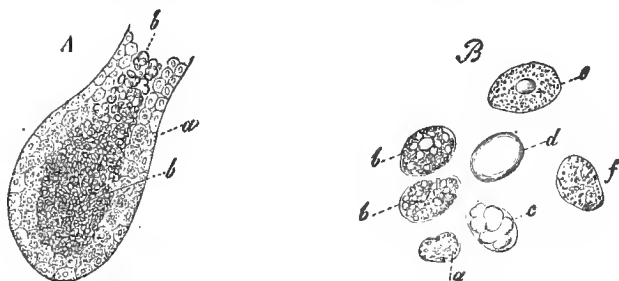


FIG. 123.—*A*, the vesicle of a sebaceous gland; *a*, the gland-cells resting on the wall; *b*, those which have been cast off, containing fat and filling the cavity; *B*, the cells more highly magnified; *a*, smaller ones, poorer in fat and belonging to the wall; *b*, larger ones, more abundantly filled with fat; *c*, a cell with larger fat drops joined together, and *d* one with a single drop of fat; *e*, *f*, cells whose fat has partially escaped.

sebum with these cells fatty degenerated to a high degree, with their fragments, their nuclei which have become free, and fat molecules with an albuminous connecting substance. This is the origin of the sebum cutaneum, a relatively unimportant secretion.

The lacteal gland consists of a group of enlarged sebaceous glands, destined for a higher performance. Even before the final period of pregnancy, the human organ forms the so-called colostrum. We meet in the latter with globular cellular elements of 0.0151 to 0.0563 mm. in size (Fig. 124, *b*).

These "colostrum corpuscles" are similar to the detached, highly fatty, sebaceous follicle cells. Subsequently, soon after the delivery, the milk contains millions of the so-called milk globules (*a*). They are drops of fat which have become free, and are surrounded by a very thin shell of a coagulated albuminous body, which is usually

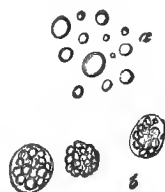

FIG. 124.—Elementary forms of human milk; *a*, milk globule; *b*, colostrum corpuscle.

called caseine. Their size varies between 0.003 to 0.009 mm. The gland cells should now, with a far more energetic secretion in the acinus, have been early destroyed. A different view might, however, be entertained. The membraneless cells may have thrown out the elaborated secretion, as the crater of the volcano does the lava—only the cells, like the volcano, may persist. I regard this as indeed very plausible.

We have just spoken of probably the most perishable gland elements, immediately after the discussion of more permanent elements. Let us now return to the latter for an instant, taking up the liver cells. One meets in them, from time to time, with brownish molecules and drops of fat. Both appear subsequently in the bile; the former is the "biliary coloring matter" (to repeat a crude expression of former days), the latter becomes "cholesterine." Therefore, even here, the gland cell once enclosed in its body the secretory substance which subsequently becomes free. Here the coming and going of the latter through the permanent cell body is not to be doubted.

A still further confirmation of the persistence of many gland cells has been more recently obtained. Extraordinarily fine permanent canaliculi, "the gland capillaries" (first found in the liver), occur between the gland cells as the terminal offshoots of the excretory ducts. Our Fig. 125 represents such from the pancreas. We shall, later, refer to the matter more in detail.

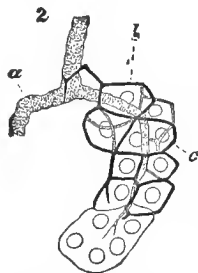


FIG. 125.—From the pancreas of the rabbit; *a*, larger excretory duct; *b*, finer one of an acinus, *c*, finest secretory canal.

With the *membrana propria* and the secretory cells we are, therefore, finished. Let us now refer to the capillary reticulum, the art and manner in which the indispensable blood current reaches the surface of the secreting organ.

We repeat what we said at page 96.

The form of the tissue elements determines the arrangement of the capillaries.

With thin and long glandular tubes, such as stand close to

each other in the gastric-mucous membrane, the individual tubes occupy about the position of the transversely striated muscular filament (Fig. 91). The reticulum (Fig. 126) becomes similarly elongated; only the rings around the gland apertures, together with anomalous arterial and venous branches, produce a considerable difference in the thing.

Turning to the racemose glands, with the generally rounded form of the element, the small acinus, the capillary net-work must, as we have already remarked, correspond to the form of a fat lobule (Fig. 93). Our Fig. 127 represents the capillary arrangement of a larger lobular group of the pancreas. The figure might, with equal propriety, be used for the vascular arrangement of a conglomeration of the lobules of fat cells.

The immense assimilation of glandular organs renders a considerable wealth of lymphatic passages, which are to restore the superfluous transudation to the blood passage, very appreciable. A portion of these lymphatic passages have been discovered very recently. Smooth muscular fibres, which either invest the gland body or occur in the parieties of the excretory ducts, scarcely require a further physiological explanation. They are of great importance for the expulsion of the secretion.

Concerning the gland nerves, this most obscure portion of the structure of the organ in question, we shall speak later.

The last which remains for discussion is the excretory duct. If we take a simple gland tube (Fig. 128), such as are con-

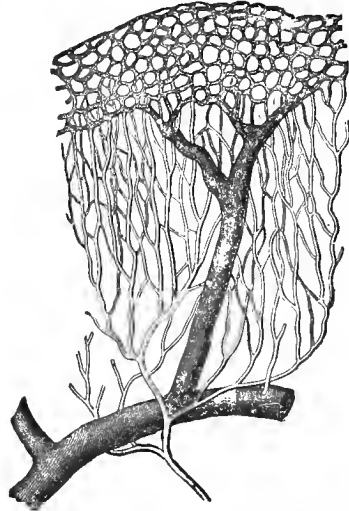


FIG. 126.—The vascular net-work of the mucous membrane of the human stomach—semi-diagrammatic. The (finer) arterial trunk divides into the elongated capillary net-work, which passes over into the rounded reticulum of the gland apertures, from which the vein (the wider, darker vessel) arises.

tained in infinite numbers in the gastric mucous membrane, and examine a so-called "peptic-gastric gland" (it may also, it is true, be somewhat more complicated), we readily recognize from *d* to *b* the secretory cells. Over *b* we meet with a cylindrical epithelium, the same which covers the surface of the gastric mucous membrane. A further explanation is, therefore, superfluous.

Let us, furthermore, cast a glance back to our Fig. 122. The drawing represents a so-called "gastric-mucous gland." A long,



FIG. 127.—The vascular net work of the rabbit's pancreas.

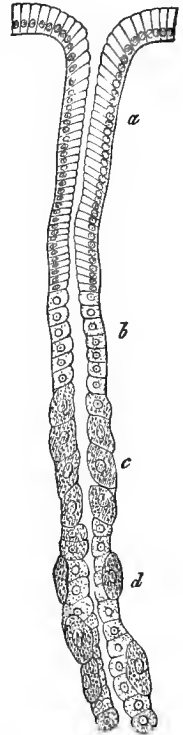


FIG. 128.—A lateral view of a gastric gland of the cat; *a*, stomach cells; *b*, inner; *c*, external intercalary portion; *d*, the gland tube, with both varieties of cells.

excretory duct bears the same cylinder cells (*a*). It then divides into two cæcal tubes. These (*b*) contain lower cubical elements, the suppliers of a tolerably unknown secretion.

Let us examine a still earlier figure—our Fig. 120—the small racemose glands. No doubt can prevail here concern-

ing the excretory duct. Its cell covering is not rarely different from that of the acini.

The wall of the excretory canal is here of a connective-tissue nature. In larger, and the largest glands of a similar structure, the omitted duct acquires an increasing complication. We shall later return to the particulars.

Let us now take a cursory survey of the different glands of the human body.

a. To the tubular group belong: the Bowman's glands in the regio olfactoria of the organ of smell; the tubes of the mucous membrane of the stomach, small and large intestine, which bear the names of the gastric juice glands, or peptic-gastric glands, or gastric-mucous and Lieberkühnian tubes; finally, the uterine glands. Then, as modified structures, as so-called convoluted glands, we have, finally, to mention the smaller and larger sudoriparous glands, together with the ceruminous glands of the ear.

Very complicated tubular organs are, as we previously mentioned, the kidney and testicle.

b. Among the racemose glands are included a host of our organs from the smallest to the largest dimensions. First belong here all the small glands of the mucous membranes of the body, then the so-called Brunner's glands of the duodenum, the sebaceous glands of the skin, and the Meibomian of the eyelids. As larger and largest, the group includes: the lachrymal gland, the various salivary glands, the pancreas, the lacteal glands, then the Cowper's and Bartholinian glands of the sexual system; and, furthermore, the prostate. Finally, according to their manner of origin, the lungs should also be included here. We shall subsequently have to refer more particularly to them, as well as to their predecessors.

c. The closed gland capsules. We scarcely need to repeat that the ovarium forms the only gland of this kind in the human body.

Our organs, with slight exceptions (the primitive kidney and the generative glands), originate, in their cellular portions,

either from the upper or lower germinal layer, from the corneous and intestinal gland layer of Remak. The membrana propria and capillary reticulum are aggregated productions of the middle layer, which produces so much.

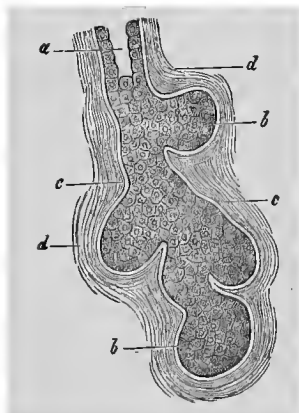


FIG. 129.—Developing racemose gland: *a*, excretory duct, already permeable; *b*, solid gland bud; *c*, membrana propria; *d*, surrounding connective tissue.

A previous figure, 41, the primary rudiment of a hair germ, passes as well for the glands of the external integument as for those of the mucous membrane. When, by a continuous increase of the cells, lateral buds branch off from the cellular cone as it grows downwards, there is formed at first a solid, slightly berry-shaped mass (Fig. 129). It finally becomes a complicated racemose system, which at last becomes hollow (*a*), and thereby constitutes the completed gland.

With this we leave the glandular organs in general.

The subsequent lectures will, however, carry us back to certain of them.

THIRTEENTH LECTURE.

THE DIGESTIVE APPARATUS WITH ITS GLANDS.

THE digestive apparatus, in its connective-tissue external layers and the muscular middle layers, is certainly of a relatively simple nature. The mucous membrane, however, with the immediately adjacent loose connective tissue, and with all which is connected with it, presents an abundance of the most diversified structural relations.

Let us therefore briefly examine the long canal work, with the varying constituents in its interior.

The oral cavity contains the already described teeth (p. 73), as well as the tongue. In it open the salivary glands, large racemose organs, and, together with these, a number of smaller associates, the so-called mucous glands.

From the vascular mucous membrane of the mouth project closely crowded papillæ. It is covered by the stratified pavement epithelium spoken of at page 30. The latter may here acquire a thickness of 0.45 mm. The submucous connective tissue appears sometimes dense (gums), sometimes loose and extensible (the floor of the mouth). In it lie the bodies of the numerous small racemose glands. The secretion is mucus; the cells form a layer of pale, cubical or low cylindrical elements (Fig. 130). They occur as labial, buccal, palatine and lingual glands.

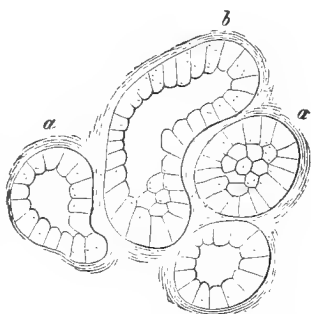


FIG. 130.—Gland vesicles of the palatine gland of the rabbit; *a*, rounded, *b*, an elongated acinus.

Among the salivary glands the submaxillary has recently undergone an accurate investigation (Pflüger, Gianuzzi, Hei-

denhain). Its cells differ in the several animals. The former are granular in the rabbit. In the dog and cat, on the contrary, we find a mucous gland.

The cells (Fig. 131) here consist of two different structures. Firstly (*a*), we meet with large rounded elements, which are

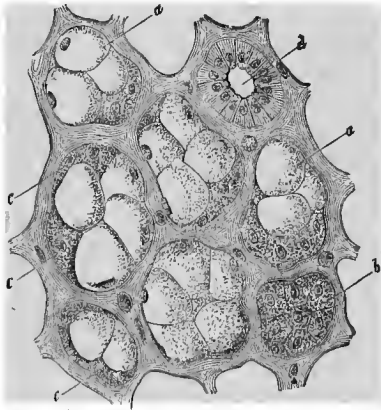


FIG. 131.—The submaxillary gland of the dog; *a*, mucous cells; *b*, protoplasmic cells; *c*, crescent; *d*, transverse section of an excretory duct, with the peculiar cylindrical epithelium.

filled with a homogeneous mucous substance. Besides these, quite granular, smaller cells occur in the periphery of the gland vesicle (*c*). Pressed closely together, and indistinctly separated from each other, they form a sort of crescent (Gianuzzi). They subsequently change into those large mucous cells. The finest secretory capillaries, after the manner of our Fig. 125, likewise make their appearance here, as also do the flat

stellate cells of the membrana propria (see Fig. 118). The excretory ducts show cylinder cells (Fig. 131, *d*), with longitudinal striations beneath the nucleus. We have, finally, to mention a rounded capillary reticulum, and abundant lymphatics around and between the lobules and lobes.

The sublingual appears to be nearly related to the submaxillary gland.

We cannot, however, yet leave the latter. As experimental physiology teaches, the irritation of the chorda tympani produces a profuse watery secretion; that of the sympathetic, on the contrary, a scanty quantity of a thick fluid substance.

The continued irritation of the nerves, as Heidenhain ascertained, produces an important change in the contents of the acini (Fig. 132). Nearly all the large round cells (*a*) have,

in the mean time, given off their mucine as a secretion. A granular protoplasmatic substance now fills the altered cell body.

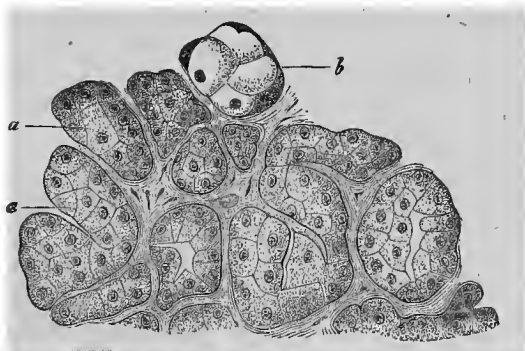


FIG. 132.—Submaxillary gland of the dog, with its contained cells: *a*, changed by the strong irritation of the chorda; *b*, those remaining unchanged (after Heidenhain).

This was altogether the first difference which a quiescent and active gland presented to the eye of the microscopist.

The parotid gland contains in its acinus (measuring 0.034 to 0.052 mm.), granular cubical cells (of 0.014 to 0.018 mm.), without any mucous metamorphosis. Fine secretory tubes have been met with between the latter. Here, again, the excretory duct has ordinary cylinder cells.

The tongue is an essentially muscular organ, with transversely striated filaments crossing each other. The dorsum of the tongue has innumerable different papillæ. Three forms have been distinguished here: the filiform (papillæ filiformes, *s. conicæ*), the fungiform (*p. fungiformes, s. clavatæ*), and, finally, the circumvallated (*p. circumvallatæ*). To the latter have also been added the so-called papillæ foliatæ, which were early discovered, then forgotten, and recently more accurately investigated. Both the latter organs contain the terminations of the gustatory nerves.

Our organ is rich in racemose glands. We meet principally with mucous glands, with the contents rendered familiar to us by Fig. 130. In the vicinity of the *p. circumvallata* and the

p. foliata, quite similarly shaped glands appear, it is true, but they have different anomalous contents, with granular cloudy cells (Fig. 133). The same organs have been met with in great numbers in the nasal mucous membrane, and they have received the name of the "serous glands" (Heidenhain).

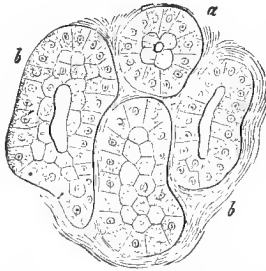


FIG. 133.—Acini (α , round, β , oblong) of a serous gland from the vicinity of a circumvolved papilla of the cat.

The tissue of the mucous membrane commences at the posterior fourth of the tongue to undergo a lymphoid metamorphosis, in which the pharynx may also participate. We thus have demarcated lymphoid organs, the lingual follicles, the tonsils, and the pharyngeal tonsils, discovered by Koelliker (compare p. 113).

The pharynx, with its transversely striated muscles, has the same covering of stratified pavement epithelium as the oral cavity. The tough mucous membrane acquires papillæ below. The upper portion is rich in mucous glands.

The œsophagus also retains the old epithelial covering. The muscular coating consists of a thicker longitudinal external layer and a thinner internal transverse layer, and, as it descends, shows a replacement of the voluntary transversely striated fibrous formation by the involuntary smooth tissue. The mucous membrane projects in longitudinal folds, and contains racemose mucous glands.

We may touch upon these only cursorily.

The stomach or ventriculus, on the contrary, requires a more careful discussion. Its serous covering, it is true, presents nothing worthy of remark, neither do its smooth muscles, which consist of layers running in longitudinal, transverse, and oblique directions. But the mucous membrane, which is lined with cylinder cells 0.0226 to 0.0323 mm. high and 0.0045 to 0.0056 mm. broad, shows, on the contrary, an abundance of interesting and important things.

Its surface is not smooth, but uneven. Either lower or

higher isolated prominences (Fig. 134, *a*), are met with there, or projecting folds, which are united in crossing each other.

The glands open only in the valleys, and never on a hill or a fold. Numerous differences of the gastric surfaces occur according to the variety of animal. In general, the cardiac half of the stomach presents a thinner and more even mucous membrane than the pyloric portion. The mucous membrane may here, at last, acquire an elevation of 2 mm.

An enormous quantity of tubular glands (Fig. 134, *b*) permeate the mucous membrane. The massiveness of the latter is, therefore, in comparison to this embedment, but slight. We find an ordinary soft connective tissue (Fig. 135, *a*). Lymphoid metamorphosis of the latter may, however, take place.

The glandular tubes of the stomach have been divided into two different forms; the so-called peptic-gastric glands and the gastric-mucous gland.

The former constitute the more disseminated and more important glandular formations (Fig. 134). They open in part singly (Fig. 128), in part by the conjunction of several tubes into a common excretory duct (Fig. 136, 1).

In both cases the aperture appears in the transverse section to be rounded (*a*), and lined with the ordinary slender, high cylindrical epithelium of the gastric mucous membrane (Fig. 128, *a*, 136, *a*).

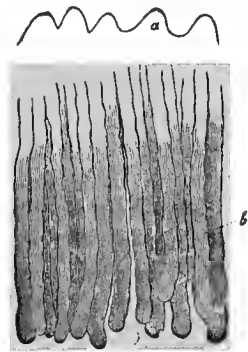


FIG. 134.—Vertical section of the human gastric mucous membrane; *a*, surface papillæ; *b*, glands.

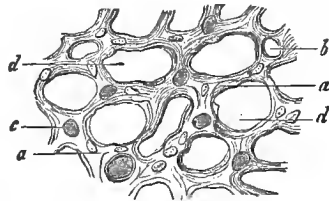


FIG. 135.—Transverse section through the gastric mucous membrane of the rabbit; *a*, tissue of the mucous membrane; *b*, transverse sections of empty and injected blood-vessels; *c*, *d*, spaces for the glands.

The gland body itself appears as a sometimes smooth bordered, sometimes sinuous tube. The membrana propria shows the familiar flattened stellate cells.

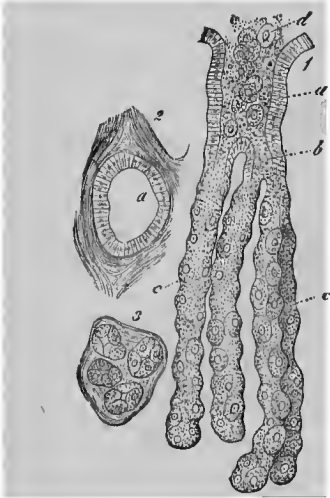


FIG. 136.—1, a compound peptic-gastric gland of the dog; *a*, the wide aperture (stomach cell) with the cylinder epithelium; *b*, the division; *c*, the isolated tubes lined with peptic cells; *d*, the escaping contents; 2, the aperture *a* in transverse section; 3, transverse section through the individual glands.

Passing, now, from the outlet of the gland in a downward direction, we meet at *b* with a new metamorphosed cell formation, broader, lower and more granular. Further below, at *c*, we have two large gland cells (peptic cells). The latter are, however, first met with at *d* in their highest development. Here, lying on an uninterrupted series of smaller gland cells are isolated larger, granular elements (Fig. 128, *d*), lodged in niche-like sinuosities of the membrana propria. The latter structures are the "overlying cells" of Heidenhain, in contradistinction to his "chief cells."

We have already learned how different is the appearance presented by the quiescent and overworked submaxillary gland of the dog. Something similar—and we are again indebted to Heidenhain for the interesting fact—is shown by the peptic-gastric glands. In the fasting animal they appear smooth bordered, somewhat shrunken, and their chief cells are transparent. A few hours after a plentiful meal an essentially different appearance is met with. The peptic-gastric glands are now swollen, their walls are sinuous, their chief cells enlarged, granular and cloudy. At a later period they again shrink; the chief cells, however, remain perceptibly clouded.

Now which of the two varieties of cells supply the gastric juice, we do not yet know. We are inclined to conjecture that it is the peptic-gastric glands.

The second glandular formation, the gastric mucous glands, were long since discovered in the hog. In the dog, cat, rabbit and Guinea-pig they occupy a large extent of the pyloric region; in man, on the contrary, but a small zone here. They are, again, in part ramified, in part unramified tubes. One may also recognize here in the excretory duct (and it may acquire a very considerable length) the ordinary cylindrical epithelium of the gastric mucous membrane (Fig. 122, *a*). The lower true portion of the gland shows, on the contrary, lower cubical cells (*b*) richer in fine granules. They become cloudy in acetic acid, and call to mind the "chief cells" of the peptic-gastric glands.

Small racemose glandules appear in the human pyloric region. Isolated lymphoid follicles form the lenticular glandules, familiar to us from p. 112.

At the border of the mucous membrane, towards the submucous tissue, there is a network of smooth muscular fibres, the muscularis mucosæ (p. 80). Thin strips pass up between the gland tubes.

The arrangement of the vessels in the gastric mucous membrane (Fig. 126) is elegant and characteristic. Thin and slender arterial branches, rising up through the submucous tissue, terminate in a long-meshed capillary network, circumvoluting the gland tubes, and forming rings around the apertures of the latter. The transition into venous roots takes place on the surface only, and these rapidly unite into large descending veins. The latter form a broad-meshed reticulum of wider tubes beneath the mucous membrane.

The lymphatic passages were recently discovered by an eminent Swedish investigator, Lovén. Large networks, situated in the submucous tissue, send upwards considerable cæcal canals, which pass between the glands and reach nearly to the gastric surface.

The gastric juice, an acid fluid, contains a peculiar fermentative body, pepsine. The granules in the covering cells (and possibly in the chief cells) are this substance, which has been formed by the gland cells. The power of the secretion to

digest albumen must be left for discussion in another lecture.

Let us pass to the small intestine.

Its serous covering and the smooth muscles, forming a double layer, we here omit. The mucous membrane, on the contrary, requires an accurate description, for its structure is more complicated than in the stomach.

In the first place, we meet with innumerable large crescentic folds (increasing downwards in height), the *valvulæ conniventes Kerkringii*. The surface of the small intestine, besides, projects in millions of complicated *papillæ*, the intestinal villi. In the mucous membrane we meet, furthermore, with an infinite number of small glandular tubes, the *Lieberkühnian glands*; and in the duodenum, with small racemose organs, the *Brunonian glands*. Finally, the small intestine contains solitary and aggregate (*Peyerian*) lymph follicles.

The tissue of the mucous membrane of the small intestine also shows a *muscularis mucosæ*, but it is thinner than in the

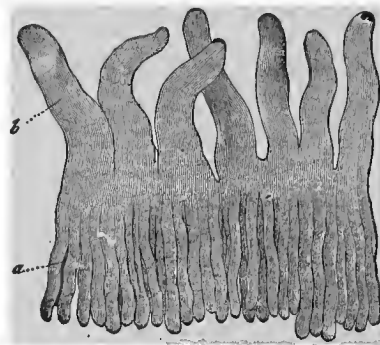


FIG. 137.—*Lieberkühnian glands (a)* of the cat, with the intestinal villi (*b*) situated over them.

stomach, and then a reticular connective substance containing numerous lymphoid cells (Fig. 47, *a*). The villi (Fig. 137)—we have already mentioned them in a previous lecture—also consist of a similar tissue. Even the surface is distinctly fenestrated, although with narrower meshes. In the axis we find the chyle vessel (Fig. 95, *d*), single or multiple, in the latter case sometimes connected in an arched and bridge-like manner, covered by thin slips of smooth muscle (*c*) derived from the *muscularis mucosæ*, and finally circumvolved by a looped net-work of capillaries (*b*). We are already familiar with this from what has preceded.

That the whole intestinal canal is lined with cylindrical epithelium, was mentioned in the second lecture. We also described the peculiarity which the cylinder cells of the small intestines presented, the thickened seam, permeated by porous canals, of the free broad surface.

We now turn to the glands. By far the more important formations are the Lieberkühnian tubular glands (Fig. 137, *a*). They are infinitely numerous, and occupy not only the mucous membrane of the small, but also that of the large intestine. We are thus reminded of the gastric glands; the capillary net-work is also the same.

The Lieberkühnian glands are smaller, however; they are only 0.38 to 0.45 mm. long, and 0.056 to 0.09 mm. broad. Their membrana propria also appears more delicate; the tube remains undivided, and is lined by a simple layer of cylindrical gland cells (Fig. 117, *b*). The opening occurs regularly in the narrow vales which are enclosed by the adjacent villi. They secrete the intestinal juice.

The racemose or Brunonian glands (Fig. 138) of the small intestine are of far more subordinate importance. They com-




FIG. 138.—A human Brunner's gland.

mence, in man, just beyond the stomach, and form, in a crowded sequence, a regular glandular cushion embedded in the submucous tissue. They thus extend to about the en-

trance of the biliary duct, becoming more scanty further downwards. The mammalia show numerous variations.

The size varies in man from 0.25 to 2 mm. The acini appear rounded, elongated, sometimes regularly tube-like (0.56 to 0.14 mm.) The duct and gland body have the same covering of low cylindrical, pale and irregular cells. If I am not mistaken, the Brunonian gland stands in the middle, between the ordinary racemose mucous gland, the gastric-mucous gland and the serous gland. Concerning the secretion we know very little.

Isolated lymphoid follicles (solitary glands) may occur throughout the entire small intestine. These, as well as the aggregated lymphoid follicles (the Peyer's plates) have already been mentioned in the eleventh lecture.

We have already mentioned that the Lieberkühnian tubular glands have an elongated net-work of blood-vessels. From it arise, and to it return, the afferent and efferent vessels of the intestinal villi, which form the looped net-work (Fig. 95, *b*).

The lymph or chyle vessels of the intestinal villi, having descended into the mucous membrane, likewise form a network, very much more incomplete it is true, of wider tubes. Our Fig. 109 (*a, b, c, k*, to the left) may represent this tolerably. During the resorption of the chyme, its fat, in a condition of the finest division, penetrates first the body of the cylindrical epithelium; it then enters a wall-less passage through the reticular connective substance of the villi, and, at last, the cæcal chyle canal (Fig.

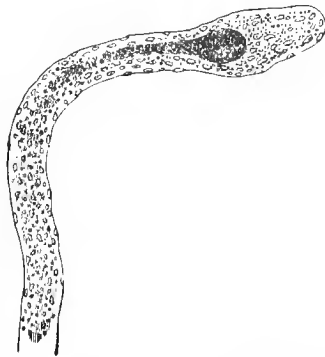


FIG. 139.—The very slender intestinal villus of a kid, killed during digestion, without epithelium, and with the lymphatic vessel filled with chyle, in the axis.

139) occupying the axis of the latter. "Preformed passages" for this process of wandering have frequently been searched for, it is true, and they have often been thought to be found,

but subsequently nothing of all this was confirmed. These were simply microscopic observations such as should not be made, instituted for the purpose of filling up a gap in the present physiological knowledge at any price.

The Lieberkühnian tubes continue throughout the mucous membrane of the whole large intestine, but now receive, most superfluously, a new name, that of the glands of the large intestine (Fig. 140). They have not become changed in the least.

The reticular connective substance of the mucous membrane of the small intestine has, however, been further transformed into an ordinary connective tissue; the reticular character is less pronounced, and the number of lymphoid cells contained in the tissue has decreased enormously. The intestinal villi of the small intestine have finally entirely disappeared.

If the mucous membrane, as in the upper part of the rabbit's colon, still projects as papillæ, the latter appear broader and as prominences of the ordinary mucous membrane permeated by tubular glands (Fig. 100).

The colon presents isolated lymphoid follicles. In the vermiform process of man and the rabbit, on the contrary, there is an enormous Peyerian plate, as we remarked at page 114.

The blood-vessels of the large intestine correspond with those of the stomach (Fig. 126) for an interchange. Lymphatics have also been subsequently met with in the carnivora and herbivora. Those of the upper colon of the rabbit are represented by our Fig. 100, *g, f, e*.

In the anus the simple cylinder epithelium is sharply demarcated from the modified epidermis. At the lower end of the intestine, the smooth and transversely striated muscles become intermixed, reminding us of the œsophagus.

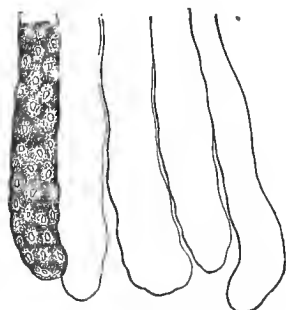


FIG. 140.—Glands of the large intestine of the rabbit. One tube with cells; the others drawn without cells.

FOURTEENTH LECTURE.

PANCREAS AND LIVER.

WE have still left the two largest glandular organs of the digestive apparatus, the pancreas and liver. We shall soon finish the pancreas ; the liver, on the contrary, requires a more accurate discussion, in consequence of its peculiarities.

The pancreas is an enormous racemose structure. It reminds one of the salivary glands. The rounded acini measure 0.06 to 0.09 mm. The membrana propria is likewise said to have flat stellate cells. The rounded vascular network was represented in our Fig. 127. The lymphatics require still more accurate investigation.

The gland vesicles are lined with indistinctly separated, very granular cubical cells. In the adult rabbit the latter show fatty molecules in their interior, that is in the parts turned towards the lumen. The middle and external portions remain transparent. Between them appears the net work of finest secretory tubes, already familiar to us from Fig. 125 (Saviotti).

The thin-walled excretory duct of the human pancreas contains no muscular elements. Below, it presents mucous glandules.

It is covered by a low cylindrical epithelium. If followed, in animals, into the gland, these cells are found to become more and more flat in the branches. Finally, in the gland vesicles themselves, we meet with thoroughly flattened elements, reminding us of the endothelia of the vessels. These are the so-called "centro-acinary" cells (Langerhans), which are found widely extended, not only in the pancreas, but also in the parotid.

The character of the gland cells in a quiescent and active condition requires further investigation.

Let us now turn to the liver.

The liver—as its natural external surface, or that of an artificial section teaches—consists of individual, crowded areas, the so-called hepatic islets or hepatic lobules. In many creatures, as the pig, the demarcation of the lobules is very distinct. The borders of the lobules appear tolerably distinct in the human organ during the infantile period of life, but

very indistinct, on the contrary, in the adult. Our liver islets are assumed to measure, as a mean, 2.2 mm.

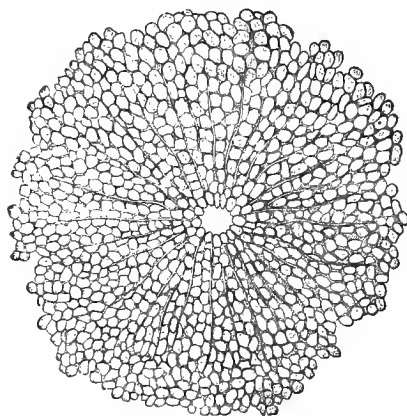


FIG. 141.—Hepatic lobule of a boy ten years old, with the transverse section of the central hepatic vein trunk.

A hepatic lobule (Fig. 141), however, consists essentially of innumerable gland cells and, crossing them, an uncommonly complicated capillary network. The latter unite at the central point of the lobule to form an initial branch of the hepatic vein; the limits are shown externally

by the branches of the portal vein and the fine biliary branches.

The liver cells have already been noticed at Fig. 121. These thick, obtuse-angled structures, whose mean measurement is 0.018 to 0.023 mm., contain nuclei of 0.006 to 0.007 mm., with nucleoli. The soft, granular cell body remains membraneless and endowed with a slow contractility (Leuckart). The brown molecules of the biliary coloring matter in the cell body, as well as the fatty embeddings, we have already mentioned. The latter occur in the suckling infant, in adults whose diet is rich, and also in fattened animals. They form the so-called fatty liver (Fig. 142). The cell supports such an overloading with fat (*c*, *d*) relatively well.

With an altered manner of life, the unusual contents soon disappear again.

In the lobule (Fig. 141) the cells lie crowded together in a radiated manner, forming simple rows. Reticular combinations gradually become more frequent externally. These are the so-called cellular trabeculæ and cellulotrabeular reticula of our organ.

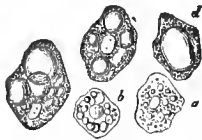


FIG. 142.—Cells of the fatty liver; *a*, *b*, with smaller fat molecules and drops; *c*, *d*, with large drops.

Between the lobules we meet with interstitial connective tissue, sometimes only slightly developed (man), sometimes abundantly (pig). This connective tissue derives its origin, in part, from the investing membrane of the liver; it is, in part, the continuation of a connective-tissue sheath which surrounds the blood-vessels and biliary passages entering the porta hepatis (Glisson's capsule).

The liver receives its blood from two unequally developed supply tubes, the wide portal vein and the narrow hepatic artery. The first forms, around the lobules, partly shorter or longer branches (Fig. 94), sometimes, however, nearly and actually assuming a ring-shaped arrangement (pig). These branches rapidly divide into the compact capillary network of 0.009 to 0.0126 mm. wide tubes. They approach the centre of the lobule in a radial manner to bury themselves in the commencing portion of the hepatic vein, which is situated at this point. The latter, like its larger trunks, has uncommonly thin walls, and has coalesced externally with the parenchyma of the liver.

The branches of the hepatic artery, running along with the portal vein and biliary ducts, form, in the first place, nutritious vessels for both the last mentioned parts, and then capsular capillaries; finally, they penetrate the lobule itself. They either bury themselves here in the branches of the portal vein, or pass over into the peripheral portion of the capillary net-work.

Both varieties of net-work, that of the hepatic cell trabeculæ and that of the blood-vessels, are most intimately

interwoven with each other, so that every space of the one meshwork is occupied by portions of the other.

After suitable treatment, as Beale and Wagner found, thin sections of the hardened hepatic tissue show an uncommonly elegant reticular tissue of a right delicate, homogeneous, nucleated, connective substance (Fig. 143, *a*).

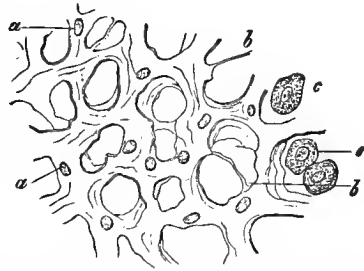


FIG. 143.—Frame-work substance from the rabbit's liver; *a*, homogeneous membrane with nuclei; *b*, thread-like strands of the latter; *c*, several hepatic cells still retained.

In the last period of fetal life, or in the new-born (Fig. 143), this consists distinctly, in places, of a double membrane. The one layer corresponds to the capillary walls (and shows here and there a combination of the flat, vascular cells—Eberth); the other, investing the hepatic cell-trabeculae, represents a finest membrana propria.

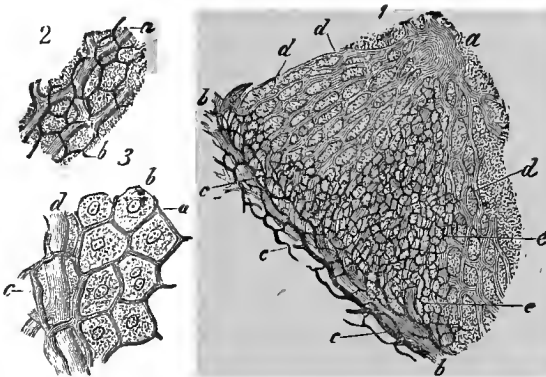


FIG. 144.—Biliary capillaries of the rabbit's liver. 1. A part of the lobule; *a*, vena hepatica; *b*, branch of the portal vein; *c*, biliary ducts; *d*, capillaries. 2. The biliary capillaries (*b*) in their relation to the capillary blood-vessels (*a*). 3. The relation of the biliary capillaries to the hepatic cells; *a*, capillaries; *b*, hepatic cells; *c*, biliary ducts; *d*, capillary blood-vessels.

Great difficulty was encountered, during a long period, in the investigation of the finest biliary passages (Fig. 144). A

reliable result was at last secured here by means of troublesome injections * (Gerlach, Budge, Andréjevic, MacGillavry)

The finer ramified system of the biliary passages may, it is true, be still readily recognized (Fig. 144, 1). They run with the branches of the portal vein (*b*), in the intervening spaces of adjacent hepatic lobules. From them arise fine branches which circumvolute the branch of the portal vein (*c*).

They are continuous inwards with a marvelously delicate net-work of finest canals, the so-called biliary capillaries (*d*). The diameter of the latter is 0.0025 to 0.0018 mm. (rabbit). They surround the individual liver cells (3, *b*) with elegant cubical meshes (*a*), so that the cellular element comes into contact at one point or another of its surface with these finest tubules. We thus have, in addition to the two coarse networks of the cellular trabeculæ and capillary vessels, this third, finest one, of the biliary capillaries.

They are also not wanting in the other classes of vertebrate animals. There is, nevertheless, considerable variation (Hering, Eberth).

We now encounter the question: do the biliary capillaries possess a proper wall, or are they only the finest lacunar canals? Furthermore, what is their more exact relation to the hepatic cells?

I have not doubted that there was a special, although extremely thin wall, from the instant that I began to study the biliary capillaries of the rabbit. One sees here, not only the artificially injected, but also the adjacent empty tubules (often to a considerable extent), regularly demarcated by sharp, straight lines. A lacunar system between contractile cells would otherwise scarcely present the regularity of the biliary net-work. We therefore coincide with Eberth and Koelliker in the assumption of a wall. The same is also shown by the cat's liver.

* These may be made from the biliary passages in the fresh animal cadaver. This was the earlier procedure. An injection may also be made into the vein of the living animal of indigo sulphate of soda, which is soon (as in the kidney) secreted by the liver (Chizonszczewsky).

Years ago, Andréjevic had already correctly asserted that the blood and biliary capillaries never touched each other, but rather that the body of a hepatic cell always lies between them as a separating structure.

The livers of the amphibia and reptiles, and even of birds, show this most distinctly. Nevertheless, the more complicated relations of the mammalian liver yield the same result (Fig. 145), although with more trouble, to the attentive observer. We see the blood-vessels (*a*) in part transversely, in part longitudinally. The biliary capillaries (*c*) are in repeated contact with the hepatic cells (*b*); but portions of the cell body always remain as intervening parts between these and the capillary vessels of the passage.

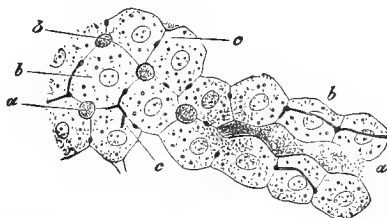


FIG. 145.—Finest biliary passages of the rabbit's liver; *a*, blood-vessels; *b*, hepatic cells; *c*, biliary capillaries.

Our figure teaches, furthermore, that biliary capillaries occur only at the contiguous surfaces of two cells. We shall, therefore, have to regard the extremely thin walls of the capillaries as the product of adjacent cells which has become hardened.

The lymphatics run in the capsule of Glisson in the same manner as the portal vein, hepatic artery, and biliary ducts. Having entered the lobule, they invest the capillary blood-vessels (MacGillavry, Frey, Biesiadecky and Asp). The delicate external wall of these "perivascular" lymph passages is without doubt the thin membrana propria of the hepatic cell trabeculæ.

Let us, finally, look after the efferent biliary canals.

These canals also show between the lobules a membrana propria covered with low cylinder cells. Later, the walls become connective tissue, the cells are higher and have a seam which is permeated by porous canals (p. 8).

In the largest canals passing out from the hepatic paren-

chyma, there is an external fibrous membrane and an internal mucous membrane. In the gall bladder there are, in addition, smooth muscular fibres.

The largest biliary canals have numerous excavations (probably reservoirs for bile), as well as racemose glandules.

FIFTEENTH LECTURE.

THE LUNGS.

THE lungs originate in the same manner as the racemose glands, but acquire an essentially different texture. Their efferent canal system requires an especial preliminary discussion, on account of its peculiarity and complication.

The cartilages of the larynx are hyaline, as the thyroid and cricoid cartilages. In certain parts of the arytenoid cartilages there is an elastic metamorphosis. The Wrisbergian and Santorinian cartilages, with the epiglottis, are pure reticular cartilage. The triticean cartilages are formed of hyaline or connective-tissue cartilaginous substance. The ligaments of the larynx present a considerable wealth of elastic tissue. The lower true vocal cords are purely elastic. The muscles are transversely striated. The mucous membrane, rather compact and likewise not poor in elastic elements, shows embedments of lymphoid cells. It contains racemose, true mucous glands.

Strongly stratified pavement epithelium covers the anterior surface of the epiglottis; there are not so many layers in that covering the posterior surface as far as the base; the same is also true of the lower vocal cords. Otherwise, we meet with slightly stratified ciliated epithelium, which descends far down into the lungs.

The wind-pipe or trachea, with its system of branches, the bronchi, presents a fibrous tube, in the anterior wall of which are embedded half rings of hyaline cartilage (*annuli cartilaginei*). A deeper layer of transverse smooth muscles connects the terminal portions of the half rings posteriorly. In the mucous membrane we again meet with numerous mucous glandules.

In the lungs themselves the bronchi divide dichotomously again and again, and thus become finer and finer passages. The cartilaginous half rings disappear, simple lamellæ appearing in their place. Their last remains are still seen in canals of 0.23 mm. The thin parietes have a simple ciliated epithelium of 0.0135 mm. in height. Mucous glandules continue far down, as also do the smooth muscles, which form regular rings round the bronchial ramifications, and possibly till near the so-called pulmonary vesicles.

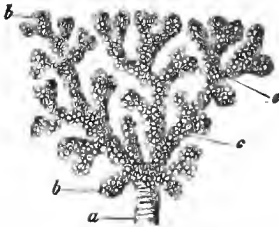


FIG. 146.—A portion of the lung of an ape (*Cercopithecus*, injected with quicksilver; *a*, end of a bronchial twig; *c*, alveolar canal; *b*, infundibula.

At the end of the terminal bronchial branches (Fig. 146, *a*) we now arrive at the true respiratory portion of our organ.

We have, first, thin-walled (0.4 to 0.2 mm. wide) canaliculi, the alveolar passages (Schulze).

Their acute-angled ramifications (*c*) are familiar. Communicating with them laterally and also terminally are short, conical hollow structures (*b*), the primary pulmonary lobules or, as they are commonly called, the infundibula.

As the gland lobule consists of the gland saccules or acini, so does the just mentioned infundibulum consist of similar structures, the pulmonary vesicles, pulmonary cells or alveoli. They are less isolated from each other, however, and to a certain extent present more diverticulations of their walls, which meet in common cavities. At a later period, indeed, there is not unfrequently an absorption of individual portions of the walls. Such expansions of the wall of the alveolar passage into pulmonary vesicles (*c*) are met with everywhere.

On making a section through the lung tissue, we meet with the alveoli in the form of rounded and oval spaces (Fig. 147, *b*, *b*). Their diameter varies from 0.1128 to 0.3760 mm., and increases with the age.

The hermetic enclosure of the respiratory organs in the

thoracic cavity compels the pulmonary alveoli to maintain a certain expansion permanently. In consequence of their great distensibility, the lungs follow the expansion of the thorax. By means of their elastic power, and assisted by the muscles of their canals, they contract at each expiration,

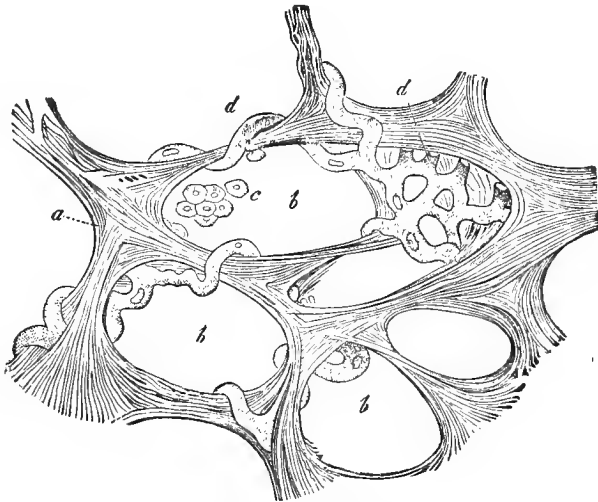


FIG. 147.--Transverse section through the pulmonary substance of a child of nine months. A number of pulmonary cells, *b*, surrounded by the elastic fibrous net-work, which bound them in a trabecula-like manner, and, with the thin structureless membrane, forming their walls (*a*); *d*, portions of the capillary net-work with their vessels curved in a tendril-like manner, projecting into the cavities of the pulmonary cells; *c*, remains of the epithelium.

as far as the thoracic walls permit. It is only when the thoracic cavity is opened that the lungs with their alveoli completely collapse.

The parietes of the pulmonary vesicles, a continuation of the terminal canal system, is a very thin connective-tissue membrane. It is surrounded by elastic fibres, finer and coarser, sometimes single, sometimes aggregated in groups. The latter are met with in the interalveolar septa. The fundus of the pulmonary alveolus shows only the finest elements, measuring 0.0011 mm., in part more isolated, in part connected in a reticular manner.

The primary pulmonary lobules of the new-born—later the nature of the arrangement becomes more indistinct—united by connective-tissue intermediate substance, form larger or secondary lobules. The latter appear on the surface of the organ in the human adult as areæ, measuring 1 to 2 mm. and more, demarcated by a black substance, and often appearing quite distinct. They form, at last, the large lobes. Their delineation belongs to descriptive anatomy.

We have just mentioned the black substance in the interlobular connective tissue; it may occur between and in the walls of the pulmonary vesicles, and even in the bodies of their epithelial cells, as we shall mention hereafter. This is the so-called black lung pigment.

We have just used the epithet "so-called." In fact these substances are not melanine, the complicated, dark ferruginous coloring matter of the organism. They have rather an extraneous origin; they are carbon, breathed in in a finely divided condition, which is induced by our artificial life in enclosed places.

Mammals living wild show nothing of this, but it is seen in their kin when domesticated by man. In human beings constantly surrounded by smoke and soot, or in laborers in coal mines, the lungs may at last become quite black. If we shut a dog up in a place in which there is a constant generation of soot, a similar change of the respiratory organs takes place with relative rapidity.

In a condition of the finest division, these particles of carbon penetrate the epithelial cells, and from them enter the pulmonary tissue. A great portion of them here become permanently quiet. Others enter the lymphatics, and pass from these into the lymphoid bronchial glands. They also become fixed in the latter organs. This is the so-called melanosis of these structures.

Let us now examine the vascular arrangement.

By the continual division of the pulmonary artery, there arises a system of fine blood-vessels, which encircle the individual pulmonary vesicles, and frequently combine into

incomplete or more complete rings (Fig. 148, *a*). From them arises an uncommonly close capillary net-work of tubes 0.0056 to 0.0113 mm. wide, which are scarcely separated from the atmospheric air by the thin membrane of the alveolar walls (*b*). The respiratory interchange of gases takes place here. These capillaries appear elongated when the lung vesicles are strongly expanded. When less expanded they project, in a tendril-like manner, into the cavity, reminding us of a relative condition in the muscles. The pulmonary veins commence with small branches in the interalveolar septa. Gradually combining into larger trunks, they accompany the ramifications of the bronchia and the divisions of the pulmonary arteries.

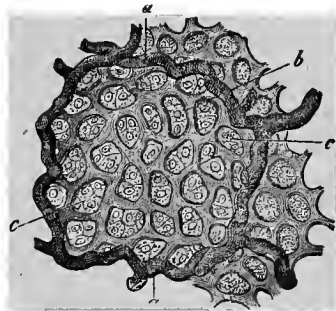


FIG. 148.—A pulmonary alveolus of the calf; *a*, larger blood-vessels, which run in the alveolar septa; *b*, capillary net-work; *c*, epithelial cells.

The bronchial arteries are regarded as the nutritive vessels of the respiratory organ, but there is no very sharp demarcation between them and the respiratory pulmonary arteries.

The former supply the walls of the larger blood-vessels, the adjacent lymphatic glands, the connective tissue between the pulmonary lobules and beneath the pleura. Finally, they form the capillary net-works of the various parietal layers of the efferent bronchial system; but the most superficial net-work of the mucous membrane arises, in a peculiar manner, from the respiratory system of vessels.

The bronchial veins appear to be quite peculiar. They are conjectured to be only the reflux vessels of the arterial branches from the larger bronchial ramifications, from the lymphatic glands and from the pleura nearest the hilus of the lungs. The venous roots from the walls of the finer bronchi pass, on the contrary, into the respiratory pulmonary veins.

The lungs are rich in lymphatics, beneath the pleura as well

as in the bronchial system. Lymphatic lacuni also occur in the pulmonary vesicles, and their efferent vessels subsequently invest the blood-vessels (Wywodzoff).

We have, finally, to mention the epithelial lining of the alveoli. This has occasioned much discussion. In the mammalian and human embryo there is a continuous covering of flat, protoplasmatic, nucleated cells. A change occurs after birth, however, with the commencement of aerial respiration.

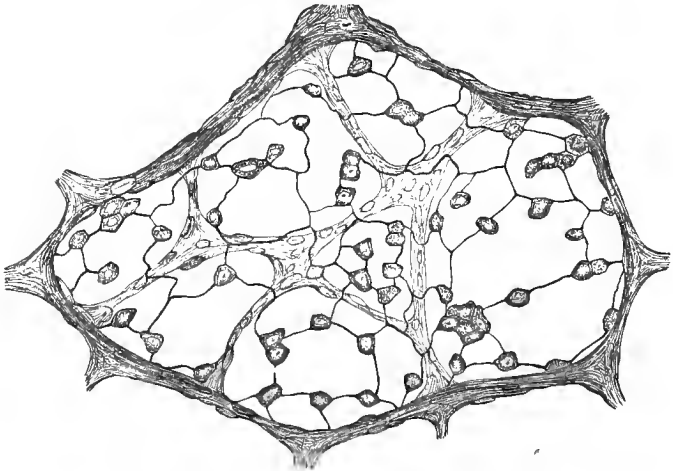


FIG. 149.—The epithelium from the basis portion of an infundibulum, situated just beneath the pleura of the developed cat; treated with nitrate of silver.

Only a small contingent of our cells now retain their old characteristics (Fig. 149). The epithelial element, over the incurvations of the pulmonary vessels, and over all the other prominences, has become a much more considerable protoplasmless and non-nucleated scale.

SIXTEENTH LECTURE.

THE KIDNEY, WITH THE URINARY PASSAGES.

THE structure of the mammalian kidney is extremely complicated. This bean-shaped organ is covered by a not very thick, but resistant, connective-tissue envelope. The blood-vessels and lymphatics pass in and out at the hilus, and the efferent canal, the ureter, also has its exit at this point.

The kidney (Fig. 150), consists of two different layers, a cortical, and a medullary substance. The former (above, *f*), appears to the naked eye dark and homogeneous; the latter (*a*, *b*), paler, displays a radiated fibrous arrangement. In most mammals it projects in a single point into the pelvis of the kidney (*a*). In man the medullary substance is divided into a number of conical portions, with their bases turned towards the cortex and their points towards the hilus.

These are the Malpighian or medullary pyramids. The columnæ Bertini are depressions of the cortical substance between the latter portions of these cones.

The cortex and medulla are, furthermore, permeated by a connective-tissue frame-work.

The elements of the cortex, as well as of the medulla, are long, glandular tubes, the so-called uriniferous canals or Bellinian tubes.

In the medulla they divide frequently, and run in a radial direction (*b*). They continue through the

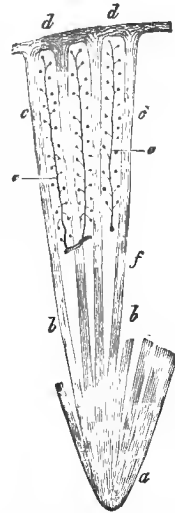


FIG. 150.—Diagram of the mammalian kidney; *a*, papilla; *b*, straight uriniferous canals of the medulla; *c*, so-called medullary rays of the cortex; *d*, outermost cortical layer; *e*, cortical pyramids, with the arteries connected with the glomeruli; *f*, border layer.

cortex from point to point, in the form of straight bundles (*c*). They are here called medullary rays. Between them, although incompletely demarcated, remain considerable portions of the cortical substance (*e*), comparable to a truncated pyramid. These are the so-called cortical pyramids. In them run the glandular tubules, with the most manifold turnings, which finally encompass, with their knob-like dilatations, the Malpighian vascular coil or glomerulus (Fig. 96). The latter structures occur in this portion of the organ only.

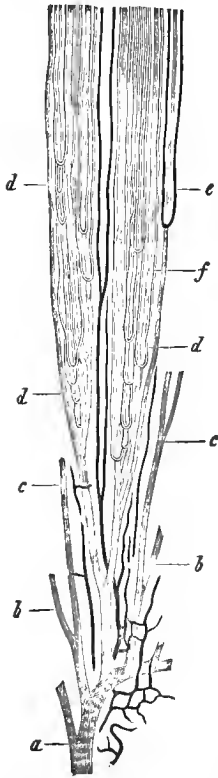


FIG. 151.—Vertical section through the medullary pyramids of the pig's kidney (semi-diagrammatic); *a*, trunk of a uriniferous canal, opening at the apex of the pyramid; *b* and *c*, its system of branches; *d*, loop-shaped uriniferous canals; *e*, vascular loop, and *f*, ramification of the vasa recta.

Let us now commence the discussion of the particulars with the most internal division, with the apices of the medullary pyramids, the renal papillæ. Here, alone, in the form of 10 to 15 apertures, the efferent canal-work of this organ, which is so complicated in its structure, opens as a system of short canals (Fig. 151, *a*). Very soon afterwards they break up, by acute-angled ramifications, into branches of the first and second order (*b*, *c*), and this is repeated several times more. The whole thus acquires a brush-like appearance. The canals become narrowed, in consequence of this continual subdivision, from 0.3 and 0.2 to 0.05 mm. About 4 to 5 mm. from the apex of the papilla the process of division ceases, however; the straight canals now maintain their diameter unchanged for a long distance.

Between them—and this was discovered by Henle—occurs an additional system of much finer loop-shaped canals (*d*). In order to facilitate a further insight, let us give to that particular part

of the tube which descends from the convoluted cortical portion, and the side of the loop which passes off from this, the name of the descending, and that portion which returns towards the surface of the organ the name of the ascending side. The former usually has the least, and the latter the greatest diameter. The number of the looped canals increases in proportion as we examine the cortical layer further upwards towards the medullary layer.

The terminal trunk of the efferent canal-work is invested by the connective-tissue frame-work of the papillary apices, and is without a membrana propria. The latter gradually makes its appearance at the system of branches, and is more distinct as well as more compact at the looped canals. Low cylinder cells of 0.03 to 0.02 mm. border the transverse section of the efferent canal system (Fig. 152, *a*). In the further system of branches the lining cells are still lower (down to 0.016 mm.)

Let us now, for an instant, leave the efferent apparatus and examine the secretory portion of the kidney.

We will now turn to the cortical layer of our organ and, first of all, examine more closely the so-called cortical pyramids (Fig. 150, *e*). In their axis is seen a branch of the renal artery, to which the glomeruli are attached by lateral branches, like the berries on the stem of the grape (Fig. 150, *e*; Fig. 155).

A cortical pyramid, however—we repeat what was previously said—consists, for the rest, entirely of convoluted uriniferous canals. They take their origin with a balloon-shaped portion which surrounds the glomerules, as a bag does a sponge. This is the Müller's or Bowman's capsule. Its con-

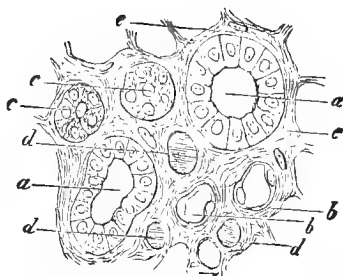


FIG. 152.--Transverse section through a renal pyramid of the new-born child; *a*, collecting tubes with cylindrical epithelium; *b*, descending side of the looped canal with flat cells; *c*, returning side of the loop with granular cells; *d*, transverse sections of vessels; *e*, connective-tissue frame-work substance.

tracted transition into the uriniferous canals (the so-called neck) was discovered at a relatively recent period.

Only the most external cortical portion of our organ (Hyrtl named it the cortex corticis) is without this peculiar vascular coil (Fig. 150, *d*; Fig. 155, *d*).

The inner surface of this capsule has a lining of large, flat, endothelial cells.

The external surface of the glomerulus presents an investment of smaller cells which are not so flat. I found them thus, formerly. According to Heidenhain, however, the latter elements are likewise quite flat.

In the convoluted uriniferous canals we meet with a clouded, granular, cubical epithelium, and the lumen is quite narrow.

Following this glandular tubule downwards, we find it assuming a straight and direct course. At first it still remains

wide, and the gland cells are unchanged. Then, having entered the medullary substance, it diminishes in width, exceedingly, and now becomes the narrow descending side of Henle's looped canal. A remarkable transformation of the epithelial lining has taken place at the same time; quite thin, flat scales, appearing like vascular endothelium, now line the canal (Fig. 152, *b*.)

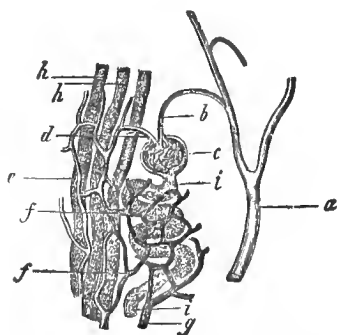


FIG. 153.—From the kidney of the pig (semi-diagrammatic); *a*, arterial branch; *b*, afferent vessels of the glomerulus; *c*, *d*, vas efferens; *e*, breaking up of the same into the straight capillary plexus of the medullary ray; *f*, rounded plexus of the convoluted canals; *g*, commencement of the venous branch.

Following the loop further, we arrive at the ascending wider side. Its epithelium is

again the old, clouded, glandular variety of the convoluted uriniferous canals, as we must maintain in contradistinction to Ludwig.

The returning side finally passes over in the cortex—sometimes deeper, sometimes quite near the surface—into an expanded, gut-like convoluted structure, the so-called “inter-

calary piece." Several of these intercalary pieces open into a collective tube, and the latter combine into larger canals. We have thus presented the whole connection of the kidney.

Heidenhain has quite recently made an interesting discovery concerning the epithelium of the convoluted uriniferous canals, of the returning side of the loop, and of the intercalary piece. Its protoplasm is in great part metamorphosed into a considerable number of very fine cylinders or rods.

Around the nucleus, which these "rod cells" invest, as well as between the rods, there remains a residue of unchanged protoplasm. These rods, with which the gland cells rest on the membrana, give the transverse section of these uriniferous canals a radiostriated appearance.

The medullary rays penetrate the cortex, like groups of pegs driven close together into a board. They consist of two different elements. In the first

place we have the cortical branches of the efferent canal-work of the medullary substance pushing forwards to near the surface of the kidney; these are accompanied by the upper portions of the ascending looped canals, which have a smaller diameter.

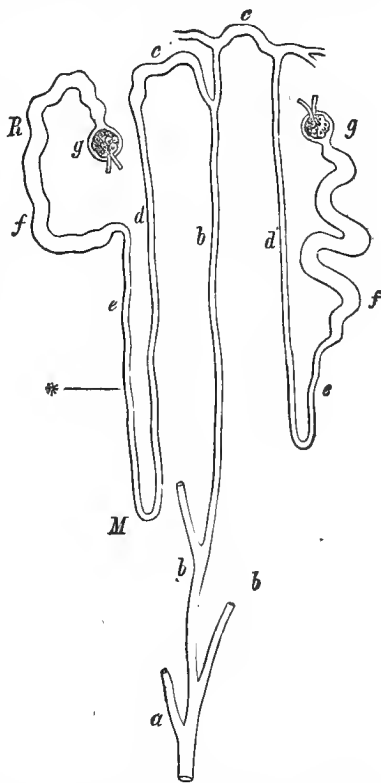


FIG. 154.—Diagram of the uriniferous canals in a vertical section of the kidney; *R*, cortex; *M*, medulla; *, border; *a*, efferent canal-work, with the system of branches *b*; *c*, transition canal (or intercalary piece) in the ascending or returning side *d*; *e*, descending; *f*, convoluted uriniferous canal of the cortex; *g*, capsule with the glomerulus.

I cannot presume that the highly complicated structure of the mammalian and human kidney is hereby rendered appreciable to every one; let us, therefore, make a brief repetition. From the glomerulus (Fig. 154, *g*) and convoluted cortical canals (*f*) the secretion reaches the descending (narrower) side (*e*), and from this into the ascending (*d*). From the latter, the secretion passes through the intercalary piece (*c*) into the efferent canal system (*b* and *a*). Our urine, therefore, passes through this long course.

The frame-work substance consists, in the cortex, of a scanty scaffolding of a connected, undeveloped connective tissue. The latter is somewhat thicker in the medullary substance, especially below (Fig. 152, *e*). Cells are not wanting.

We have the blood-vessels and lymphatics still remaining.

The arrangement of the former vessels (Fig. 155) is the most complicated, and, therefore, certain differences of opinion still prevail in regard to it.

In man the arterial and venous branches enter at the hilus and pass into the interior, becoming more and more ramified. After giving off branches to the capsule, they perforate the latter external to the calyx of the kidney, an arterial branch being accompanied, as a rule, by a venous branch. They thus pass between the medullary pyramids to the bases of the latter (*a*, *h*). They here assume an arched arrangement, which is less complete in the arteries than in the veins.

From the arteries now arise the coil-bearing branches (*b*), which, keeping in the axis of the cortical pyramids, continue as far as the surface, and give off laterally the vasa afferentia of the glomeruli (*c*). In the lower animals, such as the frog and the adder, the latter forms a single coil-shaped convolution. In man and the mammalia (Fig. 196), on the contrary, we meet within the latter with the already mentioned (p. 98) acute-angled divisions, which subsequently unite into the single vas efferens.

This (Fig. 153, *d*; Fig. 155) is now resolved in a peculiar manner into a capillary net-work (Key), forming at first an elongated reticulum in the medullary rays (Fig. 153, *e*; Fig.

155, *e*). From the periphery of the latter a rounded network of somewhat wider vessels extends to the convoluted uriniferous canals of the cortical pyramids (Fig. 153, *f*; Fig. 155, *g*).

The most external cortical layer, Hyrtl's cortex corticis, receives its blood from the efferent vessels of the uppermost glomeruli and the terminal branches of the coil-bearing arteries (Fig. 155, *d*).

Let us pass to the veins of the cortex. Stellate venous rootlets, the so-called stellulæ Verheyenii (*e*), appear quite superficially. Connected with these stars, there is then formed in the cortical pyramids a long venous trunk (*h*), which lies in close apposition to the coil-bearing artery. Into its regular lateral branches open the rounded capillary network of the cortical pyramids. The vein, itself, sinks at the margin between the cortex and medulla, into the venous arched vessel which we mentioned above.

Thus far all is settled.

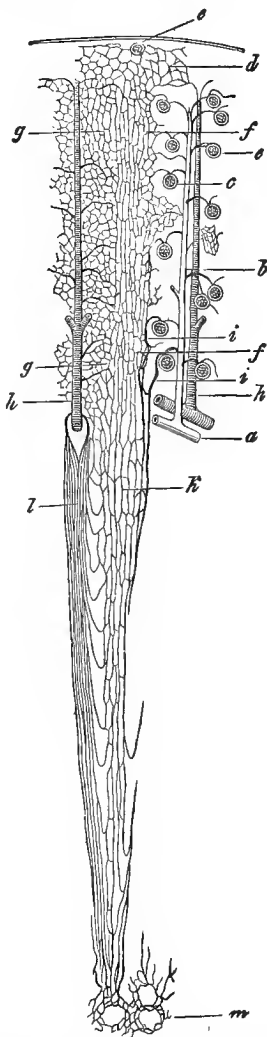


FIG. 155.—The vascular arrangement of the kidney in vertical section; *a*, arterial branch at the margin between the cortex and medulla; *b*, coil-bearing artery; *c*, vasa afferentia of the glomeruli; *d*, capillary reticulum of the external cortical layer; *e*, vein of this part; *f*, elongated capillary net-work of the medullary rays; *g*, rounded net-work around the convoluted uriniferous canals of the cortical pyramids; *h*, venous branch of the cortex; *i*, efferent vessels of the deepest glomeruli; *k*, their capillary net-work; *l*, venous tubes of the medulla; *m*, capillary net-work of the papilla.

A variety of views prevail, however, concerning the vascular relations of the medulla. Elongated vascular tufts, which appear in the upper portion of the medullary substance, the so-called boundary layer (Fig. 150, *f*), are called vasa recta (Fig. 151, *f*; 155, *k* and *l*). They pass, sometimes further upwards, sometimes further downwards, in a looped or noose-like manner, into each other, and may be mistaken for the looped canals of the urinary passages (Fig. 151, *e*). Our vasa recta then form an elegant net-work (Fig. 155, *m*) around the apertures of the uriniferous canals at the apex of the medullary pyramids.

These vasa recta have frequently, if not predominantly, a venous character (*l*); they are continuations of the capillary net-work of the cortical pyramids.

Then—and we regard this source of supply as the more important—the medullary vessels arise from the breaking up of the vasa efferentia of the deepest glomeruli (Fig. 155, *i*).

Quite isolated arterial branches, which have left the coil-bearing arteries before the giving off of the glomerulus branches, are, according to our views, of little consequence, though many investigators have considered these so-called arteriolæ rectæ to be of great importance.

The combination of the vasa recta into venous roots (*l*) presents a similar condition. They frequently have a tuft-like character. Their affluent tubes are the returning sides of the looped vessels and the effluent canals of the papillary apices. These venous roots empty in part into the lower terminal portion of the cortical veins, in part into the arched communications at the margin between the cortex and the medulla.

We are familiar with the lymphatics of the dog's kidney (Ludwig and Zawarykin). They occupy the interstices of a connective tissue full of clefts, which is situated beneath the capsule, and from here are in communication with the capsular passages, and then form in the cortical pyramids finer, deeper canals between the uriniferous canals, capsules of the

glomeruli and blood-vessels. Later, in making the injection, the narrower passages of the medullary rays become filled, and at last the lymphatics of the medullary substance itself. The whole reminds us of the arrangement in the testicle (see below). True lymphatics with valves first appear, however, at the hilus.

The question now arises, which of the two systems of vessels, that of the glomerulus or the net-work circumvolving the uriniferous canals, secretes the urine? This rôle has been assigned to the glomerulus, and only the signification of an absorbing arrangement ascribed to the capillary net-work of the uriniferous canals (Ludwig). According to another view (Bowman), however, the glomeruli secrete the water chiefly, and the cells of the uriniferous canals, as true gland cells, furnish the characteristic solid constituents of the urine, which are washed out by the water flowing past. A new, and as I can say correct, observation of Heidenhain's is of significance for this theory of Bowman's. Indigo sulphate of soda injected into the veins of a living mammal is not excreted by the glomeruli, but through the convoluted glandular canals of the cortical pyramids.

Let us finally take a hasty glance at the passages which convey away the urine.

The calices and pelvis of the kidney present a connective-tissue outer layer, a middle layer of crossed smooth muscles (especially in the pelvis of the kidney), then a mucous membrane with the pavement epithelium mentioned at p. 30. Mucous glands may also occur.

The muscular coating is thicker in the ureter. An external layer shows longitudinal, and an inner layer transverse fibres. Further downwards, a third, innermost, longitudinal layer is added. The urinary bladder has a relative structure. The muscular layer, considerably thickened, consists of oblique and transverse reticularly connected bundles of fibres. The sphincter vesicæ appears at the neck of the bladder as a thicker annular layer. The longitudinal layers of the detrusor urinæ run over the vertex and anterior wall of the organ.

The mucous membrane and epithelium remain the same. Simple mucous glandules are likewise met with.

The female urinary canal, the urethra, presents a longitudinally folded mucous membrane with papillæ. The mucous membrane is very vascular, and has numerous mucous glandules, the largest of which bear the name of Littre's glands. A strongly developed muscular layer consists of longitudinally and transversely arranged fibres. The epithelium is of the stratified flattened variety.

W. L. Lull, M. D.
Veterinarian,
1526 Race St., Phila.

SEVENTEENTH LECTURE.

THE FEMALE GENERATIVE GLANDS.—THE OVARY WITH THE EFFERENT APPARATUS.

THE ovary, a peculiarly constructed organ, forms the most important portion of the female sexual apparatus. It has a flattened oval, occasionally bean-shaped form, and therefore has a hilus through which considerable blood-vessels and lymphatics enter and leave the organ.

We may distinguish in the ovary a sort of medullary substance, that is, a connective tissue, uncommonly vascular substance or the vascular zone of Waldeyer; and then an investing glandular layer, the parenchyma zone.

The medullary substance begins at the hilus. Its large vascular canals remind us of the later-to-be-mentioned cavernous tissue of the urinary and sexual passages. It radiates outwards into a frame-work permeating the glandular cortical layer. At the surface of the organ the frame-work reunites into a more solid continuous substance (Fig. 156, *b*). The entire ovary is covered by a simple layer of low cylindrical cells (*a*). This was formerly erroneously called a serous membrane, but now bears the name of the germinal epithelium, a designation the correctness of which we shall learn later.

We have next to describe the glandular constituents of the ovary, which are by far the most important.

Beneath the firmer connective-tissue border layer we meet with an almost non-vascular layer of youngest ovules, the cortical or primordial follicle zone (Fig. 156, *c*).

We here discover the young ova, already represented in Fig. 5. They are small globular elements (0.0587 mm. large), with an elegant globular and vesicular nucleus (0.0226 mm.).

The cell body is constituted by a membraneless protoplasm containing fat granules. Each of these ovules is surrounded by a corona of small nucleated cells. The whole is finally enveloped in connective tissue. These are the so-called primordial follicles which, often occurring quite crowded here, present an enormous excess of egg-germs.

Other primordial follicles (Fig. 5, 2) become larger; the ovule, which has meanwhile also increased somewhat in size, appears to be surrounded by a thicker hyaline rind. The small investing cells now form a double row (*a*).

In the further development, however, both the cell layers

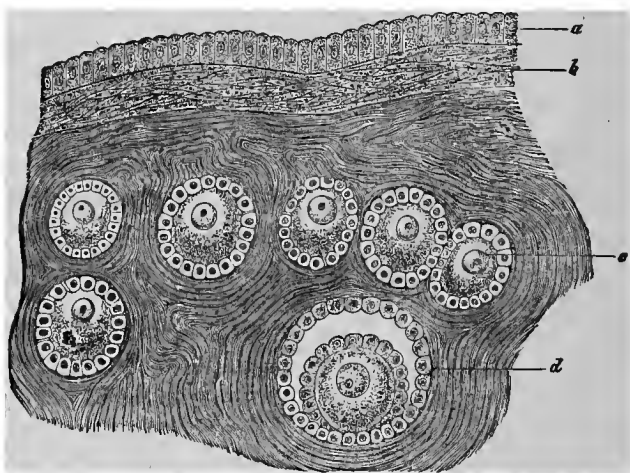


FIG. 156.—Ovary of the rabbit; *a*, germinal epithelium (serosa); *b*, cortical or external fibrous layer; *c*, youngest follicles; *d*, a somewhat more developed older one.

are separated from each other; there is thus formed a smaller cavity (Fig. 156, *d*) filled with a clear albuminous fluid.

In the growing follicle, this cavity becomes larger and larger. The small cells increase and gradually form a stratified epithelium. The ovum lies at one point crowded against the wall, and surrounded and held by a heap of these cells. A developed vascular net-work has, in the meanwhile, also been formed in the follicular walls.

The normal ovarium contains besides a small number of ripest gland capsules (12 to 20). These are the Graafian follicles (Fig. 157), discovered long ago by De Graaf. Their size is determined, in a measure, by the dimensions of the mammalian ovum. In women they finally attain to 6 to 9 mm.

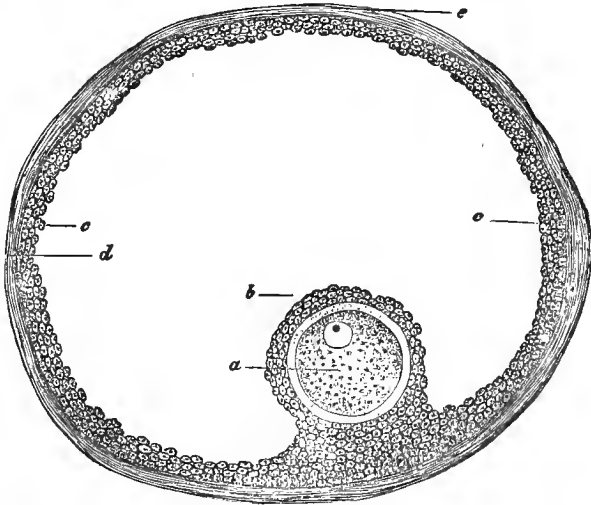


FIG. 157.—Mature follicle; *a*, ovum; epithelial stratum covering the same, *b*, and lining the cavity, *c*; *d*, connective-tissue wall; *e*, outer surface of the follicle.

The parietes consist of a double layer, an inner one with a close capillary net-work, and an outer one with the ramification of the larger blood-vessels. The wall itself (*e*, *d*) is undeveloped connective tissue. We here again meet with the granular connective-tissue cells mentioned at page 54. They may surround the vessel like a mantle. The small epithelial cells of the follicles measure 0.0074 to 0.0113 mm. (*c*).

At one point, mostly at the bottom of the follicle (Schrön, His), but occasionally also at the surface that is turned towards the germinal epithelium (Waldeyer), we meet with the mature ovum (*a*) surrounded by a thicker epithelial stratification (*b*).

In the mammalian animal it remains uncommonly small, 0.2 to 0.3 mm. in diameter. This explains why its discovery was

first made in 1827, by an investigator of great merit, K. E. von Baer. It appears scarcely conceivable to us; for a sharp eye sees the ovule, removed from the ruptured follicle, as a white point, without a magnifying glass. The successor, however, stands on the shoulders of the predecessor.

Let us tarry for an instant at this most important of all cells (Fig. 158), without which there would be no higher animal world.

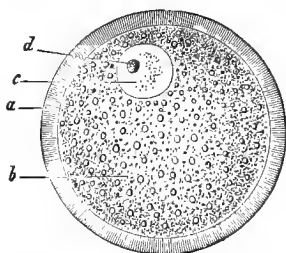


FIG. 158.—Mature ovum of the rabbit; *a*, zona pellucida; *b*, yolk; *c*, germinal vesicle; *d*, germinal spot.

Let us remove from its surface the cells, which have now become cylindrical, of the epithelial investment, and our attention will be first of all attracted by the thick (0.009 to 0.0113 mm.), resistant hyaline capsule, the so-called zona pellucida or chorion (*a*). It is an inwardly deposited product of the surrounding smaller

cells, and, seen with higher magnifying powers, is permeated by the finest radial passages, the so called porous canals.

The cell-body is a thick, fluid, more or less cloudy mass. We perceive in it granules of albuminous matter, as well as small drops of fat. In many mammalian animals, the quantity of the latter may become great, and the substance darker and darker. This cell body is called the yolk or vitellus.

The cell nucleus (*c*) attracts our attention by its elegant globular form, bordered by the finest lines. It now lies concentrically; its diameter is 0.0377 to 0.0451 mm. It has received the name of the germinal, or Purkinje's vesicle.

In it, and almost always single, we finally notice the nucleolus (*d*), a fat-like, glistening granule 0.0046 to 0.0068 mm. in size. It bears the name of the germinal, or Wagner's spot, the macula germinativa.*

* We have just become familiar with quite ordinary things provided with special names. This nomenclature originated in a former epoch of embryology. Furthermore, the follicular walls are called theca; their epithelial lining has been denominated the formatio or membrana granulosa, and the cellular substance surrounding the ovum the cumulus proligerus.

The blood-vessels of the ovary pass, as we mentioned above, from the hilus into the medullary substance. They at once acquire such a development that the connective tissue forms a relatively scanty connecting substance. The outer surfaces of the veins coalesce with the latter tissue. The spindle cells of the connective tissue must be muscular, for the ovary is contractile (His, Frey). From the medulla numerous and elegant vascular expansions pass between the follicles of the cortex, circumvoluting them with the already described network. The cortical zone, alone, is very poor in blood-vessels, as we already know.

A considerable wealth of lymphatics is also met with in the medullary substance. A net-work of the same also circumvolutes the follicles.

The parovarium represents the remains of the embryonic primitive kidney or the Wolffian body. It consists of connective-tissue passages, lined with ciliated cells.

The ovary also originated from this primitive kidney, and the permanent ordinary kidney from the efferent canal of the

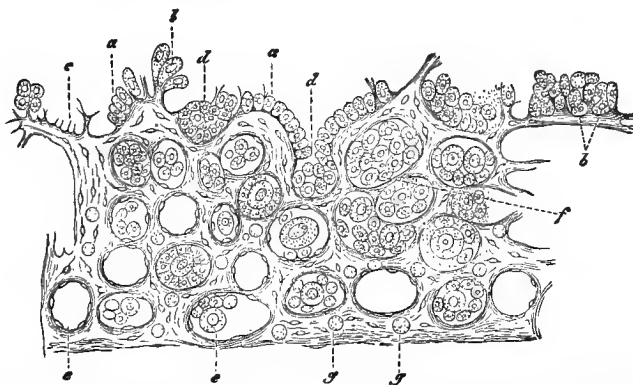


FIG. 159.—The ovary of a human fetus of 32 weeks, in perpendicular section; *a*, germinal epithelium; *b*, youngest ova cells (primordial ova) lying in this; *c*, a growing connective-tissue trabecula; *d*, epithelial cells becoming buried; *e*, youngest follicles; *f*, ovum—and germinal epithelial cells in groups; *g*, lymphoid cells.

latter gland. Unfortunately, we cannot enter further into this subject. We merely mention that, according to Waldeyer, in the embryonic chicken, at an early period, at the inner side

of the primitive kidney, an epithelial thickening appears, into which the connective tissue of this organ sprouts in a hill-like form. The latter becomes the frame-work substance; from the former originate the germinative epithelium, the epithelial cells of the Graafian follicle, and, as the favored daughters of the latter, the ova.

This section of the development is represented by our Fig. 159, a copy from Waldeyer's excellent monograph. The first embryonic ovula, the "primitive ova," are, therefore, of epithelial origin.

Pflüger had, even before Waldeyer, acquired interesting conclusions concerning the ovaries of the creature after birth.

From time to time, soon after birth, and then towards the period of parturition, in the adult mammalian animal, the

old embryonic affinity reasserts itself. The germinal epithelium again proliferates downwards in a conical form, and is at last separated from the point of origin. Thus arise irregular, occasionally cord-like, and cylindrical masses. These are Pflüger's follicular chains. I have called them the egg strands (Fig. 160). In their axis we meet with certain of the epithelial cells which have grown to be ova. By constriction (2, *a*), new Graafian vesicles are formed.

What becomes of the follicles of the ovary?

Before sexual maturity they appear to be frequently destroyed by fatty degeneration and also by colloid metamorphosis (Slavjansky, Frey). During the period of propagation,

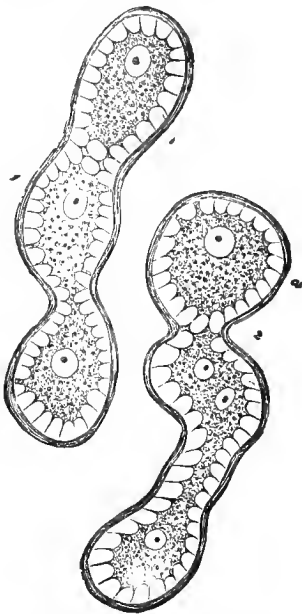


FIG. 160.—Follicular chains from the ovary of the calf; 1, with ova forming; 2 at *a*, showing constriction into Graafian vesicles.

also, a similar destruction takes place in a portion of the follicles.

Others, on the contrary, meet with a different fate. The ripest follicles, which have reached the surface of the ovary, become ruptured, naturally at the place of the least resistance, and, therefore, towards the surface. The follicular fluid with the ovule leaves the organ through the ruptured outlet. The ruptured follicle is transformed into the so-called corpus luteum, that is—to express ourselves more intelligibly—it returns, at last, by a complicated process of cicatrization, to a connective-tissue frame-work substance, leaving no trace.

In the human female, the follicle normally ruptures at the menstrual period; in mammalian animals at the period of rutting.

The ovule, liberated from the ovary and received into the oviduct, there undergoes the familiar segmentation of the encapsulated cell (p. 15). Without impregnation, however, this multiplying action is soon paralyzed. If the former takes place, the old life is merrily and energetically continued. The encapsulated ovum at last becomes an aggregation of numerous small cells. From these living building stones is constructed the new animal body, somewhat as the architect builds his house with stones. But the latter, the lifeless ones, are brought from all directions, the former are the primitive offspring of a single cell, members of a living family. It is the difference between the living and the lifeless.

The oviducts, Fallopian tubes, have, beneath the serous covering, longitudinal and transversely arranged smooth muscles. The mucous membrane is glandless,* and projects in a highly developed system of papillæ and folds. The inner surface is covered by ciliated epithelium.

During menstruation and pregnancy the womb or uterus undergoes extremely important anatomical transformations. There is scarcely any organ, except the ovary, perhaps, on

* All attempts to discover nerves here have, thus far, been unsuccessful.

which is so thoroughly impressed the stamp of a proliferating formative life as the uterus.

Its fleshy substance is formed of longitudinal, transverse and oblique muscles. Developed in an annular form, it at last constitutes the sphincter uteri.

The mucous membrane—its tissue reminds one of lymphoid connective substance—is lined with ciliated epithelium. Below, in the neck, commences the stratified flattened epithelium of the vagina. The surface of the mucous membrane is sometimes smooth (fundus and body), sometimes with transverse folds (upper portion of the cervix), sometimes projecting in papillæ (terminal portion of the cervix).

Tubular, frequently spiral uterine glands, which are subject to considerable variation, occur in the fundus and body of the uterus. They have a lining of ciliated cylinder cells (Lott). Our glands disappear below.

The uterus has a highly developed system of blood-vessels. The wide veins coalesce with the tissue of the latter, and gape in transverse sections.

The lymphatic apparatus also acquires a great development, especially in the loose connective tissue of the mucous membrane, then in the muscular layer, and finally, in the subserous layer (Leopold). This is also in beautiful harmony with this proliferating formative life.

The immense enlargement of the pregnant uterus consists in the first line, in an increase of the muscular tissue. The old mucous membrane is hereby disposed about the ovum as a so-called transient membrane, the decidua, while a new mucous membrane, destined to be a substitute, is meanwhile formed beneath. Still, much is here obscure, and, in certain groups of mammalian animals, we meet with great variations.

In the vagina we find external annular, and internal longitudinal muscles. The mucous membrane shows numerous rugosities and folds, columnæ rugarum. It has no glands, and is covered by stratified, flattened epithelium.

The hymen is a vascular duplicature of the mucous membrane.

The clitoris has a prepuce of mucous membrane tissue ; the female glans is also covered by such a membrane with numerous papillæ. The corpora cavernosa and bulbi vestibuli remind us of the same tissue in the male.

The labia minora, nymphæ, are folds of mucous membrane, containing no fat, but numerous papillæ and sebaceous follicles.

The labia majora are rich in fat, and have internally the characteristics of the mucous tissues, externally those of the corium.

In the vestibulum and the ostium vaginæ, numerous mucous glands occur. The glands of Duverney or Bartholini are larger organs of this kind.

The lacteal glands are primarily of similar formation in the male and female body ; they do not become developed in the former, and in the latter only after a prolonged period of quiescence, and even then only when pregnancy commences.

We recognize in the mammary gland an aggregation of individual racemose glands, which open into numerous (18, 20 and more) canals, the so-called "lactiferous ducts."

Examined in the earlier period of life, our organ consists merely of a ramified canal-work. It is hollow above ; below in its knob-like terminal portion, it is completely plugged by closely compressed cellular masses. The special gland-vesicles or acini destined for secreting are still wanting. This is the condition, during the days of childhood, of the male and female lacteal gland, though the latter gradually advances somewhat in its development.

The entrance of puberty exerts no influence on the male organ, but a great one on that of the female. There is here a bud-like production of numerous terminal vesicles. Assisted by a development of fat cells, they produce the curved elevation of the maturing female breast. In this manner the female gland is prepared for a possibly coming activity ; but it is only with pregnancy, and towards the end of the same, that the lacteal secreting apparatus acquires its complete development.

Let us now examine the organ at the height of its activity in the body of the nursing woman (Fig. 161).

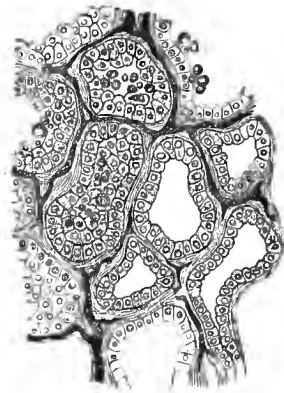


FIG. 161.—Gland-vesicles of a nursing woman, with cells and capillaries.

The gland vesicles, rounded or elongated (0.1128 to 0.1872 mm.), are formed by a membrana propria with flat stellate cells. They have a simple lining of low cylinder cells (of 0.0113 mm.). Those finest secretory canals between the cells, which we have already mentioned at p. 134, have also been demonstrated here by means of injections.

The excretory canal-work also has a cylindrical epithelium. How far the fatty secretion of our organ, the milk, depends upon the destruction of the gland cell, or whether the latter structure does not simply express the produced or received fat substance from the membraneless, contractile cell-body—are questions which require more accurate investigation.

In advanced life, the female mammary gland loses its secretory apparatus. It becomes reduced to the old canal-system of a long passed period of childhood (Langer).

The colostrum (already mentioned at Fig. 124) contains, in addition to albuminous fat vesicles surrounded by a very thin envelope, gland cells and cell fragments, 0.0151 to 0.0564 mm. in size. The ordinary milk of a later period contains only the former elements, the so-called milk globules. The size of the latter varies from about 0.0023 to 0.009 mm.

EIGHTEENTH LECTURE.

THE MALE GENERATIVE GLANDS, THE TESTICLES WITH THE EFFERENT APPARATUS.

THE seminal gland or testicle represents in the male organism that which the ovary does in the female body. We leave its coarser structure, for the greater part, to descriptive anatomy.

A firm connective-tissue envelope, called the albuginea, invests our organ. Numerous and incomplete septa radiate from it into the interior, where they finally unite above into a thickened wedge-shaped mass, the corpus Highmori. The interior is thereby divided into conical lobules whose apices are turned towards the corpus Highmori.

A testicle-lobule consists of an aggregation of uncommonly long convoluted canals or tubes. They present divisions and communications, and finally pass over into each other in the form of a loop, but never terminate in a cul-de-sac (Mihal-kovics). These tubules are called seminiferous canals.

At the apex of the lobule, the seminiferous canal becomes united into a straight excretory duct (tubulus rectus) which, passing into the corpus Highmori, unites with others in a reticular manner and forms a further tubular system, the rete testis. From the latter continue nine to seventeen larger canals, the so-called vascula efferentia. They at first pursue a direct course, and thus perforate the albuginea; then, becoming narrow, they form with numerous convolutions several conical lobes, the so-called coni vasculosi; the latter form the caput epididymis. The terminal canals gradually come together into a single one 0.3767 to 0.45 mm. in diameter. It forms, with numerous convolutions, the cauda epididymis.

Further below, the efferent canal becomes straighter, and its diameter increases to 2 mm. It is now called the vas deferens. Not infrequently, a lateral cæcal branch, the vas aberrans Halleri, has previously entered it. This is the coarser structure.

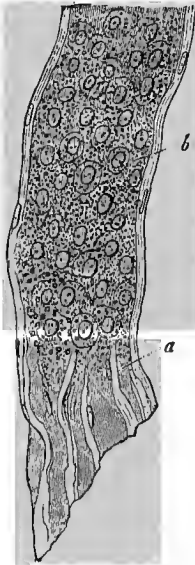


FIG. 162.—Human seminiferous canal; *a*, parietes, *b*, cells.

Having become familiar with this complicated arrangement, let us investigate the histological texture.

The seminiferous canals (Fig. 162) have about the same diameter throughout their entire length. Their diameter is, in most mammals, 0.1 to 0.25 mm. They are remarkably large in the rat (0.4 mm.). In small animals the walls consist of a single layer of firmly cemented endothelial cells. In larger creatures, this inner layer is surrounded by others which show the same construction of flat nucleated scales, but are fenestrated (Mihalkovics). As we shall subsequently return to the parenchyma cells, we merely remark here that the efferent ductuli recti, deviating from these, have a different epithelial lining, namely, cylinder cells. In the rete testis there is

no gland membrane; the cells are pavement shaped. Towards the end of the rete, however, commences the cylinder epithelium of the epididymis.

The quiescent seminiferous canal is either entirely (Fig. 163, *a*, *b*), or, up to a narrow lumen, filled with rounded polygonal

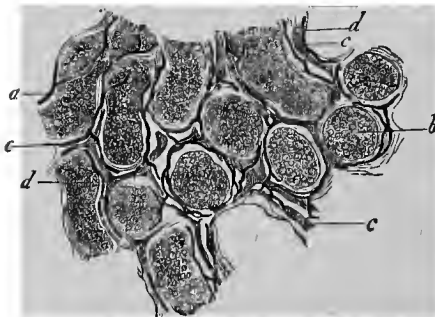


FIG. 163.—From the testicle of the calf; *a*, seminiferous canals seen in more oblique, *b*, in more transverse sections; *c*, blood-vessels; *d*, lymphatics.

cells, measuring 0.0113 to 0.0142 mm. The peripheral ones present a radiated appearance. In man, their cell bodies may contain a yellowish pigment. A coagulated, originally thick fluid, albuminous substance between the spermatic cells has been erroneously regarded as a second cell-work.

The connective-tissue frame-work substance of the organ is, as we have previously said, developed from the inner surface of the albuginea and the system of septa.

In many creatures (man, dog, rabbit) fibrillated connective tissue prevails; in others (rat, male cat, boar) it is much less developed. In the rabbit the connective-tissue bundles are invested by the first mentioned (Fig. 55, *a*) forms of cells (the thin, nucleated plates, with protoplasm in the centre, and a hyaline, cortical portion); there may even be regular, endothelial cell membranes spread out over the seminiferous canals and the blood-vessels. In the just mentioned second group of animals we find the granular connective-tissue cells (Fig. 55, *b*) in immense numbers, while in the first division they are more scanty, or are scarcely met with.

These granular cells (generally rounded or polygonal, rarely having processes, rich in protoplasm, fat, and brownish pigment) remind one of the hepatic cell (Fig. 121). They have a strand or column-like arrangement. Very frequently the blood-vessels are here regularly ensheathed by such cell layers, as we have described them (p. 55) in connection with the vicinity of the vessels.

The blood-vessels (Fig. 163, *c*) circumvolute the convoluted seminiferous canals in close apposition, with a long-meshed, tolerably wide capillary net-work. We find this net-work more strongly developed and rounded in the epididymis. The latter part, also, probably has a secretory glandular activity (Mihalkovics).

Let us consider, finally, the lymph passages (*d*); for the gland tissue is entirely without lymphatic vessels. It was Ludwig and Tomsa who founded our knowledge of this subject. Subsequent investigations, also a trifle of mine, have been added.

The lymph passages keep in the spaces of the connective tissue, bounded by the membranous but fenestrated combinations of the flat connective-tissue cells.

They form a copious reticular canal-work. In transverse sections of the seminiferous canals they form regular rings around the latter, with large expansions at the nodal points. A continued injection finally drives the mass through the spaces of the flattened cells, as far as the outer layers of the walls of the seminiferous canals. The solid inner layer of the latter alone prevents the further advance of the mass (Mihalkovics). Here and there a blood-vessel becomes ensheathed by the lymph current, but this is not the rule.

Larger lymph passages penetrate from the glandular portion into the septal system and from here, coalescing, pass beneath the albuginea. Having entered the latter, they become valved vessels, which unite with those of the epididymis. The final removal of the lymph takes place through the spermatic cord.

The testicle arises, similar to the ovary, at the inner side of the Wolffian body. From its canal-work arises the epididymis (equivalent to the parovarium); the efferent canal of the primitive kidney, disappearing in the female, persists in the male generative apparatus, and becomes the vas deferens. The remainder must be left to the history of development.

We have thus far considered only the quiescent gland. Let us now, however, examine the same at the height of its activity.

Let us commence with its product, the semen, or sperm. It is by no means exclusively the product of the convoluted glandular canals of the testicle, but its fluid portions are certainly also derived from the epididymis and the accessory glands, although its most important and characteristic elements originate from the former source.

The whitish, thickened fluid, spread out in a thin layer on the microscopic glass slide, presents a remarkable appearance, which has been stared at for two hundred years, and was formerly very curiously explained.

Innumerable, lively moving, thread-like elements, the so-called seminal filaments, seminal animalculæ, spermatozoa (Fig. 164) are here met with, suspended in a hyaline fluid. Their movement was, at an earlier epoch, credulously accepted as a proof of an independent animal life. The name of the seminal animalculæ, spermatozoa, reminds one of that period.

Nowadays we know that the motility of the seminal filaments is very nearly related to the ciliary motion (p. 35); we likewise know that the so-called "seminal animalculæ" represent tissue elements, cell derivatives. We are now no less familiar with the motley diversity of forms which these filaments present in the animal kingdom.

Let us confine ourselves to the class of mammalia.

The filamentous, diminutive thing here shows a so-called head (*a*), then a somewhat thicker, thread-like, middle appendage, the middle piece (*b*), and finally, extraordinarily thin, and becoming finer, the terminal piece or tail (*c*). There was formerly no distinction made between these filamentous portions.

Whether this remarkable structure also has an internal complication is not determined, but is improbable.

The head of the human seminal element appears as an oval disk, somewhat widened backwards, 0.0045 mm. long and about half as much in breadth, and not more than 0.0013 to 0.0018 mm. thick. The entire filament may have a length of 0.0451 mm.; but its terminal end is infinitely thin and difficult to recognize.

In the fruitful copulation, the seminal filaments penetrate the zona pellucida of the ovum, conducted through the very fine porous canals of this envelope (Fig. 158, *a*), and pass into the yolk, that is, into the true ovum cell. They here finally disintegrate by fatty degeneration.

The process of division which we have already mentioned



Fig. 164.—Spermatozoa of the sheep; *a*, head; *b*, middle piece; *c*, tail.

at p. 14 may, indeed, commence without spermatozoa, and even in the mammalian animal; but it soon ceases. When, however, the seminal elements have mingled their expiring body with the yolk, then (in an enigmatical manner, it is true), the multiplying process of the segmentation of the vitellus is continued, until at last innumerable building stones have been acquired, of which we have already spoken (p. 179).

Whence comes the seminal filament?

For more than one generation this question has been very correctly answered: from the convoluted canals of the testicle. But the *how* has called forth the most diversified answers among the older investigators, their successors, as well as the present generation of histologists. The incipient, crude and bad methods of examination certainly led the pioneers to the grossest delusions.

That we at present understand the whole, I certainly doubt very much; still we have made some progress.

Let us listen, therefore, to the results of the most recent studies (Neumann, von Ebner, Mihalkovics).

We have already mentioned (p. 185) that the most external gland-cell layer of the quiescent seminiferous canal presents

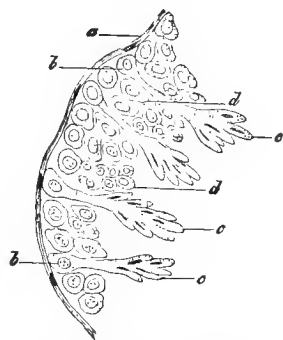


FIG. 165.—From the seminiferous canals of the rat; *a*, parietes with the cell nuclei; parietal cells and spermatoblasts, *c*, the latter with small narrow nuclear corpuscles; *d*, inner cell layer.

a prismatic radiated form. This cell is the spermatozoa-producing structure. All the numerous inner cells of this glandular canal appear to have no future; they form merely an indifferent redundant substance.

When the seminal gland becomes active—in mammals this is only periodically the case, generally once a year, in man in uninterrupted sequence throughout the entire procreative epoch—when, therefore, the testicle is active, a remarkable metamorphosis occurs in these prismatic parietal cells (Fig. 165, *b*).

The epithelial cell-body grows inwards, that is towards the

axis of the glandular canal, into a pedicle or neck-like protoplasmic process. It might remind one of a rude and clumsy candelabrum—but the comparison is a lame one.

These modifications of our peripheral cell layer have been appropriately named spermatoblasts (von Ebner).

In each club-like projection there is formed a nucleus (*c*)—how, we do not know. It becomes the head of the seminal element. The protoplasm, further inwards, is changed into the filament or tail. Thus each of our spermatoblasts produces a number (8 to 12) of seminal filaments. At last the latter are set free, and lie in the lumen of the convoluted canals of the testicle, the caudal end in the axis of the canal, and directed downwards (Fig. 166, 1, *b, c, 2*).

Ova and spermatozoa are, therefore, according to their origin, quite different things. The former represent very highly developed cells; the latter proceed from portions of a more simple cell body.

Let us finally turn to the efferent apparatus.

The vas deferens presents an external connective-tissue layer, a middle layer consisting of three strata of muscles, and, finally, a mucous membrane covered with cylinder cells. The latter acquires below a greater development.

The seminal vesicles and ejaculatory duct have a similar structure.

The prostate presents a system of small racemose glands embedded in an abundance of connective tissue, which first acquire their complete development at the period of puberty. The epithelium has a double layer (Langerhans).

The Cowper's glands likewise belong to the racemose for-

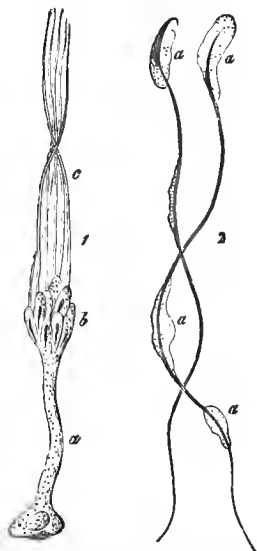


FIG. 166.—Development of the rat's spermatozoa. 1. Spermatoblast *a*, with head *b*, and filament *c*. 2. Nearly mature seminal filament with adherent protoplasmic remains.

mation. Their cells are cylindrical, but become lower in the efferent canal-work.

The male urethra presents a *pars prostatica*, a consecutive membranous middle portion (*pars membranacea*), and a terminal division running through the penis (*pars cavernosa*). The latter portion is surrounded by a cavernous tissue (*corpus spongiosum urethræ*), which takes the shape of the glans anteriorly. Two similar cavernous structures, the *corpora cavernosa penis*, are added.

The mucous membrane of the urethra has at first flattened, and further downwards cylindrical cells. It is surrounded by loose connective tissue, which might be called cavernous in consequence of its great vascularity, and over this there are smooth muscles. Racemose glandules occur in the prostatic portion, as well as in the *colliculus seminalis*. The mucous membrane presents folds. In the middle and lower portions the muscular coating diminishes more and more. The mucous membrane of the lower portion contains excavations (*lacunæ Morgagnii*) and small, undeveloped Littre's mucous glandules. Towards the orifice of the urethra stratified flattened epithelium again commences.

The skin of the penis, thin and flaccid, has a loose subcutaneous cellular tissue, free from fat, and permeated by smooth muscular fibres. An extensible connective tissue, free from fat, unites the two plates of the prepuce; it also contains muscular elements.

The thin skin of the glans has numerous papillæ, which disappear in the epithelial covering; the inner, mucous-membrane-like surface of the prepuce also shows such papillæ.

The Tyson's glands occur on the inner surface of the prepuce, occasionally also on the glans, especially on the *frenulum*. They participate in a very subordinate manner in the formation of the fatty *smegma præputii*.

Let us also mention, in conclusion, the structure of the *corpora cavernosa*. These structures are surrounded by a firmer, elastic element, which is however poor in muscular elements, a so-called *albuginea*. It sends off innumerable

processes in an inward direction, which are sometimes larger sometimes smaller, in the form of trabeculæ and plates. Connective tissue, elastic fibres and smooth muscular substance combined form the latter.

This incomplete system of septa, as we must call it, is divided and interconnected in the most multifarious manner.

We have, therefore, a system of spaces and cavities, reminding one of a bathing sponge, lined with vascular cells, destined to receive venous blood. Herein consists just the peculiarity of the so-called cavernous tissue.

The various "cavernous bodies" present small subordinate structural peculiarities. We pass over these minutiae.

Constantly filled with blood, they become periodically overcharged with the same, and cause the erection of the male organ.

The cavernous bodies receive their blood supply to a slight extent from the *arteria dorsalis penis*, essentially from the *arteria profundæ*. These arterial branches, enclosed in the tissue of the septum, pass into the cavernous spaces, partly through a capillary net-work, partly with an intermediate opening (Langer). Corkscrew-like, crooked arterial branches, the so-called *arteriæ helicinæ* of J. Müller, constitute artefacts (Bouget, Langer).

The various *venæ emissariæ* serve for the removal of the blood from the caverni.

Abundant lymphatic net-works are not wanting in the male urethra and the organ of copulation (Teichmann, Belajeff).

The theory of the erection we leave to physiology.

NINETEENTH LECTURE.

NERVE TISSUE.

WE turn to the final and highest histological formation of the animal body: we refer to the nerve tissue.

This has been included among the so-called "compound tissues," that is those which possess more than one element. And, in fact, we here meet with two such, namely, fibres and cells. The former bear the name of the nerve fibres, nerve tubes or primitive fibres; the latter are called nerve cells or ganglion bodies.

The human nerve fibres appear either as dark contoured medullated elements (Fig. 167) or as pale non-medullated ones (Fig. 172, *b*).

Since the former constitute by far the most widely extended and important peripheral elements, let us begin our discussion with them.

They are, like the non-medullated, for long distances unramified filaments, but of very unequal diameter, from 0.0226 to 0.0018 mm. and less. We distinguish, accordingly, broad or coarse nerve fibres (Fig. 167, *a*) and fine or narrow ones (*c*, *d*, *e*). Intermediately between these appear the nerve tubes of medium width (*b*).

Let us commence our investigations of the structure with the coarse, medullated elements.

Fresh and living, it appears like a thread of a homogeneous milk-glass-like substance. We recognize in it no further composition.

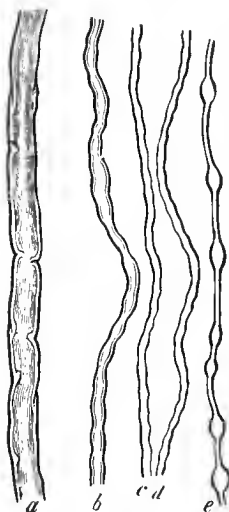


FIG. 167.—Human nerve fibres: *a*, broad; *b*, medium breadth; *c*, *d*, *e*, fine.

The nerve tube is, however, a marvelously changeable thing. Under our eyes, and against the will of the observer, it changes its original appearance most rapidly into a second, third cadaveric image.

It is at present established that every broad nerve tube consists of three elements.

It is invested by a, as a rule, very fine homogeneous connective-tissue envelope, the neurilemma, the Schwann's or primitive sheath (Fig. 169, *b*, 171, *e*). The latter contains, from point to point, an elongated nucleus. Occasionally the neurilemma appears considerably thickened (Fig. 171, *c*).

In the axis, occupying a fifth to a fourth of the entire diameter, we recognize a pale cylindrical filament, formed of

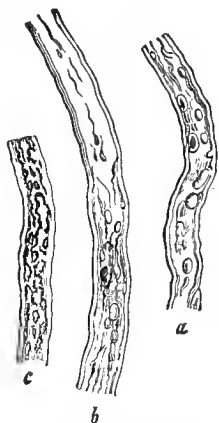


FIG. 168.—Human nerve fibres in various stages of coagulation.

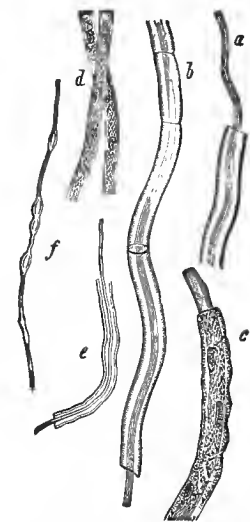


FIG. 169.—Various nerve fibres; *a*, after treatment with absolute alcohol; *b*, with collodion; *c*, fibres of the lamprey; *d*, from the olfactory nerve of the calf; *e* and *f*, from the human brain.

an albuminous substance. This is the axis cylinder, the sole essential portion of the nerve tube (Fig. 169, *a*, *b*, *c*, *e*, 171, *e*). It is surrounded by the so-called nerve medulla or medullary sheath, a peculiar and very delicate combination of albumin-

ous bodies, as well as lecithin and cerebrin. This investment originally conceals the axis cylinder.

As soon as we isolate broad nerve tubes, we encounter the cadaveric form of the medullary sheath (Fig. 168). "They are now coagulated," is a customary expression of the histologists. We meet with the most varying stages of coagulation, often close to each other, and even in the course of one and the same primitive tube.

As a commencing stage, we discover on both sides a double contour, a sharp but dark external, and a closely applied finer border (Fig. 167, *a, b*, 168, *b*, above).

Later, the double contours no longer run parallel with each other, and the inner one appears frequently interrupted (Fig. 168, *b*, below). The latter becomes constantly more and more irregular, and in the previously homogeneous axis portion, dark bordered, lumpy substances are formed (*a, b*). The process of coagulation may, it is true, be arrested at an earlier stage. The cortex then forms to a certain extent, a protective mantle around the axis portion. In other cases, the latter also does not escape its final destiny; together with the cortex it is completely disintegrated into clots (*c*).

It was a long time before the just described structure of the nerve tubes could be agreed upon. The existence of the axis cylinder, especially, gave rise to heated debates. It is to-day a child's play to recognize the latter in any transverse section of a hardened peripheral nerve or—which amounts to the same—each primitive tube in a white column of the spinal cord (Fig. 170).

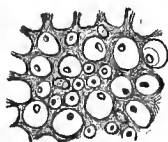


FIG. 170.—Transversely divided nerve fibres from the posterior column of the human spinal cord.

The nerve tubes of medium size have a similar constitution.

A similar structure—envelope, axis cylinder and medullary sheath—is also perceived in the fine filaments of the nerve trunks. The medullary sheath (Fig. 167, *c, d*) remains clear, and simply demarcated, even with advanced post-mortem changes. Osmic acid, which rapidly blackens the medulla of the broad nerve

fibres, as it does other fatty substances, here acts much less thoroughly and more slowly; there must certainly, therefore, be a difference in the constitution of these two different fibrous substances.

Our fine nerve tubes present an additional peculiarity. Every mistreatment, pressure, pulling or reagent to which it is subjected causes a certain displacement of the medulla, so that unnaturally thinned spaces interchange with rounded bulgings (*e*). The latter have been designated as varicosities, and varicose nerve fibres are spoken of. Nothing of the kind exists during life.

We here touch upon another unsettled question. Ranvier, at present the first histologist of France, called attention to a familiar phenomenon, to constrictions which occur in the course of broad medullated (peripheral, but not central) fibres. Formerly, however, these constrictions were always regarded as a product of the methods of preparation. Now, these constricted places (Fig. 171) are pretty regularly situated, and between every two, very nearly at half the distance, one meets with a nucleus of the sheath of Swann (*a*). It is thus in mammals, birds, and amphibia; but in fishes the number of nuclei is greater between every two of these constrictions.

These Ranvier's "constriction rings," as the Germans have christened them, deserve—although we are at present far removed from an accurate knowledge of them—every consideration. The medullary sheath certainly isolates the axis cylinder; but this medullary space permits the penetration of nutrient

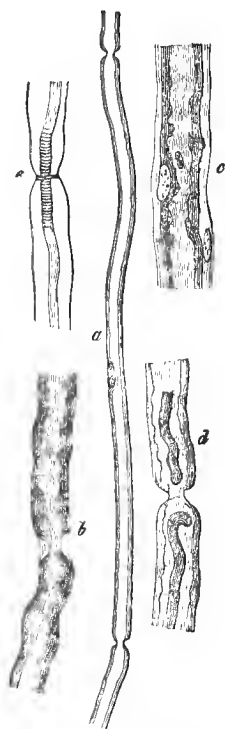

FIG. 171.—Nerve fibres of the frog; *a*, after treatment with picric acid; *b*, *c*, *d*, with osmic acid; *e*, with nitrate of silver.

constituents and the giving off of the products of decomposition.

Let us now pass to the pale non-medullated nerve fibres.

Originally, in the fœtal period, all the primitive tubes of the entire nervous system were thus constituted. If we take one of the lowest fishes, the lamprey (*petromyzon*), we meet with this condition throughout its entire life (Fig. 169, *c*). A nucleated sheath invests the axis cylinder. Medullated nerve fibres are here entirely wanting.

Let us turn, at a bound, to the highest animal being, to man.

In us, the olfactory nerve, alone, consists throughout of pale, non-medullated fibres, as does in great part the sympathetic with its ramifications.

These structures have been called Remak's fibres. They appear as delicate 0.0038 to 0.0068 mm. wide, nucleated filaments (Fig. 172, *b*).

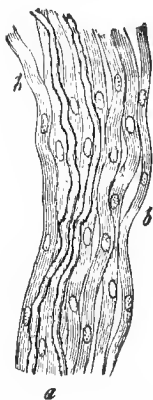

FIG. 172.—A sympathetic nerve branch of a mammalian animal; two dark bordered nerve fibres, *a*, with an excess of the Remak's formation, *b*.

Does what has been mentioned above, however, contain the entire structure of the nerve fibre? We now encounter this difficult question.

It does not appear so; nevertheless, we are once more at the limits of the microscopy of the present day.

The axis cylinder, the best portion of the nerve tube, most probably consists of a bundle of extremely fine filaments.

They (Fig. 173) appear to be embedded in a delicate granular substance. They have been called axis fibrillæ (Waldeyer) or primitive fibrillæ (Schultze). Here, also, the incitation was furnished by a brilliant investigator, who has by no means been honored by his cotemporaries in proportion to his merits, Remak, the founder of the modern history of development. Many years ago he saw this combination in the nerve fibres of the river-crab.

Diagnostic weight has subsequently been laid on the finest varicosities of these primitive fibrillæ (M. Schultze).

We shall subsequently return to this.

We are now, so far as it is at present possible, familiar with the fibres. Let us turn to the cellular elements. They belong solely to the gray substance of the nervous system (the peripheral, as well as the central); the white substance consists throughout solely of nerve tubes.

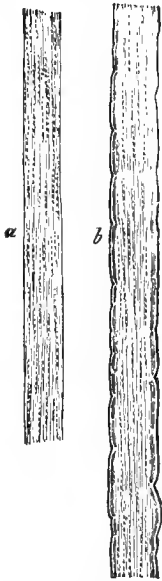


FIG. 173.—Fibrillated arrangement of the axis cylinder; *a*, a thick axis cylinder from the spinal cord of the ox; *b*, nerve fibre from the brain of the torpedo.

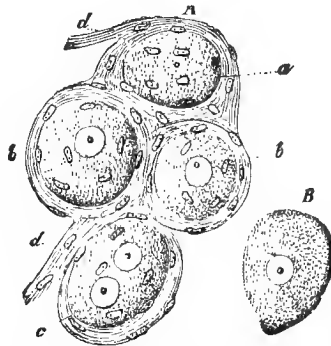


FIG. 174.—Ganglion cells of the mammalia; *a*, cells with connective-tissue envelopes, which are continued in fibres, *d*, *d*; *a*, *a* cell without a nucleus; *b*, two single nucleated ones; and *c*, one with two nuclei; *b*, a ganglion body with an envelope.

We frequently encounter, in a very characteristic form, those cellular elements, the ganglion bodies (Fig. 174, *B*). It is one of the handsomest cell-forms which the organism possesses. The dimensions of most of the globular, ovoid or pear-shaped elements lies between 0.0992 to 0.0451 and 0.0226 mm. In a very delicate granular, thickly gelatinous, generally colorless, occasionally brown or black pigmented mass, we meet with a globular, delicate walled nuclear vesicle, 0.0180 to 0.009 mm. in diameter. In it occurs, as a rule single, a dull glistening granule, the nucleolus, 0.0029 to 0.0045 mm. in size.

Our structure is surrounded by an envelope. It appears thick, a sort of nucleated connective tissue at the first glance; however, the nuclei may have another signification, for, on the inner surface of the capsule, a lining of endothelial cells has subsequently been noticed.

This envelope appears more simple and thinner around the ganglion cells of the lower vertebrates, fishes (Fig. 175) and amphibia.

At the first, most cursory examination—and the older histologists, with their bad methods of investigation, arrived no further—all the peripheral ganglion cells appear to have no processes or, as a scholastic expression runs, are apolar. We have subsequently adopted an entirely different view; apolar ganglion cells either do not occur at all, or only exceptionally as embryonic, arrested in their development, and possibly futureless elements.

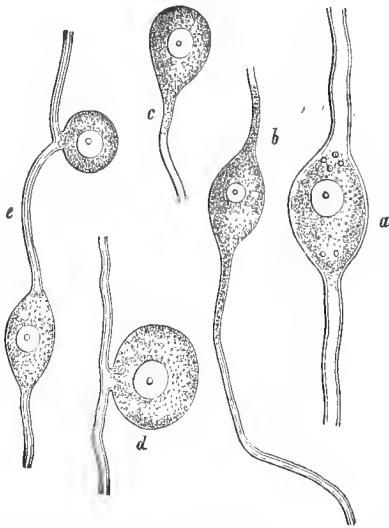


FIG. 175.—From the peripheral nerve ganglion of a fish, *godus lota*; *a, b*, bipolar ganglion cells; *c*, unipolar; *d, e*, abnormal forms.

About 1845, Koelliker, one of the most celebrated histologists, discovered in the sympathetic of the vertebrates ganglion bodies which sent off from one of their ends a pale filament, which after a sometimes shorter, sometimes longer course, was enveloped in a medullary sheath, and became a nerve fibre (Fig. 175, *c*).

In vertebrate creatures something of the kind has, it is true, been previously seen. These are the so-called unipolar ganglion cells.

Soon after this, R. Wagner, Robin and Bidder, with R. i

chert, met with other conditions. They discovered the bipolar cells.

The spinal nerves arise by a double root; an anterior, which passes over the spinal ganglion, and a posterior, which passes through the ganglion.

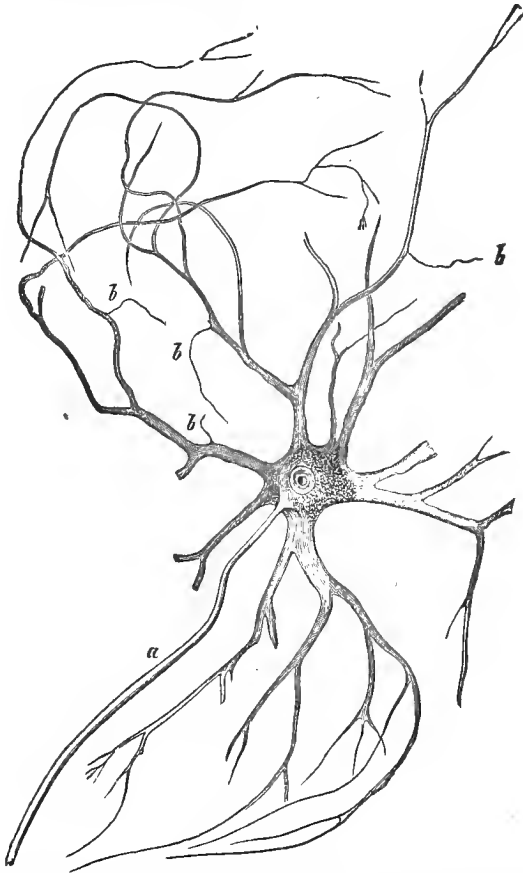


FIG. 176.—Multipolar ganglion cell from the anterior horn of the spinal cord of the ox, with the axis cylinder process (*a*), and the branched protoplasmic process, from which, at *b*, the finest filaments arise.

As has been known since the days of Charles Bell, the former consists of motory, the latter of sensory filaments.

On teasing out the spinal ganglion of a fish (the ray is most to be recommended) we recognize (Fig. 175) that each nerve fibre penetrates a ganglion cell, to again pass out at the other pole (*a*, *b*). Broad fibres connect with larger cells, narrow nerve tubes with smaller ones.

The latter nerve fibres are probably sensory constituents of the sympathetic. Numerous individual, otherwise constituted combinations occur, in addition to these, perhaps as anomalous products of development (*d*, *e*).

Both varieties of ganglion cells show distinctly that their envelope passes over into the primitive sheath of the nerve fibre connected with them.

As a third form, we have to mention the multipolar ganglion cells. They were seen for the first time in the year 1838 (Purkinje). They are met with in man in the sympathetic ganglia, in the retina of the eye, and in the gray substance of the brain and spinal cord.

In the so-called anterior cornu of the latter is found the elegant form of our Fig. 176.

A membraneless cell body sends off a varying, often quite considerable number of delicate granular processes (*b*), which undergo repeated divisions and continual ramifications, until they at last disappear from view in the form of the finest filaments. The finest lateral filaments were regarded as primitive fibrillæ of the axis cylinders (Deiters), but hardly with accuracy, for all is here obscure.

Together with this system of processes—they have been called protoplasmic processes—we also meet with a long process, which is always single, and usually arises from the cell body, more rarely from the origin of another thick offshoot. It never ramifies, and is conspicuous from its sharper, homogeneous appearance. This is the axis-cylinder process (*a*). Later it is invested by the medullary sheath, and becomes a nerve fibre. This has also, however, been recently doubted (Golgi).

In the sympathetic of the frog Beale and Arnold met with an interesting, although not yet accurately determined struc-

ture of the cells (Fig. 177). From the interior of its rounded, or pear and kidney-shaped body passes a straight axis-cylinder process (*c*), which subsequently acquires a medullary sheath.

From the surface of the cell arises, singly or doubly, with close spiral convolutions, another filament, which surrounds the straight axis cylinder with wider turns; it may also run alongside of the latter (*d*), and subsequently leave it (*f*), passing further in a straight form. Whether these spiral fibres are elastic or—which we regard as more probable—are actually of a nervous nature, is still undecided. Subsequent German investigations have, unfortunately, not determined this.

Finally, the fine, fibrillated formations, such as are presented by the axis cylinder (p. 196), have also been most recently observed, continuing into the interior of the cell body, and more especially in the cortical portion of the latter. The finest fibrillæ which stream in from the protoplasm, as well as the axis-cylinder process, run sometimes divergently, sometimes crossing each other.

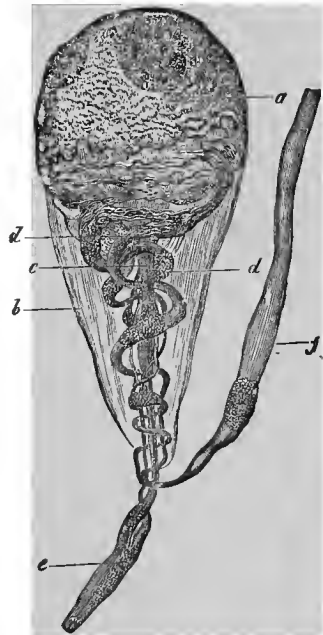


FIG. 177.—Ganglion cell from the sympathetic of the hyla or green tree-frog; *a*, cell body; *b*, sheath; *c*, straight nerve fibre; and *d*, spiral fibre; continuation of the former, *e*; and of the latter, *f*.

TWENTIETH LECTURE.

THE ARRANGEMENT AND TERMINATION OF THE NERVE FIBRES.

THE spinal nerves and those of the brain appear white through the medullary sheaths of their tubular constituents; the trunks of the sympathetic appear gray from the excess of non-medullated fibres.

The former, at their exit from the central organ, become invested in a delicate connective-tissue envelope; they are subsequently surrounded by an additional reinforcement of connective tissue, furnished by the dura mater. This affords together the nerve sheath, perineurium or neurilemma. This connective tissue penetrates, in a lamellar or sheath-like manner, between the bundles of nerve fibres, becoming, at the same time, looser and softer. Its modified boundary layer forms at last the primitive sheath of the nerve tube. A scanty, straight net-work of finest capillary vessels permeates the whole. Injections made from the lymph spaces likewise penetrate beneath the perineurium and between the nerve bundles (Key and Retzius).

The primitive fibres run alongside of each other in the nerve trunk, undivided and indifferent. The nerve trunks usually send off their branches at an acute angle, the bundles of fibres bending away from the main path to the lateral.

When anastomoses take place, groups of fibres pass, at the point of communication, from the one nerve to the other, or we have a double interchange of fibres.

The perineurium becomes finer and finer in proportion as we proceed from the larger trunks to the finest systems of branches. Finally, it appears as a striated or more homogeneous connective substance with rather stunted cells.

The investigation of the peripheral termination of the nerve tubes—in the crude, incipient period they were erroneously regarded as a noose or loop-shaped connection between each two fibres—cost the histologists much trouble and labor, and even at the present day we are still far removed from a satisfactory scientific possession. We present only the most important facts, and leave numerous, in part very uncertain, minutiae to the more comprehensive text-books on this subject.

Let us commence with the termination of the motory nerve fibres in the transversely striated muscle.

If we follow the small nerve branches which have entered the latter, in suitable objects, for example, many quite thin membranous muscles of the frog, we meet with a few broad, double contoured nerve fibres, subsequently surrounded by a hyaline sheath. If the branch divides again, we not infrequently perceive that something new comes over the nerve tube; it becomes narrower, forming a Ranvier's constriction ring (p. 195), and, at the same time, divides into branches, two as a rule. With the continued division of these smallest nerve trunks, this diminution of the nerve branches is continued; they divide into branches of a new order, and so on. The latter hereby become finer, but still retain the double contours for a distance; at last they are bordered by a simple boundary line.

In the lower vertebrates this ramification of the primitive tubes is very extensive. In fishes, the latter may finally divide into fifty and even one hundred branches. Reichert, many years ago, examined the so-called thoracic cutaneous muscle of the frog. It contains from 160 to 180 muscular filaments, but only from 7 to 10 nerve tubes pass in for their supply.

While, therefore, in the lower vertebrates a motory primitive fibre supplies with its system of branches quite a number of transversely striated muscular filaments, the arrangement is different and higher in mammals (and even in reptiles and birds). The primitive fibre is much less divided; the mis-

proportion between the number of the nerve and muscular filaments is accordingly very much less.

In regard to the termination, the lower vertebrates present a different condition from that of the higher. The termination takes place regularly, however, in the interior of the muscular filament, beneath its sarcolemma. We consider only the mammalian muscle (Fig. 178).

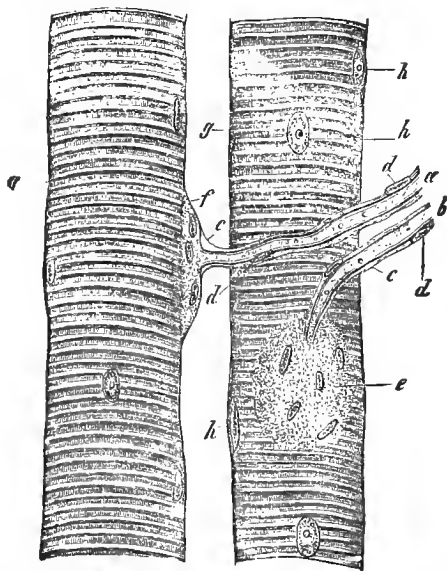


FIG. 178.—Two muscular filaments from the psoas of the Guinea pig, with the nerve terminations; *a, b*, the primitive fibres and their continuation into the two terminal plates *e, f*; *c*, neurilemma with nuclei, *d, d*, and passing over into the sarcolemma, *g, g*; *h*, muscular nuclei.

The nerve fibre (*a, b*), surrounded by an expanding nucleated primitive sheath (*c, d*), here passes to the muscular filament. Its neurilemma becomes the sarcolemma (*g*). Beneath the latter, at the place of entrance, appears a nucleated, delicate molecular substance, a rounded or oval bent plate with nuclei (*e, f*), concave within, convex without. This (occurring only single in the mammalian muscle, and more towards the middle) is the terminal plate of Krause, Rouget and Engelmann, or the nerve-mound of Kuehne. At *f*, we have the

profile view; at *e*, we see the structure from its broad external surface. Its size varies between 0.0399 to 0.0602 mm.; the number of the nuclei from 4 to 20.

The great delicacy and changeableness of the motory terminal plate impedes its further study considerably. Does the axis cylinder actually cease on spreading out into the former? Or, does the termination of the axis cylinder first occur in the interior of the terminal plate, so that the signification of something like a cushion is to be ascribed to the latter?

In the muscular filament of the lizard (Fig. 179) we obtain, under certain circumstances, a peculiar interesting appearance. In penetrating the terminal plate, the axis cylinder of the nerve fibre (*b*, *c*) divides and, rapidly losing its medulla, passes over by a continual ramification into a pale, obtusely branched, antler-like figure (*d*, *d*). The molecular nucleated substance is just beneath this expansion. We are indebted to Kuehne for this observation. I have seen something similar by reëxamination; but we are once more at the limits of the present microscopy. Kuehne named this antler-like formation the true terminal plate.

This is, according to our experience, the present state of the matter. Others maintain deviating views, as most recently Arndt and Gehrlach. It is impossible for us to enter here into a polemic, the more so as this lies at the limits of the present microscopic perception.

Concerning the nerve termination in the muscles of the heart, only hypotheses exist at present.

We have also no very satisfactory knowledge of the nerves of the smooth muscles.

Many years ago various observers (Beale, Arnold, His,

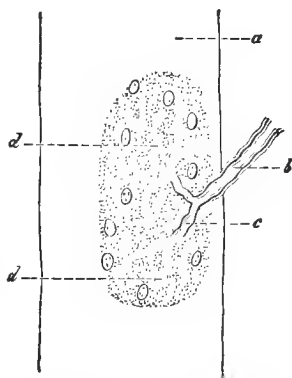


FIG. 179.—Muscular filament (*a*) of the lizard; *b*, nerve fibre; *c*, its branches with the peculiar terminal figure, *d*.

Klebs and others) had met in this tissue formation with plexuses or net-works of pale, fine nerve fibres with nuclei in the nodal points. This net-work was regarded as terminal. Others have, however, proceeded further, whether correctly we certainly doubt.

Arnold, who has investigated these things most accurately, gives us the following information concerning them :

The nerve trunks of the smooth muscular tissue (Fig 180) consist in part of medullated, in part of non-medullated fibres.

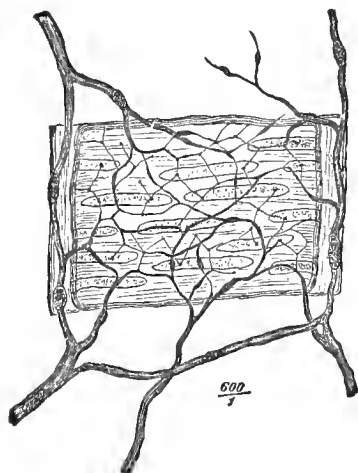


FIG. 180.—The termination of the nerves in the smooth muscles of a frog's artery.

The latter diminish into nucleated filaments measuring 0.0018 to 0.0023 mm. Even externally in the connective tissue surrounding the muscular substance, there occurs a wide-meshed plexus, having ganglion cells in places, Arnold's so-called basis plexus. From the latter pass nucleated fibres, which become pale, longitudinally striated, nucleated filaments, 0.0041 to 0.005 mm. in diameter. The latter gradually diminish to 0.0018 to 0.0023 mm.

From these—though pale and, therefore, non-medullated fibres also enter it from the basis plexus—there is formed a second and likewise tolerably wide-meshed reticulum, which also has nuclei at the nodal points. This is Arnold's intermediate plexus. It is either closely applied to the smooth muscles, or lies in the connective tissue between the several layers of the first-mentioned tissue.

From this second plexus pass off fine fibres, which are at first still nucleated. They rapidly become finer, and pass between the contractile fibre cells. Finally, after repeated divi-

sions, they have diminished to fibrillæ of only 0.0005 to 0.0003 mm. They are said to form a new, but now very narrow-meshed reticulum of the third order, the intramuscular plexus, between the spindle cells of the tissue.

From the latter proceed extremely fine filaments, 0.0002 mm. in size, and therefore primitive fibrillæ, into the fibre cells. Their discoverer, Frankenhaeuser, asserts that they terminate in the nucleoli, but Arnold is already doubtful on this point.

A few years ago, as I examined the muscular vascular walls of the frog, by the aid of the best customary methods, I saw only nerve plexuses. Klein also went no further. I suspect that the predecessors—in this most difficult department—have also deceived themselves.

The nerves of the cornea of the eye have been the object of very extensive researches for years. We here meet with a twofold manner of termination; one in the proper corneal tissue, and another in the epithelial stratum of the free anterior surface. The latter is certainly sensory, the former most probably of a motory nature.

The corneal nerves enter at the periphery as a bundle of fine, at first medullated fibres. The medullary sheath is soon lost; we have pale filaments to which must here, as in the smooth muscles, be at first ascribed the signification of the axis cylinder, and subsequently of the primitive fibrillæ (p. 196). In the cornea we also meet, from behind forwards, with a series of nerve plexuses, lying one over the other, with evident divisions of the fibres.

A considerable contingent of the latter terminate in the corneal tissue. *How*, is unknown. A former statement of Kuehne's, according to which the primitive fibrillæ were said to finally unite with the corneal cells (p. 56), could not be confirmed.

Cohnheim, after the example of Hoyer, has shown that from the most superficial nerve plexus of the cornea the finest nerve filaments (primitive fibrillæ or fasciculi of the latter) pass into the stratified, flattened epithelium of the above mentioned

conjunctiva corneæ. Ascending perpendicularly, and ramifying once more, they finally disappear in the most superficial layers of flattened cells (Fig 36, *d, e, f*).

We have no certain knowledge concerning the termination of the nerves of glandular organs. That the secretion of the submaxillary gland is very dependent on nervous influence (p. 140), is an old physiological experience. What Pflueger has communicated concerning the salivary glands and the liver has not been confirmed. Other statements of Krause's must likewise be more accurately tested.

Passing now to the sensory nerves, we meet with three different conditions :

- a.* A portion of the same run out into considerable, and in part, right complicated larger or large structures.
- b.* Others have their termination in the small corpuscles of the epithelium.
- c.* The higher nerves of sense, finally, pass into quite peculiar specific cellular elements, so-called "sensory cells."

We discuss directly the first two terminations. The third and last we shall have to mention at the organs of sense, at the close of these lectures.

The larger terminal apparatuses of the sensory nerves are :

- 1. Krause's terminal bulbs.
- 2. The Pacinian corpuscles.
- 3. The Wagner-Meissner's tactile bodies.

Let us commence with the first. The terminal bulbs, discovered by Krause, are of isolated occurrence, and are not easy to find in the unpropitious tissue of the mucous membrane ; they are by no means favorites of the histologists. For years, only Koelliker and myself maintained their existence, which was at that time doubted even by Arnold. Waldeyer, an excellent investigator, recently declared to us that he had also been unable to find them. I have seen them in the calf, but have not had a sufficiency of human autopsies.

According to Krause, the terminal bulbs occur in the conjunctiva bulbi, in the mucous membrane of the floor of the

mouth, in the papillæ fungiformes and circumvallatæ of the tongue, in the glans penis and clitoridis. The discoverer also found them in not inconsiderable extension in mammals.

Let us take the sclerotic conjunctiva of a calf's eye (Fig. 181), and follow the course of the nerve through the separated mucous membrane. After a long interval, we meet in the first place (*) with a dichotomous division of the double contoured nerve fibre (*c*). Then, after following the branch for a shorter or longer distance, we arrive at a striking appearance (*a*). It is an elongated oval, occasionally slightly bent body, measuring 0.0751 to 0.1409 mm. in its greatest diameter, and about one-third as much in its transverse. In man and the ape, the structure has a globular form, according to Krause.

Let us return to the calf. We here meet with a dull, nucleated, moderately thick envelope, with an enclosed hyaline, homogeneous, rather thick fluid contents.

The primitive sheath of the nerve trunk gives off its neurilemma to this membrane, or, to express ourselves more intelligibly perhaps, it increases in thickness and becomes the parietes of the terminal bulb.

At the first cursory examination, one might suppose that the nerve fibre had thus terminated. One would, however, be very much deceived; for, after losing its medullary sheath, the most important constituent of the nerve fibre, the axis cylinder, passes through the structure to end at the opposite pole, occasionally with the slightest intumescence.

This is the terminal bulb, so far as I am familiar with it.

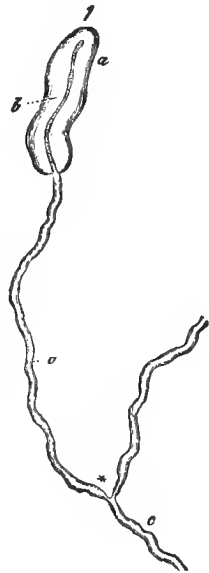


FIG. 181.—Terminal bulb from the conjunctiva bulbi of the calf; *a*, terminal bulb; *c*, nerve fibre, branching at*; *b*, axis cylinder.

Concerning the Pacinian capsules (Fig. 182) we have abundant and no longer to be doubted material.

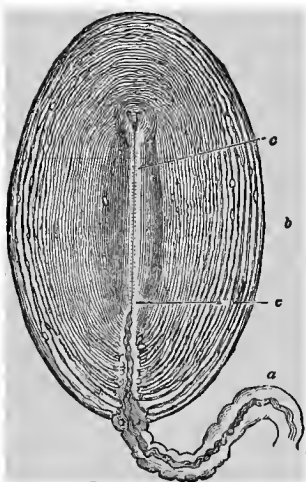


FIG. 182.—Pacinian body from the mesentery of the cat; *a*, nerve fibre with its envelope, forming the stem; *b*, the capsular system; *c*, the axis canal or inner bulb, in which the nerve tube ends.

These structures have had a peculiar history.

They have been known for more than one hundred and thirty years.

They were described in 1741, in the doctor's dissertation of a certain Lehmann, having already been discovered by a professor Vater of that period. They were forgotten for nearly three generations.

They were rediscovered soon after 1830, without any presentiment of a predecessor, by Pacini of Pistoja and, almost simultaneously, on the occasion of an anatomical concourse, by Parisian physicians. The attention of the German investigators was

especially directed to our structure by the monographs of Henle and Koelliker, in the year 1844. As a student at that time in Göttingen, I had already found them in the abdominal cavity of the cat, and had seen the entering nerve.

Let us leave these historical reminiscences, however, and pass to matters of fact.

The Pacinian bodies appear as elliptic structures, measuring 1 to 2 mm. and more, sometimes more elongated, sometimes more developed in width. Without the microscope, we perceive them to be tense, tolerably firm, semi-transparent, and with white axial striations.

They are regularly met with in the human body on the nerves of the palm of the hand and the sole of the foot, especially of the fingers and toes. Their total number varies

here between 600 and 1,400 examples. They may occur manifold or isolated.

In mammals we meet with them in the sole of the foot. An admirable locality is the mesentery of the cat. Many of the latter animals contain them in innumerable quantities; in others, on the contrary, one may bother and fret one's self and find only 6 to 12 altogether.

The capsular system of the Pacinian corpuscle (*b*) is much more complicated in its structure than the simple envelope of the terminal bulb.

It consists of a considerable number of thin, connective-tissue membranes, embedded over each other, and kept tense by a fluid intermediate substance. They formerly appeared to contain nuclei in their parietes. According to the investigation of Hoyer, however, their inner surfaces are lined by a thin covering of nucleated endothelial cells. The outer capsular systems are further removed from each other, following the curvature of the entire structure; the inner ones are more nearly approached to each other, their lateral curvature is lessened, and they finally surround an axial canal. This, the so-called inner bulb (*c*), may be compared to the Krause's corpuscle. It is filled by a homogeneous, tolerably resistant substance.

The capsular systems unite below, and form a thicker connective-tissue tube (*a*). Through it passes a broad or medium sized, but always double contoured nerve fibre. Having entered the inner bulb, it loses (at *c*, below) the medullary sheath; it becomes an axis cylinder, and terminates towards the upper closed pole, for the most part undivided, occasionally (and then varying in its details) divided (*c*, above). This axis cylinder is the most beautiful known. It shows a longitudinally striated structure, and consists of primitive fibrillæ.

Let us turn, finally, to the so-called tactile bodies of the human integument (Fig. 183). They belong—no doubt can prevail concerning this—to the related series of the terminal bulbs and Pacinian structures; but the nerve termination is not yet known.

In a preceding lecture (p. 58), we remarked that the human corium developed papilla-like projections, which were some-

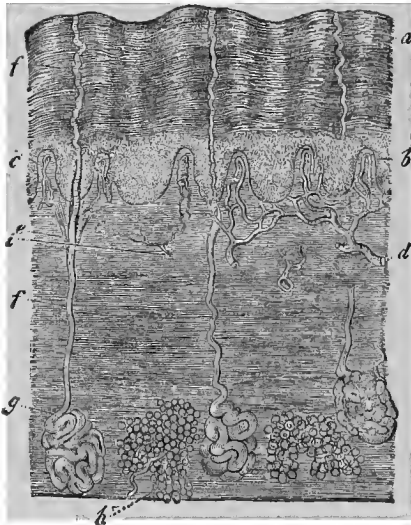


FIG. 183.—Human skin in perpendicular section; *a*, superficial layers of the epidermis; *b*, Malpighian rete-mucosum. Beneath the latter is the corium, forming the papillæ above at *c*, and terminating below in the subcutaneous connective tissue, in which at *h*, aggregations of fat cells appear; *g*, sudoriparous glands, with their excretory ducts *e* and *f*; *d*, vessels; *c*, nerves.

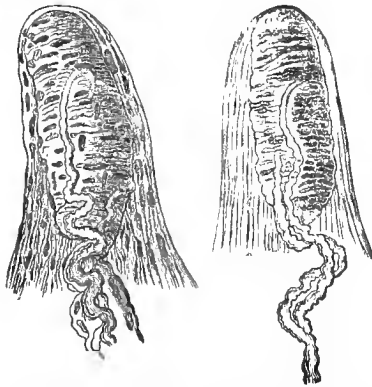


FIG. 184.—Two human nervous papillæ from the skin of the volar surface of the index finger. In the interior of the papilla is the tactile body, into the tissue of which the nerve fibres enter.

times higher, sometimes lower. In the volar surface of the fingers and toes, the hollow of the hand, and the sole of the foot, and, finally, the heel, we meet with papillæ of a double nature. One portion contains a vascular loop (*b*); others, non-vascular, contain the nerve termination (above, *i*). The number of these nerve papillæ is greatest at the volar surface of the finger point; from here they constantly decrease. The toes are less favored;

but here, also, the same law prevails of the diminution towards the sole of the foot. Without going further into this subject, we merely remark here that only the ape, our nearest corporeal relation, presents tactile bodies. They are wanting in the other mammals.

A tactile body (Fig. 184) is either oval or, with smaller dimensions, rounded. Its diameter

varies between 0.0133 and 0.0037 mm. It lies in the axis portion of the papilla, and consists of homogeneous connective substance, with transverse and obliquely disposed nuclei. The whole thing acquires thereby a peculiar appearance, which reminds one of a fir cone. The nerve fibres (with their trunks passing from below upwards) arrive at our structure singly, doubly, or three or four together. Their neurilemma passes over into the capsule. They themselves, after previous curved excursions or looped windings, enter the tactile bodies manifoldly. Having become pale and transformed into axis cylinders, they soon disappear from the eye.

We have thus become familiar with this most peculiar manner of termination of the sensory nerves.

How do the millions of other simple sensory nerve filaments terminate? We now raise this question.

Unfortunately, we know but little concerning this at the present time. Much has been stated concerning the terminal plexuses of the finest nerve fibres, in the frog as well as in mammals.

It is, furthermore, settled that occasionally the terminal filaments of the sensory nerves pass into the epithelium and end in it. We have already become familiar above (p. 207) with the most beautiful example of this kind, in the cornea of the eye (Fig. 36). The primitive fibrillæ here run out between the epithelial cells.

Others speak of a penetration of these filaments into the cells, and of a termination in the nucleolus; thus Hensen concerning the skin of the frog, Lipmann concerning the posterior corneal epithelium of the same animal.

Other cutaneous nerves appear finally in the form of fine non-medullated filaments, which terminate in small cells, 0.0088 to 0.0033 mm. in size, embedded in the human rete Malpighii; a portion of them may also pass further downwards. They have been called Langerhans' corpuscles.

Something similar has been subsequently observed in quite different mucous membranes, where these Langerhans' struc-

tures have sometimes been met with, and sometimes also not found.

The dental nerves appear to be peculiarly constituted (Boll) We have long been familiar with medullated nerve tubes, 0.0067 to 0.0038 mm. in diameter, situated in the parietes of the dental sac. They form below an elongated nerve plexus.

From the dichotomous separation of these nerve tubes arise innumerable very fine primitive fibrillæ. They press through the covering of the odontoblasts (p. 75), reach the inner surface of the dentine, and probably penetrate the dentinal tubules. The latter have, according to this, a double variety of contents, one part being the filamentous processes of the odontoblasts, and then the remains of these nervous filaments. The sensitiveness of the dentine has also been long known by the dentists.

TWENTY-FIRST LECTURE.

THE CENTRAL ORGANS OF THE NERVOUS SYSTEM.—THE GANGLIA AND THE SPINAL CORD.

WHEREVER the ganglion cells accumulate, the formation of a central nerve organ commences. Therefore, from these smallest cells, only to be discovered by means of the microscope, up to the brain and spinal cord, with their immense, frequently combined, gray substances, proceeds a continuous series of developments. Our knowledge concerning the latter is at present, however, very insufficient; methods for managing such complicated structures are wanting.

Let us discuss, first, the peripheral ganglia or nerve nodules (Fig. 185). A connective-tissue envelope, a modified perineurium, surrounds the organ. It sends into the interior, fenestrated, leaf-like processes, the bearers of a tolerably developed capillary network. The irregular and also connected cavities are filled with ganglion cells (*d, e, f*), placed close to each other, and invested by connective tissue.

Between them run isolated nerve fibres or bundles of the same. At an earlier period it was believed that both these elements, the cellular and the fibrous, merely lay alongside of each other. At that time they distinguished penetrating primitive fibres, which passed for the most part in bundles and straight through the nodules, and circumgyrating, which passed singly, with

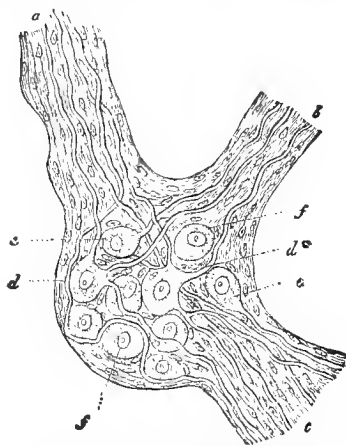


FIG. 185.—A sympathetic ganglion of the mammalian animal (diagramatic); *a, b, c*, the nerve trunks; *d*, multipolar cells; *d**, one with a dividing nerve fibre; *e*, unipolar; *f*, apolar.

manifold turnings, through the narrow spaces between the ganglion bodies, to subsequently reassociate themselves with the out coming (single or multiple) nerve trunks.

This arrangement does in reality (combined, it is true, with transitions) occur. We already know that the ganglion cell enters into communication with the nerve fibre (Fig. 175).

In the ganglia of fishes and amphibia, the connective tissue is weakly developed; the elements are, therefore, more readily isolated, still we have by no means any satisfactory results to report. The ganglia of higher animals are, however, permeated by an exuberant fulness of firm connective tissue; picking them apart yields us, unfortunately, only the fragments of the nervous contents.

The requirements of the physiologist, who desires an insight, cannot at present suffice here for the microscopist, and, indeed, should not. For he would have to combine an imperfect perception with hypotheses into an abstract image. For the coming races of men, the light of a better intelligence will be kindled at some future day. We grope about in the dark.

Let us take a spinal ganglion of the fish, with its ganglion bodies. The greater portion of the latter are certainly bipolar, that is, the cell is interpolated into the course of a broad sensory fibre of the spinal cord (Fig. 175, *a*).

Since the elements of the sympathetic in fishes exhibit narrow medullated nerve fibres, we should accordingly declare the nerve fibres connected with ganglion bodies to be sensory elements of this division of the nervous system (*b*).

One meets in our ganglia, furthermore, with smaller unipolar cells (*c*). Their narrow, sympathetic nerve fibre passes downwards and spreads out peripherically. The ganglion might, with these latter constituents, be one of the many centres of the sympathetic, like all the remaining ganglia of the fish's body.

Even in the frog, however, the matter becomes much more difficult. The presence of bipolar ganglion cells, interpolated into the course of a sensory fibre of the spinal cord,

is not determined with certainty; neither is that of sympathetic bipolar ganglion cells. We are only familiar here with the unipolar cells with the descending, narrow, sympathetic nerve fibres.

We know next to nothing, at present, about the similar nerve ganglia of the mammalian animal.

Let us now pass to the sympathetic in the sense of the older anatomy. In the frog we can, at least, demonstrate unipolar ganglion cells. Others give us the impression of the apolar, whether rightly or not we leave undecided.

Sixteen years ago, by the aid of Remak's investigations, I drew the diagrammatic figure 185, as a sympathetic ganglion. I repeat the figure here; not because I regard it as complete (I am far removed from this), but because I am unable to present any better substitute in a more reliable manner. So slight has been the advance made during this long epoch! Remak, that excellent observer, here met with multipolar ganglion cells. He attributed to them 3 to 12 processes, which might be increased two or threefold by further ramifications. They are said to at last become nerve tubes. According to what we have learned above (Fig. 176) concerning the protoplasm and axis-cylinder processes of the ganglion cells, this cannot very well be correct. Repeated, more accurate investigations appear, in consequence, to be urgently necessary; but who will make them?

With the larger sympathetic ganglia are associated a number of smaller and smallest ones. This is the case in the ciliary muscle and in the choroid of the eye, in the expansions of the glosso-pharyngeal nerve passing to the œsophagus, in the lingual branches of the ramus lingualis of the fifth nerve. We also meet with similar small ganglionic enlargements in the walls of the larynx, and of the bronchi, in the interior of the lungs, and in the heart muscles.

In the walls of the digestive apparatus there is a developed plexus of ganglia belonging, in the first place, to the submucous tissue; then there occurs in the muscles, between the longitudinal and annular layers of fibres, the plexus my-

entericus, discovered by Auerbach, with its manifoldly multipolar cells (L. Gerlach). The former plexus appears to be of a motory and sensory constitution; the latter possesses predominantly the former nature. Such small ganglia are also encountered in the urinary and generative organs, as well as in glandular structures. Our Fig. 186, a ganglion

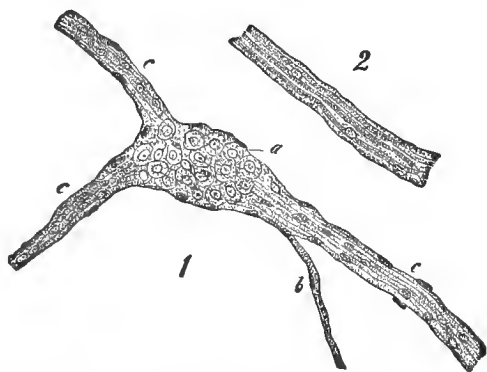


FIG. 186.—Ganglion from the submucous plexus of the small intestine of an infant; *a*, ganglion with the ganglion cells; *b*, *c*, nerve trunk, with the pale, nucleated fibres; 2, a nerve trunk from a boy five years old.

from the submucous plexus, may represent this. At *a*, we perceive the ganglion with the non-medullated, nucleated fibres; at 2, a similar nerve trunk is isolated.

Let us now turn to the cerebro-spinal system, to the spinal cord and brain.

The spinal cord (Fig. 187) presents a cylindrical cord, consisting of an inner gray and an outer white substance. Both form connected layers of substance throughout the entire length of the spinal cord. The gray substance forms an irregular Latin H, in transverse sections. One distinguishes accordingly, anterior (*d*) and posterior (*e*) horns. The latter are then invested by Rolando's "gelatinous" substance. In the centre of the whole we perceive, lined with cylinder cells, the axis canal (*a*), the last remains of a much wider cavity in the earlier foetal period. Two deep furrows, the fissura anterior (*b*) and posterior (*c*), cut nearly into the centre. In

front of this exists a crossing of nervous fibres, the commissura anterior (*f*); behind the axis canal we meet with a predominantly connective-tissue mass, the so-called commissura posterior (*h*). The white investing substance presents the

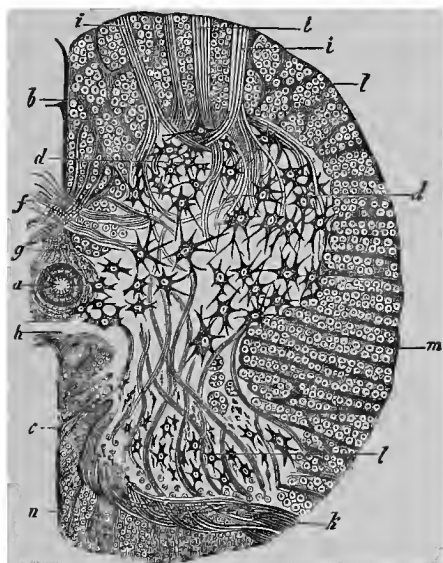


FIG. 187.—Transverse section through the lower half of the human spinal cord; *a*, central canal; *b*, fissura anterior; *c*, fissura posterior; *d*, anterior horn, with the considerable ganglion cells; *e*, posterior horn, with the smaller ones; *f*, anterior white commissure; *g*, frame-work substance around the central canal; *h*, posterior gray commissure; *i*, bundles of the anterior, and *k*, posterior spinal roots; *l*, anterior, *m*, lateral, and *n*, posterior column.

anterior column (*l*), the lateral (*m*), and the posterior (*n*), consisting essentially of longitudinally arranged medullated nerve fibres. At the margin of the anterior and lateral columns, the motory roots of the spinal nerves pass through to the gray substance (*i*); between the middle and posterior systems of columns we perceive, shining through, the posterior sensory roots of these nerves (*k*).

A delicate connective tissue permeates the whole organ as a supporting and frame-work substance. It is the bearer of the nutritive system of blood-vessels.

Let us first discuss this connective-tissue substratum.

Our supporting substance comes forward most purely in the vicinity of the axis canal; externally, toward the periphery of the gray substance, it becomes profusely permeated by nervous elements. It has been given the name of the neuroglia (Virchow).

As we here naturally pass over the subordinate varieties, we will characterize this supporting tissue as a very delicate and extremely decomposable, fine reticular substance, with nuclei at the nodal points, so that cell-bodies must be present here (Fig. 188). The fine clefts are permeated by a chaotic maze of the finest nerve fibrillæ; in the larger spaces are ganglion cells.



FIG. 188.—Neuroglia from the gray substance of the human central nervous system (cerebellum), with embedded nuclei.

Proceeding further towards the periphery of the spinal cord, we arrive at the white columnar systems, and here the connective-tissue substratum has become more compact and firmer. Sometimes appearing more homogeneous, sometimes more striated, and again containing nuclei in individual nodal points, it forms a system of septa, an incomplete one it is true, which surrounds the descending nerve fibres as a fenestrated system of sheaths (Fig. 170). Thicker, connective-tissue vascular lamellæ radiate out to the pia mater which, as is known, surrounds the surface of the spinal cord. This envelope finally sends folds with considerable blood-vessels into the anterior and posterior longitudinal clefts of the organ.

The vascular net-works of the white substance, which maintain a radial arrangement, are scanty and large-meshed. The capillary net-work of the gray substance is compact and narrow-meshed; the latter is very vascular.

Let us now consider the nervous contents of the connective-tissue frame-work.

The white cortical substance consists essentially of vertically arranged nerve tubes of 0.0029 up to 0.009 mm. diameter. The thickest fibres are presented by the anterior columns; the finest by the posterior, especially towards the fissura pos

terior. The latter here forms the wedge-shaped or Goll's column. The inner nerve fibres, that is, those which are adjacent to the gray cornua, are also usually finer than their external associates.

These longitudinally arranged fibrous masses are permeated by the bundles of the transversely and obliquely departing and entering roots of the spinal cord.

The anterior or motory roots of the latter reach the anterior cornu (Fig. 187, *i*), and radiate into the latter in every direction in a brush-like form.

Let us now examine this gray substance of the anterior cornu.

Here (*d*) lie groups of large multipolar ganglion cells, after the manner of our Fig. 176. The so-called axis-cylinder process (*a*) is the commencement of the motory nerve fibre, its axis cylinder. This is settled, according to my experience, although it has recently been doubted (Golgi). It is certainly not easy to observe, but it is and remains the best portion of our present knowledge concerning the origin of nervous elements in this so infinitely complicated organ.

If we turn further backwards towards the posterior cornu, we meet with, for the most part, smaller, not rarely spindle-shaped cells (*l*), with the same duplicity of systems of processes. At the base of the posterior cornu, further inwards, there is also a group of smaller rounded ganglion cells. These are the Clarke's columns.

The cellular elements of the posterior cornu have generally been considered as sensory, and brought into relation with the origin of the fibres of the posterior roots; still this cannot be demonstrated.

We now encounter the question: What becomes of the second system of processes (Fig. 176), the so-called protoplasmic processes?

Their lateral finest filaments (*b*), like the terminal radiations of the branch itself, were considered by Deiters, as we already know, to be primitive nerve fibrillæ. From them—and they might arise from different cells—an axis cylinder was said to

be at last composed. Gerlach subsequently came to a different conclusion. According to him, the terminal ramifications of this system of processes unite into a narrow, fine network, from which the nerve fibres arise by the combination of the thinnest filaments. The last-mentioned investigator absolutely denies that the proper cells of the posterior cornu have axis-cylinder processes. A fundamental anatomical difference is, therefore, maintained for the motory and sensory cells. I trust neither the statements of Deiters or Gerlach. With the present accessories we can, unfortunately, obtain no certain result. Everything remains a conjecture. The manner of arrangement of the bundles of the posterior sensory root is, unfortunately, still more complicated than that of the anterior, and the fibres become considerably narrower on their entrance into the gray substance. Our knowledge is, accordingly, here still incomplete.

The greater portion of the bundles of fibres appear to maintain a chaotic course through the posterior columns, to later pass from the side into the convex part, or portion turned inwards, of the posterior cornu (*k*). The substantia gelatinosa Rolandi is here seen to be permeated by the finest nerve fibres. The latter are said to pass in part to the base of the posterior cornu, part of them reaching the Clarke's columns. Furthermore, still other bundles of fibres pass over the latter, more in front. Bundles of sensory fibres may even enter both commissures.

We now come to the question, what do the white longitudinally disposed systems of columns signify?

That they do not represent the bent fibrous masses of the roots of the spinal cord which pass to the brain, as was asserted at an earlier epoch, requires no further discussion after what we have learned concerning these roots.

According to the views of Deiters, these vertical bundles of white fibres come from one transverse plane of the gray substance to subsequently sink into another. The roots of the spinal cord terminated, therefore, in the ganglion cells, and the latter sent off, as a simplified continuation, these ver-

tical fibres of the white columnar system. These cell groups were accordingly a provisory centre.

The further communications of the ganglion bodies, of the equivalent between each other, as well as of the motory with the sensory cells, are up to the present time veiled in the deepest obscurity.

Let us mention, finally, in the uncertainty of our knowledge, the transverse commissures of the spinal cord. The anterior shows true nerve fibres in the most distinct manner. The bundles of the same arise from the gray substance of the one half (without our knowledge of the manner of their origin), to ascend and descend and gain the fibrous mass of the anterior column at the other side. An endeavor has been made to deduce from this a total decussation of the motory tract of our organ.

The posterior commissure also contains, together with connective-tissue constituents, bundles of fine nerve fibres.

W. L. Fuill, M. D.
Veterinarian,
1526 Fair St., Phila.

TWENTY-SECOND LECTURE.

THE CENTRAL ORGANS OF THE NERVOUS SYSTEM, CONTINUED.—THE MEDULLA OBLONGATA AND THE BRAIN.

THE spinal cord, as we learned, cannot be mastered with the present methods of investigation.

It appears still more dubious with regard to the far more complicated medulla oblongata. As with the subsequently to be mentioned brain, it is scarcely possible to here condense the existing, in part contradictory material, into a short summary view. We limit ourselves, therefore, to a fragmentary discussion.

The most recent investigations of this central structure were made by Deiters, of Bonn, and Meynert, of Vienna.

The axis canal of the spinal cord opens in the medulla oblongata, in a dorsal direction, into the sinus rhomboideus or calamus scriptorius, to continue forward as the fourth ventricle. By this means changes of position occur in the white columns, as well as the gray substance of the spinal cord. The anterior longitudinal fissure finally closes as the raphē.

Large portions form anteriorly and inwardly, with their decussations, the pyramids, externally from these the (lower) corpora olivaria. Then follow externally the lateral columns and the corpus restiforme, that is, the wedge-shaped and delicate columns (the latter is a continuation of Goll's column, p. 221).

In the direction of the brain, the pons Varolii rests upon the organ. As a connection with the cerebellum we have the crura cerebelli (with their two portions, the crura cerebelli ad medullam oblongatam and ad pontem). The connection with the cerebrum takes place through the peduncles of the brain. Finally, ten cerebral nerves arise from the medulla oblongata.

The homogeneous connected gray substance here changes,

becoming permeated by bands of nerve fibres. This arrangement, the so-called *formatio reticularis*, gradually extends over nearly the whole medulla oblongata.

Connected masses of gray substance form what has been called "nuclei." A portion of these are the centres of escaping nerves; in others, systems of fibres of the medulla oblongata acquire a provisory termination, to become modified at these places, and subsequently pass further on with their derivatives. Among the latter, the so-called "specific nuclei," are included the superior and inferior olivary bodies, the Deiters' nucleus, the pyramidal nucleus, the ganglia post pyramidalia, the gray substances of the pons Varolii, and in further extension also, the corpus dentatum cerebelli, the gray masses of the crura cerebelli, and the greater portion of the *eminentia quadrigeminæ* (Deiters).

There is besides a transverse, arched and circular system of fibres, Arnold's *stratum zonale*.

In the *formatio reticularis*, as well as in the nuclei, we meet with ganglion cells of the most varied form, and in part of considerable size, with axis cylinder and protoplasmic processes. In consequence of the penetration of the gray substance into the *funiculus gracilis*, the floor of the fourth ventricle is almost exclusively formed of gray substance. The neuroglia which surrounded the axis canal of the spinal cord also undergoes a proliferous increase to subsequently form a considerable share of the walls of the *aqueductus Sylvii*, the third ventricle and the *infundibulum*.

Now, how do the cerebral nerves arise from the medulla oblongata?

Deiters found here not only an anterior and a posterior centre of origin, as in the spinal cord, but also a third lateral one. The latter begins in this organ, at the anterior horn, and gradually acquires a mixed character.

From it arise the *accessorius*, *vagus*, *glosso-pharyngeus*, *facialis*, *acusticus* and *anterior trigeminus* root.

The sensory portion of the *trigeminus* is said to be derived from the posterior system of origin.

To the anterior roots of the spinal cord correspond, together with the hypoglossus, the nerves of the muscles of the eye ; the abducens, trochlearis and oculo-motorius.

We cannot here enter further into the nerve nuclei. The centres of the hypoglossus and accessorius, with large multipolar cells, are located furthest below.

What becomes of the columns of the spinal cord within the medulla oblongata ?

As we have already remarked, there can here be only a simplified continuation of the same.

The anterior columns, passing to the side of the raphē, and displaced by the pyramids, may be followed far under the pons ; they are perforated by zonal fibres and gray substance, and finally, after the intercalation of ganglion cells, are still finely fibrillated. They appear to pass towards the cerebrum and cerebellum.

The lateral columns, forming the funiculus lateralis, reach, in part, the cerebrum. Their fibres are interrupted and displaced by the formatio reticularis, the Deiter's nucleus, the inferior, accessory and superior olivary bodies.

The posterior columns of the spinal cord do not, as we formerly conjectured, continue as the crura cerebelli ad medullam oblongatam directly into the cerebellum. Their processes in the medulla oblongata, the funiculus gracilis and cuneatus, are interrupted by intruded gray substance, the so-called ganglia post pyramidalia, and here cease as white fibrous masses. The gray continuations pass in part into these crura, in part (crossed and uncrossed) to the corpora olivia, and, finally, increased in size, to the pyramids.

The pyramids commence with fine nerve fibres from the formatio reticularis. With them are associated nerve fibres from the lateral and posterior columns. After the decussation they pass in the pedunculi cerebri to the cerebrum, to probably reach the corpora striata, the nucleus lenticularis, and even the cortex of the hemispheres.

The inferior corpora olivaria, in man, contain in their gray

substance a peculiarly folded leaf (*corpus dentatum*) which encloses white substance.

The former substance contains small yellowish pigmented ganglion cells. A system of fibres arising from the olivary bodies is said to pass in part to the cerebellum, in part to the cerebrum.

The *crura cerebelli ad medullam oblongatam* form in part processes of the medulla oblongata into the cerebellum; they probably also send motory fibres from the latter in a downward direction to the medulla oblongata (Meynert).

The *crura cerebelli ad pontem* are of an essentially different nature. They form in the first place a transverse commissure system between both the cerebellar hemispheres; then they conduct fibrous masses, arising from the cerebellum, up to the cerebrum.

The cerebellum can, however, absorb only a portion of the fibrous masses which ascend from below, and subsequently, after the passage of gray substances, sends them off transformed to the cerebrum. It is merely—as we must at present assume—an accessory conducting apparatus; for the other fibrous masses ascend directly through the *pedunculi cerebri*.

The blood-vessels of the medulla oblongata remind us of those of the spinal cord.

We know very little indeed concerning the cerebellum. We have already mentioned two of its *crura*; a third commissure, the *crura cerebelli ad corpora quadrigemina*, connects the organ with the cerebrum.

The cerebellum consists essentially of aggregations of white nerve substance, with fibres 0.0029 to 0.0902 mm. broad. Gray substance occurs in the roof of the fourth ventricle, in the *corpus dentatum*, in Stilling's so-called roof nucleus, and as the external covering layer of the convolutions.

In the folded gray plate of the *corpus dentatum* lie ganglion cells in a threefold stratum. We pass over the entirely uncertain course of the fibres.

The structure of the cortical layer is interesting. It presents an internal rust-brown, and an external gray stratum.

The former, 1 to 0.5 mm. thick, has crowded and stratified granules, that is nucleus like structures or, more properly said, small cells of 0.0067 mm. They remind one of the subsequently to be described elements of the retina of the eye, and, like the latter, give off the finest filaments from both poles (Fig. 189, below).

Whether these granules of the cerebellum are of a nervous or connective-tissue nature is still undecided.

The gray stratum contains a simple layer of large remarkable ganglion cells. Purkinje described them forty years ago.

They send downwards an axis-cylinder process (*d'*), and upwards or outwards a system of antler-like ramified protoplasmic processes (*c*). The finest terminal branches of the latter (Hadlich) are said to bend over (*a*) in a loop-like manner at the surface, and return to the rust-colored layer.

Connective-tissue supporting fibres (*r*) form a special boundary layer at the surface.

The pedunculi cerebri receive ascending masses of fibres from the medulla oblongata and cerebellum; they also receive others which descend from the cerebrum to the medulla oblongata. Their superior rounded portion (cap) is separated from the inferior semilunar (basis) portion by a dark substance.

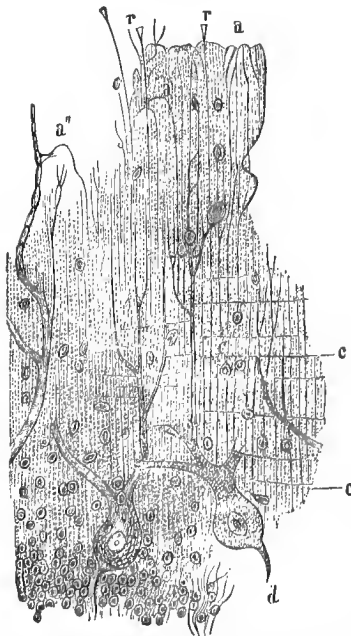


FIG. 189.—The cortex of the human cerebellum in perpendicular section. Two Purkinje's cells, beneath them a portion of the granular layer; *a*, the lower, *c* the upper process of the former. At *r*, supporting fibres; at *a*, the loop-shaped bends of the finest cell processes; *c*, tangential thinnest nerve fibres.

Black pigmented multipolar ganglion cells occur here.

The so-called cerebral ganglia consist of the corpora

quadrigemina, the thalamus opticus, the corpus striatum, and the nucleus dentatus. They are only imperfectly known.

The crura cerebelli ad corpora quadrigemina simply pass off beneath the corpora quadrigemina. They pass to the hemispheres of the cerebrum; they are in truth the crura cerebelli ad cerebrum. The histological acquisitions in this department remain, up to the present time, scarcely worth mentioning. Small cells, larger multipolar, and spindle-shaped ganglion bodies have been met with here.

The thalamus opticus has likewise yielded nothing further in a histological direction. A portion of the optic nerve radiates into it, as well as into the anterior corpora quadrigemina. The cap of the crus cerebri is intimately connected with the thalamus (Meynert).

Fibrous masses of the basal portions of the cerebral peduncles are said to terminate in the corpus striatum and nucleus dentatus. Their finer structure likewise requires more accurate investigation.

The so-called rod corona fibres, in their great development in man, are probably connected with his mental abilities.

They consist in the first place of fibrous masses which, without having been in contact with the cerebral ganglia, are conducted upwards through the peduncle of the brain, and secondly of the radiations of the ganglionic substances.

The trabeculæ and anterior commissure are probably true simple commissures, which have nothing to do with either the crura cerebri or these rod-corona fibres.

The white substance of the hemispheres consists essentially of medullated nerve fibers, measuring 0.0026 to 0.0067 mm.

The gray cortical stratum of the hemispheres may be reduced to a number of single layers. They may be assumed to be six in number.

Smaller cells occur in the more superficial layers. In the fourth layer one meets with considerable many rayed ganglion bodies, measuring 0.025 to 0.040 mm. One of their processes is usually directed towards the surface, and three others inwards. The central one of these three basal pro-

longations is an axis-cylinder process. Then two other cell layers follow. This is all that we know at present.

Here, also, Gerlach assumes the presence of a very fine problematical nerve reticulum, such as we have already mentioned at page 222, in connection with the gray substance of the spinal cord.

At the apex of the occipital portion, in the vicinity of the so-called sulcus hippocampi, the cortical stratum becomes still more complicated. The cornu ammonis also has its peculiarities.

A remarkable, although in man considerably stunted portion, of the cerebral substance is the bulbus olfactorius. The cavity, which is lined with ciliated epithelium, presents parietes consisting of internal white, and external gray substance.

The former contains the root bundles, which are two in number, a thicker external one, coming in part from the anterior inferior cerebral convolution, in part from the corpus callosum, and a thinner internal one, which is thought to be derived from the corpus striatum, the chiasma nervorum opticorum and the pedunculus cerebri.

In a strongly developed neuroglia, we meet, in an inward direction, with the longitudinally arranged medullated root fibers, and then, connected with these, a nerve plexus of very fine tubes. We finally meet with granules and multipolar ganglion cells.

Below, or rather externally, the gray substance becomes strongly altered. One here meets with globular balls of a granular substance with nuclei (glomeruli nervi olfactorii, according to Meynert).

From these lumps are developed the pale nucleated fibres of the special olfactory nerves.

The apophysis cerebri has already been discussed, so far as its anterior portion is concerned, in connection with the blood-vascular glands (page 126); the posterior consists of gray cerebral substance.

The so-called Pineal gland, conarium, has long been remarkable on account of its calcareous concretions. In its connec-

tive-tissue substratum it presents rounded cavities which are sometimes more and sometimes less complete. We here meet with two kinds of cells; large stellate ones, forming a net-work, and smaller ones. In the adult, the latter have processes, in the new-born child, however, they were at one time without these (Bizzozero).

The blood-vessels of the brain, similar to those of the spinal cord, form very compact vascular net-works in the gray substance; in the white substance the meshes are much wider.

The arrangement in the individual portions of the brain is often, however, very characteristic and elegant, as for example in the olfactory lobules, the corpus striatum and the cortex of the cerebellum. We cannot here enter into details.

We have finally to mention the membranes of the cerebro-spinal system.

The dura mater (page 57) of the brain is intimately connected with the periosteum of the cranial cavity. Around the spinal cord, on the contrary, with the exception of the anterior side, it forms a freely suspended tube. The spaces of the vertebral canal are filled by connective tissue with fat cells. The vascularity is very moderate in the cerebral portion, and very slight in the spinal portion. The lymphatics of the dura mater are very abundant. The dura mater of the brain presents nerves of unknown termination.

The dura mater and arachnoid leave a system of cavities, the subdural space (Key and Retzius), between them.

The latter membrane, the arachnoid, is very poor in blood-vessels, is thin, delicate and fenestrated in a reticular manner.

Over the spinal cord it is separated from the lowermost tunic of the pia mater, with the exception of connecting filaments of connective tissue. There is thus formed a considerable subarachnoidal space. Over the brain, on the contrary, the arachnoid and pia mater are for the greater part coalesced with each other, and spaces occur only in those places where the former membrane stretches over the furrows of the surface in a bridge-like manner, while the pia mater descends to the bottom. The considerable subarachnoidal space of the

spinal cord is therefore broken up into numerous smaller spaces.

The connective-tissue bundles of the arachnoid are invested in a sheath-like manner by the familiar flat stellate endothelial cells (Key and Retzius). The latter also fill the connective-tissue spaces, and after treatment with nitrate of silver, show the familiar areolations.

The connected cavities contain a very watery fluid, the cerebro-spinal fluid.

The pia mater likewise appears thin and delicate, with similar flat connective-tissue cells. It is characterized, however, by its immense wealth of blood-vessels; it is, also, by no means poor in lymphatics. Its numerous nerves are probably designed (at least principally) for the vascular walls.

Our pia mater covers, in close apposition, the nervous masses of the central organ. His, it is true, formerly assumed that there was here an epispinal and epicerebral cavity. This does not exist, however; it is an artefact. More recent observations teach that the blood-vessels entering the nervous substance have connective-tissue adventitia, only loosely spread over their so-called tunica media, and that they thus open into the subarachnoidal space with funnel-shaped dilatations of the outer layers. They may be artificially injected from the subarachnoidal space far into the interior of the brain.

The nerve trunks and ganglia have, according to Key and Retzius, the same external dural and internal arachnoidal sheath, as well as subarachnoidal spaces. The injection also succeeds here. All this, like the serous sacs, belongs to the lymphatic apparatus.

The name of the Pacchionian "glands" or granulations has been given to small rounded connective-tissue masses which occur especially at the upper longitudinal venous sinuses of the brain.

According to the two frequently mentioned Swedish investigators, the just mentioned structures form transition

portes of these lymphatic spaces into the venous blood current. This naturally requires further confirmation.

The venous plexus, the plexus choroidei, contains an immense vascular convolution in undeveloped connective tissue. Its covering is formed by a low cubical epithelium, which runs downwards into numerous points.

TWENTY-THIRD LECTURE.

THE ORGANS OF SENSE.—THE SKIN; THE GUSTATORY, OLFACTORY AND AUDITORY APPARATUS.

THE human external integument presents the apparatus of feeling and touch. The tongue alone takes a further share in the function of this sense.

The course of our lectures required that we should discuss the individual portions of the general protecting organ in different places. We mentioned the epidermis at p. 32, the corium at p. 58, the subcutaneous cellular tissue at p. 56, the nails and hair at pp. 36 and 37. The tactile nerves were alluded to at p. 211, the simple sensory cutaneous nerves at p. 212. Additional information may also be obtained from our Fig. 183.

We will also add something here. The corium is thinnest over the eyelids, the prepuce, the glans penis and inner surface of the labia majora; it is thickest over the back, the palm of the hand, the buttocks and sole of the foot, which are the seat of the greatest pressure. The thickness of the epidermis (p. 32) varies still more. We have already mentioned that the color of the skin of Europeans is determined by the latter.

That the corium is uncommonly vascular is known to everybody. In it occurs a highly developed net-work of capillary vessels, 0.0074 to 0.0113 mm. broad, which send loops into by far the greater proportion of the cutaneous papillæ. We meet with more independent portions of the vascular system around the flat lobules of the panniculus adiposus, the hair follicles and the bodies of the sudoriparous glands (Tomsa).

Lymphatics, which are said to possess independent parietes, are abundant in the corium (Teichmann and J. Neumann),

forming a double flat net-work. They penetrate the papillæ as culs-de-sac and loops, so that one is reminded of relative conditions of the intestinal villi (p. 98). Great variations prevail, however, in the individual portions of the skin.

We have, finally, to discuss the glands of the skin, which have thus far been only cursorily mentioned.

The more important ones are the convoluted, sudoriparous glands (Fig. 183, *g*, 190, *a*, *b*). They remain small, with the exception of those of the axilla, where they acquire enormous dimensions and more fatty contents. Their convoluted gland body is more rarely situated in the depths of the corium, but, as a rule, in the subcutaneous cellular tissue. The excretory duct (*e*, *f*), sometimes shorter, sometimes longer, according to the thickness of the part, is slightly spiral, and terminates in the palm of the hand and sole of the foot, by way of ex-

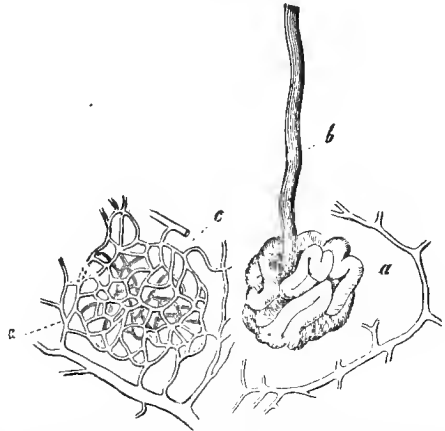


FIG. 190.—A human sudoriparous gland; *a*, the coil, surrounded by the commencement of venous vessels; *b*, the excretory canal; *c*, the basket-like capillary plexus, with the arterial trunk.

ception, with funnel-shaped dilatations. It has a double layer of epithelium. The walls of the convoluted gland body present smooth muscles, which apparently increase with the size of the gland body.

The gland cells form a simple layer of low, cubical elements. An elegant wicker-work of capillary vessels (*c*) surrounds the secretory portion.

The human skin contains these sudoriparous glands, with few exceptions, but they are quite variable as to number and position. The older Krause—he was a thorough observer—

once computed that our body contains nearly two and a half millions of these convoluted glands.

Considerable sudoriparous glands also surround the anus (Gay).

In the external auditory canal, these convoluted glands acquire a shorter excretory duct, which is no longer convoluted, and their secretion is fatty and brownish-yellow. These are the *glandulæ ceruminosæ*.

Let us now investigate the submucous follicles, the *glandulæ sebaceæ* of the older anatomists. Their secretion, an essentially fatty, thickish substance, we have already become familiar with in a preceding lecture (p. 132).

They form racemose organs (Fig. 191), which are sometimes smaller and more simple, sometimes more voluminous and complicated in their structure. They are situated in the corium, and are, for the most part, but by no means unexceptionally, confined to the vicinity of the hair, into the sac of which (p. 37) they excrete the tough, fat substance. We also meet with smaller examples of our organ connected with thick hairs, and larger glands with lanugo hairs. At last these open freely externally, without the intermediation of a hair sac. Their size varies considerably, from 0.2 to 1 mm. and more. The vesicles differ considerably in dimensions and form. Young, striated connective tissue here replaces the so-called *membrana propria*.

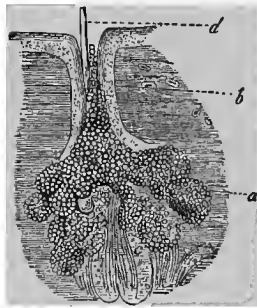


FIG. 191.—A sebaceous follicle; *a*, the gland vesicle; *b*, the excretory duct; *c*, the sac of a lanugo hair; *d*, the shaft of the latter.

Passing now to the gustatory organ, we have again to combine what has been previously mentioned. Even at that time (p. 141) we remarked that the posterior portion of the tongue, upwards in the long known *papillæ circumvallatæ*, and laterally in the subsequently rediscovered *papillæ foliatæ*, contained terminal fibres of the glosso-pharyngeus serving as

nerves of taste. Both systems of papillæ occur in man, though the foliatæ are subject to many individual variations. The change is great in mammalian animals. Cats have no papillæ foliatæ; Guinea-pigs have no circumvallatæ.

We have now to examine the above nerve terminations more closely. They are more recent histological acquisitions (Lovén, Schwalbe, and others). Complicated cup or bud-shaped organs, the so-called gustatory buds, have been met with here. Large

numbers of them occur, as is distinctly represented in our Fig. 192, in the lateral walls of the papillæ themselves, and in the

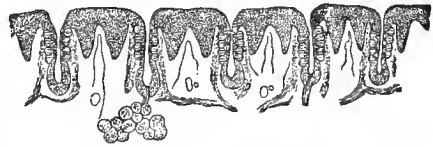


FIG. 192.—Vertical section through the so-called papilla foliata of the rabbit.

inner surface of the surrounding mounds of mucous membrane. The gustatory bud (about 0.08 mm. high in man) is an epithelial structure. It (Fig. 193) permeates the entire thickness of this layer, and its points lie free.

We meet, in the first place, with flattened, lancet-shaped, pointed parietal cells (*a*). They stand like the staves of a barrel. Above, possibly running out into the finest ciliæ, they surround a small opening.

These supporting or cover cells (*2 a*) ensheath an inner cell formation, belonging to the axis portion of the gustatory bud, the rod cell, or, as it has also (hypothetically, it is true) been called, the gustatory cell (*2 b*).

Above, there is a sort of styliform or rod-shaped process

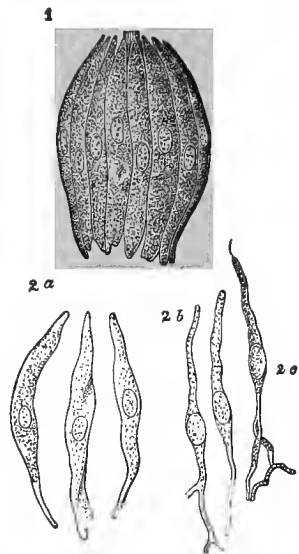


FIG. 193.—1. Gustatory bud of the rabbit; 2 a, cover cells; 2 b, rod cells; 2 c, a rod cell with a fine terminal filament.

(of irregular form, it is true); below, there is a filamentous process. It is conjectured that the latter passes over as an axis cylinder or primitive fibrilla (?) into the gustatory nerve fibres, which run beneath the gustatory bud, and, therefore, that the gustatory cells may be terminal nerve structures. No one has yet seen this, however. We shall first appreciate the consequences subsequently, at the olfactory, auditory, and optic nerves. The circumstance is interesting that so-called mucous glandules (p. 141) occur in both varieties of papillæ (von Exner).

Accurate facts are wanting concerning the nerve terminations in the other papillæ of the tongue.

The human olfactory apparatus consists of a relatively small part, which contains the termination of the specific nerve of sense. This is the soft parts over the upper portion of the septum, the upper and a portion of the middle turbinated bone. The mucous membrane, which is here yellowish or brownish, bears the appropriate name of the regio olfactoria. All the remainder, the lower divisions of both main cavities, as well as the three adjacent cavities, are unimportant accessory parts, as has also been long since taught by comparative anatomy.

The latter division is lined by a very vascular mucous membrane having ciliated cells (the Schneiderian membrane). It contains an immense wealth of serous racemose glands (p. 142). The mucous membrane is thinner in the accessory cavities, and the glands begin to disappear.

We have no intimate knowledge of the terminations of the sensory nerves of the latter parts.

Let us now return to the most essential parts, and examine more closely the structure of the regio olfactoria (Fig. 194).

The region bordering on the Schneiderian mucous membrane, which therefore is unprovided with olfactory fibres, presents the old ciliated covering and the old serous glands. Here, however, it is different. Bowman's gland tubes appear in the mucous membrane, with yellowish cells. A thickened

(as a rule) non-ciliated epithelial mass finally covers the olfactory region.

Let us first examine this epithelium.

We here meet with two different elements. Firstly (*a*), long cylindrical cells (2 *a*). Their body contains yellowish granules and, in connection with the Bowman's glands, causes the mentioned color of our locality. The lank non-ciliated cylinder sends downwards a thin process which becomes divided. By the union of such systems of processes a regular horizontal net-work is formed in the connective tissue of the mucous membrane.

The cells just described have nothing at all to do with the nerve termination. They are a modified, but indifferent epithelium.

Between them, however, there appears a second cell formation, the terminal structure of the olfactory nerve, the olfactory cell (*b*); at least, it is at present thus called, and with probability. Sometimes higher, sometimes more deeply situated, we meet with a spindle-shaped cell body (1, 2, *b*). Below (1, 2, *d*) the latter gives off an exceedingly thin filamentous process. It presents, with certain treatment, small varicosities, like a primitive fibrilla of the nerve fibre (p. 196). At the upper pole, our spindle cell sends off a broader, smooth rod (1, 2, *c*), 0.0018 to 0.0009 mm. wide. Ascending between the epithelial cylinders, it reaches the surface of the parts.

In many animals, the terminal surface of the rod has

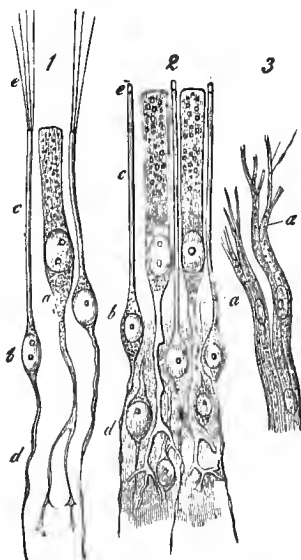


FIG. 194.—1, Cells of the regio olfactoria of the frog; *a*, an epithelial cell, terminating below in a ramified process; *b*, olfactory cells with the descending filament; *d*, the peripheral rod, *c*, and the long vibratile ciliae. *e*; 2, cells from the same region of man. The references the same, only short projections, *e*, occur (as artefacts) on the rods; 3, fibres of the olfactory nerve from the dog; at *a* dividing into fine fibrillae.

single or multiple long ciliæ, as for example in the frog (1, *e*).

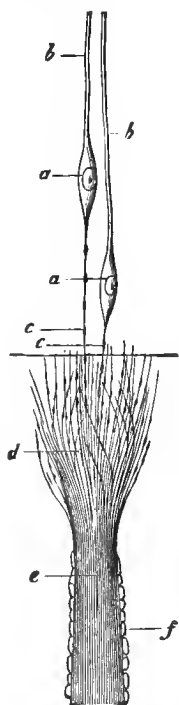


FIG. 195.—Probable termination of the olfactory nerve in the pike; *a*, olfactory cells; *b*, rods; *c*, lower varicose filaments; *e*, axis fibrillæ in the sheath *f*; *d*, spreading out of these; at-wanting connection with the same fibrillæ, *c*.

The olfactory nerve—we are already familiar with its pale primitive fibres (Fig. 194, 3, Fig. 195, *f*) from p. 196—gives off branches as it ascends to the cell layer of the regio olfactoria. The axis cylinder (Fig. 195, *e*) proves to be finely striated. At last, after losing their sheath, the primitive or axis-cylinder fibrillæ radiate upwards in a brush-like manner, as exceedingly thin varicose filaments (*d*). It is assumed that they are connected with the descending, similarly constituted finest processes of the “olfactory cells” (*c*).

This theory proceeded from M. Schultze. The eminent investigator—he has, unfortunately, been prematurely torn from us—could not, however, bring forward a forcible proof here, any more than with regard to the other nerves of sense, after years of arduous honest labor. One cannot avoid certain conclusions, therefore, that by the aid of improved methods, the matter may subsequently become quite different. However, this is my subjective view.

Exner has more recently denied the difference between the epithelial and olfactory cells. In contradistinction to him, Von Brunn has subsequently subscribed to the older view of Schultze. Brunn found over the regio olfactoria a homogeneous boundary layer after the manner of the retina (see below). It has pores for the olfactory cells only.

Let us now pass to the termination of the nervus acusticus, and thus enter the most difficult department of modern histology.

Let us first make a cursory sketch of the unessential accessory parts.

The external ear presents the auricle and the external auditory canal. The former consists of elastic cartilage covered with rarefied corium. Its muscles are transversely striated.

The ceruminous glands of the external auditory canal have been previously mentioned (p. 137).

The drum membrane, or *membrana tympani*, a fibrous diaphragm, is clothed externally by a rarefied cuticular covering, internally by the delicate mucous membrane of the tympanic cavity with simple pavement epithelium. The vascular net-work of this membrane is complicated (Gerlach). Lymphatics and nerves are likewise abundant. The termination of the latter is for the most part unknown.

The entire "middle ear" is lined with a thin, vascular mucous membrane. The vascular net-work shows a considerable development of the venous portion. The *nervus tympanicus* presents ganglia. The auditory ossicles consist of true compact bone substance; their muscles are transversely striated. The Eustachian tubes have stratified ciliated epithelium and true mucous glandules. Their nerves show small ganglia.

The internal ear, as is known, consists of the vestibule, the semi-circular canals and the cochlea. Vesicles filled with watery lymphatic fluid occupy the cavities. The auditory nerve terminates in the ampulla and in the saccules of the vestibule, and then on the spiral plate of the cochlea (*ramus vestibuli* and *ramus cochleæ*).

The vestibule and the inner surfaces of the semicircular canals are lined with periosteum. The fluid contained in their interior is called the perilymph. The periosteum and the tissue of the mucous membrane of the tympanic cavity combined, form the so-called *membrana tympani secundaria*. The parietes of the saccules of the vestibule (*sacculus hemiellipticus* and *rotundus*) and the membranous semicircular canals, together with their ampullæ, present externally undeveloped connective tissue, internally a hyaline nucleated layer

(in the latter, canals with papilla-like incurvations), as well as a flattened epithelium. A second watery fluid, the endolymph, fills this system of cavities.

The otoliths are enclosed within a special saccule, and form columnar-shaped crystals, measuring 0.009 to 0.002 mm.

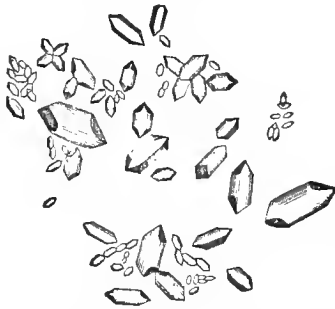

FIG. 196.—Otoliths, consisting of carbonate of lime.

They consist of carbonate of lime, though they are said to have an organic basis.

Let us pass to the expansion of the auditory nerve. The ampullæ and sacculus hemi-ellipticus are supplied by the vestibular branch, the sacculus rotundus, on the contrary, by a branch of the cochlear nerve. It terminates in the duplicatures of the parietes, that is at the entering

angle of the same, the crista acustica.

In fishes (rays), M. Schultze, many years ago, observed simple cylinder epithelium and rod cells intermingled with them, reminding one of the probable terminal structures of the olfactory nerves (p. 239). F. E. Schulze subsequently met with a shock of uncommonly long stiff ciliæ in osseous fishes and tritons. The otolith sacs of fishes also presented a similar condition.

In man the salient points of the vestibular saccules are less developed (maculæ acusticæ of Henle), but are more diffused. Here, also, fine non-medullated nerve fibres penetrate the epithelium. Two kinds of cells and cilia-like processes have also been noticed.

We now come to the cochlea.

This convoluted structure contains two nerveless winding canals, the two so-called scala of the older anatomists, the scala vestibuli and the scala tympani (Fig. 197, *V*, *T*), separated by an internally osseous, and externally soft membranous spiral plate. Reissner has discovered, in addition, a third cen-

tral spiral canal, forming on transverse section an irregular triangle, with its apex directed towards the axis of the cochlea. This is Reissner's cochlear canal, canalis cochlearis (*C*), the

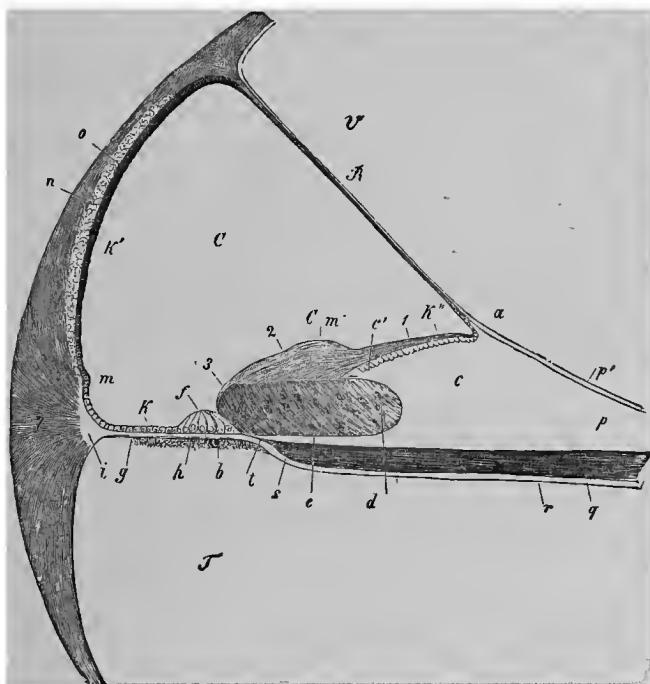


FIG. 197.—Perpendicular transverse section through the canal of the cochlea and neighborhood, in an older embryonic calf; *V*, scala vestibuli; *T*, scala tympani; *C*, canal of the cochlea; *B*, Reissner's membrane with its insertion (*a*) into a projection at the so-called habenula sulcata (*c*); *b*, connective tissue stratum with a vas spirale at the under surface of the membrana basilaris; *c'*, teeth of the first series; *d*, sulcus spiralis, with thickened epithelium, which extends as far as the developing Cortian organ; *f*: *e*, habenula perforata; *Cm*, Corti's membrane (1, inner thinner, 2, middle thicker portion of the same, 3, its outer end); *g*, zona pectinata; *h*, habenula tecta; *h'*, epithelium of the zona pectinata; *k*, of the outer wall of the canal of the cochlea; *k'*, of the habenula sulcata; *l*, ligamentum spirale (*i*, transparent connecting portion of the same with the zona pectinata); *m*, entering projection; *n*, cartilaginous plate; *o*, stria vascularis; *p*, perosteum of the zona ossea; *q*, bundle of the cochlear nerve; *s*, place of termination of the medullated nerve fibres; *r*, place of the axis cylinder in the canalicula of the habenula perforata; *r*, tympanic perosteum of the zona ossea.

proper cochlea of the lower groups of amphibia. Here alone, at the bottom, terminates the nervus cochlearis.

It is impossible for us to describe here the infinitely complicated structure of the fundamental portion of this true cochlea, the more so as, unfortunately, in addition to all the

uncertainty, an extremely complicated nomenclature has also been developed.*

The osseous portion of the spiral plate contains the expansion of the cochlear nerve. At its peripheral exit its bundles of fibres meet the so-called organ of Corti (Fig. 198, *h*).

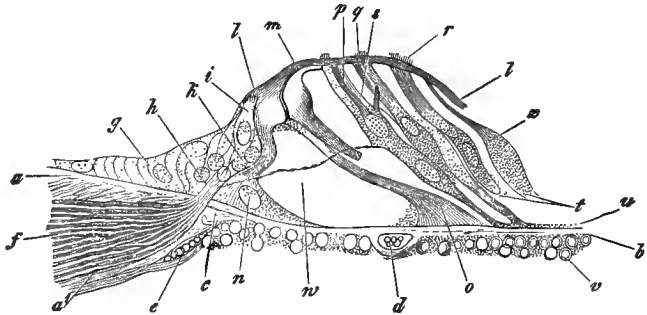


FIG. 198.—The Corti's organ of the dog in perpendicular section: *a, b*, homogeneous stratum of the membrana basilaris; *u*, vesicular stratum; *v*, tympanic stratum with nuclei and protoplasm; *a*, labium tympanicum of the crista spiralis; *a*, continuation of the tympanic periosteum of the lamina spiralis ossea; *c*, thickened commencing portion of the membrana basilaris, together with the place of section, *h*, of the nerve *d*, and *e*, blood-vessels; *f*, the nerve; *g*, epithelium of the sulcus spiralis externus; *i*, inner hair cell with the basal process, *h*, surrounded by nuclei and protoplasm (of the "granule stratum"), into which the nerve fibres radiate; *n*, base or foot of the inner pillar of the Corti's organ; *m*, its "head piece," connected with the same part of the outer pillar, the lower part of which is wanting, while the next following pillar *o*, presents the middle part and the base; *p, q, r*, the three outer hair cells; *z*, a so-called supporting cell of Hensen; *l*, lamina reticularis; *w*, nerve fibre terminating at the first of the outer hair cells.

In a transverse section it forms a conical elevation of the membranous base of the cochlear canal. It is hollow in its interior, and forms collectively, by the cochlear convolutions, a spiral tunnel. Its structure is infinitely complicated.

We here meet with a double row of convergent ascending "pillars" (*n, m, o*) which meet each other at the top of the Cortian organ. There are two of the "external pillars" (*o*) to three of these internal elements (*n, m*). At their base we meet with cell rudiments.

A further diversity is induced by the epithelial cells of the cochlear canals. They become from within outwards (that is from the axis of the cochlea towards its convex external arch)

* The cochlear canal has been the object of extraordinarily extensive labors on the part of Reissner, Claudius, Boettcher, Schultze, Deiters, Hensen, Waldeyer, Gottstein and others.

higher and higher (*g*). To the inner side of the inner pillar of the Cortian organ is applied a long cylinder cell, which is covered at the free upper border with short hairs (*i*). This is the "inner hair cell" of Deiters. The "outer hair cells" (*p*, *q*, *r*), which are also obliquely directed, adhere in three or fourfold rows to the outer pillars of this Cortian tunnel. Further outwards occur spindle-shaped elements, "supporting cells" of Hensen (*s*), and then, gradually becoming flattened, lower cubical epithelial cells.

The supports of the inner and outer pillars lock into each other in a quite peculiar form. From this point is developed an extremely remarkable horizontally extended membrane, the lamina velamentosa of Deiters (*l*, *l*). It is impossible to describe here the marvelous reticular structure.

Where do the primitive fibrillæ of the cochlear nerves end? Freed at last from the confinement of the lamina spiralis ossea, it passes between the inner pillars in the tunnel of the Cortian organ. They are said to have previously become partially lost in the inner hair cells. They now terminate in the outer hair cells (*w*). Notwithstanding the infinite pains and labor bestowed on this subject, it still stands on a weak foundation.

TWENTY-FOURTH LECTURE.

THE ORGANS OF SENSE, CONTINUED.—THE EYE.

We have still to mention the termination of the optic nerve. In doing this we must of course draw into the circle of our discussion the entire eye, that magnificent and wonderful organ which is so important for the physician. Nevertheless, in consequence of its extremely complicated structure, we can only present a cursory incomplete description.

The eyeball (Fig. 199) presents first an external capsular

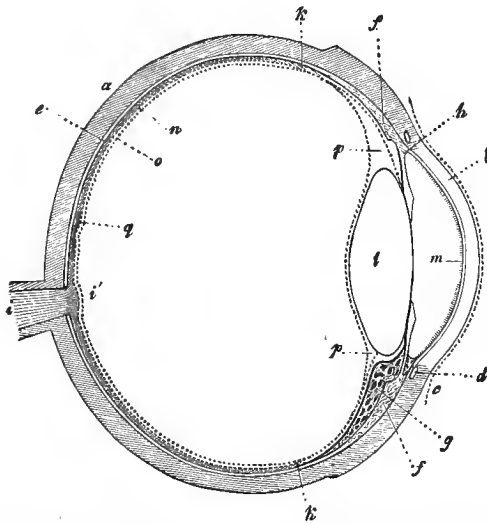


FIG. 199.—Transverse section of the eye; *a*, sclerotica; *b*, cornea; *c*, conjunctiva; *d*, circulus venosus iridis; *e*, choroid, with the pigment layer of the retina; *f*, ciliary muscle; *g*, ciliary process; *h*, iris; *i*, optic nerve; *l*, colliculus opticus; *k*, ora serrata retinae; *l*, crystalline lens; *m*, tunica Descemetii; *n*, membrana limitans interna of the retina; *o*, membrana hyaloidea; *p*, canalis Petii; *q*, macula lutea.

system; the posterior, opaque, greater portion is formed by the sclerotic (*a*), while the anterior, smaller, transparent seg-

ment (*b*) is constituted by the cornea. These membranes enclose a black stratum, the so-called uvea. It consists of the choroid (*e*) with the ciliary processes (*g*) and, applied externally to the latter, the ciliary muscle (*f*) and, finally, a more anterior ring-shaped disk, the iris (*l*).

The contents of the hollow ball are formed by the various light-refracting media. Even the cornea (*b*) participates in this action. Next to it comes the so-called humor aqueus, that is, the watery contents of the anterior and posterior chambers of the eye (in front of *l*). Then follows a firmer structure, the most important refracting body, the crystalline lens (*l*). The completion is formed by a large globular mass, having a concave impression in front, the vitreous body or humor vitreus (behind *l*).

The greater portion of the latter is covered by the cup-shaped expansion of the optic nerve, the retina (*i*). It terminates anteriorly, according to the usual impression, in the region of the origin of the ciliary processes, with an undulated border, the so-called ora serrata (*k*).

A very complicated system of vessels, springing almost exclusively from the arteria ophthalmica, supplies our organ with blood. Lymphatics are, naturally, also not wanting.

The cornea, with its two homogeneous boundary layers, was mentioned at p. 56; the stratified pavement epithelium of the anterior surface at p. 31; the simple cell layer of the posterior at p. 29; the nerves at p. 207.

We mentioned at that time the system of passages of the cornea, and ascribed to them a sort of parietes. Differences of opinion prevail concerning this, however. The passages of this system of juice clefts (Fig. 200) may be artificially filled by the puncturing method, in successful cases, with the preservation of their old shapes, in numerous others, however, distorted, with the appearance of wide misshapen canals. They have been not badly termed "rupture spaces." The circumstance is interesting that a successful injection of the juice-spaces finally leads to the lymphatics of the conjunctiva.

The cellular contents of the canal-work has caused endless

controversies; not the lymph corpuscles wandering through them, but rather the "fixed" corneal cells (Fig. 200, to the left and below). They are stellate and water-wheel-like cells, the nucleus of which is always invested by some protoplasm, while the peripheral portions are metamorphosed into homo-

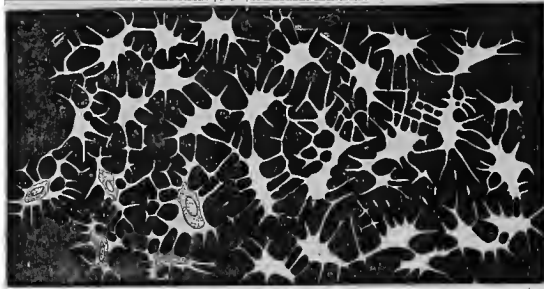

FIG. 200.—The human cornea impregnated with silver. The corneal corpuscles, that is, the system of juice-spaces, colorless. To the left, below, four metamorphosed parenchyma cells.

geneous veil-like plates. The cells probably have a limited contractility. Their processes do not, according to our views, form any connected net-work. Hence, a portion of the juice-canals remain filled with fluid. All this is disputed by others, however. No one should here leave the decision with confidence to one reagent, such as gold, for instance.

The sclerotica (p. 57) is a firm connective-tissue membrane, and consists of bundles arranged meridionally, with others crossing them in an equatorial direction. In front they pass continuously over into the modified hyaline connective tissue of the cornea. It also contains regular passages with lymph corpuscles and in part colorless, in part pigmented connective-tissue cells (Waldeyer). It appears to have nerves only at the corneal border.

At the margin of both membranes, although belonging to the inner surface of the sclerotica, we meet with a complicated ring-shaped reservoir. This is the sinus Schlemmii (Fig. 199, *d*). It has been declared to be a venous reservoir

(Leber). Others regard it as a lymphatic passage (Schwalbe, Waldeyer).

Posteriorly, the sclerotica passes over into the external sheath of the optic nerve, derived from the dura mater. This membrane is finally strengthened by the insertions of the tendinous bundles of the ocular muscles.

The system of the uvea, with the exception of its most anterior portion, the iris, is characterized by very considerably developed vessels.

The entire inner surface (and the posterior surface of the iris) is covered by the pigmented outer epithelium of the retina (p. 30). During a portion of the fœtal period, the latter extended much further forwards than it does at a more mature period.

The greater portion of the uvea is formed by the posterior segment, the choroid. The thin membrane consists of several, not sharply demarcated, connective-tissue layers.

We recognize a, an inner hyaline boundary layer, 0.0006 to 0.0008 mm. in thickness, thicker and more uneven in front; b, a thin homogeneous layer, with extraordinarily developed stellate capillary net-works (choroidea capillaris); c, the choroid proper of the histologists, with stellate, very generally pigmented connective-tissue cells, and a great wealth of arterial, as well as venous vessels; and, finally, d, a loose pigmented connective tissue, which forms the connection with the inner surface of the sclerotica. It is called the lamina fusca, and also the supra-choroidea; it forms a lymphatic space.

The vascular net-work in the ciliary body, and in the ciliary processes which project inwards from the latter, is greatly developed. The substratum remains similar to that of the choroid, though the pigmented connective-tissue cells disappear.

Externally to these processes we meet with a peculiar smooth muscular mass, the tensor choroideæ, musculus ciliaris, or ligamentum ciliare of an older epoch (Fig. 199, *f*).

The human ciliary muscle arises from the inner side of the

boundary region of the cornea and sclerótica. Meridional bundles of the former radiate in a posterior direction into the ciliary body. Below and inwards occur interwoven filaments, and still further inwards, circular bundles (Mueller's ring muscle).

We meet with colorless connective-tissue cells in the connective-tissue substratum of the iris of light eyes, and pigmented cells in that of dark ones. Besides these, smooth muscular elements occur. Annular bundles (Fig. 201, *a*)




FIG. 201.—Surface of the human iris; *a*, the sphincter; *b*, the dilator of the pupil.

form the constrictor or sphincter of the pupil. From it proceeds the dilator pupillæ, an object of controversy of later years.

Muscular bundles, which are at first separated, form more peripherically a connected radial layer of fibres (*b*). At the ciliary, that is the outer border, we finally meet with an annular muscular layer.

This external or ciliary border of the iris gives rise at its anterior surface to another peculiar tissue, the ligamentum pectinatum iridis (Huek).

We have already learned (p. 56) that the posterior surface of the cornea is covered by a hyaline membrane, the membrana Descemetica or Demoursii. At its periphery, this posterior covering layer passes over into a peculiar reticular tissue (probably, in man, most intimately connected with the elastic tissue), which passes through the outer margin of the

anterior chamber of the eye. This is the ligamentum pectinatum, which has just been mentioned. Its trabeculæ are covered with epithelial cells. The anterior surface of the iris also has such a layer. An incompletely closed, ring-shaped canal, which is bounded by the trabeculæ of this ligamentum, has been called the canalis Fontanæ.

Small ganglia of the ciliary nerves occur in the choroid. The ciliary muscle and the iris are more plentifully supplied with nerve fibres, but their manner of termination we do not yet know.

Concerning the crystalline lens and the vitreous body in general, we refer to pages 78 and 45. There is one circumstance which requires more special mention here. According to a widely disseminated acceptance, the hyaloid membrane (Fig. 199 in the vicinity of *k*), separates into two leaves, a posterior and an anterior, the so-called zonula Zinnii, which is impressed in a ruffle-like manner by the ciliary processes. Both continue on to the crystalline lens at its equatorial zone. The zonula Zinnii presents a peculiar pale and resistant system of fibres. A three-cornered annular sinus, bounded by both lamellæ, bears the name of the canalis Petiti. Much is still obscure here, and the space is, after all, only an artefact (Merkel, Mihalcovics).

Let us now turn to the expansion of the optic nerve into the retina. Our membrane has its greatest thickness (0.38 to 0.23 mm.) at the place of the entrance of the optic nerve. It becomes thinner (to about the half) towards the periphery. Passing beyond the equator (thinned to 0.09 mm.) it terminates as the so-called ora serrata (Fig. 199, *k*). Externally from the place of entrance of the optic nerve (*i'*), about 3 to 4 mm. removed from it, is the macula lutea, the seat of the most distinct vision (*g*). In its centre there is an excavation, the so-called fovea centralis.

The retina, provided with numerous other elements, appears to be an extraordinarily complicated structure, and, at the same time, of extreme delicacy and variability. It has been the object of infinite research in older and more recent times ;

but, notwithstanding the labors of H. Mueller and M. Schultze, we are still exceedingly distant from a conclusion, as Schwalbe's most recent studies show.

The retina (Fig. 202) is invested externally by the simple pigmented epithelial layer already familiar to us (p. 30).




FIG. 202.—The human retina in vertical section; 1, layer of the rods and cones, demarcated below by the membrana limitans externa; 2, the external granular layer; 3, intergranular layer; 4, internal granular layer; 5, fine granular layer; 6, layer of ganglion cells; 7, expansion of the optic nerve fibres; 8, Mueller's supporting fibres; 9, their transformation into the inner limiting membrane; 10, the membrana limitans interna.

Then (1) we have the stratum of rods and cones; thereupon follows the so-called external limiting membrane, the membrana limitans externa (the transverse line between 1 and 2). Next comes the external granular layer (2), then the intergranular layer (3). Thereupon follows the inner granular layer (4), then the molecular stratum (5). Further inwards we meet with the stratum of the ganglion cells (6), thereupon the radial expansion of the optic nerve fibres (7). The termination is formed by the internal limiting membrane, the membrana limitans interna (10). The layer of rods and cones, as well as the external granular layer, is called by Schwalbe the neuro-epithelial stratum, all the rest the cerebral stratum.

In the structure of this thin and wonderfully complicated membrane we must, however, distinguish two different elements, connective tissue and nervous.

Let us first take the former into account (Fig. 203, A), and commence at the inner surface.

The membrana limitans interna (1), an apparently hyaline, 0.0011 mm. thick layer, deserves mention as the first connective-tissue boundary layer. In an inward direction (towards the vitreous body), smoothly demarcated, it passes over

externally (towards the choroid), commencing with a triangular expansion, and then diminishing into a connective-tissue radial fibre system (*e*), which is wanting only in the macula lutea.

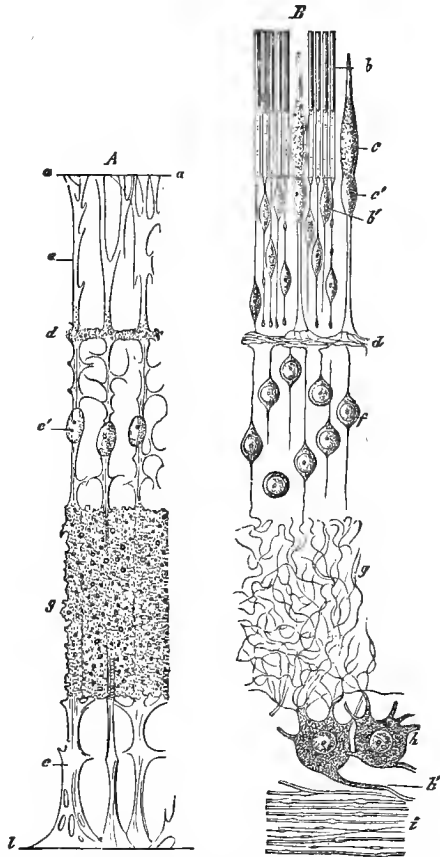


FIG. 203.—Diagrammatic representation of the retina : *A*, connective-tissue frame-work ; *a*, membrana limitans externa ; *e*, radial or Muellerian supporting fibres with their nuclei, *e'* ; *d*, frame-work substance of the intergranular, and *g*, of the molecular layer ; *z*, membrana limitans interna ; *B*, nervous elements ; *b*, rods with outer and inner members ; *c*, cones with outer member and body ; *b'*, rod, and *c'*, cone granule ; *d*, expansion of the cone fibre into the finest fibrillæ in the intergranular layer ; *f*, granules of the inner granular layer ; *g*, confused mass of finest fibres in the molecular layer ; *h*, ganglion cells ; *h'*, their axis-cylinder processes ; *i*, layer of nerve fibres.

These are the Mueller's supporting fibres (*e*). They increase more and more towards the anterior terminal portion.

Lateral branches of the latter lead to manifold communications. In the molecular (*g*) and the intergranular layer (*d*) there is thus formed a very fine reticular frame-work, such as we are already familiar with in the gray substance of the cerebro-spinal system (p. 220).

Nuclei or cell equivalents occur occasionally in the system of supporting fibres, as in the external granular layer (*e'*).

The supporting substance certainly extends as far as the base of the rod and cone layer (*a*). There is scarcely any doubt, however, that it extends still further as a delicate, homogeneous connecting substance. At the former locality it forms, as the *membrana limitans externa*, a fenestrated boundary layer, further outwards a connecting medium of the rods and cones.

Having thus become familiar with the connective-tissue substratum—it should by no means be genetically confounded with the ordinary connective tissue—let us pass to the nervous elements of the retina (*B*). Let us here select the reversed course, and commence with the outer layer.

This stratum is formed by the rods and cones. The whole layer is called the rod-layer, *stratum bacillosum*. They are terminal nerve cells, similar to those which we previously met with at the higher nerves of sense. Those of the retina, however, possess many peculiarities, and we have a more accurate knowledge of them than of their relatives. The circumstance is also interesting that the rods and cones vary according to animal groups. Their dimensions are proportionate to that of the red blood cells.

The rods, bacilli (*B, b*), are slender cylindrical structures. They consist (Mueller, Braun, Krause) regularly of two parts, an apparently homogeneous narrower so-called "outer member," which refracts the light more strongly, and a shorter "inner member." The latter appears paler, somewhat granular, and of considerable diameter. In the lower vertebrate animals the retinal pigment forms regular sheaths around the outer member of the rods and cones. In mammals and man the pigment sheath is less developed.

The rods acquire their greatest length, 0.06 mm. and more, at the bottom of the retina. Further forwards they become shorter, towards the ora serrata they are only 0.0399 mm. high. Their diameter may be estimated at 0.0016 to 0.0018 mm.

Downwards or inwards, beneath the membrana limitans externa, the rod becomes pointed, and runs out into an extraordinarily fine filament, a primitive nerve fibrilla (Fig. 203, *B*, Fig. 204, 1, 4, Fig. 205, 1, 3). The latter passes through the outer granular layer vertically (and also radially). A small cell, the so-called "rod granule" (Fig. 203, *B*, *b*¹, Fig. 204, 1, 2, 3, Fig. 205, 3) is embedded in its course, sometimes higher up, sometimes further downwards. This granule forms the single element of the outer granular layer.

Still more complicated textural conditions have been observed in the rods (Fig. 204). At the border of the inner member towards the outer member, embedded in the former, a plano-convex body has been found with its plane base directed upwards (1, *a*, 2). This is the so-called "rod-ellipsoid" of Krause.

Furthermore, as has been long known, the outer member breaks up into transverse plates (3). These discs may have a thickness of 0.0003 to 0.0004 mm. in man (Schultze).

The outer member shows a longitudinal striation, caused by longitudinal, channel-like depressions, with longitudinal elevations springing up between them, like a fluted column (Fig. 204, 1, 2, and Fig. 205, 1 *a*). Longitudinal striations have also been subsequently discovered on the inner members (Fig. 205, 1, and 3 *b*). In the axis of the rod a very fine filament, a primitive nerve fibrilla, is also said to have been noticed (Ritter).

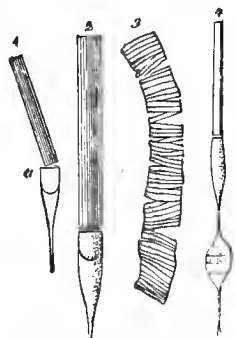


FIG. 204.—Final structure of the rods; 1, from the chicken with the outer and inner member, as well as the cone-ellipsoid; 2, from the frog; 3, the outer member of the rod of a frog dividing into transverse discs; 4, rod with granule from the Guinea-pig.

Our present knowledge concerning the cones (Fig. 203, *B*, *c*, Fig. 205 2), is uncertain.

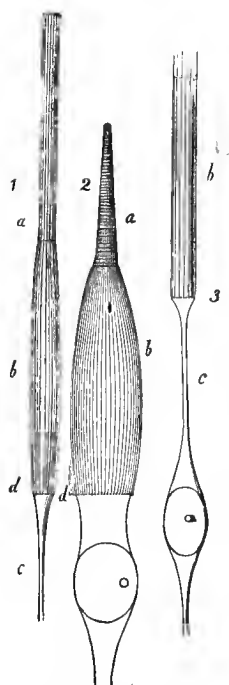


FIG. 205.—Fibrillated covering of the rods and cones; 1, rods; 2, cones of man; *a*, outer; *b*, inner member; *c*, rod-filament; *d*, limitans externa; 3, rod of the sheep. The fibrillæ project beyond the inner member; the outer member is wanting.

In man, they have the form of a slender bottle. Their base rests on the *membrana limitans externa*. Upwards, the cone passes into a shorter, conical, infinitely changeable structure, the so-called cone rod (Fig. 203, *B*, above *c*, Fig. 205, 2 *a*). It is the equivalent of the external member of the rod, characterized by its great tendency to break up into transverse discs. The inner member, or the cone body (Fig. 205, 2 *b*), also shows the longitudinal striation, similar to the equivalent portion of the rod.

At the base of the rod, immediately beneath the *limitans externa*, we meet

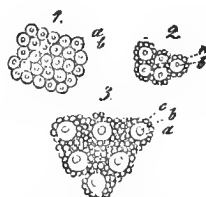


FIG. 206.—The rod layer seen from without; *a*, cones; *b*, cone rods; *c*, ordinary rods; 1, from the macula lutea; 2, at the margin of the same; 3, from the centre of the retina.

with a cell-like body, the so-called cone granule (Fig. 203, *B*, *c'*, Fig. 205, 2, below *d*).

A broad cone filament (up to 0.0029 mm. in thickness) finally runs downward, passing through

the outer granular layer (Fig. 203, below *c'*). It is a fasciculus of primitive fibrillæ.

Interesting local variations (Fig. 206) in regard to the number of cones and rods occur in the human eye.

In the macula lutea, the seat of the most distinct vision, we meet with cones alone, which have become extremely fine (1). In the vicinity the latter are still quite crowded, and are

surrounded by a single circle of rods (2). The further outwards we proceed, the further we find the cones removed from each other, and the greater the number of rods situated between them (3).

Apes, and the most of our domestic animals, present an analogous condition. Nocturnal animals, such as the cat, have only stunted cones; bats, hedgehogs, moles, are entirely deprived of the latter elements. Birds, on the contrary, generally have an abundance of cones. In the chameleon and lizard there are no rods at all; we find only cones, as in the human macula lutea. The rod appears to be the terminal apparatus, serving for the objective colorless vision, as the cone does for the color perception of the outer world (Schultze).

The *membrana limitans externa*, the sieve-like fenestrated boundary structure, we are already familiar with. The rod apices pass downwards through small spaces, the cone granules through larger ones. Finally, this membrane sends outwards the already mentioned delicate homogeneous connecting substance between the rods and cones.

The external granular layer, *stratum granulosum externum*, is already familiar to us so far as its connective-tissue framework is concerned. It (Fig. 203, *B*) consists of layers of small cells stratified over each other, a minimal body closely surrounding the nucleus. We distinguish here the larger higher cone granules (*c'*), measuring 0.009 to 0.012 mm., and the smaller rod granules, measuring 0.0045 to 0.0079 mm., situated more deeply. The latter alone present a peculiar, perhaps normal transverse striation (Fig. 204, 4).

Thus far the connection of the retinal elements is clear. Now, however, on coming to the so-called intergranular layer, the *stratum intergranulosum*, this clearness is lost. There exists here a grievous defect of knowledge.

Schultze, the excellent investigator whom we have thus far followed, asserted that the finest rod-fibrillæ, having arrived at the intergranular stratum, formed very fine terminal knobs (Fig. 203, *B*, above *d*). This is decidedly not the case. The

filament simply bends into another plane, suddenly and at a considerable angle. I have convinced myself of this with certainty.

The broad cone fibres divide at the same place into three very fine processes (above *d*).

In the most delicate connective-tissue frame-work of the intergranular layer we meet with a confused mass of fine horizontally and obliquely disposed filaments (*d*), the continuations of the rod and cone fibrillæ.

The inner granular layer—the stratum granulosum internum—contains, in the first place, as we already know (*A, e'*), connective-tissue nuclei or cellules of oval shape. Together with these appear layers of sharply demarcated, globular, nucleated cells (*B, f*), into the upper pole of which sinks a rather fine nervous filament, to again pass out at the lower pole, very much finer, and continuing further in a perpendicular direction. These nervous granules do not show any transverse striation.

The molecular or fine granular layer, stratum moleculare (*B, g*), repeats, although with greater thickness, the fine connective-tissue spongy structure of the stratum intergranulosum. We again discover in it a confused mass of primitive fibrillæ. Ascending fibres from the more deeply situated cells of the intergranular layer, having entered this confused mass, may be observed here and there; following their course is not to be thought of. We have here, therefore, a new defect in our knowledge of the retina.

We now arrive at the layer of the ganglion bodies, the stratum celluloseum (*B, h*). These occur stratified (in 10 to 6 layers) at the bottom of the retina, to gradually appear towards the periphery as a single layer, and with an increasing distance from each other. With the exception of the macula lutea, where the ganglion bodies are bipolar, they form fine multipolar cells of not inconsiderable size (up to 0.0377 mm.). Their protoplasmic processes turn outwards, and finally disappear with their terminal branches in the maze of fibres of the molecular stratum; their axis-cylinder process is directed in-

wards (*h'*). It passes over into a nerve fibre of the optic nerve-fibre layer, the stratum fibrillosum (*i*).

In order to comprehend the latter we must commence with the contents of the optic nerve. It has medullated nerve fibres, 0.0045 to 1.0014 mm. thick. Having entered the ball of the eye, their medullary sheath is lost, and they become pale axis cylinders.*

Having advanced into the retina, our optic nerve fibres divide and reunite at acute angles into bundles, forming a nerve plexus. In proportion as we follow their further course forwards, the fibre bundles become thinner and thinner, and the distance between them is constantly increased. At last we meet with only isolated axis cylinders.

We have grounds for assuming that each optic-nerve fibre penetrates the body of a ganglion cell as an axis-cylinder process; still we cannot prove this at the present time.

The membrana limitans interna, of a connective-tissue nature, has been previously mentioned.

The best portion of the retina, the yellow spot or macula lutea, requires a short mention.

The connective-tissue frame-work substance, with the exception of the limitans interna, is undeveloped. The nerve-fibre layer likewise disappears; the layer of the ganglion cells, still largely developed at the periphery, also disappears completely in the centre of the fovea. The molecular and inner granular layers also suffer the same fate. There remains, therefore, only the (exclusively occurring) cones with the stratum granulosum externum.

The latter (Fig. 207) are no longer as of old. Their body has at last become narrowed to 0.0028 to 0.0033 mm. (Schultze); it has diminished to nearly the thinness of the rod, and the cone rod to 0.001 to 0.0009 mm. The cone fibre appears to have participated but little in this thinning. The

* It is remarkable that in individual human retinas the medullary sheath of the nerve tubes is preserved. In the dog the same not unfrequently occurs; in rabbits and hares it is even the rule.

cone granule lies sometimes higher, sometimes deeper (*a*); we might say from necessity.

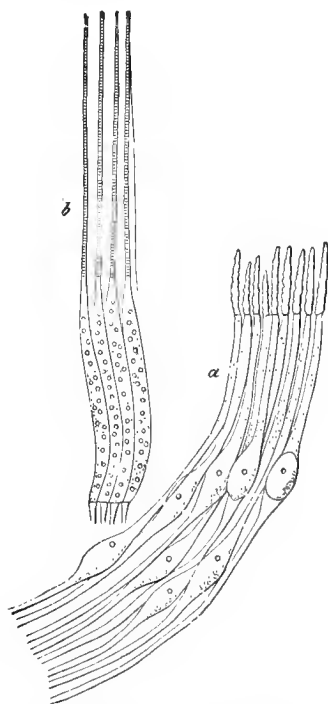


FIG. 207.—Cones from the macula lutea and fovea centralis of man; *a*, with decomposed outer membrane; *b*, with the lamellar decomposition of the same.

We meet with still another condition. In the peripheral layers of the retina the cone fibre passes through our membrane in an ascending perpendicular direction. The latter now leaves this direction more and more, to pass obliquely outwards and downwards (*a*). This induces beneath the outer granular layer (that is the cone granules), a quite peculiar appearance.

Forwards, towards the ora serrata, the retina increases in thinness, and the nervous elements diminish; the connective tissue frame-work acquires the upper hand more and more; finally all the nervous elements have disappeared.

By the ciliary portion of the retina is designated a system of cylindrical cells which lie on the zonula Zinnii beyond the ora serrata, and run as far as the iris, according to many even to the pupillary border of the latter.

The blood-vessels of the retina, springing from the arteria centralis, form an elegant wide-meshed reticulum of very fine tubes. They occupy the inner portion of the retina, but pass outwards to the inner granular layer, and perhaps still further. The adventitia of the same surrounds the inner layer but loosely, leaving a lymphatic space.

It is impossible for us to enter into the exceedingly com-

plicated arrangement of the blood vessels of the eyeball. We must leave this to more special works.

We would add, however, a few words concerning the lymphatics of the eyeball (Fig. 208), basing them on Schwalbe's admirable work.

We may assume with this investigator an anterior and a posterior system of lymphatics.

The former, arising from the iris and ciliary processes, has its central reservoir in the anterior chamber of the eye. To this division belong also the lymphatics of the cornea and conjunctiva.

All that lies behind the ciliary processes forms the posterior lymphatic system. The sclerotic and the choroid are perhaps without definite lymphatic canals.

The cup-like space between both membranes, with which we are already familiar as the lamina fusca, has, on the contrary, the signification of a lymph reservoir. This is Schwalbe's perichoroideal space (p). From it (at the elevation of $m r$ of our figure) occurs the transition of the lymphatic fluid into the so-called Tenon's space (t), that is the interval between the outer surface of the sclera and the Tenon's capsule of the eyeball. The connecting lymph canals surround the vasa vorticiosa of the choroid in a sheath-like manner. Posteriorly the Tenon's reservoir continues into the supravaginal space ($s p v$), a cylindrical sheath membrane of the optic nerve.

Key and Retzius, the two able investigators mentioned in

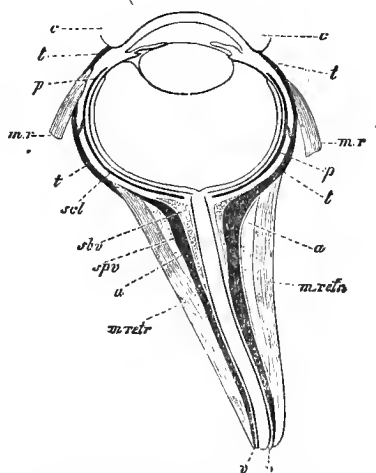


FIG. 208.—The posterior lymphatics of the hog's eye; c , conjunctiva; $m r$, the recti muscles; $m retr.$, retractor bulbi; a , layer of fat; v , the outer sheath of the optic nerve; t , the "Tenon's" space, passing backwards into the "supravaginal," $s p v$; $s b v$, "subvaginal" space between the inner and outer sheath of the optic nerve; p , "perichoroideal" space connected with the Tenon's space by oblique passages.

connection with the lymphatics of the nervous central organs, injected from the subdural space of the brain (p. 231) an intermediate space located between the external and internal sheath of the optic nerve, the subvaginal space of Schwalbe (*s b v*), and from this they drove the injection mass into the perichoroideal space of Schwalbe. Schwalbe does not, however, accept the latter communication.

Injection masses may be forced beneath the inner sheath of the optic nerve, between the bundles of optic-nerve fibres, and this may be done from the subarachnoidal space of the brain (p. 231).

The lymphatics of the retina invest its capillaries and veins, therefore, in a sheath-like manner.

We return to the chambers of the eye, the central reservoir of the lymph of the anterior portion of the globe. What is the relation of its affluent passages?

In the first place a cleft system leads from the canal of Petit into the posterior, and thus into the anterior chamber of the eye. Wider and more important introductory passages open from the Fontana's space in the ligamentum pectinatum iridis, probably for the lymph of the iris and ciliary processes.

Injection masses pass from the periphery of the membrane of Descemet into the canal of Schlemm (p. 248).

Can a communication between the lymphatic and venous passages actually exist here, similar to that which Key and Retzius admitted, by the aid of the Pacchionian granulations for the membranes of the brain (p. 232)? Leber, an observer who has rendered great service to the anatomy of the eye, has, it is true, disputed this, and he may be right.

We have still to mention, briefly, the external, less important appendices of the eyeball.

The eyelids contain, embedded in the firm connective tissue of the tarsal cartilage, the so-called Meibomian glands, short sinuous tubes with fatty parenchyma cells, but without a membrana propria or muscular tissue in the excretory duct. Its secretion is the sebum palpebrale.

The conjunctiva presents a complete mucous membrane over the posterior surface of the eyelids and the anterior surface of the sclera ; only the stratified pavement epithelium remains over the cornea, the mucous membrane having become metamorphosed into corneal tissue.

The conjunctival glands are of manifold species. In man and in certain mammals we meet with small mucous glandules, though the cells contain fat granules. Convolted glands (Fig. 119) occur at the periphery of the cornea in ruminating animals (Meissner). Simple culs-de-sac have been recognized in the hog, externally to the corneal periphery, towards the outer canthus of the eye (Manz). In the tarsal border of the human eye we meet with modified sudoriparous glands (Waldeyer).

Concerning the trachoma glands, we have already communicated all that was necessary (p. 113). In man there are probably no true lymphoid follicles (Waldeyer). The terminal bulbs of the conjunctiva have been mentioned at p. 209.

The tear-gland, *glandula lacrymalis*, consists of an aggregation of single racemose glands. We are not yet familiar with the nerve terminations here. The efferent apparatus presents differences of structure in its different portions. We leave the description of them, like that of so many other things, to more comprehensive text-books.

INDEX.

- ACINUS** of the glands, 130.
Adventitia of the capillaries, see **Vessels**.
Air cells, see **Lungs**.
Alveoli of the lungs, 158.
Amœboid changes of form of the cells, 9.
Anthraxis of the lungs, 160; of the bronchial glands, 160.
Aquila Cotunnii (perilymph) of the auditory organs, see **Auditory apparatus**.
Aquila vitrea auditiva (endolymph), see **Auditory apparatus**.
Arachnoid, see **Nerve centres**.
Arrectores pilorum, 81.
Arteriæ helicinæ, 191.
Arteries, 94.
Arteriolæ rectæ of the kidney, 170.
Articular cartilage, 44.
Assimilation by the cell, 11.
Auditory organ, 240; external ear, 241; membrana tympani, 241; auditory ossicles, 241; Eustachian tube, 241; internal ear, 241; vestibule and semi-circular canals, 241; otoliths, 242; cochlea, 242; its structure, 242; Reissner's, or the cochlear canal, Corti's organ, termination of the cochlear nerves, etc., 243.
Auditory ossicles, see **Auditory organ**.
Auerbach's plexus myentericus, 218.
Axis canal of the spinal cord, 224.
Axis cylinder, 193.
Axis-cylinder process of the ganglion cells, 200.
Axis fibrillæ of the nerves, 196.

Bacilli of the retina, see the **Eye**.
Bartholinian glands, 181.
Bathybius, 1.
Becher cells, 5.
Bellini's tubes, see **Kidney**.
Biliary capillaries, see **Liver**.
Biliary passages, see **Liver**.
Bladder, see **Urinary apparatus**.
Blood, 21; cells and plasma, 21; red blood corpuscles and lymphoid cells, 21; nature of the former, 22; differences of the same according to the groups of vertebrate animals, 23; lymphoid cells of the blood, 23; relative number, 24; circulation of the blood, 24; fate of the lymphoid cells; 25; genesis of the blood in the embryo, 26.
Blood-vascular glands, 123; thyroid gland, 123; structure, 123; colloid formation, 124; suprarenal capsules, 124; cortical and medullary layer, 124; structure, 125; vessels and nerves, 126; apophysis cerebri, 126; coccygeal gland, 126; ganglion intercaroticum, 127.
Blood-vessels, see **Vascular system**.
Bone tissue, 60; kinds of bone, 60; medullary or Haversian canal, 60; Haversian and general lamellæ, 61; canaliculi, 61; bone corpuscles or lacunæ, 62; bone cells, 62; composition of bone, 63; bone cartilage, 64; bone medulla, 64; osteogenesis, 64; cartilage marrow, 65; ossification points, 65; formation of bone at the expense of the cartilage tissue, 65; osteoblasts, 68; endochondral bones, 69; theory of apposition and expansion, 69; Haversian spaces, 70; osteoclasts, 70; periosteal bone formation, 70; Sharpey's fibres, 71.
Bowman's glands of the olfactory region, see **Olfactory organ**.
Brain, cerebrum and cerebellum, see **Nerve centres**.
Bronchia, see **Lungs**.
Bruch's trachoma follicles, 113, 263.
Brunner's glands, 147.
Buccal glandules, see **Digestive apparatus**.
Bulbus olfactorious, see **Olfactory apparatus**.

Canaliculi, see **Bone tissue**.
Canalis cochlearis, see **Auditory apparatus**.

- Canalis Fontanæ, see Eye.
 Canalis Pettii, see Eye.
 Canalis Schlemmii, see Eye.
 Canalis semi-circular of the ear, see Auditory apparatus.
 Capillaries, see Vessels.
 Carotid gland, 126.
 Cartilage, 42; hyaline, elastic (reticular) and connective-tissue cartilage, 42; cartilage cavities and cartilage cells, 43; cartilage capsules, 43; intercellular substance, 43; metamorphosis of fibres and calcification, 44; occurrence of hyaline cartilage, 44; reticular cartilage, 45; connective tissue, 45.
 Cartilage capsules, see Cartilage.
 Cartilage cell, see Cartilage.
 Cartilage medulla, see Bone.
 Cavernous bodies, see Sexual apparatus of the male.
 Cavernous passages of the lymphatic glands, see Lymphatic glands.
 Cells, 3; naked cells, 3; cell doctrine, 3; cell and cytochrome, 4; cell forms, 4, 5; globular, flattened and cylindrical forms, 5; spindle cells, 5; protoplasm, 5; transformation of the same, 5; nucleus, 6; nucleolus, 6; non-nuclear cells, 6; multinuclear cells (myeloplaxes), 7; cell envelope and capsule, 7; porous canals, 8; vital (amœboid) changes in form of the cell, 9; pns corpuscles, 9; nutrition and locomotion, 9; penetration of cells into cells, 10; ciliated or vibratory cells, 10; sensibility of cells, 11; assimilation, 11; duration of life, 12; kinds of death of the cell, 13; spontaneous genesis, 14; processes of division, 14; endogenous cell formation, with mother and daughter cells, 15; intercellular substance, or tissue cement, 16; metamorphosis of the cells, and production of tissues, 17; metamorphosis of the intercellular substance, 17; elastic fibres, 17; glands, 18; transversely striated muscular filaments, 19.
 Cerebellum, see Nerve centres.
 Cerebral ganglia, see Nerve centres.
 Cerebrin, 194.
 Cerebrum, see Nerve centres.
 Cerumen, see Auditory apparatus.
 Ceruminous glands, see Auditory apparatus.
 Chlorio-capillaris, see Eye.
 Chorion of the ovum, 176.
 Chloroid, see Eye.
 Chyle, 26.
 Chyle vessels, 103, 116.
 Ciliary cells, see Epithelium.
 Ciliary motion, see Epithelium.
 Ciliary muscles, see Eye.
 Circulatory apparatus, see Vessels.
 Clitoris, see Sexual system of the female.
 Coagulation of the blood, 25.
 Coagulation of the nerve medulla, 194.
 Coccygeal gland, 126.
 Cochlea, see Auditory apparatus.
 Cochlear canal, see Auditory apparatus.
 Colloid, 124.
 Colloid metamorphosis of the thyroid cavities, 124; of the apophysis cerebri, 126.
 Colostrum, see Sexual system of the female.
 Columnæ Bertini, see Kidneys.
 Columns of the spinal cord, see Nerve centres.
 Commissura anterior and posterior of the spinal cord, see Nerve centres.
 Commissures of the spinal cord, see Nerve centres.
 Conarium of the brain, see Nerve centres.
 Coni of the retina, see Eye.
 Coni vasculosi, see Sexual apparatus of the male.
 Conjunctiva, see Eye.
 Connective substance, 41.
 Connective substance, lymphoid and reticular, 45.
 Connective tissues, 51; fibrillæ, bundles, elastic elements, 51; elastic sheaths, 53; cells of two different forms, 54; formless connective tissue, 56; formed, 56; cornea, 56; tendons, 57; ligaments, 57; connective-tissue cartilage, 57; fibrous membranes, 57; serous, 57; corium, 58; mucous membranes, 58; vascular membranes (pia mater, plexus choroides, and choroid), 58; connective tissue vascular walls, 58; elastic structures, 58; pathological, 59; embryonic conditions of the tissue, 59.
 Constituents of the body, 3.
 Contour, double, of the nerves, see Nerve tissue.
 Contractility of the living cell, 9.
 Convoluted glands, 130.
 Cornea, 56, 207, and see Eye.
 Corneal cells, 56, 248.
 Corneal corpuscles, 56, 248.
 Corneal nerves, 207.
 Corneal tubes, see Eye.
 Corneous layer of the epidermis, 32.

- Cornification of the pavement epithelium, see Epithelium.
- Cornu ammonis of the brain, see Nerve centres.
- Corpora cavernosa, 190.
- Corpora quadrigemina of the brain, see Nerve centres.
- Corpus callosum, see Nerve centres
- Corpus ciliare, see Eye.
- Corpus epididymis, see Sexual apparatus of the male.
- Corpus Highmori, see Sexual apparatus of the male.
- Corpus luteum, see Sexual apparatus of the female.
- Corpus striatum of the brain, see Nerve centres.
- Corpus vitreum, see Eye.
- Cortex corticis of the kidney, see Kidney.
- Corti's cells, see Auditory apparatus.
- Corti's fibres, see Auditory apparatus.
- Corti's organ, see Auditory apparatus.
- Cowper's glands, see Sexual apparatus of the male.
- Crura cerebri and cerebelli of the brain, see Nerve centres.
- Cuticula of the hair, see Epithelium.
- Cytode, 2.
- Daughter cells, 15.
- Dehiscence of the ovarian follicles, see Sexual system of the female.
- Deiter's cells of the cochlea, see Auditory apparatus.
- Dental nerves, 214.
- Dentinal cells, 75.
- Dentinal tubes, etc., see Tooth tissue.
- Dentine, 73.
- Desquamation of the cells, 12.
- Digestive apparatus, 139; oral cavity, 139; mucous glands, 139; salivary glands, submaxillary and sublingual, 139; change of the gland cells, 140; parotid, 141; tongue with its various papillæ, 141; serous glands of the tongue, 142; pharynx, 142; œsophagus, 142; stomach, 142; tubular glands, 143; frame-work of the mucous membrane, 143; peptic and gastric-mucous glands, 143; blood-vessels, 145; lymphatics, 145; small intestines, 146; intestinal villi and Lieberkühnian glands, 146; Brunner's glands, 146; lymph or chyle passages, 148; absorption of fat, 148; large intestine and its tubular glands, 149; lymphoid follicles of the intestines, 149; blood-vessels, 149; anus, 149.
- Dilator pupillæ, see Eye.
- Discs of the transversely striated muscles, see Muscles.
- Division of the cells, 14.
- Ductus ejaculatorii of the testicle, 189.
- Dura mater, 57 and 231.
- Duverney's glands, 181.
- Ear, see Auditory apparatus.
- Egg germ, see Sexual organs of the female.
- Egg-strands, see Sexual organs of the female.
- Elastic tissue, 52.
- Emigration of colored blood-cells through the walls of the vessels, 90; of lymphoid cells, 90.
- Emigration of red, and colorless blood-cells, 90.
- Enamel germ, 76.
- Enamel of the teeth, 75; enamel prisms, 75; enamel cuticle, 75; transverse section, 75; genesis, 76.
- Enamel organ, 46, 76.
- Enamel prisms, etc., see Enamel.
- Endogenous cell formation, 15.
- Endothelium, 28.
- Engelmann's accessory discs of the transversely striated muscle, 85.
- Envelopes of the finer nerve trunks, 57, 202.
- Enveloping structures of the central nervous system, 231.
- Epidermis, see Epithelium.
- Epididymis, see Sexual apparatus of the male.
- Epithelium, 28; endothelium, 28; pavement, cylinder and ciliated epithelium, 28; cement substance, 31; pigmented epithelium, 30; stratified, 30; stachel and ruff cells 32; epidermis, 32; ciliary movement, 35; nail tissue, 36; nail cells, 37; hairs, 38; hair shaft and root, 38; root sheath, 38; cortex and medulla of the hair, 39; epidermis, 39; appearance of the hairs, lanugo hairs, 40.
- Erection, 191.
- Eustachian tubes, see Auditory apparatus.
- Eye, 246; parts of the eyeball, 247; cornea, 247; sclerotic, 248; canalis Schlemmii, 249; choroid, 249; parts of the same, 249; ciliary body, 249; ciliary processes, 249; ciliary muscle, 249; iris, 250; sphincter and dilator of the pupil, 250; ligamentum pectinatum iridis, 250; nerves of the iris, etc.,

- 251; crystalline lens, 251; vitreous body, 251; zonula Zinnii, 251; canalis Petitii, 251; retina, 251; arrangement, 252; macula lutea, 252; layers, 252; frame-work substance, 252; membrana limitans interna, 252; Mueller's fibres, 253; membrana limitans externa, 254; rods and cones, 254; external granular layer, 257; intergranular layer, 257; inner granular layer, 258; molecular stratum, 258; layer of ganglion cells, 258; of nerve fibres, 259; macula lutea, 259; pars ciliaris, 260; lymphatics of the eye, 261; eyelids, 262; glands of the conjunctiva, 262; lachrymal glands, 263.
- Eyeball, see Eye.
- Fallopian tube, see Sexual organs of the female.
- Fat tissue, 48; fat cells, 48; fat drops, 48; chemical constitution of the fat of the body, 49; cells losing their fat, 49; occurrence of fat tissue, 50; genesis, 50.
- Fatty degeneration, 13, 88.
- Fire cell, contractile, see Muscular tissue.
- Fibro-cartilage, see Cartilage tissue.
- Fibro-reticular cartilage, see Cartilage tissue.
- Follicles, Graafian, of the ovary, see Sexual organs of the female.
- Follicles, Malpighian, of the spleen, see the latter.
- Follicles of the lymphatic glands, see the latter.
- Follicular chains of the ovary, see Sexual organs of the female.
- Follicular rudiments of the ovary, see Sexual organs of the female.
- Forked cells, see Gustatory apparatus.
- Formatio granulosa of the ovary, see Sexual organs of the female.
- Fovea centralis of the retina, see Eye.
- Gall-bladder, see Liver.
- Ganglia, see Nerve centres.
- Ganglion body, see Nerve tissue.
- Ganglion cell layer of the retina, see Eye.
- Ganglion cells, see Nerve tissue.
- Gastric glands, see Digestive apparatus.
- Gastric-mucous glands, see Digestive apparatus.
- Gastric-mucous membrane, see Digestive apparatus.
- Gegenbaur's osteoblasts, see Bone tissue.
- Gelatinous tissue and reticular connective substance, 45; vitreous body, 46; reticular connective substance, 47; lymphoid cells and modifications of the tissue, 47.
- General lamellæ, see Bone tissue.
- Germinal plates, 28, etc.
- Germinal spot, see Ovum.
- Germinal vesicle, see Ovum.
- Giant cells, see Myeloplaxes.
- Gland capillaries, 134.
- Gland nerves, 208.
- Gland tissue, 128; definition, 128; constituents of the glands, 129; various forms of glands, 130; gland cells, 131; secretions, 132; vessels, 134; lymphatics, 135; nerves, 135; excretory ducts, 135; individual glands of the body, 137; genesis, 138.
- Glands, mucous, 139.
- Glands, serous, 142.
- Glomerulus of the kidney, 98, 164.
- Goll's column of the spinal cord, see Nerve centres.
- Graafian follicles of the ovary, see Sexual organs of the female.
- Granular layer of the retina, see Eye.
- Growth of the cells, 11.
- Gustatory apparatus, 236; the various papillæ, 236; papillæ circumvallatæ and foliatæ, 236; gustatory buds, 237; nerve termination, 238; gustatory cells, 238.
- Gustatory buds, see Gustatory apparatus.
- Gustatory organ (tongue), see Gustatory apparatus.
- Gustatory papillæ of the tongue, see Gustatory apparatus.
- Habenule of the cochlea, see Auditory apparatus.
- Hæmoglobin, 22.
- Hair bulb, see Epithelium.
- Hair sac, see Epithelium.
- Hair, see Epithelium.
- Haversian canals, see Bone tissue.
- Haversian lamellæ, see Bone tissue.
- Haversian spaces, see Bone tissue.
- Heart muscles, 86.
- Hemispheres of the cerebrum and cerebellum, see Nerve centres.
- Henle's loops of the uriniferous canals, see Urinary apparatus.
- Hensen's middle discs of the transversely striated muscles, 84.

- Hepatic lobules, see Liver.
 Hepatic vessels, see Liver.
 Hilus-stroma of the lymphatic glands, 108.
 Histology, 3.
 Horn layer, 28.
 Horn layer of the epidermis, 32.
 Humor aqueus of the eye, see Eye.
 Humor vitreus of the eye, see Eye.
 Hymen, see Sexual apparatus of the female.
 Hypophysis cerebri, 126.
- Infundibula of the lungs, see Lungs.
 Interglobular spaces of the dentinal tissue, see Teeth.
 Intestinal glands, see Glands, and Digestive organs.
 Intestinal villi, 104; and Digestive organs.
 Iris, see Eye.
 Iris nerves, see Eye.
- Keratine, 5.
 Kidney, 163; cortex and medulla, 163; Malpighian or medullary pyramids, 163; columnæ Bertini, 163; uriniferous canals or Bellini's tubes, 163; medullary rays, 164; cortical pyramids, 164; glomerulus, 164; papillæ renales, 164; looped canals, 164; excretory passages and secretory portion of the kidney, 165; vascular arrangement of the cortical pyramids, 165; Mueller's or Bowman's capsule, 165; epithelial relations, 166; intercalary piece, 167; frame-work substance of the kidney, 168; blood and lymph vessels, 168; blood passages, 168; lymph passages, 170; urinary passages, 171; renal calices and pelvis, 171; ureter, 171; bladder, 171; female urethra, 172.
 Krause's transverse line of the muscles, see Muscular tissue.
- Labia, see Sexual organs of the female.
 Lacrymal gland, etc., see Eye.
 Lacunæ, see Bone tissue.
 Lamellæ of the bones, see Bone tissue.
 Lamina elastica of the cornea, see Eye.
 Lamina fusca of the choroid, see Eye.
 Lamina recticularis (velamentosa), see Auditory apparatus.
 Lamina spiralis of the cochlea, see Auditory apparatus.
 Large intestine, see Digestive organs.
 Larynx, see Lungs.
- Lens tissue, 78; lens capsule, 78; lens fibres, 78.
 Lentiform gastric glands, see Lymphoid organs.
 Leucæmia, 123.
 Lieberkühnian glands, see Digestive apparatus.
 Ligaments, see Connective tissue.
 Ligaments, elastic, see Connective tissue.
 Ligamentum ciliare, see Eye.
 Ligamentum pectinatum iridis, see Eye.
 Ligamentum spirale of the cochlea, see Auditory apparatus.
 Lingual papillæ, 141.
 Liquor folliculi, see Sexual apparatus of the female.
 Liver, 150; hepatic lobules, 151; hepatic cells, 151; fatty liver, 151; hepatic cell trabeculæ, 152; vessels, 152; frame-work, 153; biliary passages and biliary capillaries, 154; lymphatics, 155.
 Lungs, 157; larynx, 157; trachea, 157; lungs, 158; alveolar passages and pulmonary lobules, 158; pulmonary vesicles, p. cells, alveoli, 158; structure, 159; black lung pigment, 160; arrangement of vessels, 160; pulmonary epithelium, 162.
- Lymph, 27.
 Lymph corpuscles, see Lymphoid cells.
 Lymph passages, 102; ductus thoracicus, 102; lymphatics, 103; injection of the lymphatics, 103; arrangement of the same, 104; clefts, 106; juice canals or juice clefts, 107; lymphatic glands, 107; envelope, cortex and medulla, hilus-stroma, 108; follicles 108; septa and tender-fibres, 109; investment spaces, 109; lymph canals, 110; blood-vessels, 110.
 Lymph sheaths of the blood-vessels, see Vessels.
 Lymph vessels, see Lymph passages.
 Lymphatic glands, see Lymph passages.
 Lymphoid cells, 5, 9, 23, etc.
 Lymphoid follicles, see Lymphoid organs.
 Lymphoid organs, 112; lens-shaped glandules, solitary and Peyerian follicles, tonsils and trachoma glands, 112; structure of the tonsils, 113; trachoma glands in particular, 113; structure of the Peyerian plaques, 114; spleen, 116; Malpighian corpuscles, and pulp, 117; vessels, 119; cells containing blood corpuscles, 122;

- leucæmia, 123; lymphatics, 123; blood-vascular glands, 123.
- Macula lutea of the retina, see Eye.
- Malpighian bodies of the spleen, see Lymphoid organs.
- Malpighian glomerulus, see Kidney.
- Malpighian pyramids of the kidney, see Kidney.
- Malpighian rete mucosum, see Epidermis.
- Medulla, see Spinal cord and medulla oblongata.
- Medulla oblongata, see Nerve centres.
- Medulla of the nerves, see Nerve tissue.
- Medullary canals of the bones, see Bone tissue.
- Medullary substance of the lymphatic glands, kidney, etc., see the organs in question.
- Meibomian glands, see Eye.
- Melanin, 5, 30.
- Membrana Descemetica (Demourisiana), see Eye.
- Membrana hyaloidea, see Eye.
- Membrana limitans of the retina, see Eye.
- Membrana propria of the glands, see Glands.
- Membrana tympani, see Auditory apparatus.
- Membranes, fibrous, serous, etc., see Connective tissue.
- Middle germinal layer, 28.
- Milk, see Sexual organs of the female.
- Milk glands, see Sexual organs of the female.
- Milk globules, see Sexual organs of the female.
- Molecular movement (Brunonian), 27.
- Mother cells, 15.
- Mucous corpuscles, see Lymphoid cells.
- Mucous membrane, see Connective tissue.
- Mucous tissue, 46.
- Mueller's capsule of the kidney, see Kidney.
- Mueller's supporting fibres of the retina, see Eye.
- Muscle nerves, 203.
- Muscles, see Muscular tissue.
- Muscular filaments, etc., see Muscular tissue.
- Muscular tissue, 79; smooth and transversely striated, 79; smooth muscles, contractile fibre cells, 80; their occurrence, 80; transversely striated, 81; sarcolemma and sarcous elements, 81; fibrillæ and discs, 83; transverse discs, 84; accessory discs, 85; interstitial granules, 85; heart muscle, 86; transverse section of the muscle, 86; connection with the tendons, 86; embryonic development, 87; increase, 88; fatty degeneration, 88.
- Myeloplaxes, 7.
- Nail tissue, 37.
- Nails, 36.
- Nasal cavities, see Olfactory apparatus.
- Nerve centres, 215; ganglia, 215; their structure, 215; sympathetic, 217; sympathetic ganglia, submucous and plexus myentericus, etc., 217, 218; spinal cord, 218; neuroglia, 220; nerve roots of spinal cord, 221; white substance of spinal cord, 222; medulla oblongata, 224; its several parts, 224; cerebellum, 227; its several parts, with the cortex, 227; cerebrum, 229; its several parts, 229; blood and lymph vessels, 231.
- Nerve fibres, etc., see Nerve tissue.
- Nerve plexuses, etc., see Nerves, arrangement of.
- Nerve sheath, 202.
- Nerve tissue, 192; nerve fibres and ganglion cells, 192; medullated and non-medullated nerve fibres, 192; broad and narrow medullated fibres, 192; primitive sheaths, 193; axis cylinders, 193; nerve medulla (medullary sheath), 193; coagulation of the medulla, 194; transverse section, 194; varicosities, 195; Ranvier's constriction rings, 195; pale (Remy's), nerve fibres 196; axis or primitive fibrillæ, 196; ganglion cells, 197; apolar ganglion cells, 198; origin of nerve fibres, 198; uni- and bipolar ganglion cells, 198, 199; multipolar ganglia, 200; protoplasma and axis-cylinder processes, 200.
- Nerve tubes, see Nerve tissue.
- Nerves, arrangement and termination of, 202; nerve sheath (neurilemma), 193, 202; nerve termination, 203; terminal plates of voluntary muscles, 204; nerves of the smooth muscles, 206; nerve termination in the cornea, 207; gland nerves, 208; terminal bulbs, 208; Pacinian corpuscles, 210; tactile bodies, 211; other nerve terminations, 213; Langerhans' corpuscles, 213.

- Nerves, see Nerve tissue.
 Neurilemma (nerve sheath), 202.
 Neuroglia, see Nerve centres.
 Nipple, see Sexual apparatus of the female.
 Nucleus dentatus cerebelli, see Cerebellum.
 Nucleus of the cell, 6.
 Nymphæ, see Sexual organs of the female.

 Odontoblasts, see Dentine.
 Oesophagus, see Digestive apparatus.
 Olfactory hairs, etc., see Olfactory apparatus.
 Olfactory nerve, see Olfactory organ.
 Olfactory organ, 238; regio olfactoria, 238; its structure, 238; olfactory cells, 239; termination of the same, 240.
 Optic nerve, see Eye.
 Ora serrata retinae, see Eye.
 Oral cavity, see Digestive apparatus.
 Ossification process, see Bone tissue.
 Osteoblasts, etc., see Bone tissue.
 Otoliths, see Auditory organ.
 Ovarian follicles, see Sexual organs of the female.
 Ovary, see Sexual organs of the female.
 Oviduct, see Sexual organs of the female.
 Ovulum, see Sexual organs of the female.
 Ovum, 5, 175.
 Ovum, primordial, see Sexual organs of the female.

 Pacchionian granulations, see Nerve centres.
 Pacinian corpuscles, see Nerve terminations.
 Palatine glands, see Digestive apparatus.
 Palpebrae, see Eye.
 Pancreas, 150; contents, 150; centro-acinary cells, 150.
 Panniculus adiposus, 49.
 Papilla foliata of the tongue, see Gustatory apparatus.
 Papilla spiralis (Corti's organ) of the cochlea, see Auditory apparatus.
 Papillæ circumvallatæ of the tongue, see Gustatory apparatus.
 Papillæ filiformes of the tongue, see Gustatory apparatus.
 Papillæ fungiformes, see Gustatory apparatus.
 Papillæ of the corium, 58, 212.
 Papillæ renales, see Kidney.
 Parotid, see Digestive apparatus.

 Parovarium, see Sexual apparatus of the female.
 Pavement epithelium, see Epithelium.
 Pedunculi cerebri, see Nerve centres.
 Penicilli of the splenic arteries, see Spleen.
 Penis, see Sexual apparatus of the male.
 Peptic-gastric glands, see Stomach.
 Peptic-renal cells, see Stomach.
 Pericardium, see Connective tissue.
 Perichondrium, see Connective tissue.
 Perilymph (aqua Cotunnii), see Auditory apparatus.
 Perimysium, see Muscular tissue.
 Perineurium (nerve sheath), 202.
 Periosteum, see Connective tissue and Bones.
 Petit's canal, see Eye.
 Peyer's glands (follicles), see Lymphoid organs.
 Pharynx, see Digestive apparatus.
 Pia mater, see Connective tissue and Nerve centres.
 Pigment cells, see Epithelium and Connective tissue.
 Pigment epithelium of the retina, see Epithelium.
 Pineal gland of the brain, 230.
 Pleura, see Connective tissue.
 Plexus choroidei of the brain, see Nerve centres.
 Plexus myentericus, see Nerve tissue.
 Plexus of the nerves, see Nerve arrangement.
 Plica semilunaris, see Eye.
 Pons Varolii, see Nerve centres.
 Porous canals of the cells, 8.
 Primitive fibrillæ of the connective tissue, muscles, and nerves, see these tissues.
 Primitive sheaths of muscles and nerves, see these tissues.
 Primordial kidney, see Kidney.
 Primordial ova, see Sexual organs of the female.
 Processus ciliaris of the eye, see Eye.
 Processus vermiformis, 114.
 Prostate, see Sexual organs of the male.
 Protamœba, 2.
 Protoplasma, 2, etc.
 Pulp of the spleen, see Lymphoid organs.
 Pulpa dentis (tooth germ), 74.
 Purkinje's ganglion cells, see Central nervous system; germinal vesicle of the ovum, see Sexual organs of the female.
 Pus corpuscles (lymphoid cells), 9.

- Pyramids of the kidney, see Kidney.
 Pyramids of the medulla oblongata, see Nerve centres.
- Regio olfactoria, see Olfactory apparatus.
 Reissner's membrane of the cochlea, see Auditory apparatus.
 Remak's nerve fibres, see Nerve tissue.
 Remak's studies on cell formation, 14.
 Renal papillæ, etc., see Kidney.
 Respiratory organs, see Lungs.
 Rete Malpighii, see Epithelium.
 Rete testis, see Sexual organs of the male.
 Reticular cartilage, see Cartilage.
 Retina, see Eye.
 Retinal vessels, see Eye.
 Riff cells (stachel cells), see Epithelium.
 Rod corona fibres, see Nerve centres.
 Rods of the retina, see Eye.
- Salivary glands, see Digestive apparatus.
 Sarcolemma, see Muscular tissue.
 Sarcous element, see Muscular tissue.
 Scala media of the cochlea, see Auditory apparatus.
 Schlemm's canal, see Eye.
 Schneiderian membrane, see Olfactory apparatus.
 Schwann's cell doctrine, 14; Schwann's nerve sheath, see Nerve tissue.
 Sclerotic, see Eye.
 Sebaceous follicles, 236.
 Sebum cutaneum, 132, 236.
 Sebum formation of the glands of the skin, 132.
 Sebum palpebræ, see Eye.
 Segmentation of the yolk, 179.
 Semen, see Sexual organs of the male.
 Seminal filaments, etc., see Sexual organs of the male.
 Sexual organs of the female; ovary, 173; cortical and medullary substance of the same, 173; germinal epithelium, 173; cortical or zone of the primordial follicle, 173; ripe Graafian follicle, 175; ovum with the chorion, yolk, germinal vesicle, and germinal spot, 176; blood and lymph vessels, 177; parovarium, 177; genesis, 178; follicle chains or ovum strands, 178; corpus luteum, 179; segmentation of the ovule, 179; oviduct, 179; uterus, 179; uterine glands, 180; blood and lymph passages of the uterus, 180; pregnancy, 180; vagina, 180; hymen, clitoris, nymphæ, and labia majora, 181; vestibule, entrance to the vagina, 181; lacteal glands, 181; colostrum and milk, 182.
- Sexual organs of the male; testicle, 183; corpus Highmori and seminal canals, 183; epididymis, etc., 183; vas deferens, 184; vas aberrans Halleri, 184; structure of the seminal canals, 184; blood and lymph vessels, 185; genesis, 186; seminal filaments, 187; copulation, 187; genesis, 188; spermato-blasts, 189; structure of the vas deferens, 189; seminal vesicles, ejaculatory ducts, prostate, other glands, 189; urethra, 190; corpora cavernosa, glands 190; colliculus seminalis, 190; Littre's and Tyson's glands, 190; structure of the cavernous tissue, 190; erection, 191; vessels, 191.
 Sharpey's fibres of the bone, see Bone tissue.
 Sheath of the nerve fibres, see Nerve tissue.
 Skin, see Connective tissue, 58, and organs of sense, 234; tactile papillæ, 234; blood-vessels and lymphatics, 234; glands, 235.
 Small intestine, see Digestive apparatus.
 Solitary glands of the intestinal canal, see Lymphoid organs.
 Sperm (semen), see Sexual organs of the male.
 Spermatozoa, see Sexual organs of the male.
 Sphincter pupillæ, see Eye.
 Spinal cord, see Nerve centres.
 Spinal ganglia, see Nerve centres.
 Spiral fibres of the ganglion cells, see Nerve tissue.
 Spiral leaf of the cochlea, see Auditory apparatus.
 Spleen, see Lymphoid tissue.
 Splenic follicles, see Lymphoid organs.
 Splenic vessels, see Lymphoid organs.
 Spot, yellow, of the retina, see Visual apparatus.
 Stachel cells (riff cells), see Epithelium.
 Stellulæ Verheyenii of the kidney, see Kidney.
 Stomach, see Digestive apparatus.
 Stomata of the vessels, see Blood and lymph vessels.
 Subarachnoidal spaces, see Nerve centres.
 Subdural space, see Nerve centres.
 Sublingual glands, see Digestive apparatus.
 Submaxillary gland, see Digestive apparatus.

- Submucoas ganglion plexuses of the digestive organs, see Nerve centres.
- Suprarenal capsule, see Blood-vascular glands.
- Sweat glands, see Gland tissue.
- Sympathetic nerve, see Nerve arrangement.
- Tactile bodies, see Nerve terminations.
- Tactile organs, 234.
- Teeth, 73.
- Tendons, see Connective tissue.
- Tensor choroidiæ, see Eye.
- Terminal bulbs of the nervous system, 203.
- Terminal plates of the muscular nerves, see Nerve terminations.
- Terminal structures of the nerves, see Nerve terminations.
- Testicles, see Sexual apparatus of the male.
- Thalamus opticus, see Nerve centres.
- Theca of the ovary follicles, see Sexual organs of the female.
- Thymus, see Blood-vascular glands.
- Thyroid, see Blood-vascular glands.
- Tissue, 3; simple, 20; compound, 21.
- Tissue cement, 16.
- Tissue elements, 4.
- Tissues, division of the, 20.
- Tonsils, see Lymphoid organs.
- Tooth tissue, 73; dentine, 73; enamel and cement, 73; dentinal tubes, 73; cement, 74; interglobular spaces, 74; dentinal cells or odontoblasts, 75; genesis of the teeth, 76; tooth mound, enamel germ, tooth germ, 76; enamel organ, tooth sac, 77.
- Trachea, see Lungs.
- Trachoma glands, see Lymphoid organs and Eye.
- Tubæ Fallopii, see Sexual organs of the female.
- Tunica vasculosa of the eye, see Eye.
- Tympanum, etc., see Auditory apparatus.
- Tyson's glands, see Sexual organs of the male.
- Ureter, see Kidney.
- Urethra, 172, 190.
- Urethra, female, see Urinary apparatus; urethra, male, see Sexual organs of the male.
- Urinary apparatus, 163; kidneys, 163; cortex and medulla, 163; medullary pyramids, 163; columnæ Bertini, 163; uriniferous canals (Bellini's tubes), 163; cortical pyramids and glomerulus, 164; papillæ renales, 164; looped canals, 164; their two sides, 163; Mueller's or Bowman's capsule of the glomerulus, 165; course of the uriniferous canals, intercalary portion, etc., 166; vascular arrangement, 168; cortex corticis, 169; vasa recta, 170; lymphatics, 170; theory of the urinary secretion according to Ludwig, Bowman, 171; urinary canals, renal calices and pelvis, 171; ureter, 171; urinary bladder, 171; female urethra, 172.
- Uterine glands, see Sexual organs of the female.
- Uterus, see Sexual organs of the female.
- Uvea of the eye, see Eye.
- Vagina, see Sexual organs of the female.
- Varicosities of the nerves, see Nerve tissue.
- Vas aberrans Halleri of the testicle, see Sexual organs of the male.
- Vas afferens and efferens of the lymphatic glands, see Lymphatics.
- Vasa recta of the kidney, see Kidney.
- Vascula efferentia of the testicle, see Sexual organs of the male.
- Vascular membranes, see Vessels and Connective tissue.
- Vascular tissue, see Vessels.
- Veins, see Vessels.
- Venæ, inter- and intralobulares of the liver, see Liver.
- Venæ vorticose of the eye, see Eye.
- Venous plexus (plexus choroides), of the brain, see Central organ of the nervous system.
- Vesiculæ seminales, see Sexual organs of the male.
- Vessels, blood, 16; arteries, veins and capillaries, 89; capillaries, 89; vascular cells, 90; adventitia capillaris, 91; lymph sheath, 91; structure of the large arterial and venous trunks, 91; structure of the veins, 93; of the arteries, 94; valves, 95; capillary system, 95; capillary network, 96; various forms of the same, 96; genesis in the embryo, 99.
- Vessels, lymphatic, 102; intestinal villi, 104; other localities, 105; lymphatic apertures, 106; juice canals and clefts, 107; lymphatic glands, 107; their structure, 103; cortex, medulla, follicles, medullary strands, septum sys-

- tem, investment space, 108, 109; lymphatics of the medulla, 110; vessels, 110; lymph current, 111.
- Vestibule of the ear, see Auditory apparatus.
- Visual apparatus, 246.
- Vitreous body, 45, and the Eye.
- Wandering of the cells, 10.
- Wolfian body, 177, 186.
- Yolk, see Ovum.



