

TWO CASES

25.

OF

PARTIAL OBSTRUCTION OF A BRONCHUS
BY A FOREIGN BODY,

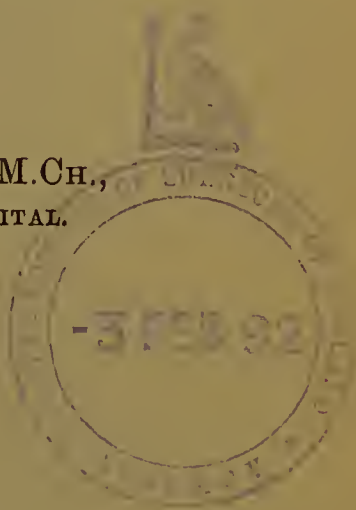
WITH

REMARKS ON THE OPERATION OF TRACHEOTOMY
FOR ITS REMOVAL.

BY

THOMAS BRYANT, F.R.C.S., M.Ch.,
CONSULTING SURGEON TO GUY'S HOSPITAL.

Read June 11th, 1889.



*from Vol. LXXII of the 'Medico-Chirurgical Transactions,' published
by the Royal Medical and Chirurgical Society of London.]*

LONDON:

PRINTED BY

ADLARD AND SON, BARTHOLOMEW CLOSE.

1890.



TWO CASES
OF
PARTIAL OBSTRUCTION OF A BRONCHUS
BY A FOREIGN BODY,
WITH
REMARKS ON THE OPERATION OF TRACHEOTOMY
FOR ITS REMOVAL.

BY
THOMAS BRYANT, F.R.C.S., M.Ch.,
CONSULTING SURGEON TO GUY'S HOSPITAL.

Received April 9th—Read June 11th, 1889.

MICHAEL P—, a tanner, æt. 49, was admitted into Guy's Hospital under my care on April 17th, 1886. The day before his admission, when sucking a button, he fell asleep, and awoke gasping for breath, but this difficulty rapidly subsided. On recovering his breath he remembered the button and looked for it, but without success; he was then led to think that he might have swallowed it, or that it had gone down into his chest. The button was about three quarters of an inch in diameter, with a shank. He coughed voluntarily for some time to bring the button up, but without avail; later on he took an emetic and vomited, but no button was ejected. He then came to Guy's.

On admission the man was coughing much and expectorating a good deal of mucus, but the cough was not paroxysmal. He had had a cough for many years and been expectorating for many weeks. The breathing generally was rough, but the râles seemed to be louder on the left than on the right side of the chest, and air also appeared to enter the right more than the left lung. Dr. Goodhart was asked to see the patient, and the following day he reported :

“ There is a marked diminution of respiratory murmur on the *left* side of the chest, as stated by the reporter. This extends down the upper half of the lung, but is less marked at the base. I am, however, inclined to doubt whether this means that the button is still in the left bronchus, because the patient is a deep-chested man, and there is a long wheezy expiration all over the chest, associated with a good deal of inspiratory sibilus, and he tells me that he has often had a bad cough in the winter, and therefore the deficient expansion of the left lung may easily be explained by some inequality of the disease on the two sides. I should therefore advise the man be simply watched.”

During the next two weeks the man went on much as usual, and his cough remained about the same. He now maintains that he feels the button in his right bronchus, and that the moment he turns over on that side he commences to cough. The coughing is periodical, not incessant.

On May 13th Dr. Goodhart again saw him, and reported :

“ The patient looks altered, he is of an ashy-grey colour, and has very laboured respiration. He has now a patch of tubular breathing at the base of the right lung, with sharp crepitation. There is still much bronchitic wheezing all over the chest, but more on the right than the left side. Expectoration purulent. No fœtor. Larynx healthy.” “ I am still,” adds Goodhart, “ unable to see any certain relations between the symptoms and the button, although it is of course possible that they may be due to its pre-

sence in the bronchus. On the former examination the left side if any seemed involved ; on the present it is the reverse."

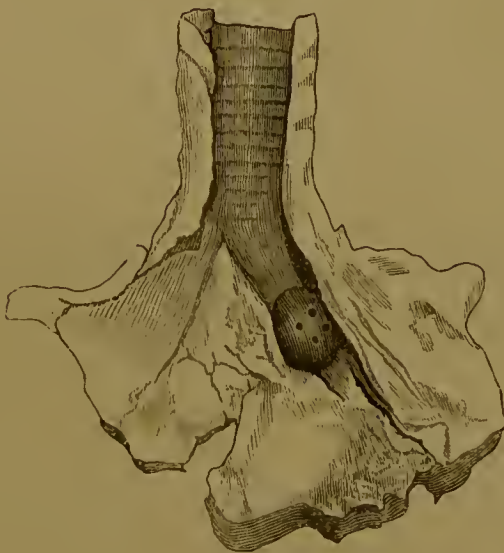With this uncertain view of his case the man refused to allow me to do what I wished, and operate upon him.

On May 31st the man was apparently better, and he did not expectorate so much. Dr. Goodhart reported, "The man is much better, chest much clearer. There is still, however, much tubular breathing of a whiffing character at the base of the right lung, and considerable dulness. Pulse regular."

On June 12th the man left the hospital, twenty-six days after his admission.

On July 20th, six weeks after his leaving Guy's, he was taken into the infirmary of St. Saviour's parish, as his cough had much increased, and he felt ill. Dr. Gross,

FIG. 1.



who has medical charge of the infirmary, reported that the man on his admission was very much emaciated, and had a constant cough, with profuse expectoration of foetid pus. The whole of the right side of his chest was dull, and there were loud numerous râles throughout. He died on August 4th, exhausted.

At the post-mortem made by Dr. Gross, the button was

found in the position indicated by the drawing (1) resting on the spur formed by the first bifurcation of the right bronchus. It was lying quite loose transversely in profile, and had set up very slight ulceration of the parts against which it had pressed (*vide* preparation 1717¹², Guy's Museum). The whole lung was consolidated. Diffuse suppuration existed throughout, and there were numerous small cavities containing pus, which were probably due to a general bronchiectasis.

CASE 2.—Robert H—, æt. 7, and living at Banstead, was admitted into Guy's Hospital under my care on the evening of August 5th, 1886, having three hours previously when blowing a toy trumpet swallowed or inhaled the mouthpiece which had become detached. The accident did not cause any special symptom beyond a momentary cough. The boy was taken at once to a medical man who examined him with a laryngoscope, but saw nothing abnormal. He was then brought to Guy's. On his way by train he amused his fellow passengers by blowing the trumpet when taking a deep breath or coughing.

On admission the boy was breathing naturally and seemed well; there was no constitutional disturbance. When the boy coughed or took a deep inspiration with his mouth closed, the note of the trumpet was clearly sounded. When the nostrils were closed and the mouth opened no note could be obtained.

When I saw the boy the next day I carefully explored the nose, thinking from the above fact that the foreign body might have lodged in its posterior chamber; and at the same time I examined the pharynx and laryngeal orifice, but this examination yielded no result. The chest on careful investigation seemed to be normal, as nothing abnormal could be made out, and no sound of whistling was heard.

The boy was therefore left alone and kept quiet in bed. On the eighth day after his admission the patient was

unable to blow the trumpet by any respiratory effort ; there was, however, no cough and no chest symptoms. Temperature 98.8° . On the twelfth day cough appeared, and it was then for the first time palpable that air entered the right lung better than it did the left.

Dr. Carrington who saw the case at this time reported, "There is very deficient entry of air into, and movement of, the left chest. I cannot find any physical signs of pneumonia. I should judge, however, that the foreign body is in the left bronchus."

On the following day, therefore, or thirteenth after the accident, I was led by this report to open the trachea with the view of removing the foreign body. For this purpose the child was placed upon a light table and given chloroform. A free incision was made so as to expose at least an inch of the upper part of the trachea, and in this incision the isthmus of the thyroid gland was divided without bleeding. The trachea was then opened and the table tilted upwards at the foot, the head of the child at the same time being made to hang over the other end. The thorax was then succussed on its posterior as well as anterior aspect, but without any good result. I then with a long silver bent probe sounded the trachea and bronchi with their branches, the head of the child being still dependent, and after repeated attempts at last struck in the left chest what sounded like a foreign body. With the forceps I now show you (Durham's) I then removed the whistle from the chest, having passed the instrument exactly five and a half inches from the lower limit of the wound in the trachea downwards into the chest before seizing it. The drawing now handed round (No. 2) was copied from one taken at the time of the operation by my friend Mr. Gowan.

The foreign body, which was composed of a tube of tin, when removed measured $\frac{15}{16}$ ths of an inch in length, and $\frac{5}{16}$ ths in its largest diameter. Its narrow end, which measured $\frac{4}{16}$ ths of an inch, presented downwards. Its lumen was only partially blocked by the structure which

formed the whistle, and consequently at least half its circumference was patent for the passage of air.

FIG. 2.



After the operation the wound was carefully bathed with iodine water, dressed with narrow strips of iodoform gauze made soft by being dipped into a mixture of terebene one part and olive oil four parts, and subsequently well pressed so as to get out all superfluous fluid, and covered with Gamgee tissue. The boy was then placed in bed in a small ward tent, into which water vapour was introduced. The boy's evening temperature was $100\cdot6^{\circ}$.

The next day everything was most comfortable, although

there was a little emphysema about the wound. The boy's respiration and pulse were normal; temperature 98·6°.

On the third day the wound was dressed and was found to have nearly healed. The same kind of dressing was applied. The boy had still a little cough.

On the fourth day no abnormal symptoms existed, consequently the steam tube was given up.

On the fifth day the boy was taken out of his tent and placed in a ward bed, and by the ninth day he was convalescent. He left the hospital on September 12th, quite comfortable, and when I saw him a month later was as well as he had ever been.

Remarks.—Cases of partial obstruction of a bronchus, in which the foreign body, by its gravity, is of sufficient weight to maintain its position, and yet is neither of such a size nor of such a form as to mechanically prevent the ingress and egress of air into the lung for respiratory purposes, are of sufficient rarity to justify their record; and the lessons to be learned from the two examples I have to-night brought under your notice seem worthy of our consideration.

In both cases the initial paroxysm of respiratory difficulty which followed the introduction of the foreign body into the trachea was brief and feebly marked.

In Case 1 the man awoke gasping for breath, but speedily recovered, and it was not till he recalled the fact that he went to sleep sucking a button that he was led to suspect that he might have swallowed it, or that it may have travelled downwards into his chest.

In Case 2, that of the boy, the inhalation of the foreign body did not cause any special symptom beyond a momentary cough.

In neither case was there, on the patients first coming under notice in the hospital—in one twenty-four and in the other four hours after the accident—any laryngeal or respiratory symptom to support the diagnosis of foreign body in the trachea or one of its branches, which the his-

tory of the cases had suggested, unless stress be laid upon the fact that in the case of the boy the whistle was sounded on a forced expiratory effort. This sound, it is to be noted, was only elicited on a forced nasal, and not oral, expiration.

In Case 1 such a trustworthy stethoscopist as my colleague, Dr. J. Goodhart, is known to be was inclined to doubt, even on the second day after the accident, whether the symptoms he found were to be explained by the presence of the button rather than by the chronic bronchitic changes from which the man had long suffered, and in Case 2 nothing whatever abnormal could be made out in the boy's chest on a careful examination, and it was not till the eighth day when the sound of the whistle on a nasal expiration was lost, and the twelfth day, when cough appeared, with physical chest symptoms, that it became clear that the left bronchus was more or less blocked.

As a matter of fact it may be said that the primary physical signs and symptoms of bronchial obstruction were in both cases of so unpronounced a character as to give little or no support to the diagnosis which the histories of the cases had rendered so highly probable ; and it was not till the secondary changes had taken place in the lungs, from the local irritation caused by the presence of the foreign body, that anything like a certain diagnosis could be made.

The fact that, in Case 2, the whistle sounded only on a forced nasal expiratory effort, and that the sound could neither be obtained by a forced oral expiration, nor heard on auscultation, is somewhat puzzling. It suggested to me at the time that the whistle must have found another resting place other than a bronchus, and induced me to explore very fully the upper laryngeal and nasal cavities.

The uncertainty of diagnosis in both cases consequently led to delay in treatment, and with an unfortunate result ; for in Case 1 it rendered my advice to the man, to submit to an operation, somewhat half-hearted, and it at the same time supported him in his natural wish to avoid what, to

his mind, seemed a severe operation. In Case 2 it likewise encouraged a delay, which might have proved very serious. To my own mind, these two cases very forcibly illustrate the evil of a procrastinating practice in this variety of accident, and more than suggests the expediency of performing the operation of tracheotomy in every case in which even a suspicion of the presence of a foreign body in the trachea or one of its branches finds the least support, from either the history of the case or the physical phenomena which may be present.

To wait for a certainty in diagnosis is often to wait too long. The risks of a tracheotomy operation *per se* cannot be looked upon in any way as serious, when compared with the certain evil which attends the presence of a foreign body, which, from its weight, cannot be expected to be expelled. I would much rather occasionally perform an unnecessary operation than leave a patient to his almost certain fate with a foreign body in his lung.

The opening into the trachea was a free one, and as a result no difficulty was experienced in the subsequent manipulation. I explored the tubes with the child's head and body in a somewhat dependent position, and believe that by this measure some advantages were gained, such as the avoidance of any lung irritation from the trickling of blood into its structure, and the ready escape of all secretions. Nothing could have answered better for the exploration of the bronchial tubes, or for the removal of the foreign body than the forceps I employed, for as soon as I felt the whistle with the blades of the closed instrument I caught it on opening and closing them.

Into what division of the left bronchus the foreign body had descended I cannot say, but as exactly five and a half inches of the instrument were passed through the tracheal wound before the foreign body was caught, and the patient was only seven years old, the distance must have been great.

(For discussion on this paper, see 'Proceedings of the Royal Medical and Chirurgical Society,' Third Series, vol. i, p. 149.)

