



Ex libris

Charles

Wood

Kofoid

J.M.C.



THE LIBRARY
OF
THE UNIVERSITY
OF CALIFORNIA

PRESENTED BY
PROF. CHARLES A. KOFOID AND
MRS. PRUDENCE W. KOFOID

MEMOIRS
OF
THE WISTAR INSTITUTE OF ANATOMY AND BIOLOGY
No. 1

THE ANATOMY AND DEVELOPMENT OF
THE SYSTEMIC LYMPHATIC VESSELS
IN THE DOMESTIC CAT

GEO. S. HUNTINGTON
FROM THE ANATOMICAL LABORATORY OF COLUMBIA UNIVERSITY

PHILADELPHIA, PA.
MAY, 1911



MEMOIRS
OF
THE WISTAR INSTITUTE OF ANATOMY AND BIOLOGY
No. 1

THE ANATOMY AND DEVELOPMENT OF
THE SYSTEMIC LYMPHATIC VESSELS
IN THE DOMESTIC CAT

GEO. S. HUNTINGTON
FROM THE ANATOMICAL LABORATORY OF COLUMBIA UNIVERSITY


PHILADELPHIA, PA.
1911

COMPOSED AND PRINTED AT THE
WAVERLY PRESS
By THE WILLIAMS & WILKINS COMPANY
BALTIMORE, U. S. A.

K-

CONTENTS

Introduction	5
Part I. The development of the systemic lymphatic vessels in their relation to the blood-vascular system.....	9
Historical review of theories of lymphatic development.....	10
Material used in present investigation.....	16
Comparison of haemal and lymphatic vascular development.....	19
Ontogeny of mammalian systemic lymphatic vessels.....	24
Mutual relations of developing systemic lymphatic vessels and embryonic veins	27
Phylogenetic relations of the abdominal veins and axial lymphatics in mammals.....	33
Development of systemic lymphatic vessels in the mammal independent of topographical association with embryonal veins.....	49
Summary and conclusions of Part I.....	53
Figs. 1 to 28	
Part II. The development of the preazygos and azygos segments of the thoracic ducts.....	55
1. The thoracic duct approach of the jugular lymph sacs.....	60
Figs 29 to 91.	
2. The preazygos segment.....	83
Adult conditions.....	84
Figs. 92 to 99.	
A. The development of the broncho-mediastinal trunk.....	91
Figs. 100 to 158.	
B. The development of the preazygos segment of the thoracic duct.....	107
Figs. 159 to 169.	
C. Junction of preazygos segment of thoracic duct and broncho-mediastinal trunk with each other and with the thoracic duct approach of the jugular lymph sac.....	113
Figs. 170 to 187.	
3. Azygos segment.....	121
A. General analysis of the development of the thoracic duct in the azygos region	123
Figs. 188 to 193.	
B. Detailed consideration of the individual stages in the development of the azygos segment of the thoracic duct.....	129
Junction of azygos and preazygos segments of the thoracic duct.....	150
Figs. 194 to 275.	
Summary and conclusions of Part II.....	153



INTRODUCTION

I have recently published in a preliminary communication,¹ a résumé of the results obtained in an investigation of mammalian lymphatic development and organization extending over the past six years, and now, in its main chapters, concluded. The paper above quoted was presented, with demonstrations of slides, at the 25th session of the Association of American Anatomists held in Boston during Convocation week of 1910, and is intended as an attempt to definitely establish what I believe to be the genetic principle upon which all systemic lymphatic development in the mammalian embryo is based. In outline this matter was also presented and demonstrated to the Section of Anatomy and Embryology of the XVIth International Medical Congress held at Budapest, August-September, 1909, and published in the Proceedings of the Congress.²

Owing to the character of the problem and its complexity, a detailed consideration of the same exceeds the reasonable limits of an article suitable for publication in our current anatomical periodicals, and the unavoidable number of microphotographic illustrations demanded makes publication through the ordinary channel still more inadvisable. For these reasons I have arranged, with the coöperation of The Wistar Institute of Anatomy, through Director Greenman, to publish the details of my observations on mammalian lymphatic ontogeny in the form of a series of monographs, in which the subject can be handled with

¹ G. S. Huntington: "The Genetic Principles of the Development of the Systemic Lymphatic Vessels in the Mammalian Embryo." *Anat. Record.*, vol. iv, no. 11, 1910, pp. 399 to 403, with 32 illustrations. (18 plates.)

² G. S. Huntington: "Ueber die Entwicklung des Lymphatischen Systems beim Säuger-Embryo." *Compte-Rendu*, xvi. Congres International de Médecine, Section 1, Anatomie, Embryologie, 2. Fascicule, pp. 127-142, Budapest, 1910.

less restraint than in one of the current publications. I have been led to the undertaking largely by my conviction of the value of the work which has been done within the last decade in this field by American investigators. The development of the lymphatic system is one of the very few broad morphological problems as yet incompletely solved, and I believe that the painstaking, able and conscientious work of the relatively large number of interested investigators of the subject in this country will eventually furnish a satisfactory answer to the question, as a national contribution to the advancement of anatomical science.

I have been obliged to differ, on the basis of my own investigations, from the conclusions reached by most of my American colleagues. I hence welcome the opportunity of placing my results fully on record, in such a manner that they can be readily examined and verified, if correct, or refuted, if found to be erroneous. In carrying out this purpose it is of course necessary, in order to avoid repetition and economize space, to simply refer to those parts of the subject which have been already fully covered in the existing publications, and to include these articles as part of the entire record. The main problem then is narrowed down to the developmental history of the mammalian systemic lymphatic channels, as distinguished from the jugular lymph sacs, or other homologous structures of like origin and equivalent functional significance, wherever situated.

The proposed series of publications will include the following topics in the order given:

Part I. The development of the systemic lymphatic vessels in their relation to the blood vascular system.


Part II. The development of the preazygos and azygos segments of the thoracic ducts.

Part III. The development of the visceral lymphatic drainage, and especially of the lymphatics of the abdominal cavity; the formation of the receptaculum, and of the postazygos segment of the thoracic ducts, as well as the lymphatic return from the pelvic and caudal regions and from the posterior extremity.

Part IV. The development of the main lymphatic trunks, other than the thoracic ducts, draining into the jugular lymph sacs, and through them into the venous system, viz., the cervical, jugular and supra-scapular lymphatics, and their mediastinal connections, and the lymphatic return from the anterior extremity along the sub-clavian vein.

Part V. The interpretation of adult normal and variant lymphatic organization on the genetic basis, and the interdependence of the adult venous and lymphatic systems.

The present publication includes Parts I and II of the above list.



PART I

THE DEVELOPMENT OF THE SYSTEMIC LYMPHATIC VESSELS, IN THEIR RELATION TO THE BLOOD- VASCULAR SYSTEM

The question as to the origin of the lymphatic vessels has, especially since 1902, occupied the attention of a number of American observers. These investigations have followed the older work on the same subject of Langer ('68), Budge ('80-'87), Gulland ('94), Ranvier ('95-'97) and Sala (1900), and the results have been published chiefly in the *American Journal of Anatomy*³ and in the *Anatomical Record*.⁴

During the progress of these researches a number of facts of primary importance bearing on the problem of lymphatic development and organization have been discovered. Some of these facts have been worked out in detail and are based on sufficiently extensive material and accurate observation to carry conviction by their constancy and consistency and to warrant their acceptance as definitely established ontogenetic conditions in the mammalian embryo. Other observations still lack complete confirmation, and in some others the methods employed in their determination create a doubt as to their validity, and tend to confuse the subject. Finally there are other conditions concerning which there still exists an honest difference of opinion, and which hence require further study and definite determination. On the whole, however, the American work of the last six or seven years has led to considerable and permanent advance in

³ Vol. i, 1902; vol. iii, 1904; vol. iv, 1904; vol. v, 1905; vol. vi, 1907; vol. ix, 1909; vol. x, 1910

⁴ Vol. ii. 1908; vol. iv, 1910.

our knowledge of the genesis of the mammalian lymphatic system.

The results so far obtained, and the views based thereon, may, with inclusion of the older work on the subject of vertebrate lymphatic development in general, be briefly summed up as follows in the form of short theoretic statements:

I. The lymphatic system is developed independently of the blood-vascular system. It is formed by the confluence of independently developed mesenchymal spaces, and, in case of the avian thoracic duct, by canalization of preformed solid strands of differentiated mesenchyme.^{5, 6, 7}

The works of Brachet and the combined researches of Brachet and Swaen,⁸ in their relation to the interpretation of lymphatic development, also support the independent origin of the lymphatic system from the mesenchyme.

The interesting observations of Marcus on the development and organization of the lymphatic system in *Hypogeophis*⁹ place the conclusions of this investigator in regard to the genesis of lymphatic structures in this general division, with the addition of the conception of the coelomata as primary lymphatic spaces (vide infra, pp. 25 and 26), and the phylogenetic derivation of the peripheral lymphatic system from the same.

⁵ Budge: "Ueber ein Canalsystem im Mesoderm von Hühnerembryonen." *Arch. für Anat. und Phys.*, Anat. Abth., 1880, s. 320. "Untersuchungen über die Entwicklung des Lymphsystems beim Hühnerembryo." *Arch. f. Anat. u. Phys.*, Anat. Abth., 1887, s. 59.

⁶ L. Sala: "Sullo sviluppo dei cuori linfatici e dei dotti toracici nell' embrione di pollo," *Ricerche fatta nel Laboratorio di Anatomia Normale della R. Univ. di Roma*, vol. vii, p. 263-269, April, 1900.

⁷ G. Lovell Gulland: "The Development of Lymphatic Glands", *Jour. Path. and Bact.*, vol. ii, 1894, pp. 447-485.

⁸ A. Brachet, "Recherches sur le développ. du coeur, des premiers vaisseaux et du sang chez les amphibiens urodèles," *Arch. d'anat. microscopique*, ii, 1898. "Recherches sur l'origine de l'appareil vasculaire sanguin chez les amphibiens," *Arch. de Biologie*, xix, 1903.

A. Swaen et A. Brachet, "Étude sur les premiers phases du développ. des organs dérivés du mésoblast chez les poissons téléostiens," *Arch. de Biologie*, xvi, 1899-1900.

⁹ H. Marcus, "Beiträge zur Kenntniss der Gymnophionen; II. Ueber intersegmentale Lymphherzen, nebst Bemerkungen über das Lymphsystem," *Morphol. Jahrbuch*, Bd. xxxviii, Heft 4, 1908.

II. The lymphatic vessels are directly derived from the venous system, certain embryonic venous channels being transferred in toto to the lymphatic system.^{10, 11, 12, 13}

III. All systemic lymphatics are formed by union of multiple direct derivatives from the embryonic veins,¹⁴ or only the thoracic ducts are so developed, while the other systemic lymphatic vessels arise independently.¹⁵

IV. The mammalian lymphatic system as a whole is developed by blind ducts which "bud off" from the embryonic veins of the cervical, and later from those of the inguinal region, widen out to form sacs, from which lymphatics grow to the skin and "cover its surface, while at the same time a growth of ducts occurs along the dorsal line following the aorta to make a thoracic duct from which lymphatics grow to the various organs." The theory underlying this conception of lymphatic development assumes the primary formation of a number of sacs, derived from the veins, and lined by embryonic venous endothelium, from which, as the

¹⁰ C. Langer: "Ueber das Lymphgefäßsystems des Frosches." *Sitzb. d. Akad. d. Wissensch.*, Bd. lviii., I. Abth., 1868.

¹¹ L. Ranvier: *Comptes Rendues*, 1895, 1896. "Morphologie et développement des vaisseaux lymphatiques chez les mammifères." *Archives d'Anatomie Microscopique*, Tome I, 1897.

¹² Giuseppe Favaro, "Ricerche intorno alla morfologia ed allo sviluppo dei vasi, seni e cuori caudali nei Ciclostomi e nei Pesci," *Atti del Reali Istituto Veneto di Scienze, Lettere et Arti.*, anno accad. 1905-1906, Tomo lxxv, Parte seconda. Appendice alla Dispensa X. "Note fisiologiche intorno al cuore caudale dei Murenoidi (Tipo *Anguilla vulgaris*, Turt.)," *Archiv. di Fisiologia*, vol. ii, Fasc. v, Luglio, 1905. "Il cuori ed i seni caudali dei Teleostei," *Anat. Anz.*, xxvii. Band, no. 14 und 15, 1905.

¹³ W. F. Allen, "The Distribution of the Lymphatics in the Head and in the Dorsal, Pectoral and Ventral Fins of *Scorpaenichthys marmoratus*," *Proc. Washington Acad. of Sciences*, vol. viii, pp. 41-90, May 18 1906. "The Distribution of the Subcutaneous Vessels in the Head region of the Ganoids, Polyodon and Lepidosteus," *ibid.*, vol. ix, pp. 79-158. July 1907. "The blood-vascular system of the Loricati, the mail-checked fishes," *ibid.*, vol. vii, 1905.

"Distribution of the subcutaneous vessels in the tail region of *Lepisosteus*," *Am. Jour. Anat.* vol. viii, 1908.

¹⁴ F. T. Lewis: "The Development of the Lymphatic System in Rabbits." *Am. Journ. of Anat.*, vol. v, 1905, pp. 95-111.

¹⁵ C. F. W. McClure: "The Development of the Thoracic and Right Lymphatic Ducts in the Domestic Cat." *Anat. Anz.*, xxxii. Band, No. 21 and 22, 1908, p. 534.

starting points, the lymph channels of the entire body develop by a process of continuous and uninterrupted centrifugal "sprouting" toward the periphery.^{16,17,18,19,20}

V. The systemic lymphatics are formed by confluence of perivenous mesodermal spaces, developed, as separate anlagen, outside the intima of the early venous channels, but not communicating with the same except at definite points of lymphaticovenous connection which are secondarily formed.²¹

This view pronounces for the ontogenesis of endothelial cells, lining the separate mesodermal spaces, independently of the haemal vascular endothelium. The spaces forming the first anlagen of the systemic lymphatic vessels are in no sense derived from the embryonic veins, although closely associated with them topographically.

At the time of the publication of the paper embodying these views, McClure and I were not aware of the important rôle played by the jugular lymph sacs, as affording the portals of entry of the entire systemic lymphatic circulation into the venous system. This relation was only subsequently ascertained

¹⁶ F. R. Sabin: "On the Origin of the Lymphatic System from the Veins, and the Development of the Lymph Hearts and Thoracic Duct in the Pig," *Am. Jour. Anat.*, vol. i, 1902, pp. 367-389. "On the Development of the Superficial Lymphatics in the Skin of the Pig," *Am. Jour. Anat.*, vol. iii, 1904, pp. 183-195. "The Development of the Lymphatic Nodes in the Pig and the Relation to the Lymph Hearts," *Am. Jour. Anat.*, vol. iv, 1905, p. 355-389. "Further Evidence on the Origin of the Lymphatic Endothelium from the Endothelium of the Blood Vascular System," *Anat. Record.*, vol. ii, 1908, pp. 46-54. "The Lymphatic System in Human Embryos. with a Consideration of the Morphology of the System," *Am. Jour. Anat.*, vol. ix, 1909, pp. 43-90.

¹⁷ W. J. MacCallum: "Die Beziehung der Lymphgefäße zum Bindegewebe." *Arch. f. Anat. und Phys.*, Anat. Abth., 1902.

¹⁸ G. Heuer: "The Development of the Lymphatics in the Small Intestine of the Pig." *Am. Jour. Anat.*, vol. ix, no. 1, 1909.

¹⁹ W. A. Baetjer: "The Origin of the Mesenteric Lymph Sac in the Pig." *Anat. Record.*, vol. ii, 1908.

²⁰ H. Hoyer, "Untersuchungen über das Lymphgefäßsystem der Froschlärven. I. Theil." *Extrait du Bulletin de l'Academie des Sciences de Cracovie, Classe des Sciences mathematiques et naturelles.* Juillet, 1905. II. Theil, *ibid.*, Mai, 1908.

²¹ G. S. Huntington and C. F. W. McClure: "The Development of the Main Lymph Channels of the Cat in their Relation to the Venous System." *Am. Jour. Anat.*, vol. vi, 1907. *Abstr. Anat. Rec.*, vol. i, pp. 36-41.

in the course of a detailed joint investigation of the development of these organs. We consequently failed to correctly recognize the origin of the adult lymphatico-venous junctions, and regarded them as direct secondary connections of the systemic lymphatics with the veins. The paper quoted, however, describes the genesis of the lymphatic vessels in their relation to the venous system correctly.

VI. In 1907 I published,²² based on McClure's and my own joint investigations, a genetic interpretation of the development of the mammalian lymphatic system as a whole, in which I defined the same as the product of the union of two genetically different and very unequal portions:

1. The entire extensive system of the lymphatic vessels proper of the adult animal, including the thoracic and right lymphatic ducts and their tributaries, is formed by the confluence of extra-venous intercellular mesodermal spaces, in the sense above defined (V).

These spaces are lined by a lymphatic vascular endothelium which is *not* derived from the haemal vascular endothelium, but develops independently of the same. The lymphatic channels, which result from the confluence of these spaces, follow in large part the embryonic veins closely, but they are neither derived from them, nor do they communicate with them, except at definite points, at which the rudimentary mammalian type of lymphatico-venous heart is developed.

2. A definite structure, the *Jugular Lymph Sac*, develops in the prevalent and typical mammalian lymphatic organization, directly from a perivenous capillary reticulum of the early pre- and postcardinal veins, adjacent to and including their point of confluence to form the duct of Cuvier. This jugular lymph sac, or rudimentary homologue of one of the lymph hearts of lower vertebrates, arising directly from the veins, subsequently separates for a short period entirely from the same, and finally makes two sets of permanent connections:

²² G. S. Huntington: "The Genetic Interpretation of the Development of the Mammalian Lymphatic System." *Anat. Record*, vol. ii, 1908, pp. 19-45.

(a) With the above defined independently formed systemic lymphatic channels of the entire body.

(b) *Secondary* connections with the venous system, re-entering the same at one or more typical and constant points, and thus forming the link which finally unites the venous and the lymphatic systems, developed independently of each other.

The above are, briefly summarized, the views of lymphatic development based on recent observations.

It will be seen, as previously stated, that opinions still differ as to the origin of the first lymphatic anlagen and their subsequent method of growth, and as to the genetic derivation of the lymphatic vascular endothelium.

The following two main questions are therefore still to be definitely answered:

(1) Is the adult mammalian lymphatic system the result of continuous and uninterrupted growth from one or more central points toward the periphery, or is it genetically a channel system, developed on the same lines as the primary blood vascular system, by the confluence of a number of originally separate and independent anlagen?

(2) Is the lymphatic vascular endothelium of the mammal derived from pre-existing haemal vascular endothelium, or is it the result of independent modification of mesodermal cells?

It now remains to answer definitely these questions, and, on the evidence of sufficiently extensive material and careful observations, to clear the field of theoretical considerations, and to establish, as far as possible, by sound methods and on a broad basis, the genesis of the mammalian lymphatic system as a whole. It is evident that an interpretation, which assumes to fulfill these conditions, must be capable of accurately standing the test of both ontogenetic and phylogenetic consistency.

Believing, as I do, and have, since my first expression of opinion on the subject, that the principles embodied in the genetic interpretation of mammalian lymphatic development above outlined (VI) are correct, I have undertaken to establish their truth by a detailed critical study of the lymphatic system, both in the adult and in the embryo, in one mammalian form, the Domestic

Cat, which animal, by reason of its clear-cut type of venous development,²³ and the great range of its adult venous variation,^{24, 25} seemed to me to offer the best opportunity of viewing the problem of mammalian lymphatic development both from the standpoint of its normal course in a representative form, and with reference to the variant conditions imposed upon it by correlated variants in the organization of the main systemic veins.

I have been further influenced in my selection of the cat for special and detailed study by the fact that in my experience the embryos of this carnivore offer uniformly histological pictures of lymphatic ontogenesis which are far more definite, clean-cut and conclusive than those obtained in ungulate, rodent or marsupial embryos. I believe that the cat is the only known available mammal in which the facts of systemic lymphatic development, as set forth in the following pages, could have been definitely ascertained. Guided by the clue thus furnished, it is not difficult to determine, by comparison, the existence of absolutely corresponding developmental conditions in the embryos of the pig, rat, rabbit, and opossum. But in none of these forms are the typical genetic stages as clearly marked and the tissues as definitely differentiated as in the cat.

The investigation of mammalian lymphatic development divides itself naturally, in accordance with the postulates of the genetic theory above advanced (VI), into three separate and distinct main parts:

- (1) The development and adult anatomy of the jugular lymph sacs.
- (2) The development and adult anatomy of the general systemic lymphatic vessels.

²³ G. S. Huntington and C. F. W. McClure: "The Development of the Postcava and Tributaries in the Domestic Cat." *Am. Jour. Anat.*, vol. vi, 1907, Abstr. *Anat. Record*, vol. i.

²⁴ Wm. Darrach: "Variations of the Postcava and its Tributaries in 605 Examples of the Domestic Cat." *Am. Jour. Anat.*, vol. vi, no. 3, 1907, Abstr. *Anat. Record*, vol. i, p. 30.

²⁵ G. S. Huntington and C. F. W. McClure "The Interpretation of Variations of the Postcava and Tributaries in the Domestic Cat, based on their Development." *Am. Jour. Anat.*, vol. vi, 1907, Abstr. *Anat. Record*, vol. i, p. 33.

(3) The mode of union with each other of the two components just enumerated, and the resulting establishment of a continuous *centripetal* lymphatic vascular system, with definite and constant terminals in the venous trunks. The first part of this work has been completed in conjunction with Prof. C. F. W. McClure of Princeton University. The results of our joint investigation on the development and structure of the jugular lymph sacs of the Cat have been published in a preliminary account.²⁶ The details, with critical analysis of a large series of embryos, and illustrations of the reconstructions of all the important stages, are given in an extensive paper recently published.²⁷

In these publications McClure and I have definitely demonstrated the fact that in the embryo of the cat the jugular lymph sacs develop as a small, but vitally important, part of the entire lymphatic system, directly from the pre- and postcardinal veins and their tributary plexuses, near to and including their Cuvierian junction.

The genesis of the jugular lymph sacs and their share in the adult organization having been thus definitely established in detail, I intend to follow independently the second postulate of the theory of the composite character of the adult mammalian lymphatic system above outlined (VI), and to show that the jugular lymph sacs, of direct *venous origin*, constitute the links uniting the hæmal vascular system and the general system of the *lymphatic vessels*, the latter developed *independently* of the veins, by the confluence of intercellular mesenchymal spaces surrounding, for the most part, the embryonic venous channels, but in no sense derived from the same.

MATERIAL

For the reasons stated above I have chiefly used the embryos of the domestic cat. Of these I have examined the following 107 individual embryos in complete serial sections:

²⁶ G. S. Huntington and C. F. W. McClure: "The Anatomy and Development of the Jugular Lymph Sacs in the Domestic Cat." *Anat. Record*, vol. ii, 1908, pp. 1-18.

²⁷ *American Jour. of Anat.*, vol. x, no. 2, April, 1910, pp. 177 to 311 with 67 figures.

SERIES NO.		CROWN RUMP MEASURE (TAKEN AFTER FIXATION) mm.	SERIES NO.	CROWN RUMP MEASURE (TAKEN AFTER FIXATION) mm.
188.....	11 Somites		118.....	10.5
86.....	13 Somites		120.....	10.5
			77.....	11
82.....		4.5	98.....	11
93.....		4.5	213.....	11
226.....		5.18	256.....	11.5
110.....		5.6	78.....	12
138.....		5.6	97.....	12
103.....		5.7	100.....	12
84.....		6	217.....	12
85.....		6	92.....	13
115.....		6	107.....	13
116.....		6	76.....	13.5
117.....		6	189.....	13.5
128.....		6	223.....	13.5
187.....		6	127.....	14
109.....		6.2	210.....	14
129.....		6.5	211.....	14
130.....		6.5	212.....	14
131.....		6.5	214.....	14
186.....		6.5	75.....	15
105.....		6.8	91.....	15
135.....		7	216.....	15
137.....		7	218.....	15
108.....		7.2	219.....	15
119.....		7.2	243.....	15
121.....		7.2	244.....	15
89.....		8	245.....	15
102.....		8	246.....	15
75A.....		8.5	141.....	15.5
106.....		9	143.....	15.5
136.....		9.2	215.....	15.5
132.....		9.5	247.....	15.5
133.....		9.5	95.....	16
239.....		9.5	96.....	16
79.....		10	222.....	16
101.....		10	224.....	16
111.....		10	230.....	16
112.....		10	248.....	16
113.....		10	240.....	16.5
114.....		10	94.....	17
140.....		10	142.....	17
237.....		10	198.....	17
81.....		10.3	258.....	17

SERIES NO.	CROWN RUMP MEASURE (TAKEN AFTER FIXATION) mm.	SERIES NO.	CROWN RUMP MEASURE (TAKEN AFTER FIXATION) mm.
87.....	18	83.....	20
88.....	18	255.....	20
199.....	18.5	241.....	20
249.....	18.5	242.....	21
250.....	18.5	147.....	25
254.....	18.5	168.....	34
80.....	19	144.....	31.5
197.....	19	90.....	35
252.....	19	104.....	51
253.....	19		

These embryos are contained in the Embryological Collection of Columbia University. The majority of the preparations were fixed in Zenker's fluid and stained differentially on the slide with Hæmatoxylin (Delafield) and Orange-G.

I have also had, through the courtesy of Professor McClure, the opportunity of carefully examining three very interesting cat embryos of the Princeton Collection, series 34 and 37, each of 14 mm. crown-rump measure, and series 53, a 15 mm. embryo.

A series of 180 adult animals with successful injection of the main systemic lymphatics served as control for the embryological determinations, and for the comparison of normal and variant adult conditions of the venous and lymphatic systems with the corresponding ontogenetic stages.

The results of my observations on the development of the mammalian systemic lymphatic vessels, as distinguished from the jugular lymph sacs, studied jointly with McClure, may be briefly summed up as follows:

The systemic lymphatic vessels of the entire body are formed through confluence of numerous originally separate intercellular mesodermal spaces, which develop in great part in close apposition to the walls of the embryonic venous channels, and in exactly the same way as the primary anlagen of the hæmal vascular system, but independent of the latter. The endothelium lining these first anlagen of the lymphatic vascular channels is from the

beginning independent of the hæmal endothelium, and develops with the first appearance of the lymphatic spaces, from the indifferent mesodermal cells lining these spaces. In my opinion the lymphatic and hæmal vascular endothelium have the same genetic derivation from the modified mesodermal cell lining the tissue spaces. The primary stage of endothelial differentiation is the same, whether the resulting channel system is to be assigned to the hæmal or the lymphatic division of the vascular system. We have therefore two generations of the embryonic vascular endothelial cell, a hæmal and a lymphatic. Both develop in the same way and as the result of identical genetic factors from the indifferent mesodermal cell. Both are from the very beginning of the process independent of each other in the mammalian embryo.

I desire again to emphatically aver my conviction that *all* the systemic lymphatic vessels of the mammalian embryo, including the thoracic ducts and their tributaries, are neither in their genesis continuous "outgrowths" or "buds" from sacs of venous origin, wherever situated, nor derived from multiple outgrowths from the embryonic veins, such outgrowths subsequently separating from the veins and fusing into continuous lymphatic channels. They are, in my opinion, on the contrary, from their very first inception, independent of the hæmal vascular system, and their endothelial lining is not derived from the blood vascular endothelium. They develop as independent intercellular mesodermal spaces, which become confluent with each other to form larger and larger communicating channels. These finally attain their entrance into the venous system through the intervention of the jugular lymph sacs, in the manner outlined in the publications above quoted.^{22, 26, 27}

Before taking up the details of the development of the first lymphatic anlagen in the mammalian embryo, it seems advisable to refer briefly to a résumé of known facts in regard to the earliest formative stages of the blood vascular system, in order to facilitate the comparison between hæmal and lymphatic development.

Phylogenetically, the earliest form of a closed circulatory system in multicellular organisms consists of intercellular canals

conveying a clear plasmatic fluid without cellular contents. The same picture is presented in the earliest stages of hæmal development in vertebrates. Thoma's²⁸ investigations of the histogenesis of the blood vascular system in chick embryos have furnished us with a very clear picture of the process.

The first histogenetic inception of the vertebrate hæmal vascular system is marked by the condensation of the mesoderm into cellular strands. Between the cells of these prævascular strands multiple oval or round spaces develop, which enlarge, elongate and become confluent, forming a network of inter-communicating channels, the *hæmal capillary anlages*. These channels contain a clear colourless fluid, with no, or only very scattered, cellular elements. This fluid, obtained by secretion from the free surfaces of the cells limiting the spaces, is evidently under a certain definite pressure, which exerts an influence on the form of the cells lining the channels. These limiting cells lose their earlier isodiametric, more or less regular cuboidal form, and appear flattened, and on optical section spindle-shaped. They have begun to assume the endothelial character. Hence from its earliest inception the endothelial lining of vascular channels appears as an environmental adaptation of the mesodermal cell. One surface of a cuboidal cell is freed from contact with adjacent cells by the development of an intercellular cleft, and this free surface is subjected to the pressure of the fluid contained in the earliest capillary anlages, modified by the tension pressure of the organism as a whole. This mechanical adaptation to the altered cellular milieu results in the formation of endothelium, and the process is identical in all portions of the mesoderm, independent of the question as to whether the resulting endothelial lined space shall subsequently be incorporated in a hæmal or a lymphatic system of vascular channels, or shall remain as a closed non-vascular mesodermal space.

It seems to me futile to try to speculate on an ontogenetic stage in which endothelium acquires a "specific" character. It

²⁸ R. Thoma: "Untersuchungen über die Histogenese und Histomechanik des Blutgefäßsystems." Stuttgart, 1893.

develops de novo in the adult under appropriate normal conditions.

Furthermore, this endothelial characterization of modified mesodermal cells is from the beginning a *multiple* process, starting independently at innumerable separate and discrete points of the vascular area, and becoming only subsequently continuous by confluence of the individual separate anlagen. This fact is of importance in drawing general conclusions as to the later extension of vascular endothelium, whether hæmal or lymphatic.

Up to this point the histogenetic and physical characters of all developing vascular structures are identical. The picture just described applies equally to the earliest definite anlagen of the hæmal capillary system, and, as I shall show; to the first appearance of the earliest lymphatic structures of the body. In the case of the definite blood-vascular channels of the vertebrate embryo, however, a further developmental change occurs, namely, the addition of free, specially modified, mesodermal cells, as the red blood cells, to the clear plasma circulating in the channel-system of the earliest capillary anlagen in response to the first pulsations of the heart.

The first blood vessels of the area pellucida appear, at least in part, to develop independently of the so-called "Blood islands." These latter, originally, form broad cellular strands composed of closely packed uncolored cells, which are only distinguished from the solid strands of the earliest vascular anlagen of the area pellucida by greater size and massiveness. After the vascular cell-strands of the area pellucida have developed in their interior the intercellular closed oval or round spaces of the first capillary anlagen, similar spaces also appear in the more massive cell strands of the peripheral portion of the area vasculosa. In the subsequent confluence of these discretely developed spaces to form the early capillary reticulum, the blood islands become more and more surrounded by the forming channels and are thus separated from the adjacent tissues. New endothelial-lined spaces continue to develop on the surface of the blood-islands, enlarge and join the system of connected channels. The cells forming the walls of these primitive capillaries become, as above stated, transformed

into the typical flattened endothelial cells of the vascular intima. Excepted from this endothelial transformation are only those cells of the vascular walls which differentiate as young blood cells. Thus eventually the confluence of the originally individual and separate spaces produces a continuous and connected channel system, lined by endothelium, which nearly encircles the blood islands. The latter are therefore now in large part included within the lumen of the capillaries, with whose walls they are from place to place continuous. It only requires a further and complete solution of this continuity, and the accompanying freeing of the blood cells, to add the latter to the plasma circulating in the preformed channels. In the chick, according to Thoma's observations, the resolution of the blood islands into separate blood cells occurs between the 45th and 55th hour of incubation, while the acquisition of hæmoglobin by the cells occurs between the 40th and 45th hour. With this occurrence the development of the primary blood-vascular channels has reached its definite accomplishment.

The general picture presented by the earliest development of the blood-vascular system may therefore be summarized as follows:

(1) Differentiation of certain mesodermal areas and lines by the multiplication of mesodermal cells to form cell-strands of varying density and size (vascular strands).

This appears to be a common antecedent condition not only of all vascular mesodermal structures, but also of other mesodermal derivatives eventually destined to obtain a lumen and enter into the formation of canals, as the Wolffian tubules and the cell-strands of the gonad.

It possibly explains the conditions described, for example, by Sala in the development of the avian thoracic duct, is seen in the developing aortae of early chick embryos, and is especially significant in the pictures furnished by Sabotta of the development of the aortæ in fishes.

(2) Development in the interior of these cellular strands of intercellular spaces in large numbers.

(3) Bio-mechanical modification of cells lining these spaces to produce typical flattened vascular endothelium.

(4) Confluence of these endothelial-lined spaces to form larger and larger vascular areas of intercommunicating channels, containing a clear plasmatic fluid, which circulates in the channels in response to the establishment of cardiac pulsation.

(5) Addition to the plasmatic contents of these channels, coincident with their further growth and extension into a continuous circulatory system, of cellular elements, derived from the mesoderm and specially modified to acquire hæmoglobin and function as red blood cells. These cells, by solution of tissue continuity, are liberated from the blood islands which are first surrounded by the confluent spaces of the capillary anlagen.

(6) Subsequent differentiation of the adventitia, with specialization of districts by cardiac concentration, amalgamation of the plexus into larger arterial and venous channels, definition of permanent capillary areas, valve and septal formation, etc.

The striking features of this ontogenetic history of the blood vascular system are:

1. The relatively late addition to the preformed non-cellular circulation of free cell elements, which, as the red blood cells, stamp, from the period of their liberation and inclusion in the circulating plasma, the resulting vascular system as *hæmal*.

2. The common origin from mesoderm of both characteristic components of the hæmal system, viz., the vascular endothelium and the red blood cell. Both the vascular intima and the free cell contents of the channels lined by this intima appear as highly modified derivatives of the same mesodermal cellular ancestors, which constitute the cell-strands of the earliest period of vascular development. In their first inception the systemic lymphatic vessels of the mammalian embryo, as distinguished from the jugular lymph sacs of venous origin, repeat in every detail the primary stages of the developing hæmal capillaries, prior to the inclusion within the lumen of the latter, of the cellular contents of the blood islands. They can be identified as distinct structures as soon as the blood channels proper have differentiated. Before that period direct observation cannot determine, in case of individual mesenchymal spaces, whether they are eventually to become part of the lymphatic or of the blood vascular system.

It is therefore quite possible that in the *mammalian* embryo both sets of intercellular mesodermal spaces develop side by side and simultaneously, although prior to the setting free of the hæmoglobin cells and their appearance within the lumen of the hæmal capillaries, there is no absolute criterion which would serve to distinguish intercellular spaces as belonging definitely to either the hæmal or the lymphatic division of the general vascular anlage.

It hence appears to me futile to base serious conclusions in regard to the *genesis* of vascular structure on observations made on the vessels seen in the transparent tails of living anure amphibia. Phylogenetically, from the urodele standpoint, such larvæ are adult organisms. We all know that, once established, all divisions of the vascular organization are, under the stimulus of normal or abnormal growth, capable of further increase and extension. The observations above referred to may offer, if correctly interpreted, interesting side lights on the method of vascular growth, but they cannot, in any valid sense, bear on the problem of vascular genesis, either hæmal or lymphatic.

But in mammalian embryos of the proper stages, and specifically in embryos of the Cat between 10 and 12 mm., the first systemic lymphatic anlages are clearly differentiated in the circumscribed areas of their first appearance, coincident with the definition of the early intra-embryonic blood channels.

Thus in the omphalo-mesenteric district, and cephalad and caudad of this point, on each side of the aorta, isolated intercellular mesenchymal spaces appear at this period, closely applied to the walls of the neighboring venous plexuses of the postcardinal and mesonephric veins, but not connected with the same. These intercellular clefts enlarge rapidly to form numerous oval or round spaces, closely interwoven with the venous network and later with the sympathetic anlages. The cells limiting these early lymphatic anlages become, with the further extension of the spaces which they line, flattened and assume typical endothelial characters.

Fig. 1 shows a transverse section of a 10 mm. cat embryo (series 111, slide viii, section 4) magnified 175 diameters, cephalad

of the mesonephros and the subcardinal cross anastomosis, and gives a topographical view of the region in which the first mesodermal intercellular lymphatic tissue spaces (77) appear, in the interval between aorta (73), postcardinal vein (68) and cœlom (78).

Fig. 2 is the same section of this embryo, magnified 300 diameters, and shows the area to the left of the aorta. Between this vessel (73) and the well defined left postcardinal vein (68) dorsad, and the cœlom cavity (78) ventrad, appear a number of clear mesenchymal spaces (77) which do not communicate with the adjacent venous channels. Some of these spaces extend from the cœlom angle dorsad along the lateral aspect of the postcardinal. They are the first distinctly recognizable anlagen of the lymphatic system, and they develop, from their first inception, as independent mesenchymal spaces, closely related to the adjacent hæmal channels, but genetically independent of the latter.

Fig. 3 shows the same field in a magnification of 600 diameters. The spaces are clearly cut, separate and distinct, and the limiting cells are beginning to assume endothelial character.

The relation between the hæmal channels and the developing adjacent lymphatic spaces can be clearly traced in successive sections of this same embryo proceeding caudad.

Figs. 4, 5, 6, and 7 show, respectively, sections 7, 8, 9 and 10 of slide viii of series 111, magnified 300 diameters.

In all of these sections the uniformity, and the distinct structural character of the primary lymphatic tissue-spaces is clearly visible in the same situation and in identical relation to surrounding structures.

For comparison with the preceding series the same region is shown in another 10 mm. embryo (series 120, slide ix, sections 25 and 26) in two successive sections, magnified 300 diameters, in figs. 8 and 9.

In these sections the same independent mesodermal spaces (77) are seen in their typical relation to aorta (73), post-cardinal vein (68) and cœlom cleft (78).

The interesting question of the relationship between these early mesenchymal spaces and the cœlom cavity can only be

considered superficially at this time. Yet, in some regions, very suggestive pictures are obtained. Thus in section 4 of slide viii of series 111 (figs. 1, 2 and 3) the distinct appearance of a communication between the cœlom cavity proper (78) and the early mesenchymal spaces (77) above described is given by a clearly limited and well defined funnel-shaped stoma, occupying the dorsal extremity of the cœlomic cleft (79 in fig. 2), and apparently opening directly into the spaces of the early lymphatic plexus. The remaining sections of this series figured (figs. 4 to 7) confirm this impression.

The conditions here described for early embryos of the cat strongly support the views expressed by Marcus⁹ in his studies on the lymphatic development of Hypogeophis. The microphotographs here given should be compared with his description on pp. 599-601 of the paper quoted, with his text fig. 6, and with his figs. 5 and 6 of plate xvi.

The early mesodermal spaces here described and figured are lymphatic in character and form part of the extensive *temporary* network of lymphatic channels which appears for a time during mammalian ontogenesis and which bears a close resemblance to the corresponding lymphatic organization in amphibia and reptiles. The peri-aortic lymphatic sinuses and the exaggerated subcutaneous lymph channels of the earlier mammalian stages are portions of this evanescent and reminiscent system, which subsequently in large part retrogrades, and either disappears altogether or is extremely modified to meet the definite permanent conditions of mammalian lymphatic organization. Thus the early periaortic spaces become much reduced in course of further development. They then become associated, in a way presently to be described in detail, with elements of the axial venous plexuses of the mammalian embryo and form the anlagen of the main segments of the thoracic ducts. This ontogenetic temporary recall of antecedent phylogenetic types of vascular development appears to be chiefly centered, in the mammalian embryo, in the region around the omphalo-mesenteric artery, where, in the adult, the definite and permanent lymphatic trunks closely resemble in their arrangement the peri-omphalo-mesenteric annular veins of certain reptilian embryos.

In the succeeding stages the mesodermal lymphatic anlagen assume, in large part, the very definite relation to certain embryonic venous channels, which led McClure and myself to describe them in 1906 in our preliminary account above quoted,²¹ as "extraintimal" or "perivenous" structures.

This relationship is of two kinds:

A. *Total replacement of temporary embryonic veins by extraintimal lymphatic channels.*

In the earlier embryonic stages the areas of the future definite venous channels are largely occupied by an antecedent venous or capillary network, out of which, along definite hydrostatic lines, the subsequent veins develop by confluence of the plexus elements occupying these lines.²⁹ Parts of the early capillary reticulum, not thus included in the path of the definitely organized venous trunks, remain, after the latter have become established, as a perivenous plexus. Some of the elements of this secondarily established plexus develop into permanent tributaries of the main veins. Others undergo a process of separation from the permanent functional channels and degenerate. In many cases their blood-cell contents break down and are eliminated, while their endothelial lining appears to revert to the indifferent type of the embryonic mesodermal cell.

Thus in embryos between 13.5 and 16 mm. many striking instances of this reversion are to be observed. The former vascular channel appears as a collection of clearly differentiated and very highly stained mesodermal cells.

Figs. 47, 50, 51, in Part II, show these mesodermal vascular derivatives very clearly. They form the dark masses seen in the field dorsal and dorsolateral to the œsophagus and in the peritracheal region.

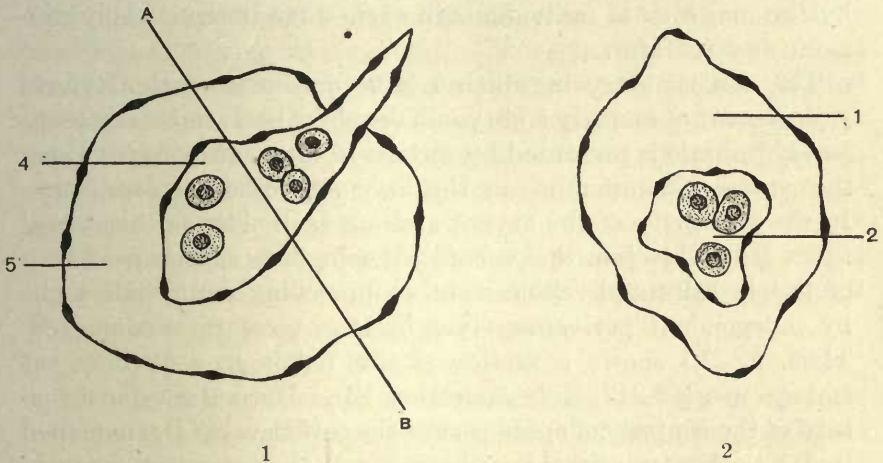
In many regions of the mammalian embryo, however, these detached and retrograding venous elements do not attain this condition, but in an earlier stage, constitute lines around which the most active primary lymphatic organization of the mammalian

²⁹ H. v. W. Schulte and Fred. Tilney: "Note on the Organization of the Venous Return, with Especial Reference to the Iliac Veins." *Anat. Record*, vol. iii, no. 11, 1909.

embryo centers. The intercellular mesodermal clefts above described develop especially along and around these decadent venules and finally envelop them. As the result of this process the lymphatic anlagen appear in certain mammalian ontogenetic stages, in large part, as distinct spaces enclosing the remnant of the embryonic vein. The latter may still, for a time, contain a few degenerating red blood cells, but these soon disappear, and then the entire anlage is formed by a collapsed and empty endothelial tube, the abandoned channel of the earlier vein, surrounded by a second endothelial tube, formed by the confluence of the independently developed extraintimal or perivenous mesodermal spaces. As these spaces enlarge and join each other their lumen increases, and the limiting cells become flattened and assume typical endothelial characters. The height of this phase of lymphatic development is reached in embryos of the cat in the 14 mm. stage, and numerous demonstrations of the appearance of the structures on section are given in Part II of this paper. The remnant of the embryonic vein bears a relation to the replacing perivenous lymphatic channel which is exactly the same as that of a collapsed inner tube to the enveloping shoe of a pneumatic tire. The inner skin of the shoe and the rim of the wheel represent the *lymphatic intimal endothelium*. The space between the shoe and the collapsed inner tube is the *lumen* of the future lymphatic channel. The empty inner tube itself is the decadent *embryonic vein* upon and around which the secondary lymphatic channel is built. In the course of further development the venous remnant disintegrates and disappears, leaving a clear lumen for the lymphatic vessel, which thus completely replaces the earlier vein and comes to occupy absolutely the topographical position of the latter.

Often the replacing lymphatic begins as an extraintimal channel *partially* surrounding the receding vein. This leads in course of further development to an expansion of the lymphatic channel not concentric with the axial line of the shrinking vein. The remnant of the vein then retires to a point on the intimal surface of the new lymphatic channel, and appears to project into the lumen of the latter. The resulting histological picture

will depend on the plane of section in reference to the course of the lymphatic and its contained venous remnant. Thus, as shown in the following schema, many sections give the appearance indicated in 1. If the plane of section should, however, lie in the line *AB*, it will divide the shrinking vein (4) and the enveloping lymphatic (5) in such a way as to produce the picture shown under 2. In other cases the lymphatic spaces unite around the entire circumference of the abandoned venule, and the lumen is then contained for long distances entirely within the lumen of the replacing lymphatic channel.



The process just described is remarkably constant and uniform in the critical stages of mammalian lymphatic development. As can be readily seen in following the individual sections in the microphotographs published in Part II, the significance of the conditions here shown is unmistakable. This is not a haphazard process, observed only occasionally, in a limited number of embryos, and then only in single sections, or, at most, in a few successive sections. In any average embryo of the proper age the same structures appear regularly in the same situations and in identical relationship to the embryonic environment. It is often possible, as the microphotographs and the corresponding

reconstructions herewith published clearly show, to trace the forming lymphatic with its atrophied vein kernel for long stretches, and in different embryos of approximately the same crown-rump measure the consistent repetition of identical histological pictures is remarkable.

There are, of course, as in the ontogeny of other structures, individual cases of variation in which systemic lymphatic development is either more advanced or more retarded than is normal for the average of any given stage. But if a large number of embryos of each typical period are examined and compared, the *average standard* of extraintimal lymphatic development attained by the majority of individuals in each stage is remarkably constant and uniform.

The earliest stage in which I have encountered this typical replacement of an early embryonic vein by a perivenous extraintimal lymphatic is presented by certain 12 mm. cat embryos along the caudal circumference of the azygos-precordial confluence. In the concavity of the azygos arch on each side, as this vessel turns ventrad to join the precordial vein, these earliest evidences of the extraintimal replacement of preceding embryonic veins by independent perivenous lymphatic spaces are encountered. Thus, fig. 10 shows a section of this region in a 12 mm. cat embryo (series 217, slide x, section 12). Here the typical picture of the central collapsed core of the earlier vein (4), enveloped by the clear extraintimal lymphatic space (5), is plainly to be seen. Fig. 11 shows the same region in another 12 mm. embryo (series 211, slide x, section 15). Both the degenerating venule (4) and the enveloping lymphatic (5) are larger than in the preceding series, and occupy the same position between aorta (7) and left precordial vein (6).

In a 14 mm. embryo (series 127, slide viii, section 12, fig. 12) the section passing just caudad to the junction of left azygos (6) with left precordial vein (6) shows these early lymphatic spaces (5) and their relation to the contained venous remnant (4) fully developed. Only one of the areas is denoted by leaders in the figure, but two equivalent areas are seen further dorsad and nearer to the ventral aspect of the azygos arch. The lym-

phatic plexus, as development proceeds, from the 12 mm. stage on, approaches the large venous trunks more and more, until the spaces lie in direct apposition with the same, and unite to form the lymphatic trunk eventually destined to replace the left azygos arch and adjacent position of the left precardinal vein. This trunk then constitutes the cephalic end of the broncho-mediastinal duct (37). Thus figs. 13 and 14 show two sections through the same region in a 15 mm. embryo (series 219, slide xiv, sections 19 and 16). Compared with the 14 mm. embryo the left azygos vein shows a marked reduction. The lymphatic spaces have enlarged and present a clear lumen on section, the remnant of the earlier vein, around which they developed, having disappeared. The spaces lie between aorta and left precaval vein, in close approximation to the dorso-medial circumference of the latter. The azygos segment of the thoracic duct (36) is seen dorsal to the interval between aorta and œsophagus, and ventral to the scant remnants of the earlier interazygos venous anastomosis (15).

The reconstruction of a 15 mm. embryo (series 218) shown in fig. 170 in Part II, gives a clear idea of the extent and relations of this lymphatic complex (37) in this stage.

B. Partial replacement of portions of the territory of an early embryonic venous pathway by an extraintimal lymphatic vessel, both venous and lymphatic channels either persisting side by side up to later developmental periods, or forming correlated components of the permanent adult vascular organization.

The developmental processes just described appear most clearly marked in the earlier stages, and in connection with temporary embryonic channels and plexuses which are destined to undergo rapid degeneration and ultimate complete elimination. In the case of the embryonic veins which are retained for a longer period, or carried over into the permanent adult organization, the histogenetic stages of lymphatic development are identical in kind, and differ only in degree from those just detailed. In place of complete replacement of the antecedent vein by the lymphatic channel, this replacement is only partial and leads to the typical

close parallel association of lymphatic and venous vessels so characteristic of the later embryonic stages and of the permanent adult pathways of both the lymphatic and the venous systems.

Figs. 15 and 16 show transverse sections of a 14 mm. embryo (series 222, slide vii, section 26, and slide viii, section 4) in the region of the external jugular vein. The lymphatic spaces (27') are in full development, and are applied chiefly to the medial aspect of the plexus of the external jugular vein (27). The lymphatic endothelium is clearly marked.

Fig. 17 shows a transverse section in the upper thoracic region of another 14 mm. embryo (series 37, slide xiii, section 12). A typical lymphatic anlage (53) is applied to the medial wall of the left precaval vein.

Fig. 18 shows a transverse section through the mid-thoracic region in a 17 mm. cat embryo (series 258, slide xviii, section 9, $\times 225$).

The extraintimal anlagen of the thoracic ducts (36), which usually in this stage have advanced to the production of a continuous and uninterrupted channel system, are seen on each side closely applied to the ventral aspect of the left and right azygos veins. The latter are in the height of their development, forming large and symmetrical longitudinal venous trunks (3, 6) connected by the supra-aortic interazygos anastomosis. In course of further development the left azygos vein and the interazygos anastomosis are destined to undergo progressive reduction until they are eventually entirely lost. Their topographical position is then occupied by the replacing left segment of the thoracic duct complex (36). The right azygos vein, which is carried as a permanent vessel into the adult organization, also undergoes considerable relative reduction, correlated to the corresponding increase in the caliber of the main (right) segment of this portion of the thoracic duct complex.

The beginning of this process is seen well in fig. 19, which shows a transection of the same region in a 19 mm. cat embryo (series 253, slide xxiv, section 9, $\times 225$). The change from the preceding

stage (fig. 18) is marked both in the venous and the lymphatic channels. The former are relatively much reduced, while the latter have correspondingly increased in extent. The azygos is mainly represented by the right channel (3). The left channel (6) has become small, but is still connected by the transverse inter-azygos anastomosis (15) with the larger and permanent right trunk. The right thoracic duct (36) is likewise large. A dorso-medial extension of the same, which carries into the interval between aorta and interazygos plexus, will, in later stages, replace the latter secondarily, after the complete recession of the left azygos vein. The left thoracic duct (36) is also of large size and fills a considerable part of the area formerly (fig. 18) occupied by the left azygos trunk. Some decadent remnants of the ventro-medial azygos plexus (4) are still seen associated with the left duct, and are in process of replacement by a lymphatic space (5) destined to make connection between the left thoracic duct anlage and the mesenteric lymphatic plexuses (cf. p. 148, figs. 266 to 270, 51).

Figs. 20 to 24 show transverse sections in the region of the developing mesenteric lymphatics and of the ascending lumbar lymphatic trunks in a 17 mm. embryo (series 258, slide xxiii, sections 34, 33, 32 and 31.) The embryonic veins (74) occupying the root of the mesentery caudal to the subcardinal cross-anastomosis are in the process of being replaced by extraintimal lymphatic spaces (51) which are destined to become confluent and form the anlage of the future mesenteric lymphatic sac.

The region in question is not only interesting in reference to the ontogenesis of the abdominal lymphatic sacs and channels, but the arrangement of the periaortic axial venous trunks and their relation to the developing lymphatics is, in combination with the next following stage (20 mm., figs. 25 and 26), of the highest importance in interpreting the phylogenetic relations of the main abdominal veins in mammalia. For these reasons a somewhat more detailed consideration of the sections may properly be introduced here.

Fig. 20 shows section 34 of slide xxiii of series 258 in a magnification of 75 diameters and affords a comprehensive picture of the entire

topographical field involved. The strands of the sympathetic (1) are supra-aortic. On each side of the aorta (7) are the large and symmetrically developed right and left postcardinal veins (67 and 68), with the ascending trunks of the ilio-lumbar arteries (A. ilio-lumb. transv. ant.) (not labelled in the figure) applied to their ventro-lateral circumference. The subaortic area shows the cross-sections of four symmetrical vascular channels, two venous and two lymphatic. Immediately ventral to the aorta, and closely applied to its ventral wall and to each other, are two longitudinal parallel axial veins which are connected at intervals by a few short transverse anastomoses. These vessels are the temporary and very evanescent homologues in the placental embryo of the channels which McClure³⁰ has described as the "cardinal collateral trunks" in the embryo of *Didelphis marsupialis*, and from which he has traced the development of the preaortic postcava characteristic of the Marsupalia. These vessels are derivatives from the earlier preaortic cardinal-subcardinal venous plexus below the cross-anastomosis, but differentiate in Marsupials along separate and distinct axial lines. They are destined, as are the corresponding portions of the subcardinals proper, to be entirely replaced in the typical placental development by the chain of preaortic lymph channels and nodes, but are capable, in aberrant types among the placentalia, of yielding, by further and continuous development, a type of preaortic postcava which in every respect corresponds to that encountered in Marsupials. McClure³¹ has described this condition in *Tragulus*, and his observation has been confirmed in a number of dissections by Beddard and others. The fortunate acquisition recently of a series of *Tragulus* embryos, through the kindness of the officials of the Smithsonian Institution, has enabled my associate Tilney to trace, in a publication now in preparation for the press, the development of the venous and lymphatic systems in this aberrant ungulate in their mutual interdependence, and to show the correspondence of the venous genetic processes

³⁰ C. F. W. McClure: "The Anatomy and Development of the Postcava in *Didelphis marsupialis*." *Am. Jour. Anat.*, vol. v, 1906.

³¹ C. F. W. McClure: "The Postcava of an Adult Indian Chevrotain (*Tragulus meminna*, Erxleben). *Anat. Anz.*, Band, xxix no. 13 and 14, 1906, pp. 375-377.

with those observed by McClure in *Didelphis*. We have here, therefore, an undoubted instance in which, in an ungulate placental, the organization of the abdominal venous and lymphatic complex dates back, phylogenetically, to the period of a common mammalian, or even amniote, vascular groundplan (text figure A, p. 41), forming the starting point from which all types of normal and variant postcaval organization, monotreme, marsupial and placental, radiate. This makes it possible, as in the ungulate genus just mentioned, to find in otherwise valid placental forms, as a constant and normal structural character, the postrenal segment of the postcava as a single median preaortic vessel, which receives, usually, both sex veins, and corresponds in every respect to the characteristic marsupial venous type. This channel is the final and permanent product of the fusion of the two embryonal cardinal collateral veins, which, in the typical placental, either do not develop at all, as distinct veins, or else, as in the cat, appear during the ontogenesis only for a very short period, and are subsequently entirely replaced by extraintimal lymphatic spaces eventually uniting to form the extensive right and left ascending lumbar lymphatic trunks. These vessels (75) are seen in the preparation under discussion on each side, ventro-lateral of the aorta in the space between the postcardinal veins (67 and 68) and the cardinal collateral veins (74). These large lymphatic channels have been developed through the fusion of numerous separate extraintimal spaces surrounding and finally replacing some of the elements of the earlier preaortic venous plexuses. A condensed portion of the latter still persists in this embryo as the cardinal collateral veins (74) above referred to. Eventually these also are destined to undergo, in course of normal development, complete extraintimal replacement by lymphatic channels. These latter thus come to occupy in the typical placental secondarily the territory which in monotremes, marsupials and atypical placentalia (*Tragulid*) is filled by the postrenal preaortic postcava (cardinal collateral).

It is interesting to note in this connection that a detailed examination of over 900 adult cats failed to reveal a single instance in which the postrenal segment of the postcava was formed through

persistence and further development of the cardinal collateral veins. In other words, not a single individual in the entire series possessed a *marsupial* postcava, although every shade in the possible range of variation in the district of the post- and supracardinal lines was represented by numerous examples. Thus with an abdominal venous organization of very unstable equilibrium, as shown by the large percentage of cardinal variants,²⁴ the cat yet keeps entirely within the district of the common genetic ground plan assigned to the placentalia. This phylogenetic consistency is maintained in spite of the fact that, as just demonstrated in series 258, the embryo develops the raw materials, as cardinal collateral channels, out of which a preaortic postcava of the marsupial type could be evolved. In my own estimation cats possessing this form of postcava may exist and may eventually be found. But the failure to encounter them in the relatively large series of adults already examined speaks volumes for the value of vascular organization in interpreting phylogenetic relations.

In this light the postcaval development and adult structure of *Tragul*, for example, are of the utmost importance and significance. The unprejudiced observer is often forced to wonder why some exponents of palaeontological research are content to draw far-reaching phylogenetic conclusions from the remnants of the incomplete locomotory apparatus at their disposal, without utilizing the results of modern comparative anatomical and embryological investigation in determining at least the mutual relations of the extant forms, massed by an ironclad taxonomy into more or less questionable groups, whose ancestry and derivation form one of the primary problems of the palaeontologist. The case of *Tragul* just alluded to, the parotid complex and alimentary canal of *Hyrax*, the amniote homologies of the derivatives of the Sulcus buccalis determined by Schulte, the sharp line of lymphatic demarcation recently shown by Silvester to structurally separate absolutely the platyrrhine and catarrhine divisions of the lower primates, these and other facts are only instances in which the inadequacy of a superficial convergence of dental and skeletal characters, for the purpose of establishing valid phylogenetic relations, is revealed by cardinal divergence in the far more stable and important organization of vascular and visceral structure.

The prevalent lack of coördinate deduction between vertebrate morphology and palaeontology is accentuated by contrast with such publications as Weber's "Säugethiere" and, more recently, W. K. Gregory's "The Orders of Mammals", based largely on the author's joint work with Osborn, and on the latter's previous classical researches, and published by the American Museum of Natural History (Bulletin, vol. 27, February, 1910).

Workers in the general field of vertebrate structure appreciate fully the immense practical value in their own special investigations of books of this type, in which, to quote Gregory's words, "the data of systematic mammology, of comparative anatomy and embryology shall ultimately be integrated with the data of palaeontology, to the great advantage of these now more or less independent lines of study."

In embryo 258 (fig. 21) the space ventral to the cardinal collateral veins and the ascending lumbar lymphatic trunks, is occupied by a plexus of mesenteric lymphatics (51) draining into the latter. On each side are seen sections of the ureter (58), and further laterad of the iliac vessels (61). Ventral of the intestine (62) are the Wolffian ducts (64) and the cloaca (63), with the hypogastric arteries (66) laterally.

Fig. 21 shows the important central vascular region of the same section in a magnification of 150 diameters. The relation of the cardinal collateral trunks (74) to the ascending lumbar lymphatics (75), and of the latter to the postcardinal veins (67, 68) can be more clearly seen. The lumen of the mesenteric lymphatics (51) still contains in places remnants of the decadent venous plexus around and upon which they developed as replacing extraintimal spaces.

The three succeeding sections, tracing the structures caudocephalad, are shown in figs. 22, 23 and 24, all in a magnification of 150 diameters. The connections of the lymphatic channels developing along the iliac vessels with the ascending lumbar trunks are especially well seen on the left side of the three figures, also the anastomoses between the two cardinal collateral veins in figs. 23 and 24.

Figs. 25 and 26 show transverse sections of the hinder end of the body in a 20 mm. embryo (series 241).

Fig. 25 (series 241, slide xxx, section 4) gives, in a magnification of 75 diameters, a topographical view of the entire field. This stage, compared with the preceding 17 mm. embryo, is marked by the full development of the supracardinal venous line, responsible for the production of the greater portion of the typical adult placental postcava below the renal level, and by the correlated development of the supra- or retro-aortic lymphatic sinuses associated with the same.

The periaortic area in fig. 25 gives a clear view of the vascular relations and of the postcardinal and supracardinal axial venous trunks.

The former (67, 68,) are seen on each side, between aorta (7) and metanephros (65), receiving the veins from the mesonephroi in whose dorso-medial border they are lodged.

The latter (59, 60) lie dorsal to the aorta (7) between this vessel and the sympathetic strands (1).

The right supracardinal (60) has already gained the ascendancy and is in process of establishing the channel of a normal right retro-aortic postcava, which is the typical vein for the cat. The correspondingly reduced left supracardinal (59) occupies the same situation on the left side. Associated with the supracardinal venous channels are the supracardinal lymphatic trunks (76), which form the anlagen of the main adult retro-aortic lymphatic plexus. These develop as extraintimal spaces replacing portions of the earlier supracardinal venous reticulum. In accordance with the normal type of development observed in this individual embryo, the large permanent supracardinal (postcaval) vein of the right side is accompanied by a relatively small lymphatic channel (76 right), while on the left side the much reduced left supracardinal (59) is already nearly replaced by the corresponding lymphatic vessel (76 left). In course of further normal development this replacement will become complete and then the area formerly occupied by the left supracardinal vein will be entirely filled by the substituted large left retro-aortic lymphatic. The permanent functional venous channel of the right side (60) on the other hand, developing into the typical placental postcava, will be accompanied by a relatively small right lymphatic

trunk following its dorso-lateral aspect. As will be shown later (Part V.), departures from the normal type of venous development in this region, and the substitution of other embryonic pathways for the right supracardinal in building up this section of the adult postcava, produce corresponding and correlated changes in the arrangement of the main retro-aortic lymphatic channels.

Fig. 26 shows the periaortic region of the same embryo, further caudad, in a magnification of 150 diameters (series 241, slide xxx, section 14.) The section is taken at the level of a pair of dorsal intersegmental arteries which pierce the supracardinal venous (59, 60) and lymphatic (76) complex, and divide the vein of the right side into two components (60, 60). Further ventrad the two postcardinal veins (67, 68) are seen, already considerably reduced, ventrolaterad to the ureters (58) and the accompanying ascending lumbar lymphatic trunks (75). The connection of the latter with the supracardinal lymphatic channel is especially clear on the right side of the embryo.

Taken together, the 17 mm. and 20 mm. embryos just figured and described afford a very clear and comprehensive picture of venous and lymphatic development in their mutual relationship in this region.

The schematic text figures A, B and C may help to explain this relationship.

Fig. A is based on the joint studies which McClure and I made on the development of the postcava in embryos of the domestic cat. The figure was demonstrated to the 21st Session of the Association of American Anatomists in 1906 at the time of presentation of the communications, although not reproduced in the brief abstracts of the papers subsequently published.^{23, 25}

The figure represents a composite schema of the main periaortic venous axial pathways of the abdominal region. These pathways developing along definite and constant axial hydrostatic lines out of the periaortic venous reticulum, have all been determined by us in embryos of the cat. They do not, of course, all coexist at the same time in any embryonic stage, but normally succeed each other in definite sequence. The entire range of

extensive variations in the domain of the adult postcava of the cat can be clearly interpreted genetically²⁵ on the basis of this common groundplan, through abnormal persistence of one or more of the embryonal pathways usually destined for complete obliteration, thus producing far-reaching modifications in the structure and relations of the resulting atypical postrenal segment of the adult postcava.

This periaortic axial venous lattice with connecting transverse branches (Fig. A) contains four components on each side, which develop in the following order:

1. The postcardinal veins (1).
2. The subcardinal veins (2).
3. As secondary derivatives of these two veins, the preaortic cardinal collateral channels (3).
4. As secondary dorsal derivatives of the postcardinal trunks, the supracardinal veins (4).

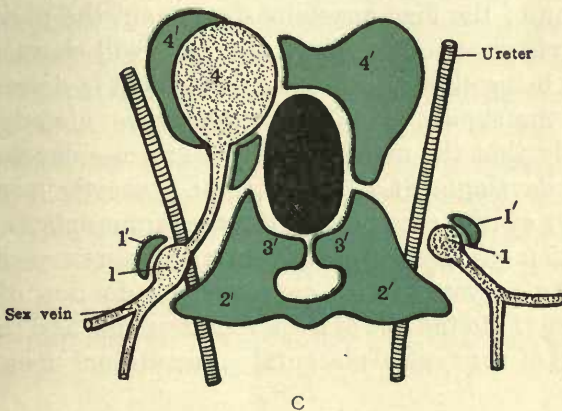
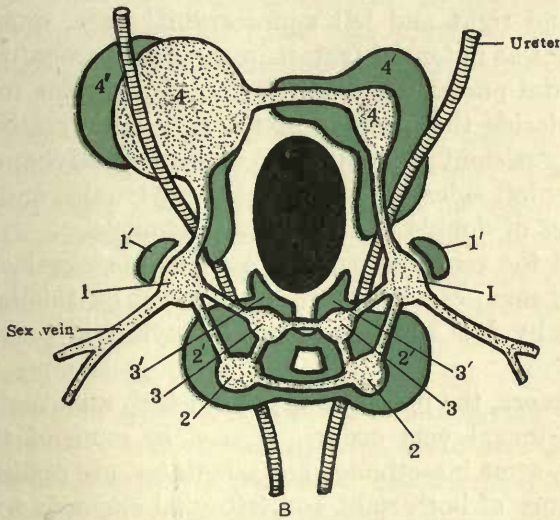
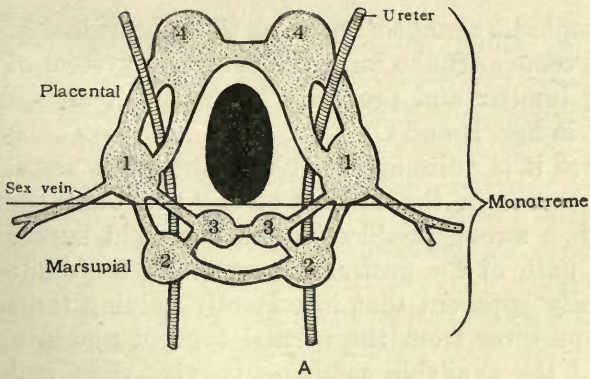
In the course of normal venous development along the line typical for the great majority of placental mammals the right supracardinal vein (4) obtains the preponderance and furnishes the postrenal segment of the adult postcava, thus freeing the ureter from its primitive retro-venous position.

A part of the early capillary periaortic reticulum, out of which this vessel develops, is secondarily replaced by extraintimal lymphatic spaces, which through their confluence form the relatively small retro-aortic lymph channel (4'), following in the adult the dorso-lateral circumference of the postcava (4). (Figs. B and C).

The right and left postcardinal veins (1) are in part retained as the terminals of the sex veins, in part replaced by the accompanying lymphatic trunks (1'). (Figs. B and C).

The left supracardinal vein (4), and both subcardinal veins (2), below the cross-anastomosis, as well as both cardinal collateral veins (3), retrograde and are entirely replaced secondarily by lymphatic channels.

The lymphatic replacing the left supracardinal vein (4) forms normally in the adult the main retro-aortic lymphatic sinus. (4', left, in figs. B and C).



The lymphatic channels replacing the subcardinal and cardinal collateral venous trunks form the extensive system of the adult ascending lumbar and preaortic lymphatic vessels and nodes (2' and 3' in figs. B and C).

Of course it is quite apparent that the adult placental differentiation occurs in the district of the post- and supracardinal lines, with a strong predilection for the right supracardinal as the main path of the postrenal segment of the adult postcava. It is equally apparent that in correctly valuing the significance of the departures from the normal type of placental postcava all four of the available components, viz., right and left postcardinal and right and left supracardinal lines, must be taken into account as potential factors in the development of the atypical placental postcava. The relation of the veins to the ureter will then decide the question of the genetic derivation, as being either the persistent postcardinal or supracardinal channel of either the right or left sides, in the case of single trunks, or of both sides in instances of double bilateral adult channels.

Thus all the recorded cases of variant postcaval veins of the cat, and of man, can be clearly interpreted on this basis, as has been done by McClure, Darrach and myself in previous publications.^{23, 24, 25}

Furthermore, the placental types in which a normally so-called double postcaval vein occurs, as, *e.g.* in some of the aquatic carnivores, some insectivores and edentates, are readily led back to persistence of both right and left axial channels with absence or reduction of the iliac anastomosis. Again the position of the ureter in reference to the bilateral trunks will characterize each of them as being either post- or supracardinal in derivation.

In the marsupials McClure's researches already quoted,³¹ show clearly that the members of this subclass depend upon the continued development of the ventral preaortic venous pathways (2, 3) of the common vertebrate groundplan (fig. A) for the evolution of their typical ventral preaortic postrenal segment of the postcava, with consequent reduction of the postcardinal line (1) to the rôle of a sex vein terminal, and the complete suppression of the typical placental supracardinal lines (4) in most

forms, while rudiments of the same are found, as shown by Schulte's and Tilney's observations, in connection with the venous return along the caudal vein only in the Macropodidae.²⁹

Schulte's work on the venous organization of the Monotremes³² proves, I think, conclusively the phylogenetic value of the periaortic venous reticulum with axial pathways of hydrostatic selection which the detailed study of placental embryos establish. His dissections of both *Platypus* and *Echidna* revealed for the first time the persistence in the Monotreme of both dorsal supra-cardinal channels, and of ventral preaortic vessels of subcardinal and cardinal collateral derivation, while, as appears uniformly throughout the mammalian class, the primitive postcardinals retain normally solely the function of venous drainage for the gonad.

The facts just stated have been in a large part already published in outline by McClure, Schulte, Tilney, Darrach and myself. I hope it will be possible to collect the numerous observations, with adequate illustrations, in a publication to be issued in the near future. I have recorded some of the results obtained through these joint investigations in this paper in order to use them for the purpose of clearly outlining on a broad basis the genetic possibilities in the development of the venous system, and the correlated interdependence of the systemic lymphatic vessels. The latter will, in the mammal, take over and further develop territory formerly occupied by transient embryonic venous channels, which they secondarily replace through extra-intimal development. Hence the resulting mirror picture which the lymphatic system of the adult mammal presents in reference to the axial venous trunks, whatever type of central venous organization may obtain in any individual instance.

The examples just given could, of course, be indefinitely multiplied. They all show absolutely congruent, uniform and constant pictures in all parts of the body of the developing lymphatic channels in close association with the adjacent veins, but not connected

³² H. v. W. Schulte: "The Range of Variations in Monotremes and Australian Marsupials." *Anat. Rec.*, no. 3, April 1, 1907. *Am. Jour. Anat.*, vol. vi, no. 3, 1907.

with the same. Nowhere is there any suggestion of a bud or an outgrowth from the vein as forming the origin of these lymphatic spaces. It now remains to clearly prove the genesis of these spaces, and to trace their growth from their inception up to the stages just pictured in which fully organized lymphatic and venous channels lie side by side in the mutual relation above figured and described. The proof of their origin is furnished by the series of microphotographs of successive sections of the earlier stages given in Part II of this communication, in connection with the individual series described and figured in tracing the development of the preazygos and azygos portions of the thoracic ducts. The microphotographs, and especially the reduced reproductions figured, are not so clear as the actual preparations, because focal adjustment is required to follow the endothelial lining of the spaces in their entire circumference, and because they lack the differential stain of the sections. Still they are sufficiently distinct to establish definite conclusions. Merely referring, therefore, at this time to the following detailed illustrations, the general topic of extraintimal replacement of embryonic veins by lymphatic spaces and the character of the latter deserve some further consideration.

The lymphatic anlagen, as above stated, if studied under sufficiently high power and with some care, are seen to begin as *intercellular clefts* in the periaortic mesoderm, adjacent to the postcardinal venous plexus, and chiefly on its ental aspect, between it and the aorta.

The individual lymphatic spaces, at first small and separated from each other, enlarge, elongate and become confluent, to form larger continuous channel segments, while innumerable newly formed spaces of the same character appear in the surrounding tissue, join with each other, and with the earlier preformed lymphatic channels, in exactly the same manner, and with the same appearance of lymph endothelial "budding" or "sprouting" as is observed in haemal vascularization of new areas by the junction of the earlier blood capillary anlagen with secondary haemal plexuses. In these later stages the veins are surrounded by a close lymphatic plexus, which, however, does not as yet form a con-

nected channel system, but is composed of longer and shorter segments still independent of each other.

These finally become confluent, to form the main systemic lymphatic collecting trunks, and then only do these establish their final junction with the jugular lymph sacs, through whose interposition, as above stated, they gain in the typical mammal their permanent entry into the venous system.

In this ontogenesis of the systemic lymphatic vessels certain relations between them and the venous system deserve further notice.

In the early stages the lymphatic mesenchymal spaces form a wide meshed network (cf. series 111, figs. 1 to 7, series 120, figs. 8 and 9). There is thus a marked similarity in the earliest stages of both the haemal and the lymphatic vessels, for the peripheral venous embryonic pathways are in their corresponding stages likewise still largely in the condition of a capillary reticulum. As the main lines of venous drainage crystallize out of the antecedent plexiform arrangement, the adjacent enlarging lymphatic channels crowd in on the condensing venous line and continue the close relationship which the earliest lymphatic anlagen maintain to the adjacent veins. Thus the main embryonic venous channels develop along certain definite hydrostatic lines by enlargement and confluence of the individual plexiform elements of the indefinite antecedent network occupying these lines. The capillaries outside of these lines retrograde, so that the area of crosssection of the defined venous channel is less than the cross-cut area of the plexiform network which it replaces.²⁹

The distinct impression is given that the space thus vacated by the condensation of the plexiform venous network of the earlier stages affords to the replacing lymphatic plexus the opportunity for greater growth and expansion, and that subsequently, in repetition of the process previously active in the venous reticulum, the lymphatic network condenses in a similar manner into more defined channels along similar hydrostatic drainage lines, so that the newly established main lymphatic vessel now closely follows the main venous channel. It is to be noted, however, that this organization of main vascular channels is usually less

complete in case of the lymphatic vessels, as compared with the corresponding vein. The lymphatic system retains, much more perfectly than the venous, in many situations the original embryonic plexiform type.

At first the cells limiting the earliest lymphatic spaces are of the usual irregular cuboidal form. As the spaces enlarge, open out and thus become better defined, the limiting mesodermal cells become flattened, and finally assume a typical endothelial character and form. Thus, for example, the endothelial lining of the primitive mesodermal lymphatic spaces (77) is more clearly developed in the 10 mm. embryo, series 120, shown in figs. 8 and 9, than in the corresponding sections of embryo 111, of the same crown-rump measure (figs. 1 to 7). The former embryo is slightly in advance of the latter as regards the development of the parietal endothelial lining of the primitive mesodermal intercellular lymphatic spaces. In some instances a few modified mesodermal cells intervene between the cells limiting the lymphatic spaces and the endothelium of the adjacent venous radicle. In others no such intervening cell-layer exists, and the lymphatic space is separated from the venous lumen only by the latter's endothelial wall. In other words, in the extent of the lymphatic anlage, a single-celled membrane furnishes a part of the venous intima and at the same time contributes to the endothelial definition of the lymphatic space. This relation of vein and lymphatic anlage is shown very clearly in fig. 17. The lymphatic space (53), which is closely applied to the medial wall of the left precardinal vein, is only separated from the lumen of the latter by the endothelial membrane which serves to line both spaces for the area of their mutual contact in this stage. Subsequently, with the regression of the left precardinal vein, this lymphatic anlage will correspondingly enlarge to form an extensive lymphatic plexus, which will eventually topographically replace the vein along which it arose. In order to briefly characterize this relation between vein and lymphatic, McClure and I defined in an earlier publication²¹ these spaces as the "Extra-intimal" anlages of the systemic lymphatic vessels, with due regard to the relation existing between them and the intimal endothelial lining of the embryonic veins. The mechan-

ical concept involved in this term seems, to judge from a recent publication,³³ to have been difficult to acquire. I am glad to be able to make myself clear by reference to fig. 17, where the mutual relation of the two vascular lumina is evident without further description, and to the numerous detailed illustrations on a larger scale of magnification which accompany the account of the development of the thoracic ducts in Part II of this communication.

By far the larger number of the early lymphatic channels are the product of fusion of these "extra-intimal" spaces, and hence closely follow the veins of their respective regions. Subsequently, with the development of a venous adventitia, this relationship is somewhat altered in case of those veins which are included in the permanent venous organization. The close relation existing, however, throughout life between these veins and the accompanying lymphatics is based on this intimate primitive association of their respective anlagen.

On the other hand, the extra-intimal position of the earliest lymphatic spaces furnishes the explanation of another relation manifested between the developing systemic lymphatic channels and those embryonic veins which in course of normal venous development are destined to undergo reduction and finally complete suppression, when the primitive bilateral and symmetrical venous system of the earlier embryonic stages shifts to the dextral asymmetrical type of the main adult axial channels. In these circumstances the systemic lymphatic vessel associated with the temporary embryonic vein experiences, apparently through the shrinkage of the latter, an impetus to its own more extensive development, so that it comes to occupy in general topographically the space filled by the vein in the earlier stages.

Thus the embryonic period which marks the normal ontogenetic swing of the main venous line to the right through the secondary sinistro-dextral iliac, hemiazygos and brachiocephalic cross anastomoses, sees the simultaneous increase in the corresponding lymphatic channels of the left side, which topographically replace the abandoned left embryonic venous pathways of the earlier and sym-

³³ Sabin: *Anat. Rec.*, vol. ii, 1908, p. 50.

metrical stage. This occurrence leads to the well-known relative location of the main axial veins and lymphatics in the normal adult, in which the lymphatic vessels are chiefly situated on the left side and form, so to speak, a mirror-picture of the right sided axial venous channels.

Fig. 27 shows the reconstruction of the anterior venous and lymphatic complex in a cat embryo of 18 mm. (series 88) in the ventral view, and fig. 28 of the same preparation in the lateral aspect from the left side. The brachiocephalic cross anastomosis is already well under way, resulting in a marked diminution of the left anterior caval vessel and a corresponding increase in the permanent right anterior cava or right duct of Cuvier. Conversely, the lymphatic vessel accompanying the diminishing left precaval vein is of large size, while that applied to the massive right precaval is comparatively small.

This principle of lymphatico-venous replacement, indicated clearly in the later embryonic stages, is strikingly illustrated in the adult. Thus, for example, the adult cat presents normally the arrangement of the great veins of the head and neck which is so frequently encountered in mammals below Primates, in which the large embryonic internal jugular vein is much reduced or even entirely obliterated, while secondarily the external jugular vein has assumed the function of the main vessel. Under these normal circumstances the lymphatic trunk accompanying the minute internal jugular vein or, in case of its entire default, occupying its position, is well developed and the largest element of the entire cervical lymphatic complex, while the external jugular vein is, on the other hand, accompanied usually by two very slender lymphatic vessels.

In instances, however, in which the embryonic proportion between the two jugular veins is retained in the adult, so that the internal jugular appears as a large and functionally important vessel, while the external is correspondingly diminished, the internal jugular lymphatic trunk is reduced, while the double lymphatic vessel along the external jugular is enlarged, and evidently acts in compensation in the cervical lymphatic return.

Again, in the same way, in adult animals with normally placed right postcava, the main supracardinal lymphatic trunk, draining the abdomen and the posterior extremities, follows the left side of the large artery.

In the not infrequent instances, however, of left sided postcava or postcardinal vein in the adult the reverse obtains, and the peri-aortic lymphatic channels predominate on the right side and occupy the place usually filled by the large vein in normal venous development.

I have encountered in the adult series so far examined no instance of persistent left precava replacing functionally the normal right superior cava, but have no doubt that this venous variation would involve a transposition of the proximal end of the thoracic duct to the right side, or at least a marked increase in the size and functional importance of the usually insignificant preazygos segment of the adult right lymphatic duct.

The developmental outline just given describes the mutual ontogenetic relations of the venous and lymphatic systems throughout the greater part of the body.

Systemic lymphatic development in these regions is, however, by no means *confined* to the immediate environment of degenerating embryonic veins. The same field, which shows the above described histogenetic processes in the development of extraintimal lymphatic spaces surrounding and replacing a decadent venule, will at the same time contain *numerous equivalent lymphatic mesenchymal clefts and spaces* which continue to develop independently of any association with retrograding veins. Naturally, these independently developed early lymphatic anlagen are less striking than those above described as developing in association with a receding vein. They are smaller, because they lack the bulk of the contained venous core, and they are more difficult to clearly differentiate against the surrounding mesenchyme. They are, however, always present and their eventual connection with the larger perivenous lymphatic spaces can be ascertained definitely by following their development through the proper stages.

In addition, in certain areas, a small group of the earliest lymphatic anlagen appear to develop in the mesenchyme along definite lines, and in distinct patterns, but without any preceding venous reticulum. They impress me, for example, in the area surrounding the omphalomesenteric artery, as systemic lymphatic channels developing in the placental embryo in regions which are no longer ontogenetically the seat of venous development, although occupied by veins in other mammalian types. Thus the cardinal collateral line of the marsupials³¹ and the correlated venous area of the monotremes³² no longer develops as a permanent venous plexus in placentalia³⁴ but only partially appears in certain forms as a temporary and evanescent component of the abdominal venous complex, as described above for certain stages in the development of the cat (pp. 29 to 33 and figs. 20 to 24). Its place, however, is partially occupied by an early lymphatic plexus developed in the preaortic mesoderm from the omphalomesenteric anlagen caudad. Here we are apparently dealing with an instance in which general phylogenetic venous lines have been almost or entirely abandoned in favor of other pathways. Such lines appear, however, to be retained under these conditions in the lymphatic organization. Thus, the spaces just referred to, as will be shown subsequently, form the first inception of the extensive network of lymphatic vessels which in the adult cat surrounds the aorta and the origin of the superior mesenteric artery, closely interwoven with the semilunar sympathetic and the adrenal plexus, and connecting on the one hand with the portal and intestinal lymphatics, and on the other with the beginning of the thoracic duct. This adult mammalian lymphatic plexus forms a perfect lymphatic shadow-picture of the lacertilian ontogenetic peri-omphalomesenteric venous ring.

In conclusion, I wish to give briefly a summary of my reasons for regarding the structures described in this communication as the anlagen of the systemic lymphatic vessels.

³⁴Except, as recently determined, in *Tragulid*, in which Ungulate the adult postcaecal system is of the marsupial type, and in certain embryonic stages of the Cat (15.5-17 mm.) in which the channels appear as evanescent preaortic vessels, subsequently entirely replaced by lymphatics. (Cf. series 258; figs. 20 to 24.)

These early lymphatic anlagen, whether formed independently in mesoderm, or on the site of phylogenetically abandoned venous lines, or, as is generally the case throughout the body, in close correlation to the embryonic venous pathways, always appear in the same situations and, in the average embryo, at the same developmental period. Their constant character, and regular occurrence and relations, repeated within very narrow limits of individual variation in every embryo of the proper stage, imparts to them a definite morphological character. In every series of the proper age in my collection I find the same spaces in the same place and in identical relationship to the adjacent veins. In some individuals, as above stated, they develop earlier than usual, in others their appearance is retarded, but this applies only to the achievement of the full development typical for the *average* embryo of a given stage. In the retarded individuals the same structures are always present, only they are less strikingly developed and less numerous when compared with the average normal type characteristic of the period under consideration. With sufficient magnification it is not difficult to distinguish sharply between the perihæmal lymphatic spaces and the blood-vascular channels proper.

With sufficient material every stage of their development can be followed up to the confluence of the entire system and its final entrance into the jugular lymph sacs.

These spaces are neither artefacts due to embryonic shrinkage, nor are they the unfilled portions of the blood-vascular capillary network. They are, on the other hand, the well-defined earliest anlagen of the systemic lymphatic vessels. The more perfect, as a matter of fact, the embryonic fixation is, the more clearly can these structures be indentified under the microscope. Their history, as will be shown presently, can be traced with the utmost accuracy, and they can be followed step by step in their development up to their inclusion in the completed and connected lymphatic channel system.

But even in their earliest stages they possess an unmistakable and definite morphological character, quite as distinct as that of the adjacent blood channels. They can be followed closely in

good serial sections of the proper thickness and fixation, and can be reconstructed in the same manner and with the same accuracy and certainty as the blood channels with which they are for the most part so closely associated, although their lumen connects at no point with that of the vascular channels.

These statements are based, not on isolated observations, but on the close and repeated examination of a very large number of embryos of the same form. It seems curious to me that the presence of the first lymphatic anlagen, as above described, should be denied, or, as has been recently done, that the isolated appearance of these spaces should be ascribed to the "sudden collapsing" of a lymph vessel. At the time at which they make their first appearance there are no "lymph vessels" to "collapse," no more than there are in the homologous haemal ontogenetic stages blood-vessels in the sense of continuous channels. On the contrary, when they reach their period of most striking development (cat, 13-14 mm.) these perivenous lymphatic spaces are, if anything, distended, not only by their fluid contents, but by the remnant of the embryonic atrophying vein which they are in the process of replacing. The only structure showing any sign of "collapse" is the empty endothelial bag of the decadent venule. The spaces become relatively reduced in size in the later stages, after the multiple separate early anlagen have fused into a more continuous lymphatic channel system.

These spaces are always present in embryos of the proper stages in the typical position and in constant relation to the venous channels. By following carefully and with sufficient material their further growth and development in succeeding stages, a clear and consecutive picture of systemic lymphatic genesis is given.

It is noteworthy, in view of the incorrect statements published to the contrary, that these primary anlagen of the systemic lymphatic system develop constantly in embryos of the cat before the definite organization of the jugular lymph sacs. These latter structures, in the 10 mm. cat embryo, are still largely in the condition of a perivenous capillary plexus, at a time when the first lymphatic anlagen can be distinctly recognized in the axial mesoderm.

In view of the fact that these first anlagen can be traced step by step as developing into the systemic lymphatic channels of the adult, it becomes apparent that their origin cannot be ascribed to "outgrowths" from the jugular sacs, as yet not formed. A similar lack of correct reasoning appears in portions of the recent anatomical literature in reference to the injection of lymphatics in the early stages. It is manifestly impossible to inject something which does not as yet exist in the form of a continuous and injectable system of communicating channels. The spaces which I am describing and which I regard as the first anlagen of the systemic lymphatics cannot be injected at the time of their first appearance because they are intercellular spaces, extremely numerous, but as yet isolated from each other, and not in communication with veins or with anything else that could be injected, in the sense of filling a lumen artificially with a colored fluid, or air, or any other foreign substance. They multiply rapidly, become confluent to form larger spaces, and these finally unite into continuous channels. But the genetic determination of the origin of the lymphatic system must be based on the close study of embryonic stages long prior to the formation of continuous channels capable of injection. Where lymphatic vessels can once be demonstrated by this method they have passed the formative stage. It then becomes merely a question of topographical extension and readjustment, such as is encountered in all vascular structures alike in the later embryonic periods.

The real problem of the genesis of the lymphatics can only be solved by the recognition of the earliest formative stages, beginning with the first appearance of the mesodermal spaces above described.

Finally I can sum up my observations, and the views thereon based, as follows:

- 1 The *systemic* lymphatic vessels of the entire body arise, in the mammalian embryo, by confluence of mesodermal spaces, developed on the same lines as those governing the formation of the earliest haemal vascular channels, but independent of the same.

2 The lymphatic endothelium is an independent modification of the mesodermal cells lining the first anlagen of the lymphatic spaces, and is not derived from the haemal vascular endothelium.

3 I am obliged to deny the assumption that the mammalian systemic lymphatic vessels arise by the confluence of numerous elements detached in course of development from the embryonic veins.

4 I am obliged to put myself emphatically on record against the assumption that the mammalian systemic lymphatic vessels arise by a progressive sprouting from center to periphery from the endothelium of veins, or from that lining the jugular lymph sacs, or equivalent structures in other regions of the body. The mammalian embryo offers no evidence of such occurrences.

PART I, PLATES

FIGURES 1 TO 28

The series here figured and described are in the embryological collection of Columbia University, with the exception of series 34, which belongs to the embryological collection of Princeton University. I am greatly indebted to Prof. C. F. W. McClure for the opportunity of studying this series and publishing the eight sections shown in figs. 245 to 251.

FIGURE 1

1 Transverse section of 10 mm. cat embryo (series 111, slide VIII, section 4),
× 175—Topographical picture of site of earliest lymphatic space development.

- 1 Sympathetic nerve.
- 8 Oesophagus.
- 68 Left postcardinal vein.
- 69 Lungs.
- 72 Right dorsal aorta.
- 73 Left dorsal aorta.
- 77 Mesenchymal intercellular lymphatic anlagen.
- 78 Coelom.

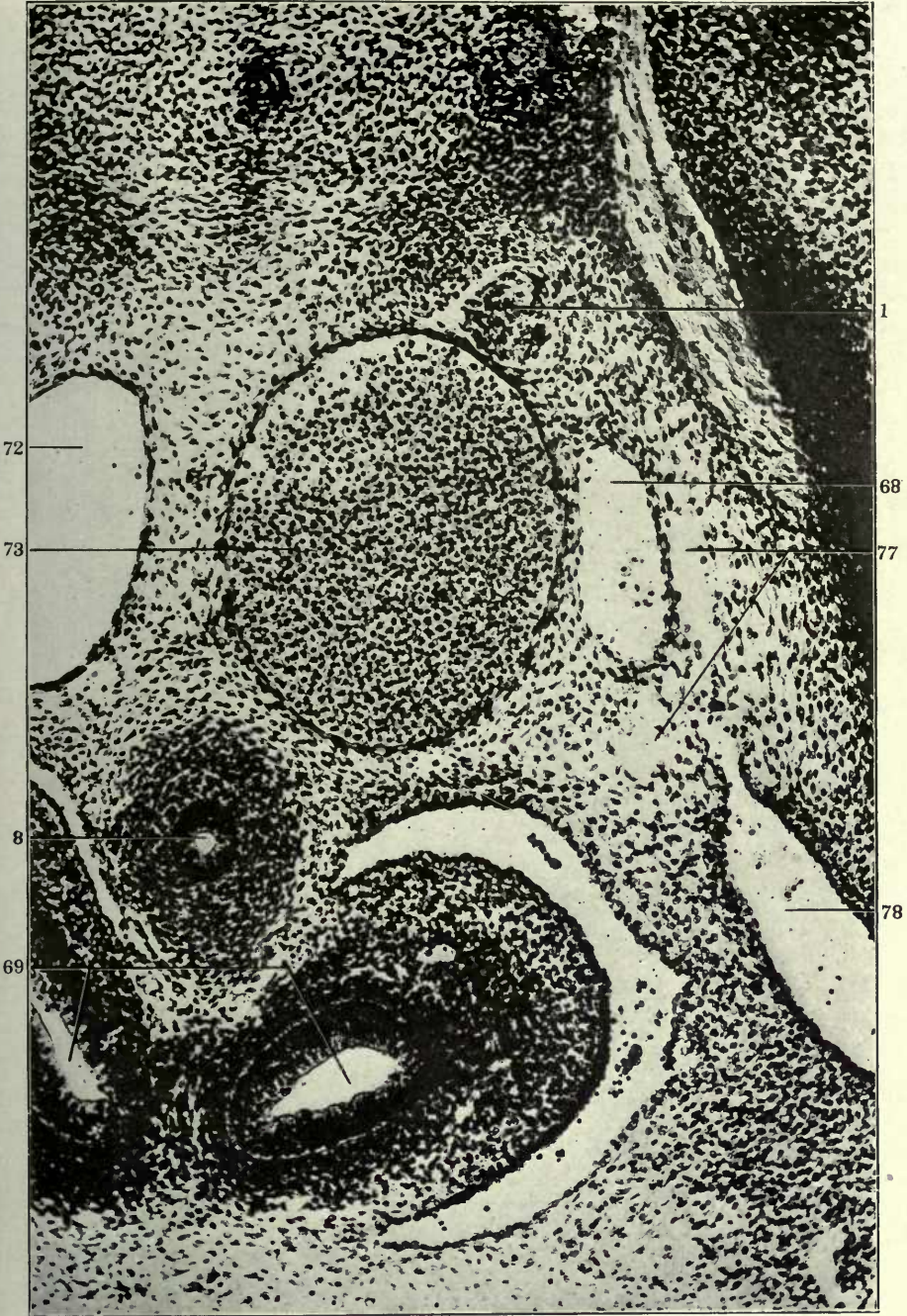

FIGURE 2

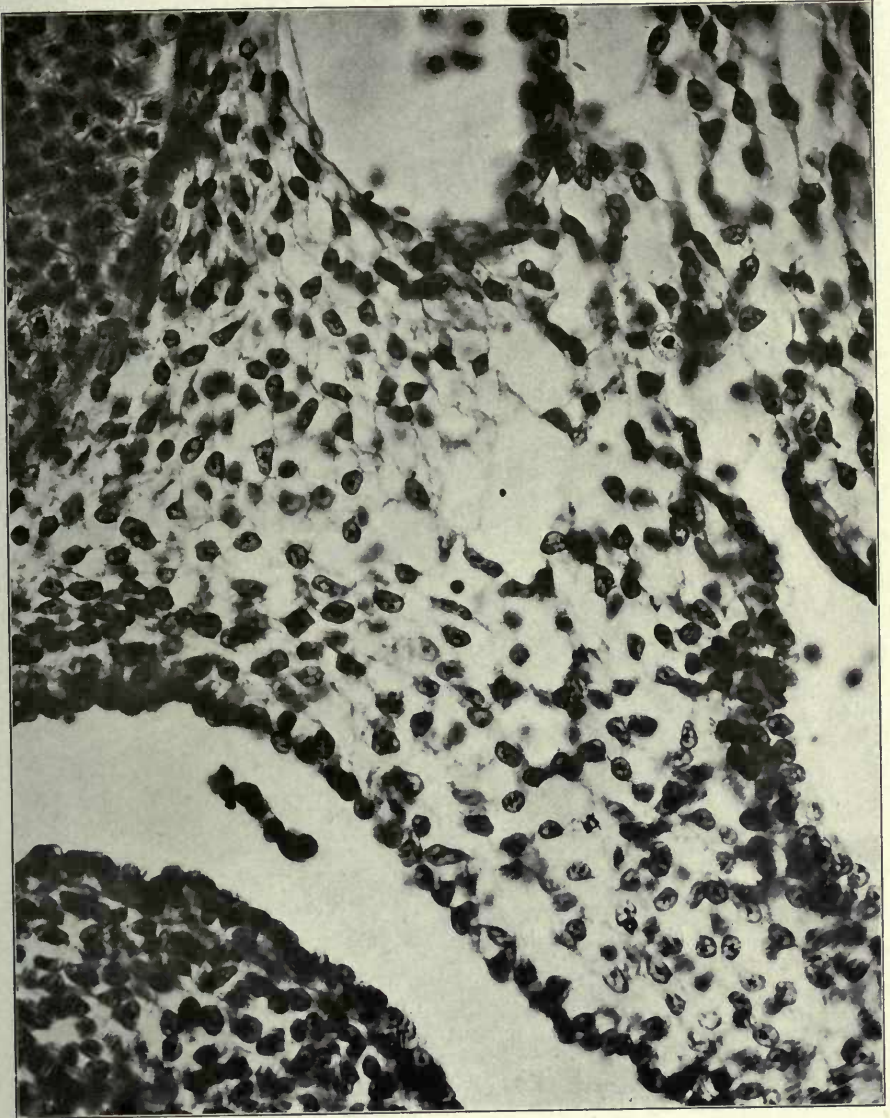
2 Transverse section of 10 mm. cat embryo (series 111, slide VIII, section 4)
× 300—left side of embryo.

- 68 Left postcardinal vein.
- 73 Left dorsal aorta.
- 77 Mesenchymal intercellular lymphatic anlagen.
- 78 Coelom.
- 79 Coelomic stoma.

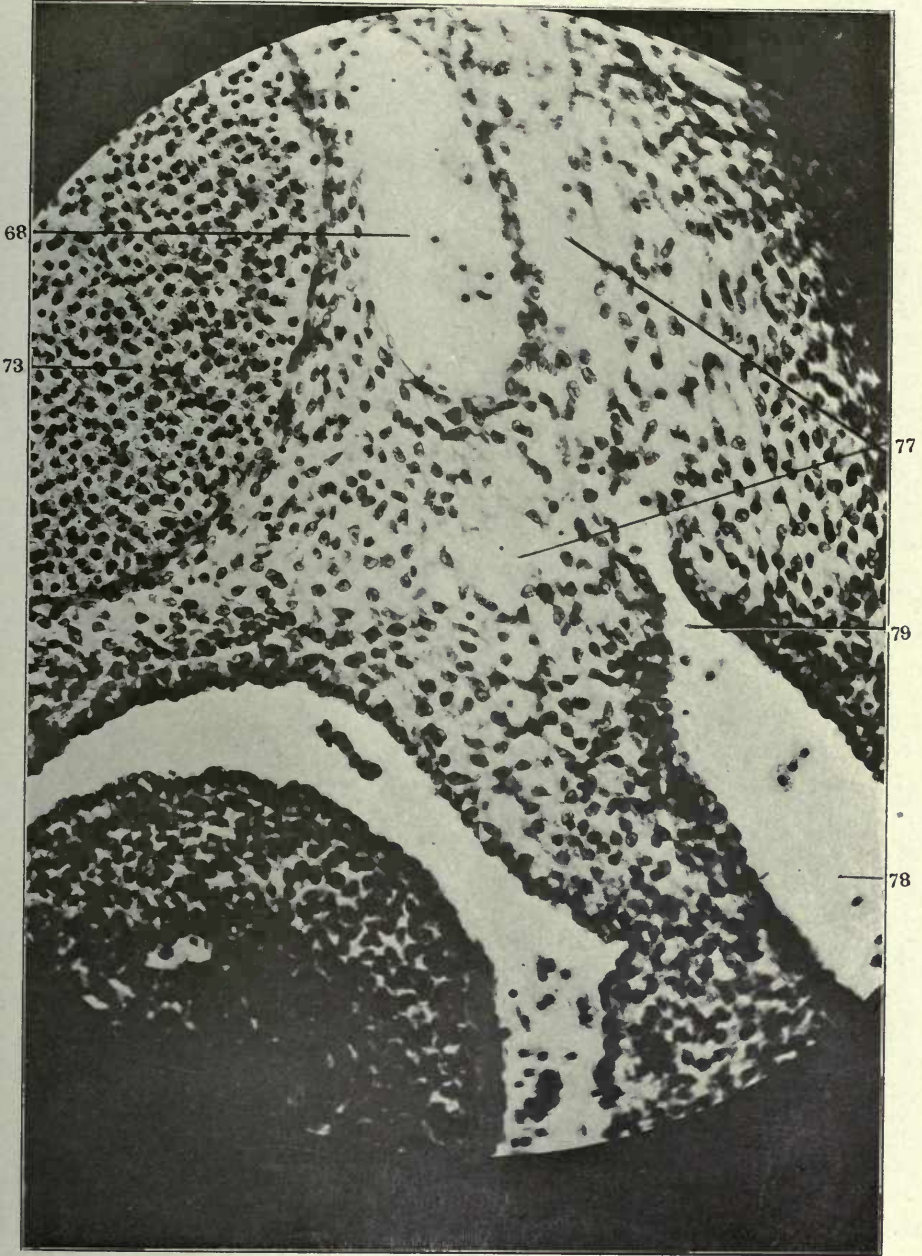

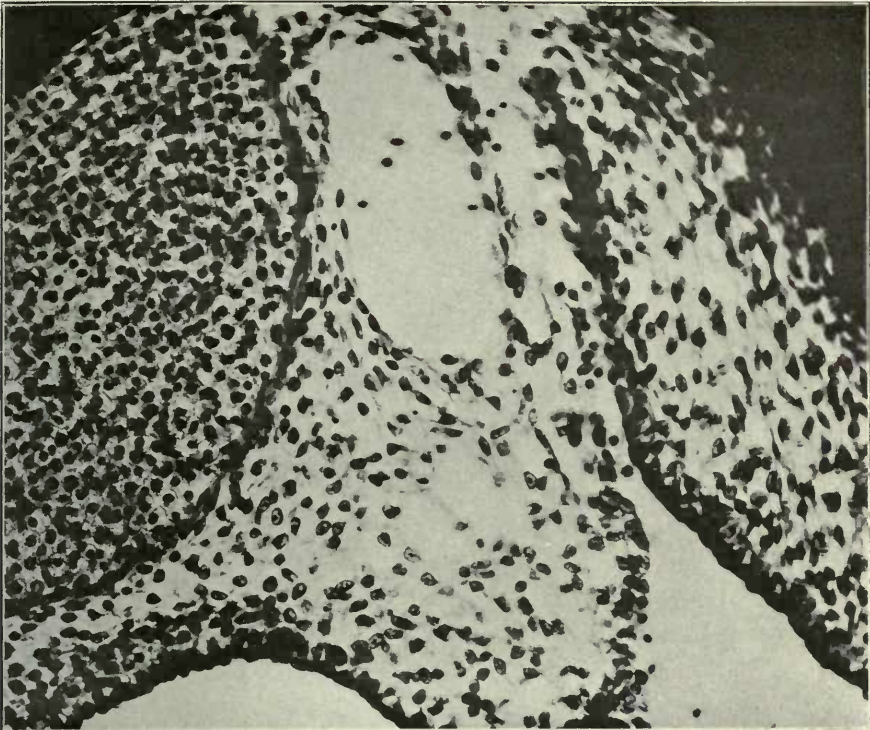
FIGURE 3

3 Same, $\times 600$.

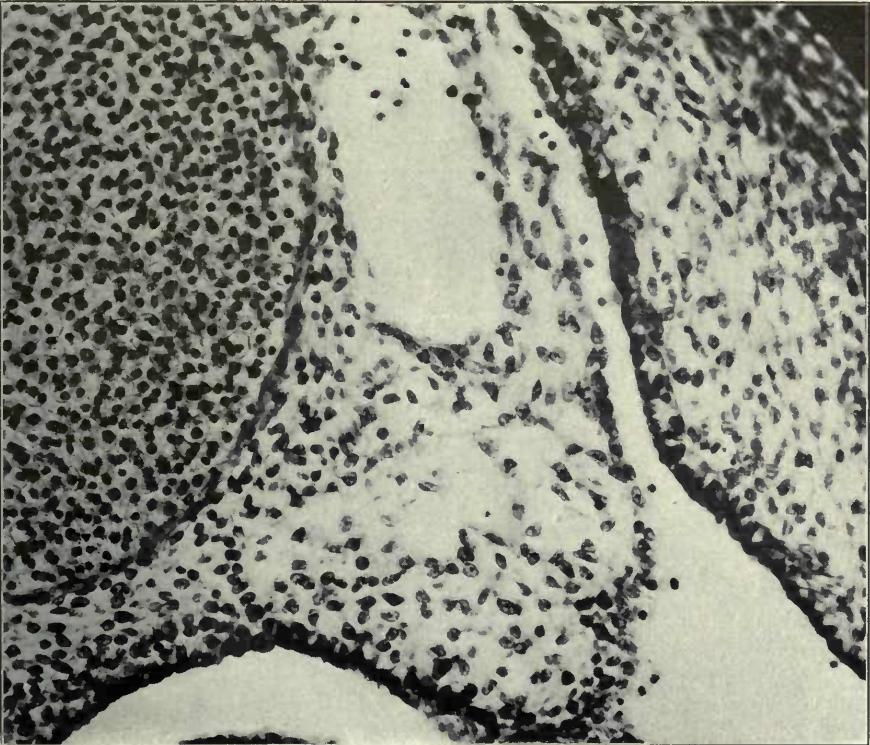


FIGURES 4 AND 5

- 4 Transverse section of 10 mm. cat embryo (series 111, slide VIII, section 6),
× 300.
- 5 Same, section 7.



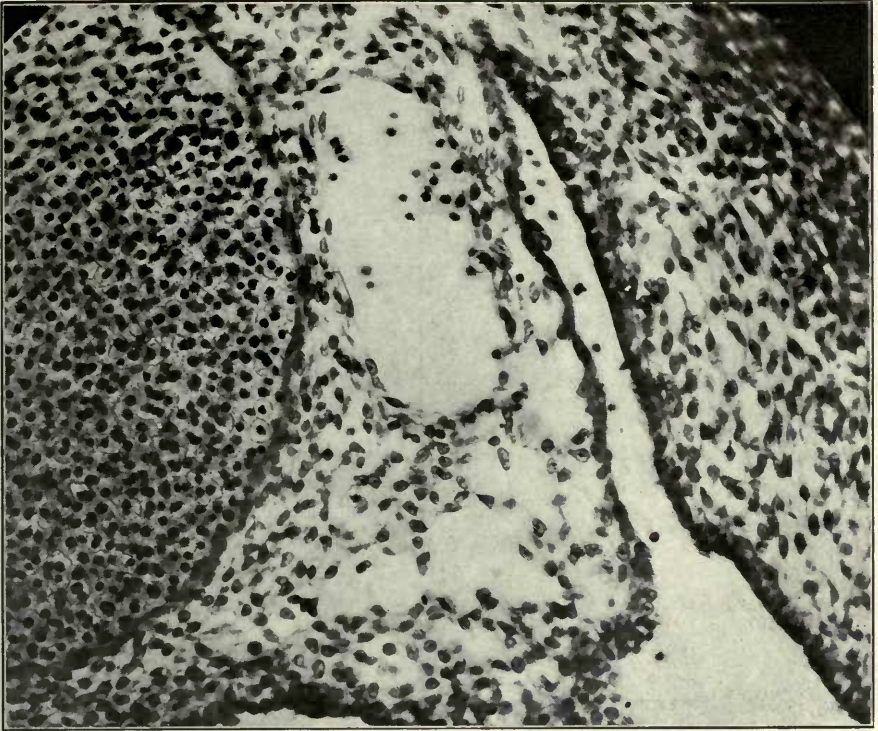
4



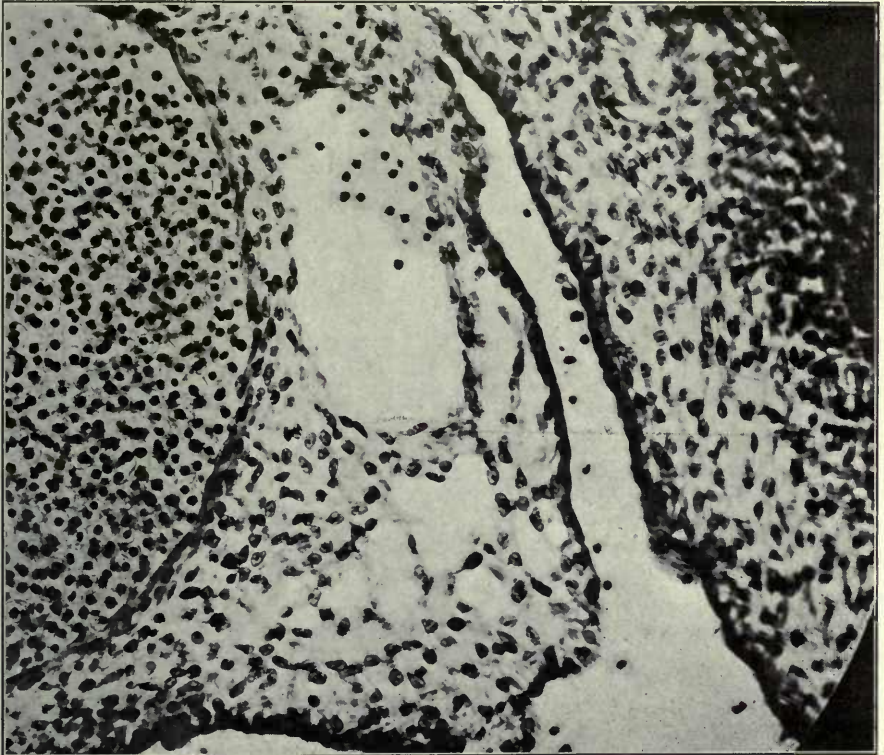
5

FIGURES 6 AND 7

- 6 Same, section 8.
- 7 Same, section 9.



6



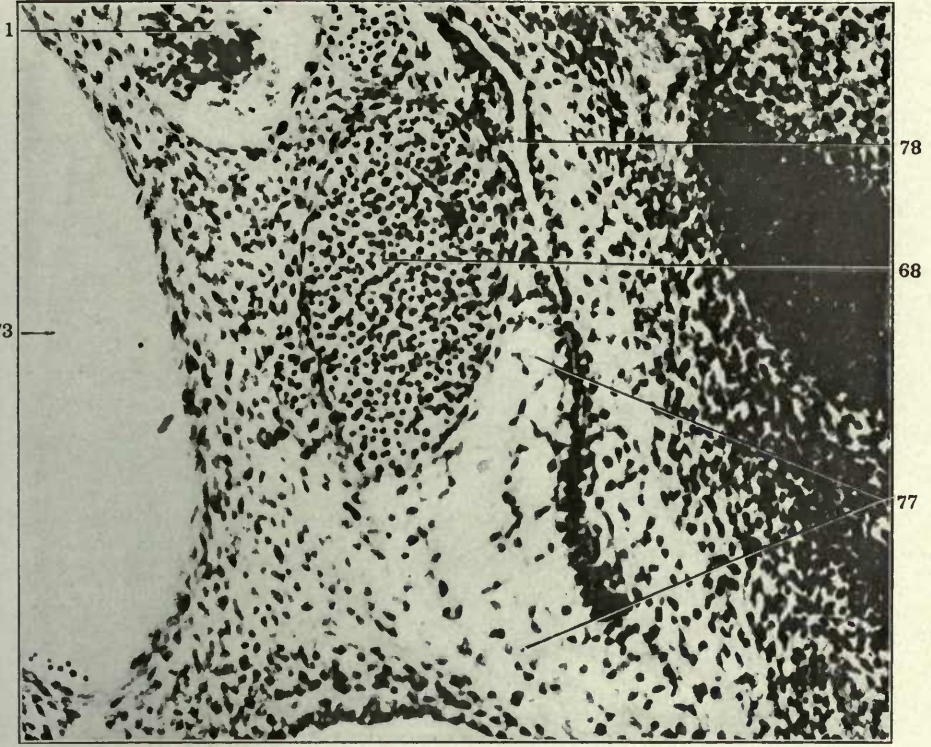
7

FIGURES 8 AND 9

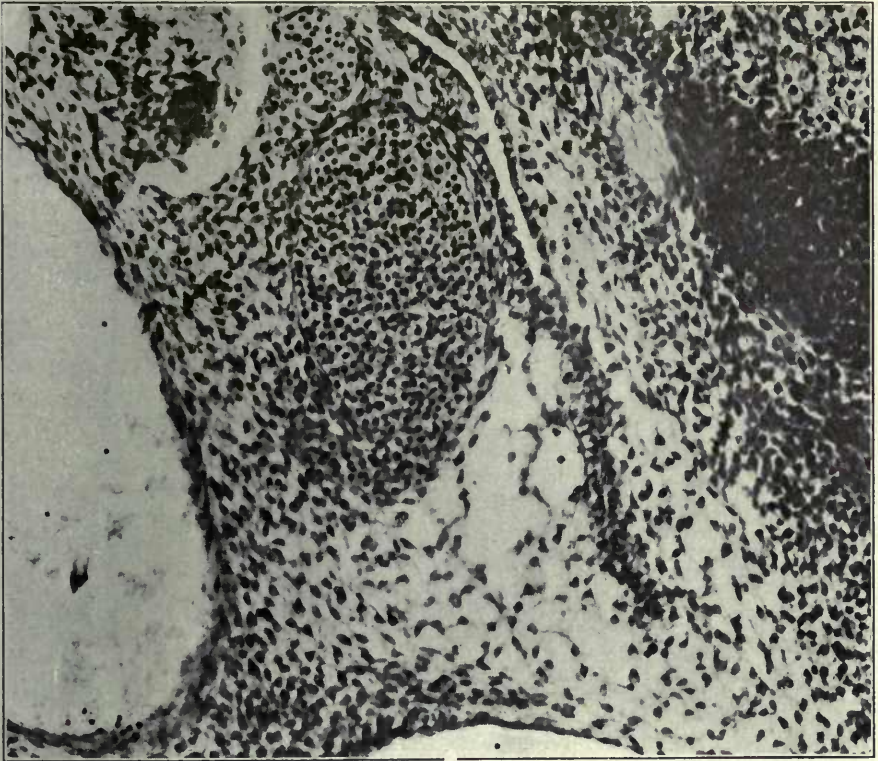
8 Transverse section of 10 mm. cat embryo (series 120, slide IX, section 25)
× 300.

9 Same, section 26.

- 1 Sympathetic nerve.
- 68 Left postcardinal vein.
- 73 Left dorsal aorta.
- 77 Mesenchymal intercellular lymphatic anlagen.
- 78 Coelom.



8



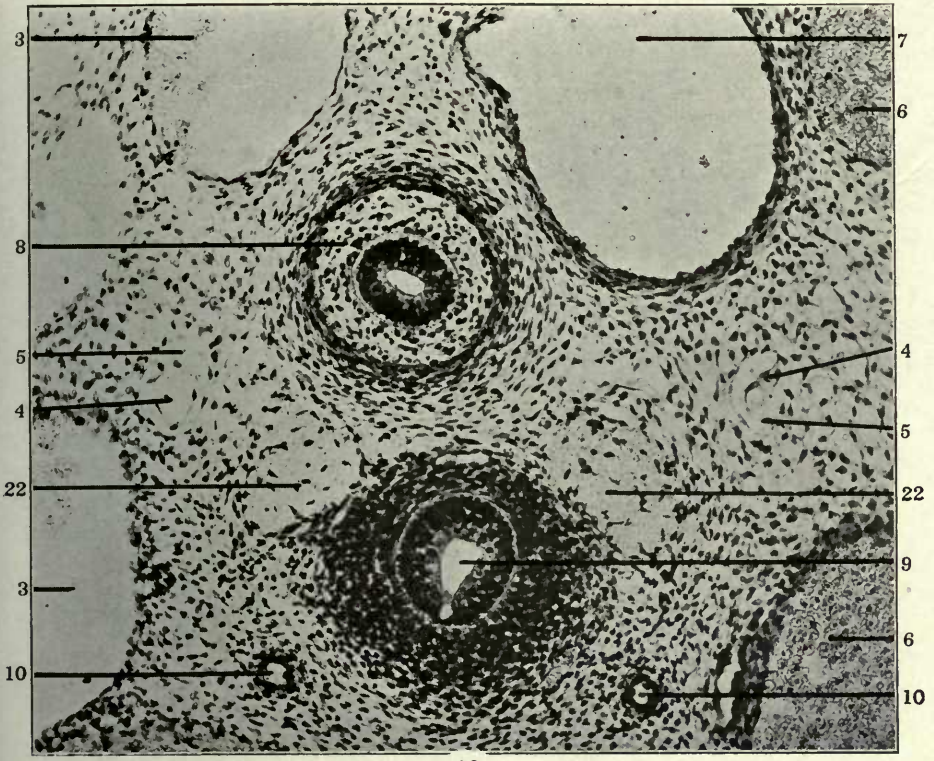
9

FIGURES 10 AND 11

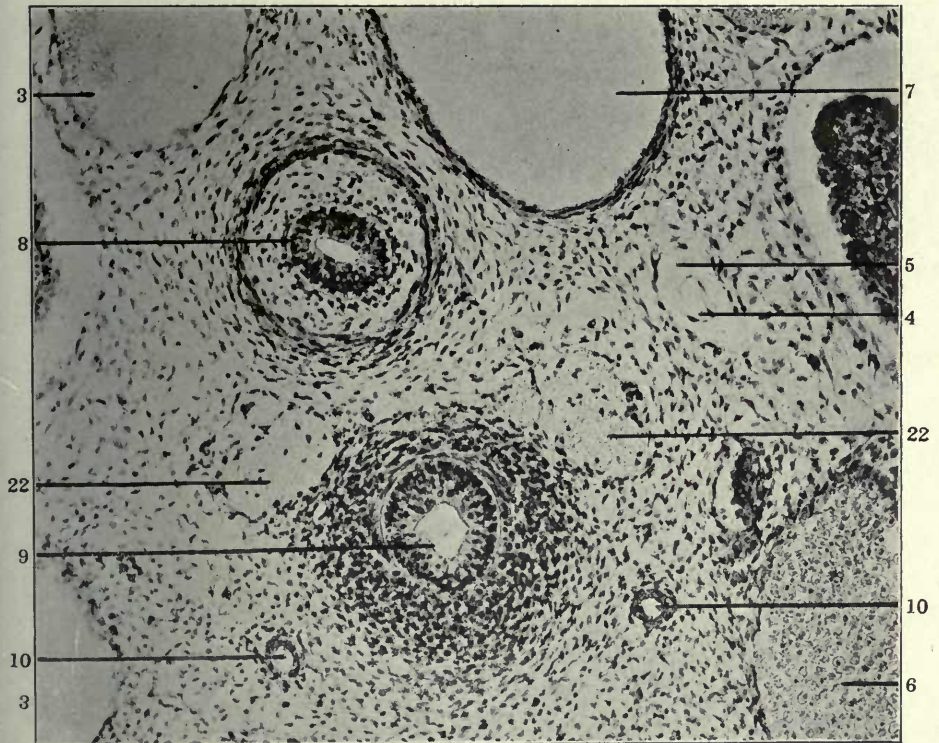
10 Transverse section of anterior thoracic region of 12 mm. cat embryo (series 217, slide X, section 12), \times 225—showing early extraintimal lymphatic development.

11 Transverse section of anterior thoracic region in a 12 mm. cat embryo (series 211, slide X, section 15), \times 225.

- 3 Precardinal or precava, resp. azygos of right side.
- 4 Atrophying embryonal vein, forming kernel in interior of developing and replacing lymphatic space.
- 5 Extraintimal or perivenous lymphatic space surrounding degenerating embryonal vein.
- 6 Precardinal or precava, resp. azygos of left side.
- 7 Aorta.
- 8 Oesophagus.
- 9 Trachea.
- 10 Pulmonary artery.
- 22 Vagus.



10

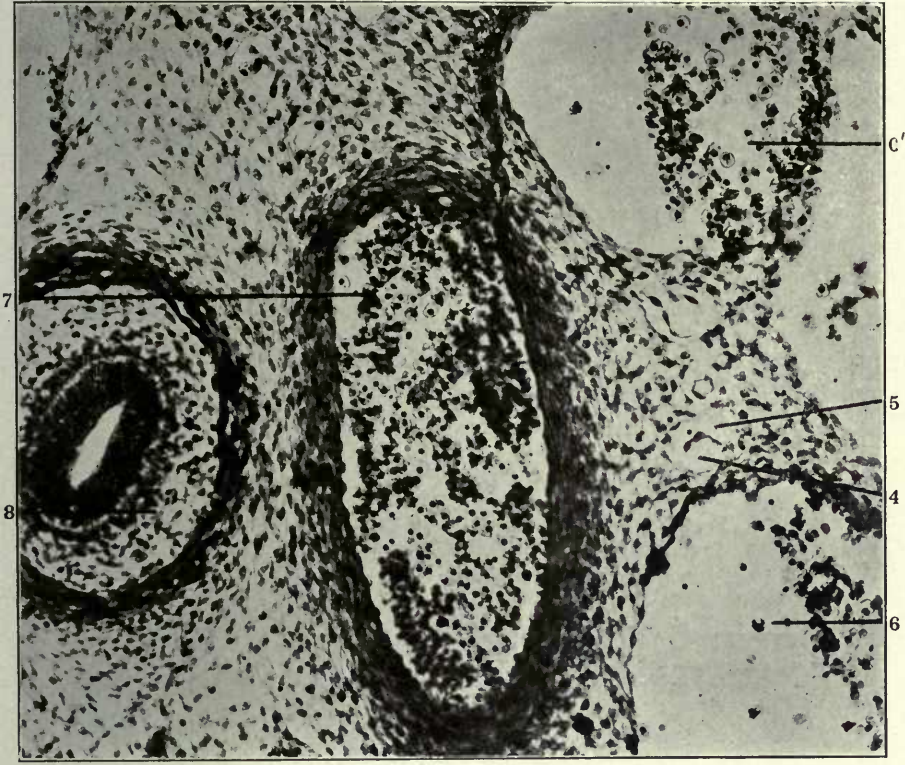


11

FIGURE 12

12 Transverse section of anterior thoracic region in a 14 mm. embryo (series 127, slide VIII, section 12), \times 225.

- 4 Atrophying embryonal vein, forming kernel in interior of developing and replacing lymphatic space.
- 5 Extraintimal or perivenous lymphatic space surrounding degenerating embryonal vein.
- 6 Precardinal or precava, resp. azygos of left side.
- 6' Left azygos vein, thoracic portion.
- 7 Aorta.
- 8 Oesophagus.

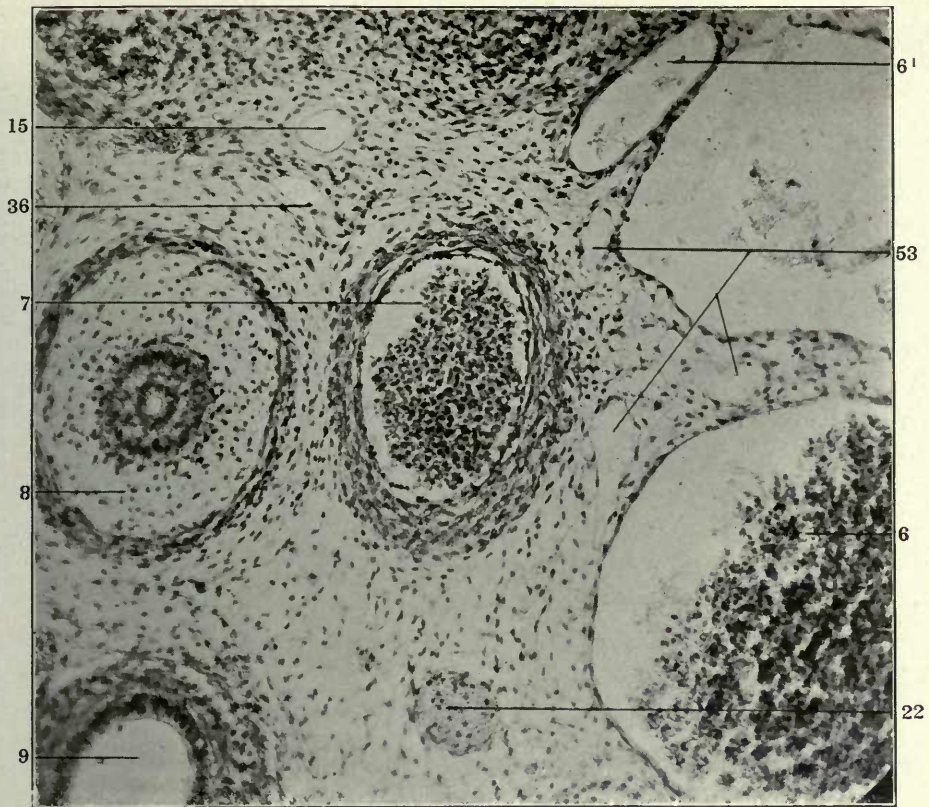


FIGURES 13 AND 14

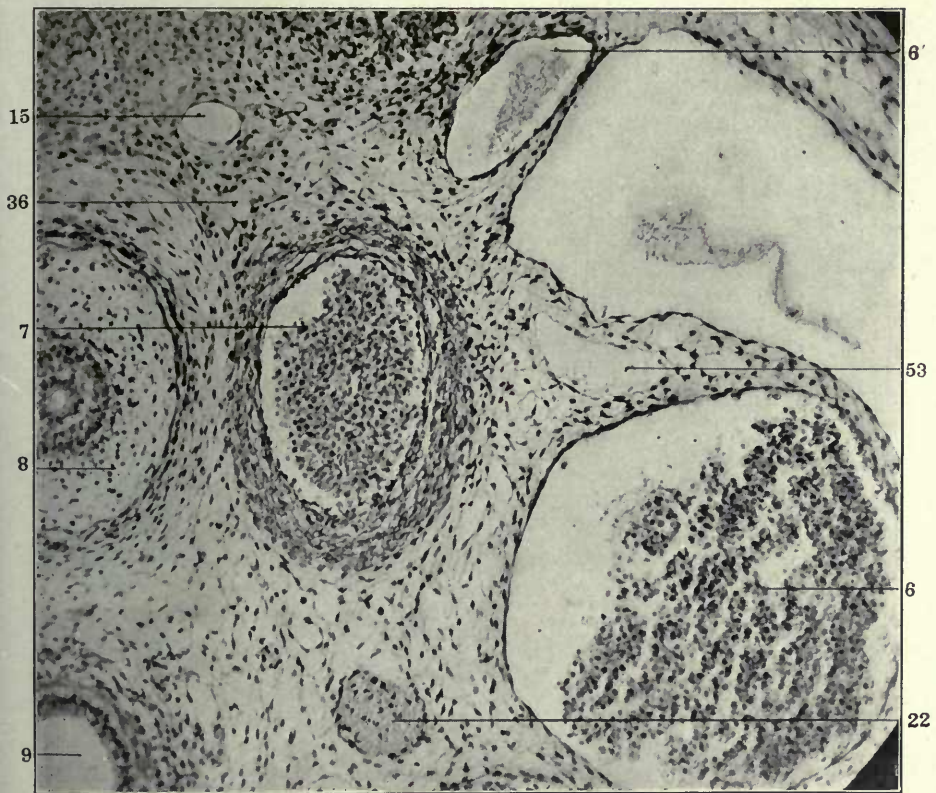
13 Transverse section of anterior thoracic region in a 15 mm. cat embryo (series 219, slide XIV, section 17), \times 225.

14 Same, section 18.

- 6 Precardinal or precava, resp. azygos of left side.
- 6' Left azygos vein, thoracic portion.
- 7 Aorta.
- 8 Oesophagus.
- 9 Trachea.
- 15 Interazygos segment of thoracic duct.
- 22 Vagus.
- 36 Azygos segment of thoracic duct.
- 53 Precaval lymphatics.



13



14

FIGURE 15

15 Transverse section through lower cervical region of a 14 mm. cat embryo (series 222, slide VII, section 26), $\times 150$.

- 11 Jugular lymph sac.
- 25 Internal jugular vein.
- 27 External jugular vein.
- 27' External jugular lymphatics.

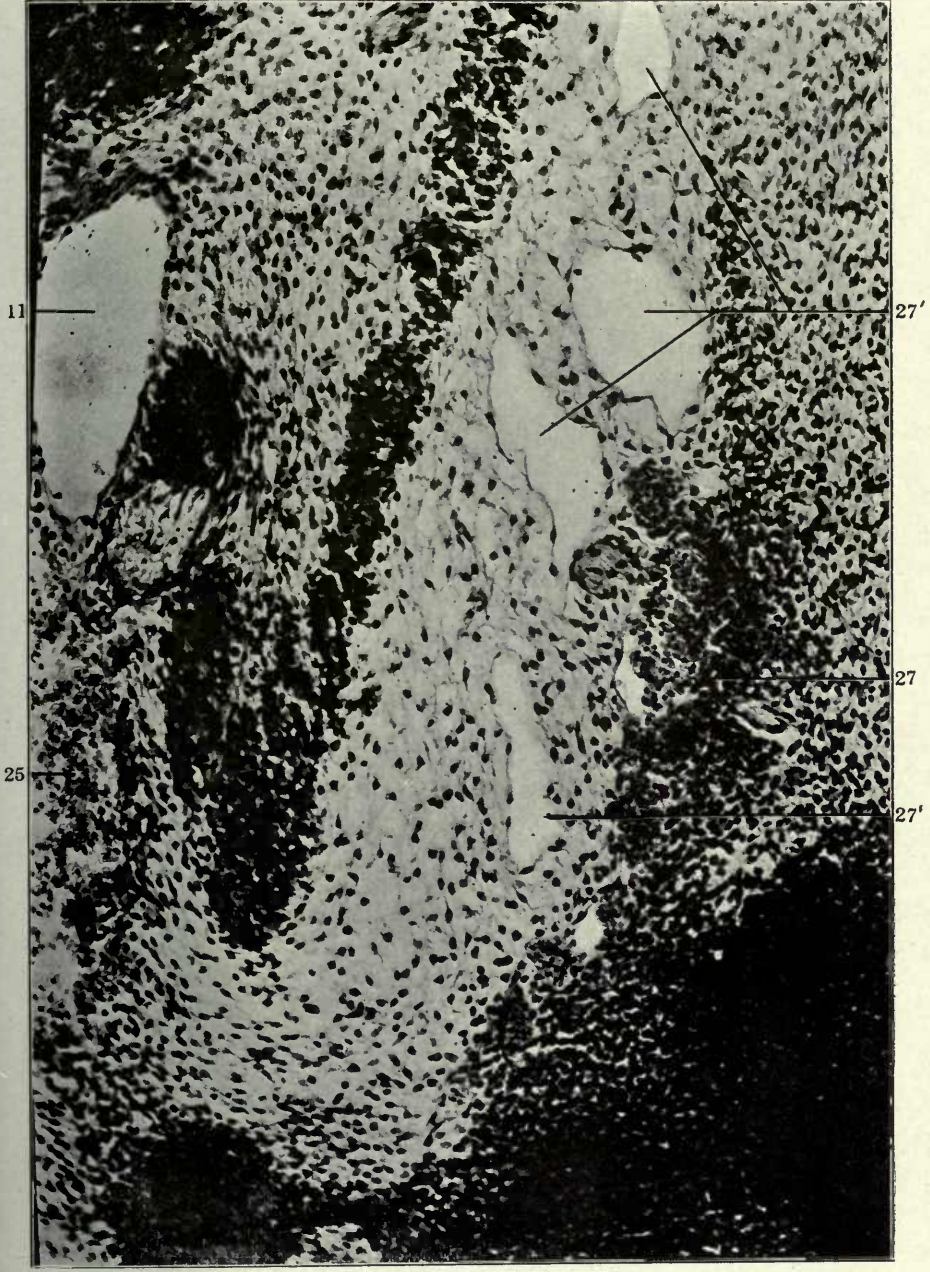

FIGURE 16

16 Same, slide VIII, section 4.

- 11 Jugular lymph sac.
- 25 Internal jugular vein.
- 27 External jugular vein.
- 27' External jugular lymphatics. •

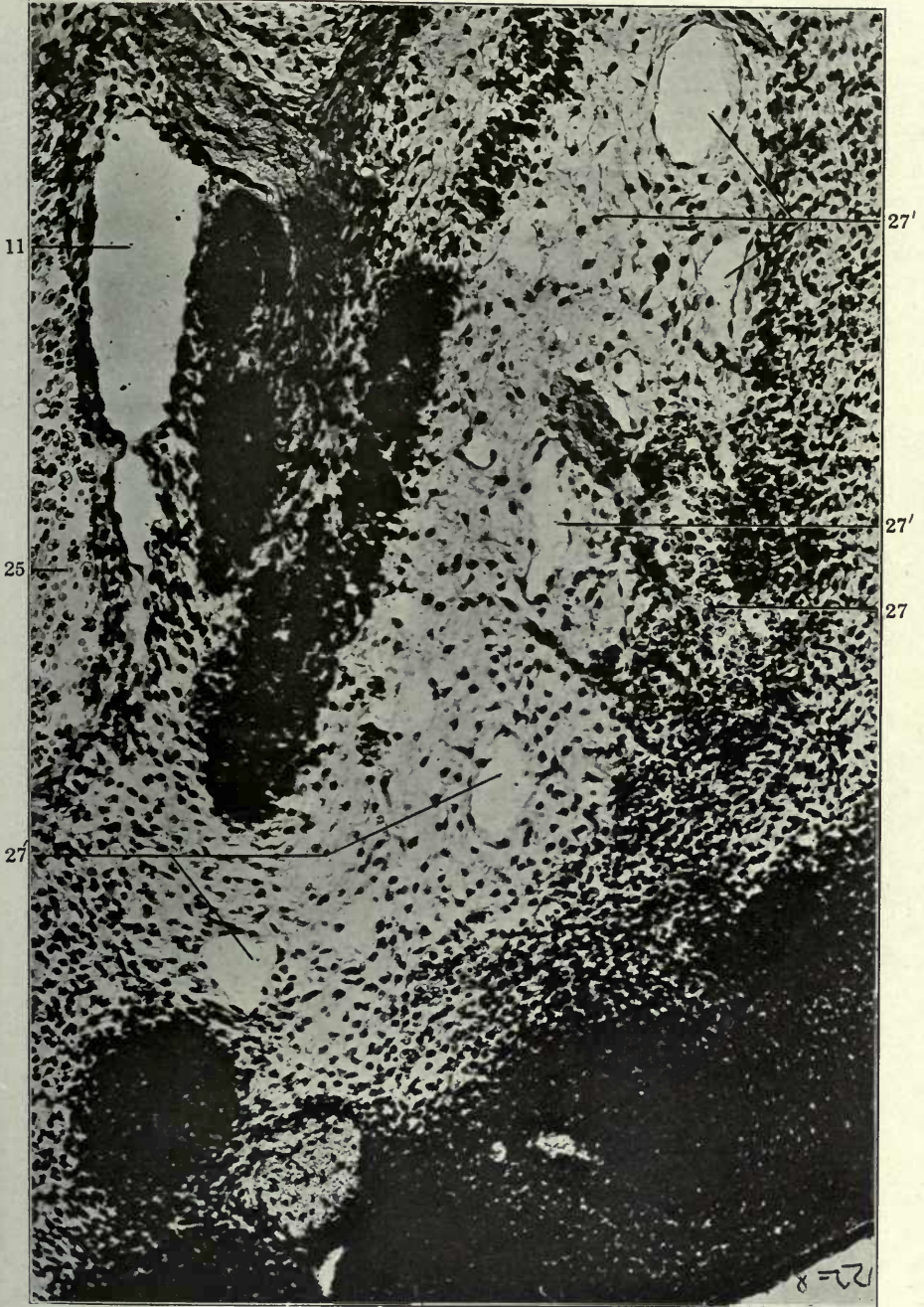
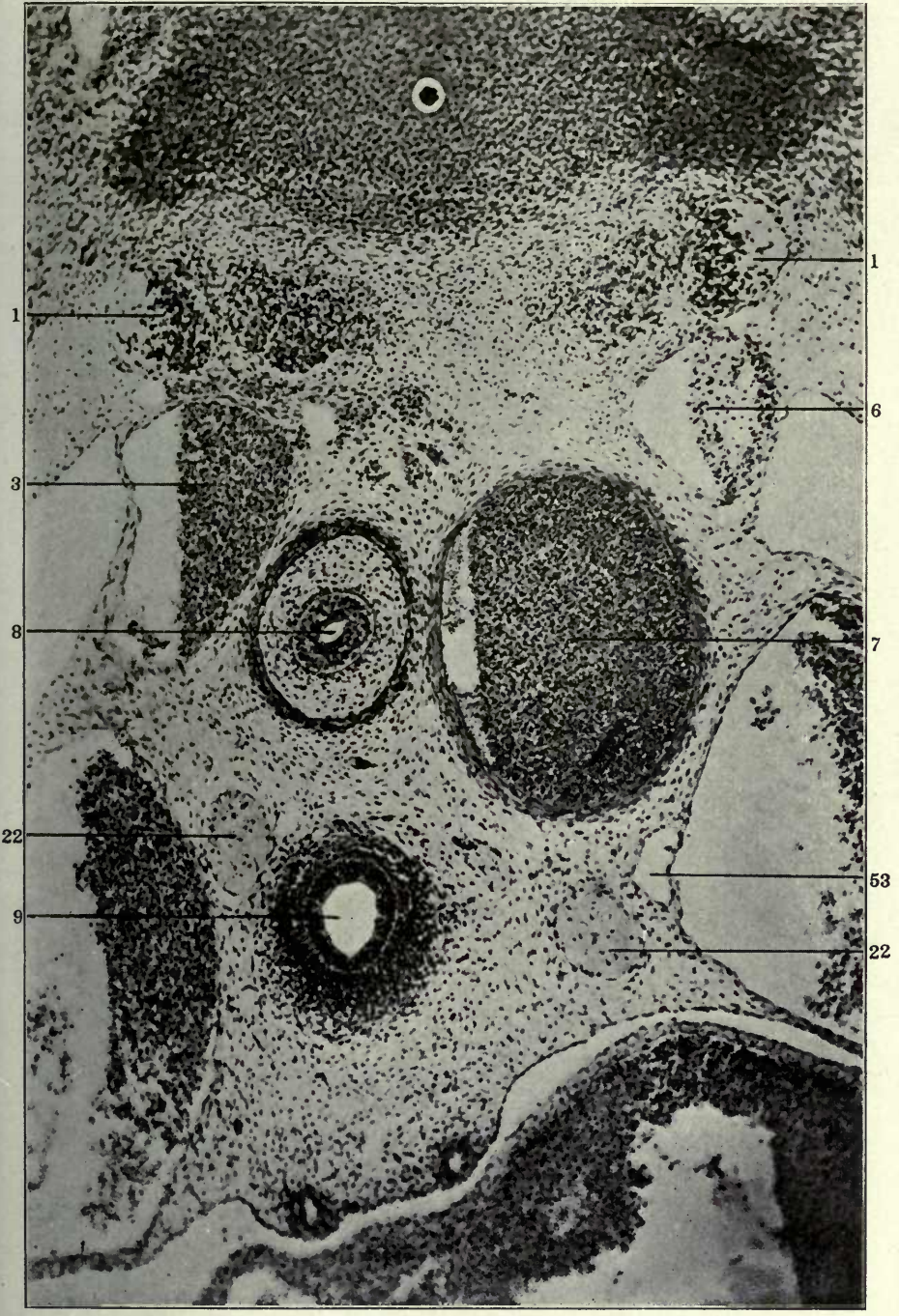


FIGURE 17

17 Transverse section of upper thoracic region of 14 mm. embryo (series 37, slide XIII, section 12), \times 150.

- 1 Sympathetic nerve.
- 3 Precardinal or precava, resp. azygos of right side.
- 6 Precardinal or precava, resp. azygos of left side.
- 7 Aorta.
- 8 Oesophagus.
- 9 Trachea.
- 22 Vagus.
- 53 Precaval lymphatics.

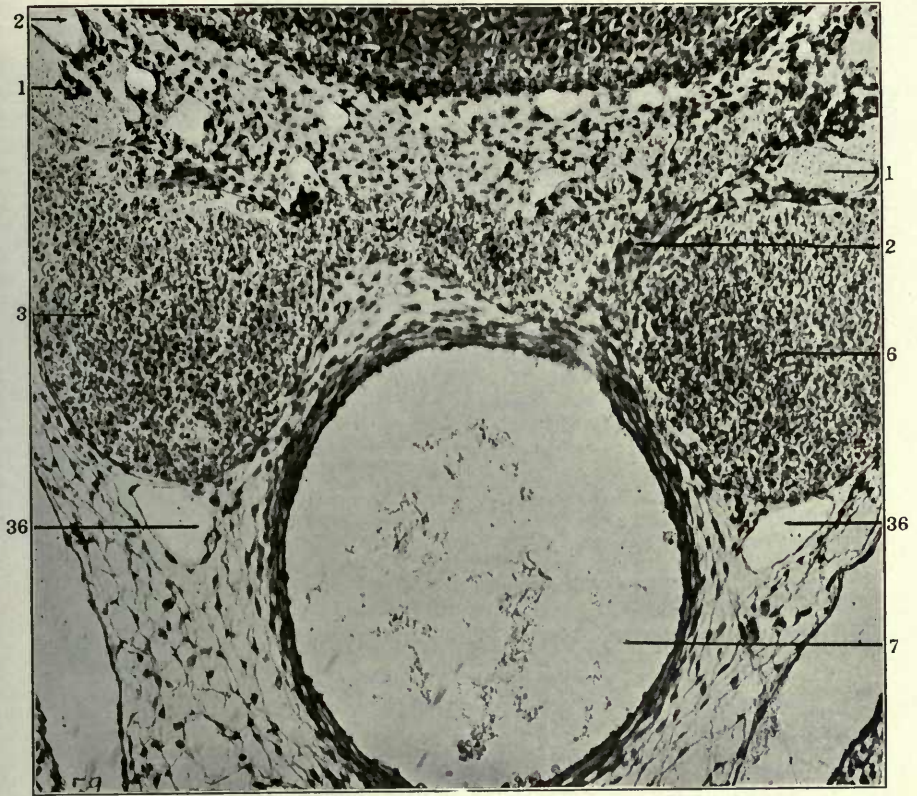


FIGURES 18 AND 19

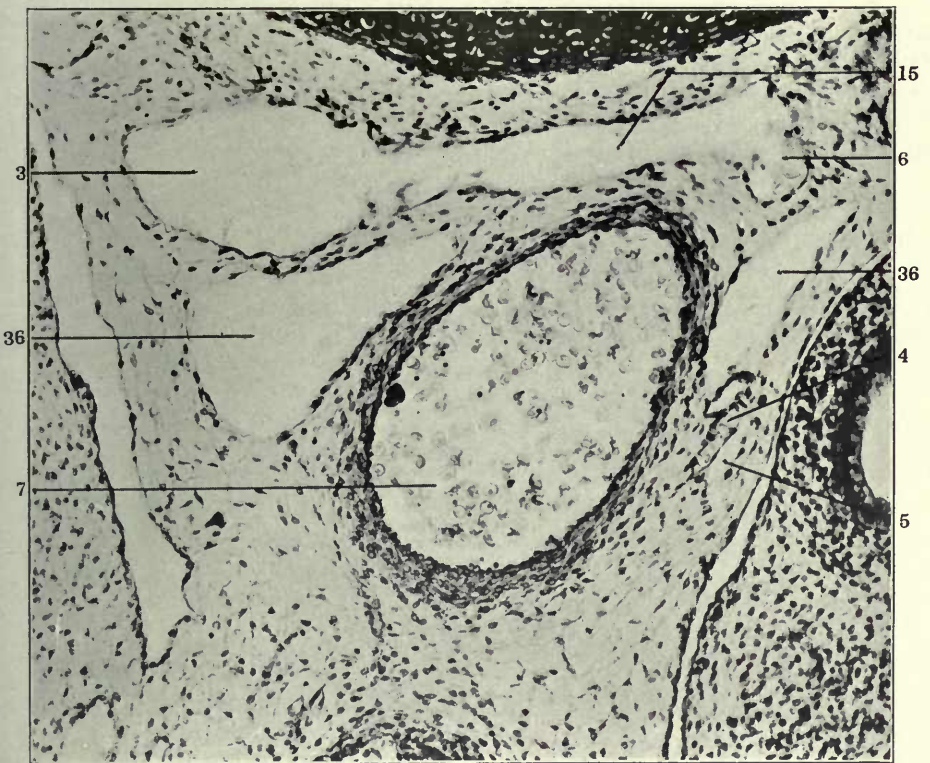
18 Transverse section of middle thoracic region in a 17 mm. cat embryo (series 258, slide XVIII, section 9), \times 225.

19 Transverse section through mid-thoracic region of a 19 mm. cat embryo (series 253, slide XXIV, section 9), \times 225.

- 1 Sympathetic nerve.
- 2 Intersegmental arteries.
- 3 Right azygos.
- 4 Atrophying embryonal vein.
- 5 Extraintimal or perivenous lymphatic space.
- 6 Left azygos.
- 7 Aorta.
- 15 Interazygos venous plexus.
- 36 Azygos segment of thoracic duct.



18



19

FIGURE 20

20 Transverse section of upper abdominal region of a 17 mm. cat embryo, showing developing components of ascending lumbar lymphatic trunks and of mesenteric sac in relation to embryonic veins in the root of the dorsal mesentery and their relation to the cardinal collateral venous channels (series 258, slide XXIII, section 34), $\times 75$.

- 1 Sympathetic nerve.
- 7 Aorta.
- 51 Mesenteric lymphatics.
- 58 Ureters.
- 61 Iliac vessels.
- 62 End gut.
- 63 Ventral division of cloaca (urinary bladder).
- 64 Wolffian ducts.
- 66 Umbilical arteries.
- 67 Right postcardinal vein.
- 68 Left postcardinal vein.
- 74 Cardinal collateral veins.
- 75 Ascending lumbar lymphatic trunks.

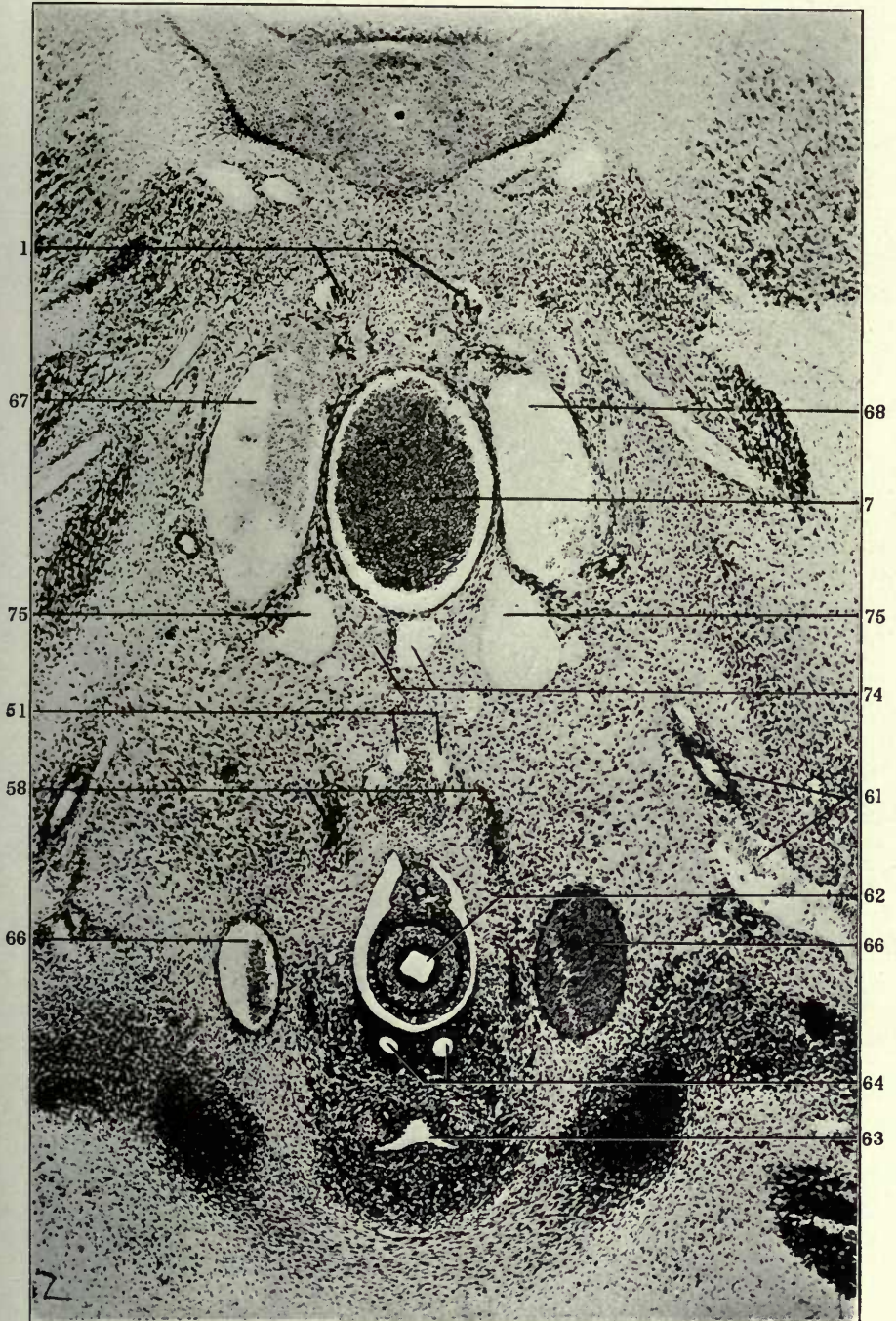


FIGURE 21

21 Same section, $\times 150$.

- 7 Aorta.
- 51 Mesenteric lymphatics.
- 58 Ureters.
- 67 Right postcardinal vein.
- 68 Left postcardinal vein.
- 74 Cardinal collateral veins.
- 75 Ascending lumbar lymphatic trunks.

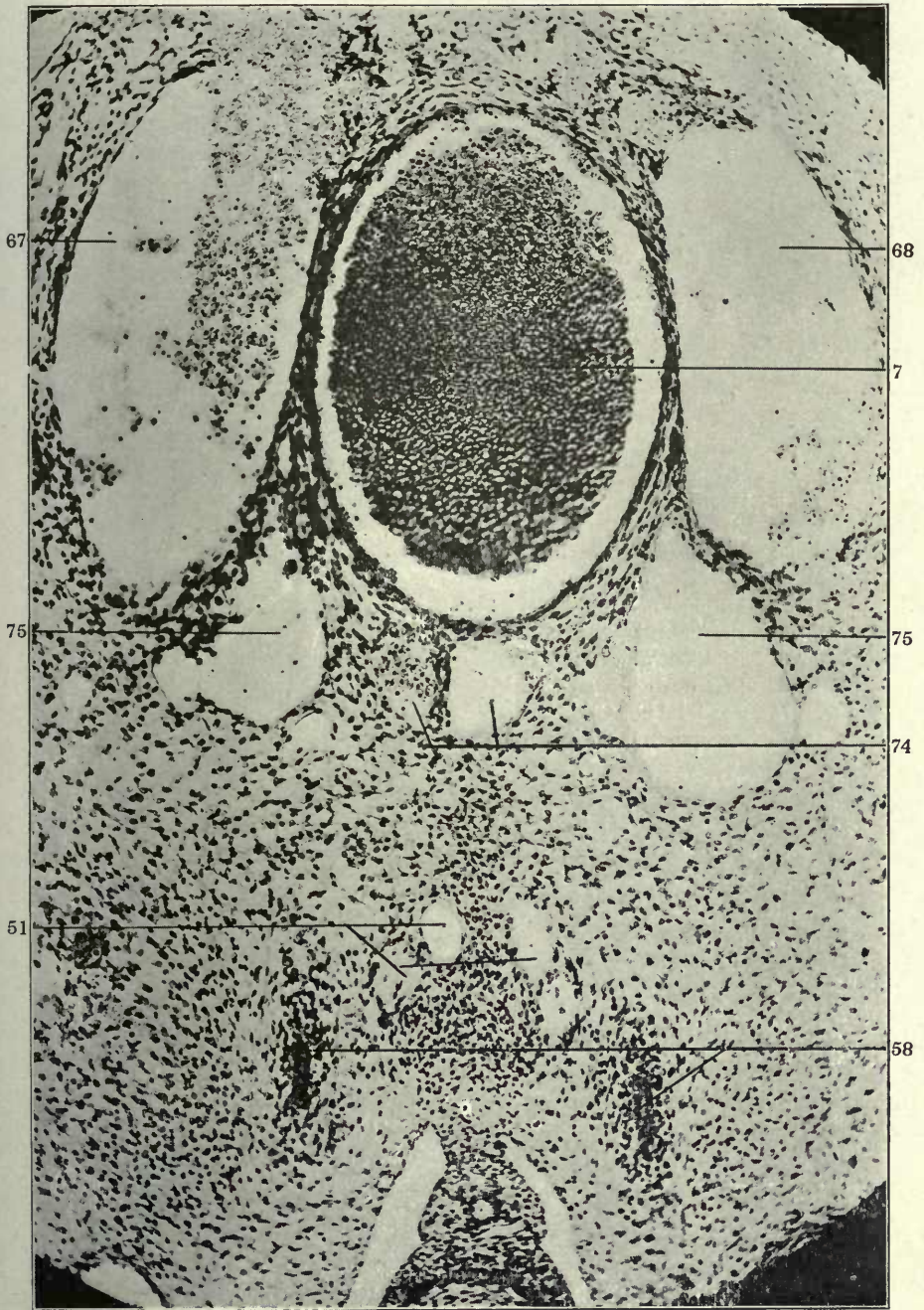
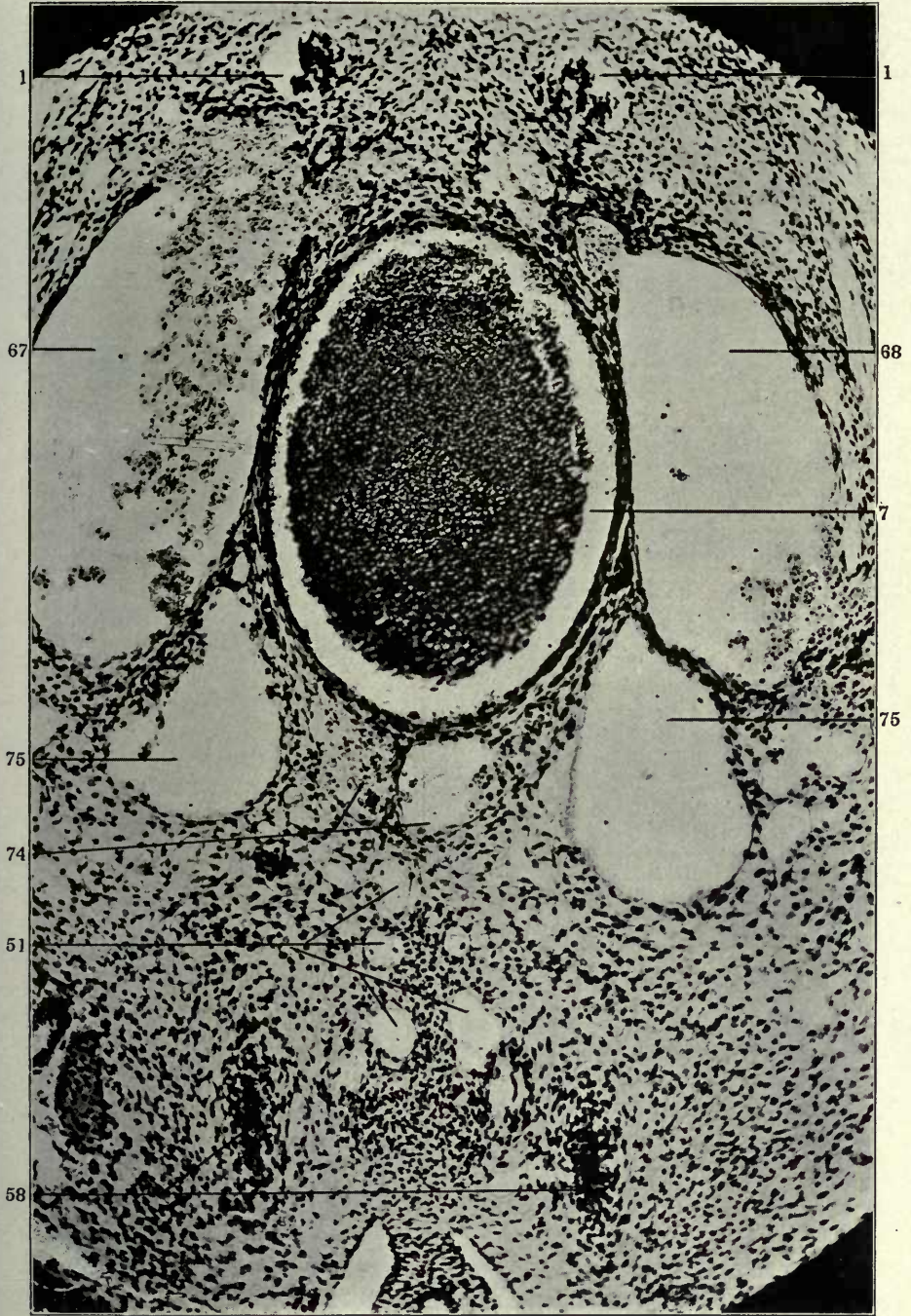


FIGURE 22

22 Same, section 33.

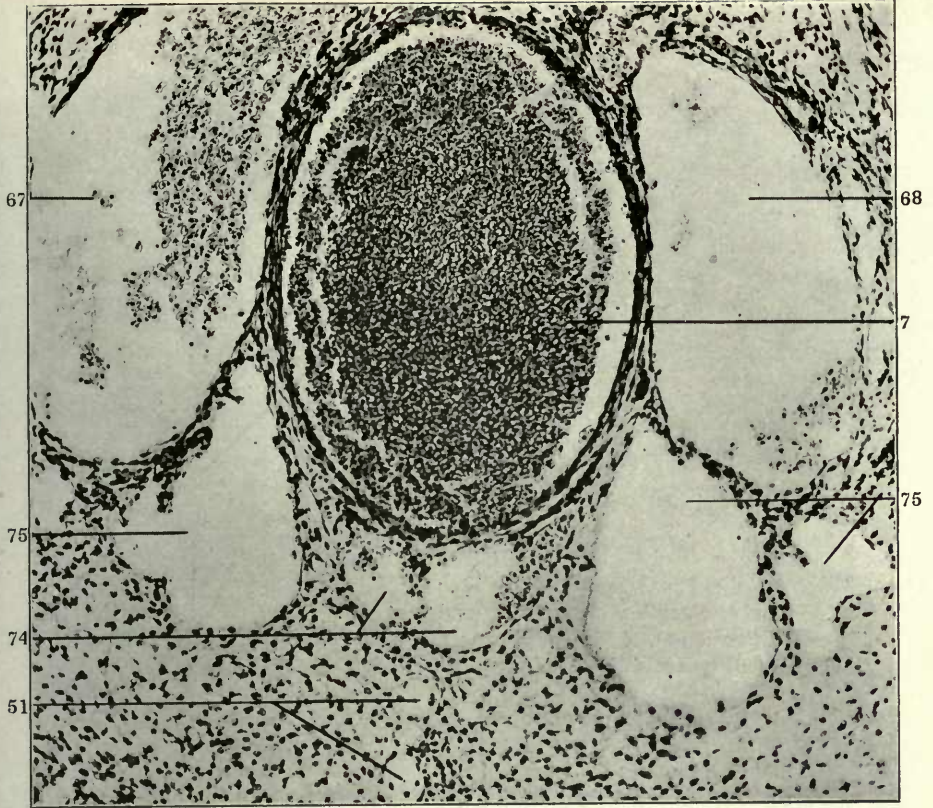
- 1 Sympathetic nerve.
- 7 Aorta.
- 51 Mesenteric lymphatics.
- 58 Ureters.
- 67 Right postcardinal vein.
- 68 Left postcardinal vein.
- 74 Cardinal collateral veins.
- 75 Ascending lumbar lymphatic trunks.



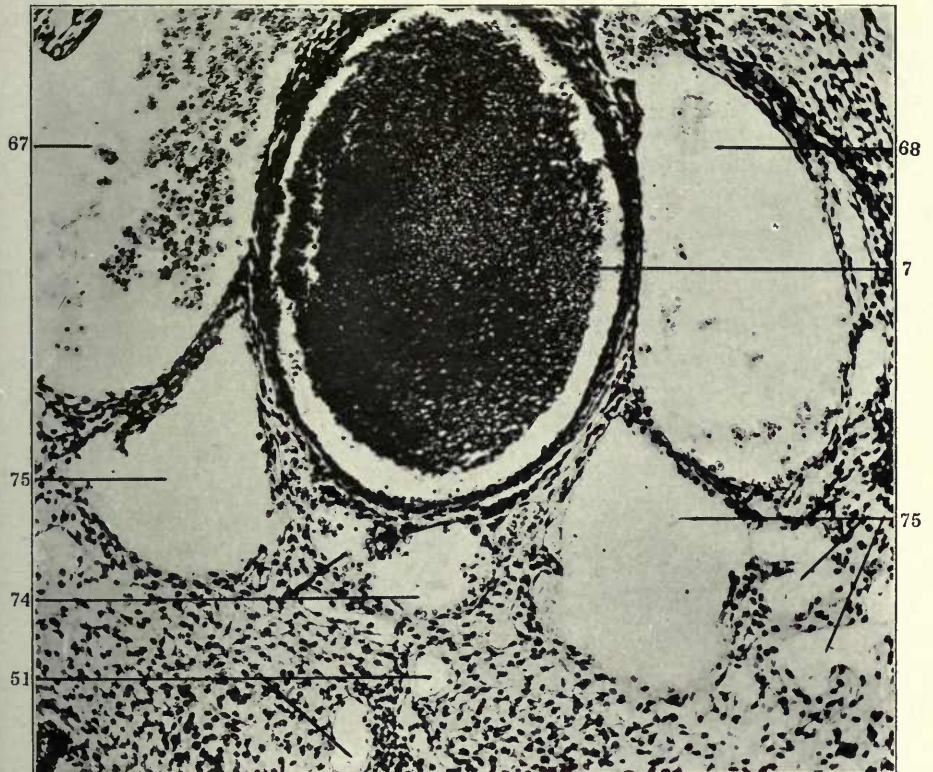
FIGURES 23 AND 24

- 23 Same, section 32.
- 24 Same, section 31.

- 7 Aorta.
- 51 Mesenteric lymphatics.
- 67 Right postcardinal vein.
- 68 Left postcardinal vein.
- 74 Cardinal collateral veins.
- 75 Ascending lumbar lymphatic trunks.



23

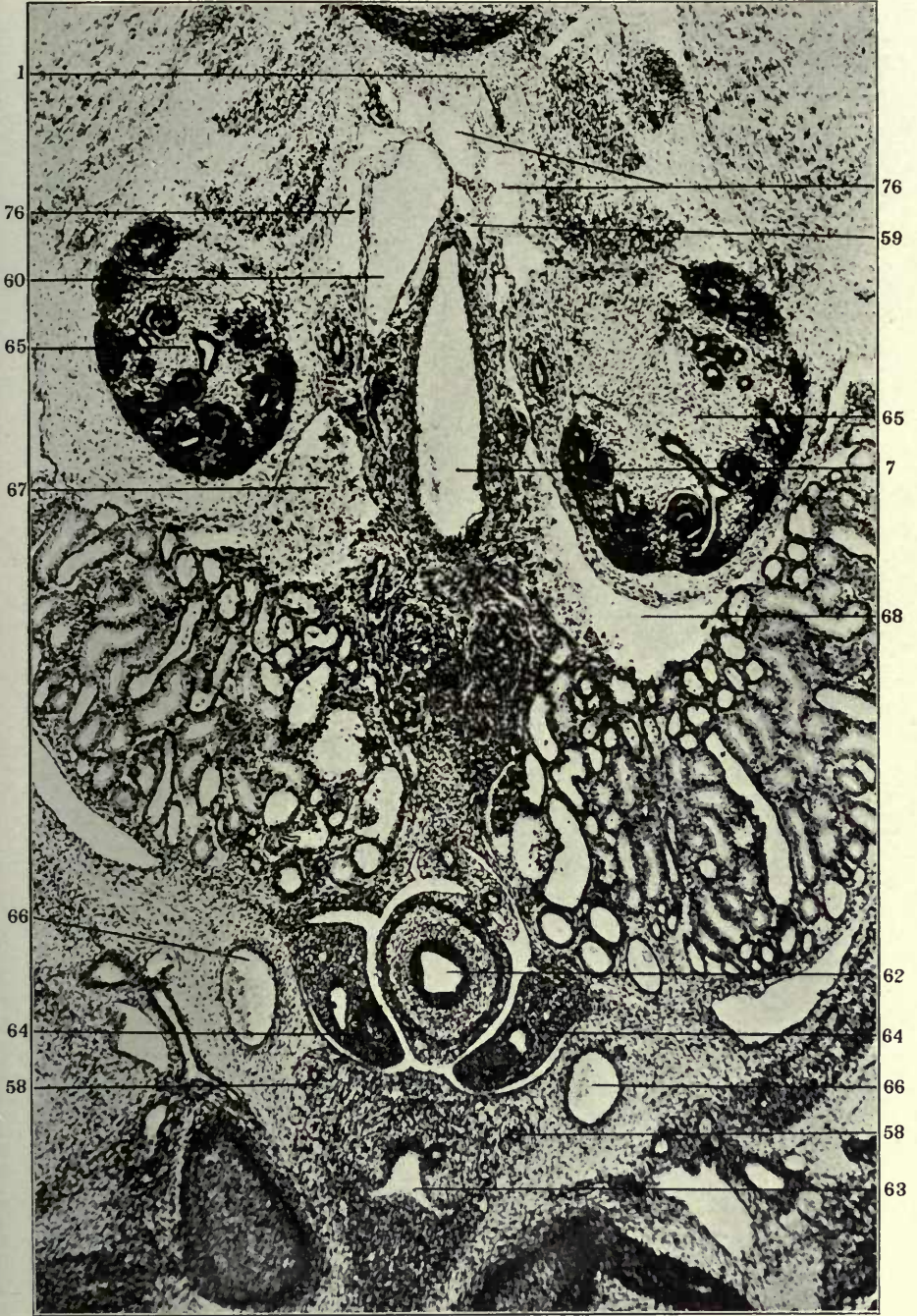


24

FIGURE 25

25 Transverse section of posterior end of a 20 mm. cat embryo (series 241, slide XXX, section 4), $\times 75$ —showing extraintimal replacement of left supra-cardinal vein (59) by ascending lumbar retroaortic lymphatic channel (76).

- 1 Sympathetic nerve.
- 7 Aorta.
- 58 Ureters.
- 59 Left supracardinal vein.
- 60 Right supracardinal vein.
- 62 End gut.
- 63 Ventral division of cloaca (urinary bladder).
- 64 Wolffian ducts.
- 65 Metanephros.
- 66 Umbilical arteries.
- 67 Right postcardinal vein.
- 68 Left postcardinal vein.
- 76 Retroaortic supracardinal lymphatic trunks.






FIGURE 26

26 Same, section 14, \times 150.

- 1 Sympathetic nerve.
- 58 Ureters..
- 59 Left supracardinal vein.
- 60 Right supracardinal vein.
- 67 Right postcardinal vein.
- 68 Left postcardinal vein.
- 75 Ascending lumbar lymphatic trunks.
- 76 Retroaortic supracardinal lymphatic trunks.

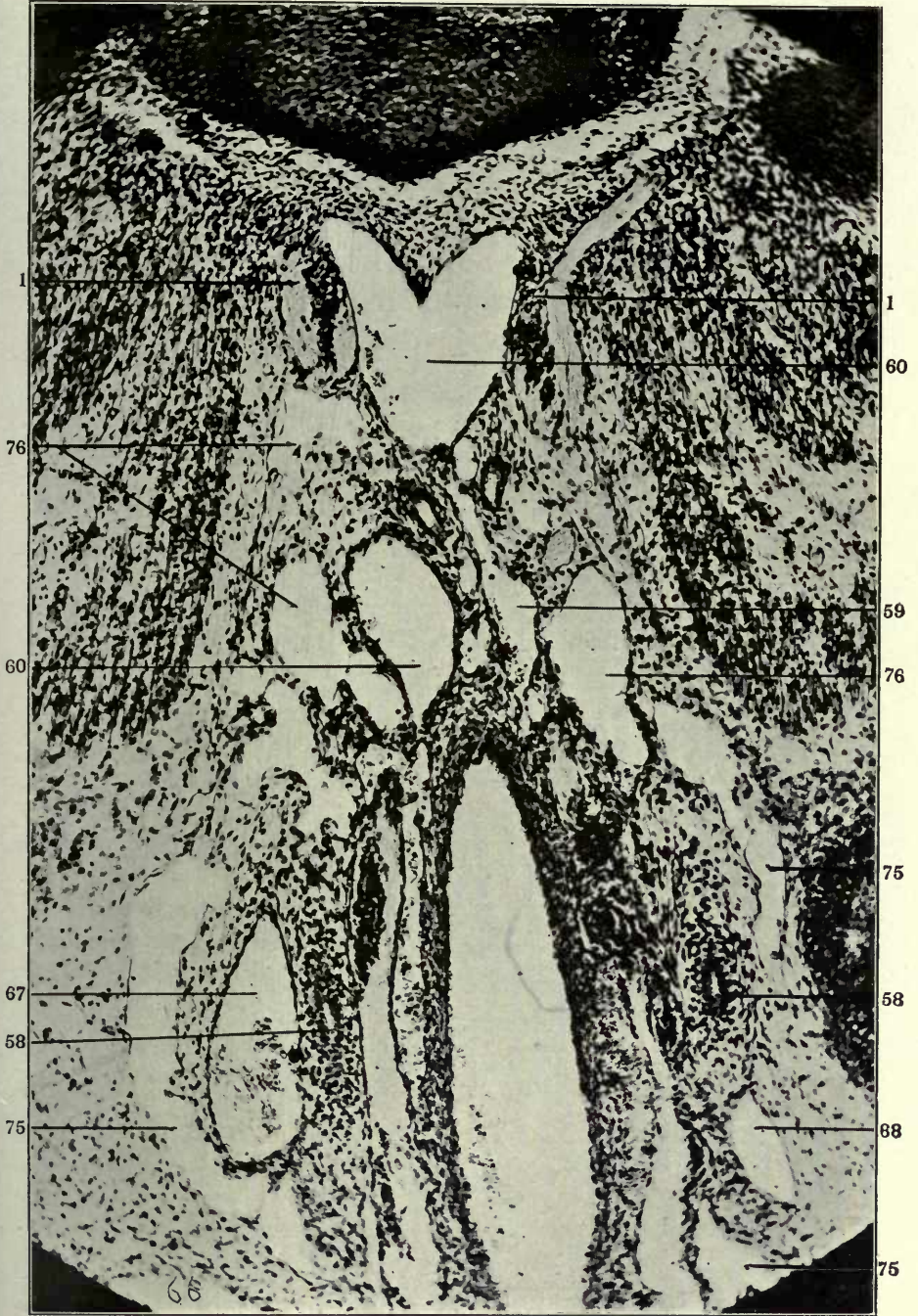

FIGURE 27

27 Reconstruction of anterior vascular complex in an 18 mm. cat embryo (series 88), $\times 50$. Ventral view.

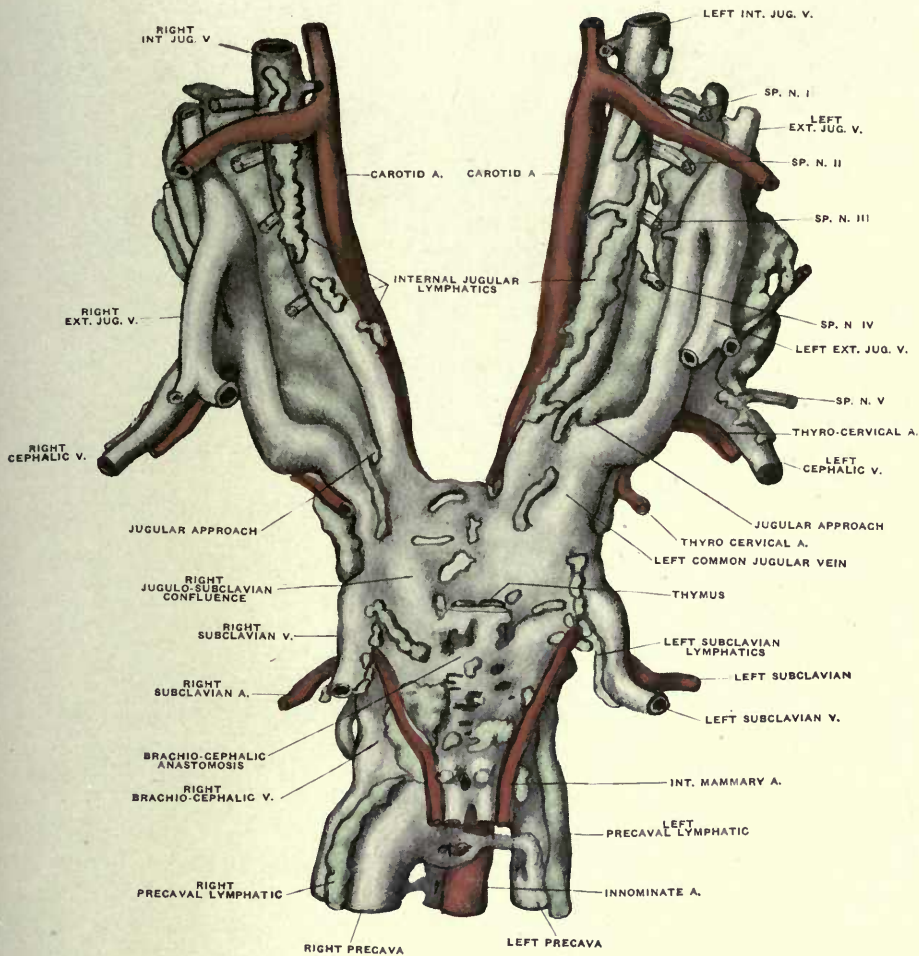
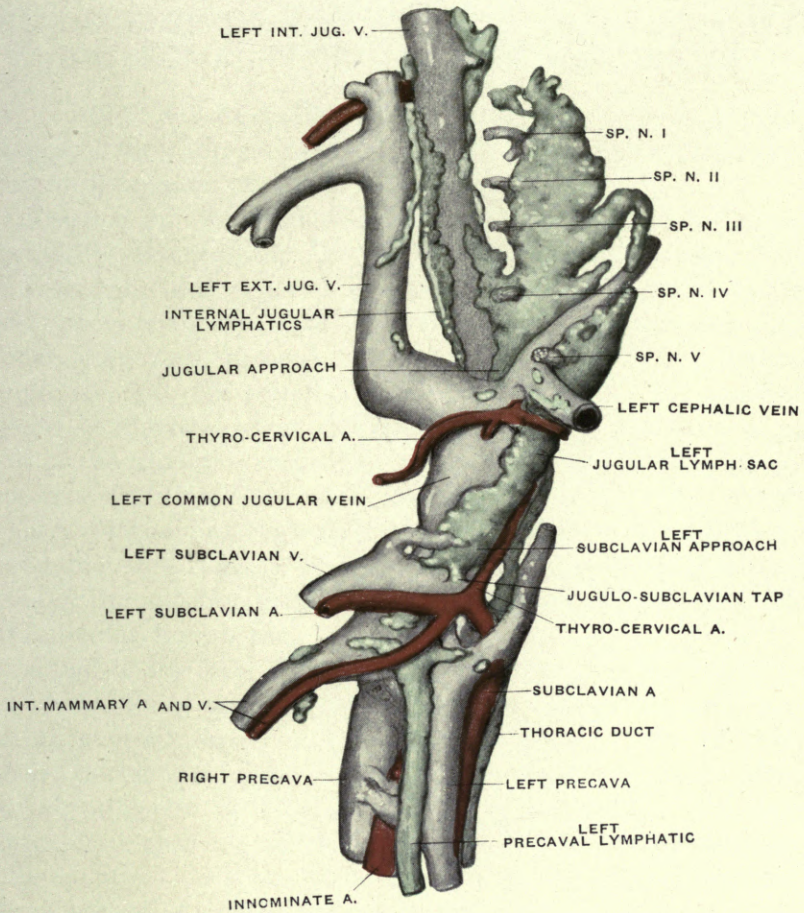


FIGURE 28

28 Same, lateral view of left side.



PART II

THE DEVELOPMENT OF THE PREAZYGOS AND AZYGOS SEGMENTS OF THE THORACIC DUCTS

In certain developmental stages in the cat, the embryonic anlagen of the thoracic ducts appear as potentially symmetrical bilateral lymphatic channels.

Subsequently, the cephalic portion of the left duct, having secondarily assumed the function of conveying the lymph from the trunk and the posterior extremities, forms, cephalad to the aortic arch level, the main continuation of the thoracic duct proper, emptying, through the intervention of the left jugular lymph sac, into the general venous system at the left common jugular confluence, or at the jugulo-subclavian junction, or at both of these points, according to the type of adult lymphatico-venous connection established in individual cases ^{(26), (27), (34), (35),}

The corresponding cephalic preazygos portion of the right lymphatic duct then remains as a more or less rudimentary structure, draining the anterior mediastinal region and emptying into the right jugular lymph sac.

Caudad of the level of the aortic arch, the adult thoracic duct is a composite of parts of three embryonic lymph channels presenting a great range of individual variation. Two of these anlagen develop as bilateral extraintimal lymphatic trunks along the ventral aspect of the right and left azygos veins. The third intermediate channel, which is the first to distinctly differentiate in the embryo and is the main element in the typical organization of the adult duct, develops in the caudal portion from extraintimal lymphatic anlagen, which replace part of the ventromedial tributary plexus of the right azygos vein. In ascending

³⁵ C. F. W. McClure and C. F. Silvester: "A comparative study of the Lymphatic-Venous communications in Adult Mammals," *Anat. Rec.*, Vol. III, pp. 534-551.

it increasingly turns to the left and continues to develop cephalad along the ventral surface of the inter-azygos plexus, by extra-intimal replacement of elements belonging to the latter. (Compare the series of six reconstructions shown in figs. 188, 189, 190, 191, 192, 193.)

The details of the adult organization of the thoracic ducts, and the genesis of the observed adult variations on the basis of the development of the embryonic channels, will be considered subsequently (Part V). The present communication is confined to the consideration of the development of the *preazygos* and *azygos segments* of the ducts. The thoracic ducts develop in cat embryos between 11 and 16 mm. crown rump measure. In the 16 mm. embryo, McClure ⁽¹⁵⁾ states that they "for the first time make their appearance as definite, continuous lymph channels, which are disconnected from the venous system, except through the mediation of the jugular lymph sacs." This is the case in the majority of 16 mm. embryos, but in a number of 15, 15.5 and 16 mm. series in my collection the final union of the individual segments has not yet taken place. It is possible, by combining a large number of observations on numerous embryos of the same length, to establish an average developmental condition of the thoracic ducts for each stage in embryos between 12 mm. and 17 mm. crown-rump measure. Individual embryos will, however, show marked differences in development, and many departures from the standard plan are encountered. The same conditions obtain here which McClure and I found in our study of the development of the jugular lymph sacs. Some embryos show, for their length, unusually advanced thoracic duct development in certain areas, while in other parts this development is relatively retarded and more primitive. In other series the entire region of thoracic duct development appears more uniformly ahead of the average condition, normally encountered in embryos of this period. Finally, in a third group, the appearance of the typical lymphatic development seems to be delayed until a later stage than is normally the case. But in spite of these individual differences, a uniform and consistent ground plan of thoracic duct development can be demonstrated, to

which the majority of embryos conform and into which even the aberrant types fit. As a matter of fact, the regularity with which the thoracic duct anlagen first appear in the majority of the individuals of the proper stage, and the uniform and constant character of the resulting histological pictures, is one of the most striking and significant features of the entire process. Prior to the 11 mm. stage no definite anlage of the anterior segments of the future ducts is observable.

I believe that the adult thoracic ducts of the cat are developed by fusion of three distinct and separate regional segments. Each of these segments is in turn formed by confluence of a number of originally discrete and independent anlagen, which develop independently of the venous system as extra-intimal or perivenous mesenchymal spaces in the sense previously defined. ^(1, 2, 21, 22). These spaces are applied to, or surround, the walls of the embryonic veins of the lower cervical and of the dorsal mediastinal region. The three main divisions, thus developed independently of the venous system, unite with each other to form the channels of the left and right thoracic ducts, and these usually gain their point of entrance into the systemic veins by uniting with a process of the jugular lymph sacs ("thoracic duct approach") derived from their dorsal aspect, just cephalad to the common jugular approach. Exceptionally the main (left) thoracic duct, by combining with the ventral mediastinal trunk presently to be described, unites (fig. 98) with the ventral process of the "subclavian approach," prolonged from the jugular lymph sac over the ventral surface of the jugulo-subclavian confluence, and thus establishes its connection with the venous system (cf. pp. 84 89, figs. 89 to 99).

The ontogenetic history of the ducts may therefore (fig. 29) be considered under four headings, viz.:

1. THE THORACIC DUCT APPROACH of the jugular lymph sac, forming the terminal of the adult duct on each side (fig. 29, I, blue).
2. THE PREAZYGOS SEGMENT (fig. 29, II). This includes two distinct and separate channels:

A. *The broncho-mediastinal or ventral mediastinal lymphatic trunk* (fig. 29, 37, green), which drains the ventral mediastinum

cephalad of the pericardium, viz., the pericardial, tracheal, bronchial, lateral oesophageal, and thymic areas.

This lymphatic channel, associated with the embryonic venous plexuses of the pretracheal region, the pulmonary vessels and the vagi, develops through confluence of a large number of separate and independent extra-intimal lymphatic spaces following and surrounding the embryonic venous plexuses of the ventral mediastinum. The chain formed by these spaces eventually unites with the similar chain forming the anlagen of the preazygos segment of the thoracic duct.

B. The preazygos segment of the main thoracic duct (fig. 29, 35, brown). This portion of the main duct extends from the point of its entrance into the jugular lymph sac, through the thoracic duct approach of the latter, caudad to its intersection with the dorsal surface of the aortic arch.

In the adult animal this segment forms the relatively long portion which ascends cephalo-sinistrad from the point where the duct parts company with the right azygos vein, to its junction with the jugular lymph sac, under cover of the aortic arch, and the vertical portion of the left subclavian artery, dorsal to the vertebral vein and to the left innominate confluence. In this part of its course the thoracic duct frequently receives the lymphatic return from the ventral mediastinum through channels which unite it to the ventral mediastinal trunk as just defined. The preazygos segment of the main duct is again formed in the embryo by confluence of independent mesenchymal spaces around and along the prevertebral and dorsal mediastinal venous plexuses of the embryo.

3. THE AZYGOS SEGMENT (fig. 29, III, 36, yellow) comprises the portions of the thoracic ducts caudal to the level of the aortic arch. It develops, again independently, as the result of fusion of a number of extraintimal mesenchymal spaces closely applied to the ventral surface of the azygos veins, or of their ventromedial tributaries, or surrounding the latter.

4. THE POST-AZYGOS SEGMENT (fig. 29, IV, 52, green), through which the thoracic ducts establish their connection with the Receptaculum and the system of the abdominal lymphatics.

Inasmuch as the development of this segment of both ducts is intimately connected with that of the principal abdominal lymphatic channels, its consideration will be included in that of the latter system (Part III). The present communication deals only with the first three segments above enumerated.

Fig. 29 shows in a color schema the genetic composition of the thoracic ducts according to the segments just outlined, and their relation to the embryonic venous system.

In proceeding caudo-cephalad the post-azygos portion (IV) develops in the larger right segment (52) by replacement of the caudal part of the ventro-medial tributary plexus of the right azygos vein.

The smaller channel of the left side replaces the caudal part of the left azygos vein. In the azygos area (III) the left channel follows, as a much reduced left thoracic duct, the prevertebral portion of the left azygos vein. The larger right lymphatic channel (36), gradually inclining cephalo-sinistrad, develops along the ventral aspect of the inter-azygos cross-anastomosis and unites with the left duct eventually in a close plexiform interlacement perforated by the intersegmental arteries, which continues cephalad to near the level of the aortic arch. Here the plexus condenses into two more or less well defined channels which turn up to the right and left into the preazygos segment (II). The smaller right channel follows, cephalad of the right azygos terminal, the dorso-medial aspect of the right precaval, innominate and common jugular veins, developing by confluence of extraintimal spaces along the course of these vessels (cf. reconstruction of series 88, figs. 27 and 28), and forms the cephalic end of the reduced right thoracic duct of the adult. It terminates by joining the thoracic duct approach (12) of the right jugular lymph sac. The left and larger trunk replaces the extra-pericardial portion of the left precava, and ascends dorsal to the left innominate confluence to its junction with the thoracic duct approach (12) of the left jugular lymph sac. 37 in fig. 29 indicates the broncho-mediastinal trunk in one of its commonly encountered types, joining caudally the preazygos portion of the thoracic duct (35), and terminating cephalad in the ventral

process of the subclavian approach (14) of the jugular lymph sac, in company with the main lymphatic channels returning from the anterior extremity.

1. THE THORACIC DUCT APPROACH OF THE JUGULAR LYMPH SACS
(FIG. 29, 12)

This structure is an integral part of the jugular lymph sacs and forms in the adult animal the portal of entry of the thoracic ducts into the lymph sacs, and through them into the systemic veins. McClure, in the paper quoted ⁽¹⁵⁾, has described its general formation and relation to the jugular lymph sac and has given an excellent illustration of its appearance in the dorsal view of a reconstruction of a 14 mm. cat embryo. I have here defined it as the "thoracic duct approach" of the sacs, in conformity with the nomenclature which McClure and I adopted in describing ^(26, 27) the development of those portions of the jugular sac which, forming the "jugular" and "subclavian" "approaches," project as blind processes from the caudal end of the sac, and are destined to effect subsequently the permanent lymphatico-venous connections at either the common jugular, or the jugulo-subclavian confluence, or at both of these venous angles. The term, as here used in describing the similar process of the sac which is to establish definite connections with the thoracic duct, is intended to emphasize the fact that the "thoracic approach" of the lymph sac is, like the rest of the structure from which it proceeds, *venous* in origin, while the thoracic ducts proper, with which it *secondarily* unites, are *not* derived from the veins, but are, from their beginning, *independent of the blood-vascular channels*, and develop by confluence of *independent extra- or peri-venous mesenchymal spaces*.

This fundamental difference in origin is shared, in my opinion, by all the other *main systemic lymphatics* which, in addition to the thoracic ducts, enter the jugular sacs as the subclavian, external jugular, cephalic and internal jugular lymphatics through the processes which the sac sends to meet them.

The thoracic duct approach of the earlier embryos arises as a short, blunt, curved, conical process from the dorso-medial aspect

of the sac, a short distance cephalad of the jugular approach and of the common jugular venous confluence.

It extends meso-caudad across the dorso-lateral and dorsal aspects of the internal and common jugular veins between them and the thyro-cervical artery, towards the vagus-sympathetic strand, dipping ventro-mesad between the main vein and the nerves and ending blindly in this situation.

The process makes its first distinct appearance, after the jugular sac has been fully established, in embryos of between 11 mm. and 14 mm. crown-rump measure.

It is noteworthy that individual embryos within these limits show considerable difference in the degree of development of the process. In some it appears earlier, in others a little later, so that in individual instances an embryo of slightly shorter measure may have the thoracic duct approach of the jugular lymph sac further developed than one which exceeds the first in total length by the fraction of a millimeter.

Thus one of the earliest distinct stages of the process is seen in a 14 mm. embryo (series 210, slide viii, sections 39-42, figs. 30 to 33 inclusive).

In this embryo, the thoracic duct approach appears as a short blunt process which projects dorso-mesad from the caudal end of the left jugular lymph sac, a short distance cephalad of the common jugular confluence. Sections 39, 40 and 41 (figs. 30, 31 and 32, 12) show the earliest stage in the development of this process. In them the area dorsal to the main vein, between the sympathetic nerve and the jugular lymph sac, is occupied, in the direction meso-laterad, by the sympathetic nerve (1), the termination of the large dorso-medial venous tributary (left sup. intercostal vein) (16), the thyro-cervical artery (24), and, laterad to this, by the blind terminal portion of the thoracic duct approach (12), derived from the dorso-medial aspect of the jugular lymph sac (11). In this embryo the process of the sac ends blindly laterad to the thyro-cervical artery (figs. 33, 34, 24). It has not yet extended meso-caudad across the dorsal surface of the main vein toward the interval between the thyro-cervical artery and the sympathetic nerve. The thyro-cervical artery

(24) lies at a little distance directly dorsad of the internal jugular vein. The dorso-medial angle of the main vein is related to a large compound medial venous tributary, draining the dorso-medial (prevertebral), (17) and the dorsal somatic areas (16). This compound vessel is the anlage of the future superior intercostal vein. In fig. 33 (section 42) the common trunk opens into the main vein just dorsal to the sympathetic nerve (1). In this section, the blunt medial extremity of the thoracic duct approach (12) is separated from the portion still connected with the jugular lymph sac, thus expressing the caudo-mesal curve of the entire process. It ends blindly in the following section, and does not reappear in the succeeding sections. The common jugular confluence occurs in section 44 of this slide.

We are dealing, therefore, with a short, blunt conical process of the left jugular lymph sac, which curves meso-caudad for two sections, and terminates blindly dorsal to the main vein.

In another 14 mm. embryo (series 212) the thoracic duct approach is much more extensively developed and occupies sections 11 to 26 of slide ix. Selected sections of this series are shown in figs. 34 to 42 inclusive.

Fig. 34 (series 212, slide ix, sec. 14) shows part of the caudal end of the left jugular lymph sac (11) with the thoracic duct approach (12) arising from its medial aspect and extending mesad across the dorsal surface of the internal jugular vein (25). On the mesal aspect of the vein are seen the sympathetic (1) and the vagus (22).

The large common trunk formed by the union of the dorsal somatic and prevertebral venous tributaries (16, 17) lies dorso-medial to the main jugular channel. It joins the latter, as left superior intercostal vein, (16, 46,) in section 26 of this slide (fig. 41). On the lateral aspect of this vessel is the ascending dorsal branch of the thyro-cervical artery (24).

The six succeeding figures (35 to 40 inclusive) are cut down so as to only show the dorsal circumference of the internal jugular vein and the superincumbent thoracic duct approach of the jugular lymph sac.

In fig. 35 (section 15) the approach has extended further mesad

across the main vein. In fig. 36 (section 16) a blind terminal protrusion (12) separates from the main lumen of the sac (11), indicating the frequent bifid character of the thoracic duct approach. The succeeding sections (18 and 20, figs. 37 and 38) hence show an apparent recession of the entire process. In section 22 (fig. 39) the approach has again extended mesad toward the thyro-cervical artery and the superior intercostal vein. In the succeeding section (fig. 40) the fundus of the process terminates for the second time in a blind pouch-like protrusion (12). In the following section (24, fig. 41) the approach (12) again appears fully developed and in open connection with the main jugular lymph sac (11). It maintains the character in section 25, and in section 26 (fig. 42) the terminal of this second protrusion (12) ends blindly. It does not reappear in the succeeding sections.

We are dealing here with an instance of very common occurrence, in which the thoracic duct approach of these earlier stages not only gives off a number of blind terminal diverticula, but in which the entire approach arises by two or three distinct and separate origins from the main jugular lymph sac. This character will again be discussed below (cf. p. 66), in connection with the interpretation of certain adult conditions, but the instance now under discussion shows the early type of this variation very clearly, so that in a graphic reconstruction the thoracic duct approach of this embryo would appear as in figure on page 64.

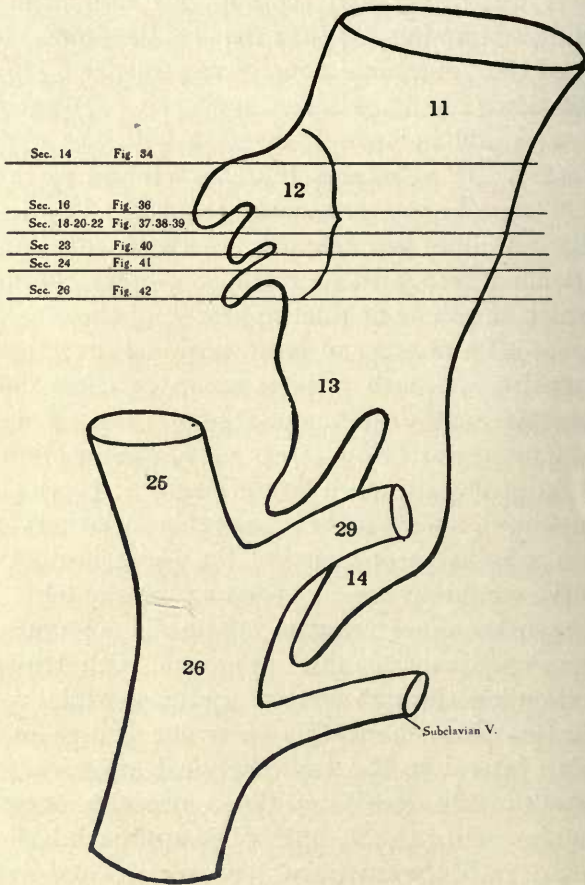
This embryo therefore presents for its age an unusually long and well developed thoracic duct approach, with triple terminal pouches, extending through sixteen sections, while at the same time it remains throughout this extensive course in the early position, viz.: lateral to the thyro-cervical artery (24) and the common trunk of the dorsal and dorso-medial tributaries of the internal jugular vein (16, 17, 46). The approach has not as yet arched mesad into the neuro-venous recess, and is hence in marked contrast to the succeeding stages presently to be described.

In a 13.5 mm. embryo, series 189, the development of the thoracic duct approach has gone much further, although the embryo, a litter mate of series 210, measures half a millimeter less.

The thoracic duct approach of the left jugular lymph sac

occupies sections 10 to 23 of slide vii in this embryo, and is shown in the dorsal view of the reconstruction, fig. 89, to which the individual sections following are referred for orientation.

The process arises in the usual situation from the dorso-medial aspect of the left jugular lymph sac and trends dorso-mesad



across the internal jugular vein (series 189, slide vii, section 10, fig. 43). In reference to the level of the common jugular confluence, which occurs in slide vii, section 26, the thoracic duct approach in series 189 arises more anteriorly from the jugular lymph sac than in the preceding series 210. Its extent and course

can be followed accurately in the successive sections shown in figs. 43 to 55 inclusive (series 189, slide vii, sections 10 to 22 inclusive).

In section 11 (fig. 44) the thoracic duct approach is separated by a thin endothelial partition from the lumen of the main jugular lymph sac, which it rejoins in the following section (section 12, fig. 45), only to again separate in the next section (section 13, fig. 46). In the meanwhile, the thoracic duct approach has arched from the lateral to the medial side of the internal jugular vein (25), closely applied to its dorsal surface, between the same and the thyro-cervical artery (24), and its blind terminal is beginning to bend ventro-mesad into the neuro-venous recess between the vagus-sympathetic strand (1, 22) and the internal jugular vein (25). In the next three sections (sections 14, 15, 16, figs. 47, 48 and 49) the thoracic duct approach becomes slightly dilated and diverticular (sections 15 and 16, figs. 48 and 49), but remains detached from the jugular sac. In section 15 (fig. 48) it appears subdivided, by endothelial partition, into two, and in section 16 (fig. 49) into three components. The protrusion which the common jugular confluence sends towards the jugular approach of the lymph sac and which forms the point of the subsequent invagination of the venous angle by the lymphatic tap, begins to appear in section 16 (fig. 49), and can be traced through the succeeding sections as a derivative of the lateral aspect of the main internal jugular vein, between it and the median surface of the jugular lymphatic sac.

In the six following sections, 17 to 22 inclusive, (figs. 50 to 55 inclusive) the proximal end of the process, connected with the sac, gradually recedes, while the blind distal end (12') continues to develop in the ventro-medial direction between the main vein (25, in fig. 55) and the dorsal and dorso-medial venous tributaries (16 and 17, fig. 55), dipping ventrad and approaching the interval between the internal jugular vein (25) and the sympathetic nerve (1), the site of its subsequent junction with the independently developed perivenous lymphatics of the ventral mediastinal and dorsal prevertebral regions, which together constitute the anlagen of this cephalic portion of the future thoracic duct. (cf. series 143, slides x and xi, figs. 172 to 183). The thoracic duct approach ends blindly in section 26 of slide vii. The

course and the relations to surrounding structures of the thoracic duct approach of this embryo are shown in the dorsal view of the reconstruction (fig. 89), containing the 50 sections of slide vii in a magnification of 225 diameters.

This view of the reconstruction presents from the lateral to the mesal border the following structures.

1. Caudal end of left jugular lymph sac, with the jugular (13) and subclavian (14) approaches, between which passes the ventral branch of the thyro-cervical artery (24).

The fifth spinal nerve (54) penetrates the lymph sac, while the sixth nerve lies on its lateral aspect with the primitive ulnar veno-lymphatic arching over it to enter the lymph sac.

2. The dorsal aspect of the internal jugular vein (25).

3. The main trunk and branches of the thyro-cervical artery (24).

4. The left superior intercostal vein (46), with the dorsal (16) and dorso-medial or prevertebral (17) tributaries, enters the dorso-medial angle of the internal jugular vein between the thyro-cervical artery (24) and

5. the double strand of the vagus (22) and sympathetic (1) nerves.

6. The thymus (21).

7. The aortic arch (7), with the left carotid artery (23) and the origin of the innominate artery (45).

The thoracic duct approach (12) arises by two branches from the dorso-medial aspect of the sac, turns caudo-mesad between the internal jugular vein and the ascending branch of the thyro-cervical artery, in front of the left superior intercostal vein, and approaches the recess formed between the main vein and the bundle of the nerves.

The reduplication of the origin of the thoracic duct approach from the jugular lymph sac present in this embryo is not unusual, and leads to the type of divided termination of the thoracic duct in the adult shown in fig. 56. The left jugular lymph sac (3) connects with the venous system at the common jugular angle (2) by a larger ventral and smaller dorsal jugular approach (18). It also taps at the jugulo-subclavian angle (19). The thoracic duct enters the dorsal aspect of the sac by a divided terminal, the lower branch connecting with the subclavian approach.

Finally an intermediate condition is seen in another 14 mm. embryo, series 122, of which selected sections are appended, from slides ix and x (figs. 57 to 62). Section 21 of slide ix (fig. 57) is taken at the level where the jugular lymph sac has divided for the passage of the thyro-cervical artery (24) into its two main terminal components, viz., the dorsally placed subclavian approach (14), and the ventrally situated jugular approach (13). The latter appears in the interval between the internal jugular vein (25) and the jugulo-cephalic trunk (29). These veins are approaching each other to form the common jugular confluence (fig. 39, 26), at which point the jugular approach usually makes the secondary permanent lymphatico-venous tap. The thoracic duct approach (12) arises from the dorsal aspect of the jugular approach by a relatively narrow pedicle and then hooks, as an elongated and expanded curved pouch, ventro-mesad over the dorsal aspect of the internal jugular vein towards the neuro-venous recess.

In section 28 of the same slide (fig. 58) the internal jugular and jugulo-cephalic veins have met in the common jugular confluence (26) which includes the jugular approach. Consequently the latter structure only appears in its ventral prolongation which is seen occupying the ventral angle of the common jugular junction (not labelled in fig. 58).

The subclavian approach (14) has moved relatively nearer to the dorsal surface of the main vein channel.

The blind terminal end of the thoracic duct approach (12) is seen dorsal to the common jugular vein, between a large dorso-medial tributary of the latter (16) mesally, and the thyro-cervical artery (24) laterally. Its pointed extremity is directed further ventro-mesad toward the interval between the sympathetic nerve (1) and the medial surface of the common jugular vein (26).

In section 7 of slide x (fig. 59) the terminal of the thoracic duct approach (12) has relatively receded and lies in the narrow interval between thyro-cervical artery (24) and common jugular vein (26).

In fig. 60 (section 9 of slide x) a large dorso-medial venous tributary (16, left superior intercostal vein) empties into the

dorso-medial angle of the common jugular trunk. The thoracic duct approach (12), occupying the same relative position as in the preceding figure, lies between this tributary and the thyro-cervical artery, dorsal to the main vein. Section 12 of slide x (fig. 61) shows the distal reduced end of the approach in this same situation. The subclavian approach of the jugular lymph sac (14) is reduced to a narrow longitudinal cleft on the dorso-lateral aspect of the main vein. This reduction is coincident with the derivation from the dorsal aspect of the subclavian approach of the primitive ulnar veno-lymphatic (31). This channel arches dorsad over the VIth spinal nerve (30), and appears in this section in its typical relation to this nerve. Finally in the succeeding section, 13 of slide ix, (fig. 62), the thoracic duct approach ends blindly. The structures shown in the section dorsal to the common jugular trunk are now encountered in the following order: mesally the terminal of one of the branches of the dorso-medial venous plexus (16); next the thyro-cervical artery (24); then the VIth segmental nerve (30), and, dorsal of this, the primitive ulnar veno-lymphatic (31).

The series of sections of this embryo shown here are interesting not only in respect to the behavior of the thoracic duct approach, but also in reference to the mutual relations of this structure and the terminals of the dorso-medial tributary venous plexus. These relations are to be discussed subsequently in considering, as whole, the evidence upon which some investigators have based their conception of direct venous origin of the lymphatic system by fusion of a number of separate elements detached from the main venous trunks (cf. *infra* p. 153.)

The variable appearance of the thoracic duct approach in the younger stages is perhaps best illustrated by the exaggerated development presented in a 13 mm. embryo (series 92), in which the process occupies the last thirteen sections of slide x, and the first fourteen sections of slide ix. Selected microphotographs of this series are shown in figs. 63 to 78. The embryo presents the largest and most dilated thoracic duct approach of any in my collection. Fig. 63 gives a topographical view of the region involved. The succeeding sections are cut down and confined

to the immediate neighborhood of the thoracic duct approach. Fig. 63 shows the sections of the internal jugular vein (25) and jugulo-cephalic trunk (29), approaching their point of union in the common jugular confluence. A large process of the jugular lymph sac (13) extends, as the jugular approach, into the interval between the main veins. Along the mesal aspect of the internal jugular vein (25), are placed the sympathetic (1), the vagus (22), the left common carotid artery (23), and, further ventrad, the thymus (21). The dorsal portion of the sac is about to form the subclavian approach (11, 14).

In fig. 64, the jugular approach (13) has entered more deeply into the narrowing interval between the internal jugular (25) and jugulo-cephalic trunks (29), and the sharply marked constriction between it and the remainder of the sac (subclavian approach, 14) foreshadows its coming separation from the latter. A protrusion of the dorso-medial angle of the jugular approach, adjacent to the internal jugular vein, indicates the beginning derivation of the thoracic duct approach (12).

In the succeeding section (fig. 65) the jugular approach (13) has separated from the subclavian approach (14) of the jugular lymph sac and thus cleared the path for the passage of the thyro-cervical artery (24) between the two cardinal divisions of the lymph sac, whose caudal terminations are represented by the jugular and subclavian approaches. The origin of the thoracic duct approach (12) from the dorso-medial angle of the jugular approach is now defined.

In the succeeding section (fig. 66) the triple termination of the jugular lymph sac, in the subclavian (14), jugular (13) and thoracic duct approaches (12), is accomplished, and the latter is beginning to extend mesad across the dorsal surface of the internal jugular vein. The main thyro-cervical artery is approaching the junction with its secondary dorsal branches.

In fig. 67 the jugular approach (13) has divided into the intermediate part between the internal (25) and jugulo-cephalic (29) veins, which is to establish the tap at the common jugular angle, and a ventral process which extends from the tap caudad over the ventral surface of the common jugular angle and vein.

The thoracic duct approach has enlarged, is partially subdivided (cf. p. 65, figs. 48 and 49, series 189) and its blind terminal extremity is reaching ventro-mesad into the angle between internal jugular vein and sympathetic (1). The thyro-cervical artery (24) lies between the subclavian and thoracic duct approaches, dorsal to the jugulo-cephalic trunk (29).

In fig. 68 the thoracic duct approach has further enlarged and is still subdivided into two compartments the terminal of which abuts directly against the sympathetic nerve. The jugular approach (13) communicates in this section with the internal jugular vein, while a narrower slit-like division continues further caudad toward the common jugular angle.

In fig. 69 the internal (25) and jugulo-cephalic (29) trunks are only separated from each other by a narrow septum containing the lumen of the slit-like prolongation of the jugular approach. Both in this and in the preceding section the ventral process of the jugular approach lies in the angle between the two veins, closely applied to their ventral surface.

The thoracic duct approach is a large sausage-shaped structure, curved over the dorsal surface of the internal jugular vein. The septum in its interior has disappeared and the process presents a clear lumen.

In fig. 70 (slide ix, section 2), the confluence of internal jugular and jugulo-cephalic trunks has taken place (26). The thoracic duct approach (12) has extended both ventro-mesad into an area of indifferently defined mesodermal spaces, mesad to the sympathetic nerve (1), and laterad toward the subclavian approach of the jugular sac (14), passing between common jugular vein (26) and thyro-cervical artery (24).

In section 5 of slide ix (fig. 71) the thoracic duct approach (12) appears as a long curved multilocular channel, which laterad reaches the subclavian approach of the jugular lymph sac, between the thyro-cervical artery (24) and common jugular vein (26), while its blind mesal extremity terminates just dorsal to the sympathetic-vagus strand. In the following section (fig. 72) the thoracic duct approach (12) connects with the subclavian approach (14) of the jugular lymph sac affording an instance of the gene-

sis of the reduplicated or multiple thoracic duct terminations occasionally encountered in the adult as above described (cf. p. 66, fig. 56, series 212, slide ix, figs. 34 to 42).

In fig. 73 (series 92, slide ix, section 9) the subclavian approach (14) is much reduced, and lies along the lateral aspect of the common jugular vein (26). Its connection with the thoracic duct approach (12) is plainly visible, passing between the main vein (26) and the thyro-cervical artery (24). Dorsal somatic and prevertebral venous tributaries (16), approaching the dorso-medial angle of the common jugular vein (26), intersect the course of the thoracic duct approach, and begin to divide the same into a medial and a lateral element. This division is completed in the following section (fig. 74) in which the united dorsal and prevertebral tributaries form a venous trunk of considerable size (16) which is approaching its confluence with the common jugular vein by passing between the lateral and medial components of the thoracic duct approach. In other words, the appearance of the thoracic duct approach in this and in the following sections is the expression of the ventro-mesal arched course of this structure across the fork or angle between the common jugular vein (26) and the terminal of its ventro-medial tributary plexus (16). The reconstructions shown in figs. 89, 90 and 91 indicate this topographical relationship clearly. The blind mesal end of the arched process (12) now lies mesal to the tributary vein (16) and dorsal to the sympathetic nerve (1). In the following section (section 11 of slide ix, fig. 75), the dorso-medial venous tributary (16) is elongated and close to the main vessel, while the reduced sections of the thoracic duct approach lie on either side of the same, as indicated by the forked leader (12). The subclavian approach (14), still prominent and connected with the medial section of the thoracic duct approach in the preceding section 10 (fig. 74), appears now in section 11 reduced to a detached small blind end (not labelled in the figure), close to the lateral wall of the main vein and ventral to the thyro-cervical artery (24). In the succeeding section 12 (fig. 76) the dorso-medial venous tributary (superior intercostal vein) enters the common jugular trunk. The lateral portion of the thoracic duct approach (not labelled

in the figure) is seen in the deep recess between this entrance, the main vein (26) and the thyro-cervical artery (24). The mesal end of the thoracic duct approach terminates blindly in this section just dorsal to the sympathetic nerve (1). In section 13 (fig. 77) the lateral terminal of the thoracic duct approach (12) can still be clearly seen in the interval between the wide dorsal opening of the combined somatic and prevertebral (17) tributary stem into the main vein (26) and the thyro-cervical artery (24). It appears very much reduced in the same situation in section 14 (fig. 78), and ends blindly in the following section. The last three sections of this series (figs. 76, 77 and 78) show the beginning of the jugulo-subclavian confluence.

In the later stages the thoracic duct approach has extended further ventro-mesad into the recess between the common jugular vein and the sympathetic nerve, and in this situation it eventually makes its connection with the two independently developed lymphatic channels of the anterior mediastinal region, viz., the preazygos segment of the thoracic duct dorsally, and the broncho-mediastinal trunk ventrally. The mode of this union is discussed below under a separate heading (cf. *infra*, p. 111). Figs. 79 to 82 show transverse sections of the left side of the lower cervical region in a 15 mm. cat embryo (series 245, slide xi, sections 24 to 27, $\times 225$), and fig. 90 gives the dorsal view of the reconstruction on the same scale of the thoracic duct approach and the related structures in the same embryo (slide xi, sections 1-44). In fig. 79 (slide xi, section 24) the terminal extremity of the thoracic duct approach (12) is seen between the common jugular vein (26) and the sympathetic nerve (1), having reached this situation by extending ventro-mesad across the dorsal tributary 16 (left superior intercostal vein), between this vessel and the main venous trunk.

The section is taken below the common jugular confluence, consequently the jugular approach is no longer seen, and the blind end of the thoracic duct approach appears isolated. The only other portion of the jugular lymph sac carried caudad to this level is the subclavian approach (14), seen on the lateral aspect of the main vein. The sequence of structures now successively

encountered along the mesal and dorsal aspects of the main common jugular vein (26) are the following, proceeding meso-laterad:

1. Thymus (21), with sub- and suprathymic venous tributaries entering the main vein.
2. Left common carotid artery (23).
3. Vagus nerve (22).
4. Sympathetic nerve (1).
5. Thoracic duct approach (12).
6. Dorsal somatic tributary of main vein (16). (Anlage of left superior intercostal vein).
7. Thyro-cervical artery (24).
8. Subclavian approach of jugular lymph sac (14), on the dorso-lateral aspect of the common jugular vein.

This order and relationship is maintained uniformly and clearly in the three succeeding sections shown in fgs. 80, 81 and 82.

In the last of these the dorsal venous tributary (16) enters the main common jugular channel.

The sections can be easily followed and oriented by reference to the dorsal view of the reconstruction shown in fig. 90. The same is composed of the plates of all 44 sections of slide ix of series 245. In this embryo the thoracic duct approach has already established its definite and permanent connection with the independently developed channel of the preazygos segment of the thoracic duct (35, in fig. 90), as described in detail below (cf. p. 111). The point of this junction is indicated in the reconstruction by the narrowing of the two spindles 12 and 35 (thoracic duct approach and preazygos segment of thoracic duct) to form an isthmus situated just cephalad of the leader marked 16-46.

The reconstruction includes the terminal of the jugular approach (13), with the origin from the same of the thoracic duct approach (12), and the entire subclavian approach (14) of the jugular lymph sac. The ventral division of the thyro cervical artery (24) passes forward between the jugular and subclavian approaches of the lymph sac, accompanied by a vein (not labelled in the figure) which is constantly found in this situation in the adult, draining from the prevertebral area into the common jugular trunk.

The dorsal and dorso-medial venous tributary plexus has united into the stem of the left superior intercostal vein (16-46). The reconstruction shows well the caudo-mesal turn of the thoracic duct approach (12) in the fork between the main vein (26) and the superior intercostal (16-46), accompanied by the mesal branch of the thyro-cervical artery. The terminal of the thoracic duct approach (12) meets and unites with the preazygos segment of the thoracic duct (35) on the mesal shoulder of the superior intercostal vein terminal, between it and the sympathetic nerve (1). This is one of the two types of topographical relationship encountered (cf. infra pp. 75, 76). Further laterad follow the vagus (22) and the sympathetic strand (1), intersecting at an acute angle. Then the left common carotid artery (23) and the thymus (21) with the perithymic venous plexuses.

Figs. 83 to 88 show the caudal end of the left jugular lymph sac and the thoracic duct approach in a selected series of sections from a 17 mm. cat embryo (series 142), all magnified 225 diameters, and fig. 91 gives the dorsal view of the reconstruction of this region from the same embryo.

These preparations are introduced here for the purpose of illustrating, in comparison with the preceding series (245) the second type of relationship which the thoracic duct approach may bear to the combined vagus-sympathetic strand.

Fig. 83 (series 142, slide x, section 13) shows the transection of the caudal end of the left jugular lymph sac in the interval between the internal jugular (25) and jugulo-cephalic (29) veins which are approaching their confluence to form the common jugular trunk.

The form of the jugular lymph sac already indicates its coming division into the three terminal "approaches," the jugular approach (14), the subclavian approach (13) and the thoracic duct approach (12). The latter covers the entire dorsal circumference of the internal jugular vein (25) and its termination points to the angular recess between the sympathetic (1) and vagus (22). Ventrad to the latter the field includes the thymus (21). The thyro-cervical artery is cut in several of its divisions, two of which are indicated by the forked leader 24.

In fig. 84 (series 142, slide x, section 16), the subclavian approach (14) has separated from the jugular approach (13) and the thyro-cervical artery (24) is passing meso-laterad between these two divisions. The origin of the thoracic duct approach (12) from the dorso-medial circumference of the jugular approach (13) is well shown in the section. The concavity of the jugulo-cephalic arch is expressed by the two cross-sections labelled 29.

In fig. 85 (series 142, slide x, section 8) the thoracic duct approach (12) has separated from the jugular approach (13). The curve of the process, with the concavity directed meso-caudad, gives the two cross sections of its lumen included in the forked leader 12. The termination of the thoracic duct approach has still further invaded the recess between sympathetic (1) and vagus (22) and a slight interval has developed between the two nerves.

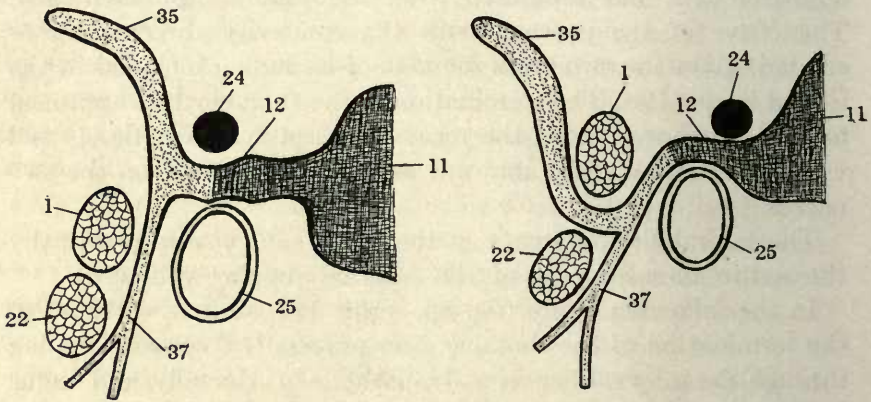
The lateral circumference of the vagus (22) covers practically the entire mesal aspect of the internal jugular vein (25).

In the following figure (fig. 86, series 142, slide x, section 20) the termination of the thoracic duct process (12) is seen slipping through the interval between sympathetic (1) dorsally and vagus (22) ventrally. Instead of lying therefore dorso-lateral to the sympathetic—as in the preceding series 245—the end of the thoracic duct approach in the present instance passes mesad on the *ventral* aspect of this nerve, between the same and the vagus. This relationship is also seen in the two succeeding figures, 87 and 88 (series 142, slide x, sections 22 and 24.)

We are dealing therefore apparently with two potential paths which the blind terminal of the thoracic duct approach may take in its passage from the jugular lymph sac mesad beyond the vagus-sympathetic line to the upper mediastinal region, where it establishes eventually its secondary connections with the preazygos segment of the thoracic duct and with the broncho-mediastinal trunk. In one type (illustrated by the sections and reconstructions of series 245 (figs. 79 to 82, fig. 90) the process dips, after passing between the left superior intercostal and main jugular vein at an acute angle, caudad on the lateral side of the sympathetic strand (fig. 90).

In the other type, illustrated by series 142 (figs. 83 to 88; fig. 91) the thoracic duct approach, maintaining the identical relation to left superior intercostal and common jugular veins, gains the ventro-medial aspect of the sympathetic cord, by passing obliquely between the same and the vagus.

In schematic cross section these two conditions may be illustrated by the accompanying text figures:



In regard to the remaining structures fig. 87 (series 142, slide X, section 22) shows, by comparison with the preceding figure 86, the tap of the jugular approach into the internal jugular vein (25) just above the confluence with the jugulo-cephalic trunk (29), and the prolongation of its ventral process (13) over the ventral aspect of the common jugular angle. Fig. 88 (series 142, slide X, section 24) shows the confluence of the internal jugular (25) and jugulo-cephalic (29) veins fully established, and gives a very clear picture of the relation which the ventral prolongation (13) from the jugular approach of the lymph sac bears to the common jugular angle. In both figs. 87 and 88 the dorsal venous tributary (sup. intercostal vein anlage) is indicated by the leader 16. It enters the main vein in section 3 of the following slide (xi). Fig. 91 gives the dorsal view of the reconstruction of the vascular and nervous structures of the left side in slides

x and xi of this embryo, carried caudad to the level of the vertebral vessels (41, 42). Comparison with fig. 90 will show the correspondence of the two preparations in all essential points and will accentuate the above described difference in the course of the thoracic duct approach (12) and the preazygos segment of the thoracic duct (35) in relation to the vagus-sympathetic strand.

It is readily seen, in comparing the reconstructions of the two older stages just described (figs. 90 and 91) with that of the earlier embryo shown in fig. 89, that the latter, in the construction of the terminal of its thoracic duct approach, combines potentially the ability of developing into either one of the two more advanced conditions just described. The process which the thoracic duct approach turns nearly horizontally mesad into the interval between vagus and sympathetic is present in all three reconstructions. In many embryos, as will appear presently in describing the critical stages in detail, the thoracic duct approach appears to make its connection with the independently developed anlagen of the preazygos portion of the thoracic duct in this situation, and continued development will lead to the condition seen in series 142 (fig. 91). If, on the other hand, the caudal extremity of the thoracic duct approach of the 13.5 mm. embryo (fig. 89) joins the independently developed lymphatic anlagen at the root of the left superior intercostal vein and along the common jugular lateral to the sympathetic line, the resulting relation will be as seen in series 245 (fig. 90).

These observations are further supported by comparison of the preparations just described with the corresponding portions of the two reconstructions shown in figs. 170 and 171.

Fig. 170 (series 218) shows the stage in a 15 mm. embryo just prior to the junction of the thoracic duct approach with the independently formed preazygos segment of the thoracic duct (35). The latter is in its greater part already a distinct and considerable segment of the future continuous duct channel. Between its blind cephalic extremity and the blind caudal end of the thoracic duct approach (12) are a number of scattered and still separate lymphatic anlagen along the common jugular and innominate veins on each side of the sympathetic line. By continued exten-

sion of these as yet isolated lymphatic anlagen the still lacking intermediate bondpiece will be produced, which, by union of its cephalic extremity with the thoracic duct approach of the jugular lymph sac and junction of its caudal end with the cephalic terminal of the preazygos segment of the thoracic duct (35), will produce the continuous and uninterrupted lymph channel of the succeeding stage (series 143, 15.5 mm. embryo, fig. 171). A study of the reconstruction of series 218 makes it evident that the opportunity still exists of developing this final junction either on the dorso-lateral or ventro-medial side of the sympathetic cord, for the lymphatic anlagen exist in both situations. The end of the thoracic duct approach of this embryo rides with a well marked lateral and medial prolongation in the fork formed by the entrance of the left superior intercostal vein (16-46) into the common jugular. The lateral process, carrying the leader 12 in the figure, is in position to join the line of separate lymphatic anlagen extending caudad on the lateral side of the sympathetic, and a prominent cephalic process of the already established segment of the preazygos lymph channel extends cephalo-laterad across the dorsal surface of the nerve, as if to meet the lymphatic line just described. If development had proceeded along this line in this embryo, the condition seen in series 245 might have resulted, with the modification of swinging the thoracic duct approach to the lateral instead of to the medial side of the left superior intercostal vein, but carrying the thoracic duct along the dorso-lateral aspect of the sympathetic nerve. In this case the large separate lymphatic anlage labelled 35' in fig. 170 would take an important share in building up the resulting lymph channel. On the other hand, the definite connection with the preazygos segment of the thoracic duct might have been established through the ventro-medial terminal prolongation of the thoracic duct approach. A piece of the sympathetic nerve has been removed in the reconstruction in order to show the position of this structure, in the interval between sympathetic nerve (1) and vagus (22). The long slender prolongation extending forward between vagus (22) and common carotid artery (23) is the path of junction for the ventral or broncho-mediastinal lymphatic trunk. I am under

the strong impression that the observed variations in the relation of the embryonic thoracic duct approach to the sympathetic nerve hinge largely for their production upon the share which the broncho-mediastinal duct is to take in individual cases in the establishment of the preazygos segment of the thoracic duct channel. (Compare relations of 35 and 37 in the schematic cross sections shown above in the text figures.)

If now this ventro-medial end piece of the thoracic duct approach had effected its junction with the preazygos segment of the thoracic duct along the line of the lymphatic anlagen on the medial side of the sympathetic and in the interval between this strand and the vagus, then the individual condition already described in series 142 (fig. 91) would have resulted.

This same topographical relationship of sympathetic nerve and lymph channel is also seen in the 15.5 mm. embryo, series 143, shown in reconstruction from the right side in Fig. 171. The thoracic duct approach (12) intersects the sympathetic nerve (1) on its ventro-medial aspect at an acute angle to establish its connection with the cephalic end of the preazygos segment of the thoracic duct (35). This type appears the prevalent one in the embryos in my collection.

I am strongly inclined, on the evidence of the embryos of my collection, to regard the development of the thoracic duct approach of the jugular lymph sac as occupying three distinct chronological stages:

1. Early stage. Embryos of 13-13.5 mm.
Series 92-13. mm.
Series 189-13.5 mm.

In this period the thoracic duct approach appears large, at times multilocular, and shares the redundancy and capacious lumen which characterizes the entire jugular lymph sac in the earlier genetic period.

2. Intermediate stage. Embryos of 14 mm.
Series 210-14 mm.
Series 212-14 mm.
Series 122-14 mm.

The sac, as a whole, and the thoracic duct approach in particu-

lar, condenses and becomes more clearly defined against the surrounding mesoderm. The multilocular character due to remnants of the capillary walls in the interior, disappears and the approach obtains a clear and clean-cut lumen. The entire structure appears to contract somewhat on itself and develops more distinct walls. The recession, during which the thoracic duct approach occupies a relatively smaller territory is succeeded by

3. Final stage. Embryos of 15-17 mm.

Series 245—15 mm.

Series 218—15 mm.

Series 143—15.5 mm.

Series 142—17 mm.

In this period the sac, through its digitate processes, establishes the definite connections with the independently formed systemic extraintimal lymphatic channels. Specifically the thoracic duct approach of the sac unites secondarily with the preazygos segment of the thoracic duct and with the broncho-mediastinal lymphatic trunk.

While I do not insist on the above outlined details in the chronological order of development of the thoracic duct approach, the embryos of my collection certainly tend to support the view expressed. Thus the 13 mm. embryo (series 92) offers the highest degree of expansion of the thoracic duct approach. The structure recedes and diminishes somewhat in extent in the 13.5 mm. stage (series 189), appears uniformly further reduced and shortened in the 14 mm. embryos (series 210, 212, 122), and finally, from the 15 and 15.5 mm. stages on, makes its definite connections with the preformed independently developed channels of the thoracic and broncho-mediastinal ducts.

In this entire genetic process there is not the slightest indication of an extension of lymphatic trunks from the jugular sac or from its thoracic duct approach toward the periphery. There is absolutely no suggestion of so-called "budding" or "sprouting," or of any other form of *centrifugal* extension of lymphatic vessels. On the contrary, the sac as a whole, and the processes therewith connected, recede actually for a time, and only then establish a secondary junction with the independently developed

general systemic lymphatic channels. These have in the meanwhile formed along and around the temporary embryonic veins, as the result of the confluence of large numbers of extraintimal perivenous spaces in the sense previously defined in detail. Their line of further growth, extension and union with each other is altogether *centripetal*, from the outlying regions *toward* the jugular lymph sacs, and their union with the latter's processes is the last and final step in the definite organization of the lymphatic system.

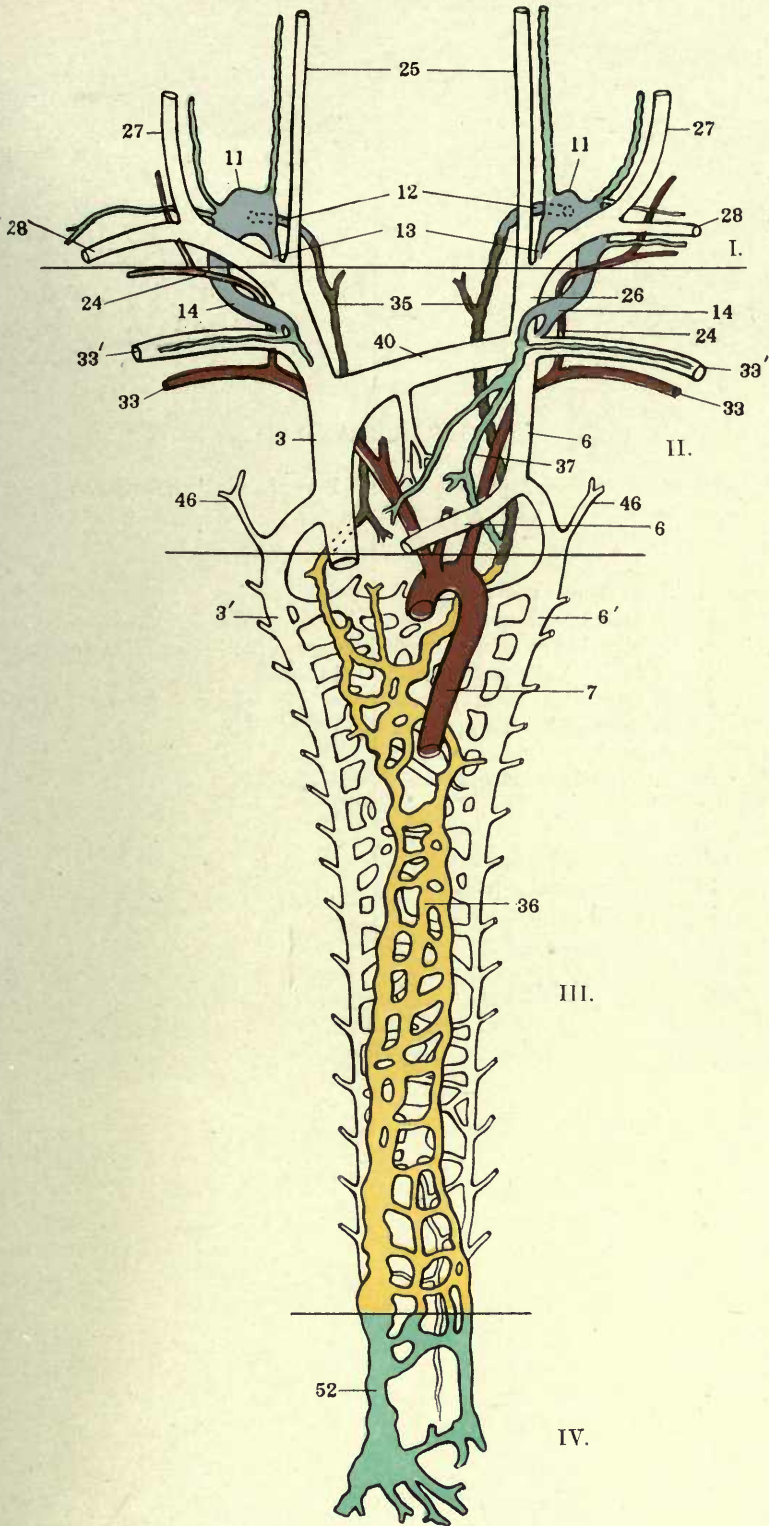
PART II, PLATES

FIGURES 29 TO 91

FIGURE 29

29 Color schema, showing the four genetic segments of the thoracic ducts (I, II, III, IV) in the cat, and their relations to the embryonal veins, the broncho-mediastinal trunk (37), and the jugular lymph sacs (II).

- 3' Precardinal or precava of right side.
- 3 Right azygos vein, thoracic portion.
- 6 Precardinal or precava of left side.
- 6' Left azygos vein, thoracic portion.
- 7 Aorta.
- 11 Jugular lymph sac.
- 12 Jugular lymph sac, thoracic duct approach.
- 13 Jugular lymph sac, jugular approach.
- 14 Jugular lymph sac, subclavian approach.
- 24 Thyrocervical artery.
- 25 Internal jugular vein.
- 26 Common jugular vein.
- 27 External jugular vein.
- 28 Cephalic vein.
- 33 Subclavian artery.
- 33' Subclavian vein.
- 35 Thoracic duct, preazygos segment.
- 36 Thoracic duct, azygos segment.
- 37 Broncho-mediastinal duct.
- 40 Innominate vein.
- 46 Left superior intercostal vein.
- 52 Postazygos segment of thoracic duct.

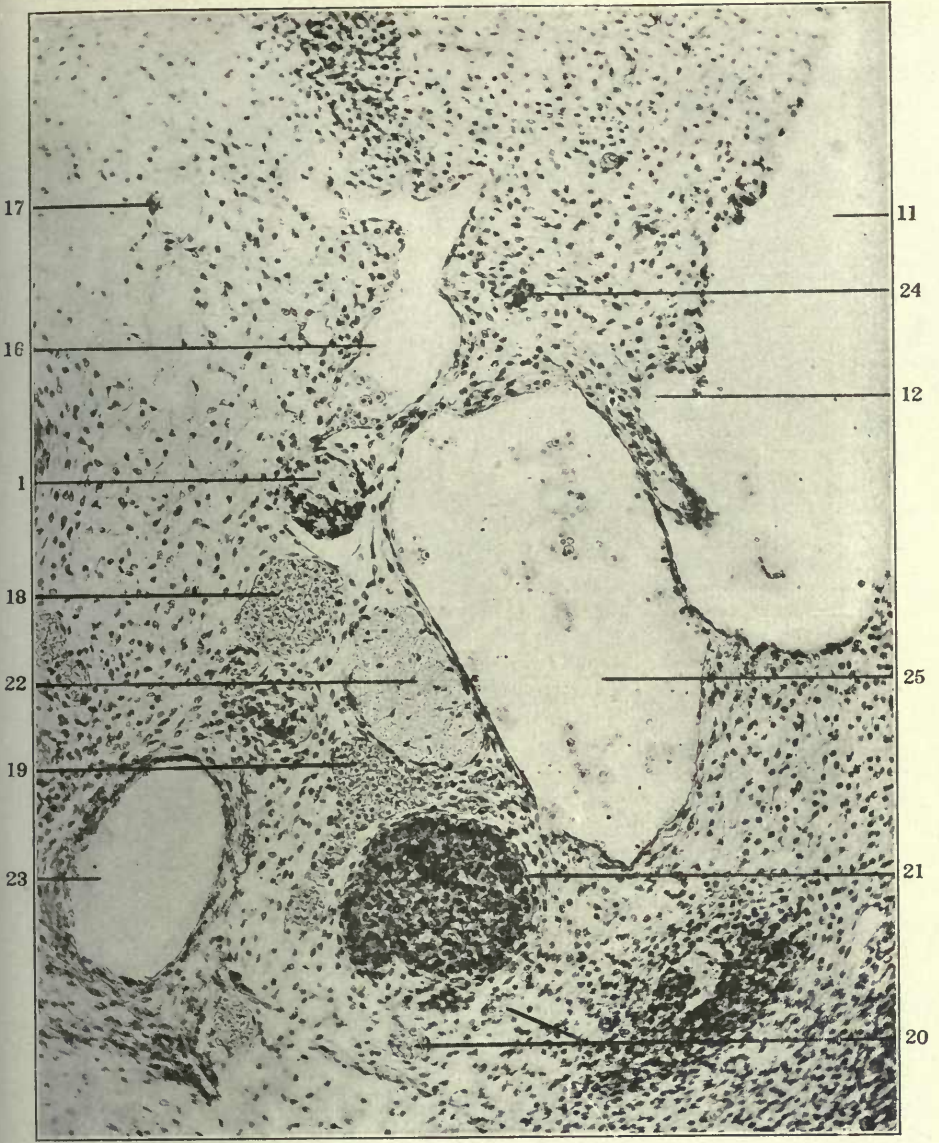

FIGURES 30 AND 31

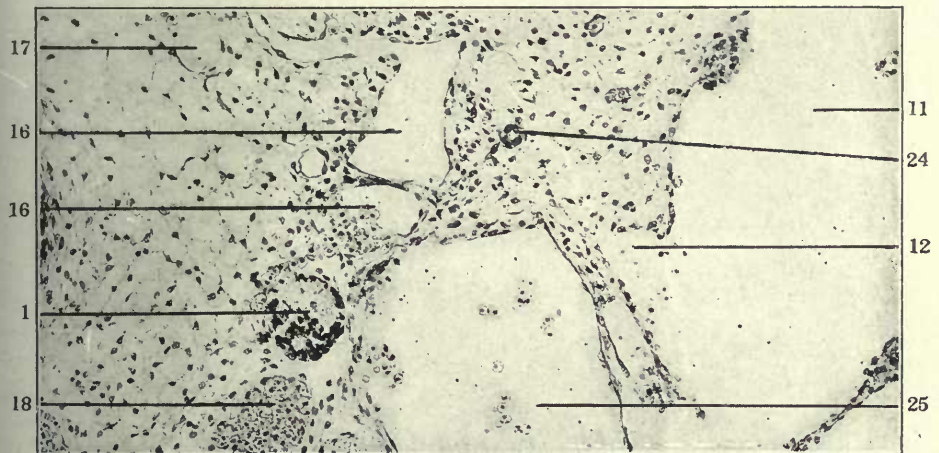
30 Transverse section through left side of lower cervical region in a 14 mm. cat embryo (series 210, slide VIII, section 39), $\times 225$.

31 Same, section 40.

- 1 Sympathetic nerve.
- 11 Jugular lymph sac.
- 12 Jugular lymph sac, thoracic duct approach.
- 16 Dorso-medial somatic venous tributaries.
- 17 Prevertebral venous plexus.
- 18 Peritracheal venous plexus.
- 19 Suprathymic venous plexus.
- 20 Subthymic venous plexus.
- 21 Thymus.
- 22 Vagus.
- 23 Left carotid artery.
- 24 Thyrocervical artery.
- 25 Internal jugular vein.



30

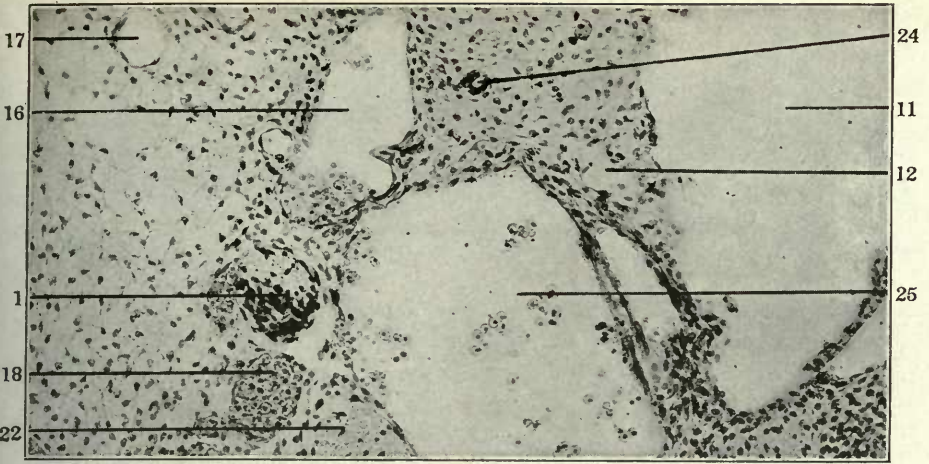


31

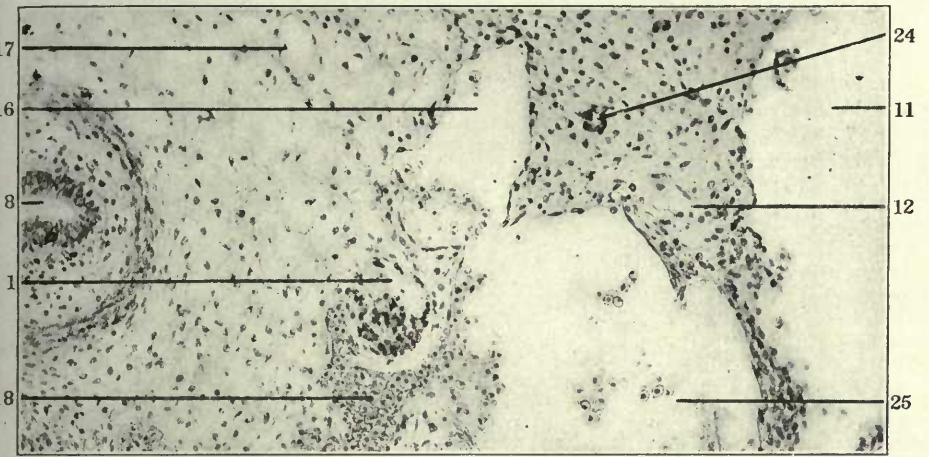
FIGURES 32, 33 AND 34

- 32 Same, section 41.
33 Same, section 42.
34 Transverse section through left side of lower cervical region in a 14 mm. cat embryo (series 212, slide IX, section 24), $\times 200$.

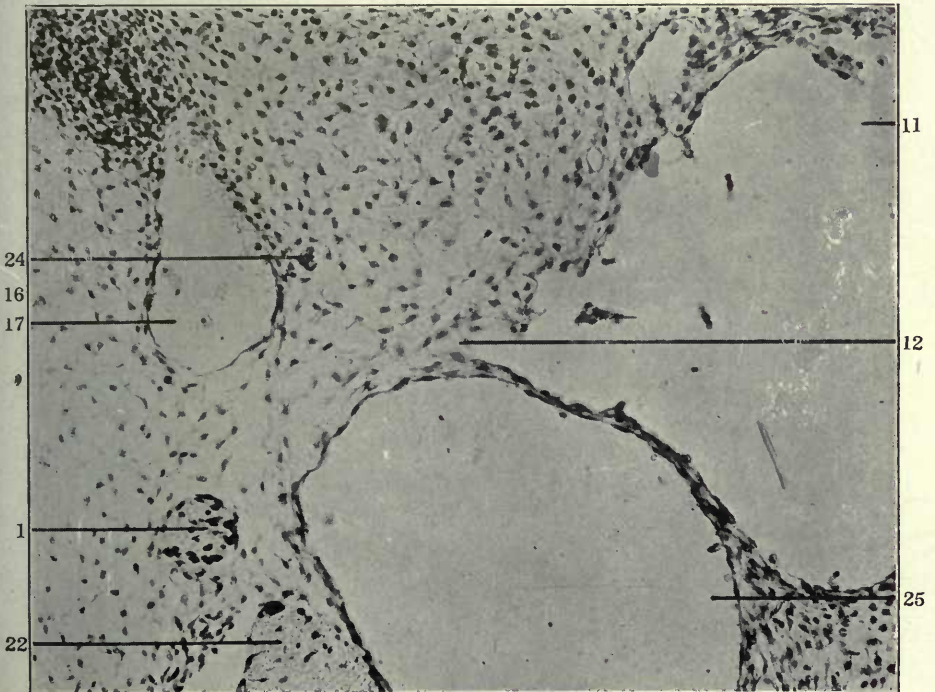
- 1 Sympathetic nerve.
8 Oesophagus.
11 Jugular lymph sac.
12 Jugular lymph sac, thoracic duct approach.
16 Dorso-medial somatic venous tributaries.
17 Prevertebral venous plexus.
18 Peritracheal venous plexus.
22 Vagus.
24 Thyrocervical artery.
25 Internal jugular vein.



32



33

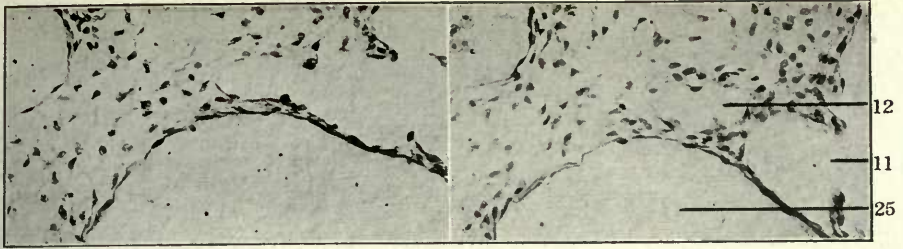


34

FIGURES 35 TO 41.

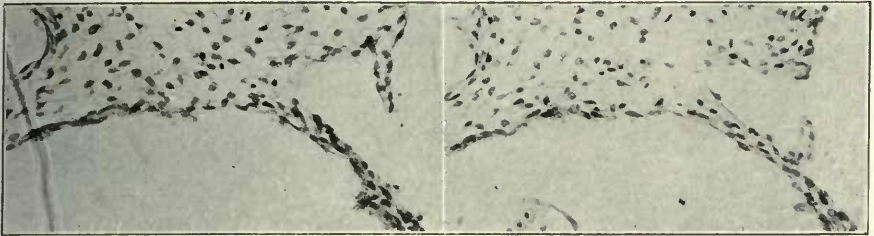
- 35 Same, section 15.
- 36 Same, section 16.
- 37 Same, section 17.
- 38 Same, section 20.
- 39 Same, section 22.
- 40 Same, section 23.
- 41 Same, section 24.

- 1 Sympathetic nerve.
- 11 Jugular lymph sac.
- 12 Jugular lymph sac, thoracic duct approach.
- 16 Dorso-medial somatic venous tributaries.
- 22 Vagus.
- 24 Thyrocervical artery.
- 25 Internal jugular vein.
- 46 Left superior intercostal vein.



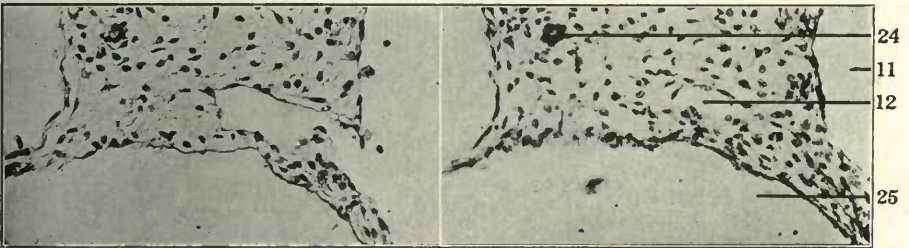
35

36



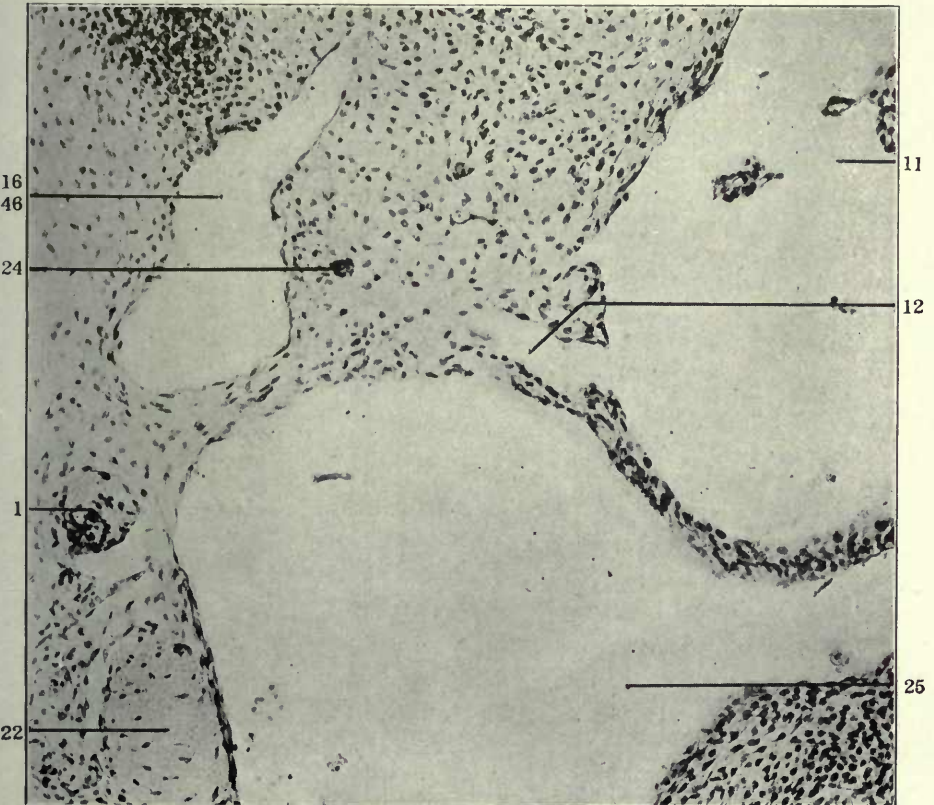
37

38



39

40



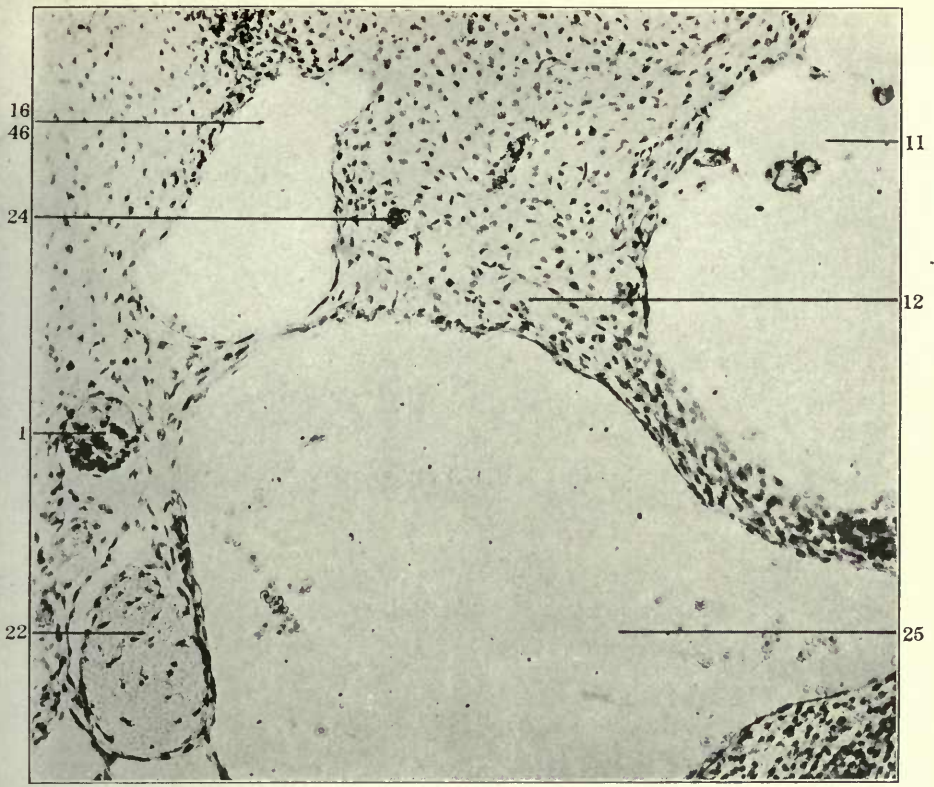
41

FIGURES 42 AND 43

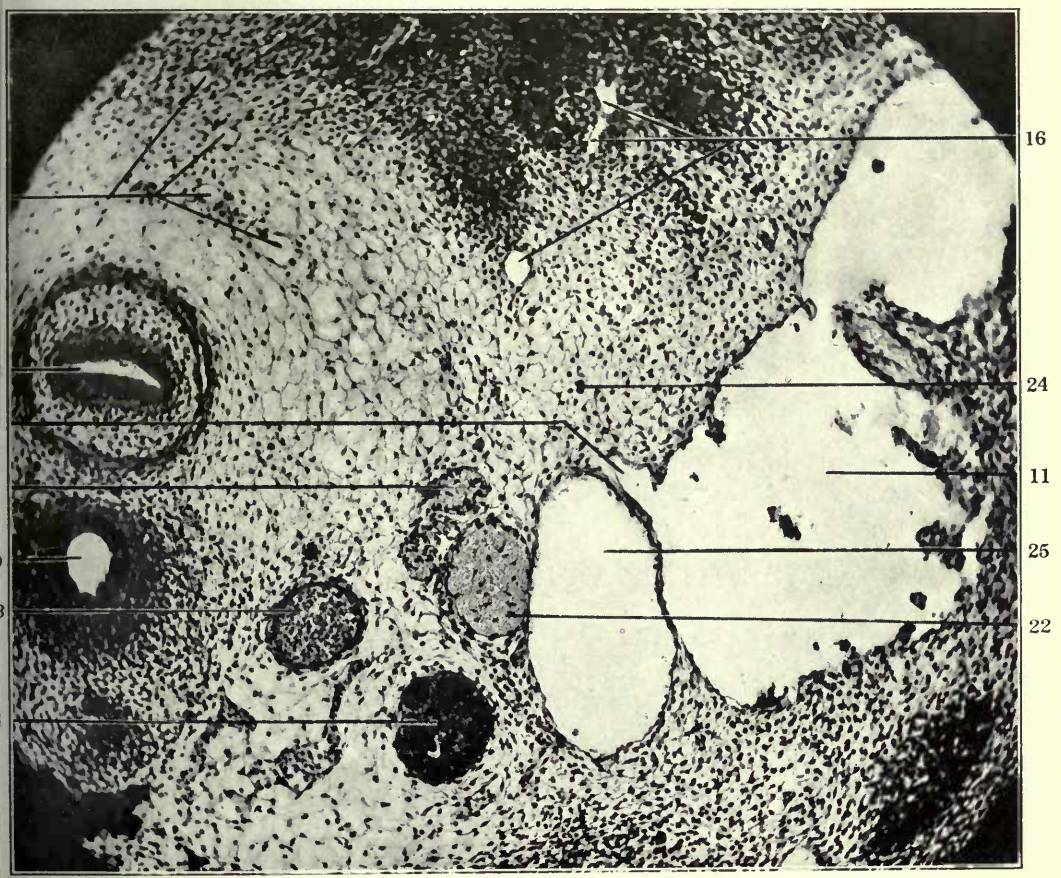
42 Same, section 26.

43 Transverse section through left side of lower cervical region of a 13.5 mm. cat embryo (series 189, slide VII, section 10), $\times 150$.

- 1 Sympathetic nerve.
- 8 Oesophagus.
- 9 Trachea.
- 11 Jugular lymph sac.
- 12 Jugular lymph sac, thoracic duct approach.
- 16 Dorso-medial somatic venous tributaries.
- 17 Prevertebral venous plexus.
- 21 Thymus.
- 22 Vagus.
- 23 Left carotid artery.
- 24 Thyrocervical artery.
- 25 Internal jugular vein.
- 46 Left superior intercostal vein.



42

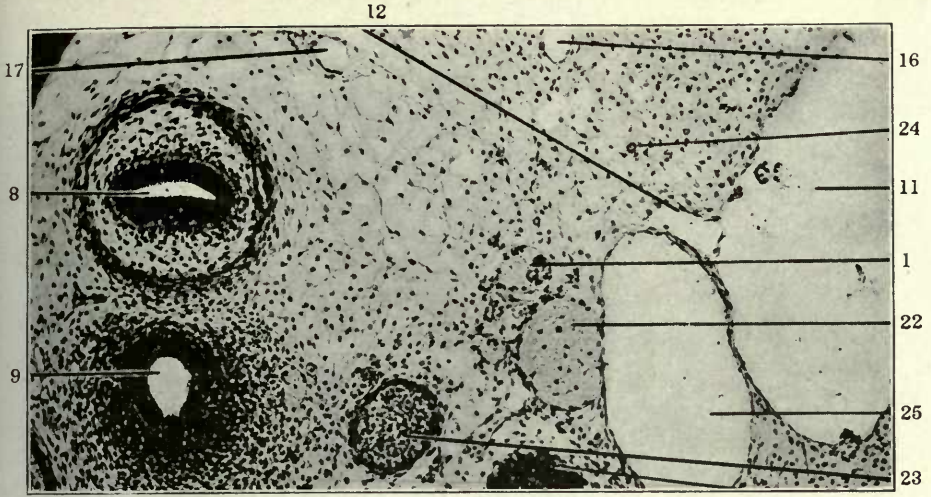


43

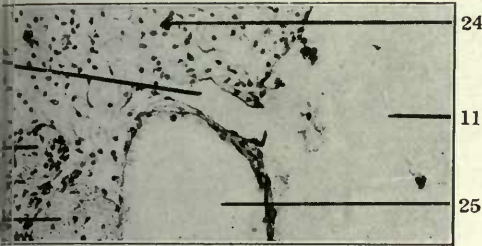
FIGURES 44 TO 49

- 44 Same, section 11.
- 45 Same, section 12.
- 46 Same, section 13
- 47 Same, section 14.
- 48 Same, section 15.
- 49 Same, section 16.

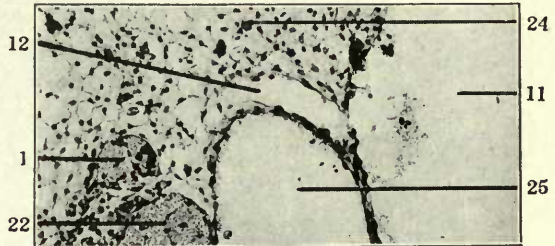
- 1 Sympathetic nerve.
- 8 Oesophagus
- 9 Trachea.
- 11 Jugular lymph sac.
- 12 Jugular lymph sac, thoracic duct approach.
- 16 Dorso-medial somatic venous tributaries.
- 17 Prevertebral venous plexus.
- 22 Vagus.
- 23 Left carotid artery.
- 24 Thyrocervical artery.
- 25 Internal jugular vein.
- 29 Jugulo-subclavian trunk



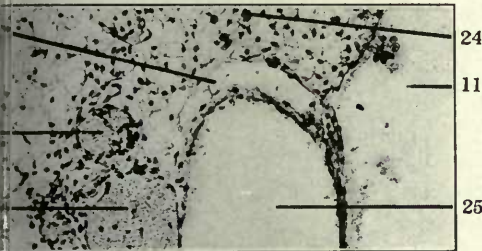
44



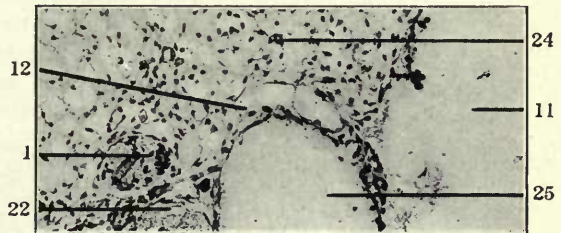
45



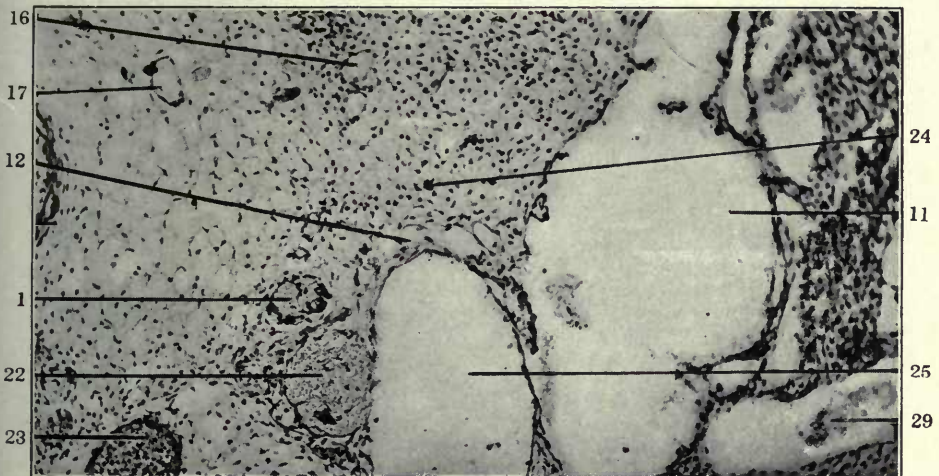
46



47



48

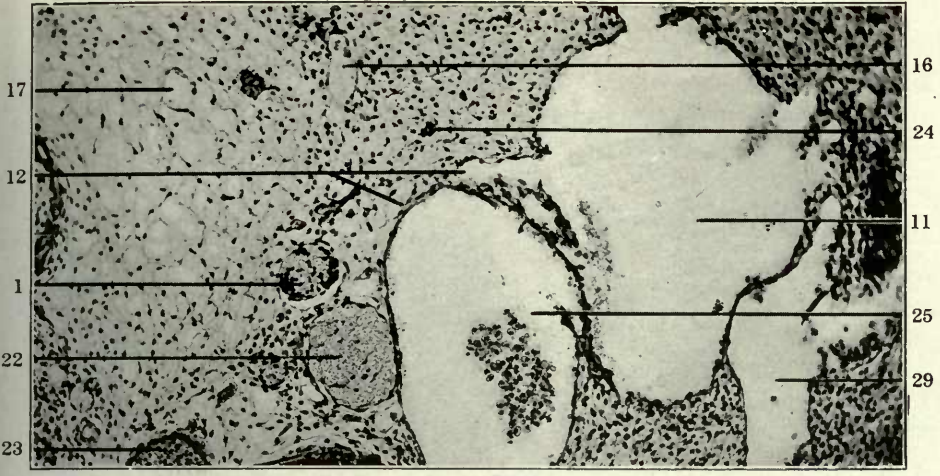


49

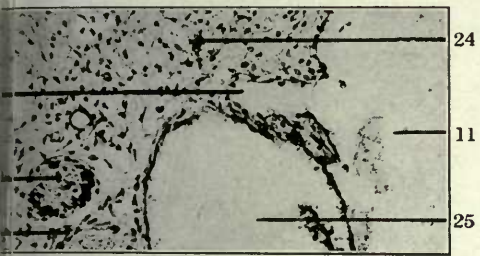FIGURES 50 TO 55

- 50 Same, section 17.
- 51 Same, section 18.
- 52 Same, section 19.
- 53 Same, section 20.
- 54 Same, section 21.
- 55 Same, section 22.

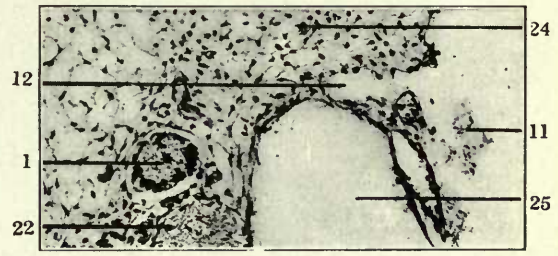
- 1 Sympathetic nerve.
- 8 Oesophagus.
- 11 Jugular lymph sac.
- 12 Jugular lymph sac, thoracic duct approach.
- 16 Dorso-medial somatic venous tributaries.
- 17 Prevertebral venous plexus.
- 21 Thymus.
- 22 Vagus.
- 23 Left carotid artery.
- 24 Thyrocervical artery.
- 25 Internal jugular vein.
- 29 Jugulo-subclavian trunk.



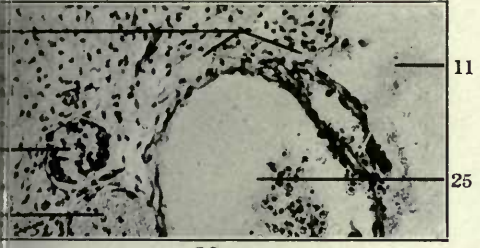50



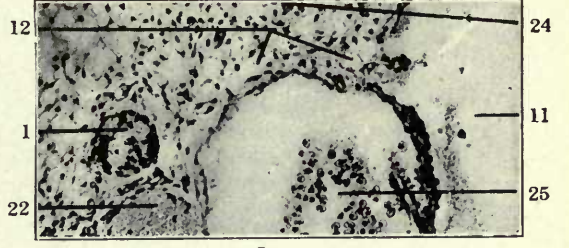
51



52

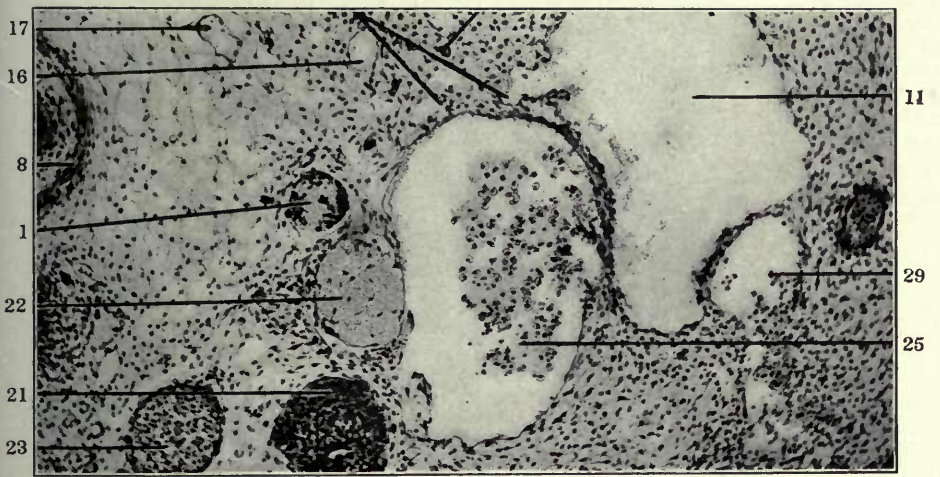


53



54

12 12 24

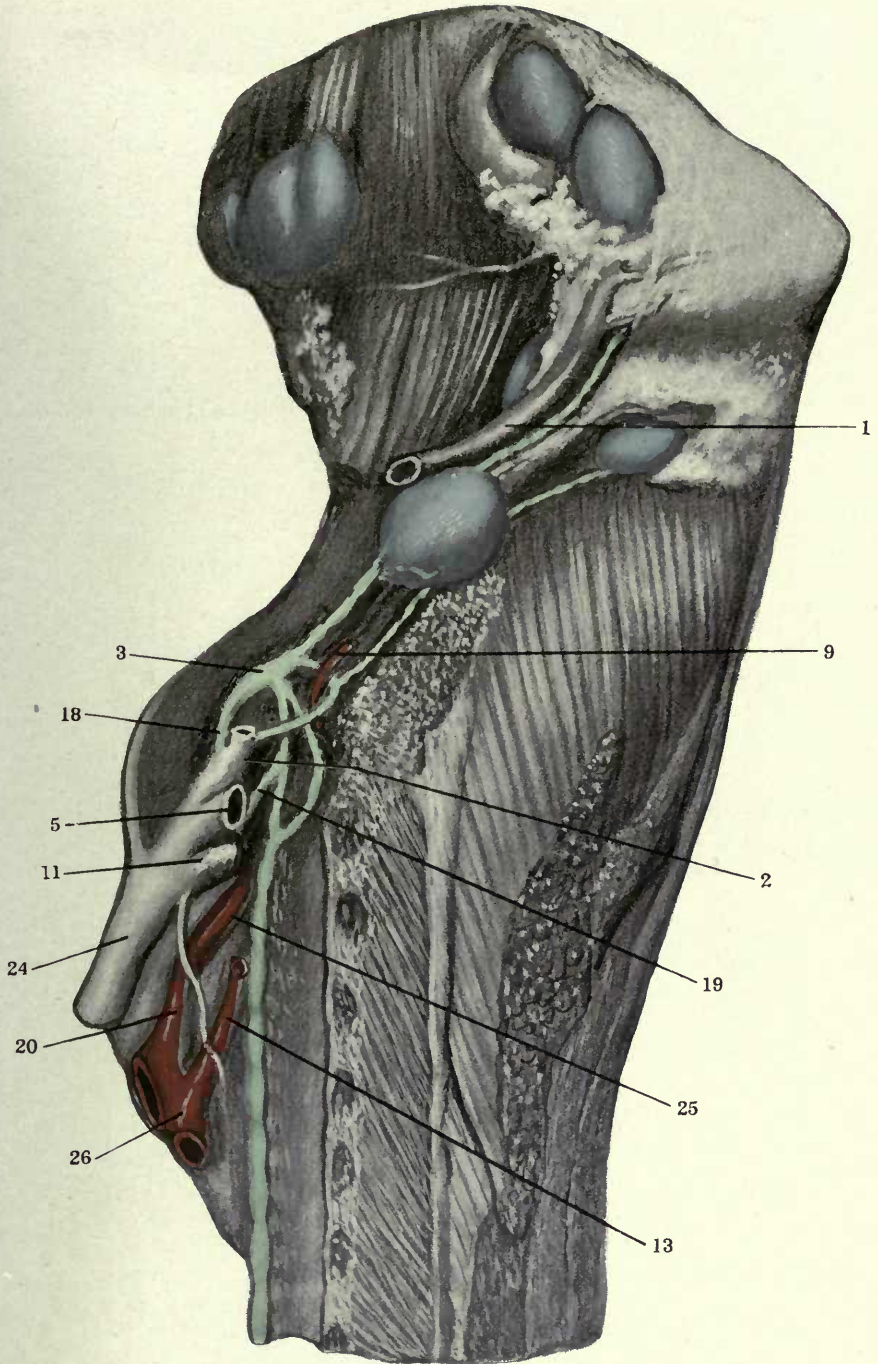


55

FIGURE 56

56 Dissection of left cervical region of adult cat, showing reduplication of thoracic duct approach of left jugular lymph sac (Adult No. S3).

- 1 External jugular vein and lymphatics.
- 2 Common jugular vein.
- 3 Jugular lymph sac.
- 5 Subclavian vein.
- 9 Thyrocervical artery.
- 11 Vertebral vein.
- 13 Left subclavian artery.
- 18 Jugular approach and tap.
- 19 Subclavian approach and tap.
- 20 Innominate artery.
- 24 Vena cava superior.
- 25 Left carotid artery.
- 26 Aorta.

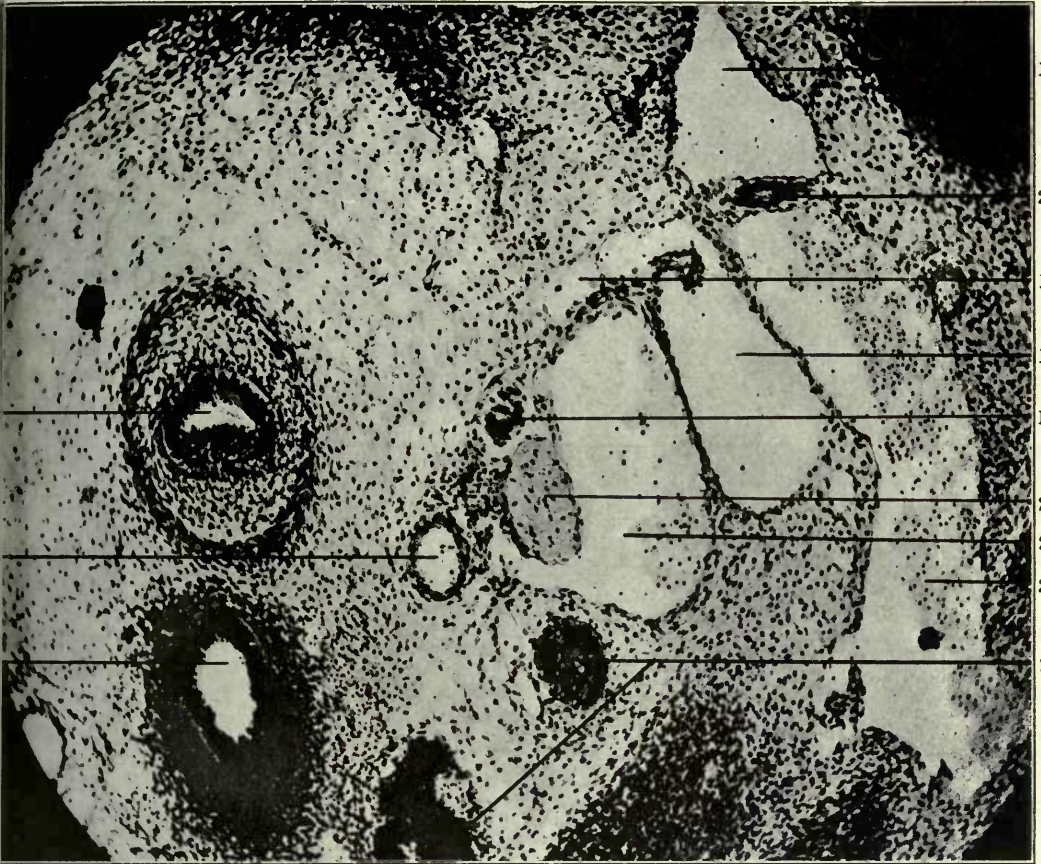


FIGURES 57 AND 58

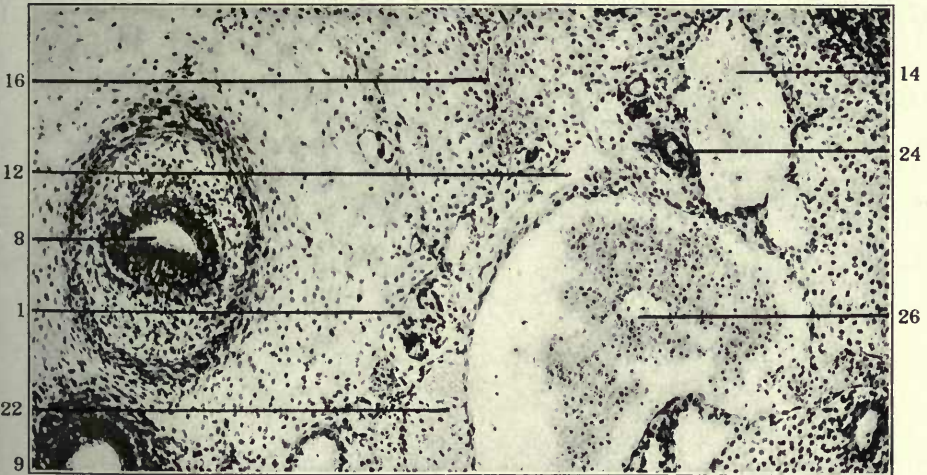
57 Transverse section through left lower cervical region of a 14 mm. cat embryo (series 122, slide IX, section 21), $\times 150$.

58 Same, section 28.

- 1 Sympathetic nerve.
- 8 Oesophagus.
- 9 Trachea.
- 12 Jugular lymph sac, thoracic duct approach.
- 13 Jugular lymph sac, jugular approach.
- 14 Jugular lymph sac, subclavian approach.
- 16 Dorso-medial somatic venous tributaries.
- 21 Thymus.
- 22 Vagus.
- 23 Left carotid artery.
- 24 Thyrocervical artery.
- 25 Internal jugular vein.
- 26 Common jugular vein.
- 29 Jugulo-subclavian trunk.



57



58

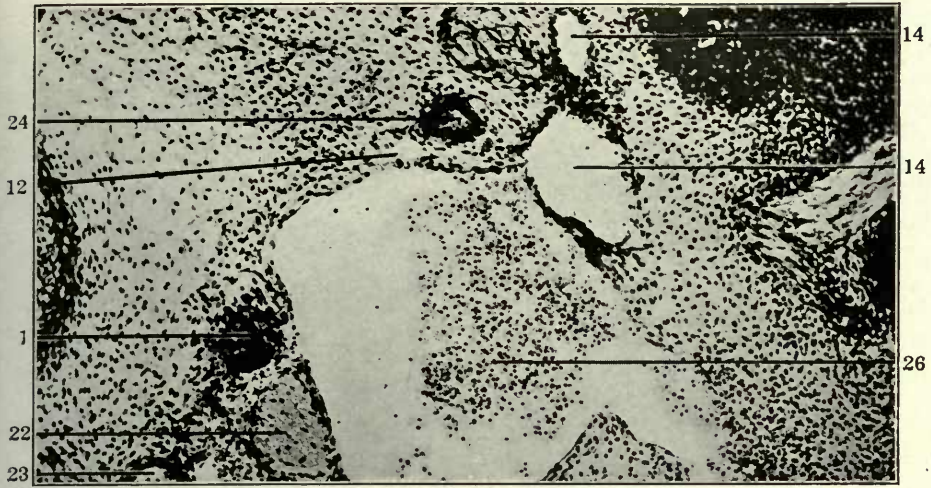
FIGURES 59, 60 AND 61

59 Same, slide X, section 7.

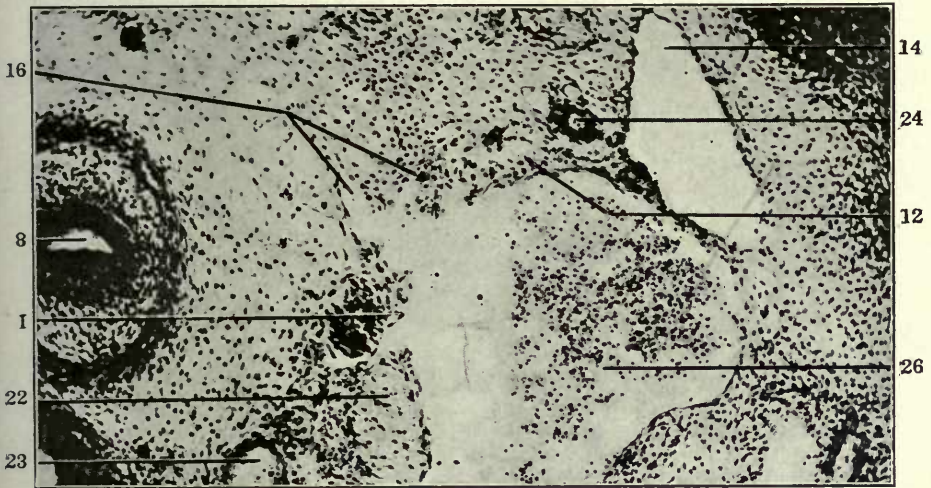
60 Same, section 9.

61 Same, section 12.

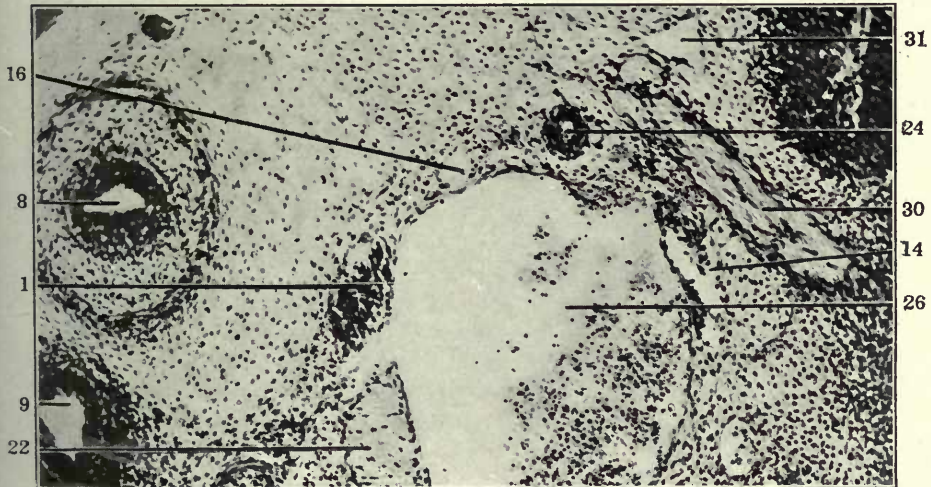
- 1 Sympathetic nerve.
- 8 Oesophagus.
- 9 Trachea.
- 12 Jugular lymph sac, thoracic duct approach.
- 14 Jugular lymph sac, subclavian approach.
- 16 Dorso-medial somatic venous tributaries.
- 22 Vagus.
- 23 Left carotid artery.
- 24 Thyrocervical artery.
- 26 Common jugular vein.
- 30 Sixth spinal nerve.
- 31 Primitive ulnar veno-lymphatic.



59



60



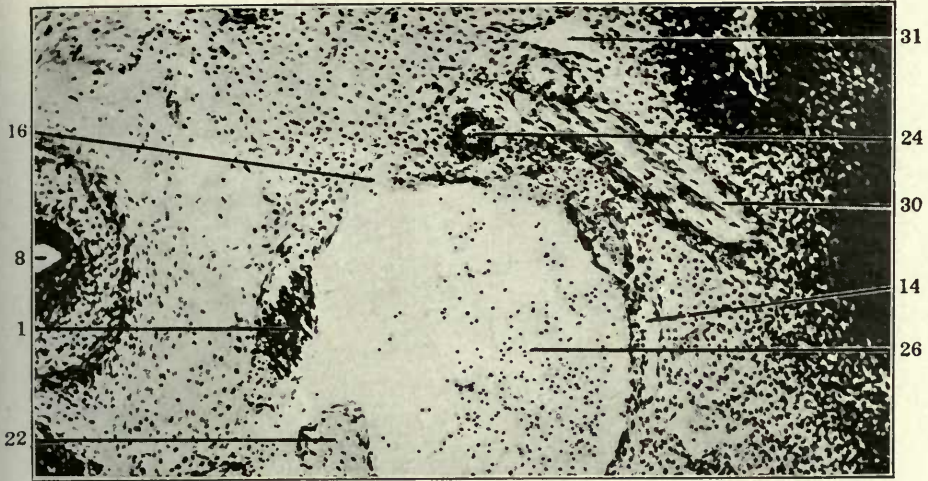
61

FIGURES 62 AND 63

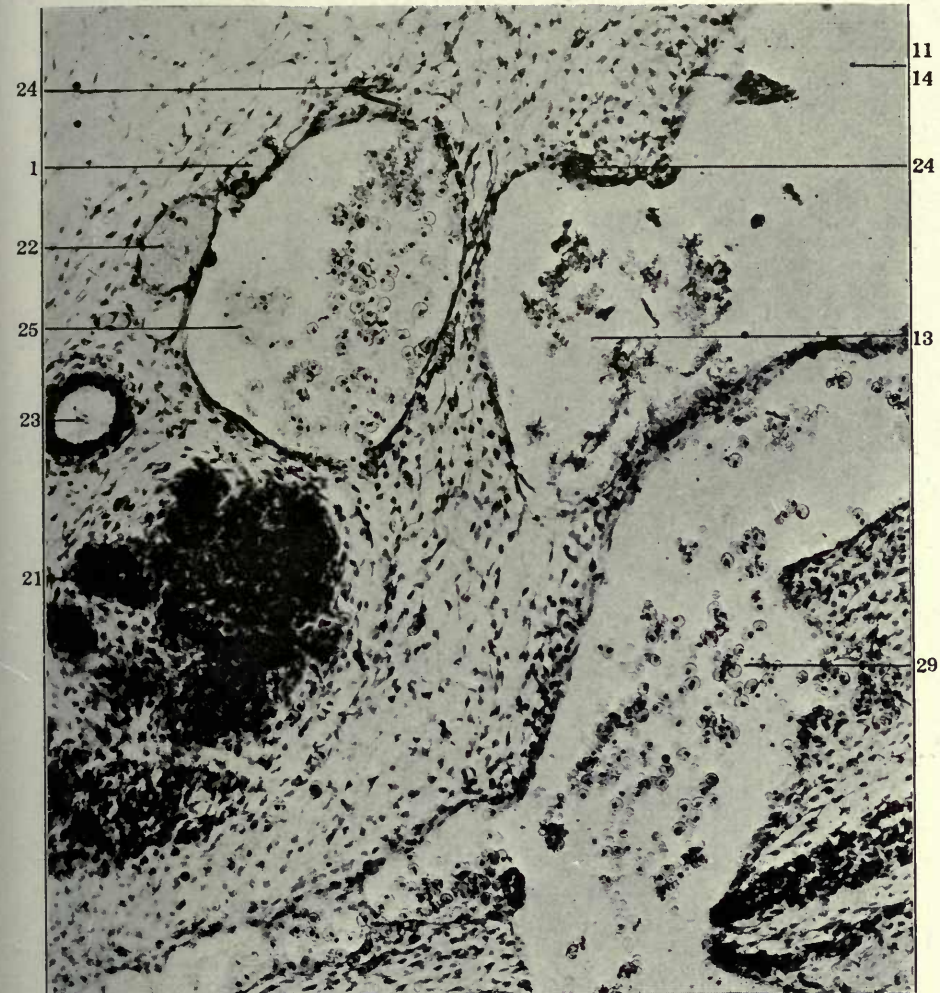
62 Same, section 13.

63 Transverse section of left lower cervical region in a 13 mm. cat embryo (series 92, slide X, section 27), \times 225.

- 1 Sympathetic nerve.
- 8 Oesophagus.
- 11 Jugular lymph sac.
- 13 Jugular lymph sac, jugular approach.
- 14 Jugular lymph sac, subclavian approach.
- 16 Dorso-medial somatic venous tributaries.
- 21 Thymus.
- 22 Vagus.
- 23 Left carotid artery.
- 24 Thyrocervical artery.
- 25 Internal jugular vein.
- 26 Common jugular vein.
- 29 Jugulo-subclavian trunk.
- 30 Sixth spinal nerve.
- 31 Primitive ulnar veno-lymphatic.



62

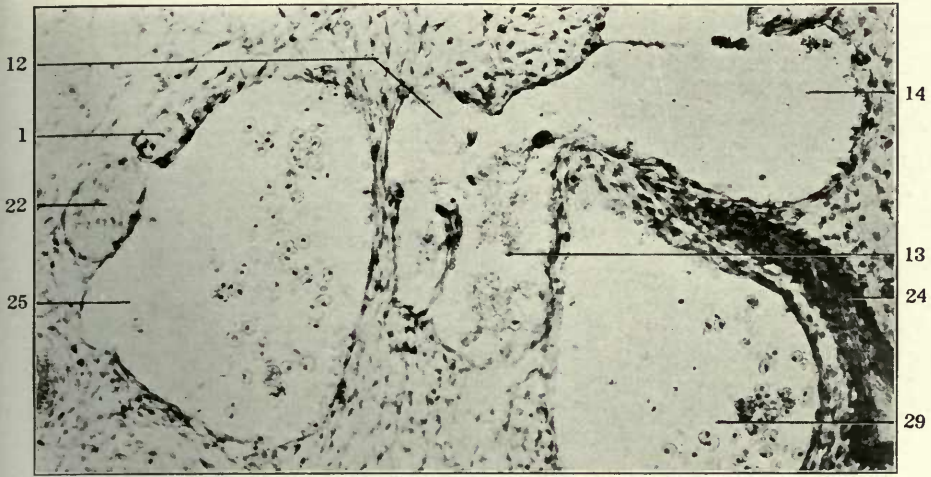


63

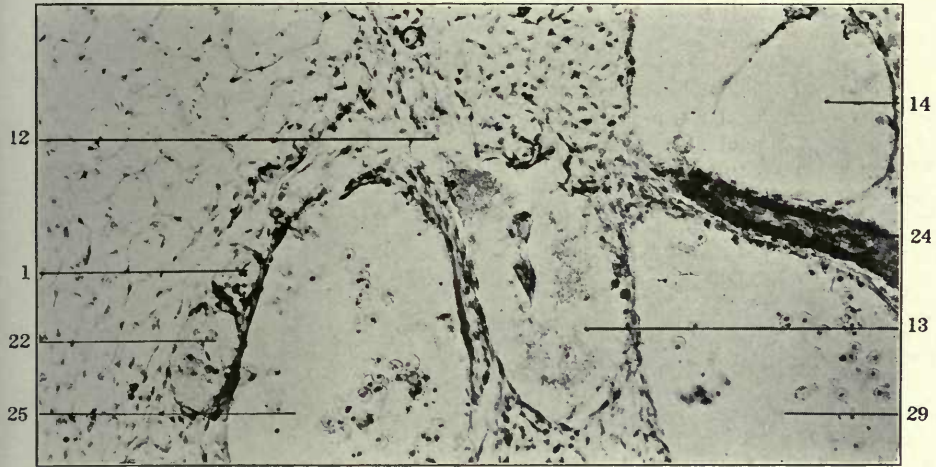
FIGURES 64, 65 AND 66

- 64 Same, section 31.
- 65 Same, section 32.
- 66 Same, section 33.

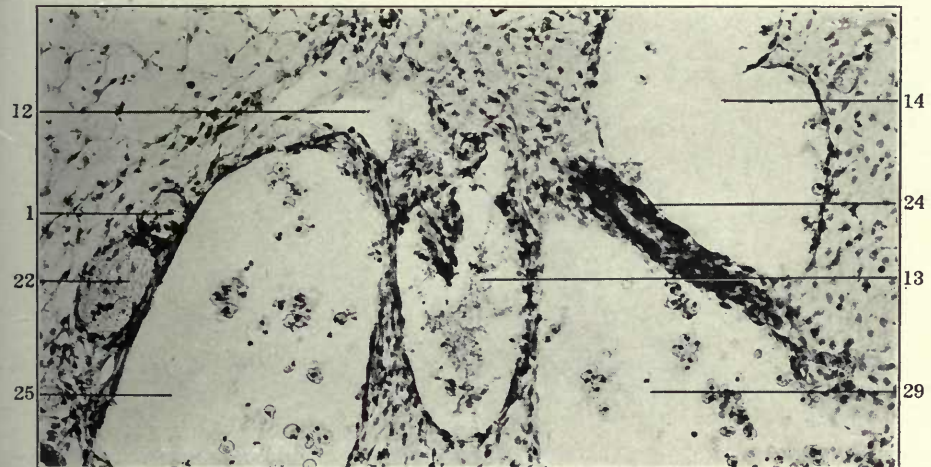
- 1 Sympathetic nerve.
- 12 Jugular lymph sac, thoracic duct approach.
- 13 Jugular lymph sac, jugular approach.
- 14 Jugular lymph sac, subclavian approach.
- 22 Vagus.
- 24 Thyrocervical artery.
- 25 Internal jugular vein.
- 29 Jugulo-subclavian trunk.



64



65

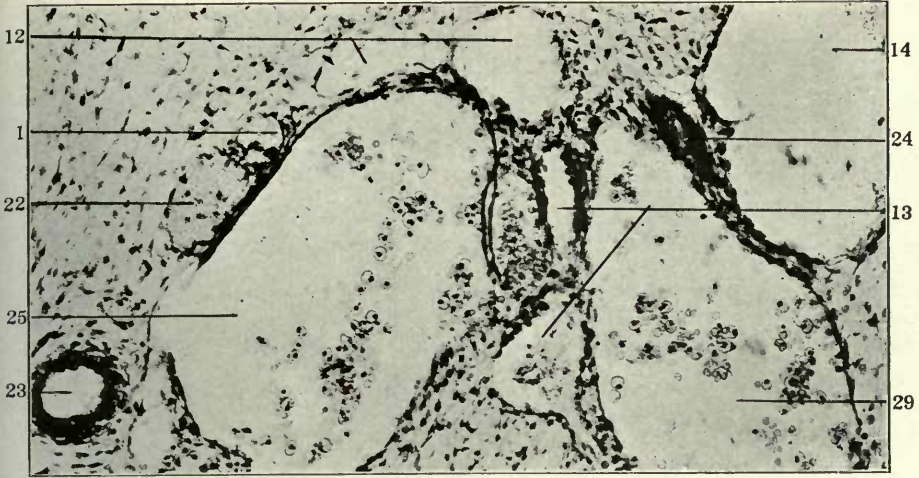


66

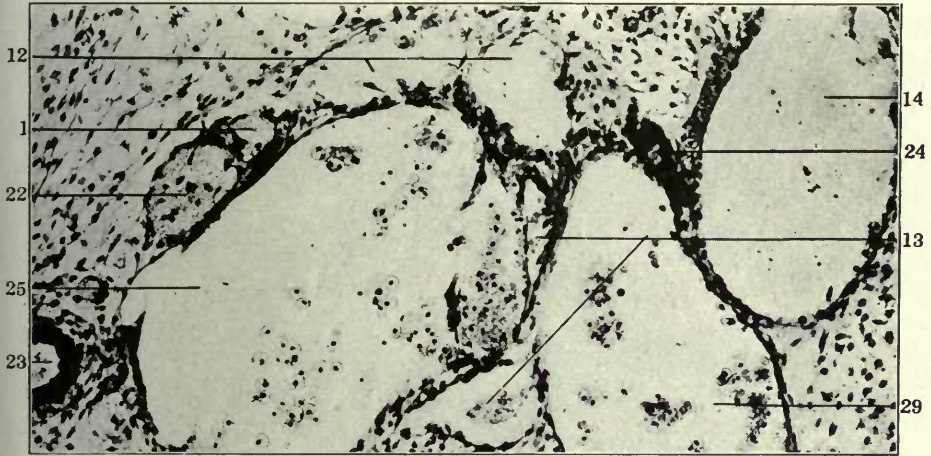
FIGURES 67, 68 AND 69

- 67 Same, section 35.
- 68 Same, section 36.
- 69 Same, section 38.

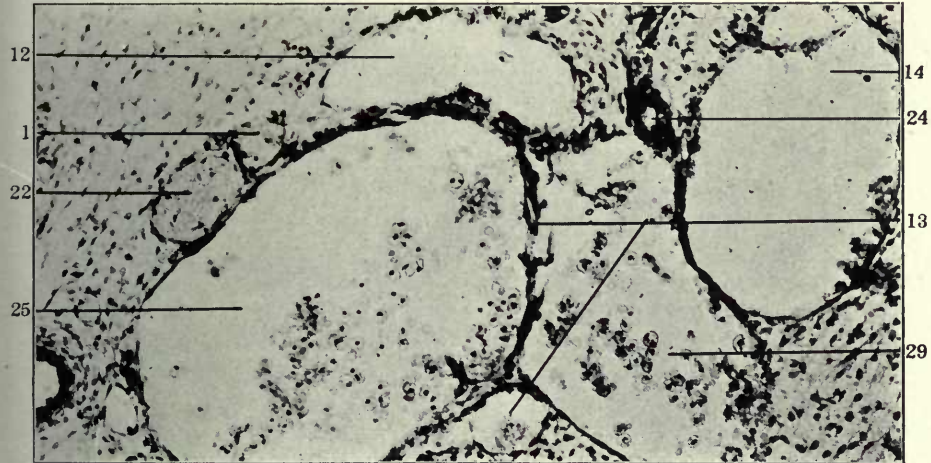
- 1 Sympathetic nerve.
- 12 Jugular lymph sac, thoracic duct approach.
- 13 Jugular lymph sac, jugular approach.
- 14 Jugular lymph sac, subclavian approach.
- 22 Vagus.
- 23 Left carotid artery.
- 24 Thyrocervical artery.
- 25 Internal jugular vein.
- 29 Jugulo-subclavian trunk.



67



68

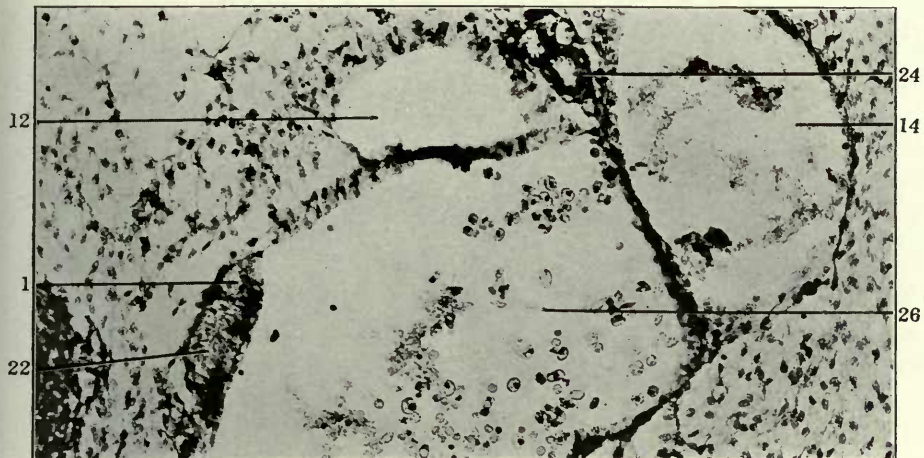


69

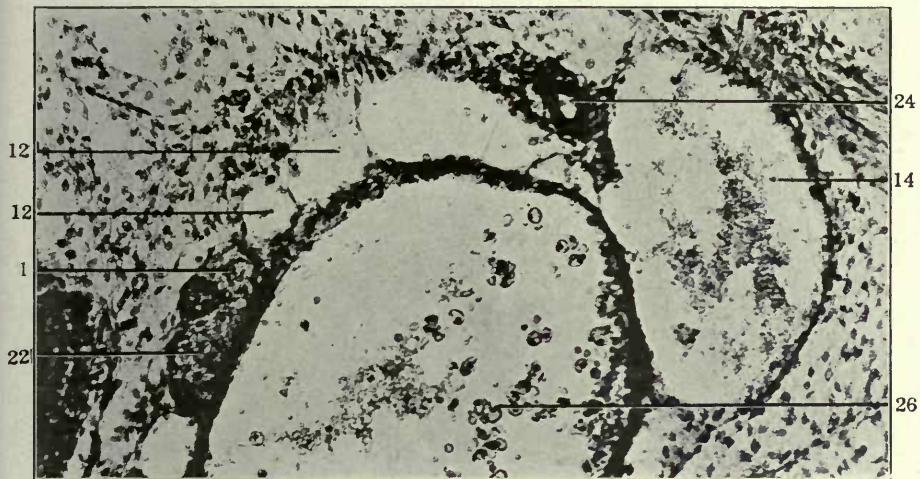
FIGURES 70, 71 AND 72

- 70 Same, slide IX, section 2.
- 71 Same, slide IX, section 5.
- 72 Same, slide IX, section 6.

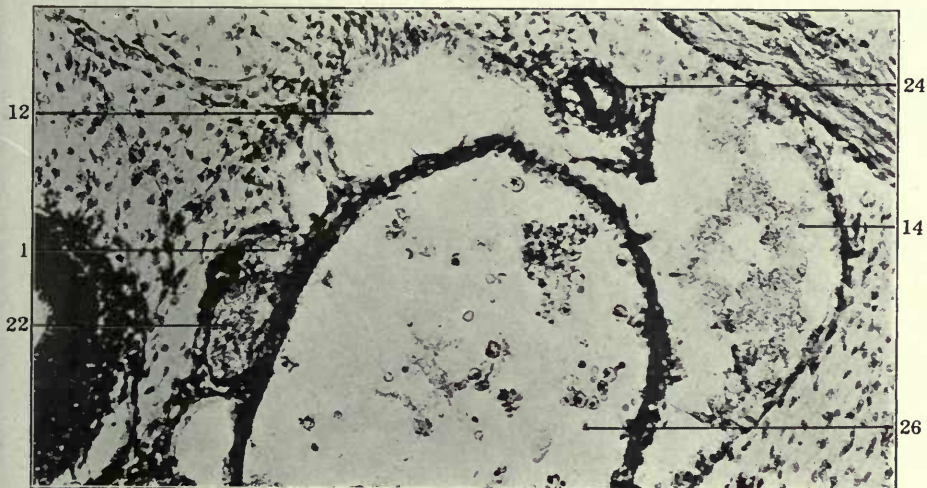
- 1 Sympathetic nerve.
- 12 Jugular lymph sac, thoracic duct approach.
- 14 Jugular lymph sac, subclavian approach.
- 22 Vagus.
- 24 Thyrocervical artery.
- 26 Common jugular vein.



70



71

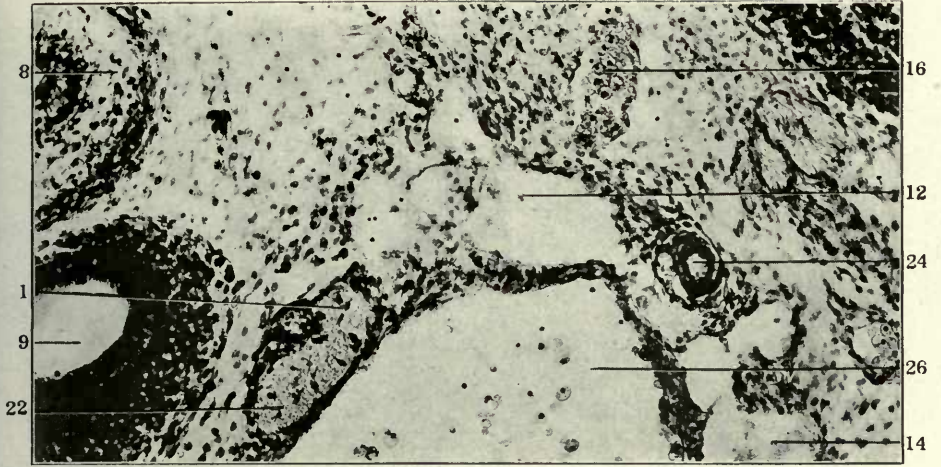


72

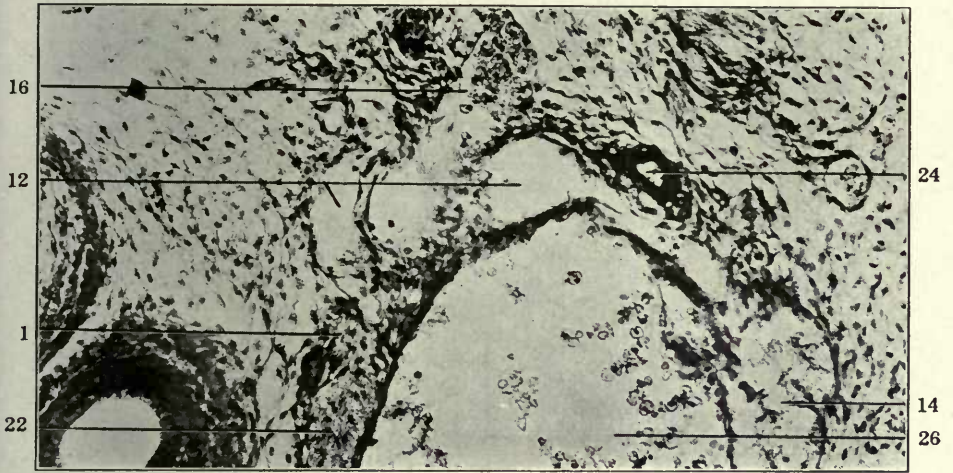
FIGURES 73, 74 AND 75

- 73 Same, slide IX, section 9.
74 Same, slide IX, section 10.
75 Same, slide IX, section 11.

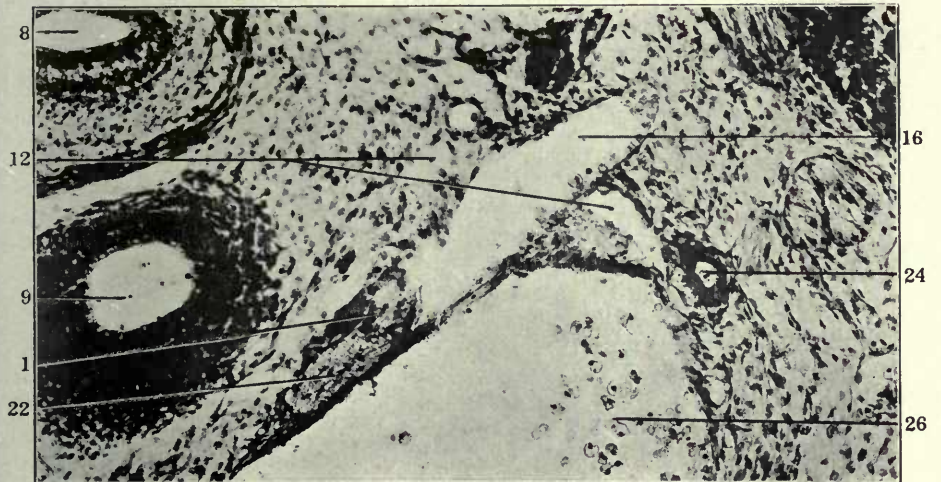
- 1 Sympathetic nerve.
8 Oesophagus.
9 Trachea.
12 Jugular lymph sac, thoracic duct approach.
14 Jugular lymph sac, subclavian approach.
16 Dorso-medial somatic venous tributaries.
22 Vagus.
24 Thyrocervical artery.
26 Common jugular vein.



73



74

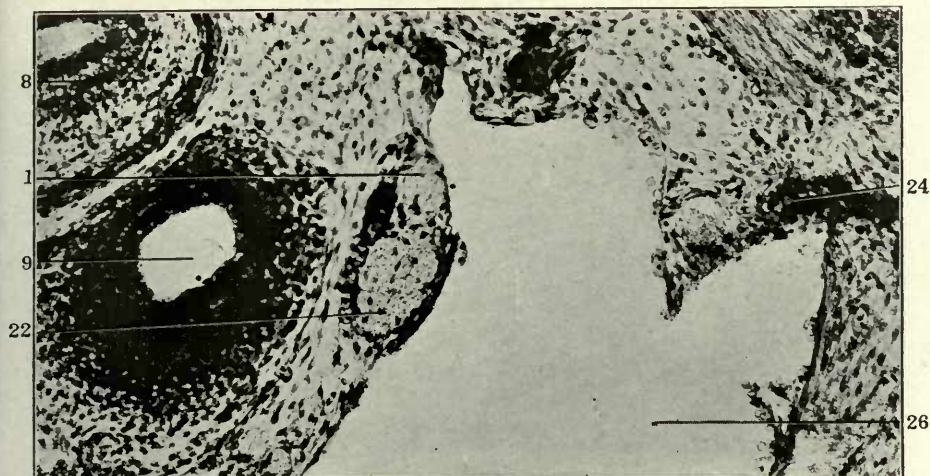


75

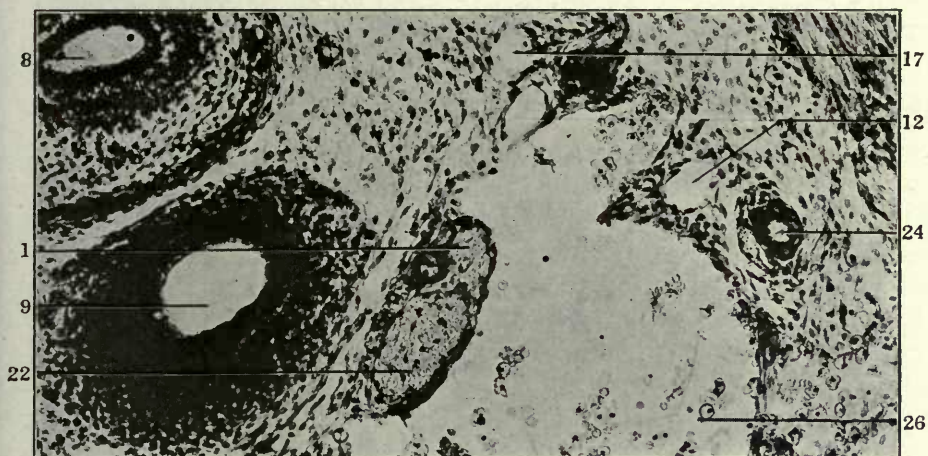
FIGURES 76, 77 AND 78

- 76 Same, slide IX, section 12.
- 77 Same, slide IX, section 13.
- 78 Same, slide IX, section 14.

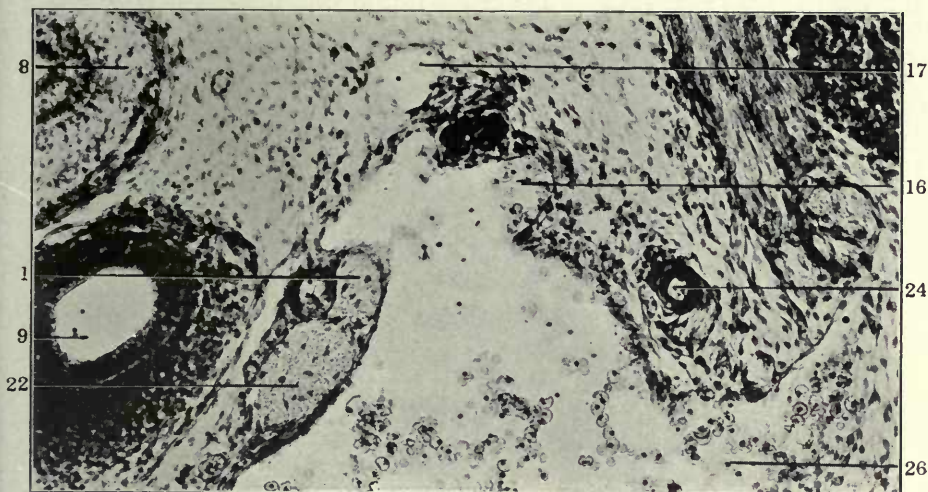
- 1 Sympathetic nerve.
- 8 Oesophagus.
- 9 Trachea.
- 12 Jugular lymph sac, thoracic duct approach.
- 16 Dorso-medial somatic venous tributaries.
- 17 Prevertebral venous plexus.
- 22 Vagus.
- 24 Thyrocervical artery.
- 26 Common jugular vein.



76



77

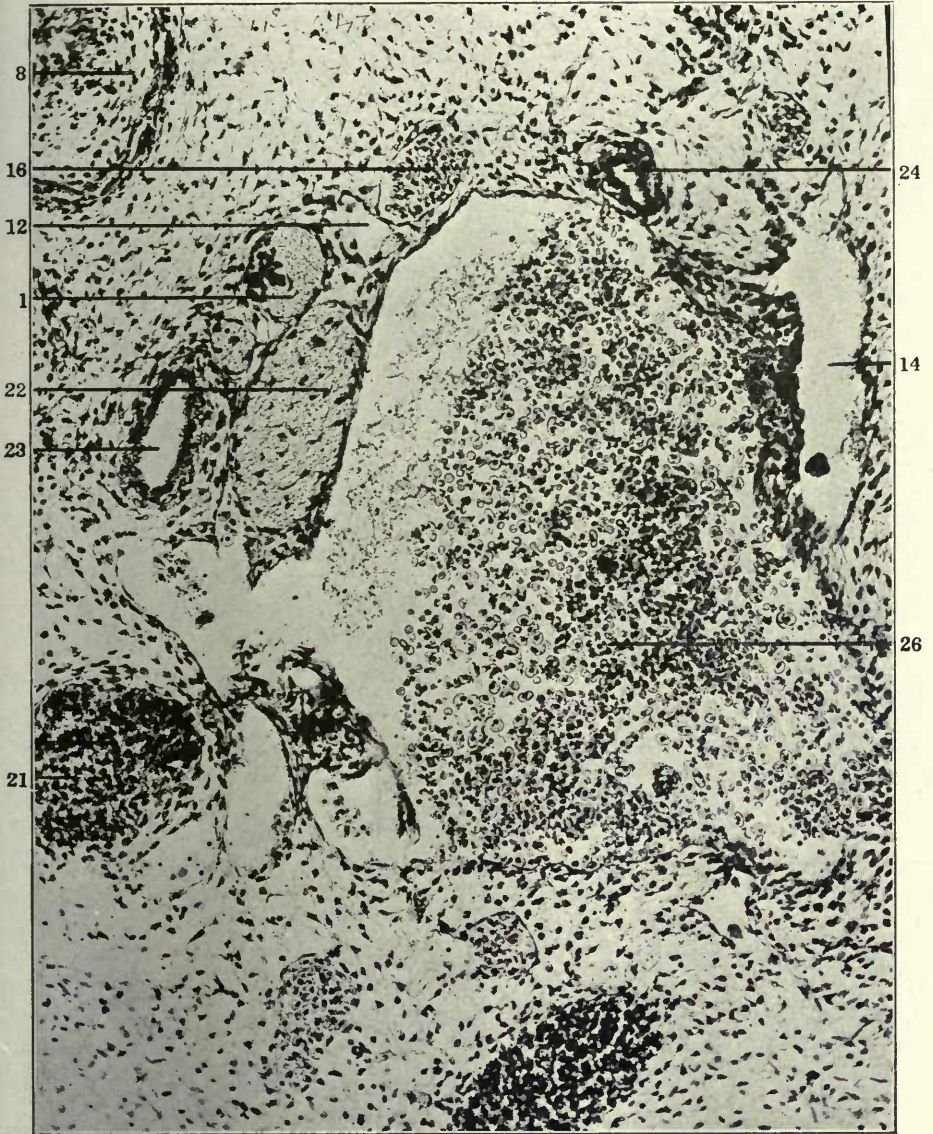


78

EXPLANATION OF FIGURE 79

79 Transverse section of left lower cervical region in a 15 mm. cat embryo (series 245, slide XI, section 24), \times 225.

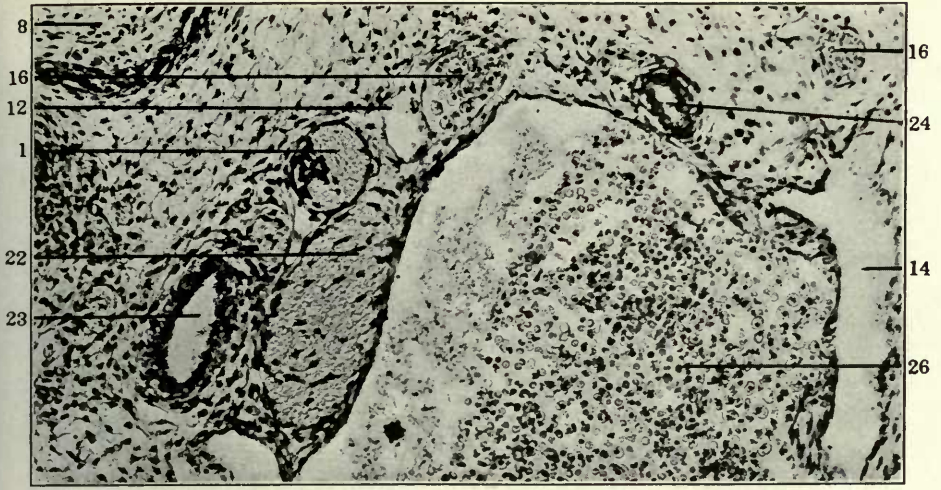
- 1 Sympathetic nerve.
- 8 Oesophagus.
- 12 Jugular lymph sac, thoracic duct approach.
- 14 Jugular lymph sac, subclavian approach.
- 16 Dorso-medial somatic venous tributaries.
- 21 Thymus.
- 22 Vagus.
- 23 Left carotid artery.
- 24 Thyrocervical artery.
- 26 Common jugular vein.



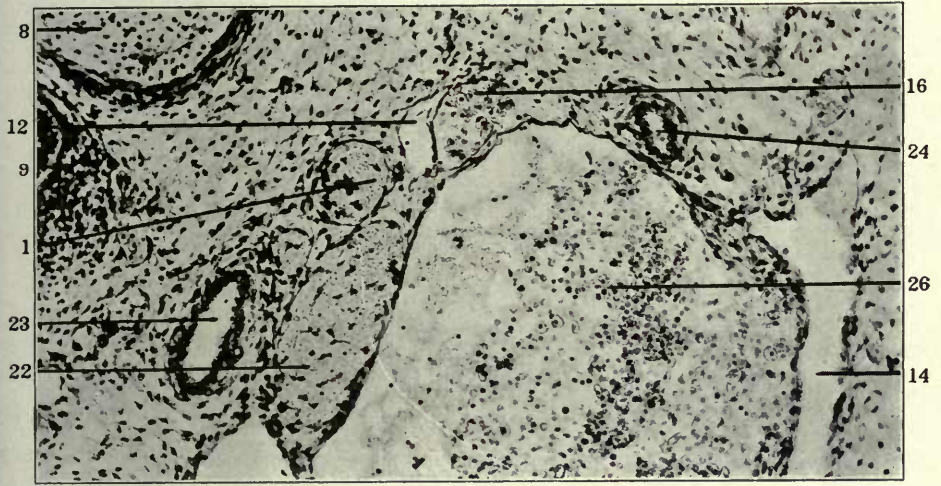
FIGURES 80, 81 AND 82

- 80 Same, section 25.
- 81 Same, section 26.
- 82 Same, section 27.

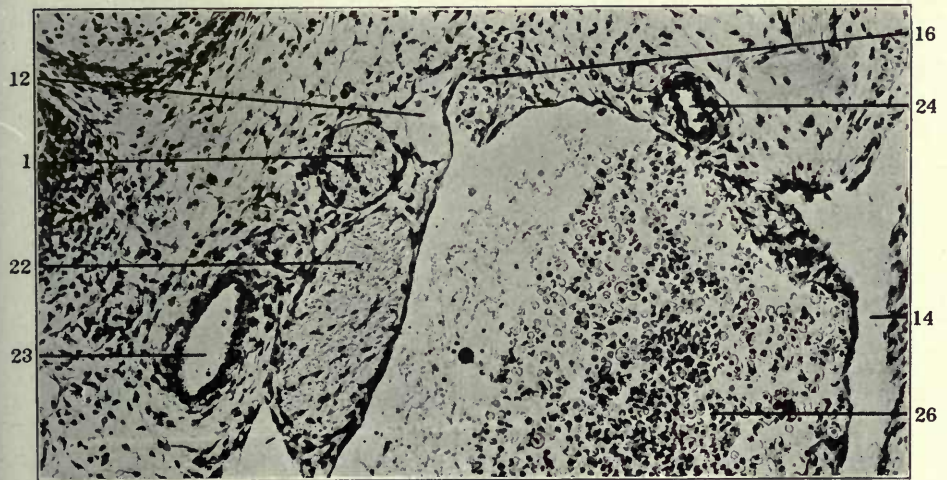
- 1 Sympathetic nerve.
- 8 Oesophagus.
- 9 Trachea.
- 12 Jugular lymph sac, thoracic duct approach.
- 14 Jugular lymph sac, subclavian approach.
- 16 Dorso-medial somatic venous tributaries.
- 22 Vagus.
- 23 Left carotid artery.
- 24 Thyrocervical artery.
- 26 Common jugular vein.



80



81



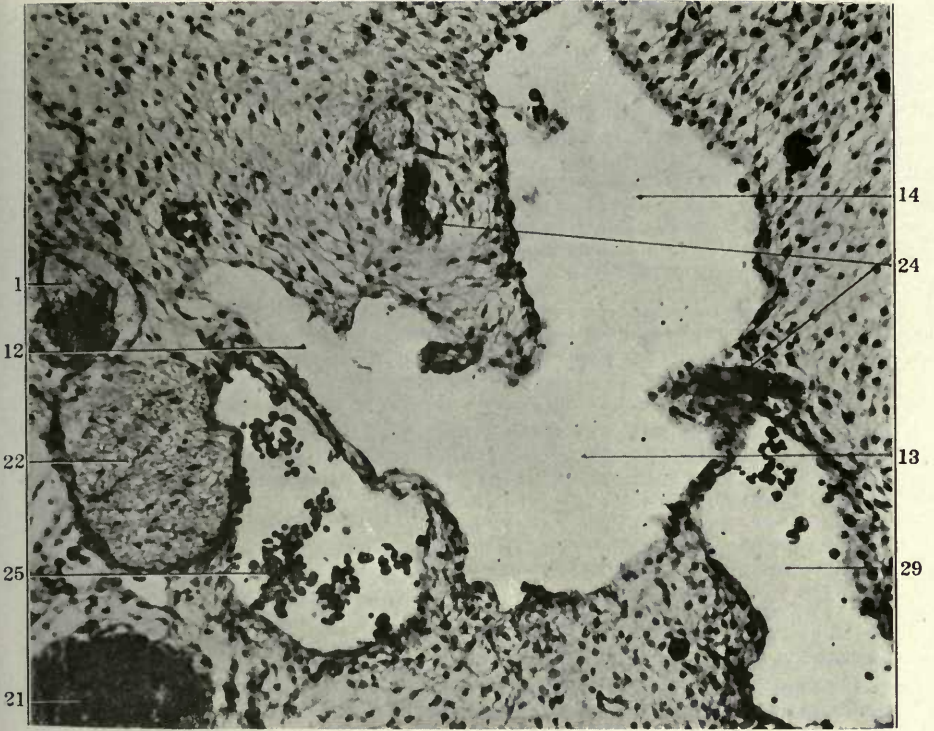
82

FIGURES 83 AND 84

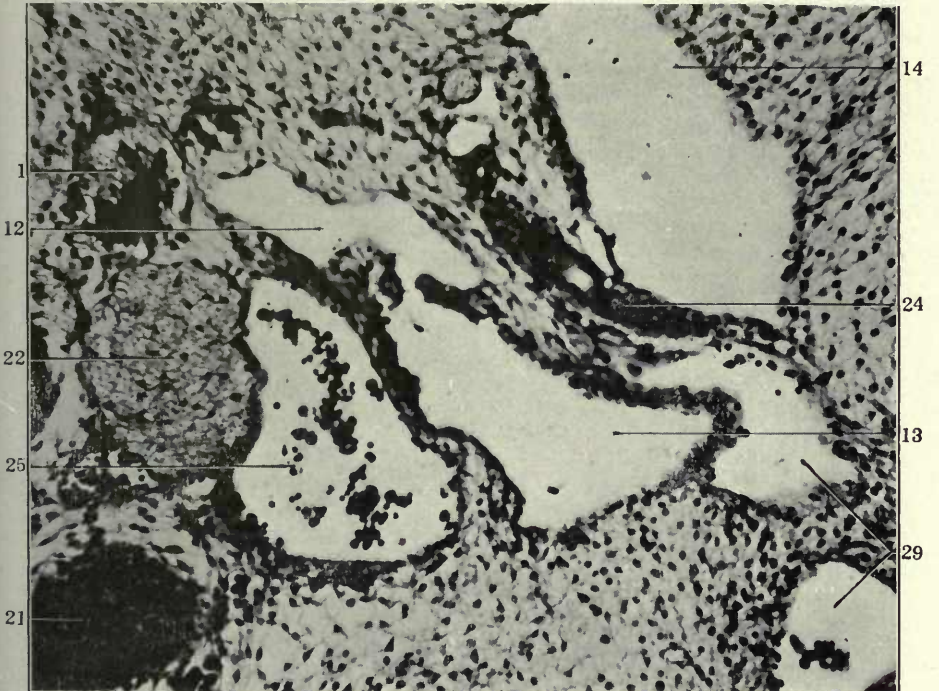
83 Transverse section of left lower cervical region in a 17 mm. cat embryo (series 142, slide X, section 13), \times 225.

84 Same, section 16.

- 1 Sympathetic nerve.
- 12 Jugular lymph sac, thoracic duct approach.
- 13 Jugular lymph sac, jugular approach.
- 14 Jugular lymph sac, subclavian approach.
- 21 Thymus.
- 22 Vagus.
- 24 Thyrocervical artery.
- 25 Internal jugular vein.
- 29 Jugulo-subclavian trunk.



83



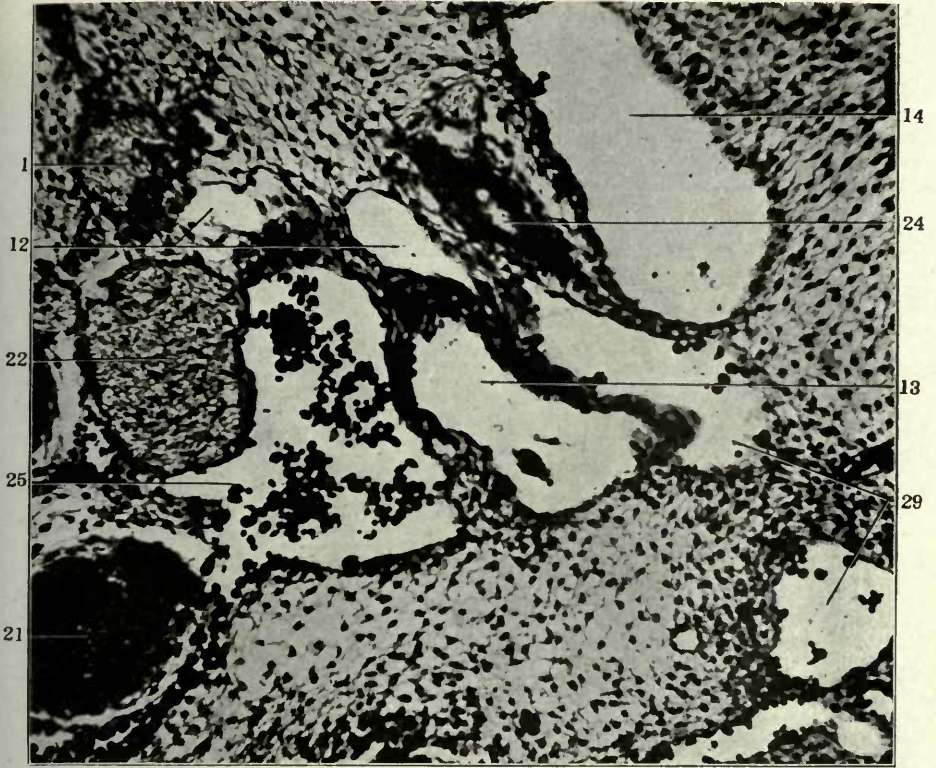
84

FIGURES 85 AND 86

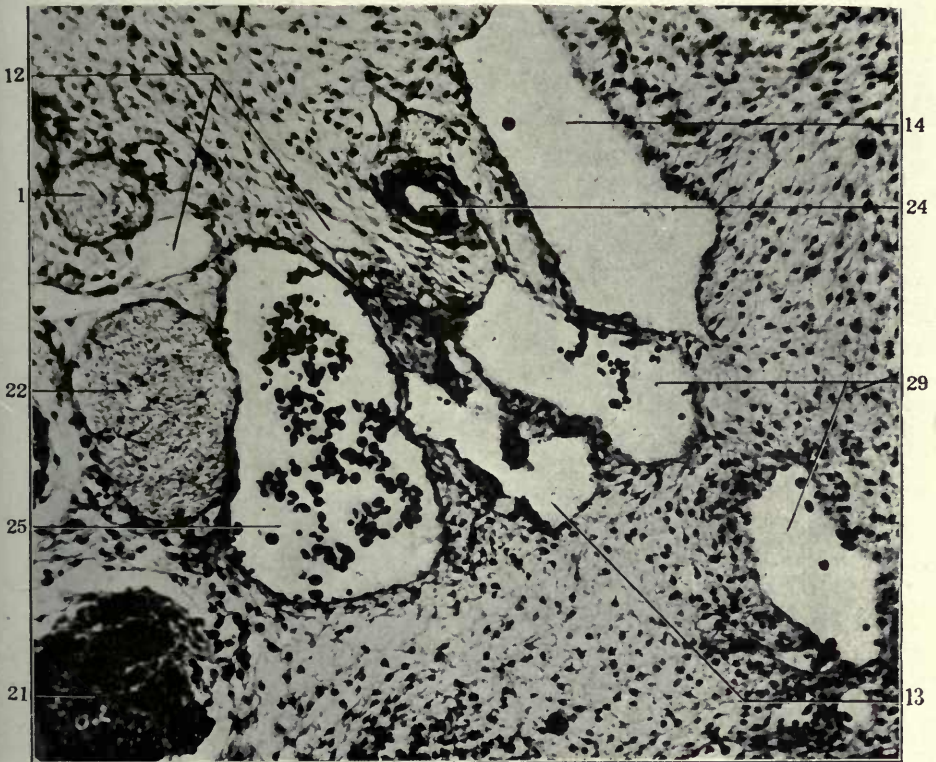
85 Same, section 18.

86 Same, section 20.

- 1 Sympathetic nerve.
- 12 Jugular lymph sac, thoracic duct approach.
- 13 Jugular lymph sac, jugular approach.
- 14 Jugular lymph sac, subclavian approach.
- 21 Thymus.
- 22 Vagus.
- 24 Thyrocervical artery.
- 25 Internal jugular vein.
- 29 Jugulo-subclavian trunk.



85

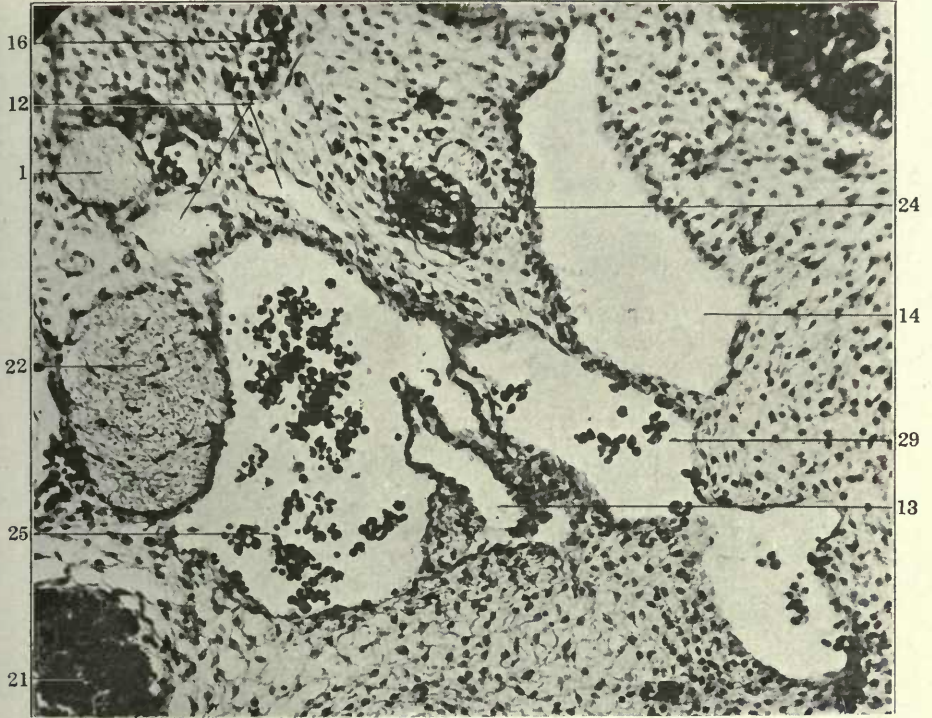


86

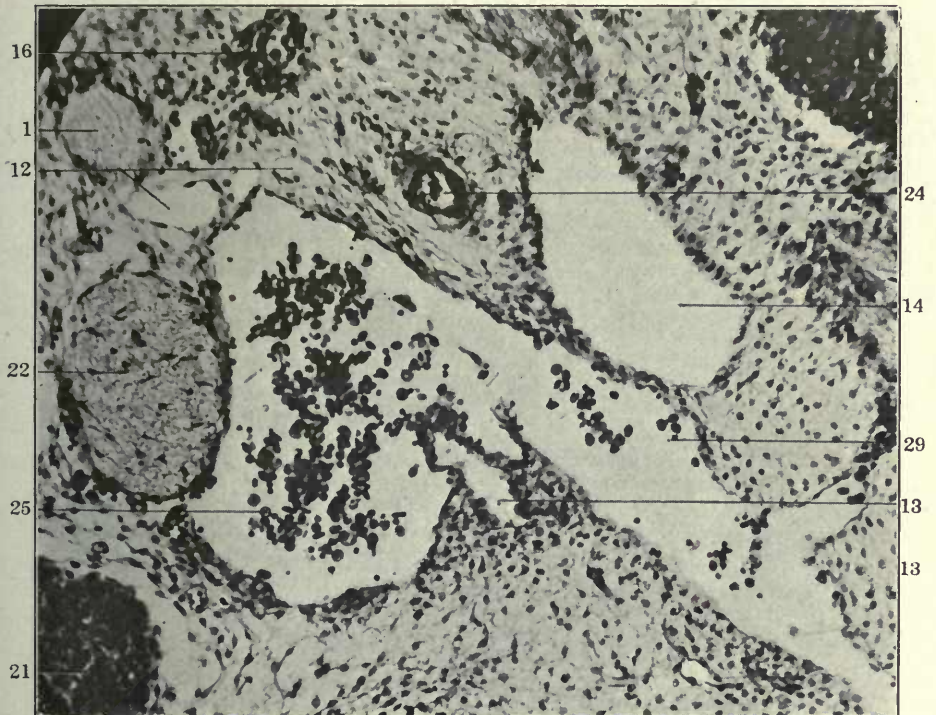
FIGURES 87 AND 88

- 87 Same, section 22.
88 Same, section 24.

- 1 Sympathetic nerve.
- 12 Jugular lymph sac, thoracic duct approach.
- 13 Jugular lymph sac, jugular approach.
- 14 Jugular lymph sac, subclavian approach.
- 16 Dorso-medial somatic venous tributaries.
- 21 Thymus.
- 22 Vagus.
- 24 Thyrocervical artery.
- 25 Internal jugular lymphatics.
- 29 Jugulo-subclavian trunk.



87



88

2. THE PREAZYGOS SEGMENT

This portion of the thoracic duct develops, again by confluence of numerous extraintimal perivenous anlagen, in the cephalic and lateral mediastinal space, between the termination of the thoracic duct approach of the jugular sac and the level of the intersection of the left duct with the aortic arch. Its ontogenesis offers the most striking and definite evidence of the development of the systemic lymphatic channels in this mammalian embryo as the result of the confluence of a large number of originally separate and independent "extra-intimal" or "perivenous" mesodermal spaces, following and enveloping the early embryonal veins, or completely surrounding them, and finally entirely replacing them. The spaces which I am describing as the anlagen of the systemic lymphatic channels in the mammalian embryo under consideration (*Felis domestica*) are surely easy enough to see. If they are followed in successive stages they fully and completely reveal the histogenesis of the systemic lymphatic vessels in this mammalian form, and conclusively establish the relation of the first mammalian lymphatic anlagen to the embryonic veins, which they are destined to replace, as previously outlined in the preliminary publications quoted (1, 2, 21, 22). The structures which form the first anlagen of the systemic lymphatic channels in the embryo of the cat cannot be *injected*, because at the time of their first definite appearance they represent the still *disjointed* links of a chain which is only subsequently to be assembled into a continuous whole. It is possible to inject in earlier periods the veins which are later replaced by these extraintimal lymphatics, and it is possible to inject in later stages the lymphatics when they have united into a connected system of channels. But in either case injection methods merely prove topographi-

cal conditions for any given stage. They afford absolutely no proof of the *histogenetic origin* of vascular structure. The mere fact that a lymphatic plexus occupies topographically the place of an antecedent venous plexus is absolutely no proof of the histogenetic identity of the channel system involved. However, to return to the matter in hand, while the region under discussion serves no better than any other part of the embryo for this purpose, it fully and completely illustrates the relative condition of embryonic veins and the replacing extraintimal lymphatics in the genesis of the adult systemic lymphatic channels.

The ontogenetic history of the *preazygos segment* of the thoracic duct must be considered in reference to three regions:

A. The development of a broncho-mediastinal or ventral mediastinal lymphatic channel, draining the ventral and lateral mediastinal areas, cephalad of the pericardium, and including the lymphatic return from the thymic, tracheal, bronchial, and oesophageal regions.

B. The development of the proximal portion of the thoracic duct proper, between the termination of the thoracic duct approach of the jugular lymph sac, and the beginning of the azygos segment of the thoracic ducts, caudal to the level of the aortic arch.

C. The junction of these two independently formed lymphatic trunks with each other and with the thoracic duct approach of the jugular lymph sac.

Adult Conditions

Before taking up the embryological consideration of the development of these channels and the establishment of their subsequent connections, it seems advisable, on account of the complicated topographical relations, to establish these clearly by reference to a small selected series of adult animals with successful injection of the lymphatic structures concerned. This becomes all the more necessary because the adult variations observed in the arrangement of the lymphatics of this region have an important

bearing on the observed embryological conditions. An understanding of the former is necessary for the correct interpretation of the latter, and vice versa. Hence, while the details of the adult anatomy of the cat's lymphatic system in its relation to the development are reserved for Part V of the second publication of this series, a limited number of adult illustrations are here introduced in order to prepare the ground for the consideration of the ontogenesis of the broncho-mediastinal trunk and of the preazygos segment of the thoracic duct.

In a certain proportion of adults the ventral or broncho-mediastinal trunk has no direct connection with the preazygos segment of the thoracic duct, but drains solely cephalad into a ventral prolongation from the subclavian approach of the jugular sac, which process also receives the main lymph vessels from the axilla and the forelimb.

Figs. 92 and 93 (adults, nos. 67 and 13) give good illustrations of this condition.

In many other adults, however, the left ventral or broncho-mediastinal trunk is connected caudally, with or without the interposition of one or more lymph nodes common to both, with the preazygos segment of the thoracic duct. This junction commonly occurs about at the level at which the innominate artery divides. The cephalic extremity of the main broncho-mediastinal trunk then usually still drains into the jugular lymph sac by establishing a connection with the ventral prolongation which the subclavian approach of the sac sends caudad over the ventral aspect of the jugulo-subclavian confluence. This process also receives the main lymphatic trunks from the anterior extremity and from the axillary area of the thoracic wall. Occasionally the cephalic end of the broncho-mediastinal trunk also connects with the similar ventral prolongation which the jugular approach of the lymph sac sends down over the ventral aspect of the common jugular angle of confluence.

The broncho-mediastinal trunk is therefore usually represented by a ventral lymph channel of some size, whose caudal extremity joins the preazygos segment of the thoracic duct, while its cephalic extremity empties, in common with other axial and appendicular

lymph paths, into the caudal end of the jugular sac, usually into the ventral process of the subclavian approach caudal to the jugulo-subclavian lymphatico-venous tap. In this course the broncho-mediastinal trunk receives afferents from the mediastinal structures. Fig. 94 shows this general arrangement on the left side in a typical adult (No. 56), in which the left jugular lymph sac connects with the veins only through the single jugulo-subclavian tap. A double ventral process from the subclavian approach effects the cephalic connection of the broncho-mediastinal trunk with the jugular sac, while caudally two lymph vessels unite it to the preazygos segment of the thoracic duct.

It is evident in following the thoracic duct caudo-cephalad that this arrangement enables the flow of lymph in the main canal to take, near the level of the innominate bifurcation, one of two equally available pathways in order to reach the jugular sac and through it enter the venous stream:

a. It may, in large part or entirely, continue cephalad in the dorsal channel of the preazygos segment of the thoracic duct proper, or

b. It may ascend in the channel of the broncho-mediastinal trunk, and empty into the venous system through the ventral prolongation of the subclavian approach of the jugular lymph sac.

This arrangement, which furnishes the keynote for the main variations of the thoracic duct in this region, and for the interpretation of certain important embryological stages, is well illustrated by the dissection of the left side of neck and thorax in the adult cat shown in fig. 95 (adult, no. 22). The azygos segment of the thoracic duct is seen caudad of the level of azygos arch (21) as a plexiform channel whose meshes are perforated by the intercostal arteries. Cephalad of the azygos arch the preazygos segment of the thoracic duct continues as an undivided canal of larger caliber to the level of division of the innominate artery (20). At this point the broncho-mediastinal trunk (8) diverges from the main canal and ascends ventral to the left subclavian artery, receiving tributaries from the ventral mediastinal nodes. It meets the subclavian lymphatic and a large ventral mediastinal

trunk accompanying the internal mammary vessels (7) in front of the jugulo-subclavian angle in a plexiform junction, which empties into a ventral process prolonged down from both the jugular (18) and subclavian (19) approaches of the jugular lymph sac.

The preazygos segment of the thoracic duct, cephalad of its connection with the broncho-mediastinal trunk, takes the usual course upward under cover of the subclavian artery and behind the vertebral vein (11) and opens into the dorsal aspect of the jugular sac a little in front of the common jugular tap.

The jugular lymph sac is well developed in its ventral division and opens into the venous system at the two typical points, viz., both at the common jugular and jugulo-subclavian taps. It receives the internal and external jugular and the cephalic lymphatics in the usual way. The subclavian vein (5) is divided close to the jugulo-subclavian confluence and turned forward to expose the vertebral vein and the duct.

The individual affords a good example of the full development of the normal preazygos segment of the thoracic duct in combination with a well marked broncho-mediastinal trunk and plexus. The former is still the main lymphatic channel, although the broncho-mediastinal vessel is fully developed and capable of draining the mediastinal lymphatics either cephalad into the lymph sac or caudad into the thoracic duct.

Fig. 96 (adult, no. 29) shows an instance in which the preazygos segment of the thoracic duct (12) and the broncho-mediastinal trunk (8) are of nearly equal size, the former receiving the internal mammary (6) and inferior thyroid (4) lymphatics and draining into the jugular sac through the ventral prolongation of its subclavian approach. The preparation shows well the main relations of the lymphatic complex to the vertical portion of the left subclavian artery (13) and its branches, with the broncho-mediastinal trunk (8) lying ventral to the artery, while the thoracic duct (2) ascends dorsal to the same, and further passes beneath the vertebral vessels (11) and the thyro-cervical artery (9) in order to reach its connection with the lymph sac. The latter has in this instance a single tap into the veins through the subclavian approach at the jugulo-subclavian angle. The subclavian vein (5)

has again been cut short and turned mesad to expose the deeper structures.

The azygos segment of the thoracic duct (16) shows the same plexiform character and relation to the perforating intercostal arteries as in the preceding dissection (fig. 95).

Fig. 97 (adult no. 131) shows an instance in which the main thoracic duct turns ventrad into the broncho-mediastinal trunk, while a small channel follows the usual dorsal course of the normal duct.

The left jugular lymph sac has only a single tap into the venous system at the jugulo-subclavian angle.

The sac receives at its cephalic end two lymphatic trunks paralleling the internal jugular vein (17), which is larger than usual, and the combined trunk formed by the external jugular and cephalic lymphatics.

The dorsal half of the thyro-cervical periarterial ring is smaller than the ventral, but the foramen is complete.

The jugulo-subclavian approach and tap is formed by a large process of the sac which sends a ventral prolongation over the jugulo-subclavian angle. This receives laterally the subclavian lymphatic, ascending along the subclavian vein (5), and from below the broncho-mediastinal trunk (8), which represents the main cephalic continuation of the thoracic duct. The duct at the aortic arch level (26) splits into a smaller dorsal (12) and larger ventral division (8). The former ascends behind the vertical part of the subclavian artery, crosses behind the vertebral vein, and turning ventro-caudad around the lateral aspect of the thyro-cervical artery (9), enters the dorsal aspect of the jugular lymph sac, just in front of the jugulo-subclavian tap. This smaller dorsal division represents the usual preazygos portion of the thoracic duct of the adult.

The second larger division of the duct takes the path of the broncho-mediastinal channel (8). It ascends first on the outer side and then in front of the subclavian artery, subdivides into two branches, which reunite and receive a small lymphatic from the left innominate plexus. The upper end of the duct crosses in front of the junction of the vertical and arched portions of the

subclavian artery and in front of the subclavian vein to terminate, in common with the subclavian lymphatic, in the ventral process of the subclavian approach of the lymph sac.

More rarely the broncho-mediastinal channel forms the only terminal path of the thoracic duct. In these instances the preaortic segment of the thoracic duct abandons its normal dorsal position and turns ventrad into the path of the broncho-mediastinal channel. Thus in fig. 98 (adult, no. 168), in which the common jugular tap (18) is the only lymphatico-venous connection of the left jugular lymph sac, the ventral process of the jugular approach is free and prolonged caudo-ventrad over the jugulo-subclavian angle as a large trunk which receives the entire drainage of the thoracic duct. The latter (8), after passing the aortic arch, swings ventrad of the subclavian artery into the pathway of the normal broncho-mediastinal trunk and ascends to meet the ventral prolongation of the jugular approach of the lymph sac.

It thus becomes apparent that in dealing with the ontogenesis of the cephalic portion of the cat's thoracic duct it is necessary to reckon with the ventral mediastinal and broncho-mediastinal channels as well as with the preazygos segment of the thoracic duct proper, since the former, as just seen, may take over, partially or entirely, the drainage of the duct into the jugular lymph sac.

A composite schema of the adult preazygos portion of the thoracic duct in relation to the broncho-mediastinal and ventral mediastinal trunks is given in fig. 99 based on the individual conditions encountered in the adult series examined. The plan represents every recorded development of the lymphatic pathways in this region, but is rarely seen in its full development in the adult (cf. adult, no. 29, fig. 96). Usually one or more of these potential segments and connections default and thus a great variety of distinct adult conditions is produced. These lymphatic pathways are, however, all present in the embryo and account for the observed adult variants.

PART II, PLATES

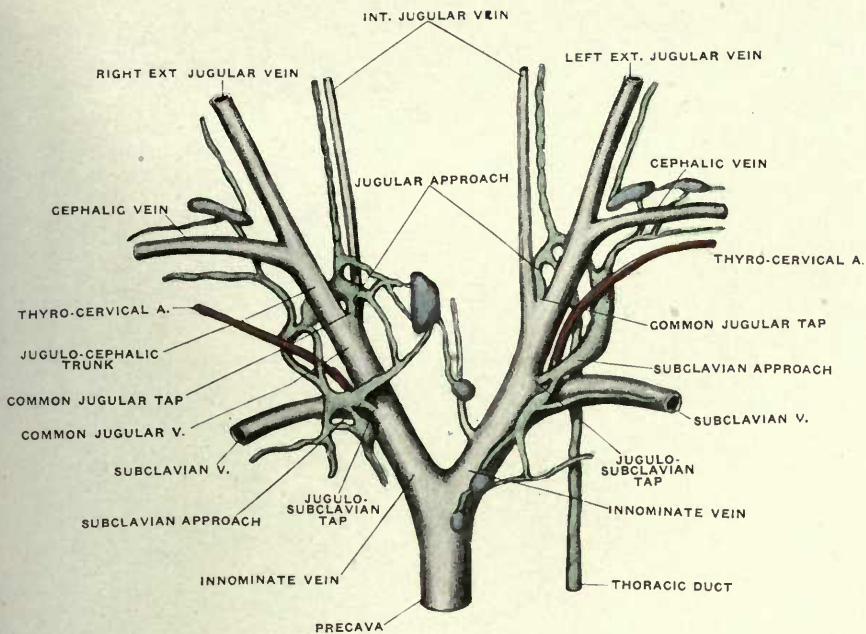
FIGURES 92 TO 99

FIGURES 92 AND 93

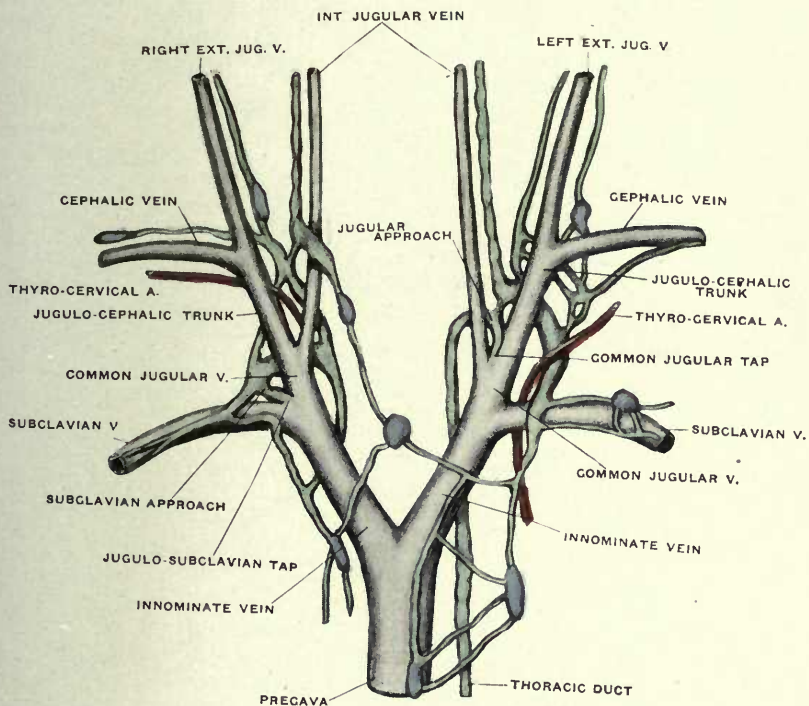
92 Dissection of the veins and lymphatics at the root of the neck in an adult cat (No. 67).

93 Same, No. 13.

(Figs. 92, 93, and 94 are republished from Huntington and McClure's "Anatomy and Development of the Jugular Lymph Sacs in the Domestic Cat," *Am. Jour. Anat.*, Vol. X, No. 2.)



92



93

FIGURE 94

94 Same, No. 56.

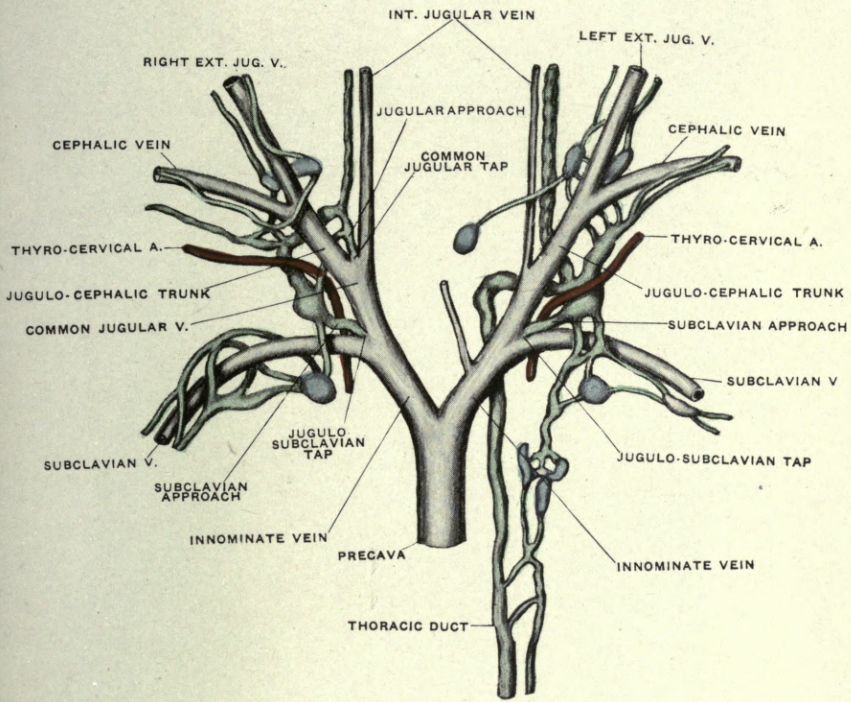


FIGURE 95

95 Dissection of main lymphatic vessels of neck and thorax in an adult cat (No. 22).

- 1 External jugular vein and lymphatics.
- 5 Subclavian vein.
- 7 Internal mammary artery and lymphatics.
- 8 Broncho-mediastinal or ventral mediastinal lymphatic trunk.
- 10 Cephalic vein and lymphatics.
- 11 Vertebral vein.
- 12 Thoracic duct, preazygos segment.
- 15 Oesophagus.
- 17 Internal jugular vein and lymphatics.
- 18 Jugular approach and tap.
- 19 Subclavian approach and tap.
- 20 Innominate artery.
- 21 Azygos vein.

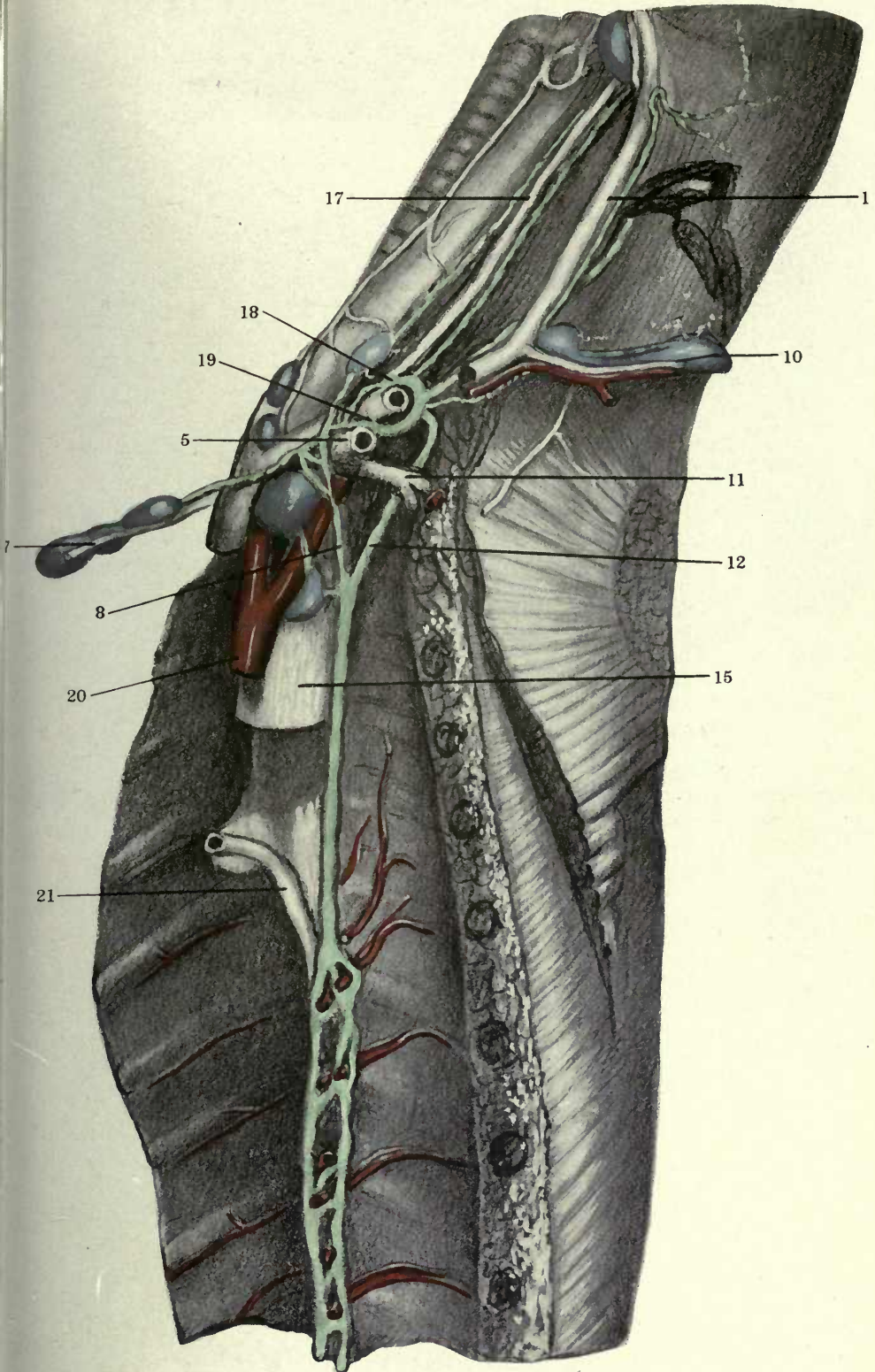


FIGURE 96

96 Dissection of main lymphatic vessels of neck and thorax in an adult cat (No. 29).

- 1 External jugular vein and lymphatics.
- 2 Common jugular vein.
- 3 Jugular lymph sac.
- 4 Inferior thyroid lymphatics.
- 5 Subclavian vein.
- 6 Internal mammary lymphatics.
- 7 Internal mammary artery.
- 8 Broncho-mediastinal or ventral mediastinal lymphatic trunk
- 9 Thyrocervical artery.
- 10 Cephalic vein and lymphatics.
- 11 Vertebral vein.
- 12 Thoracic duct, preazygos segment.
- 13 Left subclavian artery.
- 14 Junction of preazygos and azygos segments of thoracic duct.
- 15 Oesophagus.
- 16 Azygos segment of thoracic duct.

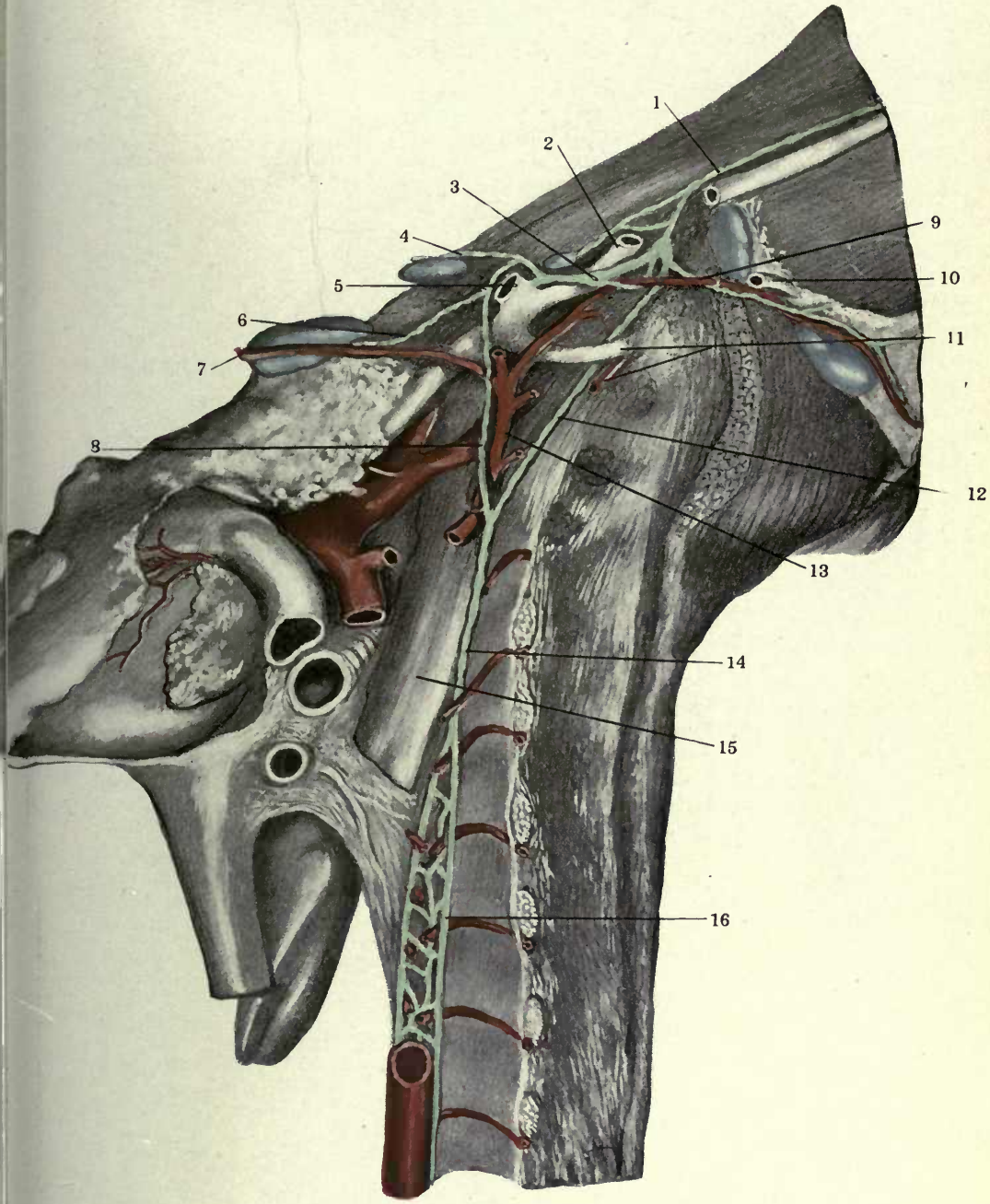


FIGURE 97

97 Dissection of main lymphatic vessels of neck and thorax in an adult cat (No. 131).

- 1 External jugular vein and lymphatics.
- 2 Common jugular vein.
- 5 Subclavian vein.
- 7 Internal mammary artery.
- 8 Broncho-mediastinal or ventral mediastinal lymphatic trunk.
- 9 Thyrocervical artery.
- 12 Thoracic duct, preazygos segment.
- 13 Left subclavian artery.
- 15 Oesophagus.
- 16 Azygos segment of thoracic duct.
- 17 Internal jugular vein and lymphatics.
- 20 Innominate artery.
- 23 Innominate vein.
- 26 Aorta.
- 27 Vagus nerve.
- 28 Inferior thyroid vein.
- 29 Jugulo-cephalic venous trunk.

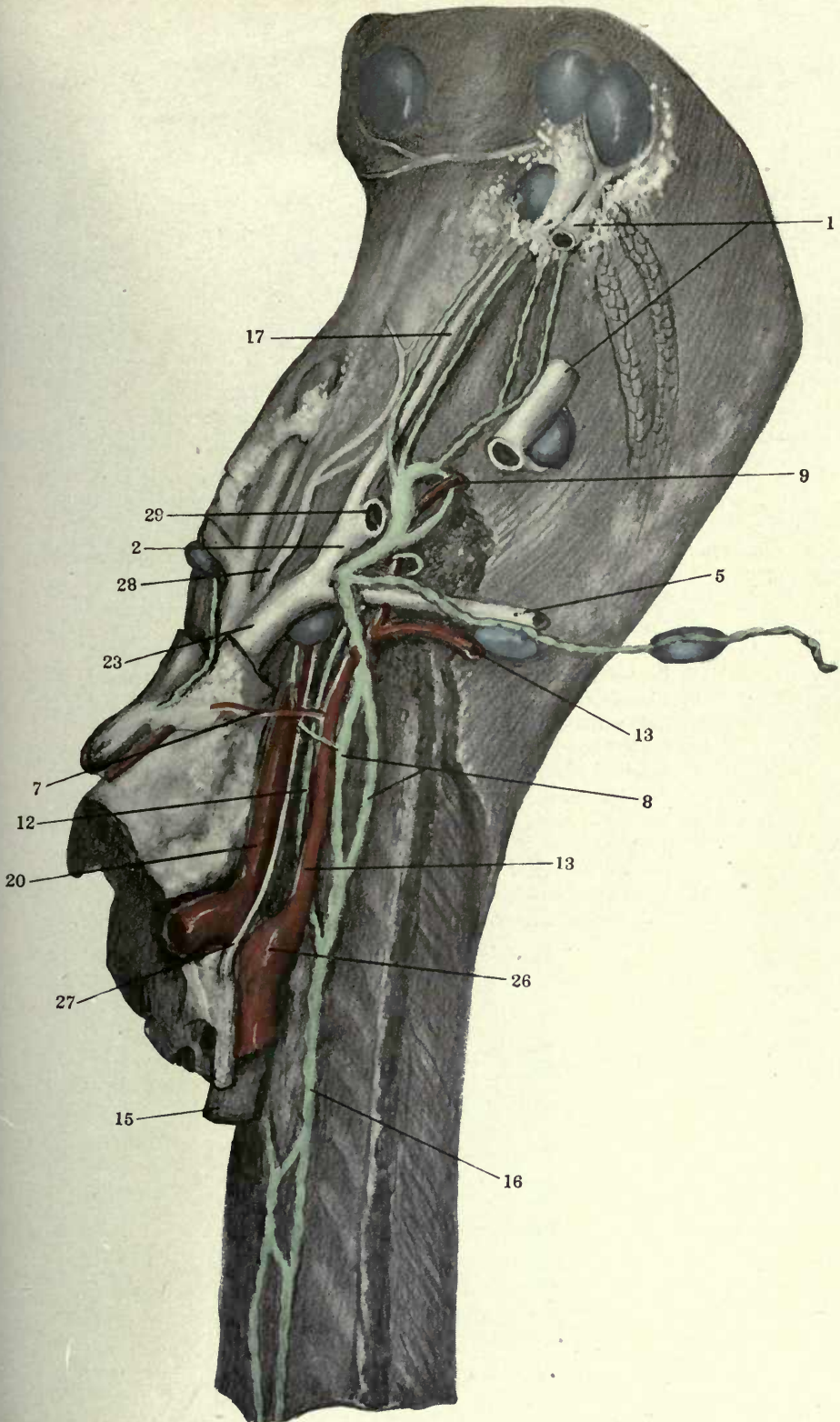


FIGURE 98

98 Dissection of left jugular lymph sac and thoracic duct in an adult cat (No. 168).

- 2 Common jugular vein.
- 5 Subclavian vein.
- 8 Broncho-mediastinal or ventral mediastinal lymphatic trunk.
- 9 Thyro-cervical artery.
- 13 Left subclavian artery.
- 15 Oesophagus.
- 17 Internal jugular vein and lymphatics.
- 18 Jugular approach and tap.
- 21 Azygos vein.
- 22 Trachea.
- 23 Innominate vein.
- 24 Vena cava superior.
- 25 Left carotid artery.

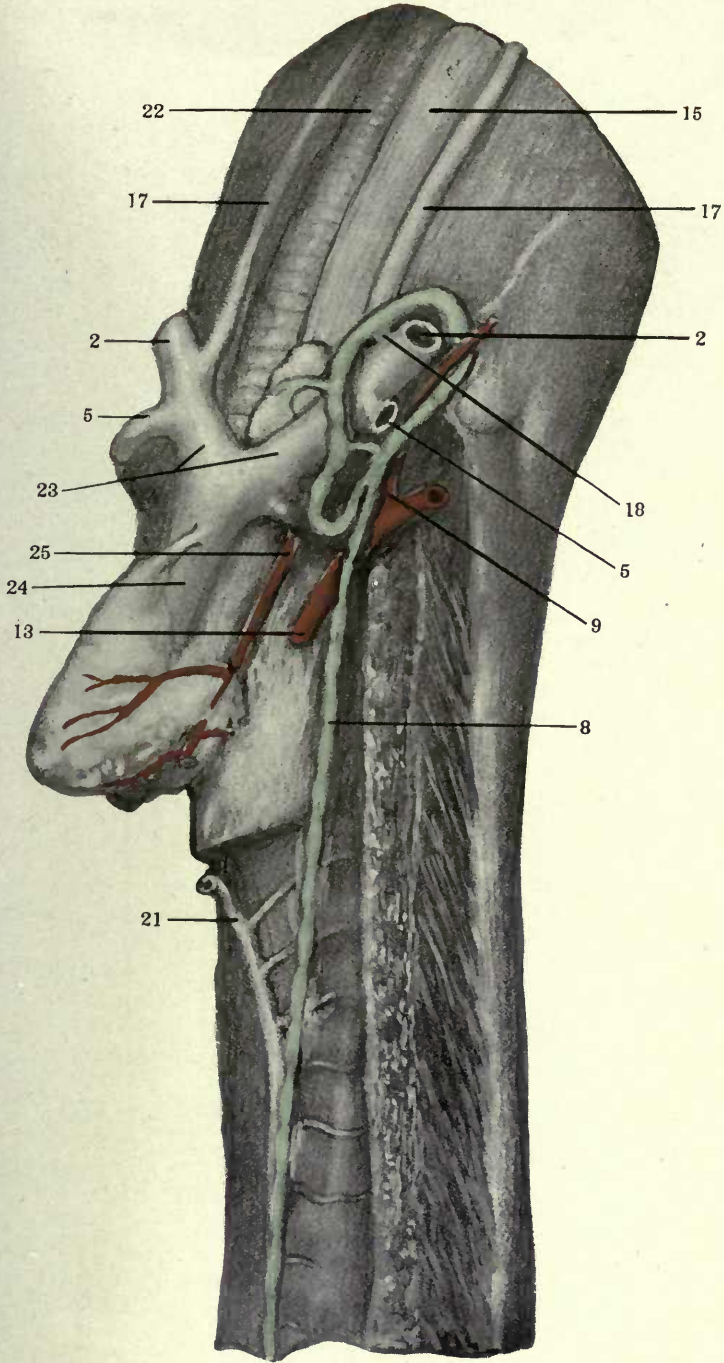
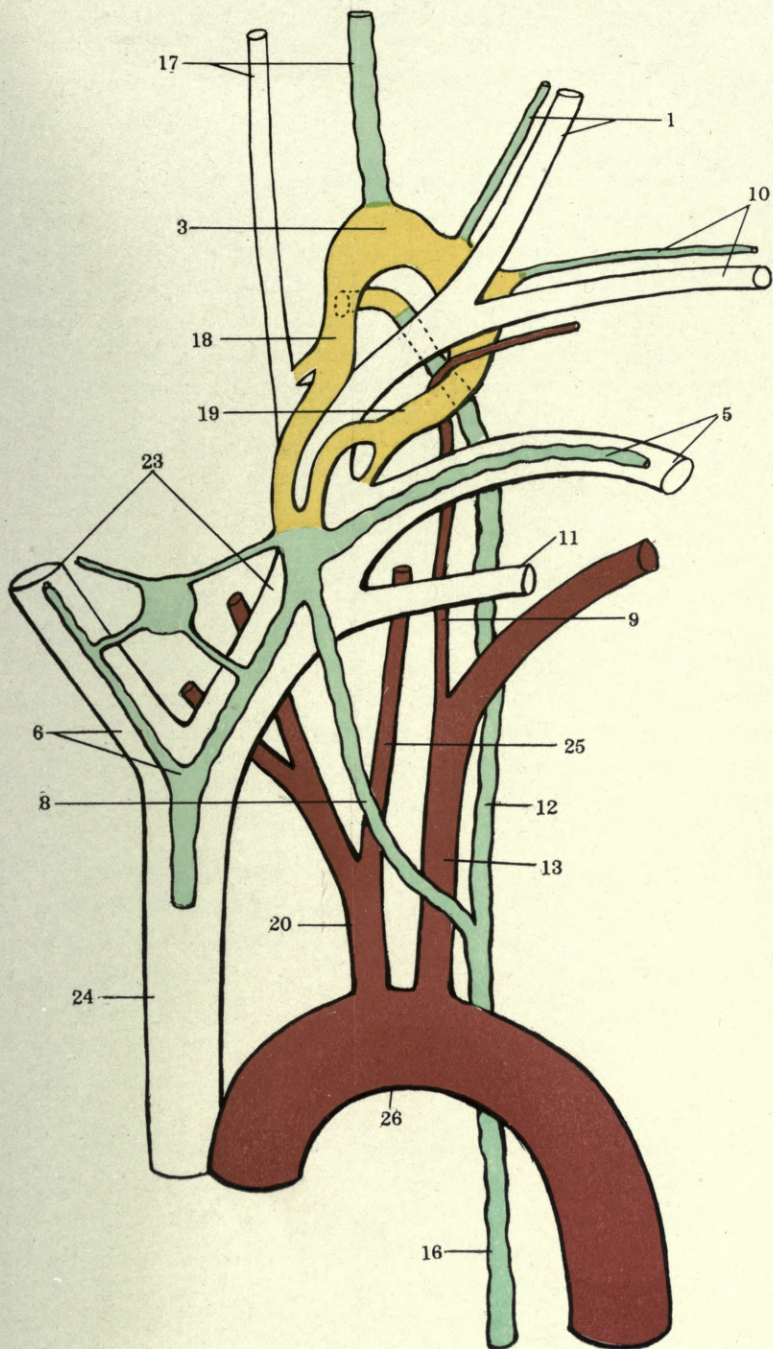


FIGURE 99

99 Schema showing composite picture of left jugular lymph sac, broncho-mediastinal trunk and preazygos segment of thoracic duct.

- 1 External jugular vein and lymphatics.
- 3 Jugular lymph sac.
- 5 Subclavian vein.
- 6 Internal mammary lymphatics.
- 8 Broncho-mediastinal or ventral mediastinal lymphatic trunk.
- 9 Thyro-cervical artery.
- 10 Cephalic vein and lymphatics.
- 11 Vertebral vein.
- 12 Thoracic duct, preazygos segment.
- 13 Left subclavian artery.
- 16 Azygos segment of thoracic duct.
- 17 Internal jugular vein and lymphatics.
- 18 Jugular approach and tap.
- 19 Subclavian approach and tap.
- 20 Innominate artery.
- 23 Innominate vein.
- 24 Vena cava superior.
- 25 Left carotid artery.
- 26 Aorta.



The Development of the Broncho-Mediastinal Trunk and of the Preazygos Segment of the Thoracic Duct

The area in which the development of the broncho-mediastinal and preazygos segments of the thoracic duct occurs is shown in fig. 100, which gives a topographical view of a transection of the upper thoracic region in a 12 mm. embryo (series 78, slide IX, section 5, $\times 50$).

The section includes the entire coelom ventrally, and the structures between it and the notochord dorsally. The right (3) and left (6) precaval veins occupy the lateral limits of the dorsal region. In the interval between them are seen the oesophagus (8), the trachea (9), the vagi (22) and the dorsal aortic arches (7). Dorsal to the main veins on each side are the strands of the brachial plexus (not labelled in the figure), and dorsal to the nerves is the primitive ulnar veno-lymphatic (31). Further mesad follow the subclavian arteries (33), the entrance of the dorso-medial venous tributaries (16) into the main veins, and the sympathetic strands (1). The letter Y in the figure, between the notochord and the dorsal mediastinal structures named, indicates the center of the area in which the development of the preazygos segment of the thoracic duct will proceed in the succeeding stages.

The ventral portion of the field contains the coelom, with right (48) and left (49) auricles, right ventricle (50), ascending aorta (7) and ascending trunk of main pulmonary artery (10). Dorsal to this are seen the cross-sections of the right and left pulmonary arteries (10) descending to the lungs. Between them ventrally, and trachea (9), aortae (7), vagi (22) and praecaval veins (3, 6) dorsally, is the area marked by the letter X, in which the development of the broncho-mediastinal trunk will proceed.

A. The development of the broncho-mediastinal or ventral mediastinal lymphatic channels, which drain subsequently caudo-sinistrad into the left thoracic duct, or cephalo-sinistrad into the subclavian approach of the jugular lymph sac, or into both.

In the earlier stages (embryos of 11-14 mm.), an extensive ventral venous capillary network develops between the main

venous trunks of the right and left sides, involving the distal part of the internal jugular, the common jugular and the innominate veins.

Out of this general antecedent sinistro-dextral capillary reticulum the definite retro- or suprathymic innominate anastomosis develops subsequently in normal individuals, but in the earlier stages this plexus extends both ventral and dorsal to the thymus anlage.

The venous network develops, in addition to the prevertebral and dorsal somatic components, chiefly on the lateral aspect of the oesophagus, in the peri-tracheal area, and around the thymus and the common carotid artery. It trends cephalo-laterad towards the main venous line (jugulo-innominate), into whose mesal surface the terminals of the plexus discharge.

In so doing they encounter, and partially surround, the sympathetic and vagus nerves, and the thymus body. Consequently the terminal branches of this ventral mediastinal plexus enter the main vein both ventral and dorsal to these three structures and through the intervals between them. Thus the composite plan of this venous area appears as shown in the schematic fig. 101, which represents the combination of a number of transverse sections of the anterior thoracic region.

The terminal connections of the ventral mediastinal plexus may be grouped in reference to their derivation and their relation to adjacent fields of venous drainage into the following five sets, (fig. 101):

1. Dorso-medial somatic tributaries of internal and common jugular and of innominate veins (fig. 101, 16) entering the main venous channel dorsal to the sympathetic nerve, and frequently combined with

2. Terminal of prevertebral venous plexus anterior to azygos veins (fig. 101, 17).

3. Terminal of peritracheal plexus passing laterad between sympathetic (1) and vagus (22) nerves (fig. 101, 18).

4. Ventral mediastinal branch, draining, as "suprathymic plexus," the area between the thymus (21), carotid (23) and vagus (22). This is the line of the future typical permanent left innominate anastomosis dorsal to the thymus (fig. 101, 19).

5. Subthymic plexus, passing ventral to the thymus anlage (fig. 101, 20). This forms, if retained and further developed in the adult, the occasionally observed "prethymic" left innominate vein ⁽³⁶⁾.

Any number of good examples of all these conditions are afforded by every 13 or 14 mm. embryo. Thus in a 14 mm. embryo (series 210, slide viii, section 41, $\times 225$), fig. 102, direct comparison of the schema shown in fig. 101 with the section will, without further description, make the arrangement of the elements composing this plexus (16, 17, 18, 19, 20) clear. (Compare also fig. 43 [series 189, slide vii, section 10, 13.5 mm.] and fig. 30 [series 210, slide viii, section 39, 14 mm.]

The ventral divisions of this plexus extend in the earlier embryonic stages (11-12 mm.) as a well developed capillary reticulum into the upper thoracic region around and between oesophagus, trachea, precardinal veins, vagi and pulmonary arteries.

Beginning in some 12 mm. embryos, but more constantly and characteristically in the 13 mm. stage, certain components of this ventral mediastinal venous plexus appear partly surrounded by independently developed extraintimal lymphatic spaces, which form the anlagen of the future broncho-mediastinal lymphatic trunk.

Thus, if the ventral portion of this venous plexus is followed caudad into the upper thoracic region, into the area of the developing broncho-mediastinal trunk marked X in fig. 100, the following observations can be made in stages of the proper length, and adequately fixed and stained:

1. In embryos between 11 and 12 mm. only venous capillaries are found. Thus figures 103 and 104 show transverse sections of this part of the upper thoracic region in a 12 mm. embryo (series 217, slide viii, sections 21 and 29, $\times 200$). The field, caudal to oesophagus and aorta (γ), contains in the middle line the trachea (9), the vagi (22), and further ventrad, the pulmonary

³⁶ Geo. S. Huntington: "Contribution to the topographical anatomy of the thorax in the fœtus at term and the new-born child." Rep. Soc. N. Y. Lying-in-Hospital, 1897, p. 343, fig. xxxi.

arteries (10). The branches of the peritracheal venous plexus (18) are well developed. There is as yet no indication of lymphatic development.

2. In 13 mm. embryos certain of the venous radicles entering into this plexus, are partly surrounded and enveloped by extraintimal lymphatic spaces, which arise independently of the venous system, as the first anlagen of the future ventral mediastinal lymphatic channel. Figures 105 and 106 show transverse sections of this region in a 13 mm. cat embryo (series 92, slide vii, sections 30 and 33) in a magnification of 225 diameters. Ventral to trachea (9), aorta (7) and left vagus (22) are seen sections of a number of venous radicles (4) of the ventral mediastinal plexus, some of which are partially surrounded by very small extraintimal perivenous lymphatic anlagen (5). Only a few of the most prominent of these are indicated in the figures by leaders, but they exist in many other parts of the field.

A similar section from another 13 mm. embryo (series 107, slide ix, section 40, \times 225) is shown in figure 107. Dorsal to the pulmonary arteries (10), between them and the trachea (9) and aorta (7), the section has cut a prominent extraintimal lymphatic space (5) in typical relation to one of the radicles (4) of the ventral mediastinal venous network.

3. In the 13.5 mm. embryo the full and convincing proof of the extraintimal derivation of this channel is given. In some embryos of the period the process is still seen in its earlier stages. Thus figs. 108 and 109 (13.5 mm. embryo, series 223, slide x, sections 11 and 12, \times 225) show on each side, ventral to the trachea (9) and the vagi (22), a number of radicles (4) of the ventral mediastinal capillary plexus. One of these small vessels, symmetrically disposed on each side in front of the respective vagus, is in process of being surrounded and replaced by an extraintimal lymphatic space (5).

Other 13.5 mm. embryos show a rapid advance in the perivenous lymphatic development.

Fig. 110 shows a transverse section of the upper thoracic region of another 13.5 mm. embryo (series 189, slide viii, section 35, \times 225). Just ventro-mesad of the left vagus nerve and its

encircling vein is a venous radicle (4) almost completely surrounded by an extraintimal lymphatic space (5) in the process of replacing the atrophying vein with which it is so closely associated. The same structures (4, 5) are seen still more clearly defined in the corresponding position on the right side of the embryo.

Comparison with the corresponding sections just given in figures 103 to 109 show that the extraintimal anlage of the earlier stages, developed along the identical venous radicle, has increased in the 13.5 mm. stage, so as to nearly envelop the vein, and that the latter, if followed cephalad and caudad, is now separated from the functional venous channels of this region and is in the process of further recession and degeneration as the lymphatic perivenous space enlarges and more and more replaces the antecedent venous channel. The vein in question in the older embryo (series 189) appears collapsed and shrunken, and contains only a few degenerating red blood cells. In the same situation on the right side of fig. 110 (series 189, slide viii, section 35), the section has cut the corresponding vein and the enveloping extraintimal space at right angles, so that the central kernel of the shrinking vein (4), still containing a few degenerating red blood cells, is nearly completely surrounded by the replacing extraintimal lymphatic (5).

Fig. 111 shows the following section of the same embryo (series 189, slide viii, section 36), magnified 225 diameters, in a larger field which gives the topographical relations and may serve in the orientation of the succeeding plates. The ventral circumference of the oesophagus (8) and the aorta (7) are seen dorsally. The trachea (9), with the vagi (22) on either side, occupies the central area. Ventrally are the two pulmonary arteries (10). The section is a most important one in interpreting the early histogenetic stages of the broncho-mediastinal lymphatic trunk and its relation to the embryonic mediastinal venous plexus. The same venous radicle (4), ventral to the vagus (22), already noted in the preceding section (fig. 110), is seen on each side. On the left side it has been cut obliquely by the plane of the section, and hence shows a segment of considerable length, as a practically empty and partially collapsed endothelial bag (4),

surrounded by the extraintimal lymphatic space (5). On the right side of the embryo the corresponding venous radicle (4) and the perivenous lymphatic anlage (5) have been again cut more at right angles, so that the envelopment of the former by the latter can be clearly traced nearly throughout the entire circumference.

Fig. 111A shows the decadent vein and the replacing extraintimal lymphatic on the left side of this section in a higher magnification, ($\times 300$). The structure of the collapsed venous endothelial tube, and the beginning development of endothelial character in the mesodermal cells limiting the perivenous extraintimal lymphatic anlage, can be here clearly made out.

Figs. 112 to 116 show the five succeeding sections of the same embryo (series 189, slide viii, sections 37 to 41 inclusive) in a magnification of 225 diameters.

I publish this series of plates in order to prove on the one hand that the extraintimal lymphatic anlages can be followed with certainty and accuracy in their relation to the contained decadent venule for longer or shorter distances, and that, on the other hand, they are, in these earlier stages, still isolated and not yet continuous with similar anlages in adjacent areas. They form, in other words, in these earlier periods, detached links of a lymphatic chain, not yet united to each other to form the continuous channel of the later stages.

In figs. 112, 113 and 114 (sections 37, 38 and 39) beautiful and clear pictures of the atrophying central venule (4) and the perivenous extra-intimal lymphatic space (5) are found on both sides in the typical situation noted in the preceding sections, with which they of course can easily be coördinated by simple comparison.

Sections 38 and 39 (figs. 113 and 114) are particularly instructive inasmuch as the detached central vein (4) on the left side still contains a few degenerating red blood cells, while its former connection with the valid and functional venous plexus around the left vagus nerve can still be faintly traced.

In section 40 (fig. 115) the atrophying vein (4) and the surrounding lymphatic (5) of the left side appear divided into two

components. On the right side the corresponding structures end blindly.

In the following section (41, fig. 116) the left venule and lymphatic also terminate almost entirely in the indifferent mesodermal tissue, only a small remnant (4, 5) persisting between trachea and left vagus. This disappears entirely in the following section.

The succeeding stage (14 mm.) shows the same lymphatic anlagen surrounding and replacing the atrophying venules of the ventral mediastinal plexus in still higher development. It appears from the study of numerous embryos of this length, that the average 14 mm. stage represents the point in the lymphatic ontogenesis of this region at which the pictures are most striking. The central kernel of the decadent vein is still large and, in places, as yet incompletely separated from the definite venous channels. At the same time the perivenous lymphatic space has acquired an increased lumen and hence the two combined structures occupy a relatively large field.

Thus figs. 117 to 122 show transverse sections of the ventral thoracic region in a 14 mm. cat embryo (series 212, slide x, sections 4, 5, 6, 7, 10 and 11, $\times 225$). In figs. 117 and 118 the developing lymphatic anlagen (5) of the broncho-mediastinal trunk can be readily recognized and present the same relation to the atrophying venules, which they surround, as in the sections of the preceding series just described and figured. In contradistinction to these structures the components of the permanent functional venous plexus of this region (32) form well-differentiated vascular channels.

In fig. 119 (series 212, slide x, section 6) the scattered lymphatic anlagen occupying in the two preceding sections the space between the left pulmonary artery (10) and the left vagus (22), with its accompanying ventral mediastinal vein (32), are gathered together into a more extensive elongated space (5). In the interior of this is seen the endothelial bag of the empty and atrophying venule (4) which the lymphatic is about to replace. The vein remnant is almost completely surrounded by the lymphatic space and only connected to the latter's endothelial wall by a bridge at one point. Other areas of similar lymphatic devel-

opment are seen on the opposite side (4-5) and (not labelled) in the center of the field, but the structures on the left side are, as in the earlier stages (cf. series 189) better developed and larger.

The succeeding figures, 120, 121 and 122 (sections 7, 10 and 11) show the same structures, which can be distinctly followed for some distance caudad of the last section figured. In fig. 122 the original connection of the large upper venous kernel of the left side (4) with one of the components of the peritracheal venous plexus (18) is still suggested by the arrangement of the adjacent cells, although the degenerating vein has been cut off from all actual communication with the permanently valid channels of the mediastinal venous plexus.

The 14 mm. stage is so important, and the results gained by the examination of a large number of embryos so conclusive in respect to the true ontogenesis of the systemic lymphatic channels, that I have selected a well marked example and publish here eighteen consecutive, or nearly consecutive, sections from the same individual. I do this in order to show the extent to which extraintimal perivenous lymphatic development has proceeded in this stage, in respect to the length of the resulting segments of the future lymphatic channel, still separated from each other, and to accentuate, by a large number of successive illustrations from the same embryo, the histogenesis of the lymphatic anlagen in their relation to the decadent embryonic venules which they eventually entirely replace. The conception involved by the theory of extraintimal systemic lymphatic development has proved apparently, to judge from published comments, difficult to understand in some laboratories from the histo-mechanical standpoint. The following eighteen reproductions of sections of a 14 mm. embryo (series 214, slide xiii) surely explain, without detailed description, the principles underlying lymphatic ontogenesis in the mammalian embryo. I very gladly welcome the opportunity, which this series of Wistar publications offers, for presenting them.

The plates comprised in this group are shown in order cephalocaudal in figures 123 to 141 inclusive. In all of them the ex-

traintimal lymphatic anlagen of the broncho-mediastinal trunk are indicated by the leader 5, while the included remnant of the atrophying embryonic vein is labelled 4, as in the preceding and following figures.

Figs. 123, 124, 125 and 126 (sections 4, 5, 6 and 7) show well the relation of the venule (4), undergoing atrophy and replacement by the extraintimal lymphatic space (5), to the permanent venous channels of the mediastinal plexus. Thus in fig. 123 the dorsal large lighter area marked 4 is the blind cephalic end of a venule which is nearly detached from the permanent peritracheal (18) and ventral mediastinal (32) venous channels, and which in the succeeding sections is seen to be partially surrounded by the extraintimal lymphatic space (5) eventually designed to replace it entirely.

In figure 124 (section 5) this perivenous space (5) has developed. The included vein (4) is still partially connected with the functional peritracheal plexus (18). Further ventrad is another portion of this same plexus. The venous kernel here still contains a number of red blood-cells. These characteristic relations of developing lymphatic and receding vein can be followed clearly throughout the succeeding sections. The contrast between the well filled permanent veins (*e.g.*, 18, 32 in figs. 123, 124, 125 and 126), with walls fitted closely into the surrounding mesenchyme, and the atrophying venule surrounded by the extraintimal lymphatic anlage, is striking throughout the series. Some of the sections show in certain regions good pictures of nearly complete reduction of the decadent vein to an insignificant central kernel of connective tissue surrounded by the extraintimal lymphatic space; thus, *e.g.*, figs. 137 to 141 in the region ventro-mesad to the left vagus (22).

The 15 mm. stage shows the developing lymphatic plexus of the broncho-mediastinal trunk further advanced. Figs. 142 to 145 show four successive transverse sections through the ventral part of the upper thoracic region in a 15 mm. cat embryo (series 216, slide x, sections 32, 33, 34 and 35, $\times 225$). The central decadent venule in the interior of the developing perivenous lymphatic space has in many places disappeared entirely, leav-

ing only the clear lymphatic lumen (5). In other places remnants of the replaced vein (4) can still be distinctly determined. This clearance has resulted in a relative diminution of the actual area of a cross section of the meshes of the lymphatic plexus, since now the entire lumen is given over to the newly formed lymphatic channel, whereas in the earlier stages its central area was still largely filled by the degenerating vein. The lymphatic spaces in these sections have increased considerably in number. (Only a few of the more prominent vessels are indicated in the figures by leaders.)

A transverse section of this region in a 15.5 mm. cat embryo (series 215, slide xiv, section 31, $\times 225$) is shown in a fig. 146. The preceding more diffuse lymphatic plexus of the earlier stages is condensed to a much smaller mesenchymal network. In a few of the larger meshes a remnant of the former central vein (4) can still be traced as a solid plug of mesoderm surrounded by the lymphatic channel (5).

In general the 15 and 15.5 mm. embryos of the cat represent the stages in the development of the broncho-mediastinal trunk in which the histological pictures of the lymph channels are least distinct and striking. This is due to the fact that on the one hand they have lost the central venous kernel around which they were originally developed through confluence of extraintimal spaces, and which gave to the combined structures their area on section and their distinctive appearance in the earlier (13.5 and 14 mm.) stages, while on the other hand the independent growth and enlargement of the lymph channels proper begins in the 16 mm. stage. In some embryos, measuring 16 mm., the appearances characteristic of the 15 mm. and 15.5 mm. stages are still encountered. Thus fig. 147 shows a transverse section through the ventral area of the upper thoracic region in a 16 mm. embryo (series 230, slide xii, section 25, $\times 225$). The correspondence of the histological picture to that presented by the 15 mm. or 15.5 mm. embryo is seen by comparison with series 215 and 216 (figs. 142 to 146).

The majority of 16 mm. embryos show, however, a marked advance in the independent growth of the lymphatic channels,

which have become fully established. Their lumen now appears for the most part entirely cleared of the remnants of the decadent venules originally contained therein. In only a few instances does the original vein kernel appear reduced to an insignificant rudiment. The resulting plexus of the broncho-mediastinal lymphatic duct fills the typical position occupied in the earlier stages by the extensive preceding perivenous lymphatic reticulum. Thus figs. 148-153 give transverse sections through the ventral part of the upper thoracic region in another 16 mm. cat embryo (series 222, slide X, sections 1, 2, 3, 10, 15 and 16, $\times 225$). This embryo affords remarkably clear pictures of the fully developed lymphatic plexus of the ventral or broncho-mediastinal trunk.

Figs. 148 and 153 (sections 1 and 16) give the topographical pictures of the entire region involved. The broncho-mediastinal lymphatic plexus (37) is fully developed in the typical area between the trachea (8) and vagi (22) dorsally and the pulmonary arteries (10) ventrally. The lymphatic spaces possess a clear lumen and distinct endothelial walls. The remnants of the degenerating ventral mediastinal venous plexus which they have replaced have almost entirely disappeared. Only slight traces of them are still to be seen here and there. In the main the lymphatic channels are clear of venous kernels and form a rich interlacing lymphatic plexus. The central field contains the oesophagus (8), aorta (7) and part of the medial circumference of the left praecava (6). Dorsally on the right side the right azygos vein (3) and sympathetic nerve (1) appear, while on the left side the section includes the cephalic part of the azygos segment of the left thoracic duct (36).

Sections 2, 3, 10 and 15 of the same slide are shown in their ventral portions in figs. 149 to 152. They all exhibit the extent and continuity of the broncho-mediastinal lymphatic channel complex in this stage. The figures are not leadered, but the individual structures can be readily identified by reference to the topographical figures 148 and 153.

The succeeding stages are characterized by a condensation of the extensive lymphatic plexus of the typical 16 mm. and 17 mm.

embryos into the more definite channel of the broncho-mediastinal trunk with larger caliber.

Figs. 154 to 158 show the region of the broncho-mediastinal channel in four successive sections in a 20 mm. cat embryo (series 241, slide xix, sections 19, 20, 21 and 22, $\times 225$). Fig. 154 again gives a topographical view of the entire field, while the same is cut down to the ventral portion in the remaining plates. In all the multi-meshed lymphatic plexus of the preceding stage is replaced by the more definite and larger channel of the broncho-mediastinal trunk proper (37), in the classical situation between the pulmonary arteries (10) ventrally and the trachea (9), vagi (22) and permanent ventral mediastinal veins (18) dorsally.

This stage marks the practical attainment of adult conditions for the lymphatic channel of the broncho-mediastinal trunk, and from this period on its further development is merely a question of continued growth and adaptation to the environment in establishing secondary connections with the tributary channels, developed independently, the preazygos segment of the thoracic duct, and (usually) the ventral prolongation of the subclavian approach of the jugular lymph sac.

As will be seen from the foregoing analysis of the development of the broncho-mediastinal lymphatic trunk in embryos of the cat, the principles of mammalian systemic lymphatic ontogenesis defined in Part I of this memoir are consistently sustained by the actual evidence afforded. The development of the perivinous extraintimal anlagen which form the basis for the subsequent evolution of the systemic lymphatic channels, is a uniform and remarkably consistent process.

The existence of these spaces in this and other regions of the embryo has been so often denied by recent contributors to the subject, or, if admitted, explained in every possible way except through the correct interpretation, that I publish in this paper a series of micro-photographs of a considerable number of sections taken from embryos of all the important stages. Of course these observations could be indefinitely multiplied. The larger the embryological collection, and the better the individual preparations are fixed and stained, the more conclusive will be the

results of a careful examination of lymphatic development along the lines here indicated.

No competent and impartial observer can mistake the significance of the conditions here shown. Every stage of the process can be followed in detail. The behavior of the decadent embryonic vein, and its relation to the enveloping extraintimal lymphatic channel, are absolutely demonstrated. The endothelium of the shrinking vein has no share in furnishing the independent lymphatic endothelium of the replacing mesenchymal space, and nowhere, in the entire process, is there the faintest suggestion of an "out-bud" or of a "splitting off" from the circumference of an otherwise valid embryonic vein of "lymphatic" or "veno-lymphatic" anlagen.

It is evident in comparing a number of embryos between 13 and 16 mm., crown-rump measure, that the extensive area occupied by the lymphatic anlagen in the earlier stages (13 mm., 13.5 mm. and 14 mm.) is due to the relatively large size of the central decadent vein. In the earlier stages (*e.g.*, figs. 111, 112, 113, 114, 119, 121, 125, 126, 127, series 189, 212 and 214) the evacuated and abandoned vein appears as a wide loose and partially collapsed endothelial bag, surrounded by a narrow extraintimal lymphatic space, with but as yet indifferently defined endothelial lining, continuous at one or more points with the external surface of the endothelium of the degenerating vein. As development proceeds the *actual* perivenous *lymphatic* spaces increase but they concentrate and narrow down on the contained venous kernel, and, as the latter continues to decrease in size and finally become completely eliminated, the resulting clear lymphatic channel occupies relatively less space than that filled in the earlier stages by the decadent venule and the early surrounding lymphatic anlage combined.

Thus in the 15, 15.5 and in some 16 mm. embryos (figs. 142, 143, 144, 145, 146, and 147, series 216, 215 and 230), while the actual lumen of the lymphatic channel has increased that of the enclosed and abandoned vein has correspondingly receded to an insignificant remnant, which projects into the lymphatic space from a narrow pedicle attached to the latter's endothelial lining.

Consequently, in the pictures of the earlier stages (13, 13.5 and 14 mm. embryos) the area occupied by the still capacious abandoned venous channel, combined with that of the relatively narrow enveloping lymphatic space, appears larger and more prominent than in the later periods (15, 15.5 mm.) in which the permanent lymphatic channel and its reduced venous kernel occupies less histological territory.

It should also be noted that in the earlier stages (13, 13.5, 14 mm.) the perivenous extraintimal lymphatic network is more diffuse and redundant than in the later stages (15, 15.5, 16 mm.). This early plexiform lymphatic reticulum is subsequently condensed into more limited and better defined lymph channels, in exact conformation to the processes observed in the haemal vascular development, in which the definite blood channels crystallize along main lines out of an antecedent indefinite and more diffuse plexus. The result of this genetic process is striking in tracing developing lymphatics through successive stages. Thus in the region here under discussion the pictures offered by the 13, 13.5 and 14 mm. embryos are more conclusive than those furnished by the 15 and 15.5 mm. stages in reference to the genesis of the lymphatic channels. In the former, the lymphatic anlagen and the decadent venules around which they develop are taken together, relatively larger and more numerous, and hence easier to recognize. In the latter, this early redundant perivenous lymphatic plexus has been replaced by a relatively smaller, but much more definite and distinct channel, occupying, however, always a part of the area filled in the earlier stages by the less circumscribed antecedent lymphatic plexus with its contained remnants of abandoned embryonic veins. I lay special stress on this fact, because it is absolutely necessary to take it into account in comparing stages between 13.5 and 15.5 mm. In the latter stage the final lymphatic anlagen have definitely formed and have reached the relation to adjacent main venous lines which they henceforth are to occupy. The further growth and enlargement of these channels begins in the 16 mm. embryo, and proceeds from this point on, in many regions at the expense of the adjacent embryonic vein undergoing atrophy.

The only conclusion which seems to me to be warranted by actual observation is that certain embryonic veins form, during the process of their atrophy and final elimination from the definite venous organization, the supporting lines along which certain of the perivenous extraintimal lymphatic anlagen first develop.

The fact that numerous early embryonic venous channels, large and small, atrophy and disappear during the normal course of subsequent development, appears to afford a more favorable field for the greater development of the adjacent mesenchymal intercellular spaces, so that these enlarge more rapidly, as the correlated vein recedes. This relationship appears, however, to be based exclusively on the physical and mechanical advantages which the abandoned and shrinking primary venous line affords to the adjacent mesenchymal spaces for more rapid enlargement, in the sense of replacing the disappearing vein and occupying secondarily the space formerly filled by the haemal channel. This is evidently an important factor in determining the size and extent of the final lymphatic channel resulting from the confluence of the originally separate and independent perivenous anlagen. Consequently, in the adult, the largest and best defined systemic lymphatic vessels either accompany reduced adult remnants of a relatively larger embryonic venous channel, or, in case of the latter's entire default, topographically replace the same. Now, while this relation manifests itself strikingly in many parts of the body, it is quite evident that the development of lymphatic channels occurs in other parts independently of preceding veins, by the confluence of independent intercellular mesenchymal spaces.

The cat may, and does, differ in its details of lymphatic development, and in its adult lymphatic organization, from the conditions obtaining in many other mammalian forms. In fact, even in the present very incomplete state of our knowledge of the comparative anatomy of the mammalian lymphatic system, we realize that what we regard as the mammalian ground plan of lymphatic organization may in certain genera undergo great and far-reaching modifications, as for example the conditions deter-

mined by Silvester³⁷ for the whole group of the *Cebidae*, and those found by myself in *Macropus rufus*. And yet these differences, established and maintained within the natural limits of the mammalian class, cannot, in whatever degree they actually exist, in individual forms be *basic*. In any given mammalian type, the systemic lymphatic vessels, whatever their adult relation to and connection with the venous system may be, must develop in accordance with a genetic ground plan common to all mammalia.

³⁷C. F. Silvester. "On the Presence of Permanent Lymphatico-Venous Communications at the Level of the Renal Veins in Adult South American Monkeys."

Anat. Anz., Ergänzungsh. z. 37. Bd., Vevh. Anat. Ges., 24 Vevs., Brüssels, 1910, S. 111-114.

PART II PLATES

FIGURES 100 TO 158

FIGURE 100

100 Transverse section of upper thoracic region in a 12 mm. cat embryo (series 78f slide IX, section 5), $\times 50$.

- 1 Sympathetic nerve.
- 3 Right azygos vein, thoracic portion.
- 6 Precardinal or precava, resp. azygos of left side.
- 7 Aorta.
- 8 Oesophagus.
- 9 Trachea.
- 10 Pulmonary artery.
- 16 Dorso-medial somatic venous tributaries.
- 22 Vagus.
- 31 Primitive ulnar veno-lymphatic.
- 33 Subclavian artery.
- 48 Right auricle.
- 49 Left auricle.
- 50 Right ventricle.

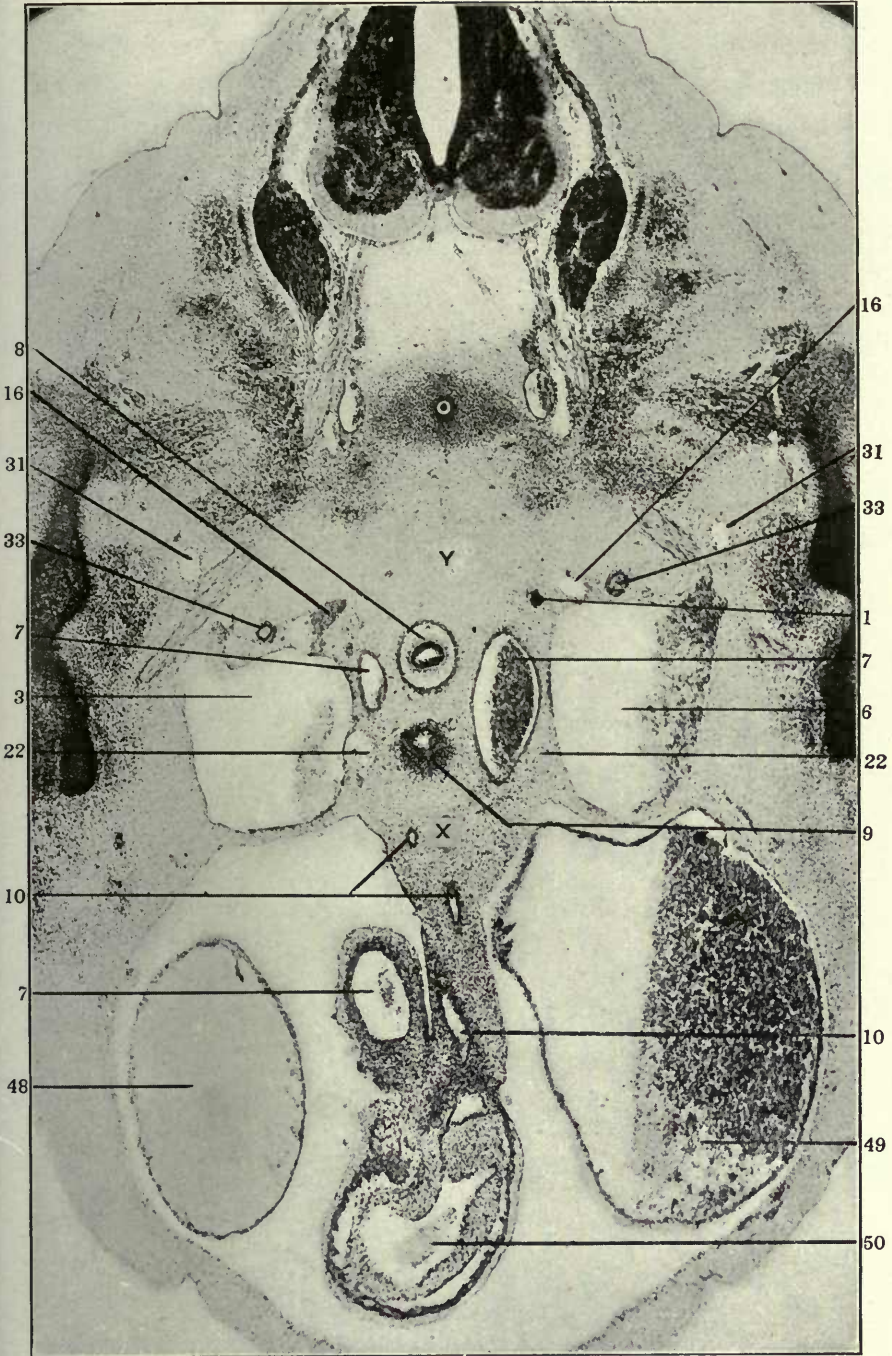


FIGURE 101

101 Schema of venous plexuses of left side in lower cervical region of cat embryo between 13 mm. and 14 mm. crown-rump measure in transverse section.

- 1 Sympathetic nerve.
- 8 Oesophagus.
- 9 Trachea.
- 16 Dorso medial somatic venous tributaries.
- 17 Prevertebral venous plexus.
- 18 Feritracheal venous plexus.
- 19 Suprathymic venous plexus.
- 20 Subthymic venous plexus.
- 21 Thymus.
- 22 Vagus.
- 23 Left carotid artery.
- 24 Thyrocervical artery.
- 26 Common jugular vein.

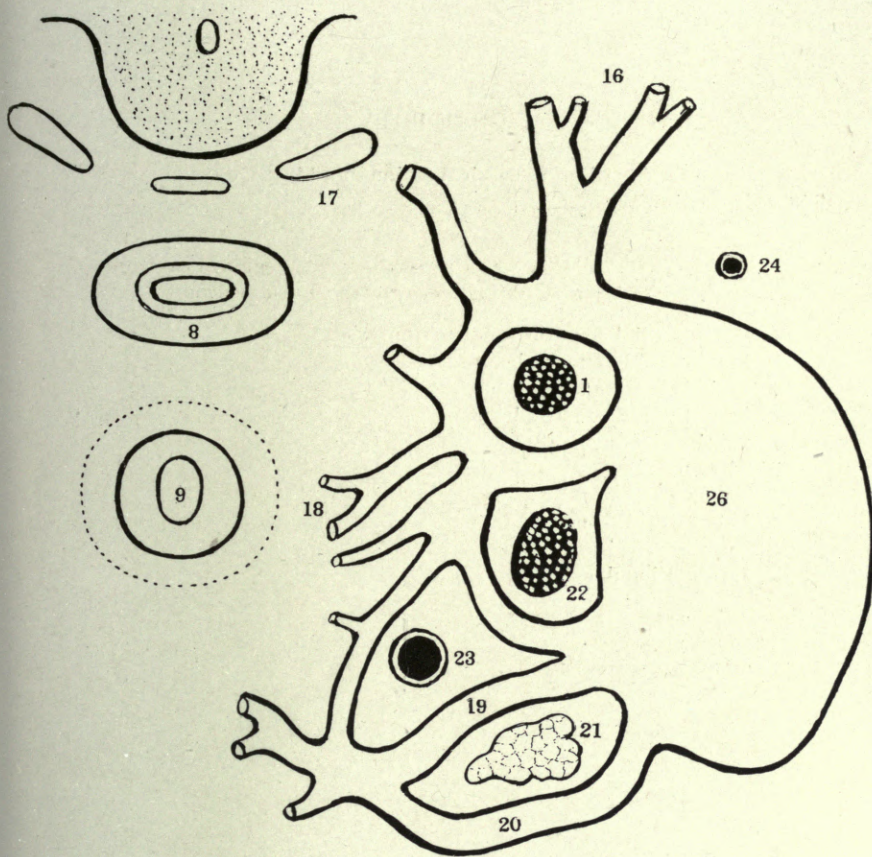
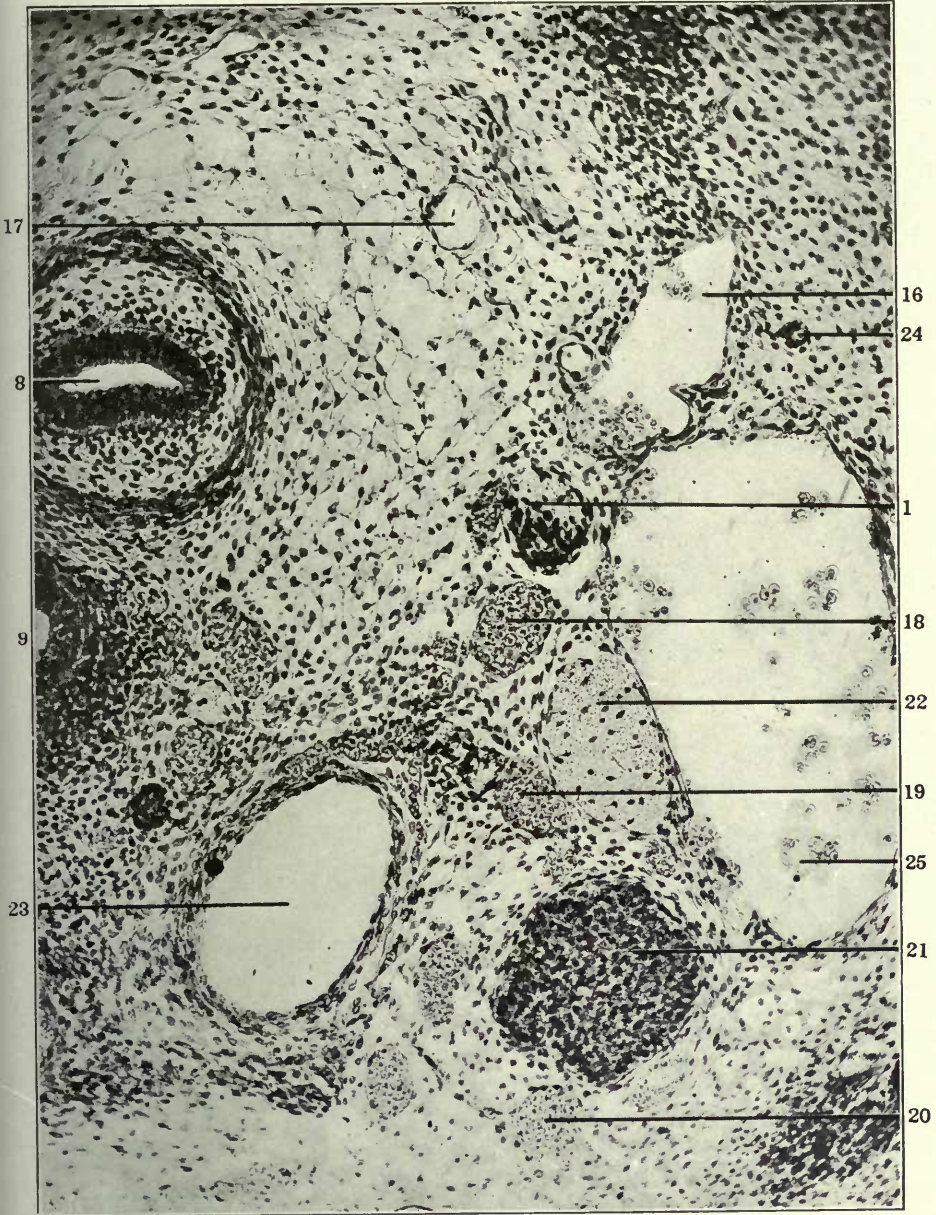


FIGURE 102

102 Transverse section of lower cervical region in a 14 mm. cat embryo (series 210, slide VIII, section 41), $\times 225$.

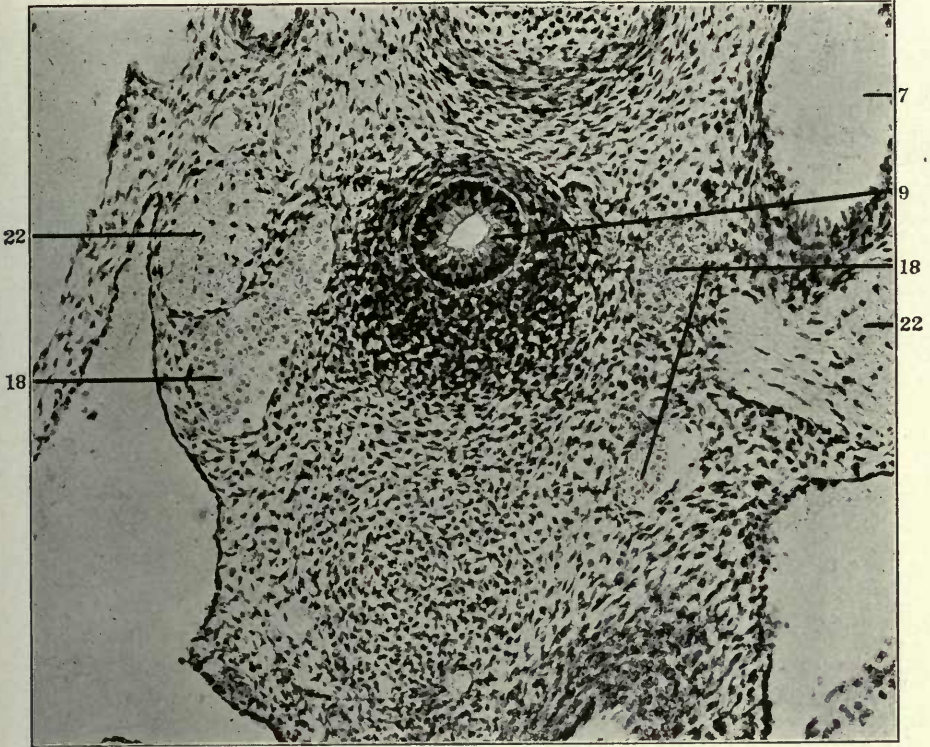
- 1 Sympathetic nerve.
- 8 Oesophagus.
- 9 Trachea.
- 16 Dorso-medial somatic venous tributaries.
- 17 Prevertebral venous plexus.
- 18 Peritracheal venous plexus.
- 19 Suprathymic venous plexus.
- 20 Subthymic venous plexus.
- 21 Thymus.
- 22 Vagus.
- 23 Left carotid artery.
- 24 Thyrocervical artery.
- 25 Internal jugular vein.



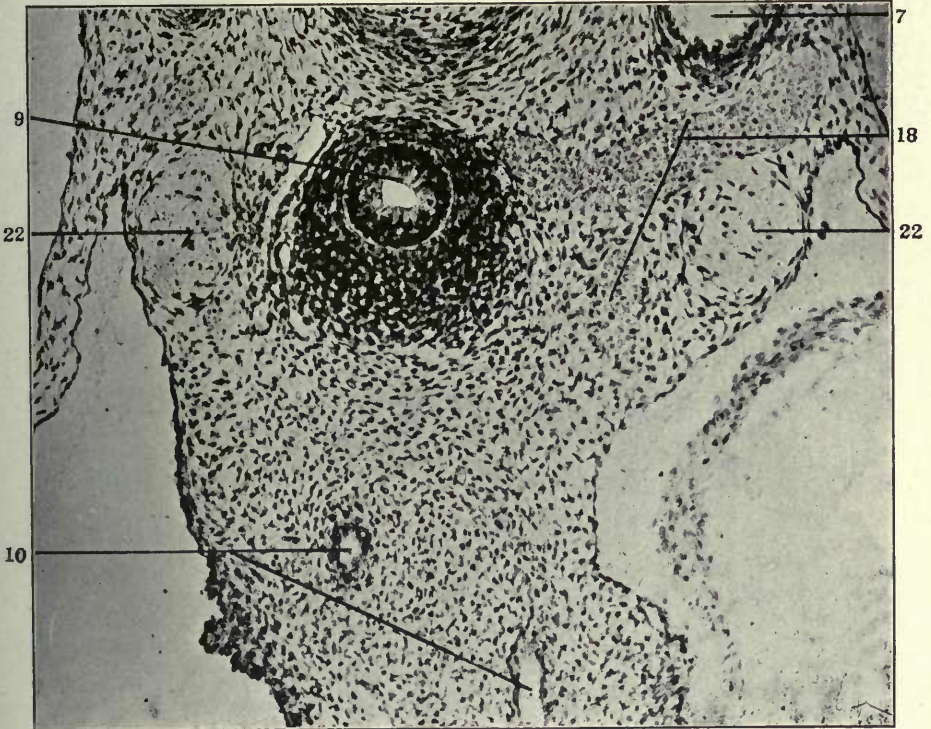
FIGURES 103 AND 104

- 103 Transverse section of ventral part of upper thoracic region in a 12 mm. cat embryo (series 217, slide VIII, section 21), $\times 200$.
104 Same, section 29.

- 7 Aorta.
9 Trachea.
10 Pulmonary artery.
18 Peritracheal venous plexus.
22 Vagus.



103



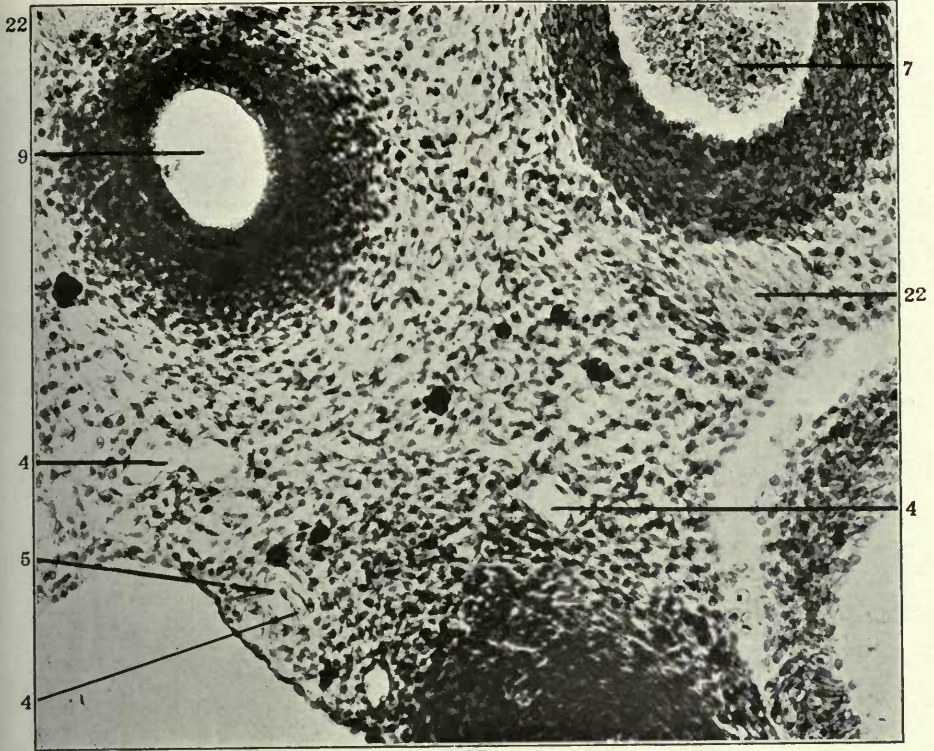
104

FIGURES 105 AND 106

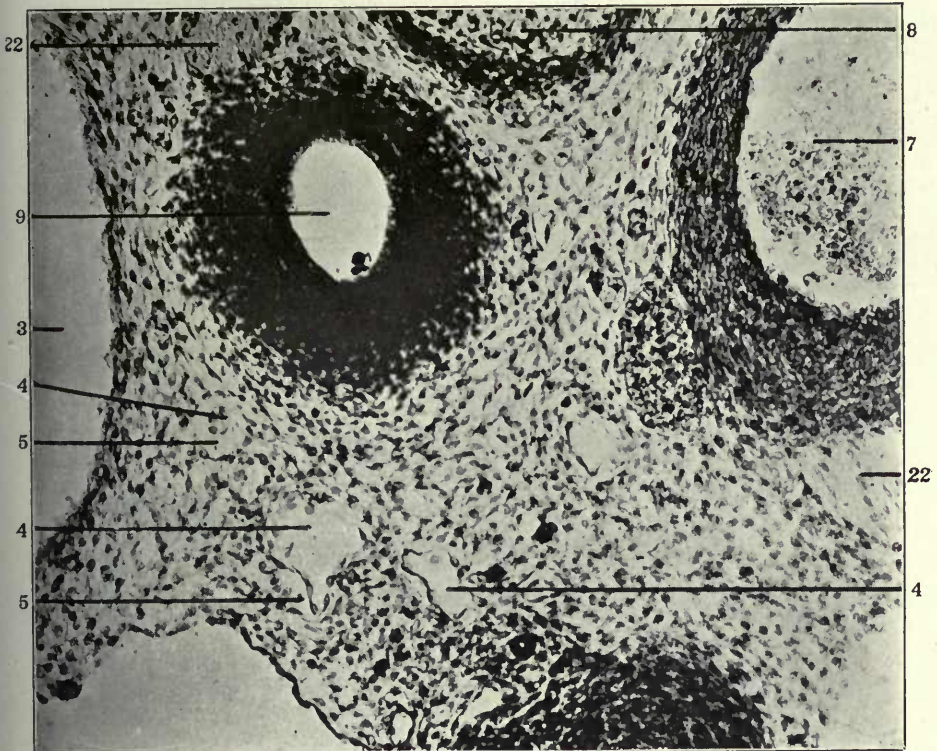
105 Transverse section of ventral part of upper thoracic region in a 13 mm. cat embryo (series 92, slide VII, section 30), \times 225.

106 Same, section 33.

- 3 Right precaval vein.
- 4 Atrophying embryonal vein, forming kernel in interior of developing and replacing lymphatic space.
- 5 Extraintimal or perivenous lymphatic space surrounding degenerating embryonal vein.
- 7 Aorta.
- 8 Oesophagus.
- 9 Trachea.
- 22 Vagus.



105

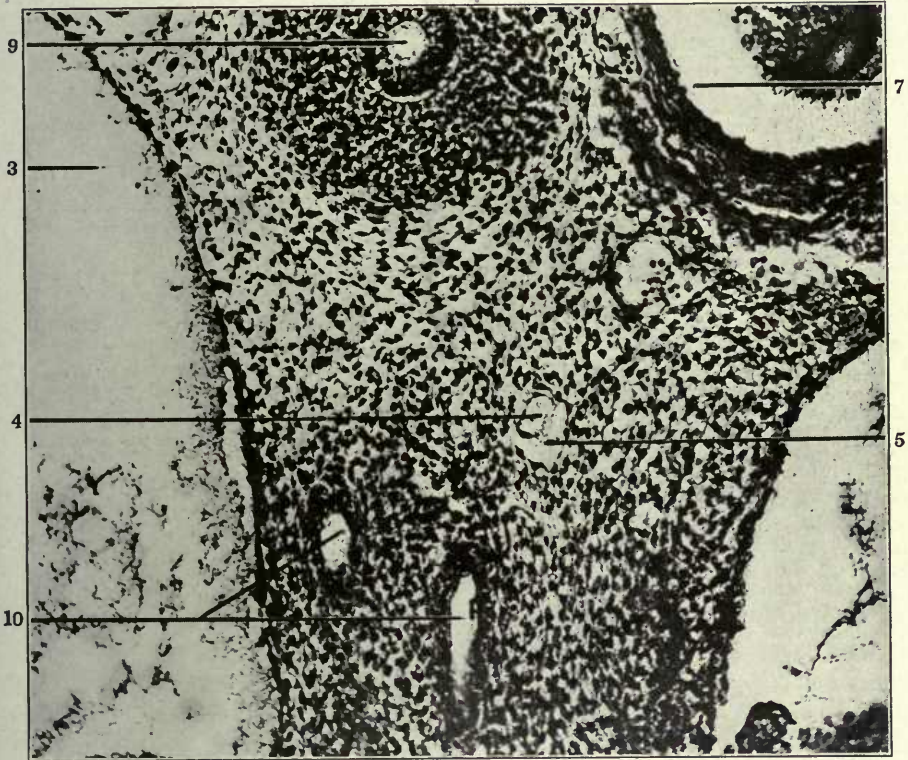


106

FIGURE 107

107 Transverse section of ventral part of upper thoracic region in a 13 mm. cat embryo (series 107, slide IX, section 40), $\times 225$.

- 3 Right precaval vein.
- 4 Atrophying embryonal vein, forming kernel in interior of developing and replacing lymphatic space.
- 5 Extraintimal or perivenous lymphatic space surrounding degenerating embryonal vein.
- 7 Aorta.
- 9 Trachea.
- 10 Pulmonary artery.

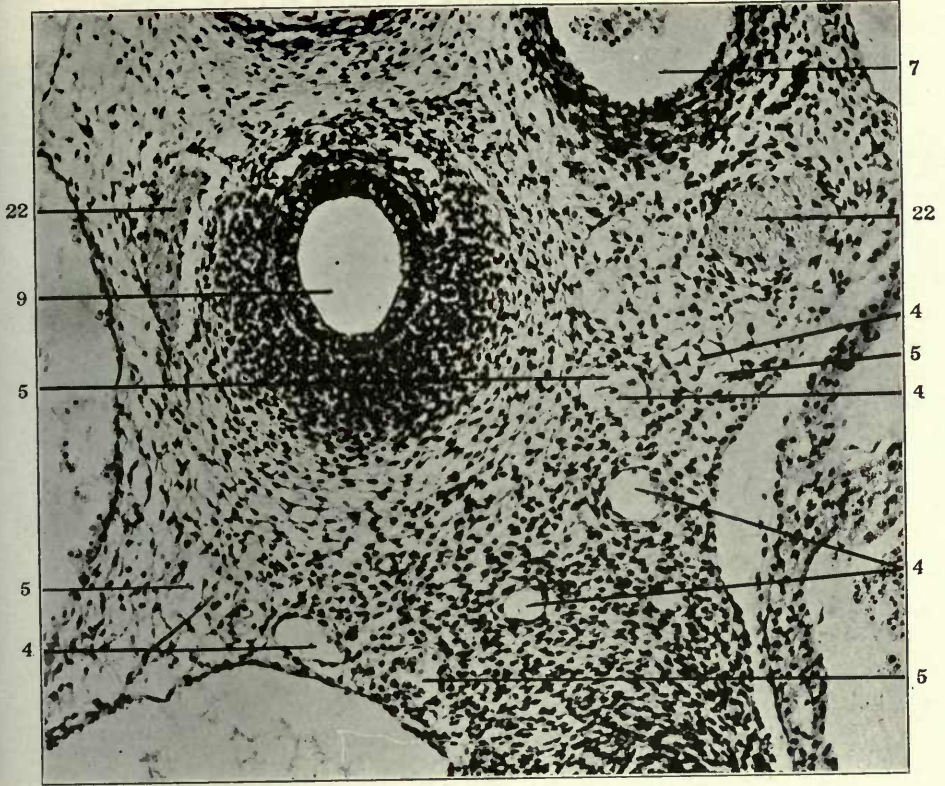


FIGURES 108 AND 109

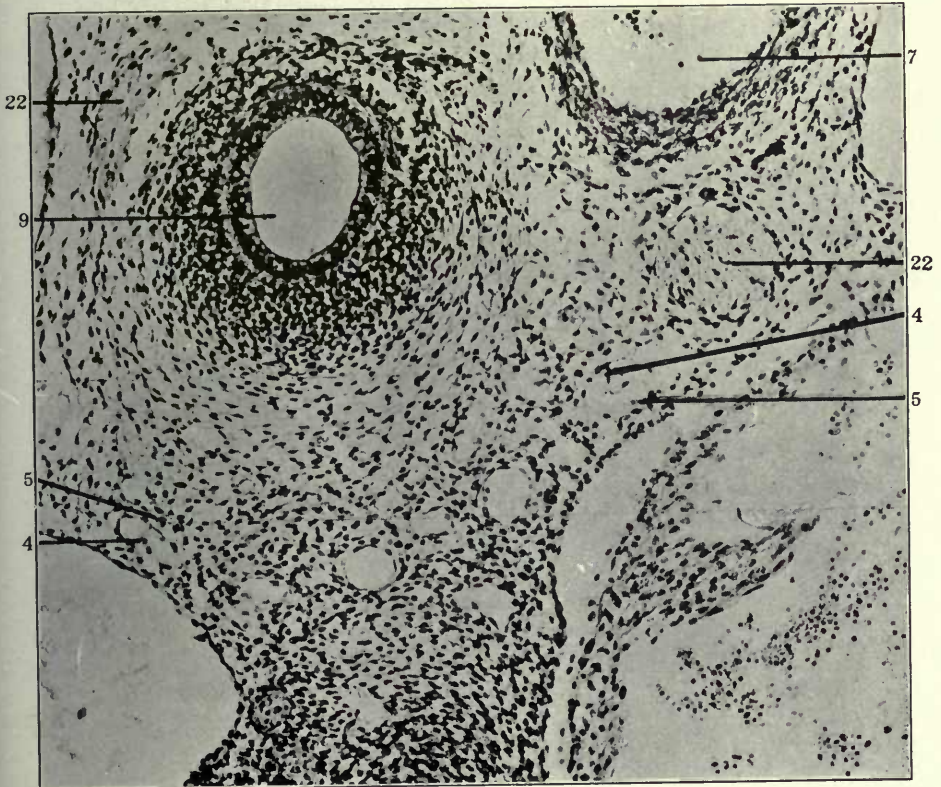
108 Transverse section of ventral part of upper thoracic region in a 13.5 mm. cat embryo (series 223, slide X, section 11), $\times 225$.

109 Same, section 12.

- 4 Atrophying embryonal vein, forming kernel in interior of developing and replacing lymphatic space.
- 5 Extraintimal or perivenous lymphatic space surrounding degenerating embryonal vein.
- 7 Aorta.
- 9 Trachea.
- 22 Vagus.



108



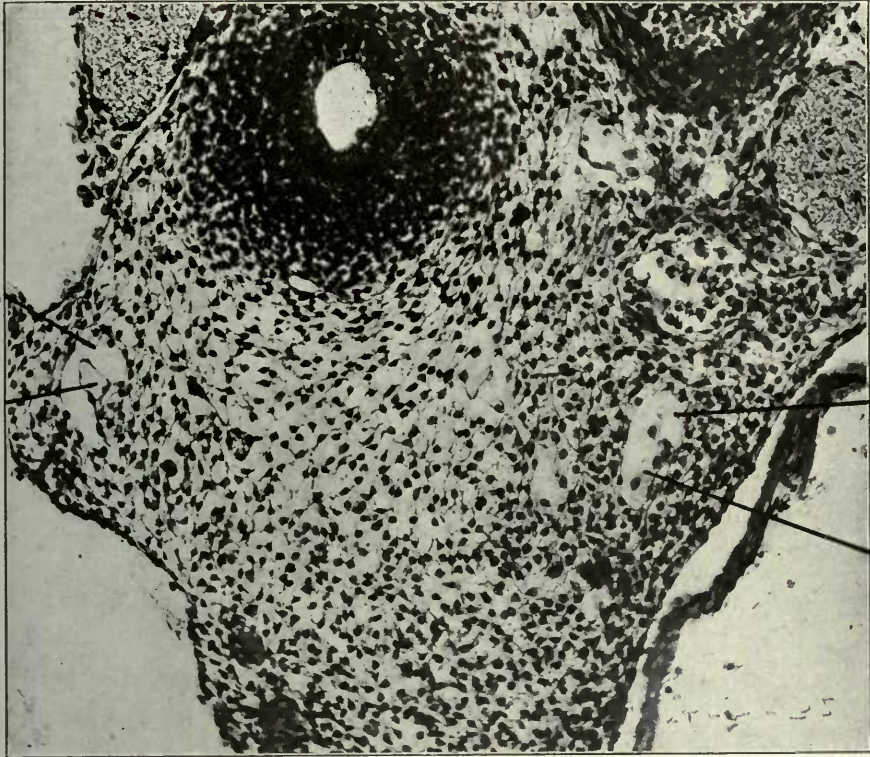
109

FIGURES 110 AND 111A

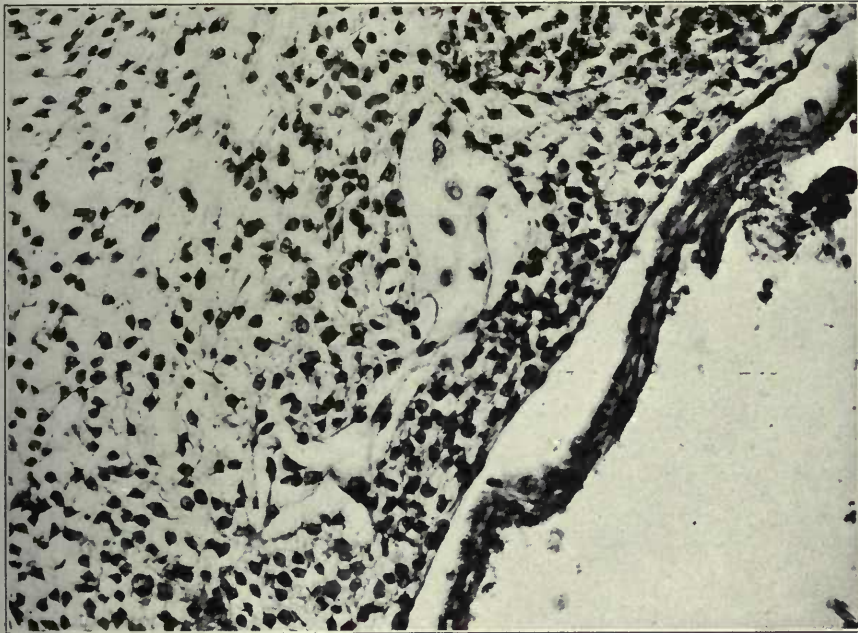
110 Transverse section through ventral part of upper thoracic region in a 13.5 mm. cat embryo (series 189, slide VIII, section 35), $\times 225$.

111A Left part of section 36 of same embryo, shown in the following figure 111, $\times 300$.

- 4 Atrophying embryonal vein, forming kernel in interior of developing and replacing lymphatic space.
- 5 Extraintimal or perivenous lymphatic space surrounding degenerating embryonal vein.



110

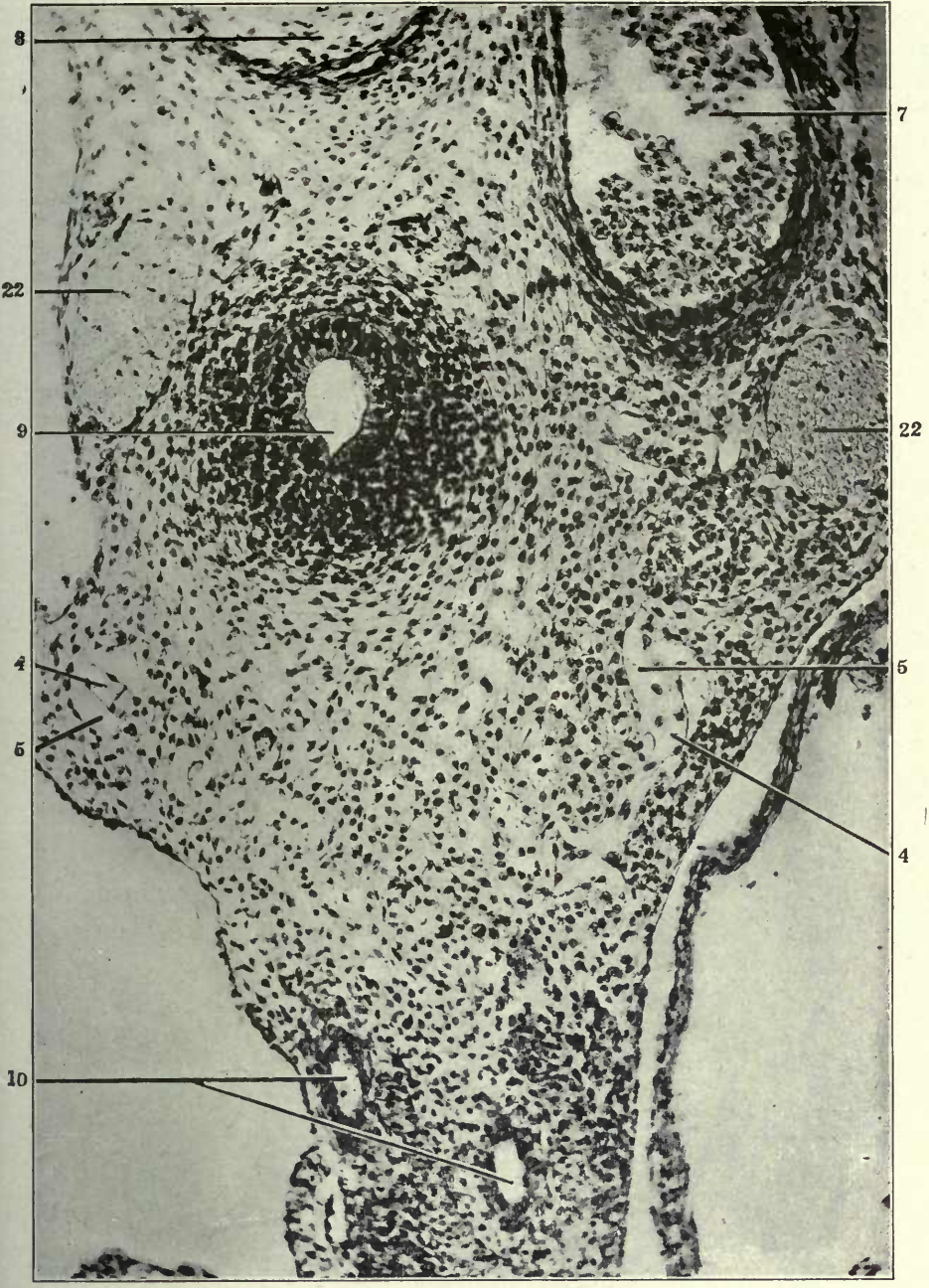


111A

FIGURE 111

111 Transverse section through ventral part of upper thoracic region in a 13.5 mm. cat embryo (series 189, slide VIII, section 36), \times 225.

- 4 Atrophying embryonal vein, forming kernel in interior of developing and replacing lymphatic space.
- 5 Extraintimal or perivenous lymphatic space surrounding degenerating embryonal vein.
- 7 Aorta.
- 8 Oesophagus.
- 9 Trachea.
- 10 Pulmonary artery.
- 22 Vagus.

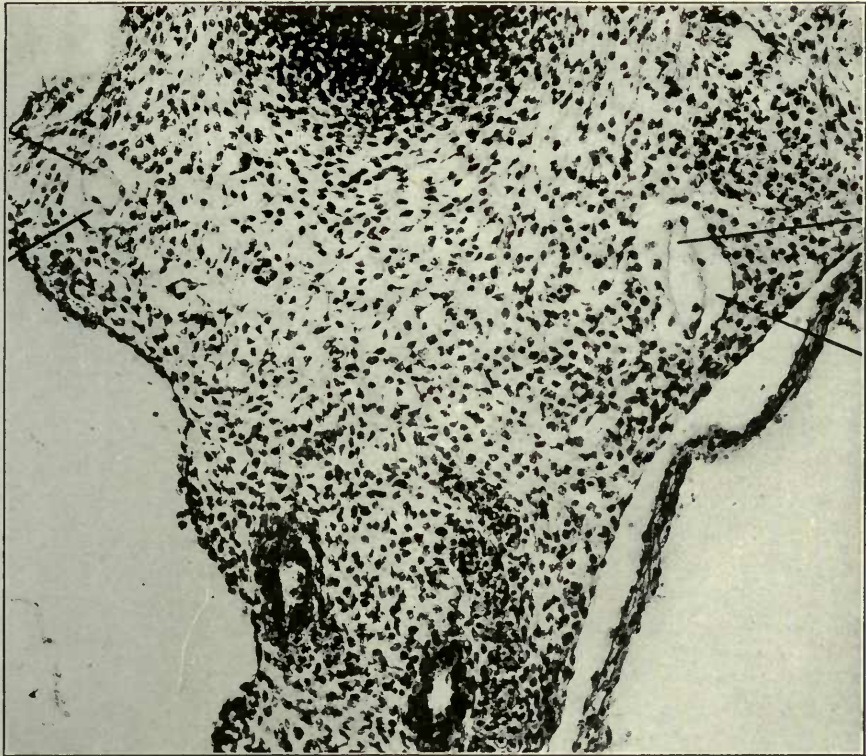


FIGURES 112 AND 113

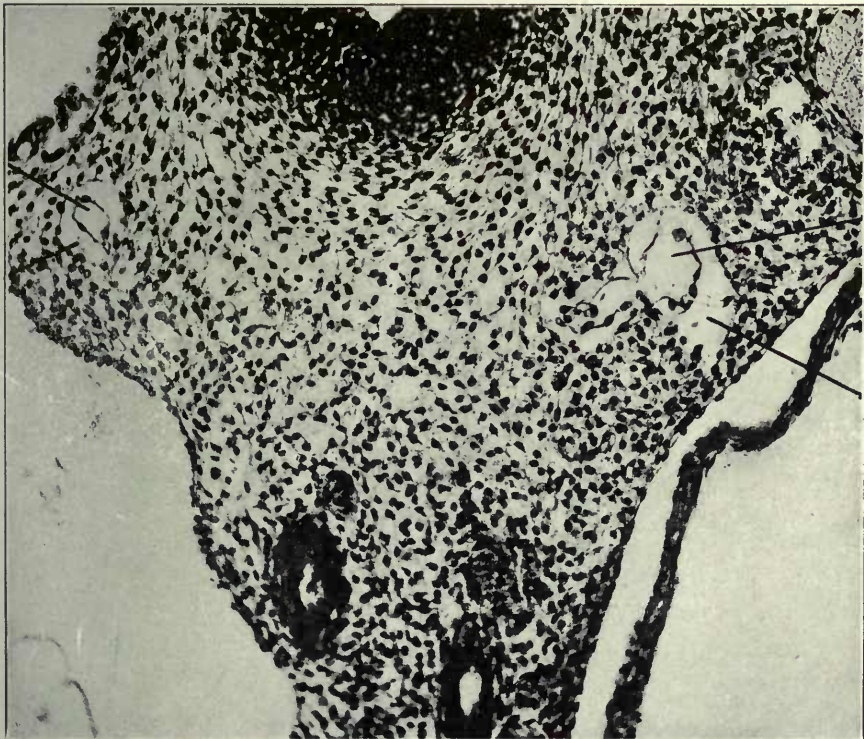
112 Same, section 37, \times 225.

113 Same, section 38, \times 225.

- 4 Atrophying embryonal vein, forming kernel in interior of developing and replacing lymphatic space.
- 5 Extraintimal or perivenous lymphatic space surrounding degenerating embryonal vein.



112



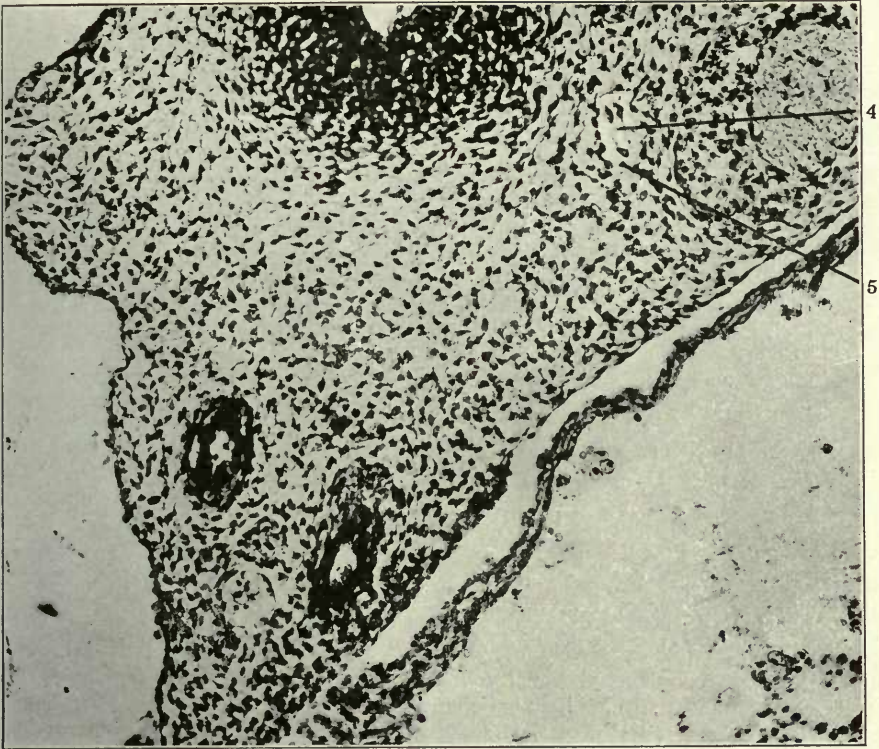
113

FIGURES 116 AND 117

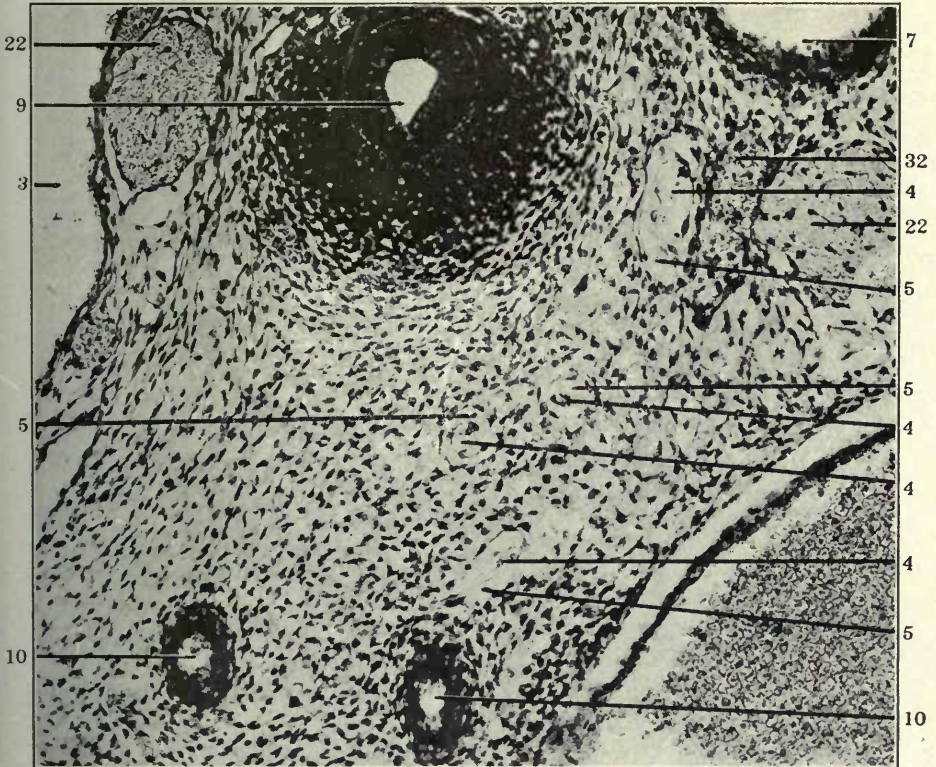
116 Same, section 41, $\times 225$.

117 Transverse section through ventral part of upper thoracic region in a 14 mm. cat embryo (series 212, slide X, section 4), $\times 225$.

- 3 Right precaval vein.
- 4 Atrophying embryonal vein, forming kernel in interior of developing and replacing lymphatic space.
- 5 Extraintimal or perivenous lymphatic space surrounding degenerating embryonal vein.
- 7 Aorta.
- 9 Trachea.
- 10 Pulmonary artery.
- 22 Vagus.
- 32 Ventral mediastinal venous plexus.



116



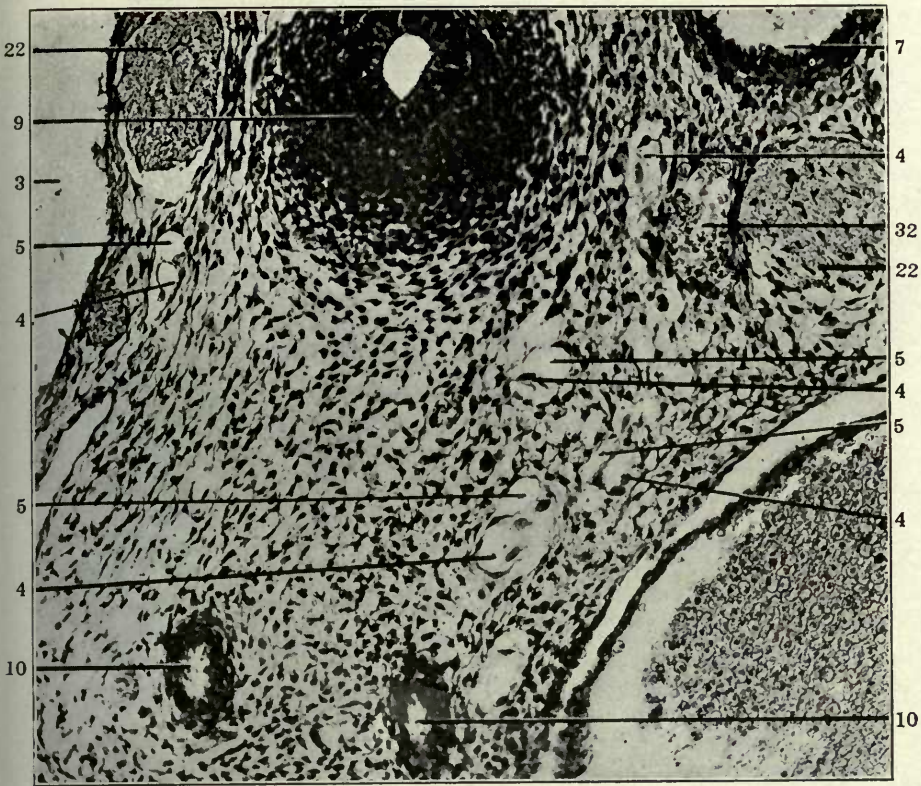
117

FIGURES 118 AND 119

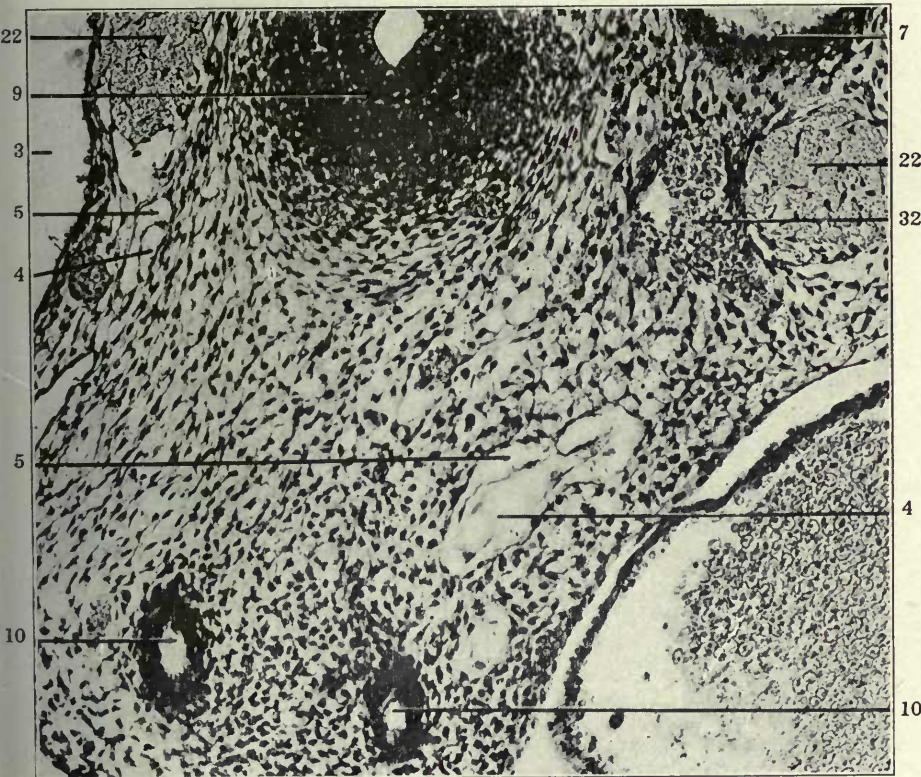
118 Same, section 5.

119 Same, section 6.

- 3 Right precaval vein.
- 4 Atrophying embryonal vein, forming kernel in interior of developing and replacing lymphatic space.
- 5 Extraintimal or perivenous lymphatic space surrounding degenerating embryonal vein.
- 7 Aorta.
- 9 Trachea.
- 10 Pulmonary artery.
- 22 Vagus.
- 32 Ventral mediastinal venous plexus.



118

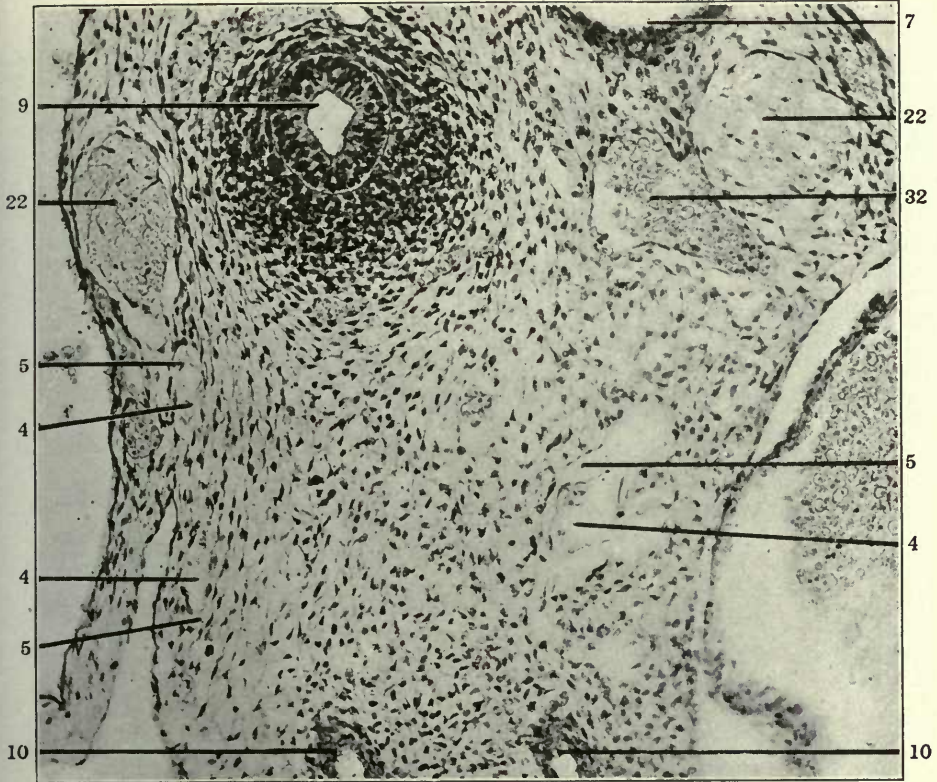

119

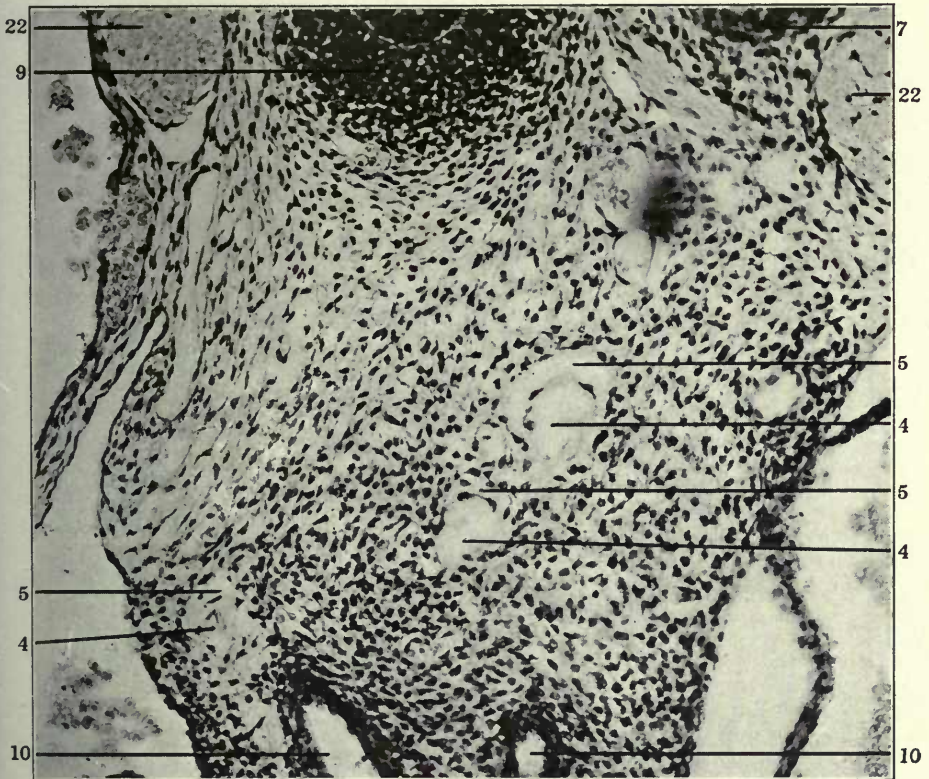
FIGURES 120 AND 121

- 120 Same, section 7.
121 Same, section 10.

- 4 Atrophying embryonal vein, forming kernel in interior of developing and replacing lymphatic space.
- 5 Extraintimal or perivenous lymphatic space surrounding degenerating embryonal vein.
- 7 Aorta
- 9 Trachea.
- 10 Pulmonary artery.
- 22 Vagus.
- 32 Ventral mediastinal venous plexus.



120



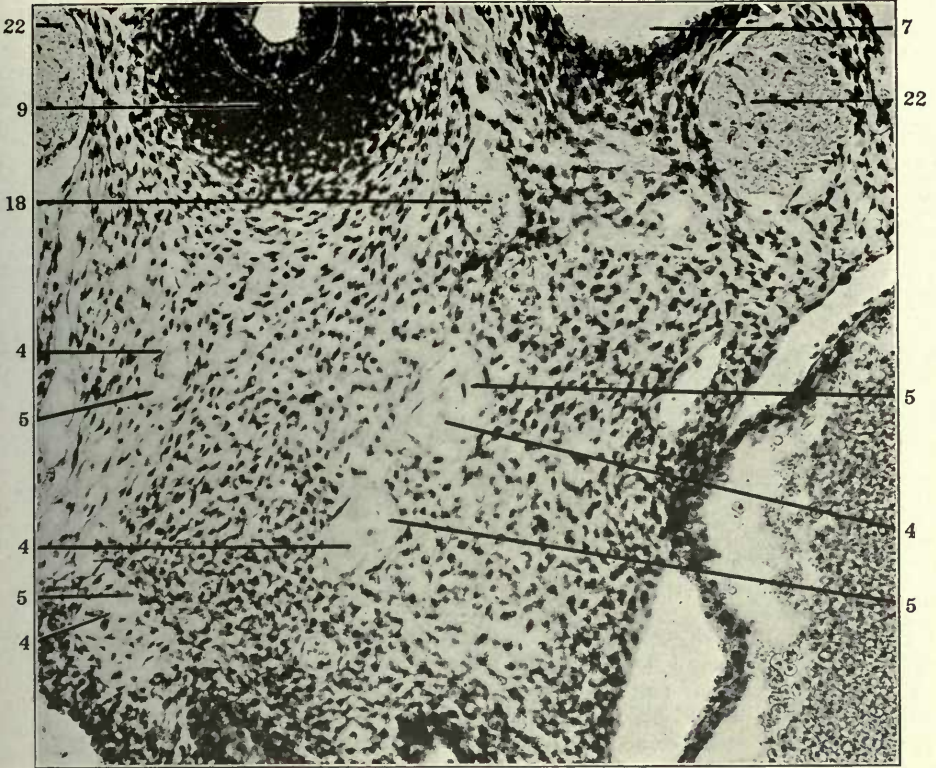
121

FIGURES 122 AND 123

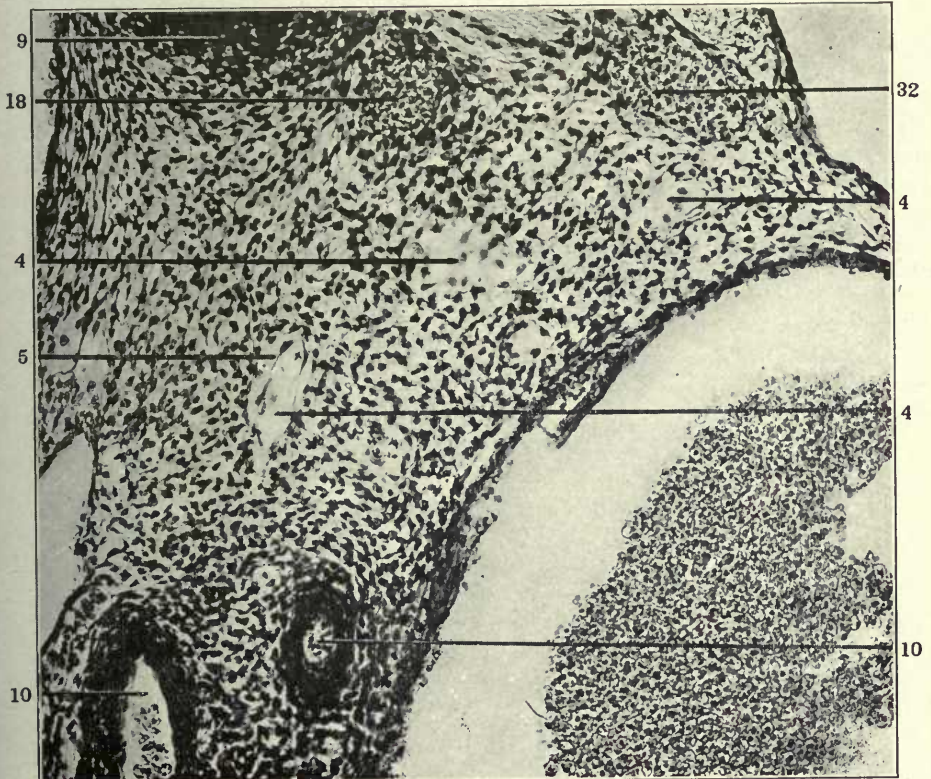
122 Same, section 11.

123 Transverse section through ventral part of upper thoracic region in a 14 mm. cat embryo (series 214, slide XIII, section 4) \times 225.

- 4 Atrophying embryonal vein, forming kernel in interior of developing and replacing lymphatic space.
- 5 Extraintimal or perivenous lymphatic space surrounding degenerating embryonal vein.
- 7 Aorta.
- 9 Trachea.
- 10 Pulmonary artery.
- 18 Peritracheal venous plexus.
- 22 Vagus.
- 32 Ventral mediastinal venous plexus.



122



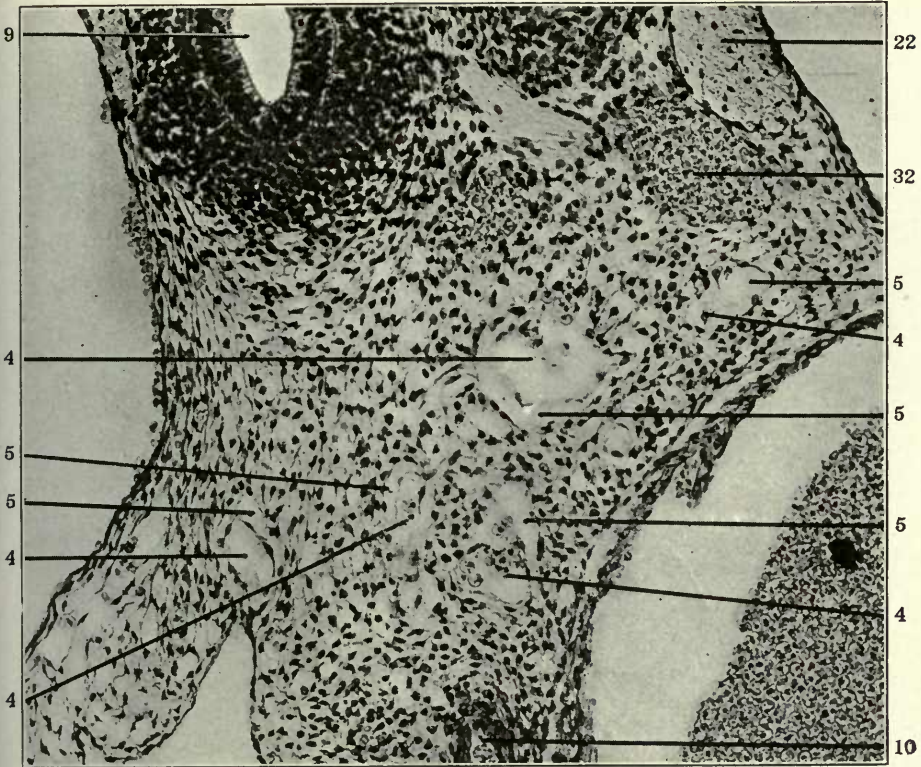
123

FIGURES 124 AND 125

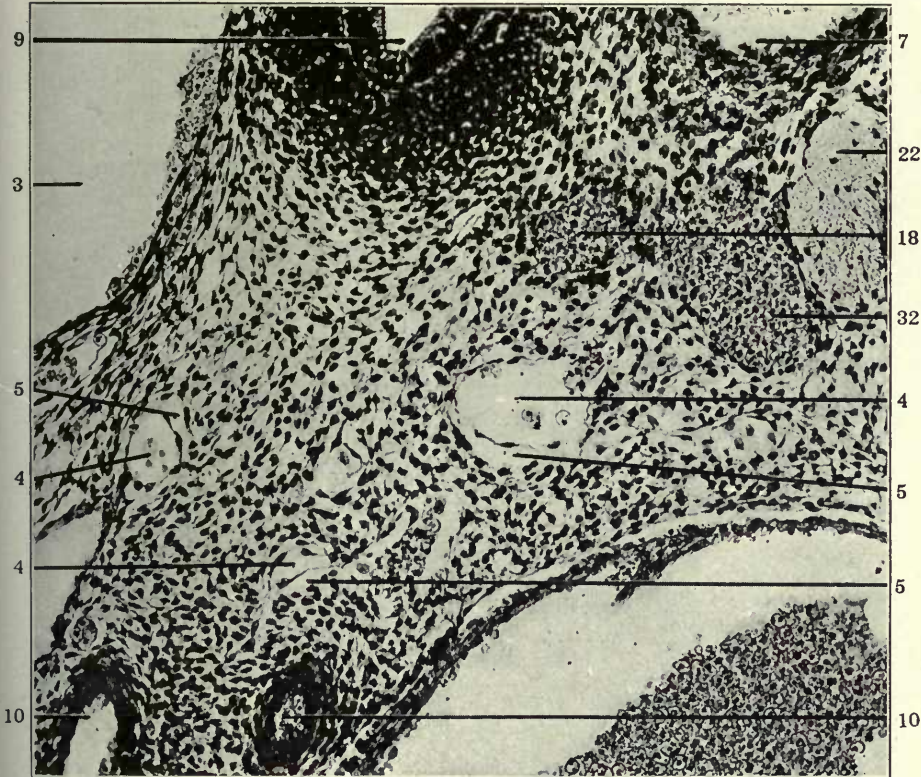
124 Same, section 5.

125 Same, section 6.

- 3 Right precaval vein.
- 4 Atrophying embryonal vein, forming kernel in interior of developing and replacing lymphatic space.
- 5 Extraintimal or perivenous lymphatic space surrounding degenerating embryonal vein.
- 7 Aorta.
- 9 Trachea.
- 10 Pulmonary artery.
- 18 Peritracheal venous plexus.
- 22 Vagus.
- 32 Ventral mediastinal venous plexus.



124



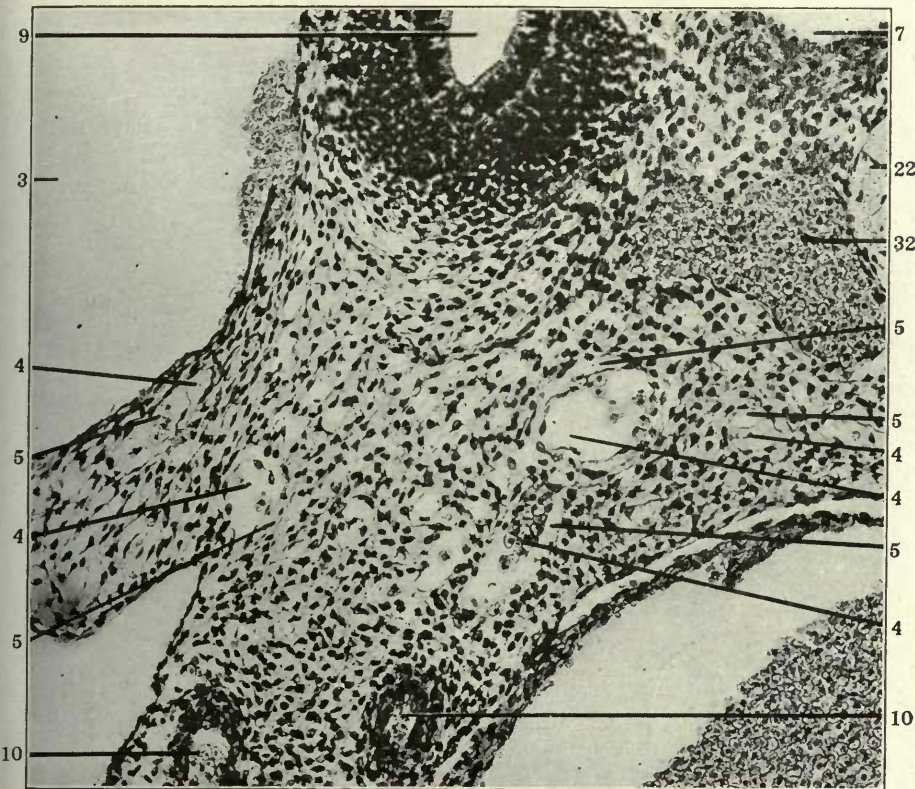
125

FIGURES 126 AND 127

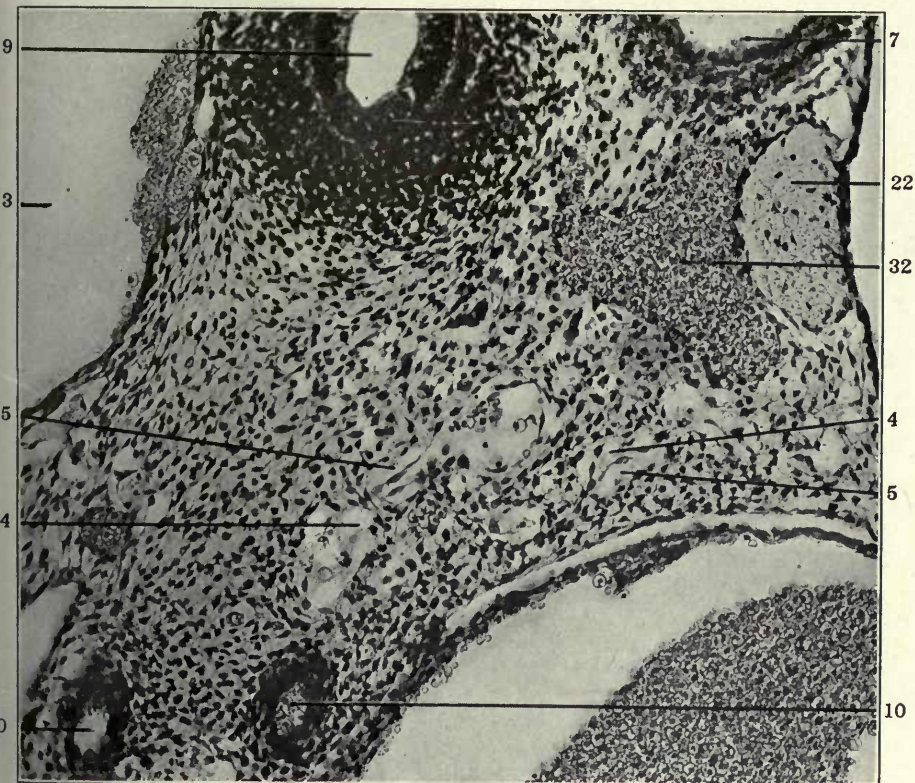
126 Same, section 7.

127 Same, section 8.

- 3 Right precaval vein.
- 4 Atrophying embryonal vein, forming kernel in interior of developing and replacing lymphatic space.
- 5 Extraintimal or perivenous lymphatic space surrounding degenerating embryonal vein.
- 7 Aorta.
- 9 Trachea.
- 10 Pulmonary artery.
- 22 Vagus.
- 32 Ventral mediastinal venous plexus.



126



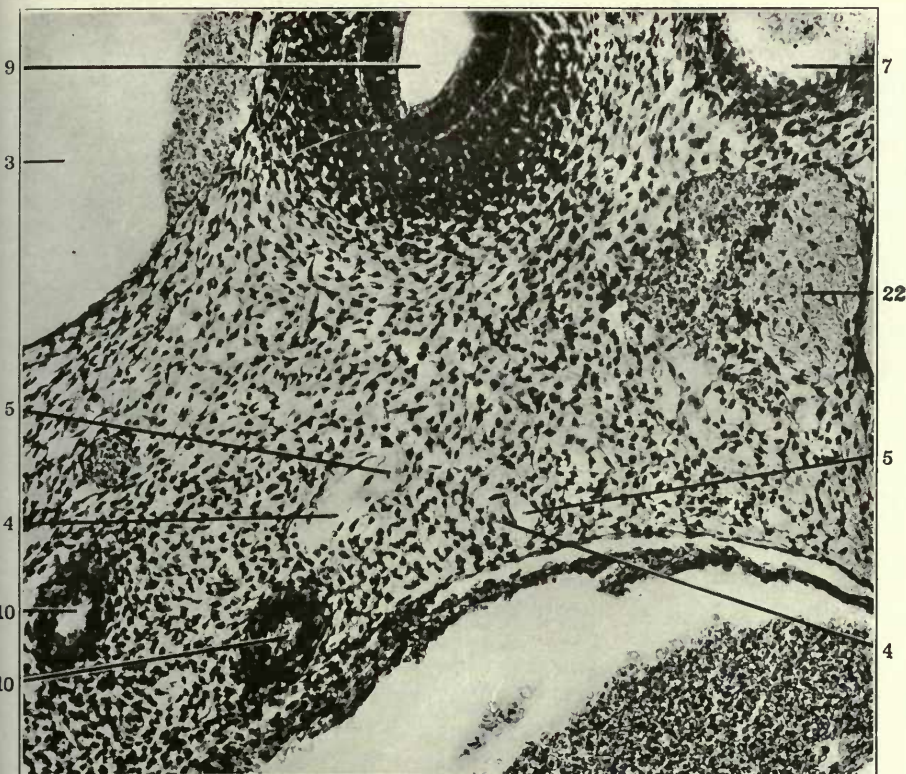
127

FIGURES 128 AND 129

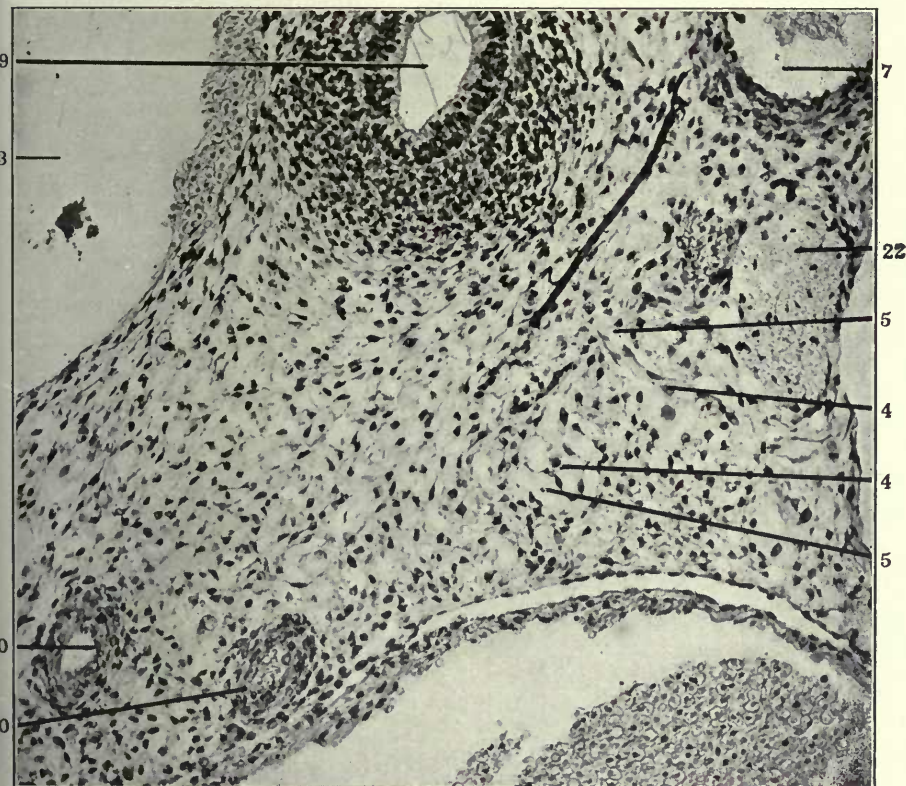
128 Same, section 10.

129 Same, section 11.

- 3 Right precaval vein.
- 4 Atrophying embryonal vein, forming kernel in interior of developing and replacing lymphatic space.
- 5 Extraintimal or perivenous lymphatic space surrounding degenerating embryonal vein.
- 7 Aorta.
- 9 Trachea.
- 10 Pulmonary artery.
- 22 Vagus.



128



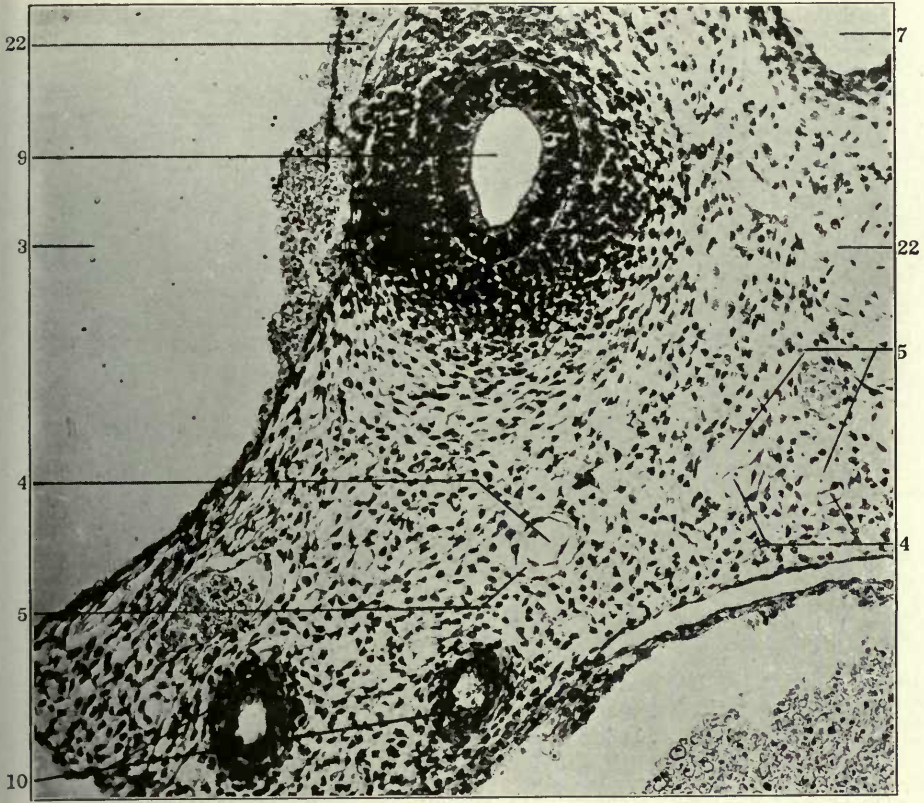
129

FIGURES 130 AND 131

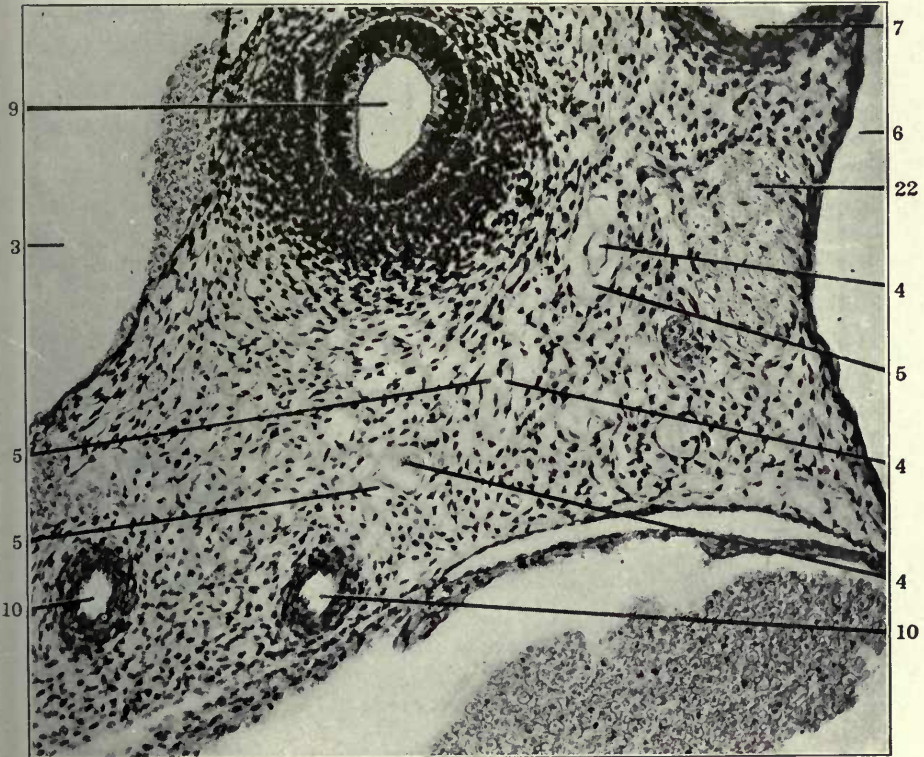
130 Same, section 14.

131 Same, section 15.

- 3 Right precaval vein.
- 4 Atrophying embryonal vein, forming kernel in interior of developing and replacing lymphatic space.
- 5 Extraintimal or perivenous lymphatic space surrounding degenerating embryonal vein.
- 6 Precardinal or precava, resp. azygos of left side.
- 7 Aorta.
- 9 Trachea.
- 10 Pulmonary artery.
- 22 Vagus.



130



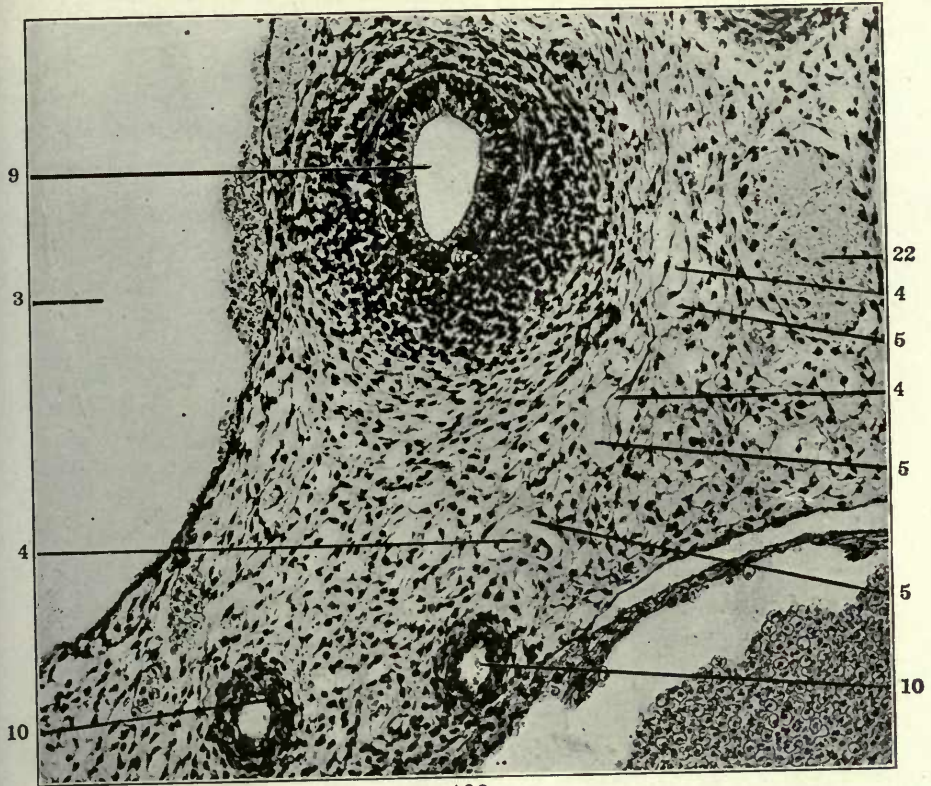
131

FIGURES 132 AND 133

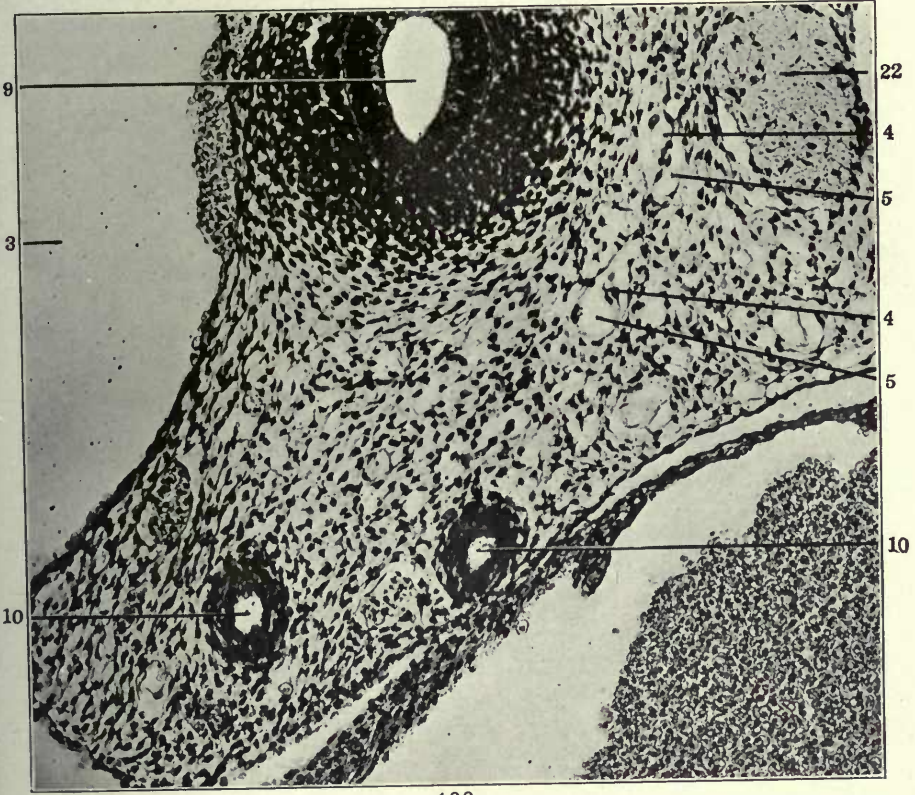
132 Same, section 16.

133 Same, section 17.

- 3 Right precaval vein, thoracic portion.
- 4 Atrophying embryonal vein, forming kernel in interior of developing and replacing lymphatic space.
- 5 Extraintimal or perivenous lymphatic space surrounding degenerating embryonal vein.
- 9 Trachea.
- 10 Pulmonary artery.
- 22 Vagus.



132



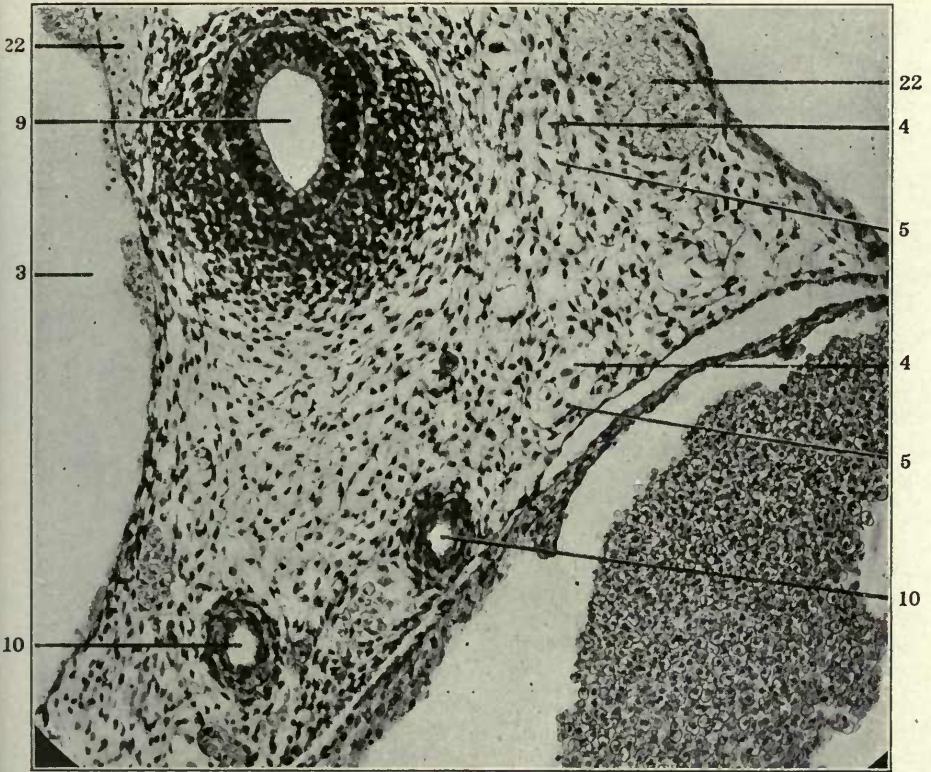
133

FIGURES 134 AND 135

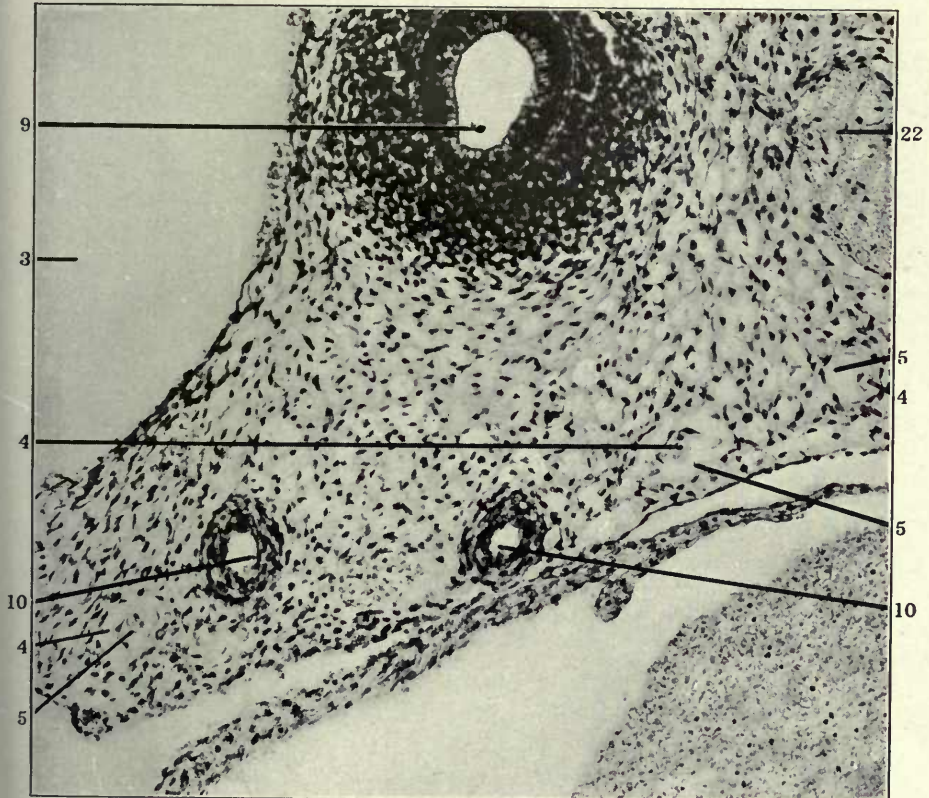
134 Same, section 18.

135 Same, section 19.

- 3 Right precaval vein.
- 4 Atrophying embryonal vein, forming kernel in interior of developing and replacing lymphatic space.
- 5 Extraintimal or perivenous lymphatic space surrounding degenerating embryonal vein.
- 9 Trachea.
- 10 Pulmonary artery.
- 22 Vagus.



134



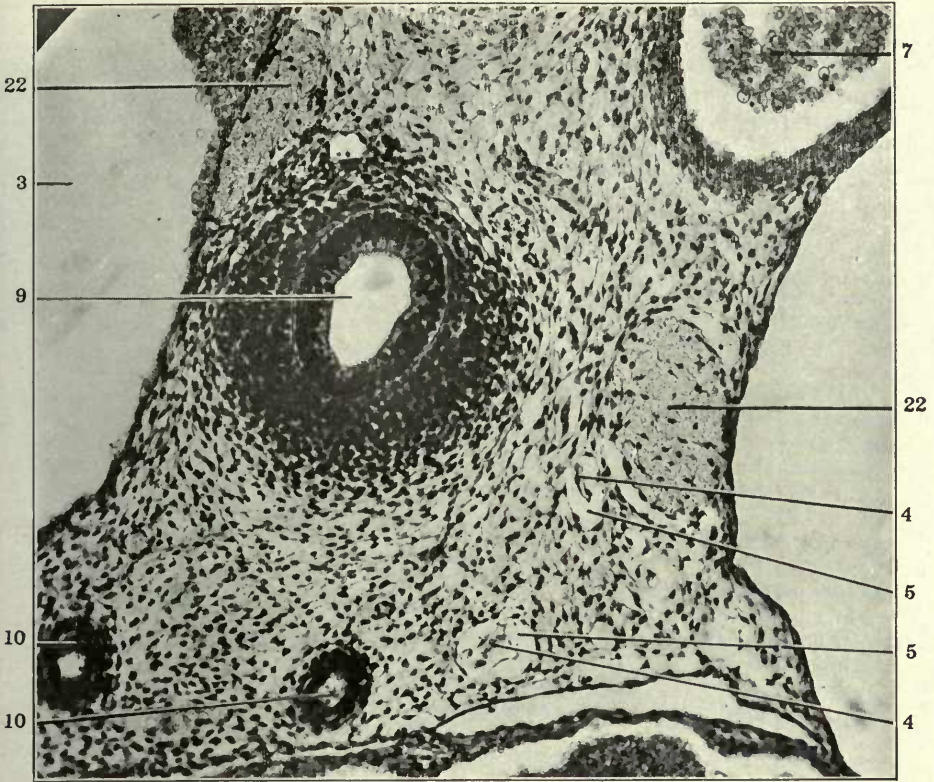
135

FIGURES 138 AND 139

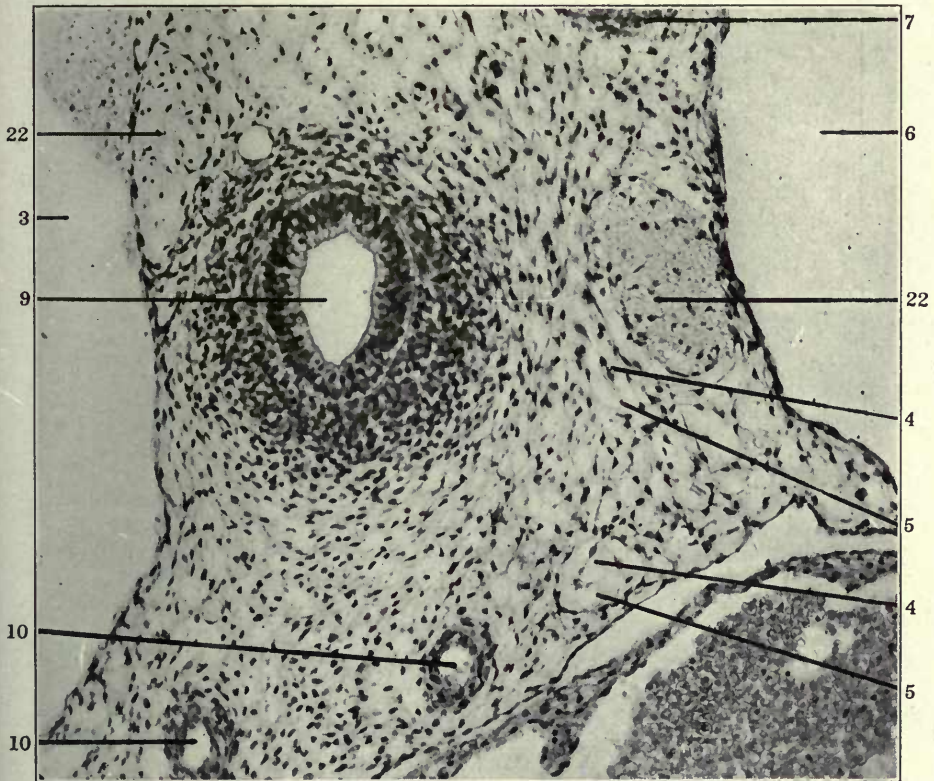
138 Same, section 22.

139 Same, section 23.

- 3 Right precaval vein.
- 4 Atrophying embryonal vein, forming kernel in interior of developing and replacing lymphatic space.
- 5 Extraintimal or perivenous lymphatic space surrounding degenerating embryonal vein.
- 6 Precardinal or precava of left side.
- 7 Aorta.
- 9 Trachea.
- 10 Pulmonary artery.
- 22 Vagus.



138

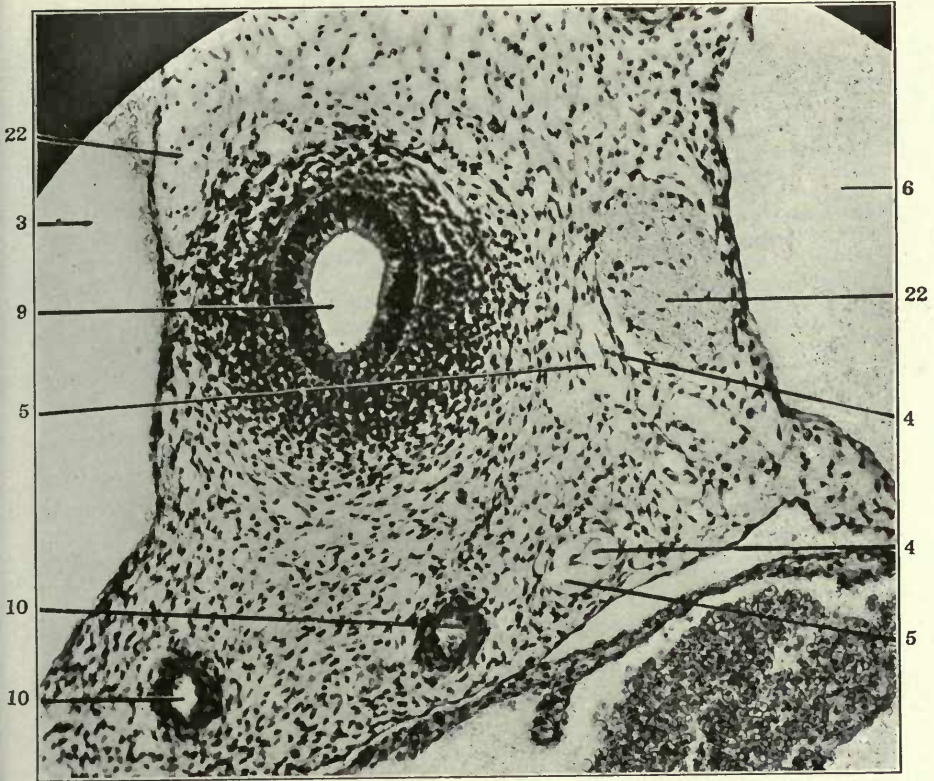


139

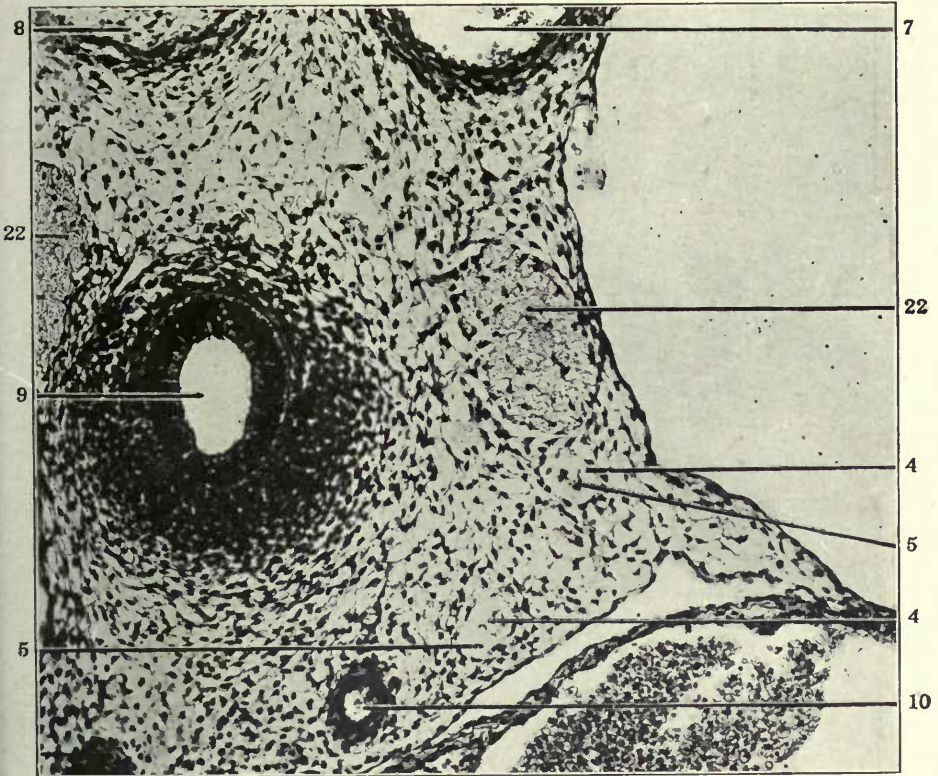
FIGURES 140 AND 141

- 140 Same, section 24.
141 Same, section 25.

- 3 Right precaval vein.
4 Atrophying embryonal vein, forming kernel in interior of developing and replacing lymphatic space.
5 Extraintimal or perivenous lymphatic space surrounding degenerating embryonal vein.
6 Precardinal or precava of left side.
7 Aorta.
8 Oesophagus.
9 Trachea.
10 Pulmonary artery.
22 Vagus.



140



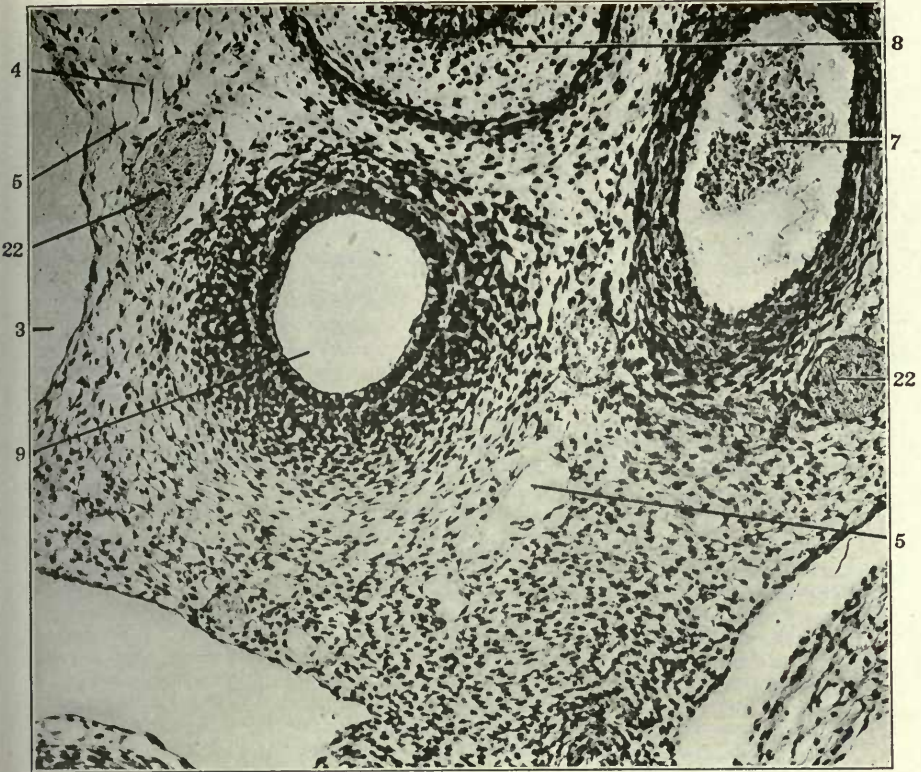
141

FIGURES 142 AND 143

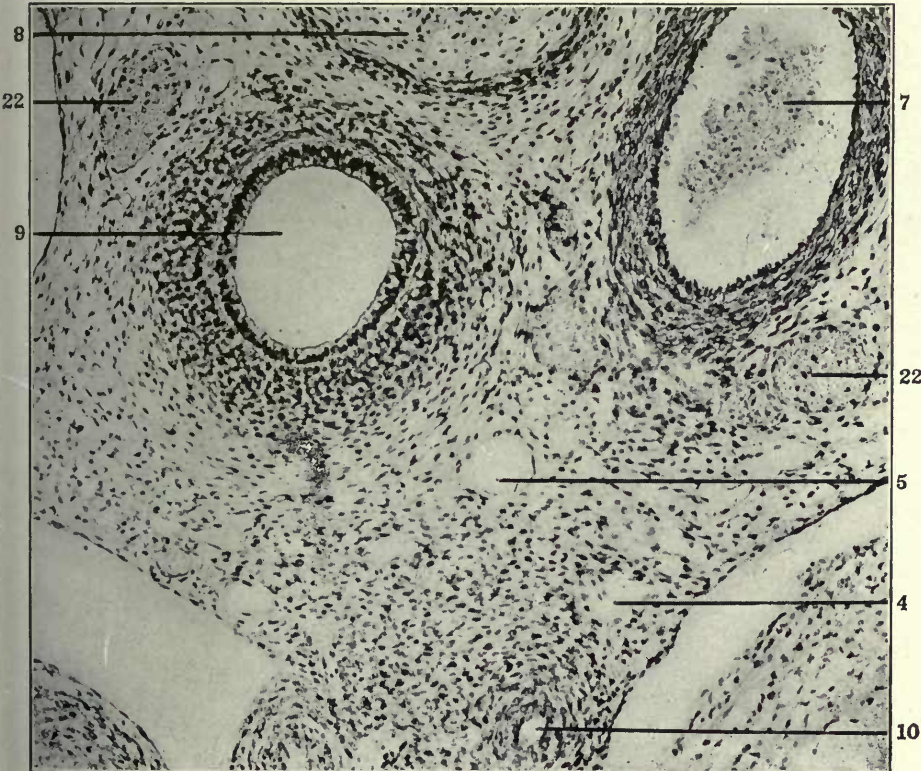
142 Transverse section through ventral part of upper thoracic region in a 15 mm. cat embryo (series 216, slide X, section 32), \times 225.

143 Same, section 33.

- 3 Right precaval vein.
- 4 Atrophying embryonal vein, forming kernel in interior of developing and replacing lymphatic space.
- 5 Extraintimal or perivenous lymphatic space surrounding degenerating embryonal vein.
- 7 Aorta.
- 8 Oesophagus.
- 9 Trachea.
- 10 Pulmonary artery.
- 22 Vagus.



142

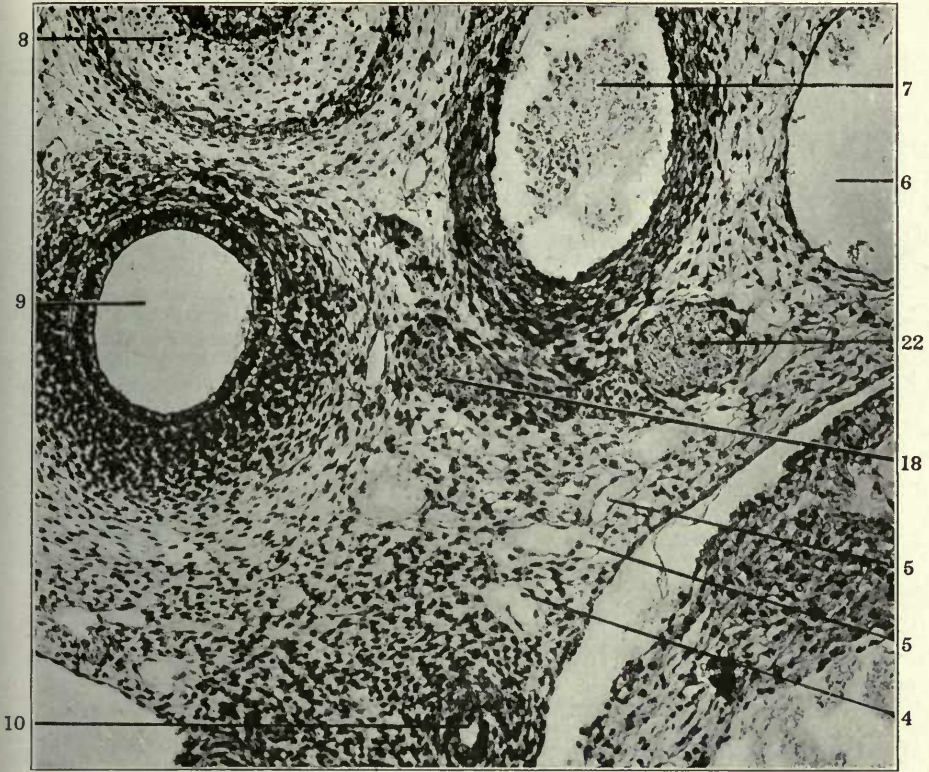


143

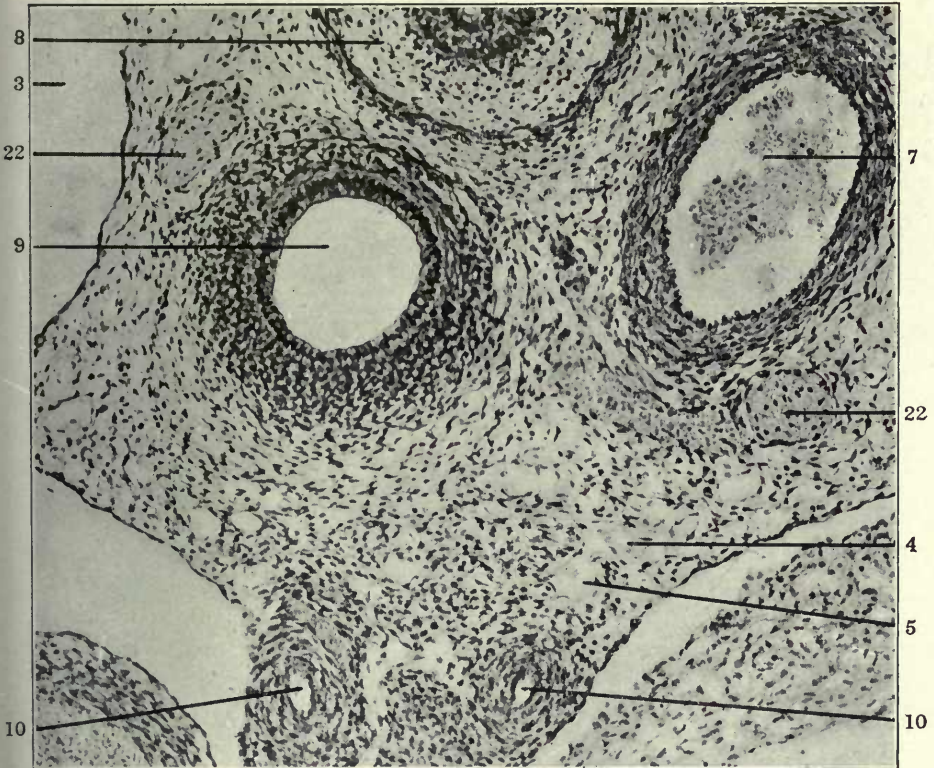
FIGURES 144 and 145

- 144 Same, section 34.
145 Same, section 35.

- 3 Right precaval vein.
4 Atrophying embryonal vein, forming kernel in interior of developing and replacing lymphatic space.
5 Extraintimal or perivenous lymphatic space surrounding degenerating embryonal vein.
6 Precardinal or precava of left side.
7 Aorta.
8 Oesophagus.
9 Trachea.
10 Pulmonary artery.
18 Peritracheal venous plexus.
22 Vagus.



144



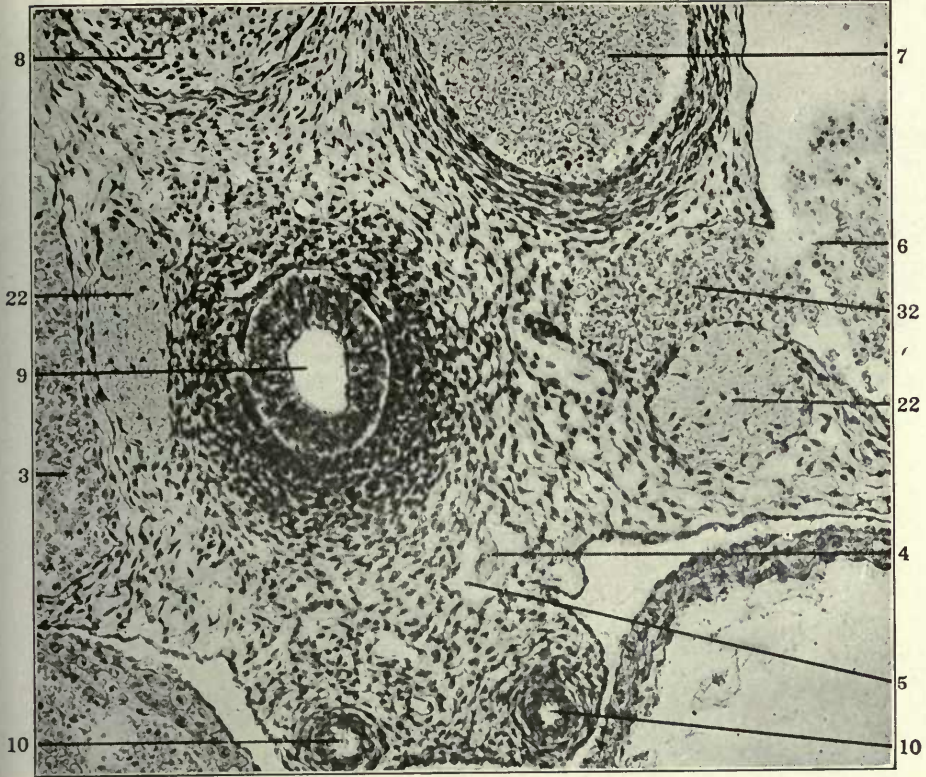
145

FIGURES 146 AND 147

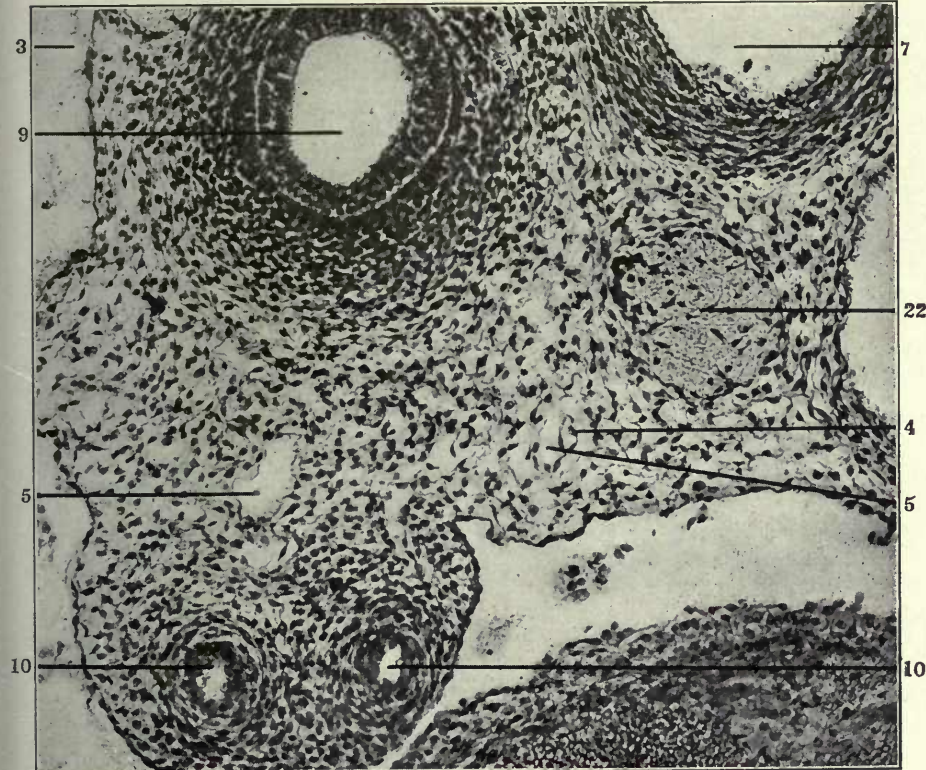
146 Transverse section through ventral part of upper thoracic region in a 15.5 mm. cat embryo (series 215, slide XIV, section 31), $\times 225$.

147 Transverse section through ventral portion of upper thoracic region in a 16 mm. cat embryo (series 230, slide XII, section 25), $\times 225$.

- 3 Right precaval vein.
- 4 Atrophying embryonal vein, forming kernel in interior of developing and replacing lymphatic space.
- 5 Extraintimal or perivenous lymphatic space surrounding degenerating embryonal vein.
- 6 Precardinal or precava of left side.
- 7 Aorta.
- 8 Oesophagus.
- 9 Trachea.
- 10 Pulmonary artery.
- 22 Vagus.
- 32 Ventral mediastinal venous plexus.



146

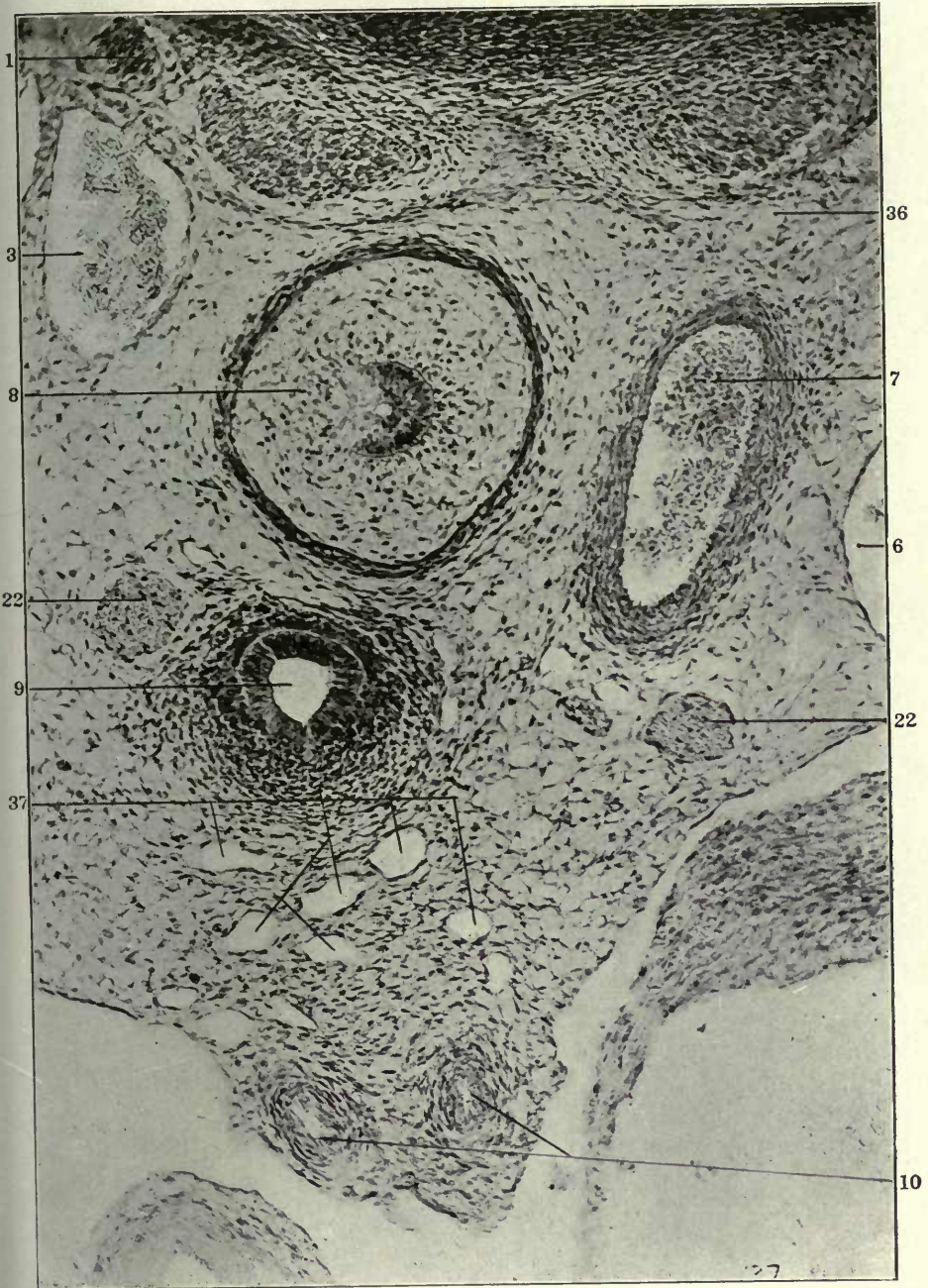


147

FIGURE 148

148 Transverse section through ventral portion of upper thoracic region in a 16 mm. cat embryo (series 222, slide X, section 2), $\times 225$.

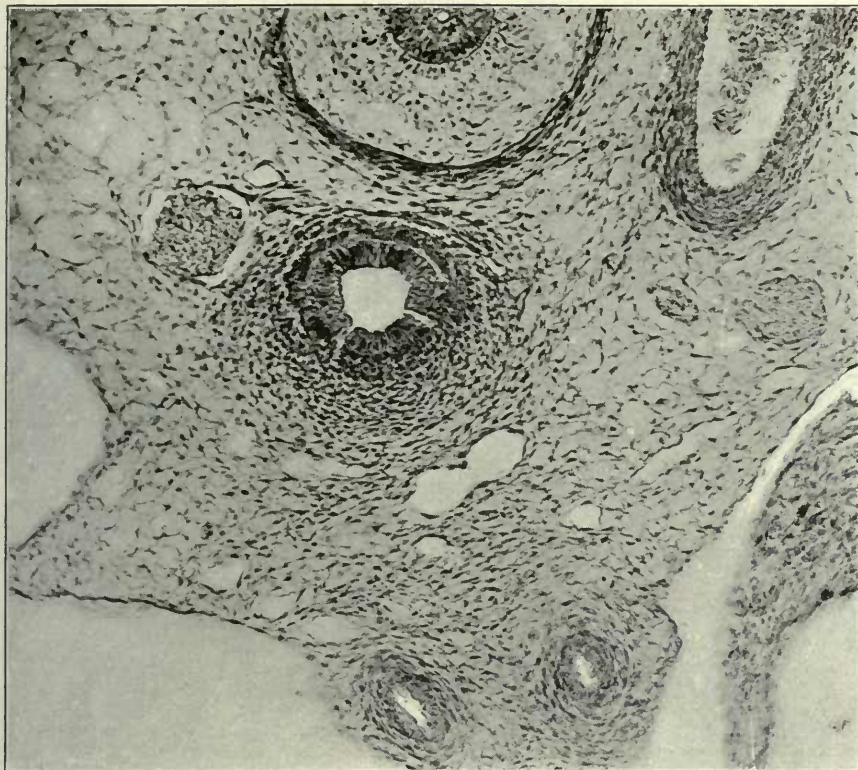
- 1 Sympathetic nerve.
- 3 Right Azygos vein, thoracic portion.
- 6 Precardinal or precava of left side.
- 7 Aorta.
- 8 Oesophagus.
- 9 Trachea.
- 10 Pulmonary artery.
- 22 Vagus.
- 36 Thoracic duct, azygos segment.
- 37 Broncho-mediastinal duct.



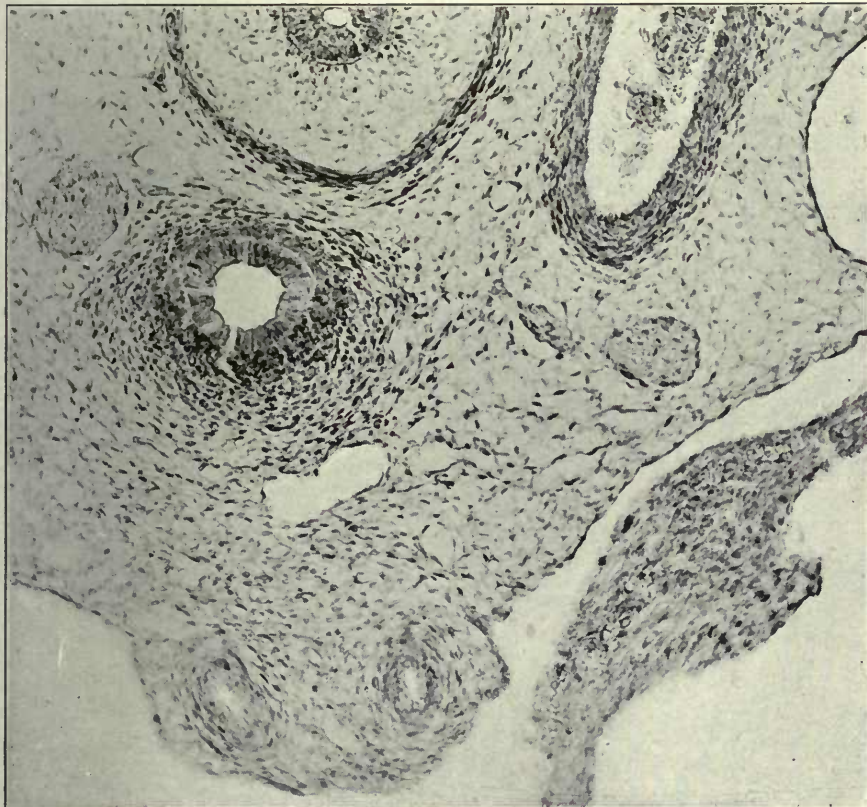FIGURES 149 AND 150

149 Same, section 2.

150 Same, section 3.



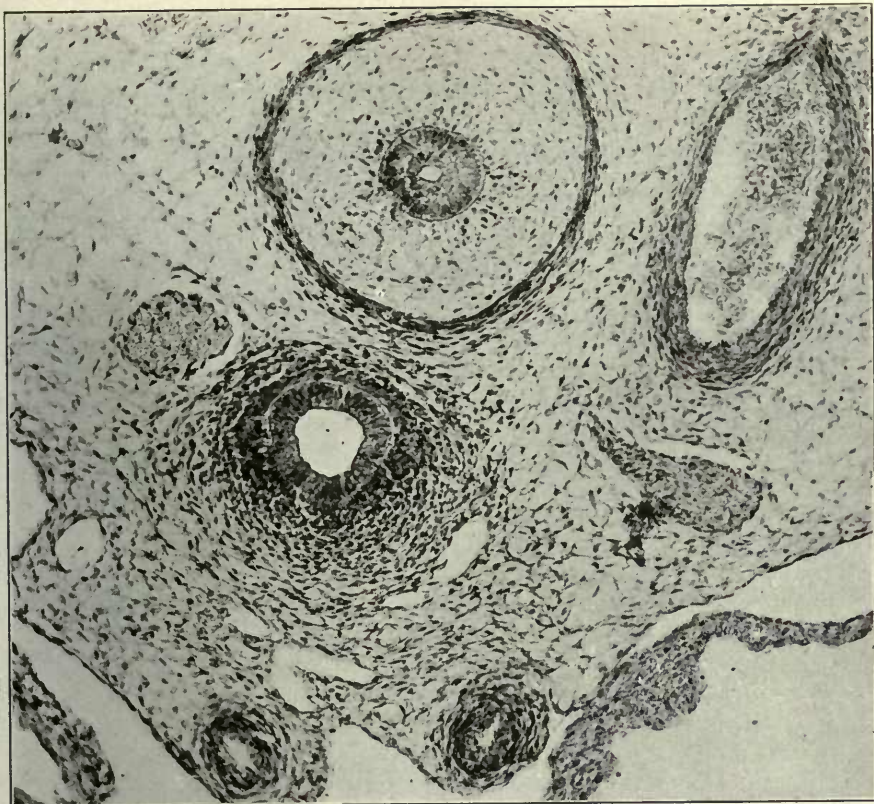
149



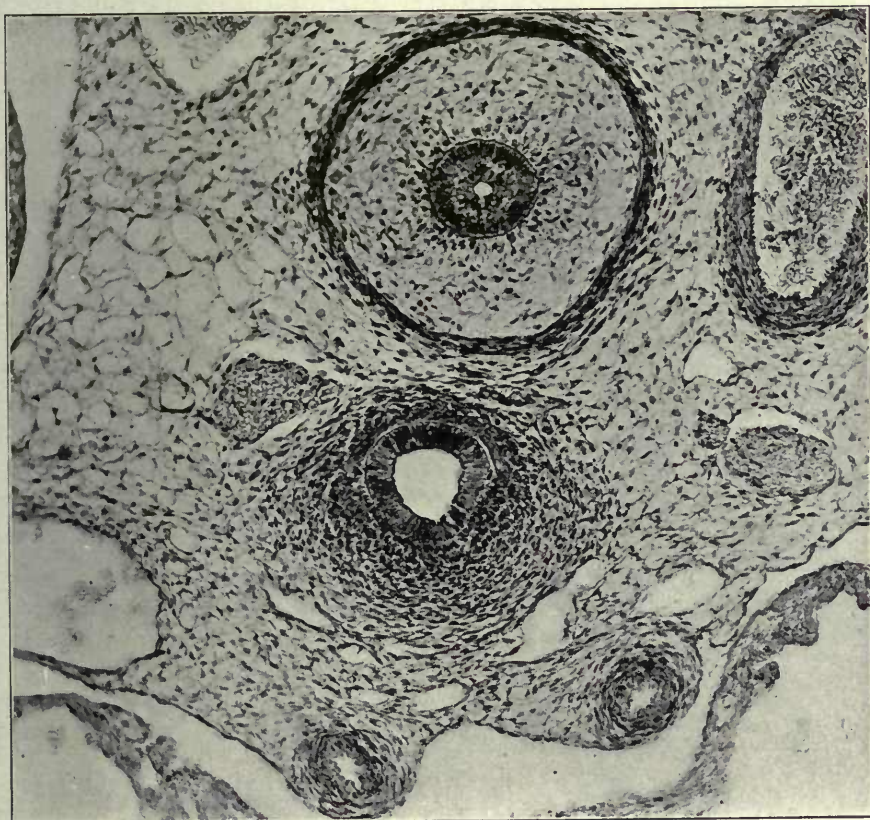150

FIGURES 151 AND 152

- 151 Same, section 10.
- 152 Same, section 15.



151



152

FIGURE 153

153 Same, section 16.

- 1 Sympathetic nerve.
- 3 Right azygos vein, thoracic portion.
- 6 Precardinal or precava, resp. azygos of left side.
- 7 Aorta.
- 8 Oesophagus.
- 9 Trachea.
- 10 Pulmonary artery.
- 22 Vagus.
- 36 Thoracic duct, azygos segment.
- 37 Broncho-mediastinal duct.

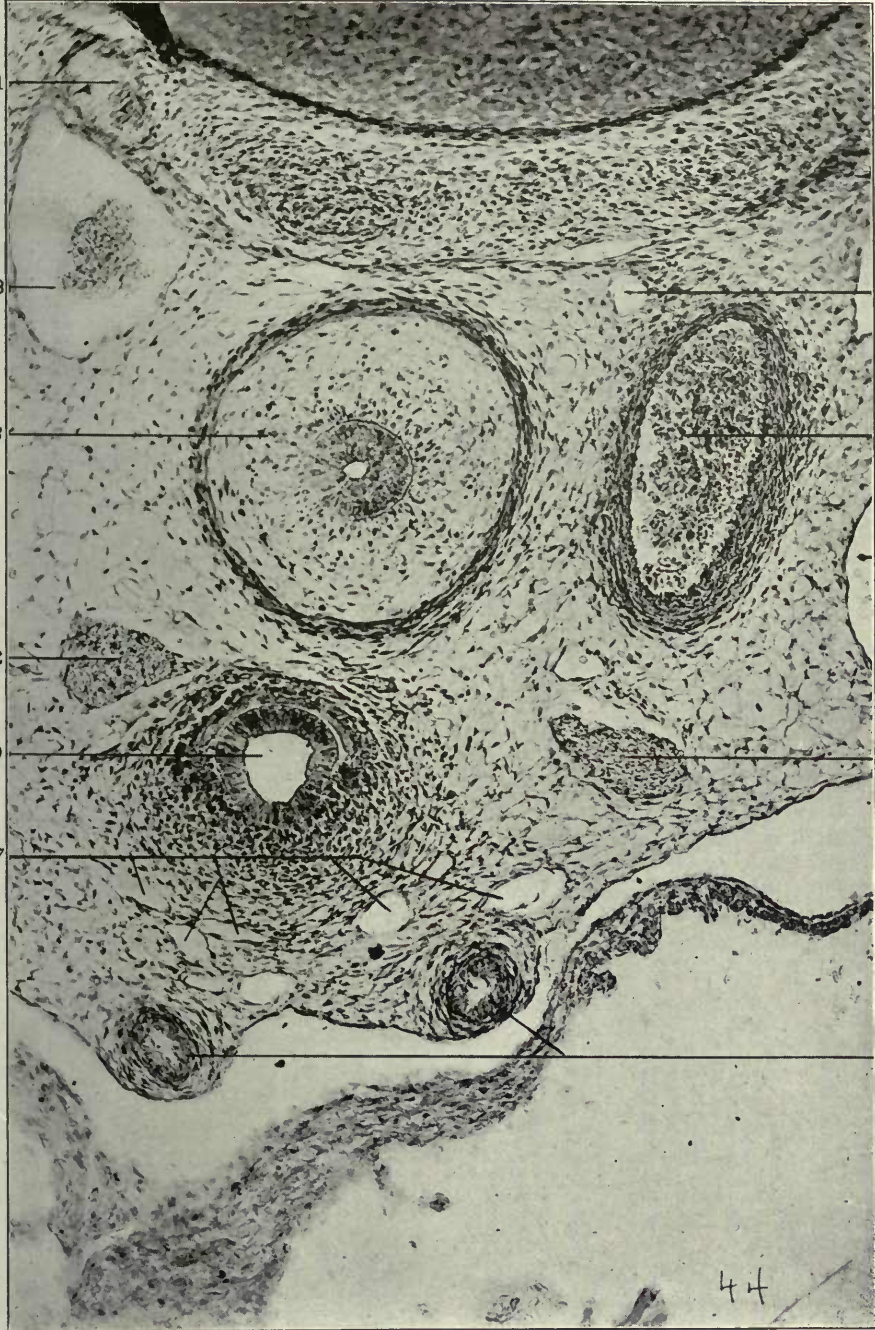
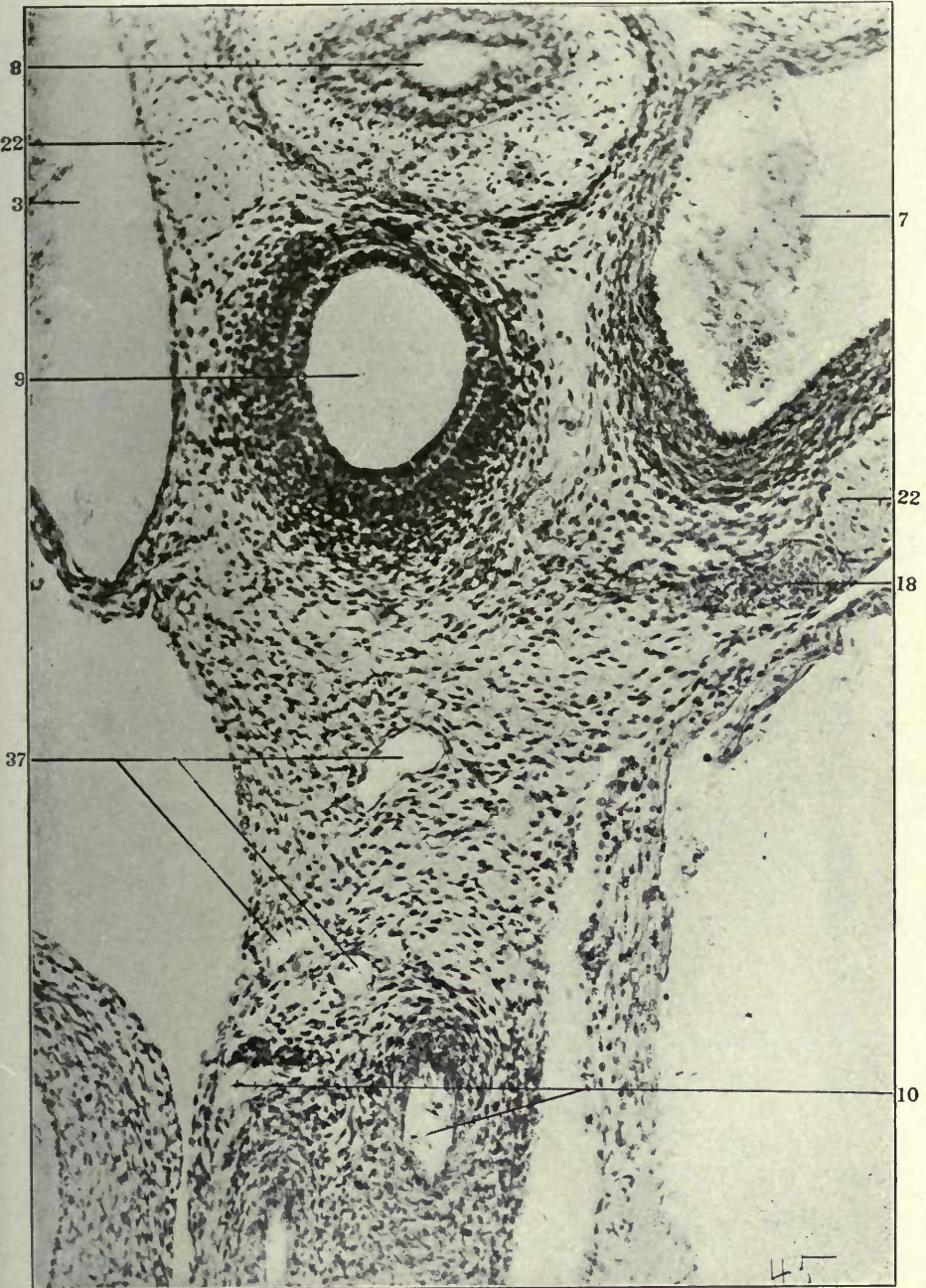


FIGURE 154

154 Transverse section through ventral portion of upper thoracic region in a 20 mm. cat embryo (series 241, slide, XIX, section 18). $\times 225$.

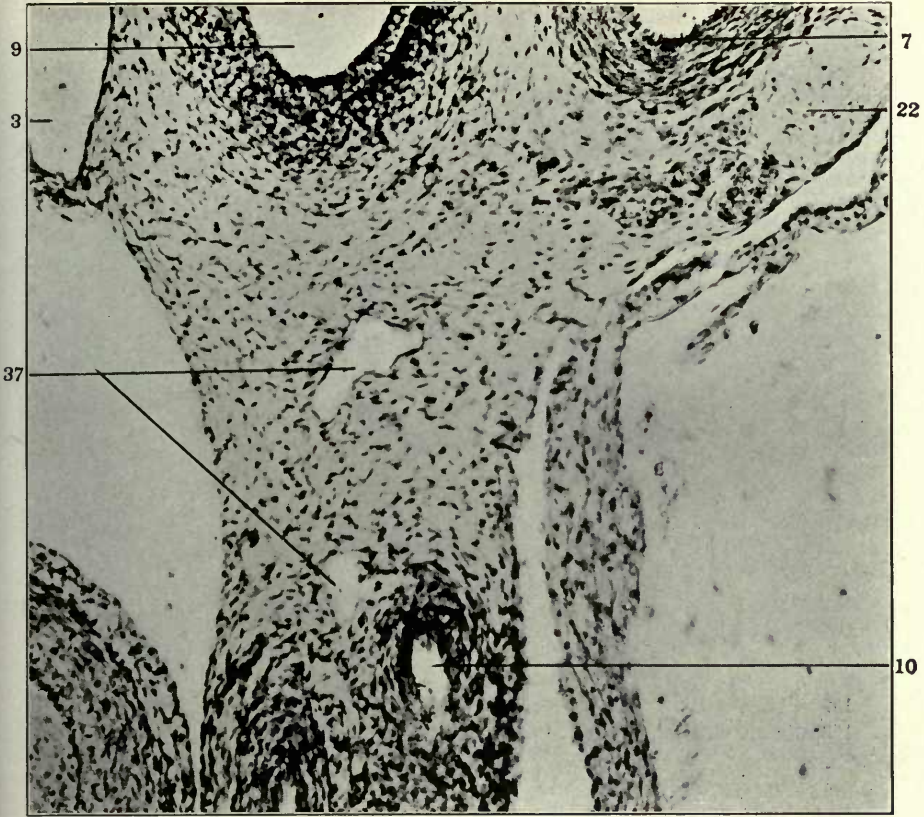
- 3 Right precaval vein.
- 7 Aorta.
- 8 Oesophagus.
- 9 Trachea.
- 10 Pulmonary artery.
- 18 Peritracheal venous plexus.
- 22 Vagus.
- 37 Broncho-mediastinal duct.



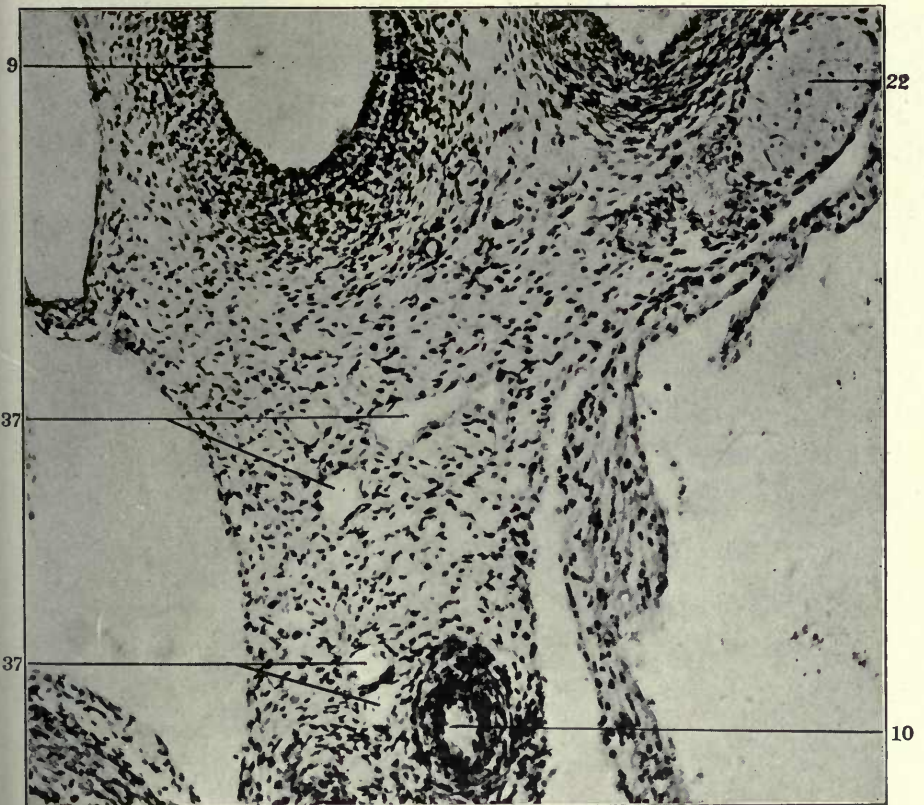
FIGURES 155 AND 156

- 155 Same, section 19.
156 Same, section 20.

- 3 Right precaval vein.
7 Aorta.
9 Trachea.
10 Pulmonary artery.
22 Vagus.
37 Broncho-mediastinal duct.



155

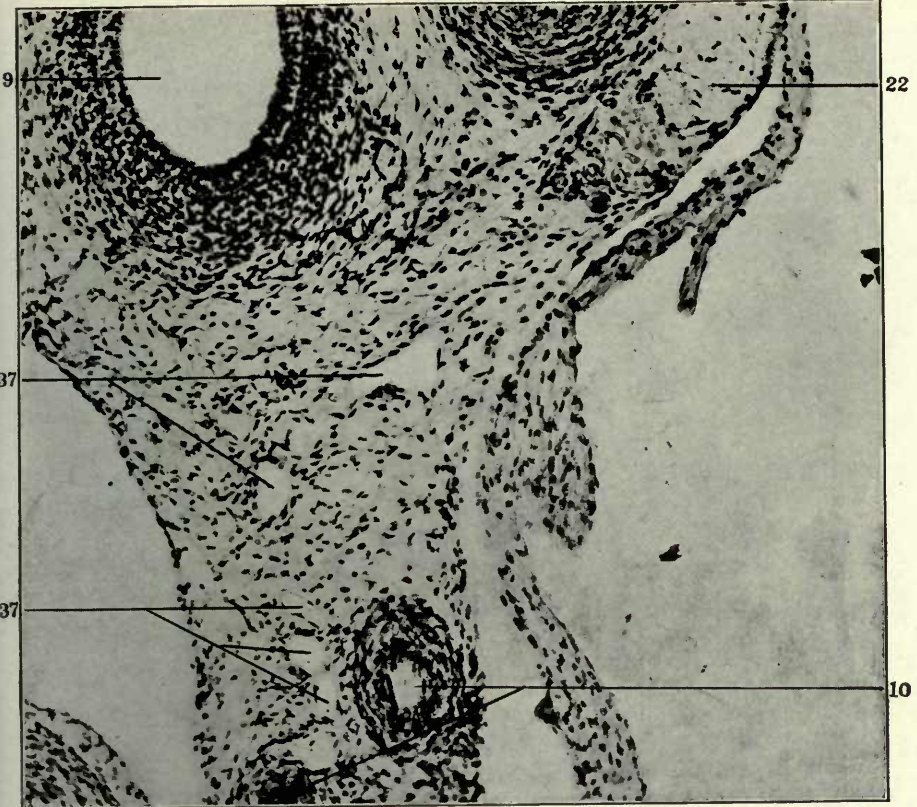


156

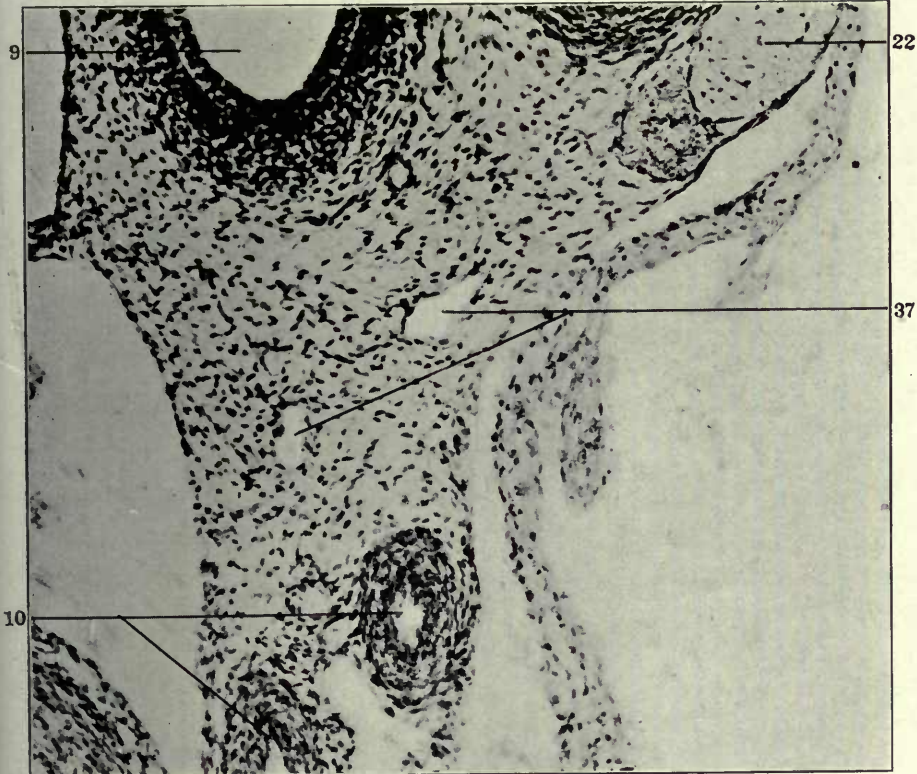
FIGURES 157 AND 158

- 157 Same, section 21.
158 Same, section 22.

- 9 Trachea.
10 Pulmonary artery.
22 Vagus.
37 Broncho-mediastinal duct.



157



158

B. The development of the proximal portion of the thoracic duct proper, between the termination of thoracic duct approach of the jugular lymph sac and the beginning of the azygos segment of the thoracic ducts, caudal to the level of the aortic arch, viz. the preazygos segment of the thoracic duct.

In the earlier purely venous stages a venous plexus between oesophagus and vertebral column (17, fig. 101), drains caudo-laterad into the mesal surface of the main jugular and innominate trunks. This plexus continues the supracardinal venous line cephalad beyond the level of the azygos-Cuvierian junction. The terminals of this plexus are frequently joined by dorsal somatic venous tributaries (16, fig. 101), near their entrance into the main vein. These vessels have been previously discussed in their relation to the general tributary system of the jugulo-innominate line (cf. supra p. (92), and their disposition is schematically shown in fig. 101.

In a 14 mm. embryo (series 210, slide viii, section 41, \times 225) the dorso-medial or prevertebral tributary (17) and the dorsal somatic branch (16) are shown in fig. 102, just prior to their union into the common large trunk emptying into the dorso-medial angle of the internal jugular vein (25), dorsal to the sympathetic nerve (1).

The same plexus elements (16 and 17) are seen in another 14 mm. embryo (series 212, slide vii, section 23, \times 150) in fig. 159. In this section their point of confluence and the entrance of the resulting combined trunk into the internal jugular vein takes place ventral to the sympathetic nerve (1), between the same and the left subclavian artery (33), by utilizing the pathway afforded by the peritracheal plexus (18, in fig. 102).

Figs. 160 and 161 show these tributaries (16 and 17) in a 13.5 mm. cat embryo (series 189, slide vii, sections 20 and 21) in a magnification of 225 diameters, as they are approaching their confluence and point of entrance into the internal jugular vein (25). In addition these sections afford admirable examples of two other conditions, previously noted (vide supra pp. 49):

a. The development of independent mesenchymal intercellular lymphatic spaces, with well defined endothelial limiting walls.

Such spaces (??) are seen in the two sections lateral to the oesophagus. They apparently develop from the beginning as intercellular clefts, without relation to embryonic veins. The preazygos region presents these spaces in almost all 13 and 14 mm. embryos. Their development in the mammalian embryo is of the utmost phylogenetic significance and affords important evidence in the interpretation of systemic lymphatic ontogenesis in the sauropsida, and especially in reptiles. The investigation of avian and reptilian lymphatic development has been carried on for the past year in the anatomical laboratory of Columbia University. These researches are now nearly completed, and some of the main results were presented at the 27th session of the American Association of Anatomists at Cornell University in December of last year. They establish a common genetic ground plan for the development and adult organization of the amniote lymphatic system. The avian and reptilian type only differs from that encountered in the mammal in respect to the higher degree of development of the jugular lymph sac, as an anterior or cervical veno-lymphatic heart, in the ontogenetic appearance of other areas of equal phylogenetic significance, as remnants of the multiple ancestral series of segmental veno-lymphatic hearts, and in the preponderance of peripheral lymphatic development by confluence of *independent* intercellular mesodermal spaces, not associated topographically, as in the mammal, with temporary embryonic venous channels. In other words, the extraintimal perivenous development of the majority of peripheral lymphatic channels described in this communication appears as a caenogenetic process in the mammalian embryo, whereas in the sauropsid amniotes most of the systemic lymphatic channels develop along more primitive phylogenetic lines, by the direct confluence of numerous intercellular mesodermal spaces.

These relative conditions have been outlined in a previous publication on the phylogenetic relations of the lymphatic and blood-vascular systems in vertebrates.³⁸ The results of the more

³⁸ Geo. S. Huntington, "The phylogenetic relations of the lymphatic and blood-vascular systems in vertebrates."

Anat. Record. vol. IV, no. 1, January 1910.

recent detailed investigations of lymphatic development in birds and reptiles have fully sustained the interpretation given in the publication quoted.

b. The darkly stained mass of cells seen in the interval between 16 and 17 in both sections is the result of obliteration of early embryonic vascular channels, which have lost their connection with the vessels, and whose endothelial walls are apparently in the process of reverting to indifferent mesodermal cells. Many of these degenerated vascular aggregations are formed in embryos between 13 and 15 mm. crown-rump measure.

Some of the elements of this early embryonic prevertebral venous plexus are secondarily replaced by perivenous or extraintimal lymphatic spaces in exactly the same way as is observed in the development of the ventral mediastinal duct. The resulting, originally separate, extraintimal lymphatic anlagen, having replaced the venule along and around which they primarily developed, unite with each other and form the preazygos segment of the thoracic duct, between the thoracic duct approach of the jugular lymph sac and the level of the aortic arch, at which the azygos portion of the thoracic duct begins.

Fig. 162 shows a transverse section of the left side of the upper thoracic region in a 14 mm. cat embryo (series 210, slide IX, section 26, $\times 200$). The prevertebral tributary plexus (17) turns mesad of the sympathetic nerve (1) to enter the dorso-medial angle of the left innominate vein (40). Dorsad of the main vein is the ascending portion of the left subclavian artery (33). Between aorta (7) and innominate vein (40) are other elements of the mediastinal venous plexus, in the interval between the sympathetic nerve (1) and the vagus (22), with ventral branches (32) in front of the latter.

Between the oesophagus and the prevertebral plexus (17) is an area in which venous elements (4), formerly connected with the same, are undergoing replacement by the extraintimal lymphatic anlagen (5) of the preazygos segment of the thoracic duct. These structures cannot be distinctly made out in fig. 162, but they are shown in a higher magnification in detail in fig. 163, which includes the region of the same section dorsal to the oesoph-

agus magnified 225 diameters. The prevertebral venous plexus (17) extends in an arch concentric with the dorsal circumference of the oesophagus (8), in front of the vertebral centers. Between it and the oesophagus, mesal to the sympathetics (1), are seen on each side former elements of the venous plexus (4) surrounded by the extraintimal lymphatic anlages (5) of the preazygos segment of the thoracic duct.

Figs. 164, 165 and 166 show the same structures in the next three sections (25, 24 and 23), proceeding cephalad. Fig. 166 is especially clear. In it the original line of connection of the atrophying venous kernel (4) with the prevertebral plexus (17) can still be made out as a band of condensed mesoderm, and the endothelium of the perivenous lymphatic space (5) is clearly marked.

Figs. 167 and 168 show this area in two successive sections of the same embryo further caudad (series 210, slide ix, sections 43 and 44, $\times 150$), and fig. 169 gives the last section magnified 200 diameters. The empty central venous remnant (4), with the enveloping extraintimal lymphatic anlage (5), and the still functional elements of the prevertebral plexus (17), can be seen in all of the sections. They also show, nearer to the dorso-lateral wall of the oesophagus, one of the collections of darkly stained mesodermal cells above referred to as representing remnants of formerly patent blood-vessels.

The series of microphotographs shown in figs. 160 to 169 inclusive again conclusively demonstrates the origin of this portion of the lymphatic channel by confluence of independent extraintimal mesenchymal spaces surrounding and replacing degenerating embryonic venules. The reproductions only give relatively faint and indistinct views of the actual conditions observed under the microscope. The general mesenchymal tissue in this region is extremely loose and the area is very difficult to photograph sharply and distinctly. The actual sections, however, offer histological pictures identical with those observed as above described in the development of the ventral mediastinal lymphatic duct. The extraintimal lymphatic spaces are either closely applied to part of the circumference of the wall of the

shrinking venule, or they occasionally completely surround the same. In the former case the contained venous remnant is connected at part of its periphery with the wall of the enveloping lymphatic space. In the latter and more exceptional case, the free ventral nucleus of the lymphatic space is formed by the atrophied vein. In either case the lumen of the latter may contain a few degenerated red blood cells. These pictures are again constant in embryos of the appropriate stages. The lymphatic anlage can be accurately traced from its indefinite beginning among the perivenous mesenchymal intercellular clefts through a number of successive sections to its similar distal terminations in the same intercellular plexus. Following the sections from this point caudad through a varying intervening area in which no distinct lymphatic channel appears, the same line will sooner or later reveal the repetition of the same process, and the formation of another link in the still disjointed chain of primitive lymphatic anlages.

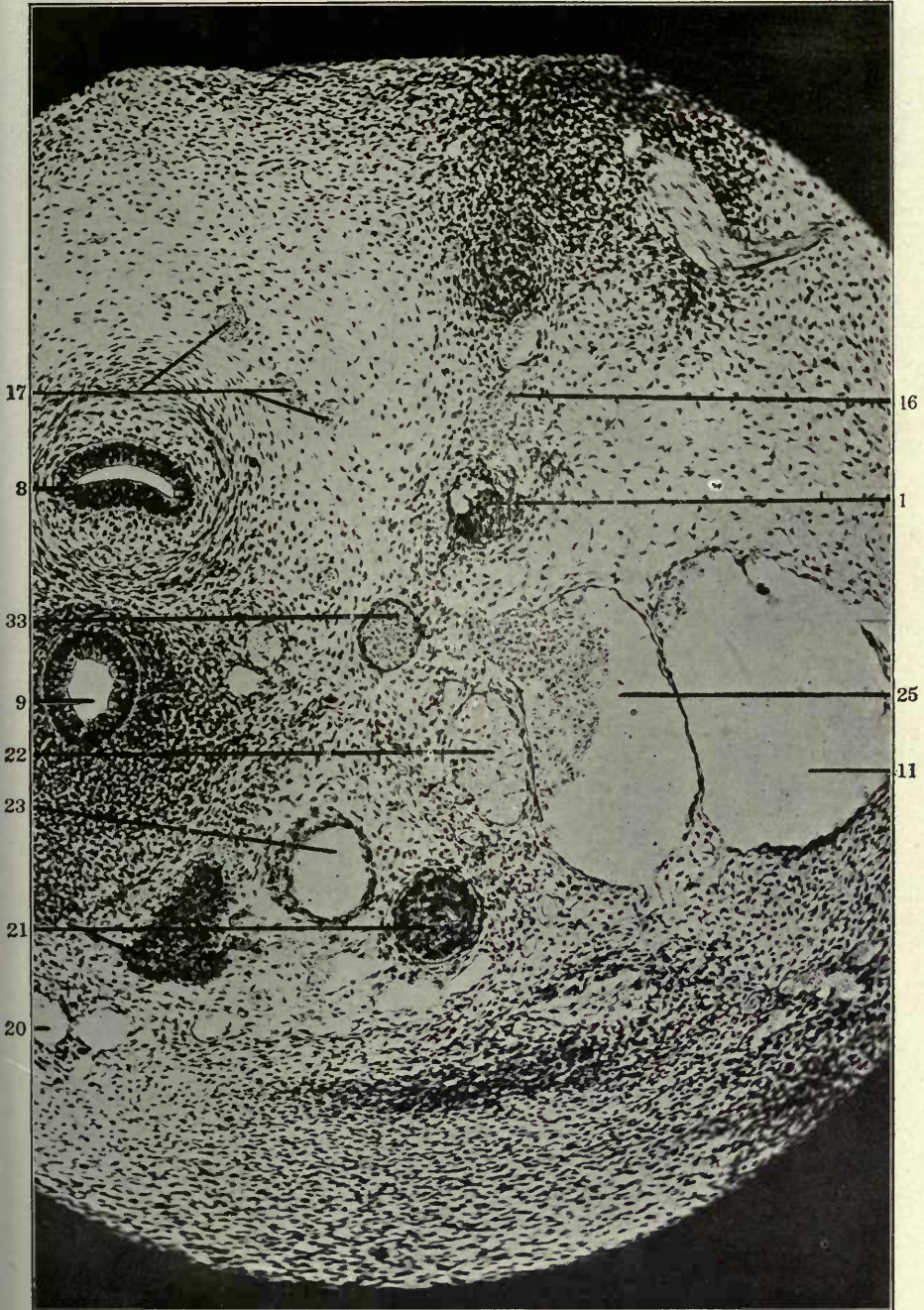
It is again to be noted here that in the earlier stages (13, 13.5, 14 mm.), the individual spaces, plus their kernel of atrophied vein, are relatively larger than in the later (15–15.5 mm.) embryos. In the earlier stages (13 mm., 13.5 mm. and 14 mm. embryos) these separate and still isolated segments of the future continuous lymphatic channel begin and end blindly. In the 15 and 15.5 mm. stages they have increased in number and adjacent links have united to form longer segments. Finally, in the 16 mm. cat embryo, the preazygos portion of the thoracic duct is usually established as a nearly continuous channel through the further confluence of the originally separate and distinct components. Every stage of the extraintimal lymphatic development can be observed with absolute certainty and accuracy in every series within the proper length limits.

PART II, PLATES
FIGURES 159 TO 169

FIGURE 159

159 Transection of upper thoracic region in a 14 mm. cat embryo (series 212, slide VII, section 23), $\times 150$.

- 1 Sympathetic nerve.
- 8 Oesophagus.
- 9 Trachea.
- 11 Jugular lymph sac.
- 16 Dorso-medial somatic venous tributaries.
- 17 Prevertebral venous plexus.
- 20 Subthymic venous plexus.
- 21 Thymus.
- 22 Vagus.
- 23 Left carotid artery.
- 25 Internal jugular vein.
- 33 Left subclavian artery.

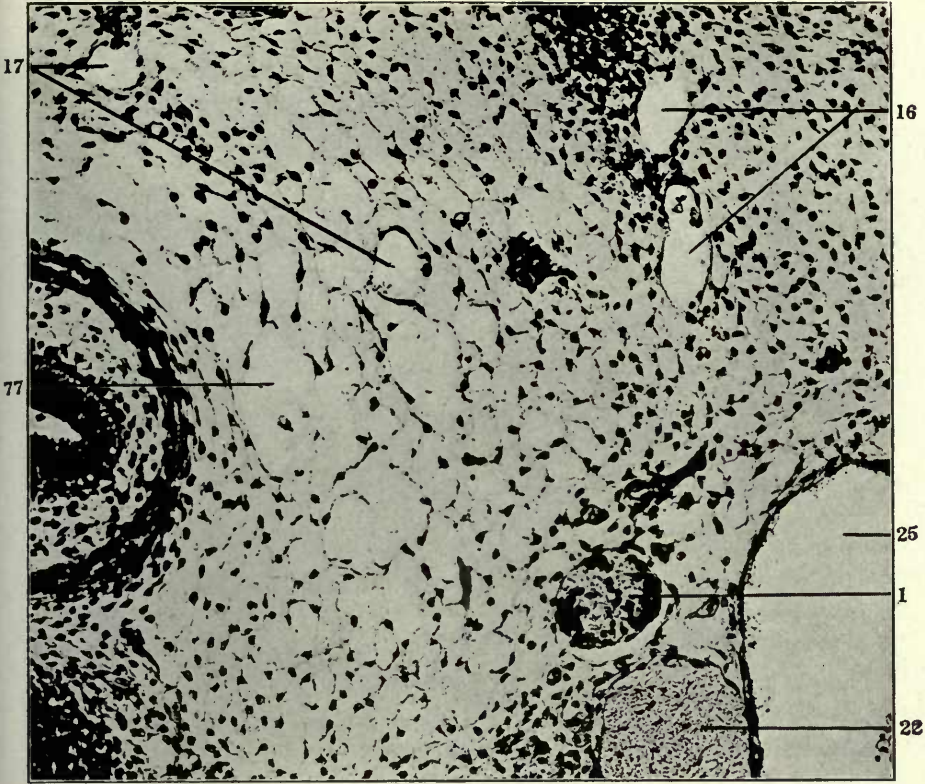


FIGURES 160 AND 161

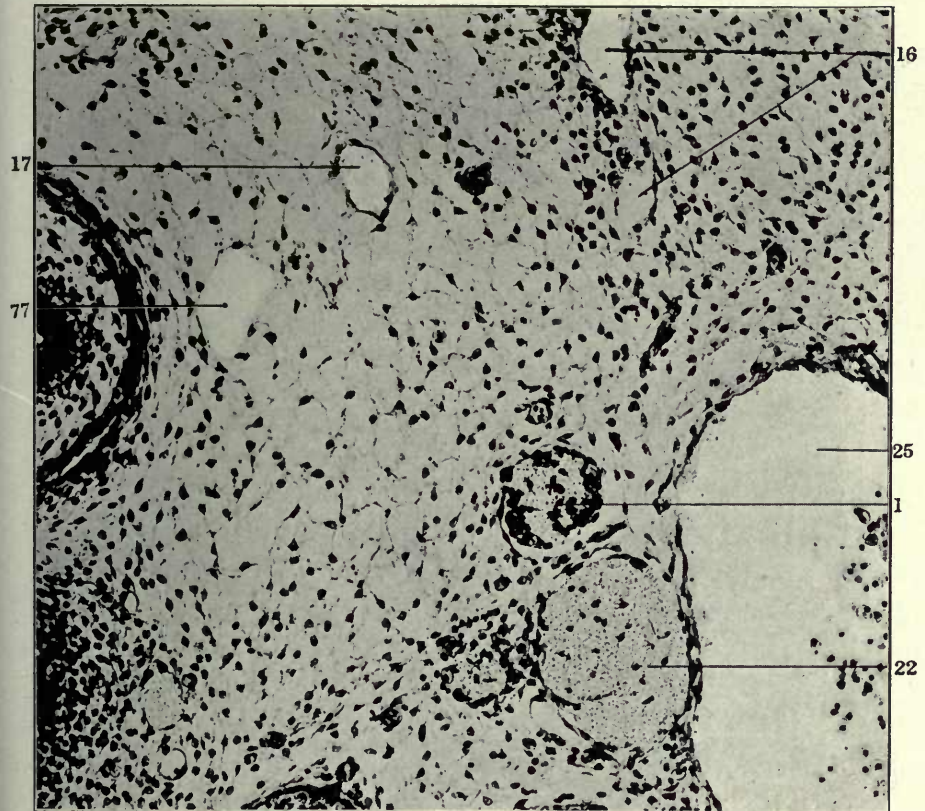
160 Transverse section of dorsal portion of upper thoracic region in a 13.5 cat embryo (series 189, slide VII, section 20), $\times 225$.

161 Same, section 21.

- 1 Sympathetic nerve.
- 16 Dorso-medial somatic venous tributaries.
- 17 Prevertebral venous plexus.
- 22 Vagus.
- 25 Internal jugular vein.
- 77 Mesenchymal intercellular lymphatic anlagen.



160



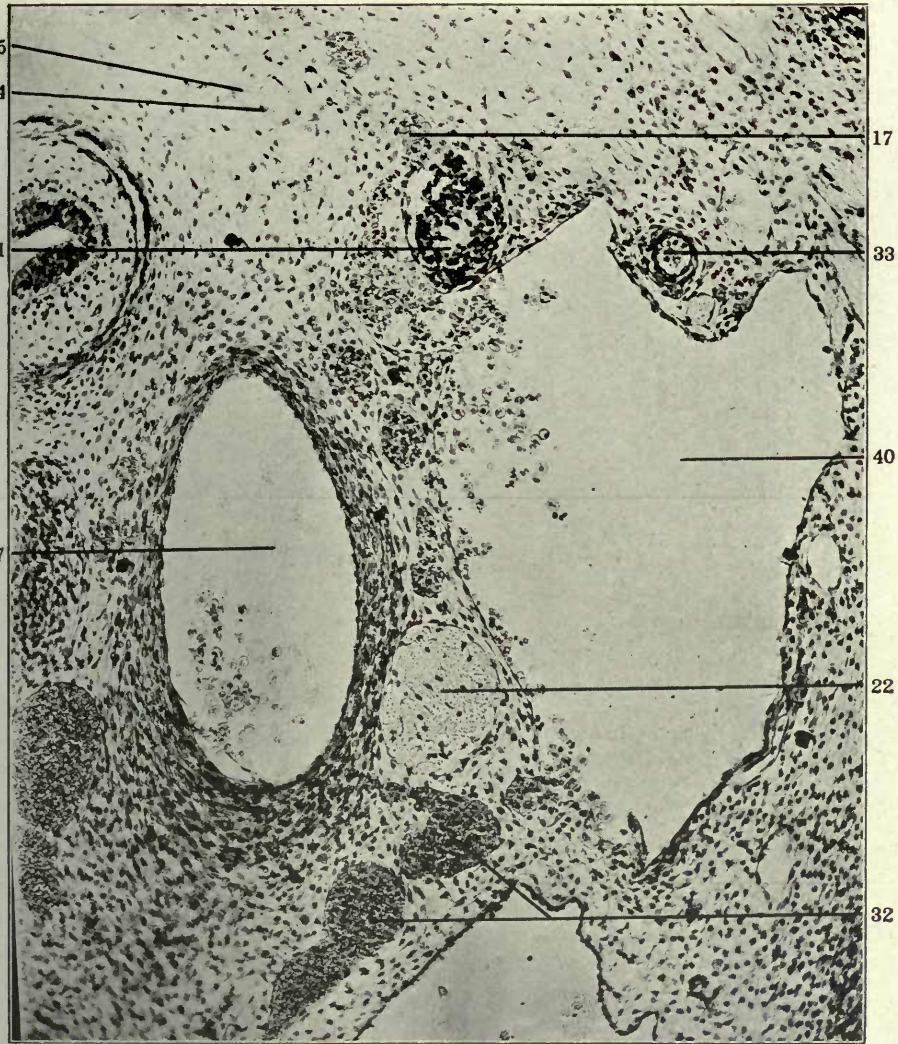
161

FIGURES 162 AND 163

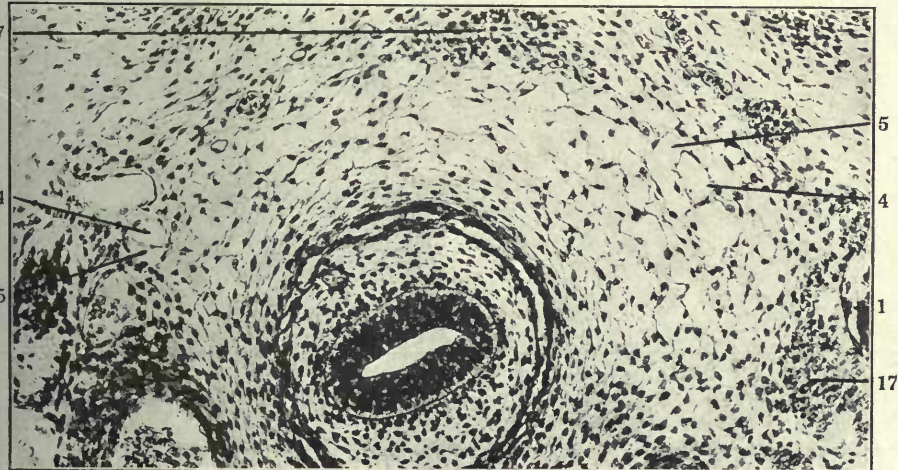
162 Transverse section of upper thoracic region in a 14 mm. cat embryo (series 210, slide IX, section 26), $\times 200$.

163 Dorsal portion of same section, $\times 225$.

- 1 Sympathetic nerve.
- 4 Atrophying embryonal vein, forming kernel in interior of developing and replacing lymphatic space.
- 5 Extraintimal or perivenous lymphatic space surrounding degenerating embryonal vein.
- 7 Aorta.
- 17 Prevertebral venous plexus.
- 22 Vagus.
- 32 Ventral mediastinal venous plexus.
- 33 Left subclavian artery.
- 40 Innominate vein.



162

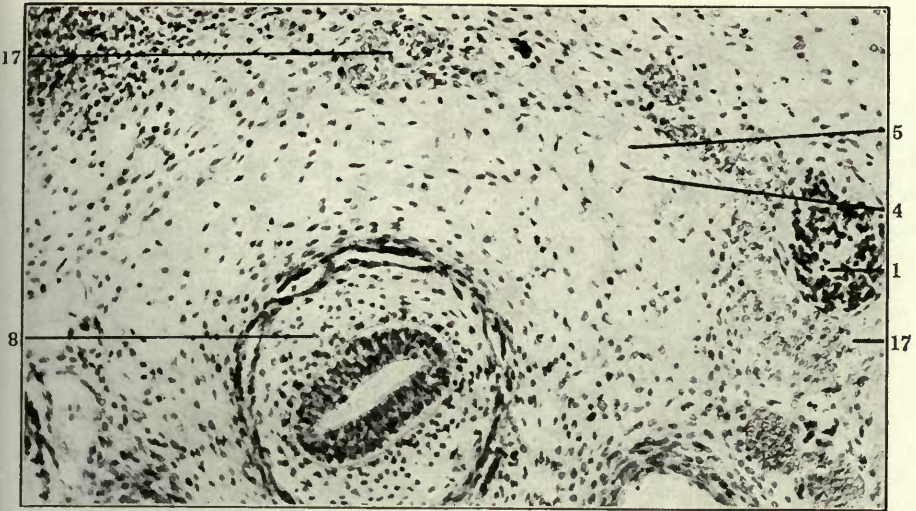


163

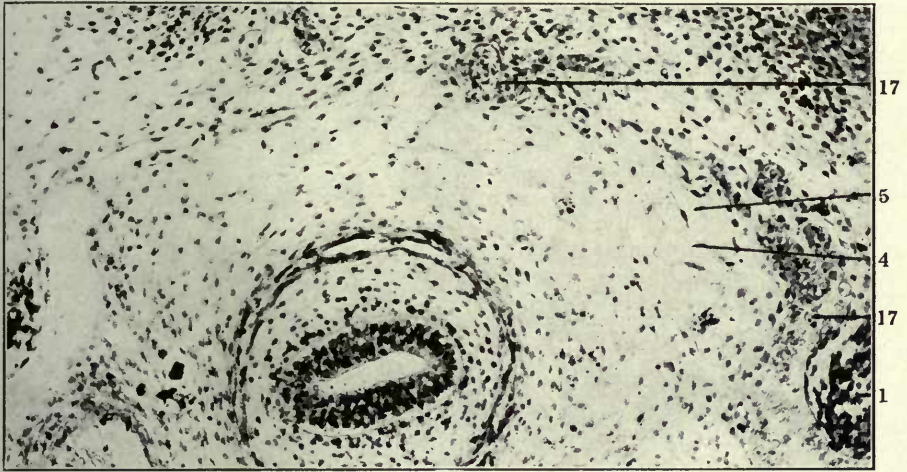
FIGURES 164, 165 AND 166

- 164 Same, section 25.
- 165 Same, section 24.
- 166 Same, section 23.

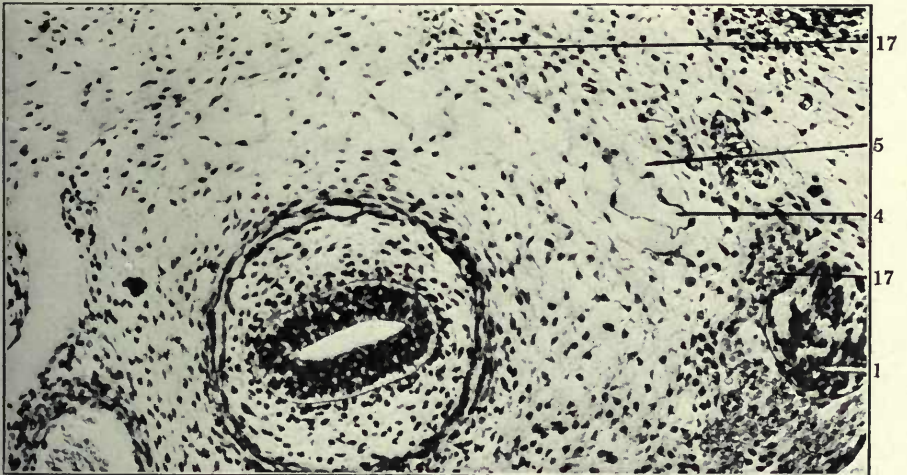
- 1 Sympathetic nerve.
- 4 Atrophying embryonal vein, forming kernel in interior of developing and replacing lymphatic space.
- 5 Extraintimal or perivenous lymphatic space surrounding degenerating embryonal vein.
- 8 Oesophagus.
- 17 Prevertebral venous plexus.



164



165



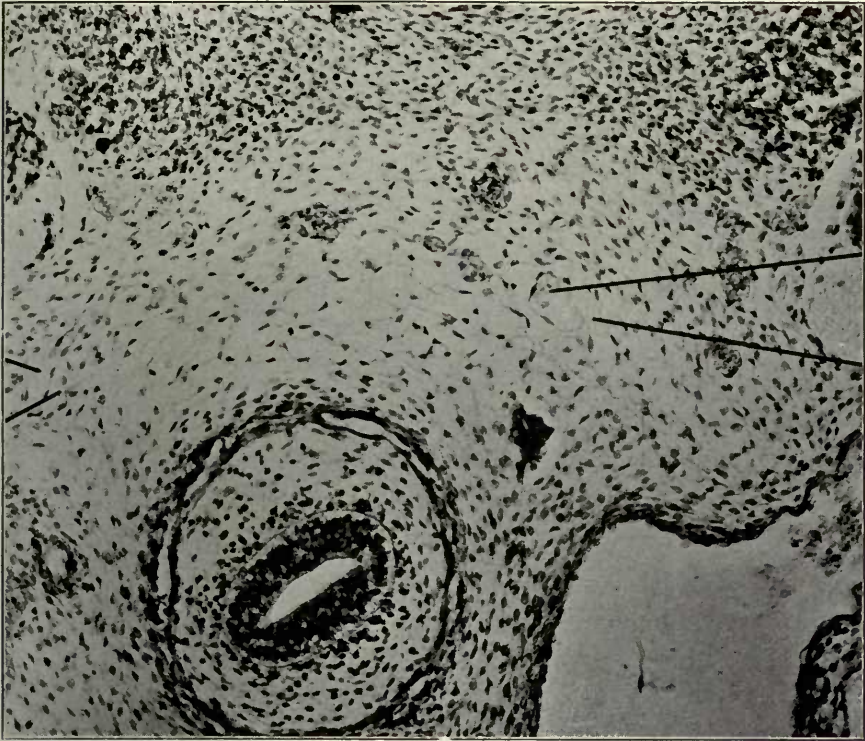
166

FIGURES 167 AND 168

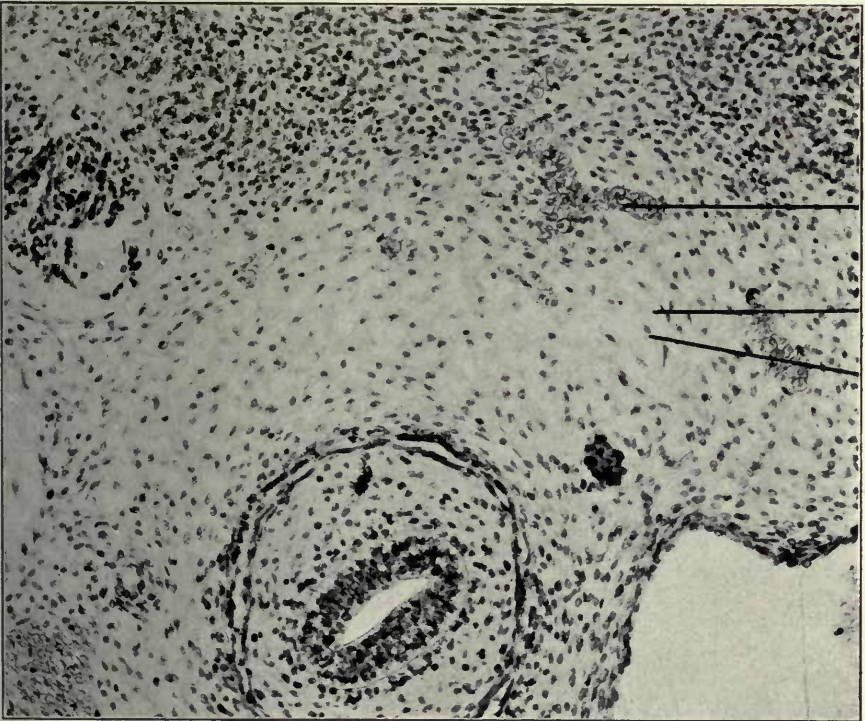
167 Same, section 43 \times 150.

168 Same, section 44 \times 150.

- 1 Sympathetic nerve.
- 4 Atrophying embryonal vein, forming kernel in interior of developing and replacing lymphatic space.
- 5 Extraintimal or perivenous lymphatic space surrounding degenerating embryonal vein.
- 17 Prevertebral venous plexus.



167

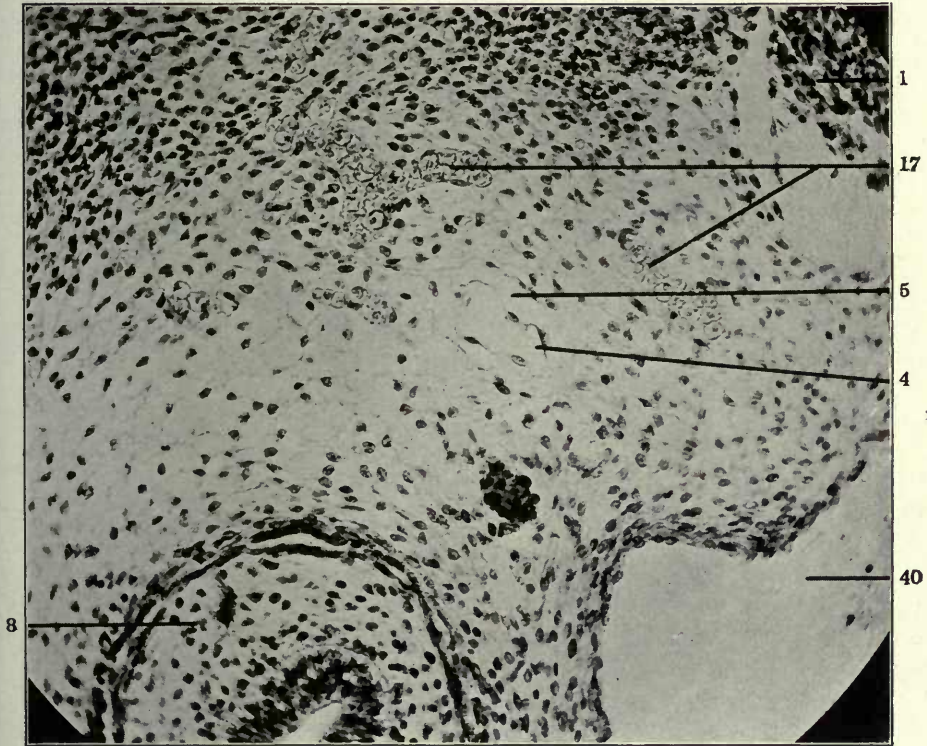


168

FIGURE 169

169 Same, section 44. $\times 200$.

- 1 Sympathetic nerve.
- 4 Atrophying embryonal vein, forming kernel in interior of developing and replacing lymphatic space.
- 5 Extraintimal or perivenous lymphatic space surrounding degenerating embryonal vein.
- 8 Oesophagus.
- 40 Innominate vein.



C. The junction of the two independently formed lymphatic channels above described, viz., the preazygos segment of the thoracic duct and the ventral mediastinal trunk, with each other and with the thoracic duct approach of the jugular lymph sac.

In the 15 and 15.5 mm. embryo of the cat the thoracic duct approach of the jugular lymph sac has extended mesad between the common jugular and innominate veins and the thyro-cervical or subclavian arteries to the interval between the main vein and the sympathetic nerve. In this region the process makes secondary connections with the independently developed ventral mediastinal lymphatic trunk and with the equally independently formed preaortic segment of the thoracic duct.

The order of this union, as previously explained, appears to have an important influence on the subsequent topographical position of this portion of the adult thoracic duct. If the jugular sac approach first meets and unites with the ventral mediastinal lymphatic channel, then the entire duct appears to pass ventrad to the sympathetic strand, between it and the adjacent dorso-medial surface of the main vein, to turn subsequently dorsad towards the prevertebral region on the mesal aspect of the nerve (reconstruction, fig. 171, series 143, slides x and xi, figs. 172 to 183).

If, on the other hand, the thoracic duct approach first joins the preazygos segment of the thoracic duct, developed by the confluence of the dorsal perivenous lymphatic anlagen accompanying and surrounding the prevertebral venous plexus cephalad of the aortic arch level, then the resulting thoracic duct passes dorso-laterad to the sympathetic nerve, after having received the ventral mediastinal trunk through the interval between this nerve and the main vein (text figs., p. (72).

Fig. 170 shows in a dorsal view the reconstruction of the left vascular complex of the lower cervical and upper thoracic regions in a 15 mm. cat embryo (series 218, slides VIII, sections 25-44; ix, sections 1-48; x, sections 1-48; xi, sections 1-48; xii, sections 1-48.)

The reconstruction should be followed in the direction caudo-cephalad. The caudal part of the reconstruction includes

the cephalic portion of the azygos system. The left (6') and the right (3') azygos veins are seen arching caudo-cephalad to empty into the left (6) and right (3) precavae. They are joined by the broad plexiform plate of the interazygos anastomosis, whose meshes are perforated by the intersegmental arteries. The sympathetic nerve strands (1) lie between the arterial branches and the azygos trunks, in the angle between them and their dorsal somatic tributaries. Ventro-mesad of the right precava (3) is seen the right vagus (22). The distal end of the right pulmonary artery (10) is seen below the right azygos-caval arch (3'-3), surrounded by the channel of the broncho-mediastinal trunk (37). In the azygos-caval arch, and along the right precava (3) are the precaval lymphatic anlagen (53) previously referred to (cf. supra pp. (30) as being the first extraintimal lymphatic spaces to develop in this region, as early as the 12 mm. stage (cf. figs. 10 and 11).

The cephalic portion of the azygos segment of the thoracic duct, well developed in this stage, is hidden in this view of the reconstruction by the dorsal interazygos venous plexus, on the ventral face of which the lymphatic network is situated. Only a few scattered and isolated lymphatic anlagen are seen projecting cephalad of this anastomosis, and not yet joined to the preazygos segment of the thoracic duct (35).

Cephalad of the area just described are the large arterial vessels, viz., the Ductus arteriosus Botalli (56), the aortic arch (7), the right subclavian artery (57), the innominate continuation of the carotid trunk (45), and the left subclavian artery (33), with the left vertebral (41) and thyro-cervical (24) arteries arising from it. The ventrolateral continuation of the left subclavian cannot be seen in this view of the reconstruction. Ventrad of the thoracic aorta is seen the ventral mediastinal venous plexus with the accompanying cephalic part of the broncho-mediastinal lymphatic complex (upper 37 in fig. 170).

The preazygos segment of the thoracic duct (35) appears as a well developed channel on the dorso-medial aspect of the aortic arch, ascending behind the left subclavian artery (33). A number of scattered lymphatic anlagen, at the level of leader 35, offer

the genetic opportunity of establishing, in later stages, a communication between the preazygos thoracic duct (35) and the broncho-mediastinal channel (37), which would correspond to the distal connection noted above (cf. p. (85) in the adult between these two lymphatic channels (cf. figs. 94, 95, 96 and 97).

The cephalic end of the preazygos segment of the thoracic duct still ends blindly in this stage in two longer prolongations, the connection with the thoracic duct approach of the jugular lymph sac not having been as yet established. The latter rides in the fork between the main jugular vein and the entrance of the left superior intercostal vein (16-46). One process of the approach (12) hooks caudad on the dorso-lateral side of this vein, between it and the thyrocervical artery (24) and ends blindly lateral to the sympathetic nerve (1). Another blunt terminal of the thoracic duct approach turns ventro-mesad, between vagus (22) and sympathetic nerve (1), and is exposed in the reconstruction by the removal of a segment of the latter nerve which otherwise would hide it in the dorsal view here given. A long slender process passes from this portion of the thoracic duct approach ventro-mesad between the vagus (22) and carotid (22). This process, which seems to be constantly present, probably effects in later stages a connection with the cephalic part of the ventral mediastinal lymphatic plexus.

It is evident, in considering the detached and isolated lymphatic anlagen intervening here between the thoracic duct approach and the blind cephalic end if the preazygos segment of the thoracic duct already formed (35) that in course of further development the union between the latter and the jugular sac could have been established either on the dorso-lateral or ventro-medial side of the sympathetic nerve, thus leading to one or the other of the topographical conditions above discussed (cf. p. 75 and text figures).

The fifth spinal nerve (54) still penetrates the caudo-lateral part of the lymph sac. Below the same are seen the sixth, seventh and eighth segmental nerves of the brachial plexus (55). The thyrocervical artery (24) sends its ventral branch forward between the jugular and subclavian approaches of the lymph sac (just caudal to vein 16-46), and then continues cephalad on the dorsal aspect of the sac.

Fig. 171 shows a reconstruction of the left vascular complex of the lower cervical and upper thoracic regions in a 15.5 mm. cat embryo (series 143, slides viii, ix, x, xi, and xii, 225) viewed from the right side and from behind, and figs. 172 to 183 give transverse sections of the left upper thoracic region in the same embryo, selected from slides xi and x. The figure of the reconstruction gives by means of side lines and roman numerals the level of the slides entering into its composition, so that the individual sections shown in the microphotographs can be referred to and oriented by the reconstruction.

The reconstruction as well as the photographs of the sections should be followed from below upwards.

Description of reconstruction, fig. 171. The reconstruction is carried caudad to the upper azygos region. The right azygos arch (3') is seen entering the dorsal circumference of the right precava (3). Azygos (6') and precava (6) of the left side cannot be distinctly seen in this view of the model. Mesal to the right praecava (3) is the right vagus (22).

Projecting cephalad above the azygos arches and the interazygos anastomosis are seen the cephalic elements of the azygos portion of the thoracic ducts (36), which extend thence caudad along the ventral surface of the azygos complex. The cephalic end of the azygos segment of the ducts has not yet joined the caudal extremity of the preazygos segment (35), although they have approached each other closely, and adjacent detached lymphatic elements between them foreshadow their coming union.

The preazygos segment of the thoracic duct (35) is a well developed plexiform channel, which receives a considerable branch from the lymphatic complex along the ventral aspect of the prevertebral venous plexus (17). The latter is now fully formed and differentiated clearly from the adjacent lymphatics, draining as a chain of venous spaces caudad into the azygos arches. This central part of the preazygos duct (35) intersects with the medial aspect of the large vertebral vessels (41, 42) and the underlying left subclavian artery and receives just caudal to this point a lymphatic channel connecting it with the broncho-mediastinal duct. This lymphatic vessel cannot be seen distinctly in this

view of the reconstruction, because it is largely under cover of the extensive venous plexus encrusting the medial surface of the left innominate vein on which it lies. It can, however, be clearly traced in the corresponding sections of slides xi and x shown in figs 172 to 183 (cf. *infra*).

The preazygos segment of the thoracic duct then continues on the mesal side of the sympathetic (1) cephalad, swings laterad on the ventrolateral aspect of the nerve, between it and the common jugular vein, mesal to the thyrocervical artery (24), and unites in this situation with the thoracic duct approach of the jugular lymph sac (12). The latter extends as a well defined prolongation from the dorsal aspect of the jugular approach (13).

The aortic arch (7) with the innominate trunk (45), the right subclavian origin (57) and the two carotid arteries (23, 32'), occupies the centre of the model. The left subclavian artery cannot be followed in this view, but the left vertebral artery (41) is shown. Further ventrad is the section of the left innominate vein (40). The thymus (21) is nearly buried in the extensive perithymic venous anastomosis (19, 20), which also hides from view the most of broncho-mediastinal lymphatic plexus.

The thyrocervical artery (24) perforates between the two divisions of the lymph sac, lateral to the jugular approach (13). The fifth spinal nerve (54) and a companion vein still penetrate the caudo-lateral part of the sac. Further caudad and laterad are the sixth and seventh segmental nerves (55). The jugular approach sends a caudal prolongation along the dorso-medial aspect of the main vein, between it and the sympathetic nerve, which parallels the thoracic duct approach, and may, together with a large detached lymphatic island further caudad, represent an incomplete form of double or bifid thoracic duct approach as previously described (cf. *supra*, p. 63, text figure.)

Union of broncho-mediastinal duct with preaortic portion of thoracic duct and junction of both with thoracic duct approach of the jugular lymph sac. The achievement of this stage is excellently illustrated in the microphotographs of this 15.5 mm. embryo (series 143) shown in figs. 172 to 183. In fig. 172 (series 143, slide xi, section 16), a section through the left side of the upper thoracic

region, the cephalic end of the preaortic segment of the thoracic duct (fig. 172, 35) is seen lateral to the oesophagus (8), between the sympathetic nerve (1) dorsad and the subclavian artery (33) and left innominate vein (40) ventrad. The cephalic end of the broncho-mediastinal channel (37) lies in the angle between subclavian artery and innominate vein, lateral to and at some distance from the trachea (9). The two lymphatic channels are traced in the succeeding sections cephalad to their union and their continuation with the thoracic duct approach of the jugular lymph sac.

In fig. 173 (series 143, slide xi, section 14) the lymphatic ducts have approached each other and a third lymphatic cross-section appears mesal to the subclavian artery in the interval between the thoracic duct and the broncho-mediastinal channel, foreshadowing their approaching fusion (38). In fig. 174 (series 143, slide xi, section 12) this fusion has occurred (38 in fig. 174 representing union of 35 and 37)

In fig. 175 (series 143, slide xi, section 11) the connection is interrupted, and in the succeeding sections (figs. 176, 177, 178 and 179) the two components of the area of confluence (38), viz, the preaortic thoracic duct segment and the broncho-mediastinal trunk, remain separated from each other. The latter assumes more and more the typical character of the thoracic duct approach of the jugular lymph sac, as previously described (cf. p. 60), occupying the typical neuro-venous recess between sympathetic nerve and innominate vein, as shown well in figs. 178 and 179 (series 143, slide xi, section 2, and slide x, section 32).

In fig. 180 (series 143, slide q, section 28) the two lymphatic components have again united (38), and they continue from this point on as a single channel following the typical course of the thoracic duct approach of the jugular lymph sac cephalad to union with that structure.

We have therefore in this stage a gradual approach of the cephalic ends of the preaortic segment of the thoracic duct and of the ventral broncho-mediastinal trunk, a preliminary anastomosis between them (figs. 173, 174), followed further cephalad by a final confluence and union with the thoracic duct approach of the jugular lymph sac.

A comparison of the series just studied (series 143) with another 15.5 mm. embryo (series 141) shows identical conditions. Thus figs. 184 and 185 show transverse sections through the upper part of the left thoracic region of the embryo. In fig. 184 the preazygos segment of the thoracic duct and the broncho-mediastinal trunk (38) are approaching each other in the interval between the innominate vein (50) and the subclavian artery (33) laterad, and trachea (9) and oesophagus (8) mesad. This quite agrees with the conditions seen in series 143, in figures 172 and 173 (sections 16 and 14 of slide xi). In fig. 185 (slide x, section 21 of series 141) the two lymphatic anlagen have joined (38), repeating practically conditions which series 143 shows in sections 11 and 12 of slide xi, figs. 174 and 175. The permanent functional peritracheal venous plexus (18) appears clearly differentiated from the lymphatic channels in both sections.

The earlier stages in the development of this junctional area just studied in the 15.5 mm. stages (series 143 and 141) are found in a 13.5 mm. cat embryo, series 223. Two sections of the left upper thoracic region are shown in figs. 186 and 187 (series 223, slide viii, sections 39 and 40, $\times 225$). The sections pass through the left innominate vein (40), the left subclavian artery (33), at the level of origin of the vertebral (41) and the costocervical arteries (43), and the innominate artery (45).

Both sections show the radicles of the peritracheal mediastinal venous plexus, and the beginning replacement of certain elements of the same (4) by extraintimal perivenous lymphatic spaces (5), which form the anlage of the future junctional channel between the broncho-mediastinal lymphatic trunk and the preazygos segment of the thoracic duct. These spaces are situated dorsad to the aorta and the innominate artery (45), in the interval between the trachea (9) mesad, the oesophagus (8) dorso-mesad, and the innominate vein (40) and sympathetic nerve (1) laterad.

The developing perivenous lymphatic spaces seen here in this earlier 13.5 mm. embryo correspond to the finished lymphatic channel segments of the later 15.5 mm. stages, in which the preazygos segment of the thoracic duct meets and joins with the independently developed broncho-mediastinal trunk, as just seen in series 143 and 141 (figs. 172 to 185).

PART II, PLATES

FIGURES 170 TO 187

FIGURE 170

170 Reconstruction of left vascular complex of lower cervical and upper thoracic regions of a 15 mm. cat embryo (series 218, slide VIII, sections 25 to 44; slide IX, sections 1 to 48; slide X, sections 1 to 48; slide XI, sections 1 to 48; slide XII, sections 1 to 48, $\times 225$), dorsal view.

- 1 Sympathetic nerve.
- 3' Right azygos vein.
- 3 Right precava.
- 6 Left precava.
- 6' Left azygos vein, thoracic portion.
- 7 Aorta.
- 10 Pulmonary artery.
- 12 Jugular lymph sac, thoracic duct approach.
- 16 Dorso-medial somatic venous tributaries.
- 22 Vagus.
- 24 Thyrocervical artery.
- 33 Left subclavian artery.
- 35 Thoracic duct, preazygos segment.
- 35' Detached lymphatic space in path of preazygos channel.
- 37 Broncho-mediastinal duct.
- 41 Vertebral artery.
- 42 Vertebral vein.
- 45 Innominate artery.
- 46 Left superior intercostal vein.
- 53 Precaval lymphatics.
- 54 Fifth spinal nerve.
- 55 Sixth, seventh and eighth spinal nerve
- 56 Ductus arteriosus Botalli.
- 57 Right subclavian artery.

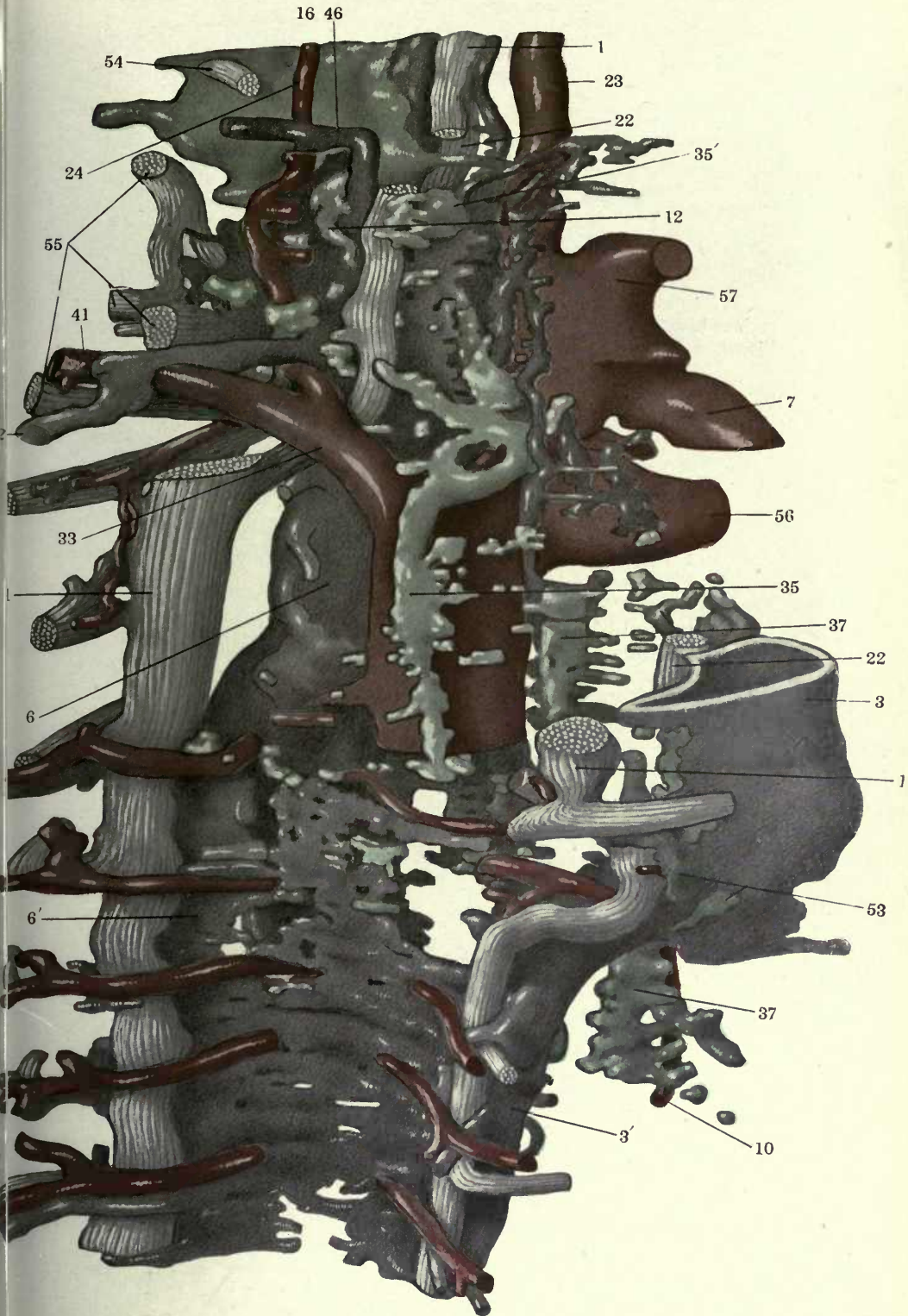
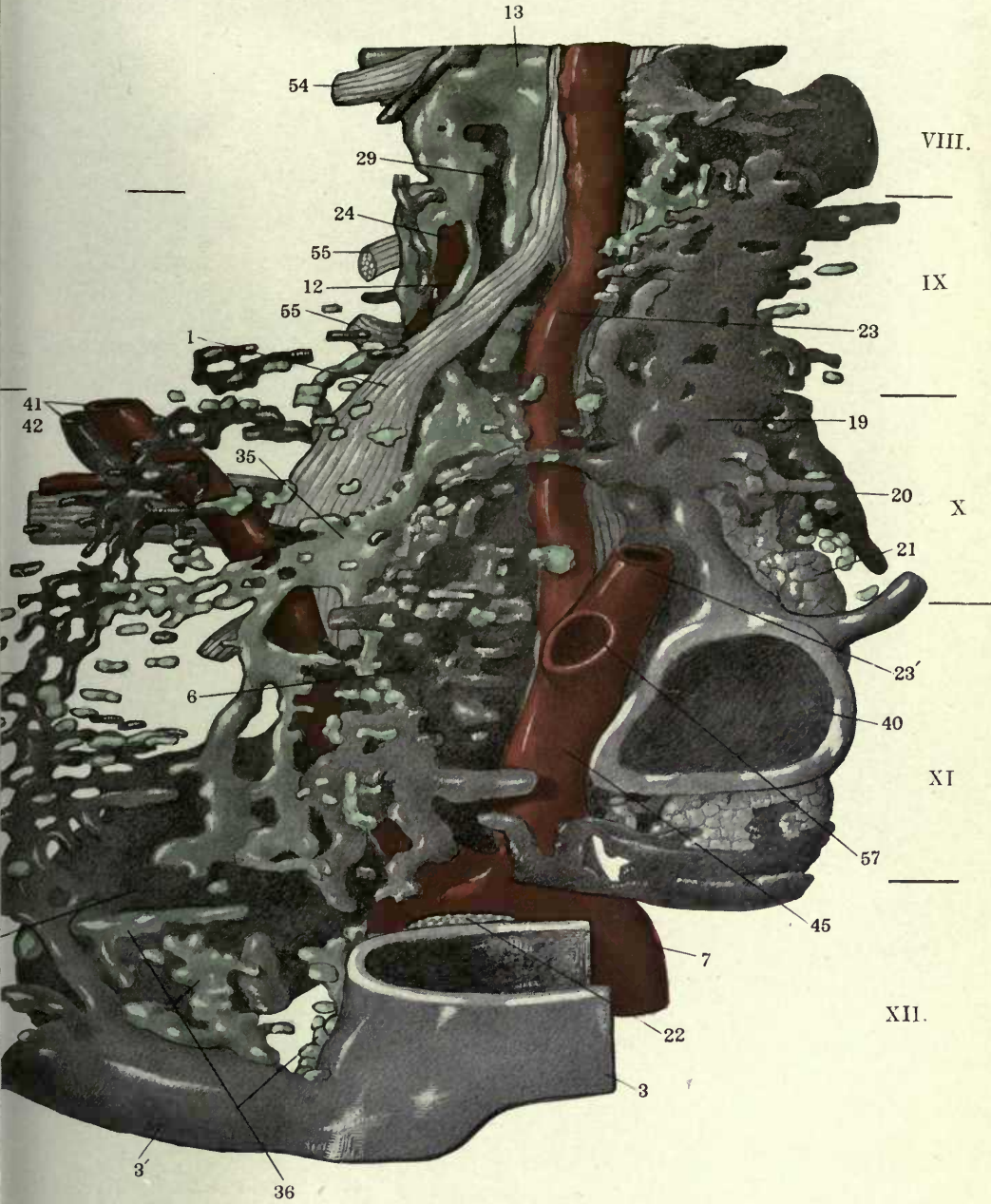


FIGURE 171

171 Reconstruction of left vascular complex of lower cervical and upper thoracic regions in a 15.5 mm. cat embryo, (series 143, slides VIII, IX, X, and XI), $\times 225$. View from behind and from right side.

- 1 Sympathetic nerve.
- 3' Right azygos arch.
- 3 Right precava.
- 6 Left precava.
- 6' Left azygos vein, thoracic portion.
- 7 Aorta.
- 12 Jugular lymph sac, thoracic duct approach.
- 13 Jugular lymph sac, jugular approach.
- 17 Prevertebral venous plexus.
- 19 Suprathymic venous plexus.
- 20 Subthymic venous plexus.
- 21 Thymus.
- 22 Vagus.
- 23 Left carotid artery.
- 23' Right carotid artery.
- 24 Thyrocervical artery.
- 29 Jugulo-subclavian trunk.
- 35 Thoracic duct, preazygos segment.
- 36 Thoracic duct, azygos segment.
- 40 Innominate vein.
- 41 Vertebral artery.
- 42 Vertebral vein.
- 45 Innominate artery.
- 54 Fifth spinal nerve.
- 55 Sixth, seventh and eighth spinal nerve
- 57 Right subclavian artery.

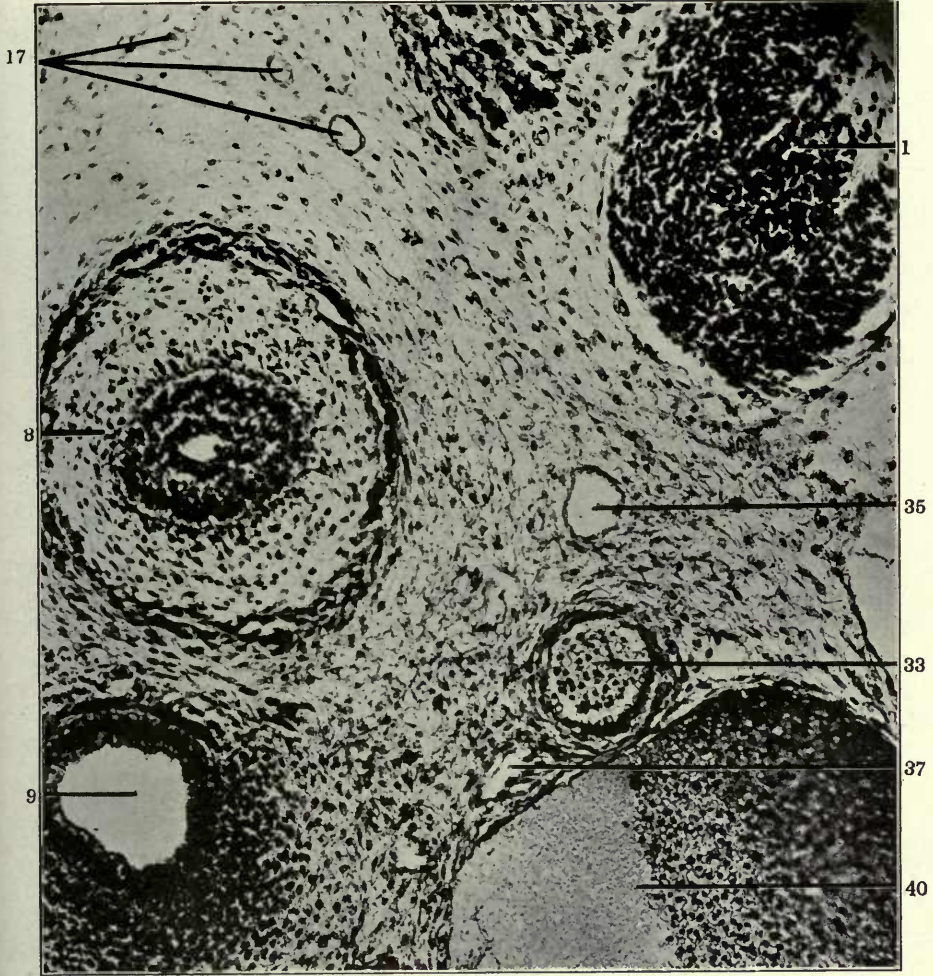


FIGURES 172 AND 173

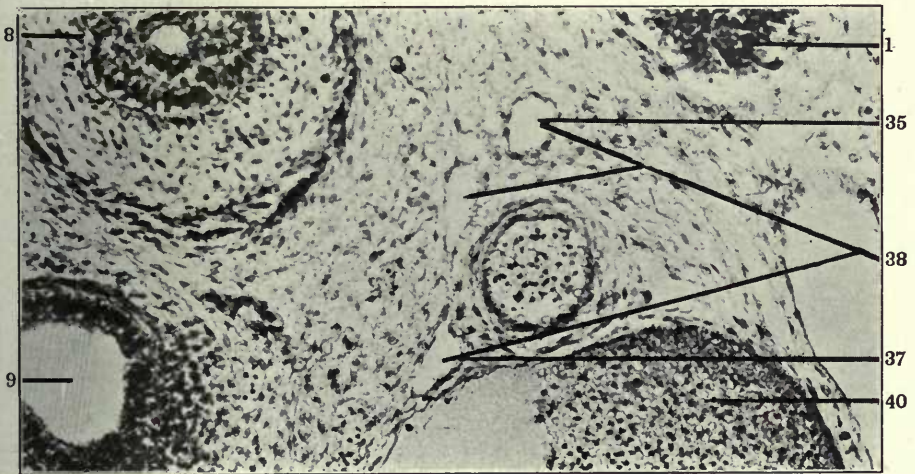
172 Transverse section of left side of upper thoracic region of a 15 mm. cat embryo, (series 143, slide XI, section 16), $\times 200$.

173 Same, section 14.

- 1 Sympathetic nerve.
- 8 Oesophagus.
- 9 Trachea.
- 17 Prevertebral venous plexus.
- 33 Left subclavian artery.
- 35 Thoracic duct, preazygos segment.
- 37 Broncho-mediastinal duct.
- 38 Confluence of broncho-mediastinal duct and preazygos segment of thoracic duct.
- 40 Innominate vein.



172

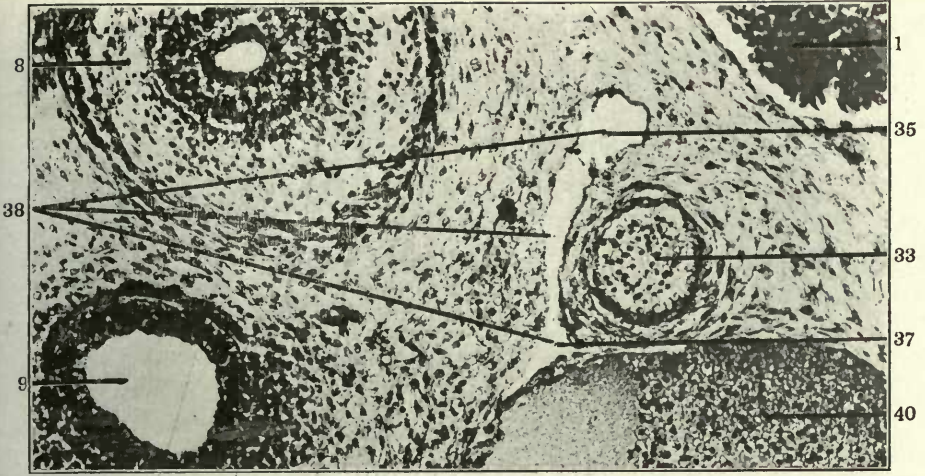


173

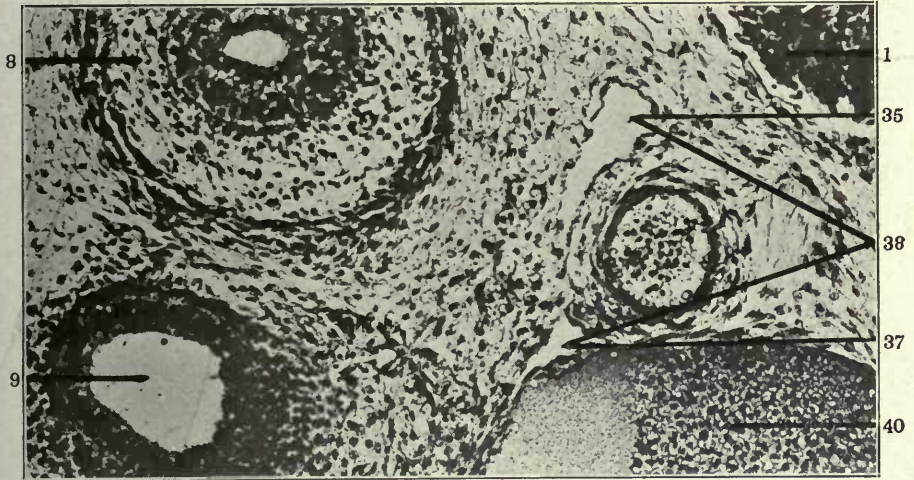
FIGURES 174, 175 AND 176

- 174 Same, section 12.
- 175 Same, section 11.
- 176 Same, section 6.

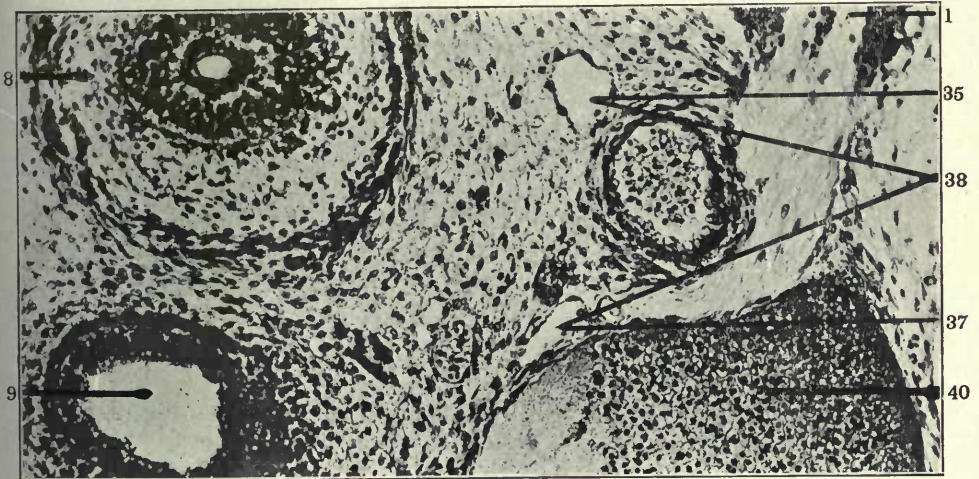
- 1 Sympathetic nerve.
- 8 Oesophagus.
- 9 Trachea.
- 33 Left subclavian artery.
- 35 Thoracic duct, preazygos segment.
- 37 Broncho-mediastinal duct.
- 38 Confluence of broncho-mediastinal duct and preazygos segment of thoracic duct.
- 40 Innominate vein.



174



175

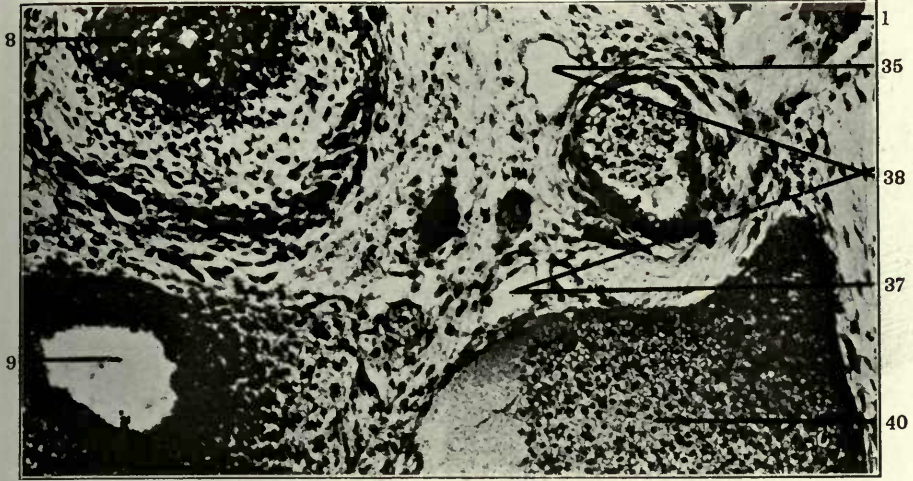


176

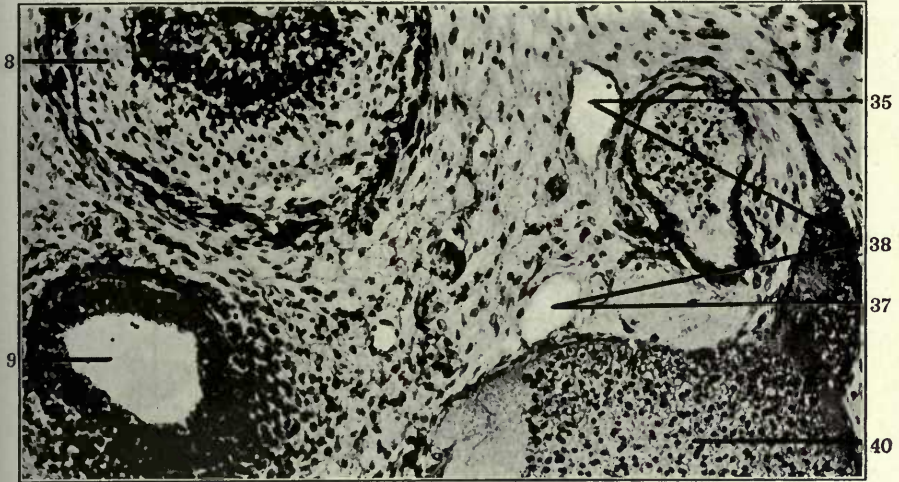FIGURES 177, 178 AND 179

- 177 Same, section 5.
178 Same, section 2.
179 Same, slide IX, section 32.

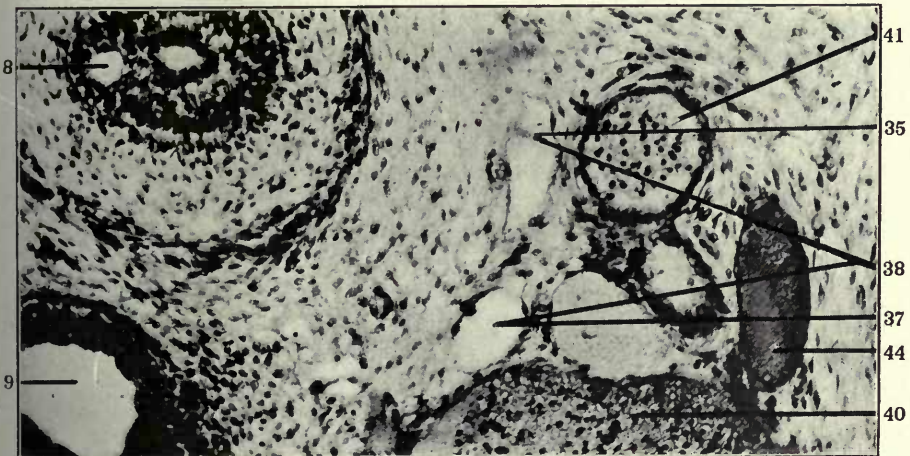
- 1 Sympathetic nerve.
8 Oesophagus.
9 Trachea.
35 Thoracic duct, preazygos segment.
37 Broncho-mediastinal duct.
38 Confluence of broncho-mediastinal duct and preazygos segment of thoracic duct.
40 Innominate vein.
41 Vertebral artery.
44 Costo-cervical vein.



177



178

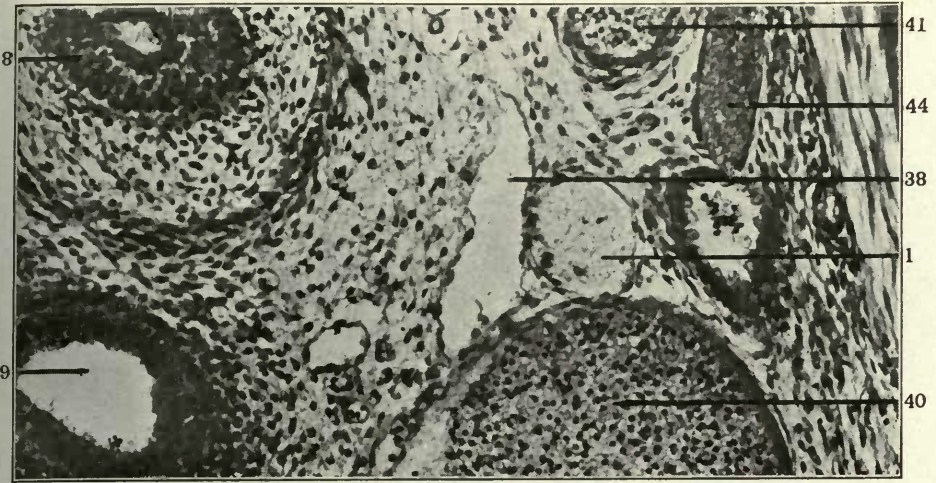


179

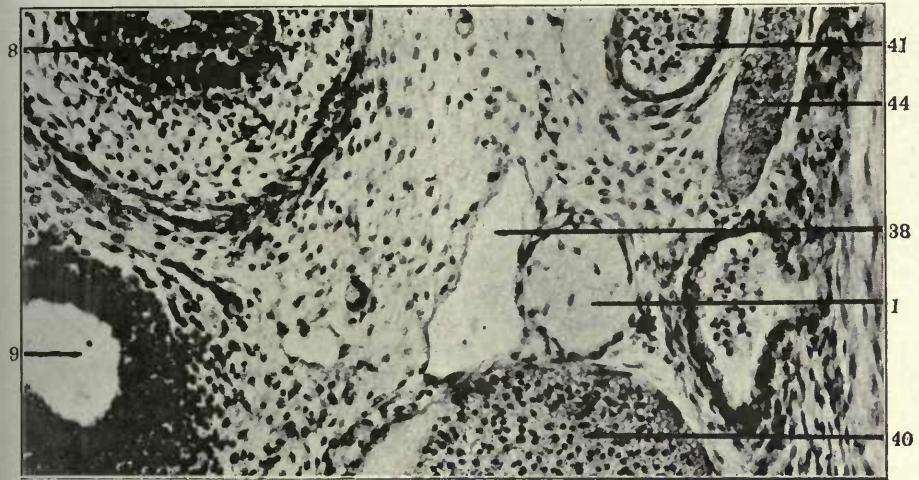
FIGURES 180, 181 AND 182

- 180 Same, slide X, section 28.
- 181 Same, slide X, section 26.
- 182 Same, slide X, section 23.

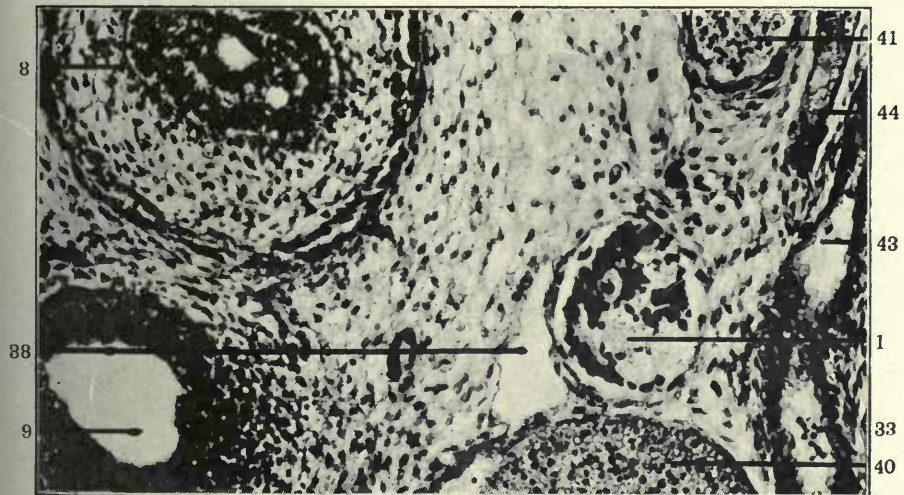
- 1 Sympathetic nerve.
- 8 Oesophagus.
- 9 Trachea.
- 33 Left subclavian artery.
- 38 Confluence of broncho-mediastinal duct and preazygos segment of thoracic duct.
- 40 Innominate vein.
- 41 Vertebral artery.
- 43 Costo-cervical artery.
- 44 Costo-cervical vein.



180



181

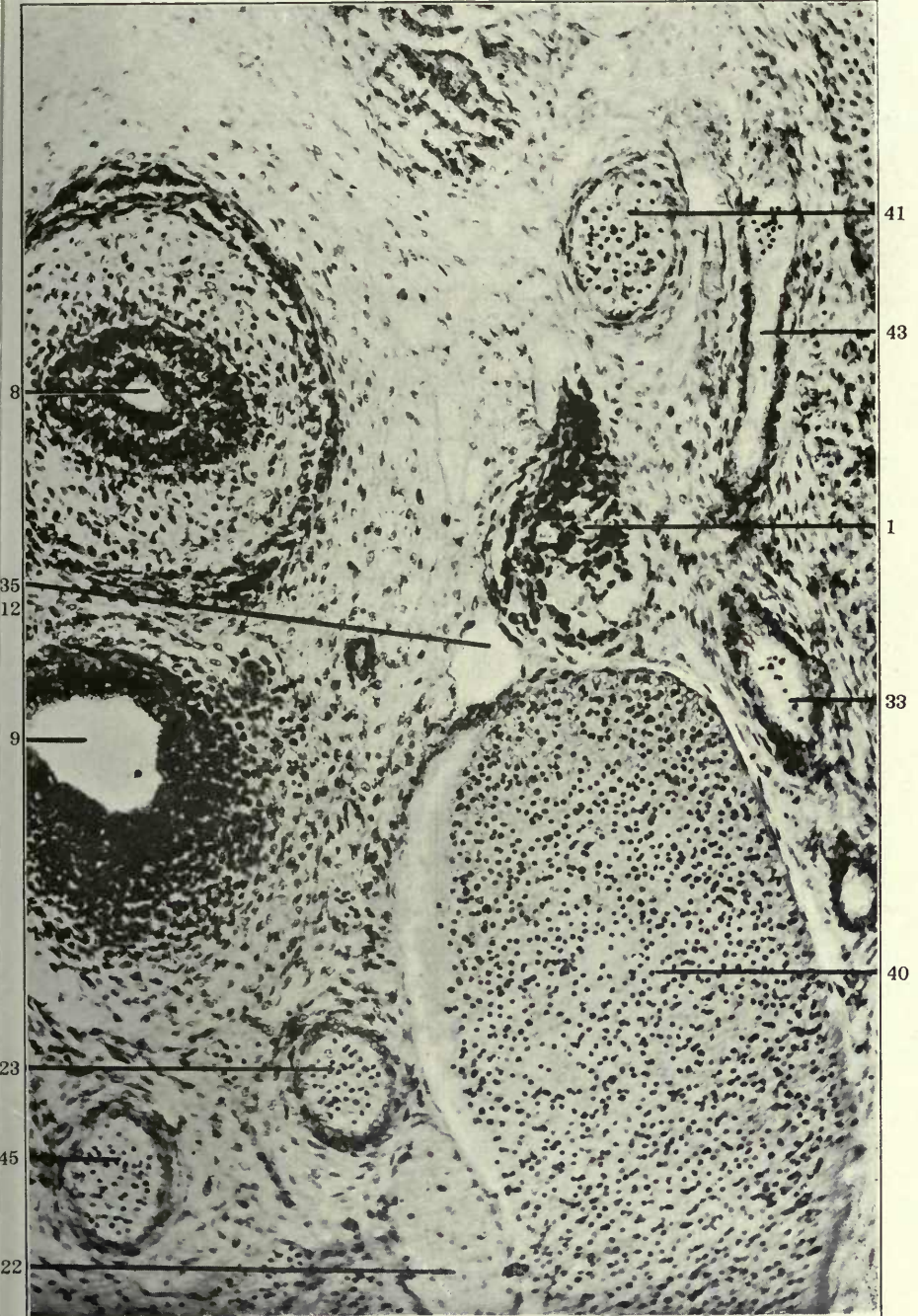


182

FIGURE 183

183 Same, slide X, section 22.

- 1 Sympathetic nerve.
- 8 Oesophagus.
- 9 Trachea.
- 12 Jugular lymph sac, thoracic duct approach.
- 22 Vagus.
- 23 Left carotid artery.
- 33 Left subclavian artery.
- 35 Thoracic duct, preazygos segment.
- 40 Innominate vein.
- 41 Vertebral artery.
- 43 Costo-cervical artery.
- 45 Innominate artery.

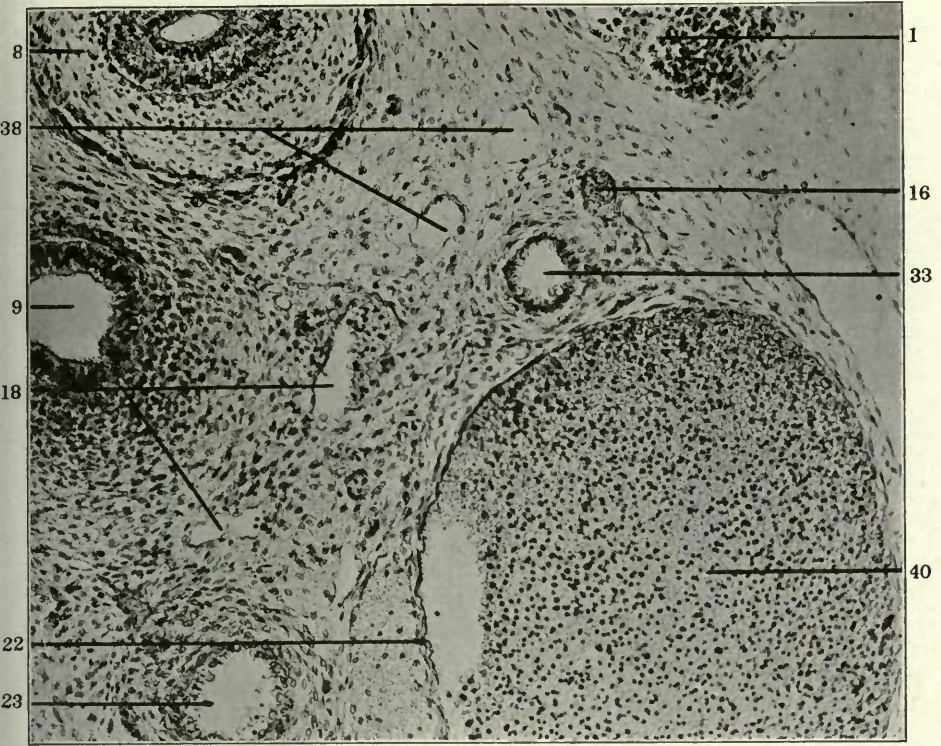


FIGURES 184 AND 185

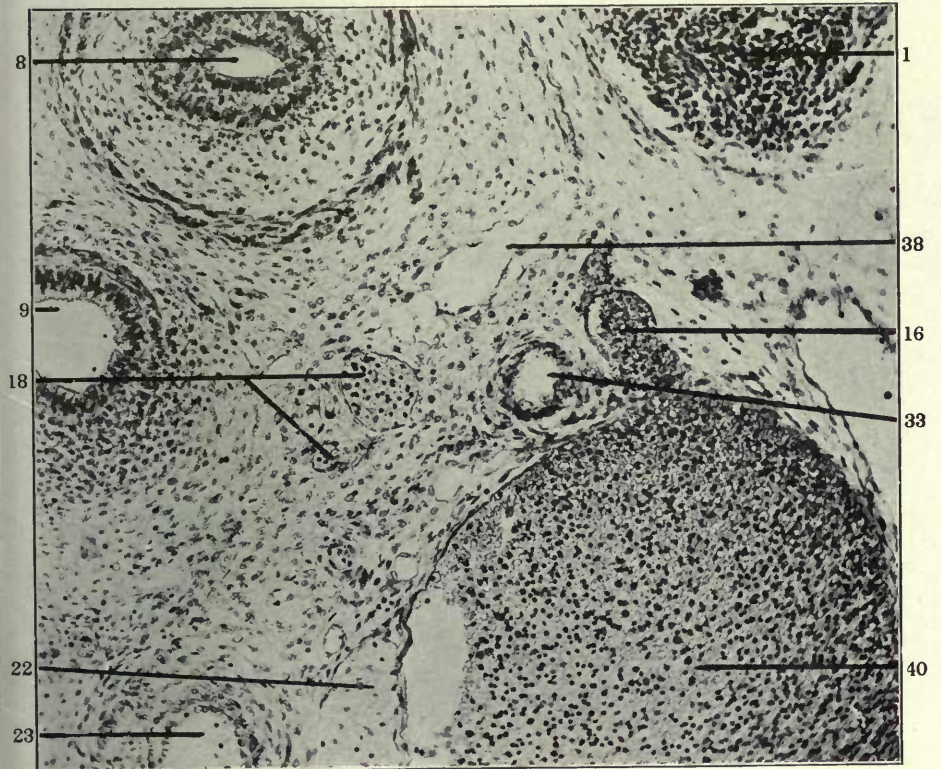
184 Transverse section through upper part of left thoracic region in a 15.5 mm. cat embryo, (series 141, slide X, section 18), $\times 200$.

185 Same, section 21.

- 1 Sympathetic nerve.
- 8 Oesophagus.
- 9 Trachea.
- 16 Dorso-medial somatic venous tributaries.
- 18 Peritracheal venous plexus.
- 22 Vagus.
- 23 Left carotid artery.
- 33 Left subclavian artery.
- 38 Confluence of broncho-mediastinal duct and preazygos segment of thoracic duct.
- 40 Innominate vein.



184



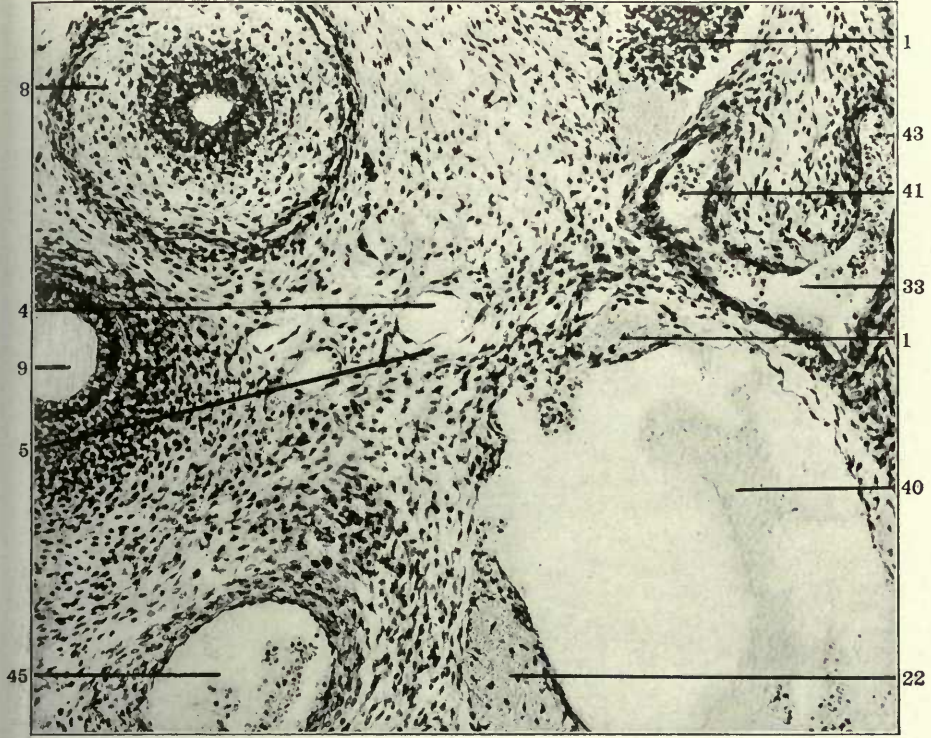
185

FIGURES 186 AND 187

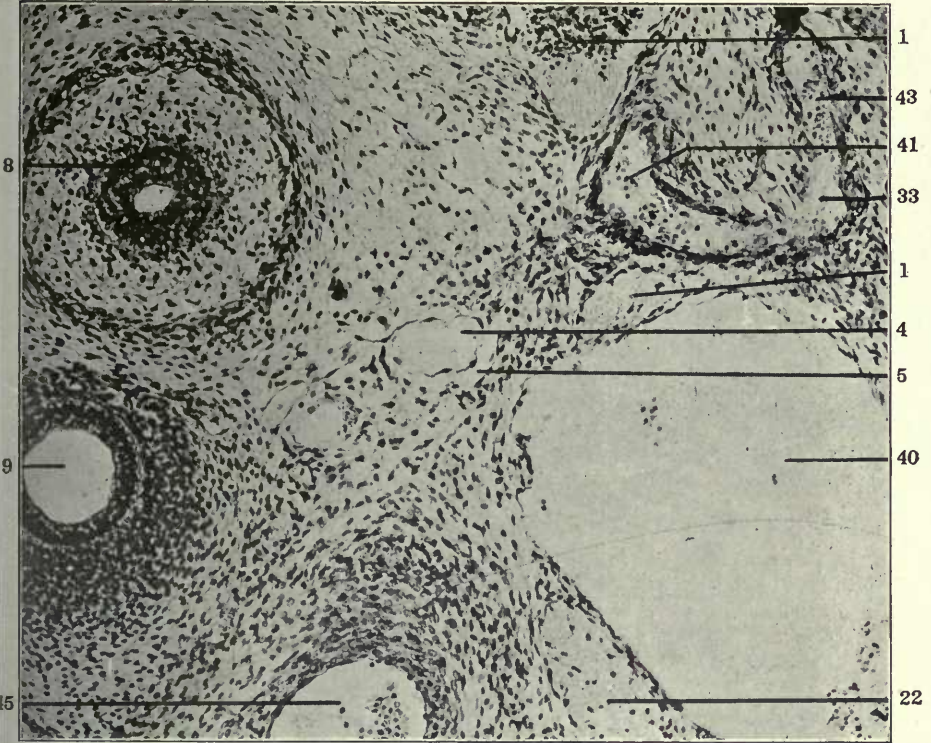
186 Transverse section of left upper thoracic region in a 13.5 mm. cat embryo, (series 223, slide VIII, section 39), \times 225.

187 Same, section 40.

- 1 Sympathetic nerve.
- 4 Atrophying embryonal vein, forming kernel in interior of developing and replacing lymphatic space.
- 5 Extraintimal or perivenous lymphatic space surrounding degenerating embryonal vein.
- 8 Oesophagus.
- 9 Trachea.
- 22 Vagus.
- 33 Left subclavian artery.
- 40 Innominate vein.
- 41 Vertebral artery.
- 43 Costo-cervical artery.
- 45 Innominate artery.



186



187

3. THE AZYGOS SEGMENT OF THE THORACIC DUCT

This main part of the thoracic duct develops by the confluence of extraintimal lymphatic anlagen which begin to appear in the 12 mm. embryo, are clearly marked in the 13 and 13.5 mm. embryo, increase in the 14 mm. stage, become confluent to form larger segments in the 15 and 15.5 mm. embryos, and finally unite into the plexiform and nearly continuous channels of the thoracic ducts in the 16 mm. stage. These extraintimal lymphatic anlagen develop at first along and around portions of the detached and degenerating veins of the ventro-medial tributary plexus of the azygos veins at some distance from the latter. Subsequently they extend dorsad along these decadent venules and then come to lie in close apposition to the ventral aspect of the main azygos trunks and the terminals of the ventral branches. They are from the beginning genetically distinct and independent of the same.

In the earlier and purely venous stages the azygos veins receive, in addition to the terminals of the extensive supracardinal plexus, which unites the veins of the two sides dorsal to the aorta, larger dorsal somatic tributaries from the body walls and from the interior of the vertebral canal, and smaller ventro-medial branches which drain the periaortic space close to the wall of the main arterial vessel. When these ventral azygos tributaries appear they occupy in general the position described as characteristic for the cardinal collateral plexus of the Marsupialia (McClure.³⁰).

The ventro-medial azygos tributary plexus, which furnishes the venous line along and around which the first extra-intimal anlagen of the azygos segment of the thoracic ducts develop, begins to appear with the first differentiation of the supracardinal plexus. The recognition of its course and extent, and of the subsequent changes in which it is involved, is of the greatest importance to the correct interpretation of the placental thoracic duct development. The plexus, and the subsequently more defined ventro-medial tributary vein, parallel to the main azygos trunks in the caudal part of the area involved, will be frequently referred to in the following pages.

McClure¹⁵ was the first investigator who definitely recognized

and reconstructed this embryonal venous pathway. While, as previously stated, I differ from the conclusions which he drew in regard to the ontogenesis of the thoracic ducts in the publication quoted, I desire to emphasize the fact that he for the first time clearly defined the para-azygos venous line, which, in my opinion, furnishes the pathway for the subsequent extra intimal development of the azygos segments of the thoracic ducts.

He interpreted the thoracic duct in embryos of the domestic cat as a direct caudal prolongation of the jugular lymph sac, developed in the same manner as the latter, through fusion of multiple venous derivatives of the para-azygos venous line above defined.

His recent work on the development of the systemic lymphatic vessels in the cat, presented before the Second International Anatomical Congress in Brussels, August 7th to 11th, 1910, and published in the Proceedings of the Congress,³⁹ is a revision of the previous publication above quoted,¹⁵ and a return, as regards the genesis of the thoracic ducts, to the original view which we advanced for all systemic lymphatic development in the embryo of the cat in our first joint publication on the subject in 1906.²¹

The extraintimal lymphatic anlagen of the ducts form along and around the venules composing the ventromedial tributary plexus of the azygos veins, and finally replace them, while in the same way the anterior part of the mesenteric lymphatic net work has its origin in the extraintimal lymphatic spaces which form around the caudal continuation of the ventral plexus, lateral and ventral to the aorta, in the root of the primitive dorsal mesogastrium.

It is necessary to exercise great care in the critical stages in order to correctly distinguish between the degenerating vessels of the plexus and the extraintimal lymphatic anlagen replacing them, and to compare results obtained from a number of embryos of

³⁹ C. F. W. McClure: The Extra-intimal Theory and the Development of the Mesenteric Lymphatics in the Domestic Cat (*Felis domestica*), 6 figs. *Anat. Anz., Ergänzungsh. z.* 37. Bd., *Verh. Anat. Ges.*, 24. Vers., Brüssel, 1910, S. 101-110.

the same stage. If this is done there can remain no doubt that the two thoracic ducts in the embryos of the cat develop by confluence of extraintimal perivenous lymphatic spaces. These anlagen appear at first as isolated spaces, either surrounding the retreating veins or closely applied to part of their circumference and subsequently to the ventral wall of the main azygos trunks, usually lateral to the points where the ventral plexus connected with the main azygos channel.

A General Analysis of the Development of the Thoracic Duct in the Azygos Region

The clearest preliminary survey of the development of the azygos segment of the cat's thoracic ducts can be obtained by comparing the series of reconstructions shown in figs. 188 to 193, all representing the structures in the ventral view and in a magnification of 225 diameters. The individual sections of these embryos will presently be described and figured in detail and will be referred to the reconstruction, but a general consideration of the six figures will, at this point, help to make the genesis of the azygos segment of the thoracic ducts clear.

The earliest stage is a 13.5 mm. embryo (series 76), shown in fig. 188. The reconstruction includes the azygos-Cuvierian junction of each side, the right (3) and left (6) azygos veins and their interazygos supraaortic anastomosis, and extends caudad to the lower azygos region.

The intercostal arteries (red) and the sympathetic nerves (1) are shown. The numerous extraintimal anlagen of the thoracic ducts (green) incrust the ventral aspect of the azygos veins and of their anastomotic plexus. In the caudal half of the preparation these lymphatic anlagen follow fairly symmetrically the main azygos trunks. On the right side they are still very numerous and separated from each other, while the corresponding spaces on the left side have already become confluent to form larger, although still discontinuous, segments of the future lymphatic channel.

At the level marked *C* in the figure the line of the lymphatic anlagen following the right azygos trunk divides. A part continues

the original direction, following the ventral surface of the right azygos. These anlagen will later become confluent to form the intra-thoracic portion of the right lymphatic duct (cf. 47 in fig. 193).

Another set of these perivenous lymphatic spaces diverges from the preceding at the level *C* and swings sinistro-cephalad, lying in contact with the ventral surface of the interazygos anastomotic plexus and of the intersegmental arteries.

The elements composing this series in the majority of embryos of this period, (13.5 —14 mm.), have already become confluent to form segments of considerable length, and offer very clear pictures of their extraintimal perivenous development, surrounding radicles of the ventromedial azygos plexus. Thus figs. 206 to 213 show transverse sections of this embryo in the area indicated on the figure of the reconstruction between the lines AA and BB. The sections of the lymphatic anlage lying ventral to the right intersegmental artery in this region show the central decadent venule and the enveloping extraintimal lymphatic space almost diagrammatically.

Fig. 189 is taken from a similar reconstruction of a 14 mm. cat embryo (series 34 of the Princeton collection).

The right (*3'*) and left (*6'*) azygos veins arch ventrad to their point of confluence with the respective precavae (*3*, *6*).

The interazygos anastomosis forms a dense closely woven supra-aortic plexus, perforated by the intersegmental arteries. In general the lymphatic development has not quite reached the stage represented by the preceding series (76), especially along the main right and left azygos trunks, where the anlagen are still relatively few and of small extent. On the other hand, the lymphatic line which in series 76 (fig. 188) is seen to swing mesad to the ventral surface of the interazygos anastomosis at the level of *C* and thence continues to ascend sinistro-cephalad, is already well developed in series 34 (fig. 189). The level *C* of the preceding figure (188) corresponds in fig. 189 to the upper of the two lines *A-B*. Cephalad of this level a well defined chain of lymphatic anlagen extends, diverging to the left from the main right azygos line, along the ventral aspect of the interazygos

plexus, between and in front of the series of right intersegmental arteries. As above stated, the earliest and best defined anlagen of the azygos segment of the thoracic ducts are usually found in this region in the 14 mm. stage. In this particular embryo (series 34) the process of replacement of the radicles of the earlier ventro-medial azygos plexus by the extraintimal lymphatic spaces has just begun, and the sections show the relation between the atrophying venous core and the enveloping perivenous lymphatic anlage clearly.

Figs. 244 to 251 show sections in the area marked A-B in the reconstruction and afford definite pictures of this relationship.

Another early character well exhibited by this embryo is the full development of the ventro-medial azygos tributary plexus in the caudal portion of the right side. A distinct plexiform venous ridge (34) courses along the ventro-medial border of the right azygos vein, with which it communicates at frequent intervals. In the series under discussion it is just beginning to undergo regression and replacement by perivenous lymphatic anlagen at a few points. In the subsequent stages it becomes detached from the main right azygos channel and forms the framework upon and around which the large caudal element of the thoracic duct forms on the right side. A similar plexiform ridge follows the left azygos, but is usually less well pronounced. These lines of para-azygos venous reticulum, preceding the actual development of the extraintimal thoracic ducts, are the ones which McClure followed and described in the paper on thoracic duct development above quoted (15).

Fig. 190, showing the reconstruction of another 14 mm. embryo (series 214), offers an interesting comparison with the two preceding preparations. The embryo is characterized by advanced development of the segment of the thoracic duct which diverges at the level *C* in fig. 188 from the right azygos line to turn up and to the left in front of the interazygos network. The path of this segment of the future thoracic duct is outlined in the two preceding preparations, series 76 and 34, by a line of detached and still isolated lymphatic spaces. In series 214 these spaces have, to a large extent, united into a longer continuous segment of the lym-

phatic channel, extending cephalad of the line *C* in fig. 190 along the ventral aspect of the right intersegmental arteries and of the interazygos plexus. It covers the cephalic part of the right ventro-medial para-azygos venous ridge (34), the remnants of which, detached from the main vein, are to be seen on section occupying the interior of the perivenous extraintimal lymphatic channel which is replacing them (Compare figs. 214 to 240, showing sections from slides xiv and xv of series 214). A part of the ridge (34) extends caudad of line *C* in fig. 190, but the process of its replacement by lymphatic spaces has proceeded much further than in series 34 (fig. 189).

Fig. 191 shows the ventral view of the reconstruction of the same region in a 15 mm. embryo (series 219). In comparison with the 13.5 and 14 mm. stages this embryo shows more uniform and in general more advanced development in all regions of the thoracic duct anlage. The individual and separate lymphatic anlages seen in series 76 and 34 (figs. 188 and 189) have become confluent to form longer and better defined lymphatic channel segments. These have arranged themselves in two groups. Caudad of the point marked *C* in fig. 191 they follow pretty symmetrically the ventro-medial margin of the left and right azygos trunks, occupying here the site of the earlier ventro-medial azygos tributary plexus which they have in part secondarily replaced. The segments are relatively long, especially on the left side. Cephalad of the level marked *C* the lymphatic spaces of the left side follow the left azygos trunk, becoming gradually smaller and more disconnected. On the right side they divide at *C* into two lines. One of these continues upward along the right azygos trunk and arch. The other and larger turns cephalo-mesad, and is prolonged upward and to the left, in front of the right intercostal arteries and the interazygos anastomosis. Caudad of the level *C* we have, therefore, two lines of lymphatic anlages, following the right and left azygos trunks, while cephalad of this level we encounter three, the right, left and intermediate. The former, diverging from the other two in ascending to right, marks the path of the future right lymphatic duct. The two caudal parallel lymphatic lines below *C* and the central and left lines cephalad of this point become subse-

quently connected by a close plexiform anastomosis and together form the azygos segment of the thoracic duct. (cf. fig. 193).

Fig. 192 shows the ventral view of the central azygos region in a 15.5 mm. embryo, series 143.

The same plan of para-azygos lymphatic development, with two lines caudad and three cephalad of the level *C*, is presented as in the preceding series. The right and left lines are composed of relatively long links of lymphatic channel segments. The intermediate line above *C* is, in the part shown in the reconstruction, not quite as far advanced as in the preceding series 219, or in the 14 mm. embryo (series 214, fig. 190). The latter, in fact, presents an unusually advanced condition of this channel, and illustrates the fact that in comparing different embryos of about the same age lymphatic organization may, in certain regions, be either ahead or behind the average level usually attained at the period in question. This is especially true in the earlier lymphatic stages, in embryos between 13 and 15 mm. crown-rump measure.

Embryo 143 (fig. 192) shows, for example, in comparison with series 214 (fig. 190) less advanced development of the intermediate thoracic duct line above the level *C*. Correspondingly, the ventro-medial venous ridge (*34*) of the right azygos trunk, upon and around which these lymphatic spaces develop and which the resulting lymphatic channel eventually replaces, is still distinctly evident in the former (fig. 192), whereas in the latter (fig. 190) all but its caudal portion is hidden by the enveloping lymphatic trunk.

Fig. 192 also shows, in the area of slide xvii, parts of the ventral azygos plexus surrounding the lateral and ventral circumference of the abdominal aorta, and the extraintimal lymphatic spaces forming along them and draining into the right thoracic duct channel.

Finally the 16 mm. embryo (fig. 193, series 96) usually marks the developmental stage in which the hitherto isolated and disconnected lymphatic segments have united with each other into the continuous channel of the azygos portion of the thoracic and right lymphatic ducts.

The latter (47) is seen in the cephalic part of the reconstruction along the lateral border of the right azygos vein. The former shows a caudal enlarged and fairly symmetrical segment, caudad of line A B, in which the right and left thoracic ducts, connected by several broad transverse anastomoses, follow the ventro-medial aspect of the right and left azygos veins.

The latter in this region have secondarily assumed the supra-cardinal position, by developing, as the main channels, out of the preceding interazygos plexus. They hence lie *dorsal* to the lower intersegmental arteries. A remnant of the former (post-cardinal) azygos trunks, *ventral* to the lower three intercostal arteries, is seen on each side between the thoracic ducts and the sympathetic nerves (1), as a slender longitudinal venous channel, connected at numerous points with the main azygos trunks. Above the level of the line A B, the entire and now united and continuous lymphatic channel swings cephalo-sinistrad and ascends on the ventral aspect of the interazygos anastomosis and of the reduced left azygos vein. It represents the further development of the left and intermediate lines of azygos lymphatic organization of the earlier stages. Each of these lines is represented now by a continuous marginal lymphatic channel, lateral to or perforated by the intersegmental arteries, and interlacing in a multiple plexiform anastomosis with its fellow of the opposite side.

The mesenteric lymphatics of the dorsal mesogastrium (51) are beginning to establish their connections with this now completed main axial lymphatic trunk. Further development of the same is in the direction of more definite condensation of the lymphatic plexus and relative reduction of the lumen, as seen in the adult preparations previously figured and described (cf. figs. 95 to 99), p. 79.

PART II, PLATES

FIGURES 188 TO 193

FIGURE 188

188 Reconstruction of cephalic portions of azygos veins and anlagen of azygos segment of thoracic ducts in a 13.5 mm. cat embryo, (series 76, slide X, sections 1 to 27; slide XI, sections 1 to 38; slide XII, sections 1 to 40; slide XIII, sections 1 to 33; slide XIV, sections 1 to 7), $\times 225$. Ventral view.

- 1 Sympathetic nerve.
- 3 Right azygos vein, thoracic portion.
- 6 Left azygos vein, thoracic portion.

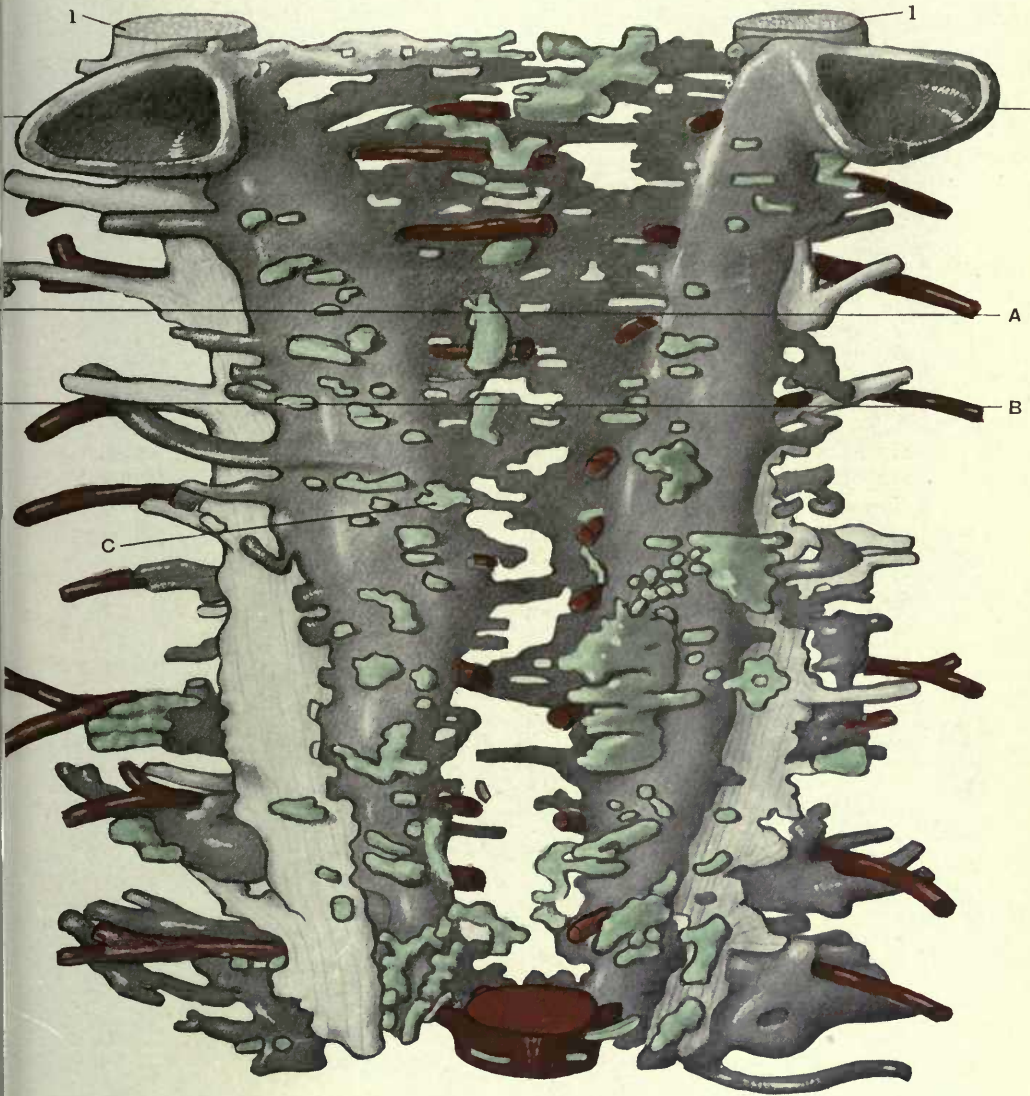


FIGURE 189

189 Reconstruction of cephalic portions of azygos veins and anlagen of azygos segment of thoracic ducts in a 14 mm. cat embryo; series 34 (Princeton Embryological Collection), slides XXIV to XXXII, 222 sections, $\times 225$. Ventral view.

- 1 Sympathetic nerve.
- 3 Right precava.
- 3' Right azygos vein, thoracic portion.
- 6 Left precava.
- 6' Left azygos vein, thoracic portion.
- 34 Vento-medial azygos plexus.

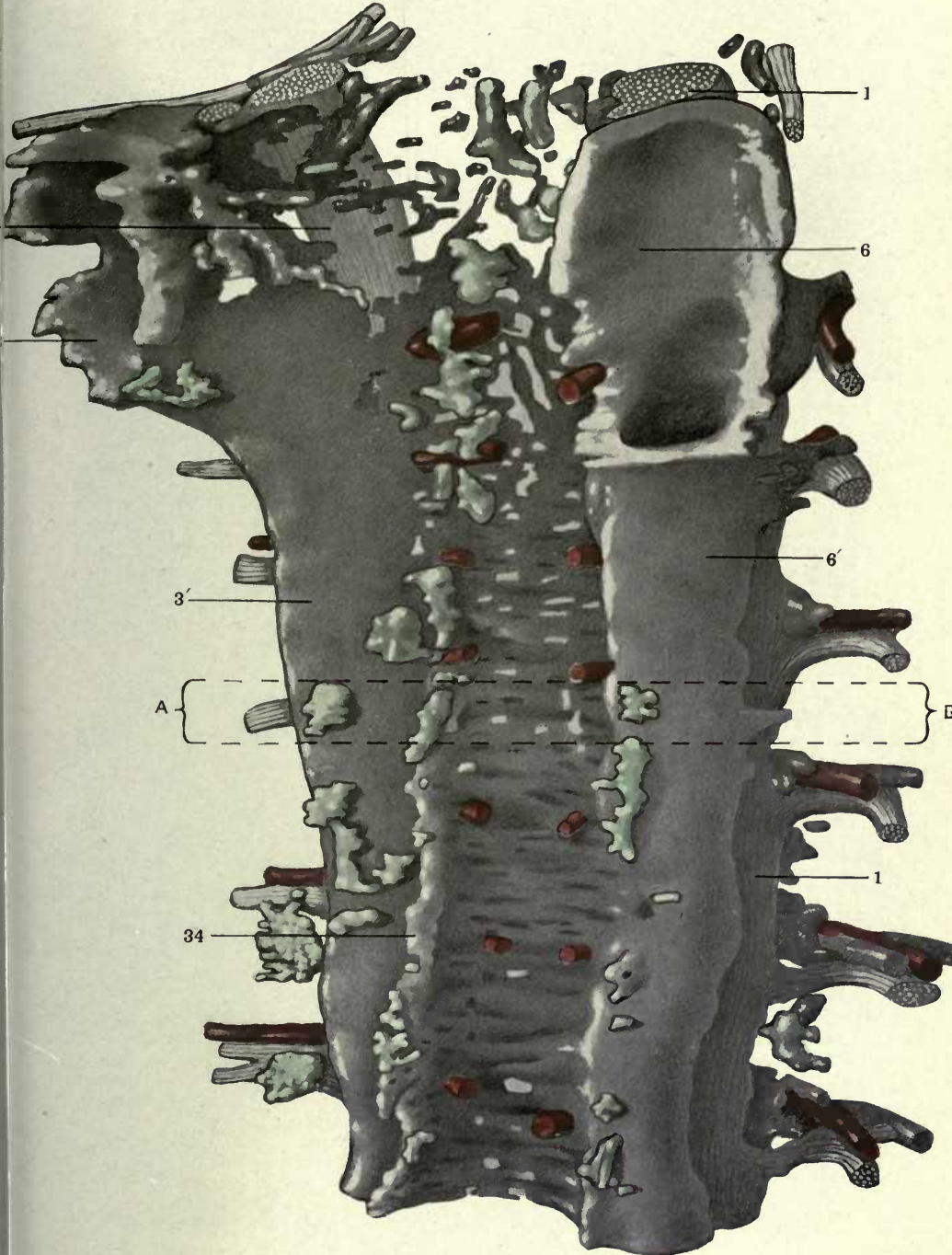


FIGURE 190

190 Reconstruction of cephalic portion of azygos veins and anlagen of azygos segment of thoracic ducts in a 14 mm. cat embryo; (series 214, slides XIII, XIV, XV, XVI and XVII), $\times 225$. Ventral view.

- 1 Sympathetic nerve.
- 3 Precardinal or precava of right side.
- 3' Right azygos vein, thoracic portion.
- 6 Precardinal or precava of left side.
- 6' Left azygos vein thoracic portion.
- 34 Ventro medial azygos plexus.

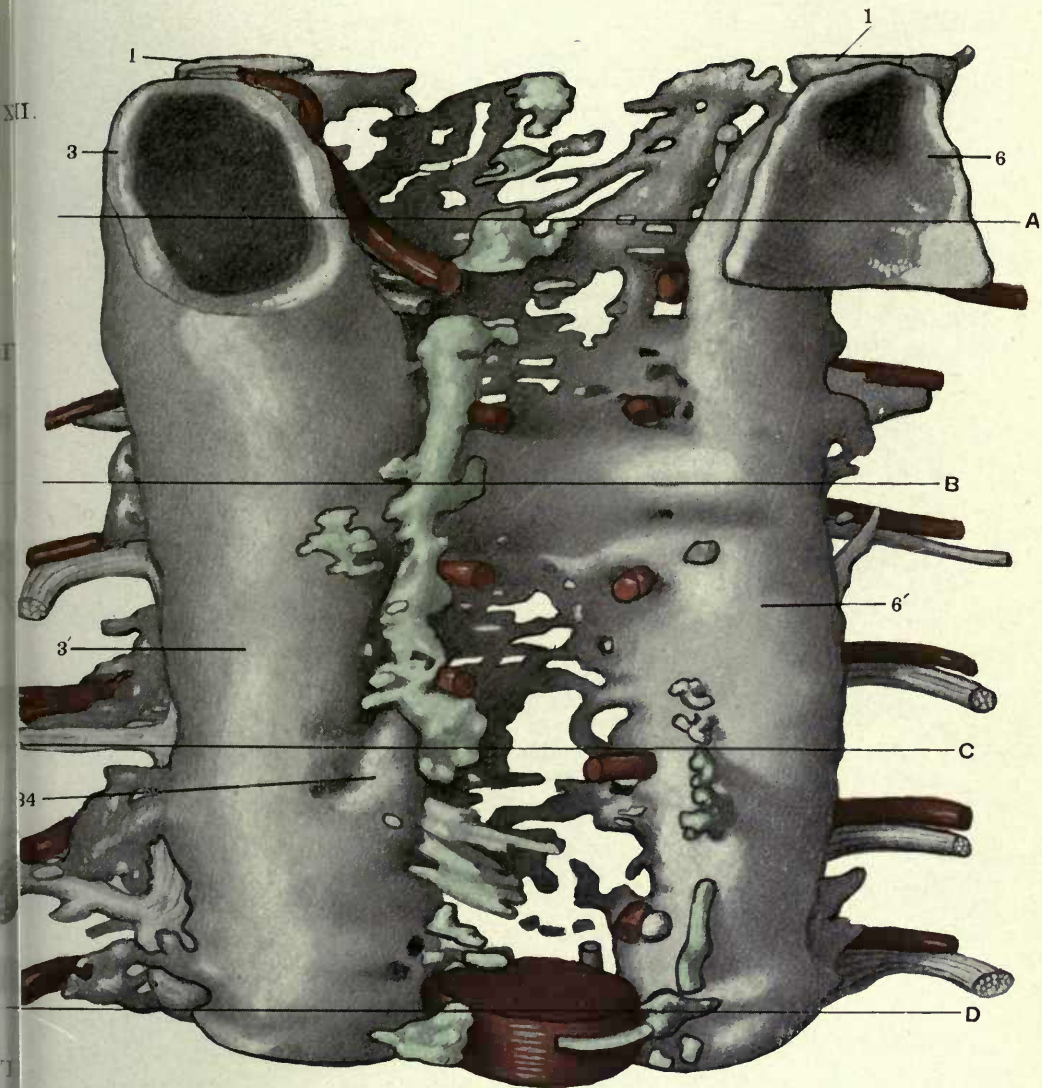


FIGURE 191

191 Reconstruction of cephalic portions of azygos veins and anlagen of azygos segment of thoracic ducts in a 15 mm. cat embryo; (series 219, slides XIV, XV, XVI and XVII), $\times 225$. Ventral view.

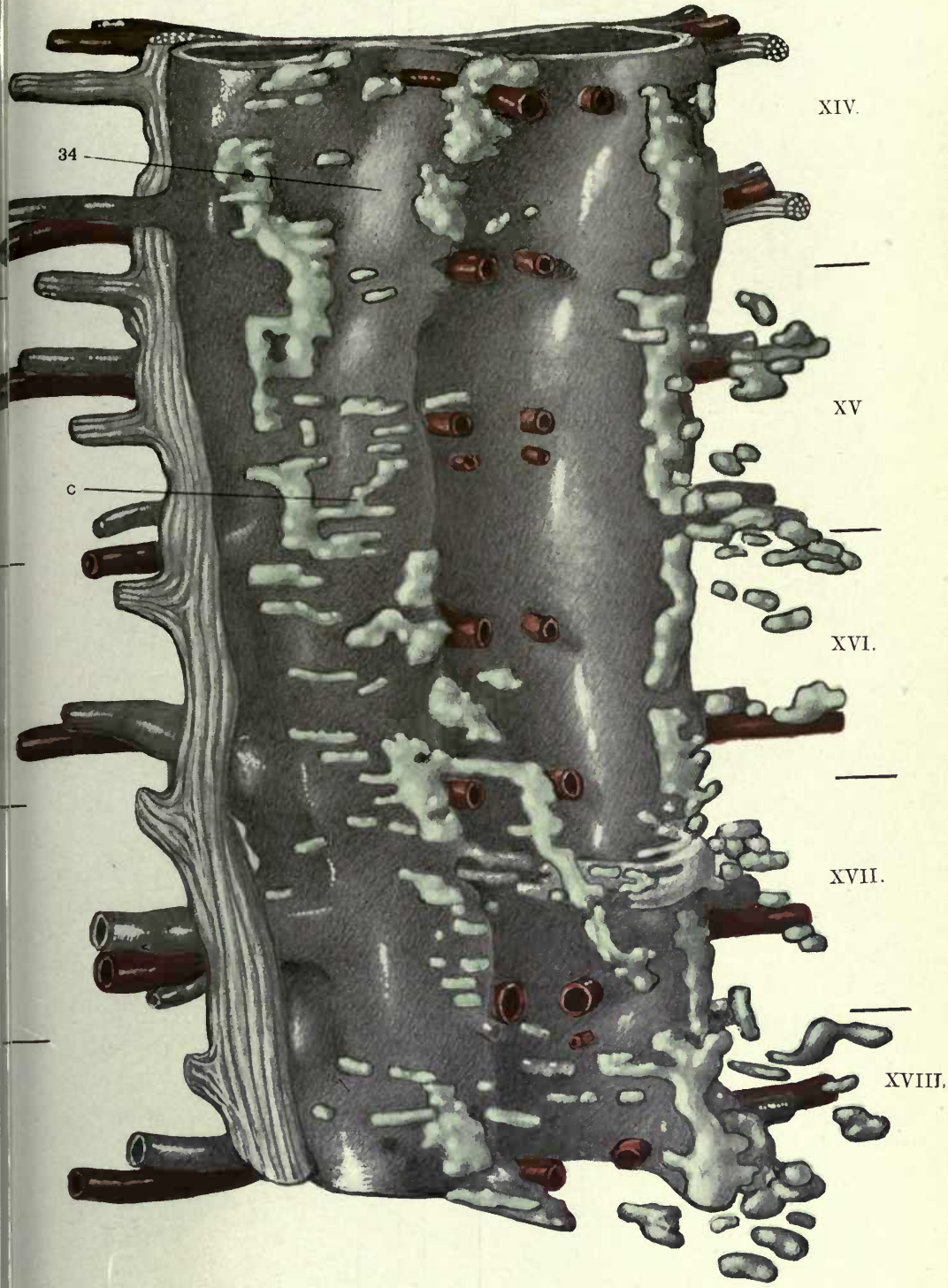
1 Sympathetic nerve.

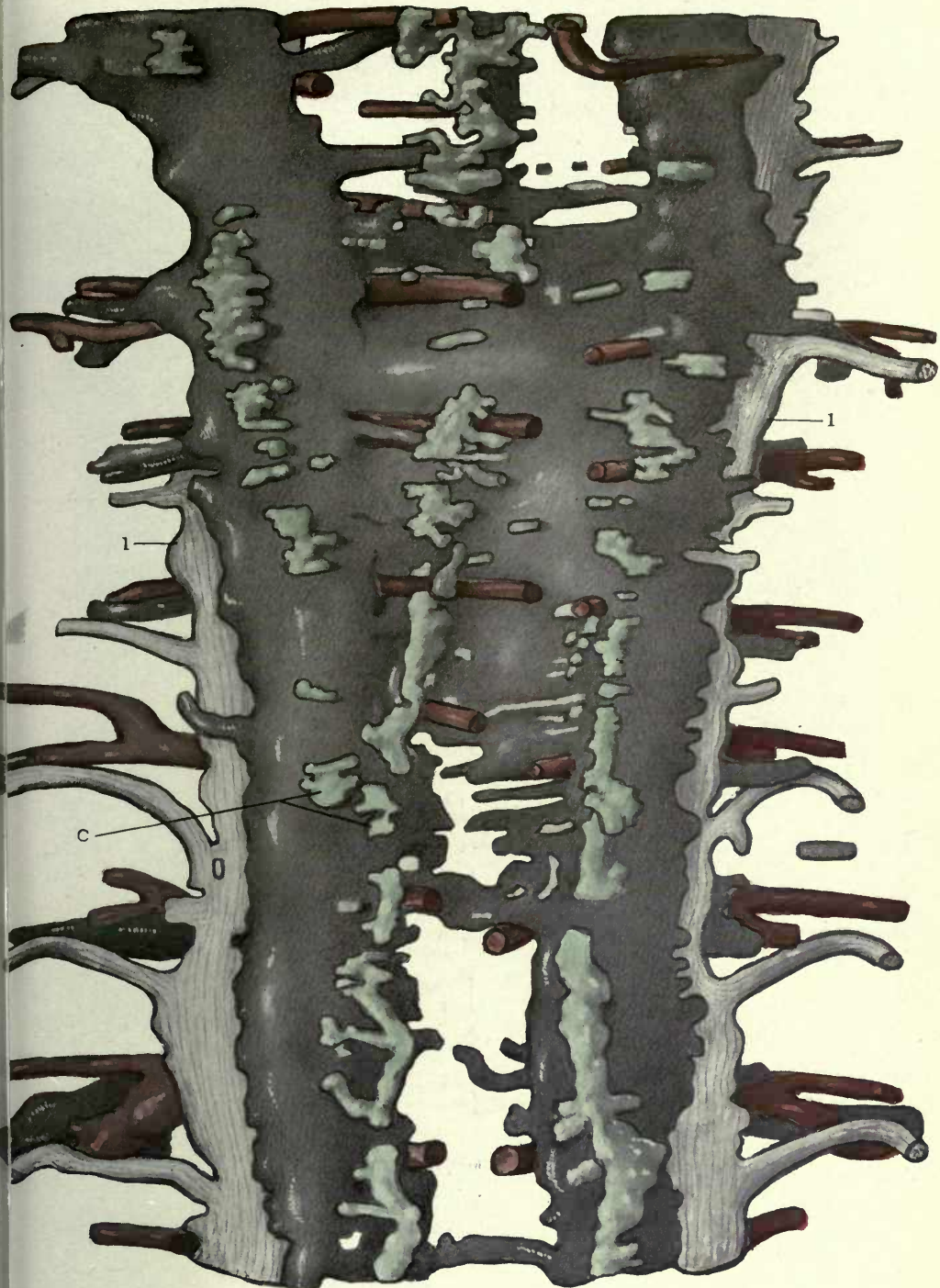

FIGURE 192

192 Reconstruction of cephalic portions of azygos veins and anlagen of azygos segment of thoracic ducts in a 15.5 mm. cat embryo; (series 143, slides XIV, XV, XVI, XVII and XVIII) \times 225. Ventral view.

34 Ventro-medial azygos plexus.



34

c

XIV.

XV

XVI.

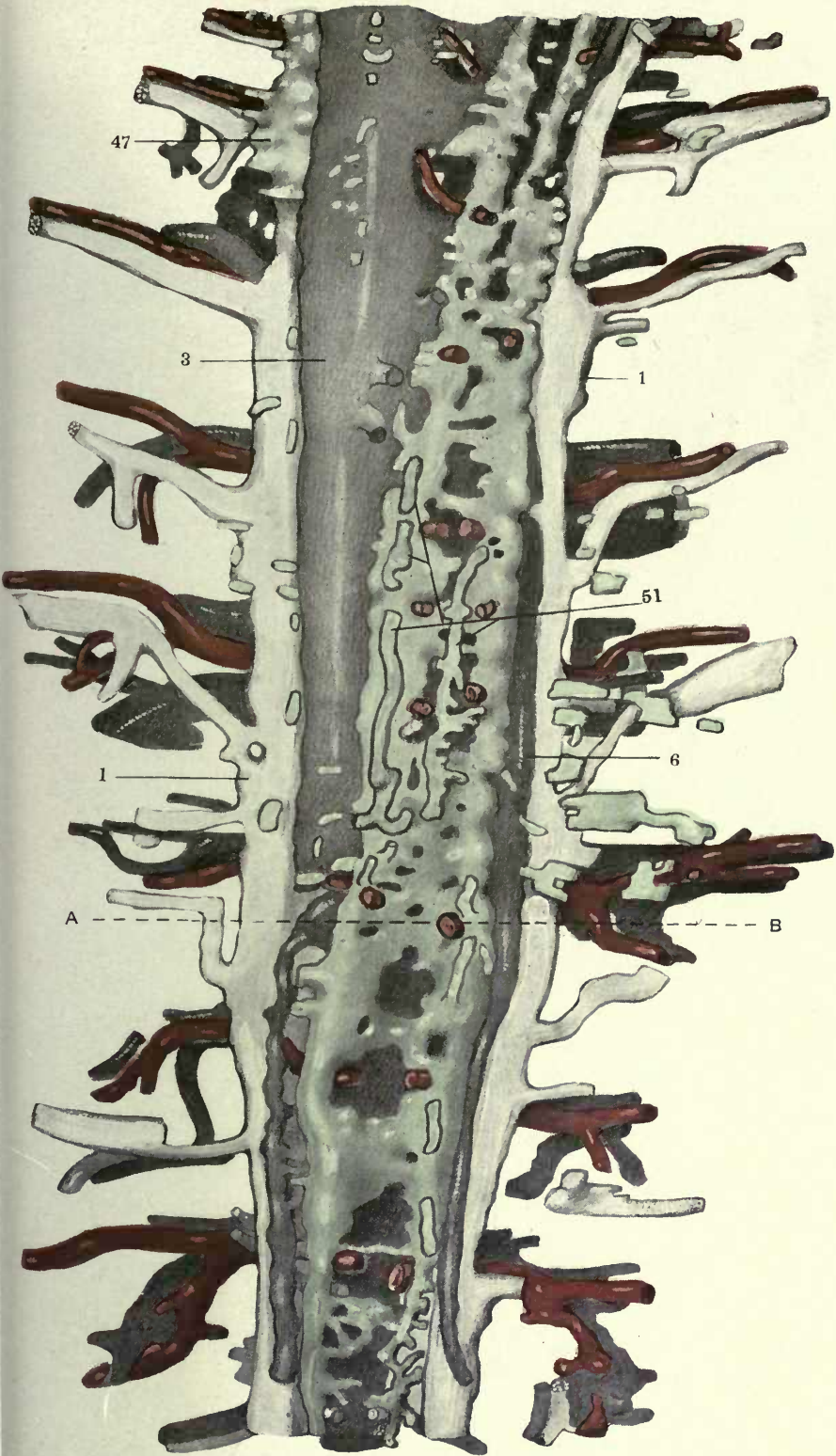
XVII.

XVIII.

FIGURE 193

193 Reconstruction of azygos veins and of thoracic and right lymphatic ducts in a 16 mm cat embryo; (series 96, slides VII to XVI) \times 225. Ventral view.

- 1 Sympathetic nerve.
- 3 Right azygos vein, thoracic portion.
- 6 Left azygos vein, thoracic portion.
- 47 Right lymphatic duct.
- 51 Mesenteric lymphatics.



B. Detailed consideration of the individual stages in the development of the azygos segment of the thoracic duct

Figs. 194 and 195 show transverse sections of the middle thoracic region in an 11 mm. cat embryo (series 213, slide xi, sections 9 and 10, $\times 225$.) The right and left azygos veins (3, 6) lie ventral to the sympathetic nerves (1) on each side of the aorta (7). Between the latter and the right azygos vein are seen portions of the ventro-medial azygos plexus (34).

Figs. 196 and 197 show transverse sections of the same region of this embryo further caudad at the level of a pair of dorsal intersegmental arteries (2) (series 213, slide xi, sections 27 and 29, $\times 225$). The main azygos veins (3, 6) are reduced in comparison with the previous sections, while, on the other hand, the radicles of the ventro-medial azygos plexus (34) are increased in number and size. This is especially so on the right side, in the space between sympathetic nerve (1) and intersegmental artery (2) dorsad, aorta (7) mesad, and main azygos trunk (3) laterad. In the later stages (14 mm.) this is the site of the earliest and most distinct extraintimal replacement of the venous plexus by the lymphatic anlagen of the right thoracic duct (cf. figs. 214 to 251).

The full development of the ventro-medial azygos plexus is seen in the 12 mm. stage. Figs. 198, 199 and 200 show three successive transverse sections of a 12 mm. embryo (series 217, slide x, section 27, 28 and 29, $\times 225$) at the level of origin of a pair of dorsal intersegmental arteries (2). Ventrad of these and of the sympathetic strand (1), in the interval between the main azygos trunks (3, 6) and the aorta (7) are numerous radicles of the plexus (34). The same has developed into a more extensive reticulum, compared with the preceding stage, and now occupies the typical ventro-medial position in relation to the parent azygos trunks. Figs. 201, 202 and 203 show three sections of the same embryo further cephalad (series 217, slide x, sections 18, 30 and 31). They are of interest because they illustrate the condition of part of the plexus just prior to its replacement by the extraintimal anlagen of the thoracic ducts. Some of the components of the plexus, occupying the site of the future lymphatic channel, begin

to lose their connection with the azygos trunks, and appear as partially detached venous elements closely applied to the ventro-medial wall of the main vein.

Thus the ventro-medial tributary 34 in fig. 202, (slide x, section 30), still in open communication with the main right azygos vein (3), is seen in the next section (fig. 201, slide x, section 31) to be separated from the same, and can be followed for a considerable distance caudad, closely applied to the ventro-medial aspect of the parent trunk, but no longer opening into the same or connected with adjacent elements of the azygos plexus. A venule of this type will, in the succeeding stages, form the line along and around which the extraintimal anlagen of the thoracic duct will develop.

Two successive transverse sections of the central thoracic region in a 13.5 mm. embryo (series 189, slide x, sections 15 and 16, $\times 225$) are shown in figs. 198 and 199. The ventro-medial azygos venous plexus (34) is still prominent, especially on the right side, between right azygos vein (3) and aorta (7). Some of its ventral and lateral components (4) are, however, detached from the main plexus and are beginning to be surrounded by the early extraintimal anlagen of the thoracic duct (5).

In another embryo of this period (series 76), extraintimal lymphatic development in the azygos region is further advanced than is usually the case in the 13.5 mm. stage. Figs. 206 to 213 inclusive show transverse sections through the middle thoracic region of this embryo (series 76, slide xi, sections 15, 16, 17, 19, 21, 22, 23, 28, $\times 300$). The microphotographs are to be referred to the ventral view of the reconstruction of slides x, x', xi, xiii, and part of slide xiv, (155 15μ sections) shown in fig. 188 and are included within the area bounded in this figure by the lines A-B. They show especially the development of the prominent extraintimal intermediate segment of the thoracic duct anlage on the ventral aspect of the interazygos plexus and of the fourth intercostal artery of the right side. Fig. 206 (section 15 of slide xi) shows the right azygos vein (3), the aorta (7) and the well developed interazygos plexus (15). A radicle of the latter (4), in the interval between the structures named, is almost completely

surrounded by the extraintimal anlage (5) of the intermediate segment of the azygos portion of the thoracic duct. The extraintimal anlage of the right segment of the duct (not labelled in figure) is seen in this and some of the succeeding sections ventral to the right azygos vein, surrounding an atrophying radicle of the ventro-medial azygos plexus. The two succeeding sections (16 and 17 of slide xi, figs. 207 and 208) show the same extraintimal lymphatic anlage and the enclosed venous radicle in its relation to the right intercostal artery (2 in fig. 208), and it can be followed through the remaining figures (209 to 213) always in the same position, in the interval between the interazygos plexus, the aorta, and the right azygos, and ventral to the right intercostal arteries. In stages slightly less developed than the present embryo the lymphatic anlages of the central thoracic duct division are usually interrupted at the level of the intersegmental arteries, and present in many cases a regular segmental character. Later, as in the present instance, these segmental anlages become confluent across the ventral aspect of the intercostal arteries. The figure of the reconstruction (fig. 188) still shows the earlier segmental arrangement of the duct anlages in the cephalic part, in relation to the first three right intercostal arteries.

In the succeeding stage, 14 mm., the isolated and interrupted lymphatic anlages of the 13.5 mm. stage have usually coalesced to form much longer continuous channel segments.

It is necessary to examine a large number of successive sections in many embryos in order to become convinced of this marked advance in lymphatic development. Thus, for example, the lymphatic anlage of the azygos segment of the thoracic duct just described in certain sections of the preceding 13.5 mm. embryo (series 76, figs. 206 to 213), is found in the identical position and relation to surrounding structures, and much more fully developed in the 14 mm. embryo shown in figs. 214 to 240 inclusive, and in reconstruction in fig. 190.

As a matter of fact every phase in the early extraintimal development of the thoracic duct anlage can be perfectly illustrated by selections from the 72 sections composing slides xiv and xv of this series.

Figs. 214 to 219 inclusive show transverse sections in the central thoracic region in this embryo, (series 214, slide xiv, sections 15, 16, 17, 19, 20, 22, \times 225), in which the extraintimal thoracic duct development and its relation to the atrophying central venule of the ventro-medial azygos plexus is shown at the height of its development. In the interval between aorta, right azygos vein and oesophagus all six sections show the empty and partially collapsed central endothelial tube of the decadent ventro-medial azygos venule (4), surrounded by the extraintimal lymphatic anlage of the thoracic duct (5), about to replace it topographically. The central atrophying venule (4) is here still of large size, although empty and completely separated from the functional azygos venous channels. It, together with the enveloping perivenous extraintimal lymphatic anlage of the thoracic duct (5), forms a conspicuous histological object in the field above defined, between aorta, oesophagus, right azygos vein and interazygos plexus. Figs. 220 to 224 inclusive show transverse sections of the same embryo further caudad on the same slide (series 214, slide XIV, sections 26, 27, 28, 32 and 34, \times 225). The central atrophying venule (4) in the interior of the replacing extraintimal perivenous lymphatic space (5) is undergoing further reduction and diminution in size and extent, until, in fig. 224, it has receded to an insignificant tab of tissue (4) still attached at one point to the interior of the endothelial lining of the lymphatic space (5). The reduced central venous remnant (4) and the surrounding extraintimal lymphatic anlage (5) have shifted in these five sections dorsad until they come into apposition with the ventral aspect of the broad interazygos anastomosis in the interval between the same, the aorta and the oesophagus.

In figs. 225 to 229 inclusive five successive sections from the beginning of the same slide are given (series 214, slide xiv, sections 1, 2, 3, 4, and 5, \times 225). This series corresponds to the one just discussed, from the caudal part of the same slide. The central decadent venule (4) in sections 1 and 2 (figs. 225 and 226) can still be made out in the interior of the perivenous extraintimal lymphatic space (5), but in the succeeding sections 3 and 4 (figs. 227 and 228) the latter alone occupies the field, showing the elimi-

nation of the antecedent venous kernel, and the establishment of a lymphatic channel with clear and empty lumen. In the following section, 5, (fig. 229) the lymphatic channel ends blindly in the mesoderm, indicating one of the intervals dividing the still separate and distinct links in the chain of lymphatic segments which are forming in this stage along the line of the future continuous thoracic ducts. (Cf. reconstruction of this embryo, shown in fig. 190, at level of first intercostal artery).

Figs. 230 to 235 inclusive show transverse sections from the central region of the next slide of the same embryo (series 214, slide xv, sections 10, 11, 14, 16, 19, 21, $\times 225$). Sections 10 and 11 (figs. 230 and 231) repeat practically the conditions above observed and recorded in sections 15, 16, 17, 19, 20 and 22 of slide xiv. A large empty central endothelial bag (4) represents the decadent ventro-medial azygos tributary around which the extraintimal lymphatic anlage of the thoracic duct (5) is forming. In sections 14, 16 and 19 (figs. 232, 233 and 234) both the central venous kernel (4) and the replacing perivenous lymphatic space (5) are diminishing, just as they are doing in figs. 220 to 224, sections 26, 27, 28, 32 and 34 of the preceding slide xiv of this embryo. In section 21 of slide xv (fig. 235) the perivenous lymphatic space stops, and only the central venous kernel (4), still connected with the ventro-medial azygos plexus of the right side, persists.

Finally figs. 236 to 240 inclusive give five successive sections of the same embryo in the terminal part of slide xv (series 214, slide xv, sections 27, 28, 29, 30 and 31, $\times 225$), in which the stage of the early formation of the extraintimal anlage of the azygos portions of the thoracic duct is shown. The decadent ventro-medial azygos tributary (4) is almost completely separated from the azygos plexus, although the path of its original connection with the same can still be traced by the arrangement of the perivenous mesodermal cells. The extraintimal lymphatic anlage of the thoracic duct (5) develops at first on the lateral aspect of the atrophying component of the ventro-medial azygos plexus, and at some distance ventral to the main azygos trunks and to the inter-azygos anastomosis. This series is, therefore, of considerable

interest, as exhibiting, at different levels in the same embryo, the following phases of early extraintimal replacement of ventro-medial azygos tributaries by the thoracic duct anlagen:

1. Detachment of venous elements of the plexus, as empty endothelial tubes, surrounded by extraintimal lymphatic anlagen: Slide xiv, sections 15, 16, 17, 19, 20, 22, (figs. 214 to 219 inclusive). Slide xv, sections 10 and 11, (figs. 230 and 231).

2. Gradual recession of degenerating central venule, and approach of same and of surrounding extraintimal lymphatic space to ventral aspect of main azygos system: Slide xiv, sections, 26, 27, 28, 32, and 34, (figs. 220 to 224 inclusive). Slide xv, sections 14, 16, and 19 (figs. 232, 233 and 234)

3. Elimination of central atrophying venous kernel with persistence of clear lumen of lymphatic channel segment: Slide xiv, sections 1, 2, 3, and 4, (figs. 225, 226, 227 and 228).

4. Blind ending of lymphatic channel anlage and development of interval between the still disjointed links of the future continuous lymphatic chain of the thoracic duct: Slide xiv, section 5, (fig. 229) and reconstruction (fig. 190).

5. Blind ending of extraintimal perivenous lymphatic anlage with persistence of ventro-medial azygos tributary venule (4): Slide xv, section 21 (fig. 235).

6. Early stage of development of azygos segment of thoracic duct, in which the same appears as an extraintimal lymphatic space (5) closely applied to the lateral circumference of a component of the ventro-medial azygos venous plexus (4), still in communication with the axial venous trunks, but destined subsequently to be separated from them and to undergo entire extraintimal replacement by the surrounding lymphatic space: Slide xv, sections 27, 28, 29, 30 and 31 (figs. 236 to 240 inclusive).

Another feature of the early development of the azygos segment of the thoracic ducts, strikingly illustrated by the embryo under discussion, is the segmental type of the originally isolated and independent perivenous extraintimal lymphatic development. Thus in the selected sections of the two slides xiv and xv just described the following succession of conditions is to be noted. Sections 1 and 2 (figs. 225 and 226) lead up, at the caudal end

of a link of the chain, by gradual reduction of the central atrophying vein, to a point (sections 3 and 4, figs. 227 and 228,) where the same stops, and only the perivenous lymphatic anlage (5) continues. The latter also ceases blindly in the following section, (5, fig. 229), and then follows an interval in which no lymphatic anlages exist.

These gradually appear again, in the same situation, and reach their full development about the middle of this slide in sections 15, 16, 17, 19, 20 and 22 (figs. 214 to 219 inclusive).

In the caudal part of the same slide both the central decadent vein core (4) and the enveloping lymphatic space (5) again diminish, and, at the same time, approach the ventral aspect of the interazygos plexus, in sections 26, 27, 28, 32, and 34 (figs. 220 to 224 inclusive). They continue in this condition in the beginning of slide xv. Further caudad the lymphatic anlage again increases in size and rapidly reaches its former degree of development. Thus section 10 of slide xv (fig. 230) corresponds to section 15 of slide xiv (fig. 214) in the extent and relations of both the central atrophying venous core (4) and the enveloping extraintimal lymphatic space (5), and the same condition is maintained in the succeeding sections 11, 14, 16 and 17 of slide xv, (figs. 231, 232, 233 and 234) which compare strictly with sections 16, 17, 19, 20 and 22 of slide xiv, (figs. 215, 216, 217, 218 and 219).

Sections 10 and 11 of slide xv (figs. 230 and 231) show especially well the relation of the atrophying central venule (4) and the surrounding extraintimal lymphatic space (5) to the right azygos trunk (3), the aorta (7) and the right intersegmental artery (2). Comparison, for example, with corresponding sections of the preceding series 76 will demonstrate the identity of both anlages in the two embryos (cf. series 76, slide xi, sections 16, 17 and 19, (figs. 207, 208 and 209).

The relations of the early thoracic duct anlages are clearly evident in the ventral view of the reconstruction of embryo 214, shown in fig. 190.

The lymphatic anlage of the left side, forming the beginning of the caudal part of the left thoracic duct, smaller and less developed in this stage, compared with the corresponding struc-

ture on the right, begins to make its appearance in slide xv of this embryo (series 214, section 33) in relation to a rudimentary ventral tributary of the left azygos vein (section 32). It can be followed through the rest of the slide to section 36, and in the succeeding slide xvi to section 7. It reappears in section 15 of slide xvi, again in association with a reduced ventral azygos branch, and continues to section 26, where it seems to end. It reappears in the following section (27) again as the extraintimal envelope of a small retrograding ventral azygos branch, and increases rapidly in size, ending in section 30. It again appears in section 33, and can be traced with frequent interruptions from this point caudad, diminishing in size and continuity, while conversely the ventral azygos tributaries of this area are larger and better developed (cf. left side of reconstruction, fig. 190).

Certain 14 mm. embryos, in which the development of the thoracic duct anlagen in the middle and lower thoracic region has not yet reached the condition usually encountered in average embryos of this period, furnish excellent examples of the early appearance of the first lymphatic spaces in their relation to the components of the ventro medial azygos tributary plexus, which they are destined to eventually replace.

Thus, in another 14 mm. embryo (series 127, slide x, sections 3, 4, and 10, $\times 225$), shown in transverse section in figs. 241, 242, and 243, the ventro-medial azygos plexus (34 in fig. 241) is still well preserved and in open communication with the main right azygos trunk. The following section (fig. 242) shows the same conditions, but a small extraintimal lymphatic space (5) appears in relation to one of the component venules (4) of the plexus, applied to its dorso-lateral circumference. The same beginning of extraintimal lymphatic space development in relation to azygos tributaries is seen further caudad in the same slide of this embryo (figs. 243, series 127, slide x, section 10).

One of the best examples of the early stages of development of the thoracic duct anlagen in relation to the ventro-medial tributaries of the azygos veins is afforded by a 14 mm. embryo (series 34 of the Princeton University embryological collection). I owe the opportunity of examining and reconstructing this remarkably

fine series to the kindness of my colleague, Prof. C. F. W. McClure. The embryo shows in the mediastinal and in the cephalic portion of the azygos region the typical extraintimal formation of the thoracic duct anlagen, while in the more caudal part the ventro-medial tributary venous plexus of the azygos trunks is still fully developed and not yet invaded by the enveloping and replacing lymphatics anlagen. Intermediate between these two districts are areas where the decadent ventro-medial azygos venous tributaries can be clearly traced into the surrounding replacing extraintimal lymphatic plexus. The general disposition of the azygos veins and of the thoracic duct anlagen in this embryo is shown in the ventral view of the reconstruction of slides (xxiv to xxxii given in fig. 189).

The perivenous lymphatic spaces are fully established in the cephalic part of the azygos and in the preazygos portions, although not yet joined into longer channel segments. In the caudal area the plexus of the ventro-medial azygos tributaries predominates, while the accompanying and enveloping extraintimal lymphatic anlagen are much reduced in size and number. Intermediate between these two areas, and corresponding to slides xxvii and xxxviii, lymphatic development is actively proceeding, especially along the right azygos tributary venous line 34 in figure 189, by the formation of extraintimal mesenchymal spaces around the venules of the azygos plexus. Sections in this area furnish conclusive early pictures of the decadent venous radicles, almost completely detached from the main channel and surrounded by perivenous lymphatic anlagen. Figs. 246 to 251 show six successive transverse sections (17 to 22 inclusive) of slide xxviii, in the region indicated in the figure of the reconstruction (fig. 189) by the lines A-B.

In fig. 246 (section 17, $\times 225$) the small central venous remnant (4) surrounded by the extraintimal lymphatic anlage (5) lies in the interval between aorta (7) mesad, right azygos vein (3) laterad, oesophagus (8) ventrad, and elements of the interazygos anastomosis dorsad.

In section 18 (fig. 247) the same structures are seen. The central vein (4) in the interior of the enveloping lymphatic anlage

(5) is larger and still contains a number of red blood cells. In the four succeeding sections, 19, 20, 21 and 22 (figs. 248, 249, 250 and 251) the former line of communication of the decadent venule (4) with the functional azygos channel can still be distinctly traced as a strand of connective tissue cells joining it to the beginning of the right interazygos plexus. The separation of the venous radicle undergoing extraintimal lymphatic replacement has just been accomplished in this area.

The six sections of this embryo shown in figs. 246 to 251 should be compared with the slightly more advanced 14 mm. embryo 214, where, *e.g.*, in figs. 230, 231, 232, 214, 215, 216, 217, 218 and 219 exactly equivalent sections are given, showing the next step in extraintimal lymphatic development in this region. The atrophying venule (4) in the earlier embryo (series 34) still contains red blood cells and still betrays its original connection with the functional venous channels. In the genetically slightly older embryo (series 214) the same structure appears now as an empty endothelial bag (4), completely detached from the azygos veins. In both embryos this decadent venous radicle is surrounded by the developing extraintimal lymphatic space (5). The comparison of the sections shows every step in the process of development in these two closely connected stages. The reduced photographic reproductions do not give the clear and unmistakable pictures presented by the actual sections, owing to the loss of the differential stain and of the focal adjustment. Still the contour of the venous core, undergoing atrophy and replacement by the extraintimal lymphatic anlage, its content of red blood cells and its recently interrupted connection with the main azygos vein in the younger embryo (series 34), can be followed with a sufficient degree of clearness and can be contrasted with the conditions presented by the succeeding stage (series 214).

Figs. 244 and 245 give two successive sections from the caudal part of the thoracic region in series 34 (slide xxxi, sections 18 and 19, $\times 225$) in which the earlier conditions, preceding the first appearance of the lymphatic anlagen of the thoracic duct in the azygos segment, are shown.

Between the right azygos vein (3) and the aorta (7) are seen

the components of the ventro-medial azygos plexus (4), partially separated from the main venous trunks, but not, as yet, surrounded by extraintimal lymphatic anlagen, as, further cephalad, (slide xxviii) in the sections just described, (figs. 246 to 251).

The 15 mm. and 15.5 mm. embryos show, in the majority of instances, an advance over the preceding stage in two directions:

I. The central venous core of the 14 mm. embryo is further reduced or entirely eliminated, leaving the lymphatic anlage, which formerly surrounded it, with a clear lumen.

II. The individual scattered lymphatic areas have united to form longer segments of the future lymphatic channel system. This condition is well shown in the ventral view of the reconstruction of an average 15 mm. embryo (series 219) in fig. 191 (cf. supra, p. 126).

Figs. 252 to 258 inclusive show transverse sections of the lower thoracic region in a 15.5 mm. cat embryo, (series 143, slide xviii section 7, 11, 12, 13, 14; slide xvii, sections 31 and 32, $\times 225$), and fig. 192 gives the ventral view of the reconstruction of the azygos region in this embryo, comprising slides xiv, xv, xvi, xvii, and xviii.

The sections (figs. 252 to 258) show the following changes in the vascular structures, compared with the preceding stages

I. The right (3) and left (6) azygos veins are concentrated, more sharply defined and relatively smaller, although still equally developed on both sides.

II. The interazygos anastomosis is still well developed and uniform (cf. also fig. 192).

III. The entire azygos complex is much more closely applied to the dorsal and dorso-lateral circumference of the aorta (7), resulting in the practical obliteration of the interval between the main veins and the artery seen in the preceding stages.

IV. This topographical rearrangement has forced the ventro-medial azygos tributaries, where they still persist (34 in figs. 252, 253, 257), and the thoracic duct anlage (36) to pass from the ventro-medial to the ventral aspect of the main azygos trunks.

V. Both azygos veins lie in the region *ventro-lateral* to the intersegmental arteries. The supra-aortic area between them is still

occupied by the interazygos (supra-cardinal) anastomosis (cf. infra, figs. 261 and 262).

VI. The sections taken from the caudal portion of the thoracic region (slides xvii and xviii) show the right and left thoracic duct anlagen (36) following the ventral aspect of the respective azygos veins (cf. fig. 192). They are not yet united into a continuous channel, but their lumen is clear, without trace of the venous kernel around which they developed.

Fig. 252 (slide xviii, section 7) shows remnants of the ventromedial azygos plexus (34) emptying on both sides into the azygos trunks. Lateral to these venous radicles lies the thoracic duct anlage of each side (36).

In section 11 of the same slide (fig. 253) the right thoracic duct anlage has enlarged and presents a beautifully clear picture of the relation of this structure to the rightazygos vein at this stage.

On the left side the conditions are as in the preceding figure, both persistent ventral venous tributary (34) and left thoracic duct anlage (36) lying side by side.

In the two succeeding sections, 12 and 13, (figs. 254 and 255) the right thoracic duct continues well developed and presents a pointed dorso-mesal prolongation indicative of its situation in the earlier stages, on the mesal aspect of the vein, between it and the aorta, and ventral to the interazygos anastomosis. (cf. series 34 and 214). The left duct anlage continues as a small channel.

In section 18, (fig. 256) both right and left lymphatic anlagen cease as distinct channels, marking one of the intervals between the still disconnected segments of the future continuous duct.

Figs. 257 and 258 (sections 31 and 32 of slide xvii) show on alternating sides small thoracic duct anlagen (36), and in the root of the dorsal mesogastrium sections of the well-developed anterior mesenteric lymphatics (51). Some of the later stages (series 253, figs. 265 to 270) will show the full development of these mesenteric channels and their confluence with the thoracic duct. This area, is, however, responsible for the development of what I have above defined as the post-azygos segment of the thoracic duct and will hence be considered in detail in the second volume of this series.

In comparison with the series just considered figs. 259 and 260 show transverse sections of the lower thoracic region of series 258, slide xviii, sections 1 and 9, $\times 225$. This embryo is rated as 17 mm. in crown-rump length, but the lymphatic development of the azygos region is relatively retarded and only slightly in advance of the conditions presented by the 15.5 mm, series 143. Direct comparison of figs. 252 to 258 with figs. 259 and 260 will show this correspondence, both at the level of the intersegmental arteries (2 in fig. 260), and in the intervals between them (fig. 259). In the older embryo the right and left thoracic duct anlagen (36) are somewhat larger and form longer channel segments, but otherwise the two series belong practically to the same developmental stage, in spite of their difference in total length measure. The correspondence, for example, between figs. 254 (series 143) and 259 (series 258) is remarkable.

On the other hand the majority of 16 mm., 16.5 mm. and 17 mm. embryos offer decided advances in the lymphatic development of this region beyond that normally found in the 15 mm. and 15.5 mm. stages.

Two successive sections of a typical 16 mm. embryo (series 96) in the azygos area are shown in figs. 261 and 262, and fig. 193 gives the ventral view of the reconstruction of the same embryo, in which the level of figs. 261 and 262 is indicated by the line *A-B*.

Comparison with the immediately preceding series (143 and 258) will show that the following fundamental changes have occurred in the azygos venous and lymphatic systems:

I. The two azygos veins (3 and 6) have become reduced in size. At the level, at which the sections of figs. 261 and 262 are taken, both veins now lie *dorsal* to the intercostal arteries (2), whereas in the earlier stages (*e.g.* figs. 260, 258, 257) the azygos trunks are *ventral* to the arteries, and the interval between the latter, along the dorsal aspect of the aorta, is occupied by the supracardinal inter-azygos plexus.

Reference to the reconstruction of series 96 (fig. 193) shows that this topographical readjustment has occurred in the caudal part of the azygos area, below the level *A-B*, by the longitudinal hydrostatic definition of the main supracardinal azygos

trunks through confluence of elements of the preceding interazygos plexus. The original post-cardinal azygos veins, which in series 258 and 143 are seen to form the main channels *ventral* to the intercostal arteries, are, in the caudal region of series 96, represented by two slender longitudinal trunks, on the lateral aspect of the thoracic ducts between them and the sympathetic nerves (1). The main azygos veins have developed as distinct circumscribed axial channels out of the antecedent *supracardinal* interazygos plexus, *dorsal* to the intercostal arterial branches (2). Correlated with this new azygos development is the reduction of the earlier *postcardinal* channels, *ventral* to the intersegmental arteries, and their topographical replacement in large part by the right and left thoracic ducts (36) (not labelled in fig. 193). Cephalad of the level *A-B* the reconstruction shows the earlier relation of the azygos trunks, ventro-lateral to the intercostal arteries. In ascending the left azygos vein gradually diminishes, while conversely the vessel of the right side increases in caliber.

II. The individual separate lymphatic anlagen of the azygos segment of the thoracic duct of the preceding stages have united into a continuous and uninterrupted lymphatic channel.

Caudad of the level *A-B* (fig. 193) the right and left thoracic ducts are fairly symmetrical bilateral channels, connected with each other by several broad and by a larger number of slender transverse anastomoses. They occupy the position of the earlier postcardinal azygos trunks, before these shifted to the supracardinal position, ventro-lateral to the intercostal arteries, along the medial border of the reduced longitudinal tributary channel representing on each side the remnant of the earlier post-cardinal azygos, and draining dorsad into the newly established supracardinal azygos line of each side.

Figs. 261 and 262 give excellent views of the topographical relations of the vascular structures, arterial, venous and lymphatic. Both sections show the right and left thoracic ducts (36), ventral to the intercostal arteries (2), the lymphatic cross anastomosis between the two along the dorsal circumference of the aorta, and the main supracardinal azygos veins (3, 6). Cephalad of the level *A-B* (fig. 193) this plexiform anastomosis between the

ducts increases in extent, and the entire lymphatic channel inclines, in ascending, to the left. This, as previously explained (cf. supra, p. 129), is due to the greater development of the intermediate lymphatic line, along the ventral aspect of the interazygos anastomosis, and its union with the left thoracic duct to form the plexiform channel of the adult. The corresponding lymphatic of the right side, on the other hand, becomes reduced above the level *A-B*, and only its cephalic portion persists as the thoracic segment of the right lymphatic duct (47 in fig. 193).

The extraintimal lymphatic anlagen ventral to the thoracic ducts, which are eventually to establish the connection between them and the mesenteric lymphatics, are in the process of development in series 96. The venous core (4) and the replacing perivenous lymphatic (5) are shown on the left side in figs. 261 and 262, and equivalent segments of this channel are seen in the reconstruction (51 in fig. 193). In other portions of the ventral and ventro-lateral periaortic mesoderm numerous independent intercellular spaces begonging to the same system are developing.

While the thoracic ducts are in the majority of 16 mm. embryos complete continuous and definite channels, as in the present average example, the acquisition of this final condition is not infrequently delayed considerably beyond this period. I have a number of 16 and 16.5 mm. embryos in which the thoracic duct development has not advanced beyond the stage typical of the average 14 mm. or 15 mm. embryo. This is another example of the considerable range of chronological variation of lymphatic development in individual embryos encountered in examining a large number of series of about the same length measure.

The 16 mm. embryo again furnishes conclusive evidence as to the secondary character of the mutual relation between embryonic venous and lymphatic vessels, and shows, in typical individuals, the final stage of the process through which temporary venous channels are replaced by the permanent components of the lymphatic system. This replacement, as demonstrated by the successive series of sections from the azygos region just considered, is a gradual process. The lymphatic channel has its inception in numerous small extraintimal mesenchymal spaces which form

along and around the components of an atrophying embryonic venous plexus, or follow part of the circumference of a more definite early venous trunk. As these spaces increase, enlarge and become confluent to form longer segments of the lymphatic channel, the related venous element continues to recede, until, in certain areas, it is entirely replaced by the lymphatic vessel. In other districts, along embryonic veins which are carried into the adult organization, as permanent components of the venous system, the redundant vein of the earlier stages becomes more circumscribed and more clearly defined as the companion lymphatic channel develops in the perivenous area. In either case the complete or partial replacement of venous by lymphatic elements does not occur suddenly, but is accomplished by gradual and progressive ontogenetic stages. I can find no evidence at any point of the separation of portions of a venous plexus or of an already organized venous channel, such detached parts then uniting directly with each other to form systemic lymphatic vessels. In every region of the mammalian embryo the above described extraintimal development of the lymphatic elements, and the subsequent secondary topographical replacement of decadent veins by them, can clearly be demonstrated. This process, of course, leads to a stage in which the advancing development of the lymphatic and the correlated regression of the associated venous components are balanced, and in which both, proceeding in opposite genetic directions, are found side by side in the same field. The stages previously discussed in detail, between 13 mm. and 15 mm. offer abundant illustration of this intermediate stage in the azygos area.

It is to be noted that in the earlier stages (13 to 14 mm.) the lymphatic extraintimal spaces first appear on the lateral aspect of the atrophying venules of the ventro-medial azygos plexus, and subsequently surround them. They are then situated at some distance ventral to the main azygos trunks. In the later stages (15 mm., 15.5 mm. and 16 mm. embryos) they have extended dorsad and lie in close apposition to the ventral and ventro-medial circumference of the larger veins, which position they maintain subsequently in their further development. Coincident with this

relative change in position of the earlier lymphatic spaces is the appearance of additional thoracic duct anlagen; which develop as extraintimal lymphatic elements along those lines of the embryonic azygos system which are destined to undergo, in the later stages, still further reduction and final elimination in the definite organization of the adult condition. [Compare on this point the sections of series 96 (figs. 261 and 262) with those of series 253 (figs. 265 to 270)].

One other fact deserves careful consideration in analyzing the development of the azygos segment of the thoracic ducts in stages between 14 mm. and 15 mm. In a certain proportion of the embryos of this period the extraintimal replacement of the earlier ventro-medial azygos plexus in the cephalic part of the future azygos segment of the thoracic duct is delayed. In these cases peculiar histological pictures are obtained in this area. The components of the ventro-medial azygos plexus have become detached from the main veins, and have fused together into an elongated spindle shaped bag, completely filled with blood, beginning and ending blindly and not in communication with any venous channel. This structure, when found, invariably occupies the site of the long lymphatic segment seen in the reconstruction of series 214 (fig. 190) on the right side, in the areas *A* and *B* (slides xiv and xv), ventral to the right intercostal arteries, in the interval between aorta and right azygos vein. The appearance presented by it on section is shown in figs. 263 and 264 in a 14 mm. cat embryo (series 211, slide xii, sections 2 and 8, $\times 225$). It is indicated in these figures by the leader 34, as a detached and confluent part of the original ventro-medial azygos plexus. Fig. 263 shows this structure in the interval between the intercostal arteries. Fig. 264 gives a typical view of it at the level of one of the right intercostal branches. It lies ventral to the same, between aorta (7) mesad, the right azygos trunk (3) laterad, dorsal to the oesophagus (8). The blood cells, which completely fill its lumen, differentiate from those circulating in the continuous vein channels by remarkably intense reaction to the Orange-G stain. As stated, this structure is completely detached from all adjacent veins, can be followed cephalad and caudad through many sec-

tions, and ends blindly at either end in a gradually diminishing pointed extremity. In a reconstruction of this embryo it would correspond absolutely in extent and relations to the long lymphatic channel above referred to on the right side of series 214 (fig. 190). A comparison of the reconstruction (fig. 190) and of the corresponding sections (figs. 214 to 240) of this latter embryo, clearly reveal the significance of this, at first sight, somewhat anomalous and puzzling structure. It will be noted that the reconstruction of series 214 (fig. 190) shows, at the level of the line *C*, the caudal end of a large ventro-medial tributary trunk (*34*) of the right azygos vein (*3*), which, in proceeding cephalad, becomes imbedded in the centre of the long extraintimal lymphatic channel. The continuation of this venous tributary line, detached from the functional veins, furnishes the central venous core (*4*) which is surrounded by the extraintimal lymphatic space (*5*) in all the sections of series 214 shown in figs. 214 to 240 inclusive. If this ventro-medial tributary trunk (*34* in fig. 190) had organized in its entire length, by confluence of the radicles of the preceding plexus, and had then become detached from the functional right azygos vein, it would, before extraintimal development of the surrounding lymphatic spaces began, present exactly the conditions seen in series 211. In comparing, therefore, these two 14 mm. embryos, we find in series 214 the venous line, around which this important segment of the thoracic duct develops and which it subsequently replaces, present in the condition typical for the average embryo of this period, as a detached and nearly empty venous bag, surrounded by the extraintimal lymphatic channel. On the other hand, series 211 shows the same tributary trunk, also detached from the main vein, but still filled with blood, while the enveloping extraintimal lymphatic anlagen have not yet made their appearance. Comparison with the reconstruction and with the sections of series 214 prove its identity with the latter's venous core (*4*) in the interior of the lymphatic channel (*5*).

A 15 mm. embryo of the Princeton embryological collection (series 53), which I had the opportunity of studying through the courtesy of Professor McClure, shows conditions identical with those just described in series 211. It is interesting and conclusive

to further compare in this respect the reconstruction of series 214 (14 mm. fig. 190) with that of series 143 (15.5 mm. fig. 192). In the former embryo the secondary para-azygos channel of the right side (34), developed by confluence of components of the right ventro-medial azygos plexus, only persists in its caudal portion, and has in the rest of its original extent been detached and surrounded by the extraintimal lymphatic channel. On the other hand, in the 15.5 mm. series 143 (fig. 192) this normal process of detachment and replacement by extraintimal lymphatic anlagen has been delayed. Fig. 192 shows the para-azygos ventro-medial channel (34) as an extensive tributary trunk of the right azygos vein, cephalad of the level *C*. Only a few areas of the extraintimal lymphatic development occur, as yet, along its course. Further development of these and their confluence will produce the condition already seen in the earlier embryo, series 214, which is typical for the average embryo of the 14 mm. stage. Thus unusual and atypical delay of lymphatic development occurs in some embryos of this period in the region above specified, and produces a definite and uniform aberrant picture. The correct interpretation of the same is given by the conditions obtaining in the average embryo of this period. I lay some stress on the facts just described, because isolated observation of an instance of this character might readily lead to the erroneous assumption that the detached venous bag (34) of figs. 263 and 264 became directly transformed into the lymphatic channel of the thoracic duct occupying in the later stages the identical topographical position and maintaining the same relations to surrounding structures. This error can only be avoided by determining, in numerous embryos of this period, the typical and average condition of lymphatic development.

Thus in the average 16 mm. cat embryo the originally separate and independent extraintimal anlagen of the two thoracic ducts have become confluent, and form from this stage onward usually a continuous and uninterrupted lymphatic channel, which is connected with the general venous system through the jugular lymph sac, by union with the thoracic duct approach of the latter.

From this stage forward the subsequent growth and readjust-

ment of the thoracic ducts is merely a question of continuous enlargement of the lymphatic channels at the expense of the azygos veins. The latter recede still further, while the former correspondingly increase until the adult relative condition of both systems is attained. In this readjustment the thoracic ducts of the adult cat acquire for themselves in large part the topographical position occupied in earlier embryonic stages by portions of the azygos complex. The method of this substitution has been sufficiently and repeatedly detailed in the preceding pages.

Figs. 265 to 270 inclusive show the results in transverse sections of the middle thoracic region in a 19 mm. cat embryo (series 253, slide xxiv, sections 9, 11, 15, 16, 17 and 18, \times 225).

In fig. 265 (section 9) both azygos veins are reduced, but the right trunk (3) has maintained itself as the principal vessel, still connected by the interazygos anastomosis (15) with the very much smaller left azygos (6). Ventral to the veins, on each side of the aorta (7), are the right and left thoracic ducts (36). The right duct, as is invariably the case in this region, is the larger, and shows a pointed dorso-medial extension which passes behind the aorta towards the ventral aspect of the interazygos anastomosis. This is a further development of the same conditions seen in the 15.5 mm. and 17 mm. embryos, in figs. 254, 255 and 259, and is responsible for the formation of the intermediate dorsal lymphatic element seen in the 16 mm. embryo, (figs. 261 and 262) behind the aorta, between the azygos veins and the intercostal arteries. (cf. especially left side of fig. 262).

On the left side of fig. 265, ventral to the left thoracic duct, is seen a venous radicle (4) in relation to an extraintimal anlage (5). In section 11 (fig. 266) this space has enlarged. In the succeeding sections 15, 16, and 17 (figs. 267, 268 and 269) the same structure appears as a well developed lymphatic channel (51), in the root of the dorsal mesentery, and in section 18, (fig. 270) it opens into the left thoracic duct. It marks one of the points of connection of the mesenteric lymphatic plexus with the thoracic duct, which leads to the ultimate differentiation of the postazygos segment of this channel. The anlage is the same previously noted in the 16 mm. embryo, (4 and 5, in figs. 261 and 262, series 96), and in the 15.5 mm. embryo, series 143 (51 in figs. 257 and 258).

Fig. 266 (section 11) is taken at the level of a pair of intercostal arteries (2), which perforate the interazygos anastomotic plexus (15) and separate the same from the azygos trunks. The dorso-medial extension of the right thoracic duct towards the interval between the interazygos channel (15) and the dorsal circumference of the aorta (7) has increased. In section 15 (fig. 267) it has crossed to the mesal side of the right intercostal artery and occupies part of the area filled in the preceding sections by the interazygos anastomosis. This latter is reduced to insignificant remnants. The left azygos vein (6) appears as a minute channel between the left intercostal artery (2) and the left thoracic duct (36). It can be traced in the same condition in the succeeding sections.

In sections 16, 17 and 18, (figs. 268, 269 and 270) the intermediate lymphatic channel appears along the dorsal circumference of the aorta, between the intercostal arteries, which now pass through meshes separating the three chief channels of the lymphatic plexus, viz. the left and right thoracic ducts and the intermediate supra-aortic lymphatic.

The three last figures of this series show very clearly, by comparison with figs. 261 and 262, the advances in lymphatic development, and the recession of the azygos system, especially of the left azygos vein, in passing from the 16 mm. (series 96) to the 19 mm. stage (series 253). The latter presents practically adult conditions in both the venous and the lymphatic systems.

It only remains to be noted that, in the adult cat, the right azygos vein shifts secondarily dorsad to a submuscular prevertebral anastomotic venous chain at the 9th or 10th costo-vertebral level, and thus affords the opportunity for the greater development of the caudal part of the right thoracic duct which replaces the original azygos channel and establishes connection with the abdominal lymphatics, forming the above defined "Post-azygos segment of the thoracic duct."

It is not the purpose of the present paper to enter into the development of the abdominal connections of the thoracic ducts. This subject requires a minute consideration of the conditions encountered in the adult mammal, and is hence properly reserved for future detailed consideration.

Junction of azygos and preazygos segments of the thoracic duct

These segments of the main adult lymphatic channel usually unite by end-to-end fusion in embryos between 15 mm. and 16 mm. crownrump measure, although, as previously stated, the establishment of a continuous lymphatic channel may be delayed in individual instances beyond this period.

Figs. 271 to 275 inclusive show five successive transverse sections of this junctional area of the two segments in the cephalic portion of the dorsal mediastinal region in a 15.5 mm. cat embryo (series 143, slide xii, sections 22, 23, 24, 25 and 26, $\times 200$).

Fig. 271 (section 22) contains the right precava (3) and the left azygos-Cuvierian arch (6), with the cephalic termination of the interazygos plexus (15,) dorsal to the oesophagus (8). The caudal extremity of the preazygos segment of the thoracic duct (35) is seen on the left side, and continues in the next section (fig. 272) as the link between the preazygos and azygos segments of the duct (35, 36 in fig. 272). In the following section 24 of this slide (fig. 273) the darker area dorsal to the lymphatic channel marks the blind cephalic end of the left azygos arch, and hence characterizes the lymphatic channel (36) as the beginning of the azygos portion of the duct. In fig. 274 (section 25) the left azygos arch (dorsal 3) is opened by the section and receives the terminal of the cephalic end of the interazygos plexus (15) seen in the three immediately preceding sections (sections 24, 23, and 22, figs. 273, 272 and 271). We are therefore now at the cephalic end of the azygos segment of the thoracic duct (36), ventral to the azygos vein (3) and the interazygos anastomosis, and can trace the same uninterruptedly from this point cephalad into continuity with the beginning of the preazygos channel (35), as seen in sections 23 and 22, figs. 272 and 273.

In the following section (26, fig. 275) the left azygos arch (3) is fully opened in its turn ventrad to join the left precaval vein, and the azygos segment of the thoracic duct (36) occupies the typical position of this period, between the ventro-medial aspect of the right azygos trunk (3) and the dorso-lateral circumference of

the oesophagus (8), trending sinistro-cephalad into the line of the preazygos segment (35, in figs. 271 and 272).

Reference to the dorsal view of the reconstruction of this embryo (fig. 171) shows that the azygos segment of the thoracic duct (36) has united with part of the caudal division of the preazygos chain of lymphatics (35), cephalad of the interazygos anastomosis, into a continuous lymphatic channel, although the continuity with the main preazygos segment has not yet been completely established. In other words this condition has been very nearly, but not quite, attained. Some of the preazygos elements (35) have already fused with the azygos segment, thus carrying the latter cephalad beyond the interazygos anastomosis into the territory of the preazygos portion of the thoracic duct.

PART II, PLATES

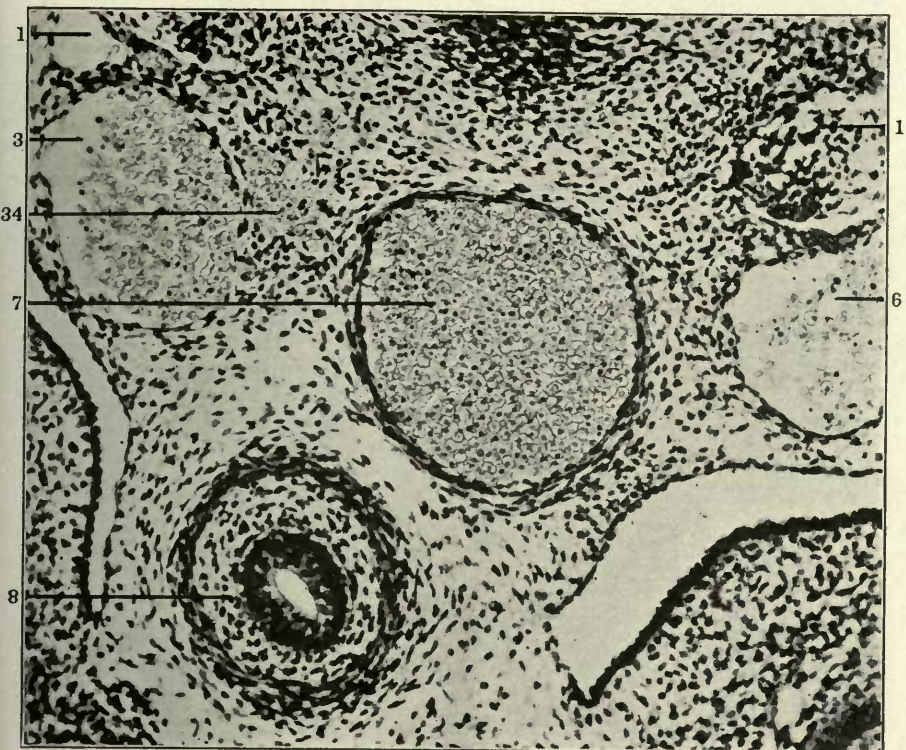
FIGURES 194 TO 275

FIGURES 194 AND 195

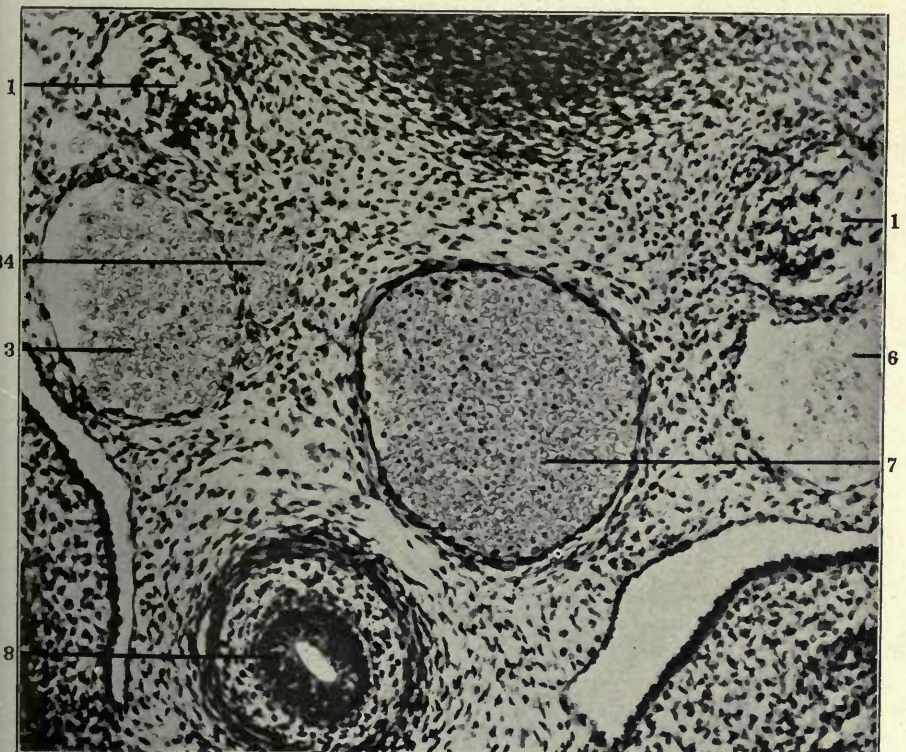
194 Transverse section of middle thoracic region of 11 mm. cat embryo;
(series 213, slide XI, section 9) \times 225.

195 Same, section 10.

- 1 Sympathetic nerve.
- 3 Right azygos vein, thoracic portion.
- 6 Left azygos vein, thoracic portion.
- 7 Aorta.
- 8 Oesophagus.
- 34 Ventro-medial azygos plexus.



194

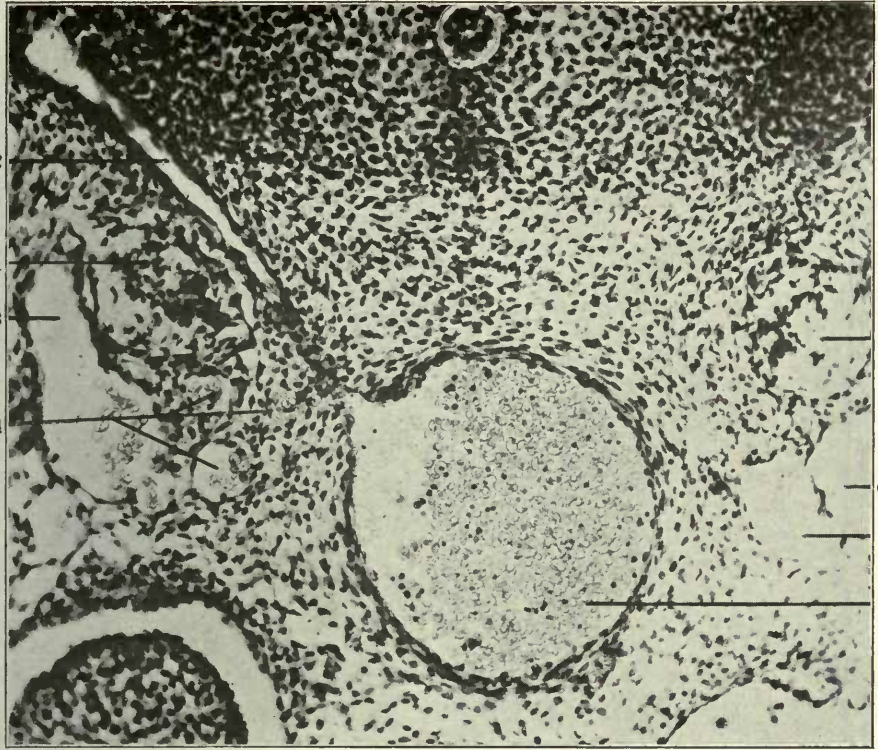


195

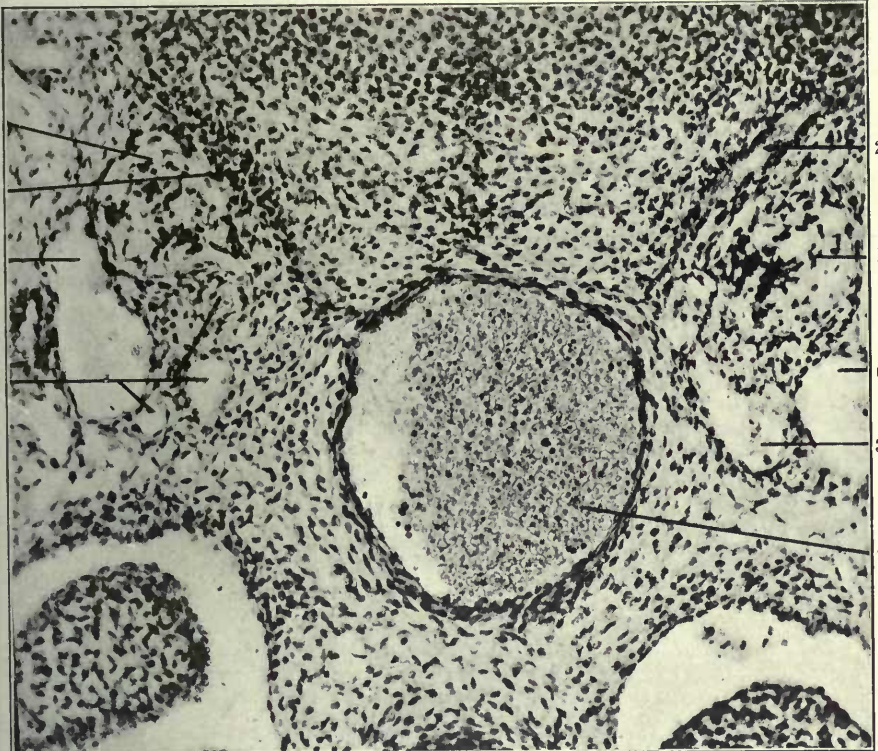
FIGURES 196 AND 197

- 196 Same, section 27.
197 Same, section 29.

- 1 Sympathetic nerve.
- 2 Intercostal artery.
- 3 Right azygos vein, thoracic portion.
- 6 Left azygos vein, thoracic portion.
- 34 Ventro-medial azygos plexus.



196



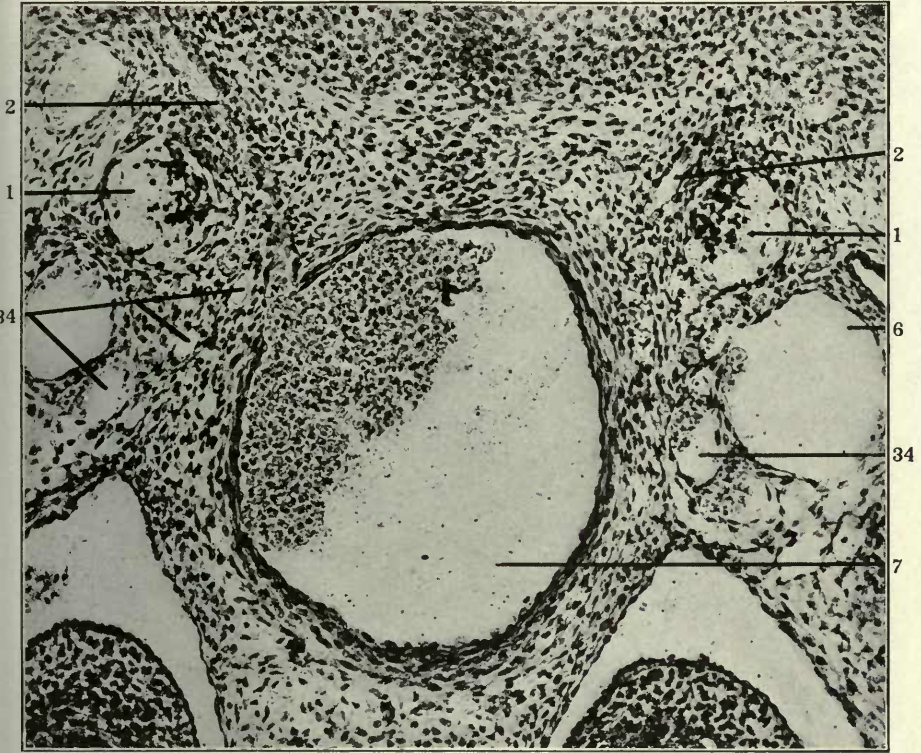
197

FIGURES 198 AND 199

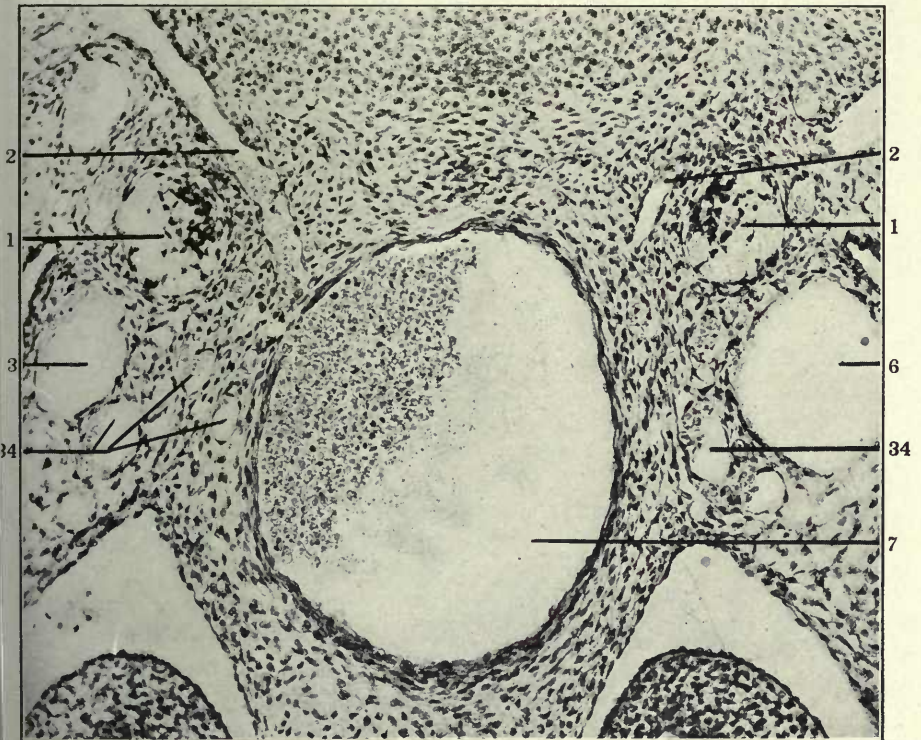
198 Transverse section of middle thoracic region of 12 mm. cat embryo,
(series 217, slide XI, section 27) (\times 225.

199 Same, section 28.

- 1 Sympathetic nerve.
- 2 Intersegmental arteries.
- 3 Right azygos vein, thoracic portion.
- 6 Left azygos vein, thoracic portion.
- 7 Aorta.
- 34 Ventro-medial azygos plexus.



198

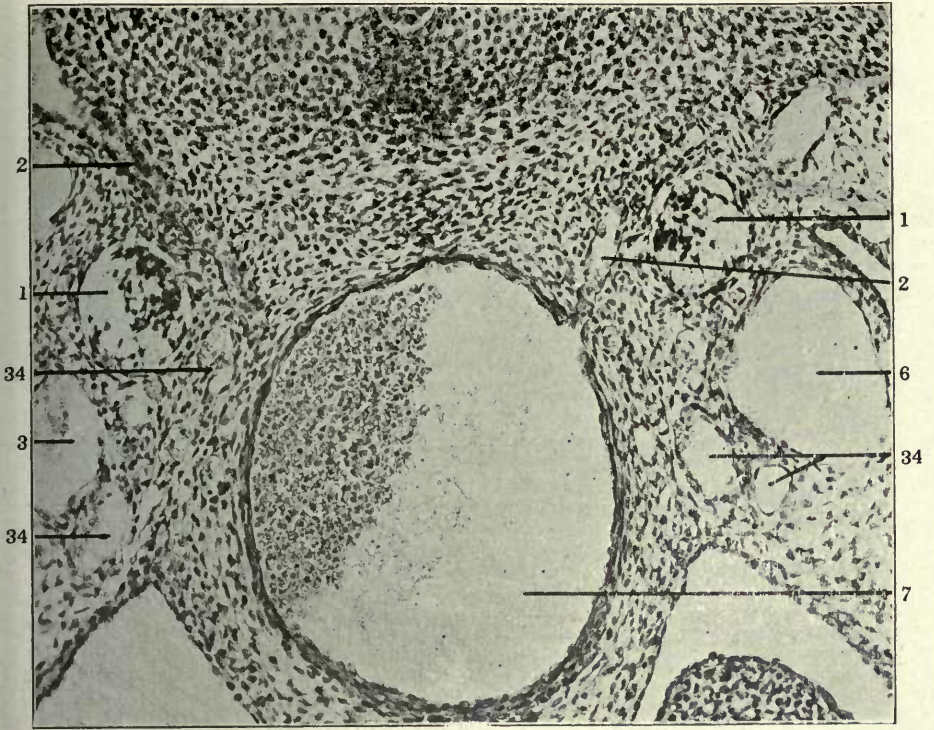


199

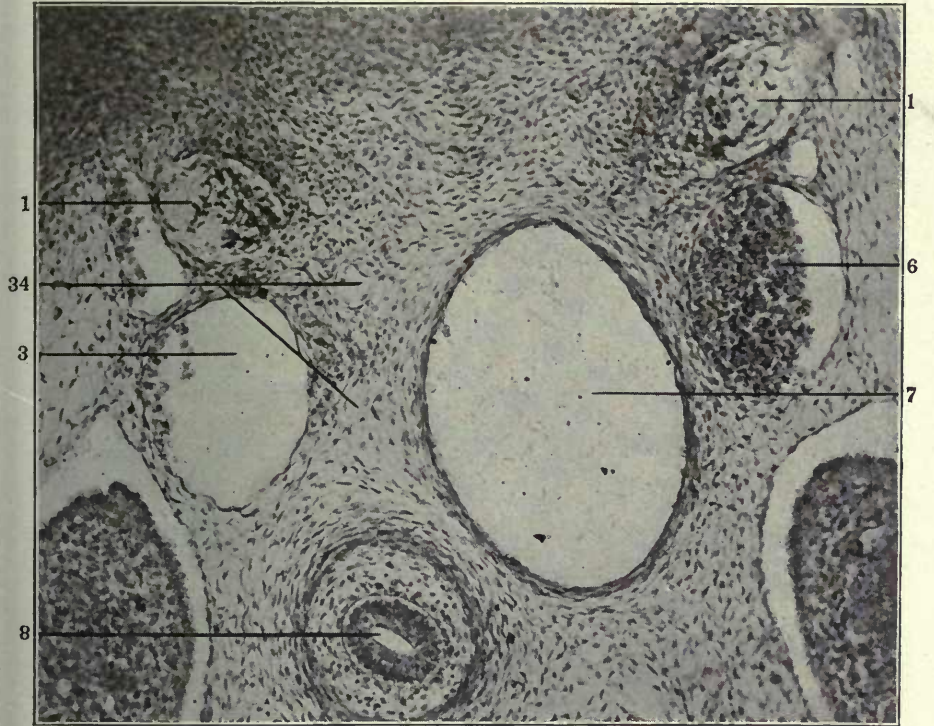
FIGURES 200 AND 201

- 200 Same, section 29.
201 Same, slide X, section 18.

- 1 Sympathetic nerve.
- 2 Intersegmental arteries.
- 3 Right azygos vein, thoracic portion.
- 6 Left azygos vein, thoracic portion.
- 7 Aorta.
- 34 Ventro-medial azygos plexus.



200



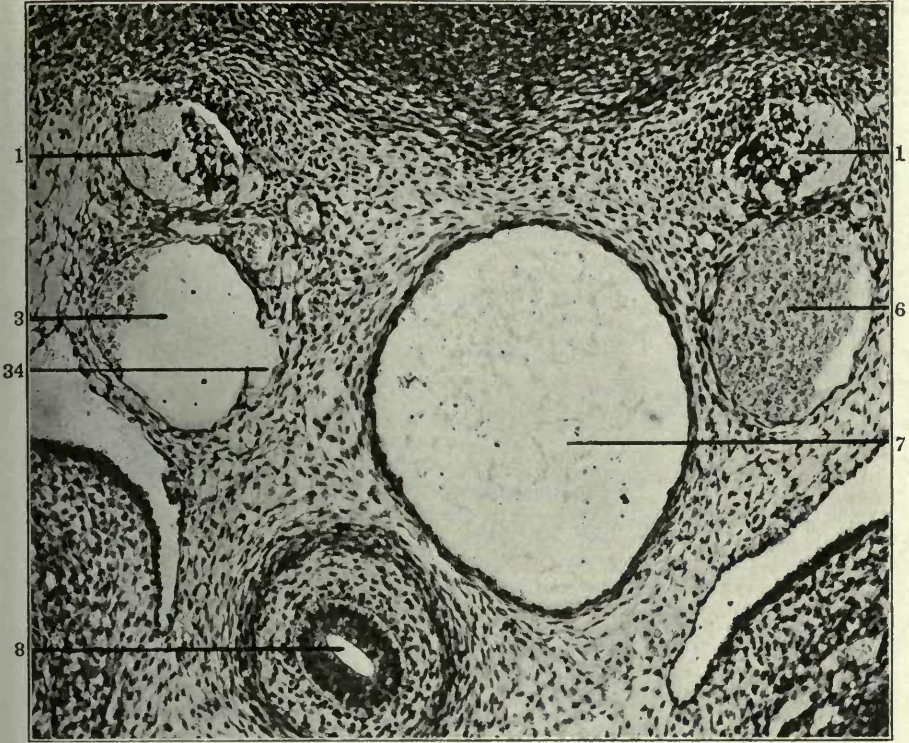
201

FIGURES 202 AND 203

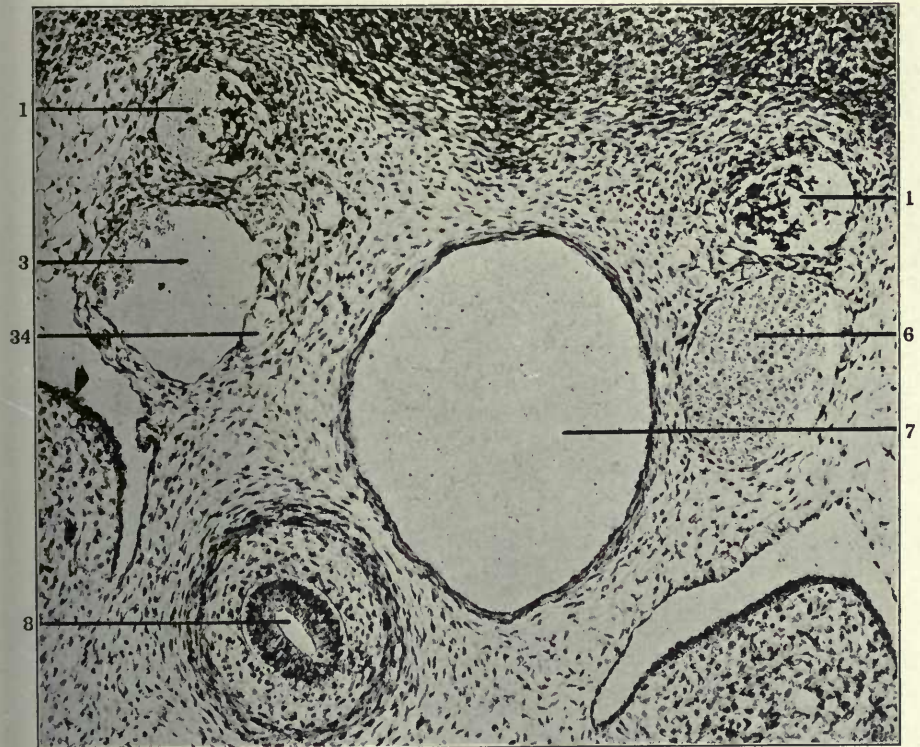
202 Same, section 30.

203 Same, section 31.

- 1 Sympathetic nerve.
- 3 Right azygos vein, thoracic portion.
- 4 Atrophying embryonal vein, forming kernel in interior of developing and replacing lymphatic space.
- 5 Extraintimal or perivenous lymphatic space surrounding degenerating embryonal vein.
- 6 Left azygos vein, thoracic portion.
- 7 Aorta.
- 8 Oesophagus.
- 34 Ventro-medial azygos plexus.



202



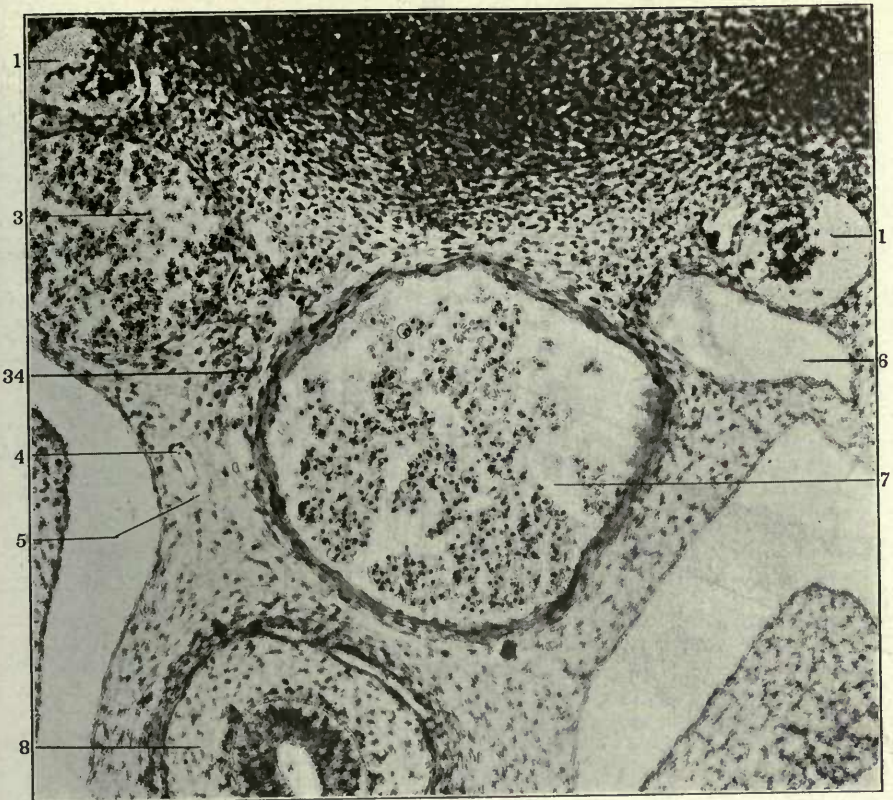
203

FIGURES 204 AND 205

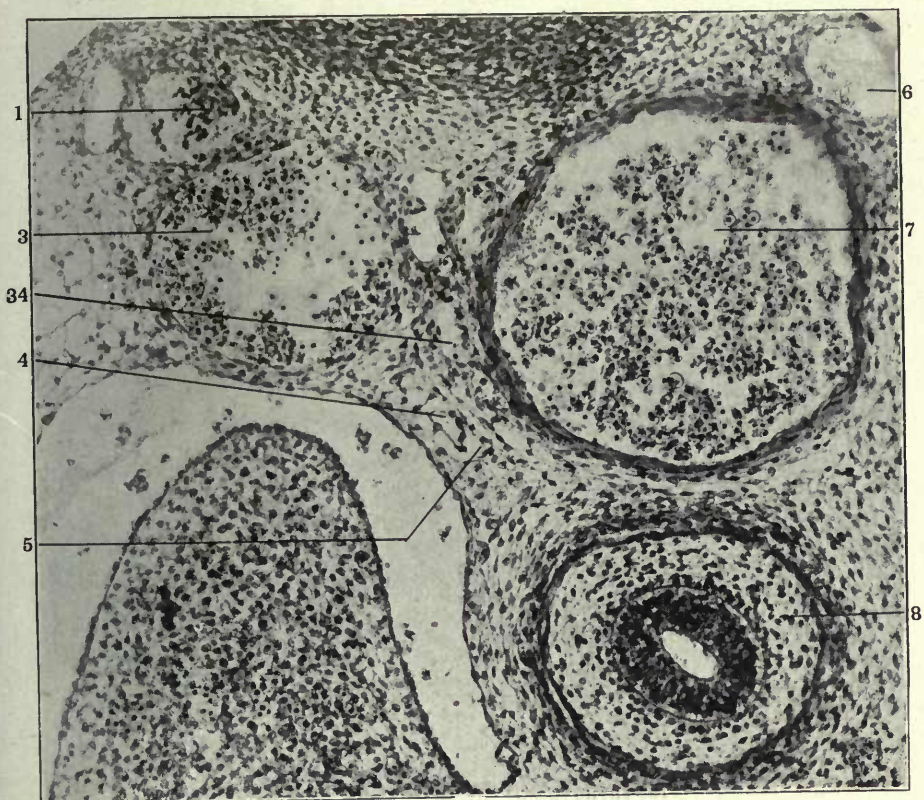
204 Transverse section through middle thoracic region of a 13.5 mm. cat embryo; (series 189, slide X, section 15) \times 225.

205 Same, section 16.

- 1 Sympathetic nerve.
- 3 Right azygos vein, thoracic portion.
- 6 Left azygos ve.n, thoracic portion.
- 7 Aorta.
- 8 Oesophagus.
- 34 Ventro-medial azygos plexus.



204



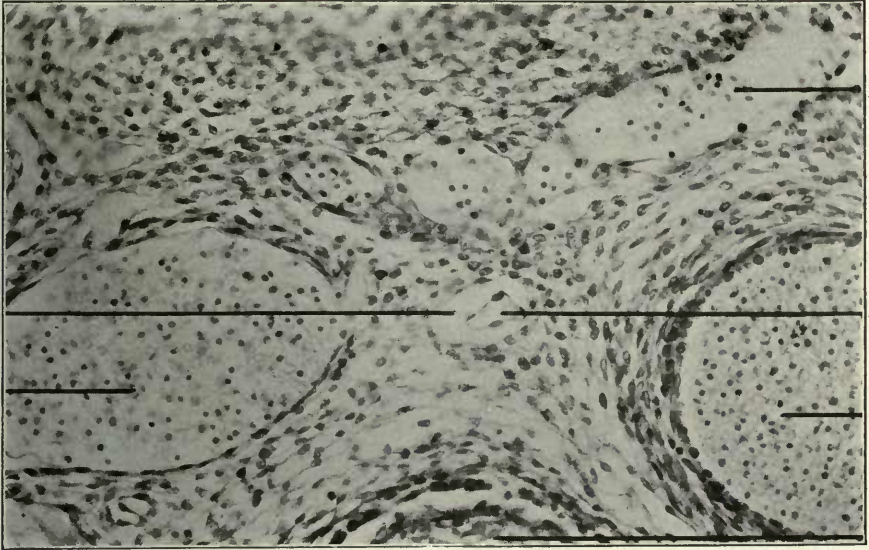
205

FIGURES 206 AND 207

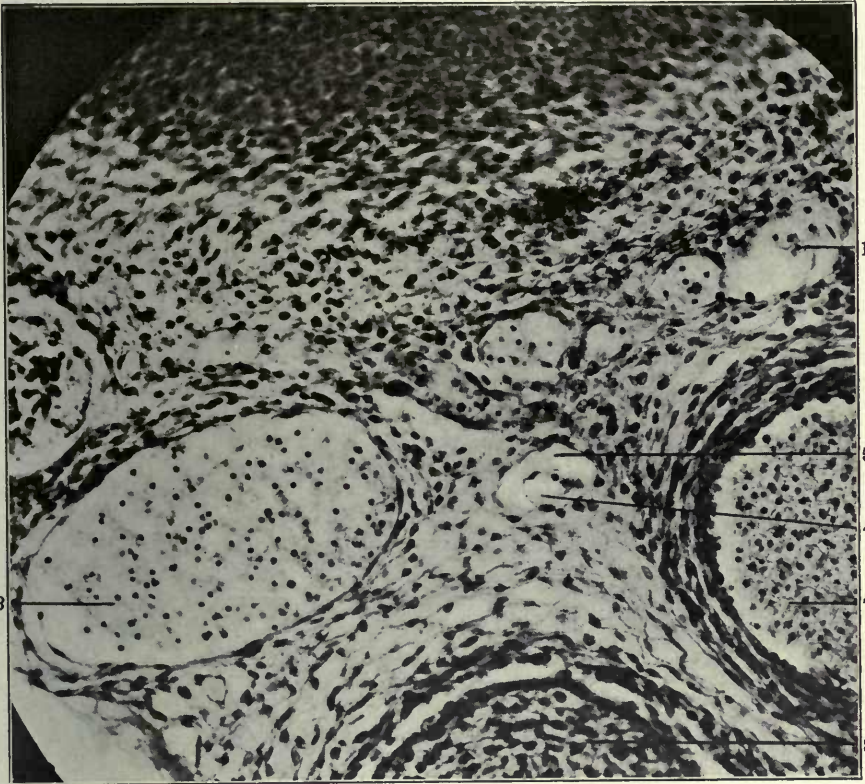
206 Transverse section through middle thoracic region in a 13.5 mm. cat embryo, (series 76, slide XI, section 15) \times 300.

207 Same, section 16.

- 3 Right azygos vein, thoracic portion.
- 4 Atrophying embryonal vein, forming kernel in interior of developing and replacing lymphatic space.
- 5 Extraintimal or perivenous lymphatic space surrounding degenerating embryonal vein
- 7 Aorta.
- 8 Oesophagus.
- 15 Interazygos venous plexus.



206

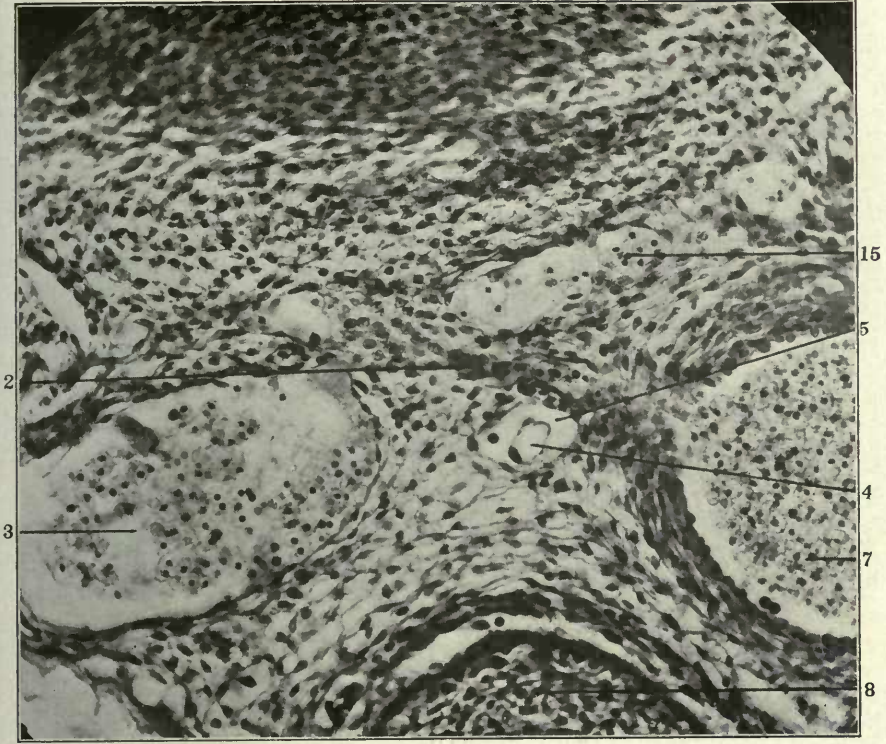


207

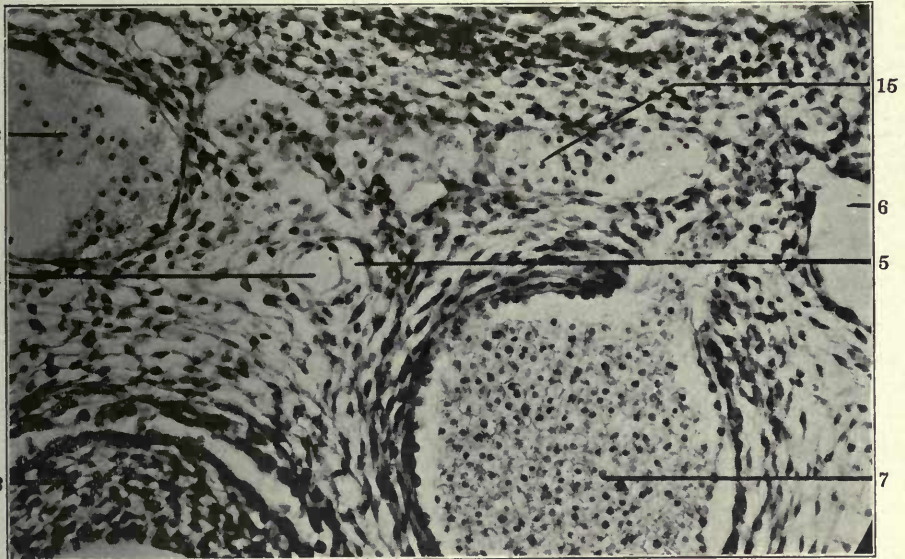
FIGURES 208 AND 209

208 Same, section 17.
209 Same, section 19.

- 2 Intersegmental arteries.
- 3 Right azygos vein, thoracic portion.
- 4 Atrophying embryonal vein, forming kernel in interior of developing and replacing lymphatic vein.
- 5 Extraintimal or perivenous lymphatic space surrounding degenerating embryonal vein.
- 6 Left azygos vein, thoracic position.
- 7 Aorta.
- 8 Oesophagus.
- 15 Interazygos venous plexus.



208

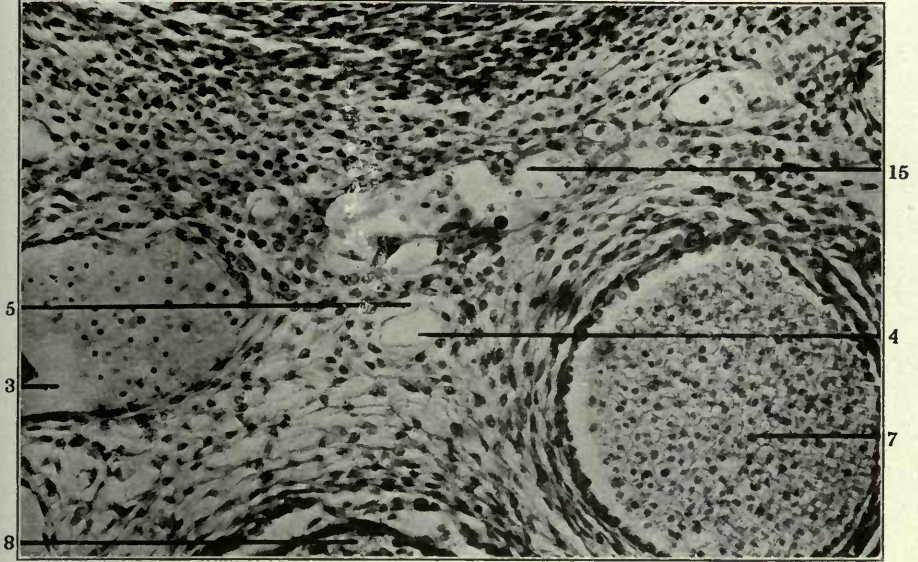


209


FIGURES 210 AND 211

- 210 Same, section 21.
211 Same, section 22.

- 1 Sympathetic nerve.
- 3 Right azygos vein, thoracic portion.
- 4 Atrophying embryonal vein, forming kernel in interior of developing and replacing lymphatic space.
- 5 Extraintimal or perivenous lymphatic space surrounding degenerating embryonal vein.
- 7 Aorta.
- 8 Oesophagus.
- 15 Interazygos venous plexus.



210



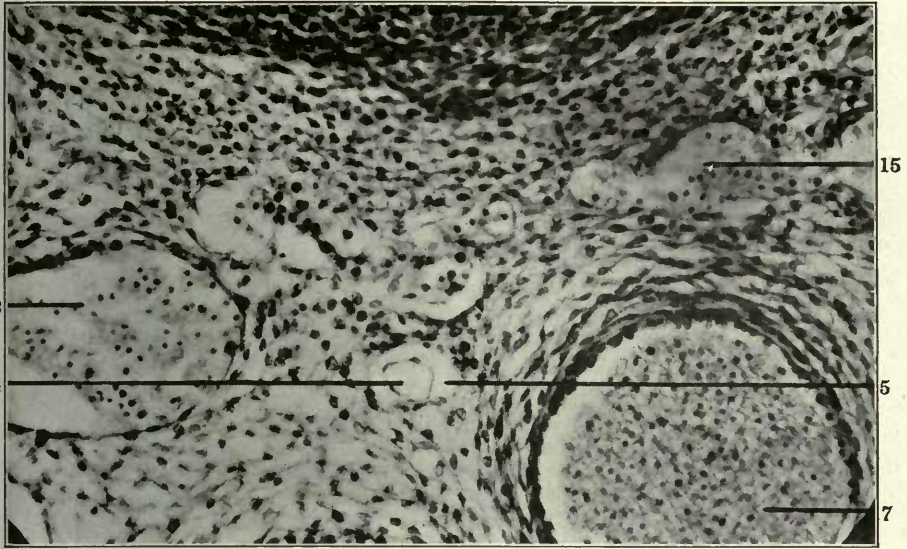
211

FIGURES 212 AND 213

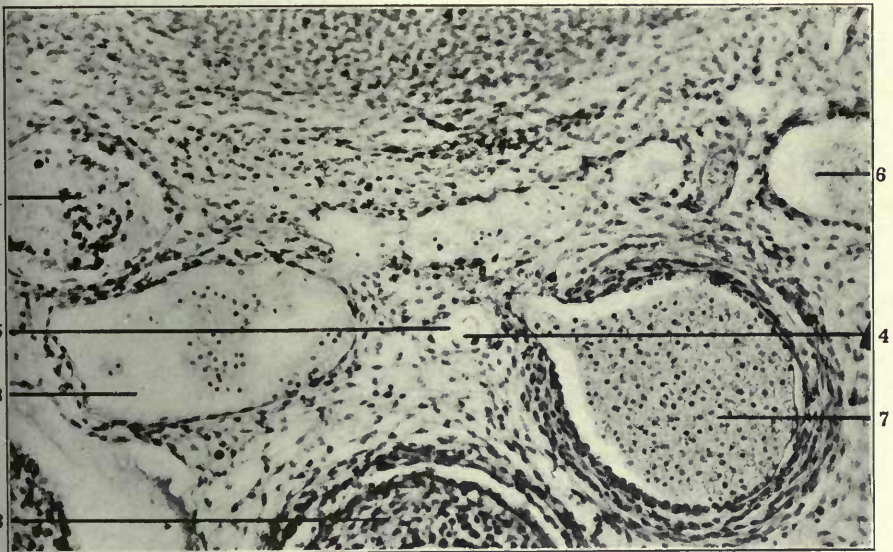
212 Same, section 23.

213 Same, section 28.

- 1 Sympathetic nerve.
- 3 Right azygos vein, thoracic portion.
- 4 Atrophying embryonal vein, forming kernel in interior of developing and replacing lymphatic space.
- 5 Extraintimal or perivenous lymphatic space surrounding degenerating embryonal vein.
- 6 Left azygos vein, thoracic portion.
- 7 Aorta.
- 8 Oesophagus.
- 15 Interazygos venous plexus.



212



213

FIGURES 214 TO 217

214 Transverse section through middle thoracic region in a 14 mm. cat embryo, (series 214, slide XIV, section 15) \times 225.

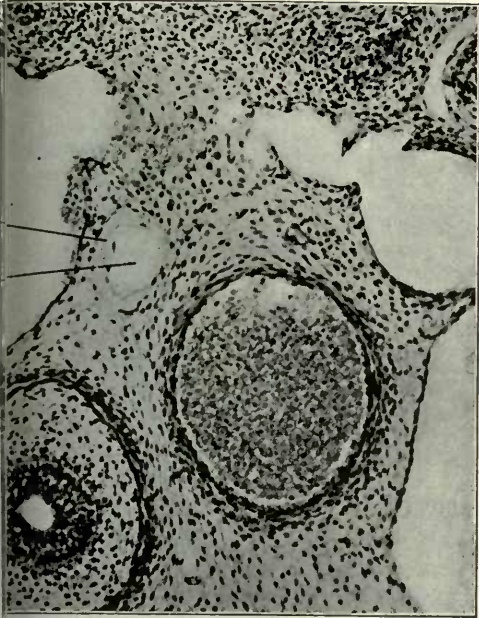
215 Same, section 16.

216 Same, section 17.

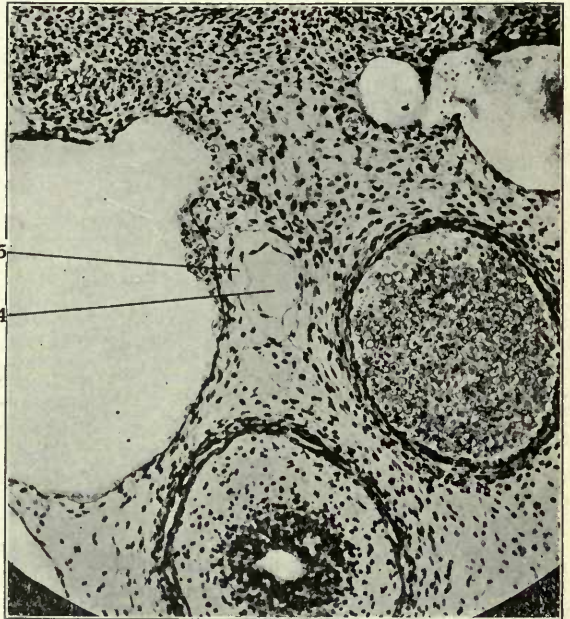
217 Same, section 19.

4 Atrophying embryonal vein, forming kernel in interior of developing and replacing lymphatic space.

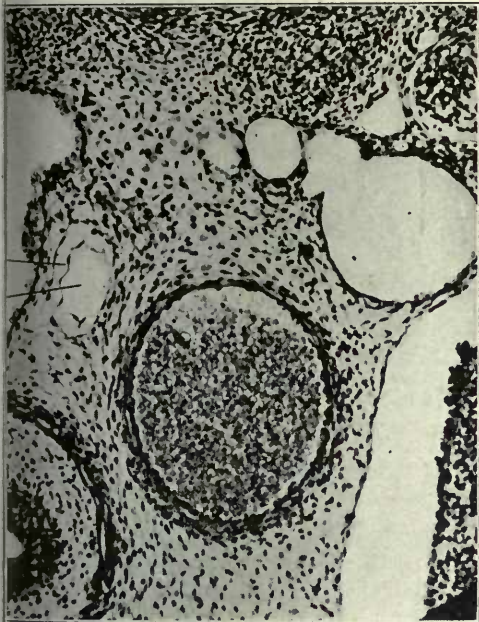
5 Extraintimal or perivenous lymphatic space surrounding degenerating embryonal vein.



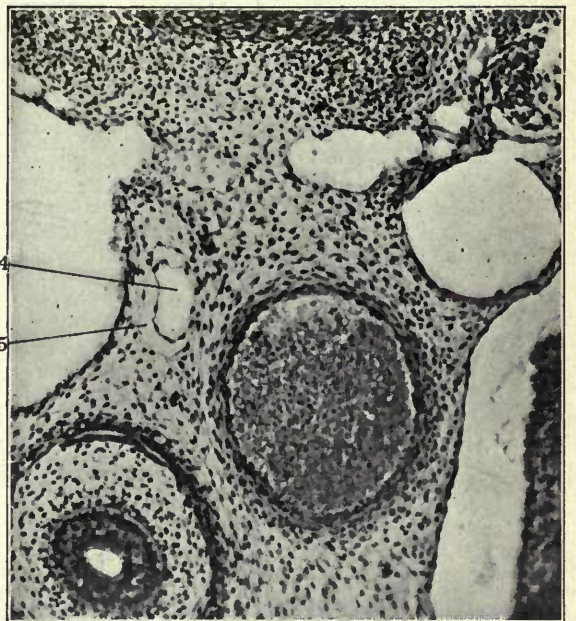214



215



216

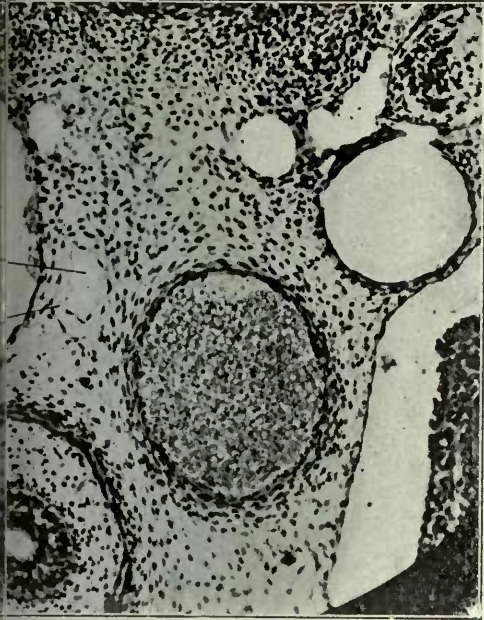


217

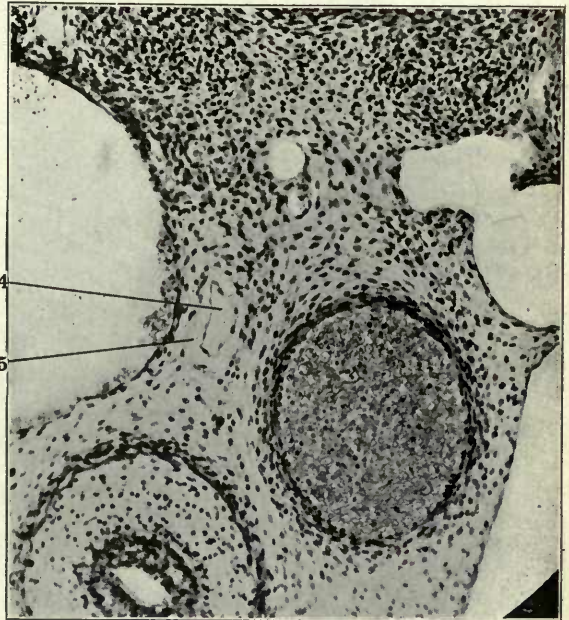
FIGURES 218 TO 221

- 218 Same, section 20.
- 219 Same, section 22.
- 220 Same, section 26.
- 221 Same, section 27.

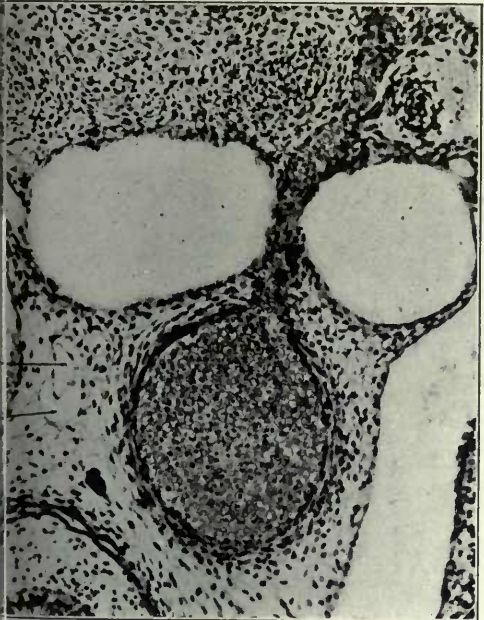
- 4 Atrophying embryonal vein, forming kernel in interior of developing and replacing lymphatic space.
- 5 Extraintimal or perivenous lymphatic space surrounding degenerating embryonal vein.



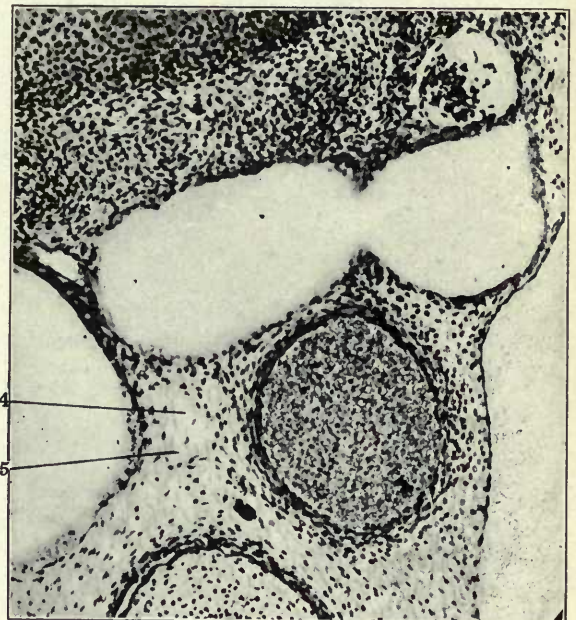218



219



220

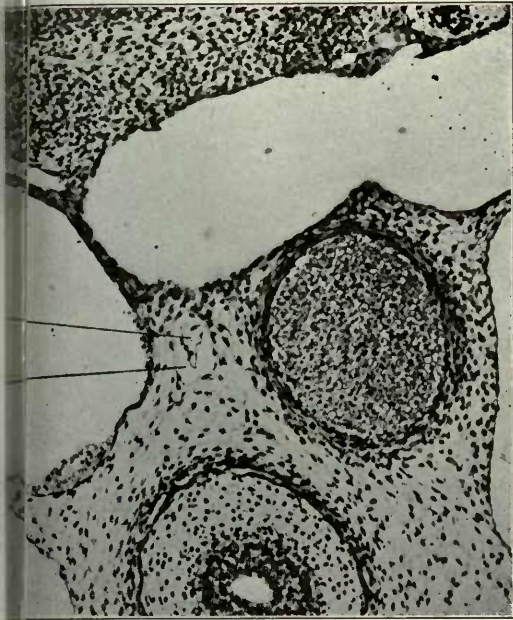


221

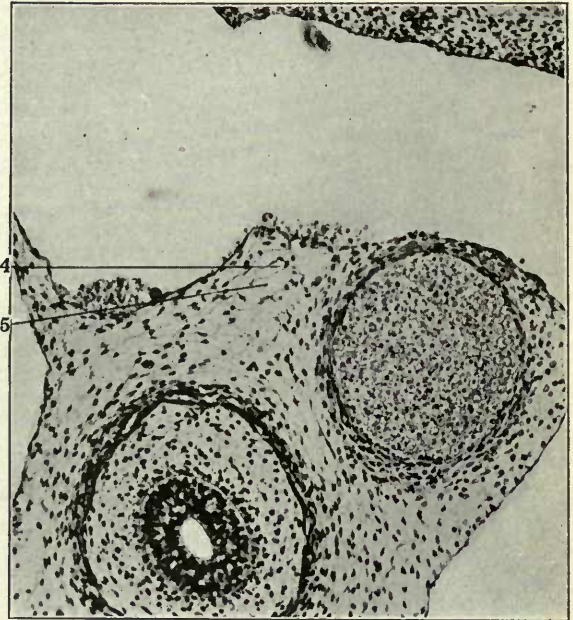
FIGURES 222 TO 225

- 222 Same, section 28.
- 223 Same, section 32.
- 224 Same, section 34.
- 225 Same, section 1.

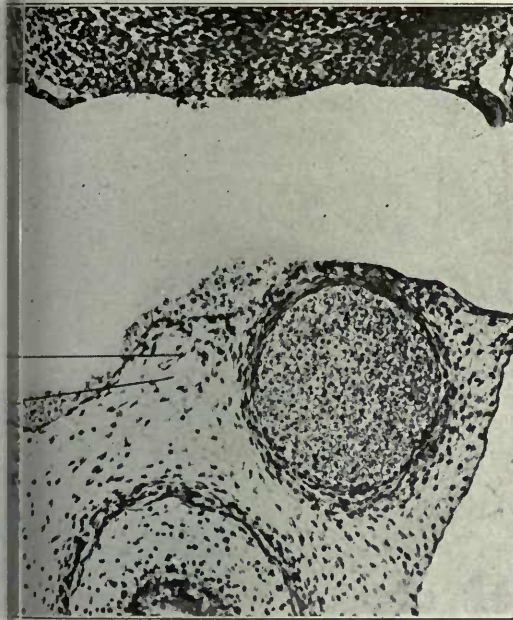
- 1 Sympathetic nerve.
- 2 Intersegmental arteries.
- 3 Right azygos vein, thoracic portion.
- 4 Atrophying embryonal vein, forming kernel in interior of developing and replacing lymphatic space.
- 5 Extraintimal or perivenous lymphatic space surrounding degenerating embryonal vein.
- 6 Left azygos vein, thoracic portion.
- 7 Aorta.
- 8 Oesophagus.
- 16 Interazygos venous plexus.



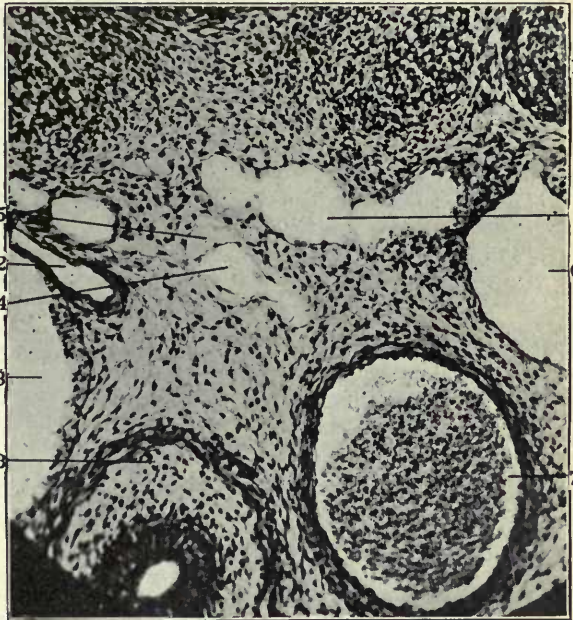
222



223



224

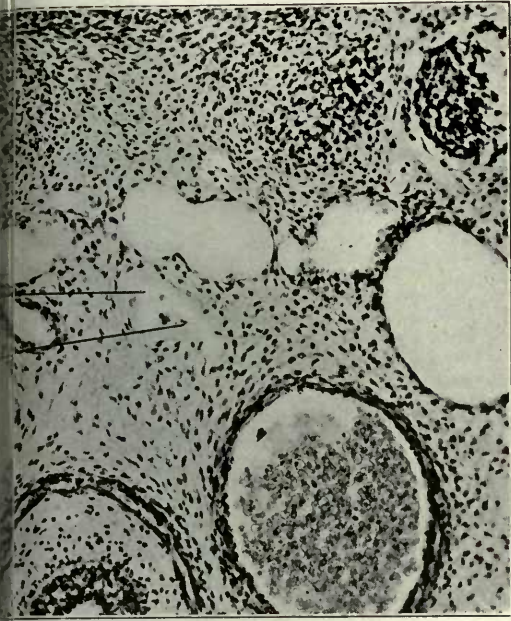


225

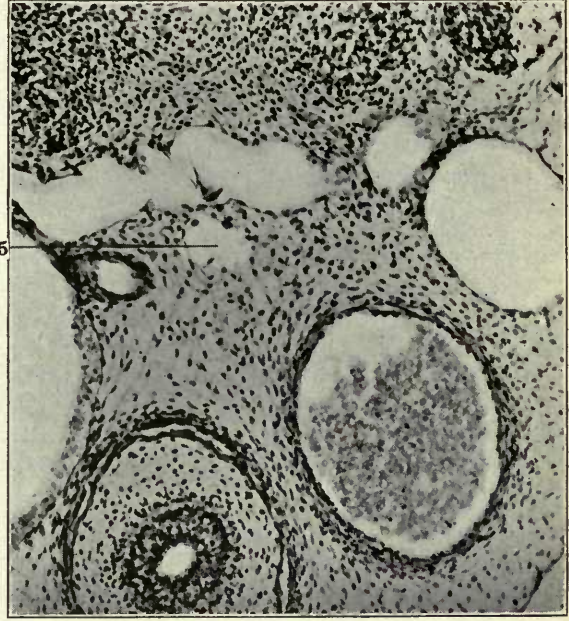
FIGURES 226 TO 229

- 226 Same, section 2.
- 227 Same, section 3.
- 228 Same, section 4.
- 229 Same, section 5.

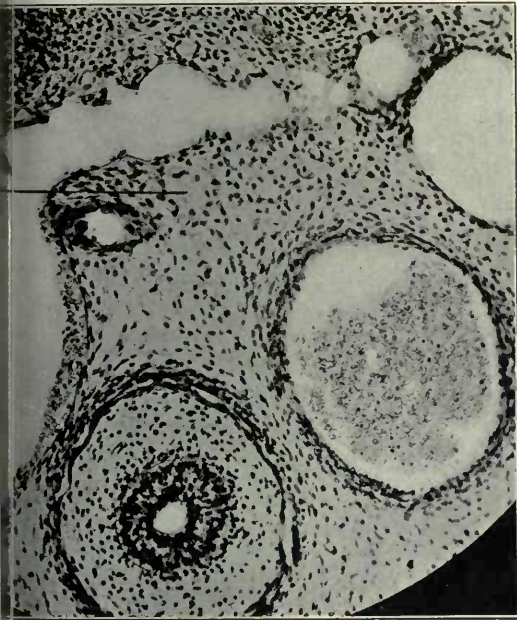
- 4 Atrophying embryonal vein, forming kernel in interior of developing and replacing lymphatic space.
- 5 Extraintimal or perivenous lymphatic space surrounding degenerating embryonal vein.



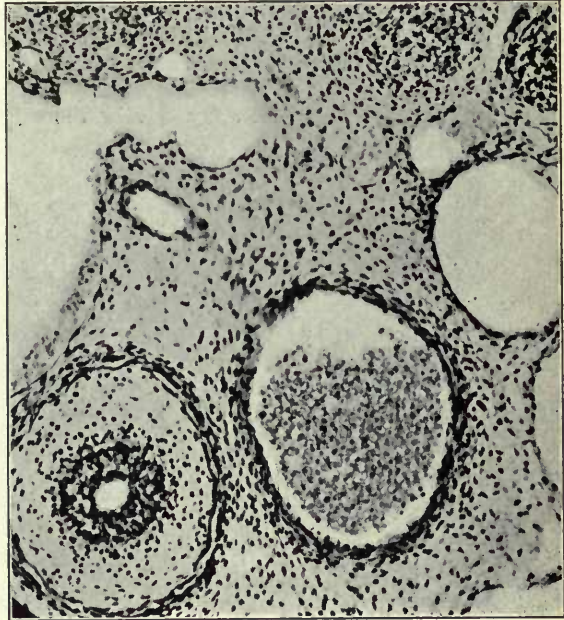226



227



228

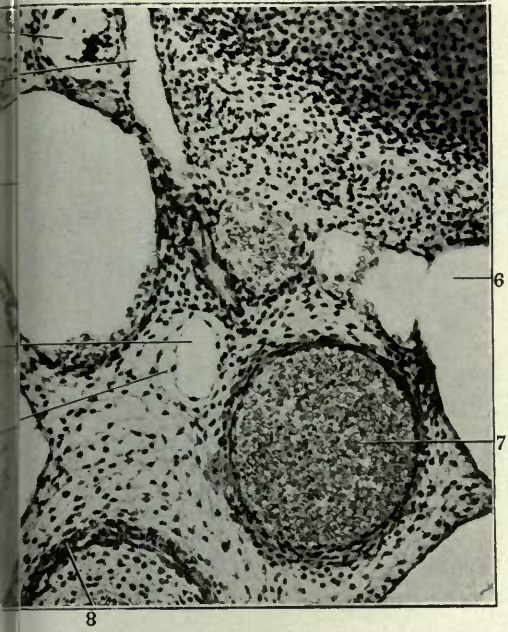


229

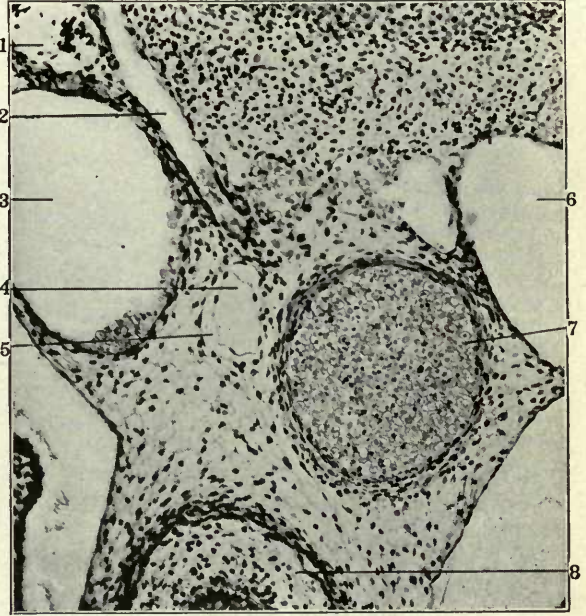
FIGURES 230 TO 233

- 230 Same, slide XV, section 10.
- 231 Same, section 11.
- 232 Same, section 14.
- 233 Same, section 16.

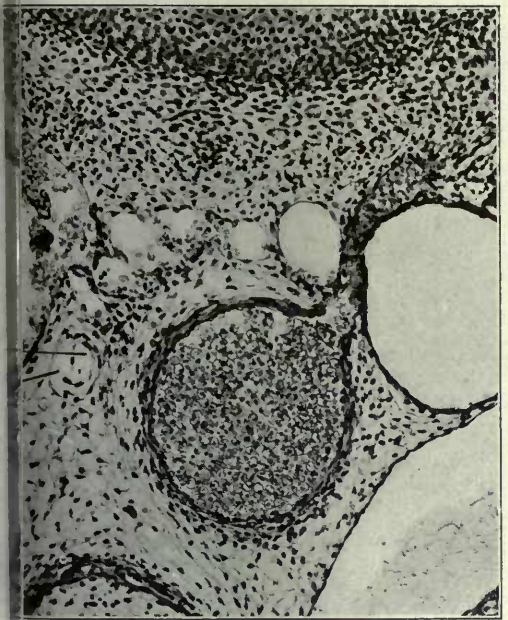
- 1 Sympathetic nerve.
- 2 Intersegmental arteries.
- 3 Right azygos vein, thoracic portion.
- 4 Atrophying embryonal vein, forming kernel in interior of developing and replacing lymphatic space.
- 5 Extraintimal or perivenous lymphatic space surrounding degenerating embryonal vein.
- 6 Left azygos vein, thoracic postion.
- 7 Aorta.
- 8 Oesophagus.



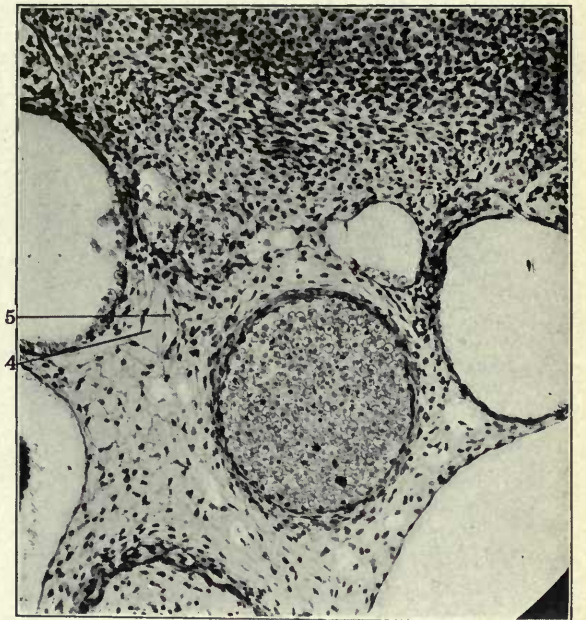230



231



232

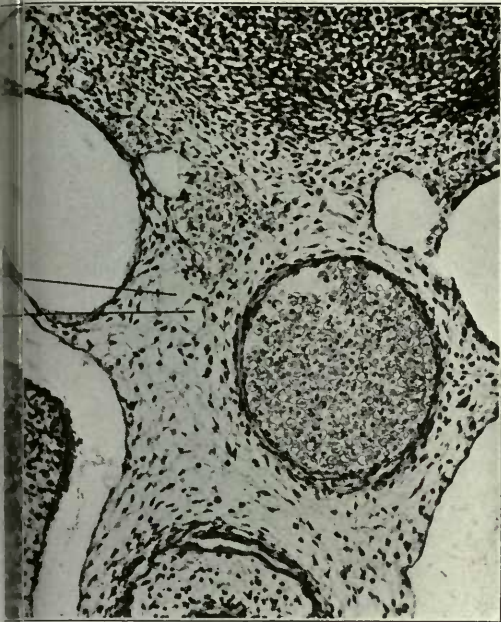


233

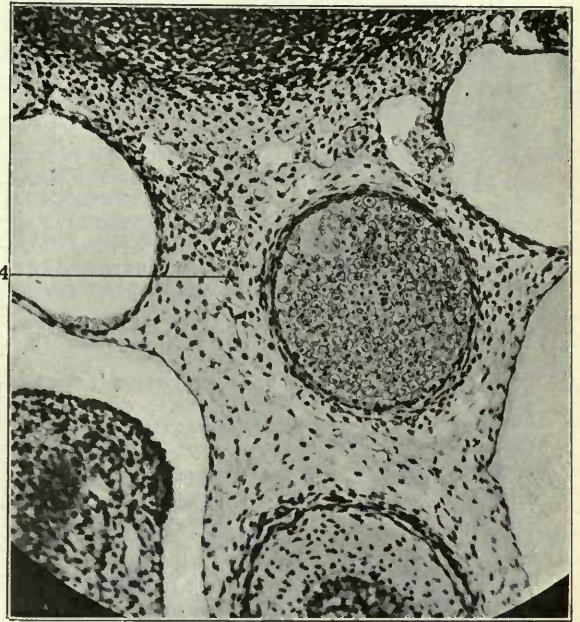
FIGURES 234 TO 237

- 234 Same, section 19.
- 235 Same, section 21.
- 236 Same, section 27.
- 237 Same, section 28.

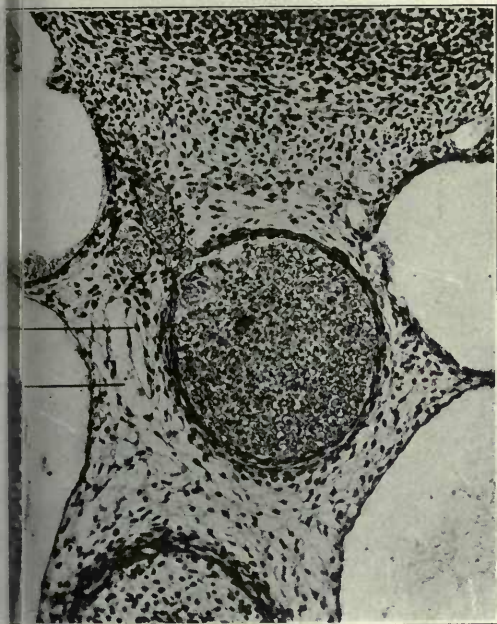
- 4 Atrophying embryonal vein, forming kernel in interior of developing and replacing lymphatic space.
- 5 Extraintimal or perivenous lymphatic space surrounding degenerating embryonal vein.



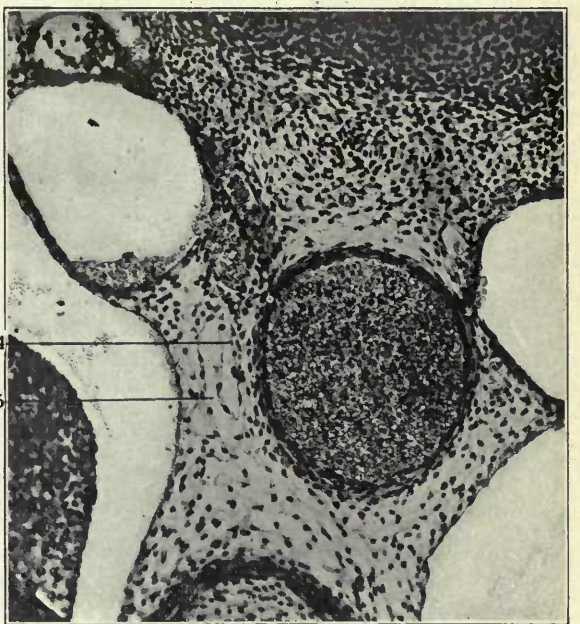
234



235



236



237

EXPLANATION OF FIGURES 238, 239 AND 240

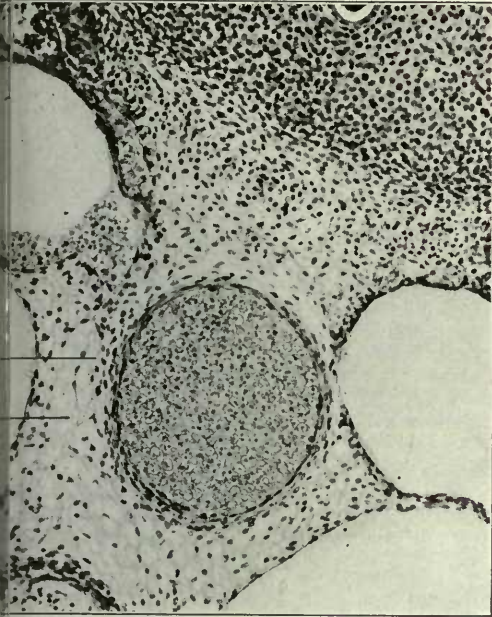
238 Same, section 29.

239 Same, section 30.

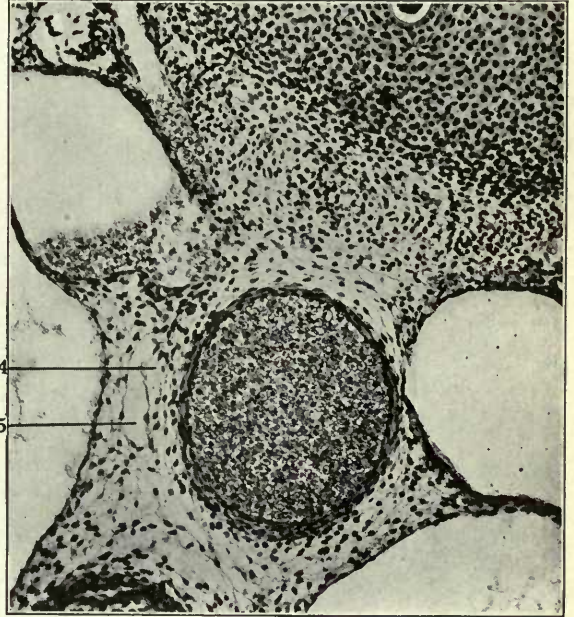
240 Same, section 31.

4 Atrophying embryonal vein, forming kernel in interior of developing and replacing lymphatic space.

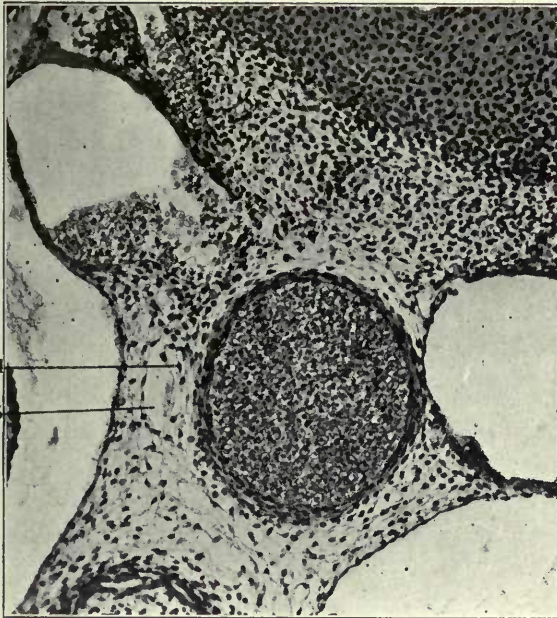
5 Extraintimal or perivenous lymphatic space surrounding degenerating embryonal vein.



238



239

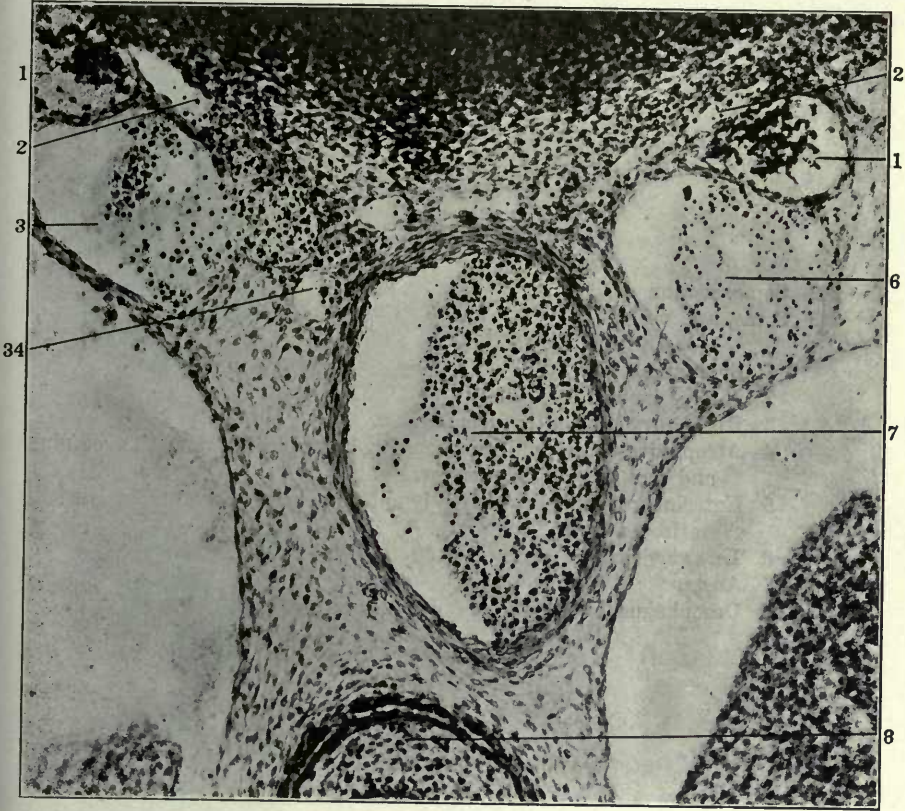


240

FIGURE 241

241 Transverse section of lower thoracic region of 14 mm. cat embryo
(series 127, slide X, section 3) \times 225.

- 1 Sympathetic nerve.
- 2 Intersegmental arteries.
- 3 Right azygos vein, thoracic portion.
- 6 Left azygos vein, thoracic portion.
- 7 Aorta.
- 8 Oesophagus.
- 34 Ventro-medial azygos plexus.



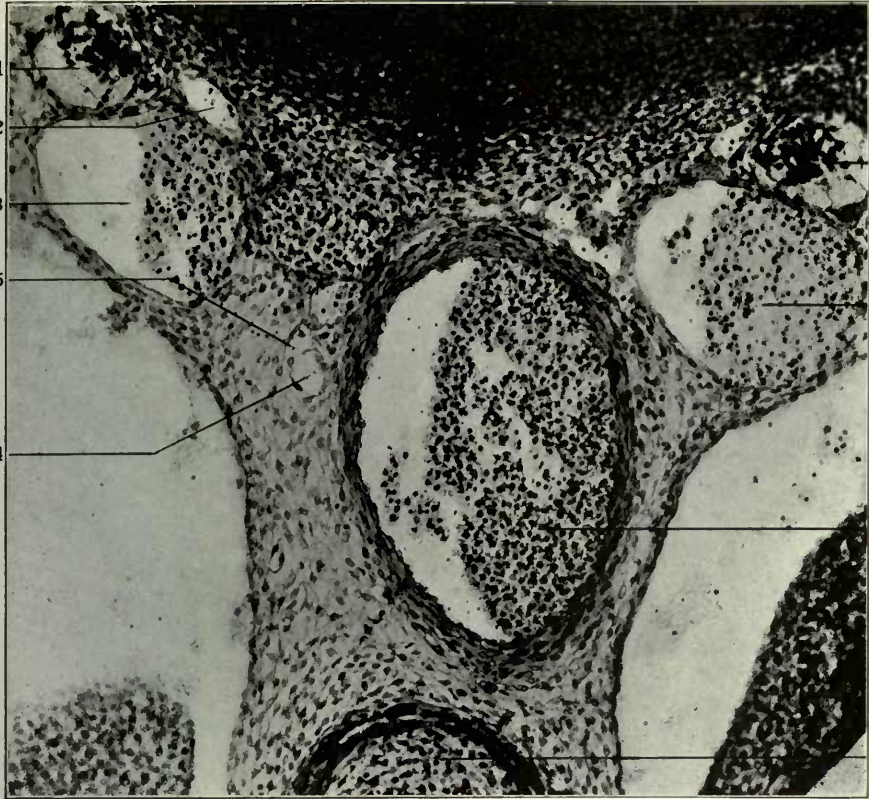
241

FIGURES 242 AND 243

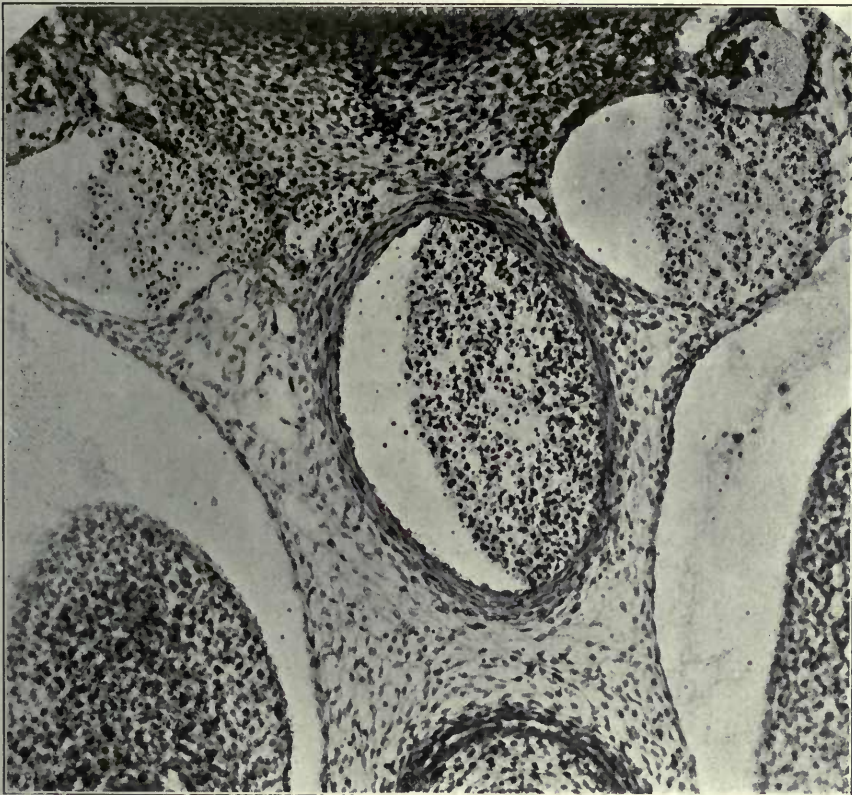242 Same, section 4.

243 Same, section 10.

- 1 Sympathetic nerve.
- 2 Intersegmental arteries.
- 3 Right azygos vein, thoracic portion.
- 4 Atrophying embryonal vein, forming kernel in interior of developing and replacing lymphatic space.
- 5 Extraintimal or perivenous lymphatic space surrounding degenerating embryonal vein.
- 6 Left azygos vein, thoracic portion.
- 7 Aorta.
- 8 Oesophagus.



242

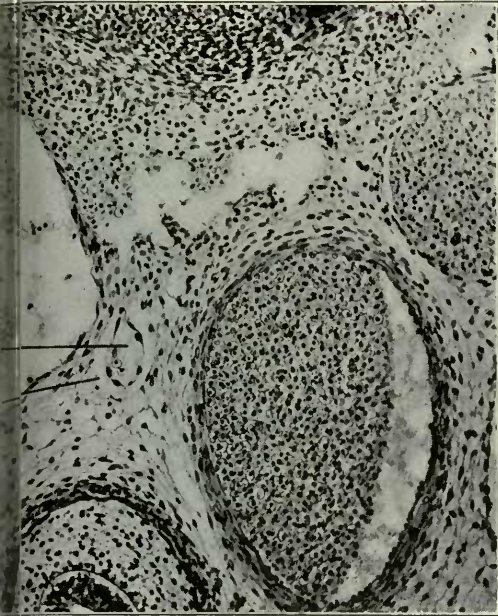

243

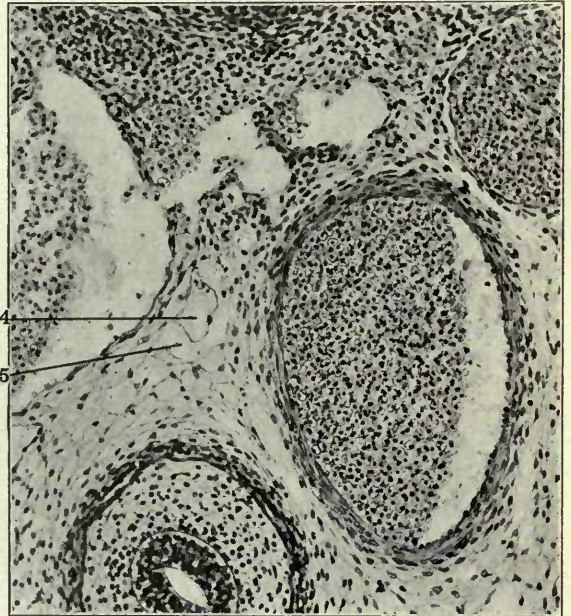
FIGURES 248 TO 251

- 248 Same, section 19.
- 249 Same, section 20.
- 250 Same, section 21.
- 251 Same, section 22.

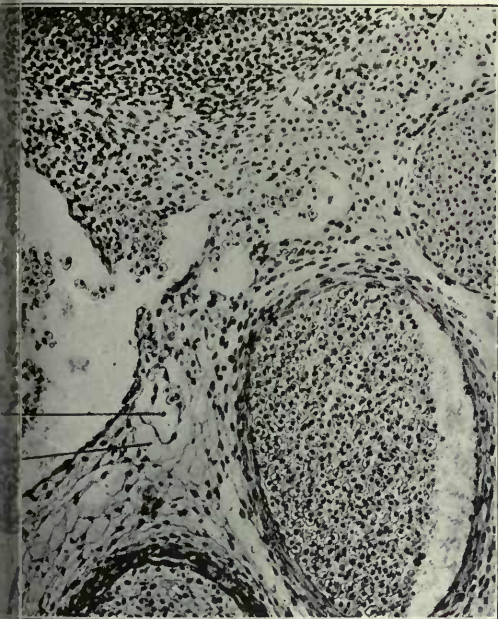
- 4 Atrophying embryonal vein, forming kernel in interior of developing and replacing lymphatic space.
- 5 Extraintimal or perivenous lymphatic space surrounding degenerating embryonal vein.



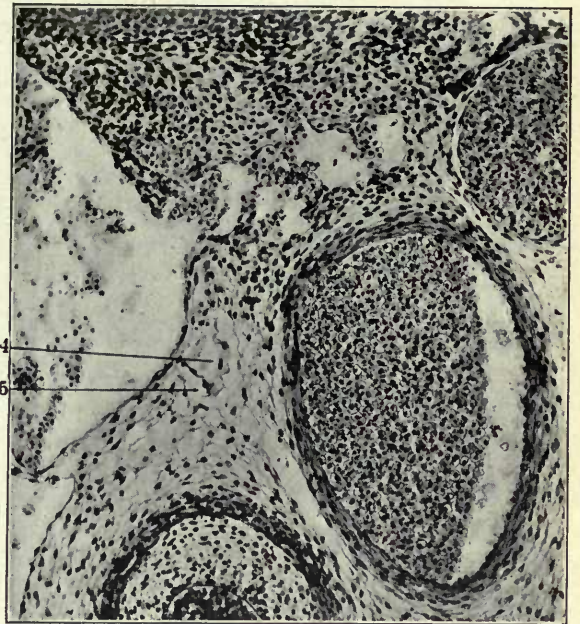
248



249



250

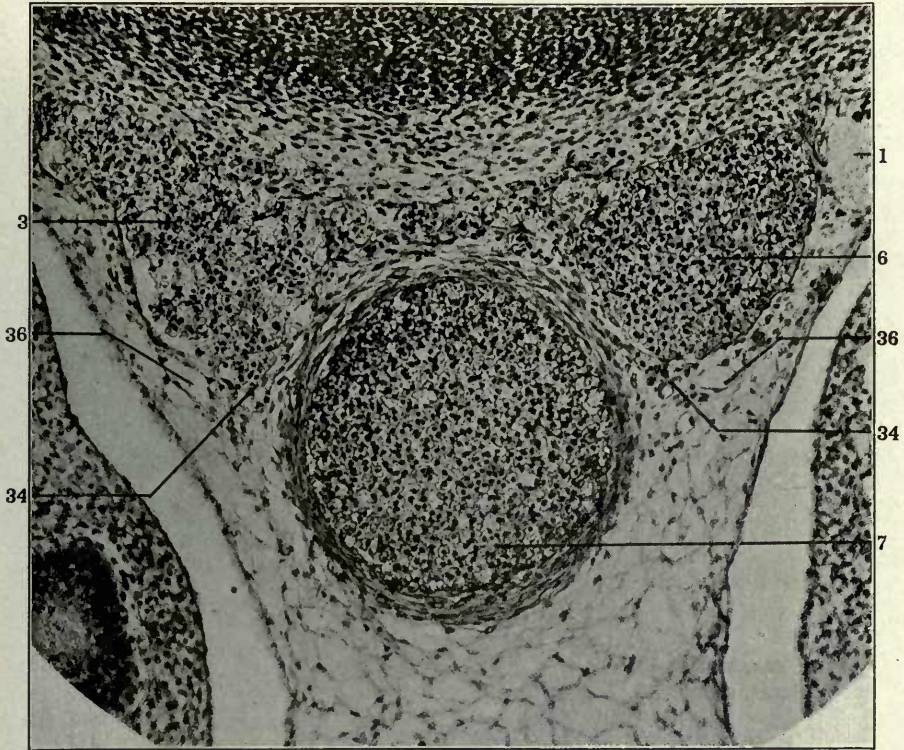


251

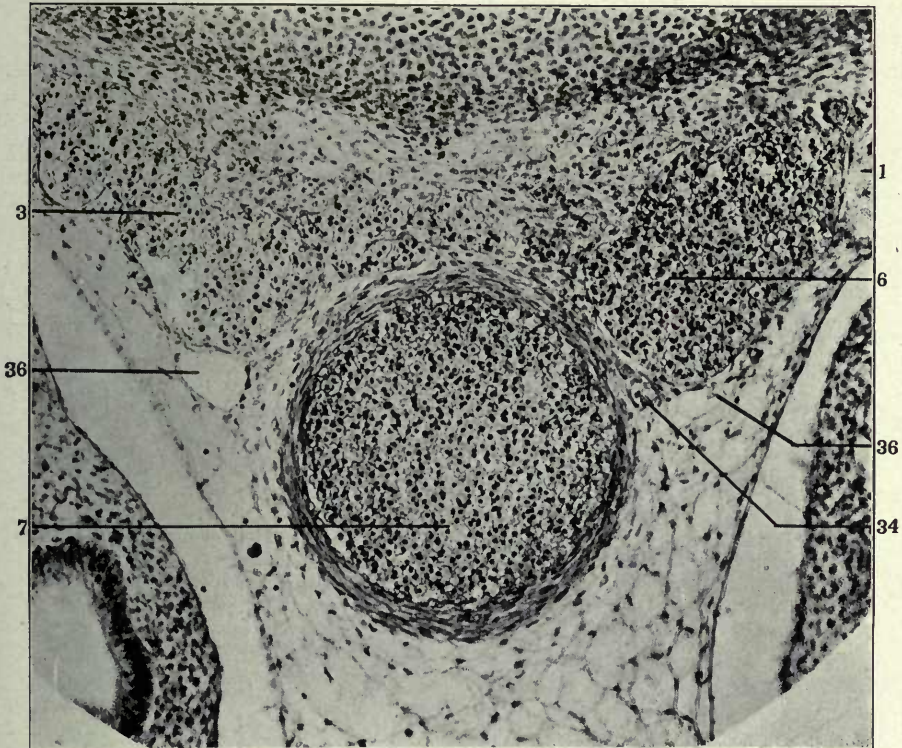
FIGURES 252 AND 253

- 252 Transverse section through lower thoracic region of a 15.5 mm. cat embryo,
(series 143, slide XVIII, section 7) \times 225.
253 Same, section 11.

- 1 Sympathetic nerve.
- 3 Right azygos vein, thoracic portion.
- 6 Left azygos vein, thoracic portion.
- 7 Aorta.
- 34 Ventro-medial azygos plexus.
- 36 Thoracic duct, azygos segment.



252



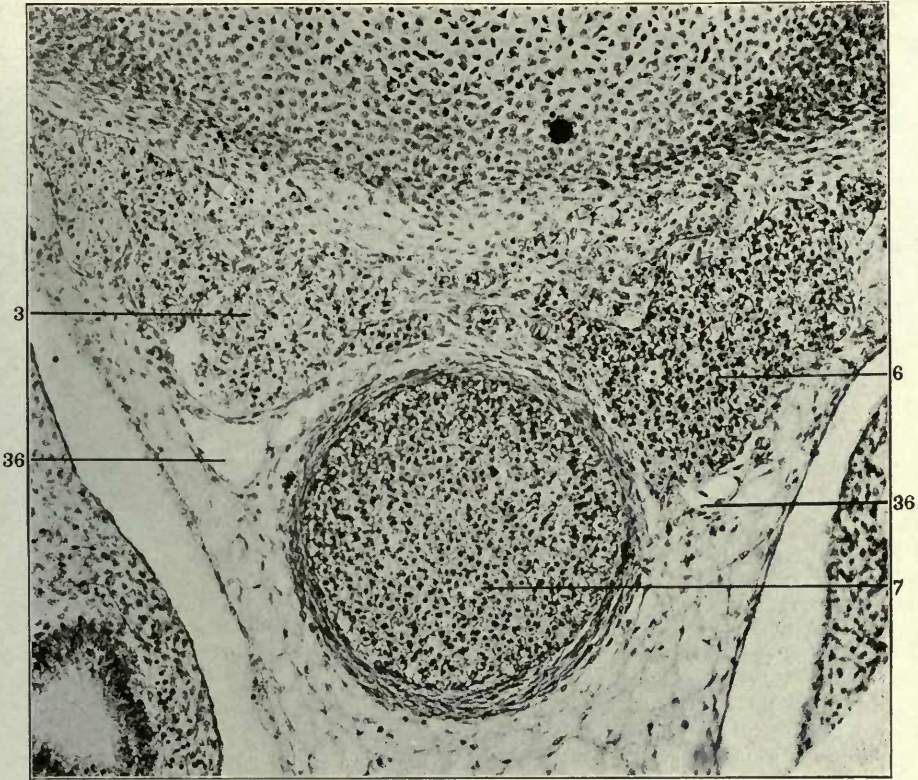
253

FIGURES 254 AND 255

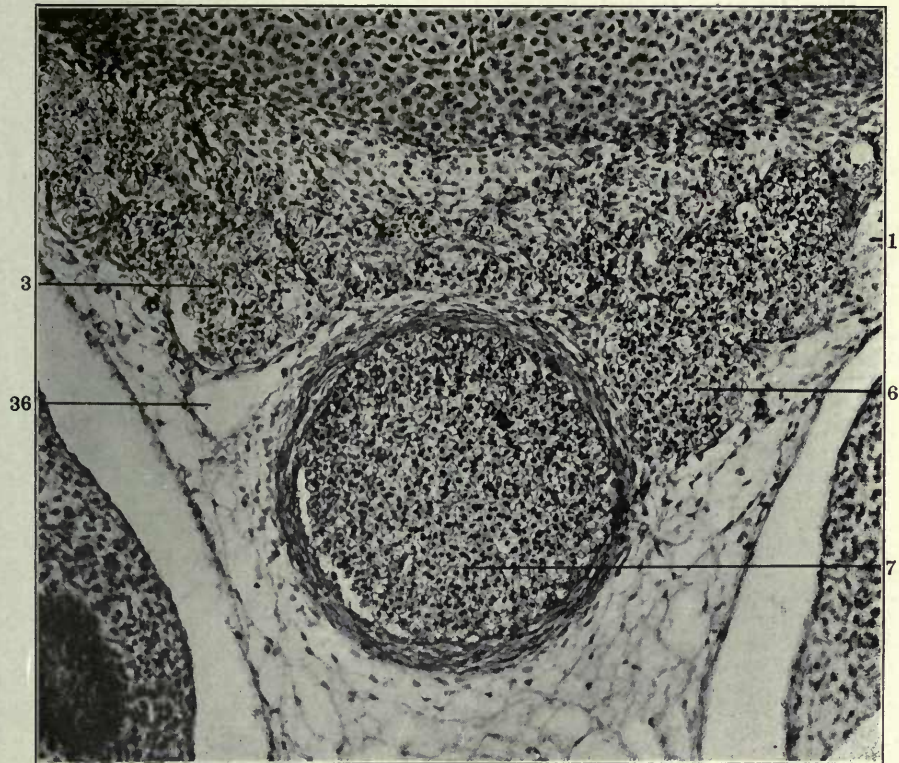
254 Same, section 12.

255 Same, section 13.

- 1 Sympathetic nerve.
- 3 Right azygos vein, thoracic portion.
- 6 Left azygos vein, thoracic portion.
- 7 Aorta.
- 36 Thoracic duct, azygos segment.



254



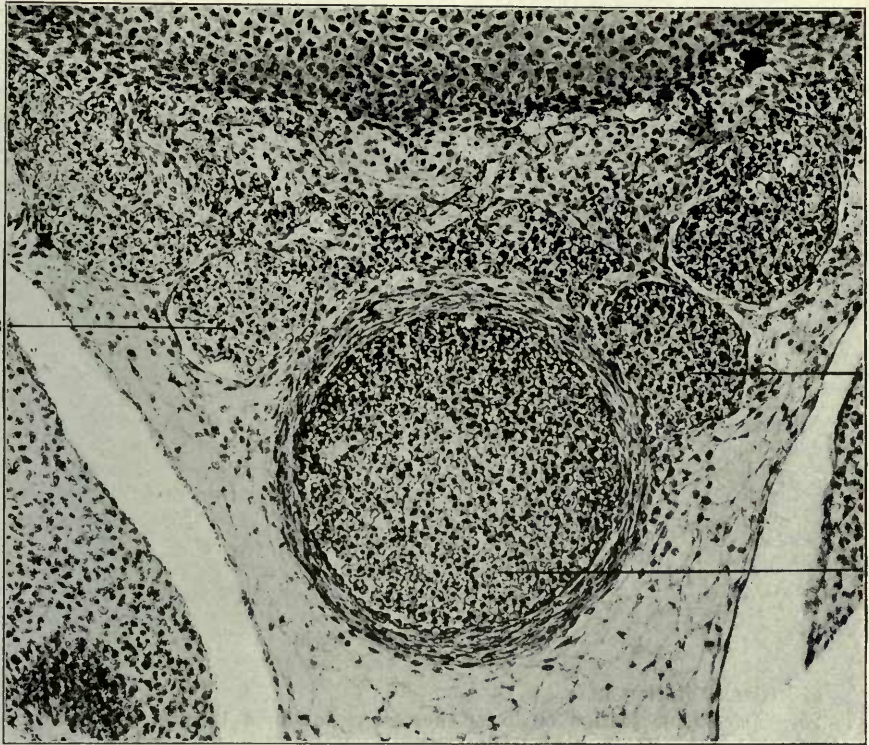
255

FIGURES 256 AND 257

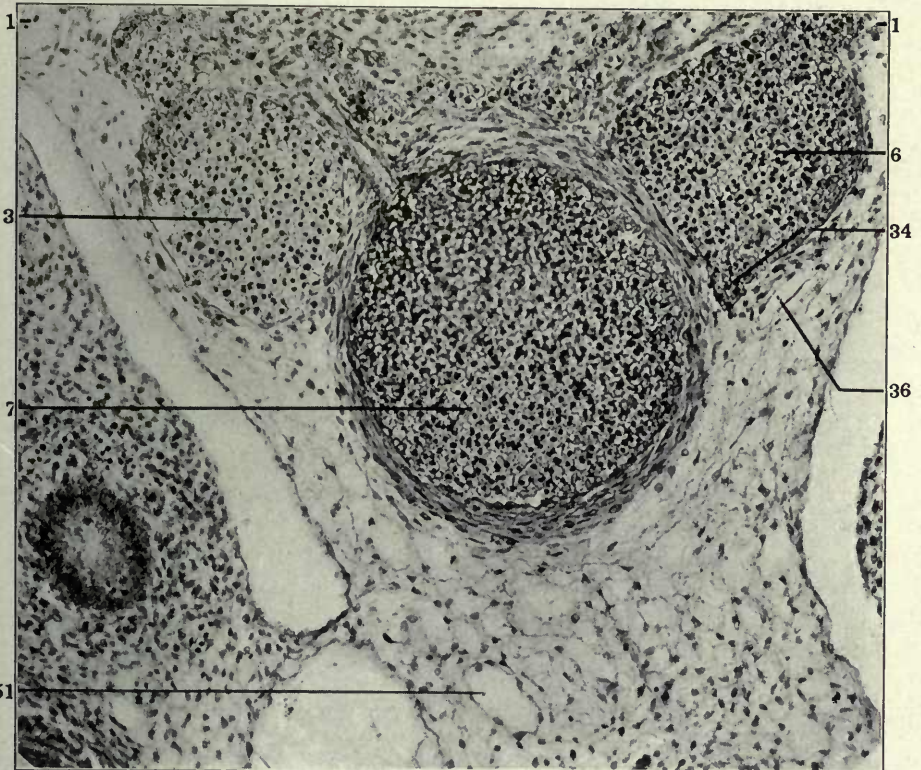
256 Same, section 14.

257 Same, slide XVII, section 31.

- 1 Sympathetic nerve.
- 3 Right azygos vein, thoracic portion.
- 6 Left azygos vein, thoracic portion.
- 7 Aorta.
- 34 Ventro-medial azygos plexus.
- 36 Thoracic duct, azygos segment.
- 51 Mesenteric lymphatics.



256



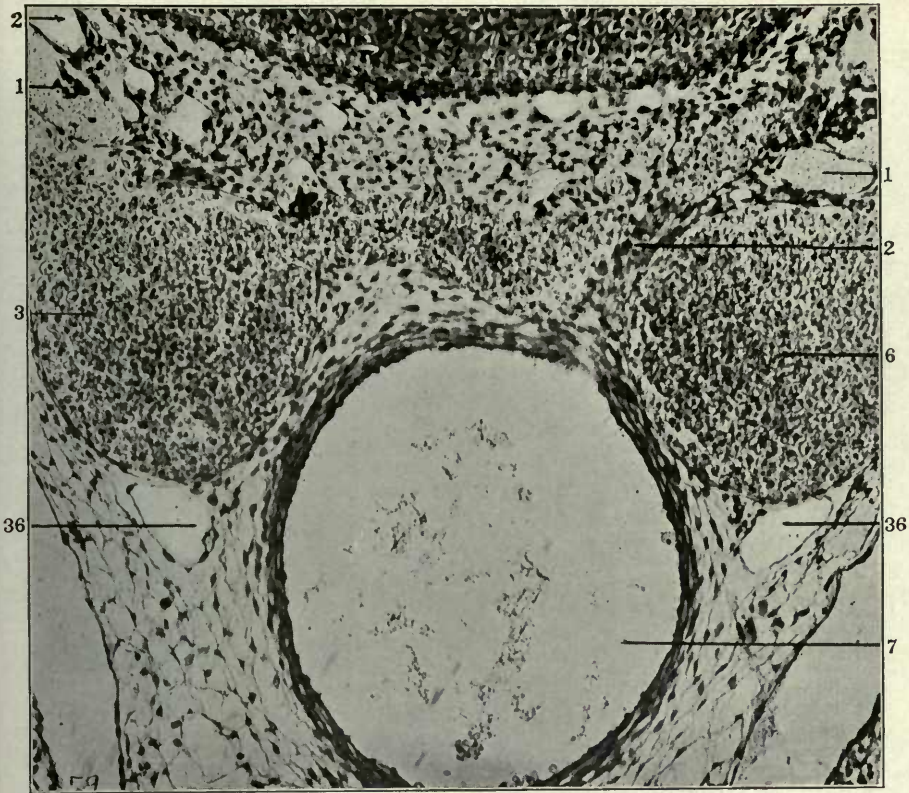
257

FIGURES 260 AND 261

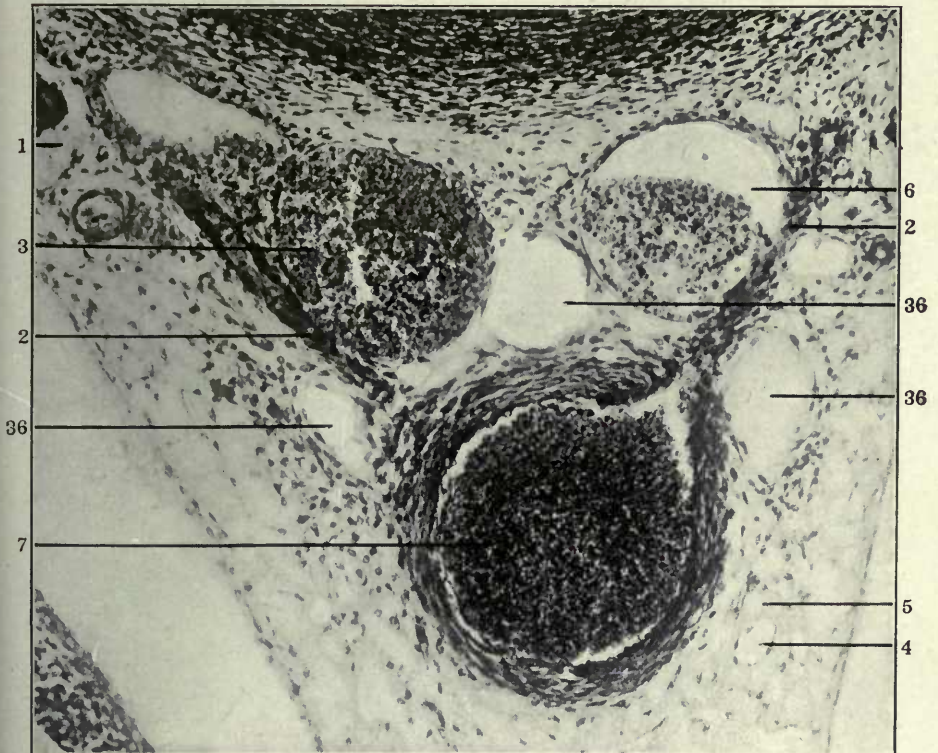
260 Same, section 9.

261 Transverse section of lower thoracic region in a 16 mm. cat embryo, (series 96, slide XII, section 32) \times 200.

- 1 Sympathetic nerve.
- 2 Intersegmental arteries.
- 3 Right azygos vein, thoracic portion.
- 4 Atrophying embryonal vein, forming kernel in interior of developing and replacing lymphatic space.
- 5 Extraintimal or perivenous lymphatic space surrounding degenerating embryonal vein.
- 6 Left azygos vein, thoracic portion.
- 7 Aorta.
- 36 Thoracic duct, azygos segment.



260



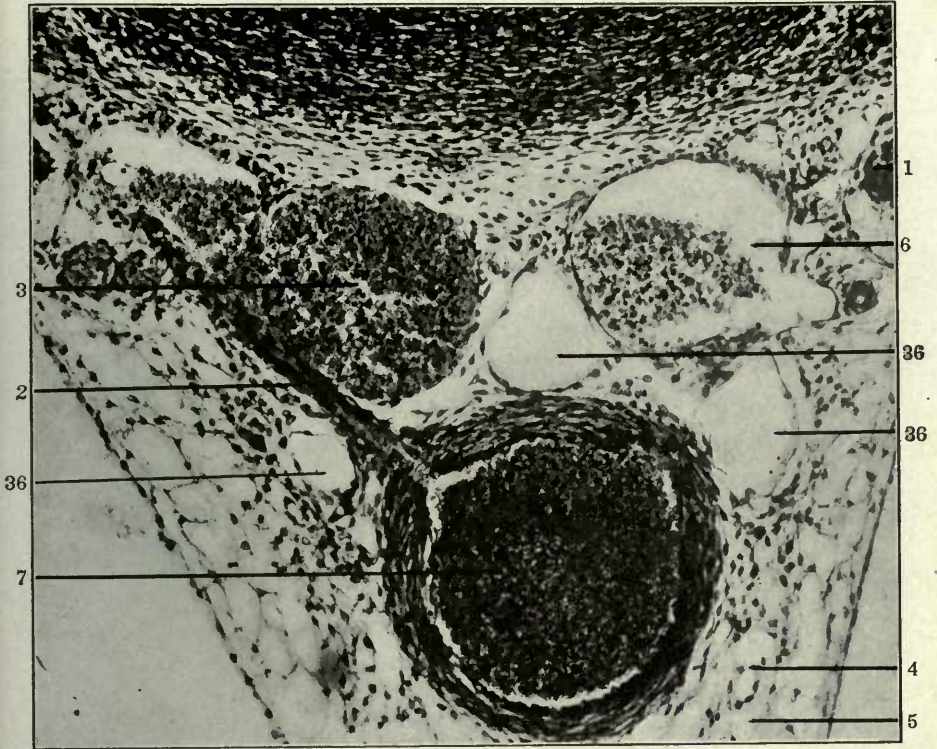
261

FIGURES 262 AND 263

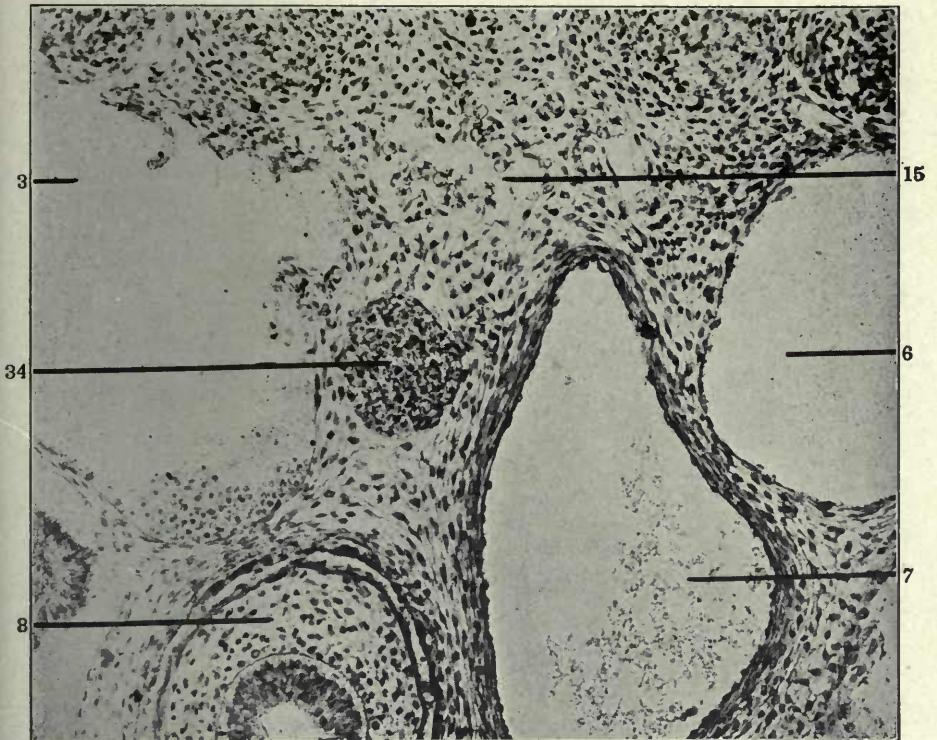
262 Same, section 33.

263 Transverse section of middle thoracic region in a 14 mm. cat embryo, (series 211, slide XII, section 2) \times 225.

- 1 Sympathetic nerve.
- 2 Intersegmental arteries.
- 3 Right azygos vein, thoracic portion.
- 4 Atrophying embryonal vein, forming kernel in interior of developing and replacing lymphatic space.
- 5 Extraintimal or perivenous lymphatic space surrounding degenerating embryonal vein.
- 6 Left azygos vein, thoracic portion.
- 7 Aorta
- 8 Oesophagus.
- 15 Interazygos venous plexus.
- 34 Ventro-medial azygos plexus.
- 36 Thoracic duct, azygos segment.



262



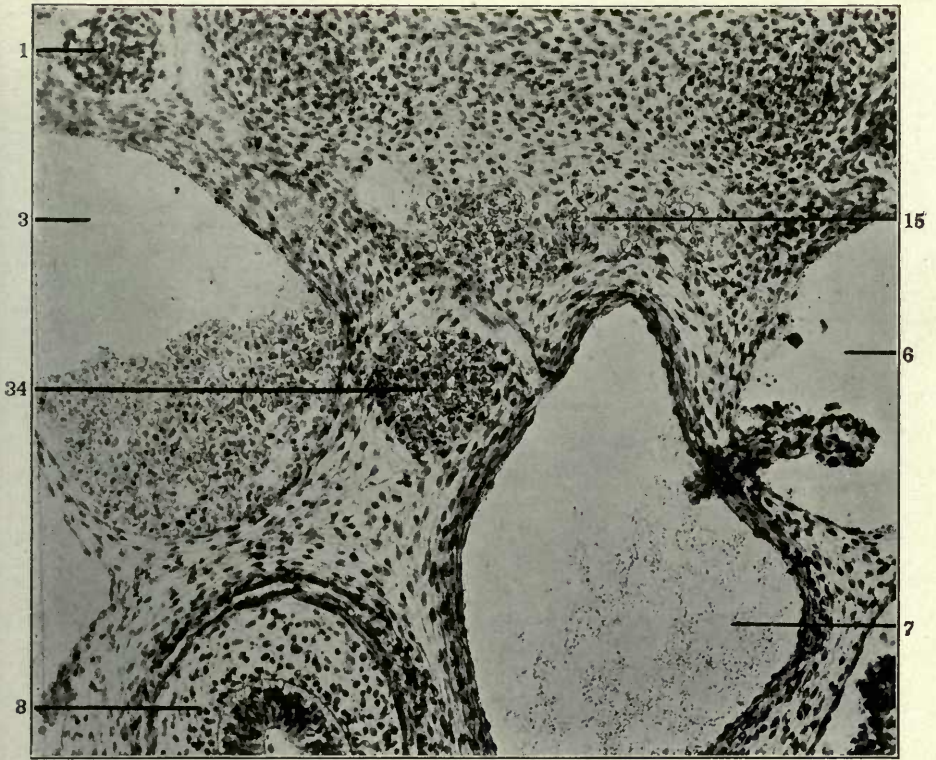
263

FIGURES 264 AND 265

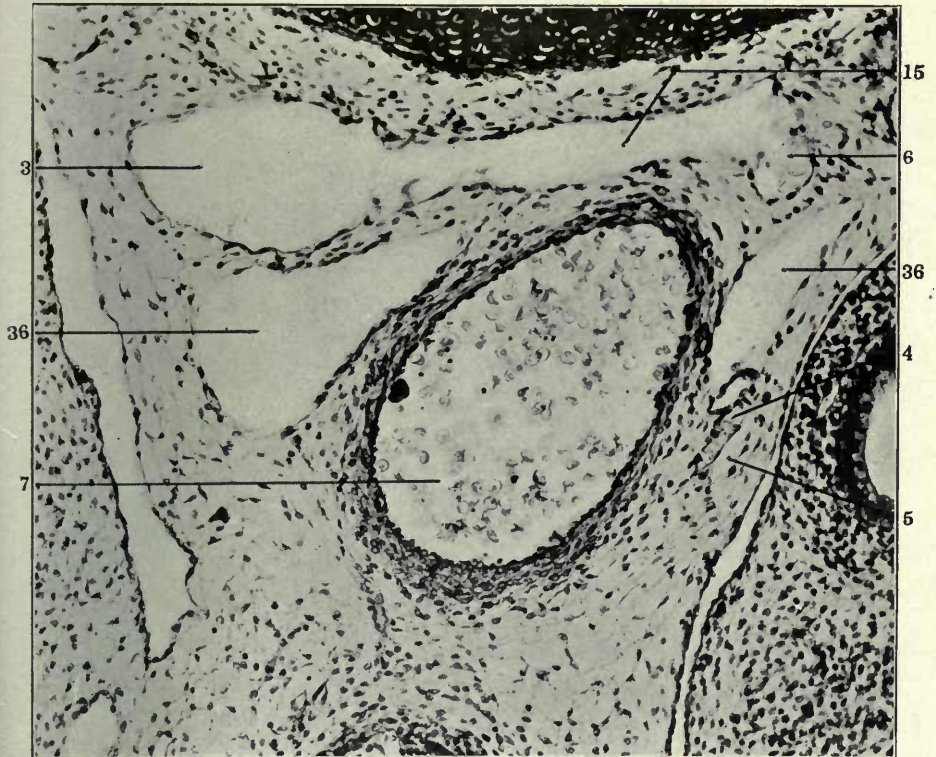
264 Same, section 8.

265 Transverse section of middle thoracic region in a 19 mm. cat embryo, (series 253, slide XXIV, section 9) \times 225.

- 1 Sympathetic nerve.
- 3 Right azygos vein, thoracic portion.
- 4 Atrophying embryonal vein, forming kernel in interior of developing and replacing lymphatic space.
- 5 Extraintimal or perivenous lymphatic space surrounding degenerating embryonal vein.
- 6 Left azygos vein, thoracic portion.
- 7 Aorta.
- 8 Oesophagus.
- 15 Interazygos venous plexus.
- 34 Ventro-medial azygos plexus.
- 36 Thoracic duct, azygos segment.



264



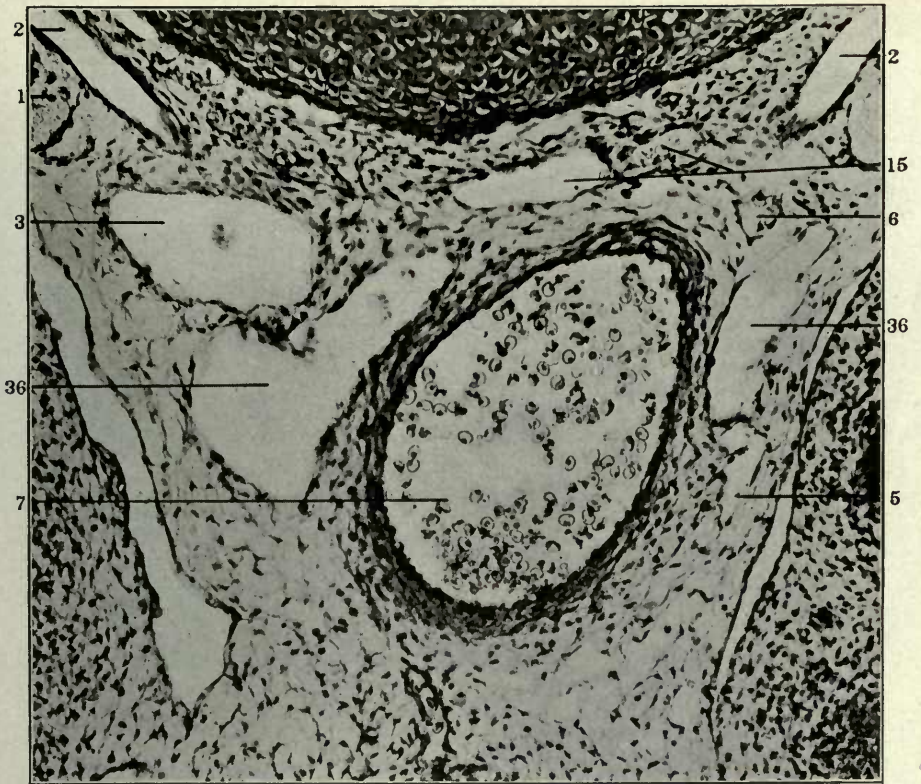
265

FIGURES 266 AND 267

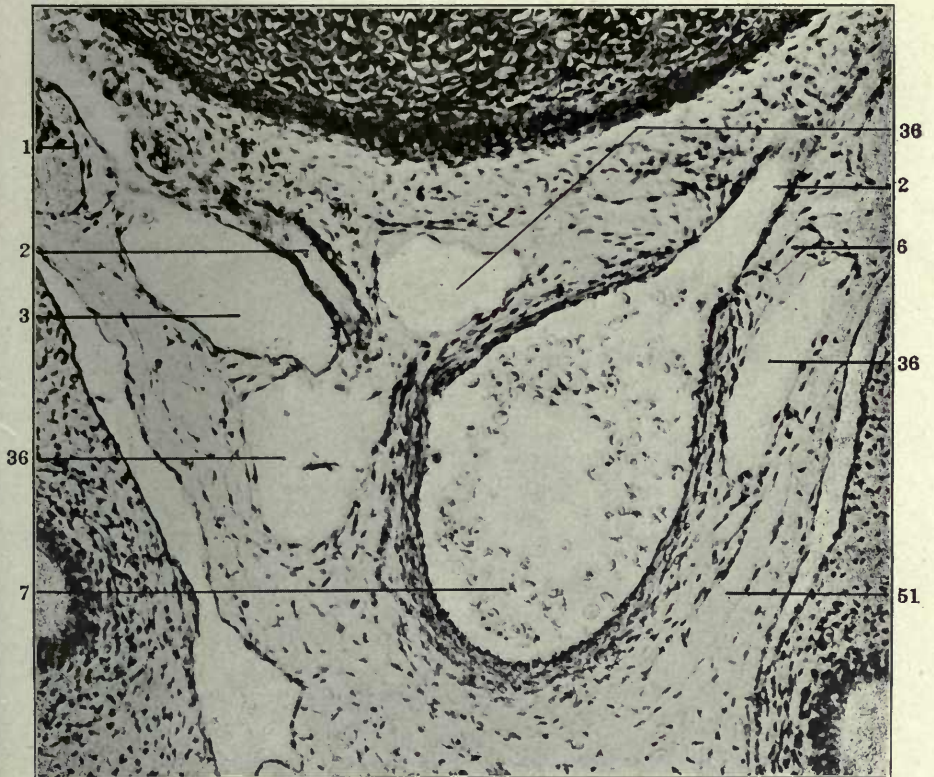
266 Same, section 11.

267 Same, section 15.

- 1 Sympathetic nerve.
- 2 Intersegmental arteries.
- 3 Right azygos vein, thoracic portion.
- 5 Extraintimal or perivenous lymphatic space surrounding degenerating embryonal vein.
- 6 Left azygos vein, thoracic portion.
- 7 Aorta.
- 15 Interazygos venous plexus.
- 36 Thoracic duct, azygos segment.
- 51 Mesenteric lymphatics.



266

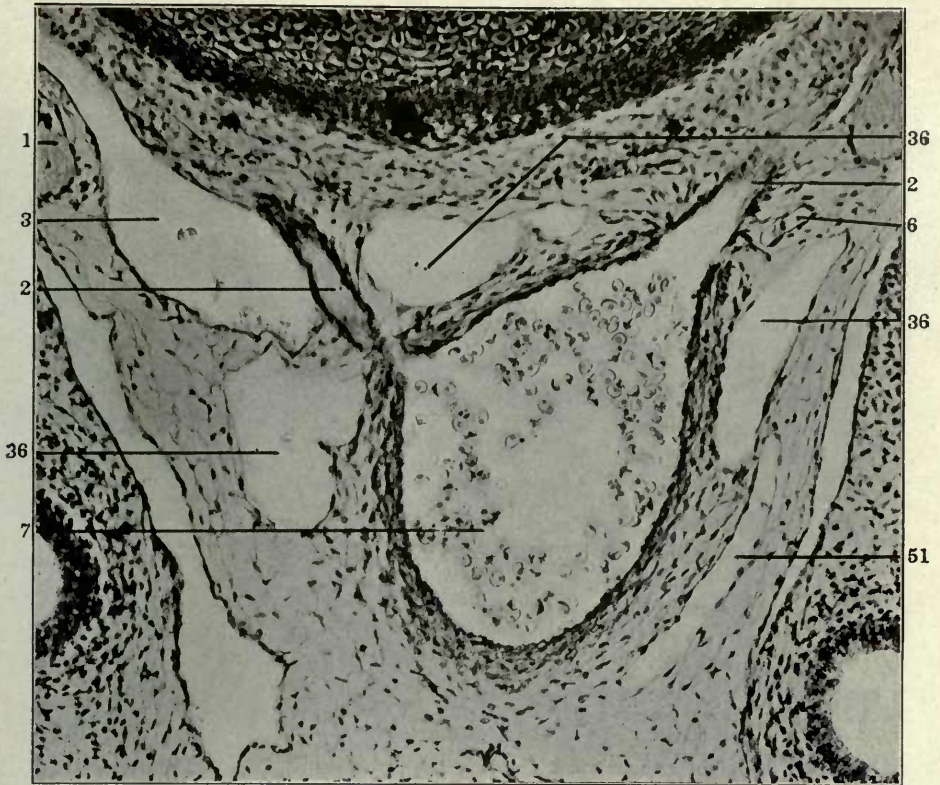


267

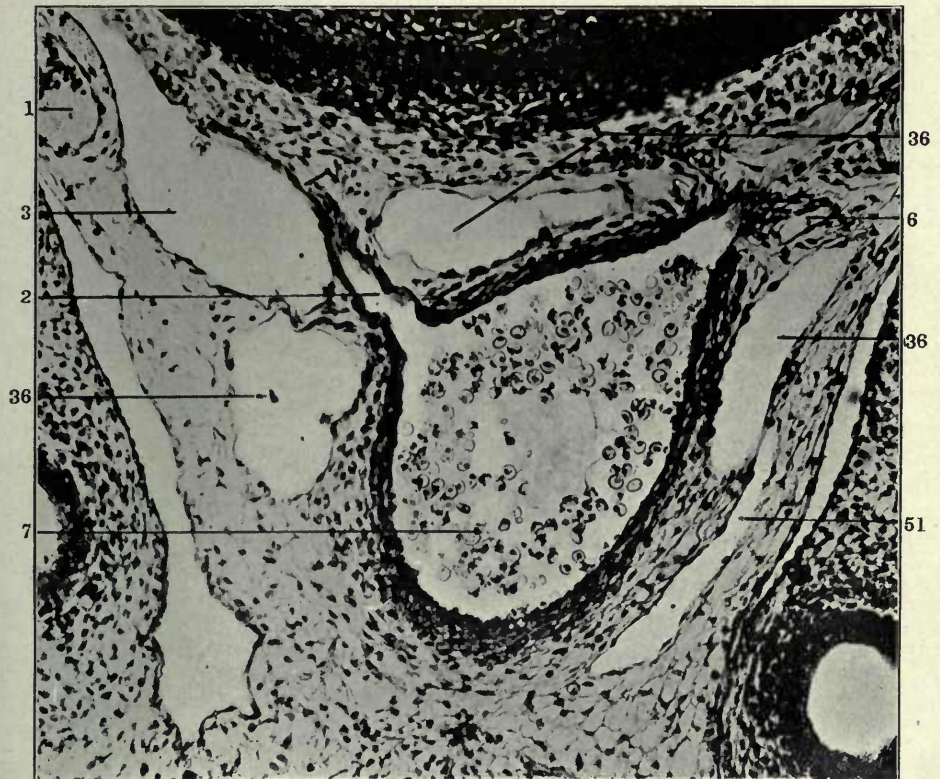
FIGURES 268 AND 269

268 Same, section 16.
269 Same, section 17.

- 1 Sympathetic nerve.
- 2 Intersegmental arteries.
- 3 Right azygos vein, thoracic portion.
- 6 Left azygos vein, thoracic portion.
- 7 Aorta.
- 36 Thoracic duct, azygos segment.
- 51 Mesenteric lymphatics.



268



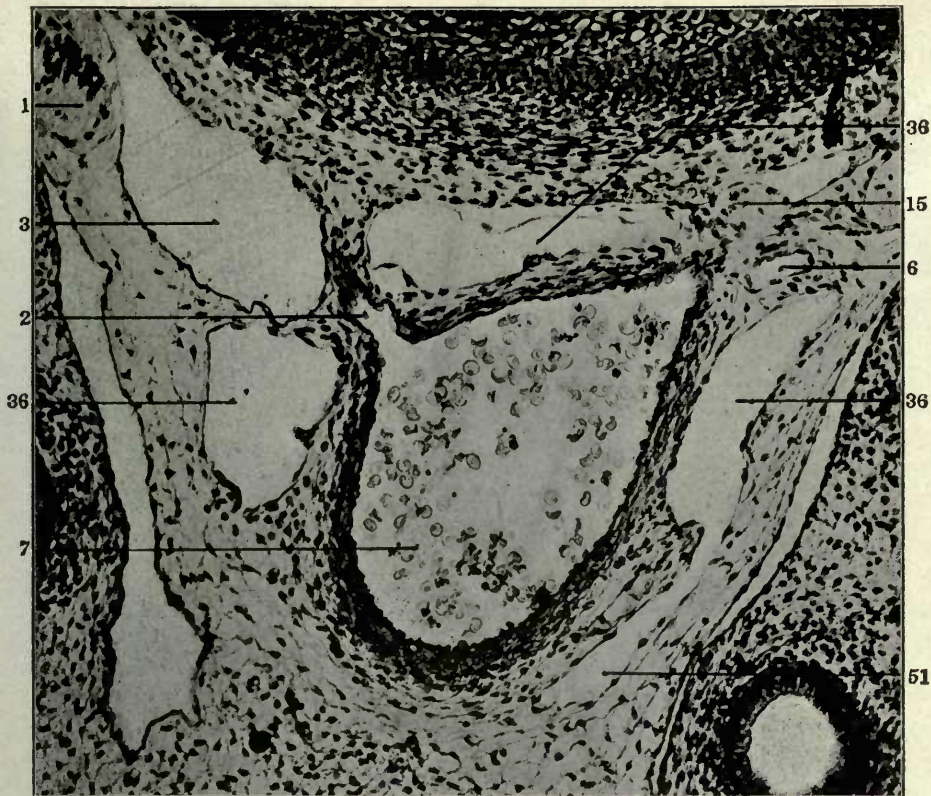
269

FIGURES 270 AND 271

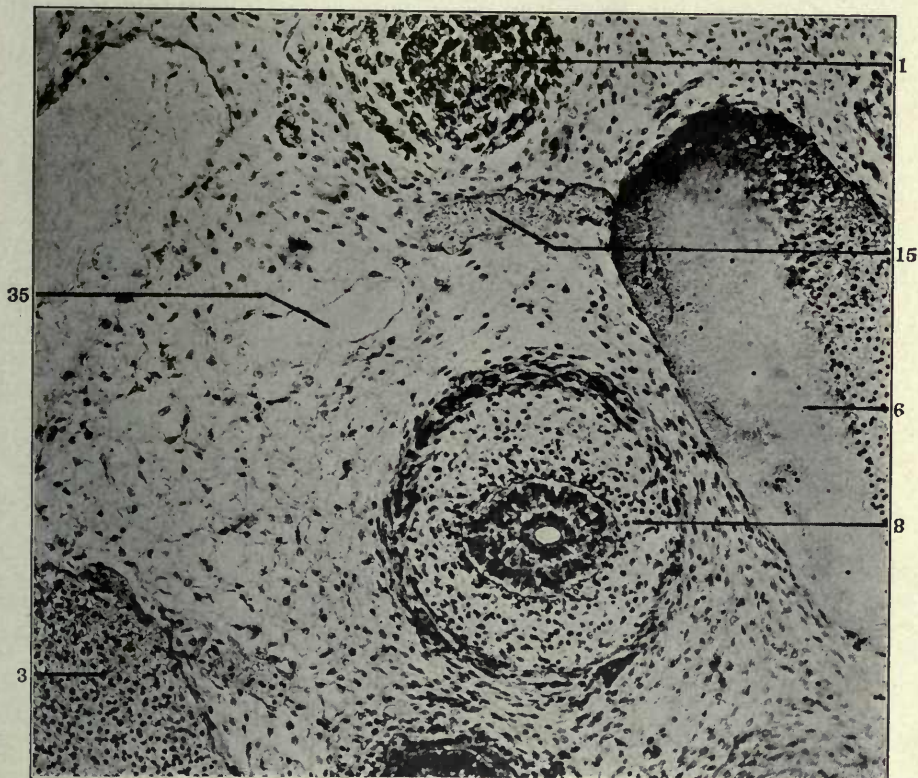
270 Same, section 18.

271 Transverse section of anterior thoracic region in a 15.5 mm. cat embryo (series 143, slide XII, section 22), $\times 200$.

- 1 Sympathetic nerve.
- 2 Intersegmental arteries.
- 3 Right azygos vein, thoracic portion.
- 6 Left azygos vein, thoracic portion.
- 7 Aorta.
- 8 Oesophagus.
- 15 Interazygos venous plexus.
- 35 Thoracic duct, preazygos segment.
- 36 Thoracic duct, azygos segment.
- 51 Mesenteric lymphatics.



270



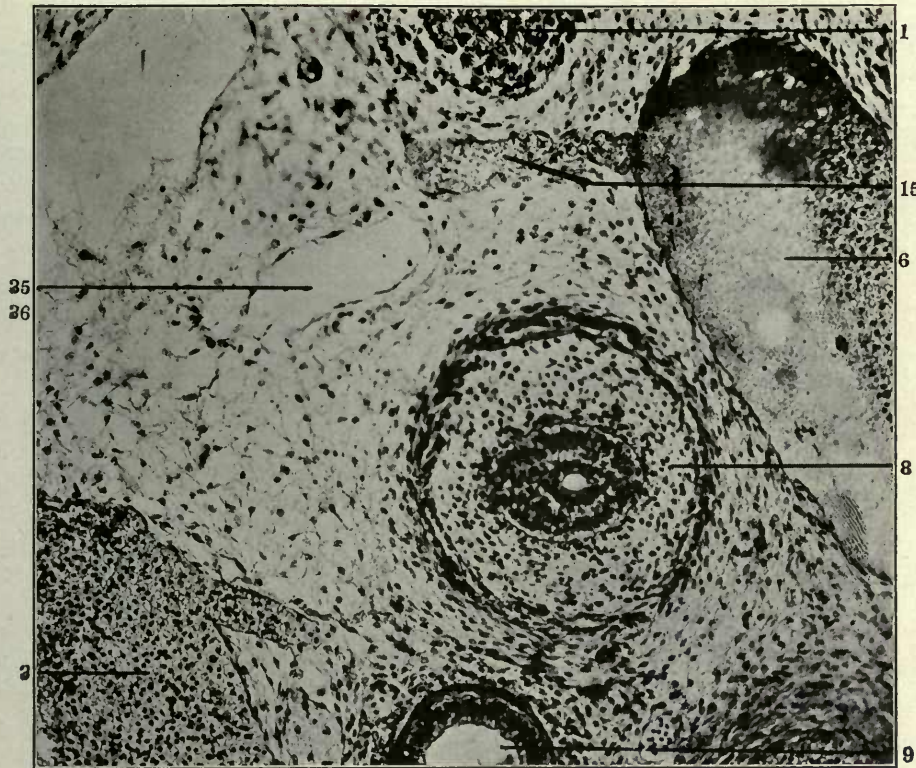
271

FIGURES 272 AND 273

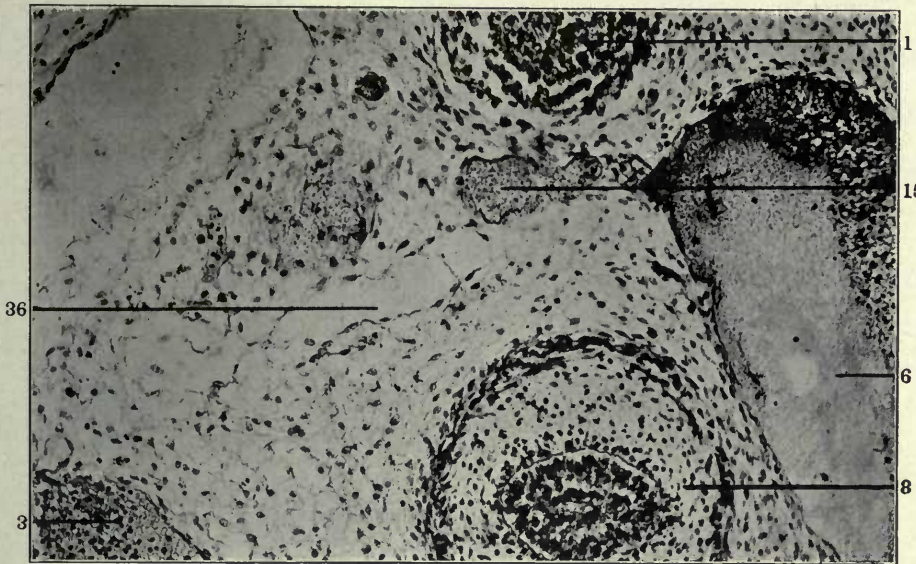
272 Same, section 23.

273 Same, section 24.

- 1 Sympathetic nerve.
- 3 Right precaval vein.
- 6 Left azygos-precaval junction.
- 8 Oesophagus.
- 9 Trachea.
- 15 Interazygos venous plexus.
- 35 Thoracic duct, preazygos segment.
- 36 Thoracic duct, azygos segment.



272



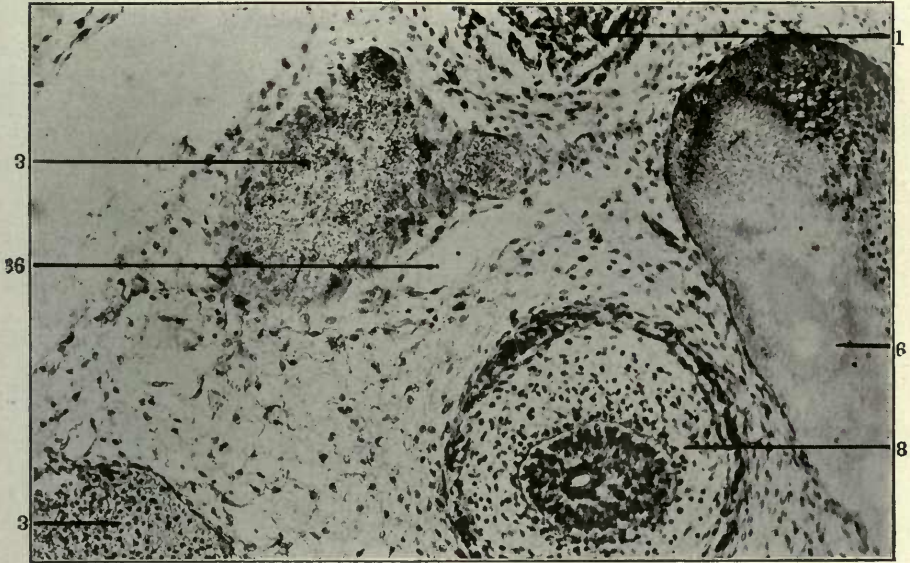
273

FIGURES 274 AND 275

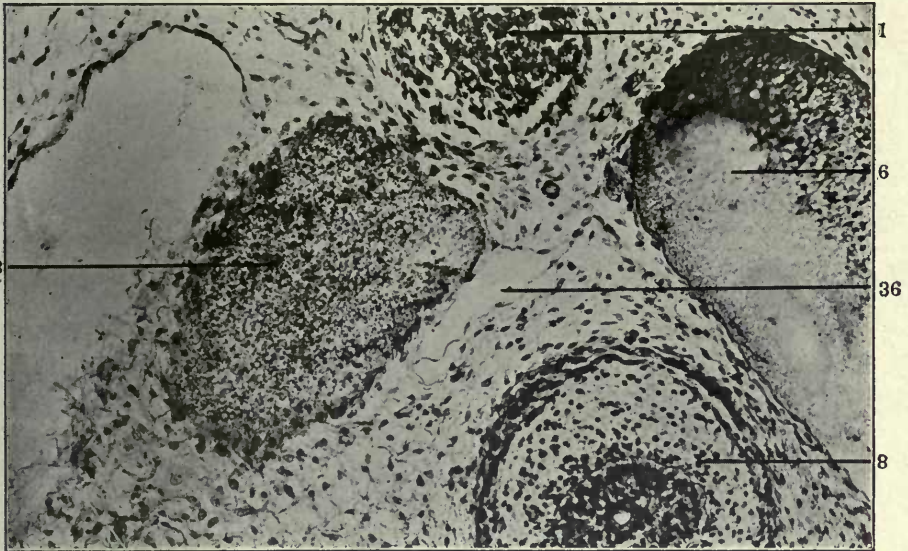
274 Same, section 25.

275 Same, section 26.

- 1 Sympathetic nerve.
- 3 Right azygos vein, thoracic portion.
- 3 Right precava.
- 6 Left azygos-precaval junction.
- 8 Oesophagus.
- 36 Thoracic duct, azygos segment.



274



275

SUMMARY AND CONCLUSIONS

In concluding this part of the record of observations on the ontogeny of certain axial systemic lymphatic channels in embryos of the domestic cat, I desire very briefly to contrast the results of this investigation with the tenets of the theories of mammalian lymphatic development divergent from the views here expressed. This is not done for the purpose of inciting or prolonging a controversial discussion. As far as I am personally concerned, controversy is at an end, because I believe that I have furnished positive evidence of the correctness of the opinion which I have maintained during the past six years, from the time on when my investigations first warranted definite conclusions. The results given in previous publications, and more in detail in the preceding pages, afford to me a sound basis for interpreting my findings of adult as well as of embryonic organization of the lymphatic system both in mammals and in the other vertebrate classes. Consequently, until these results are successfully accounted for on an equally broad and phylogenetically consistent hypothesis differing from my own interpretation, and until the deductions based on them are shown to be erroneous by equally full and comprehensive proofs, I shall rest quite satisfied with the position I have reached on this question.

It may, however, serve a useful purpose in enabling scientific men in general to draw their own conclusions, if the facts here offered are contrasted in a final review with the divergent theories of lymphatic development which have been propounded in the last decade.

In regard to the view which supposes the mammalian lymphatic system to arise by an outgrowth or bud from one or more sacs of venous origin and thence to extend by a continuous centrifugal process from centre to periphery, terminating in closed lymphatic capillaries, I find little to say.

It is quite true that it is possible to inject the jugular lymph sacs in certain mammalian embryonic stages and thus, by grading the preparations, to obtain pictures which might be interpreted in the sense of this theory, provided all questions as to the ontogenetic history of lymphatic organization are designedly left out of consideration. There may be a royal road to the solution of the vertebrate lymphatic problem, but surely the injection method has not found it. It will furnish abundant illustrations of a presumably progressive extension of lymphatic development from centre to periphery, but no proof of the actual occurrence of the process. The tissues of the developing vascular system in mammalian embryos afford at no period and in no region the slightest evidence of such an occurrence. On the other hand, the mammalian embryo does offer conclusive evidence of the development of mesenchymal spaces, arising independently of the veins, and lined by a lymphatic endothelium which is not derived from a pre-existing hæmal endothelium. These spaces form the anlagen of the future systemic lymphatic channels, and they are continuous with intercellular tissue spaces limited by the surrounding indifferent mesodermal cells which have not yet assumed endothelial character. This relation of lymphatic anlagen, lined by lymphatic endothelium, to the intercellular mesenchymal tissue spaces, while clearly determined in mammalian embryos, is moreover strikingly and diagrammatically demonstrated in reptilian embryos.

I have given in the preceding pages my reasons for assigning an absolutely negative value to injection experiments in determining *lymphatic ontogeny*. These preparations yield interesting *topographical* pictures in the different stages, showing the extent of continuous lymphatic organization at different periods, but they do not touch the problem of the *genetic processes* responsible for the establishment of a set of vascular channels capable of injection. Much of the general confusion of ideas evident in discussions of the question arises, in my opinion, from the failure to correctly appreciate the value and significance of the *lymph-heart* remnants of *venous origin* which in the mammal are interpolated as junctional links between the *independently developed systemic lymphatic vessels* and the *permanent functional veins*.

It seems difficult, in spite of carefully chosen expressions, to make it clear that in my interpretation of mammalian lymphatic ontogeny I am not trying to straddle the question of venous or non-venous origin of the lymphatic vessels. What we ordinarily describe as 'lymphatic channels' both in the embryo and in the adult animal I am forced, by the results of my investigations, to regard in amniotes as vessels developed absolutely independently of the hæmal vascular system. The association of these channels, in the mammalian embryo, with certain embryonal venous lines is purely a secondary, mechanical and topographical relationship, expressed by the condensed term of 'extraintimal' development of mammalian systemic lymphatic vessels, and absolutely devoid of genetic significance. This is, without reference to other vertebrate classes, proved by the development within restricted areas in the mammalian embryo of systemic lymphatic channels through the direct confluence of intercellular mesenchymal clefts, not related topographically or in any other sense to the embryonal veins. It is true that in the mammal this independent lymphatic genesis is extremely limited, and that the majority of the lymphatic vessels develop in close association with embryonal veins, as products of the confluence of perivascular extraintimal spaces. But this is merely, as shown by comparison with other amniote embryos, the expression of the peculiar relations obtaining in the mammal between the venous and lymphatic circuits of the vascular system, developed independently of each other.

On the other hand, I am trying to give its full value to a hitherto unrecognized component of the finished lymphatico-venous organization of the mammal. I am trying to establish the extremely reduced and rudimentary mammalian lymphatico-venous heart in the position which its phylogeny entitles it to occupy, as the link or bond-piece between vertebrate lymphatic and venous channels. I desire to make it as perfectly clear as it is possible to do in the English language that this does *not mean* the acceptance of a *mixed*, partly *venous* and partly *independent* genesis of the lymphatic system as a whole. It merely calls for the morphological recognition of a distinct and valid structure, interposed, as the connecting link, between the definite venous channels and the

lymphatic vessels, genetically a derivative from the former, but in no sense responsible for the development of the latter. It is perhaps possible to illustrate my meaning by a comparison drawn from an entirely foreign field. The pronephric, and the subsequent Wolffian duct, in approaching the cloaca, is met by a responsive outgrowth of the latter and eventually gains its permanent opening into the genito-urinary cavity by union with the same. Nobody would hold this cloacal horn responsible for the Wolffian duct development by a process of 'outgrowth' of 'budding.' The embryonal veins respond in exactly the same way to the approach of the independently developed systemic lymphatics. This response in the typical and prevalent mammal takes the form of a rudimentary and foreshortened lymphatico-venous heart, and continues to function as such throughout the life of the individual, as the jugular lymph sac. There is here certainly a distinct genetic principle involved. We, to a certain extent, disregard the cloacal participation in the final establishment of the Wolffian duct connection with the genito-urinary sinus, because the ontogeny of the duct in itself presents such marked and striking stages. In exactly the same general way I believe that we are prone to misinterpret the vertebrate lymphatico-venous junctions, unless we recognize lymphatico-venous hearts and their remnants in their true morphological significance, as links uniting structures genetically distinct and of different origin. In the matter here under discussion this does not mean a *double* genesis for the lymphatic vessels, part derived from the veins, part by independent mesenchymal confluence of intercellular spaces. This would be no more in accordance with the actual facts than a genetic description ascribing a portion of the Wolffian duct to cloacal 'outgrowth,' while another portion is credited to independent development. I would refrain from laying stress on these facts were they based on guess-work, but the entire genetic history of lymphatic and venous organization in all amniote types heretofore examined is so strikingly consistent and so uniformly constant that my personal conviction of the truth of the above statements is very firmly rooted.

Observations made on vascular structure and growth in the transparent tails of living anure amphibia have of late been offered in support of the theory of continuous centrifugal lymphatic development from pre-existing venous endothelium. These observations recall vividly the corresponding historical period in the developmental analysis of the embryonic blood-vascular channels, prior to Thoma's classical researches on this subject. Sigmund Mayer nearly thirty years ago employed the tails of living anure larvæ for the purpose of studying this phase of the circulatory system. It seems strange that to-day it should be equally, or even more, difficult to induce observers to differentiate between *development* and *growth* of vascular channels. *Development* means the genesis of the *first embryonic anlages* of a vascular system. When this has once been established its further extension by *growth* is an entirely different problem which demands equally careful and competent observation and presents many phases difficult of interpretation, involving, among others, the entire question of the 'specificity of vascular endothelium.' Much futile and controversial discussion could be avoided if the growing generation of contributors to this subject will restrain their enthusiasm long enough to bear this vital difference in mind.

On the other hand, the theory which regards the lymphatic channels of the mammalian embryo as developing by the coalescence of multiple venous 'outgrowths' or portions of embryonic venous plexuses, detached and separated secondarily from the parent veins, deserves detailed consideration.

According to the postulates of this view, the lymphatic endothelium is the direct descendant of the pre-existing hæmal vascular endothelium lining the detached venous elements which enter into the formation of the lymphatic channels. The latter, after being thus established, make secondary and permanent connections with the venous system.

It is of course a very easy matter to prove in *successive* stages the *topographical* correspondence of venous and lymphatic channels, to prove, in other words, that the area occupied by a vein in the earlier stages is filled in the following periods by a lymphatic

channel. The genetic succession of mammalian lymphatic vessels, developing along and around atrophying antecedent embryonal veins and eventually replacing them absolutely in the topographical sense, has been sufficiently elaborated in the preceding pages. There is no question whatever concerning the anatomical fact of such replacement. My quarrel lies with the deductions which the sponsors of the theory just quoted draw from the evidence of their slides.

If in an earlier stage they find a vein or venous radicle occupying a definite and clearly circumscribed topographical position in relation to surrounding structures, and if they encounter in a later stage a lymphatic channel in the identical position of the earlier vein, they reason that this topographical coincidence *proves* the direct transformation of the preceding vein into the succeeding lymphatic. They speak of the earlier vein as an 'outgrowth' from the main venous channel and describe the same as being 'detached' or 'split off' the latter to form a 'veno-lymphatic anlage,' which then, by fusion with multiple equivalent detached venous elements, forms finally a valid and permanent systemic lymphatic channel. It appears to me that in this process of reasoning topography is forced to substitute for histogenesis, and that the vital intermediate genetic stages, which finally produce the result under discussion, have been disregarded. I believe that this error in deduction is based on perfectly correct but insufficient premises and is due to the lack of sufficient material capable of demonstrating the intermediate histogenetic stages through which the replacement of a venous by a lymphatic channel is accomplished. There are many individual embryos of certain stages, which, interpreted by themselves, tend to support strongly the hypothesis of direct conversion of venous into lymphatic anlagen. It requires a very large number of embryos of approximately the same age in order to demonstrate the true genetic processes governing the early relations of the venous and lymphatic channels in the mammalian embryo. Hence the futility of reasoning, from a few human embryos, concerning primate lymphatico-venous relations, which we know, from the already ascertained conditions in adult platyrrhine and catarrhine forms, present one of the most complicated

and involved problems in the entire genetic history of mammalian vascular organization.

I am convinced that the theory of direct derivation of the mammalian systemic lymphatic vessels from the embryonal veins is utterly wrong and that it is based primarily on insufficient observation. It lends itself to an easy interpretation of a relatively small number of mammalian embryos of each appropriate stage, but fails utterly in reckoning with the conditions presented by a large consecutive series of the critical periods.

I will analyze this view on the basis of the material discussed in the preceding pages, first in the region of the thoracic duct approach of the jugular lymph sac and in the preazygos segment of the thoracic duct, and subsequently in the azygos district of the latter.

I. THORACIC DUCT APPROACH AND PREAZYGOS SEGMENT OF THE THORACIC DUCTS

The terminal portion of the thoracic duct has been described as developed by confluence of venous outgrowths, arising along the dorsal surface of the left common jugular and innominate veins in the earlier (14 mm.) stages, which occupy the same relative position with respect to the main venous channel, the thyrocervical artery and the sympathetic nerve as does the thoracic duct in the later (16 mm.) stages.

In my opinion the so-called 'outgrowths' arising from the main venous trunks are the terminals of dorso-medial tributary branches entering the same, and have nothing to do with the thoracic duct. They are part of the prevertebral capillary plexus in relation in this stage to the dorso-medial surface of the main venous channels, as described in detail in the second part of this paper dealing with the development of the preazygos segment of the thoracic duct (*supra*, p. 84). This opinion is based on the fact that in many 14 mm. embryos sections through this region show the so-called 'venous outgrowth' and the thoracic duct approach of the jugular lymph sac coexisting side by side.

As previously described in detail (*supra*. pp. 56 to 77) the thor-

acic duct approach of the jugular lymph sac, in certain typical 14 mm. embryos, extends as a curved blunt conical process mesocaudad for some distance between the main vein and the thyro-cervical artery, towards the interval between the former and the sympathetic nerve, where it ends blindly. Mesad of the thoracic duct approach the internal and common jugular veins receive a number of dorso-medial tributary radicles of the above mentioned prevertebral venous plexus. Now, it will depend altogether upon the degree of development of any particular embryo, and the selection of the sections, as to whether both the thoracic duct approach and the dorso-medial tributary terminal appear side by side in the same field, or whether one or the other, or both are absent at the particular level examined. Thus in a 14 mm. embryo (series 122, slide ix, section 28, fig. 58), the dorso-medial tributary (16) of the main vein (left internal jugular, 25) together with the thoracic duct approach of the jugular lymph sac (12), are both present in the typical relation to the thyro-cervical artery (24) and the sympathetic nerve (1). Traced back in series 122 to section 21 of slide ix (fig. 57) the thoracic duct approach (12) is seen to arise from the dorso-mesal aspect of the caudal end of that portion of the jugular lymph sac, which, as the terminal of the ventral division of the entire structure, forms the jugular approach (13).

But since in section 28 of slide ix of series 122, this portion of the future thoracic duct (lymph sac segment) is present in the classical position between thyro-cervical artery and sympathetic nerve, dorsal to the common jugular vein, *together* with the well developed dorso-medial venous tributary (16), it must become evident that the latter cannot be regarded as a 'venous outgrowth' representing the anlage of the thoracic duct, since it is manifestly impossible to include the 'anlage' of a structure and the actual structure itself side by side in a single section.

As a matter of fact, a selection of sections in this neighborhood in series 122 (14 mm.) will furnish all possible combinations of the venous dorso-medial tributary of the internal and common jugular vein and of the thoracic duct approach of the jugular sac.

The two structures, as can be clearly seen, *both* occupy in sections at the proper level the topographical position along the dor-

sal aspect of the main vein and between the thyro-cervical artery and sympathetic nerve, which has been alone employed as the basis of the conclusion that, in comparing the 14 mm. and 16 mm. embryo, the thoracic duct develops from a portion of the dorso-medial plexus, secondarily split off from the main vein.

Thus, for example, the series 122 under discussion, if employed for purposes of topographical comparison with a 16 mm. embryo, should be represented by the following sections:

	SERIES	SLIDE	SECTION	FIGURE
1.....	122	ix	21	57
2.....	122	ix	28	58
3.....	122	x	7	59
4.....	122	x	9	60
5.....	122	x	12	61
6.....	122	x	13	62

1. It will be seen that in section 21 of slide ix (fig. 57), the interval between thyro-cervical artery (24) and sympathetic nerve (1) is occupied by the thoracic duct approach (12) directed meso-caudad from the jugular lymph sac.

2. In section 28 of the same slide (fig. 58), the thoracic duct approach (12) has separated from the sac, and appears, as the free terminal of the future adult duct, mesad to the thyro-cervical artery (24). Further dorso-mesad is a venous tributary (16) approaching the main vein. Elements of the mesal peri- and inter-neural venous plexus are also seen.

3. Section 7 of slide x (fig. 59) shows, in the interval between the thyro-cervical artery (24) and the sympathetic nerve (1) the section of the thoracic duct approach (12) close to the dorsal circumference of the common jugular vein (26).

4. In section 9 of the same slide (x) (fig. 60), the blind end of the thoracic duct approach (12) is still seen on the mesal side of the thyro-cervical artery (24), while further mesad the common jugular vein (26) receives the terminals of the dorso-medial venous plexus. Here, in other words, the 'venous outgrowths' or 'an-lages of the thoracic duct,' and the thoracic duct approach of the

jugular lymph sac appear side by side, dorsal to the left common jugular vein, between the thyro-cervical artery and the sympathetic nerve.

5. Section 12 of the same slide (fig. 61) is caudal to the blind terminal of the thoracic duct approach. A radicle of the dorso-medial venous plexus (16) lies close to the dorsal circumference of the common jugular vein (26) between the thyro-cervical artery (24) and the sympathetic nerve (1), approximately in the situation occupied in the sections further cephalad by the terminal of the thoracic duct approach.

6. In the following section (fig. 62) this venous tributary opens into the main vein.

A comparison of the structures labelled respectively 16 and 12 in figs. 61 and 59 will show their close topographical correspondence and will suffice to indicate how easily the latter, a valid portion of the future thoracic duct, might be confused with the former, a dorso-medial venous terminal. Hence, in comparing successive stages, the greatest care is necessary in order to avoid the mistake of considering a lymphatic channel of the later period to be the direct derivative of a 'venous outgrowth' as seen in an earlier embryo. Other embryos of this stage will give equally conclusive pictures of the juxtaposition of thoracic duct approach (12) and dorso-medial venous tributary (16) in their various mutual relations (figs. 41, 42, 49, 50, 55).

Of course, caudal to the level at which in this stage the thoracic duct approach ends blindly, and before the independent lymphatic channels, which are subsequently (15 mm. and 15.5 mm.) to join it, are developed, the sections will only show the dorso-medial venous branches entering the main channel

But these venous terminals of a well defined plexus are in no sense 'outgrowths' from the veins, nor should they be considered as anlagen of a lymphatic structure which does not appear in the particular section figured, because it has not as yet developed at that particular level, although, as in the case in point, it may be perfectly evident and coexisting with the 'venous outgrowths' few sections further cephalad in the same embryo.

The venous plexuses, both in the prevertebral and in the ventral

mediastinal region, which form the basis for the extraintimal lymphatic channel development in the correlated segments of the thoracic ducts, are sufficiently described above (p. 85).

There is no question that the internal and common jugular veins and the innominate vein receive, along their mesal and dorso-mesal aspects during the 13 and 14 mm. stage, numerous tributaries of these two plexuses, as indicated above schematically in fig. 101. These terminals cannot, however, be interpreted as 'outgrowths' of the main venous line, constituting the venous anlagen of the thoracic duct in this region and subsequently uniting to form the continuous channel of this duct in its preaortic segment. They are a direct caudal continuation of the extensive inter- and perineural venous plexus connected, cephalad of the thoracic duct level, with the mesal aspect of the internal jugular vein throughout nearly its entire extent.

The elements of these early venous plexuses serve as lines of extraintimal perivenous lymphatic development.

Both in the prevertebral region cephalad of the aortic arch and in the ventral mediastinal area, as above described (pp. 84 to 110) the extraintimal anlagen of both channels, the *preazygos segment* of the thoracic duct *dorsally*, and the *mediastinal trunk ventrally*, can be followed in the proper stages from their earliest inception to their full completion and union with each other.

The lymphatic channel system in both areas, as in all other regions of the body, is at first very extensive and plexiform, composed of a larger number of intercommunicating spaces. Later the definite channel, smaller in cross-cut area and more direct in course, crystallizes along definite static lines out of the pre-existing lymphatic network, just as we now know that hæmal channels do. In other words, the systemic lymphatic channels, as would be expected, repeat in their development the ontogenetic stages of the hæmal channels. Both sets of vessels, lymphatic as well as hæmal, result from the condensation of an antecedent plexus along definite and determined lines and thus give rise to the characteristic vessels of the adult.

In this entire process there is never a question of the *direct* implication of a vein in the formation of a lymphatic space. The

majority of the spaces develop, as above described, extraintimally along or around a venule, but at the same time a considerable number of these spaces develop as independent mesenchymal clefts not directly related to a degenerating embryonic vein. The embryonic history of this portion of the mammalian lymphatic system, up to the junction of the completed preazygos segments of the thoracic ducts, including their ventral mediastinal tributary, with the thoracic duct approaches of the left and right jugular lymph sacs, is, as above stated, clearly shown in cat embryos of between 13 and 15.5 mm. and need not be repeated here.

Comparison of the 13 and 14 mm. stages with slightly older embryos (15 mm.) definitely proves the correctness of the view just expressed. In the course of further development the thoracic duct approach, turning ventro-mesad into the neuro-venous interval between sympathetic nerve and common jugular vein in proceeding latero-mesad across the dorsal aspect of the latter vessel, necessarily intersects the line of the dorso-medial venous tributaries. Its blind terminal must exchange the position which it occupies in the earlier (13-14 mm.) stages, lateral to the dorsal somatic venous branch, for one situated on its mesal aspect, if the vessels are functional venous tributaries and not, as has been held, venous anlagen of the future thoracic duct in this region. In other words, they should continue in the later stages side by side with the thoracic duct more fully developed, if they have not become detached from the main vein to form by fusion the lymphatic channel. This is seen to be the case, for example, in the sections of the 15 mm. cat embryo (series 245) shown in figs. 79, 80, 81 and 82. The thoracic duct approach (12) here has extended further meso-ventrad into the recess between sympathetic nerve (1) and common jugular vein (26) and now lies on the mesal aspect of the ventro-medial venous tributary (16) which opens into the main vein in fig. 82. Fig. 90 shows clearly in the dorsal view of the reconstruction of this embryo the lymphatic channel (12-35) intersecting at an acute angle the coexisting dorsomedial tributary (16-46).

II. AZYGOS SEGMENT OF THORACIC DUCT

The genesis of the azygos segment of the thoracic ducts is in my estimation the region in which the validity of divergent views as to systemic lymphatic development can best be tested.

Certain mechanical and genetic conditions combine to make the investigation of the development of the thoracic ducts in this region perhaps difficult in one sense, while in another the results of thorough investigation are most conclusive and convincing.

Part of the difficulty referred to lies in the relatively small amount of the retro- and peri-aortic space available for the development both of the azygos veins and of the subsequent lymphatic ducts replacing the same to a large extent. Again, the process of systemic lymphatic development in this region appears to proceed with great rapidity. The first anlagen of the thoracic ducts in a given stage are succeeded in stages only slightly older by well marked longer segments of the future lymphatic channel. On the other hand, the observer has the advantage of dealing with a circumscribed region and with axial venous trunks, which, both in their main line and in their tributaries, are remarkably constant, regular and easily distinguished.

As above stated, in the earlier stages a ventral tributary plexus of the azygos veins drains the periaortic region. In later stages this ventral venous plexus in large part disappears, a bilateral lymphatic duct occupying its former place. The two conditions cover each other absolutely.

No one, possessing a knowledge of the embryonic venous development of the cat, can examine a number of injections of the thoracic ducts and azygos veins of the adult animal without becoming convinced that in course of development the thoracic duct complex, caudal to the aortic arch-level, replaces a large part of the embryonic azygos venous system, and comes to occupy absolutely its topographical position and relation to surrounding structures. The relation of the dorsal intersegmental aortic branches to the inter-azygos venous anastomosis of the embryo, compared with the intercostal arteries of the adult perforating through the meshes of the plexiform lymphatic channel of the thoracic ducts, will alone absolutely demonstrate this mutual topographical correspondence.

The only question at issue is the determination of the *genetic processes* through which the embryonic azygos venous plexus is replaced by the lymphatic network of the thoracic ducts in the adult.

Some observers have derived this portion of both ducts directly from the ventral aspect of the azygos veins by comparing trans-sections of 14 mm. and 16 mm. embryos, and finding in the former ventral tributaries of the main channels, whose place in the latter is occupied by the thoracic ducts. They hence conclude that the ventral azygos plexus, forming 'the veno-lymphatic anlagen' of the thoracic ducts, separates at numerous points from the parent vein, and that the resulting detached portions of the originally continuous venous plexus, secondarily unite to form the channel of the thoracic ducts. The latter structures are therefore, in their estimation, direct derivatives of the azygos veins and their tributaries.

The preceding pages give my reasons for regarding this replacement as having occurred in course of the development of the thoracic ducts by confluence of numerous isolated mesenchymal spaces, formed along and around the azygos veins and their ventral tributaries, but genetically independent of the latter and lined by an endothelium not derived from the pre-existing hæmal endothelium.

In the region under discussion these mesenchymal clefts develop, owing to local conditions, very largely as extraintimal or perivenous spaces accompanying and surrounding the branches of the retrograding ventromedial azygos plexus. The resulting thoracic ducts thus come to occupy the place formerly filled by the ventral azygos venous network, and later are led into direct ventral contact with the main azygos veins, which they in their further growth to a large extent secondarily replace.

In the early (11-12 mm. stage) the azygos veins receive on their ventral and ventro-medial aspect the terminals of a venous plexus originating in the retro- and peri-aortic mesenchyme. While the individual embryos offer many striking pictures at various levels, I believe that my purpose of demonstrating the genesis of the thoracic ducts in this area will best be accomplished by taking

sections in successive stages which will present approximately the same topographical picture, allowing for the necessary changes consequent on increasing development. The area to which I thus desire to call detailed attention is the mesenchymal tissue, situated on the right side of the thoracic aorta, between this vessel and the mesal aspect of the right azygos vein, ventral to one of the right dorsal somatic (intercostal) branches of the aorta, and under cover of the dorsal surface of the œsophagus.

These limitations, as is well known, define the position of this portion of the main thoracic duct of the adult, and consequently the development of this structure, however produced, must run its course in this situation. The successive stages, which in my opinion definitely and conclusively prove the independent extra-intimal anlage of this portion of the right thoracic duct, may be grouped as follows, and referred to selected illustrations above described in the body of the text in detail:

A. Venous stage. (Embryos from 10 mm. to 13 mm.). Illustrations in body of text: figs. 194 to 203.

The sections show an extensive ventral and ventromedial azygos tributary plexus.

B Stage of replacement of ventral azygos venous plexus by independently developed perivenous or extraintimal lymphatic anlages which accompany and surround the branches of the antecedent venous network, and form the first anlages of the azygos segment of the thoracic ducts. (Embryos from 13 to 14 mm.) Illustrations in body of text: figs. 204 to 213; 247 to 251.

1. The earliest anlages of the future thoracic ducts are seen in certain sections of the thoracic region in embryos between 12 and 13 mm. crown-rump measure. I have found these early traces almost exclusively on the right side, the sinistral position of the aorta appearing to delay their development on the left side. They make their first appearance as delicate endothelial-lined extremely sparse and widely separated independent mesenchymal clefts, at some distance ventral to the main right azygos trunk and near the right lateral wall of the aorta.

At first they are not clearly related to the co-existing ventromedial tributaries of the azygos. But they soon extend to involve

these in the characteristic manner above detailed, and continue to develop as extraintimal or perivenous lymphatic spaces gradually replacing the shrinking ventral azygos plexus.

2. In the succeeding stage (13+ mm.) the aorta sinks more deeply into the interazygos interval and is spanned on its dorsal aspect by the horse shoe of the abundant supra-aortic cross anastomosis between the azygos trunks of the two sides. The perivenous extraintimal lymphatic spaces surrounding and accompanying the ventral azygos tributaries have increased in size, and a few spaces of the same character begin to make their appearance along the ventro-lateral aspect of the main azygos veins.

3. In the 13.5 mm. embryo the extraintimal anlagen replacing the ventro-medial azygos tributaries have increased in number, united with each other to form a series of longer continuous segments, and have, following the lead of the venules which they are replacing, approached nearer to the ventral aspect of the main azygos veins, and appear more closely interlocked with the ventro-medial tributaries of the latter.

C. 14 mm. stage. Illustrations in body of text: figs. 214 to 240.

The most instructive and conclusive pictures are obtained in embryos of approximately this crown-rump measure.

The sections are clearer and most unmistakable in their meaning and the individual spaces have become confluent for longer stretches, representing longer segments of the thoracic duct channel which is subsequently to be formed by their continued elongation and fusion with each other. This becomes clearly apparent in contrasting the ventral view of the reconstruction of series 76 (13.5 mm.) with that of series 214 (14 mm.) shown in figs. 188 and 190.

The diffuse and scattered elements of the parazygos lymphatic plexus anlagen in the 13.5 mm. stage have, in the 14 mm. embryo, become condensed and united into longer segments representing the future line of right axial prevertebral lymphatic drainage. It is noteworthy, as an important fact, that notwithstanding the clear development of unmistakable longer segments of the future right thoracic duct, these anlagen are still placed at some distance ventro-mesal to the right azygos vein and ventral to the intersegmental arteries.

The 14 mm. embryo represents thus in general the full development of the histological picture of secondary replacement of a decadent embryonic venous plexus by the secondarily developed extraintimal perivenous lymphatic spaces and channels.

The following conditions have been noted in individual sections:

a. Ventro-medial tributary of right azygos connected with main vein, detached on left side.

Anlage of right thoracic duct lateral to right ventral azygos tributary.

b. Ventro-medial tributaries of both azygos veins surrounded by extraintimal anlagen of both ducts.

c. Ventro-medial tributaries detached and surrounded by extraintimal anlagen of thoracic ducts on both sides.

d. Ventro-medial tributaries in connection with both azygos veins and accompanied by ventro-lateral lymphatic anlagen on both sides.

e. Azygos veins without ventro-medial branches or their remnants and accompanied on both sides by the thoracic duct anlagen

f. Azygos veins with ventro-medial tributaries without duct anlagen.

g. Azygos veins without either ventro-medial tributaries or thoracic duct anlagen.

D. *Later transitional lymphatic stages.* Illustrations in body of text: figs. 252 to 258.

In the 15 and 15.5 mm. embryo three further developmental characters appear:

a. The earlier more redundant and plexiform lymphatic anlagen condense into a definite channel of relatively smaller caliber.

b. The central remnants of the atrophied embryonic vein, around which the lymphatic anlagen developed, have to a large extent disappeared, leaving the lymphatic lumen clear.

c. The individual and originally separate segments of the lymphatic channels have united into segments of greater length, and have approached more closely to the ventral surface of the main azygos trunks. The definition of a right and left lymphatic trunk with supra-aortic cross anastomoses is beginning to appear, al-

though the former is still the larger and better defined. It occupies the original position between aorta and ventromesal surface of the right azygos vein, ventral to the intercostal artery, dorsal to the œsophagus.

E. Definite lymphatic stage. From the 16 mm. embryo on. Illustrations in body of text: figs. 259 to 262; figs. 265 to 270.

Here all the thoracic duct anlagen have united into the continuous and connected plexiform channel of the thoracic ducts, ventral to the azygos trunks, dorsal to the aorta.

The early independent genetic history of the spaces, which I have above described as the first anlagen of the thoracic duct channels in the embryos of the cat, and the fact that in subsequent stages they appear consistently and in every possible combination as extraintimal or perivenous mesenchymal spaces, following and surrounding the branches of the ventral azygos plexus, exclude to my mind the possibility of regarding them as derived directly from ventral azygos venous plexus, or from so-called 'venous outgrowths' of the main azygos trunks, subsequently detached from the parent trunks.

In the foregoing genetic history of part of the thoracic duct lymphatic plexus, by fusion of extraintimal and perivenous mesenchymal spaces, accompanying and surrounding certain of the ventral venous tributaries of the right azygos trunk, the following points should be noted:

1. The portion of the entire adult thoracic duct complex here considered develops in its earliest stages at some distance ventromesad to the right azygos vein. It only subsequently, by extending proximad along the venule which it replaces, reaches the position in close relation to the ventral surface of the azygos which it occupies in the 16 mm. stage.

2. In the 13.5 and 14 mm. embryos the radicles of the ventromedial tributary plexus are in the process of being surrounded by the growing perivenous extraintimal lymphatic spaces which are approaching along this line the ventral surface of the azygos, but in the 14 mm. stage have not yet acquired this position. The 16 mm. embryo shows the lymphatic anlagen in their definite relation to the azygos trunk, and the primitive ventral venous tributary

along which the lymphatic spaces expanded to reach this position, has disappeared. The successive stages of this process can be followed in such detail and in such conclusive preparations that all doubt as to the accuracy of the statements here made seems to me to disappear. It is merely a question of suitable material, accurately fixed, sectioned and stained, and sufficiently abundant to offer complete corroboration in a number of series of the same age. There can then be no question as to the genetic principles involved.

3. The portion of the thoracic duct, whose genetic history has just been outlined, forms only a component of the entire lymphatic complex entering into the formation of the adult duct. Two other equivalent components combine with it to produce the adult conditions, viz., a corresponding segment on the left side, developed in the same way in association with the ventral tributary plexus of the left azygos vein, and an intermediate plexiform lymphatic reticulum which arises as the result of fusion of extraintimal lymphatic spaces formed along the ventral aspect of the supra-aortic interazygos venous plexus.

In addition to these three cardinal elements entering into the organization of the adult thoracic ducts, these channels, when once they have gained their position ventro-mesad to the azygos trunks, grow partly by their own expansion, partly by addition of numerous new extraintimal lymphatic spaces which form along the azygos veins, especially on the left side.

The eventual reduction of the left azygos vein, and of the caudal part of the right trunk, by transference of the blood current to the vertebral chain, accounts for the topographical relations of the replacing thoracic duct complex of the adult.

BIBLIOGRAPHY

- ALLEN, W. F. 1906 The distribution of the lymphatics in the head and in the dorsal, pectoral and ventral fins of *Scorpaenichthys marmoratus*. *Proc. Washington Acad. of Sciences*, vol. 3, pp. 41-90, May 18.
- 1907 The distribution of the subcutaneous vessels in the head region of the Ganoids *Polydon* and *Lepidosteus*, *ibid.*, vol. 9, pp. 79-158, July.
- 1910 The distribution of the lymphatics in the tail region of *Scorpaenichthys marmoratus*. *Am. Jour. Anat.*, vol. 11, no. 1, Nov., pp. 1-53.
- 1908 Distribution of the subcutaneous vessels in the tail region of *Lepidosteus*. *Anat. Rec.*, vol. 2, pp. 65-70.
- BAETJER, W. A. 1908 The origin of the mesenteric lymph sac in the pig. *Anat. Rec.*, vol. 2, pp. 55-57.
- BRACHET, A. 1898 Recherches sur le développement du coeur, des premiers vaisseaux et du sang chez les amphibiens urodèles. *Arch. d'anat. microscopique*, Tome 2.
- 1899-1900 Recherches sur l'origine de l'appareil vasculaire sanguin chez les amphibiens. *Arch. de Biologie*, Tome, 19.
- BUDGE, ALBRECHT 1875 Neue Mittheilungen ueber die Lymphgefäße der Leber. *Berichte d. K. Sächs-Gesellsch. d. Wissensch.*, Math. phys. Classe, 21 Juli.
- 1876 Die Lymphwurzeln der Knochen. *Arch. f. mikroskop. Anat.*, Bd. 13.
- 1880 Ueber ein Canalsystem im Mesoderm von Hühnerembryonen. *Arch. f. Anat. u. Phys.* Anat. Abth.
- 1881 Ueber das dem zweiten Blut Kreislaufe entsprechende Lymphgefäßsystem bei Hühnerembryonen. *Centralbl. f. d. med. Wissensch.*
- 1882 Ueber die Lymphherzen bei Hühnerembryonem. *Arch. f. Anat. u. Phys.*, Anat. Abth., pp. 350-358.
- 1887 Untersuchungen über die Entwicklung des Lymphsystems beim Hühnerembryo. *Arch. f. Anat. u. Phys.*, Anat. Abth.
- DARRACH, WILLIAM 1907 Variations of the postcava and its tributaries in 605 examples of the domestic cat. *Am. Jour. Anat.*, vol. 6, no. 3. Abstr. *Anat. Rec.*, vol. 1, p. 30.
- ECKER, A. u. WIEDERSHEIM, R. 1896 Die Anatomie des Frosches, 3. Abstr. bearbeitet von E. Gaupp.
- FAVARO, GIUSEPPE 1905-1906 Ricerche intorno alla morfologia ed allo sviluppo dei vasi seni e cuori caudali nei Ciclostomi e nei Pesci. *Atti del Keali Istituto Veneto di Scienze, Lettere ed Arti*, Anno accadem. Tomo 65 Parte Seconda. Appendice alla Dispensa 10, pp. 1-279.
- 1906 Ricerche anatomo-embriologiche intorno alla circolazione caudale ed ai cuori linfatici posteriori degli Anfibi, con particolare riguardo agli Urodeli, *Atti dell' Accademia scientif. Veneto-trentino-istriana*, Classe 1, Anno 3, pp. 122-266.
- 1905 Il cuori ed i seni caudali dei Teleostei, *Anat. Anz.* Bd. 27, ncs. 14, 15.

- FAVARO, GIUSEPPE, 1905 Note fisiologiche intorno al cuore caudale dei Murenoidi (Tipo *Anguilla vulgaris* Turt.) *Archivio di Fisiologia*, vol. 2, Fasc. 5, Luglio p. 569-580.
- GULLAND, G. LOVELL. 1894 The development of lymphatic glands. *Jour. Path. and Bact.*, vol. 2, pp. 447-485.
- HEUER, G. 1908 The development of the lymphatics in the small intestine of the pig. *Anat. Rec.*, vol. 2, pp. 57-58.
- HOYER, H. 1905-1908 Untersuchungen über das Lymphgefäßsystem der Froschlärven, I. Theil. *Bullet. de l'Acad. des Sciences de Cracovie, Classe des Sciences math. et nat.*, Juillet II. Theil, *ibid.*, Mai.
- HUNTINGTON, GEORGE S. 1908 The genetic interpretation of the development of the mammalian lymphatic system. *Anat. Rec.*, vol. 2, pp. 19-45.
 1910 The genetic principles of the development of the systemic lymphatic vessels in the mammalian embryo. *Anat. Rec.*, vol. 4, no. 2, pp. 399-423.
 1910 Ueber die Entwicklung des lymphatischen Systems beim Säugerembryo. *Compte-Rendu*, XVI Congrès Internat. de Médecine, Sect. I, Anatomie, Embryologie, 2. Fasc., pp. 127-142, Budapest.
 1910 The phylogenetic relations of the lymphatic and blood-vascular systems in vertebrates. *Anat. Rec.*, vol. 4, January.
 1910 Ueber die Histogenese des lymphatischen Systems beim Säugerembryo, *Anat. Anz. Ergänz. z. Bd. 37, Verh. 2, internat. Anat. Kongr.*, Brüssel, Aug. 7-11, pp. 76-94.
 1911 The development of the lymphatic system in reptiles, *Anat. Rec.*, vol. 5.
- HUNTINGTON, GEO. S. AND McCLURE, C. F. W. 1907 The development of the main lymph channels of the cat in their relation to the venous system. *Am. Journ. Anat.*, vol. 6; *Abstr. Anat. Rec.*, vol. 1, pp. 36-41.
 1907 The development of the postcava and tributaries in the domestic cat, *Am. Journ. Anat.*, vol. 6, *Abstr. Anat. Rec.*, vol. 1, p. 29.
 1907 The interpretation of variations of the postcava and tributaries in the domestic cat, based on their development. *Am. Jour. Anat.*, vol. 6, *Abstr. Anat. Rec.*, vol. 1, p. 33.
 1908-1910 The anatomy and development of the jugular lymph sacs in the domestic cat. *Anat. Rec.*, vol. 2, pp. 1-18. *Am. Jour. Anat.*, vol. 10, pp. 177-311.
- KNOWER, HENRY McE. 1908 The origin and development of the anterior lymph hearts and the subcutaneous lymph sacs in the frog. *Anat. Rec.*, vol. 2, pp. 59-62.
- LANGER, 1868 Ueber das Lymphgefäßsystem des Frosches. *Sitzb. d. Akad. d. Wissensch.* Bd. 58, 1. Abth.
- LEWIS, F. T. 1905 The development of the lymphatic system in rabbits. *Am. Jour. Anat.*, vol. 5, pp. 95-111.
- MACCALLUM, W. J. 1902 Die Beziehungen der Lymphgefäße zum Bindegewebe. *Arch. f. Anat. u. Phys.*, Anat. Abth.
- McCLURE, C. F. W. 1903-1906 The anatomy and development of the postcava in *Didelphis marsupialis*. *Am. Jour. Anat.*, part 1, vol. 2, part 2, vol. 5.
 1906 The postcava of an adult Indian chevrotain (*Tragulus meminna*, Erxleben). *Anat. Anz. Bd. 29*, pp. 375-377.

- McCLURE, C. F. W. 1908 The development of the thoracic and right lymphatic ducts in the domestic cat. *Anat. Anz.*, Bd. 32, pp. 533-543.
- 1910 The extra-intimal theory and the development of the mesenteric lymphatics in the domestic cat (*Felis domestica*). *Anat. Anz. Ergänz. z. Bd. 37, Verh. 2. internat. Anat. Kongr., Brüssel, Aug. 7-11*, pp. 101-110.
- McCLURE, C. F. W., AND SILVESTER, C. F. 1909 A comparative study of the lymphatico-venous communication in adult mammals. *Anat. Rec.*, vol. 3, pp. 534-551.
- MARCUS, H. 1908 Beiträge zur Kenntnis der Gymnophionen; II. Ueber intersegmentale Lymphherzen, nebst Bemerkungen über das Lymphsystem. *Morphol. Jahrb.*, Bd. 38, Heft 4, pp. 590-607.
- RANVIER, L. 1895 Développement des vaisseaux lymphatiques. *Contes Rendues Acad. Sc. Paris*, Tome 121.
- 1896 Développement des vaisseaux lymphatiques et le développement des ganglions lymphatiques. *Contes Rendues, Acad. Sc. Paris*, T. 123.
- 1896 La theorie de la confluence des lymphatiques et le développement des ganglions lymphatiques. *Contes Rendues, Acad. Sc. Paris*, Tome 122.
- 1896 Aberration et repression des lymphatiques en voie de développement. *Contes Rendues Acad. Sci. Paris*, Tome, 122.
- 1897 Morphologie et développement des vaisseaux lymphatiques chez les mammifères. *Archives d'Anat. microscop.*, Tome 1, pp. 69-81.
- SABIN, F. R. 1902 On the origin of the lymphatic system from the veins, and the development of the lymph hearts and thoracic duct in the pig. *Am. Jour. Anat.*, vol. 1, 1902, pp. 367-389.
- 1904 On the development of the superficial lymphatics in the skin of the pig. *Am. Jour. Anat.* vol. 3, pp. 183-195.
- 1905 The development of the lymphatic nodes in the pig, and the relation to the lymph hearts. *Am. Jour. Anat.*, vol. 4, pp. 355-389.
- 1908 Further evidence on the origin of the lymphatic endothelium from the endothelium of the blood vascular system. *Anat. Rec.*, vol. 2, pp. 46-54.
- 1909 The lymphatic system in human embryos, with a consideration of the morphology of the system. *Am. Jour. Anat.*, vol. 9, pp. 43-90.
- SALA, LUIGI, 1900 Sullo sviluppo dei cuori linfatici e dei dotti toracici nell'embrione di pollo, Ricerche fatta nel Laborat. di Anat. norm. della R. Univ. di Roma, vol. 7.
- SCHULTE, H. v. W., 1907 The range of variations in monotremes and Australian Marsupials. *Am. Jour. Anat.*, vol. 6, *Anat. Rec.*, vol. 1, pp. 243-36.
- 1908 Further communication on the venous system of marsupials, *Anat. Rec.*, vol. 2, pp. 196-203.
- SCHULTE, H. v. W., AND TILNEY, FRED. 1909 Note on the organization of the venous return, with especial reference to the iliac veins. *Anat. Rec.*, vol. 3, pp. 555-577.
- SILVESTER, C. F. 1910 On the presence of permanent lymphatico-venous communications at the level of the renal veins in adult South American monkeys. *Anat. Anz.*, *Ergänz. z. Bd. 37, Verh. internat. Anat. Kongr., Brüssel, Aug. 7-11*, pp. 111-113.

- STROMSTEN, FRANK A. 1910 A contribution to the anatomy and development of the posterior lymph hearts of the turtles. *Publication no. 132 of the Carnegie Institution of Washington*, pp. 77-87.
- 1911 On the relations between the mesenchymal spaces and the development of the posterior lymph hearts of turtles. *Anat. Rec.*, vol. 5, pp. 173-178.
- SWAEN, A., ET BRACHET, A. 1899-1900 Étude sur les premiers phases du développement des organes dérivés du mesoblast chez les poissons téléostiens. *Arch. de Biologie*, 16.
- THOMA, R. 1893 Untersuchungen über die Histogenese und Histomechanik des Blutegefässsystems, Stuttgart.

14 DAY USE
RETURN TO DESK FROM WHICH BORROWED

Biology Library

This book is due on the last date stamped below, or
on the date to which renewed.

Renewed books are subject to immediate recall.

NOV 20 '57

AP 27 '58 JG

DEC 16 1964

De 9 '64 H R

DEC 8 1965

NOV 29 1965

JUN 7 1967

DAVIS

INTER-LIBRARY
LOAN

MAY 17 1967

AUG 15 1968 1

AUG 15 1968

AUG 19 1968 4

DAVIS

INTER-LIBRARY
LOAN

NOV 10 1965

LD 21-100m-6 '56
(B9311s10)476

General Library
University of California
Berkeley

U.C. BERKELEY LIBRARIES



C026158043

LIBRARY OF THE UNIVERSITY OF CALIFORNIA

LIBRARY



LIBRARY OF THE UNIVERSITY OF CALIFORNIA

LIBRARY OF THE UNIVERSITY OF CALIFORNIA



LIBRARY OF THE UNIVERSITY OF CALIFORNIA

LIBRARY OF THE UNIVERSITY OF CALIFORNIA



