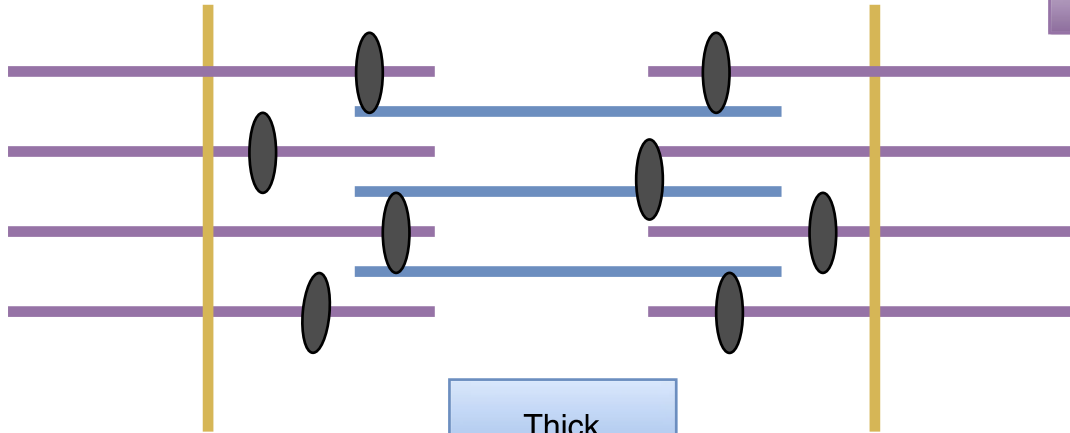


Sarcomere in
Nemaline Myopathy
Patient

Z Line

Thin Filaments



Thick
Filaments