

Kelly (H. A.)

The Conservative Treatment of
Myomatous Uteri.

Presented to the Section on Obstetrics and Diseases of Women, at
the Forty-eighth Annual Meeting of the American Medical
Association, held at Philadelphia, Pa., June 1-4, 1897.

BY HOWARD A. KELLY, M.D.
BALTIMORE, MD.

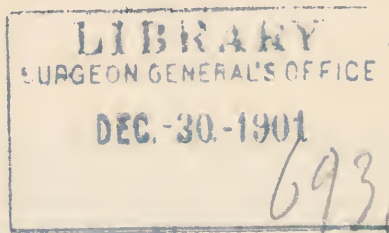
REPRINTED FROM THE
JOURNAL OF THE AMERICAN MEDICAL ASSOCIATION,
OCTOBER 2, 1897.

CHICAGO:
AMERICAN MEDICAL ASSOCIATION PRESS
1897.

LIBRARY
SURGEON GENERAL'S OFFICE

DEC. 30. 1901

6931



THE CONSERVATIVE TREATMENT OF MYOMATOUS UTERI.

BY HOWARD A. KELLY, M.D.

The next great wave of advance in gynecology will be a wide-spread application of the principle of conservatism to all but malignant affections, and this change will bring with it blessings to women greater than all the advances in exsective surgery which we have hitherto seen. I am here today to advocate the conservative treatment of myomatous uteri, to urge the plan of enucleating myomatous tumors of great size, and in any number, and wherever and however situated and attached, without the sacrifice of any considerable portion of the uterus. I do not refer to the enucleation of pediculated or sessile subserous tumors, or to the occasional splitting of the uterine muscle to enucleate an interstitial tumor; nor do I wish to dwell upon the operation of splitting open the uterus and removing a large submucous myoma through an abdominal incision, as first practiced by A. Martin of Berlin. I wish to extend the field beyond all these indications and declare the perfect feasibility of extracting six, eight, a dozen or even twenty or thirty myomata, big and little, and of sewing up the multiple incisions made and leaving the patient with a practically normal and functionally perfect uterus.

As an operative procedure such extensive myomec-
tomies performed in large uteri, as big as five or seven
months' pregnancies, are far more difficult to perform
than the removal of the myomatous uterus—hystero-
myomectomy. The operation requires greater tech-
nical skill, and the individual differences between the

different operations are more diverse; it is therefore not a routine procedure like hysteromyectomy. Liability to sepsis is increased from the prolonged and intimate handling of the tissues if the aseptic precautions of the operator are imperfect. Hemorrhage also is often far more difficult to control. In spite of all these objections, however, extensive myomectomies and multiple myomectomies are the operations of choice.

The indications for the operation lie in the age and condition of the patient. If the patient is in good or fair condition and can stand a prolonged operation lasting thirty, forty or fifty minutes and is under 37 years of age myomectomy should always be done. I would not do a myomectomy, as a rule, on a woman of more advanced years or in one exsanguinated or profoundly depressed by any associated disease or complication.

The operation.—A free incision is made into the abdomen exposing the myomatous uterus, and if it can be done, this is lifted up into or out of the incision. The tumors are then cut out, beginning with the larger and the most accessible, and sometimes two or three are removed through one incision. A straight incision is made through the uterine wall well down into the white fibrous substance of the tumor; this is then grasped with museaux forceps and dissected out with a blunt instrument like a curved spatula. The fingers and finger nails must not be used. If the tumor is a small one it is rapidly shelled out, the bleeding points clamped if active, and the wound at once sewed up with interrupted catgut sutures, using enough of them and passing them deep enough to stop all hemorrhage. If the tumor is large, then it is often best to enucleate it step by step and close the wound, stopping the bleeding as you go. A deep wound in the thick uterine muscle may even take three or four rows of buried sutures to close it and stop all the hemorrhage. After the removal of the accessible tumors the others are easier to reach, and the uterus may be pulled up and drawn sidewise or tilted in extreme ante- or retroflexion to expose the field better. I have several

times had to cut loose the bladder in order to remove a subvesical myoma of the cervix, and I have taken out a subperitoneal myoma filling the cellular tissue of the lower pelvis and pressing on the pubic rami.

Hemorrhage is best checked by rapid work, by the well-directed pressure of the fingers of an assistant at the base of the tumor, or by the constriction of the cervix uteri, if it can be reached, by means of fingers or a gauze rope. Buried catgut sutures must be so applied as to leave no dead spaces and particular attention must be given to the angles of the incision, which are most apt to bleed. Before closing the abdomen, which is always done without a drain, the table must be dropped level and each wound minutely inspected.

Sepsis is prevented by avoiding handling of the tissues. Traction is made with forceps, dissection is done with a blunt instrument, and if the lips of the big uterine incision have to be held apart it is done with gauze pads and not with bare fingers. It is well also to have the assistants wear rubber gloves, as recommended by Halsted, or Lisle thread gloves. The loop part of the ligatures which makes the tie and stays in the abdomen also need never be touched by the operator as he does his tying.

A uterus treated in this way is somewhat analogous to a Cæsarean uterus, with multiple wounds. I have made as many as seven, eight and nine separate incisions in removing myomata in this way. The uterine cavity is, as a rule, not opened. I have in my clinic demonstrated the feasibility of taking out as many as thirty myomata, filling a soup-plate, without opening the mucous surface of the uterus. In other cases I have opened the cavity from end to end. In one instance the whole anterior wall was torn up to the cornua and formed a triangular flap of mucosa, which was attached in place by delicate sutures, the big wound closed and the patient made a perfect recovery. In another case the entire anterior wall of the uterus was removed, leaving only the mucous surface of the posterior wall. A new uterus was constructed out of

what remained and the patient, who had before suffered intensely and with profuse hemorrhages, has since menstruated naturally.

The hypertrophy of the uterine muscle is sometimes so enormous that I have been unable even after the extraction of all the tumors to put the uterus back in the abdomen in its natural position in the median line and close the incision, but I have been obliged to turn the large gibbous mass well over to one side. Two of these uteri were as big as a child's head, at least fifteen times larger than the normal uterus. Both cases have done well and involution has occurred during the convalescence.

This extensive conservative operation I have just described means much to the patient. It conserves a natural function, one of the distinctive attributes of sex, and it guarantees the possibility of conception and motherhood. What it may mean is well illustrated by a recent case, by means of which I would contrast my practice with the prevailing methods. A young woman of about 30 years of age had masses of myomatous nodules fixed in and choking her pelvis and rising well into the abdomen; the only normal part of the uterus which could be distinguished was the cervical end. At her home in a Southern city she got an opinion from a surgeon known all over the world, that her case was inoperable, the risks were too great. In this city (Philadelphia) she was told that hysterectomy was the only remedy. I promised to relieve her by myomectomy, which I did, extracting a number of large myomata and leaving a much incised and a much sutured but otherwise intact uterus. She made a perfect and rapid recovery and I have since learned that she is engaged to be married. Last, and not least, the gratitude of my patient for the preservation of all her organs is a great incentive to continue in this fruitful line of surgical work.

In a case operated upon still more recently the patient, a young woman in the twenties, has been married since the operation.

