



# Images of *Aerococcus urinae*

Mikael Häggström<sup>1,2,3</sup> and Jonatan Mattila<sup>4,5</sup>

## Abstract

This is a description of an infection in 73 year old man with multiple comorbidities, with images of *Aerococcus urinae* from resultant blood cultures, showing their [alpha hemolytic](#) and [Gram-positive](#) properties.

**Plain language summary:** *Aerococcus urinae* is a type of bacteria that can lead to infections in the urinary system. This work describes a 73 year old man who had an infection with *Aerococcus urinae*. Samples of blood and urine were taken from the patient, and when put on blood cells the bacteria weakly changed the color of the blood cells around them. This result is called *alpha hemolysis*, and can be seen in *Image 1*. Adding Gram stain to the bacteria turned them violet, and therefore the bacteria were *Gram-positive*. This can be seen in microscopy in *Image 2*. The patient was treated with antibiotics.

## *Aerococcus urinae*

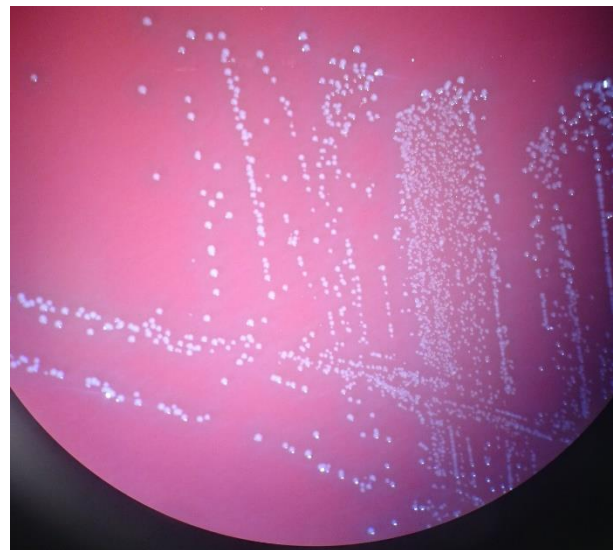*Aerococcus urinae* is a relatively new species of bacteria in clinical and microbiological practice, first reported in 1989 and designated as a separate species in 1992.<sup>[1]</sup> It can cause [urinary tract infections](#), [bacteremia](#) / [septicemia](#) and/or [endocarditis](#).<sup>[2]</sup> As a urinary tract pathogen, it causes infections predominantly in elderly persons with local or general predisposing conditions.<sup>[3]</sup> *Aerococcus urinae* has been estimated to cause approximately 0.31 - 0.44% of urinary tract infections.<sup>[3]</sup>

## Patient case

A 73 year old man presented to the emergency department with two days of fatigue, fever and chills. He had a previous history of left arterial [cerebral media infarction](#) with [expressive aphasia](#), right side [hemiparesis](#) and post-stroke seizures. He suffered from [hypertension](#), [atrial fibrillation](#) and [aortic stenosis](#) with normal systolic left [ventricular function](#) as well as [urinary incontinence](#) and [prostatic hyperplasia](#).

In the emergency department he was [afebrile](#) and the blood-samples showed a [C-reactive protein](#) level of 19

mg/l (normally less than 5<sup>[4]</sup> or 6<sup>[5]</sup>) and a [leukocyte count](#) of 13.7\*10<sup>9</sup>/l (normally less than 9.0<sup>[6]</sup> or 10.0<sup>[7]</sup>). The patient was admitted to the hospital for observation, and after one day on the ward he developed chills and was [subfebrile](#) with a [tympanic](#) body temperature of 37.6°C (normally up to 37.5°C).<sup>[8]</sup> Blood and urine samples were taken for culture. Microscopy of the blood samples showed gram-positive cocci. The patient received intravenous [cefotaxime](#). After three days all blood samples and urine samples showed growth of [gram-positive catalase-negative cocci](#) *Aerococcus urinae* (**Figures 1 and 2**).



**Figure 1** | Blood agar with [alpha hemolytic](#) colonies following culture from the patient's blood samples.

Sundsvall Regional Hospital

<sup>1</sup> Image credits and author of introduction

<sup>2</sup> ORCID: 0000-0002-2732-7631

<sup>3</sup> Author Correspondence: [online form](#)

<sup>4</sup> Author of patient case

<sup>5</sup> Author Correspondence: [online form](#)

Licensed under: [CC-BY-SA 3.0](#)

Received 01-03-2015; accepted 09-03-2015

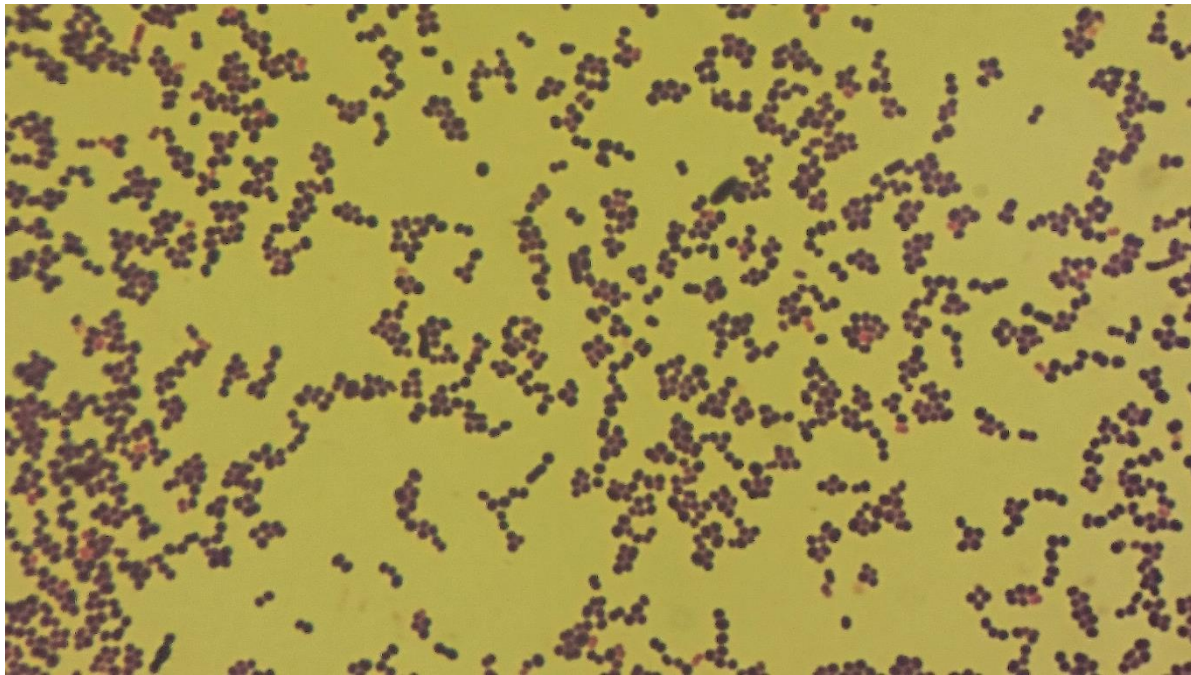


Figure 2 | Micrograph of the bacteria with Gram stain, showing gram-positive cocci.

Confirmation was done with MALDI TOF mass spectrometry.

During the seven days of inpatient care, inflammatory parameters did not reach more than 61 mg/l for C-reactive protein and  $13.7 \times 10^9/l$  for leukocyte count. The patient received a cardiac ultrasound due to a systolic murmur, but it did not show any convincing signs of endocarditis.

## Notes

Written consent was obtained from the patient for this publication.

Conflict of Interest: none declared.

## References

1. de Jong, M. F. C.; Soetekouw, R.; ten Kate, R. W.; Veenendaal, D. (2010). "Aerococcus urinae: Severe and Fatal Bloodstream Infections and Endocarditis". *Journal of Clinical Microbiology* 48 (9): 3445–3447. doi:10.1128/JCM.00835-10. ISSN 0095-1137.
2. Skov, R. (2001). "In vitro antimicrobial susceptibility of Aerococcus urinae to 14 antibiotics, and time-kill curves for penicillin, gentamicin and vancomycin". *Journal of Antimicrobial Chemotherapy* 48(5): 653–658. doi:10.1093/jac/48.5.653. ISSN 14602091.
3. Schuur PM, Kasteren ME, Sabbe L, Vos MC, Janssens MM, Buiting AG (1997). "Urinary tract infections with Aerococcus urinae in the south of The Netherlands". *Eur. J. Clin. Microbiol. Infect. Dis.* 16 (12): 871–5. PMID 9495666.
4. "C-reactive protein". GPnotebook. Retrieved 2015-03-07.
5. 2730 Serum C-Reactive Protein values in Diabetics with Periodontal Disease A.R. Choudhury, and S. Rahman, Birdem, Diabetic Association of Bangladesh, Dhaka, Bangladesh. (the diabetics were not used to determine the reference ranges)
6. Reference range list from Uppsala University Hospital ("Laborationslista"). Artnr 40284 Sj74a. Issued on April 22, 2008
7. lymphomation.org > Tests & Imaging > Labs > Complete Blood Count Retrieved on May 14, 2009
8. Tympanic temperature for men, according to: Sund-Levander M, Forsberg C, Wahren LK (2002). "Normal oral, rectal, tympanic and axillary body temperature in adult men and women: a systematic literature review". *Scand J Caring Sci* 16 (2): 122–8. PMID 12000664