

Ultrasonography of a cervical pregnancy

Author: Jesper Agrell

Correspondence: jesper.agrell@lvn.se

Suggested citation format:

Agrell, Jesper (2014). "Ultrasonography of a cervical pregnancy". *Wikiversity Journal of Medicine* 1 (2).
doi:10.15347/wjm/2014.011. ISSN 20018762 .

First submitted:

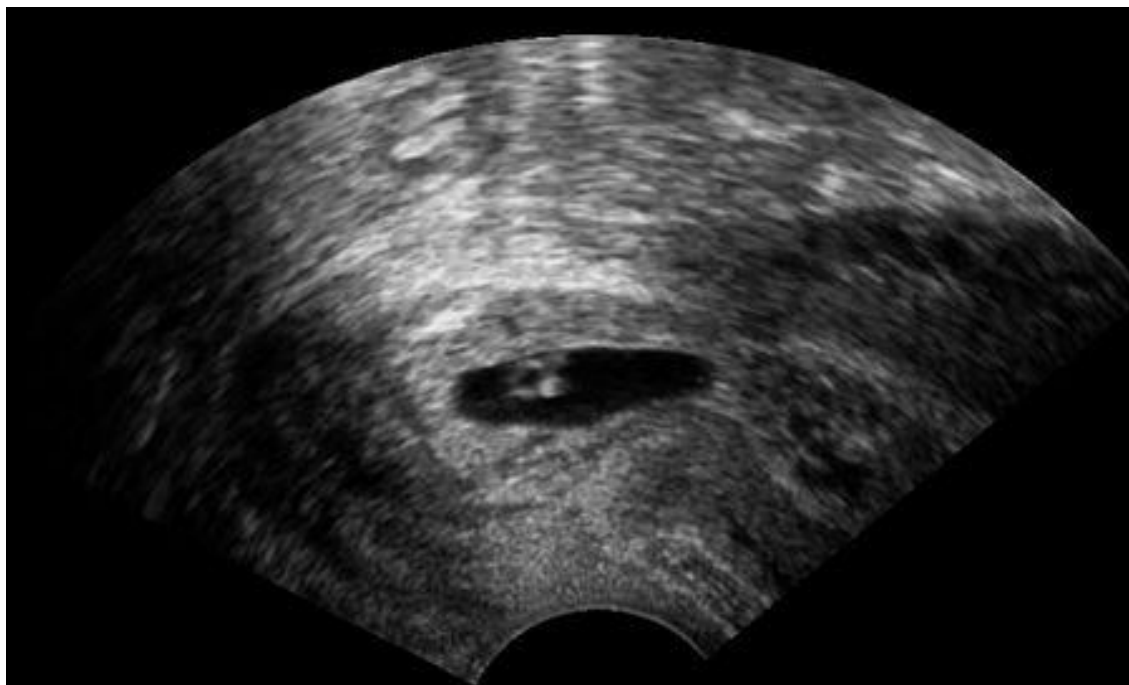
15 November 2014

Last updated:

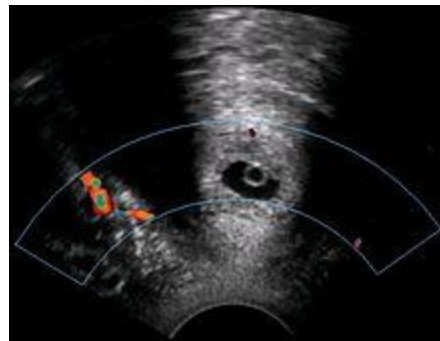
13 June 2015

Licensing:

This is an open access article distributed under the terms of the Creative Commons Attribution-ShareAlike License, which permits unrestricted use, distribution, and reproduction in any medium, provided the original author and source are credited.



A woman in her 20s came to the gynecologic clinic because of a positive pregnancy test and a history of a previous ectopic pregnancy. The vaginal ultrasonography performed by Dr. Jesper Agrell showed a gestational sac in the cervix as displayed in the sagittal plane. The corpus of the uterus is located at right in the image. There was a discernible heartbeat, and the gestational sac diameter corresponded to a gestational age of 5 weeks. The distance from the gestational sac to the external orifice was only 15 millimeters.



Trans-section of the cervix with Doppler ultrasonography, showing that the pregnancy (center) is at the same level as the uterine artery (giving a colored pattern to the right on doppler).